

Benign tumors

Classification

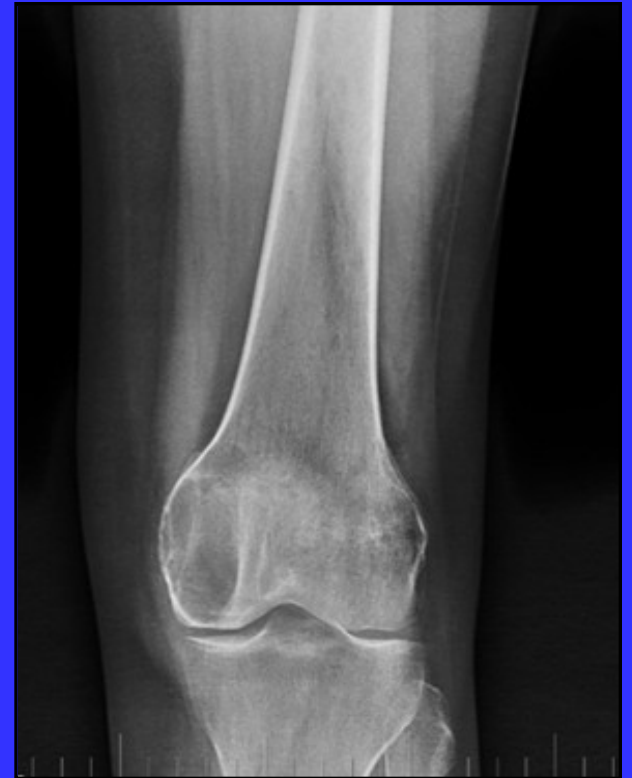- **Bone tissue** (osteoma, osteoid osteoma, osteoblastoma)
- **Cartilage tissue** (chondroma, osteochondroma, chondroblastoma, chondromyxoid fibroma)
- **Fibrous tissue** (fibroma, fibrous histiocytoma)
- **Vascular tissue** (hemangioma, glomus tumor, hemangiopericytoma)
- **Adipous tissue** (lipoma)
- **Giant cell tumor** – osteoclastoma
- **Benign soft tissue tumors**

Surgical staging system (Enneking)

- Grade 1 – latent (G0, T0, M0)
- Grade 2 – active (G0, T0,M0)
- Grade 3 – aggressive (G0, T1-2, M0-1)

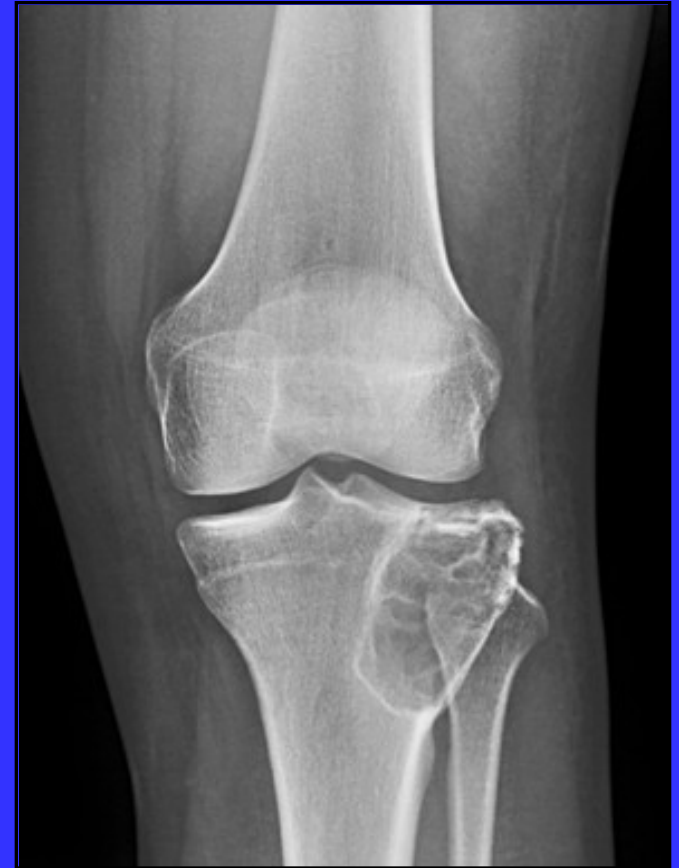Grade 1 - latent

- No symptoms
- Scintigraphy- minimal finding
- angiography – negative
- CT – sharp edges



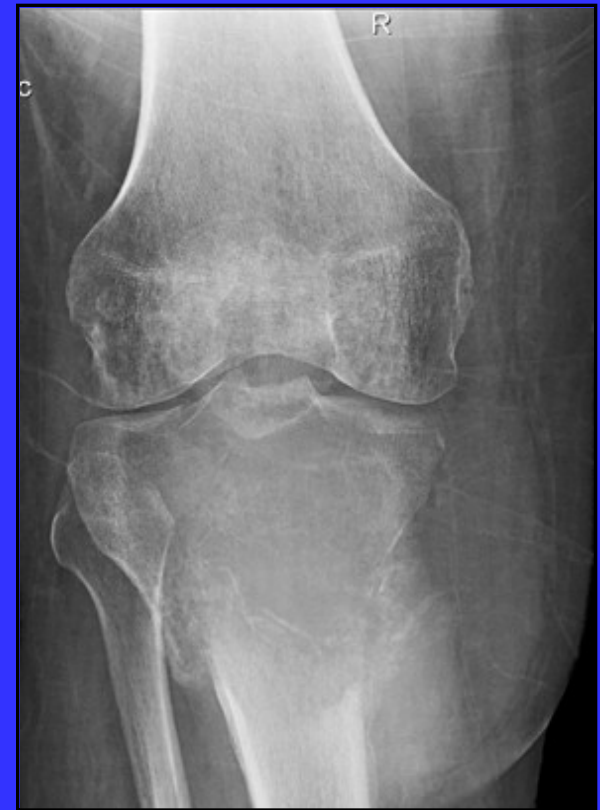Grade 2 - active

- Slight symptoms
- Scintigraphy – positive
- Angiography
 - mild neovascular reaction
- CT – mild expansion



Grade 3 - aggressive

- Pain, advanced symptoms
- Scintigraphy – positive
- Angiography –
- advanced neovascular reaction
- CT – extracompartmental expansion

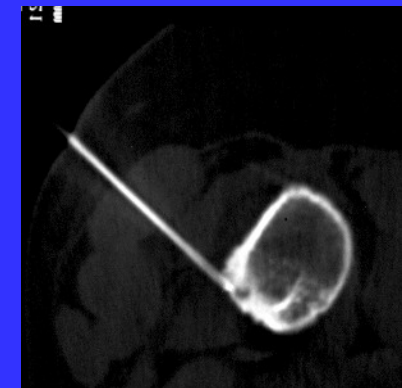
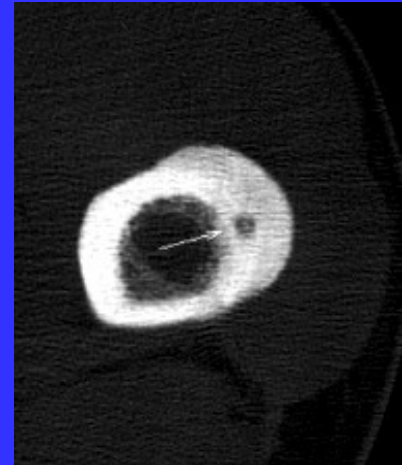
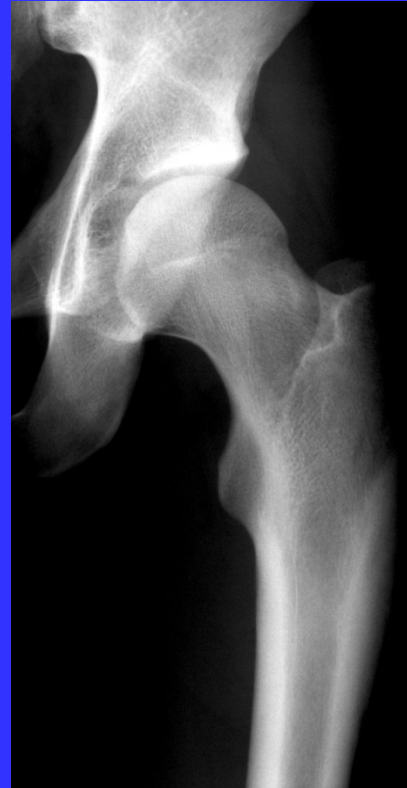

Benign bone tumors

- osteoid osteoma
- osteoblastoma
- chondroblastoma
- chondromyxoid fibroma
- osteoclastoma
- fibroma
- osteochondroma
- chondroma

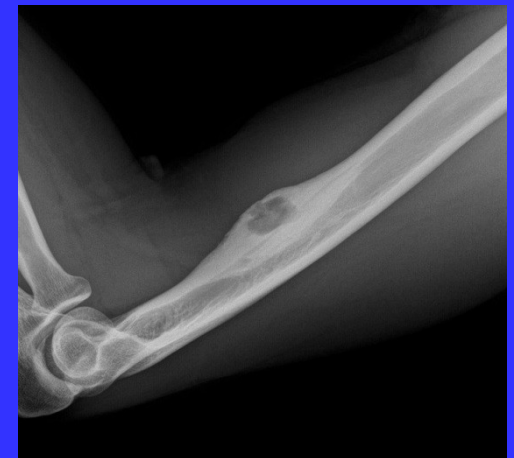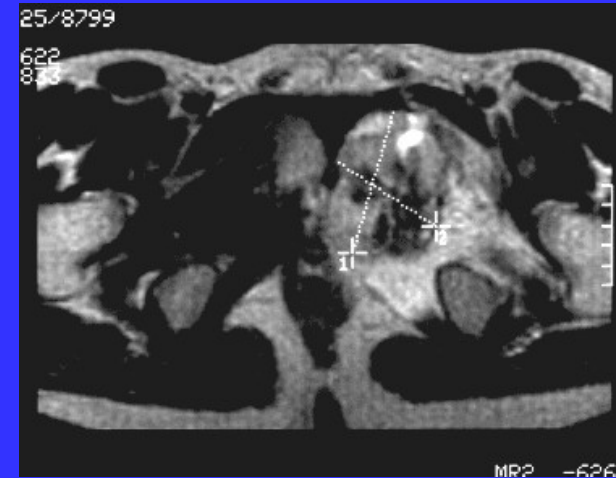
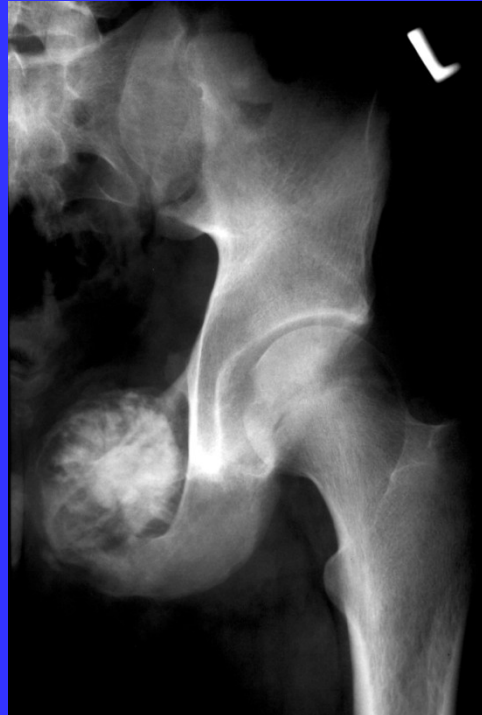Osteoid osteoma

- 5 – 25 years
- femur, tibia, spine
- solitary
- pain
- nidus – osteoid tissue
- diff.dg.:
osteoblastoma,
osteomyelitis
- Surgery, RFA



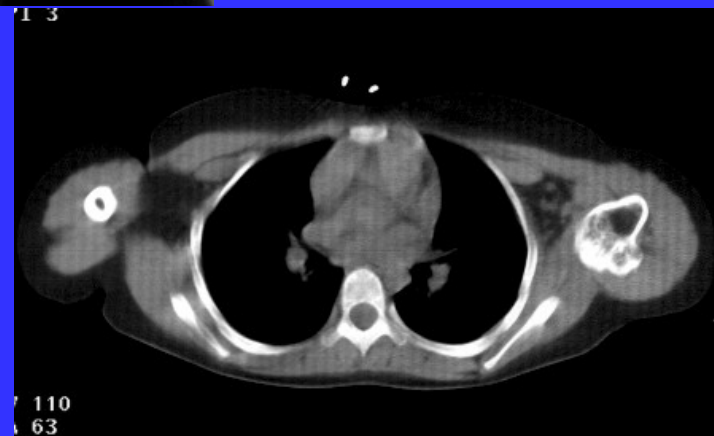
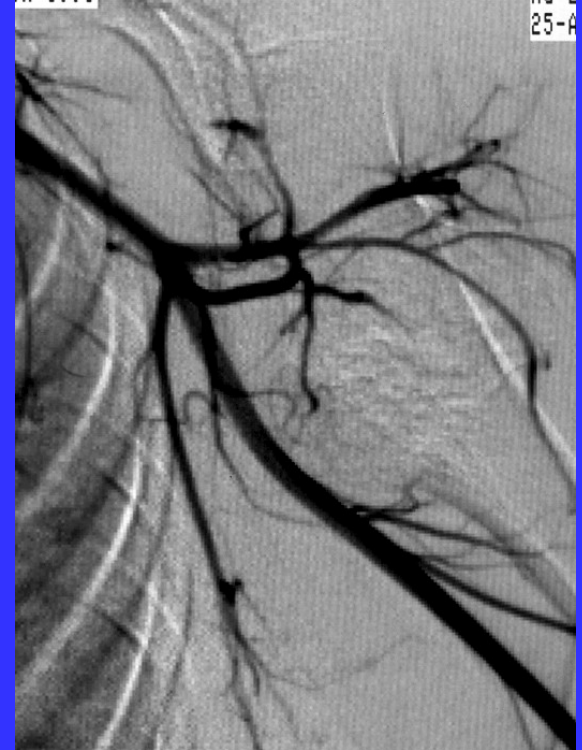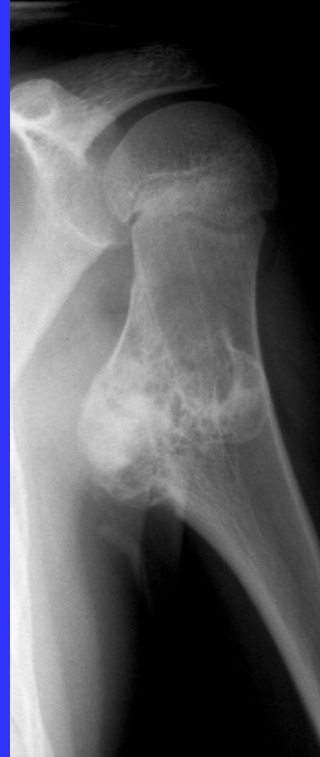Osteoblastoma

- 10-20 let
- Spine, long bones
- Pain, neurological symptoms
- Greater nidus, calcifications, expansion into soft tissue
- Local aggressive
- diff.dg.: osteoid osteom, osteosarcoma
- Resection



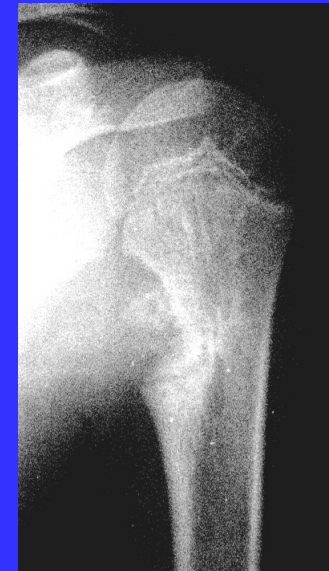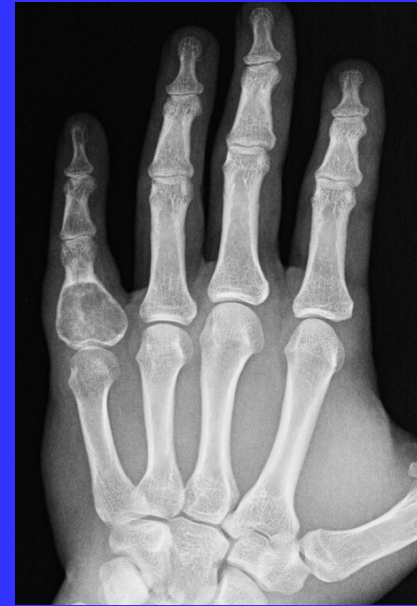Osteochondroma

- Up to 20 years
- metaphysis
- swelling
- Exostosis disease – autosomal dominant
- USG- 10 mm chondral layer –
- Malignisation – chondral lesion over 20 mm, or progression
- diff.dg.: parostal OSA, Chondrosarcoma
- Th- following
- Th- ablation



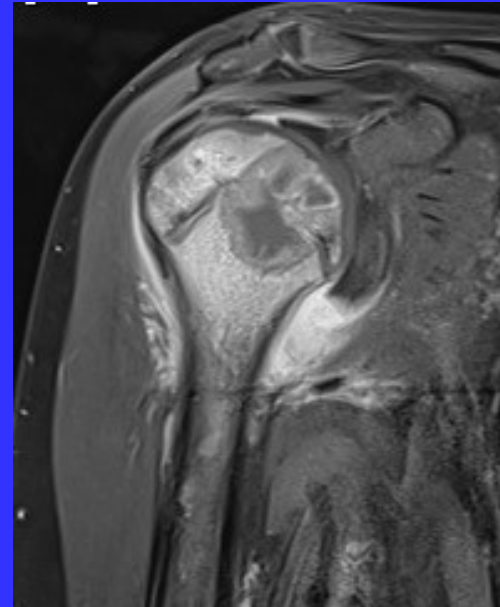
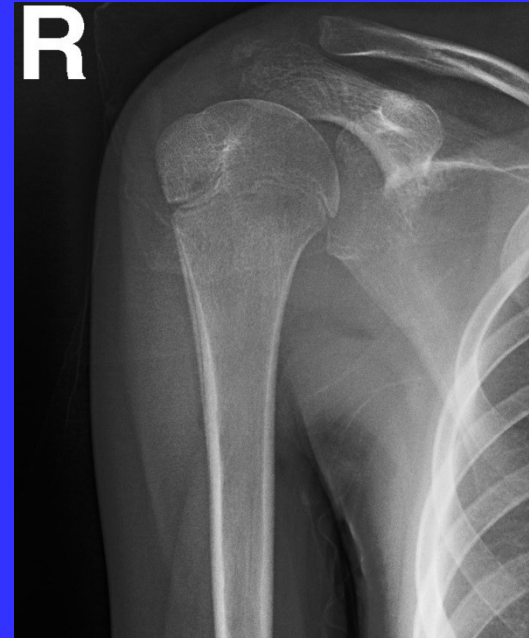
Chondroma

- 10-50 years
- Short bones
- central, periosteal, juxtacortical
- swelling
- Enchondromatosis (Ollier), + hemangioma (Mafucci)
- Malignisation
- diff.dg.: Chondrosarcoma
- Th.- following curretage, resection



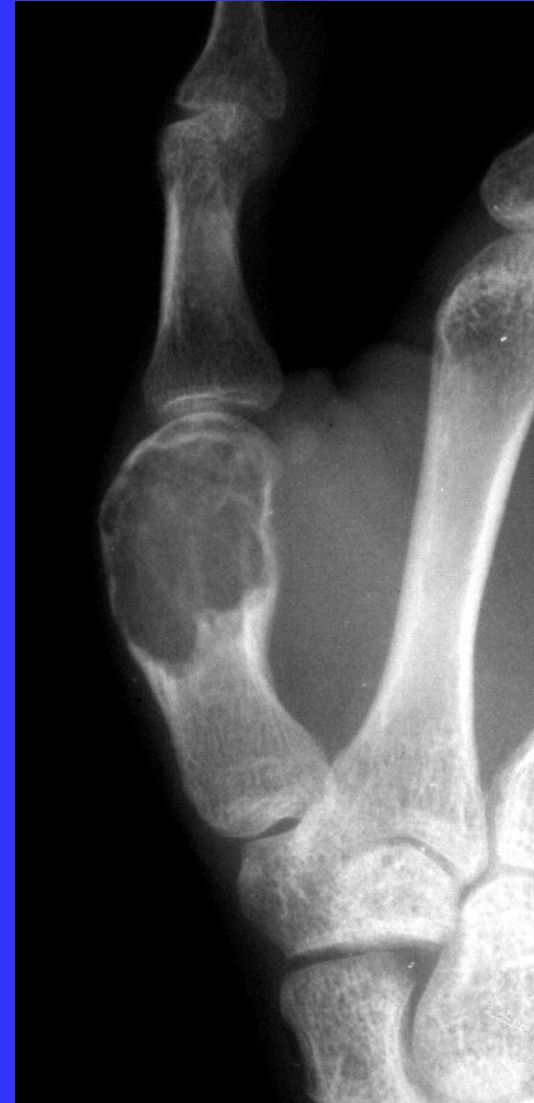Chondroblastoma

- 5-25 years
- Epiphysis, metaphysis
- solitary
- Pain, synovitis
- recurrence
- diff.dg.
Osteoclastoma,.
chondrosarcoma
- Curettage + bone
grafting, resection



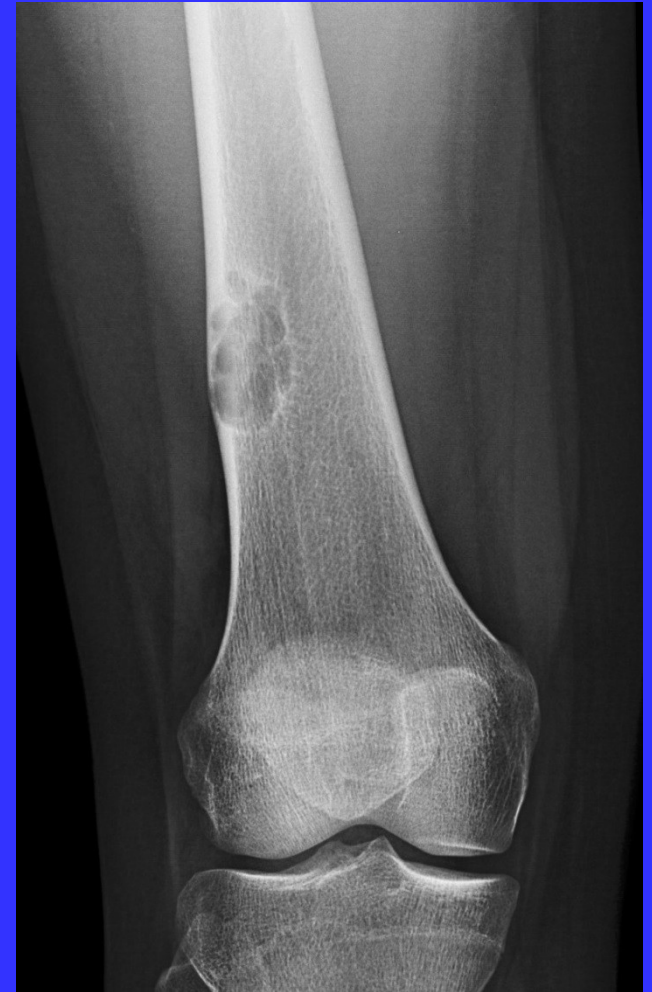Chondromyxoid fibroma

- metadiaphysis
- young adults
- solitary
- pain
- diff.dg.
chondroblastoma,
osteoclastoma,
chondrosarcoma
- resection, curettage



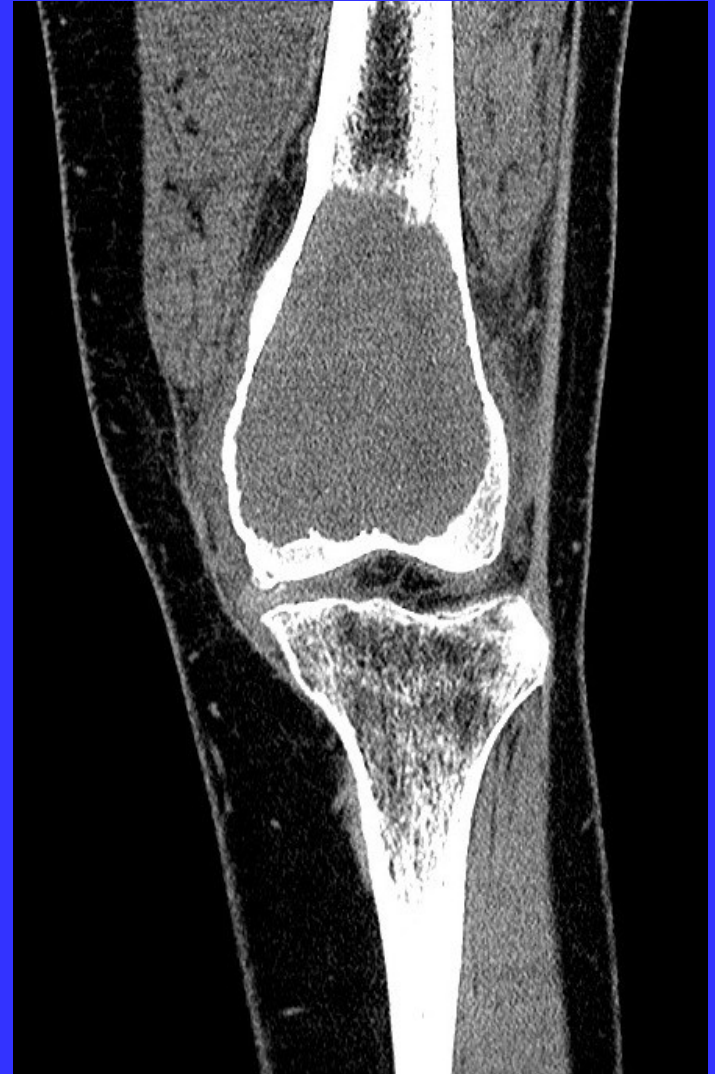Nonossifying fibroma

- In young adults
- Metaphysis of long bones
- solitary
- asymptomatic or aggressive expandig
- diff.dg. : eosinofilic granuloma, giant cell tumor
- Following curretage + grafting



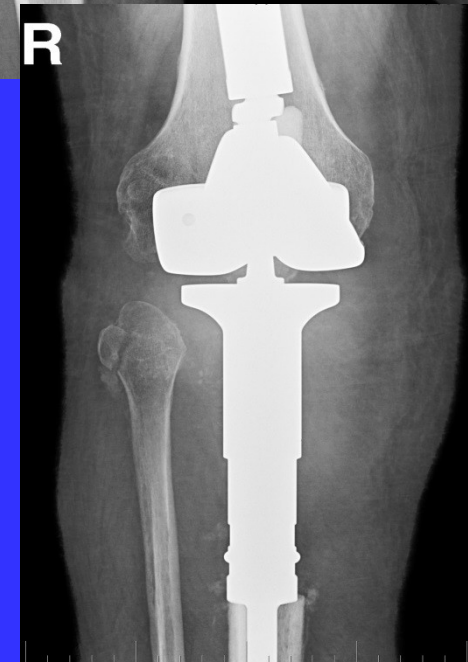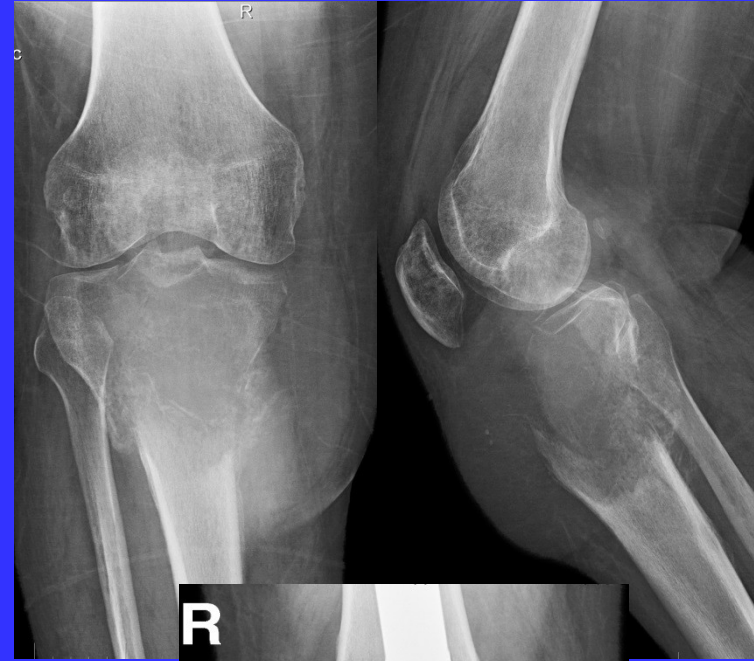Giant cell tumor - osteoclastoma

- 15-50 years
- Epimetaphysis, femur, tibia
- solitary
- Pain, swelling, fracture
- Benigne type
- Malignant type
- diff. dg.: aneurysmatal bone cyst, HPT



Giant cell tumor

- X ray, CT, MR, scintigraphy
 - CT of the lungs
 - Curettage + (fenolum, ethanolum, argon)
+ grafting + bone cement
- III. grade: denosumab +
resection + endoprosthesis

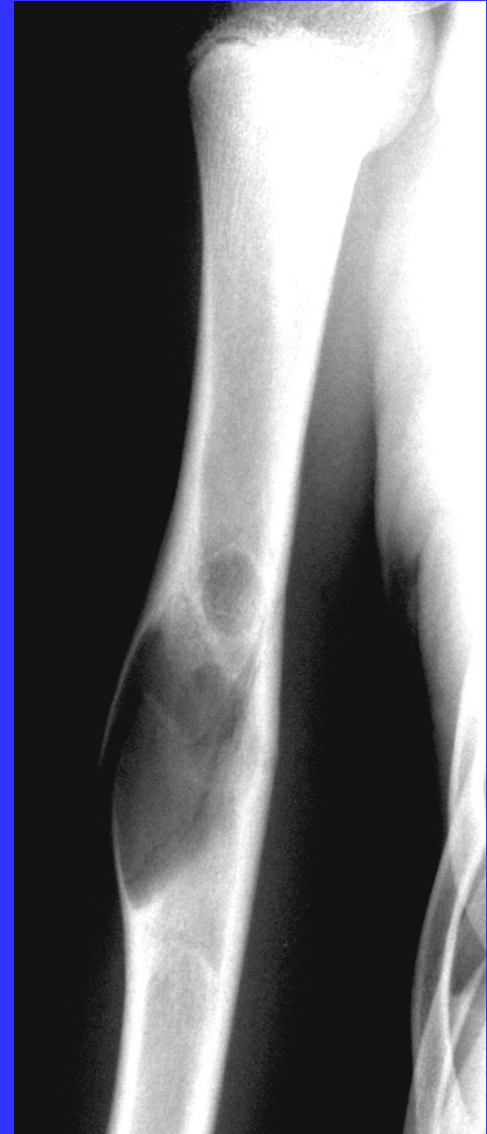

Tumor like lesions

- Juvenile bone cyst
- Aneurysmatal bone cyst
- Fibrous bone dysplasia
- Eosinofilic granuloma
- myositis ossificans
- Intraosseous gangliona
- hyperparathyroidism
- desmoid
- others

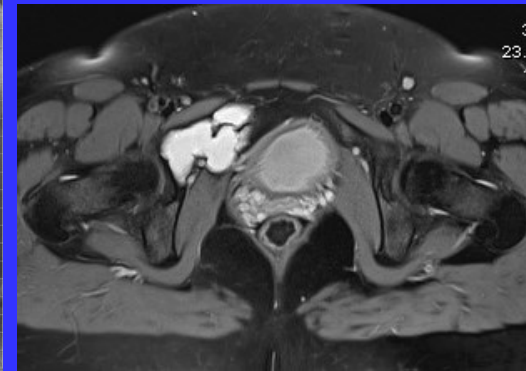
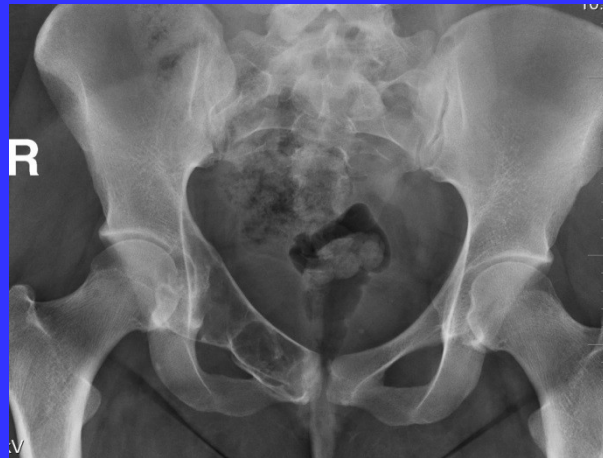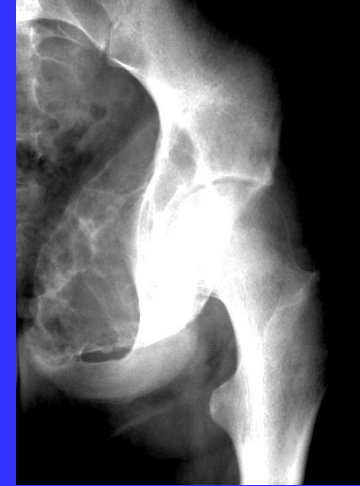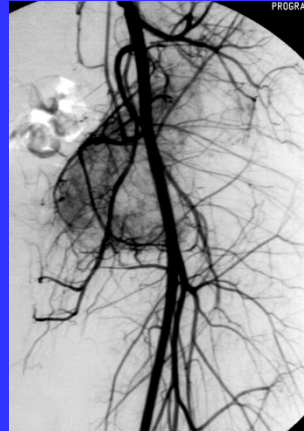
Juvenile bone cyst

- In children
- humerus, femur
- No symptoms, pathological fracture
- X-ray- cystic lesion
- diff. dg: aneurysmatal bone cysts, eosinophilic granuloma
- Spontaneous healing
- Curettage + bone grafts
- Local corticoids
- Autologous bone marrow
- Healing after a fracture



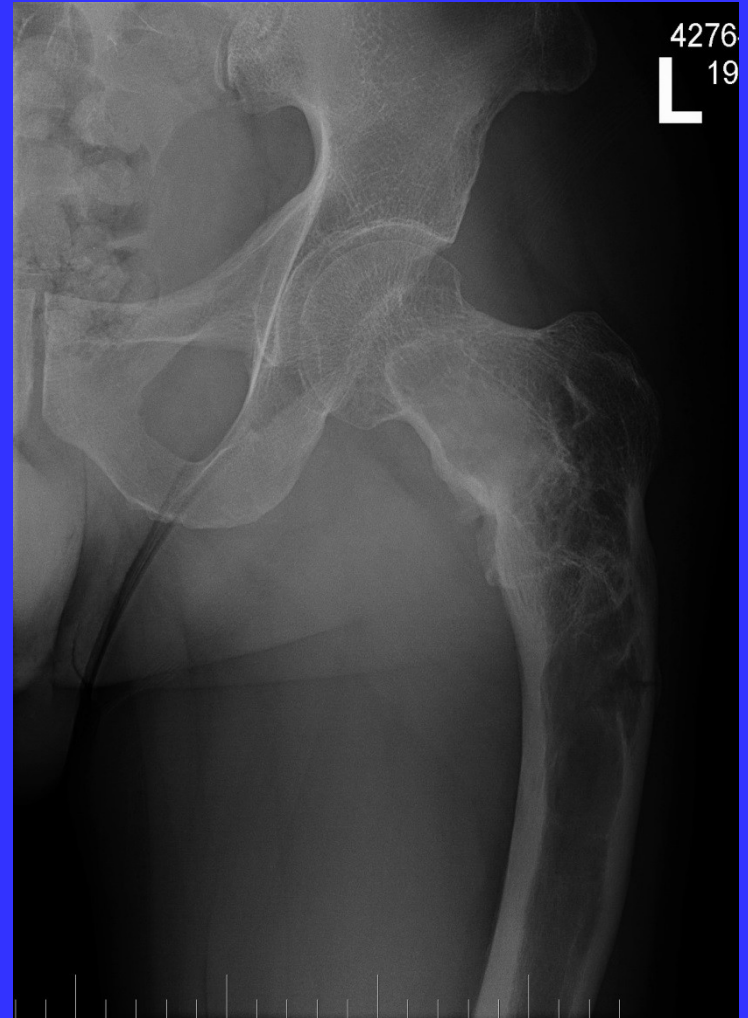
Aneurysmatal bone cyst

- 5-30 years
- Every bone
- Pain, swelling
- Content – haemoragic fluid
- Diff. dg. osteosarcoma
- Resection, curretage + fenolisation + bone cement
- Embolisation, radiotherapy



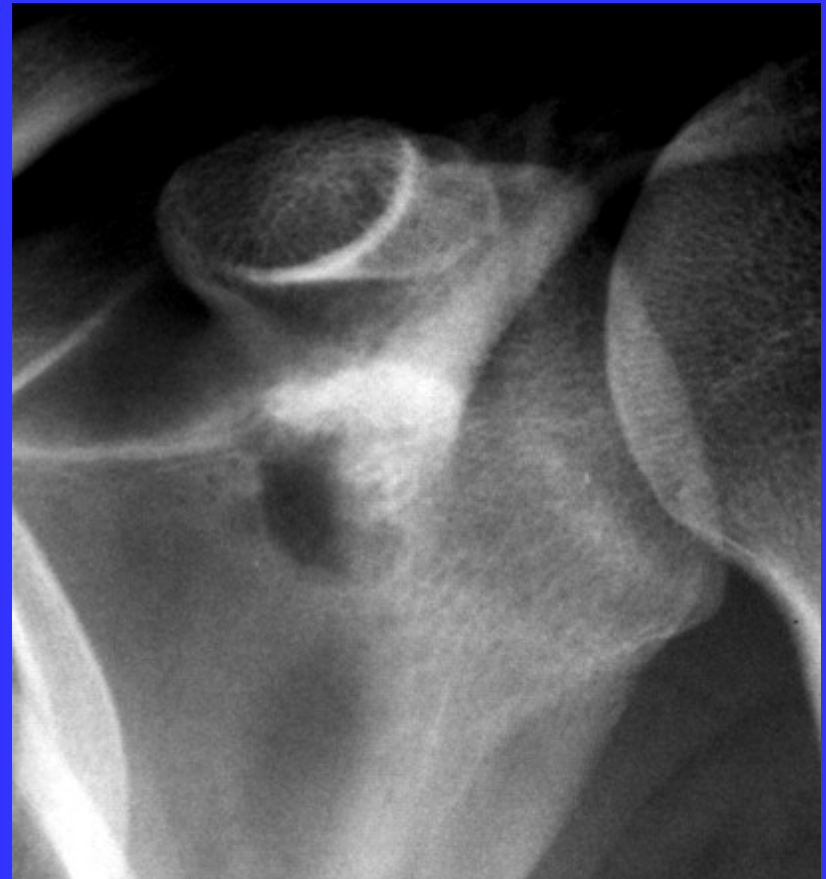Fibrous dysplasia

- Young adults
- Mono and polyostotic
- Deformity of the bone
- X ray, CT scann
- diff. dg.: bone cyst, osteosarcoma
- malignisation (1%)
- Follow up, curretage, bone grafting



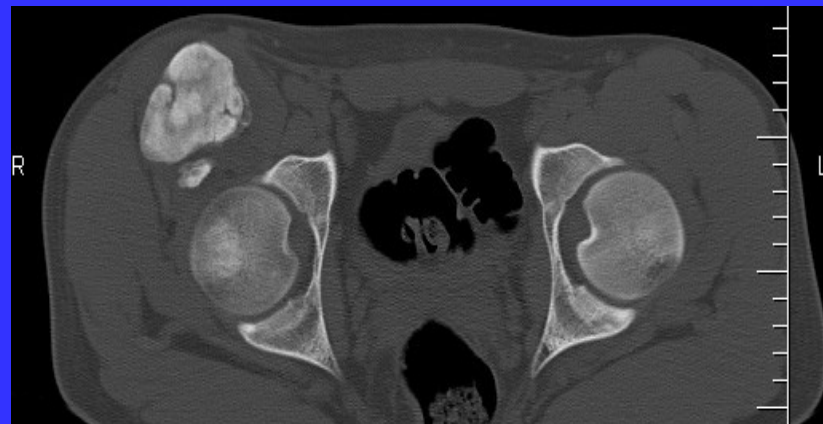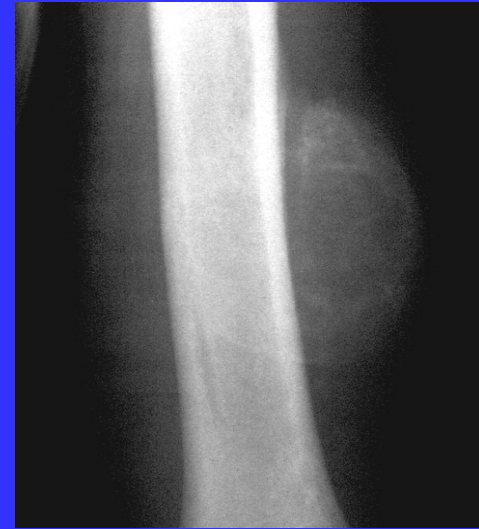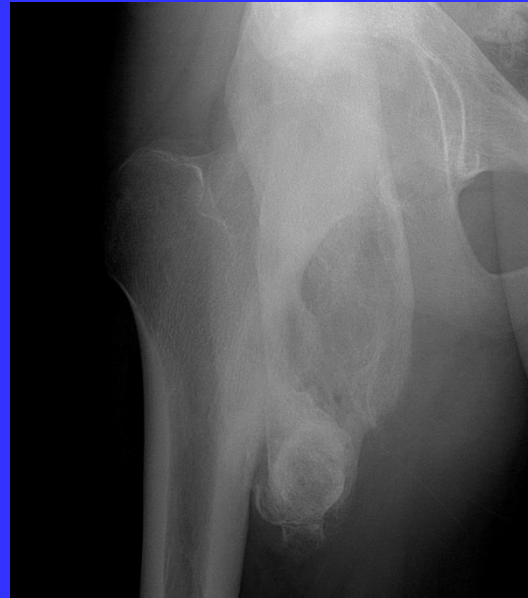Eosinophilic granuloma

- Up to do 20 years
- Skull, ribs, femur
- Solitary or polyostotic
- histiocytosis X (Letterer-Siwe, Hand-Schüller-Christian)
- Mild pain, swelling
- Diff. Dg. : Ewing sarcoma, osteomyelitis
- Self limiting process
- Following, curretage



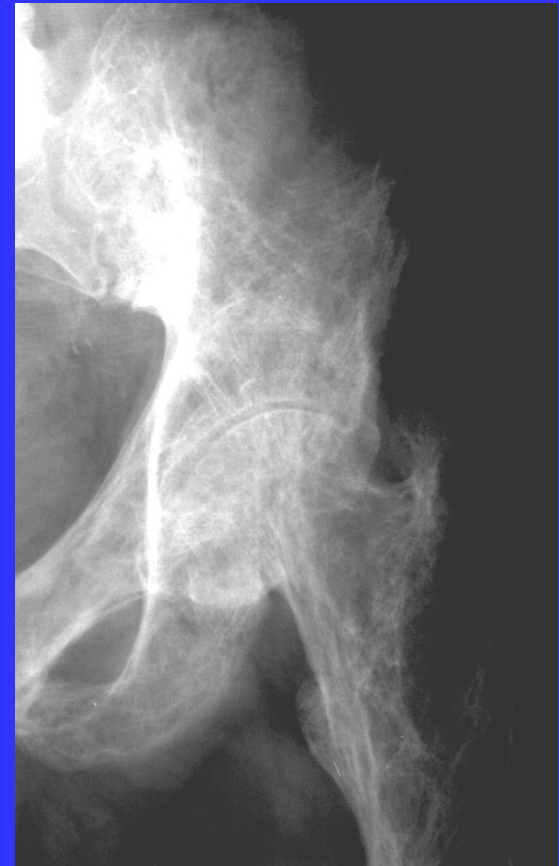Myositis ossificans

- Any age
- trauma, idiopathic, head injury
- Soft tissue along bones
- Swelling, limited movement
- X-ray finding, zonal features
- diff. dg.: OSA
- Following, resection



Paget's disease of bone

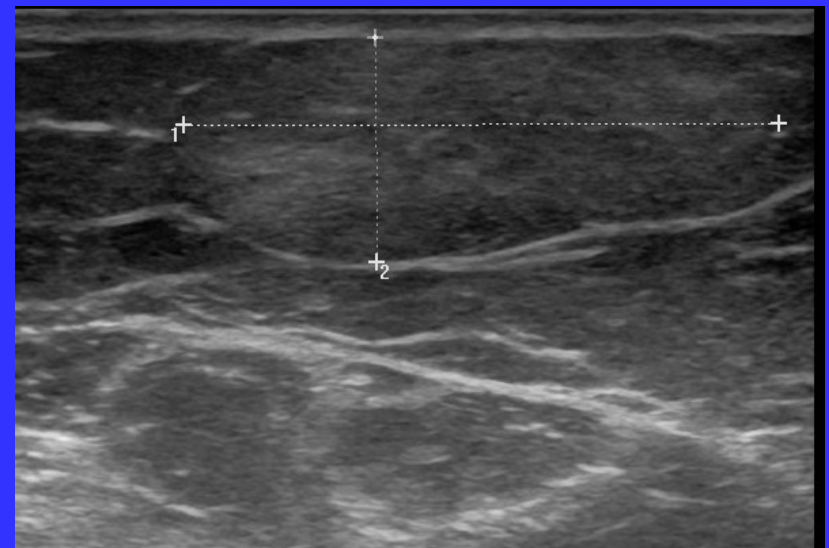
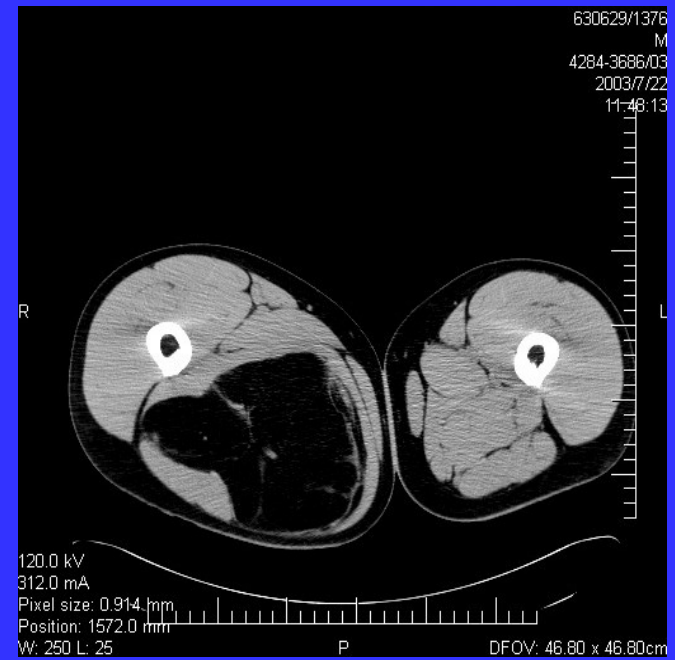
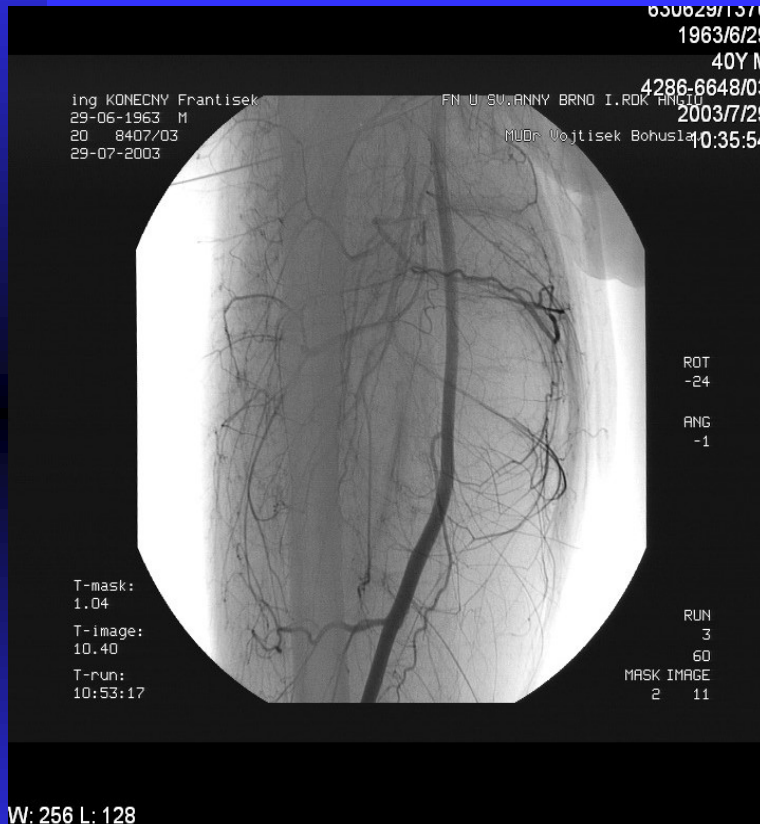- Higher age
- Coarse trabeculae
- Osteolytic, mixed , osteoblastic phase
- Monoostotic, polyostotic form
- Pain, deformity, fracture, O.A.
- Malignisation (OSA, chondrosarcoma ...)
- Following, bisphosphonates, calcitonin, surgery



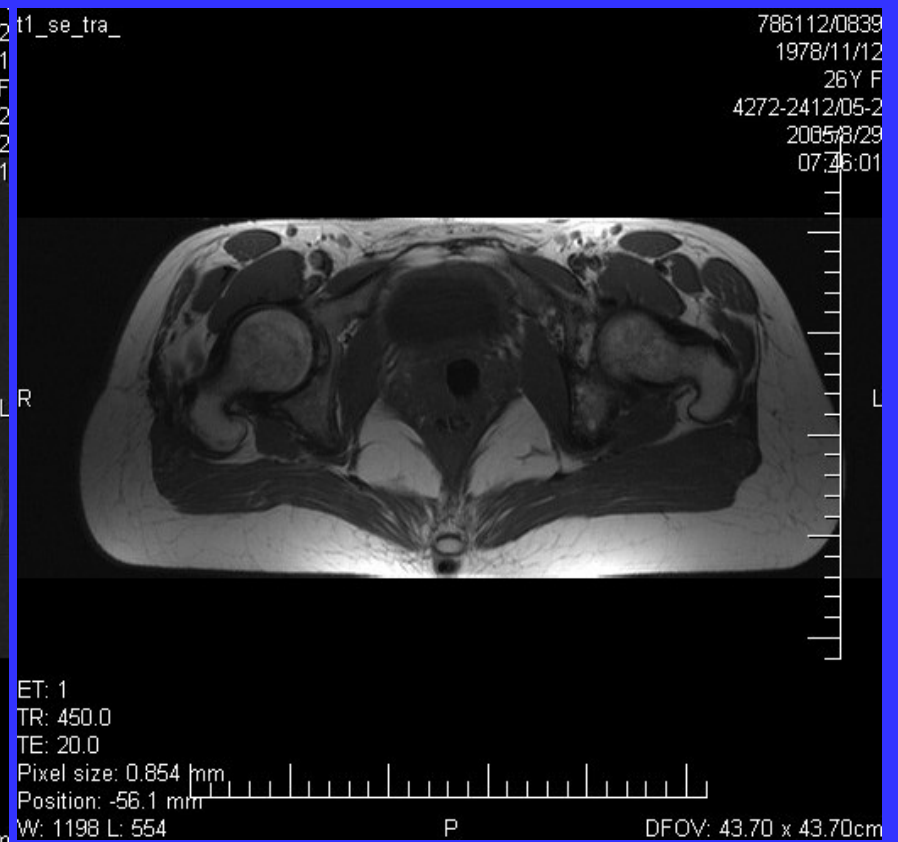
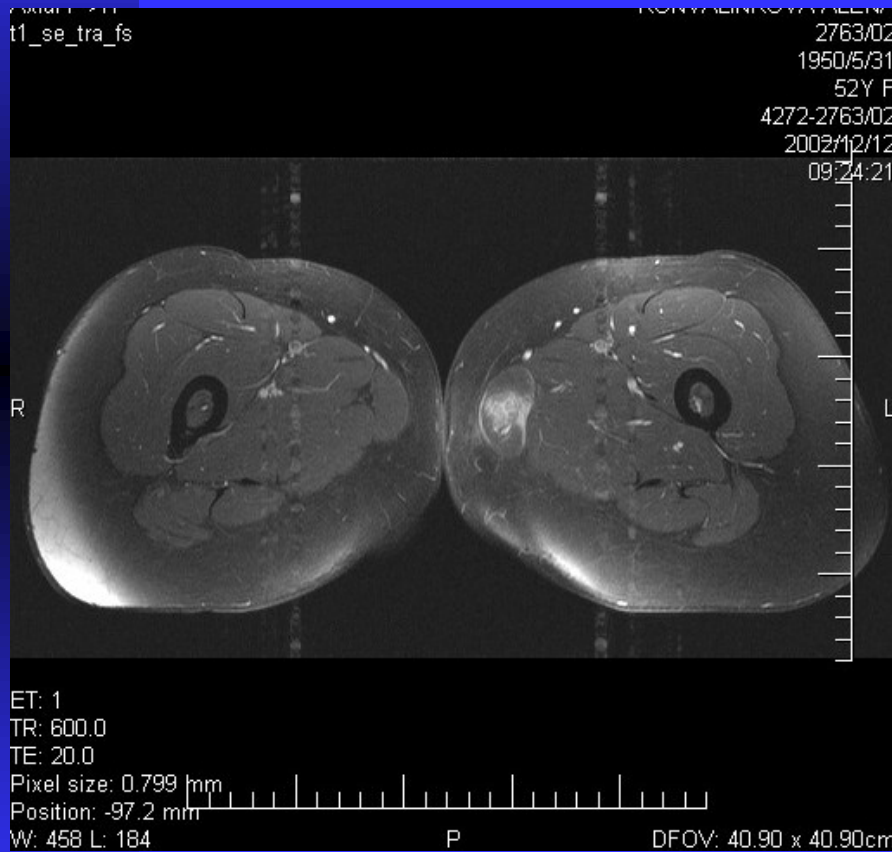
Benign soft tissue tumors

- Lipoma
- Fibrolipoma
- Desmoid
- Synovial chondromatosis
- Haemangioma
- Others

Lipoma

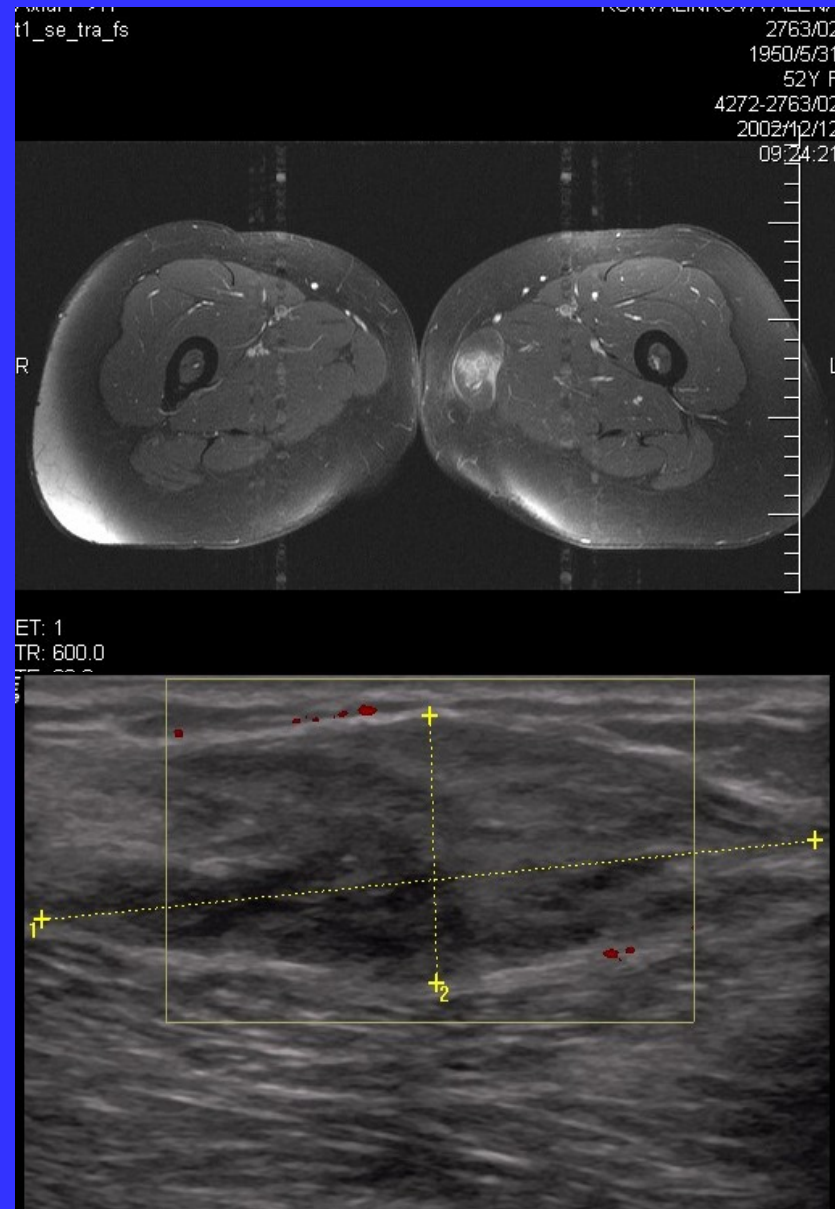


Desmoid

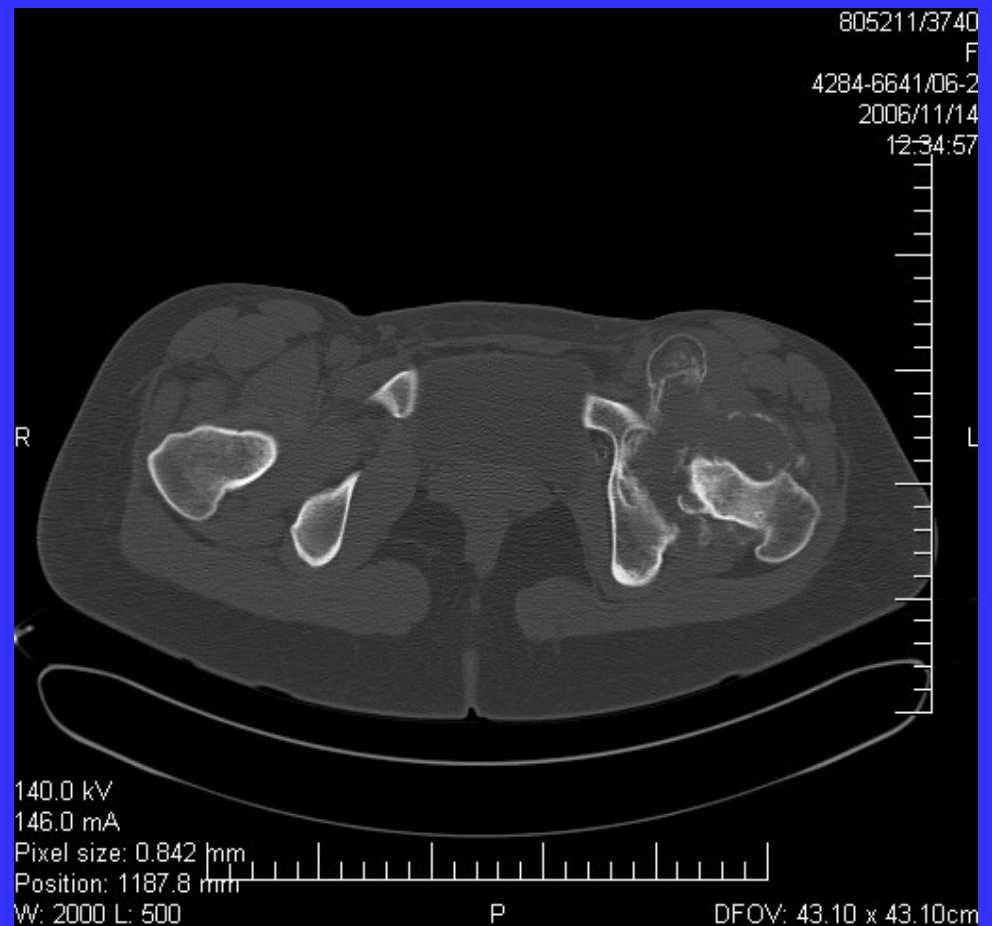
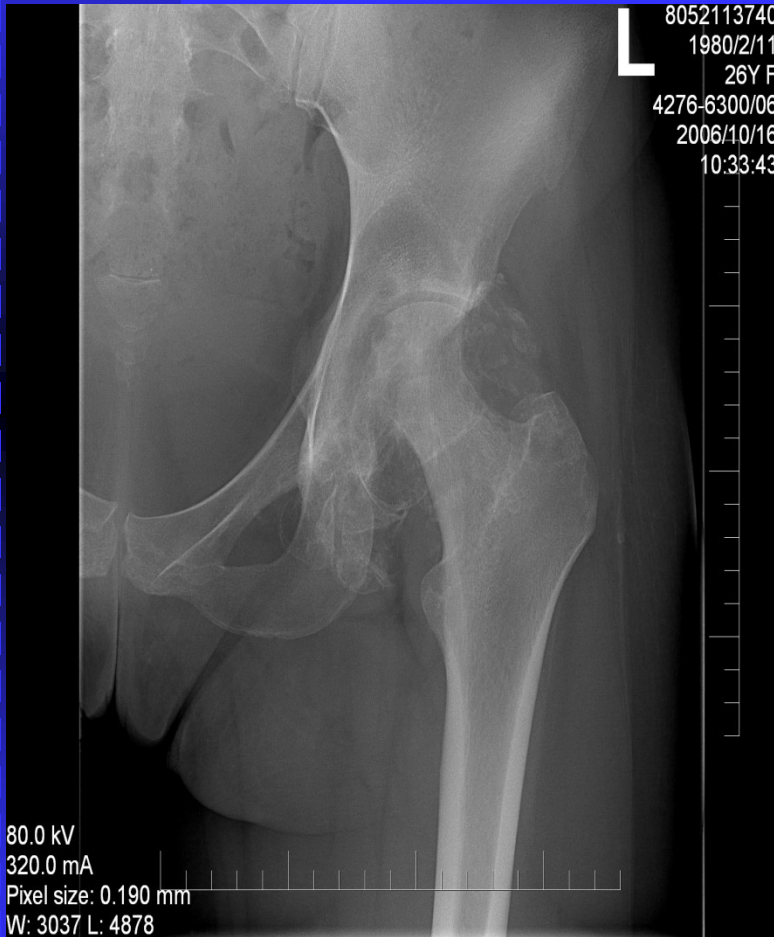

Desmoid

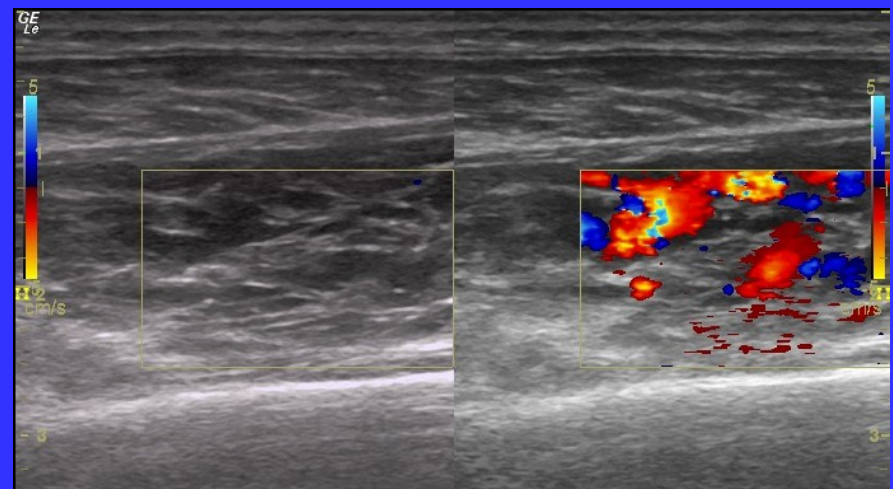
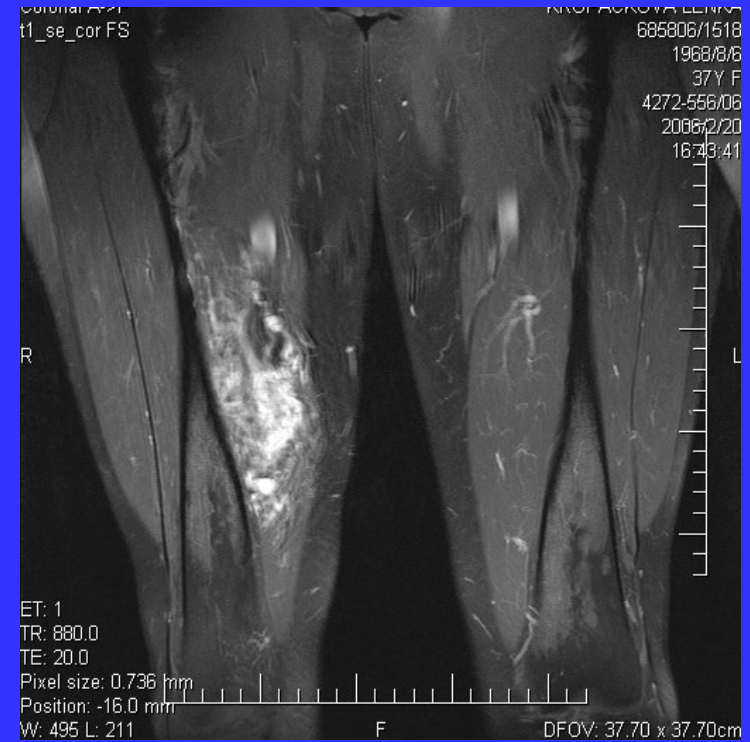
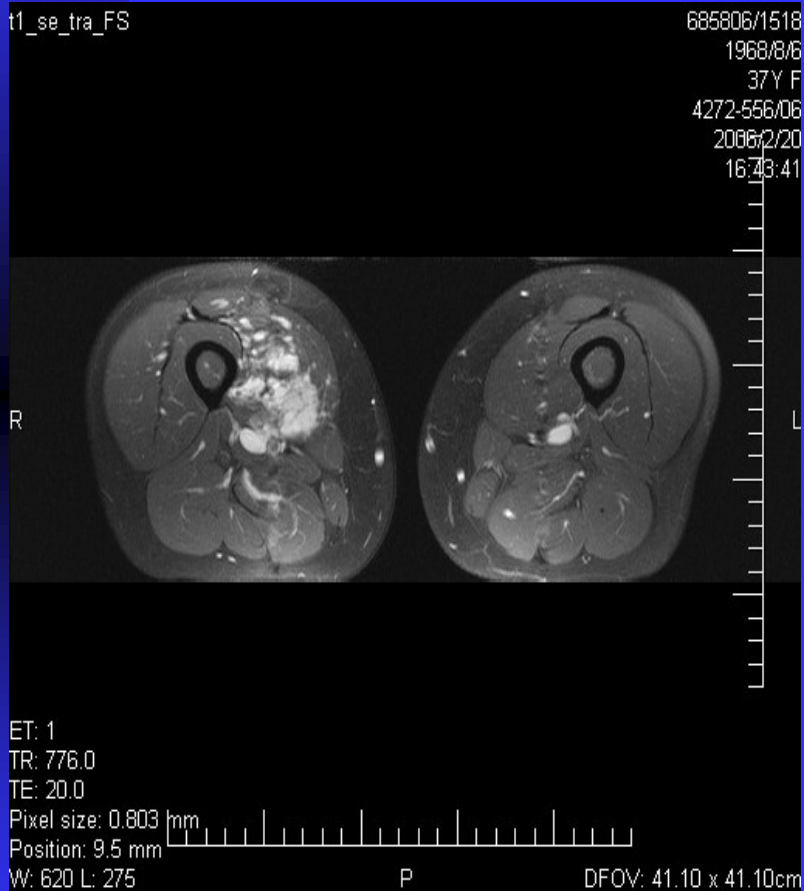
- 15 – 40 let
- hluboko uložený
- infiltrativní růst
- častý výskyt lokálních recidiv
- Sono, MR
- diff. dg. Fibrosarkom
- Th.: sledování, biologická léčba, nízkodávkovaná chemoterapie, široká resekce pokud je možná



Synovial chondromatosis

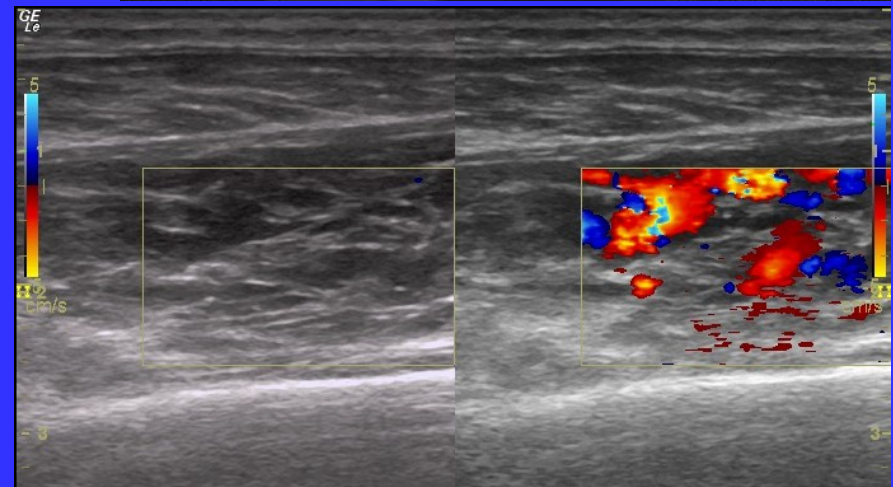
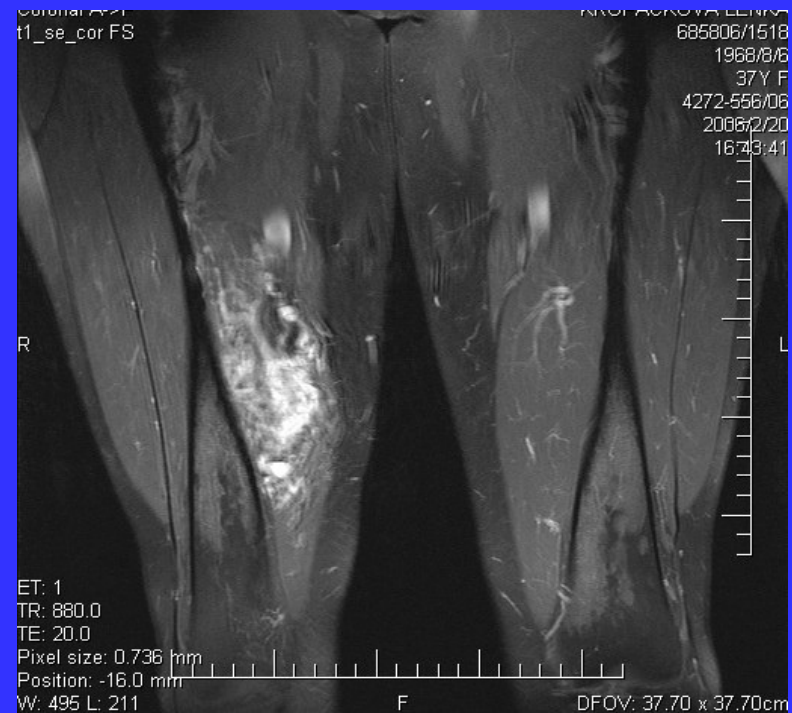


Haemangioma



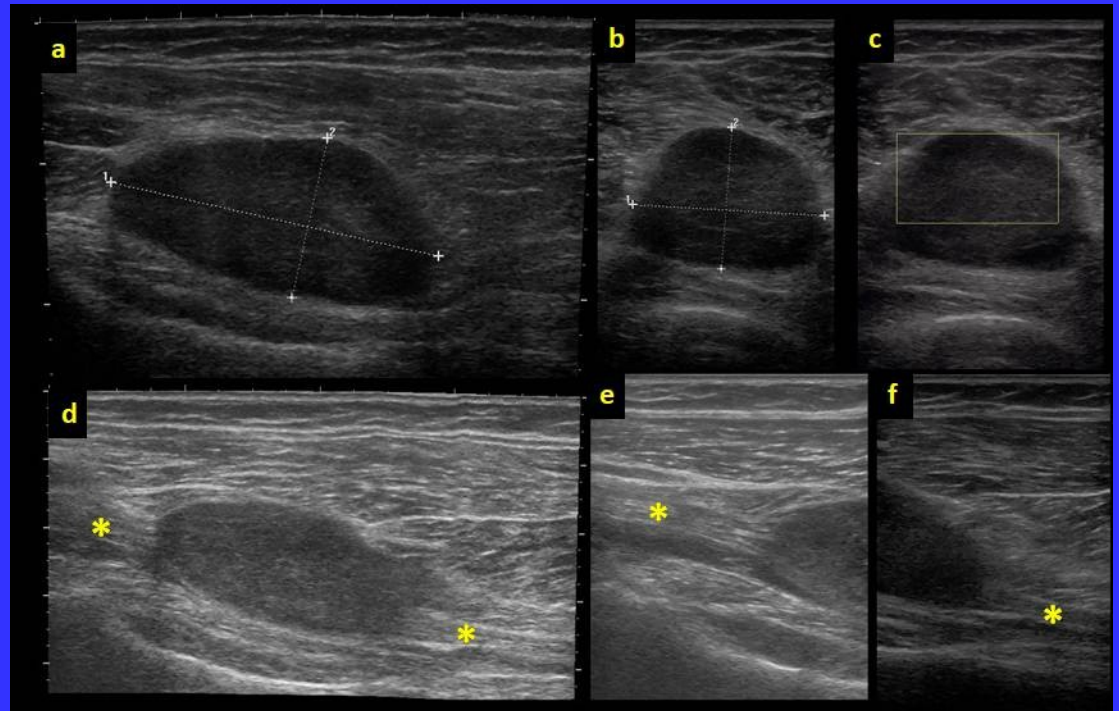
Hemangiom

- do 30 let
- intramuskulární
- oblast stehna
- bolestivá rezistence
- Sono, MR, angiografie
- sledování, embolizace, extirpace



Schwannoma

- tuhý, dobře ohraničený
- pomalu rostoucí, palpačně bolestivá rezistence
- lok. útlak, iritace nervu
- Sono, MR
- Th.: extirpace



Intraosseous ganglion

- 20-60 years
- No symptoms, mild pain
- Diff. dg:
chondroblastoma,
enchondroma
- Following, curretage

