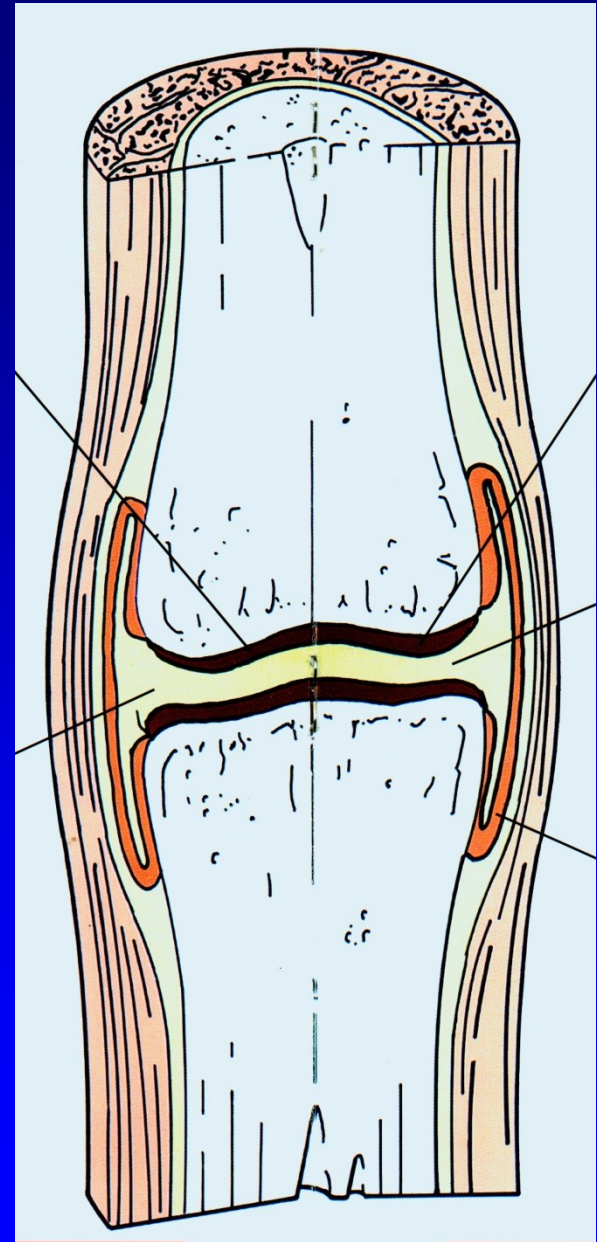


Osteoarthritis

Z. Rozkydal

Synovial joint

The end of bones
Hyaline cartilage
Ligaments
Joint capsule
Synovial membrane
Synovial fluid



Hyaline cartilage

Chondrocytes

Matrix – intercellular mass:

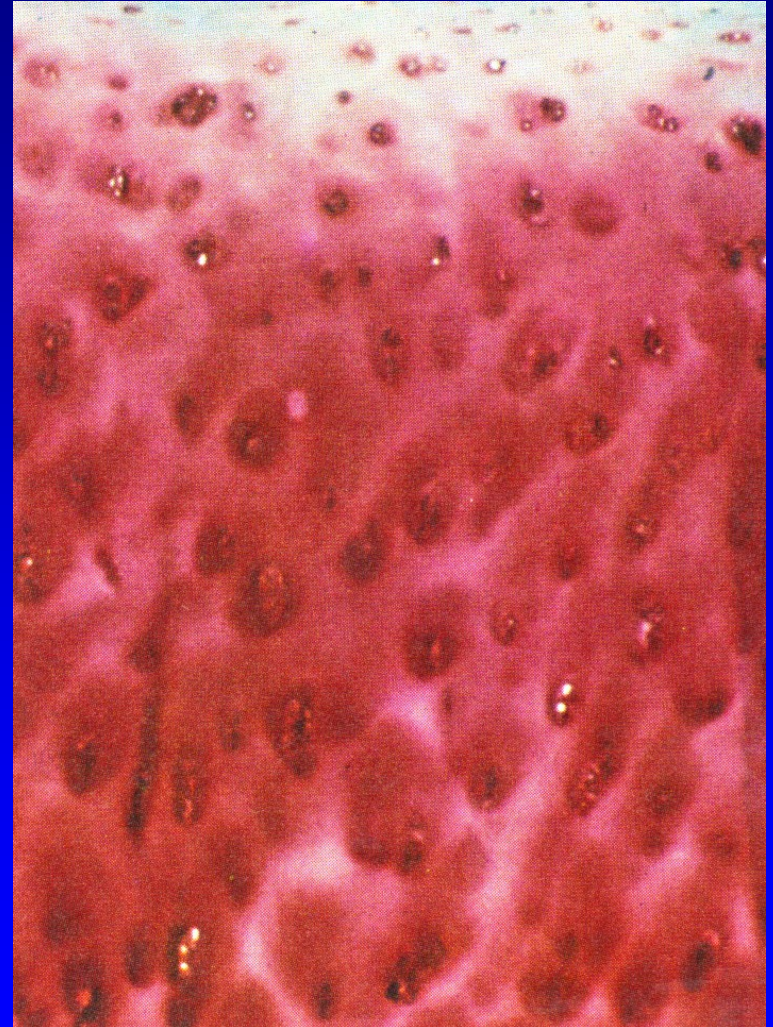
Fibrillar structure - collagen

Proteoglycans

Proteins of noncollagen nature

Hyaluronic acid

Water – 70 volume percent




Hyaline cartilage

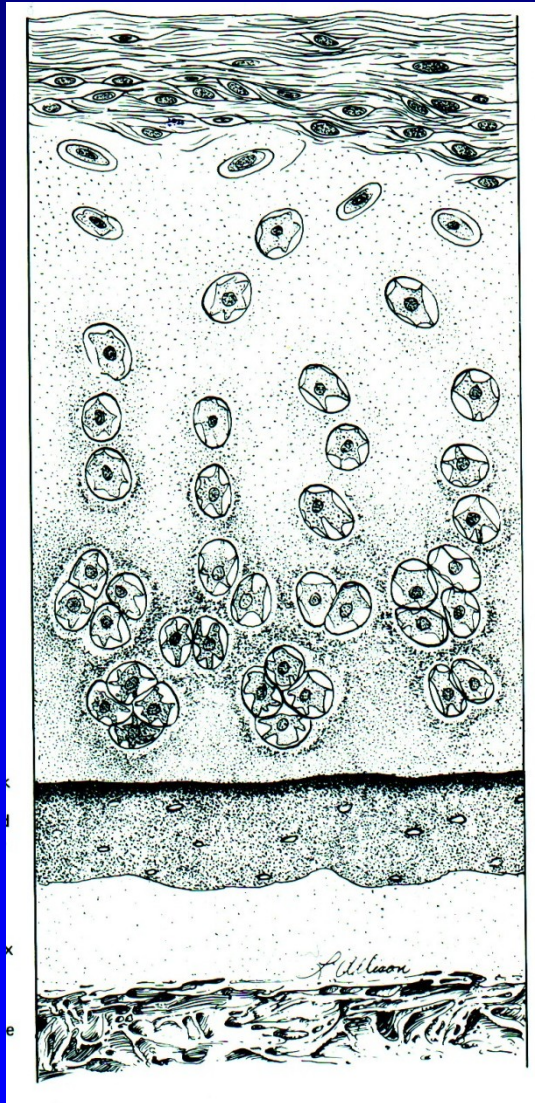
Chondrocytes- 2 percent of volume

Localised in lacunes of matrix

Isogenetic groups 2-8 cells
from one mother cell



Hyaline cartilage - layers



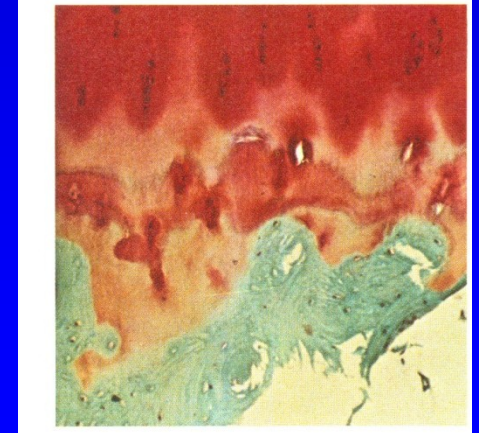
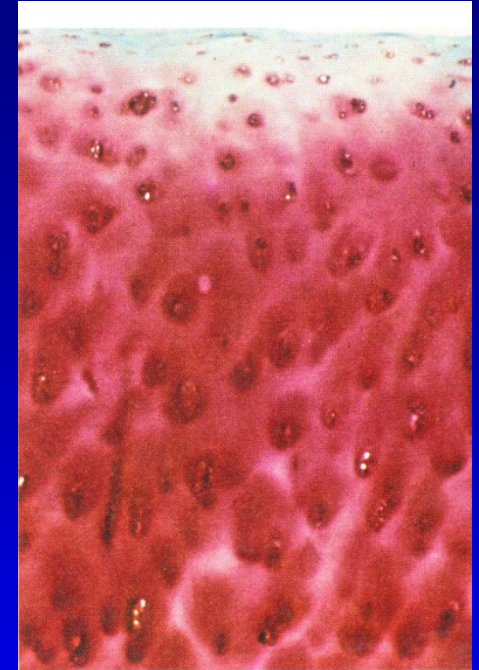
Superficial

Middle

Deep

Zone of calcifying
cartilage

Bone



Collagen

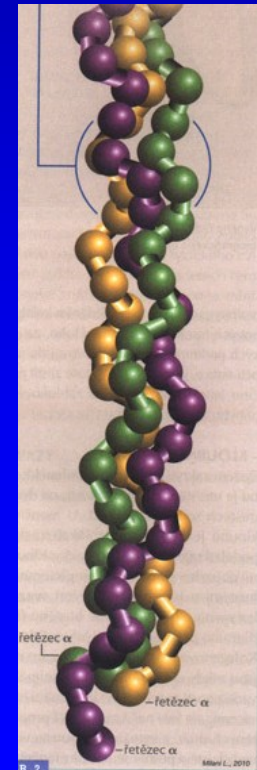
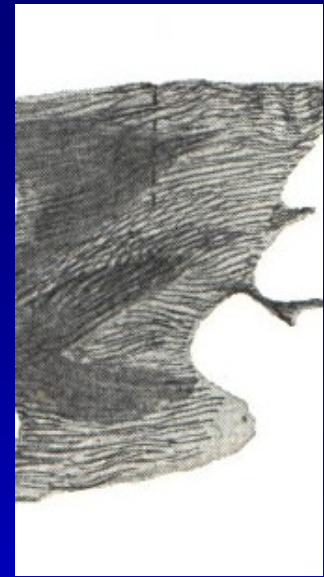
Collagen type II (3 alpha-1 chains- 90 %)

Chains form fibrils

Fibrils form a three dimensional network

Parallel to the surface

In deep layers in columns



Proteoglycans- PG

They are high hydrophylic
- elasticity !!

Large PG - glukosaminoglycans:

Chondroitin 6- sulfate

Keratansulfate

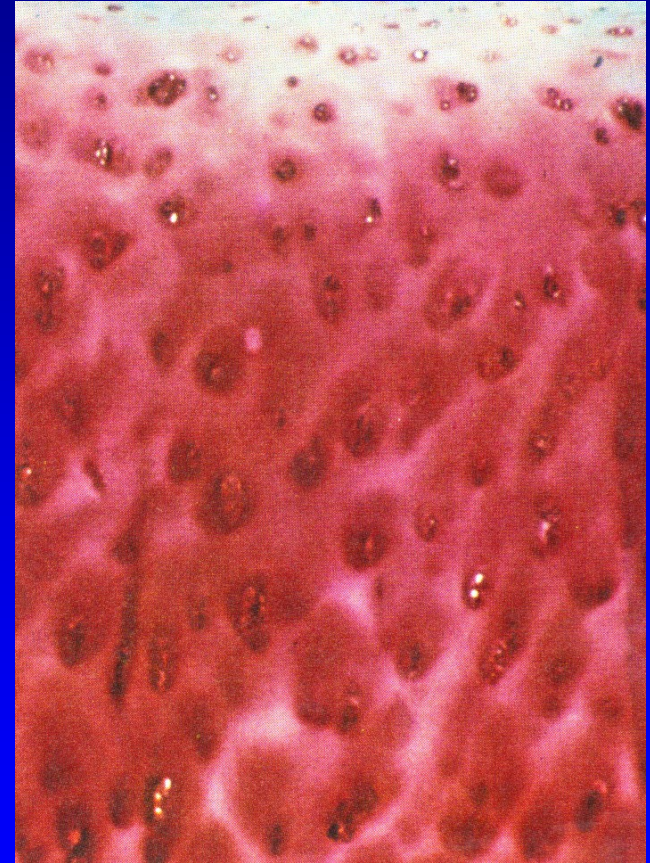
Chondroitin 4- sulfate

Small PG:

Decorin, biglycan

Agrecan – binds on hyaluronic acid

Sulfatan glukosaminoglycan



Noncollagen proteins

Fibronectin, chondronectin

Anchorin

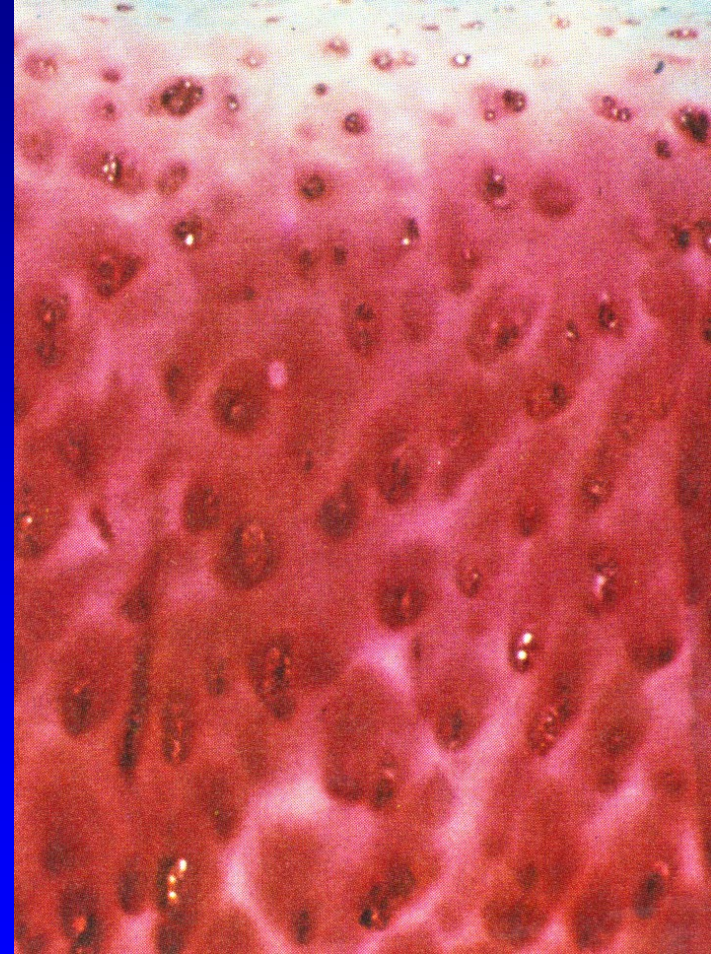
Cytocins- interleukin-1, interleukin- 6

Enzymes – metalloproteinase

(kolagenase, gelatinase)

Growth factors

Prostaglandins



Hyaluronic acid- HA

Hydrophylic, maintains homeostasis

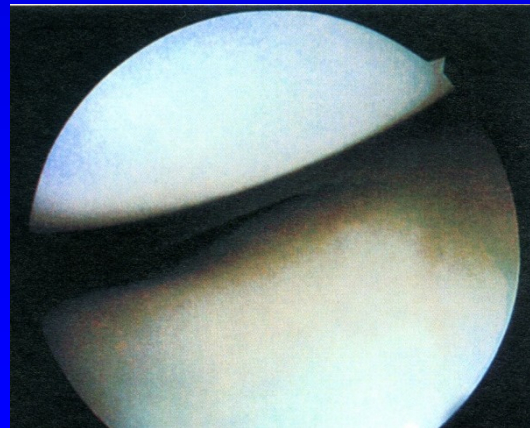
Responsible for lubrication of the joint

Promotes transport of nutrients into the cartilage

Gives the cartilage elastic resistance

Gives rheologic properties to synovial fluid

HA + proteoglycans + collagen: intercellular mass



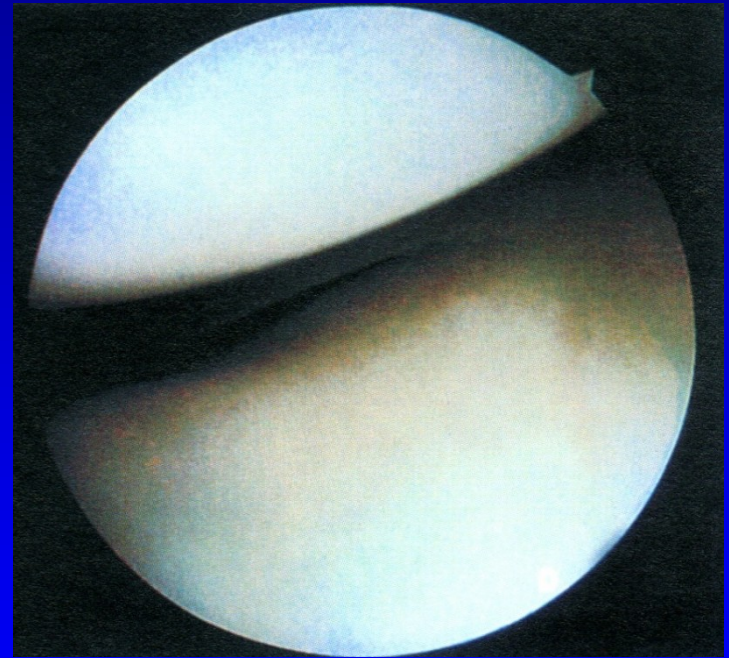Hyaline cartilage

High volume of water gives resistance in pressure

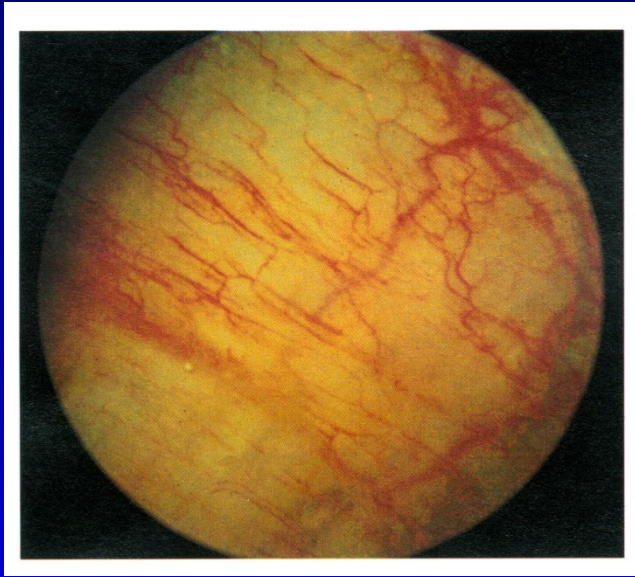Chondrocytes are nourished from synovial fluid

Cartilage has no vessels and nerves
- low regeneration

The fluid is pushed by movements into the cartilage



Synovial membrane



Network of vessels

It contains:

Cells A – macrophages

Cells B – produce hyaluronic acid

Cells C – mixed cells – properties of cells A and B

Synovial fluid

Clear, slight yellowish

Viscous

The amount of 0,13-3,5 ml
In a joint

Proteins- only one third
of concentration in plasma



Synovial fluid



Cytology: $65/\text{mm}^3$ lymphocytes, monocytes, mononuclears

Mucin = hyaluronic acid and N-acetylglucosamin
- gives viscosity

No fibrinogen

Diseases of joints

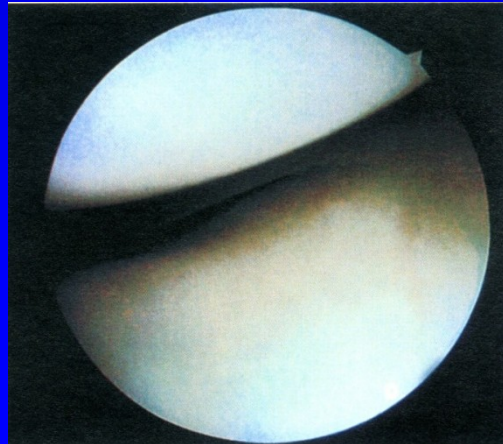
- Osteoarthritis deformans
- Rheumatoid arthritis
- Psoriatic arthritis
- Gout
- Ankylosing spondylitis
- Septic arthritis

Diseases of joints

- Systemic arthritis (lupus erythematoses)
- Haemofilia
- Aseptic necrosis
- Osteochondritis dissecans
- Chondromatosis
- Neurogenic arthropathy
- Pigmented villonodular synovitis

Osteoarthritis

- Degenerative, slow and progressive disease of hyaline cartilage of synovial joint
- All conditions changing the structure and function of hyaline membrane and surrounding tissues lead to osteoarthritis



Osteoarthritis

15 percent of the population

50 percent of people above 65 years

80 percent of people above 75 years

Osteoarthritis deformans

- Primary (after 40 years of age)
- Secondary – the cause is known

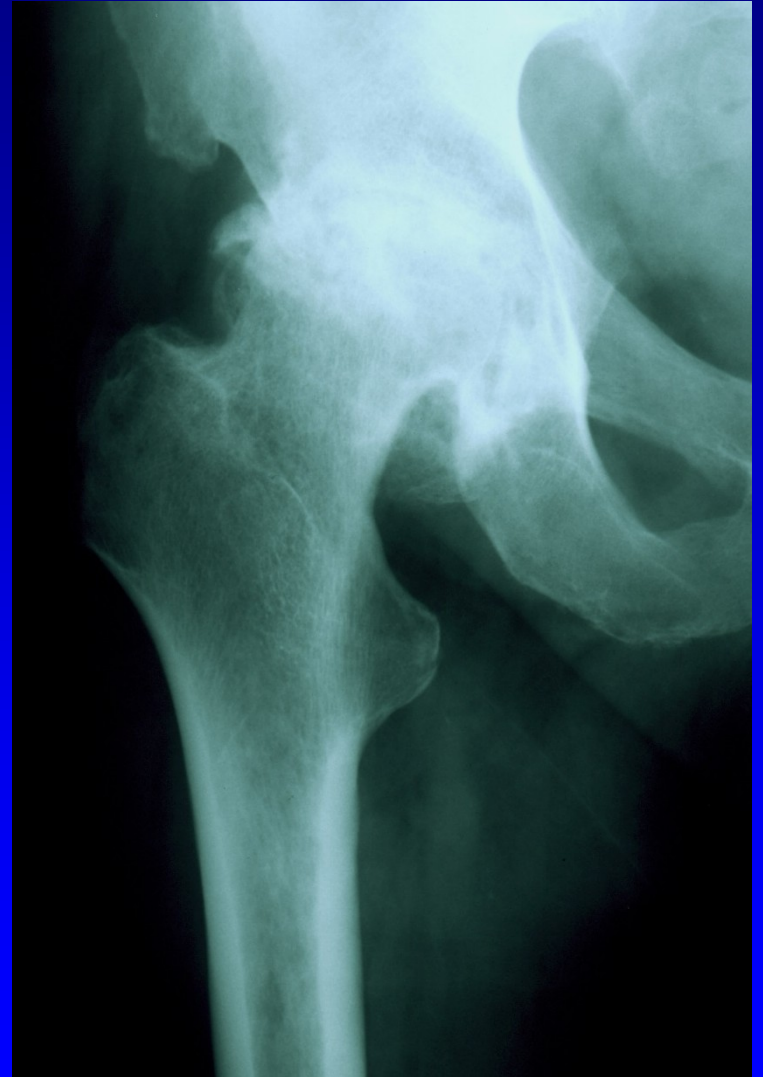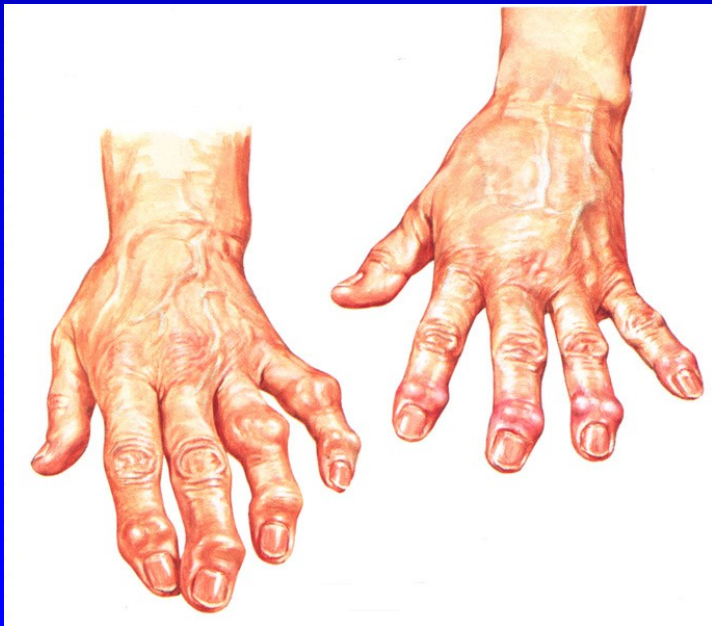Primary O.A.

Begins over 40 y.

Small joint in hands

Cervical and lumbar spine

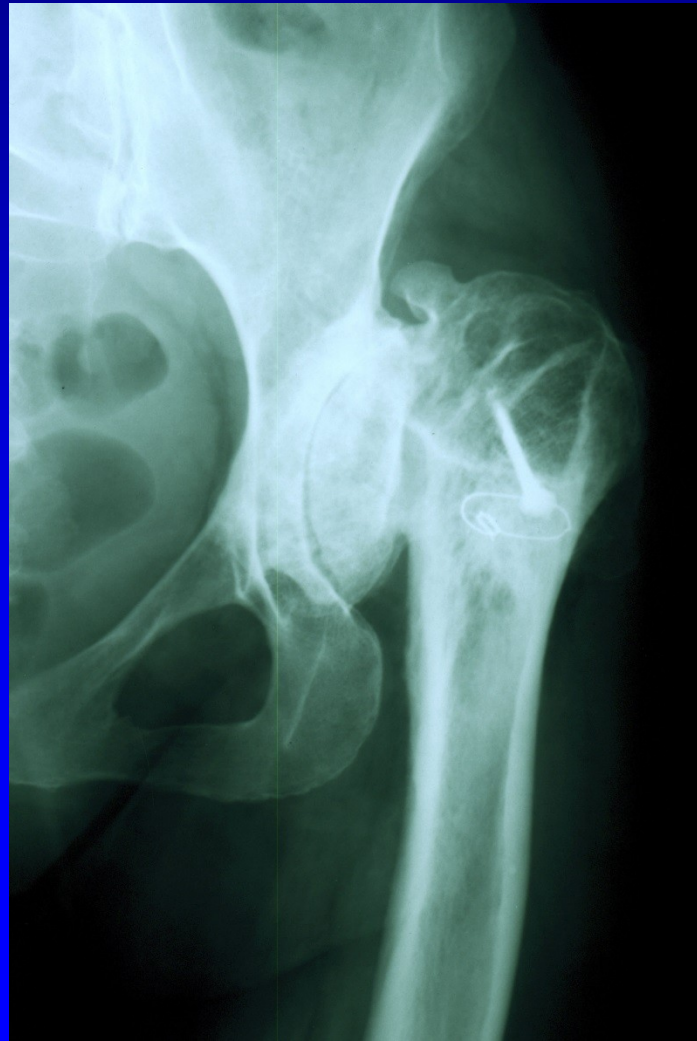Hip and knee joints



Secondary O.A.

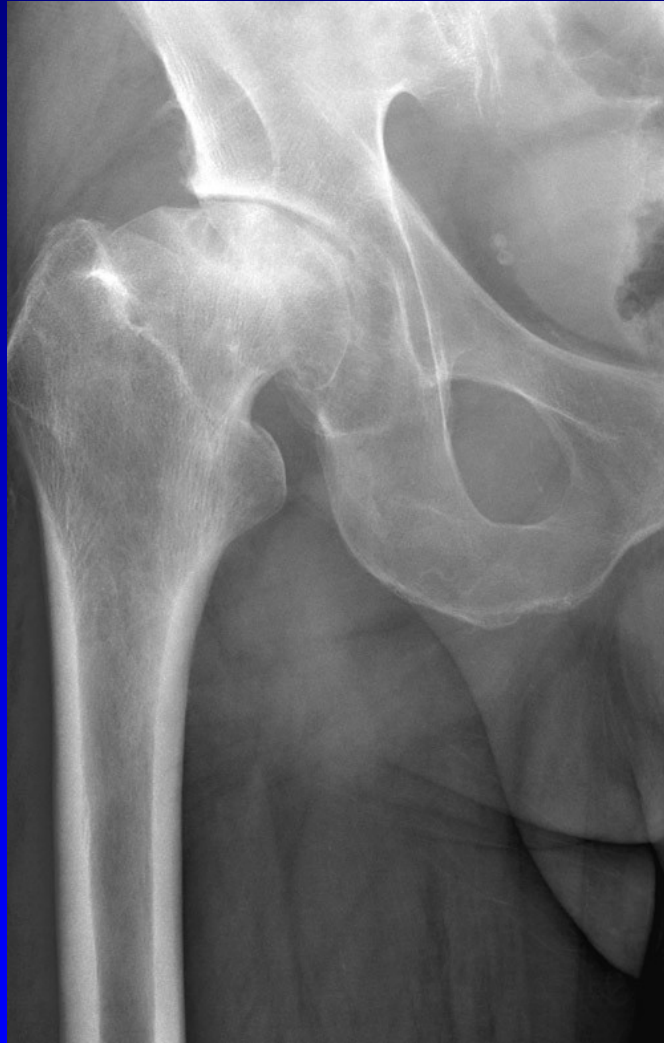1. Mechanical factors (DDH, Perthes disease, aseptic necrosis, slipped femoral epiphysis, condition after fractures)
2. Metabolic disorders (ochronosis, gout, chondrocalcinosis, Gaucher disease)
3. Hormonal disorders (acromegaly, diabetes m.)
4. Haemophilia
5. Inflamated disorders (septic arthritis, R.A.)

DDH- developmental dysplasia of the hip joint



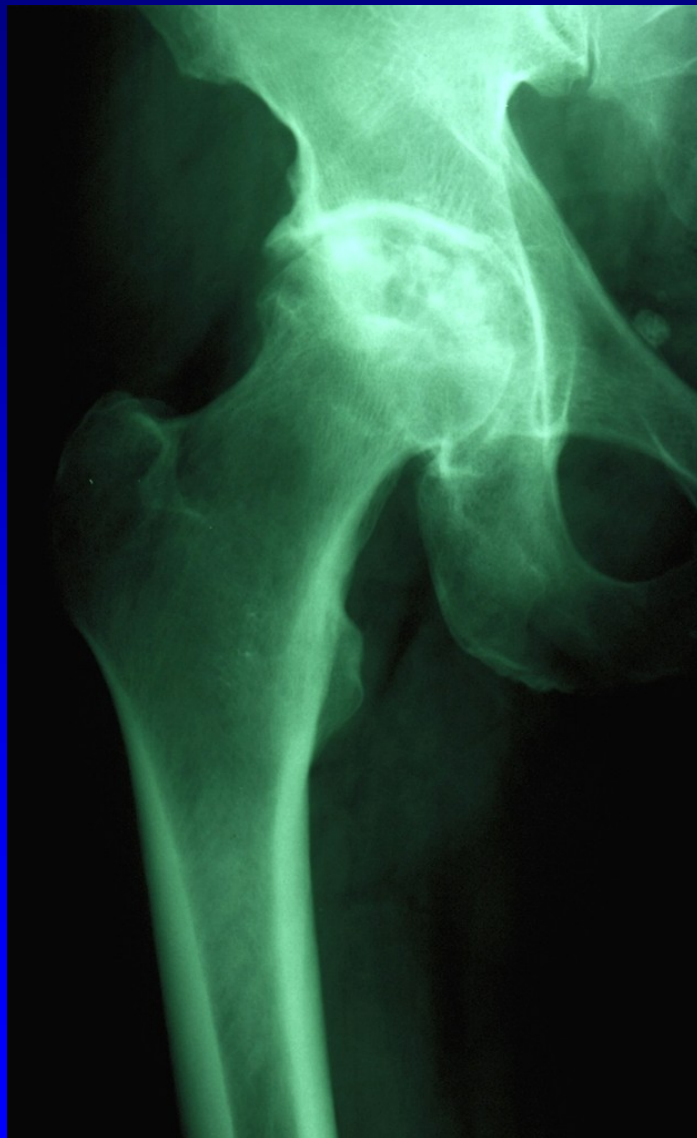Obr. 6

Condition after Perthes disease



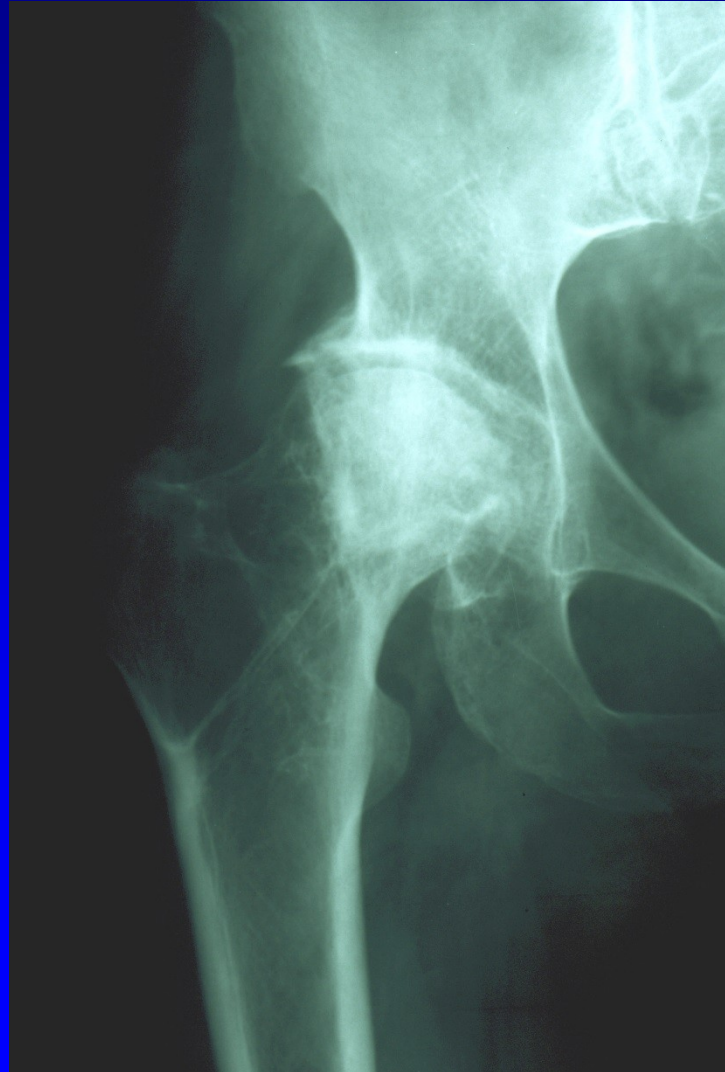
Obr. 8

Idiopathic necrosis of the femoral head



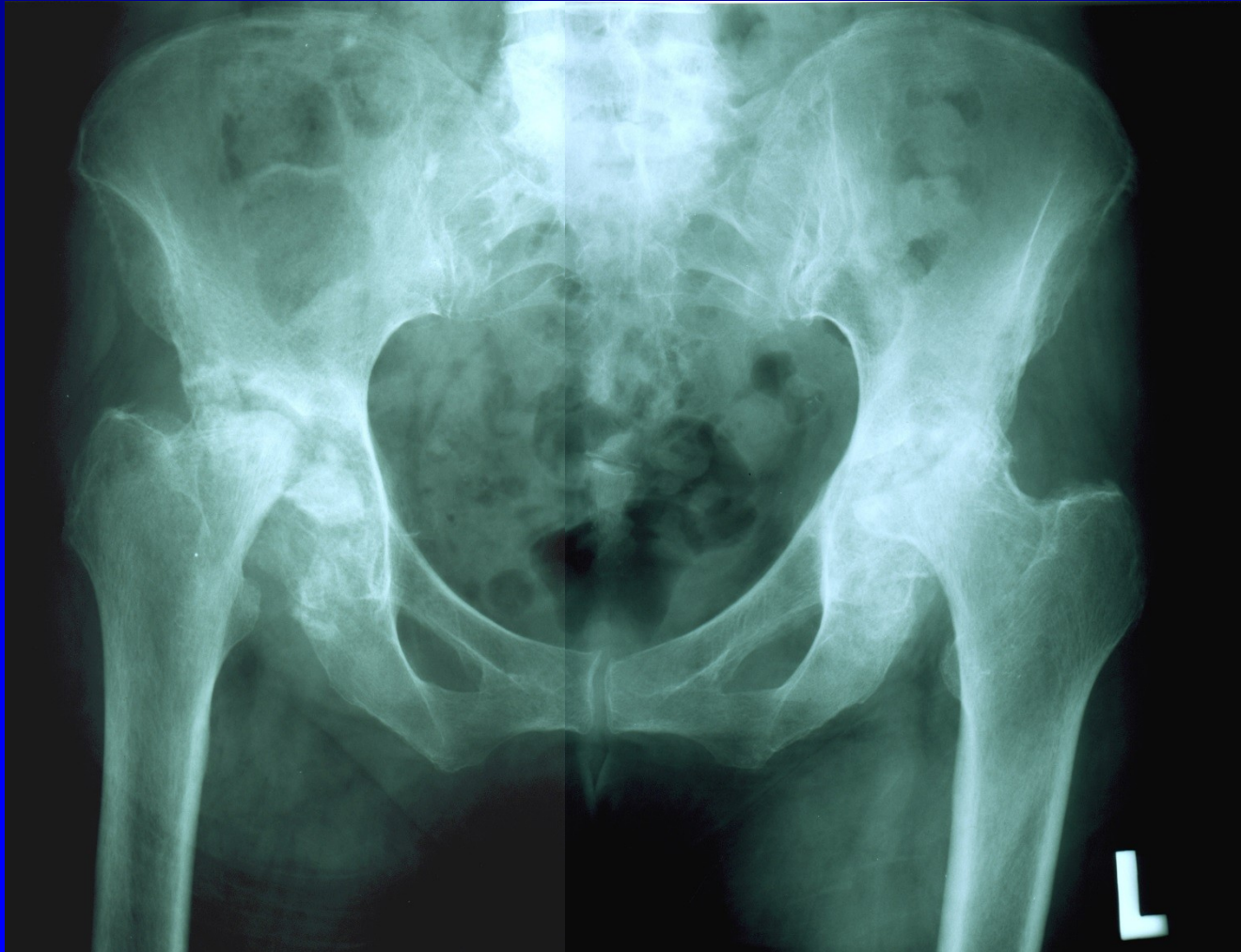Obr. 7

Necrosis after femoral neck fracture



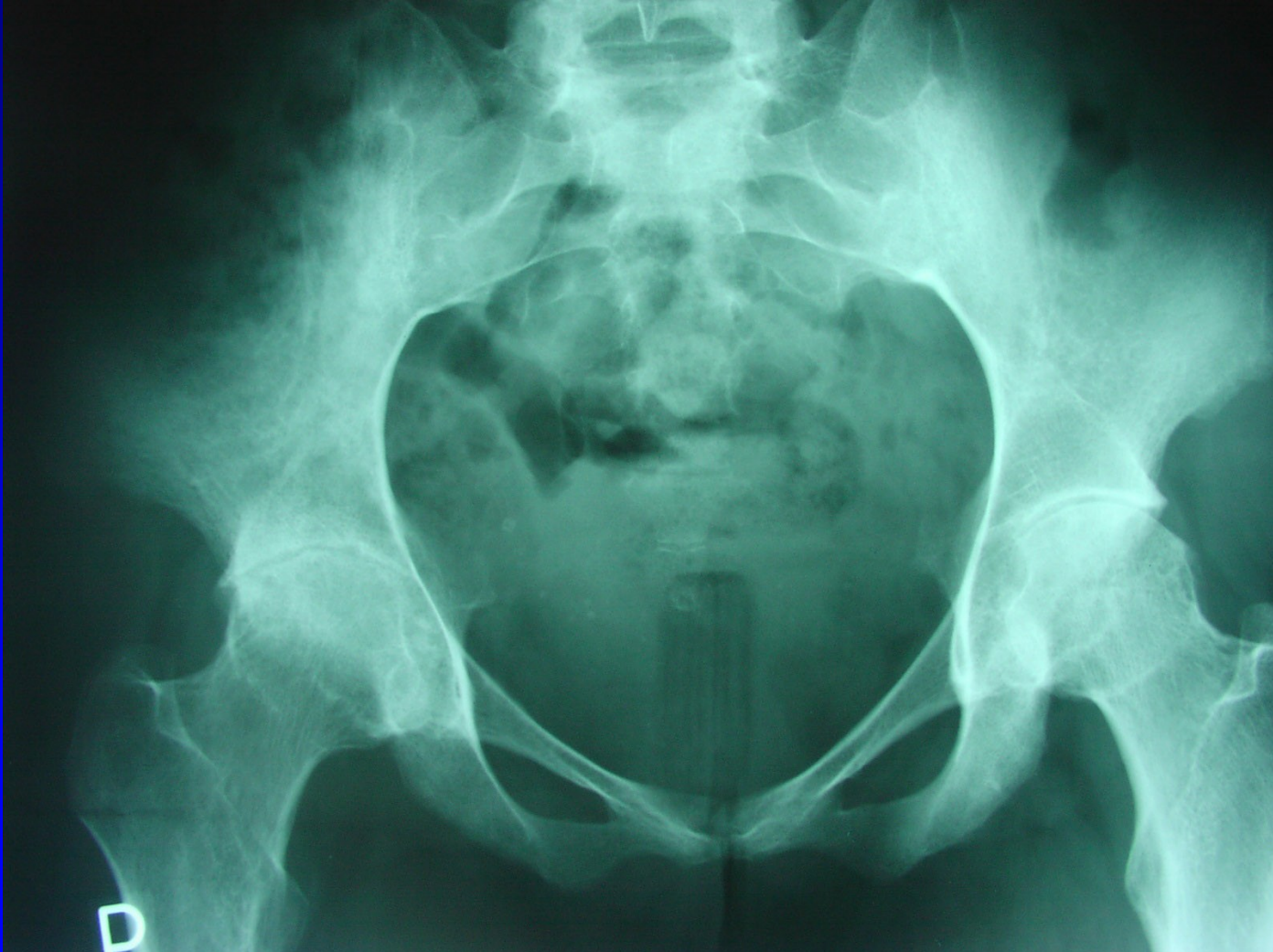Obr. 9

Rheumatoid arthritis



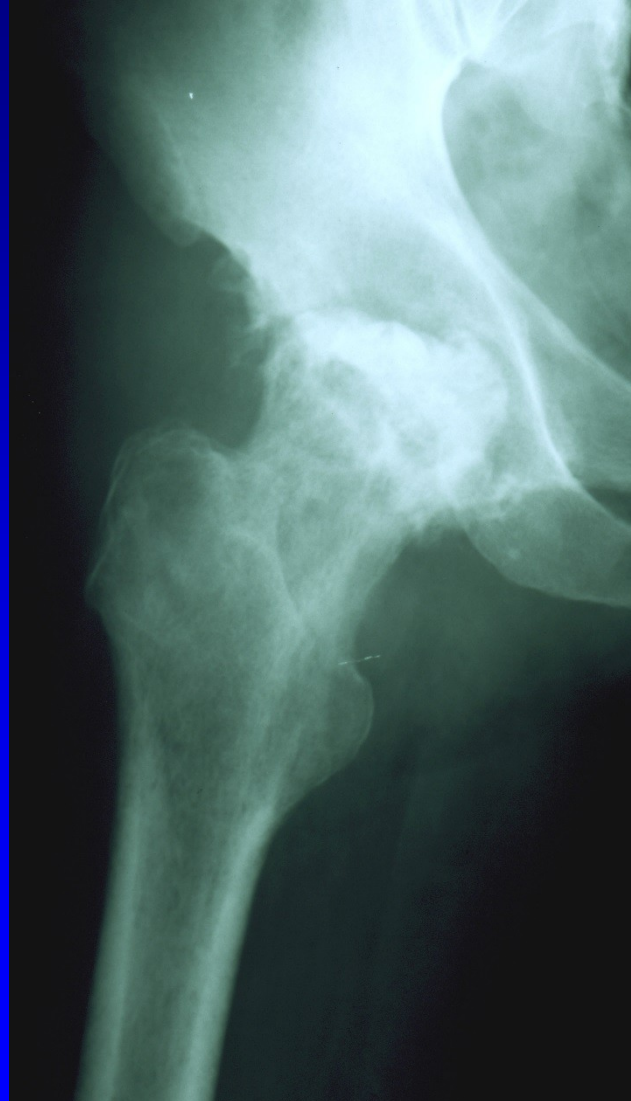
Obr. 10

Ancyllosing spondylitis



Obr. 12

Septic arthritis



Obr. 13

Risk factors

Age over 50 years

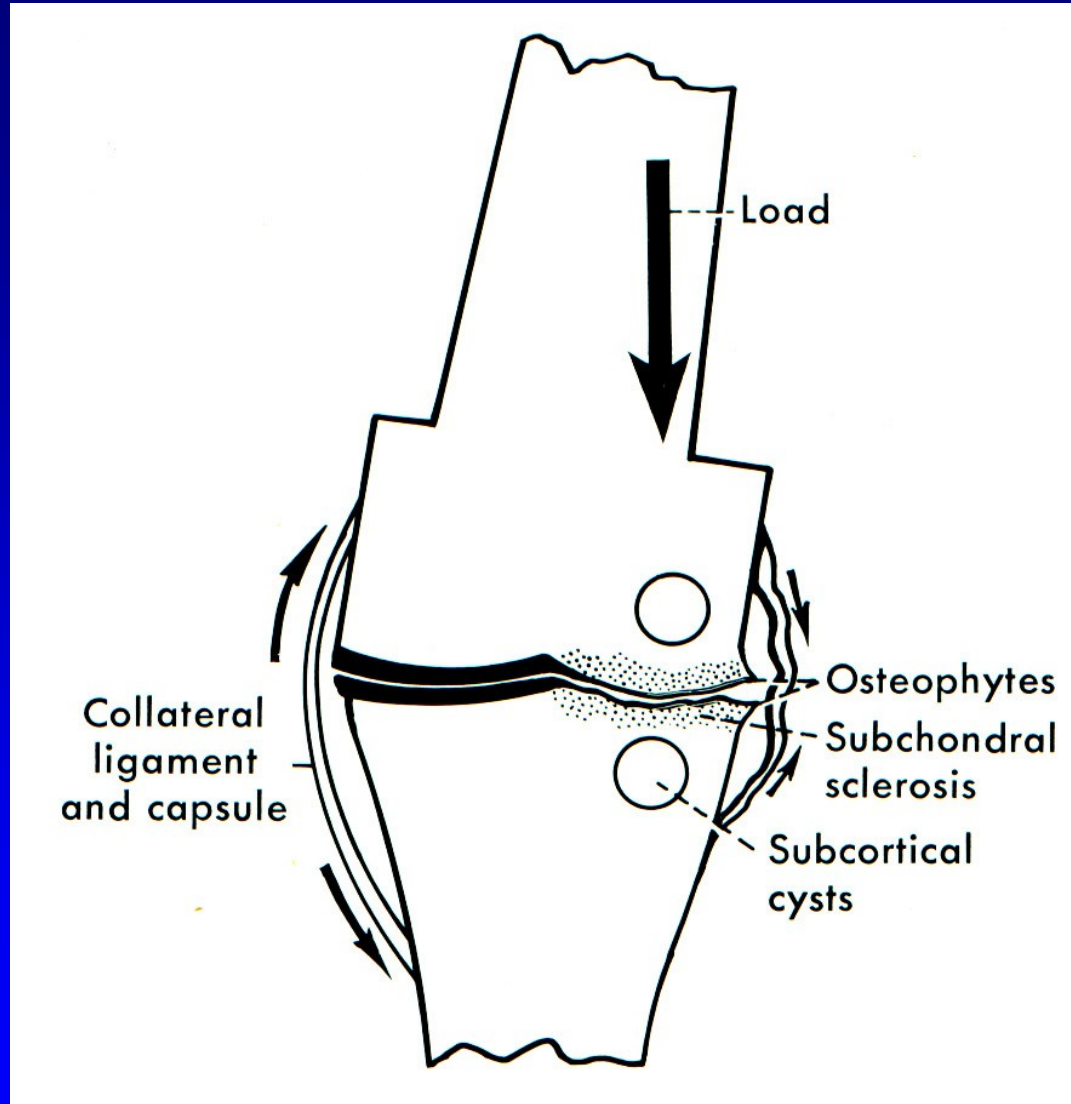
Obesity

Mutation of gene for procollagen II (COL2A1)

Autosomal gene for Heberden's nodes
is dominant in female and recessive in male

Female are involved twice oft than male
- after 55 years – postmenopausal defecit of
estrogens - O.A. is more often

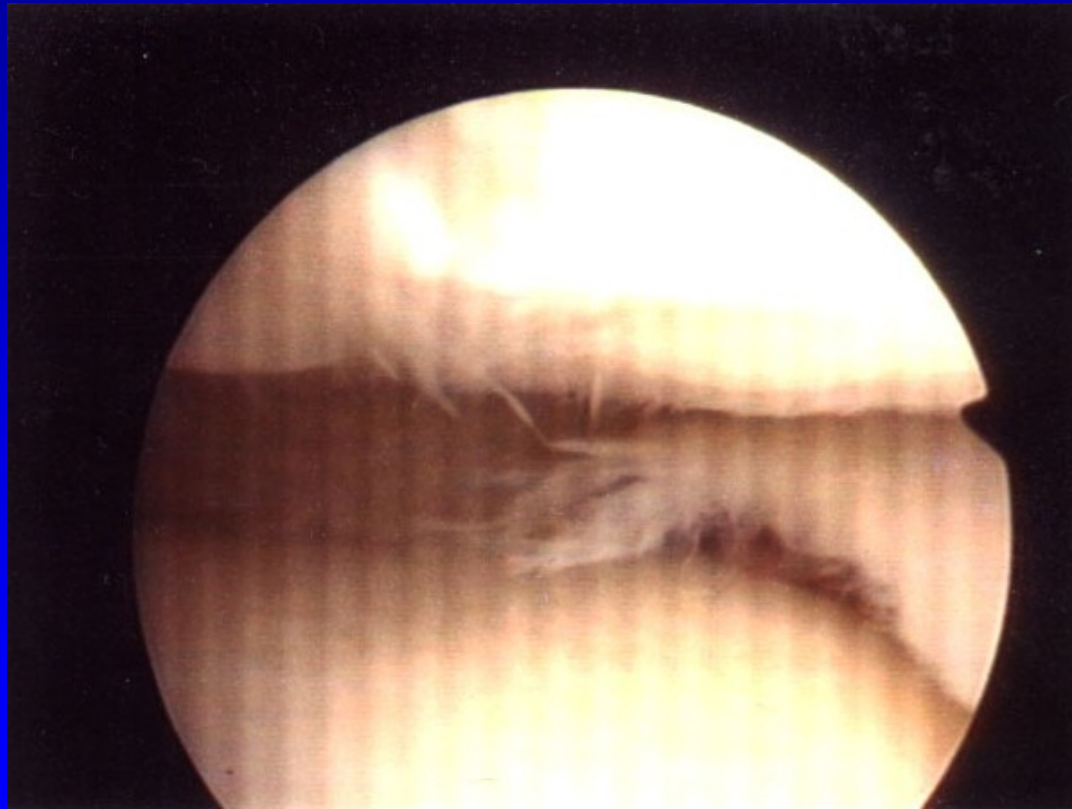
Mechanical O.A.



Obr. 14

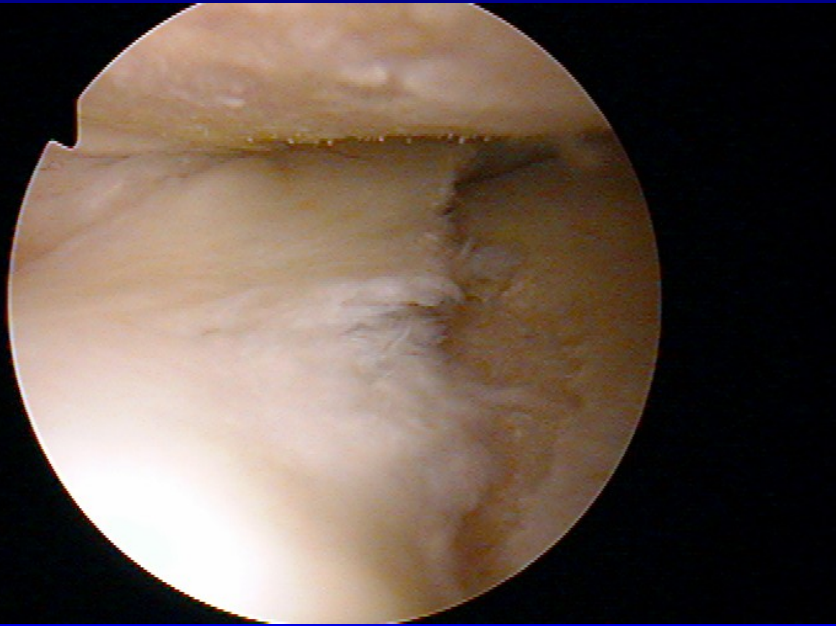
Macroscopic changes

Cartilage is soft, yellowish, fibrillations

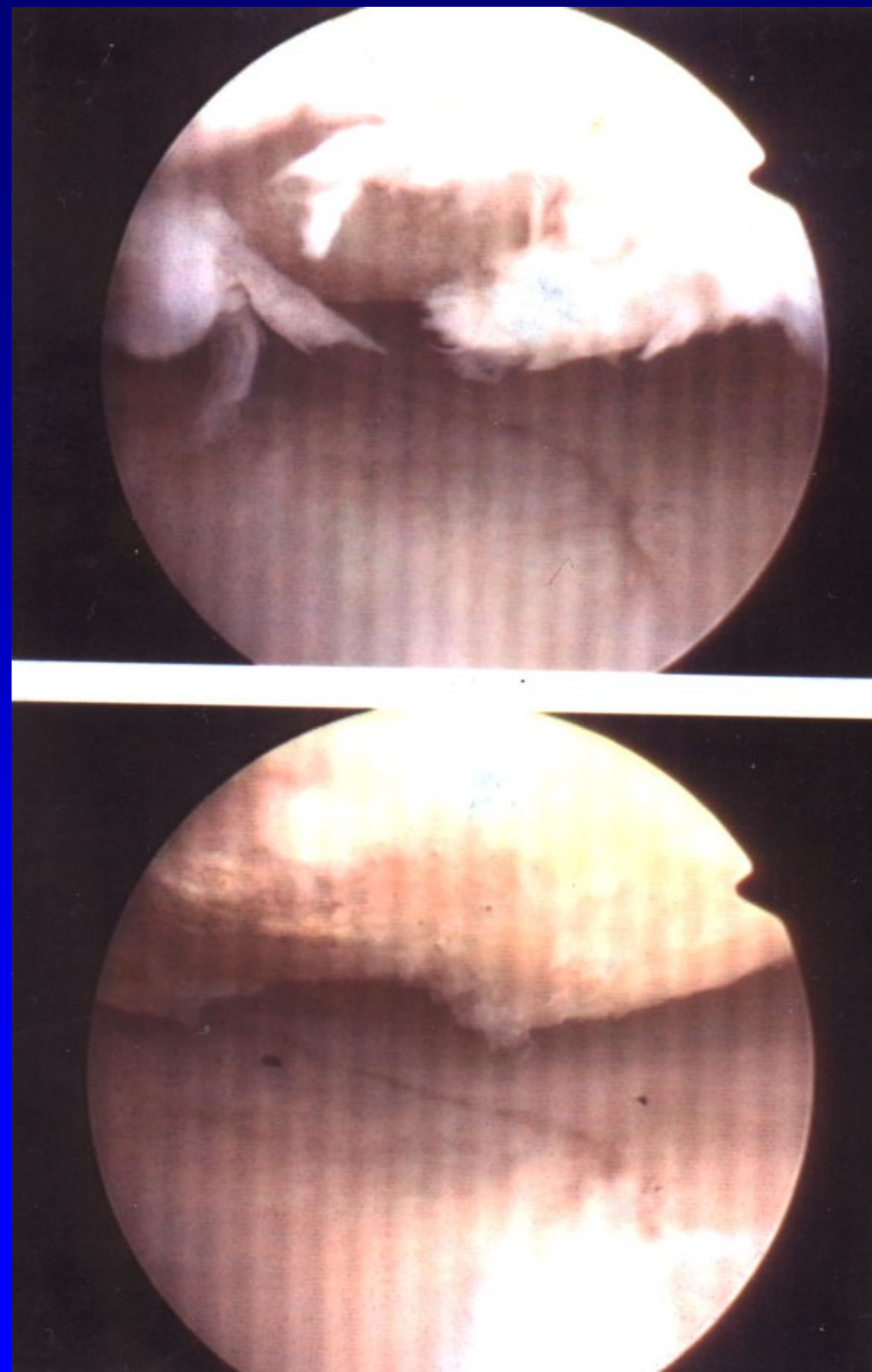


Obr. 15

Ulcers, defects

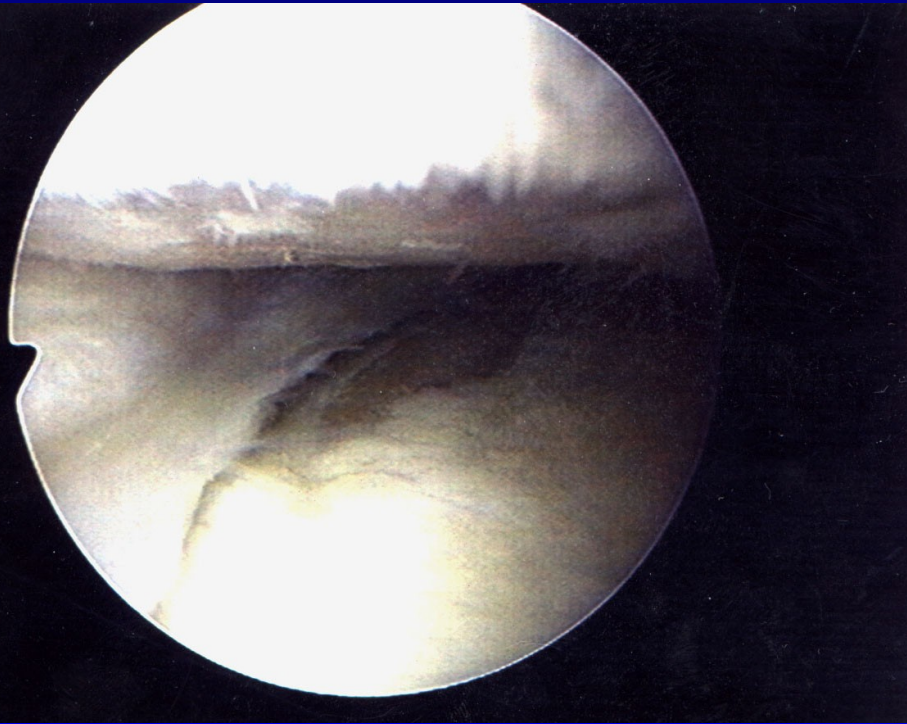


Obr. 16

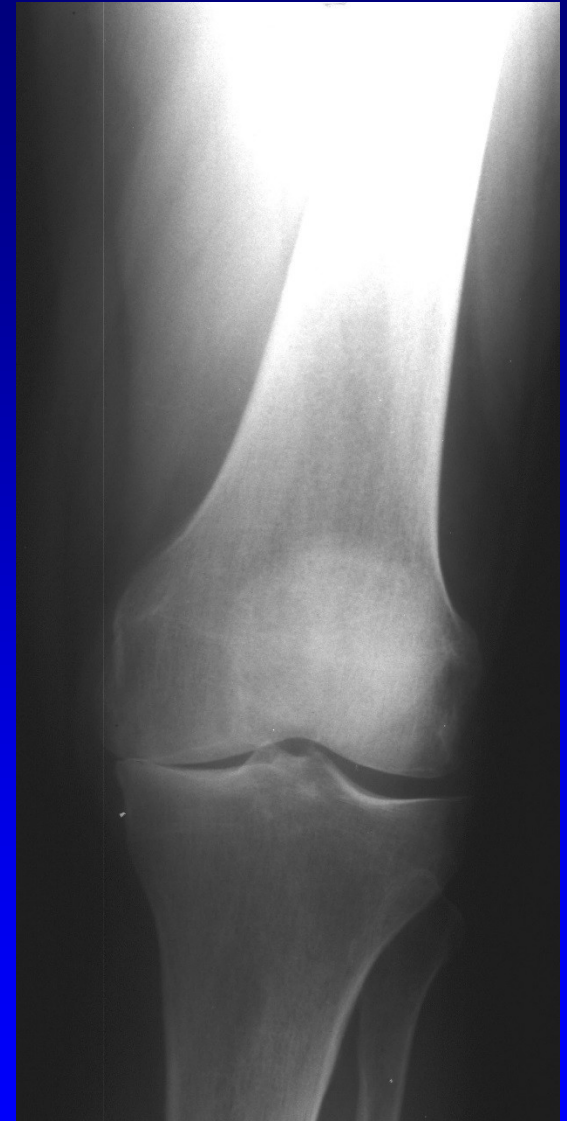

Obr. 17

Subchondral bone is sclerotic



Obr. 18



Obr. 19

Macroscopic changes

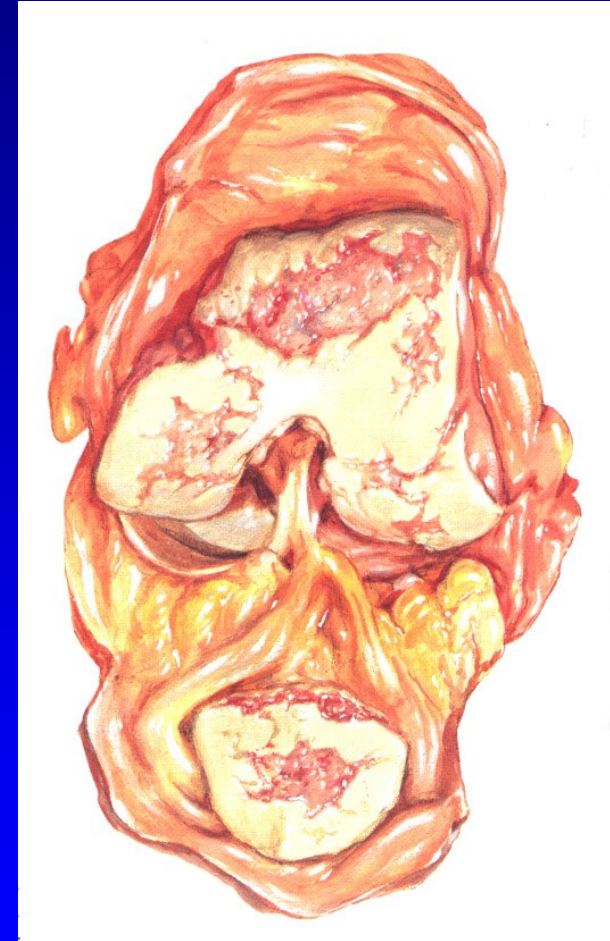
Subchondral cysts

Osteophytes

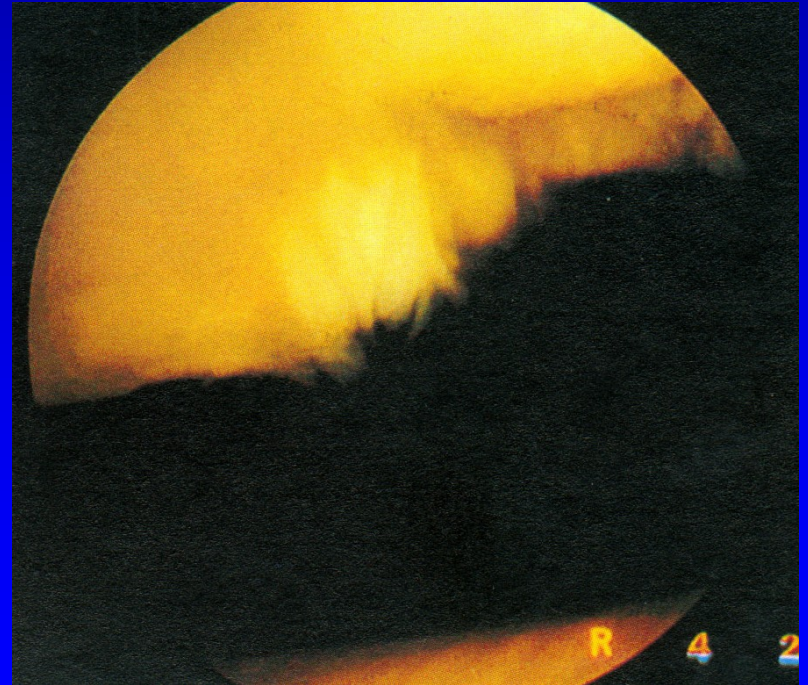
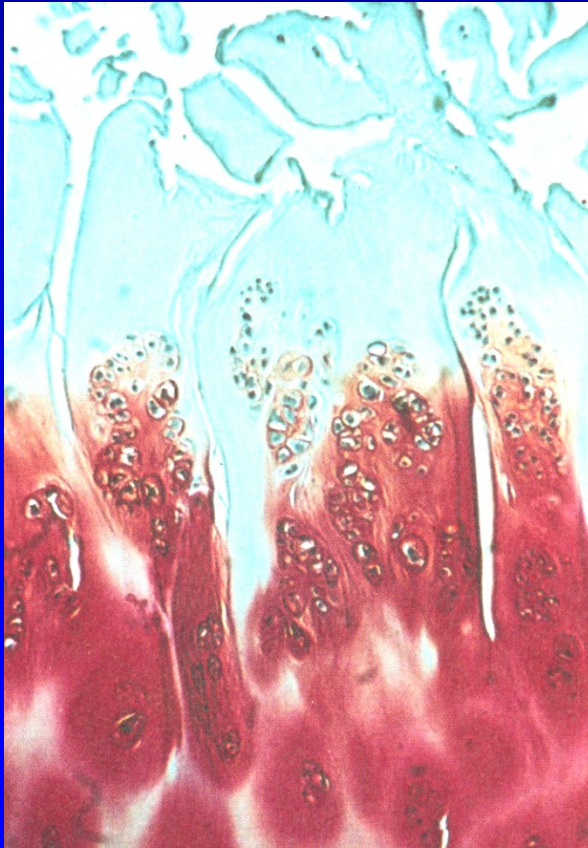
Narrowing of cartilage

Hypertrophic synovial membrane

Loose bodies

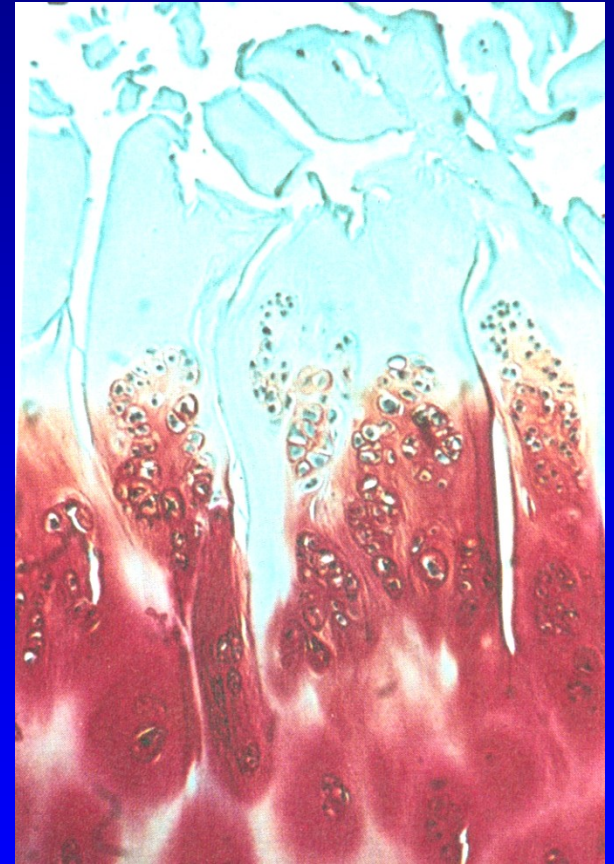


Chondrocytes make clusters in 10-20
Irregularities of the surface
Fibrillations
Fissures, defects of cartilage
Collagen network is disturbed



Biochemical changes

- Higher amount of water
- Synthesis of PG is higher
- Loss of proteoglycans is high
- Chondroitin 6 sulfate - less
- Ketaransulfate- less
- Condroitin 4 sulfate is higher



Clinical symptoms

Pain, mild, in weather changes, later is higher

Stiffness

Effusion, synovitis

Limping, difficultis in standing and walking

Muscle atrophy, joint contracture

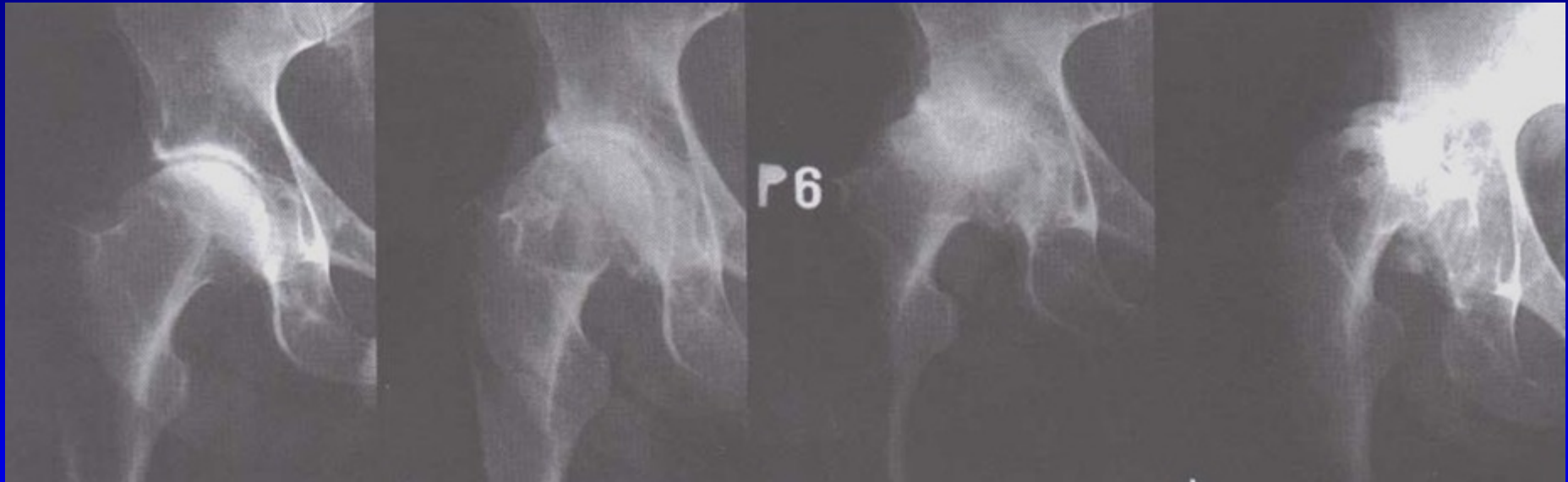
Malalignment

I.

II.

III.

IV.

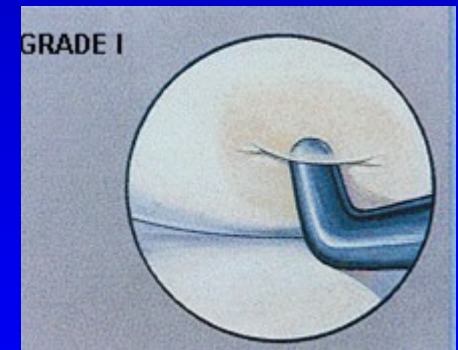
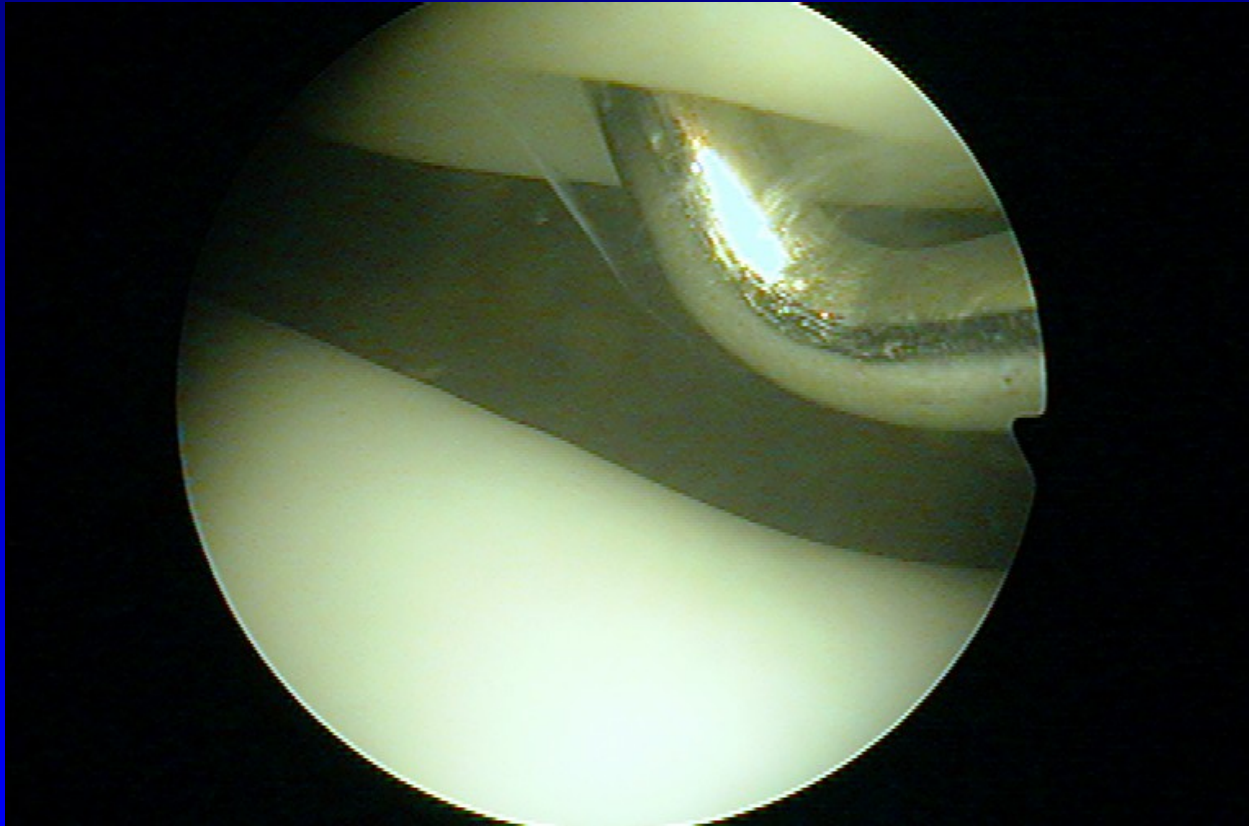


Kellgren- Lawrence classification I- IV.

Chondropathy

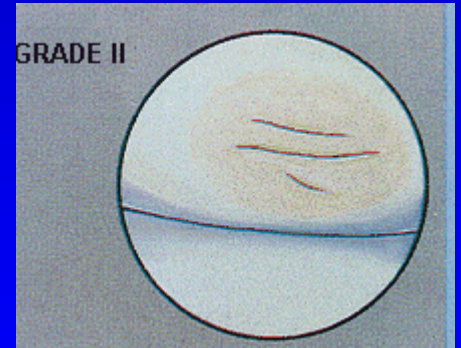
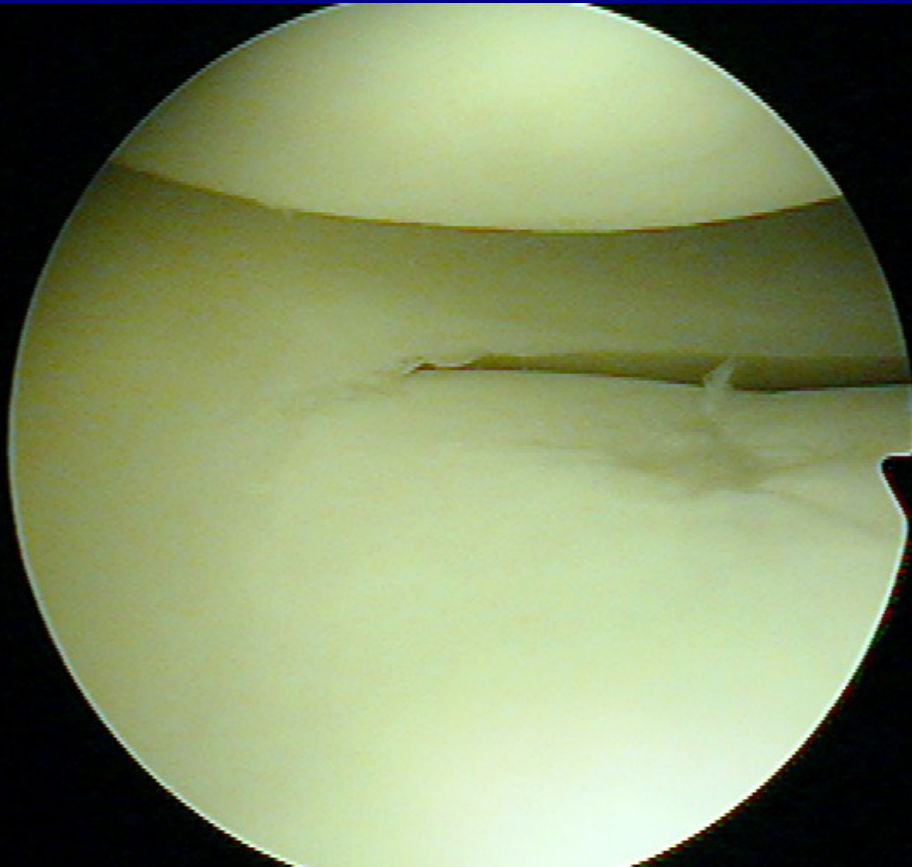
- 1 Softening and swelling
- 2 Fragmentation and fissures up to 1,3 cm
- 3 Fragmentation and fissures above 1,3 cm
- 4 Erosions up to subchondral bone

Chondropathy I. st.



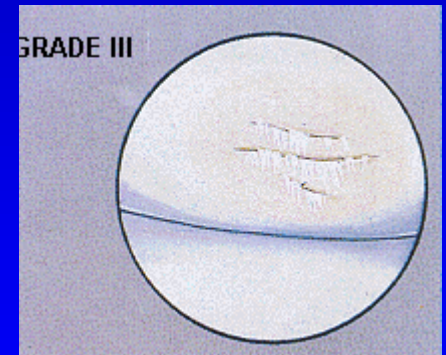
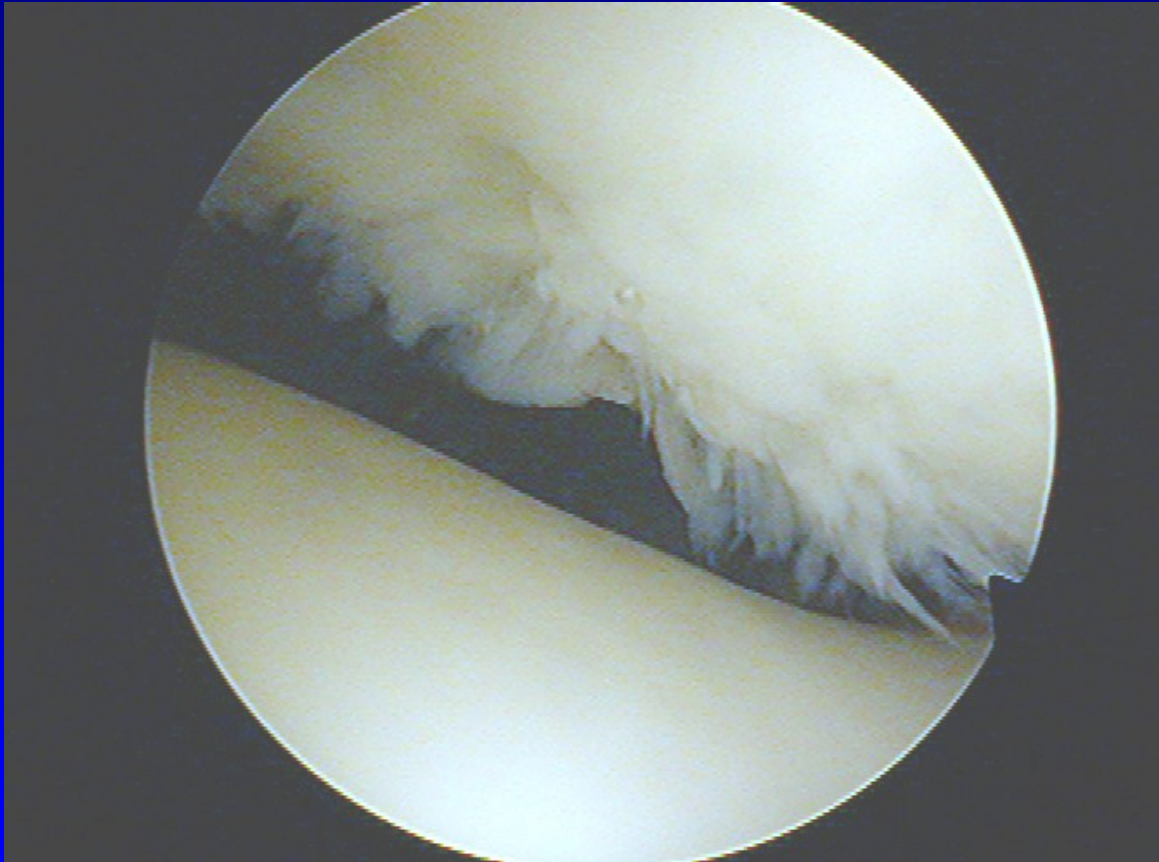
Chondromalacia- soft cartilage

Chondropathy II. st.



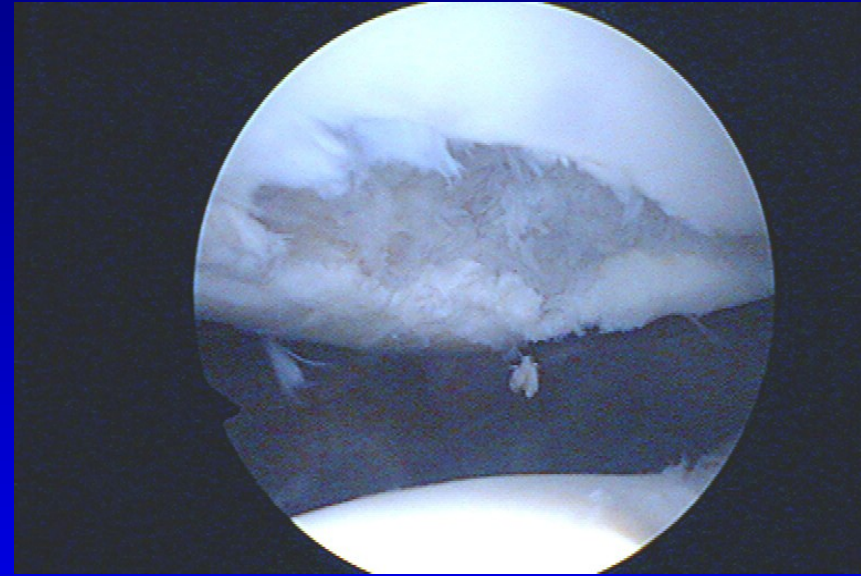
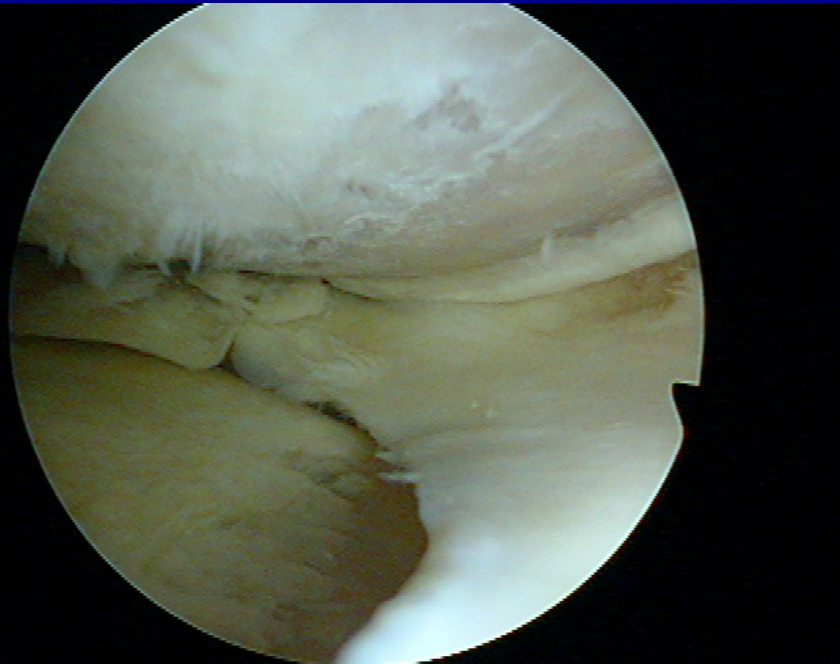
Fissures in the cartilage

Chondropathy III. st.

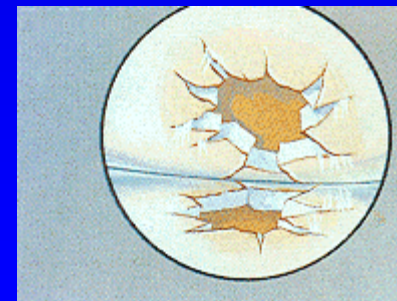


Fibrillation- „ crab meet“

Chondropathy IV. st.



Defects to subchondral bone



Conservative treatment

Change of life style

Low weightbearing

Loss of overweight

Ortheses, crutches, sticks

Physioterapy

Physical therapy

Conservative treatment

Analgetics nonopioid (paracetamol)

Analgetics opioid (tramadol, codein,)

Nonsteroidal antiinflammatory drugs (NSAID)

NSAID

Inhibitors of cyclooxygenase 1 COX - 1 inhibitors

Ibuprofen

indometacin

piroxicam

naproxen

diclofenac

tiaprofenic acid

NSAID

Inhibitors of cyclooxygenase - 2 COX 2 inhibitors

Preferred: meloxicam (Movalis, Recoxa)
nimesulid (Aulin, Coxtral, Nimesil)

Selective : celecoxib (Aclexa)
rofecoxib

SYSADOA

- Symptomatic, slow acting, antiinflammatory drugs (chondroprotectives)

Slowly acting

Long lasting effect

Stimulation of PG and collagen

Inhibition of catabolic enzymes

SYSADOA

1. systemic: glucosamin sulfate
chondroitin sulfate
diacerein
ASU piascledine

Combined drugs (Alavis)

Collagen- GUNA inj.

ChondroGrid (hydrolylisated peptids
of low molecular weight ≤ 3 kDa

SYSADOA local- hyaluronic acid - viscosupplementation

Hyalgan

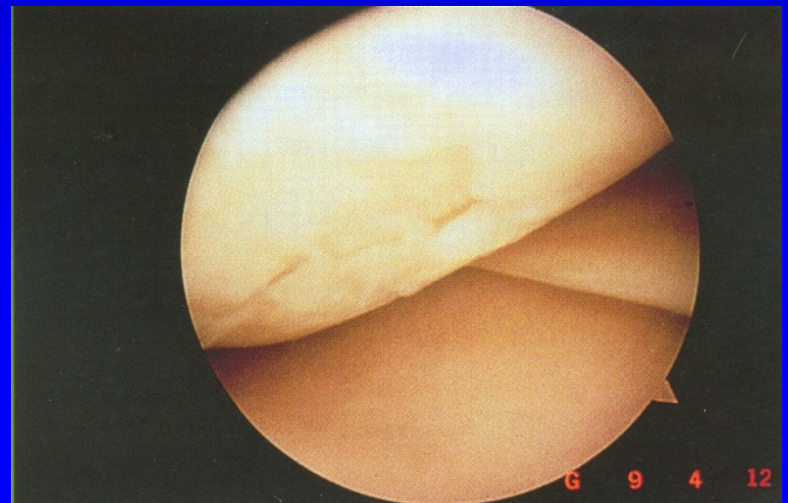
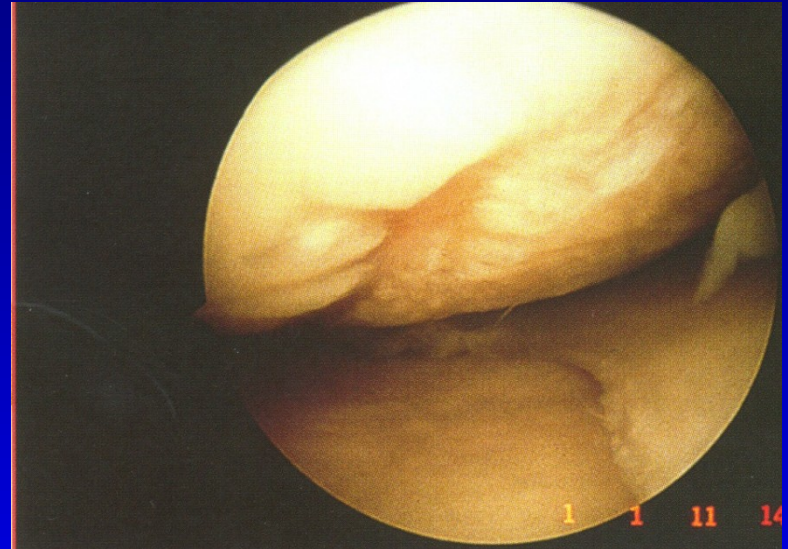
Synvisc

Synovial

Monovisc

Hyaline

Renehavis



Local corticosteroids

Diprophos

Depo-Medrol

They influence synovitis

Do not stop progression of O.A.

Synthetic activity of chondrocytes is lower

The amount of chondrocytes and PG is lower

Recommended treatment

Paracetamol- up to 4 g per day

NSAID + inhibitors of proton pump (omeprazol)

Chondroprotectives

Hyaluronic acid, collagen

Local corticosteroids

Pain department- in a case surgery is not indicated

Other options

PRP- platelets rich plasma

ACP- autologous conditioned serum- Orthokine

Mesenchymal stem cells ?

Operative treatment

Preventive surgery

- correct treatment of intraarticular fractures
- correct treatment of ligament injuries
- correct treatment of dislocations
- correct treatment of meniscal lesions
- treatment of chondromalacia
- removal of loose bodies

Operative treatment

Preventive surgery

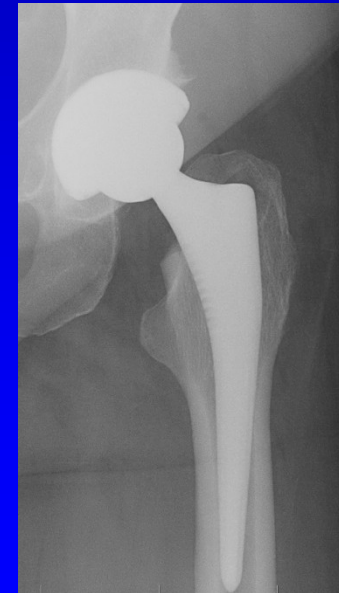
- Correction of malalignment- osteotomy
- Acetabuloplasty, shelf plasty
- Replacement of cruciate ligaments
- synovectomy, debridement, shaving

Operative treatment

Resection arthroplasty – op. sec. Keller
op. sec. Girdlestone

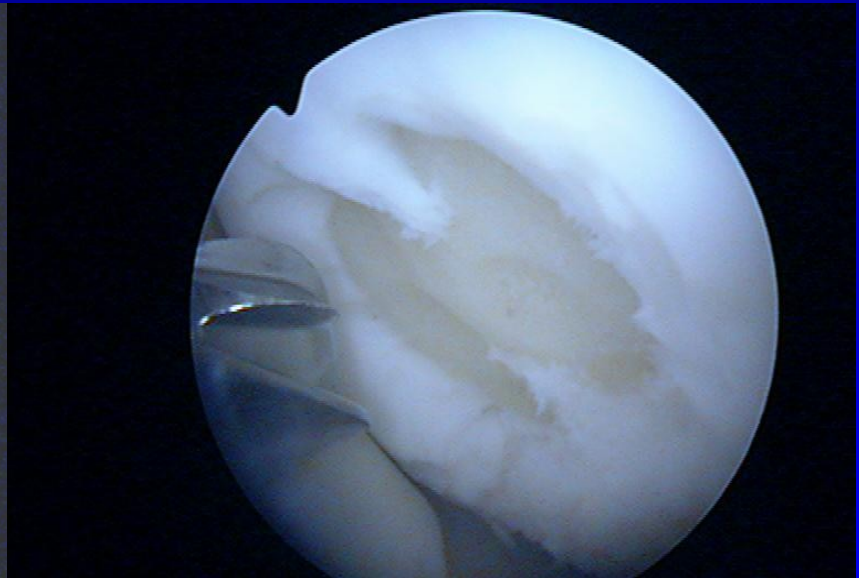
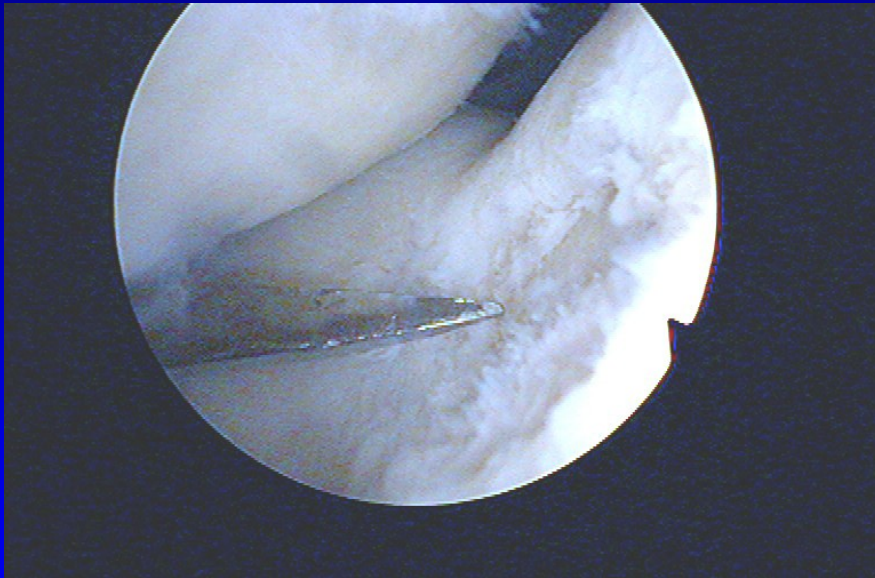
Arthrodesis

Total joint replacement



Options for localised chondral defects

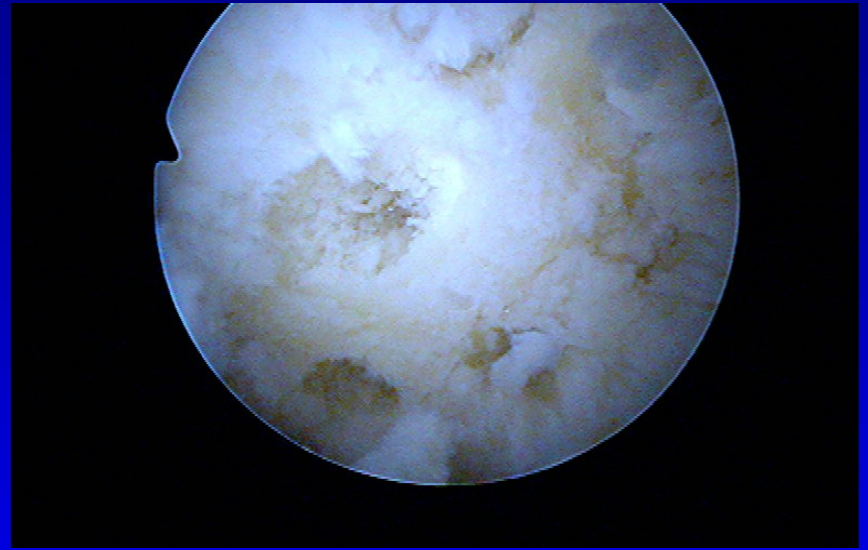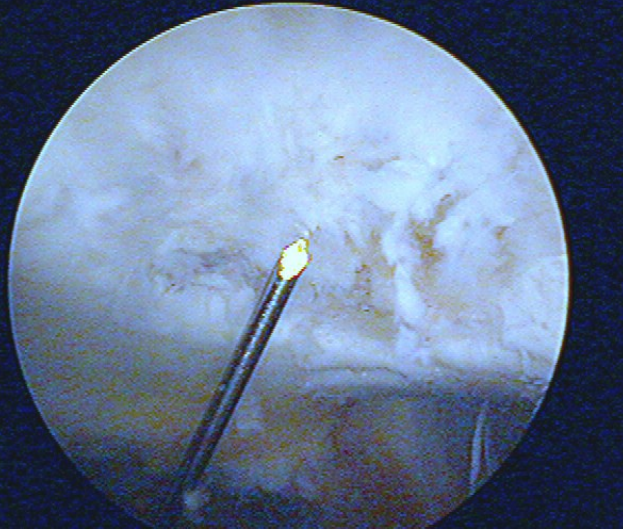
Shaving and drilling



-

-

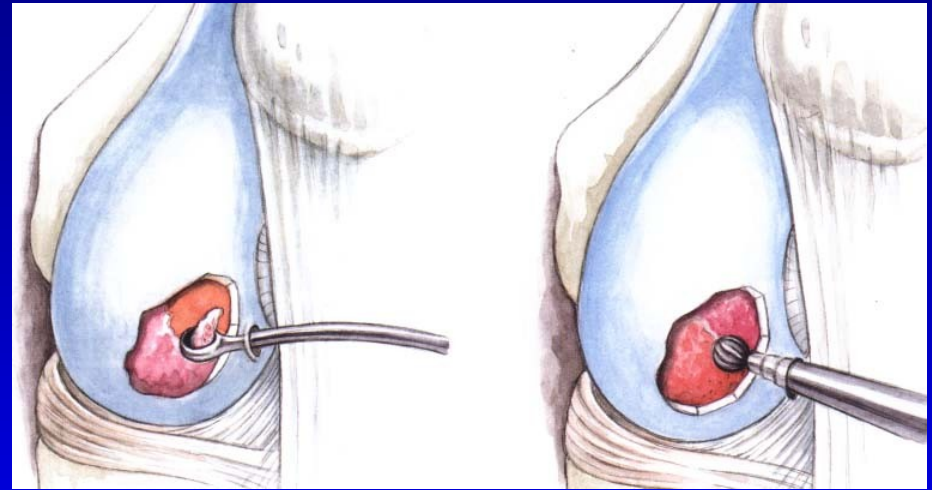
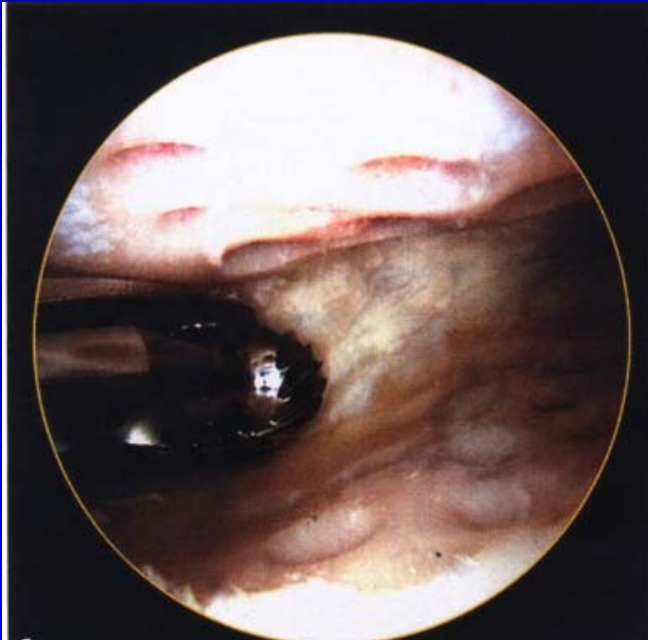
Drilling



-

Abrasion chondroplasty

Curretage
Shaver



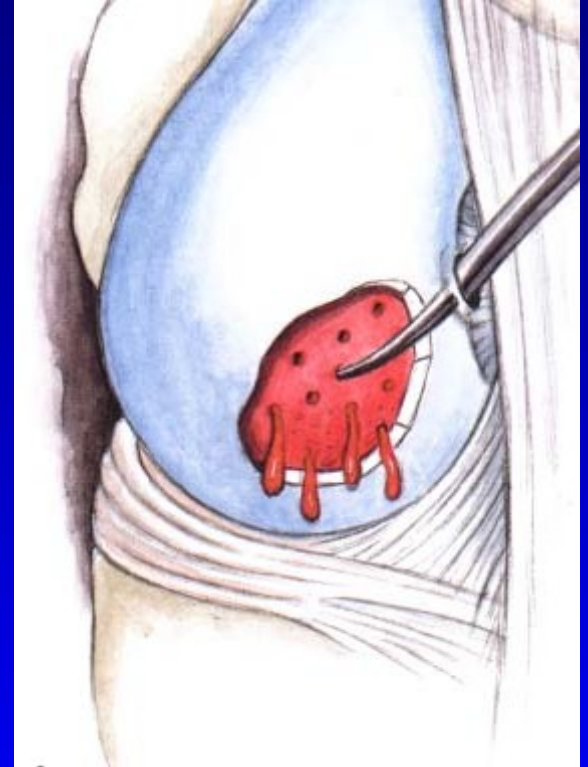Microfractures

Perforation of subchondral bone
- slight bleeding

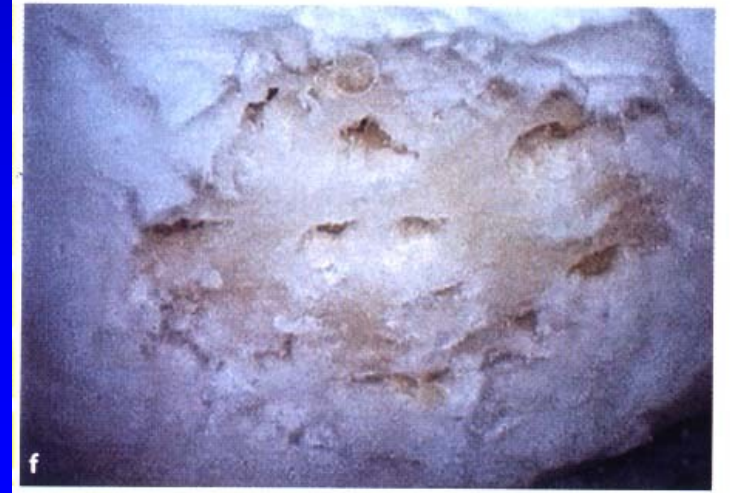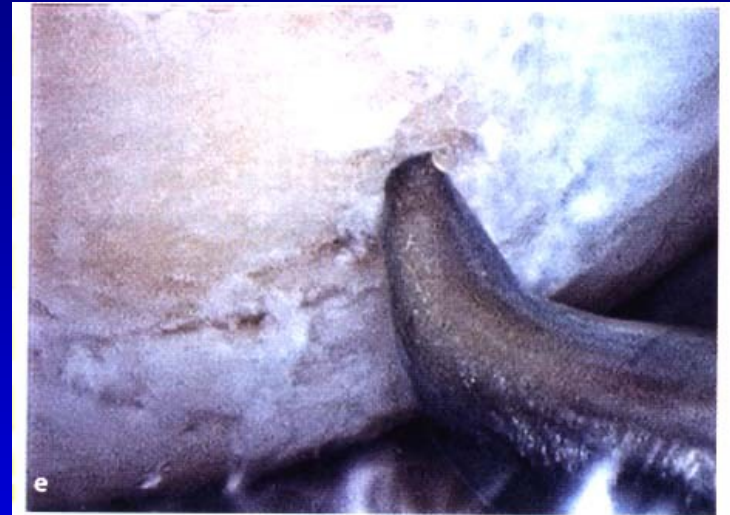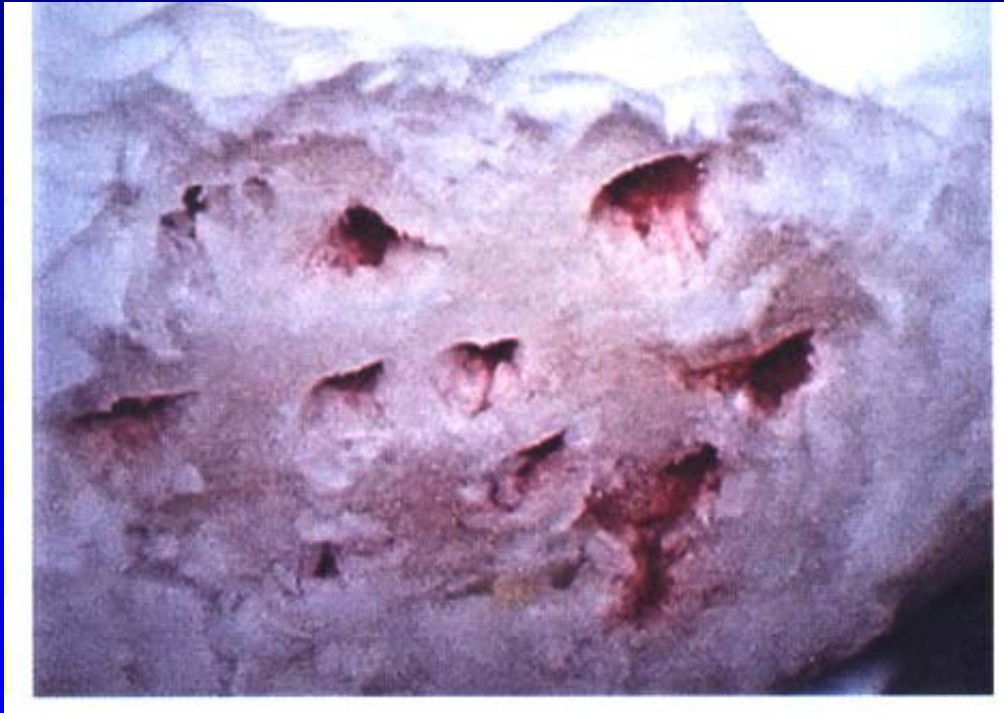Steadman, J.R., 1999

Multipotent stem cells into
the defects

The aim- to create fibrocartilago

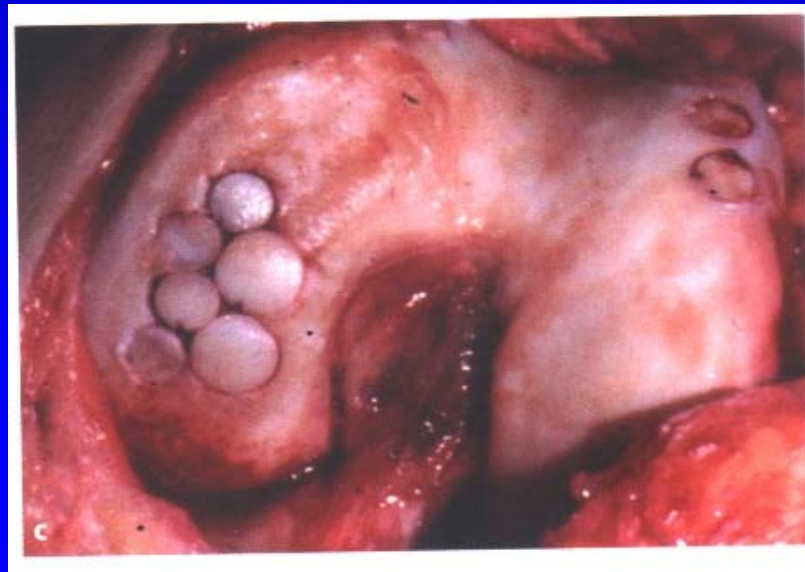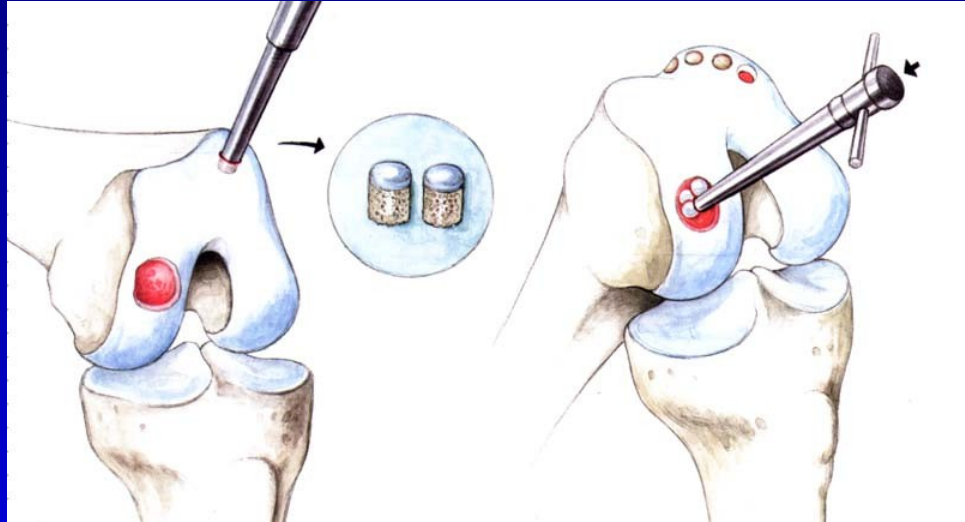


Microfractures

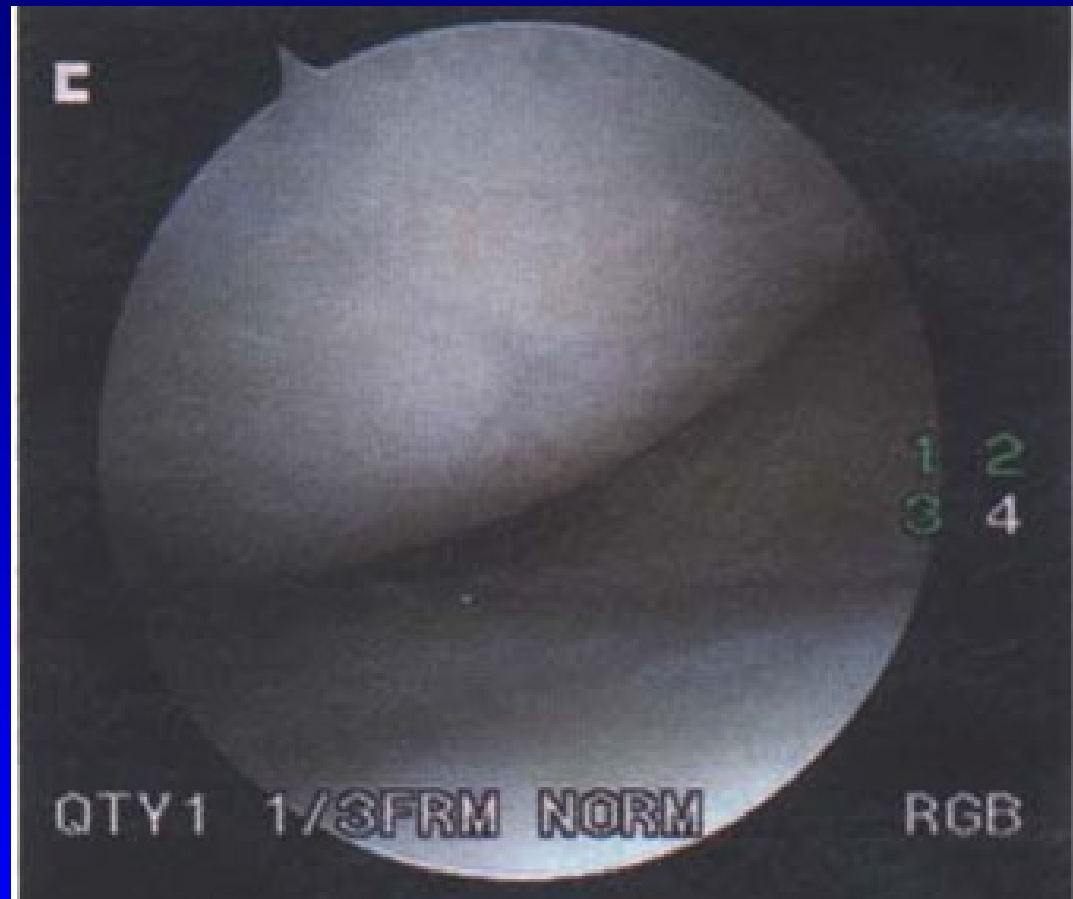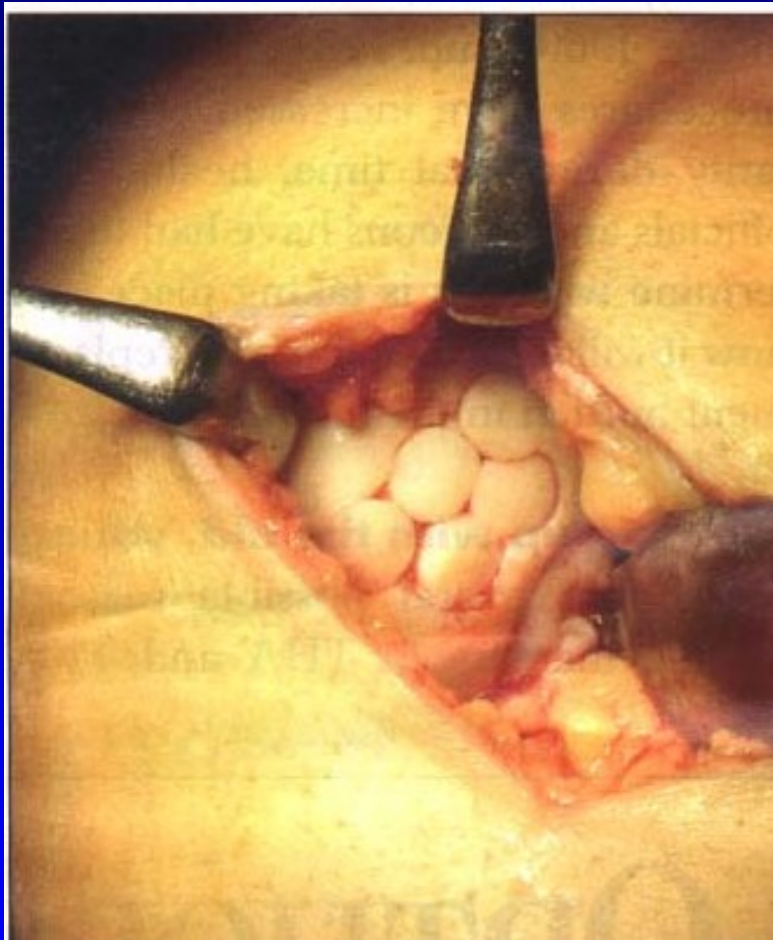


Osteochondral autograft transfer- OAT Mosaicplasty

Hangody, L., 1992
Defects up to 2 - 4 cm²



OAT



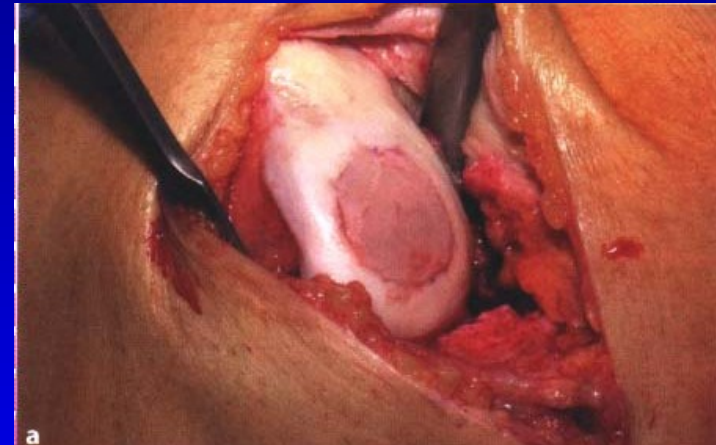
4 years after surgery

Hyalografts and chondrografts

Scaffolds- HyaloFast, Chondrotissue...

Biodegradable

Matrix for stem cells from bone marrow
after drilling or from serum



Collagen scaffolds

Hyalofast- scaffold

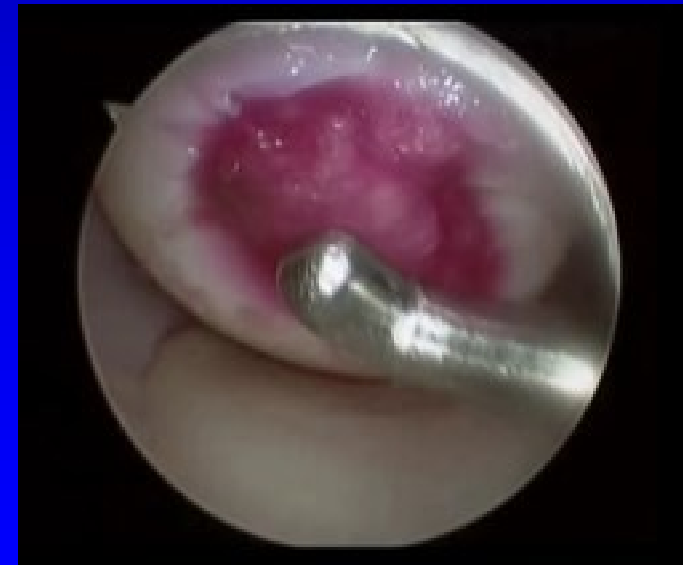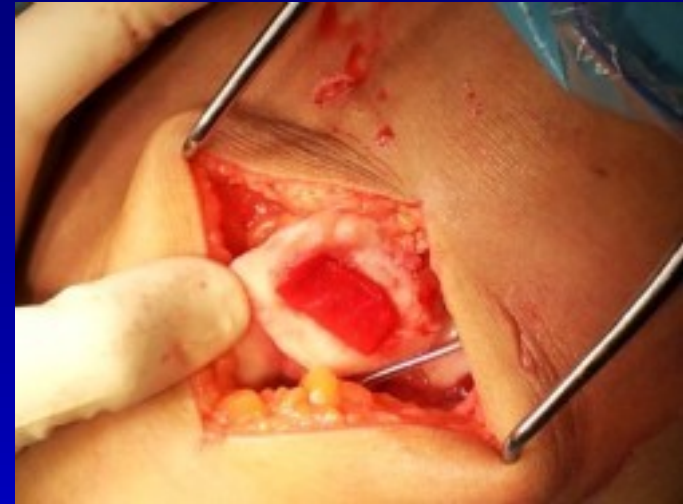Polymer of HA

No special fixation

Scaffold serves for maintaining of stem cells from bone marrow

Supports viable cells

Fills the defects of hyaline cartilage



Differential diagnosis

Rheumatoid arthritis

Ancyllosing spondylitis

Psoriatic arthritis

Septic arthritis

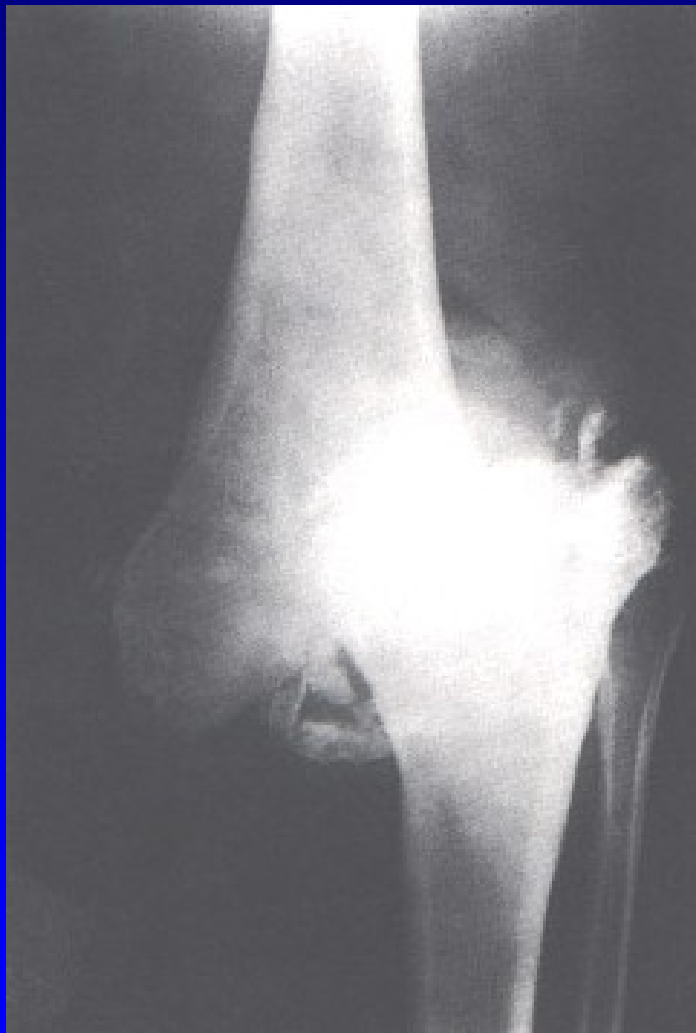Haemofilic arthropathy

Gout

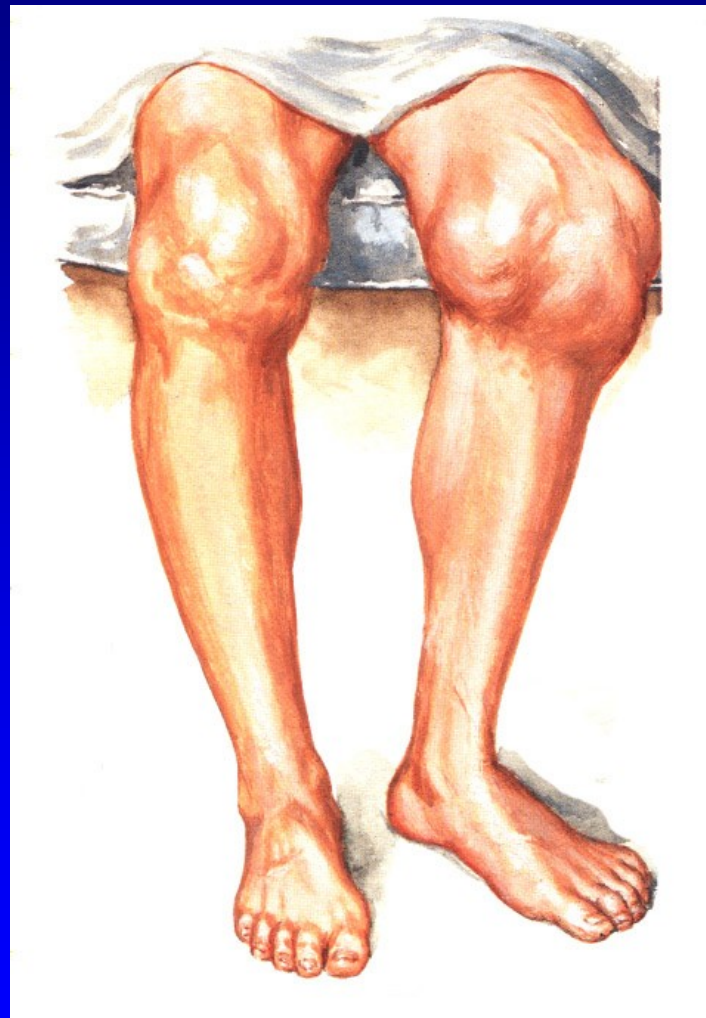
Chondrocalcinosis

Neurogenic arthropathy

Neurogenic arthropathy

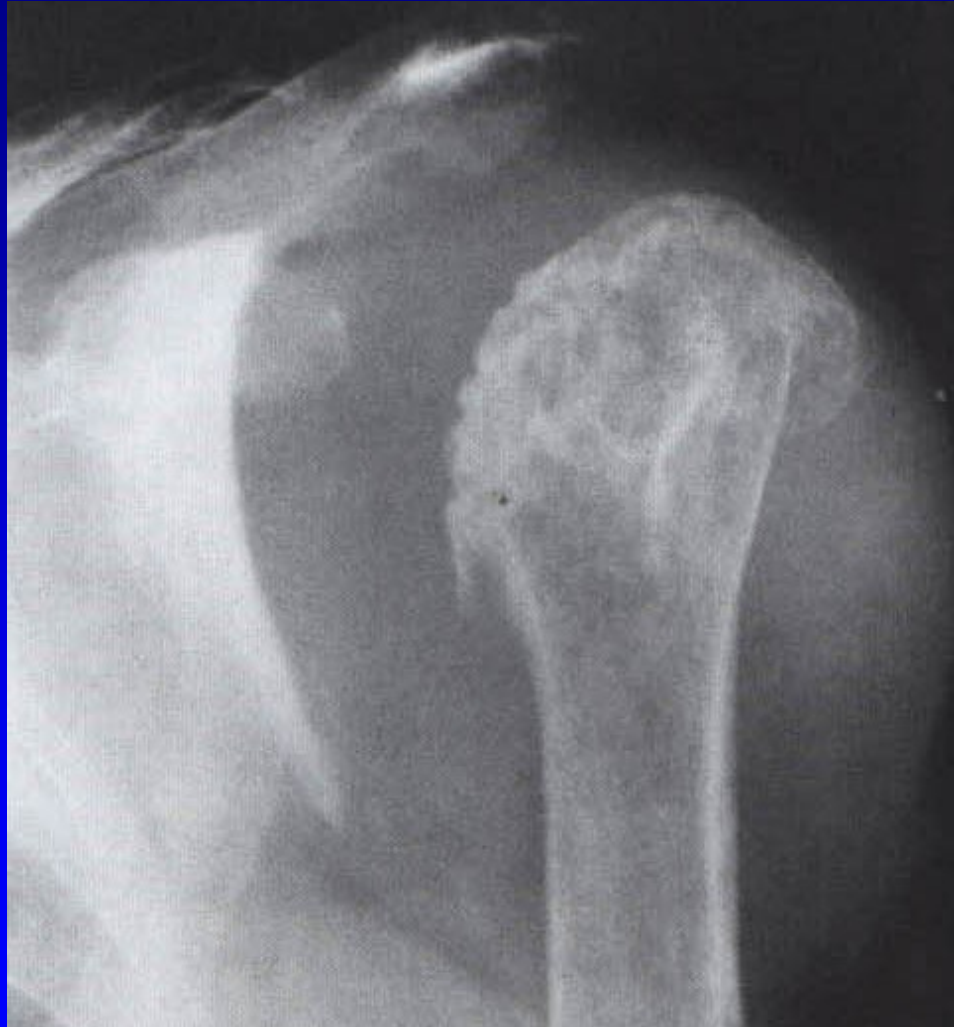

Obr. 30



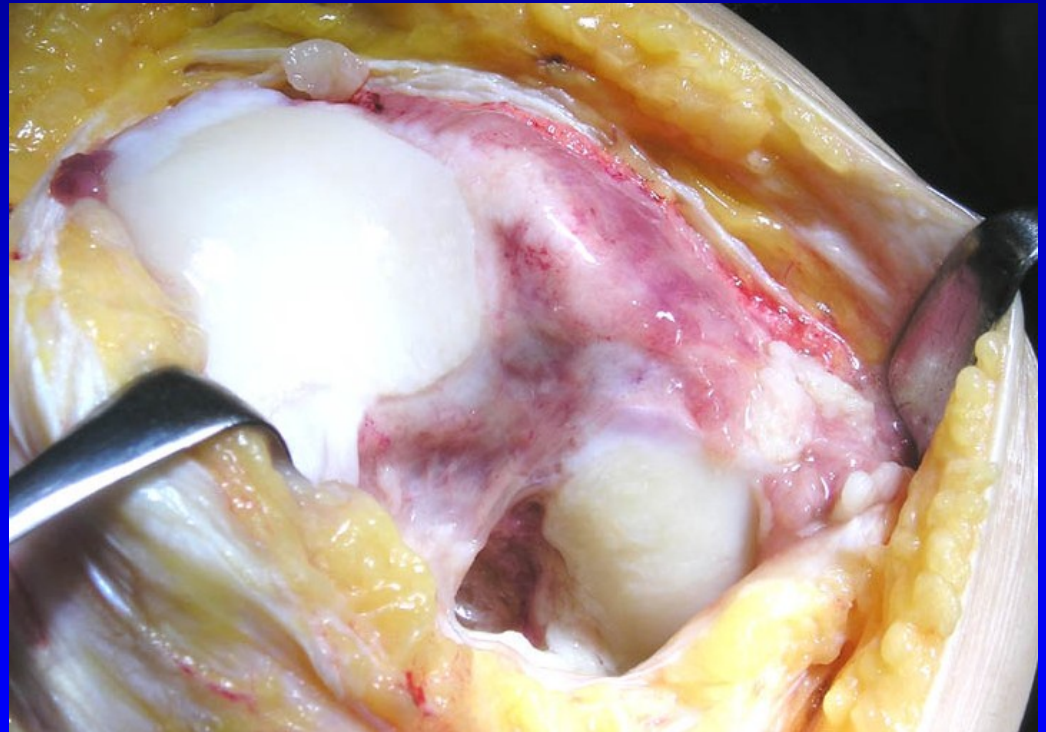
Obr. 31

Neurogenic arthropathy

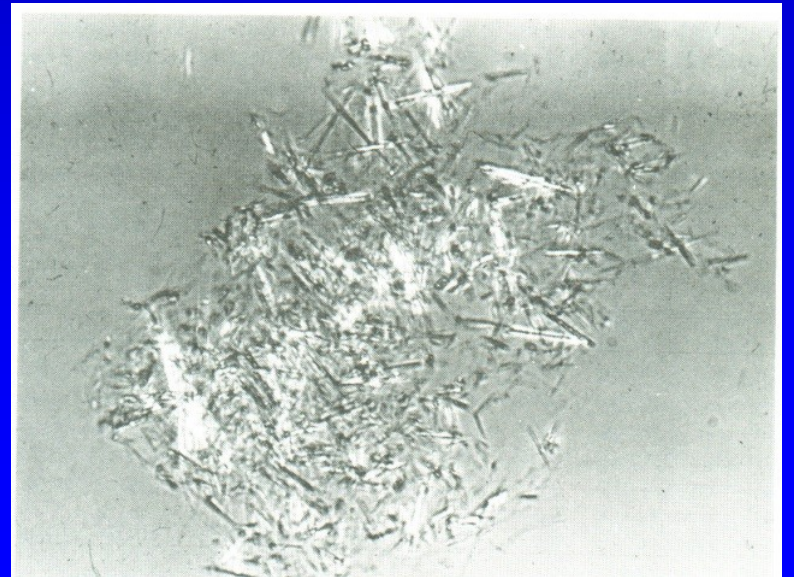
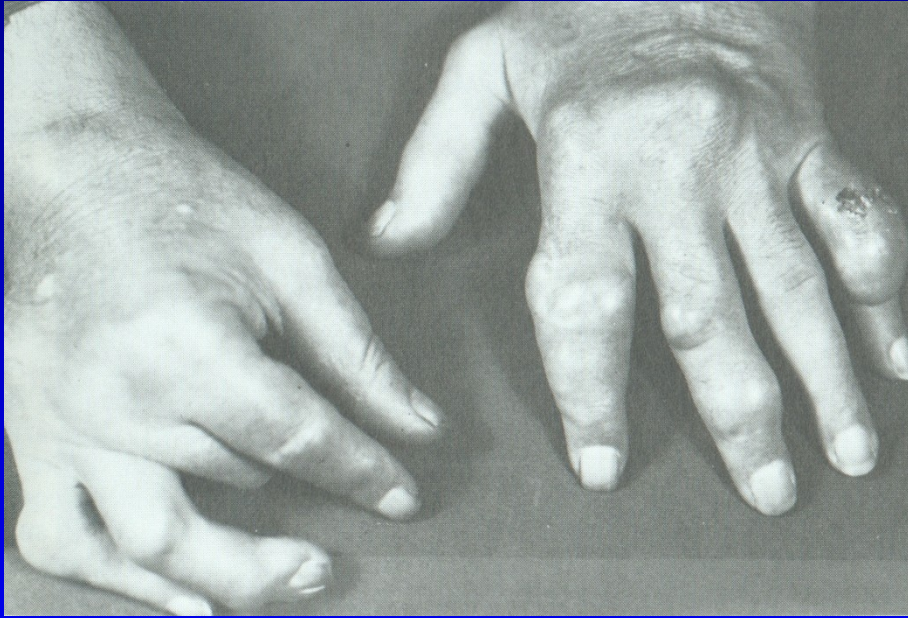

R.A.

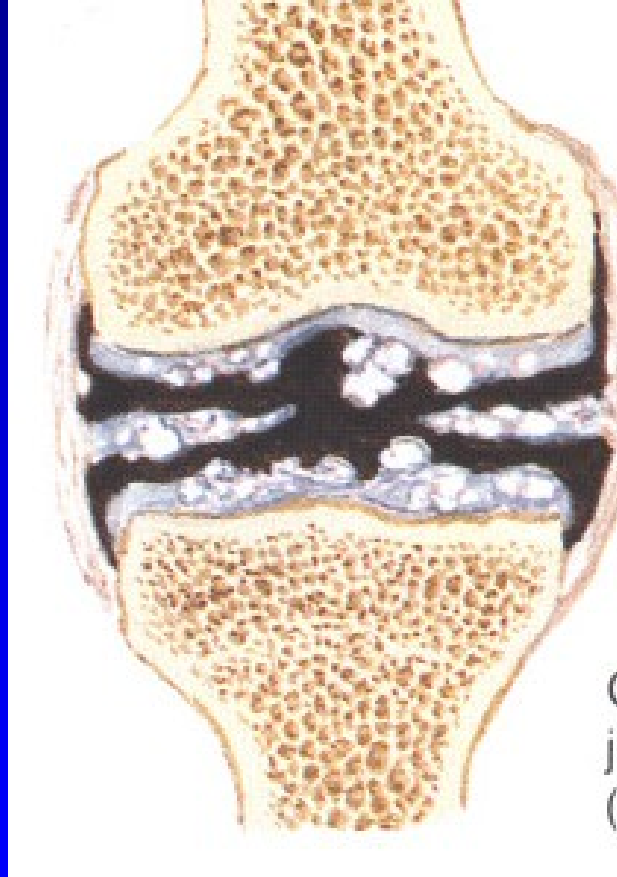- R.A.
- Juvenile R.A.
 - Still's disease



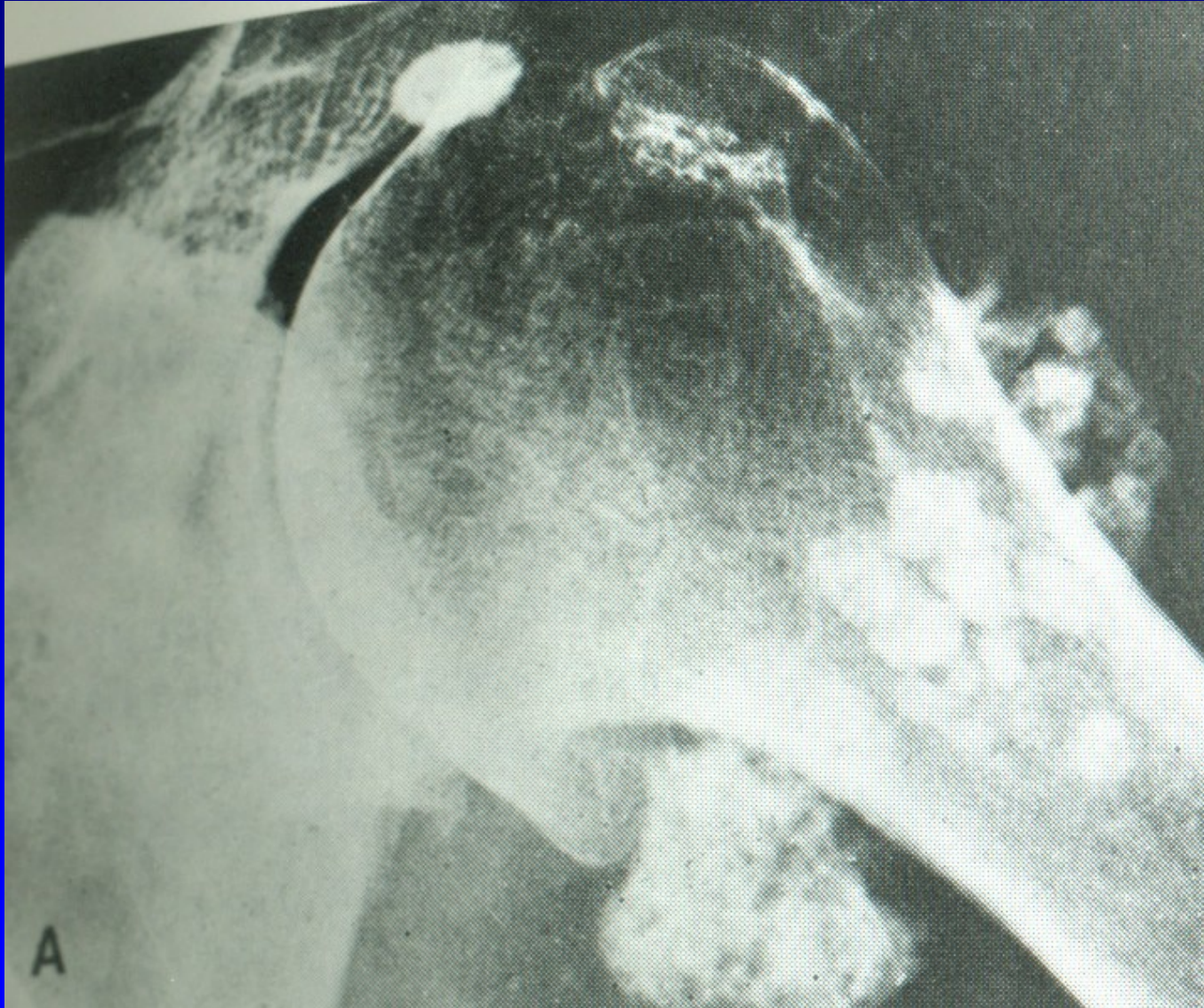Gout



Chondrocalcinosis



Synovial chondromatosis



Septic arthritis

