

**MUNI**  
**MED**

# **Systolic time intervals**

## **Apex beat**

## **Heart sounds**

Physiology – practice  
Spring, weeks 7th-9th

# Apex beat, heart sounds

Examination of external manifestations of cardiac activity using the senses:

- Inspection

- Configuration of the anterior chest - chest shape, postoperative scars and visible pulsations in this area

- Palpation

- Apex beat, heaves (systolic lifting of the sternum and left parasternal region), thrills (palpable vibration - murmur)

- Percussion

- Very approximate determination of heart size

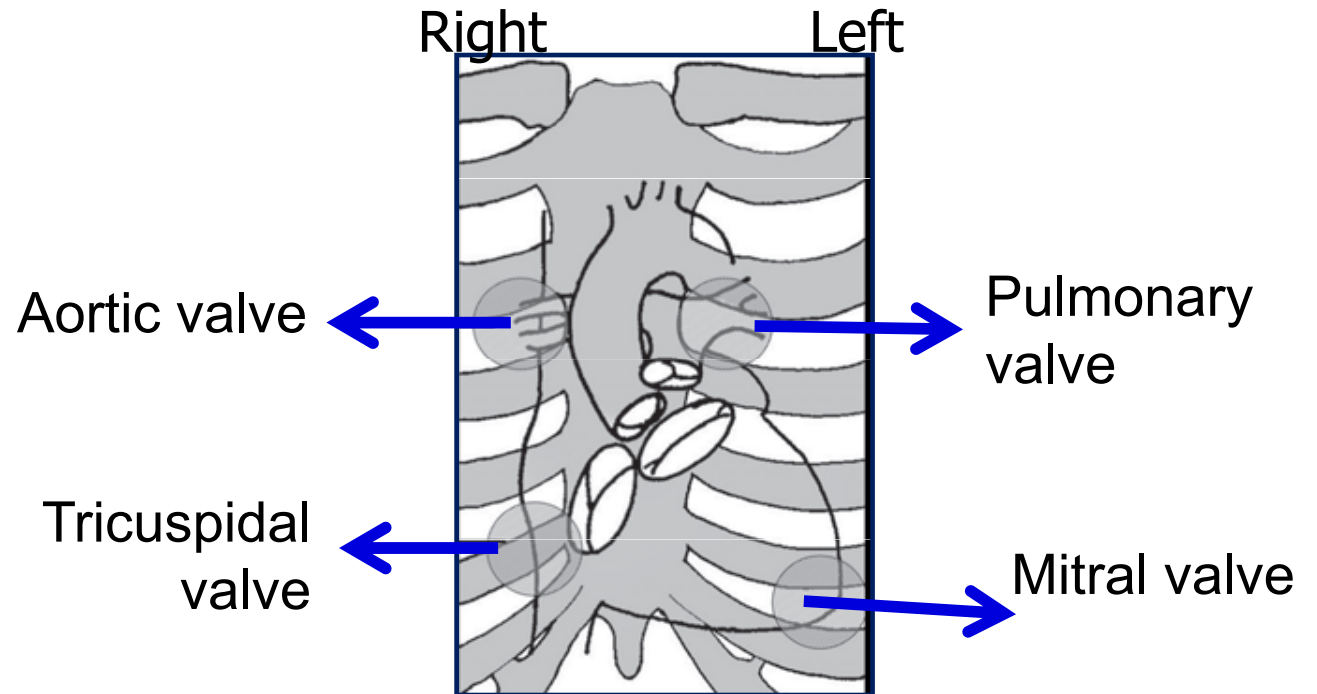
- Auscultation

# Apex beat

- The area where the heart apex is in the contact with the chest wall (1-2 cm medially from the midclavicular line in the 4th or 5th intercostal space)
- Localization of the maximal apex beat – palpation, inspection
- Examined mostly in the supine or half-sitting position
- A change in position of the maximal apex beat to the left + visible apex beat – signs of hypertrophy and dilatation of the left ventricle

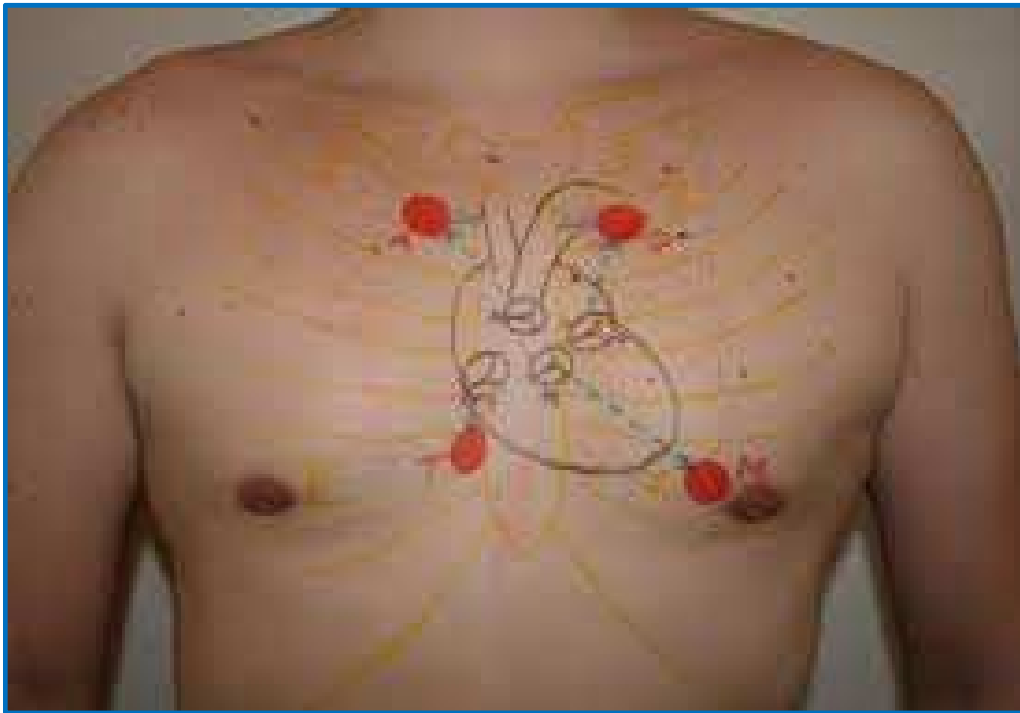
# Heart sounds – auscultation

- Ear
- Stethoscope
  - Bell
  - Diaphragm
- Microphone –  
phonocardiography



Heart valves auscultation points

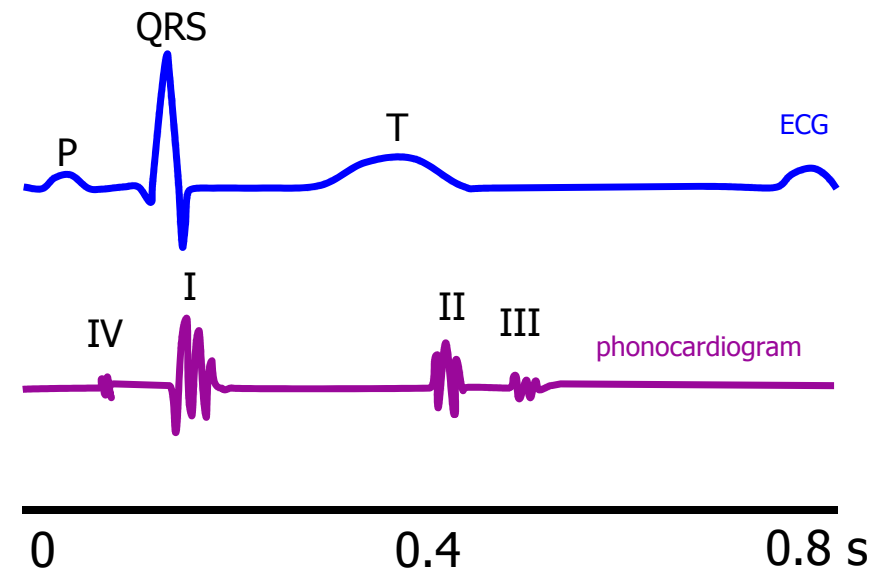
# Heart sounds – auscultation points



- **Aortic valve:**
  - 2nd intercostal space at the right sternal edge
- **Pulmonary valve:**
  - 2nd intercostal space at the left sternal edge
- **Mitral valve:**
  - 5th intercostal space in the midclavicular line  
= a site of apex beat
- **Tricuspidal valve:**
  - 5th intercostal space at the lower right sternal edge

# Heart sounds – phonocardiogram

- **1st sound:** mitral and tricuspid valve closure
- **2nd sound:** aortic and pulmonary valve closure
  - Systolic pause: between 1st and 2nd heart sound
  - Diastolic pause: between 2nd and 1st heart sound
- **3rd sound:** at the beginning of diastole, rarely heard mainly in young and athletes, in people older than 30 y. almost always a sign of pathology – dilated left ventricle
- **4th sound:** atrial systole, very rarely in children, in adults always pathological – hypertrophic left ventricle



# First heart sound (S<sub>1</sub>)

- A rapid increase in pressure at the beginning of ventricular systole and sudden opening and vibration of the mitral and tricuspid valves
- Low-frequency sound, almost only from the mitral valve
- Heard about 50 ms after the beginning of the QRS complex, duration of around 100 ms
- Best heard above the apex in the left supine position
  
- **CLINICALLY IMPORTANT:** assessment of heart sound's volume, especially amplification or attenuation of heart sounds, or split of the first sound

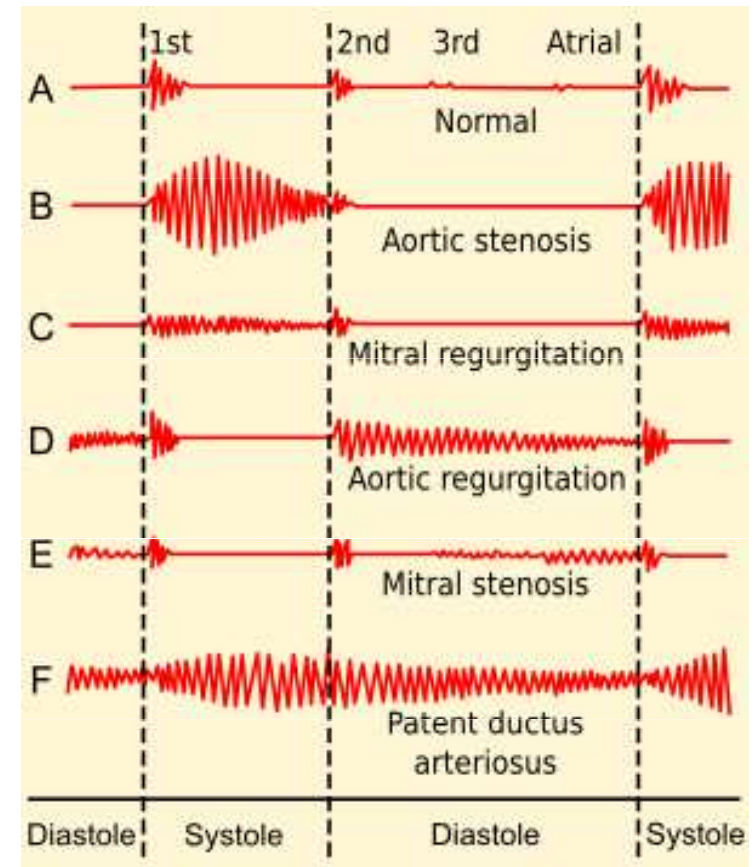
## Second heart sound (S<sub>2</sub>)

- Rapid vibrations of the aortic and pulmonary valves, associated with their closure
- A high-frequency sound that has two components – pulmonary and aortic, pulmonary one delays behind the aortic one, especially during deep inhalation
- Best heard above the apex in the left supine position
- **CLINICALLY IMPORTANT:** assessment of heart sound's volume, especially amplification or attenuation of heart sounds, or fixed split of the second sound



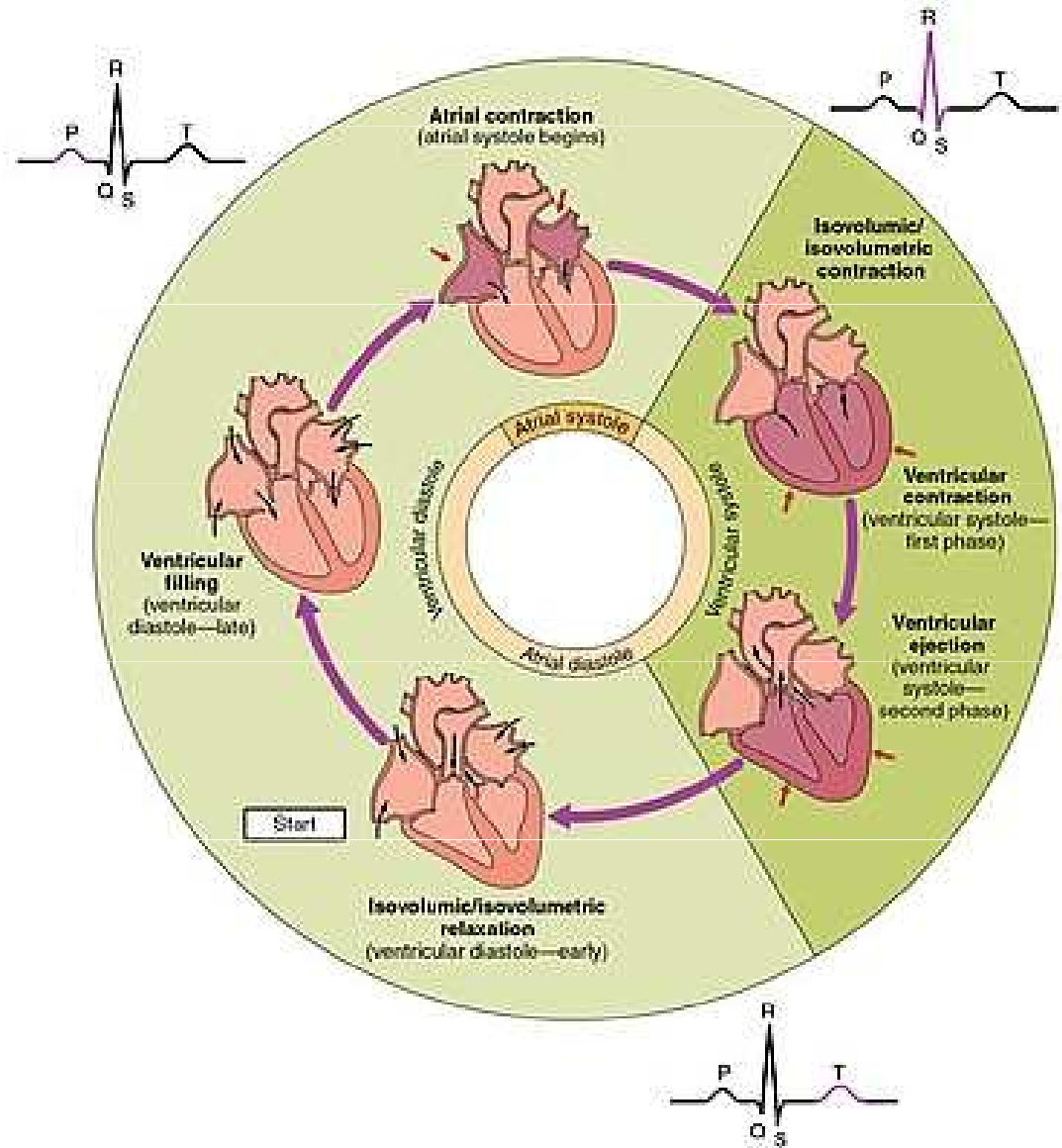
# Murmurs

Heart murmurs are produced as a result of turbulent flow of blood strong enough to produce audible noise. They arise mainly in places where the heart cavity or vessels are either narrowed or have an uneven surface.

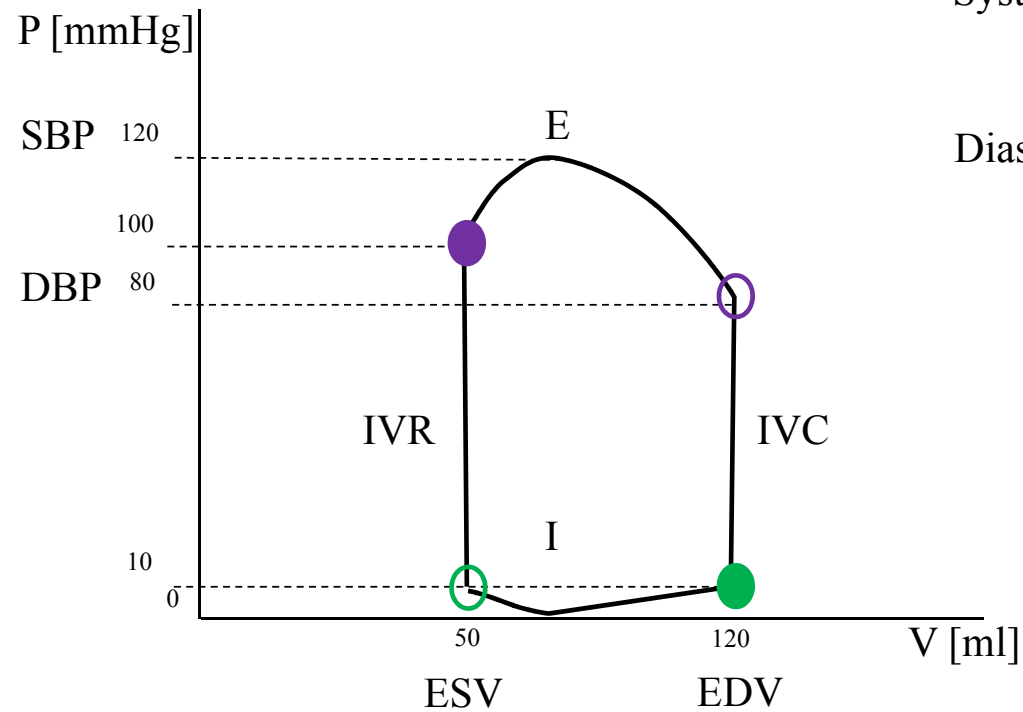


# Cardiac cycle

- Isovolumic contraction (IVC):
  - Contraction of ventricular myocardium leads to an increase in intraventricular pressure, AV valves close around 50 ms after the beginning of QRS, it produces 1st sound
- Ejection (E):
  - Intraventricular pressure overcomes diastolic pressure in big arteries, semilunar valves open, and blood flows to the arteries
- Isovolumic relaxation (IVR):
  - Semilunar valves close, rapid decrease in intraventricular pressure even below pressure values in atria, AV valves open
- Inflow (I):
  - Rapid inflow phase, slow inflow phase (ventricular diastole), atrial systole



# Cardiac cycle phases: PV (Wiggers) diagram



$$\text{Systole} = \text{IVC} + \text{E}$$

$$\text{IVC} = 0.06 \text{ s}$$

$$\text{E} = 0.21 \text{ s}$$

$$\text{Diastole} = \text{IVR} + \text{I}$$

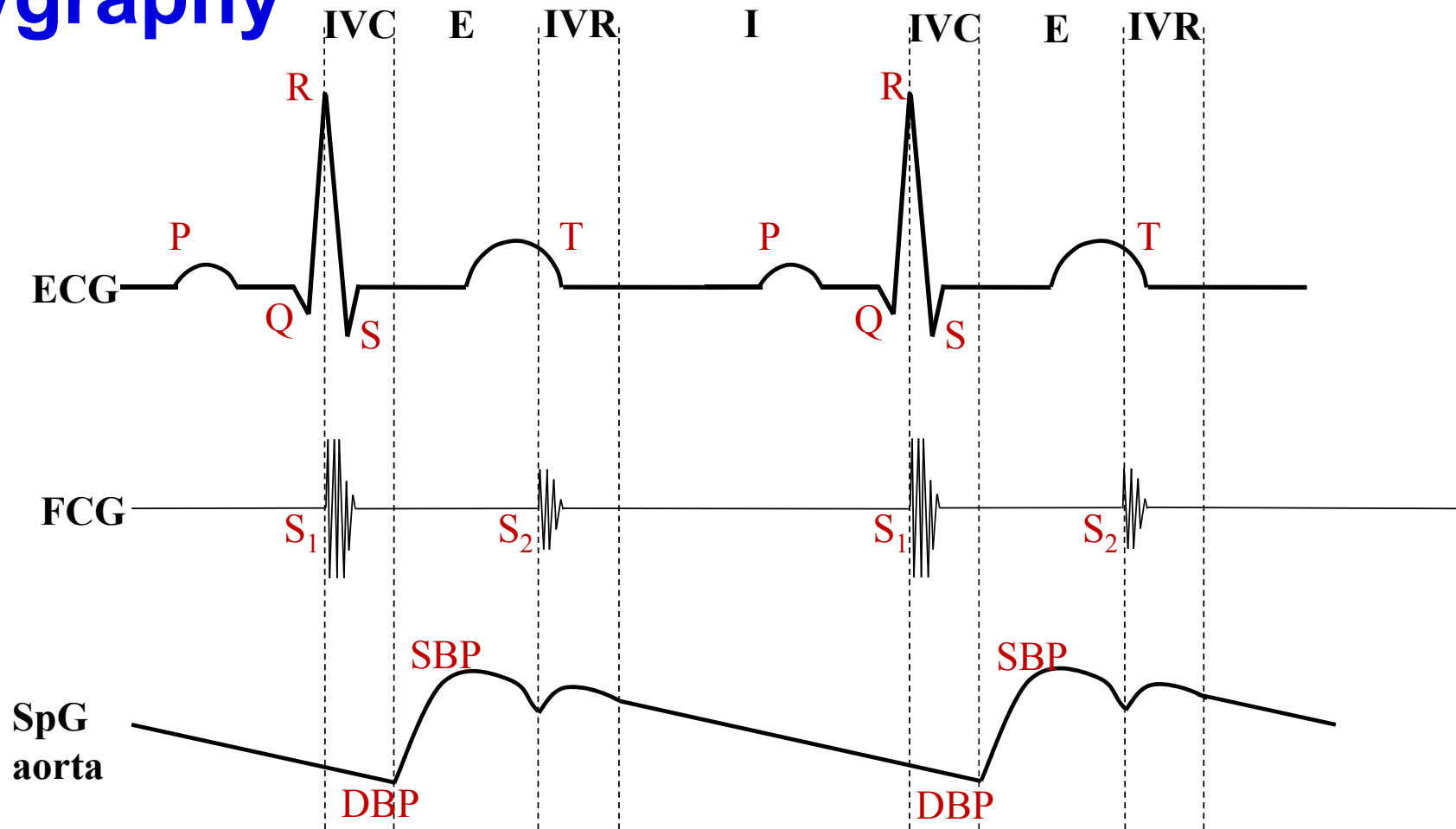
$$\text{IVR} = 0.07 \text{ s}$$

$$\text{I} = 0.49 \text{ s}$$

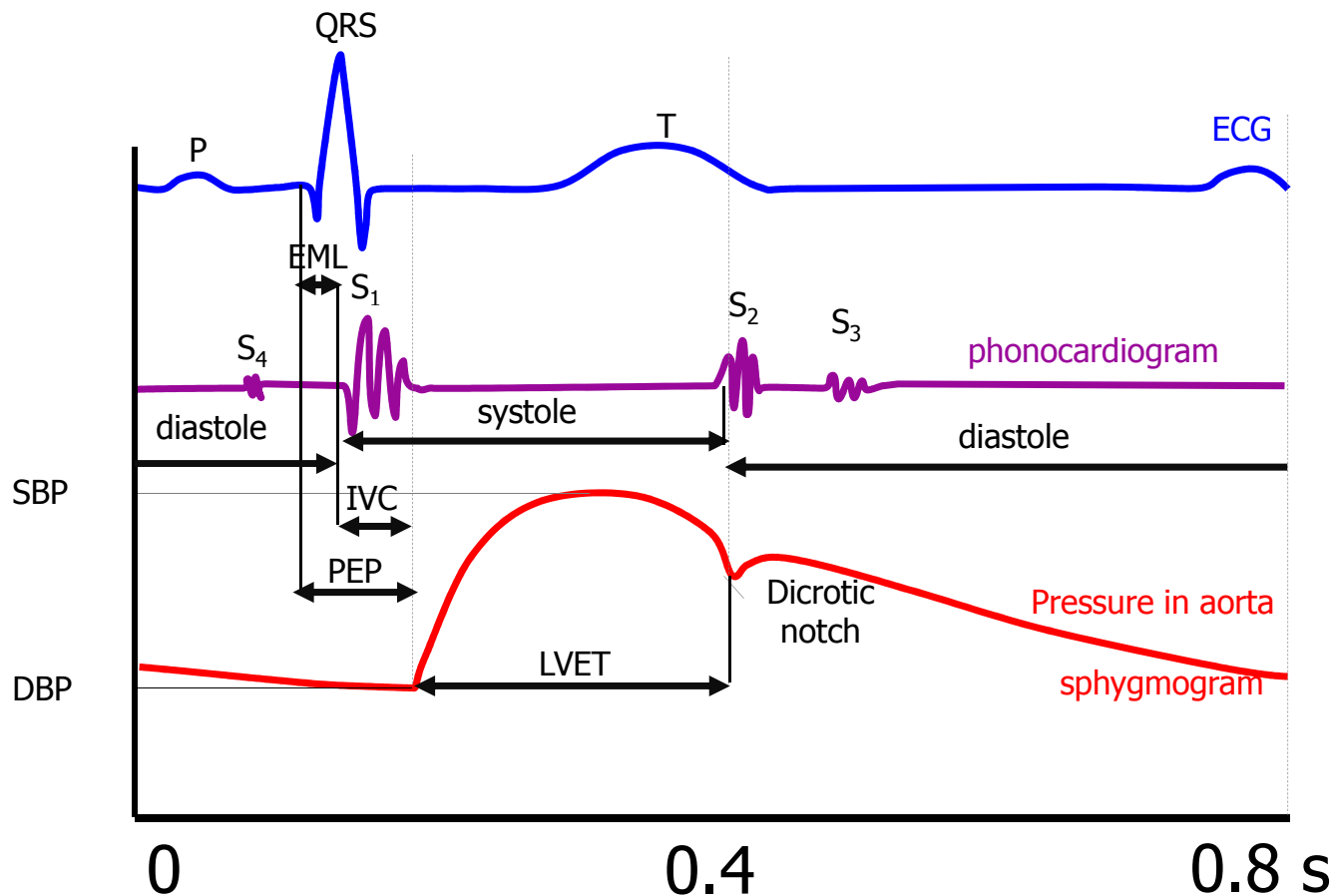
# Polygraphy

- Simultaneous recording of several physiological parameters using various non-invasive or invasive methods
- **Phonocardiography** – a graphical recording of heart sounds
- **Electrocardiography** – recording of cardiac electrical activity
- **Sphygmography** – a graphical record of the arterial pulse
- !notice: Pulse recorded on *a. carotis* is shifted in time in relation to aortal pulse!

# Polygraphy

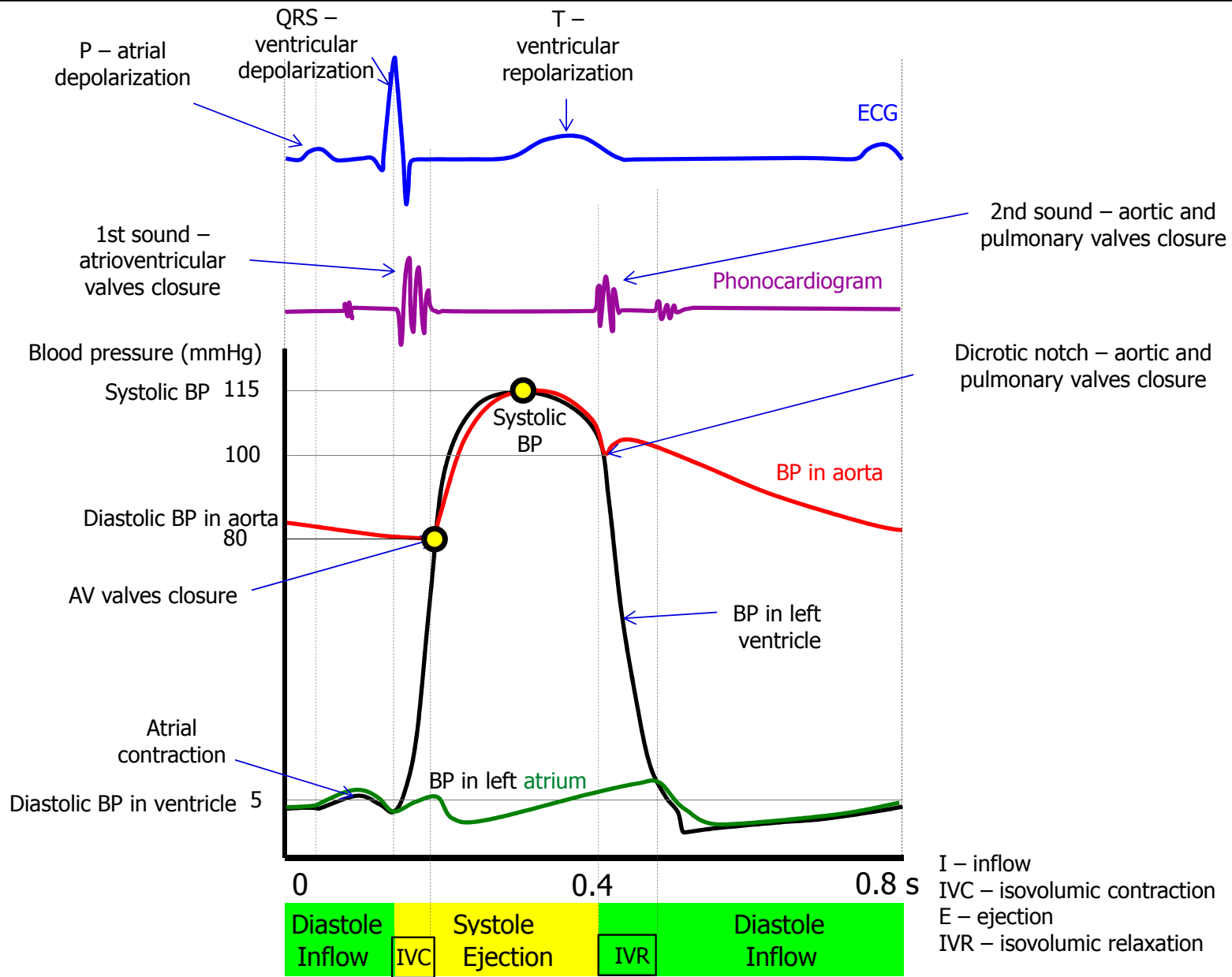


# Polygraphy

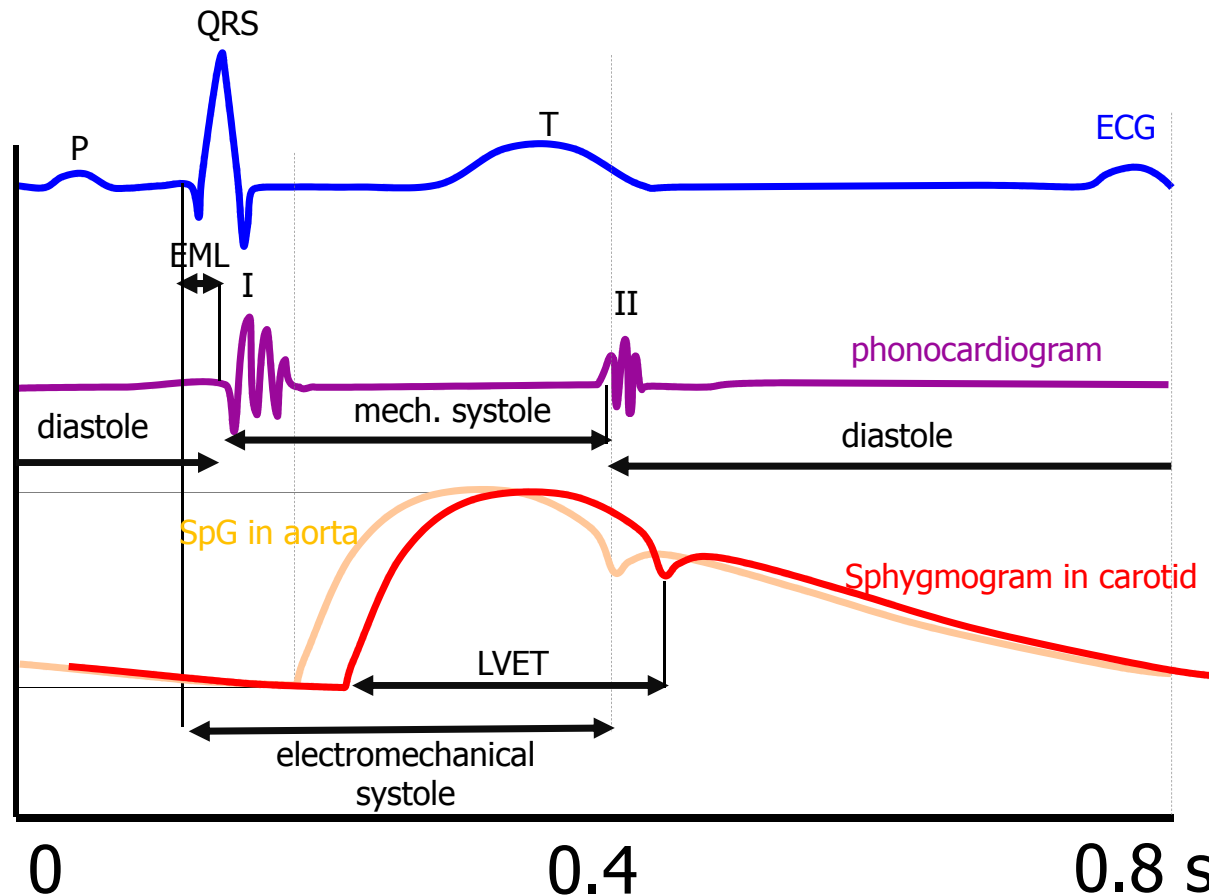


EML – electromechanical latency  
 IVC – isovolumic contraction  
 LVET – left ventricular ejection time  
 PEP – pre-ejection period (EML+IVC)

The sphygmogram (SpG) corresponds to the shape of the blood pressure curve, but with sphygmography, it is not possible to measure blood pressure values.



# Polygraphy – in practicals



The pressure wave in the carotid artery is time-shifted compared to the wave in the aorta



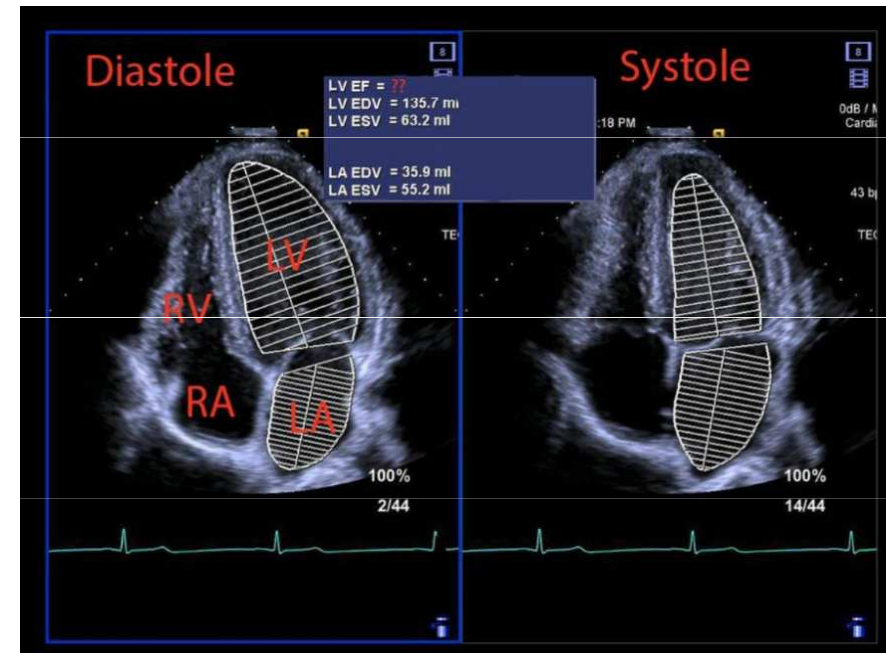
# Cardiac contractility indices – ejection fraction (EF)

$$EF = \frac{\text{systolic volume}}{\text{end - diastolic volume}}$$

- Normally, EF is around 60%. EF less than 40% is a sign of systolic dysfunction (contraction disorder). Such a low EF leads to a diagnosis of heart failure. But there are also heart failures with EF preserved.

[https://www.kardio-cz.cz/data/upload/doporucene\\_postupy/2016/Doporucene\\_postupy\\_pro\\_diagnostiku\\_a\\_lecbu\\_akutniho\\_a\\_chronickeho\\_srdecniho\\_selhani\\_2016.pdf](https://www.kardio-cz.cz/data/upload/doporucene_postupy/2016/Doporucene_postupy_pro_diagnostiku_a_lecbu_akutniho_a_chronickeho_srdecniho_selhani_2016.pdf)

- EF is influenced not only by contractility but also by the filling of the heart (Frank-Starling)
- Most often measured by ultrasound



# Cardiac contractility indices

- Relationship between end-diastolic BP (EDBP) and end-diastolic volume (EDV) at rest and during physical exercise
  - Systolic dysfunction – increase in EDV and EDBP during exercise compared to at rest
  - Diastolic dysfunction (relaxation disorder) – EDBP increases in exercise, EDV does not change
- Contractility indices derived from systolic ejection:

$$E_{\max} = \frac{dP}{dV}$$

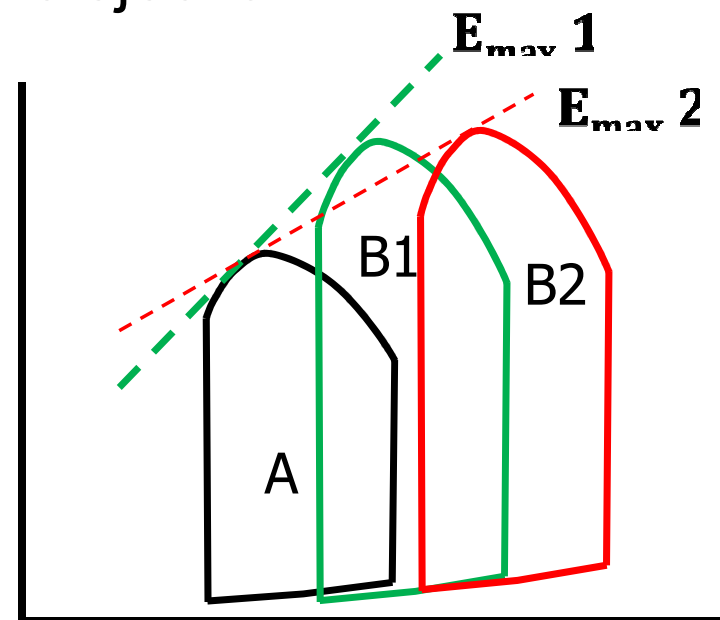
Sagawa-Suga index

**A:** normal P-V diagram

**B:** P-V diagram for artificially increased afterload

*1: healthy heart*

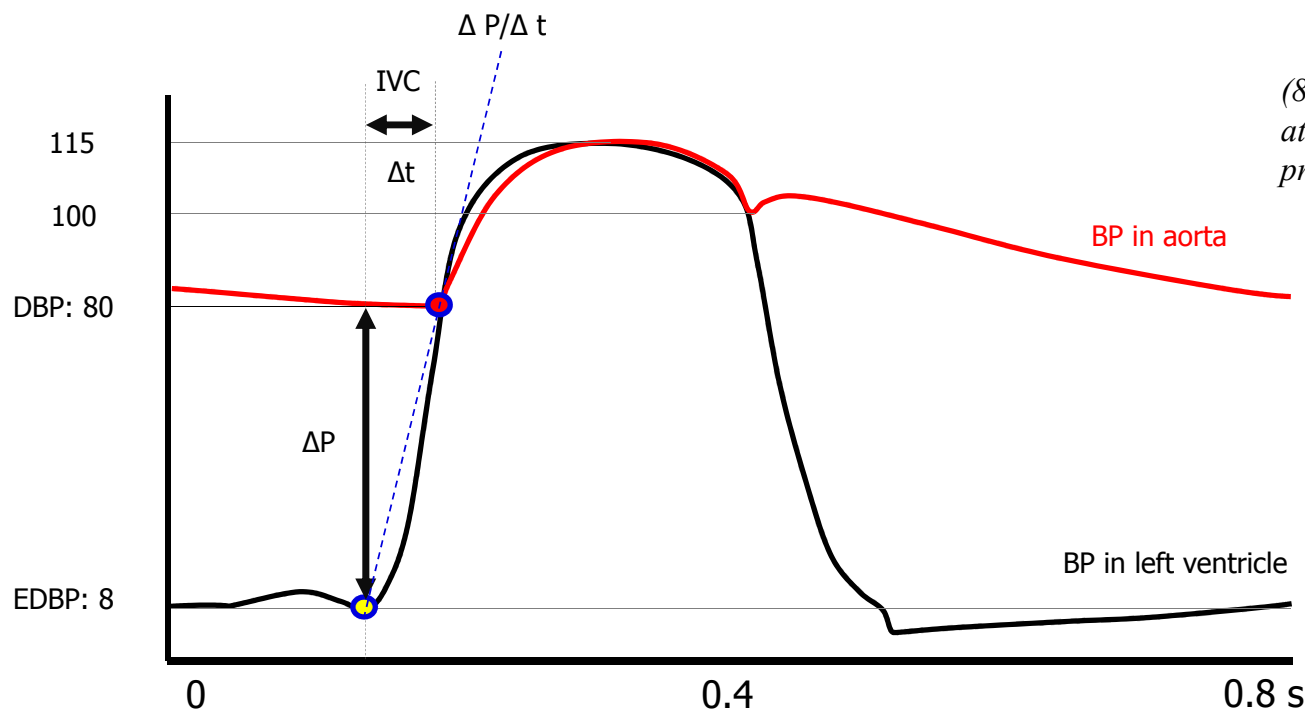
*2: failing heart*



# Cardiac contractility indices – $\Delta P/\Delta t$

- Contractility indices derived from isovolumic systolic phase:
  - In clinical practice, we determine the fastest velocity of increase in pressure during IVC (just before opening of semilunar valves – at the end of IVC)
  - In practicals, we determine a mean velocity of increase in pressure during IVC:

$$\frac{\Delta P}{\Delta t} = \frac{\text{pressure difference between the end and the start of IVC}}{\text{time duration of IVC}} = \frac{DBP - 8}{IVC}$$



*(8 mmHg corresponds approximately to the pressure at the end of the diastole, also approximately to the pressure in the left atrium)*

A slowed increase in ventricular pressure during IVC is a sign of impaired cardiac contractility

# Cardiac contractility indices – LVET and PEP

- The ratio of LVET to PEP – shortening of LVET and prolongation of PEP is a sign of decreased cardiac contractility.
- The heart spends most of its energy on reaching the opening pressure, and there is no energy left for blood ejection

