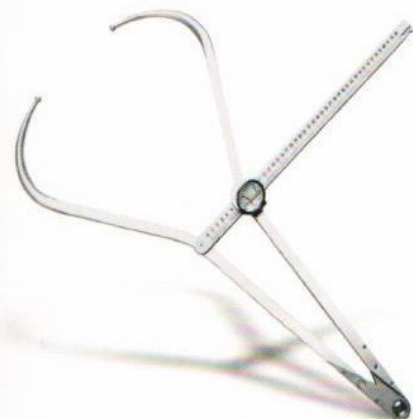

# BASIS OF CRANIOMETRY & CEPHALOMETRY

MUDr. Anna Rábová

Kefalometr K-211



■ Kefalometr – celkový pohled



■ Kefalometr – lupa



■ Kefalometr – ocelový kloub

## Craniometry

*the branch of physical **anthropology** dealing with the study and measurement of **dry skull** after removal of its soft part*

*technique used to measure the skull and determine human characteristics*

## Cephalometry

- *Is a measurement of the **head and facial structures***
- *In humans it's a subset of anthropometry, (measurement of the human body)*
- *Is used in **dentistry**, and especially in orthodontics, to gauge the **size and special relationships of the teeth, jaws, and cranium.***
- *This analysis informs about treatment planning, quantifies changes during treatment, and provides data for clinical research*

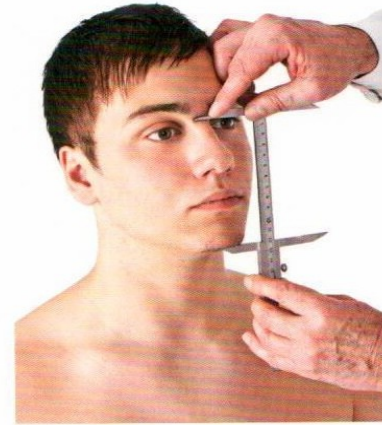

# The way of measurement

using antropometric instruments

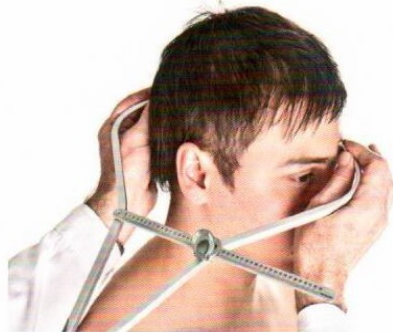(sliding gauge, cephalometr)

Obrázek 22.

Posuvné měřítko M-222  
praktické použití



Použití kefalometru při měření délky a šířky hlavy a šířky obličeje



■ délka hlavy




■ šířka hlavy



■ šířka obličeje

# Craniometric / cephalometric Points

- a landmarks on the skull from which craniometric measurements can be taken
  - PAIRED / UNPAIRED (in the central plane)
- 
- A decorative graphic consisting of several sets of concentric circles in a lighter blue shade, scattered across the bottom right portion of the slide.

# *The most important craniometric points*

Points marked with Greek or Latin names

## **Unpaired** – *in the middle line*

*nasion*

*glabella*

*bregma*

*lambda*

*opisthocranion*

*basion*

*akanthion*

*gnathion*

*orale*

*staphylion*

## **Paired**

*pteryon*

*porion*

*euryon*

*zygion*

*gonion*

*endomolare*

# UNPAIRED

bregma

glabella

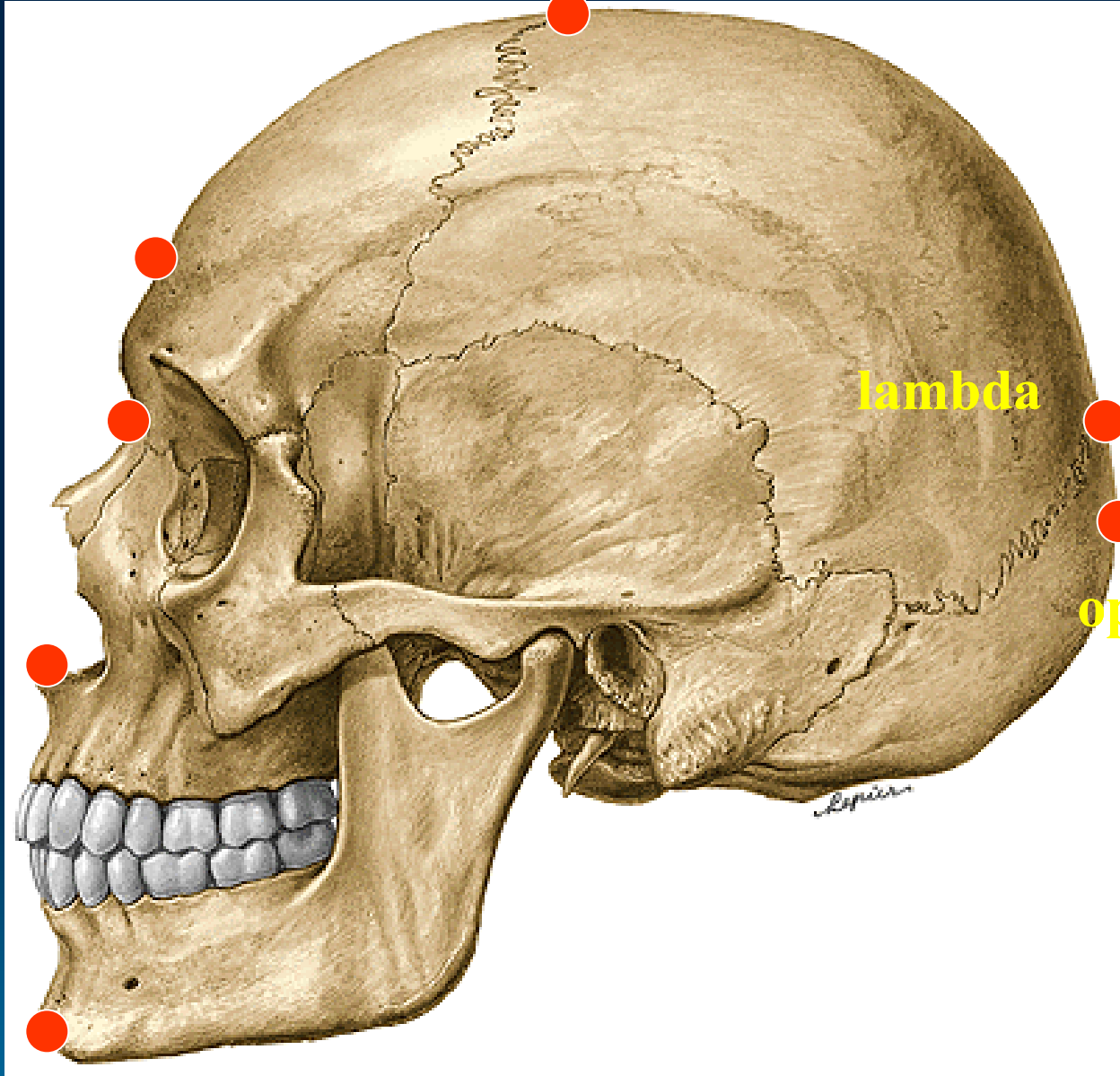
nasion

akanthion

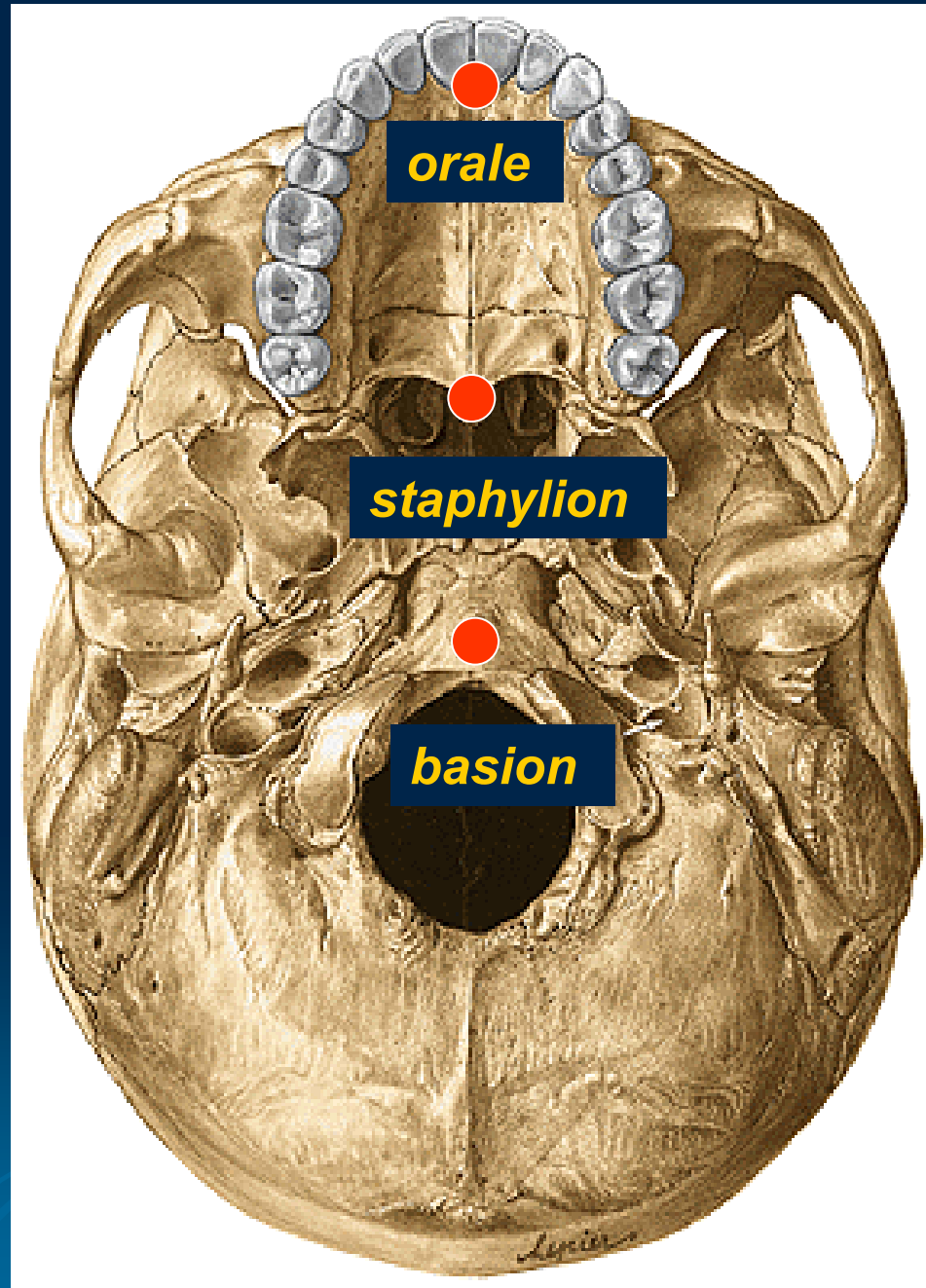
gnathion

lambda

opistocranium

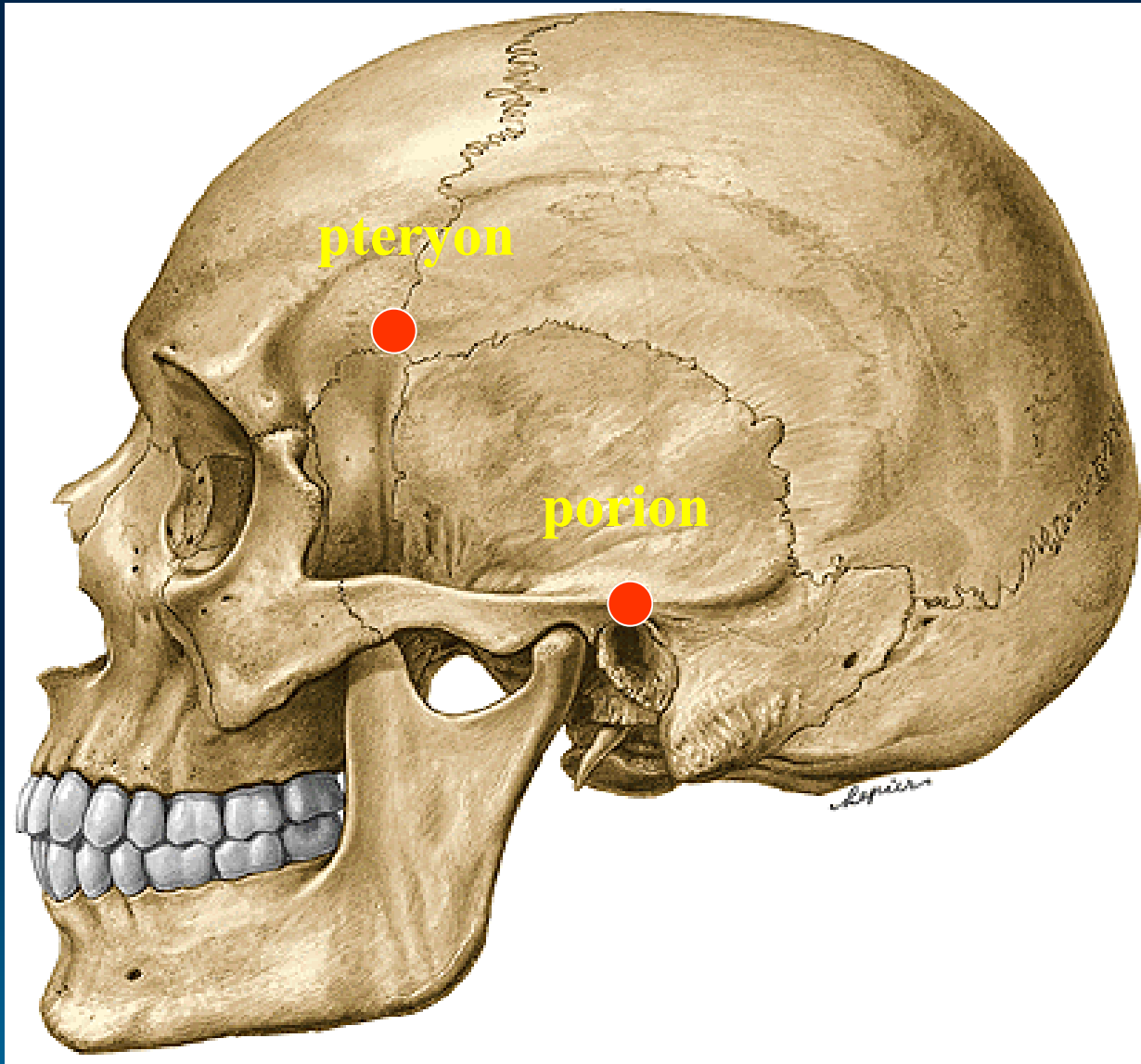


# UNPAIRED





# PAIRED



# PAIRED

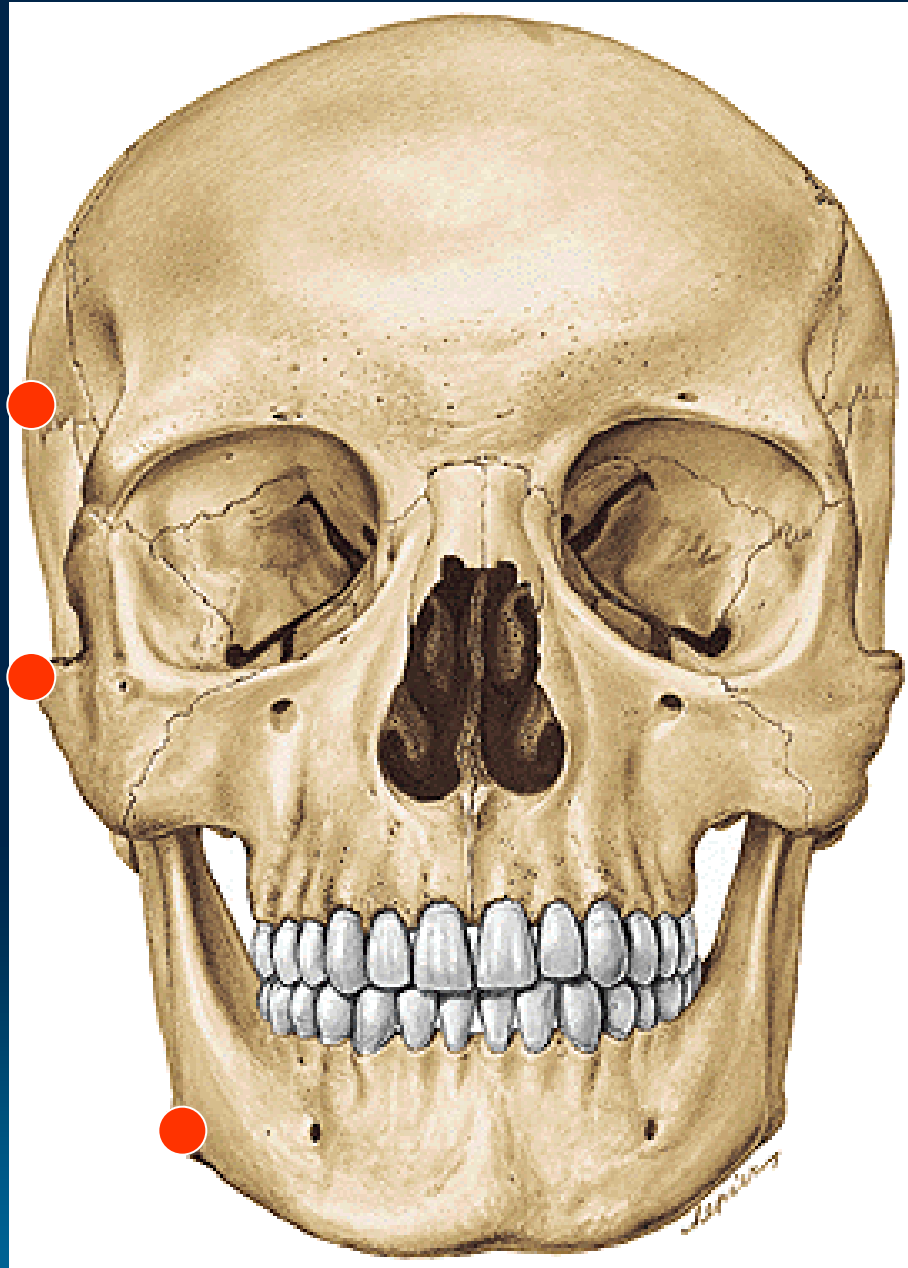
**euryon**



**zygion**

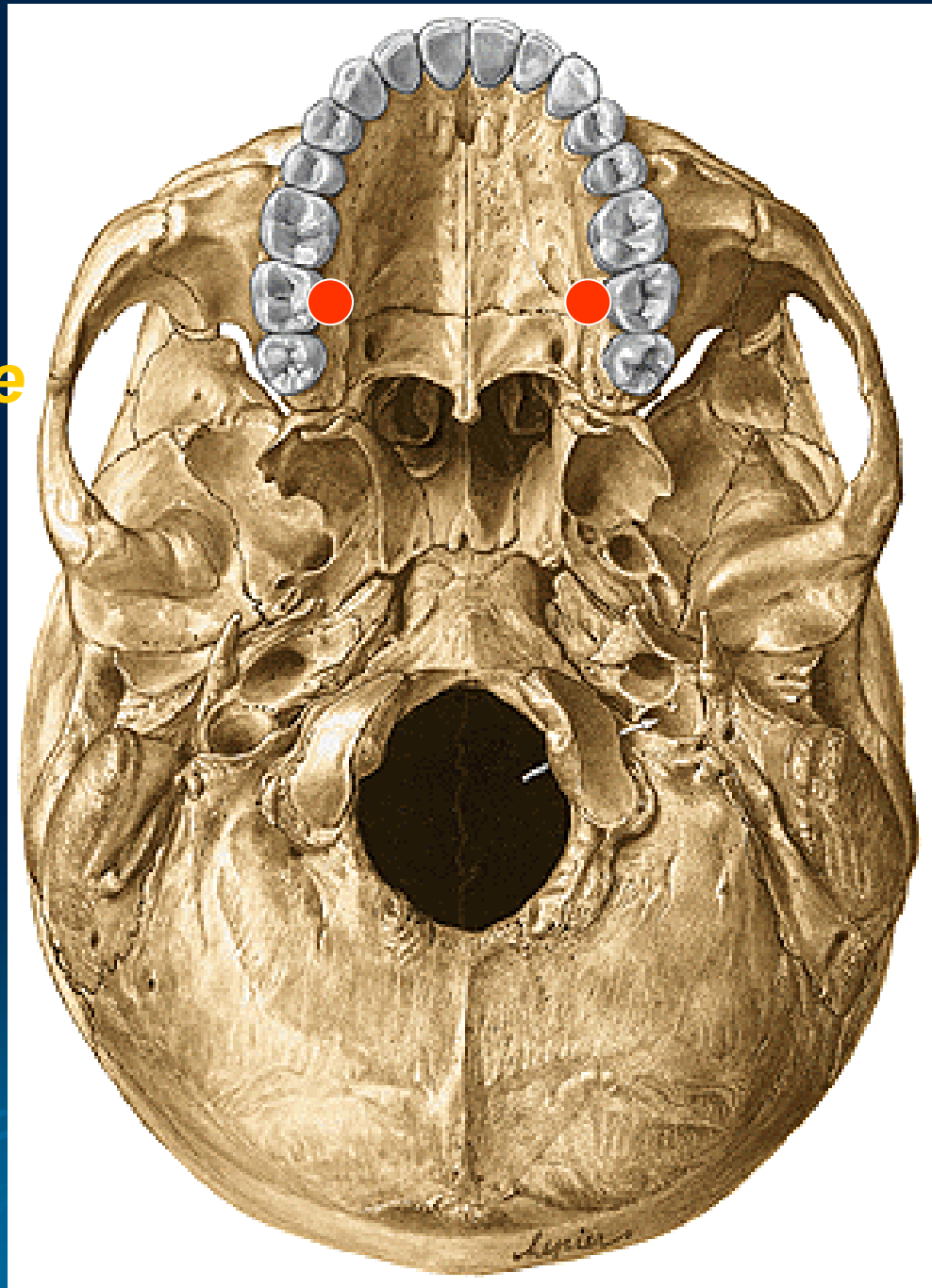


**gonion**

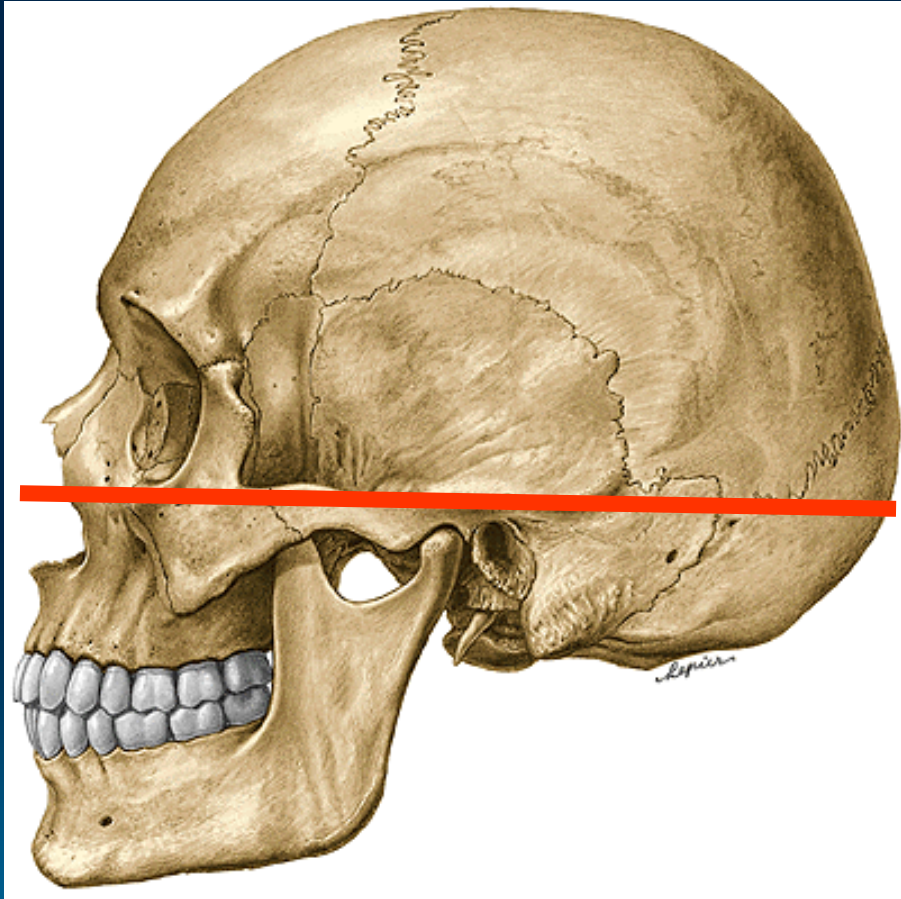


PAIRED

*endomolare*



# Frankfurt horizontal plane



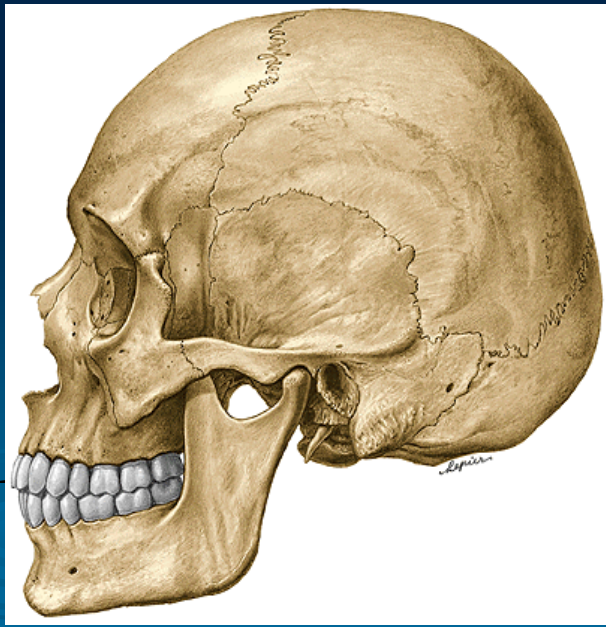
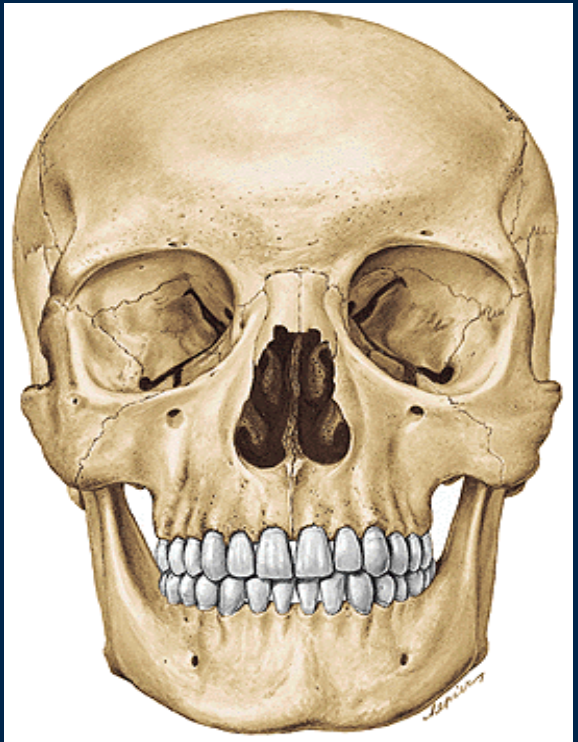
a horizontal plane represented in profile by a line between the lowest point on the margin of the orbit (orbitale) to the highest point on the margin of the auditory Meatus (porion)

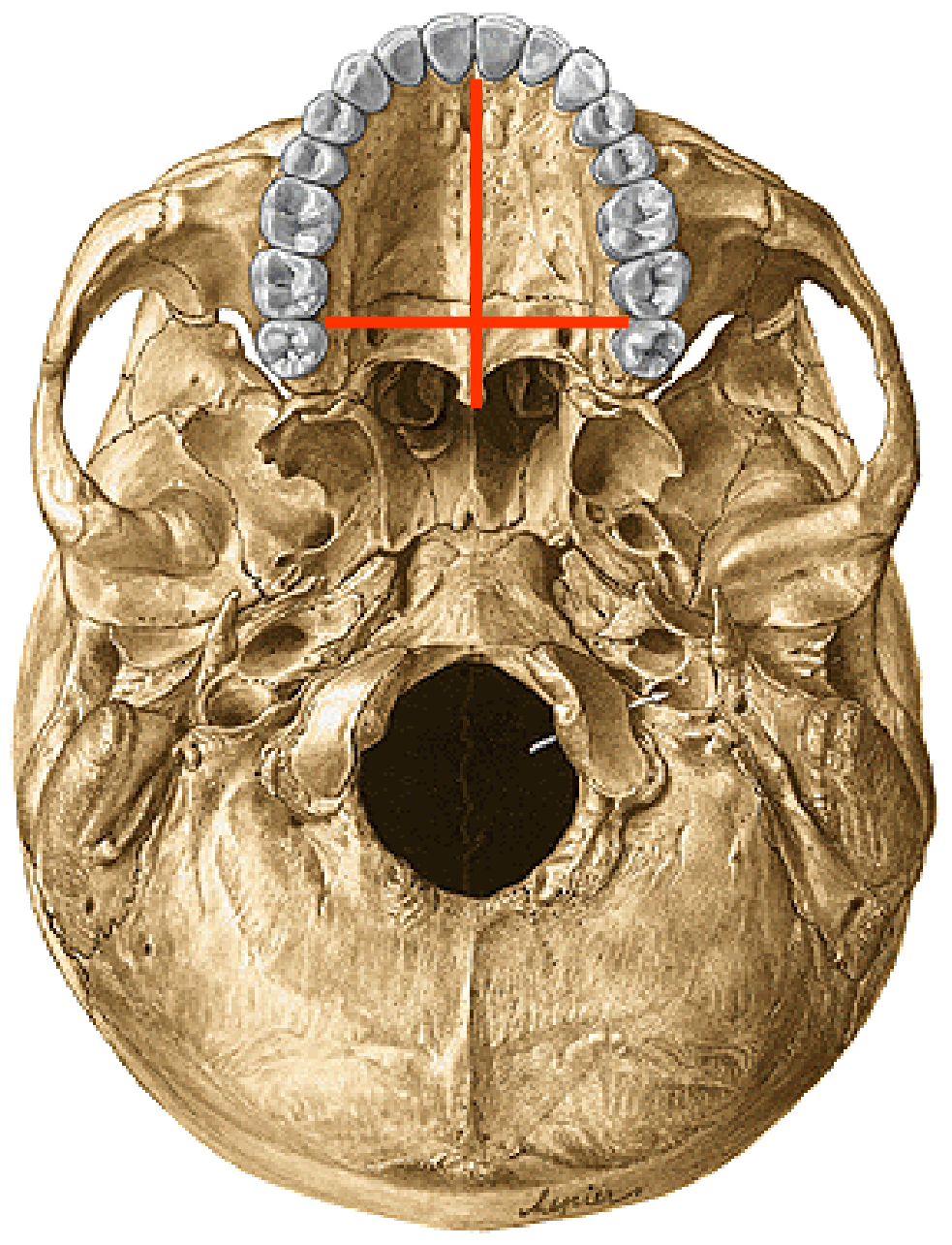
***linea horizontalis auriculoorbitalis***

# The Size Of The Human Skull

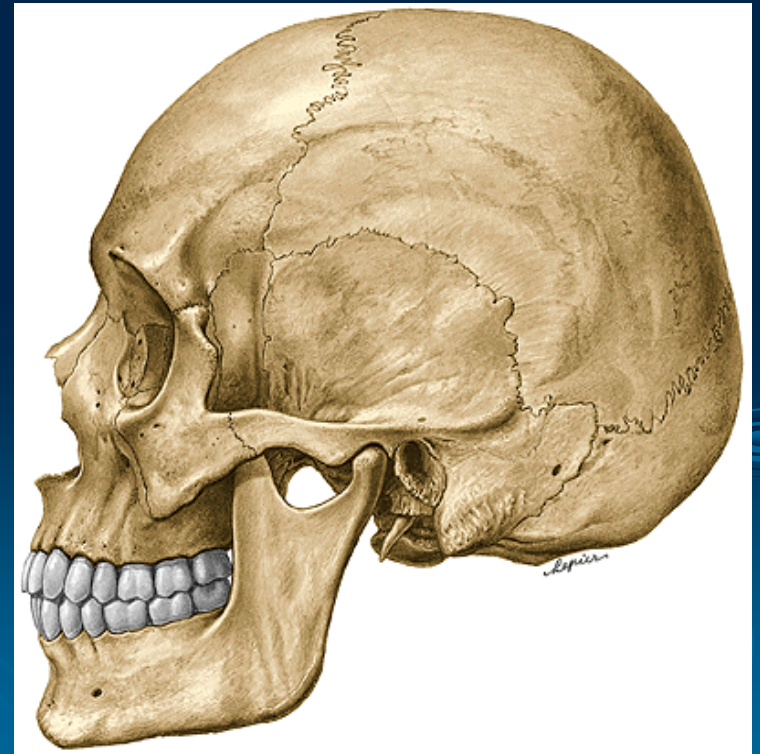



	FROM	TO
<b>Length</b>	glabella	opisthocrani on
<b>Width</b>	euryon	euryon
<b>Height</b>	bregma	basion
<b>Facial length</b>	nasion	gnathion
<b>Facial width</b>	zygion	zygion
<b>Palatal width</b>	endomolare	endomolare
<b>Palatal length</b>	orale	staphylion



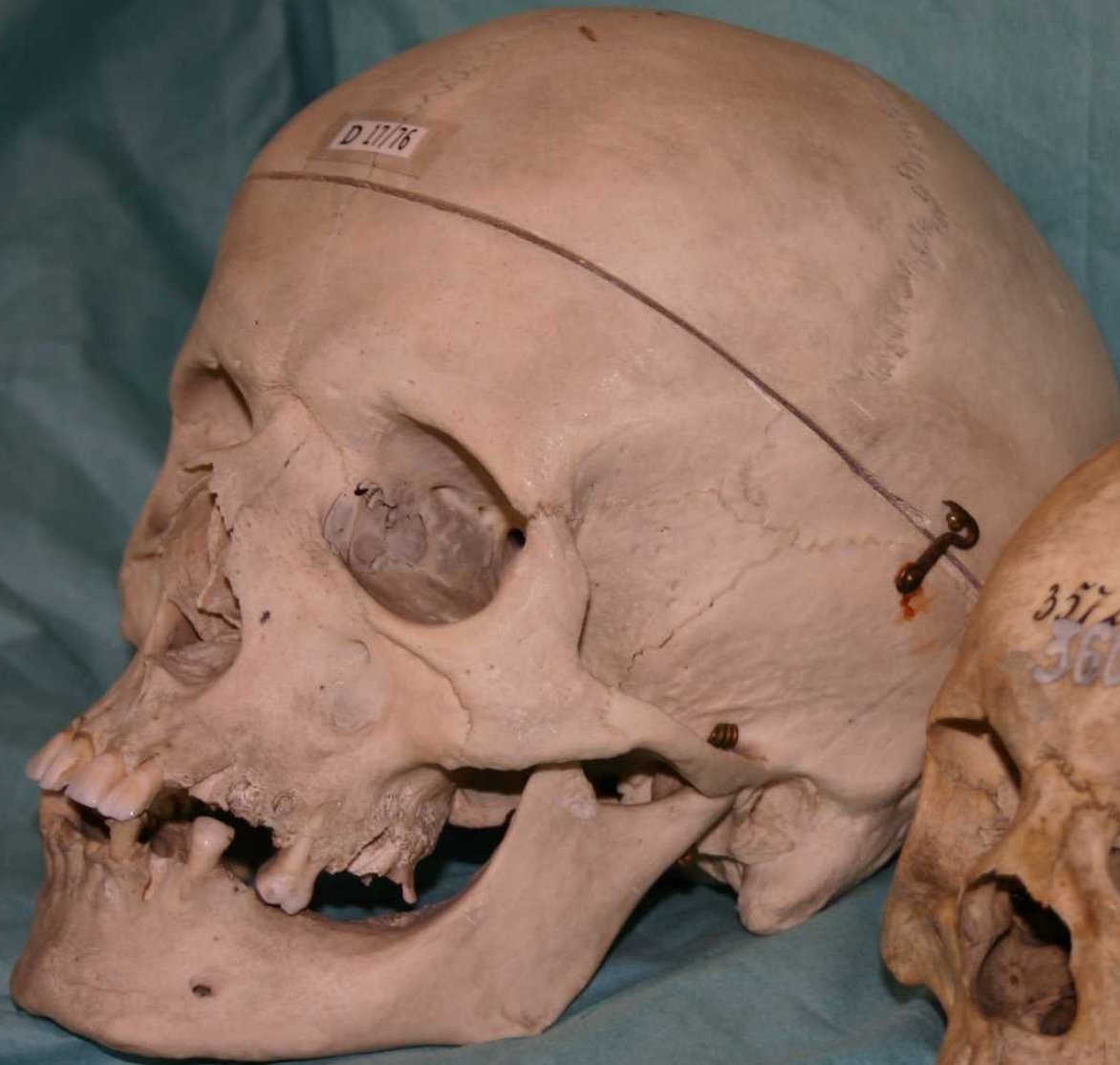

Peripheral measurement -  
***circumferentia horizontalis***  
***frontooccipitalis*** measured through glabella  
and opisthocranium



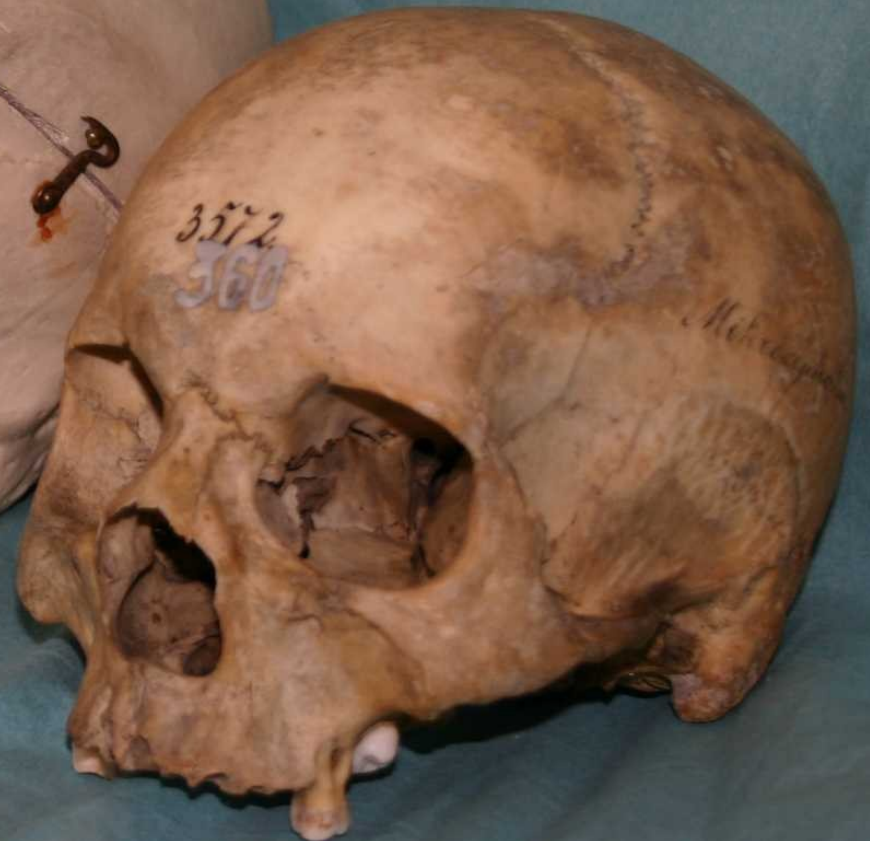

# Variability in the skull size



**Makrocephaly**

**Mikrocephaly**



We distinguish several **specific views** on the measured skill –

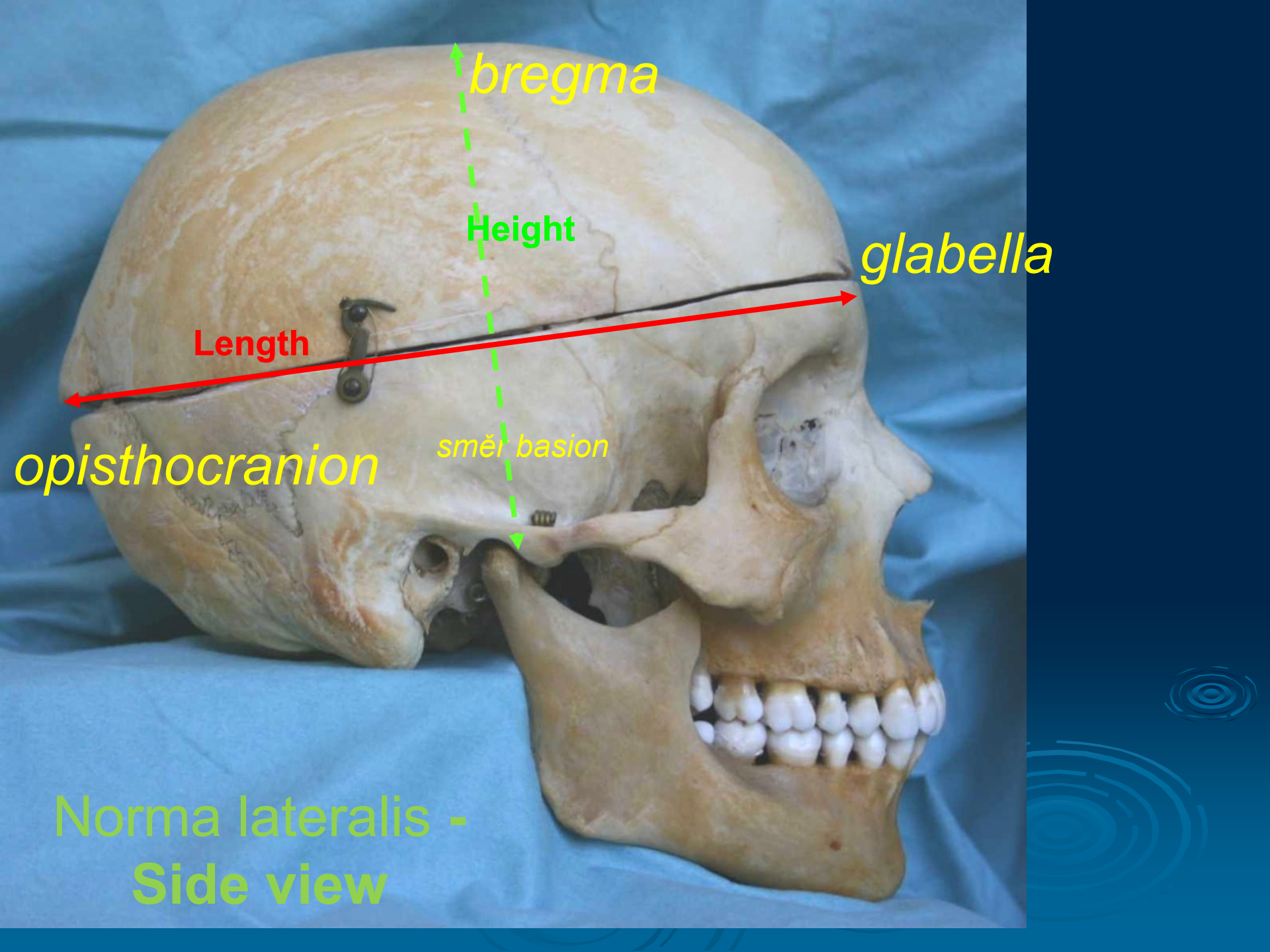
side view

front view

view from above

to be able to compare objectively





*bregma*

**Height**

*glabella*

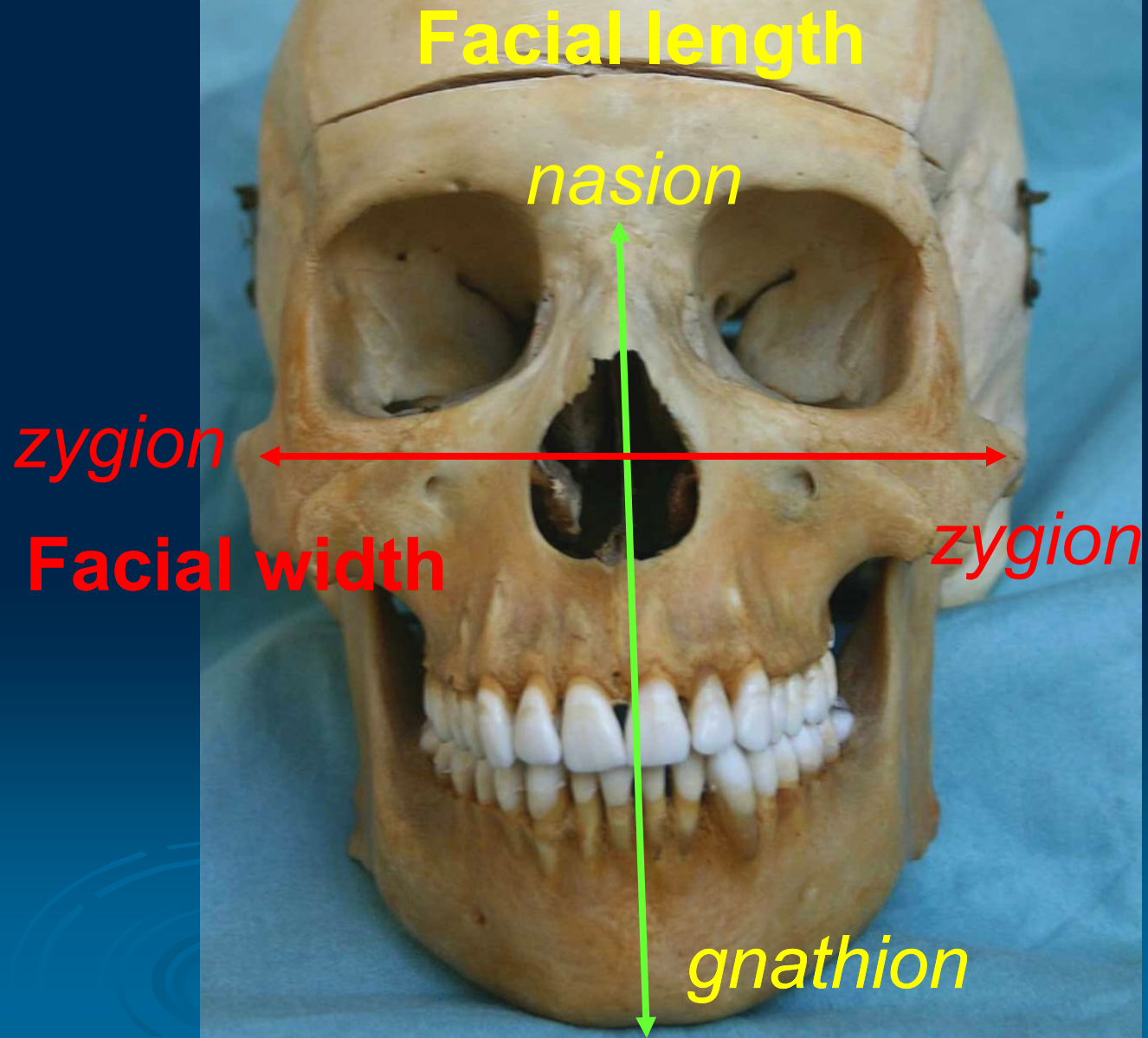
**Length**

*opisthocranium*

*sphen. basion*

**Norma lateralis -  
Side view**

*Norma frontalis –  
front view*



*Norma verticalis –  
view from above*

*euryon*

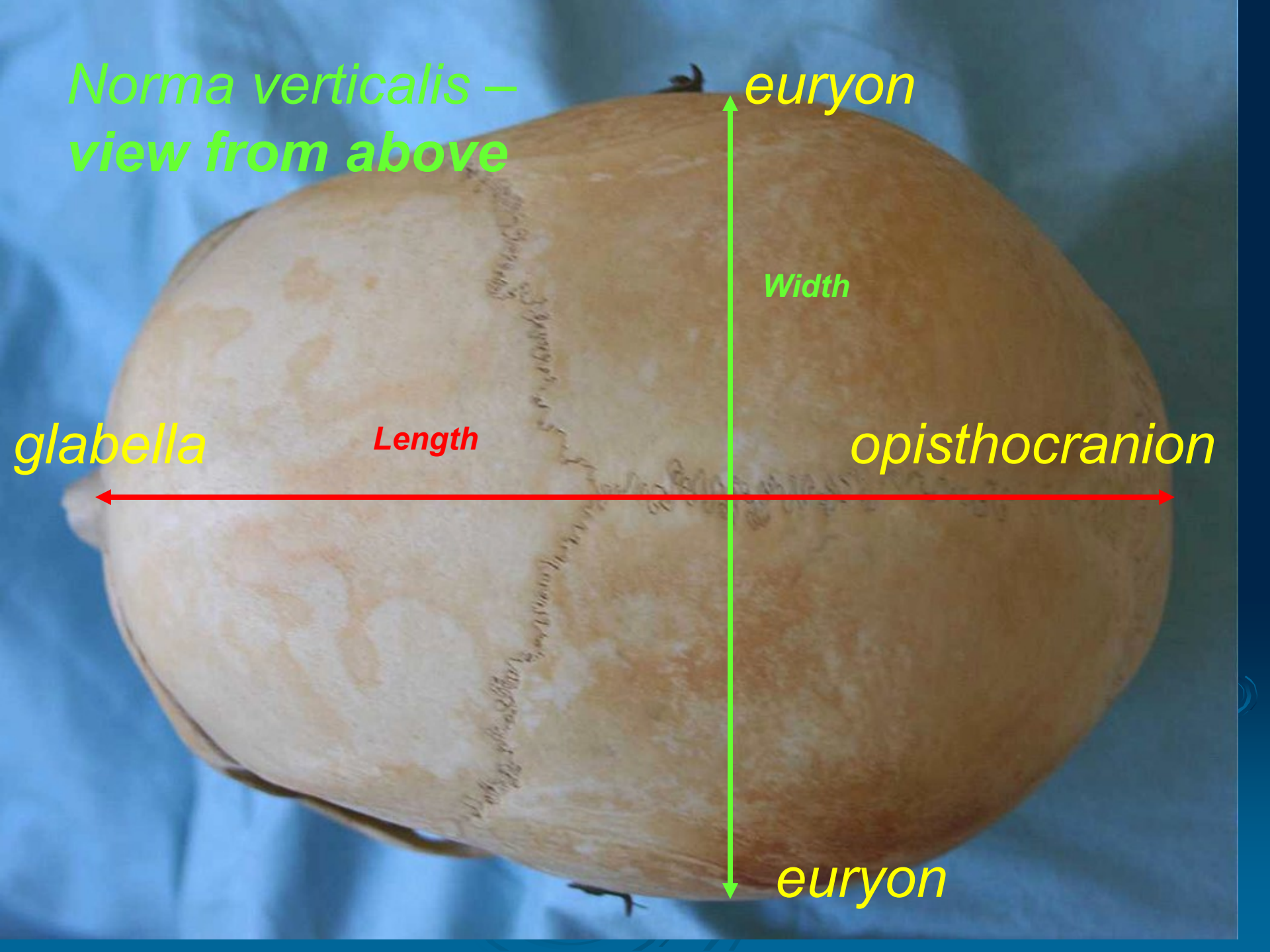
*Width*

*Length*

*opisthocranion*

*glabella*

*euryon*



On the basis of measured parameters we can calculate

***indexes:***

### **Cephalic index (CI)**

the ratio of the maximum width of the head multiplied by 100 and divided by its maximum length

### **Facial index (FI)**

the ratio of the length of the face multiplied by 100 divided by width

### **Palatamaxillary index (PMI)**

the ratio of the length of the hard palate to its breadth (width) multiplied by 100

CI	<b>Dolichocephalic</b> $x - 74,9$ ( <i>long-headed</i> )
	<b>Mesocephalic</b> $75,0 - 79,9$ ( <i>medium-headed</i> )
	<b>Brachycephalic</b> $80,0 - x$ ( <i>short-headed</i> )
FI	<b>Leptoprosopic</b> $90,9 - x$ ( <i>long narrow face</i> )
	<b>Mesoprosopic</b> $85,0 - 89,9$ ( <i>average width face</i> )
	<b>Euryprosopic</b> $x - 84,9$ ( <i>short broad face</i> )
PMI	<b>Leptostaphylic</b> $x - 79,9$ ( <i>narrow palatum</i> )
	<b>Mesostaphylic</b> $80,0 - 84,9$ ( <i>average width</i> )
	<b>Brachystaphylic</b> $85,0 - x$ ( <i>broad palatum</i> )

# Clinical Diagnosis of Orofacial Anomalies

Use of craniometry in dentistry

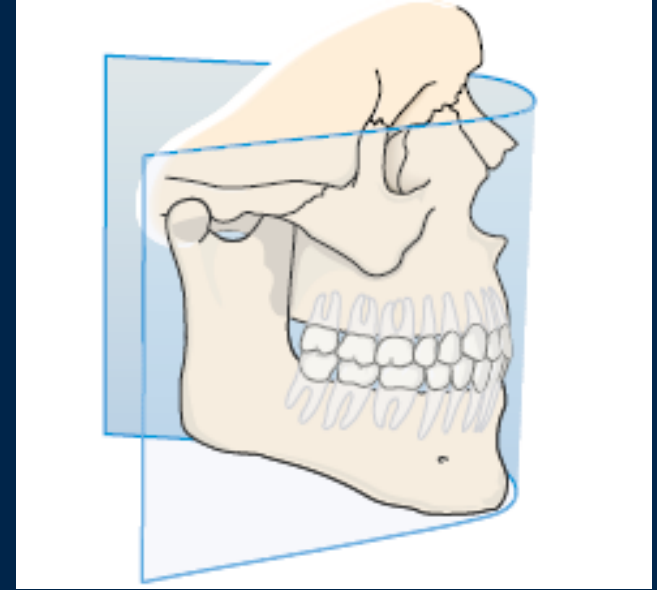




- Anamnesis (patient's medical history)
- Examination of orofacial region:
  - Intraoral, extraoral
  - Functional
  - Others: photographs (en face, profile), analysis of models, X-rays: **1.orthopantomogram (OPG)**  
**2.teleroentgenogram** – basis for cephalometric analysis

# 1. Orthopantomography (OPG)

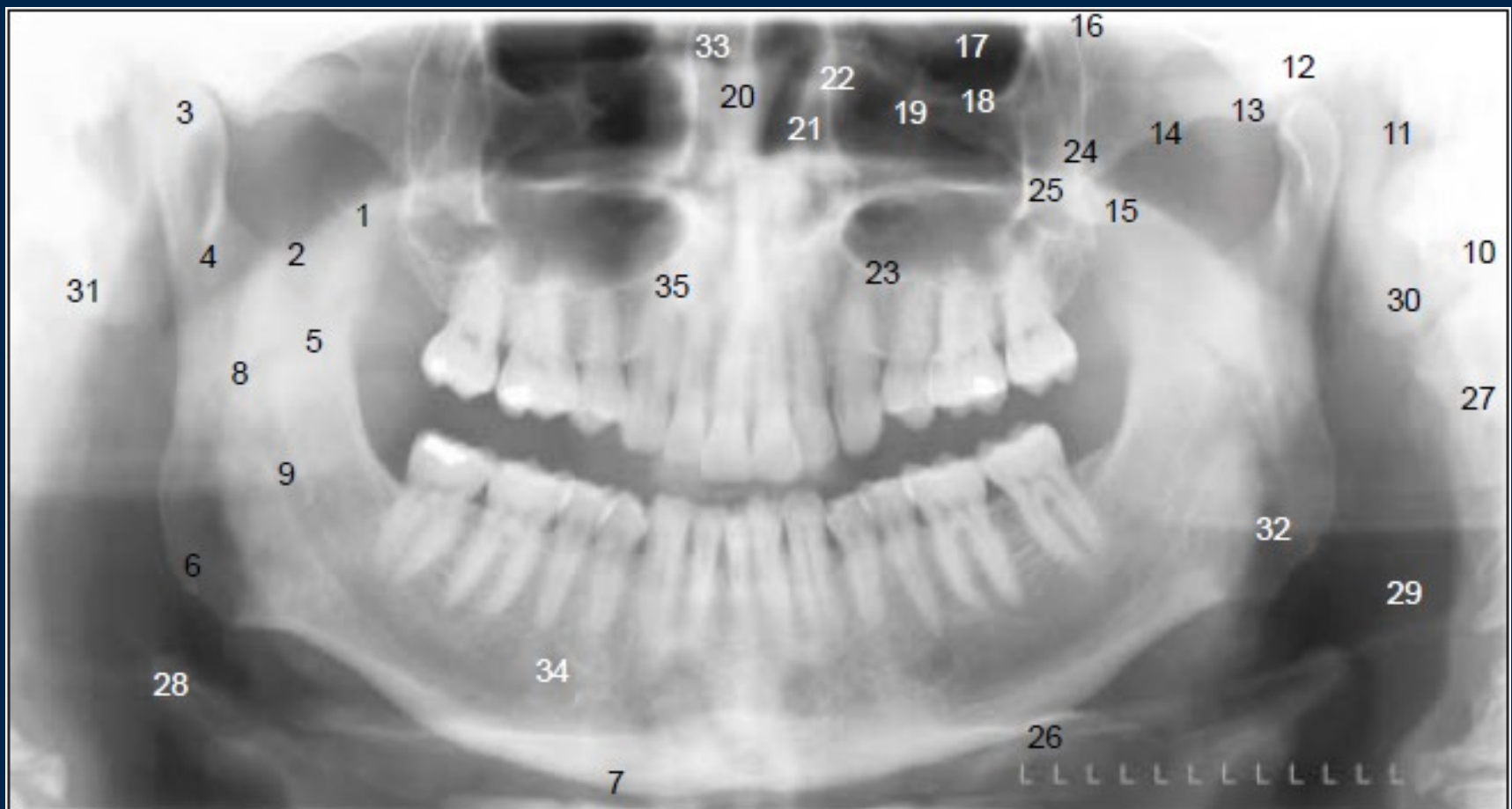
- *Panoramic  
extraoral technique*



- *Used to examine both jaws, TMJ, maxillary sinuses and the teeth together on one image*
- *Convenient and inexpensive method with low radiation exposure*

- *Patient is positioned with the Franfort plane horizontal, bite peg between the anterior teeth and the chin positioned on the chin support*
- *The film and the tubehead (X-ray source) rotate around the patient and produce a series of individual images on a single film*





1. Coronoid Process
2. Sigmoid Notch
3. Mandibular Condyle
4. Condylar Neck
5. Mandibular Ramus
6. Angle of Mandible
7. Inferior Border of Mandible
8. Lingula
9. Mandibular Canal
10. Mastoid Process
11. External Auditory Meatus
12. Glenoid Fossa

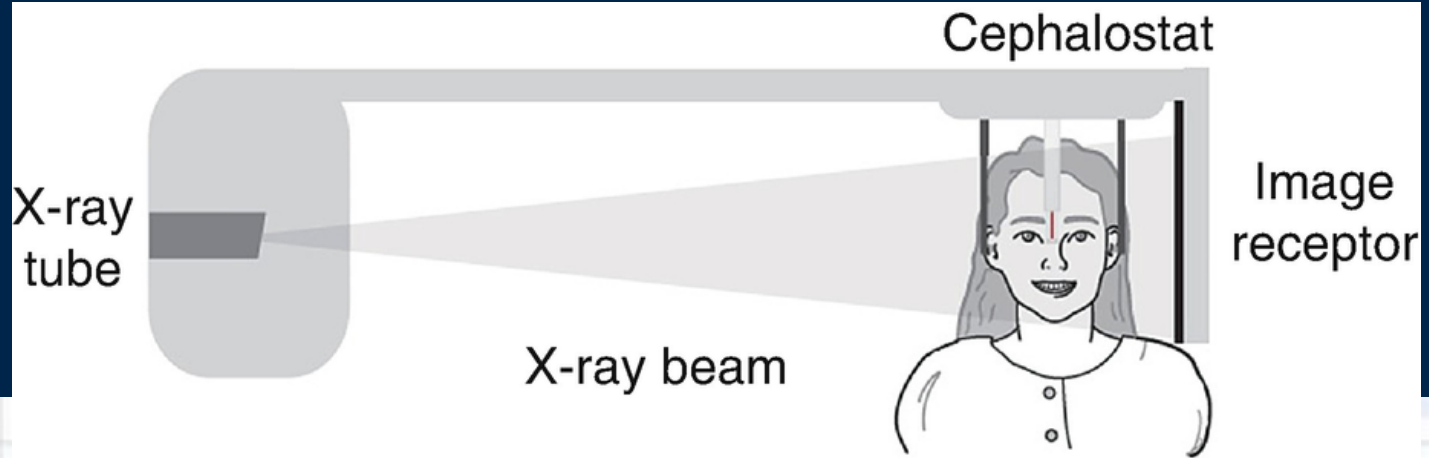
13. Articular Eminence
14. Zygomatic Arch
15. Pterygoid Plates
16. Pterygomaxillary Fissure
17. Orbit
18. Inferior Orbital Rim
19. Infraorbital Canal
20. Nasal Septum
21. Inferior Turbinate
22. Medial Wall of Max. Sinus
23. Inferior Border of Max. Sinus
24. Posterolateral Wall of Max. Sinus

25. Malar Process
26. Hyoid Bone
27. Cervical Vertebrae 1- 4
28. Epiglottis
29. Soft Tissues of Neck (Look Vertically For Corotid Artery Calcifications Here)
30. Auricle
31. Styloid Process
32. Oropharyngeal Air Space
33. Nasal Air Space
34. Mental Foramen
35. Hard Palate

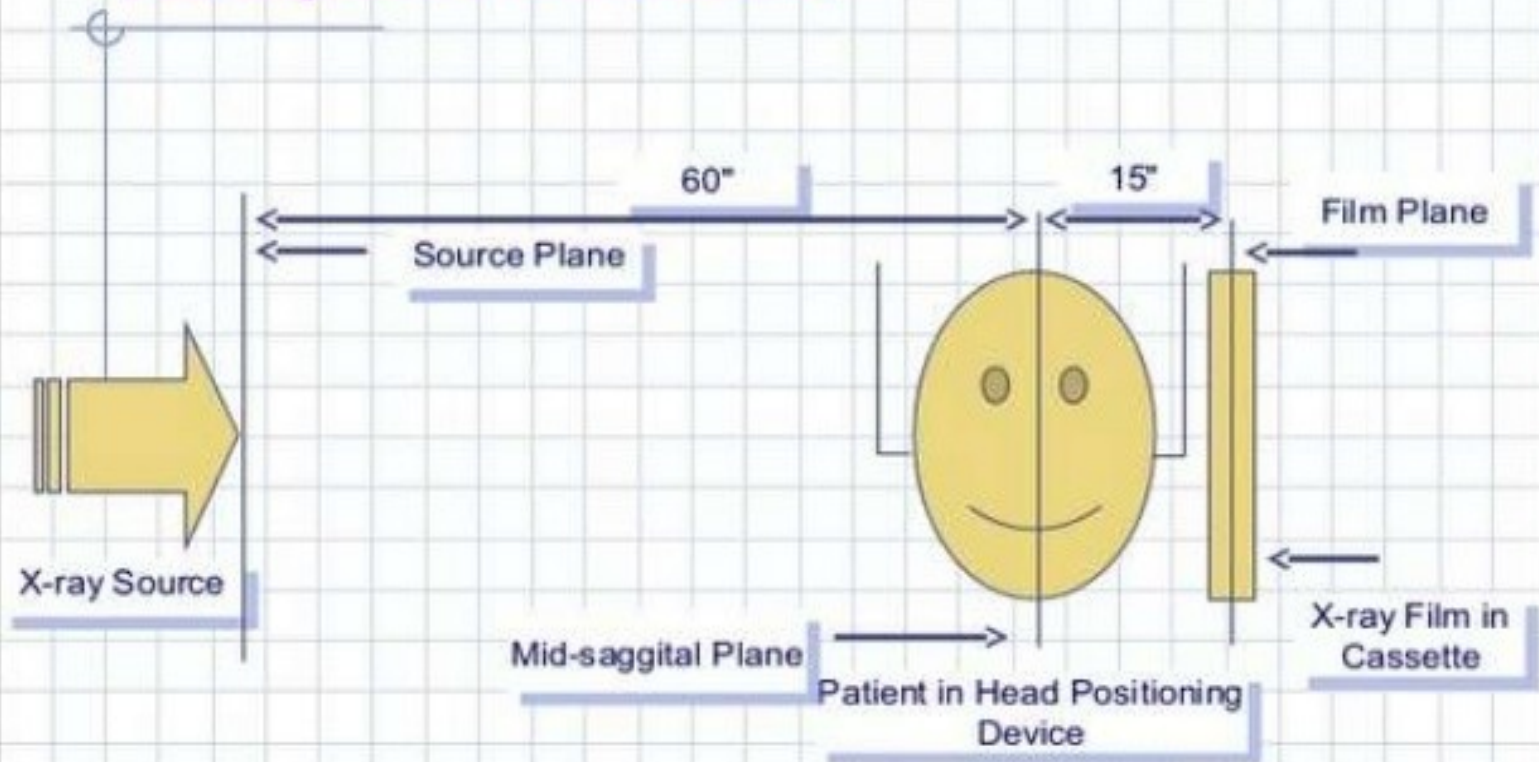
## 2. Cephalometry

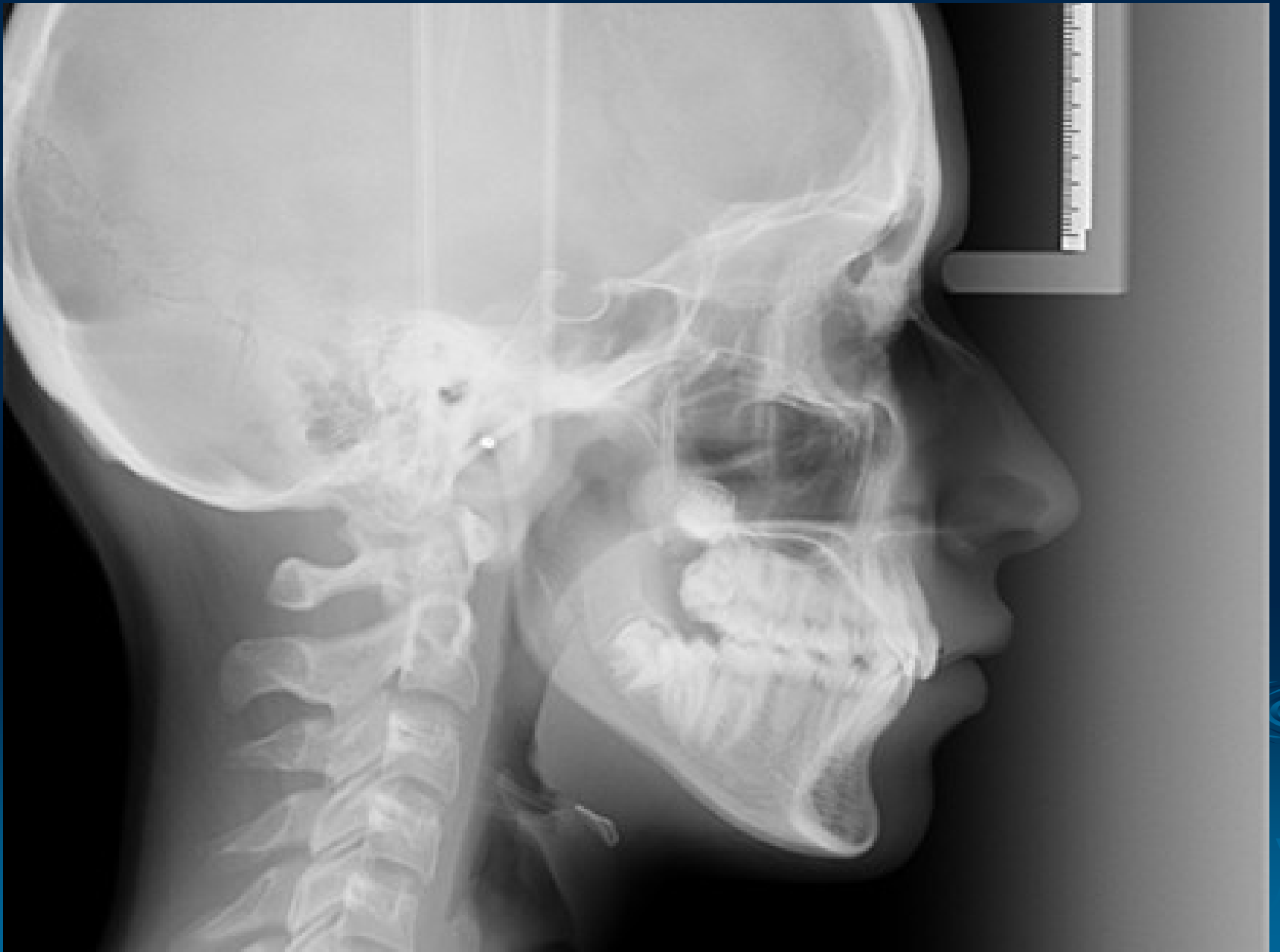- *A standardized and reproducible form of skull radiography used extensively **in orthodontics** to assess **the relationships of the teeth to the jaws and the jaws to the rest of the facial skeleton***
- *Main indications - monitoring treatment progress, preoperative evaluation of skeletal and soft tissue patterns, postoperative appraisal of the results of surgery and long-term follow-up studies*

- *The patient is positioned within the **cephalostat** in the Frankfort plane horizontal, teeth should be in maximum intercuspation*
- *The head is immobilized within the apparatus with the plastic ear rods being inserted into the external auditory meati*
- *The X-ray beam is horizontal and centred on the ear rods*
- *Soft x-rays*

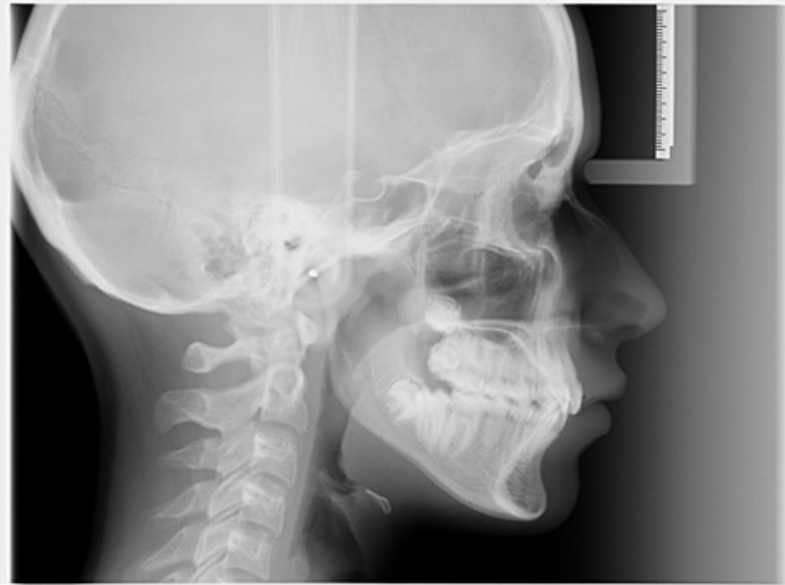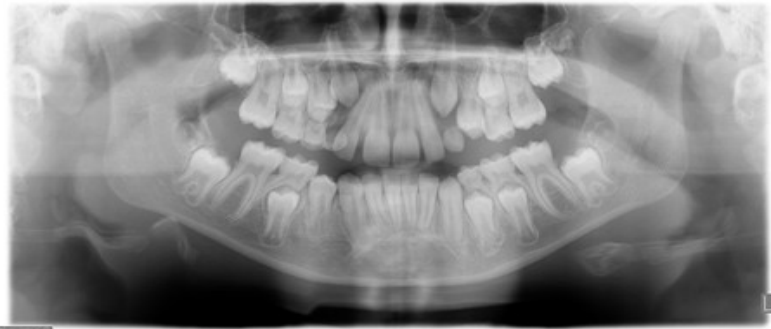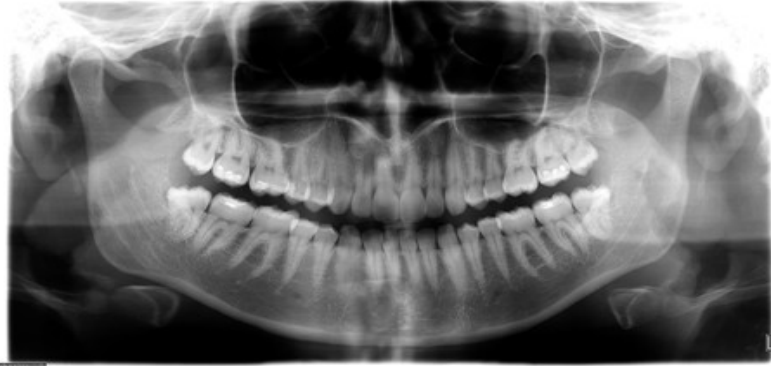


# Cephalostat









# Cephalometric Analysis



**S Sella** mid point of sella turcica

**N Nasion** most anterior point on fronto-nasal suture

**Or Orbitale** most inferior anterior point on margin of orbit

**Po Porion** upper most point on bony external auditory meatus

**ANS** anterior Nasal Spine

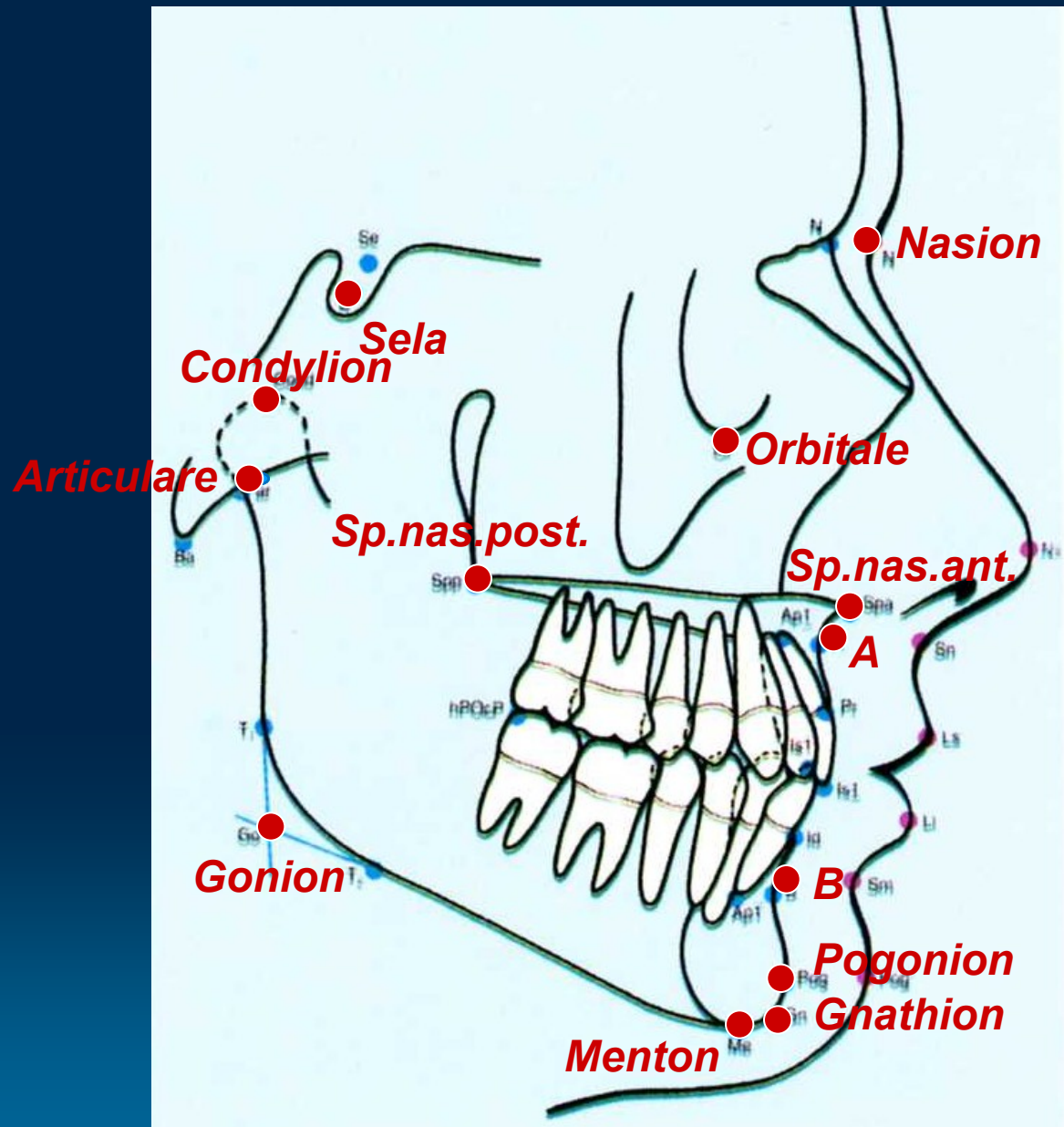
**PNS** posterior Nasal Spine

**Go Gonion** most posterior inferior point on angle of mandible

**Me Menton** lowest point on the mandibular symphysis

**A point** deepest concavity on anterior profile of maxilla

**B point** deepest concavity on anterior profile of mandibular symphysis

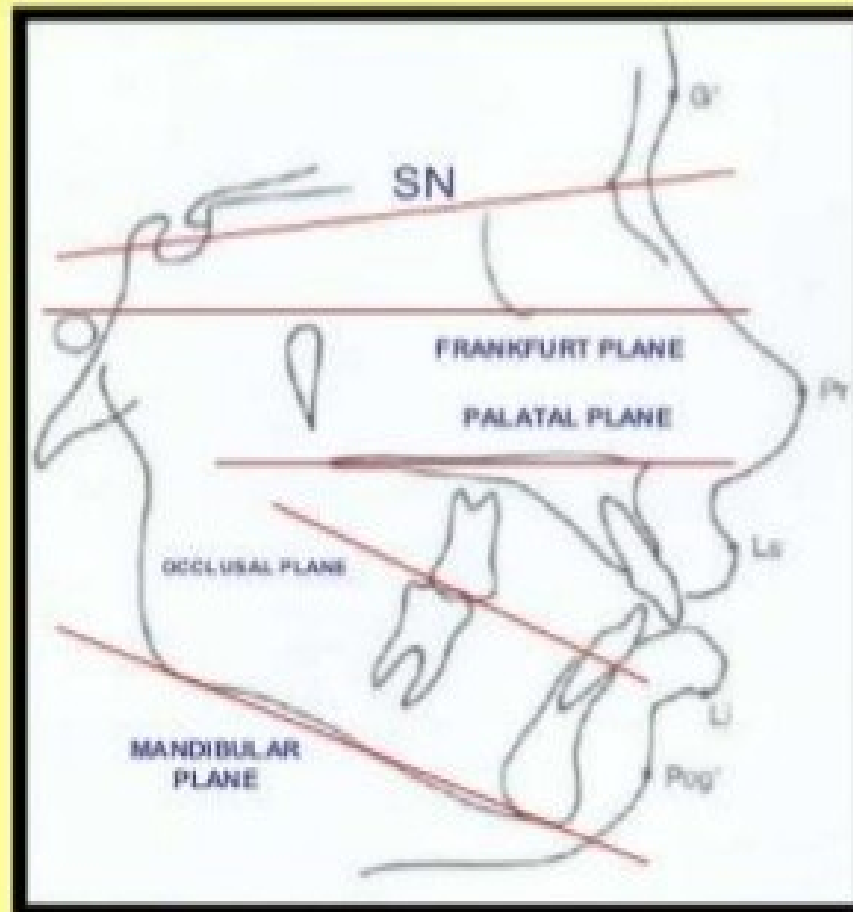


**Frankfort Plane Po - Or** Equivalent to the true horizontal when patient is standing upright

**Maxillary Plane PNS - ANS** Gives inclination of maxilla relative to other lines/planes

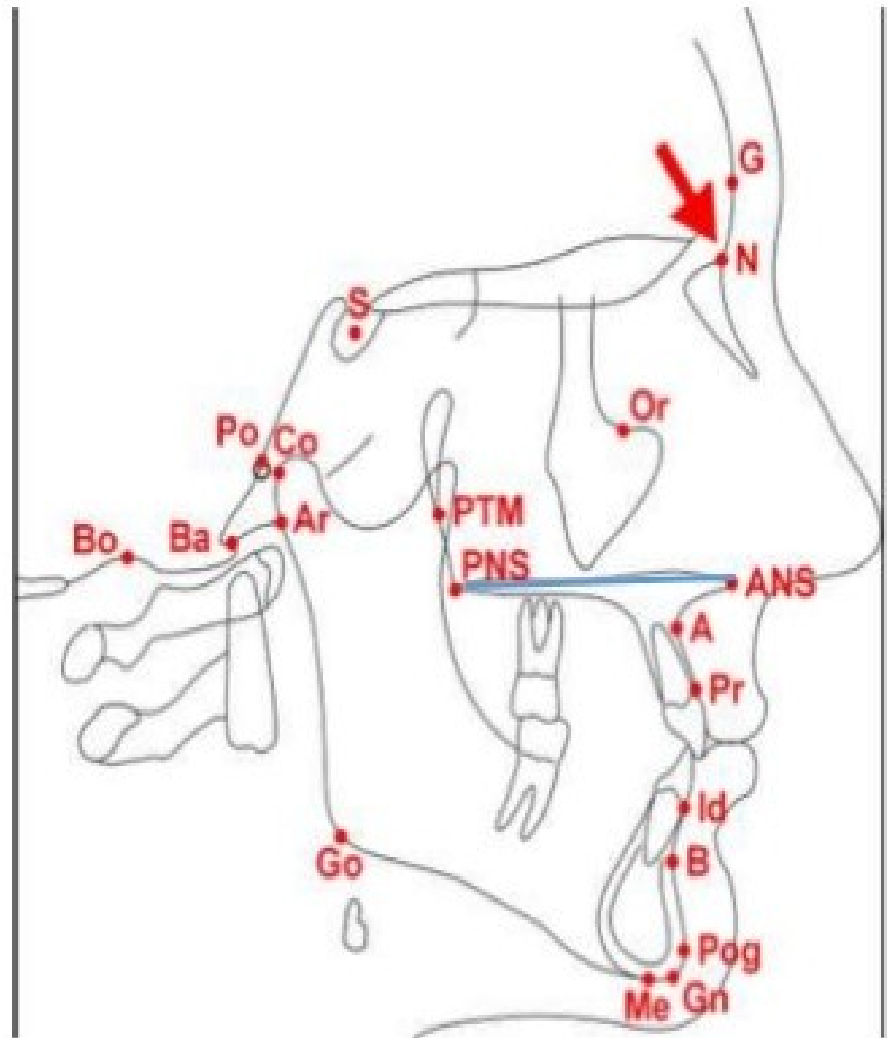
**Mandibular Plane Go - Me** Gives inclination of mandible relative to other lines/planes

# CEPHALOMETRIC PLANES



# PALATAL PLANE

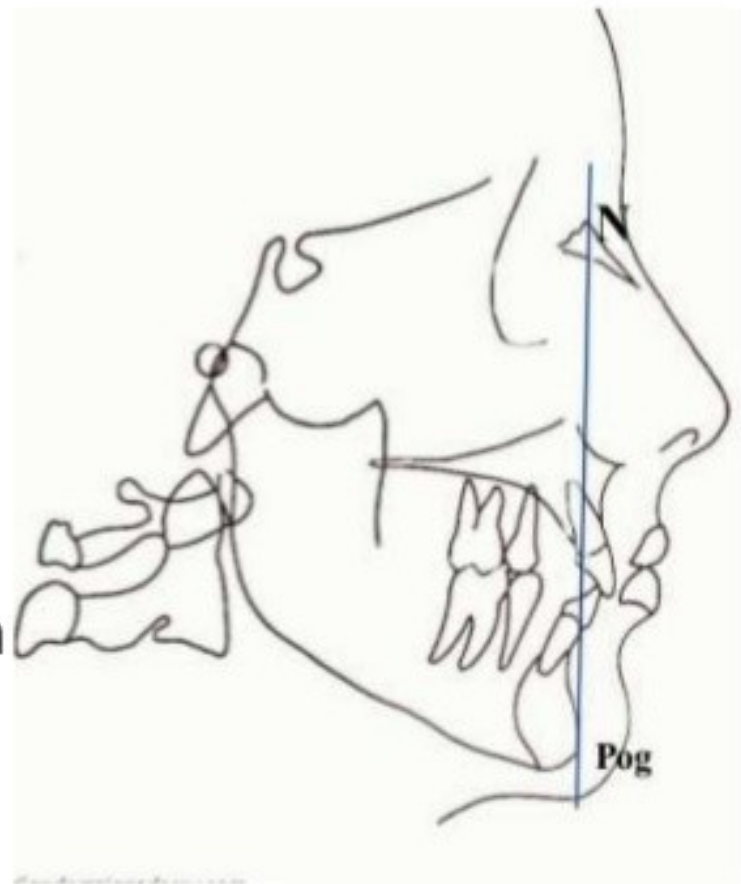
- This plane extends through the ANS to PNS.
- The relationship of this plane to FH plane is useful in evaluating treatment changes occurring in the maxilla.
- Assessment of remaining alveolar bone for implant placement.



## FACIAL Plane :

It is a line from the anterior point of the frontonasal suture (N) to the most anterior point of the mandible (Pog).

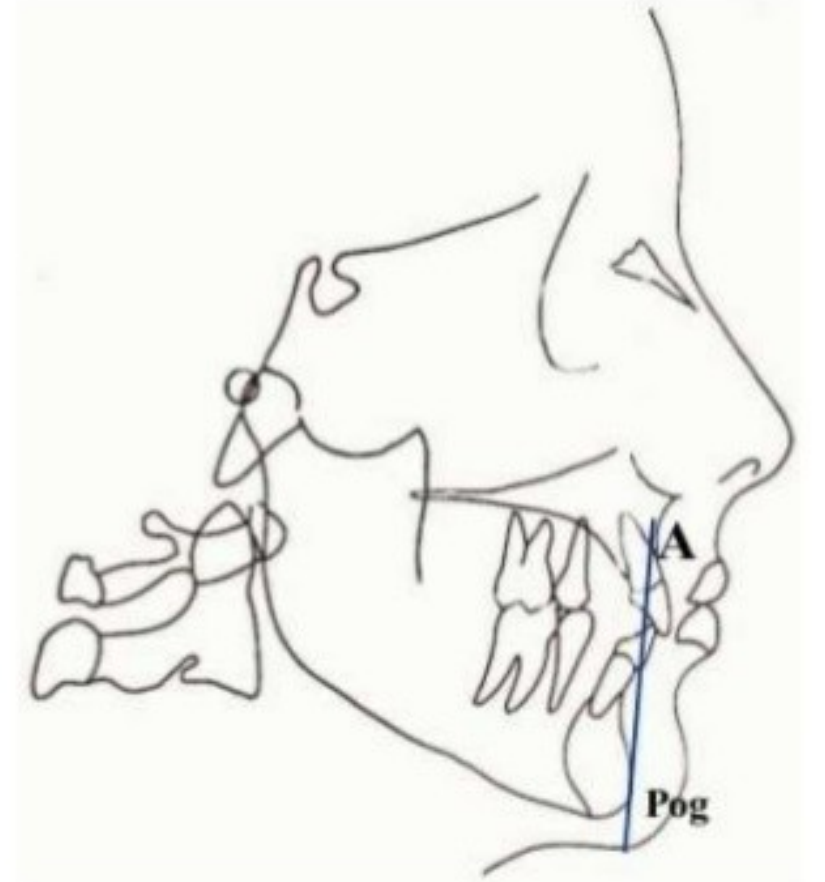
Used to record position of chin.  
And to relate position of maxilla to facial plane.





## A-Pog plane:

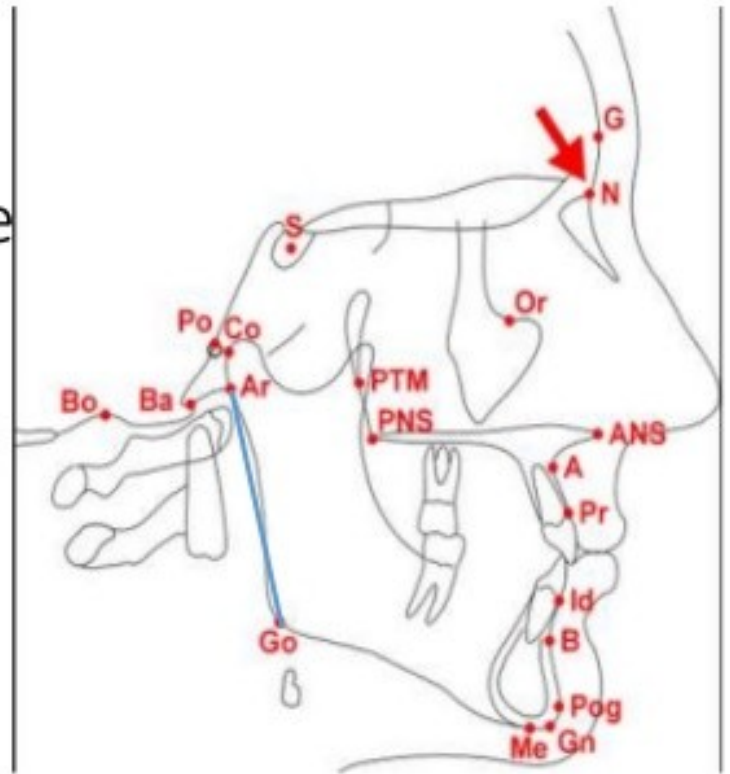
- It is a line from point A on the maxilla to pogonion on the mandible.
- Also known as Dental plane.
- Used in measure position of anterior teeth.



## Ar-Go plane:

This plane is formed by the line connecting from Articulare to Gonion.

It is important in the determination of length of ramus.



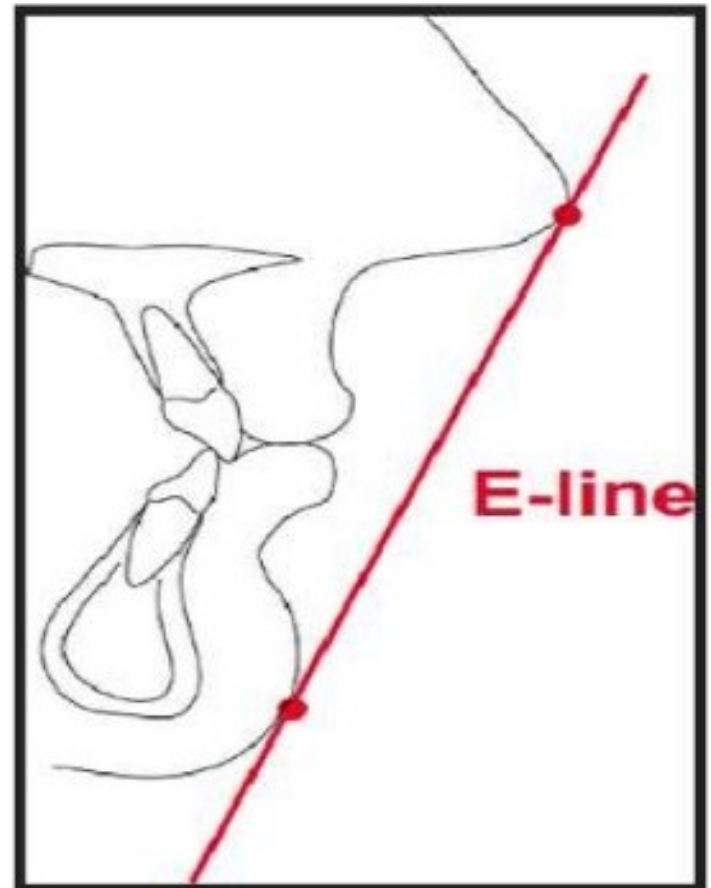
## E – PLANE: (soft tissue)

It is also called as Esthetic plane.

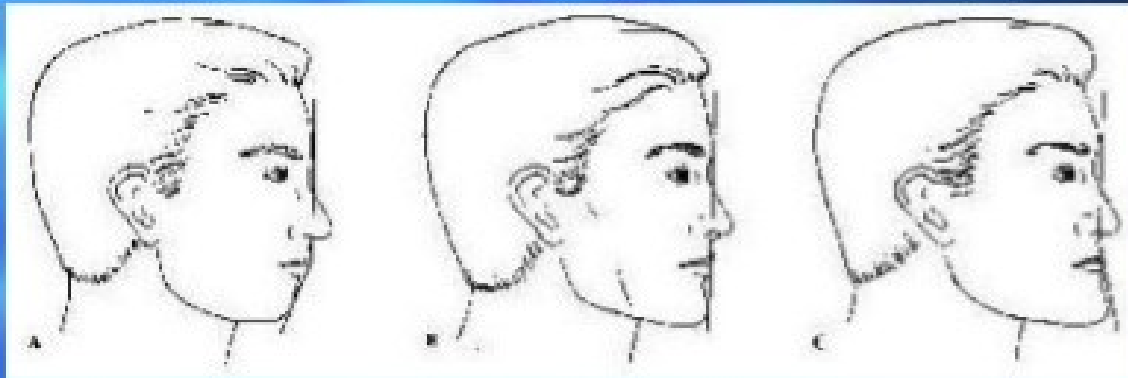
It is also known as RICKETT's esthetic line (By rickett in 1960). Which extends from the tip of the nose to the chin.

The lips should be slightly behind this line for esthetics.

This affects the lips prominency.



# Soft Tissue Profile



**Convex**

**straight**

**concave**

**retrognathic**

**orthognathic**

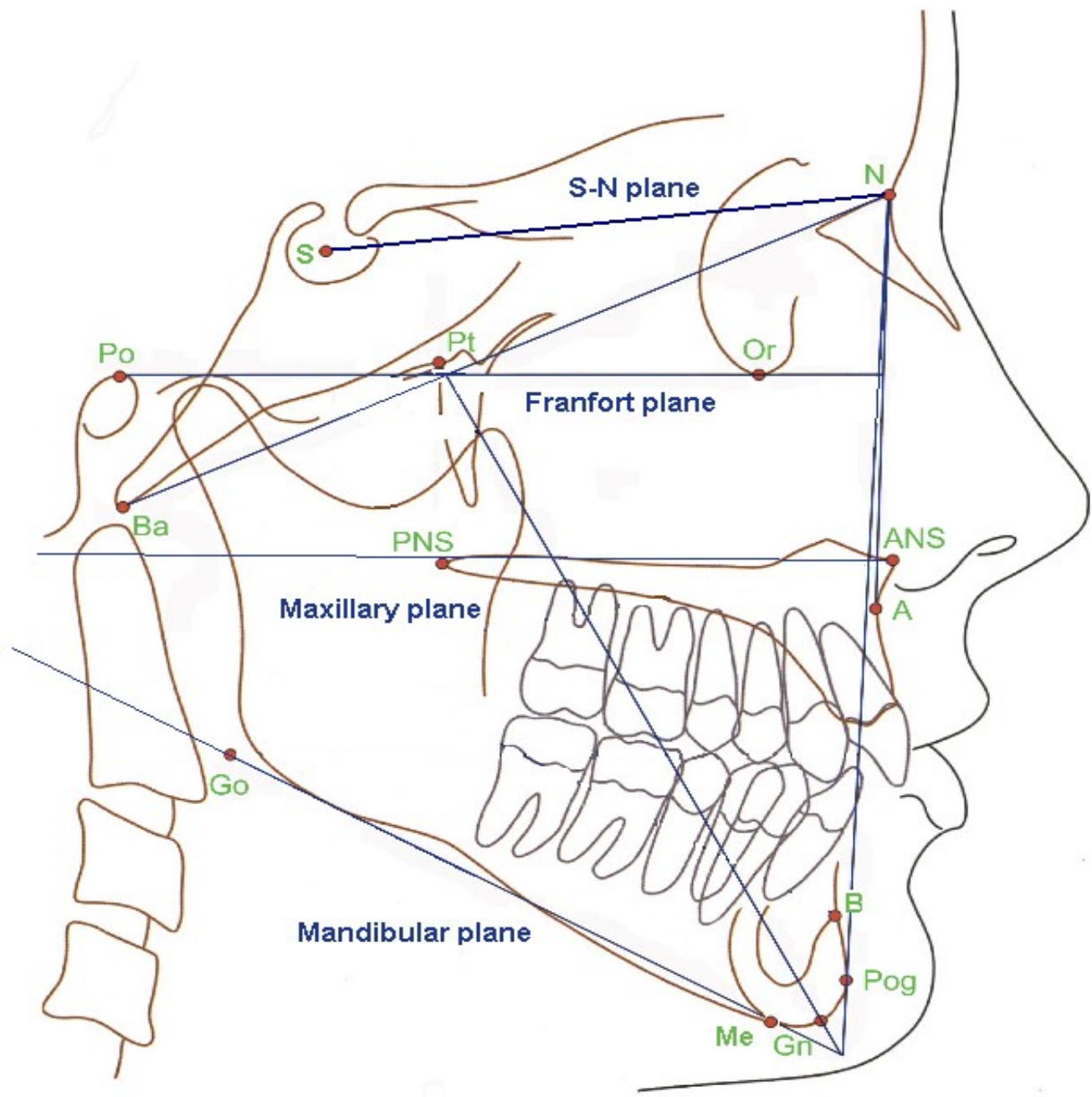
**prognathic**

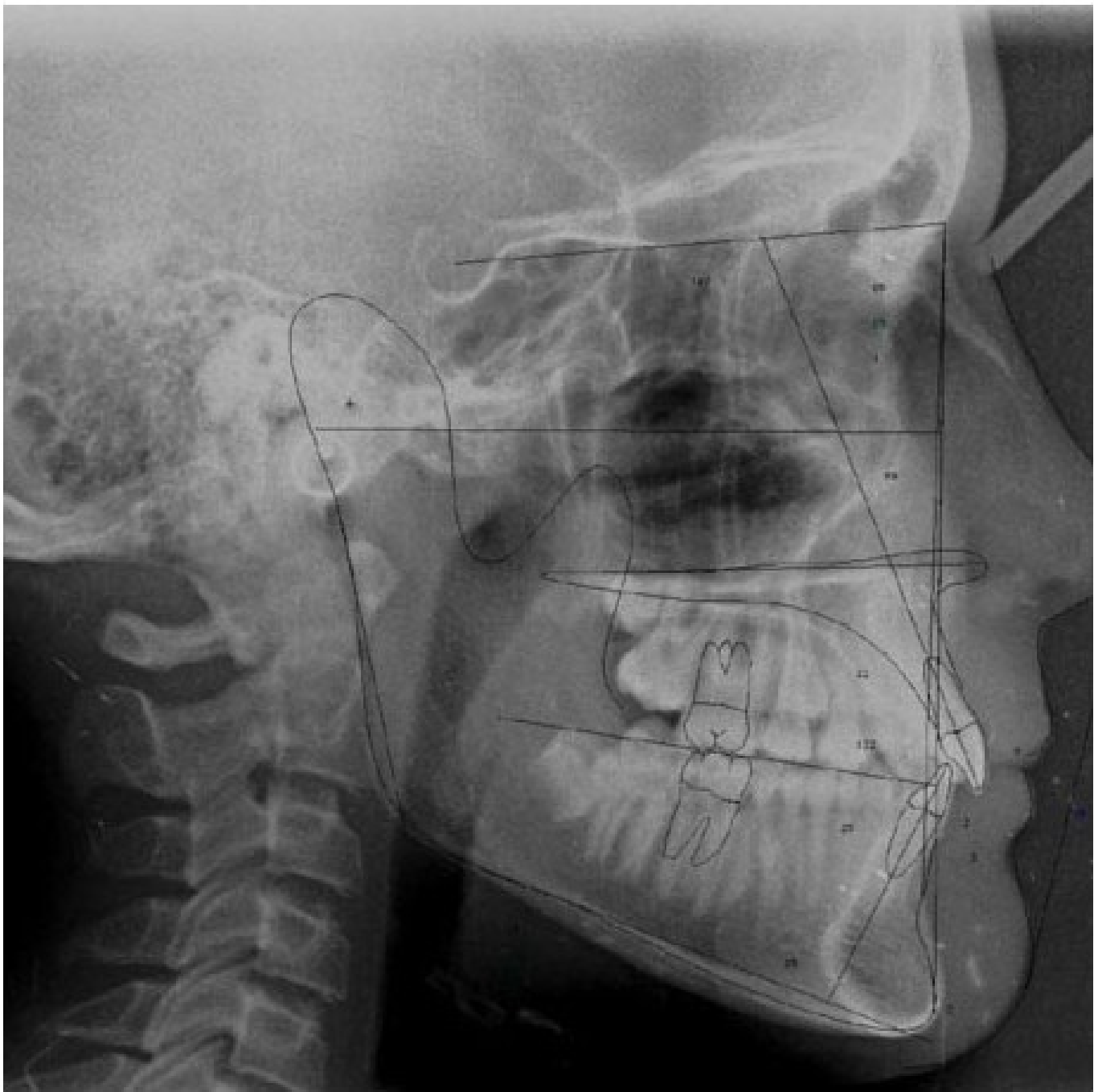
**S - N Line** indicates orientation of anterior cranial base

**N - A** indicates relative position of maxilla to the cranial base

**N - B** indicates relative position of mandib. to the cranial base

**The angles SNA; SNB; ANB** indicate relative position of maxilla or mandible to each other and to the cranial base





➤ **References:**

- Čihák, R.: Anatomie 1,2,3, Praha, Grada, 2001
- Netter, F.: Atlas of Human Anatomy, 4th ed., Elsevier, USA, 2006
- Naňka, Elišková: Přehled anatomie. Galén, Praha 2009
- Seidl et al.: Radiologie pro studium i praxi, Grada publishing, 2013
- Mrázková, Doskočil: Klinická anatomie pro stomatology, Alberta, Praha, 1994
- Brand, Isselhard: Anatomy of orofacial structures, 8th edition, Elsevier, USA, 2019
- Fehrenbach, Herring: Illustrated anatomy of the head and neck, 5th edition, Elsevier, USA, 2017
- Moore, Dalley: Clinically oriented anatomy, 5th edition, USA, 2006