

COLORS IN MEDICAL TERMINOLOGY

PRESENTED BY: SAI KEERTANA
DEVARAPALLI AND SHARANYA
MAHESWARAN

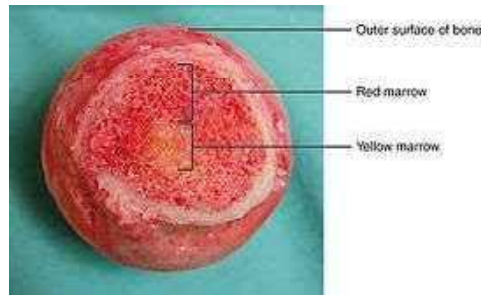
General terminology

- ▶ Latin: Color, oris, m
 - ▶ 1st and 2nd declension adjectives.
 - ▶ Used in anatomical medicine
- ▶ Greek: Chroma, chromatis, n
 - ▶ Used in clinical medicine



Yellow

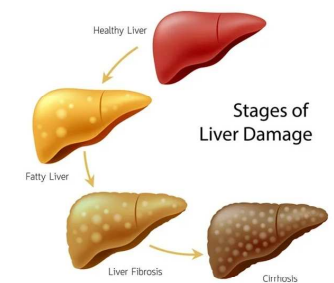
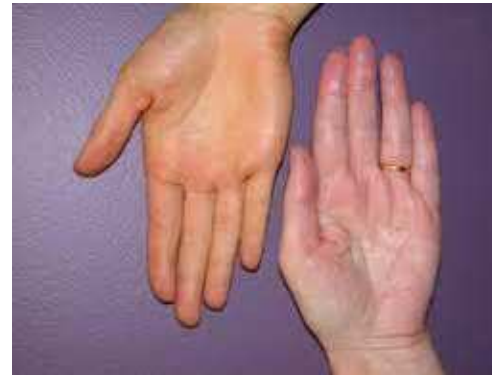- ▶ Flāvus, a, um
 - ▶ Medulla ossium flava – Yellow marrow.
 - ▶ Febris flava – yellow fever, infected by mosquitoes



- ▶ Luteus, a, um
 - ▶ Corpus luteum - a mass of cells that forms in an ovary and is responsible for the production of the hormone progesterone during early pregnancy.

- ▶ Cirrho-
 - ▶ Cirrhosis- Liver disease. Can cause yellowing of the skin.

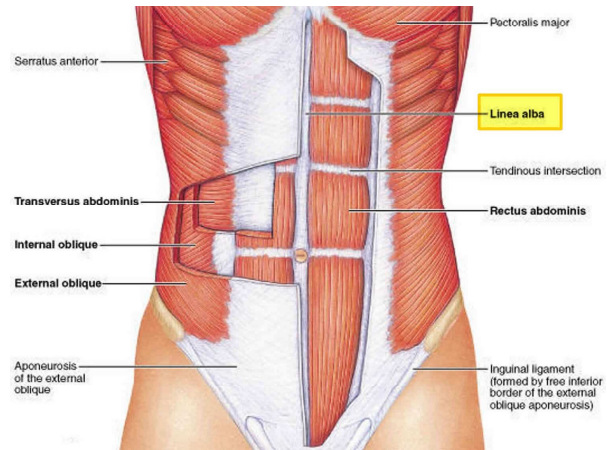
- ▶ Xantho-
 - ▶ Xanthoderma – yellow/ orange discoloration of the skin.



White

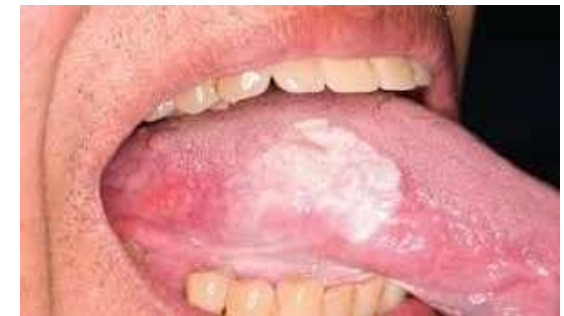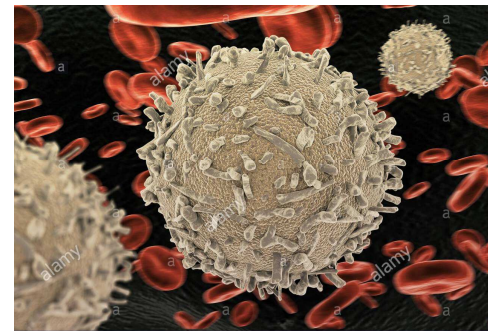
▶ Albus, a, um

- ▶ **Linea alba** – the white line is a fibrous structure that runs down the midline of the abdomen in humans and other vertebrates.



▶ Leuko-

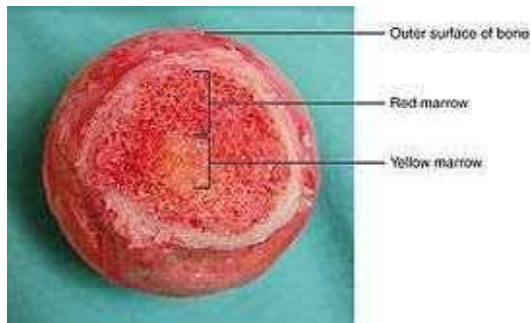
- ▶ **Leukoplakia** – is a thick, white patches in the inside of the mouth
- ▶ **Leukocytes** – white blood cell



Red

- ▶ Ruber, a, um

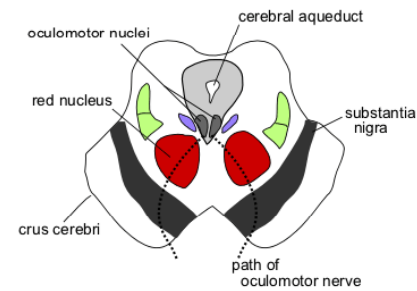
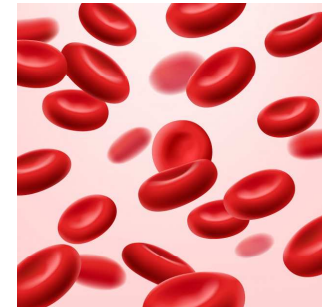
- ▶ Medulla ossium rubra – red marrow.



- ▶ Nucleus ruber - The red nucleus is a paired oval-shaped, in the midbrain.

- ▶ Erythro-

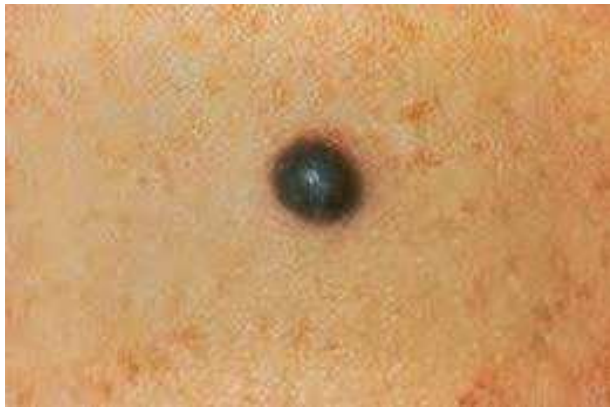- ▶ Erythrocytes – red blood cell.



Blue/black

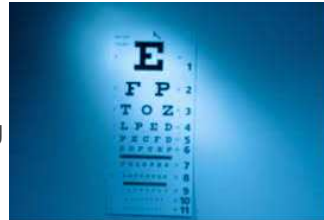- ▶ **Caeruleus, a, um**

- ▶ **Naveus caeruleus** – Tumor containing nervus cells.

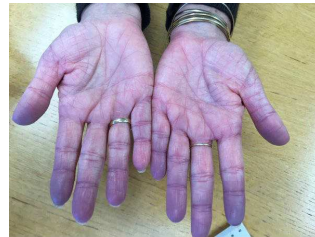

- ▶ **Cyano-**

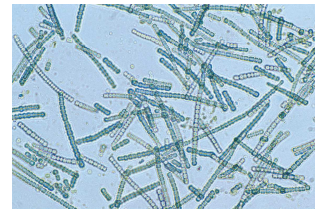- ▶ **Cyanopsia** – is a medical term for seeing everything tinted with blue. Blue vision.



- ▶ **Cyanoticus** – is the bluish or purplish discoloration of the skin.



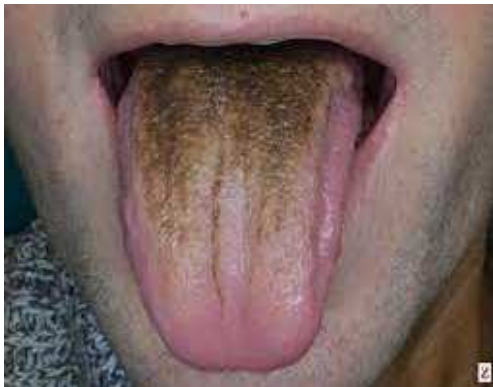- ▶ **Cyanobacteria** – photosynthetic bacteria.



Black

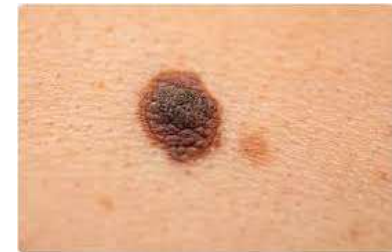▶ Niger, a, um

- ▶ **Substantia Nigra** – Part of the midbrain which produces dopamine
- ▶ **Lingua villosa nigra** - is a condition that is often attributed to poor oral hygiene, where it appears small bumps on the tongue with black or brown discoloration

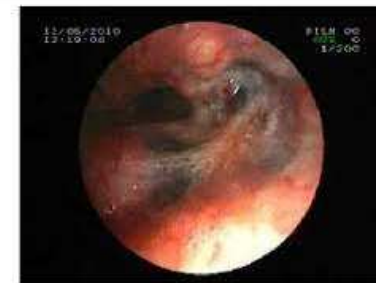

▶ Melano/anthraco

- ▶ **Melanoma** – serious type of skin cancer



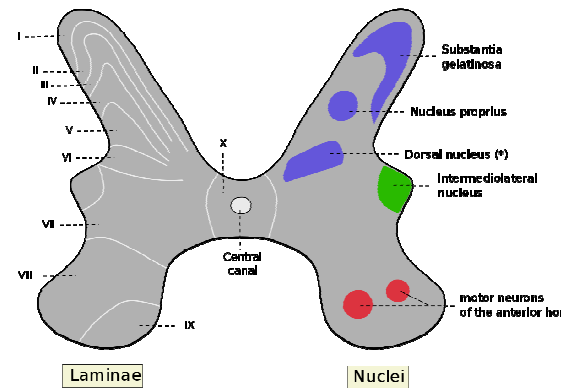
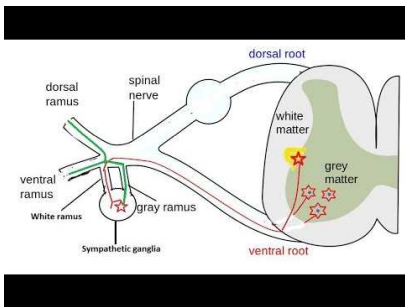
- ▶ **Anthraco-fibrosis** - black pigment discoloration of bronchi, which can cause bronchial destruction and deformity



Grey

▶ Griseus, a, um

- ▶ Ramus communicans griseus
- ▶ Substantia Grisea – grey tissue of the brain and spinal cord



* Posterior thoracic nucleus or Column of Clarke

▶ Polio-

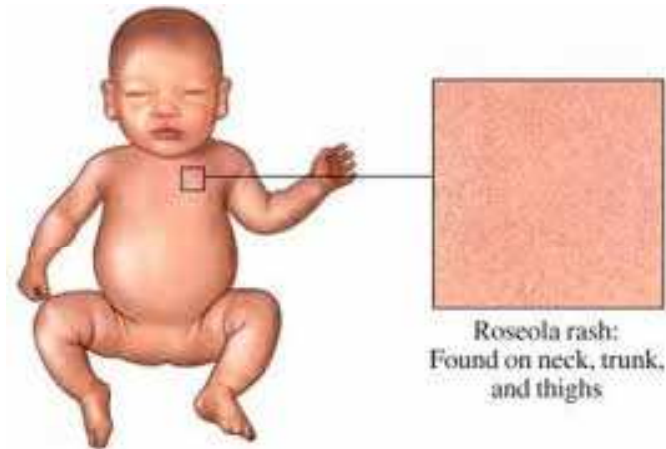
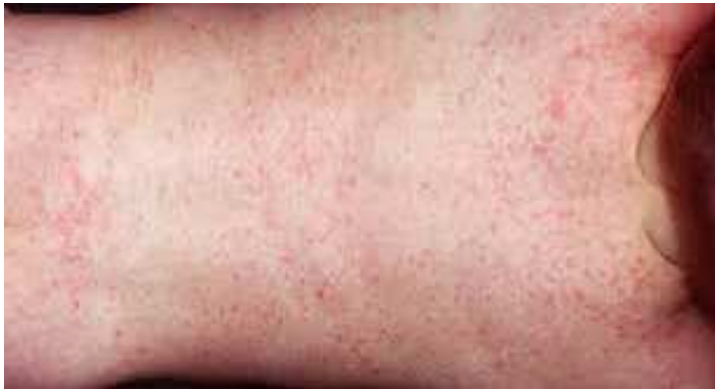- ▶ Poliomyelitis – is an infectious disease caused by the poliovirus.



Pink

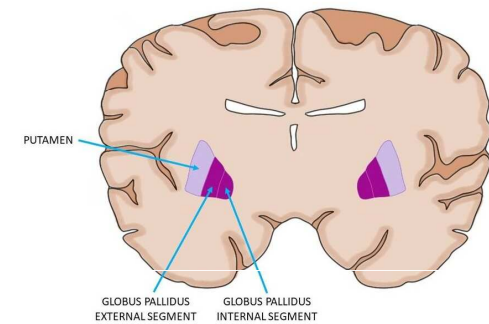
- ▶ Roseus, a, um

- ▶ Roseola - is a generally mild infectious disease caused by certain types of virus that usually affects children by age of 2.



Pale

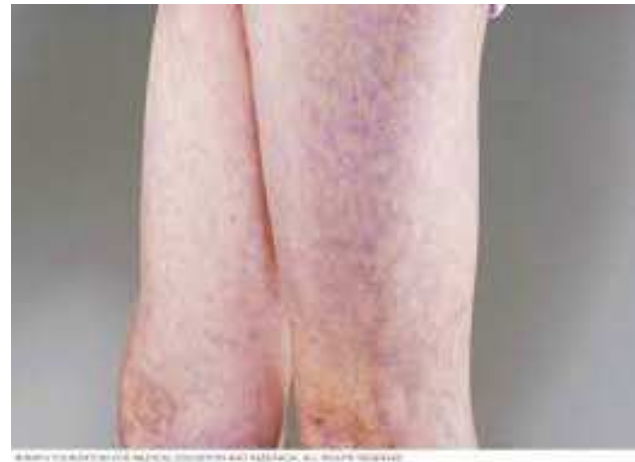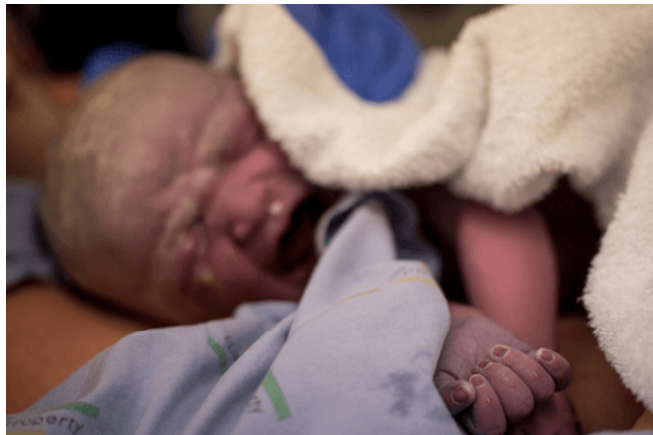- ▶ Pallidus, a, um
 - ▶ Globus pallidus – one of the components of basal ganglia
- ▶ Febris pallida – Paleness due to fever



Discolored

- ▶ Lividus, a, um

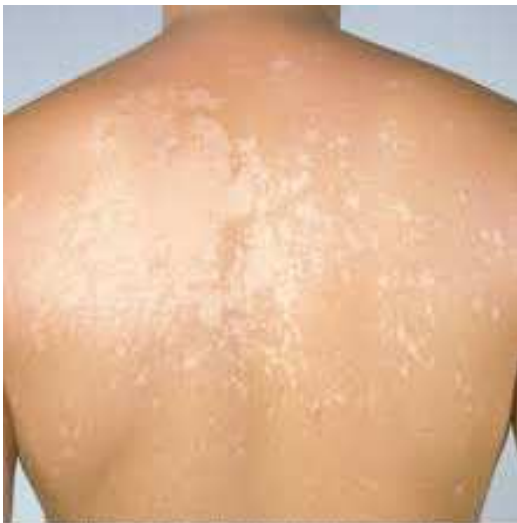- ▶ Livedo reticulari – is a skin symptom, where we can see netlike pattern of reddish-blue skin discoloration.
- ▶ Asphyxia livida - respiratory failure in a newborn which can cause a bluish discoloration.



Multicolored

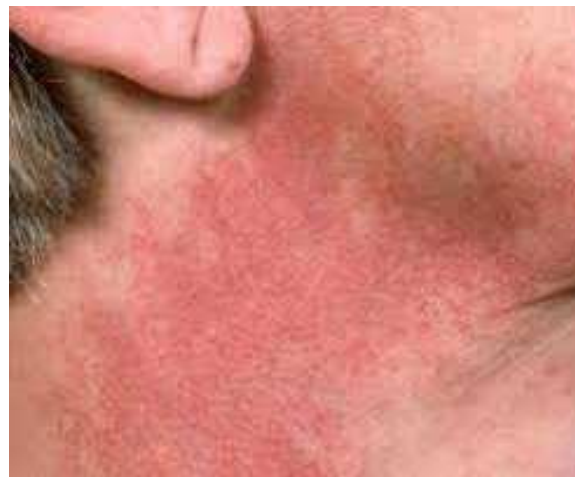- ▶ Versicolor, oris

- ▶ Tinea versicolor – Fungal infection of the skin.



- ▶ Poikilo-

- ▶ Poikiloderma – Reddish hyperpigmentation, caused by the sun damage.





How many colors can you remember?

- ▶ **Albus, a, um**
- ▶ **Ruber, a, um**
- ▶ **Lividus, a, um**
- ▶ **Griseus, a, um**
 - ▶ **Melano**
- ▶ **Versicolor, oris**

Thank you for your
attention!



Sources

- ▶ <https://teachmeanatomy.info/the-basics/anatomical-terminology/terms-of-location/> 29.03.2021
- ▶ https://en.wikipedia.org/wiki/Aspergillus_flavus 29.03.2021
- ▶ <https://no.wikipedia.org/wiki/Tredagersfeber> 29.03.2021
- ▶ https://en.wikipedia.org/wiki/Red_nucleus 29.03.2021
- ▶ <https://medlineplus.gov/ency/article/001104.htm> 29.03.2021