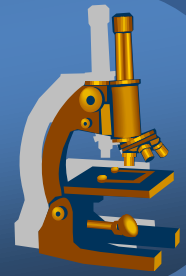
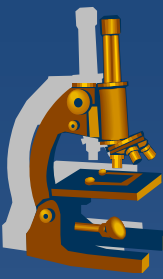


Systematic pathology

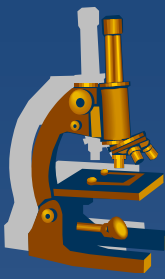


Genital system pathology

Breast pathology



Male genital tract pathology



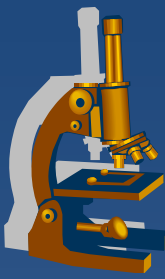
- x Prostate**
- x Penis, scrotum**
- x Testis, epididymis**

⇒ *congenital defects*

⇒ *circulatory disorders*

⇒ *inflammations*

⇒ *tumors*



Prostate gland

Prostate gland



✘ inborn defects uncommon

✘ circulatory disorders:

⇒ *infarction*

- in the setting of benign hyperplasia
- regenerative + reparative processes adjacent to the infarction focus may mimic a malignant lesion (esp. in needle biopsy)

Prostate gland



x inflammations:

⇒ *bacterial (acute purulent or chronic)*

- systemic symptoms, dysuria, frequency, local pain
- ascendent, iatrogenic (cathetrisation, surgery, ...)
- *E. coli, Klebsiella, Proteus, enterobacter...*
- tb
 - most common tb presentation in the male genital system
 - local spread or isolated metastasis of lung tb
 - diff. dg. x reactive or idiopathic granulomatous prostatitis

⇒ *abacterial*

- most common, chronic pain or asymptomatic
- *Chlamydia trachomatis, ureaplasma...*

Prostate gland



x pseudotumors, tumors:

⇒ *Benign prostatic hyperplasia*

⇒ *Carcinoma*

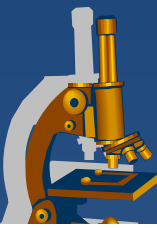
- **Acinar**

- Ductal
- Squamous cell
- Adenosquamous
- Transitional cell
- Neuroendocrine

⇒ *Secondary tumors*

- local ca infiltration from adjacent organs (bladder, rectum)
- haematogenous metastases (lung ca, malignant melanoma, ..)

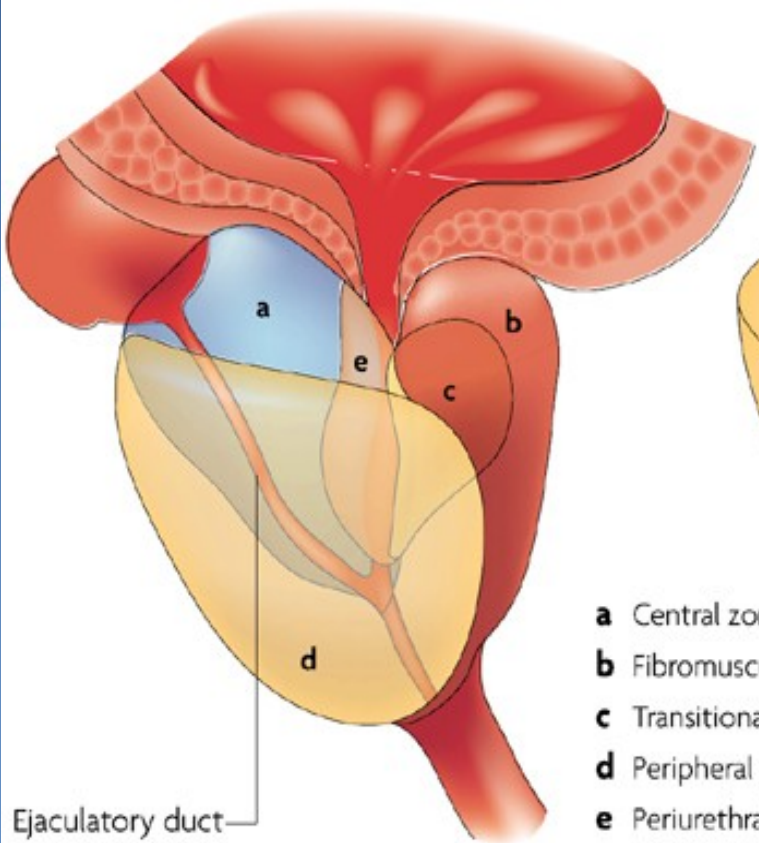
Zonal predisposition of prostate diseases



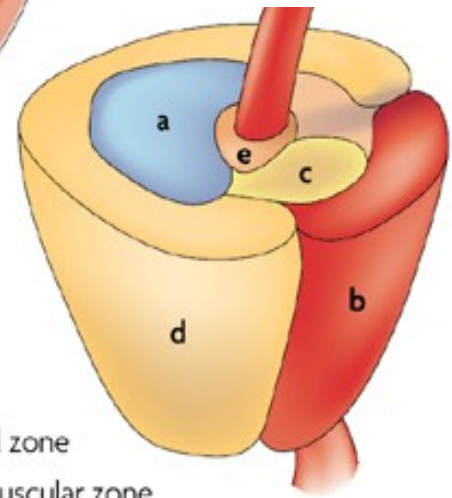
	Prostate zone		
	Peripheral	Transition	Central
Focal atrophy	Medium-high prevalence	Medium-high prevalence	Low prevalence
Acute inflammation	Low prevalence	Low prevalence	None
Chronic inflammation	Medium-high prevalence	Medium-high prevalence	Low prevalence
Benign prostatic hyperplasia	None	High prevalence	Low prevalence
High-grade PIN	Medium-high prevalence	Low prevalence	None
Carcinoma	Medium-high prevalence	Low prevalence	None

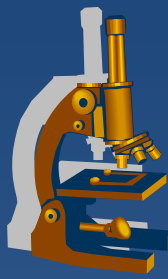
■ High prevalence ■ Low prevalence
■ Medium-high prevalence ■ None

Prostate zones



- a** Central zone
- b** Fibromuscular zone
- c** Transitional zone
- d** Peripheral zone
- e** Periurethral gland region





Benign prostatic hyperplasia

x epidemiologic factors:

- ⇒ *age (BPH prevalence rising with age, 70% by age 60, 90% by 80)*
- ⇒ *geographic/racial (low in Asia, more common in W Europe)*

x pathogenesis:

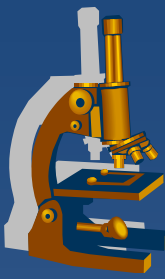
- ⇒ *not completely clear*
- ⇒ *hormonal dysbalance, dihydrotestosterone induced growth factors → stromal proliferation + ↓ death of glandular cells*

x gross nodular hyperplasia:

- ⇒ *periurethral (transition zone) mostly affected → urethral compression + obstruction → dysuria*

x consequences:

- ⇒ *lower urinary tract symptoms, acute/chronic urinary retention, cystitis*
- ⇒ *bladder hypertrophy + diverticula, hydroureter + -nephrosis, pyelonephritis*



Benign prostatic hyperplasia

x micro:

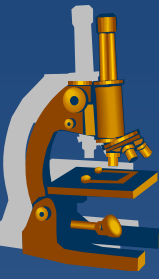
⇒ ***nodular structure***

⇒ ***glands:***

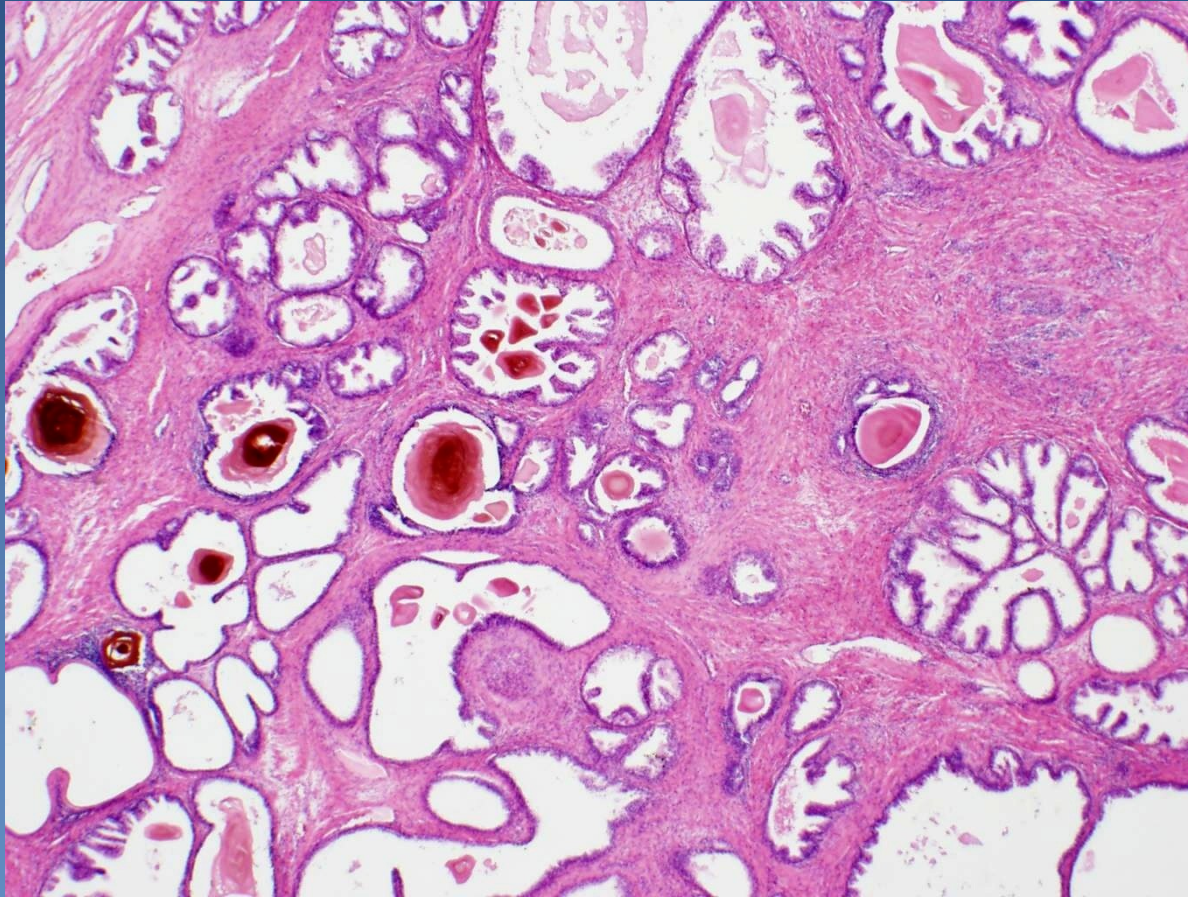
- hyperplastic, uneven size, common cystic dilatation
- bi-layered epithelium – external myoepithelial (!x invasive ca), inner secretory (sm. papillary proliferation)
- inspissated luminal secretions → corpora amylacea

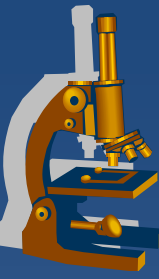
⇒ ***stroma:***

- hyperplastic, common purely stromal fibromuscular nodules
- disperse chronic inflammatory reaction

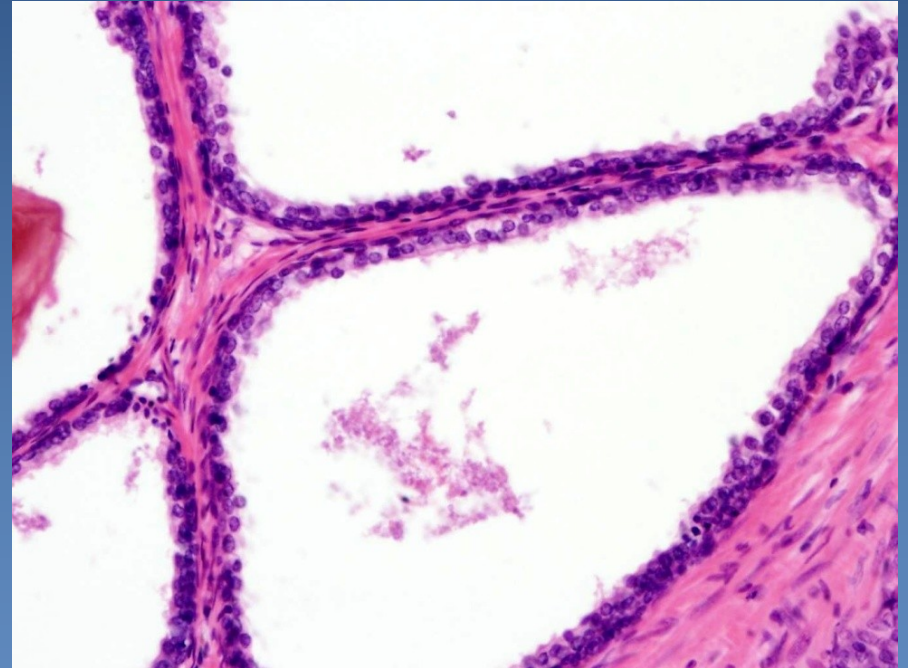
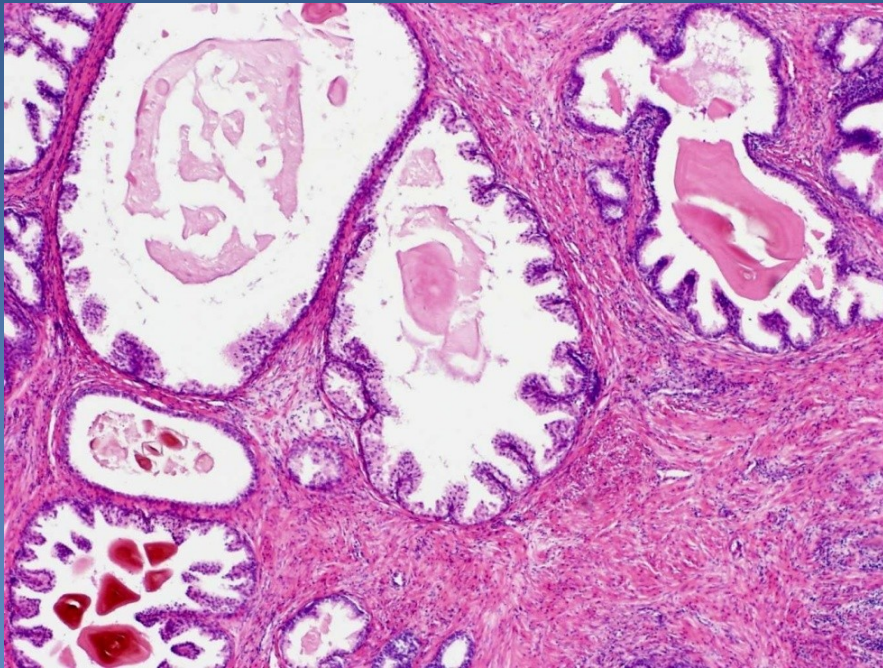


Benign prostatic hyperplasia





Benign prostatic hyperplasia



Prostatic adenocarcinoma



- x ↑ incidence
 - ⇒ *1st – 3rd of the most common male malignancies (prostate – lungs – colorectal)*

- x **peripheral zone of prostate, dorsal part (per rectum!)**

- x dg.:
 - ⇒ *needle biopsy (most common, by suspicion)*
 - ⇒ *transurethral resection (BHP treatment – accidental)*
 - ⇒ *suprapubic prostatic resection*

Prostatic adenocarcinoma



× Prostatic intraepithelial neoplasia (PIN)

⇒ *Low-grade*

- more numerous acinar cells, without significant nuclear atypias

⇒ *High-grade*

- significant cytonuclear atypia of acinar cells (enlarged nucleus, prominent nucleolus)
- **commonly in proximity of acinar adenocarcinoma – precursor lesion**

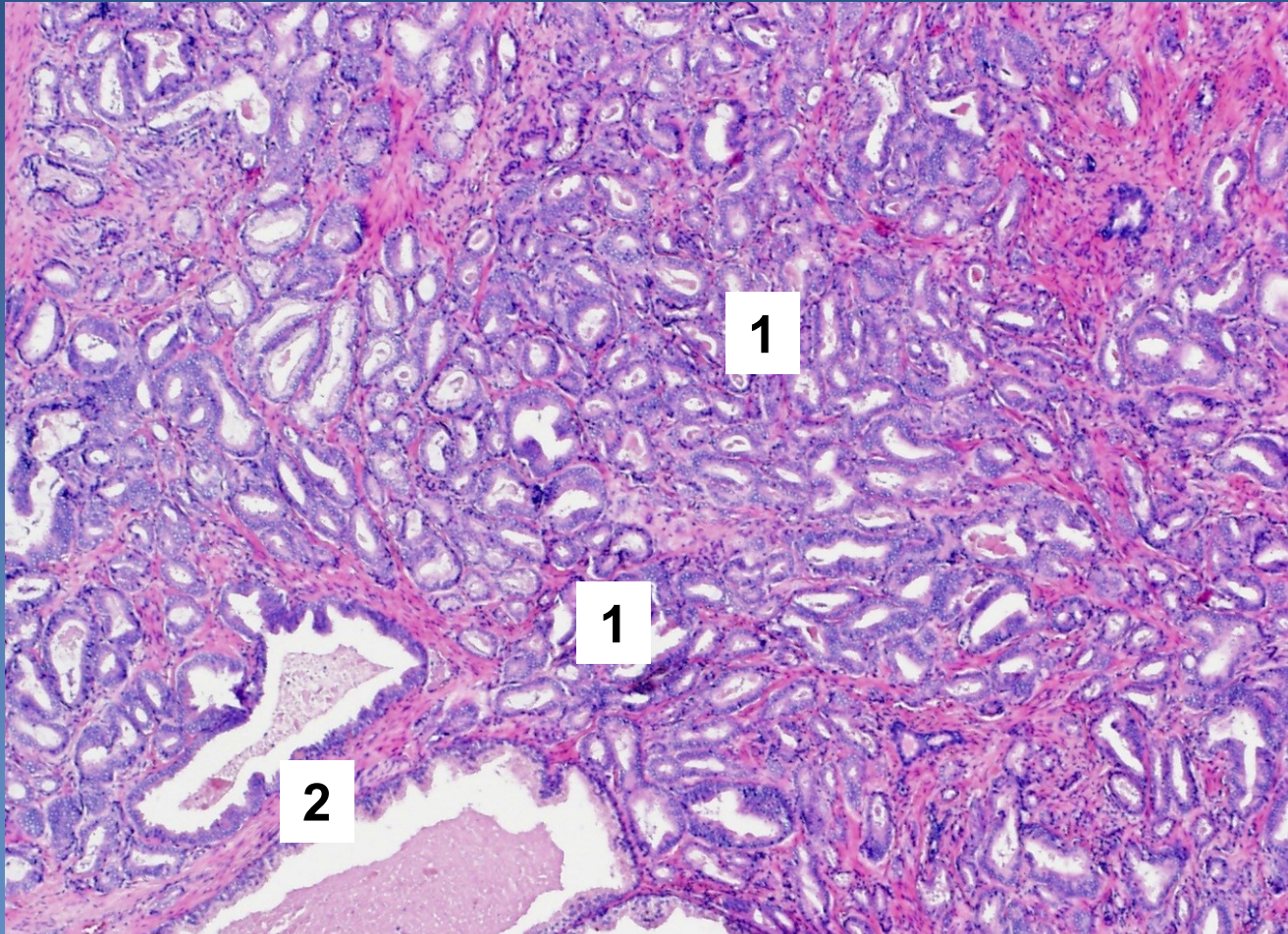
Acinar prostatic adenocarcinoma



x micro:

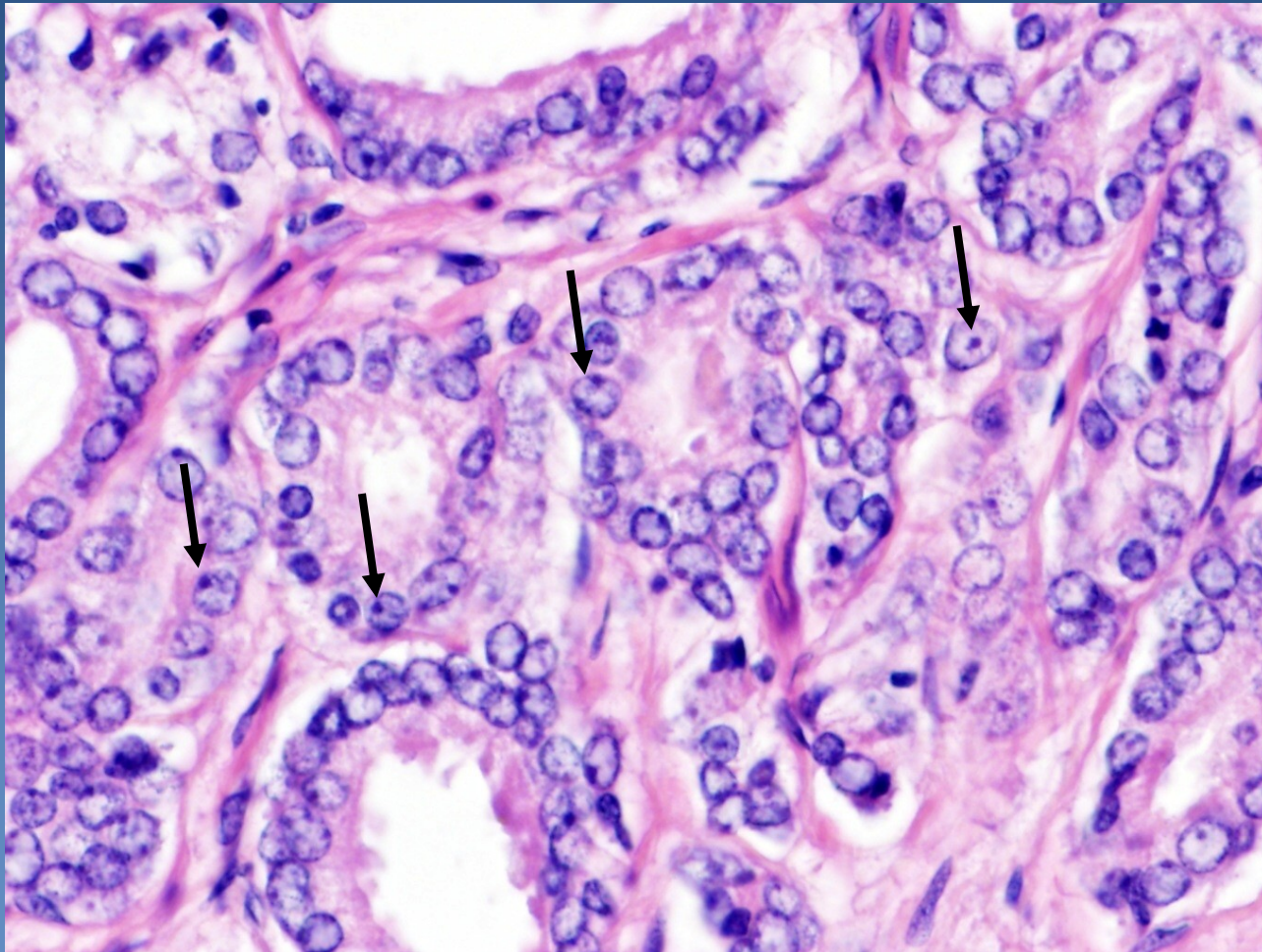
- ⇒ neoplastic cells with round nuclei and prominent nucleoli*
- ⇒ smaller crowded glands **without detectable layer of basal cells***
 - immunohistochemistry: HMW CK, p63 negative
 - neoplastic acini infiltrating between normal glands
 - intraluminal crystalloids (pale eosinophilic substance)
- ⇒ perineural and/or extraprostatic propagation possible*

Acinar prostatic adenocarcinoma



Small neoplastic acini (1) growing between prostatic glands (2)

Acinar prostatic adenocarcinoma




Nucleoli (arrows). Missing basal layer.

Acinar prostatic adenocarcinoma

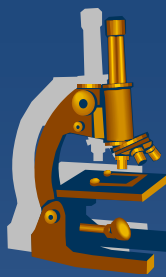


✘ Gleason histologic grading (WHO modification):

- grade of glandular differentiation, growth pattern
- **combined score - dominant + secondary pattern in 5-grade system**
- grade 1 similar to normal prostatic tissue (uncommon in ca)
- grade 5 with solid, dissociated pattern
- final combined score, commonly Gleason score 7 (4+3)

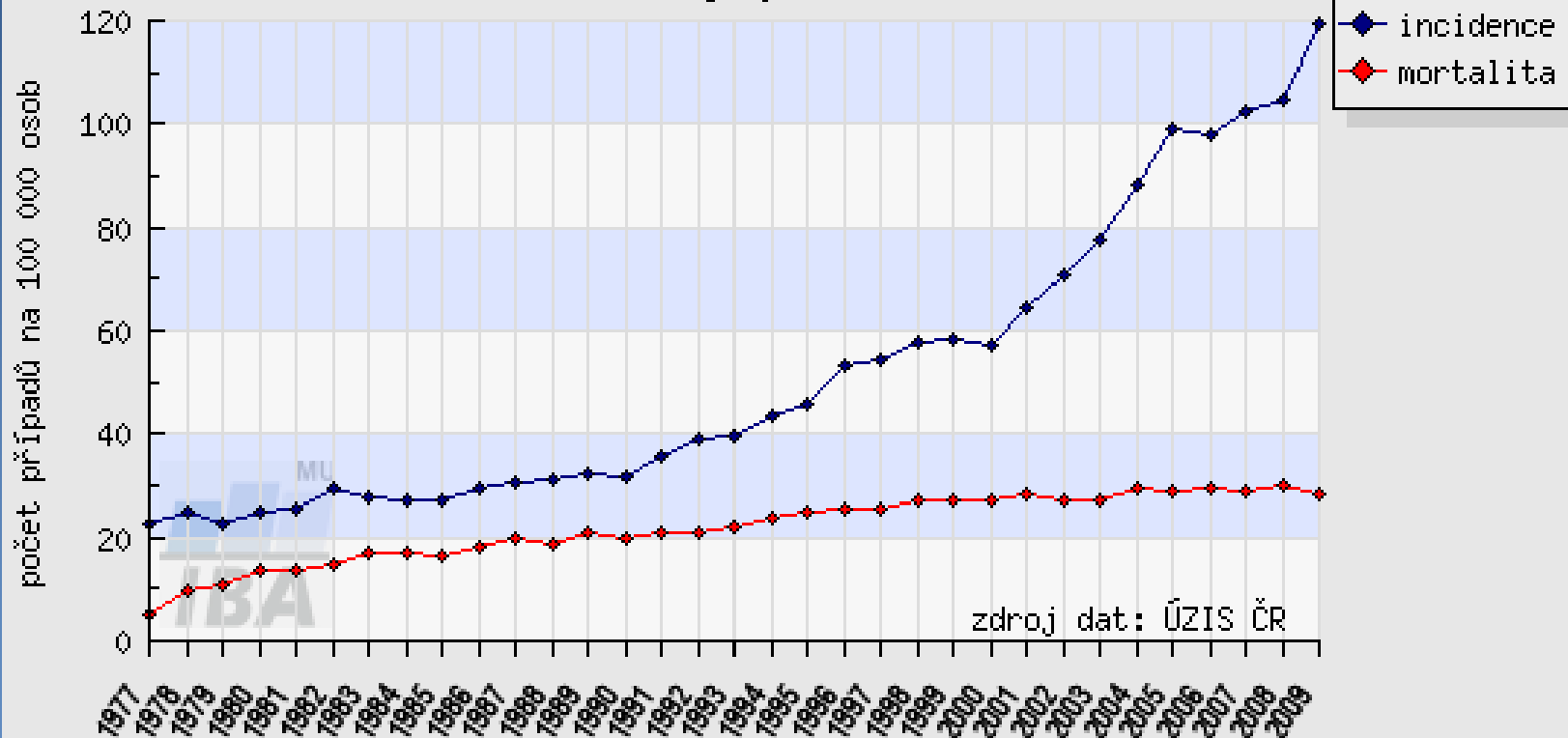


Acinar prostatic adenocarcinoma



C61 - ZN předstojné žlázy - prostaty, muži

vývoj v čase



analyzovaná data: N(inc)=85211, N(mor)=36040

<http://www.uroweb.cz>

Acinar prostatic adenocarcinoma



x spread

⇒ *local (per continuitatem)*

- into periprostatic soft tissues, seminal vesicles, urinary bladder (!x transitional cell ca, may be both in the same patient)

⇒ *via lymphatics*

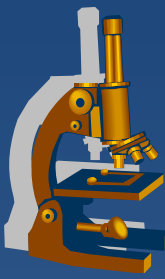
- into regional LN

⇒ *via blood*

- into bones – osteoblastic/osteosclerotic metastases (pelvis, vertebrae, ribs, long bones)
- later into liver, lungs...

x prognosis

- ### ⇒ *depend on the clinical stage (TNM), Gleason score, pre-operative PSA level in serum*



Penis, scrotum

Penis, scrotum



x congenital defects

⇒ *hypospadia, epispadia*

- commonly + cryptorchidism
- in complex somatosexual disorders

⇒ *phimosis*

x circulatory disorders

⇒ *chronic venoous congestion*

⇒ *oedema*

⇒ *corpora cavernosa thrombosis, gangrene (uncommon)*

Penis, scrotum



x inflammations

⇒ ***balanoposthitis*** (*glans + inner surface of the prepuce*)

- STD (gonorrhoea, genital herpes, lymphogranuloma venereum, syphilis ...)
- risk factors:
 - phimosis, chronic mechanical/chemical irritation
 - streptococi, staph., coliforms; candidas (DM)...

⇒ ***balanitis xerotica obliterans = lichen sclerosus***

- epithelial hyperkeratosis, atrophy, inflammatory infiltrate

Penis, scrotum



x tumors, pseudotumors:

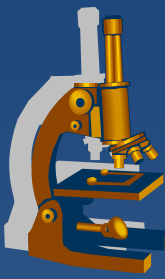
⇒ *Peyronie's disease – penile fibromatosis*

⇒ *benign epithelial tumors*

- **condyloma accuminatum**
 - HPV 6, 11

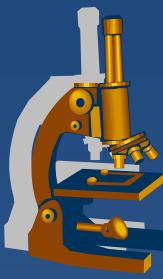
⇒ *malignant epithelial tumors*

- **carcinoma in situ**
 - Bowen's disease / erythroplasia of Queyrat on the glans
 - bowenoid papulosis (multiple, HPV 16, non-progressive)
- **invasive squamous cell carcinoma**
 - geography (Latin America, East Asia)
 - circumcision - protective factor (↓HPV, carcinogenes in smegma)
 - risk factor – smoking, occupational (mineral oil, tar)



Testis, epididymis

Testis, epididymis



x congenital defects

⇒ *cryptorchidism (undescended testis)*

x circulatory and regressive changes

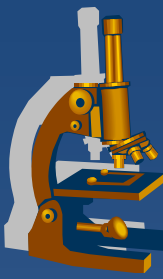
⇒ *necrosis (haemorrhagic infarction) – typical due to testicular torsion, ! emergency*

⇒ *atrophy – senile involution, vascular, hormonal...*

⇒ *intrascrotal swelling*

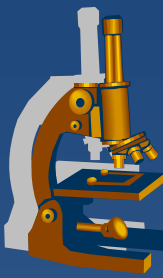
- hydrocele (serous fluid in tunica vaginalis)
- haematocele (haemorrhage into tunica vaginalis)
- varicocele (varicose veins)
- spermatocele (cystic dilatation of epididymis ducts)

Testis, epididymis inflammations



- ✗ epididymis >>> testis
- ✗ usually ascending from urinary tract and/or prostate
- ✗ caused by
 - ⇒ *gramnegative bacteria (children)*
 - ⇒ *chlamydias, gonococcus (adults)*
 - ⇒ *E. coli (older adults)*

Testis, epididymis inflammations



x Bacterial

⇒ *purulent* → *abscess, non-specific orchitis/epididymitis*

x Interstitial non-purulent orchitis

⇒ *mumps in adults*

⇒ *interstitial oedema + lymphocytes, plasma cells, macrophages*

x Granulomatous orchitis

⇒ *may be posttraumatic, v.s. autoimmune inflammation*

⇒ *non-caseating tuberculoid granulomas centered on tubules*

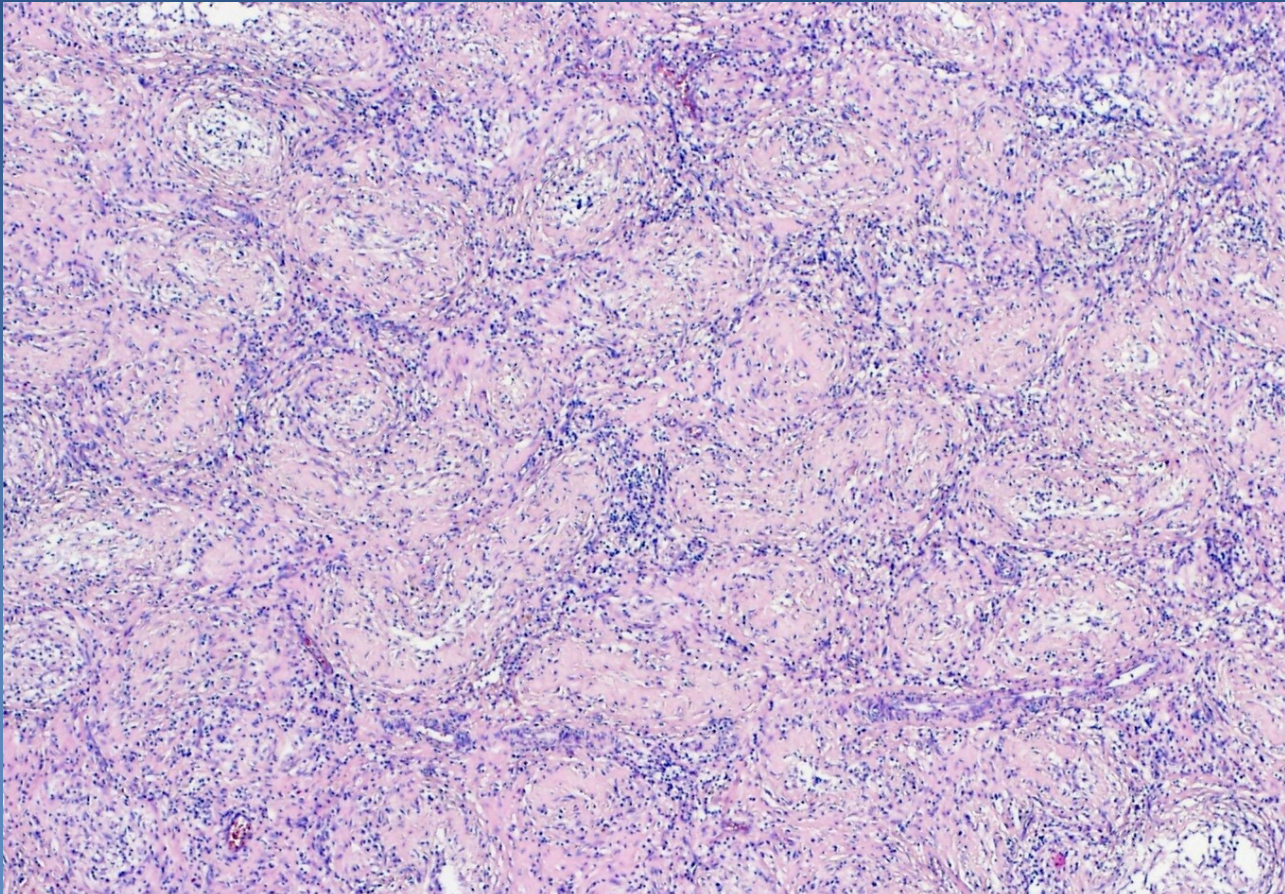
⇒ *firmer testicular mass (diff. dg. x tumor)*

x Spermatocytic granuloma

⇒ *in the head of epididymis due to rupture of tubules*

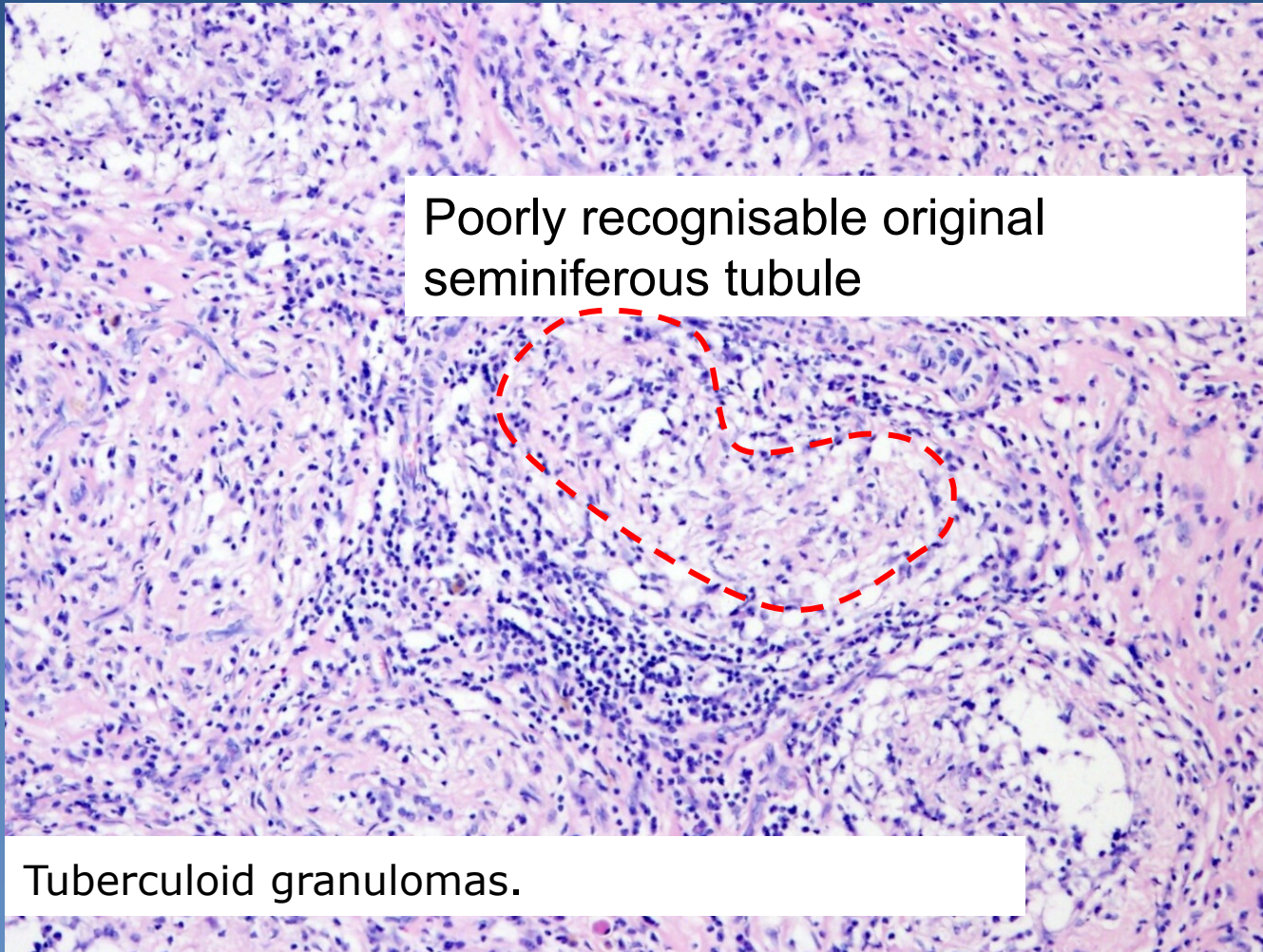
⇒ *reactive tuberculoid granulomas around spermatozoa*

Granulomatous orchitis



Tuberculoid granulomas.

Granulomatous orchitis



Poorly recognisable original seminiferous tubule

Tuberculoid granulomas.

Testicular tumors



- × **Germinal**

 - ⇒ *from germ cell*

- × **Sex cord-stromal**

 - ⇒ *from specialized mesodermal gonadal stroma*

- × **Mixed germ cell – sex cord stromal tumors**

- × **Other primary tumors**

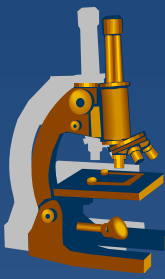
- × **Metastatic (secondary) tumors**

Testicular tumors : histopathological report




- x** gross picture (incl. size)
- x** histological type
- x** presence of vascular / lymphatic propagation
- x** tumor staging (TNM classification)
- x** presence of intratubular germ cell neoplasia (ITGCN - in situ germ cell lesion)

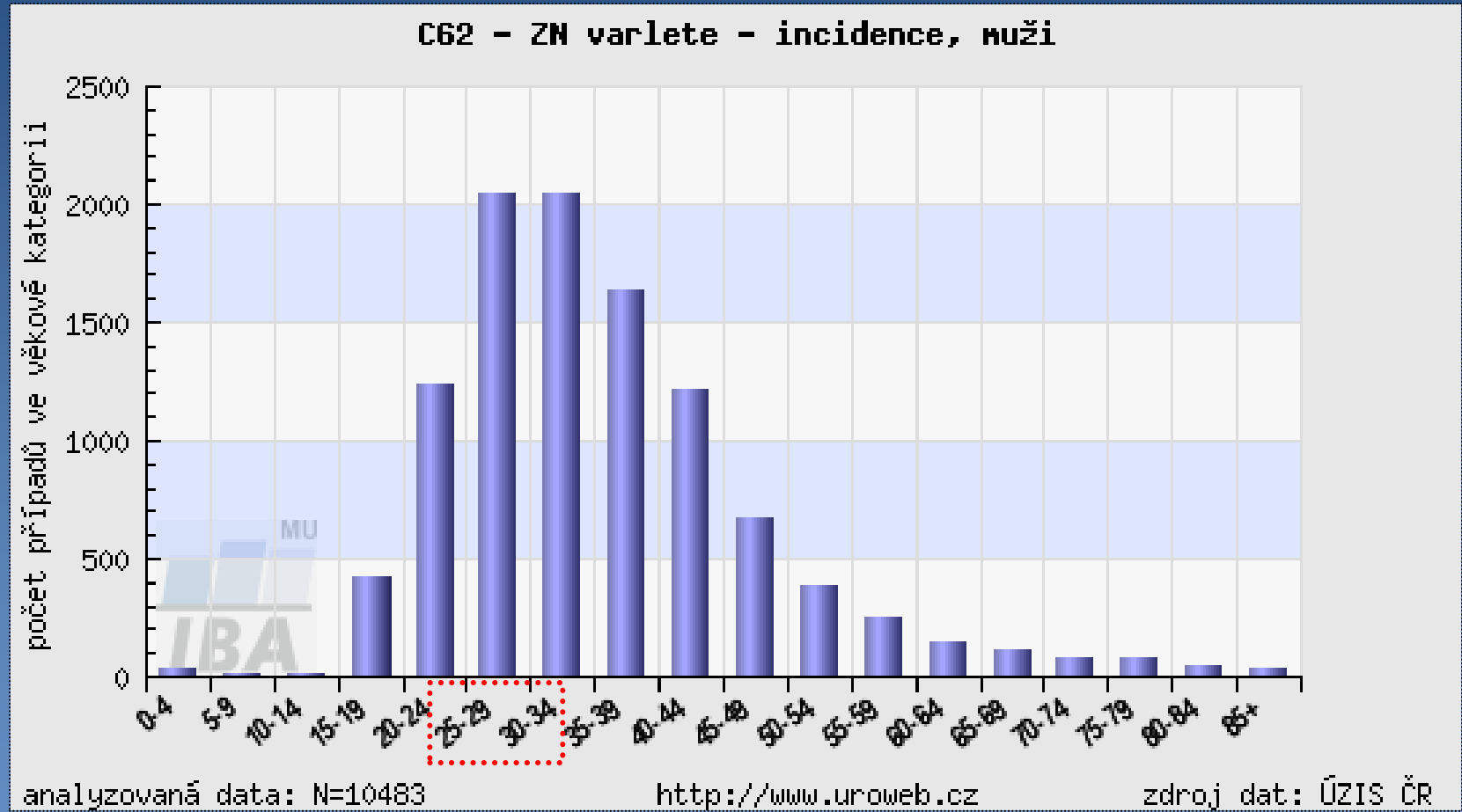
Germ cell tumors



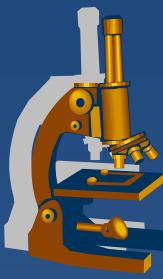
- x ~90 % of primary testicular tumors
- x cryptorchidism
 - ⇒ 3-5x ↑ risk of malignancy in undescended testis
- x oncogenic markers:
 - ⇒ α FP, hCG, PLAP, CEA, LDH
 - ⇒ detection in serum, tissues
 - ⇒ important in diagnosis, monitoring the response to therapy, patient check-up after therapy



Age structure of testicular tumors patients

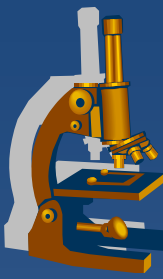


Germ cell tumors



- ✘ intratubular germ cell neoplasia
 - ⇒ *ITGCN - in situ germ cell lesion*
 - ⇒ *common precursor lesion of germ cell tumors*
- ✘ basic classification:
 - ⇒ *seminoma*
 - ⇒ *non-seminomatous tumors*
- ✘ germ cell tumors of 1 histologic type – 60 %
- ✘ mixed germ cell tumors – 40 %
- ✘ metastases into LN (paraaortal LN),
via blood (most commonly into lungs)

Germ cell tumors histogenesis



Differentiation along gonadal line (gonocyte, spermatogonia)
without further differentiation potential.
Seminoma

Original primitive
germ cell

Undifferentiated cell
Embryonal carcinoma

Totipotent cell

Extraembryonal differentiation
Yolk sac tumor
Choriocarcinoma

Intraembryonal differentiation
Teratoma (mature, immature, with
malignisation of somatic elements)
Polyembryoma

Germ cell tumors classification



x tumors of single histologic type

⇒ ***Seminoma*** (+ variants)

⇒ ***Non-seminomatous germ cell tumors***

- **Embryonal carcinoma**
- **Yolk sac tumor**
- **Choriocarcinoma**
- **Teratomas**
 - mature
 - immature
 - with malignisation of somatic elements

Germ cell tumors classification



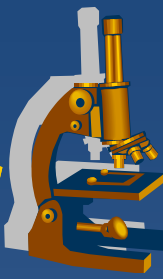
- x mixed germ cell tumors**

 - ⇒ tumors with >1 histogenetic type*

- x Spermatocytic seminoma**

 - ⇒ separate clinical and pathological entity
(different morphology/prognosis)*

Germ cell tumors Characteristics



	age	marker	structure
Seminoma	30-50	10% HCG	solid, clear cells, lymphocytic stroma
Embryonal carcinoma	20-30	90% HCG/AFP	undiff. cells, organoid, necrosis
Yolk sac	<3	90% AFP	variable
Choriocarcinoma	20-30	100% HCG	cyto- + syncytiotrophoblast
Teratoma	no predilection	possible HCG,AFP	variable structures of >1 germ layer
Mixed tu	15-30	possible HCG,AFP	variable structures

Seminoma



x classical

⇒ *morphological variants:*

- seminoma with high mitotic rate (anaplastic), same treatment
- seminoma with syncytiotrophoblastic cells (↑ HCG)

⇒ *mostly age 25 - 45 years*

⇒ *tumor cells*

- in solid nests
- large cell, clear cytoplasm (glycogen), distinctive cellular membrane, large nuclei with 1-2 nucleoli

⇒ *fibrovascular septa*

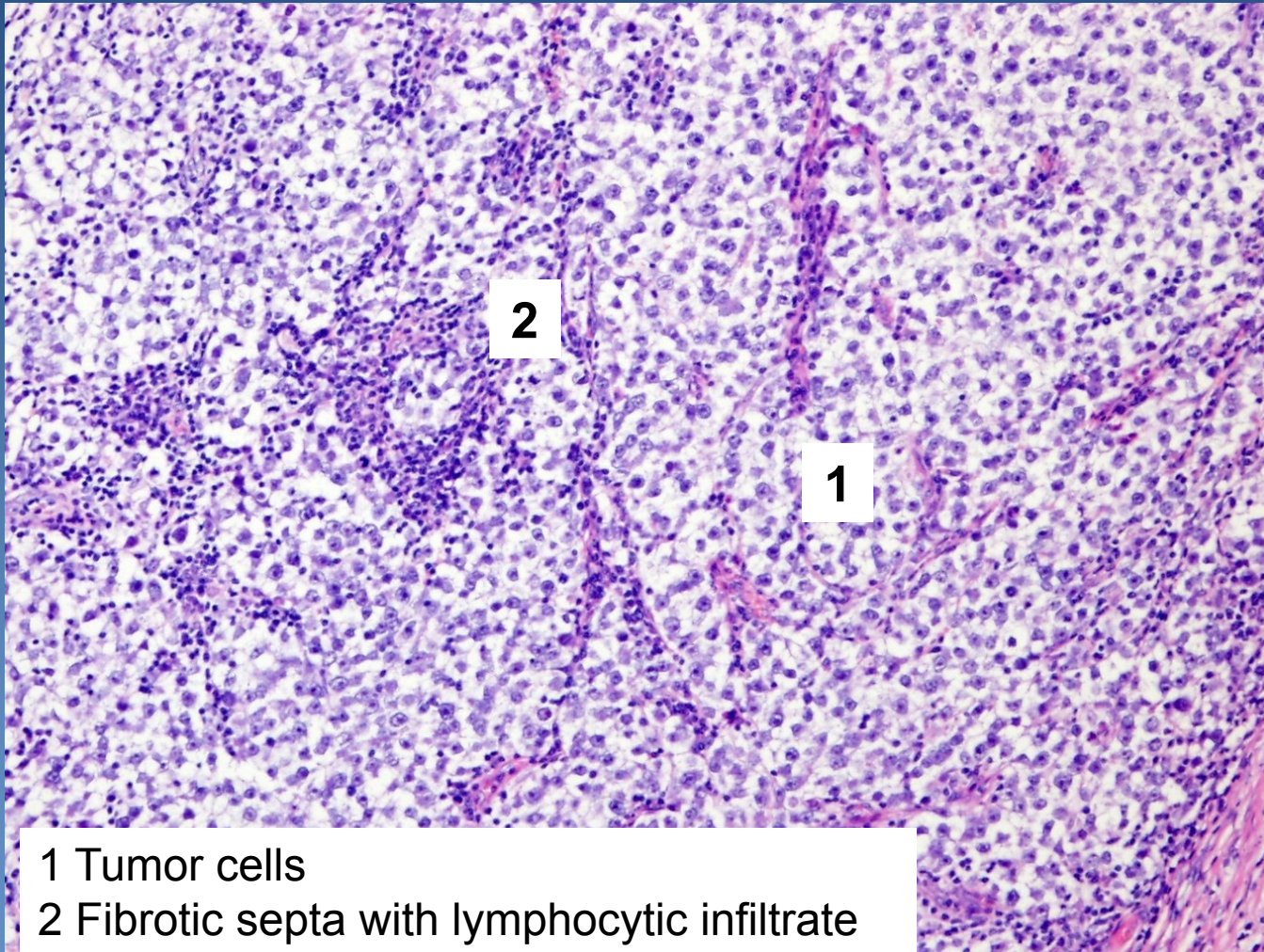
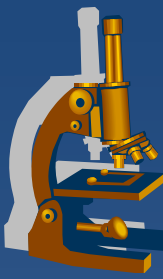
- with lymphocytic infiltrate (event. + granulomas)

⇒ *immunohistochemistry: PLAP+*

⇒ *marker – 10% HCG*

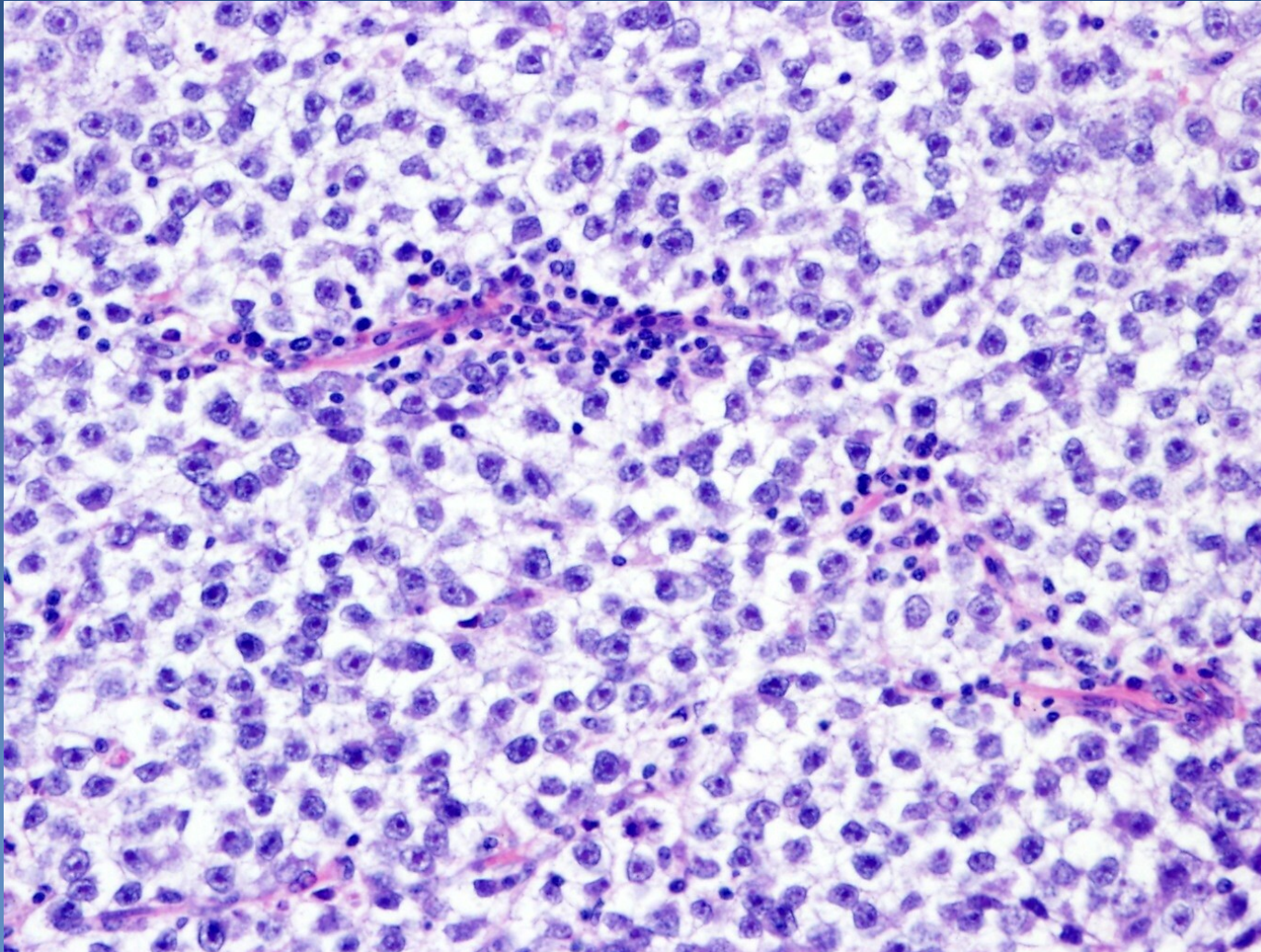
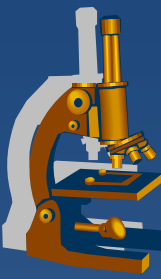
⇒ *radio- and chemosensitive (usually good prognosis)*

Seminoma



- 1 Tumor cells
- 2 Fibrotic septa with lymphocytic infiltrate

Seminoma

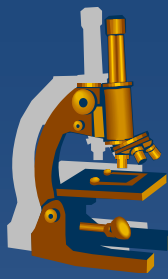


Seminoma

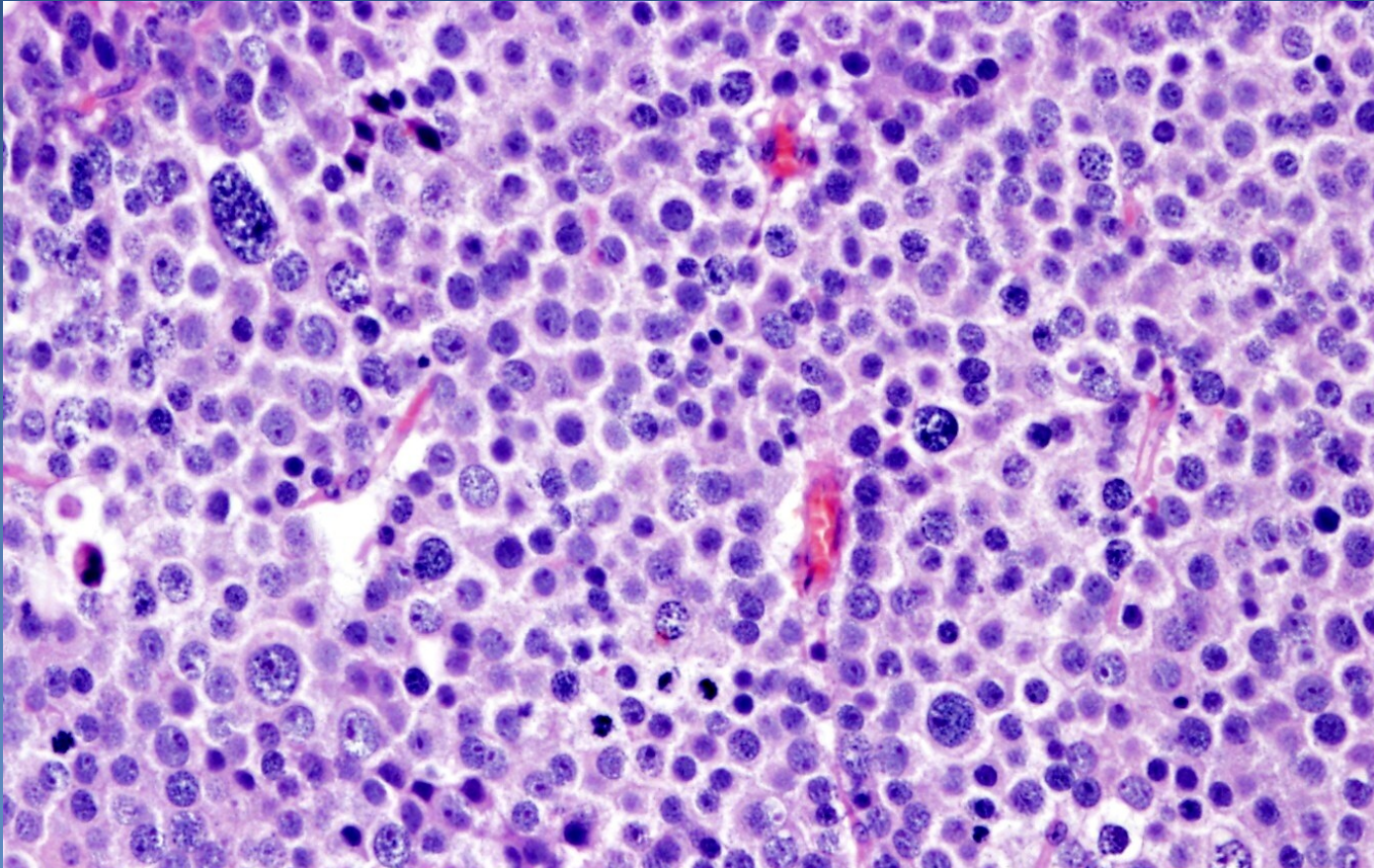


x Spermatocytic

- ⇒ *quite distinctive tumor, not a part of mixed germ cell tumors*
- ⇒ *only in the testis, older M, rare*
 - locally aggressive, no metastases
- ⇒ *tumor cells*
 - variable size (≈early stages of spermatogenesis)
 - **no glycogen**, no association with intratubular germ cell neoplasia
- ⇒ *fibrovascular septa without lymphocytic reactive infiltrate*
- ⇒ *IHC: PLAP-*



Spermatocytic seminoma



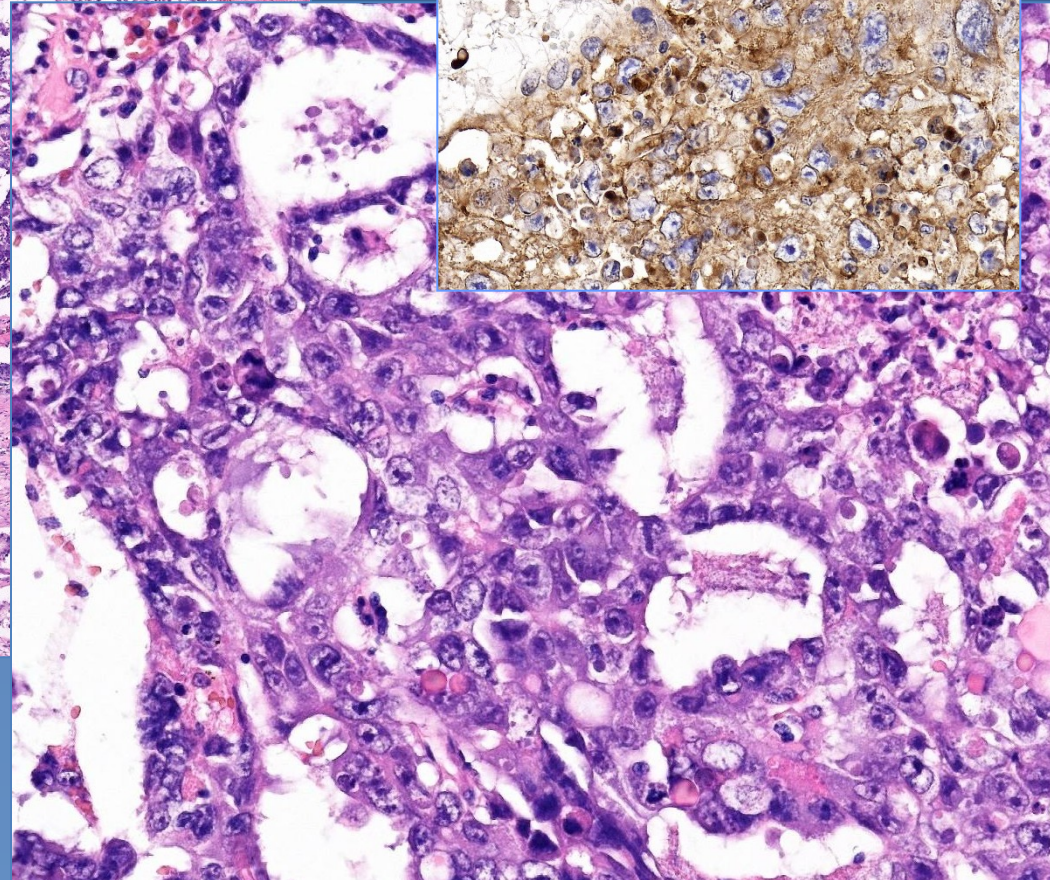
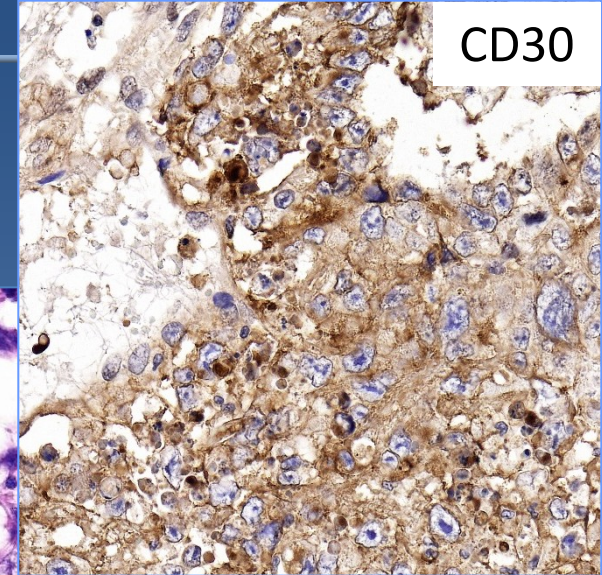
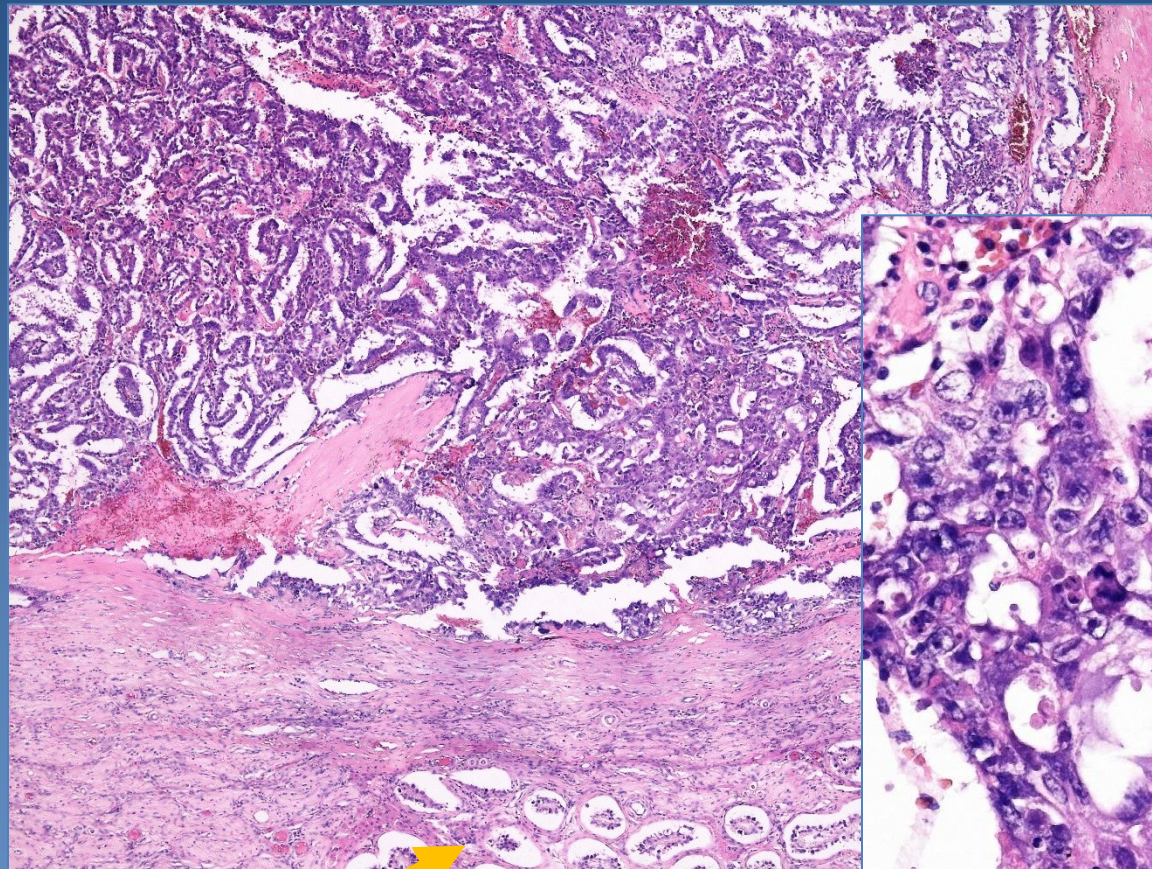
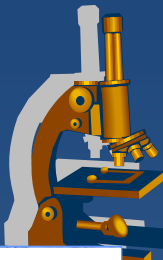
Mixture of polymorphic tumor cells (~ early stages of spermatogenesis): large cells with lacy chromatin, middle-sized cells with round nuclei, small lymphocyte-like cells.
Fibrotic septa without lymphocytic infiltrate

Embryonal carcinoma



- ✗ undifferentiated tumor, cells of epithelial appearance
- ✗ commonly as part of mixed germ cell tumors
 - ⇒ *worse prognosis*
- ✗ **micro:**
 - ⇒ *solid, trabecular, abortive tubular formations*
 - ⇒ *large cells, high mitotic activity*
 - ⇒ *stroma without lymphatic reaction*

Embryonal carcinoma



Seminiferous tubules

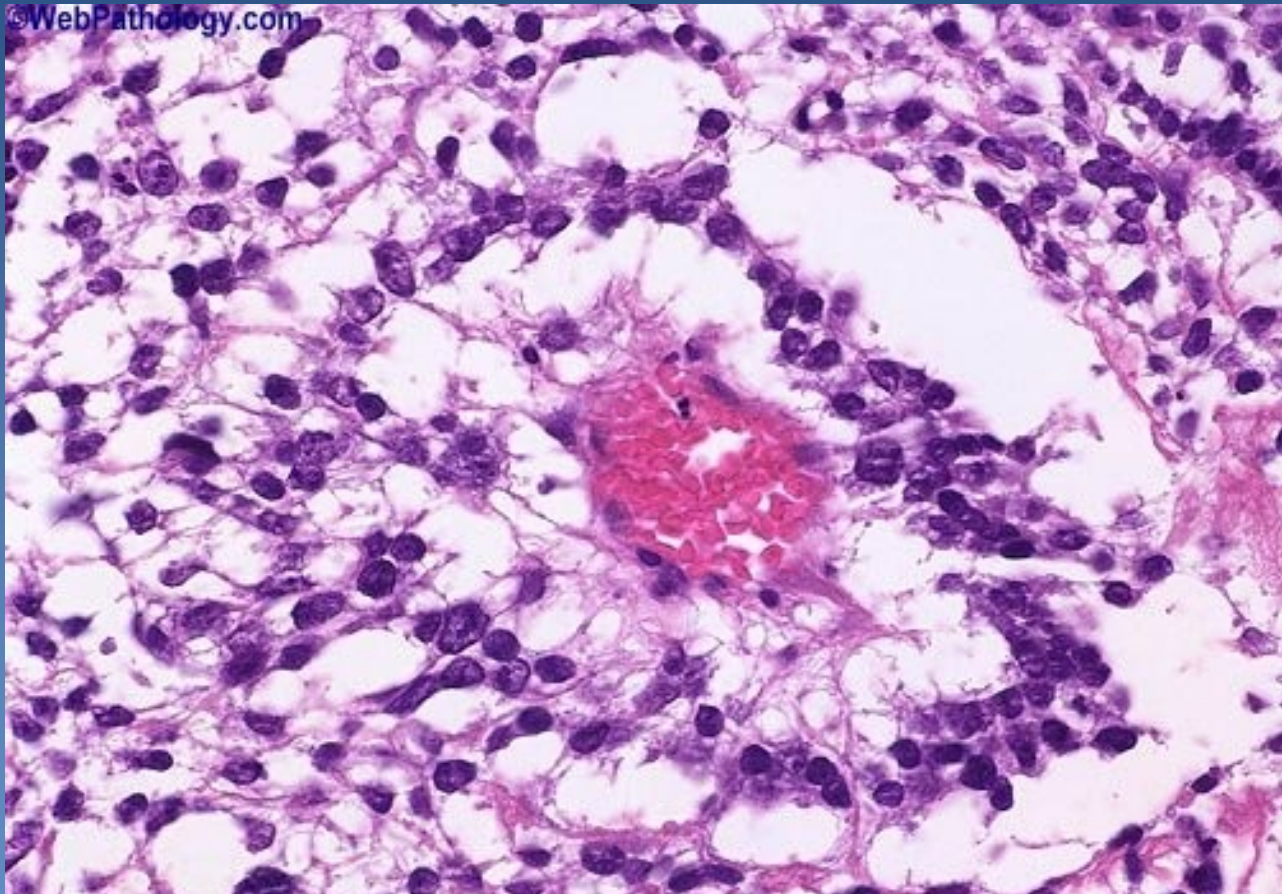
Yolk sac tumor



- ✗ ~ yolk sac structures, extraembryonal mesodermal tissues
- ✗ in pure form in infants, young (<3 yrs) children, better prognosis
- ✗ in adults a component of mixed germ cell tumors, worse prognosis
- ✗ α -fetoprotein (AFP) secretion – IHC, serum

- ✗ **micro:**
 - ⇒ *microcystic, reticular, papillary formation, variable patterns*
 - ⇒ *glomeruloid structures (Schiller-Duval bodies)*
 - stalk with capillary lined on the surface by layer of tumor cells
 - ⇒ *tumor cells*
 - flat, polygonal or cuboidal

Yolk sac tumor



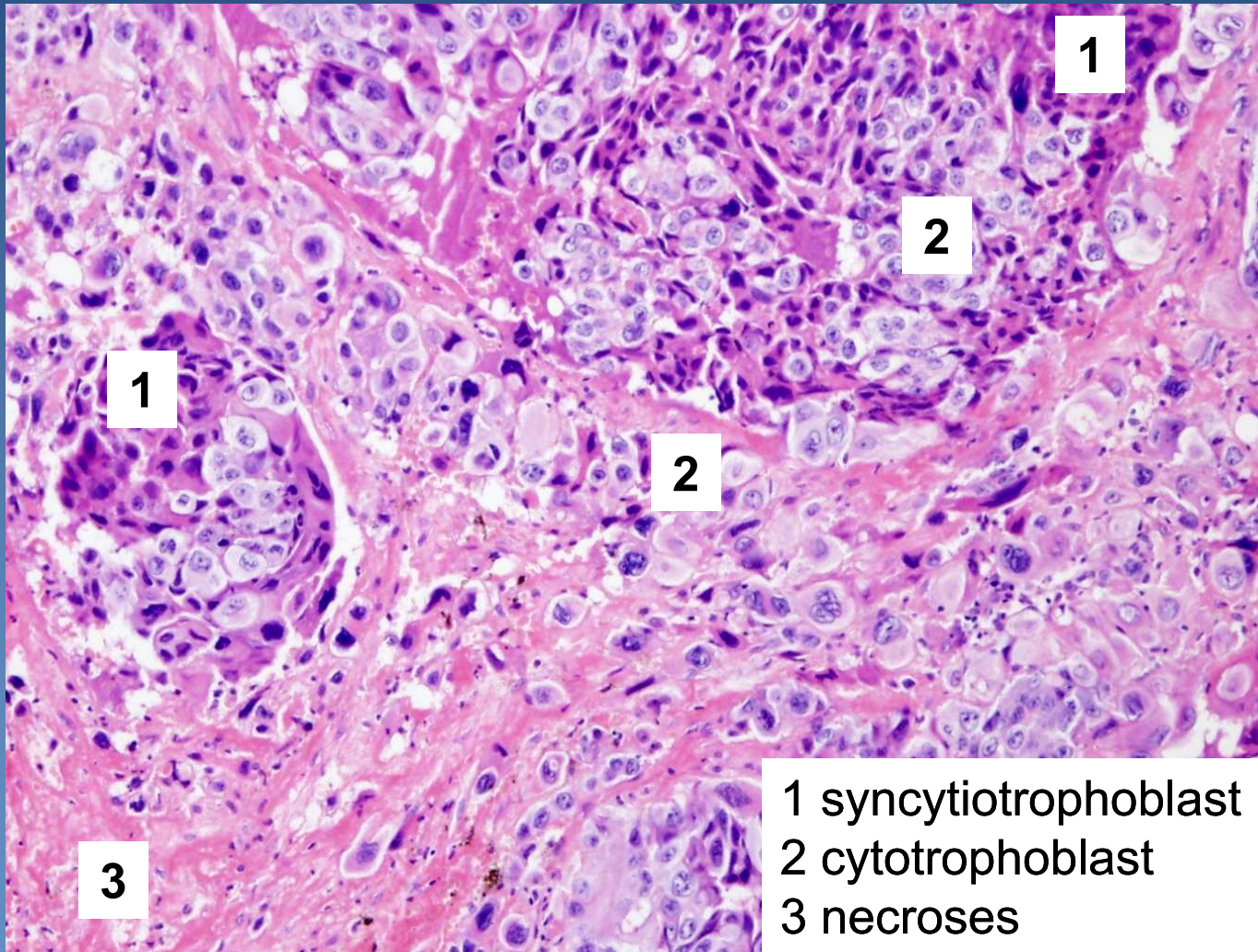
Schiller-Duval body (glomeruloid formation)

Choriocarcinoma

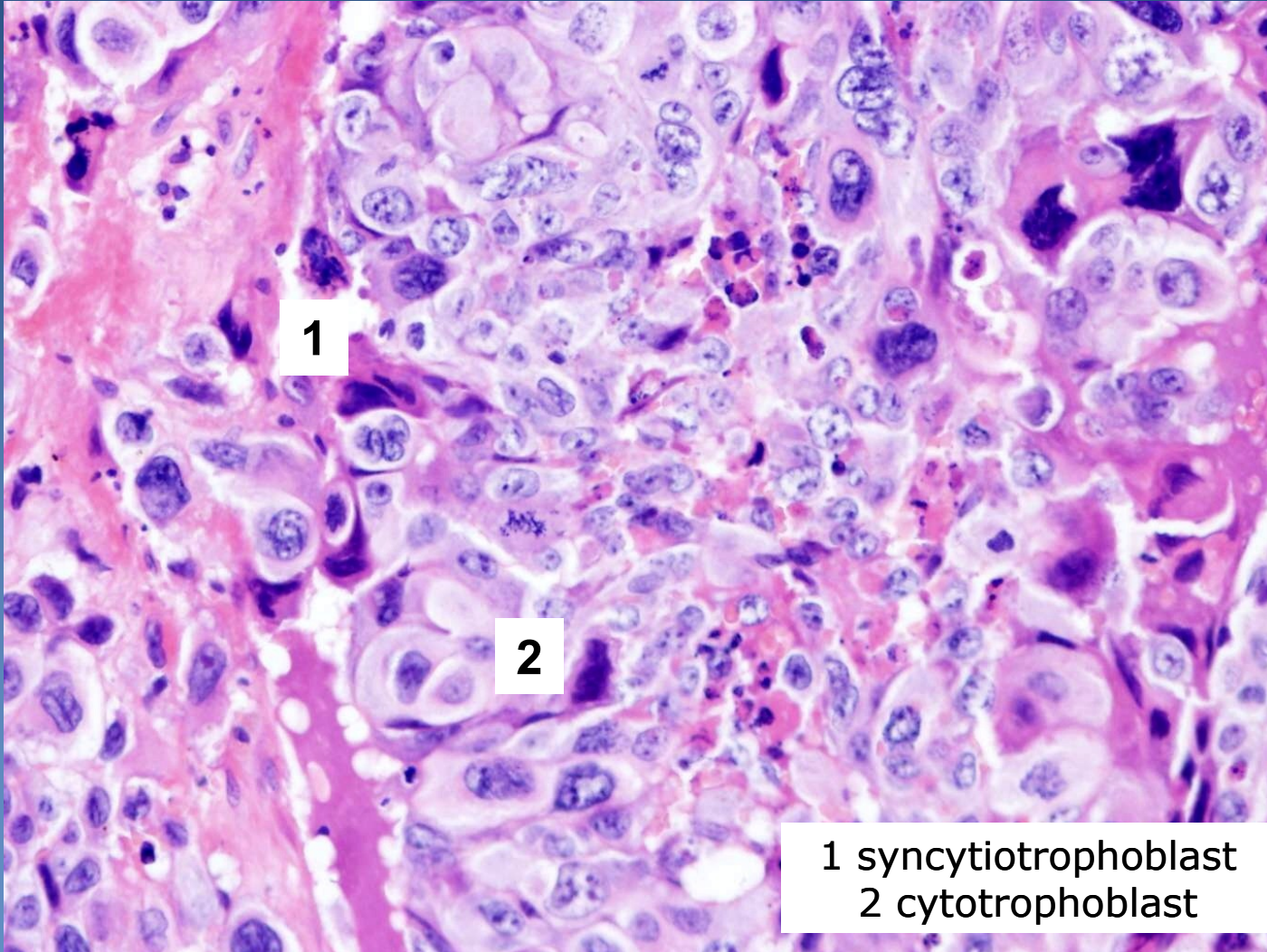


- ✘ mixture of syncytiotrophoblast, cytotrophoblast, intermediate trophoblast cells
- ✘ pure very rare, more commonly as component of mixed germ cell tumors, HCG ↑
- ✘ gross/ micro:
 - ⇒ *haemorrhagic + necrotic tumor*
 - ⇒ *variable patterns of syncytiotrophoblast with admixture of larger polygonal cells of cytotrophoblast event. + intermediate trophoblast*

Choriocarcinoma



Choriocarcinoma



Teratoma



x intraembryonal differentiation

⇒ *terminal differentiation into 3, 2 or 1 germ layers (monodermal teratoma)*

x mature uncommon in testis (x ovary); pure in children

x histologic classification

⇒ *differentiated mature t.*

- completely matured tissues with organoid structure
- commonly cystic, containing serous fluid, mucus, keratin

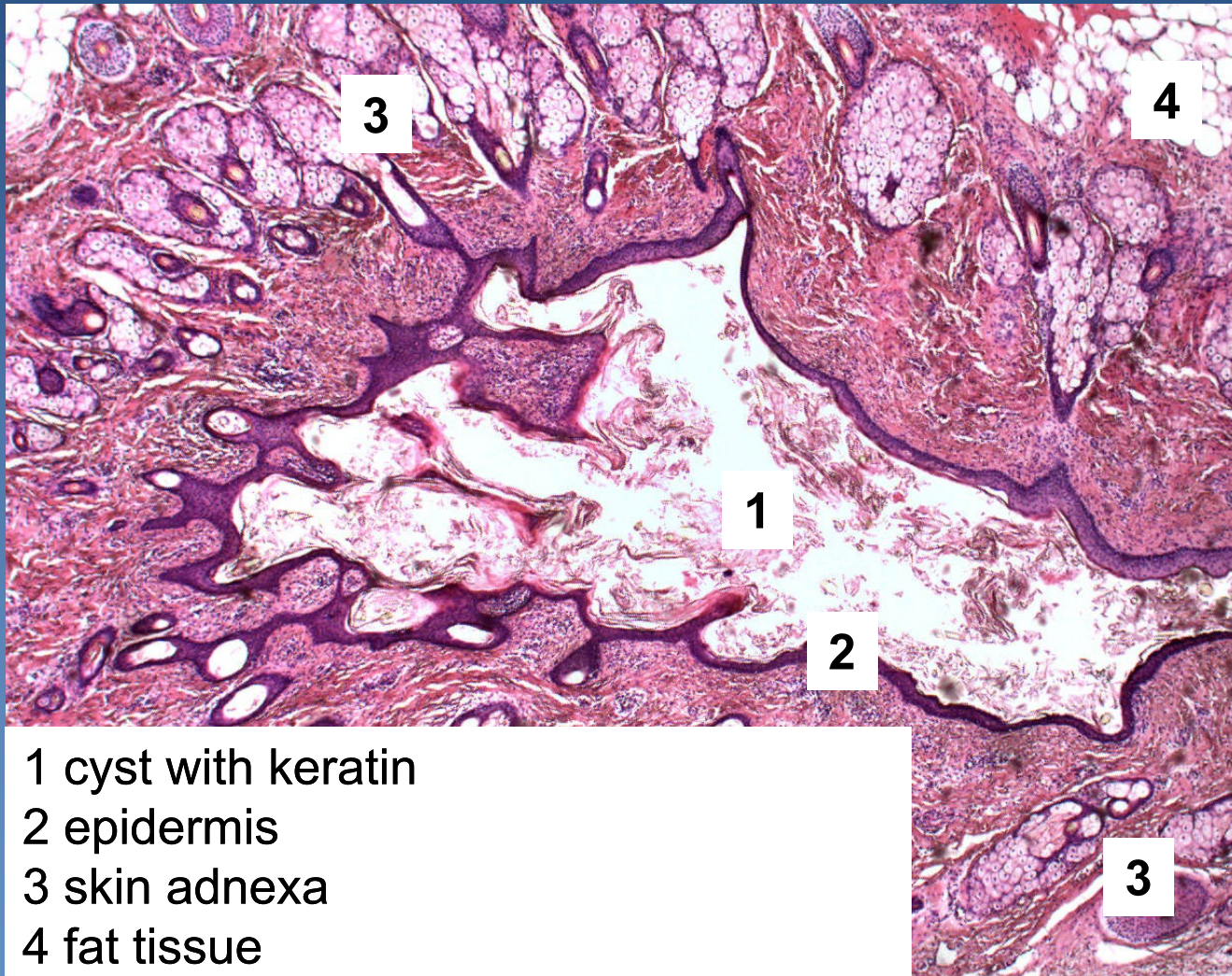
⇒ *differentiated immature t.*

- immature tissues of embryonal/fetal appearance (neuroectoderm)

⇒ *t. with somatic type malignancy*

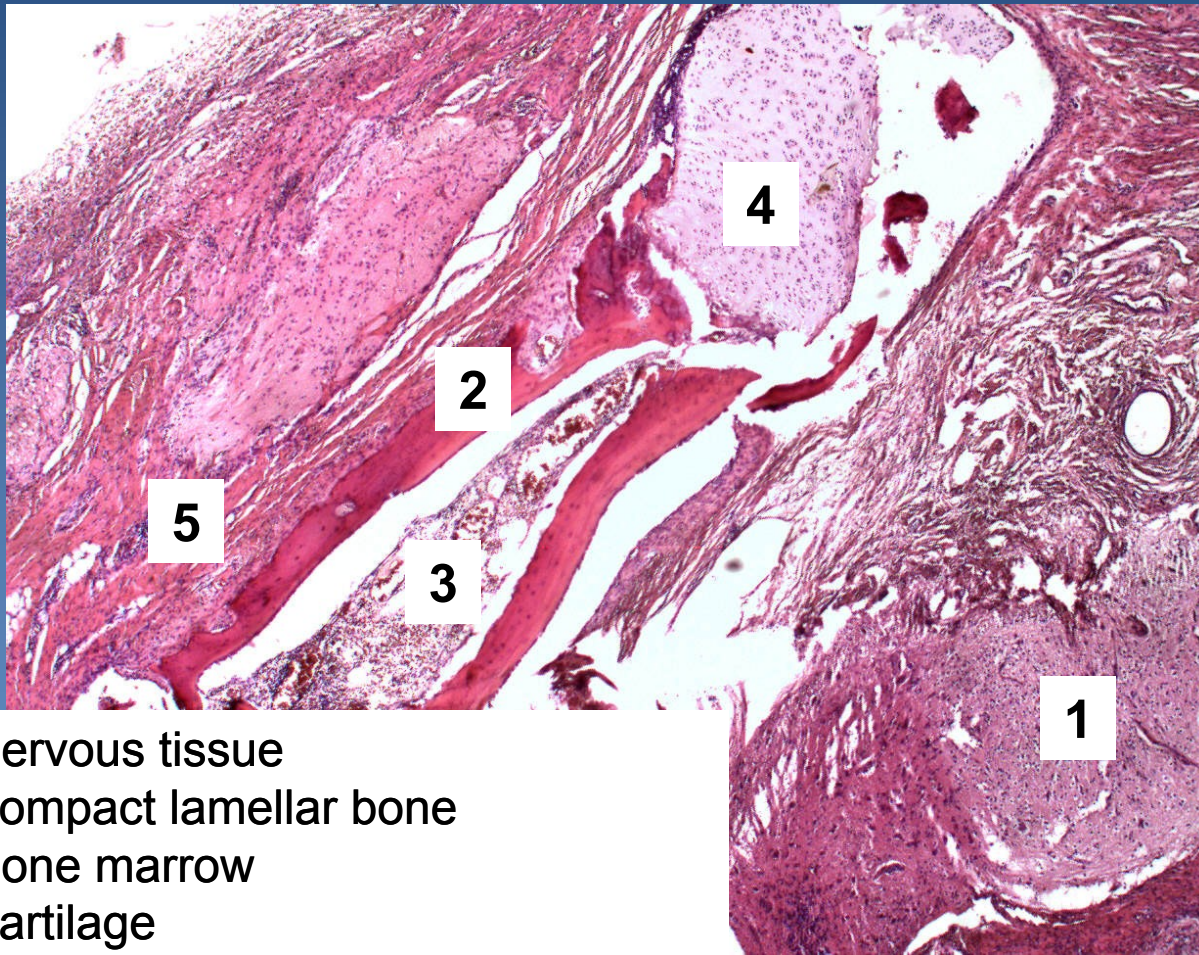
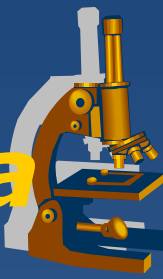- sarcoma, carcinoma, PNET

Differentiated mature teratoma (dermoid cyst)



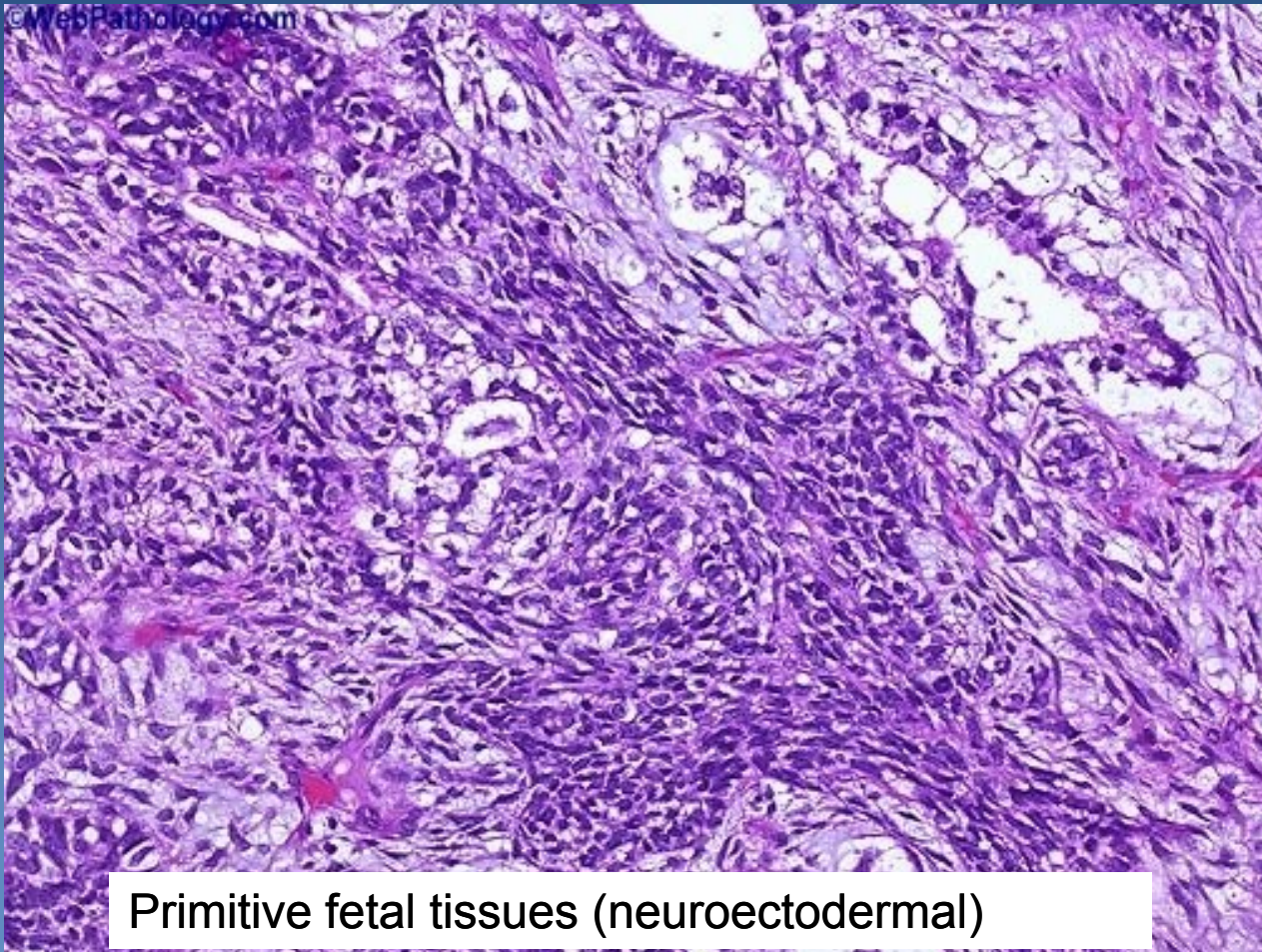
- 1 cyst with keratin
- 2 epidermis
- 3 skin adnexa
- 4 fat tissue

Differentiated mature teratoma



- 1 nervous tissue
- 2 compact lamellar bone
- 3 bone marrow
- 4 cartilage
- 5 striated muscle

Differentiated immature teratoma



Extragonadal germ cell tumors (EGT)



- ✗ primary germ cell tumors arising in extragonadal localisation

- ✗ more common in males

- ✗ origin unclear:
 - ⇒ *from primordial germ cells?*
 - ⇒ *faulty migration?*
 - ⇒ *faulty localisation of totipotent cells?*
 - ⇒ *ectopic germ cells in healthy people?*

Extragenital germ cell tumors (EGT)



✗ localisation:

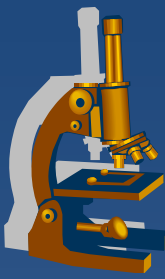
⇒ *in midline structures (pathway of germ cells descensus into gonadal blastema):*

- brain (pineal, suprasellar) sacrococcygeal, anterior mediastinum, retroperitoneum,..., thymus, prostate, stomach,.....

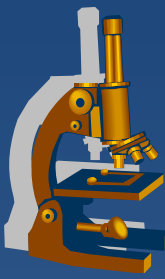
✗ seminomas, non-seminomatous

✗ pure or mixed

✗ general prognosis worse, except EGT seminoma



Female genital system pathology

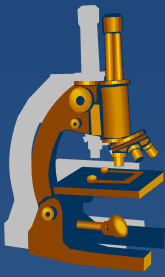


- x vulva**
- x vagina**
- x exocervix, endocervix**
- x uterine body**
 - ⇒ *endometrium*
 - ⇒ *myometrium*
- x fallopian tubes**
- x ovaries**

Pathology



- ⇒ *inborn defects*
- ⇒ *circulatory disorders*
- ⇒ ***inflammations***
- ⇒ ***tumors***



Vulva

Vulvar inflammations



- x candida**

 - ⇒ *mycotic vulvovaginitis (DM, post-ATB)*

- x HPV**

 - ⇒ *condyloma accuminatum, vulvar intraepithelial neoplasia - dysplasia (VIN I-III)*

- x HSV, type 2, 1**

 - ⇒ *vesicles → ulcers, primoinfection + systemic signs*

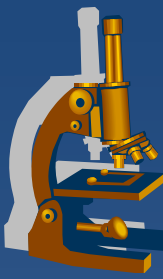
- x Neisseria gonorrhoeae**

 - ⇒ *purulent inflammation (gonorrhea) in glands – periurethral, Bartholin, ...*

- x Treponema pallidum**

 - ⇒ *lues (chancre)*

Non-neoplastic epithelial disorders

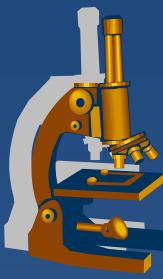


- x gross appearance of leukoplakia – white plaque**
- x mostly in peri-, postmenopausal women**
- x inflammatory dermatoses (psoriasis, chronic dermatitis), pre-malignant lesions (VIN, ca), disorders of unknown etiology**

- x Lichen sclerosus**
 - ⇒ *epithelial atrophy + hyperkeratosis*
 - ⇒ *superficial dermis – band of oedema + hyalinisation*
 - ⇒ *perivascular mononuclear inflammatory cell infiltrate*
 - ⇒ → → *stenosis of vaginal orifice (craurosis vulvae)*

- x Lichen simplex chronicus – squamous cell hyperplasia**
 - ⇒ *epithelial hyperplasia + marked hyperkeratosis*
 - ⇒ *not a precancerosis*

Vulvar neoplasia



x condyloma accuminatum

⇒ *low-risk HPV (6, 11)*

⇒ *squamous cell papilloma with koilocytar epithelial transformation*

x vulvar intraepithelial neoplasia - VIN

⇒ *high-risk HPV (16)*

⇒ *VIN II, III –high risk of progression into SCC*

x carcinoma

⇒ *squamous ca (90 %)*

- **precursor lesions:**

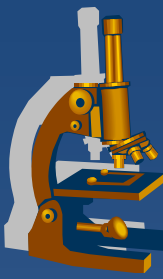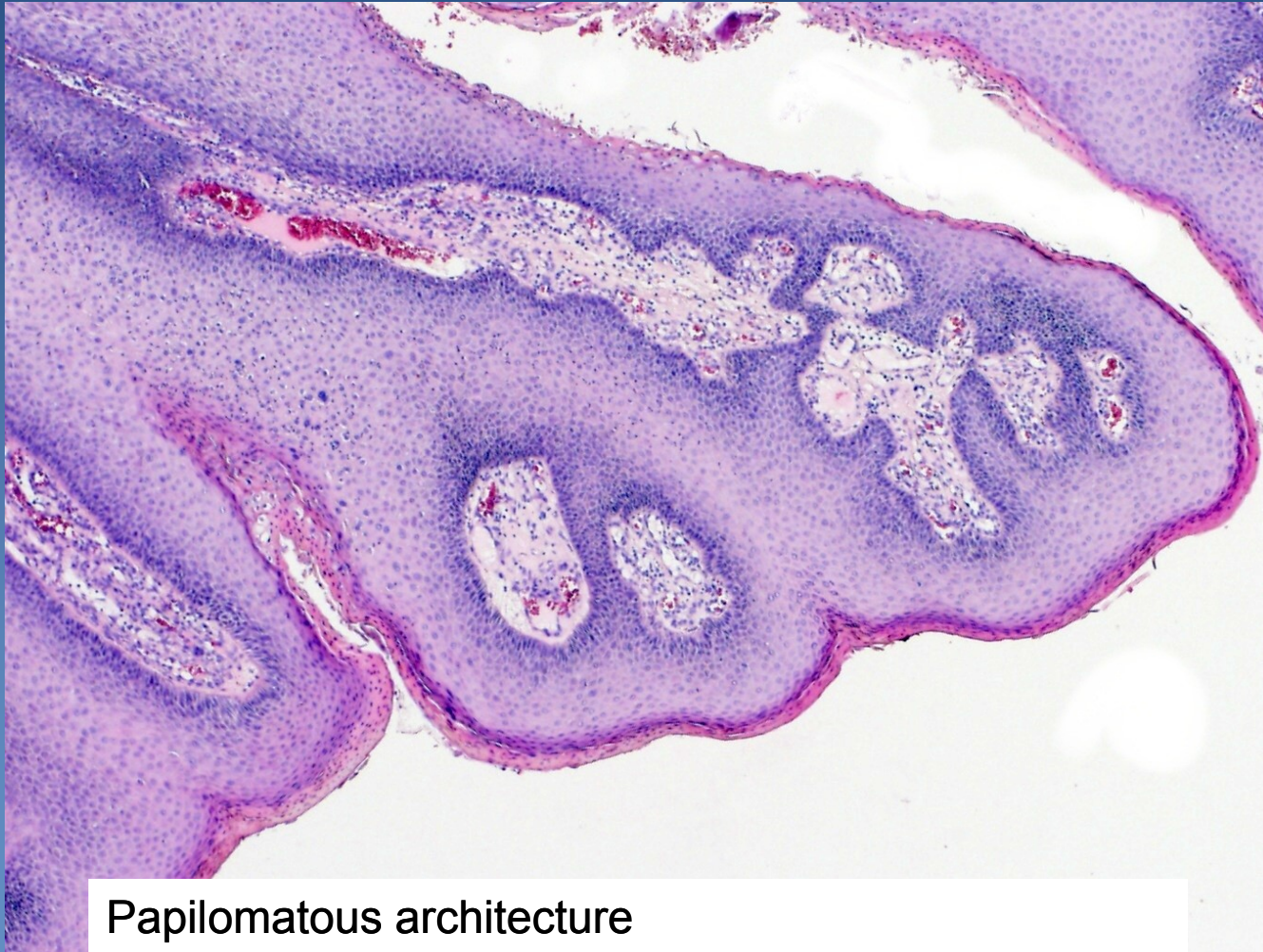
- VIN II, III

- lichen sclerosus (in older females)

⇒ *adenocarcinoma, basal cell carcinoma*

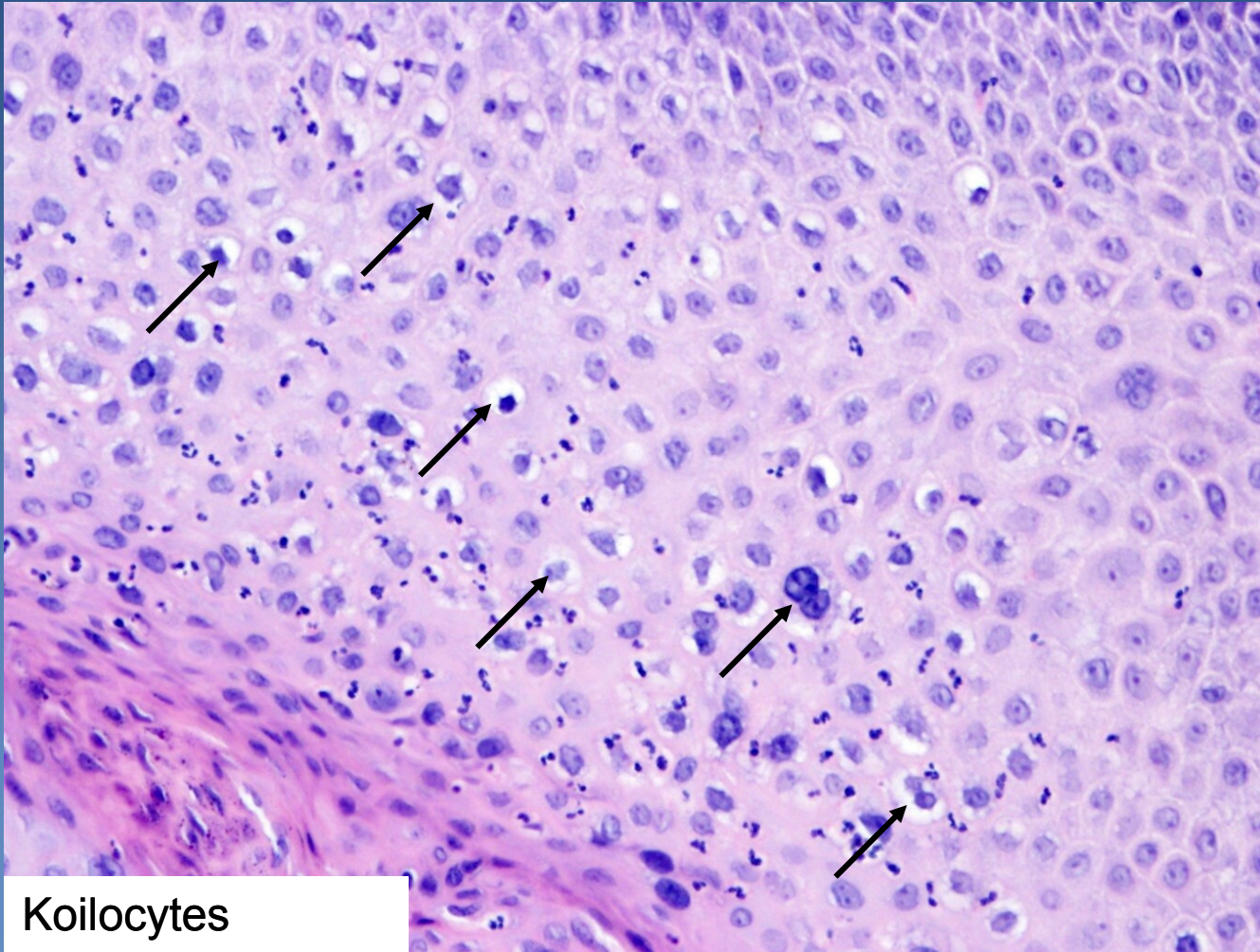
x malignant melanoma

Condyloma accuminatum

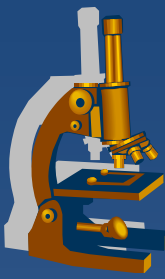


Papillomatous architecture

Condyloma accuminatum



Koilocytes
(arrows)



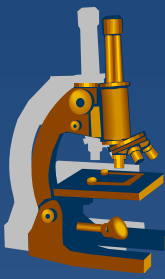
Vagina

Vaginal inflammation



- ✘ colpitis commonly concurrent with cervicitis, catarrhal or purulent inflammation
- ✘ STD: *Trichomonas vaginalis*; *Neisseria gon.*; bacterial vaginosis (*Gardnerella* + anaerobes); candidosis, ...

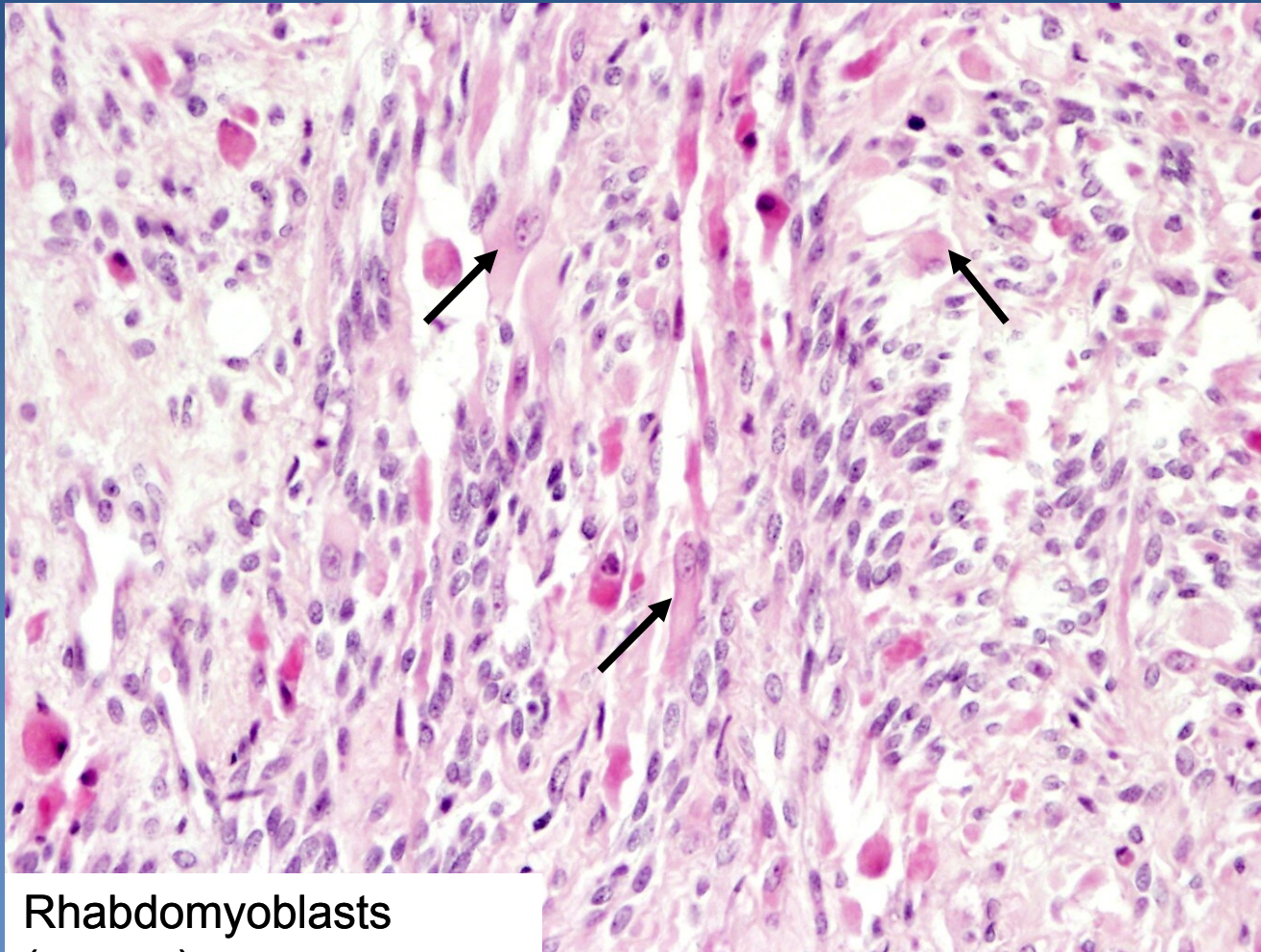
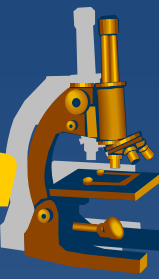
Vaginal tumors and pseudotumors



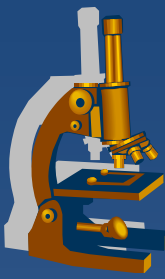
- x fibroepithelial polyps, glandular cysts**
- x HPV lesions concurrent with cervical/vulvar**
 - ⇒ *condyloma accuminatum, vaginal intraepithelial neoplasia (VaIN I-III) → squamous carcinoma*

- x embryonal rhabdomyosarcoma (sarcoma botryoides)**
 - ⇒ *gross – soft polypoid tumor protruding into vaginal lumen*
 - ⇒ *girls <5 years*

Embryonal rhabdomyosarcoma



Rhabdomyoblasts
(arrows)



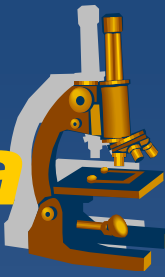Cervix (endocervix, exocervix)

Cervicitis



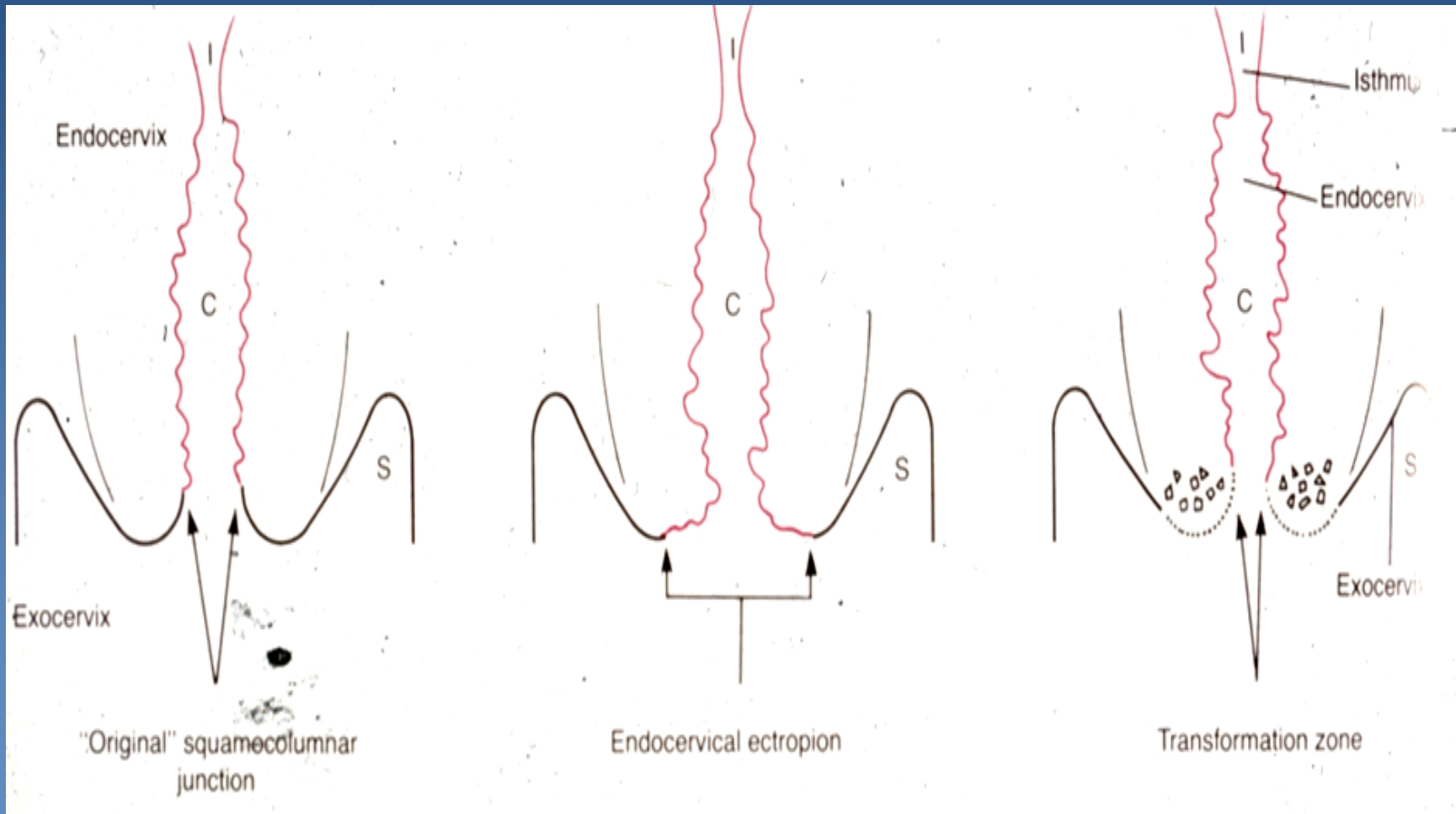
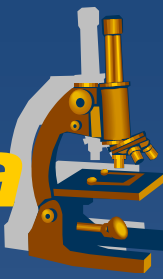
- x commonly with colpitis, non-specific
 - ⇒ *similar microbial causes*
- x chronic cervicitis may lead to mucosal hyperplasia → endocervical polyp

Cervical squamous metaplasia

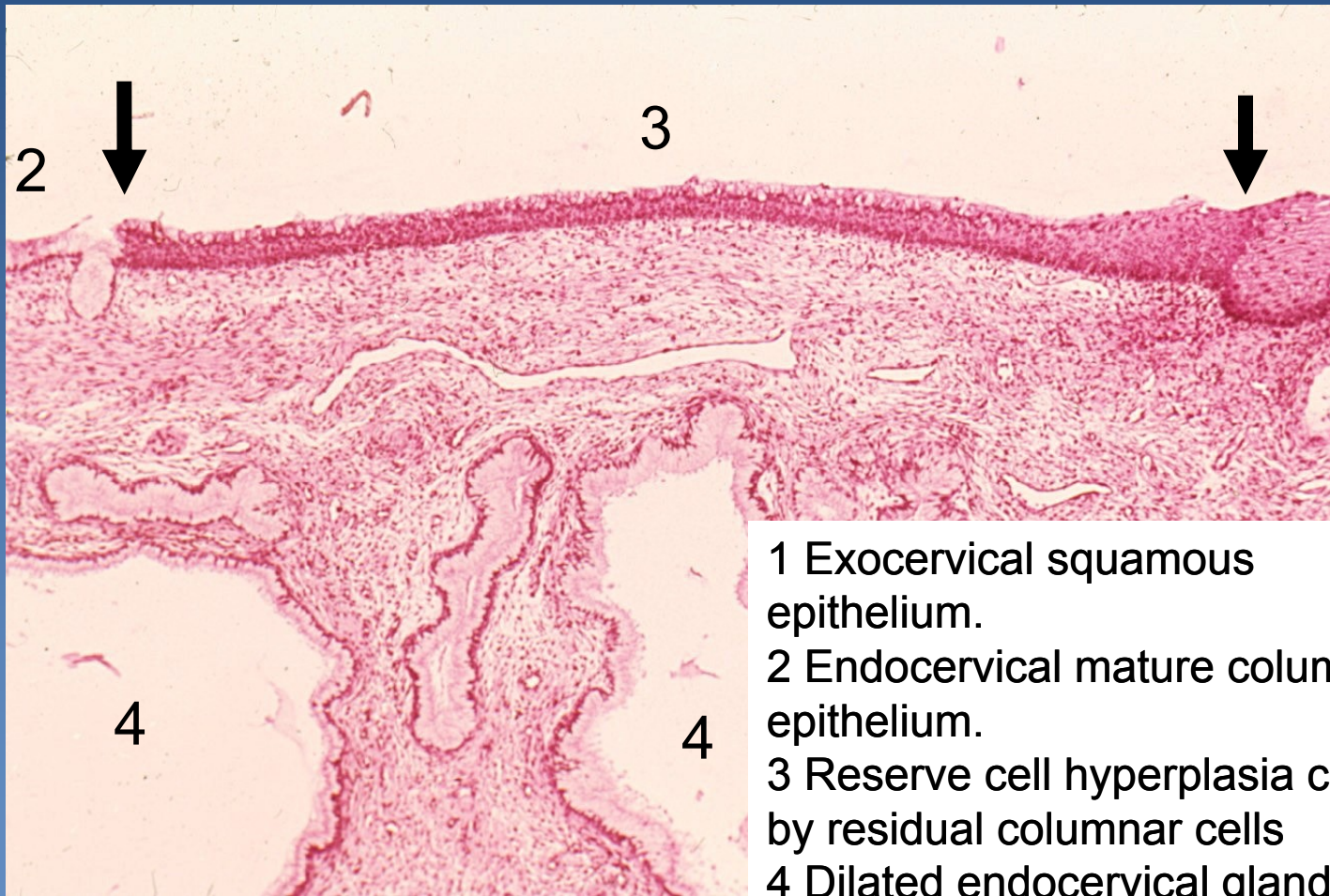
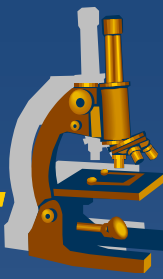


- ✘ transformation zone (squamo-columnar junction)
 - ⇒ *eversion of columnar epithelium into vagina (ectopy, ectropium)*
 - ⇒ *reserve cell hyperplasia → immature squamous metaplasia → mature metaplasia*
- ✘ closure of endocervical glands by overgrowth of squamous epithelium → *ovulosis (cystic dilatation of the glands)*

Cervical squamous metaplasia



Squamous metaplasia, ovulosis.



- 1 Exocervical squamous epithelium.
- 2 Endocervical mature columnar epithelium.
- 3 Reserve cell hyperplasia covered by residual columnar cells
- 4 Dilated endocervical glands

Cervical preneoplastic changes + intraepithelial lesion



- ✘ LR (low-risk) HPV (6,11) →→ *koilocytic atypia* of squamous cells
 - ⇒ *replication + cytopathic viral effect, productive infection*
 - ⇒ *nuclear atypia, cytoplasmic perinuclear halo*
- ✘ Cervical dysplasia – intraepithelial neoplasia associated with **HR (high-risk) HPV**:
 - ⇒ **HR HPV**:
 - 16, 18, 31, 33, 35
 - ⇒ *deregulation of the cell cycle, ↑ proliferation, ↓ or arrested maturation*

Cervical preneoplastic changes



x risk factors

⇒ HPV

- early sexual activity (<16 years of age)
- number of sexual partners

⇒ other STD (HSV, chlamydia)

⇒ cigarette smoking

⇒ early age of first pregnancy

⇒ combined oral contraceptives

⇒ immunosuppression

Cervical intraepithelial neoplasia



× Older classification

⇒ *CIN I (mild dysplasia):*

- koilocytic atypia + changes in the lower third of epithelium:
 - anisokaryosis
 - nuclear enlargement, hyperchromasia
 - loss of cell polarity
 - nuclear superposition

⇒ *CIN II (moderate dysplasia):*

- changes in the lower 2/3 of epithelial thickness, progressive atypia, expansion of the immature basal cells

⇒ *CIN III (severe dysplasia):*

- changes in the whole epithelium, diffuse atypia, almost complete loss of maturation

Cervical intraepithelial lesion



✘ 2 categories, according to the risk of progression and clinical management:

⇒ **LSIL** (*low-grade squamous intraepithelial lesion*)

= *CIN I, exophytic or flat condylomatous lesion*

- mostly self-limited (viral clearance), productive infection, lower rate of progression

⇒ **HSIL** (*high-grade squamous intraepithelial lesion*)

= *CIN II/III + ca in situ*

- majority persists or progresses to carcinoma

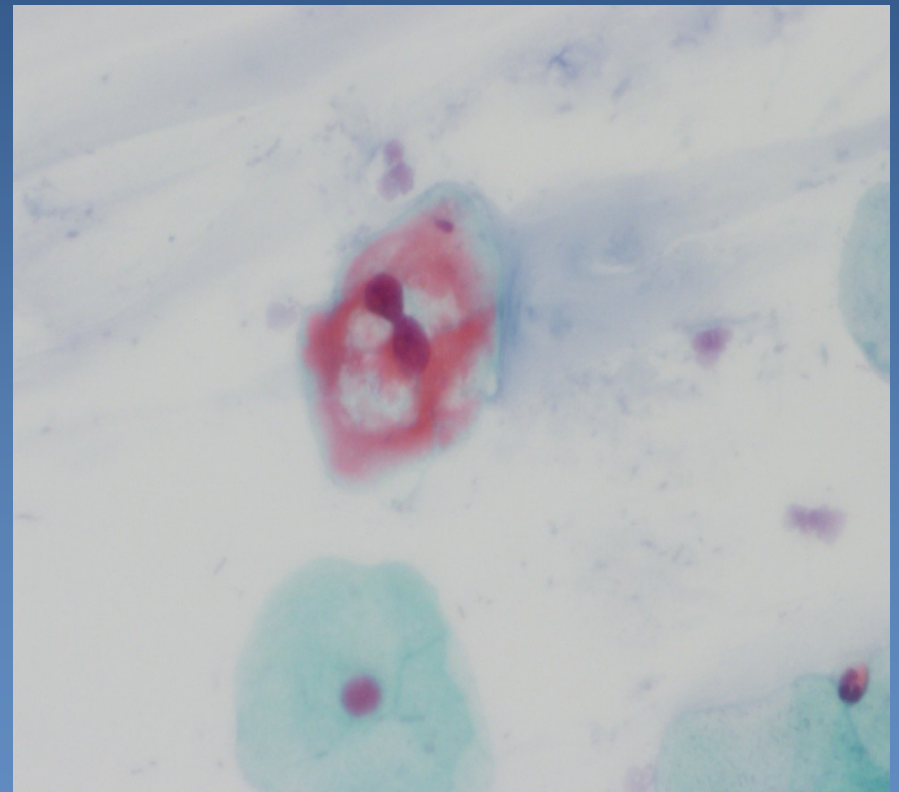
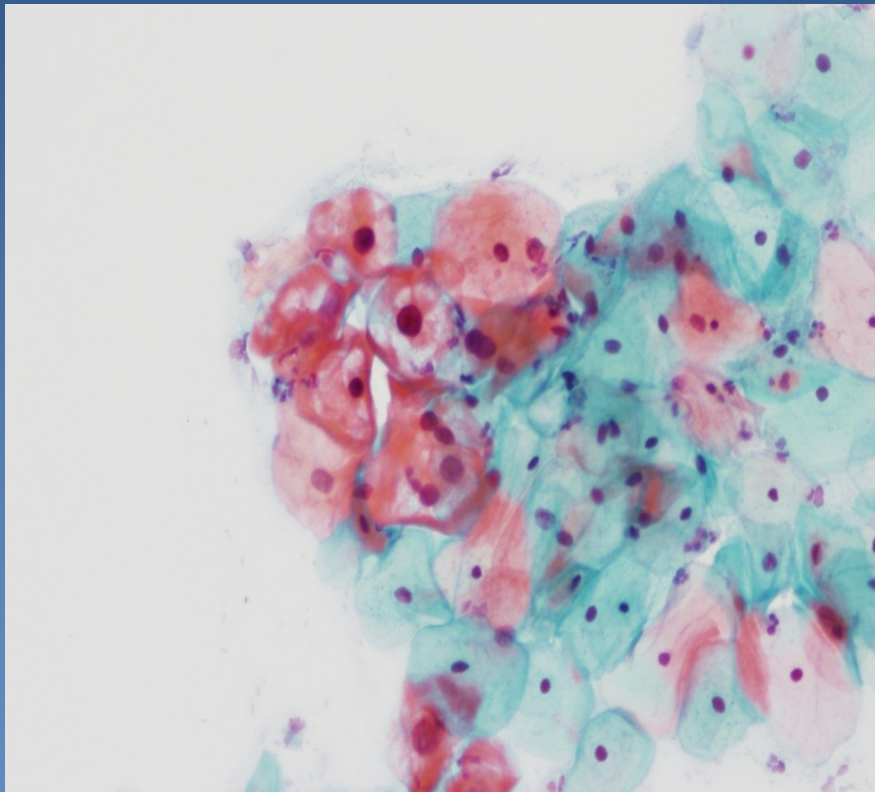
Cervical cytology: LSIL



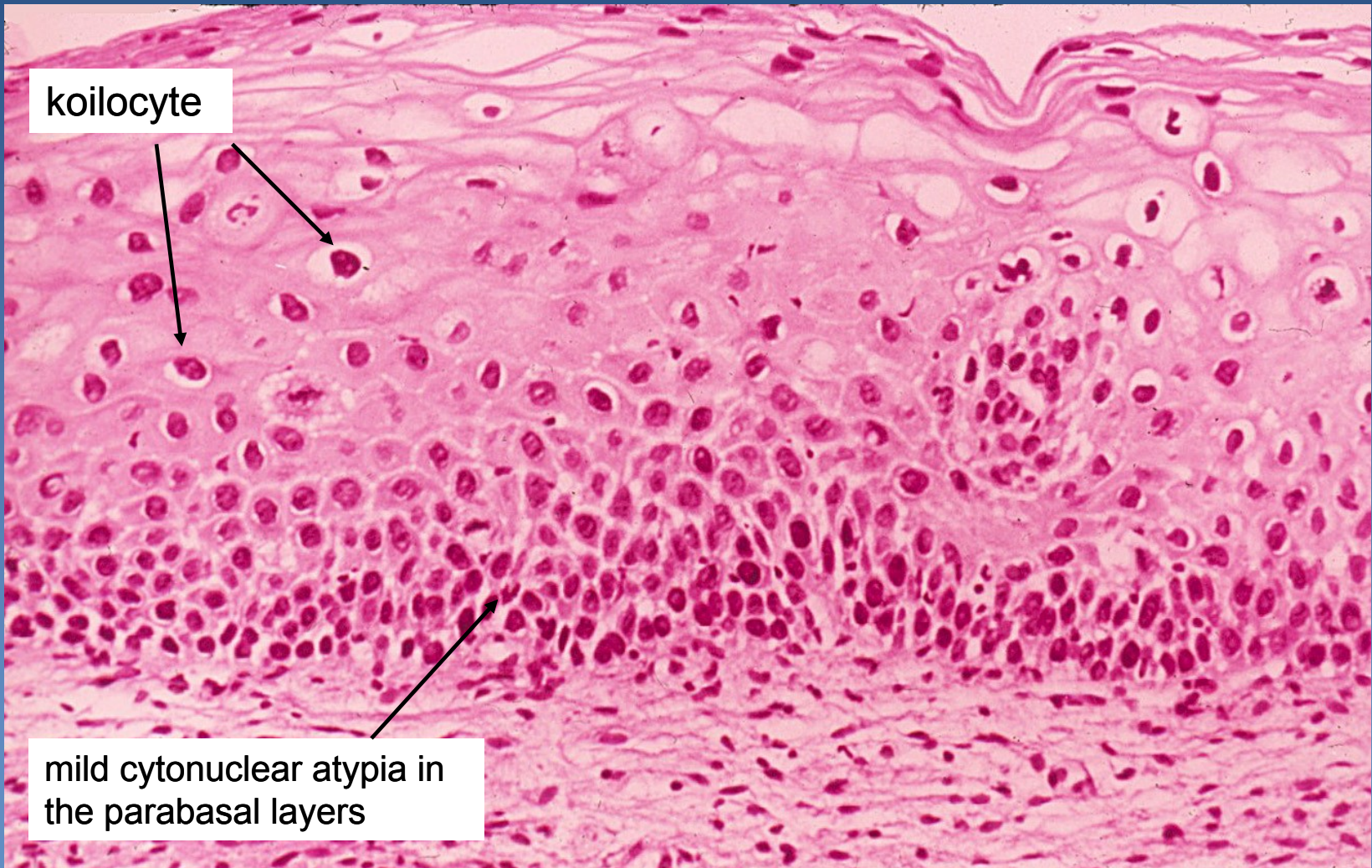
screening of cervical carcinoma

cytology (Bethesda System) + colposcopy

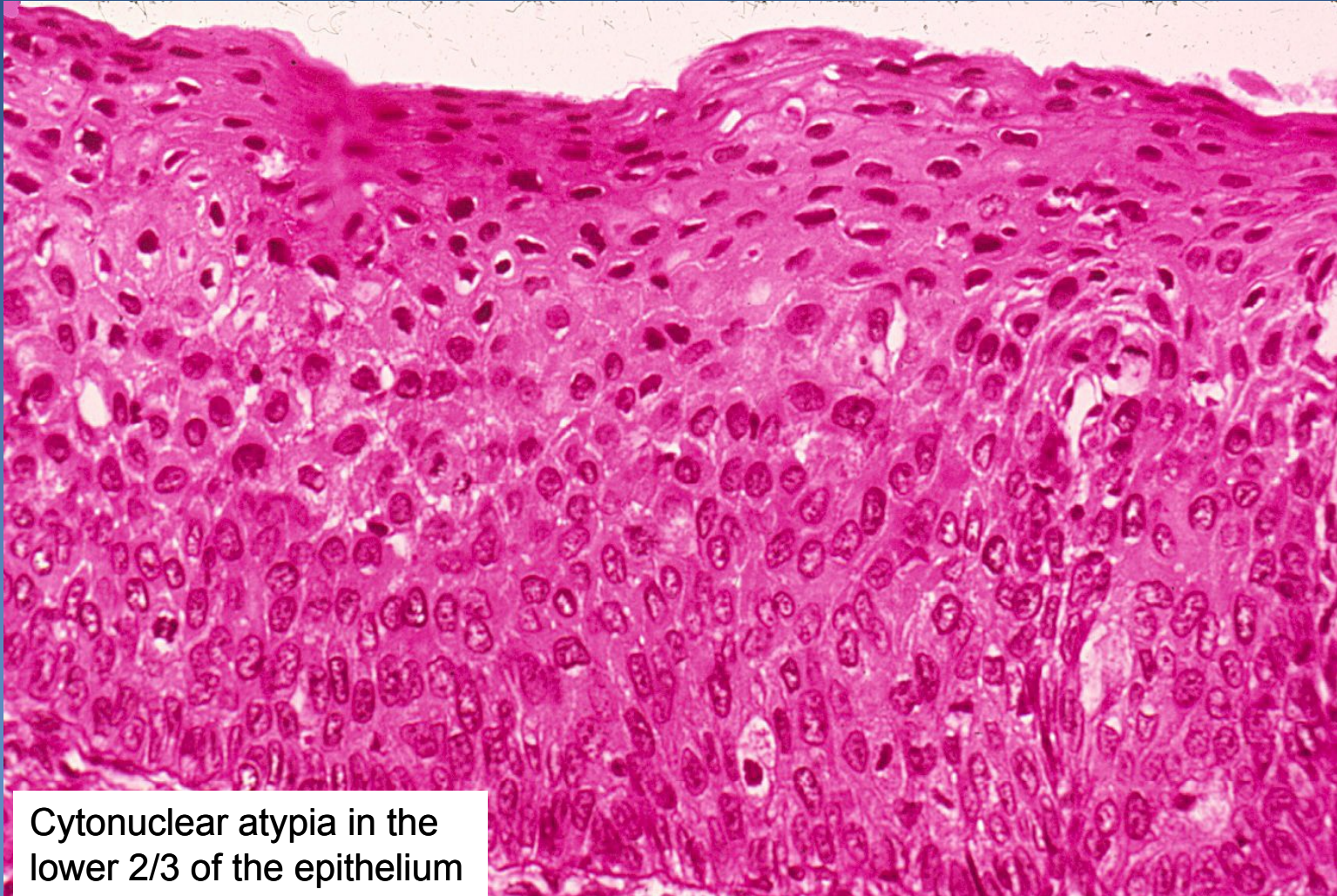
koilocytes with dyskaryotic nuclei



Cervical intraepithelial lesion LSIL (CIN I)

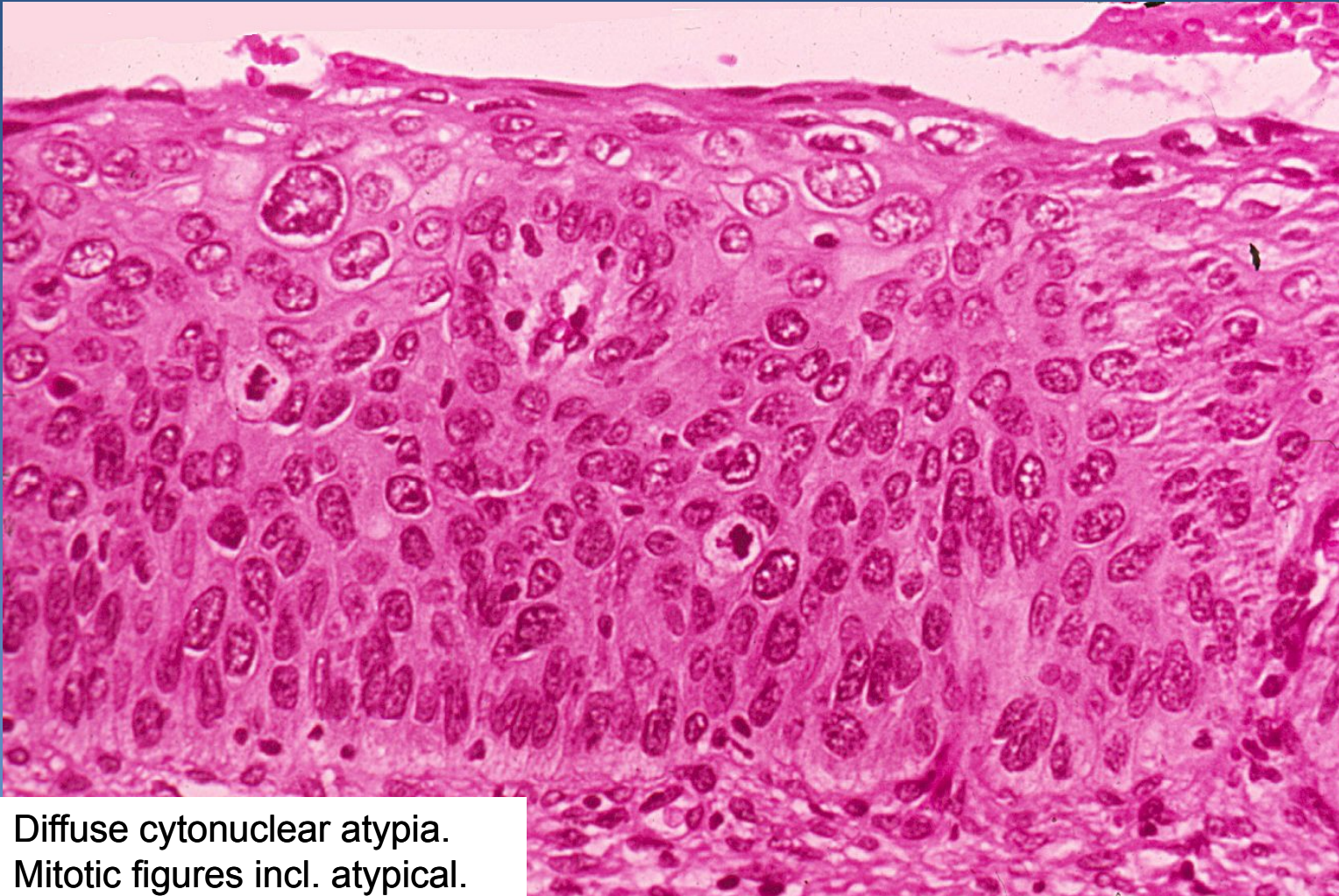
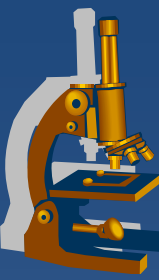


Cervical intraepithelial lesion HSIL (CIN II)



Cytonuclear atypia in the lower 2/3 of the epithelium

Cervical intraepithelial lesion HSIL (CIN III)

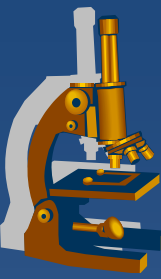


Diffuse cytonuclear atypia.
Mitotic figures incl. atypical.

Invasive cervical squamous cell carcinoma

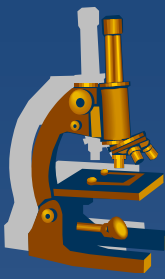


- x almost always by HSIL progression
- x mostly starts in the transformation zone
- x growth:
 - ⇒ *local progression*
 - size + depth of the invasive component
 - direct invasion into adjacent organs, fistulae
 - regional LN metastases
 - ⇒ *distant metastases via blood (lung, liver, bone marrow)*
- x ↑ incidence, but mostly lower stages (if screened), ↓ mortality



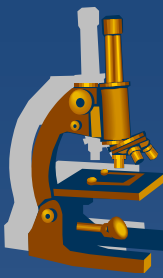
Other cervical carcinomas

- x Adenocarcinoma**
 - ⇒ *cervical glandular intraepithelial lesion*
 - ⇒ *adenocarcinoma in situ*
 - ⇒ *! diff. dg. x endometrial ca*
- x Adenosquamous carcinoma**
- x Neuroendocrine cervical carcinoma**



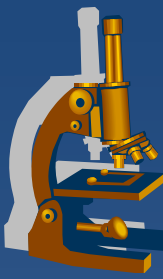
Uterine corpus

Endometritis



- ✗ rather uncommon
- ✗ acute inflammation mostly in association with
 - ⇒ *pregnancy (delivery, abortion)*
 - ⇒ *instrumentation (curetage,...)*
 - ⇒ *long-term IUD in situ (actinomycosis)*
- ✗ chronic inflammation (+ acute exacerbation)
 - ⇒ *chlamydia, chronic gonorrhoea*
 - ⇒ *tb (miliary, or per continuitatem from the fallopian tubes)*

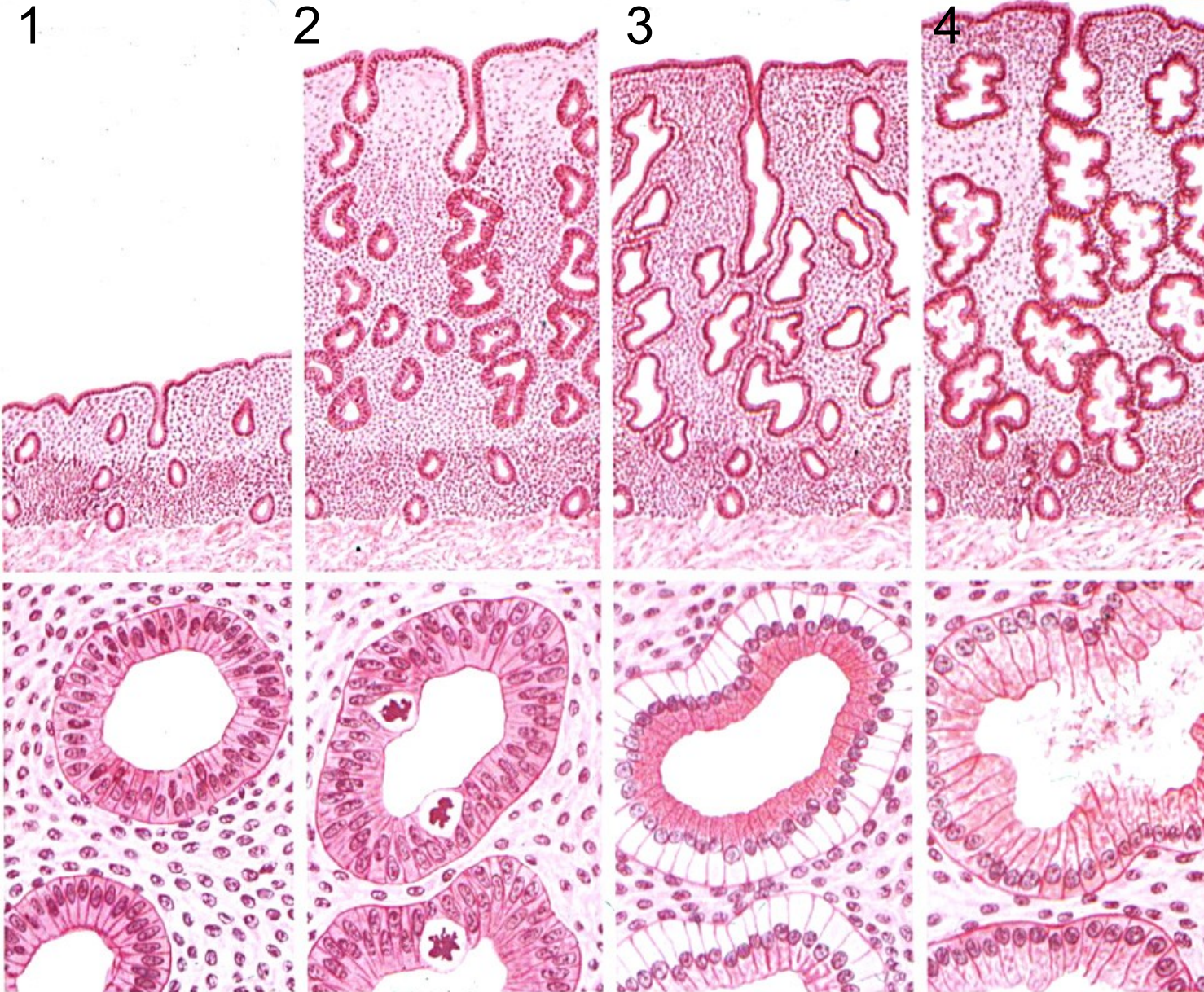
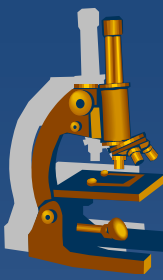
Endometriosis



- ✘ foci of functional endometrium (glands + stroma) in an ectopic localisation
 - ⇒ *ovaria, cavum Douglasi, fallopian tubes, peritoneum, bladder, umbilical skin, ... lung, bones ...)*
 - ⇒ *cyclical changes during MC*
 - haemorrhagic (chocolate) cysts, hemosiderin pigmentation
 - ⇒ *pain, pelvic inflammatory disease + adhesions, infertility*
 - ⇒ *possible source of endometrioid adenocarcinoma*

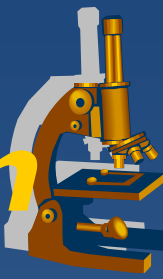
- ⇒ *adenomyosis:*
 - endometrial diverticula (outpouching of basalis into myometrium, mostly no functional hormonal changes)

Endometrium, menstrual cycle



- 1 Early proliferation
- 2 Late proliferation
- 3 Early secretion
- 4 Late secretion

Dysfunctional endometrium



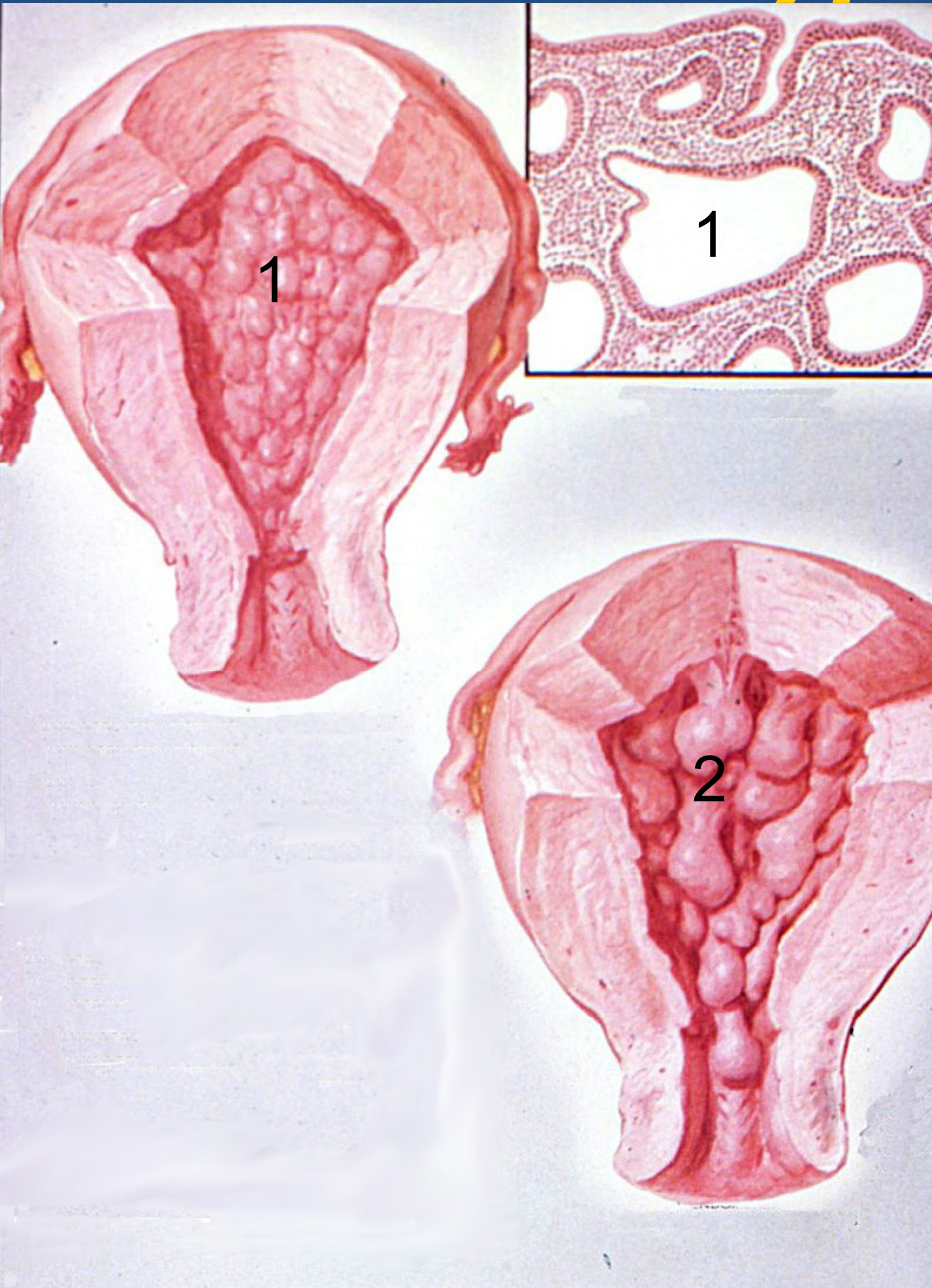
- × Usual clinical presentation – **abnormal bleeding**
- × **Hormonal dysbalance, variable origin**
- × **Non-secretory** ← abnormal estrogenic stimulation
 - ⇒ ↓ **E** → hypoproliferative → atrophic endometrium
 - ⇒ ↑ **E** → hyperproliferative → hyperplastic endometrium (anovulatory cycle)
 - ⇒ *unopposed* ↑ **E by missing progestogenes** → **hyperplastic endometrium**
- × **Secretory** ← abnormal progestogenes
 - ⇒ ↓ **P** → hyposecretory endometrium (luteal phase insufficiency)
 - ⇒ ↑ **P** exogenous (contraception) - stroma-glandular dissociation – pseudo-decidualized stroma + atrophic glands
 - ⇒ ↑ **P** → hypersecretory endometrium (similar to gestational); Arias-Stella phenomenon (!GEU)
- × **Irregular, mixed** ← E+P dysbalance
 - ⇒ **irregular shedding** – mixed secretory + menstrual + proliferative

Endometrial hyperplasia



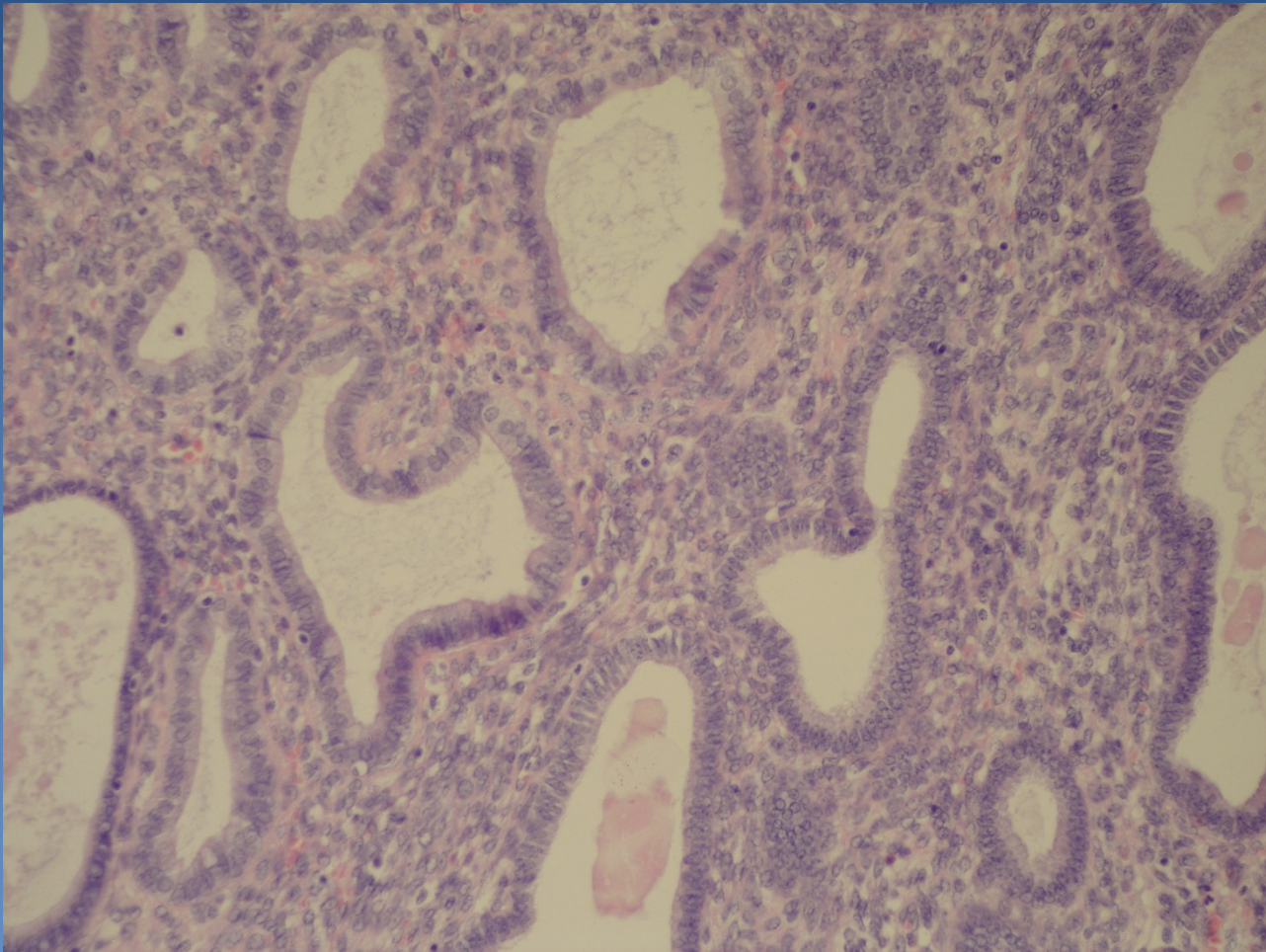
- × **increased glandular proliferation** - ↑ gland-to-stroma ratio
- × **classification according to architecture, cytological atypia**
- × **simple** – dilated irregular glands, epithelial stratification, „swiss cheese“
 - ⇒ **without atypia**, almost no progression to adenocarcinoma,
 - ⇒ **with atypia** → cytologic atypia present, low progression, rare
- × **complex** – irregular branching crowded glands, ↓ stroma (back-to-back)
 - ⇒ **without atypia**
 - ⇒ **with atypia** → round nuclei + nucleoli, commonly monoclonal – neoplastic – **high grade of progression**, commonly (1/4-1/2) concurrent ca present;

Endometrial hyperplasia



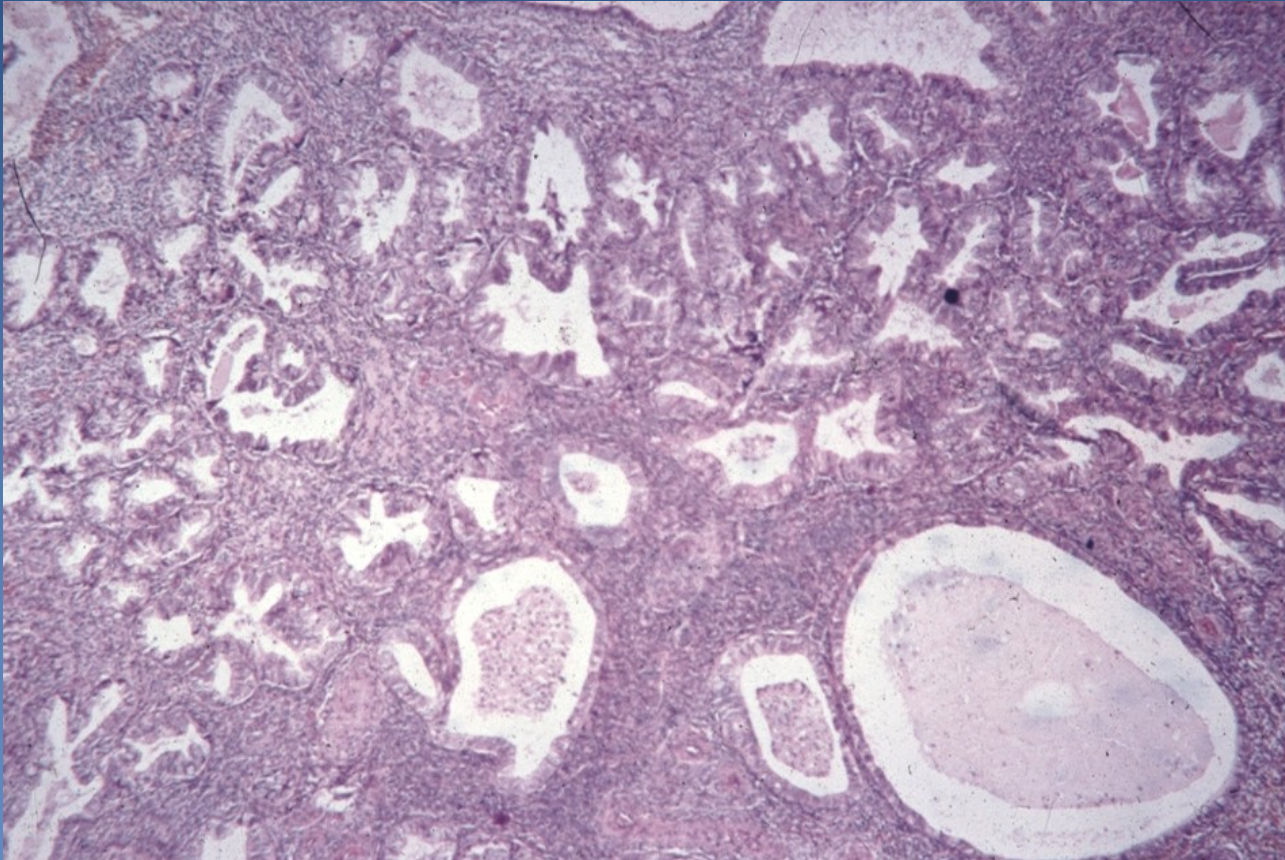
- 1 Endometrial hyperplasia
- 2 Polypous endometrial hyperplasia

Simple hyperplasia

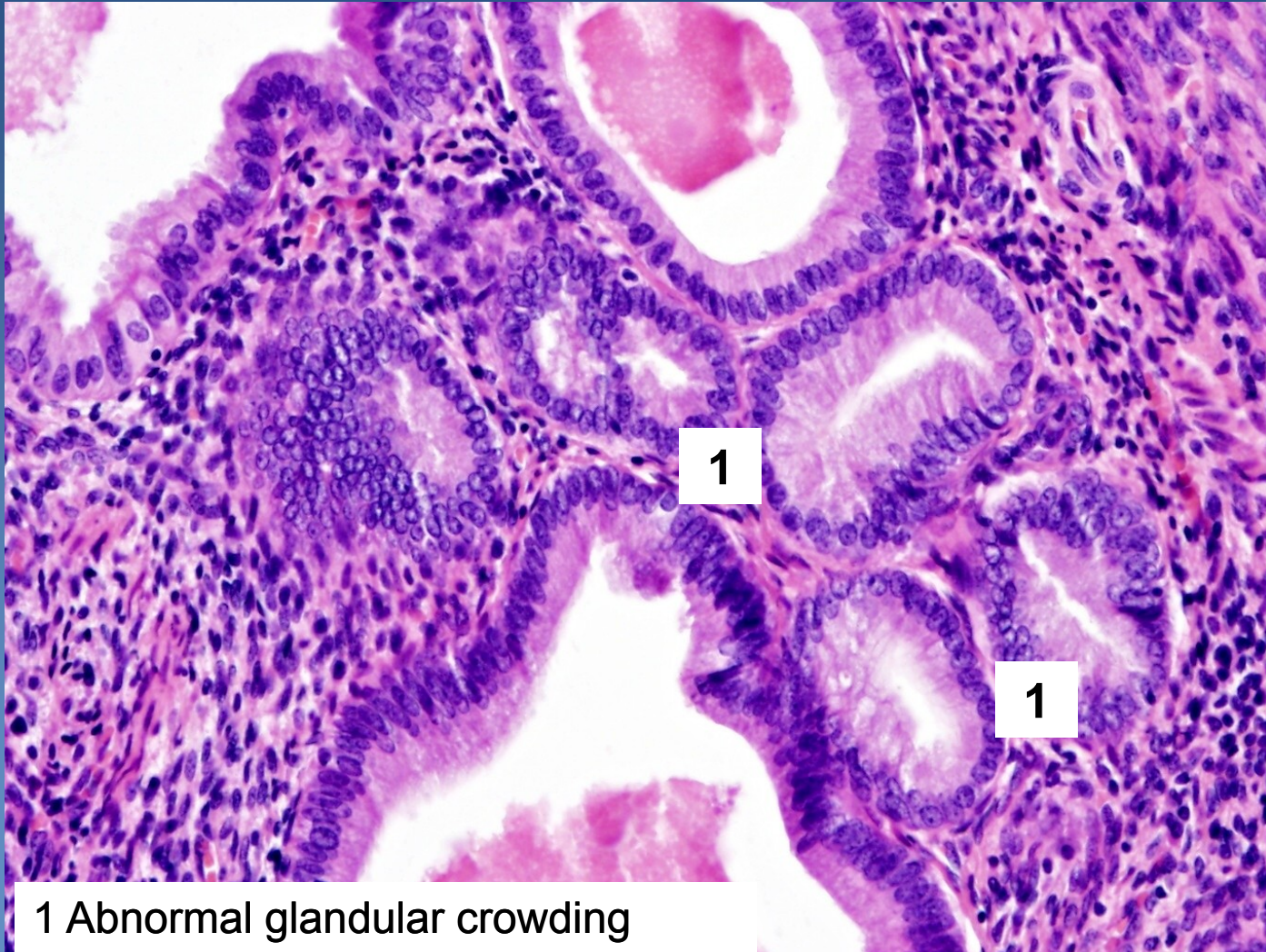


Cystic transformation of endometrial glands
Stromal hyperplasia

Complex hyperplasia

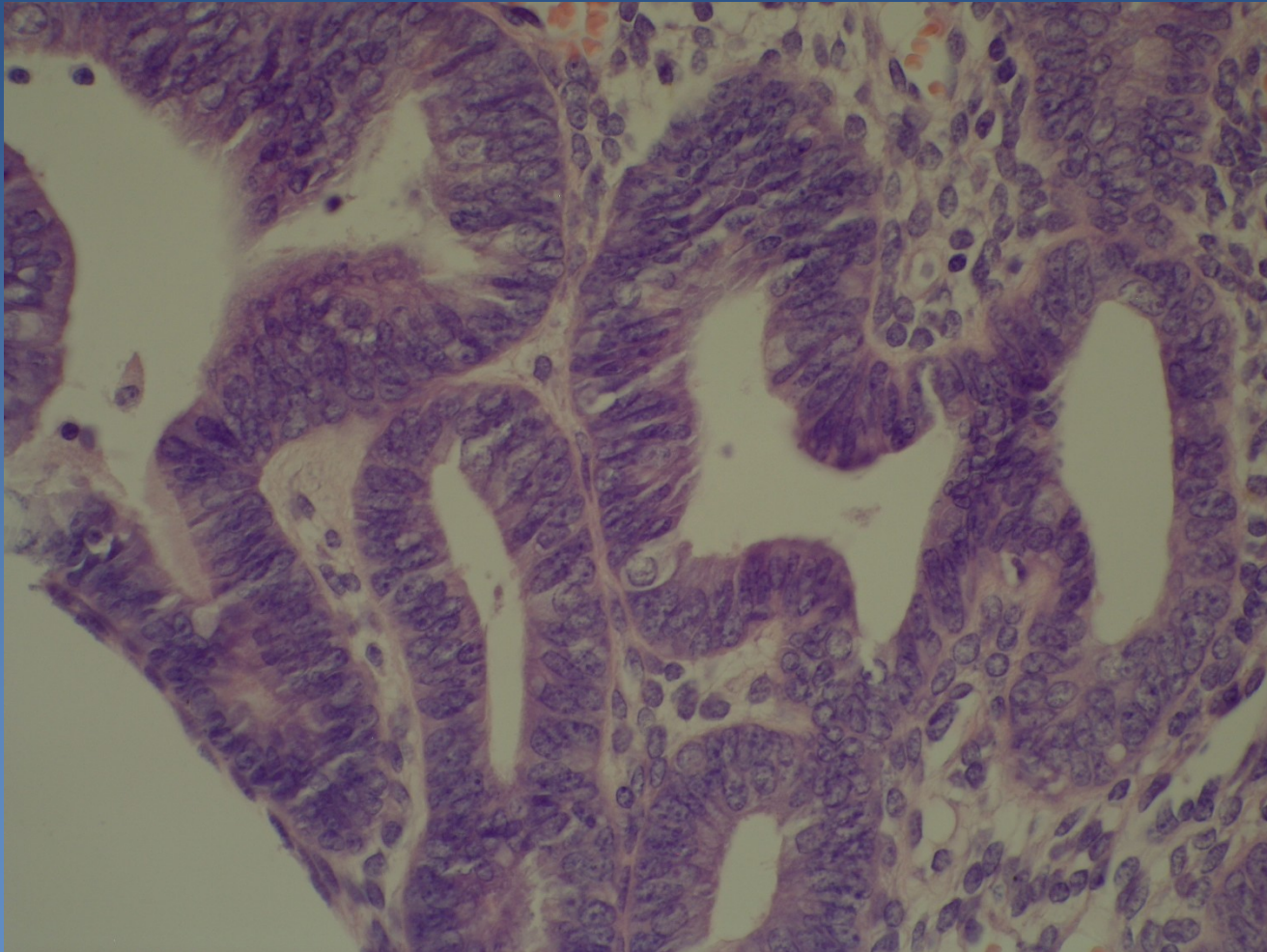


Complex hyperplasia



1 Abnormal glandular crowding

Complex hyperplasia with atypia



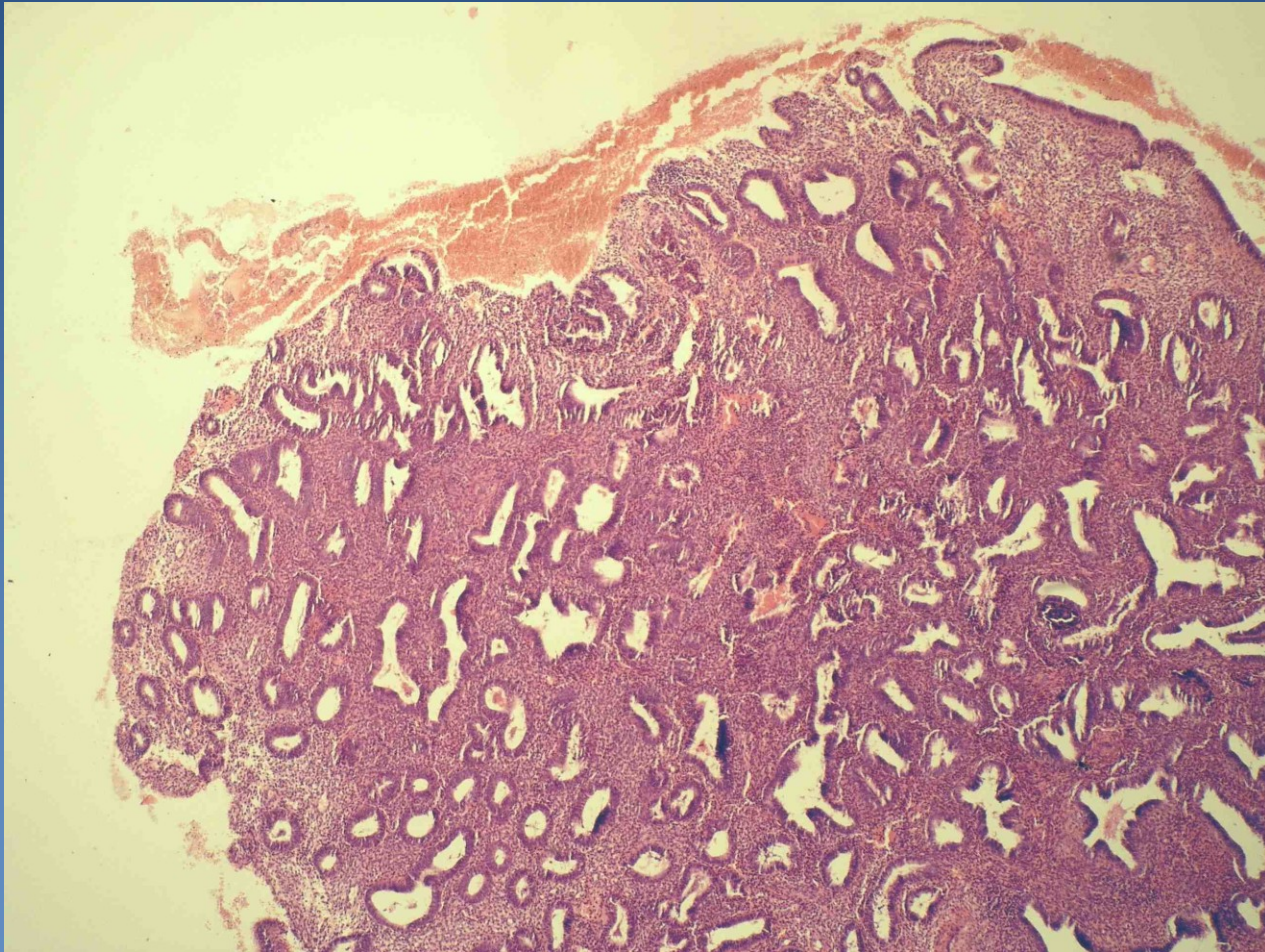
Stratification of epithelial cells, vesicular nuclei, visible nucleoli

Endometrial polyp

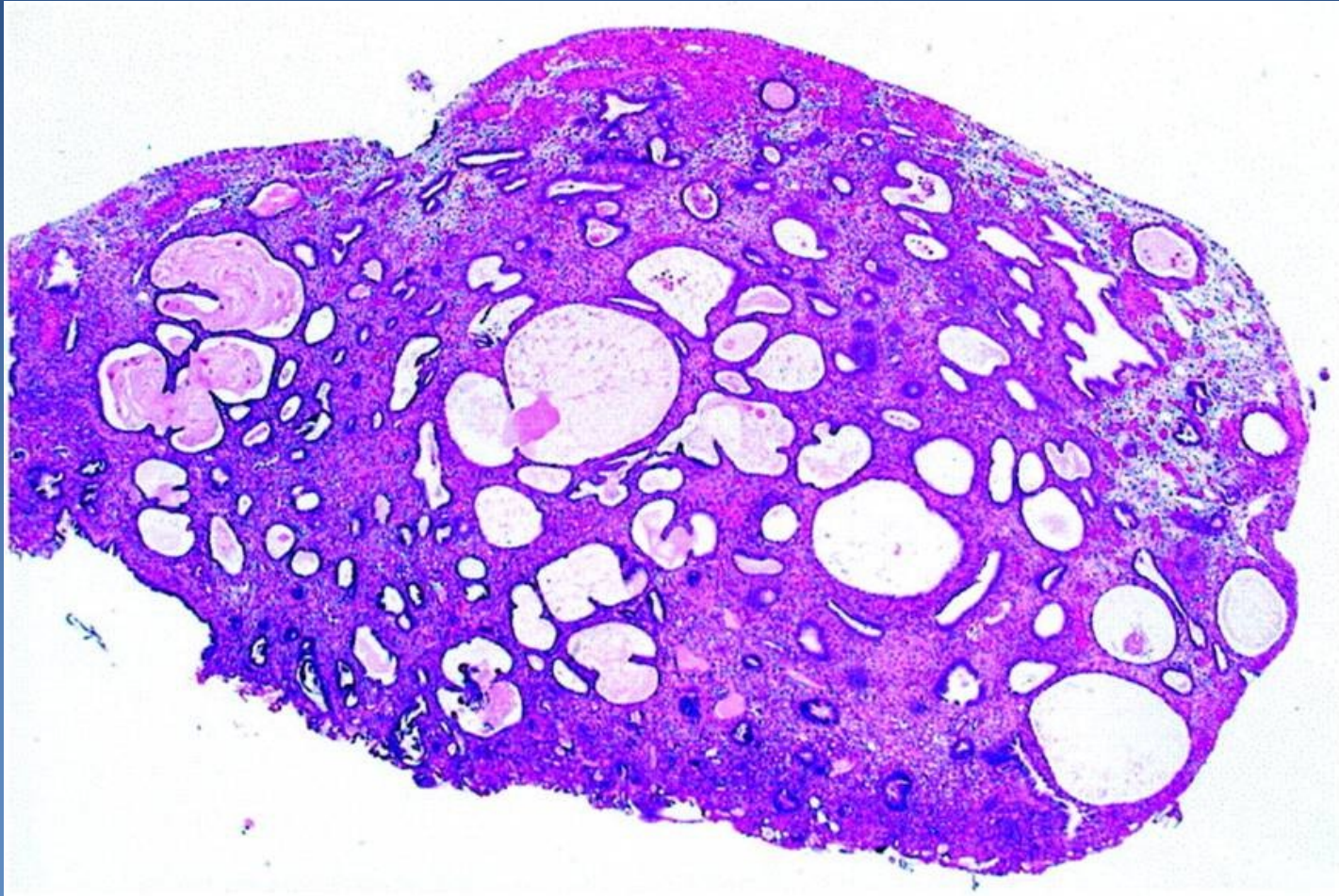
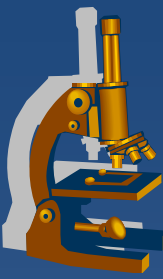


- x sessile/pedunculated, solitary/multiple exophytic endometrial focus
 - ⇒ abnormal bleeding common
 - ⇒ functional/hyperplastic/atrophic endometrium
 - ⇒ stromal fibrosis, thick-walled arteries
 - ⇒ may be in association with endometrial hyperplasia, possible progression to atypical hyperplasia → adenocarcinoma

Endometrial polyp - hyperplastic



Endometrial polyp – cystic atrophic



Endometrial adenocarcinoma



- ✘ Most common malignant tumor of female genital
 - ⇒ 2. cervical ca, 3. ovarian tumors
- ✘ **Abnormal bleeding**
- ✘ **type I: perimenopause**
 - ⇒ *Risk factors:*
 - ⇒ *unopposed estrogenic stimulation – endo-/exogenous*
 - ⇒ *DM, obesity, early menarche - late menopause*
 - ⇒ *precursor **atypical endometrial hyperplasia***
 - ⇒ *better prognosis, lymphatic spread possible*

Endometrial adenocarcinoma



× histologic forms:

⇒ *type I*

- **endometrioid adenocarcinoma**
- mucinous
- tubal (ciliated)
- squamous cell
- adenosquamous

⇒ *bez souvislosti s estrogeny, při mutaci p53 (→ velmi agresivní průběh)*

- **serózní papilární karcinom**
- **světlobuněčný karcinom**

Endometrial adenocarcinoma



x Type II

⇒ ***postmenopausal***

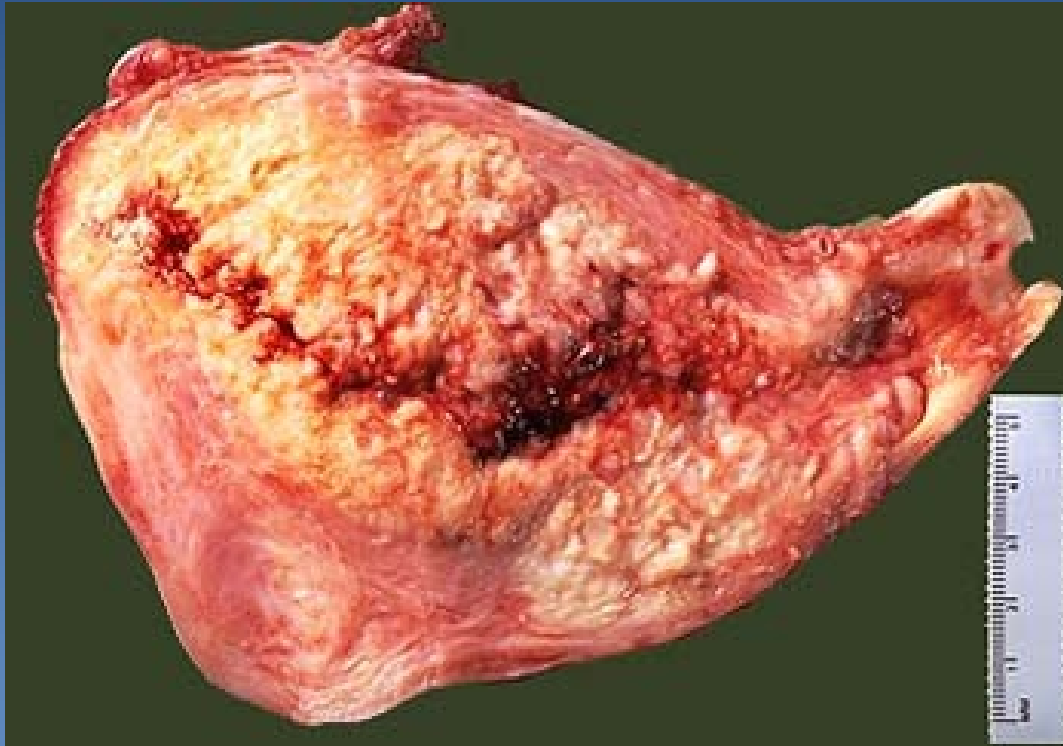⇒ ***without estrogenic stimulation, p53 mutation (→ aggressive; intraperitoneal, lymphatic spread)***

⇒ ***in the setting of atrophic endometrium***

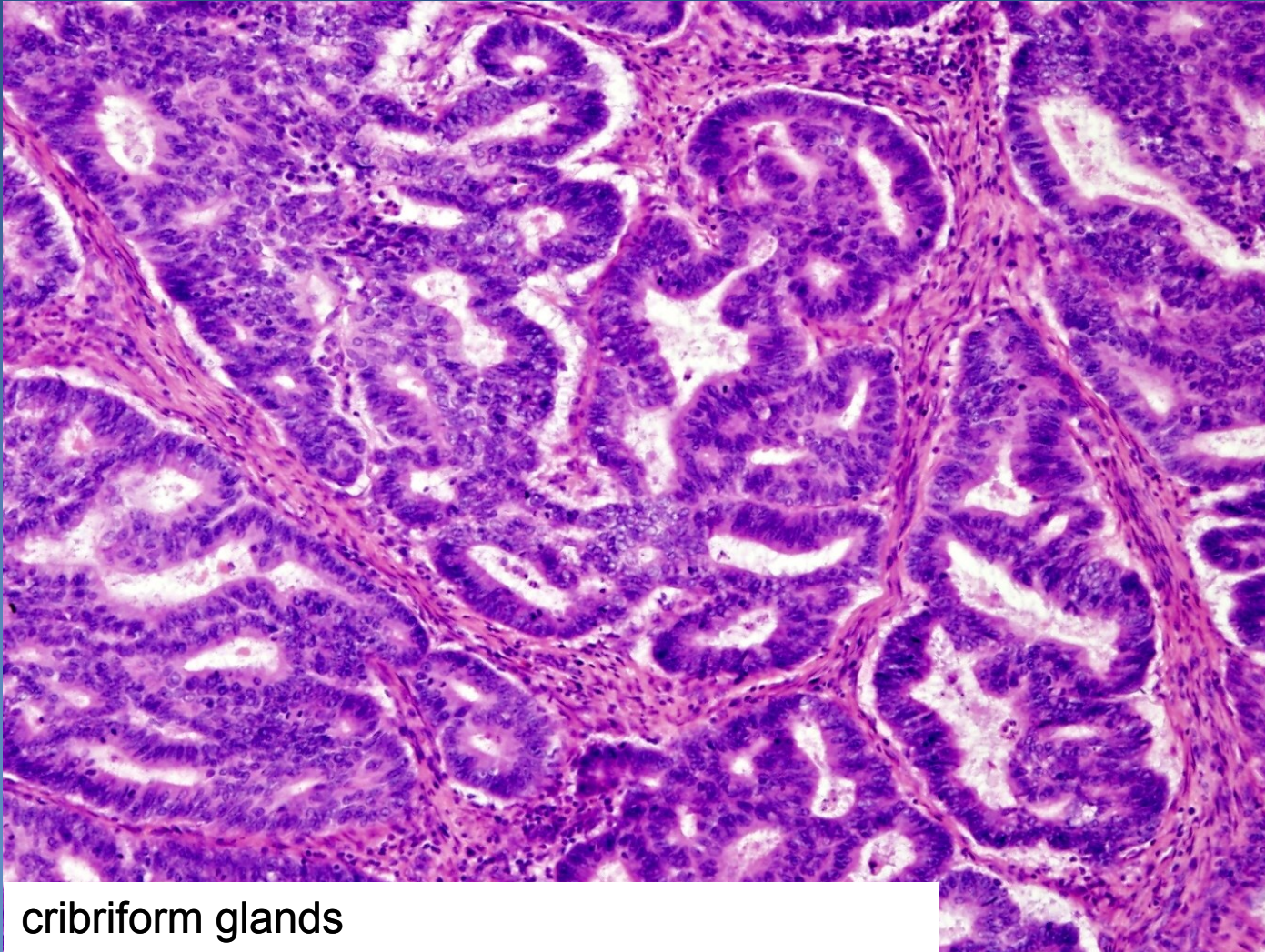
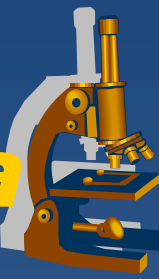⇒ ***poorly differentiated (serous, clear cell)***

⇒ ***undifferentiated (metaplastic carcinoma)***

Endometrial adenocarcinoma

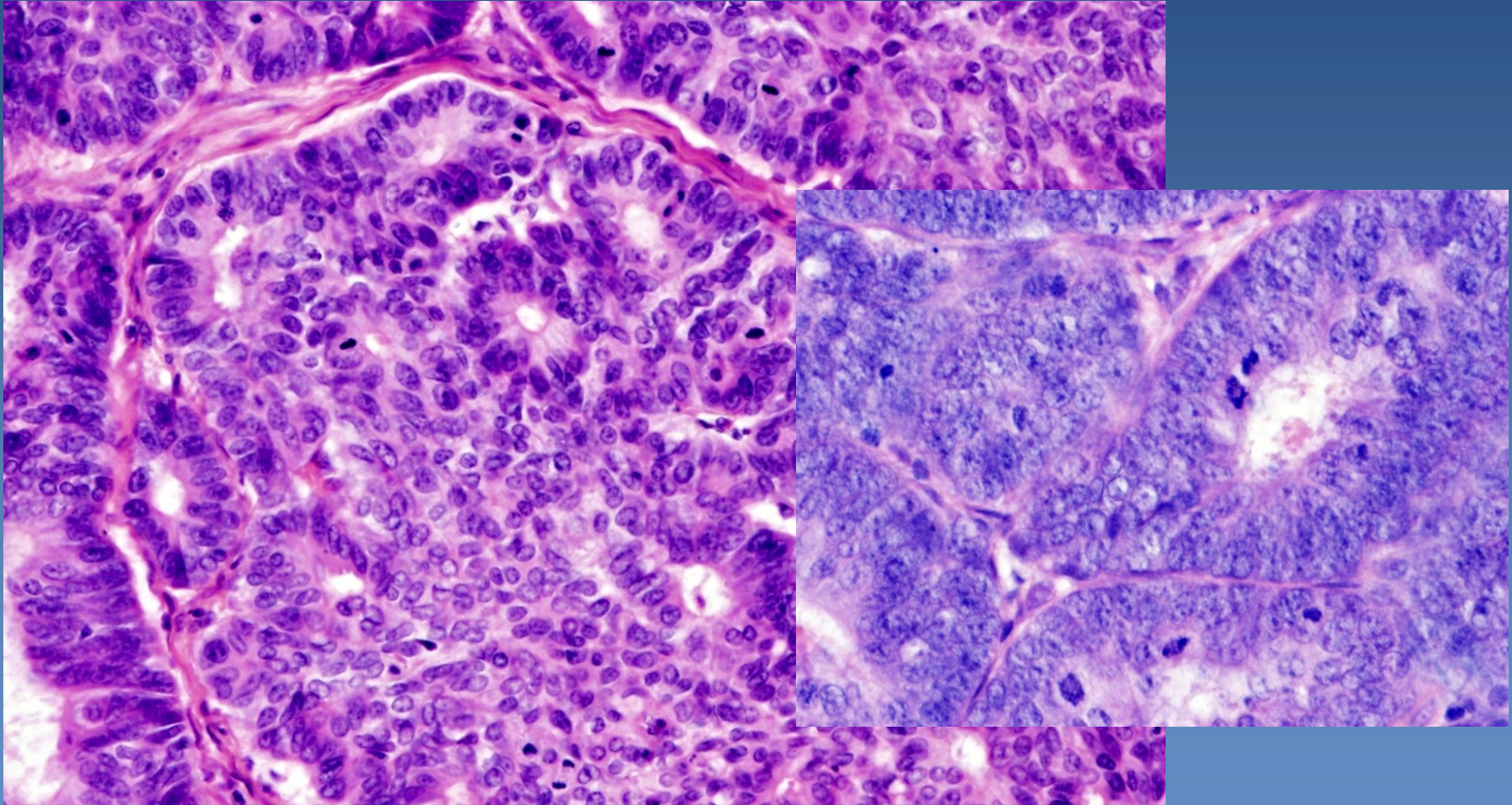


Endometrioid adenocarcinoma



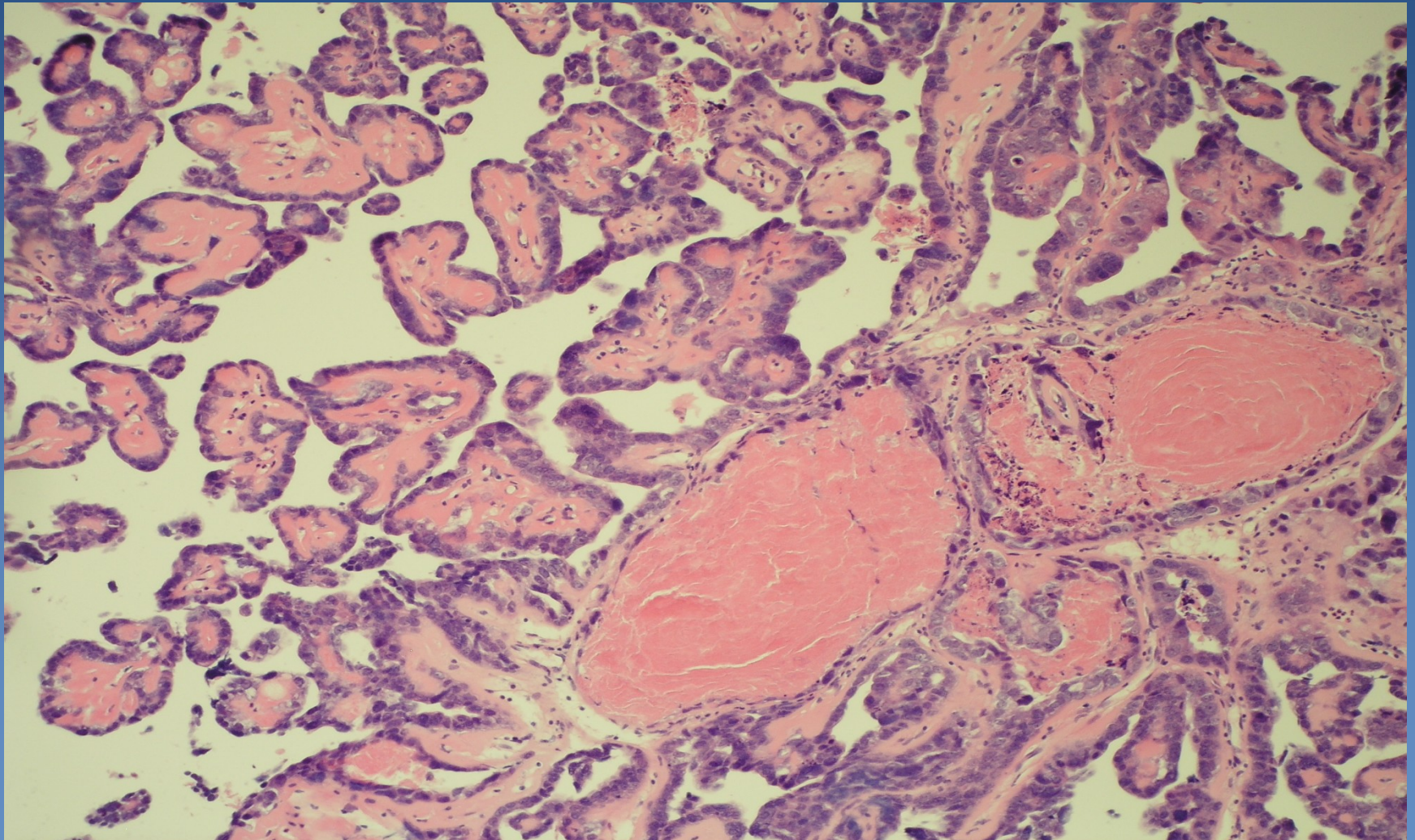
cribriform glands

Endometrioid adenocarcinoma

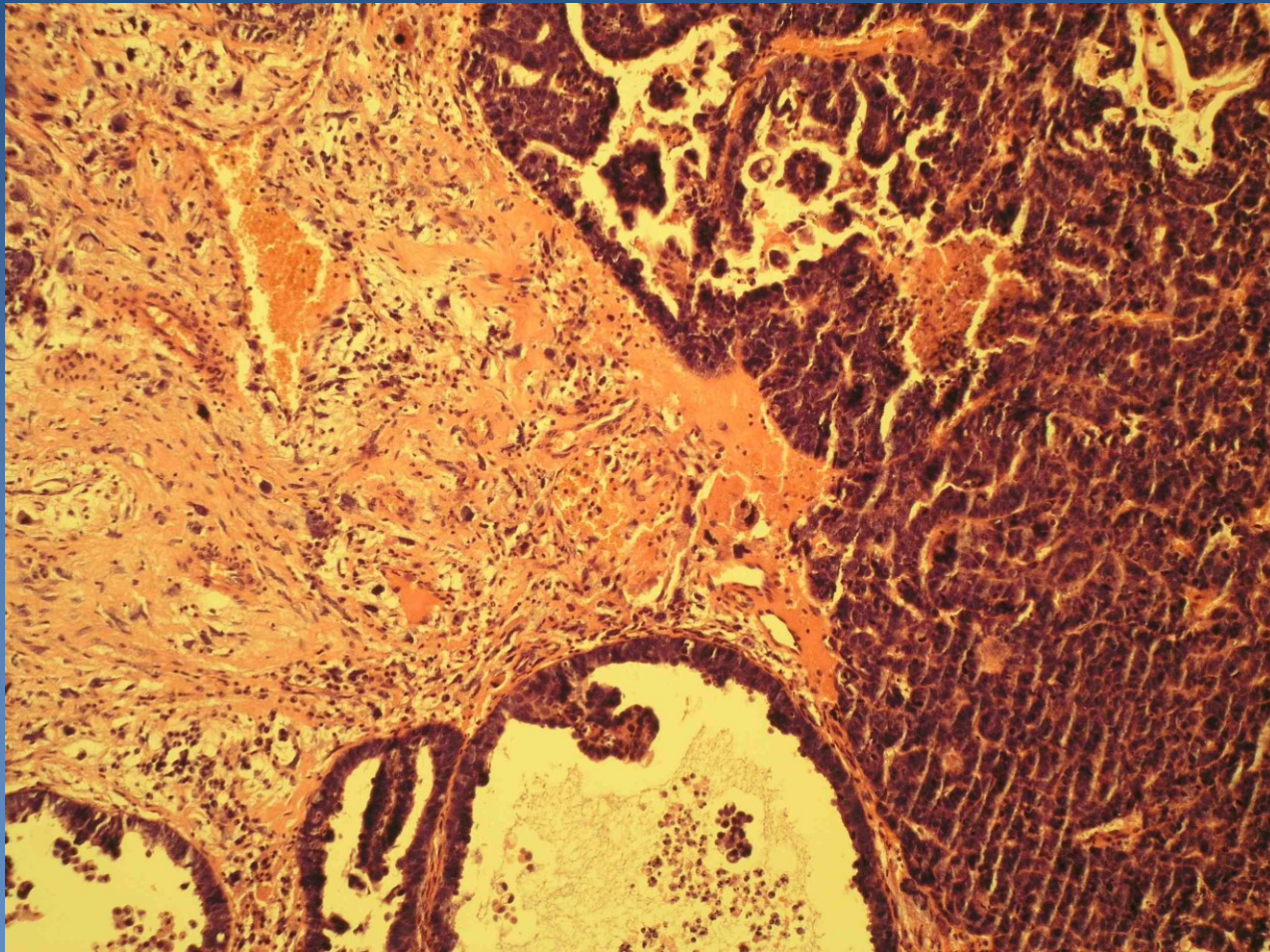


Epithelial stratification, cellular atypias, mitotic activity

Serous adenocarcinoma



Metaplastic carcinoma



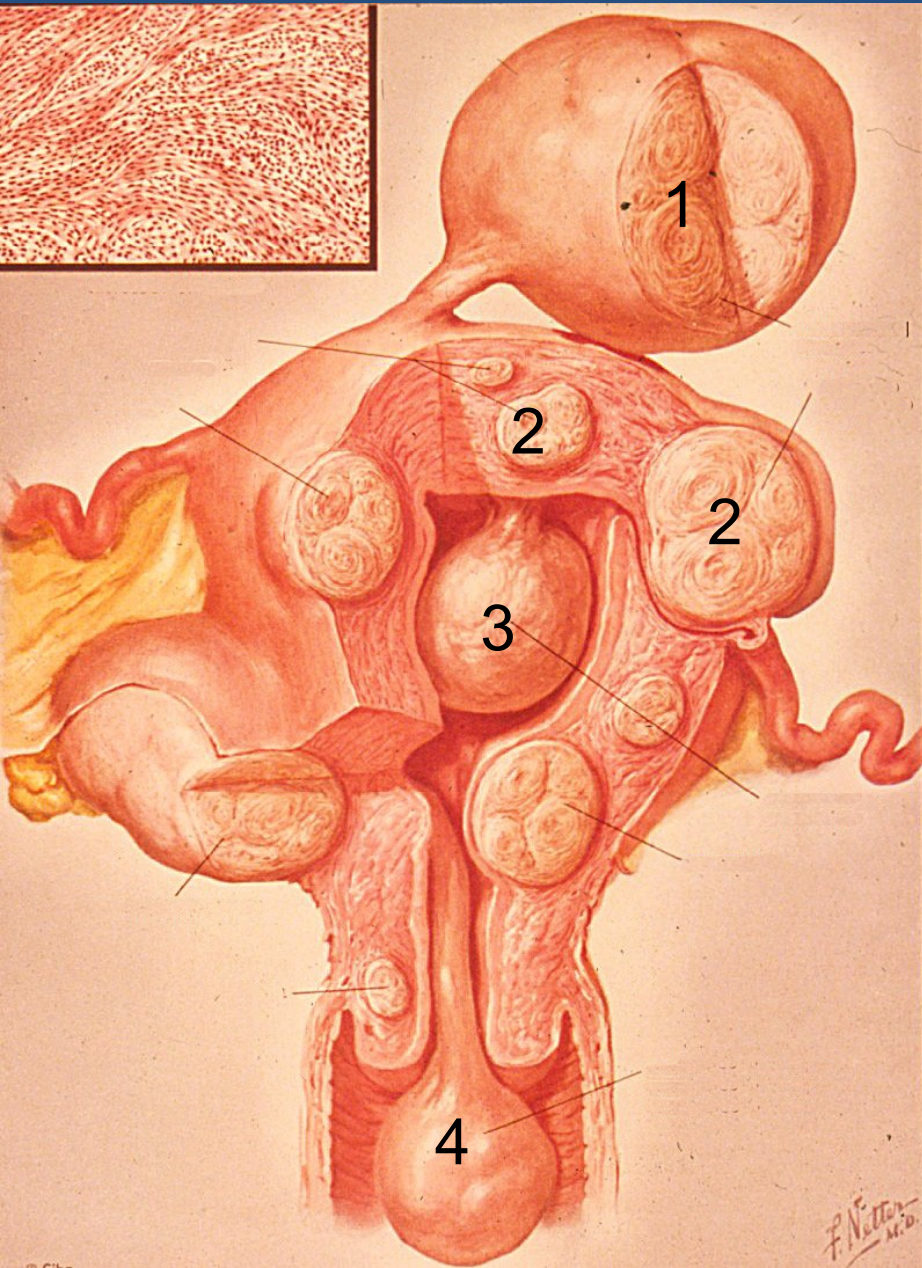
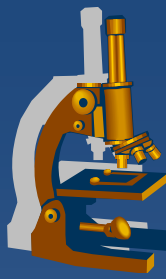
Mesenchymal tumors



x Leiomyoma

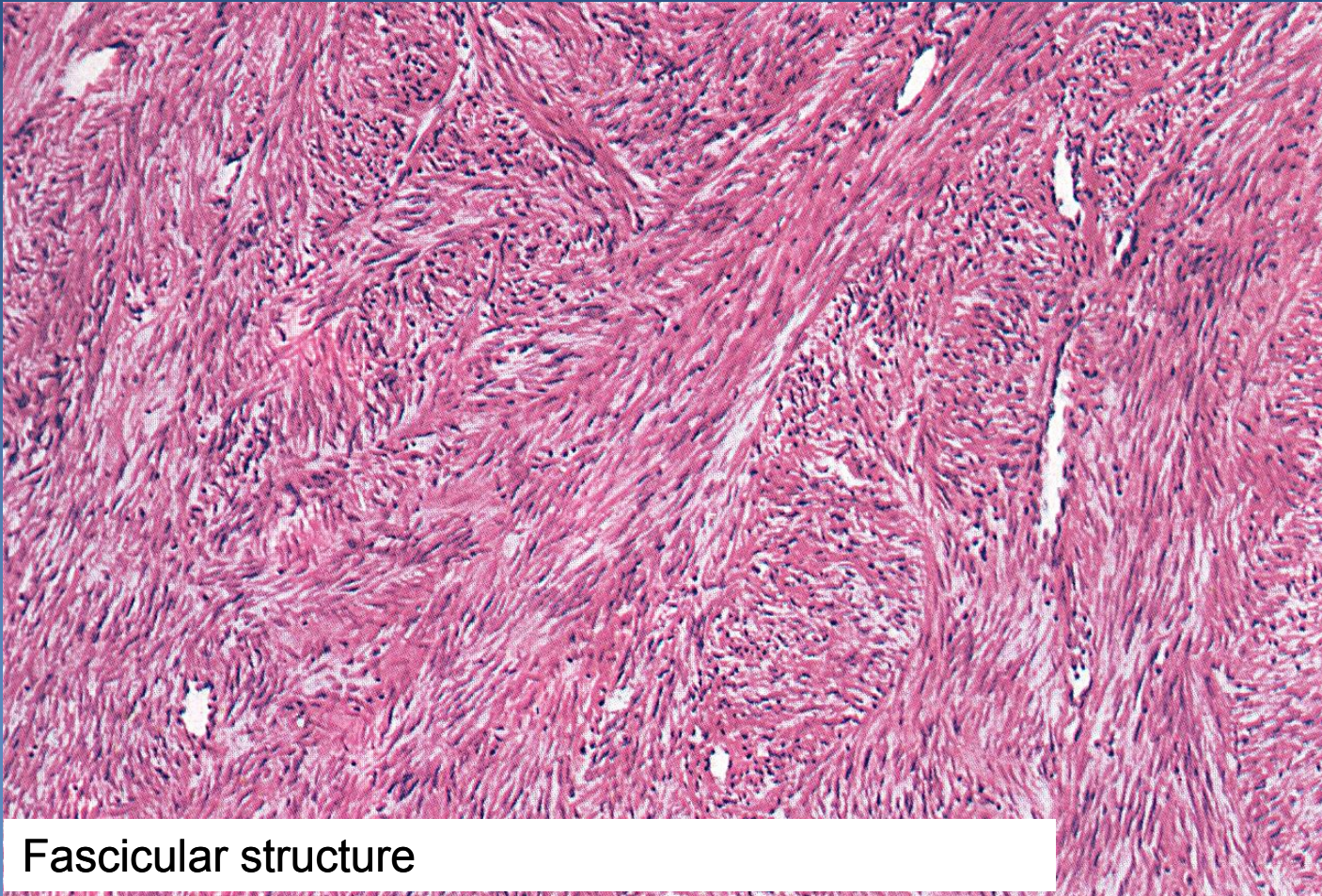
- ⇒ *most common benign female tumor (usual in later reproductive age)*
- ⇒ *size: mm - cca 20 cm*
- ⇒ *symptoms due to localisation/topography (bleeding, infertility, compression of adjacent organs)*
- ⇒ *uterus myomatosus (multiple leiomyomas)*
- ⇒ *common regressive changes (oedema, fibrosis, hyalinisation, calcification)*

Uterine leiomyomas



- 1 Subserous leiomyoma
- 2 Intramural myoma
- 3 Submucosal myoma
- 4 „Nascent“ submucosal myoma

Leiomyoma



Fascicular structure

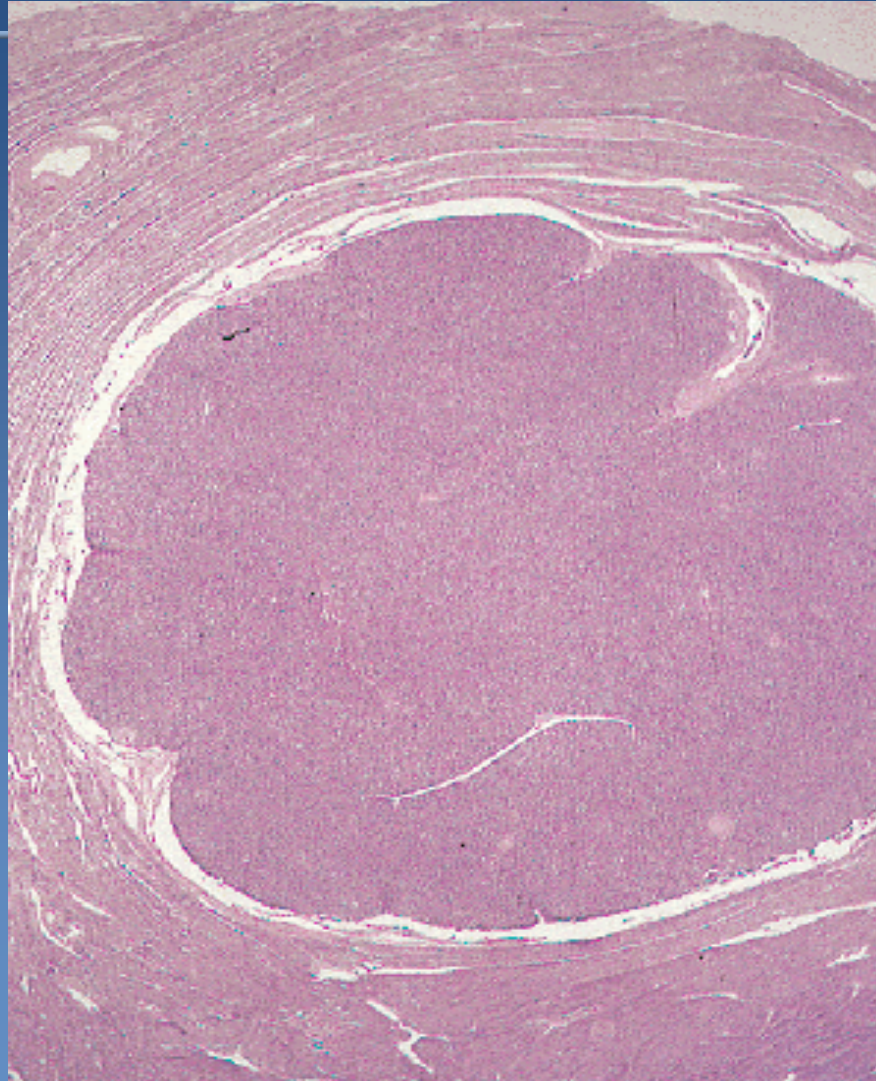
Mesenchymal tumors



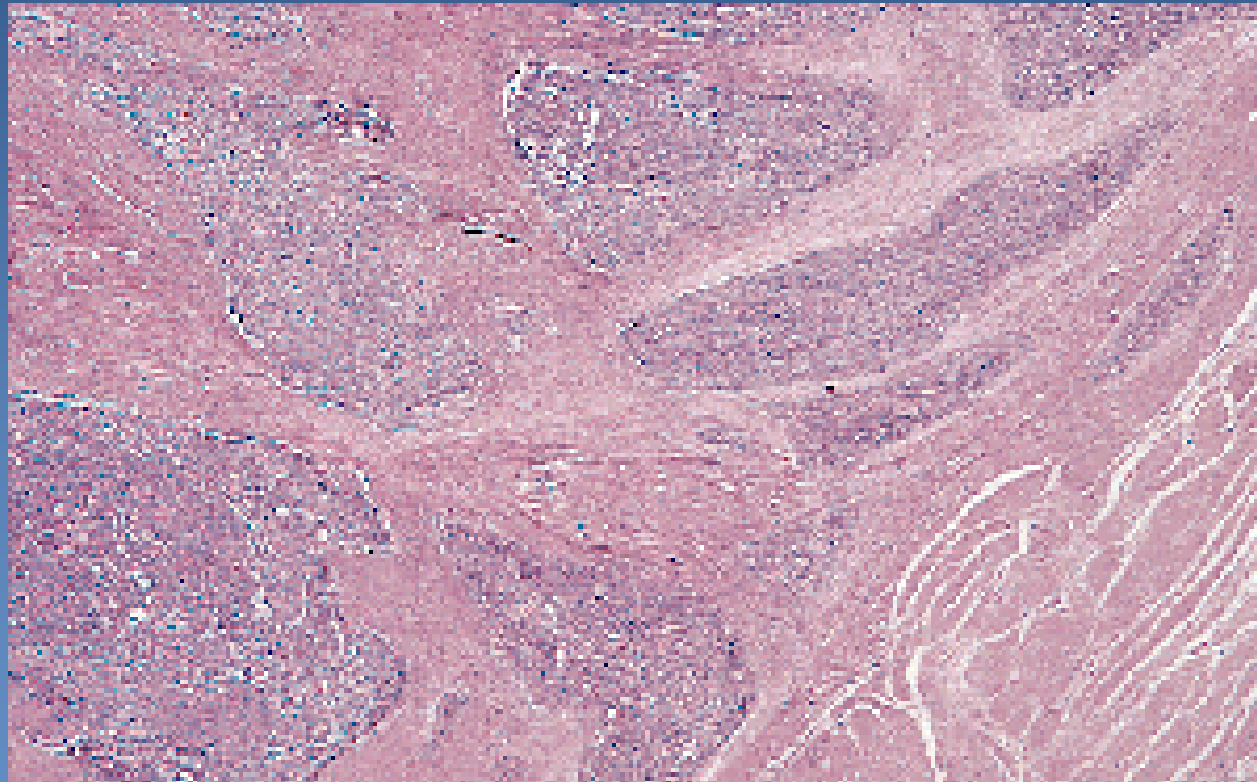
x Stromal tumors

- ⇒ *origin from endometrial stroma*
- ⇒ *Stromal nodule (benign)*
- ⇒ *Stromal sarcoma*
 - **Low-grade**
 - **High-grade**

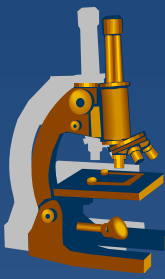
Stromal nodule



LG stromal sarcoma



Pathology of pregnancy



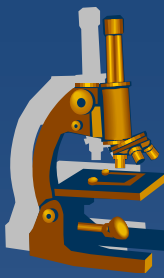
- ✗ ectopic pregnancy
- ✗ spontaneous abortion (placental disorders incl. placentation abnormalities, vascular lesions, inflammation – ascending, hematogenous; umbilical cord pathology)
- ✗ pre-eclampsia – systemic endothelial dysfunction; hypertension + oedema + proteinuria, hypercoagulative state; may → eclampsia (CNS – convulsion, coma)
- ✗ **Gestational trophoblastic disease**

Gestational trophoblastic disease



- x** proliferation of gestational trophoblast with progressive malignant potential or frankly malignant
- x** hydatidiform mole
 - ⇒ *partial, complete - benign;*
 - ⇒ *invasive – uncertain biol. potential*
 - ⇒ *from abnormal conception*
 - ⇒ *abnormal placenta with villous hydrops and variable degree of trophoblastic proliferation*
- x** trophoblastic tumors – choriocarcinoma, etc.

Hydatidiform mole

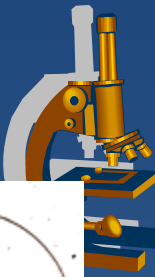

x Complete

- ⇒ „empty“ (aneuclear) egg fertilised by 1 normal sperm with duplication of haploid genome (23,X → 46,XX), or 2 normal sperm - 46,XX or 46,XY; paternal genome only
- ⇒ **gross:**
 - grape-like formations
- ⇒ **micro:**
 - cystic chorionic villi – extensive stromal oedema, central cistern – empty space
 - circumferential trophoblastic proliferation, atypias

x Partial

- ⇒ normal egg fertilised by 1 diploid sperm (46,XY) or 2 haploid sperm → triploid 69,XXX or 69,XXY
- ⇒ **gross:**
 - mixture of smaller grape-like villi, parts of embryo possible
- ⇒ **micro:**
 - mixture of oedematous and fibrotic villi
 - less marked trophoblastic proliferation



Hydatidiform mole

- complete

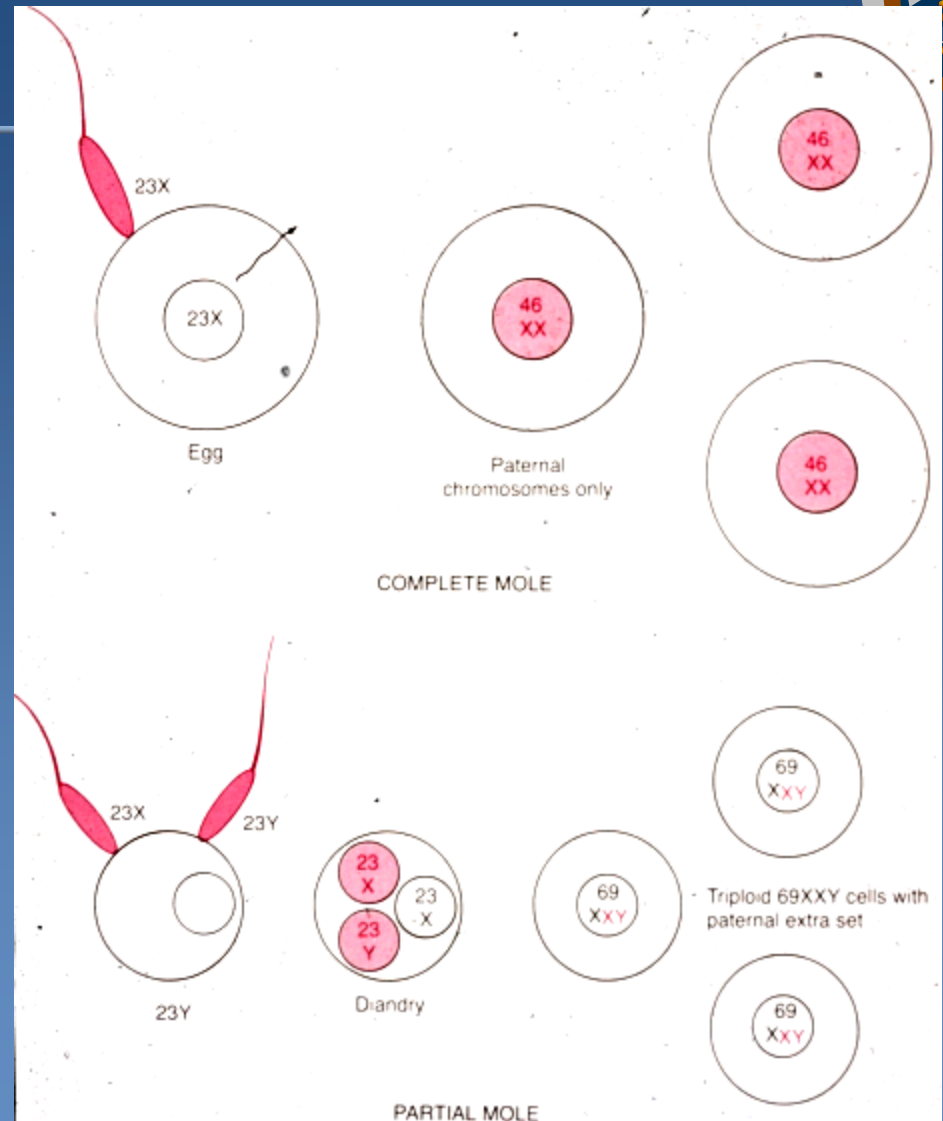
may persist or recur
10% → invasive m.
2,5% → chorioca

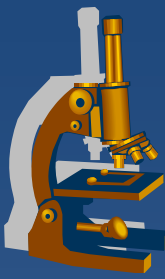
-partial

no progression,
may persist or recur

- invasive

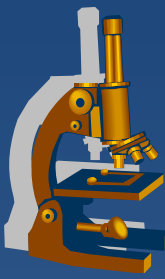
invasion of
myometrium by villi, risk of
perforation
locally destructive,
embolisation of villi into distant
organs (lungs)





Gestational choriocarcinoma

- ✗ subsequent to molar pregnancy (50%), abortion (25%), normal gestation (22,5%), ectopic pregnancy (2,5%)
- ✗ atypical syncytio- and cytotrophoblast, no villi, minimal stroma, no angiogenesis; foci of haemorrhage, necrosis present
- ✗ early haematogenous spread (lung, vagina, brain, liver...)
- ✗ highly elevated HCG
- ✗ chemosensitive (x germ cell tumor – low response to therapy, bad prognosis)



Fallopian tubes

Salpingitis



- ✗ mostly ascending inflammation from uterus
- ✗ possible secondary (appendicitis)

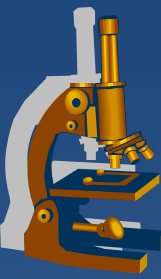
- ✗ risk of mucosal adhesions
 - ⇒ *infertility*
 - ⇒ *ectopic tubal pregnancy*

- ✗ part of pelvic inflammatory disease („adnextumor“)
 - ⇒ *inflammatory pseudotumor with abscessi*
 - ⇒ *pyosalpinx*

Tumors



- ✗ paratubal cysts
- ✗ intraepithelial serous adenocarcinoma (possible precursor of ovarian adenoca),
invasive adenocarcinoma
- ✗ pseudotumors
 - ⇒ *inflammatory pseudotumor*
 - ⇒ *endometriosis*



Ovary

Ovarian inflammation



- ✘ part of pelvic inflammatory disease (salpingo-oophoritis), tubo-ovarian abscess „adnextumor“
- ✘ common bacterial infections
- ✘ actinomycosis

Ovarian cysts



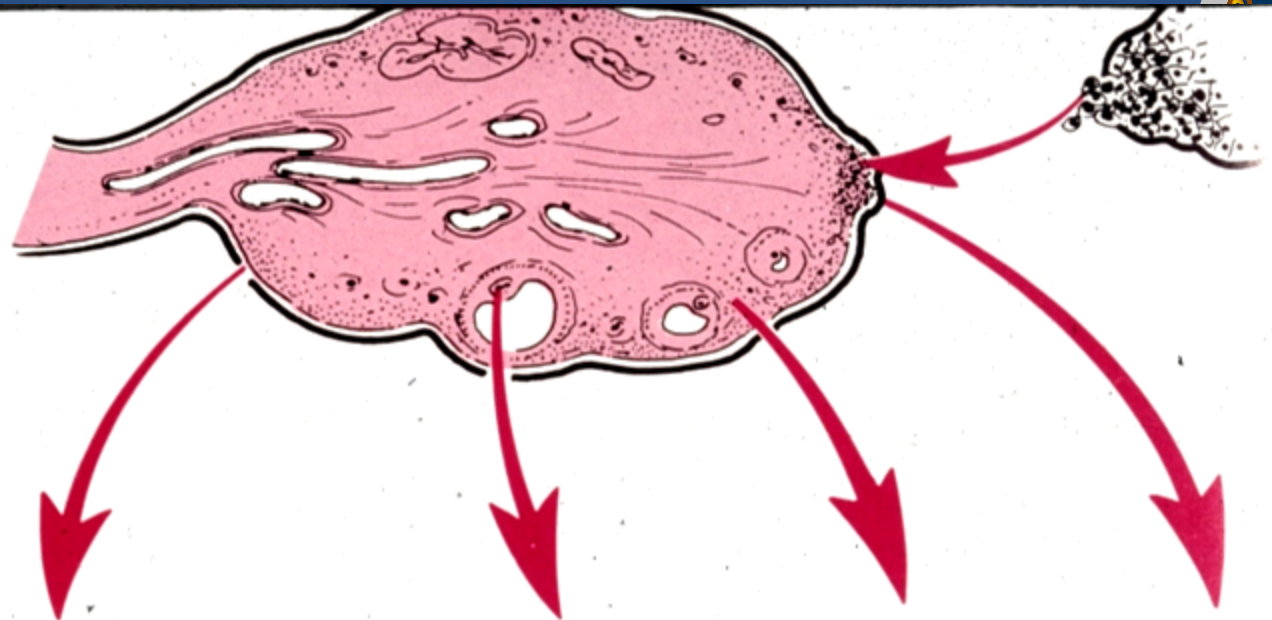
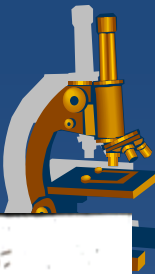
× non-neoplastic

- ⇒ inclusion c. (*mesothelial, epithelial*)
- ⇒ functional c. (*follicular, luteal, polycystic ovary syndrome, ovarian hyperstimulation syndrome*)
- ⇒ endometriosis

× neoplastic

- ⇒ surface epithelial tumors,
- ⇒ germ cell tumors
- ⇒ sex-cord stromal tumors
- ⇒ metastatic tumors
- ⇒ *others*

Ovarian tumors

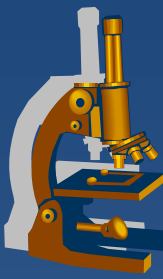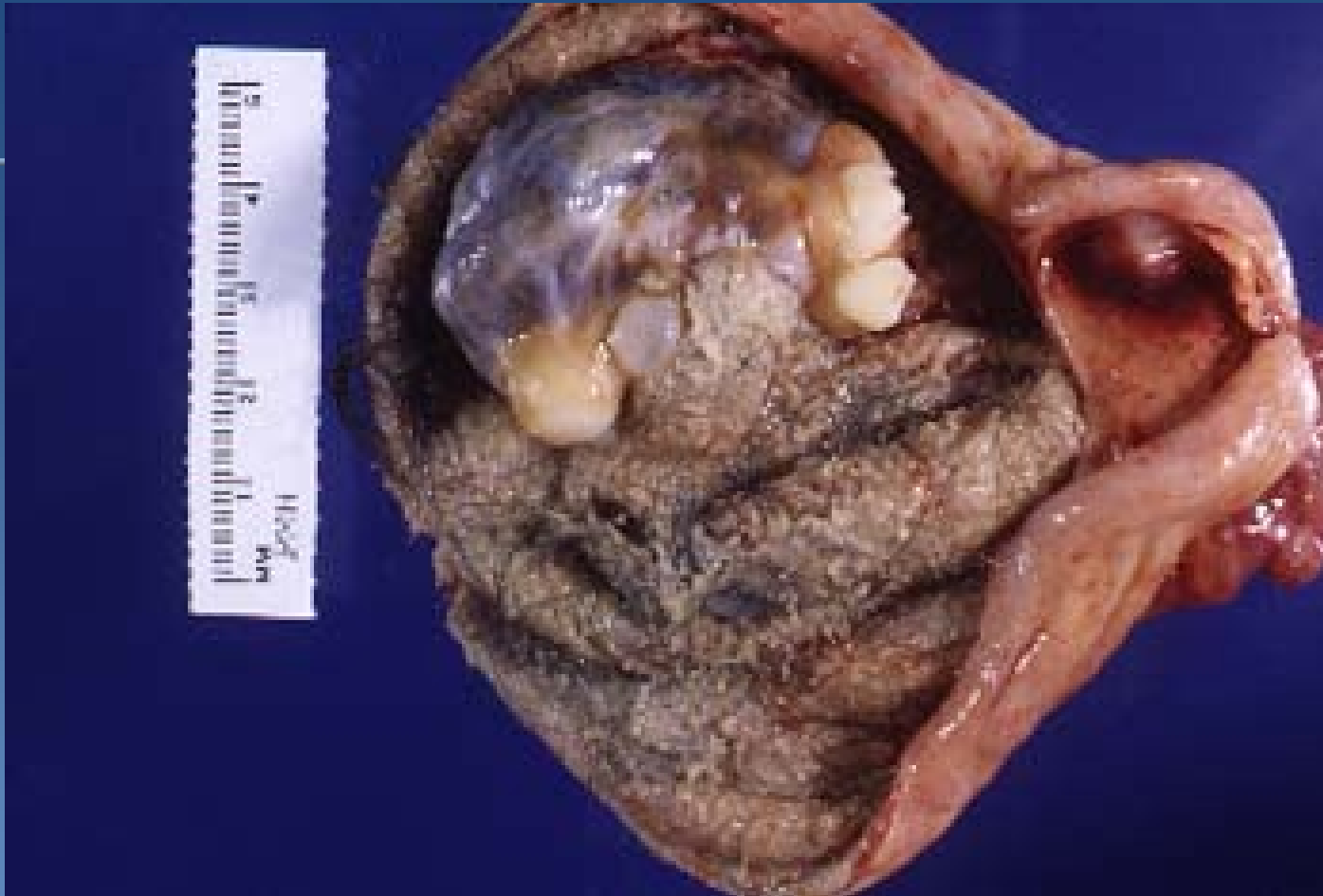


Origin	Surface epithelial cells (common epithelial tumors)	Germ cell	Sex cord–stroma	Metastasis to ovaries
Frequency	65–70%	15–20%	5–10%	5%
Age group affected	20 + years	0–25 + years	All ages	Variable
Types	<ul style="list-style-type: none"> • Serous tumor • Mucinous tumor • Endometrioid tumor • Clear cell tumor • Brenner tumor • Unclassifiable 	<ul style="list-style-type: none"> • Teratoma • Dysgerminoma • Endodermal sinus tumor • Choriocarcinoma 	<ul style="list-style-type: none"> • Fibroma • Granulosa–theca cell tumor • Sertoli–Leydig cell tumor 	

Germ cell tumors



- x counterpart to germ cell testicular tumors
- x dysgerminoma – ovarian „seminoma“
- x most common female germ cell tumor:
 - ⇒ *benign mature (differentiated) teratoma, usually in the form of dermoid cyst*



Dermoid cyst – mature cystic teratoma

Sex cord-stromal tumors



x Granulosa-theca cell tumors

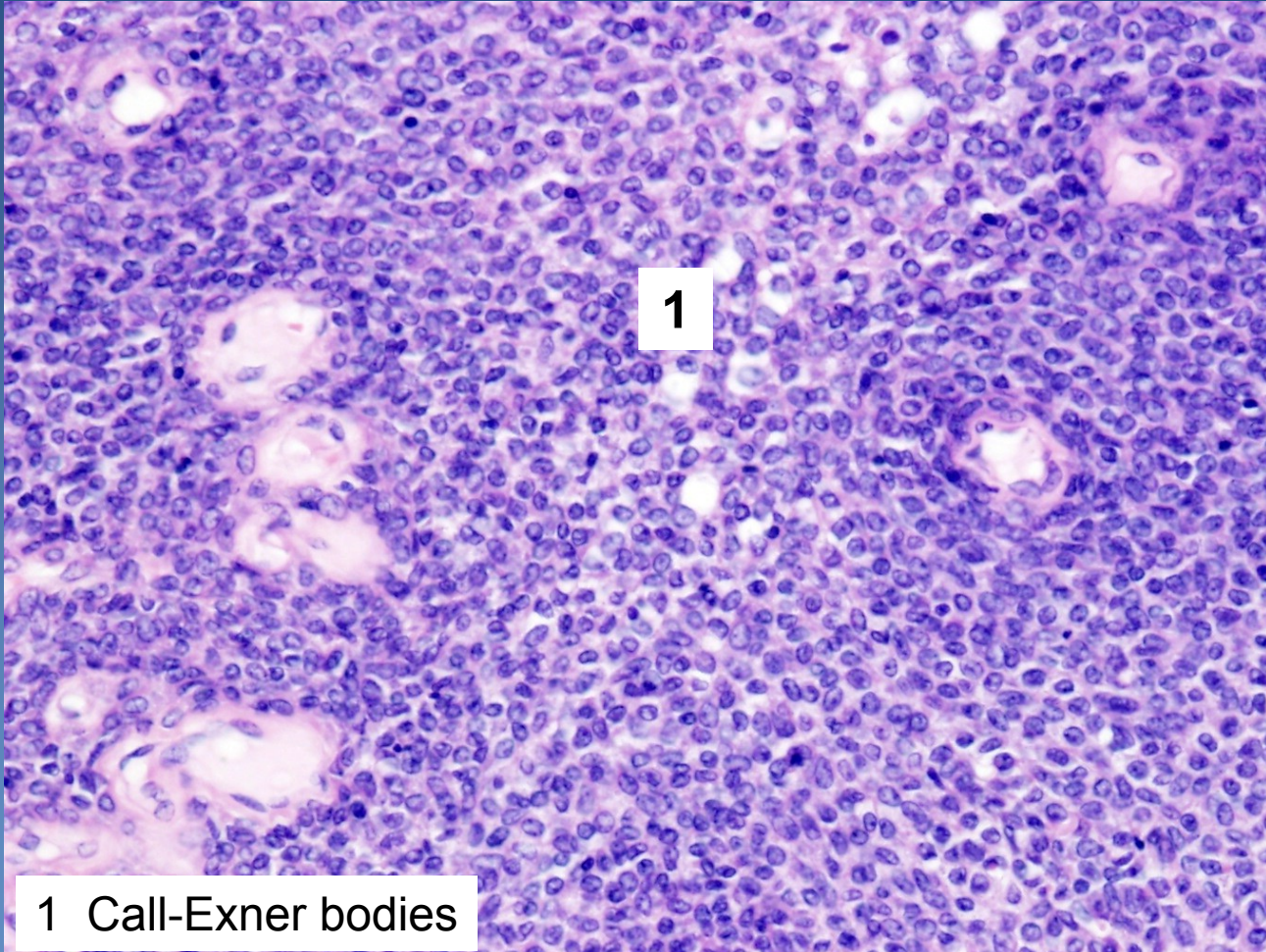
- **granulosa cell tumor (adult type)** – Call-Exner bodies; malignant potential, estrogen production
- **granulosa cell tumor (juvenile type)**
- **thecoma**
- **fibrothecoma**
- *fibroma*
- *fibrosarcoma*

x Sertoli-Leydig cell tumors

x Steroid cell tumors

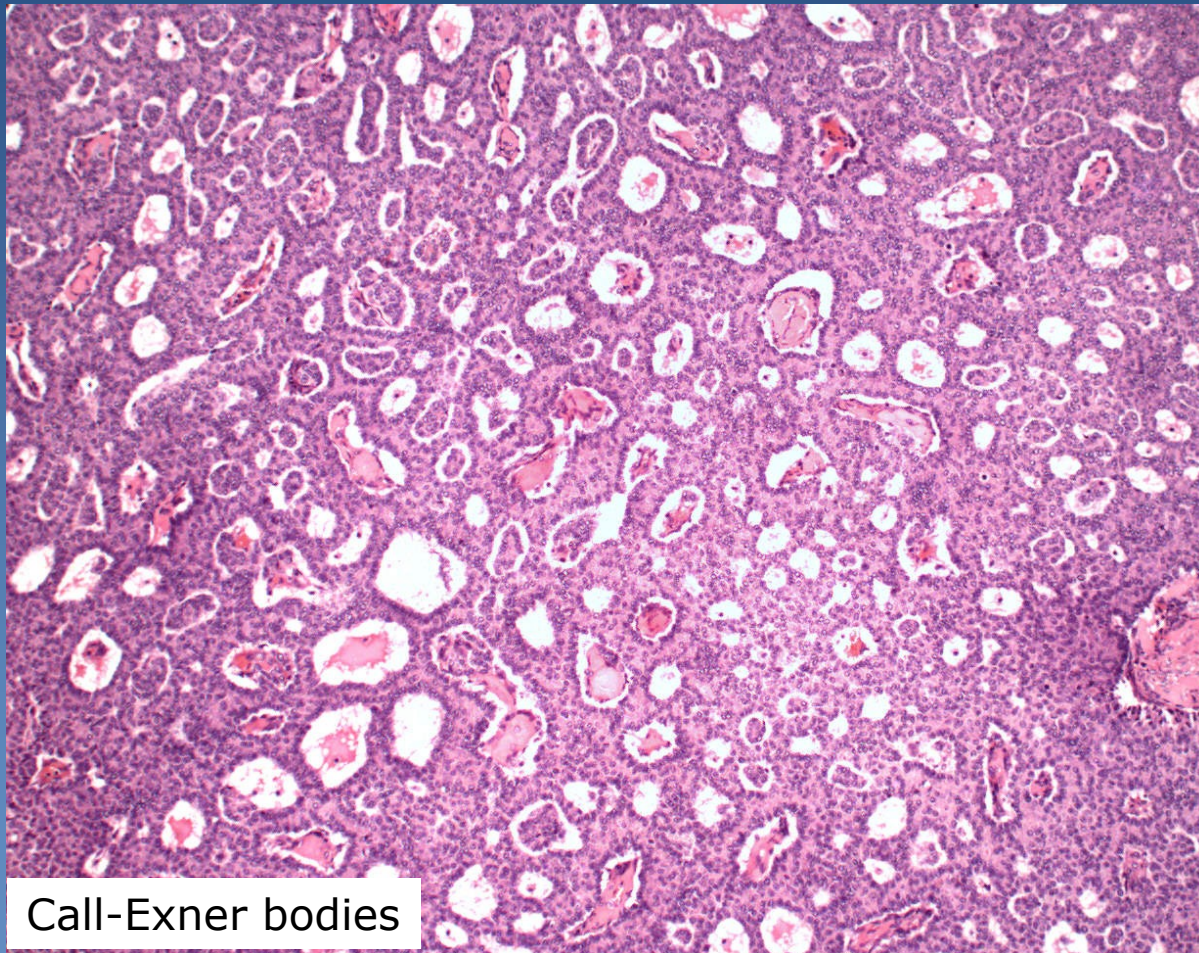
- resemble steroid hormone-secreting cells
- possible androgenic secretion

Granulosa cell tumor

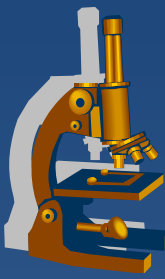


1 Call-Exner bodies

Granulosa cell tumor



Call-Exner bodies



Other tumors

- x Mixed germ cell sex cord-stromal tumors
- x Primary ovarian mesothelioma, adenomatoid tumor
- x Soft tissue tumors not specific to the ovary
- x Malignant lymphomas

....

x Secondary ovarian tumors

- ⇒ *Krukenberg tumor (metastatic mucinous adenocarcinoma)*
- ⇒ *pseudomyxoma peritonei,...*

Surface epithelial-stromal tumors



- ✗ Coelomic epithelium (mesothelium with the ability of transformation into Müllerian epithelium) → hyperplasia and metaplasia of the surface epithelium → neoplastic transformation

Biologic potential

- ✗ Benign
 - ⇒ *commonly in form of cystadenoma*
- ✗ Low malignant potential
 - ⇒ *borderline malignancy – moderate atypias, mitotic activity, architectonic changes (multilayering, irregular papillary budding), ! no invasion, but non-invasive peritoneal implants possible*
- ✗ Malignant

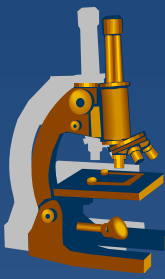
Surface epithelial-stromal tumors



Epithelial type

- x Serous*
- x Mucinous, endocervical-like and intestinal-type*
- x Endometrioid*
- x Clear cell tumors*
- x Transitional cell tumors*
- x Mixed tumors of müllerian epithelium*

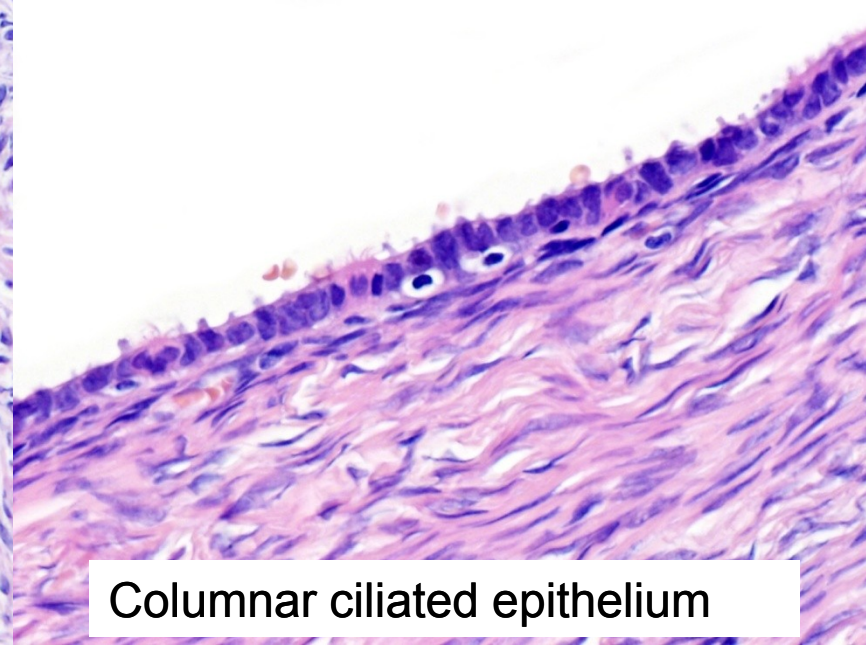
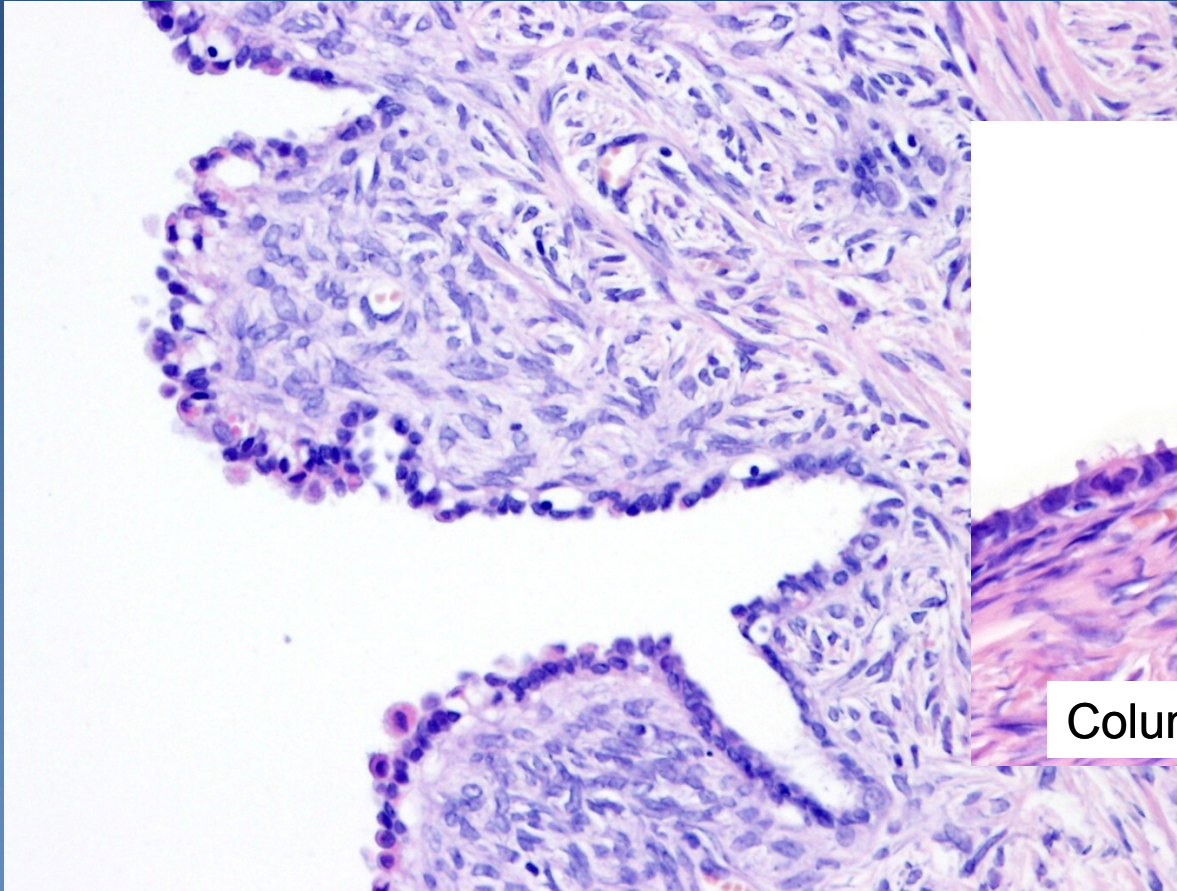
Surface epithelial-stromal tumors



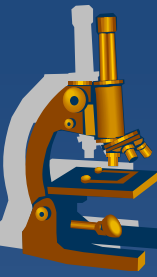
Form of growth

- ✗ Cystic
- ✗ Papillary incl. inverted
- ✗ Solid
- ✗ Increased amount of neoplastic stroma, mixed tumor (adenofibroma, adenosarcoma, etc.)

Serous cystadenoma (*cystadenofibroma*)



Columnar ciliated epithelium



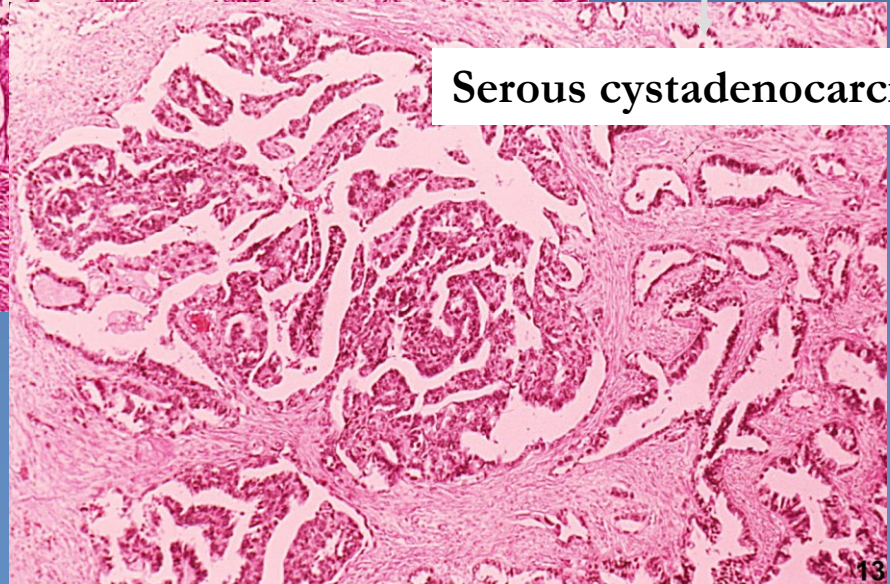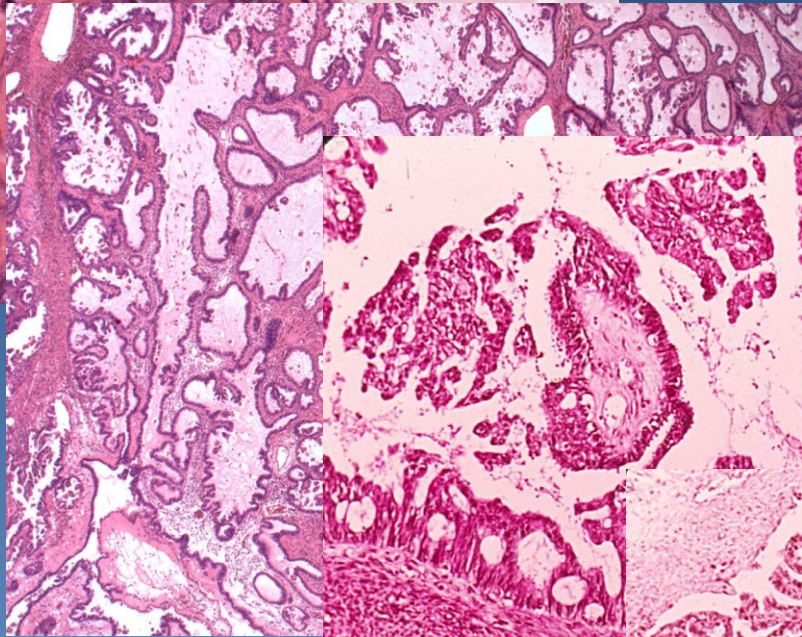
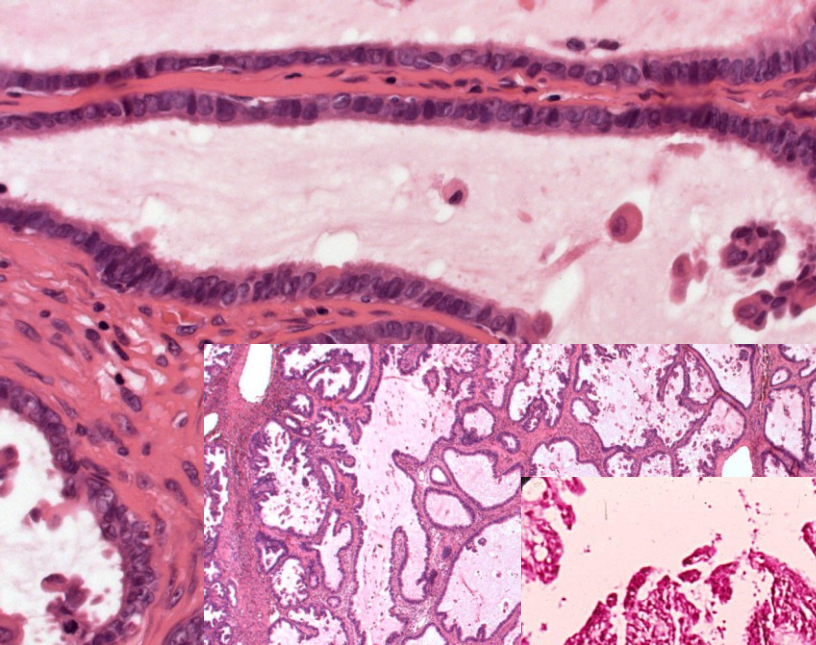
Serous cystadenoma



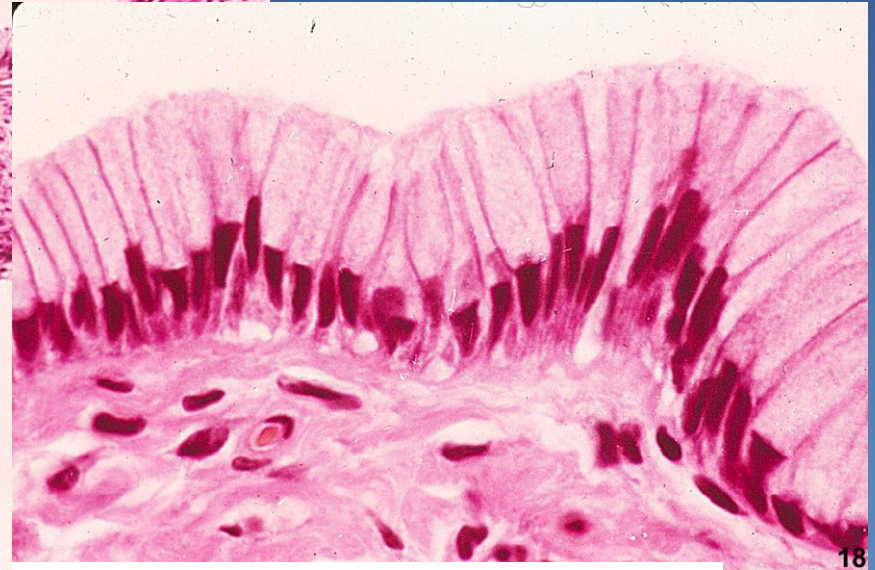
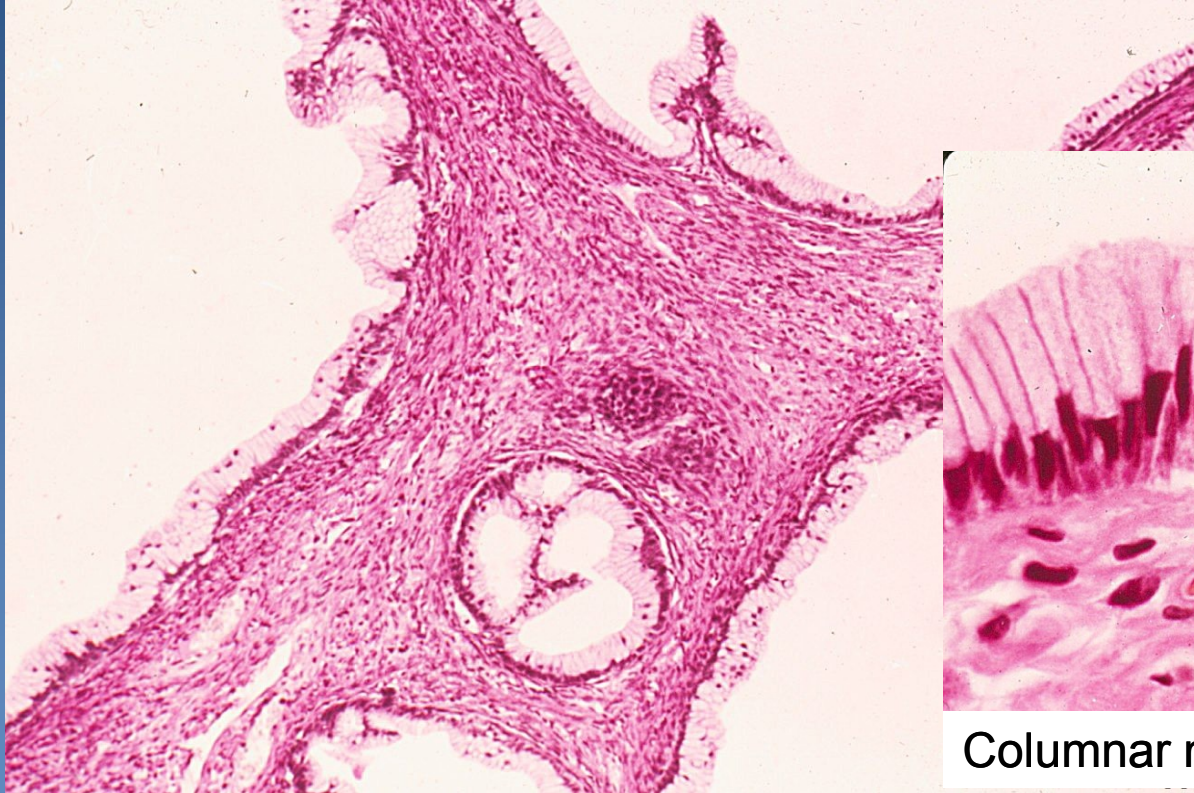
Serous borderline tumor



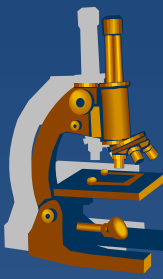
Serous cystadenocarcinoma



Mucinous cystadenoma



Columnar mucinous epithelium



Mucinous cystadenoma

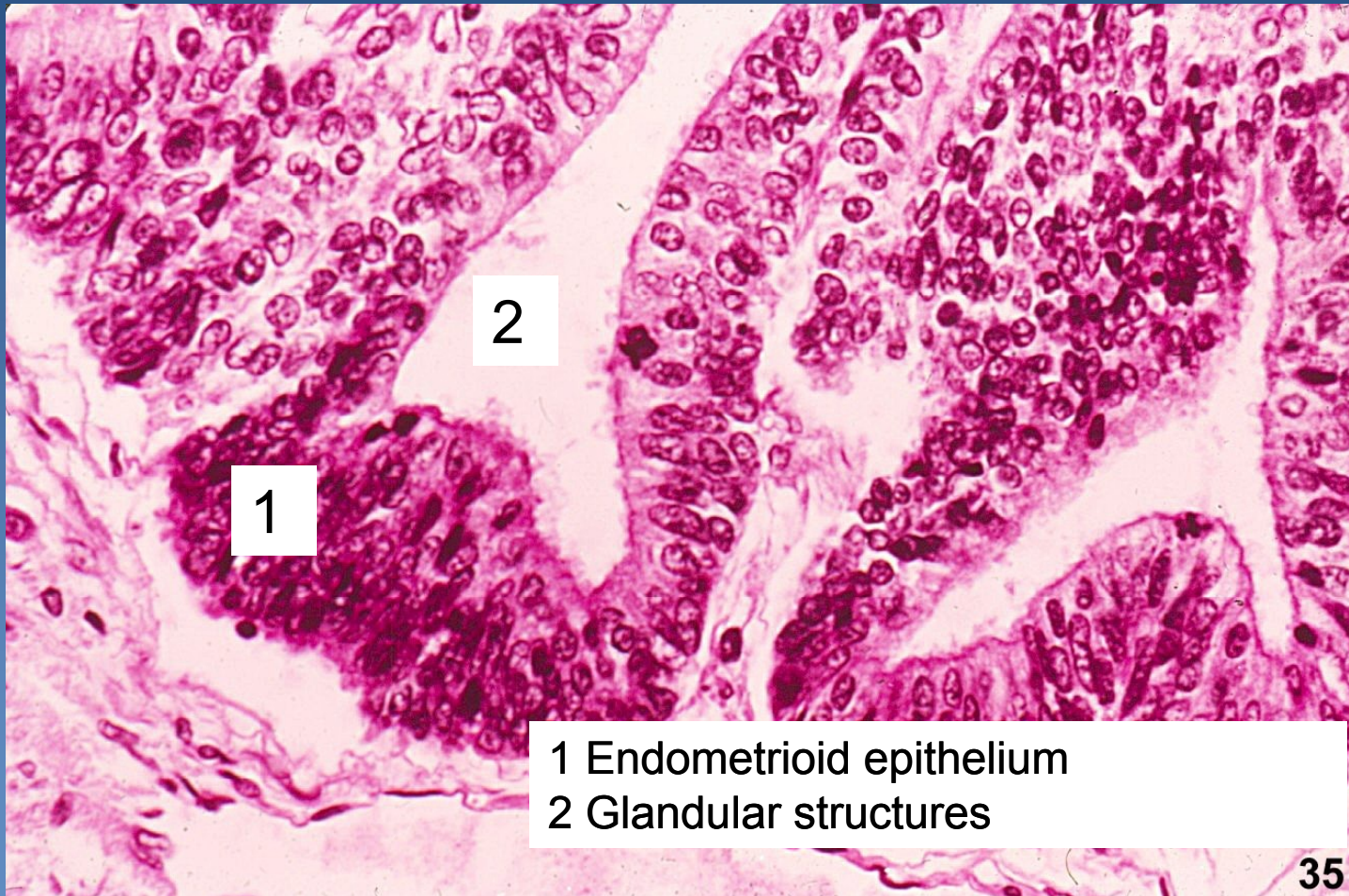
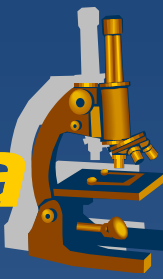

Mucinous borderline tumor



Mucinous cystadenocarcinoma

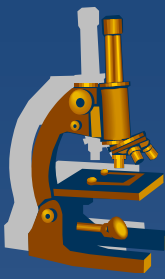
Endometrioid adenocarcinoma



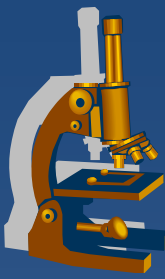
Surface epithelial-stromal tumors



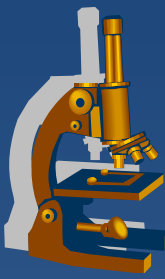
- ✘ Serous adenocarcinoma
 - ⇒ 60-80%, 30-50% bilateral
 - ⇒ usually smaller size, rapid growth
 - ⇒ common psammoma bodies
- ✘ Mucinous adenocarcinoma
 - ⇒ 5-15%, 10-20% bilateral
 - ⇒ large size, slow growth
- ✘ Endometrioid adenocarcinoma
 - ⇒ 10-30%, 10-30% bilateral
 - ⇒ slow growth, haemorrhagic content
 - ⇒ squamous metaplasia common



Pathology of the breast



- x Skin
- x **Nipple and areola**
- x **Mammary gland**
- x Soft tissues
 - ⇒ *inborn defects*
 - ⇒ *circulatory disorders*
 - ⇒ ***inflammations***
 - ⇒ ***non-neoplastic lesions***
 - ⇒ ***tumors***



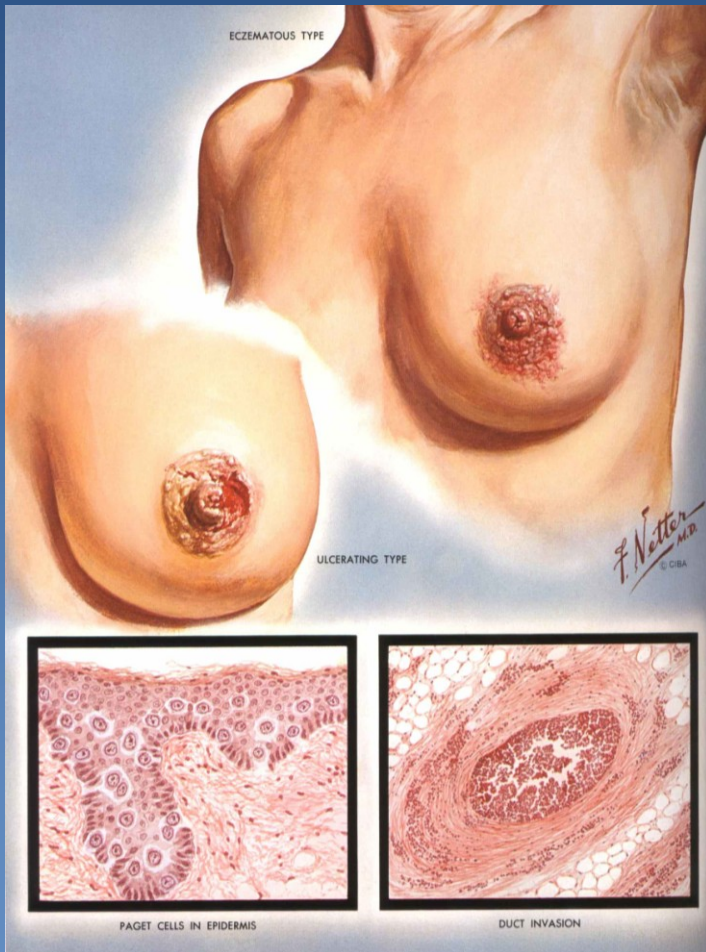Nipple and areola

Paget's carcinoma of the nipple

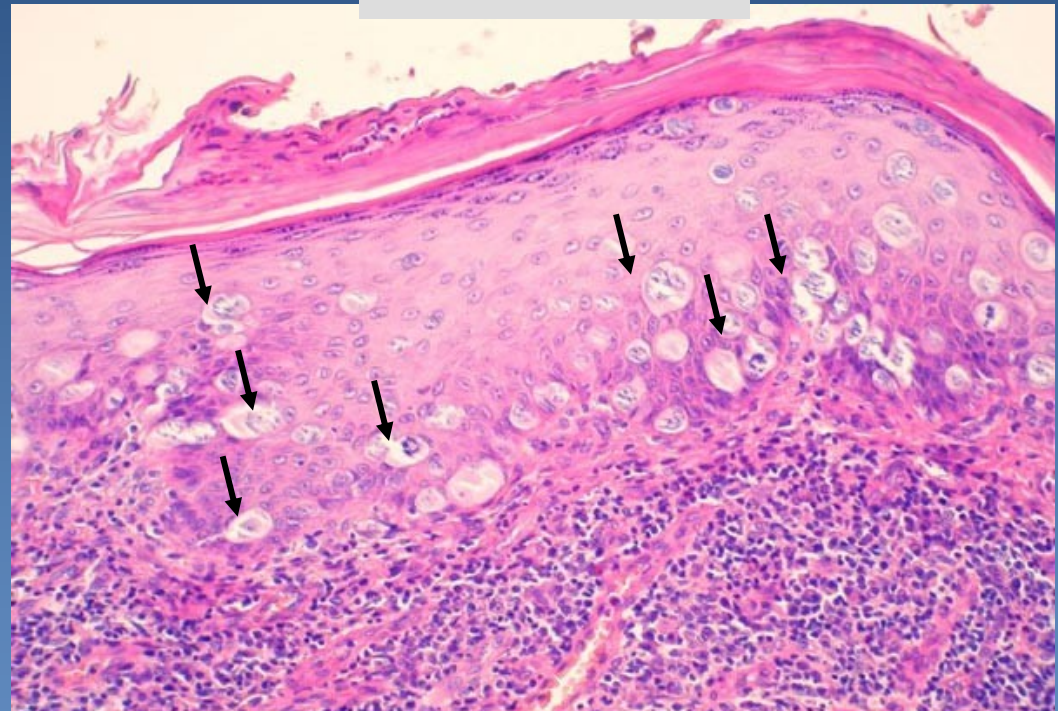


- x single neoplastic cells dispersed in the squamous cell epithelium of the nipple**
- x usually concurrent with DCIS (ductal carcinoma in situ) or invasive breast carcinoma**
- x gross: eczema-like (erythema, oozing/ ulcerated lesion)**

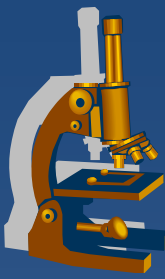
Paget's carcinoma of the nipple



www.mamma.cz

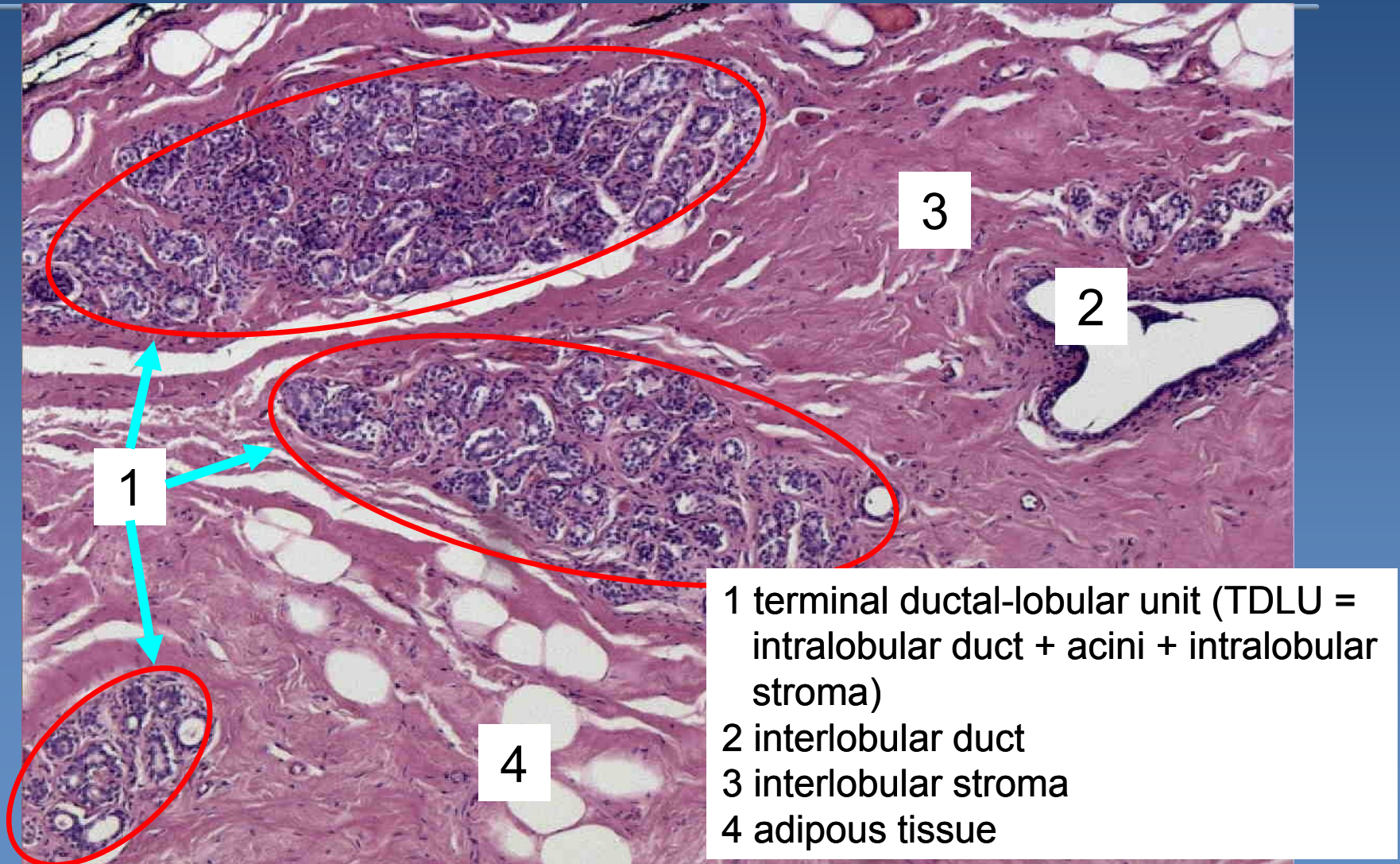


Single neoplastic cells (arrows) dispersed in squamous cell epithelium



Mammary gland

Fertile mammary gland - histology



1

3

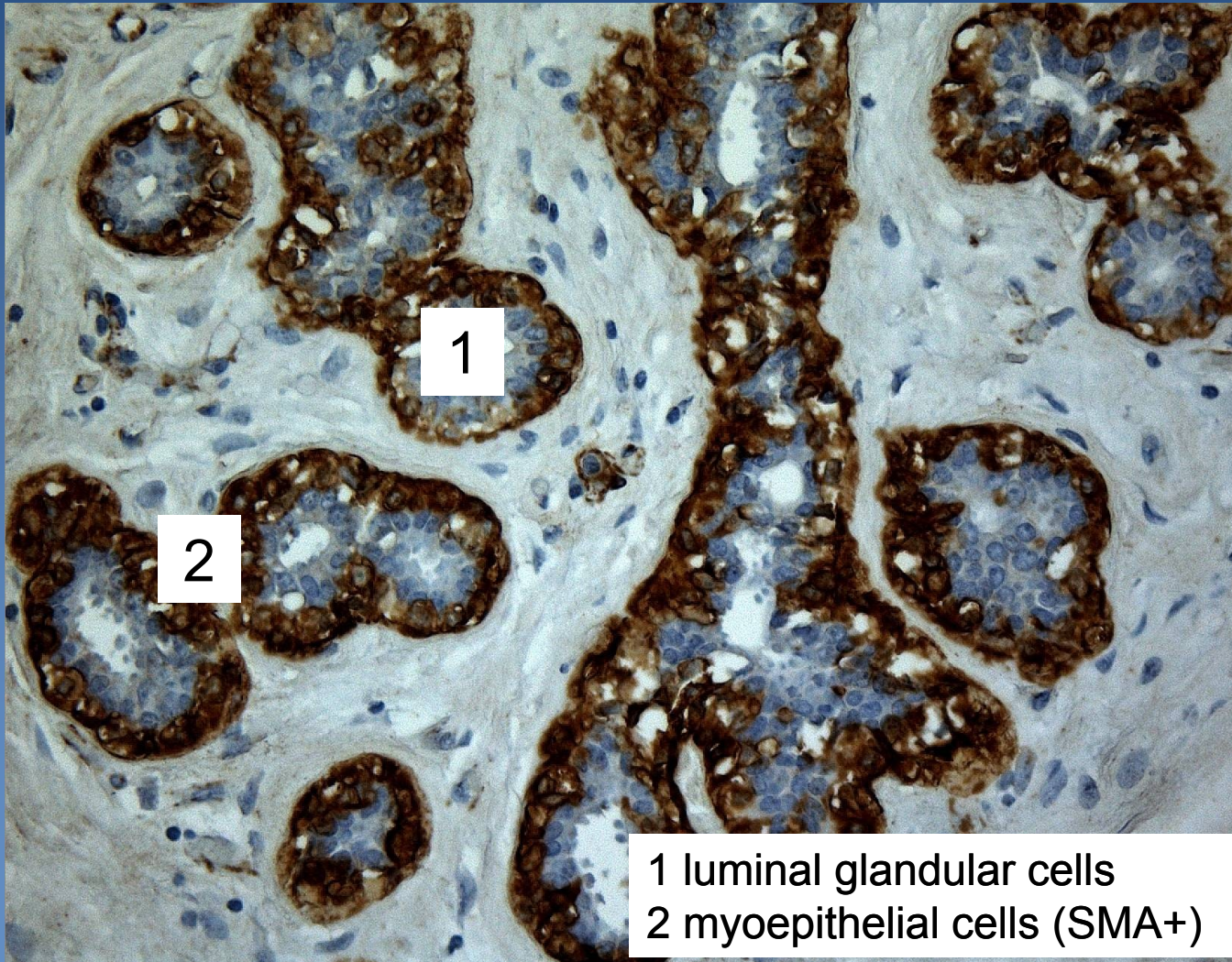
2

4

- 1 terminal ductal-lobular unit (TDLU = intralobular duct + acini + intralobular stroma)
- 2 interlobular duct
- 3 interlobular stroma
- 4 adipous tissue

TDLU

IHC anti-SMA



1 luminal glandular cells
2 myoepithelial cells (SMA+)

Mammary gland



x selected inflammations:

⇒ *Acute pyogenic mastitis*

- during first weeks of breastfeeding
- nipple fissures + infection (i.e. *Staphylococcus aureus*) → purulent inflammation / abscess formation

⇒ *Periductal mastitis*

- strongly associated with smoking
- squamous metaplasia in the distal parts of ducts → keratin plug → cystic dilatation / duct rupture → chronic /granulomatous periductal inflammation

⇒ *Lymphocytic (diabetic) mastopathy*

- type I. DM, autoimmune thyreoiditis
- periductal + perilobular sclerosis + dense lymphocytic infiltrate

Benign epithelial lesions



- x benign alterations in ducts and lobules**
- x common lesions**

⇒ *palpable irregularities (lumps, granularity), +/- tender*

⇒ *etiology:*

- hormone dependent
- inflammation-associated

⇒ *diff. dg.: malignant tumors*

Benign epithelial lesions



- x** classification according to the risk of developing subsequent breast carcinoma
- x** non-proliferative breast changes – fibrocystic change
 - ⇒ *cysts +/- apocrine metaplasia*
 - ⇒ *fibrosis*
 - ⇒ *adenosis*

Benign epithelial lesions



- ✗ proliferative breast disease without atypia
 - ⇒ proliferation of ductal epithelium +/-stroma
 - ⇒ usually in combination
 - ⇒ calcification common (mammography)
 - ⇒ epithelial hyperplasia (usual ductal hyperplasia – simple, florid)
 - ⇒ sclerosing adenosis
 - ⇒ papillomatosis
 - ⇒ complex sclerosing lesion

Benign epithelial lesions



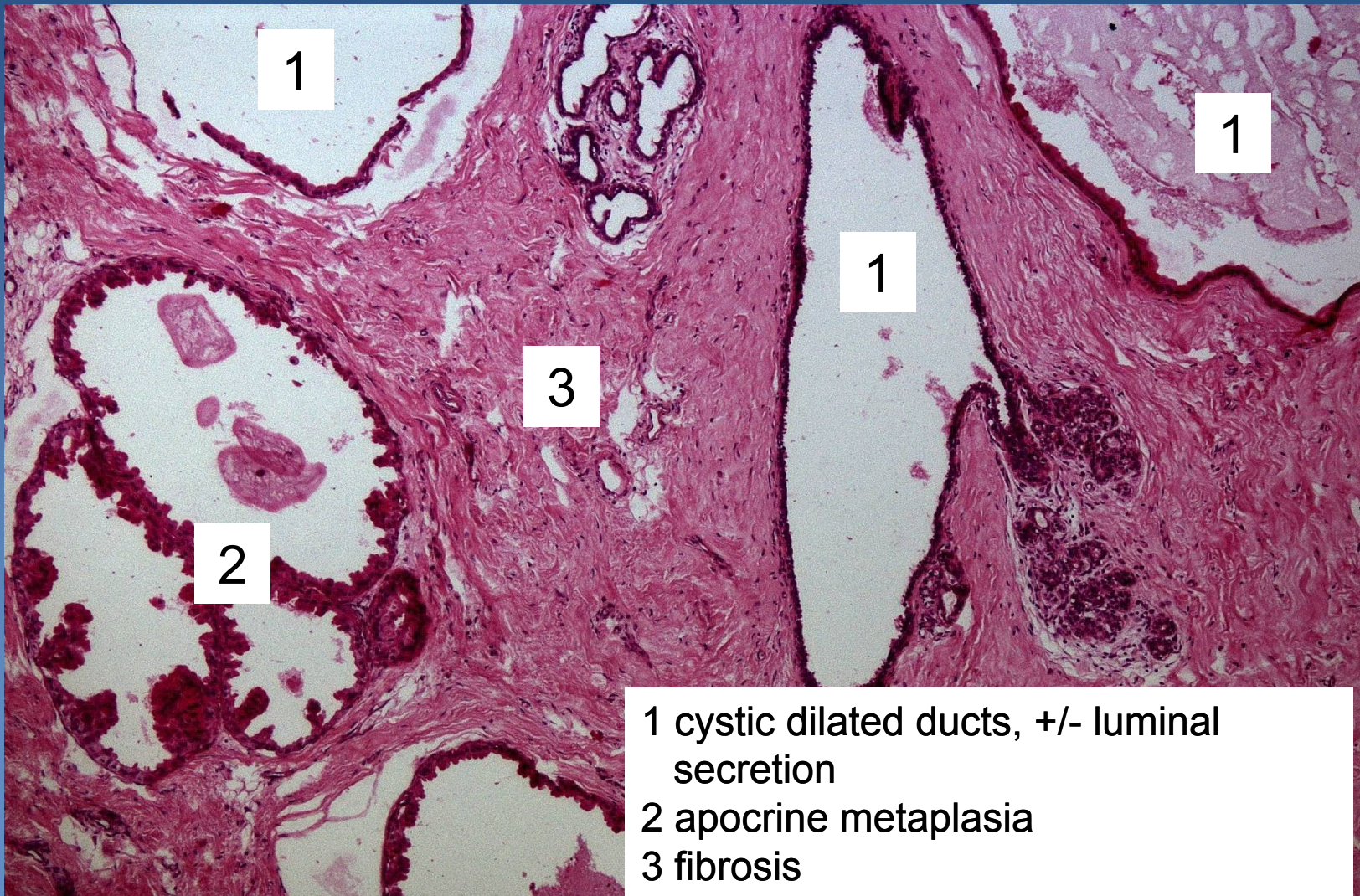
- x** proliferative breast disease with atypia
 - ⇒ *atypical ductal hyperplasia*
 - ⇒ *atypical lobular hyperplasia*

Fibrocystic change



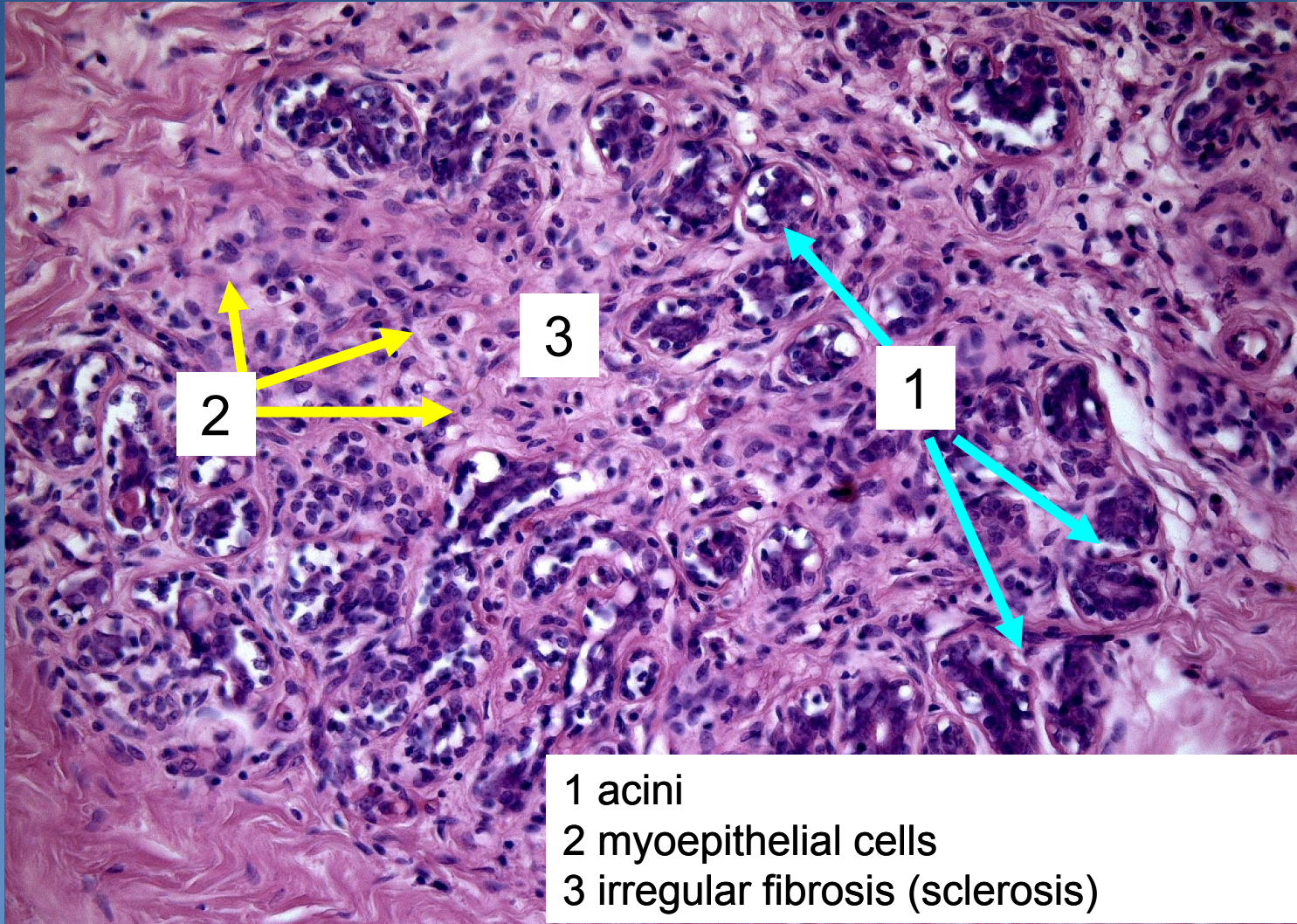
- x palpable „lumpy“ firmer tissue**
- x micro:**
 - ⇒ *extensive fibrosis*
 - ⇒ *+ cysts (apocrine metaplasia)*
 - ⇒ *+ adenosis (lobulocentric proliferative lesion = increased number of acini in a lobule, preserved lobular architectonics)*
 - ⇒ *commonly + ductal and/or lobular hyperplasia*
- x no increased risk of malignant transformation** (unless atypical epithelial hyperplasia present)

Fibrocystic change



- 1 cystic dilated ducts, +/- luminal secretion
- 2 apocrine metaplasia
- 3 fibrosis

Sclerosing adenosis



Benign epithelial tumors

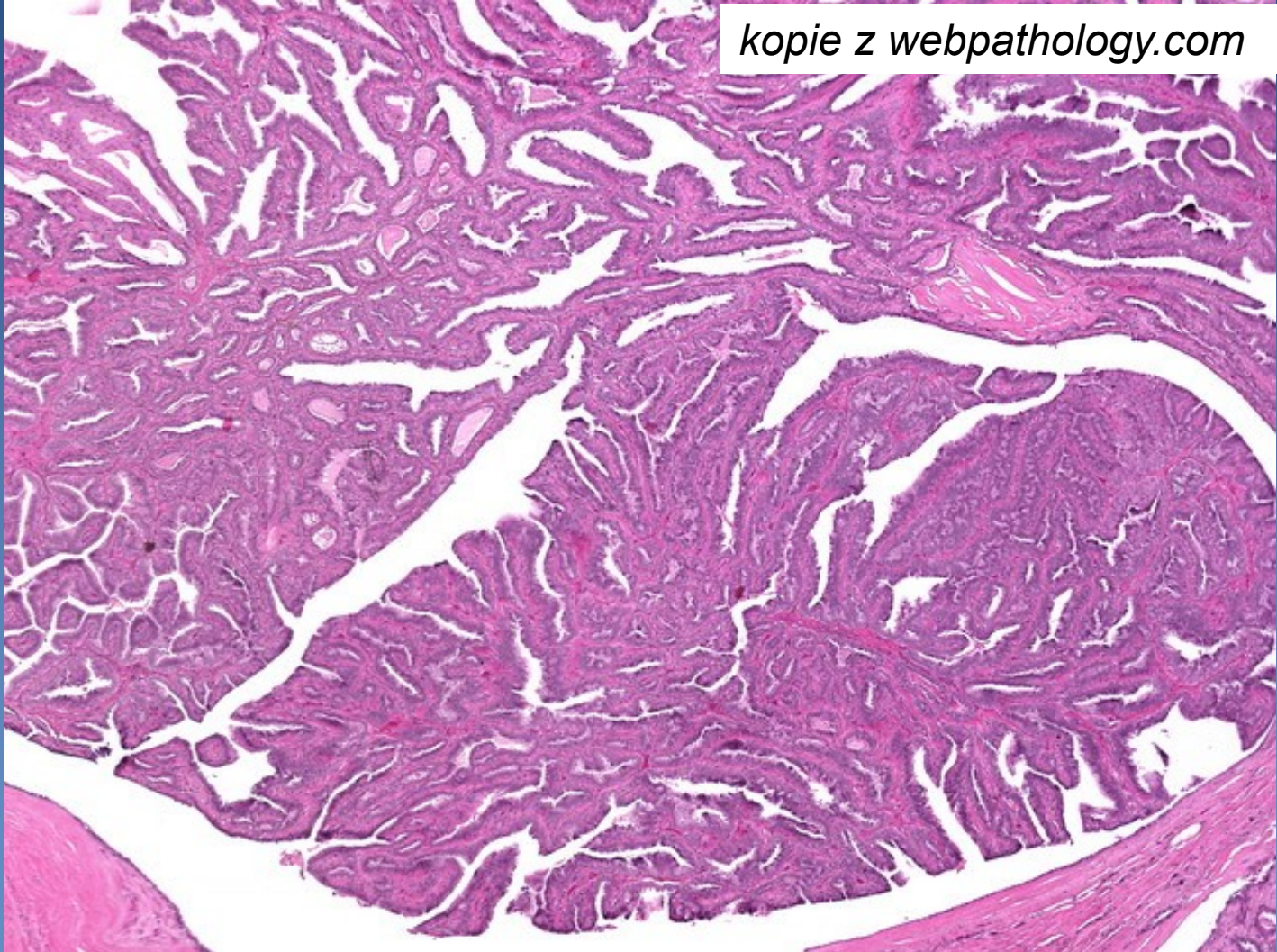


- x rather uncommon**
- x important in diff. dg. of malignant tumors**
- x selected entities:**
 - ⇒ *Intraductal, intracystic papilloma*
 - ⇒ *Lactational adenoma (?exaggerated focal response)*
 - ⇒ *Tubular adenoma*
 - ⇒ *Ductal adenoma*

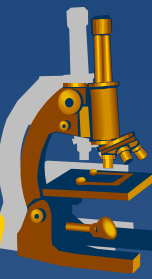
Intraductal papilloma



kopie z webpathology.com

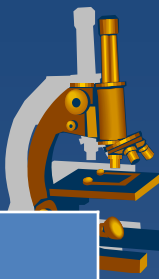

Proliferative breast disease with atypia / in situ neoplasia



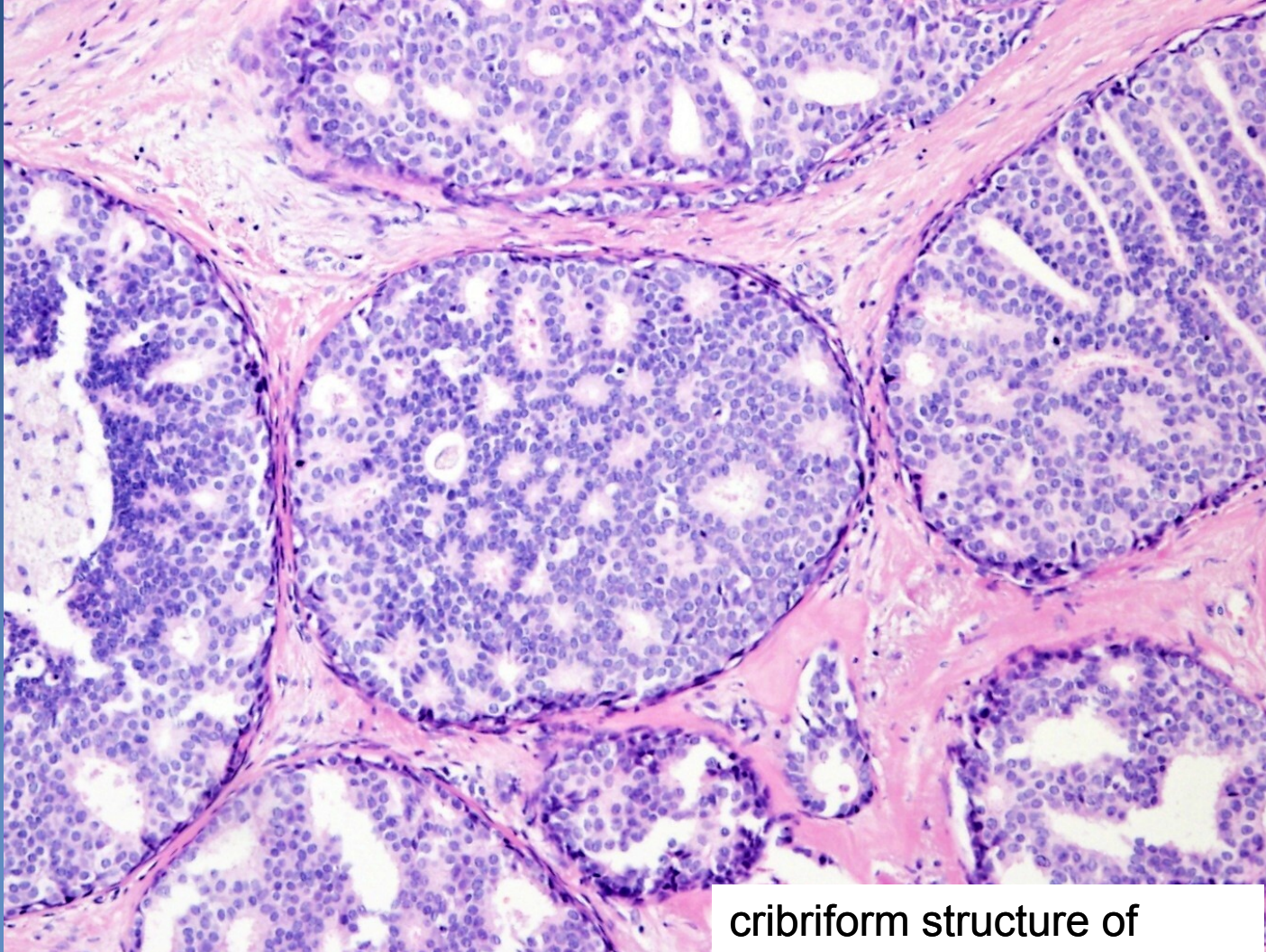
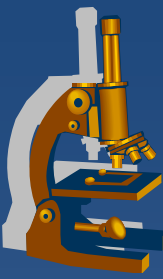
- x** relatively common
- x** potential progression into invasive carcinoma – precursor lesion
 - ⇒ ***Atypical ductal hyperplasia (ADH)***
 - ⇒ ***Atypical lobular hyperplasia (ALH)***
 - ⇒ ***Ductal carcinoma in situ (DCIS)***
 - non- high grade
 - high grade
 - ⇒ ***Lobular carcinoma in situ (LCIS)***

Proliferative epithelial lesions and in situ neoplasia



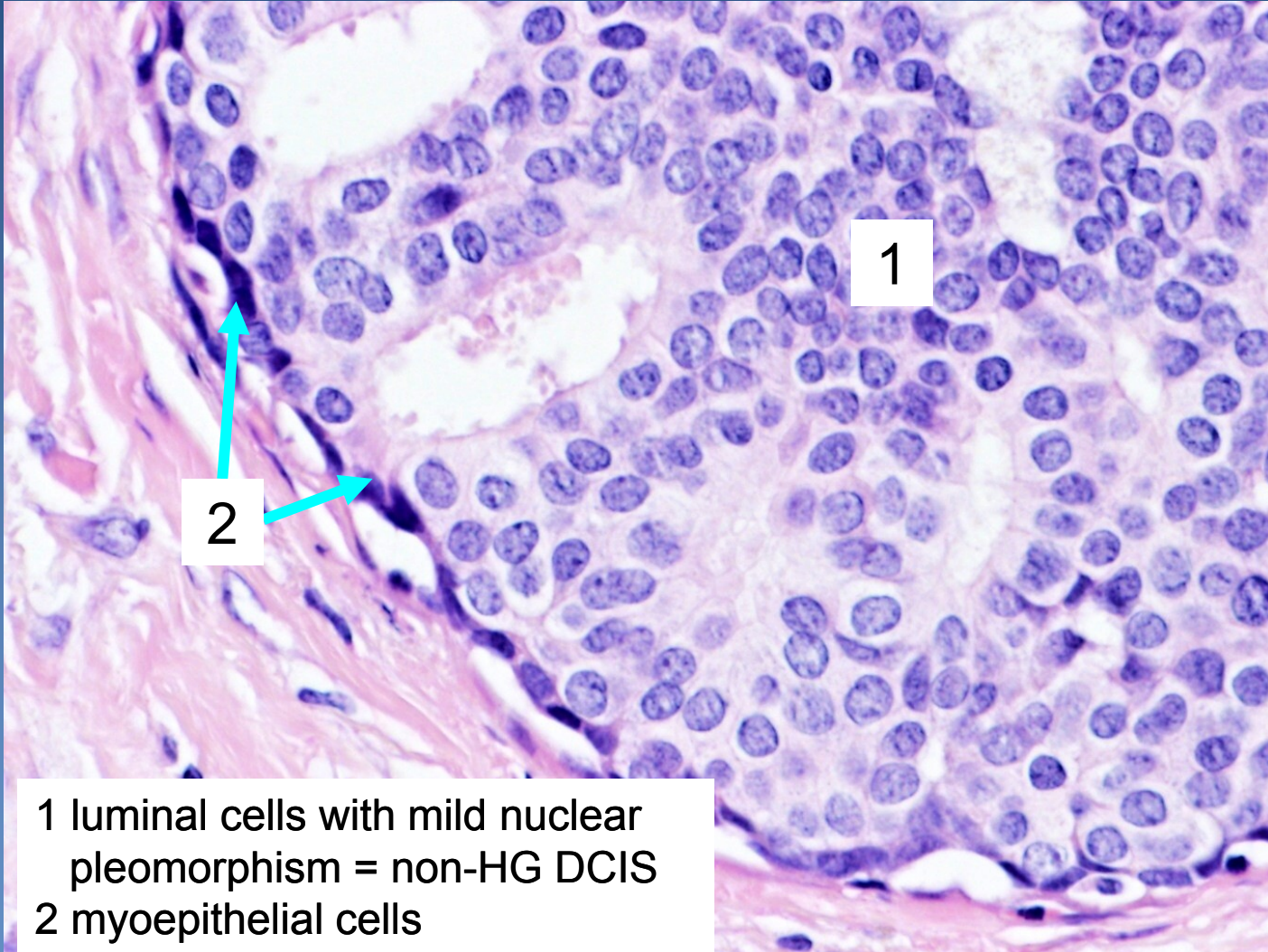
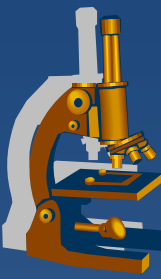
Diagnosis	Morphology
<ul style="list-style-type: none"> • Focal fibrosis • Cysts • Florid adenosis • Sclerosing adenosis 	<ul style="list-style-type: none"> • focal increase of TDLU stroma • dilated ducts • increased number of acini • increased number of acini + TDLU fibrosis
<ul style="list-style-type: none"> • Ductal hyperplasia • Lobular hyperplasia • Ductal papillomatosis • Fibroadenomatoid hyperplasia 	<ul style="list-style-type: none"> • ductal epithelium proliferation • acinar epithelium proliferation • epithelial proliferation in dilated ducts • ductal epithelial + TDLU stromal proliferation
<ul style="list-style-type: none"> • Atypical ductal hyperplasia • Atypická lobulární hyperplázie 	<ul style="list-style-type: none"> • ductal epithelium proliferation + atypias • acinar epithelium proliferation + atypias
<ul style="list-style-type: none"> • DCIS, non-high grade • LCIS 	<ul style="list-style-type: none"> • intraductal ca in situ with mild nuclear pleomorphism • lobular ca in situ
<ul style="list-style-type: none"> • DCIS, high grade 	<ul style="list-style-type: none"> • intraductal ca in situ with severe nuclear atypias

DCIS



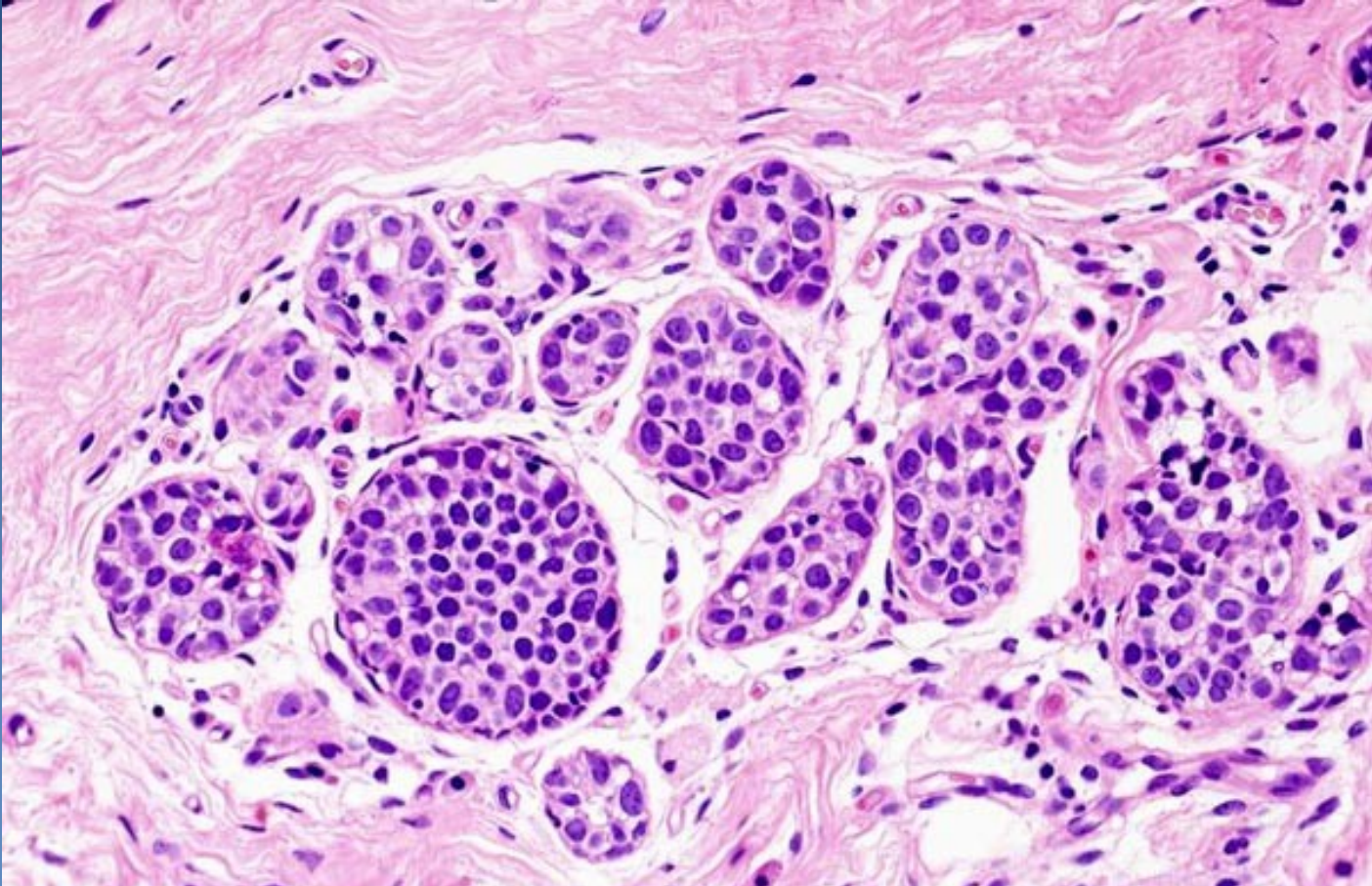
cribriform structure of
DCIS

DCIS



1 luminal cells with mild nuclear pleomorphism = non-HG DCIS
2 myoepithelial cells

LCIS



Expanded acini filled by mildly pleomorphic cells, intact basement membrane

Malignant epithelial tumors



Breast carcinoma

- x commonest** malignancy in females in high-income countries
- x rising incidence**
- x falling mortality**
 - ⇒ *screening + better diagnostics*
 - ⇒ *known modifiable risk factors*
 - ⇒ *more effective therapy*
- x metastases**
 - ⇒ *lymphatic spread – regional LN (mostly axillary)*
 - ⇒ *hematogenous spread (bones, lung, liver, brain...)*

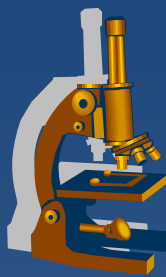
Malignant epithelial tumors



- x Sporadic carcinomas** ($\approx 95\%$)
 - \Rightarrow *accidental sequential mutations*
 - \Rightarrow *mostly perimenopausal/postmenopausal, old age (50-75)*

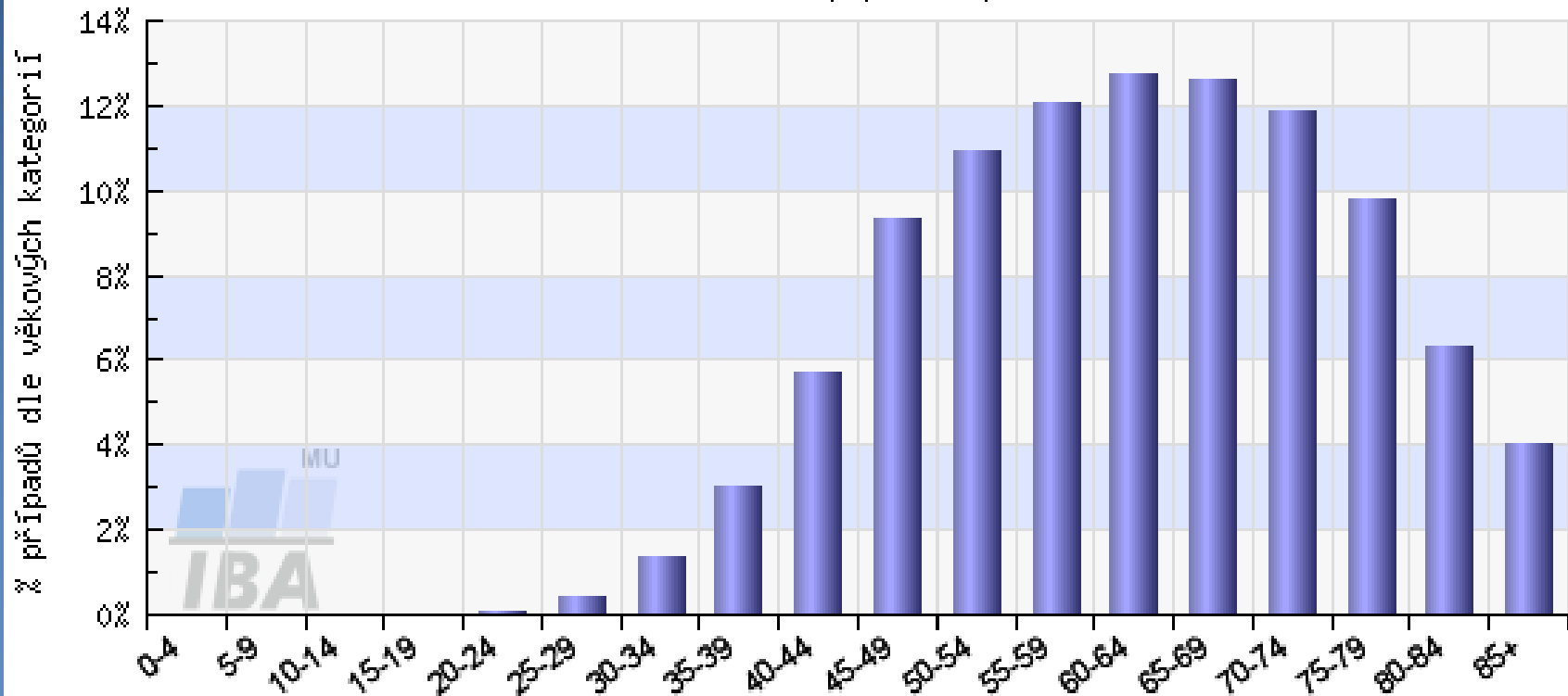
- x Familial carcinomas** ($\approx 5\%$)
 - \Rightarrow *hereditary mutations in some TSG (BRCA1, BRCA2...)*
 - \Rightarrow *typical in young females (after age of 20)*
 - \Rightarrow *possible multicentric, bilateral \rightarrow prophylactic mastectomy*
 - \Rightarrow *\uparrow risk of ovarian carcinomas*

Age incidence



C50 - ZN prsu - Incidence, ženy

věková struktura populace pacientů



Analyzovaná data: N=142275

<http://www.svod.cz>

Zdroj dat: ÚZIS ČR

WHO classification of carcinomas



× Invasive ca, no special type (NST) = ductal ca, NOS

× Invasive lobular carcinoma

- × Tubular ca
- × Invasive cribriform ca
- × Medullary ca
- × Mucin producing ca
- × Neuroendocrine tumors
- × Invasive papillary ca
- × Invasive micropapillary ca

- × Apocrine ca
- × Metaplastic ca
- × Lipid-rich ca
- × Secretory ca
- × Onkocytic ca
- × Adenoid-cystic carcinoma
- × Acinic cell ca
- × Glycogen-rich clear cell ca
- × Sebaceous ca
- × Inflammatory ca

- × Bilateral carcinoma

Invasive ductal carcinoma



✘ most common

✘ gross:

⇒ *firm lesion, irregular border*

✘ micro:

⇒ *cohesive (E-cadherin+) tumor cells*

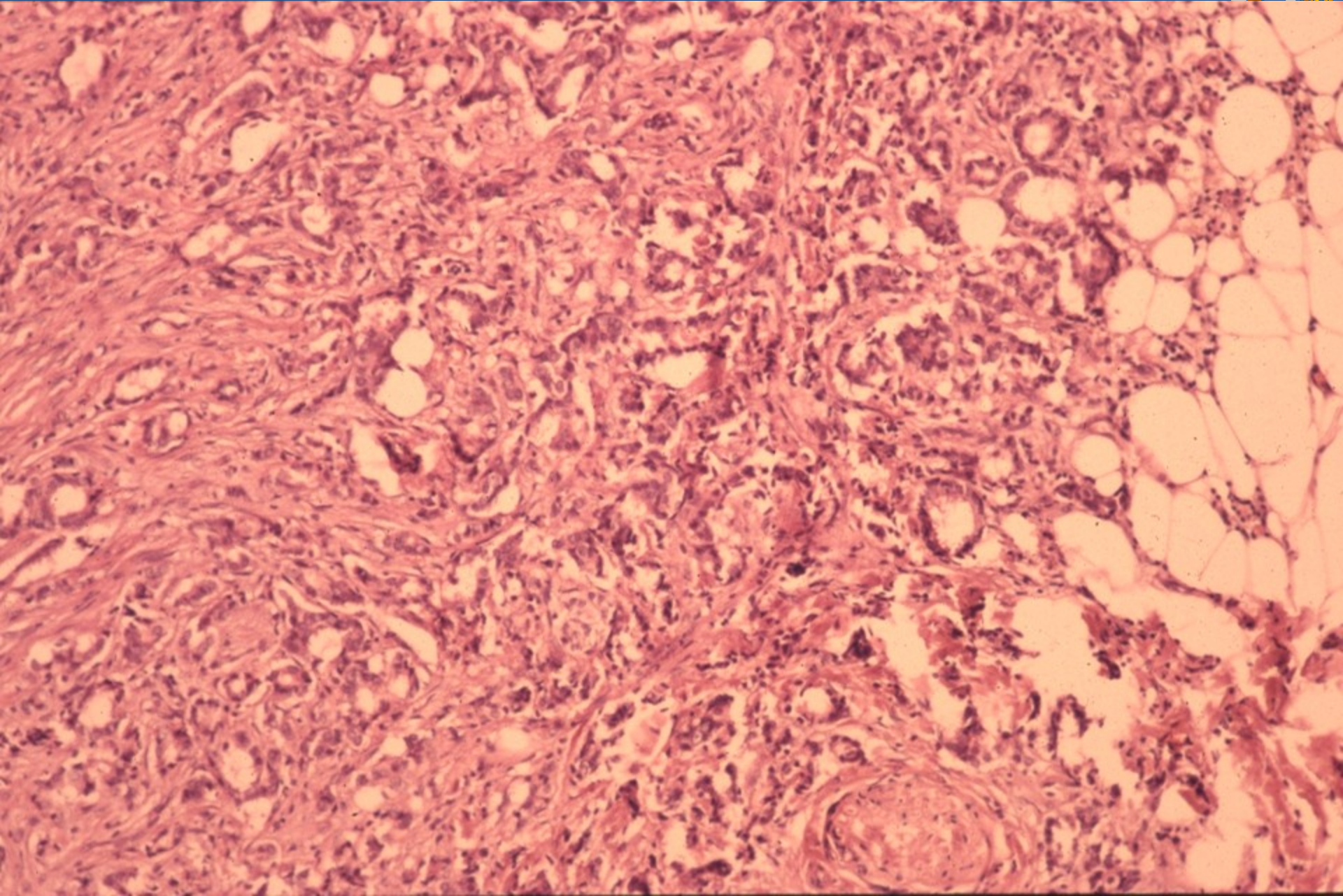
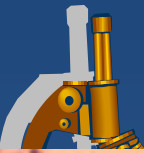- tubules, trabeculae, solid clusters
- variable grade of nuclear pleomorphism, mitotic activity (gr. I-III)

⇒ *loss of outer myoepithelial cell layer (p63-, SMA-)*

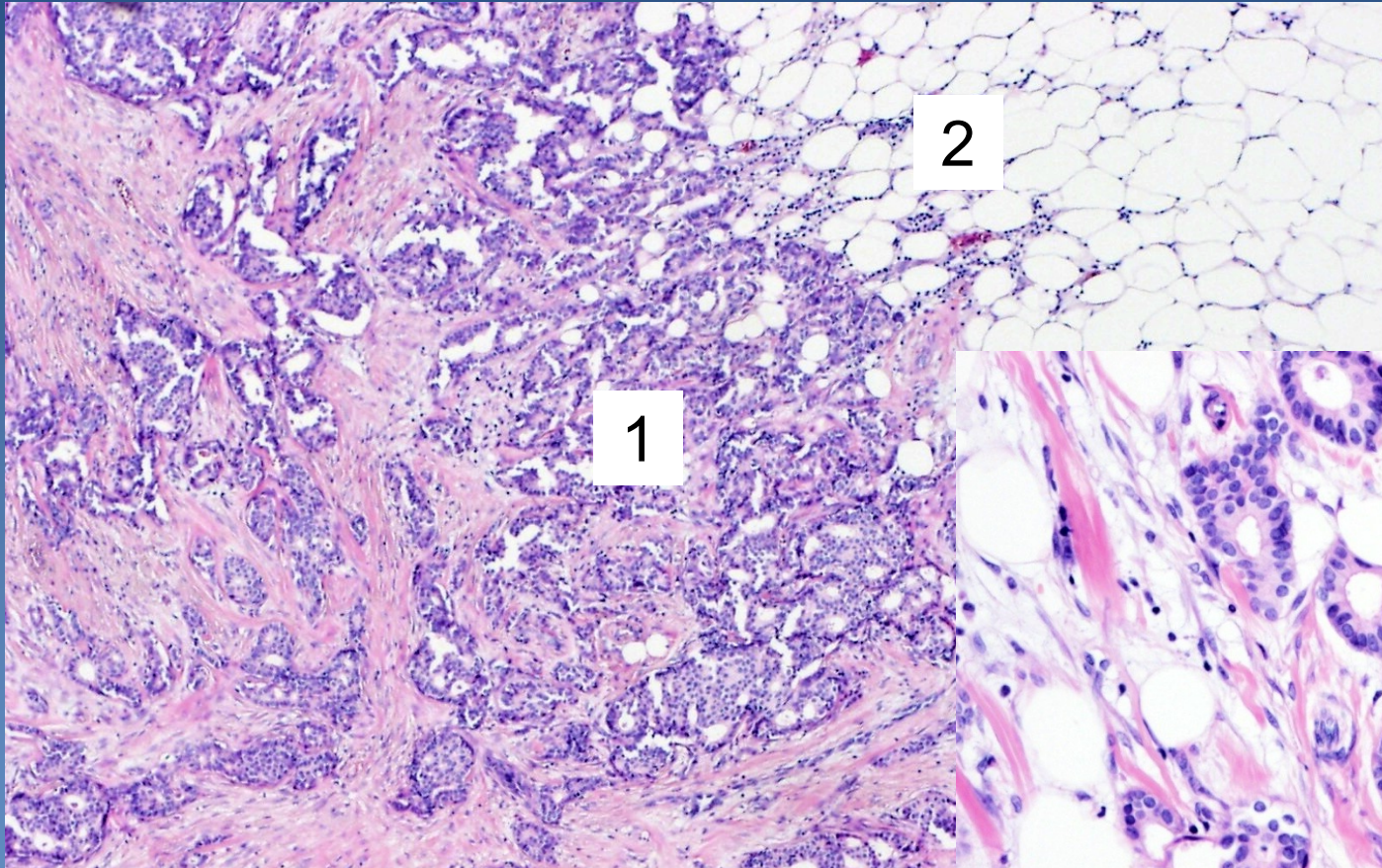
⇒ *dense fibrotic stroma, desmoplasia*

⇒ *infiltrative growth, commonly adjacent DCIS*

Invasive ductal carcinoma

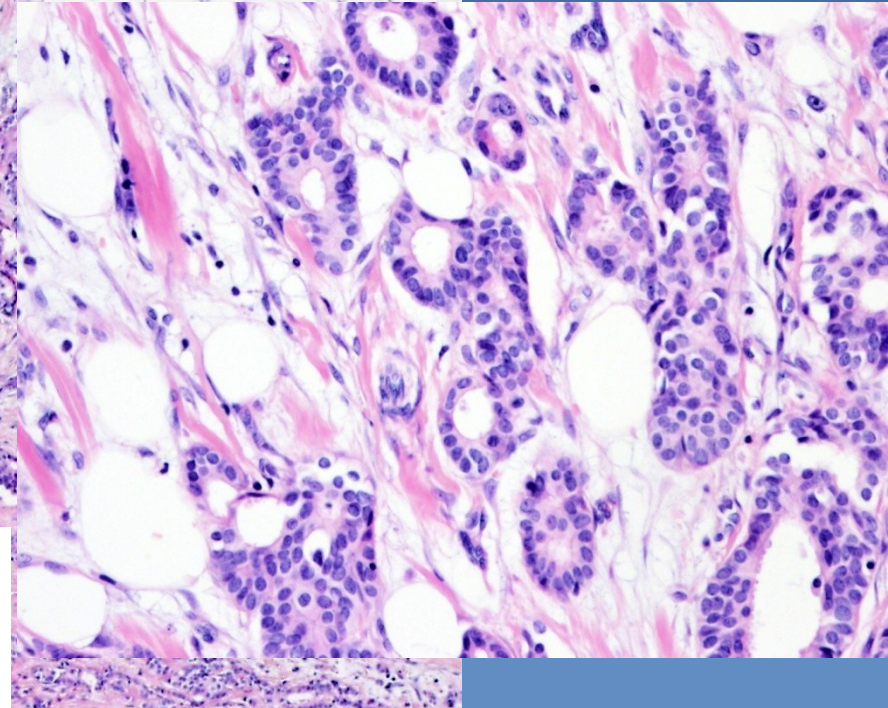


Invasive ductal carcinoma



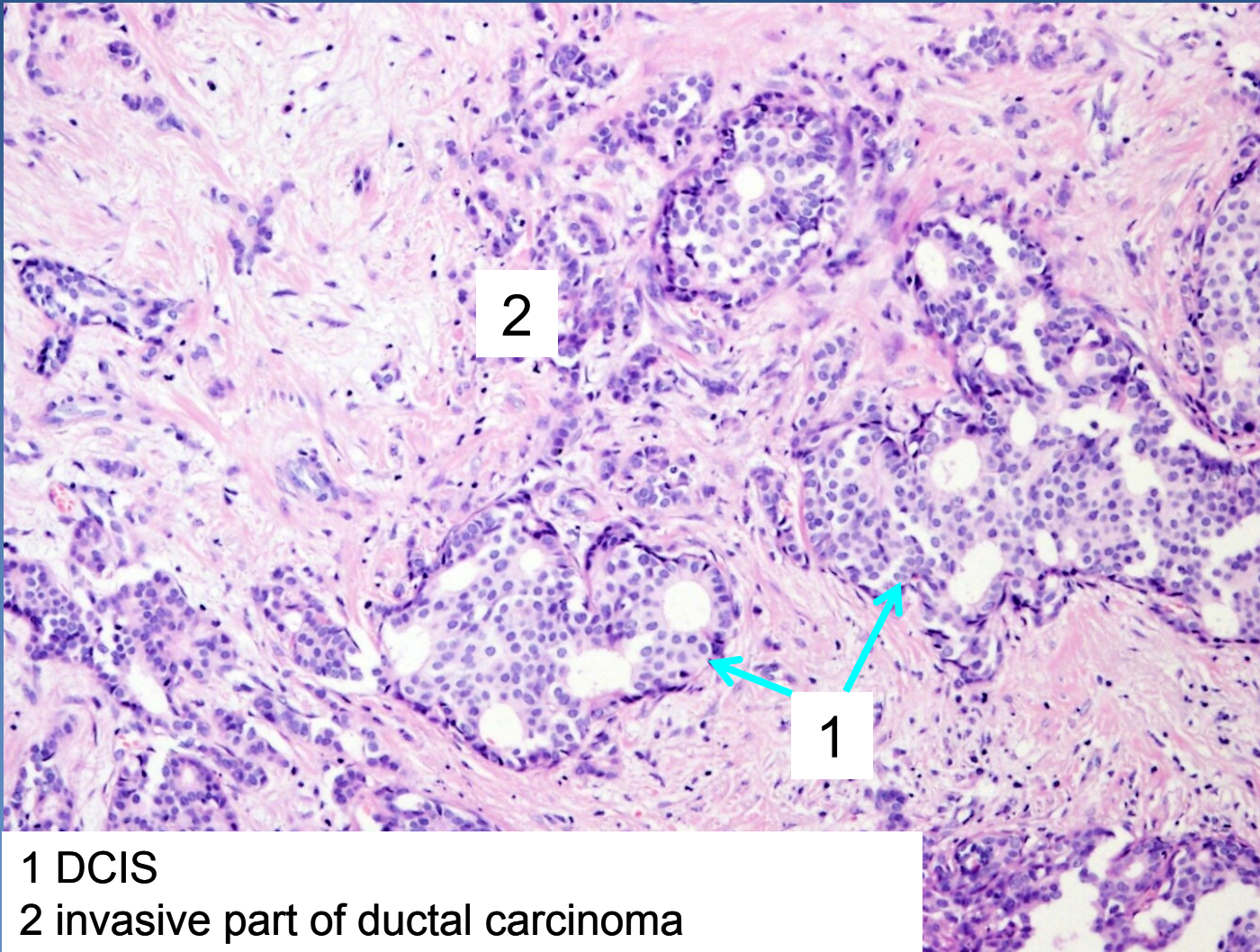
2

1



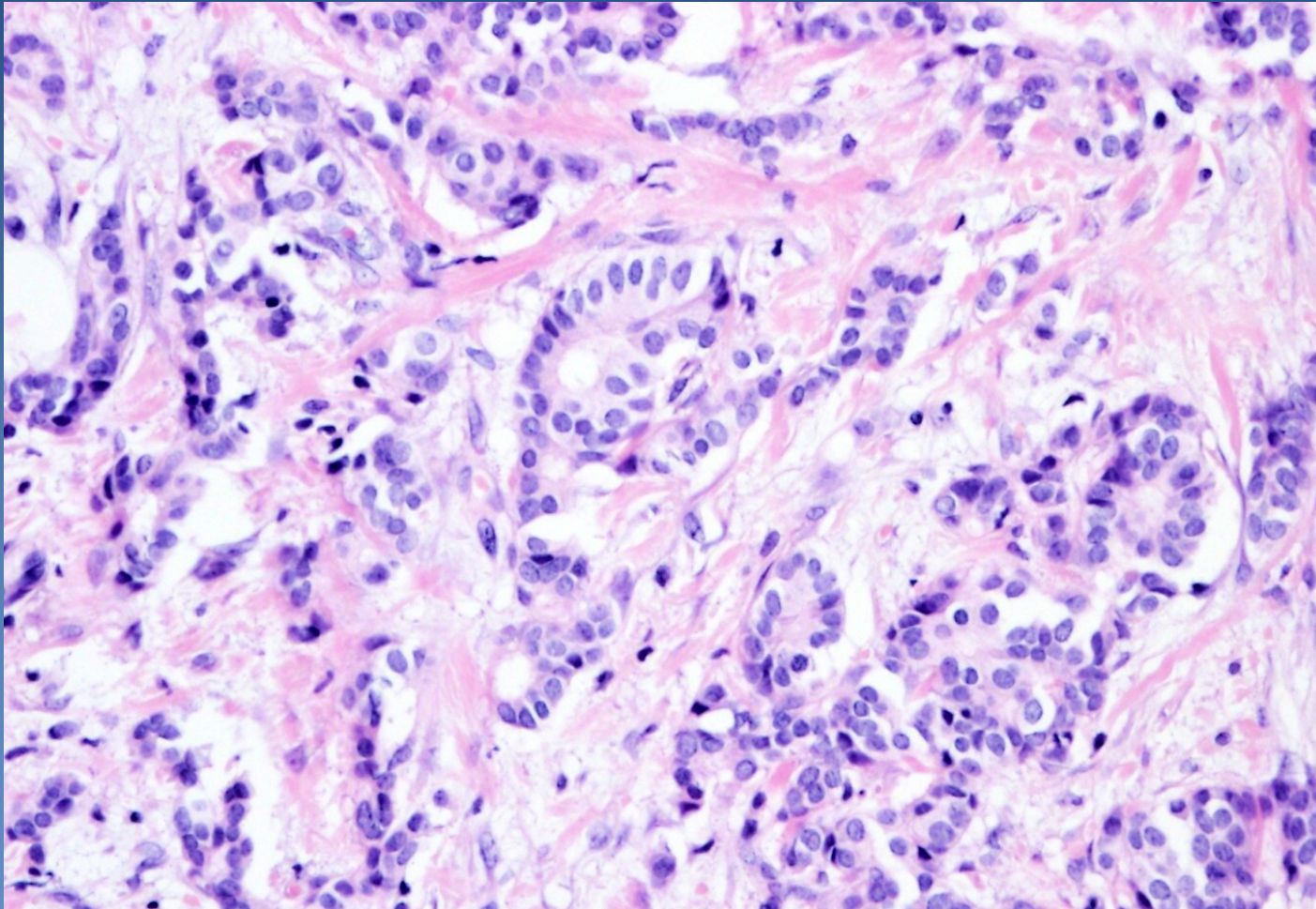
1 kohezivní nádorový infiltrát s ojedinělými tubuly
2 infiltrace tukové tkáně

Invasive ductal carcinoma



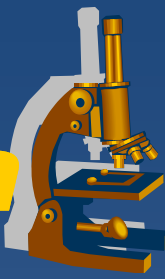1 DCIS
2 invasive part of ductal carcinoma

Invasive ductal carcinoma



Tumorous infiltrate with irregular small tubules

Invasive lobular carcinoma



× častěji roste multicentricky

× mikro:

⇒ *nádorové buňky ztratily soudržnost (E-cadherin-)*

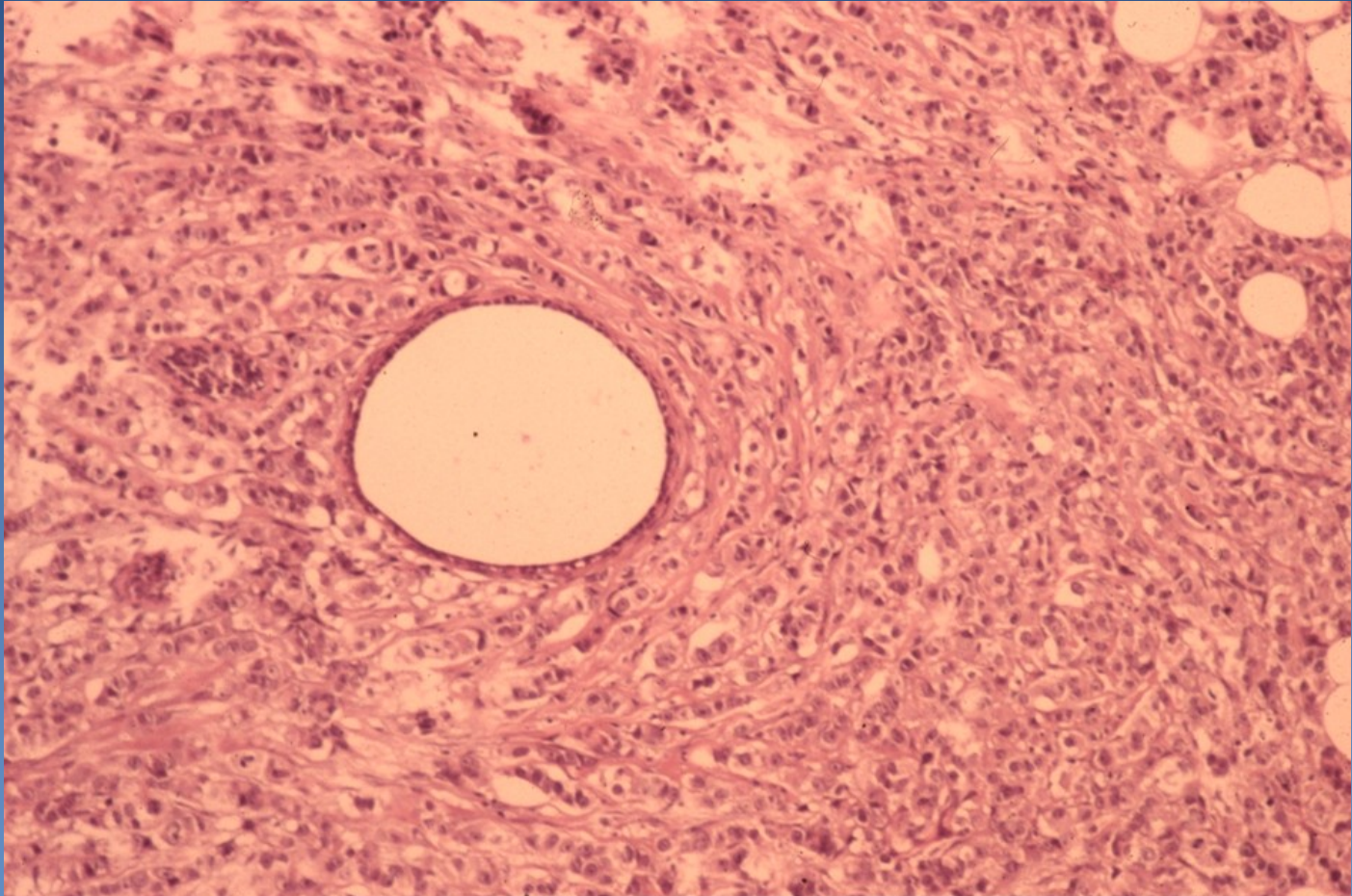
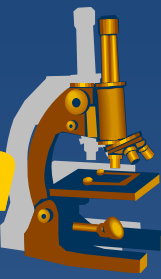
- řadí se do různě dlouhých pruhů – „husí pochod“, „indiánské péro“
- pruhy nádorových buněk jsou uspořádány naznačeně koncentricky kolem dilatovaného vývodu
- buňky mají jádra se světlejším chromatinem

⇒ *chybí myoepiteliální vrstva (SMA-)*

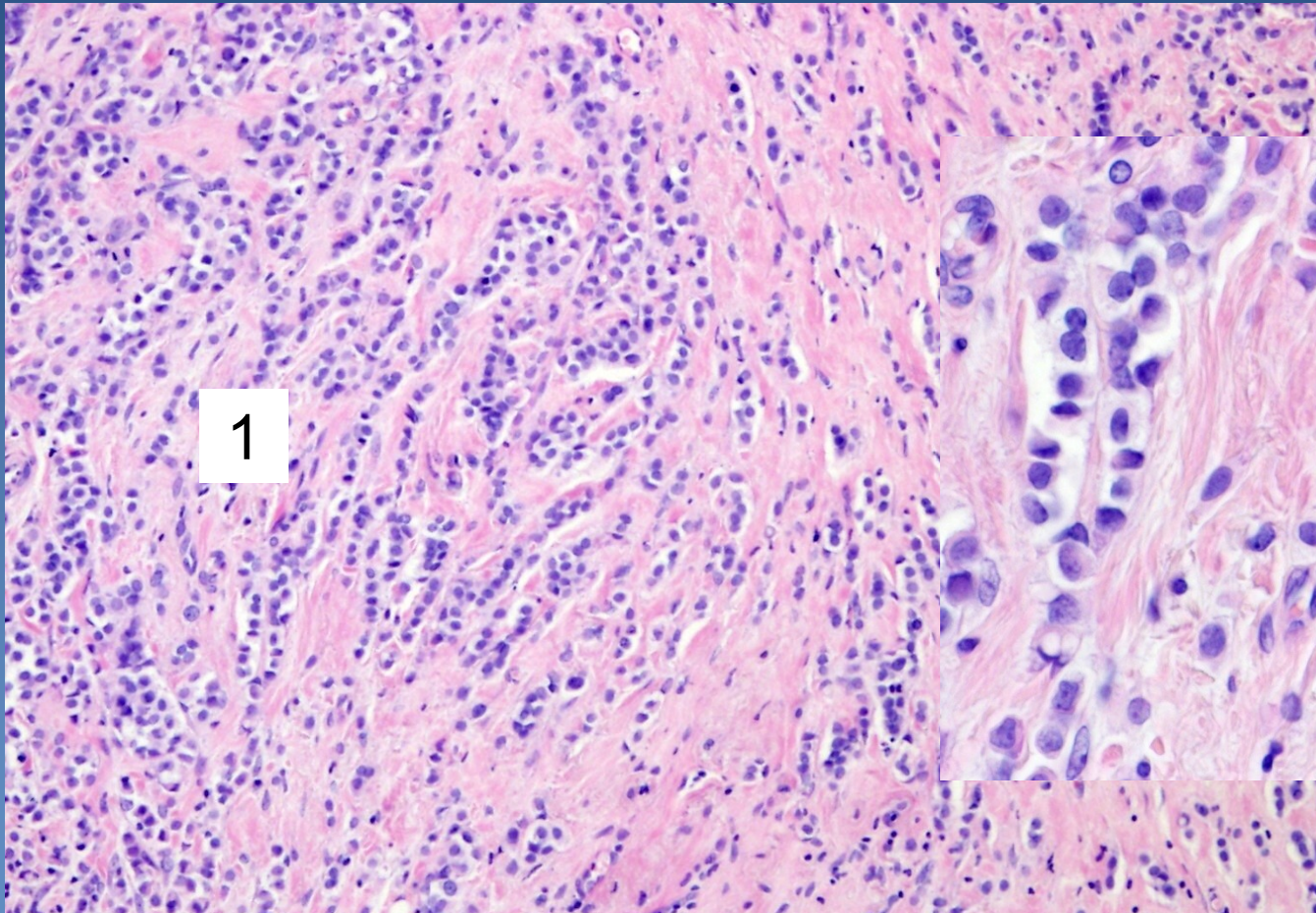
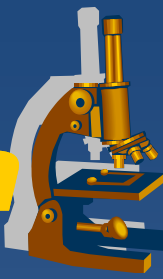⇒ *stroma denzní, vazivové*

⇒ *infiltrativní růst, často v blízkosti LCIS*

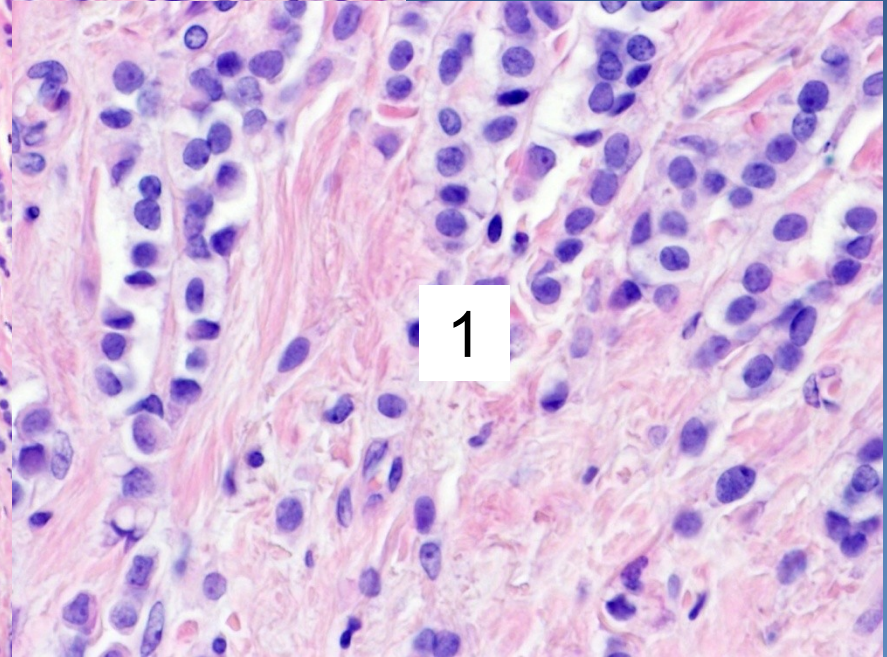
Invasive lobular carcinoma



Invasive lobular carcinoma



1



1

1 dyscohesive tumor cells in single file (Indian file)

Myoepithelial lesions



- ✘ myoepithelial cells proliferation, (sm. + luminal cells)
- ✘ uncommon
- ✘ classification:
 - ⇒ *Adenomyoepithelial hyperplasia*
 - ⇒ *Adenomyoepithelioma*
 - ⇒ *Myoepithelioma*
 - ⇒ *Myoepithelial carcinoma*

Mesenchymal tumors



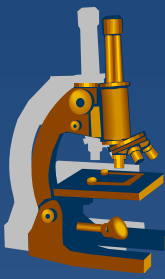
x rare in the breast

x i.e.:

⇒ *haemangiomas, leiomyoma, lipoma, schwannoma*

⇒ *angiosarcoma, leiomyosarcoma, liposarcoma*

Fibroepithelial (mixed) tumors



- x** very common

- x** **Fibroadenoma (FA)**

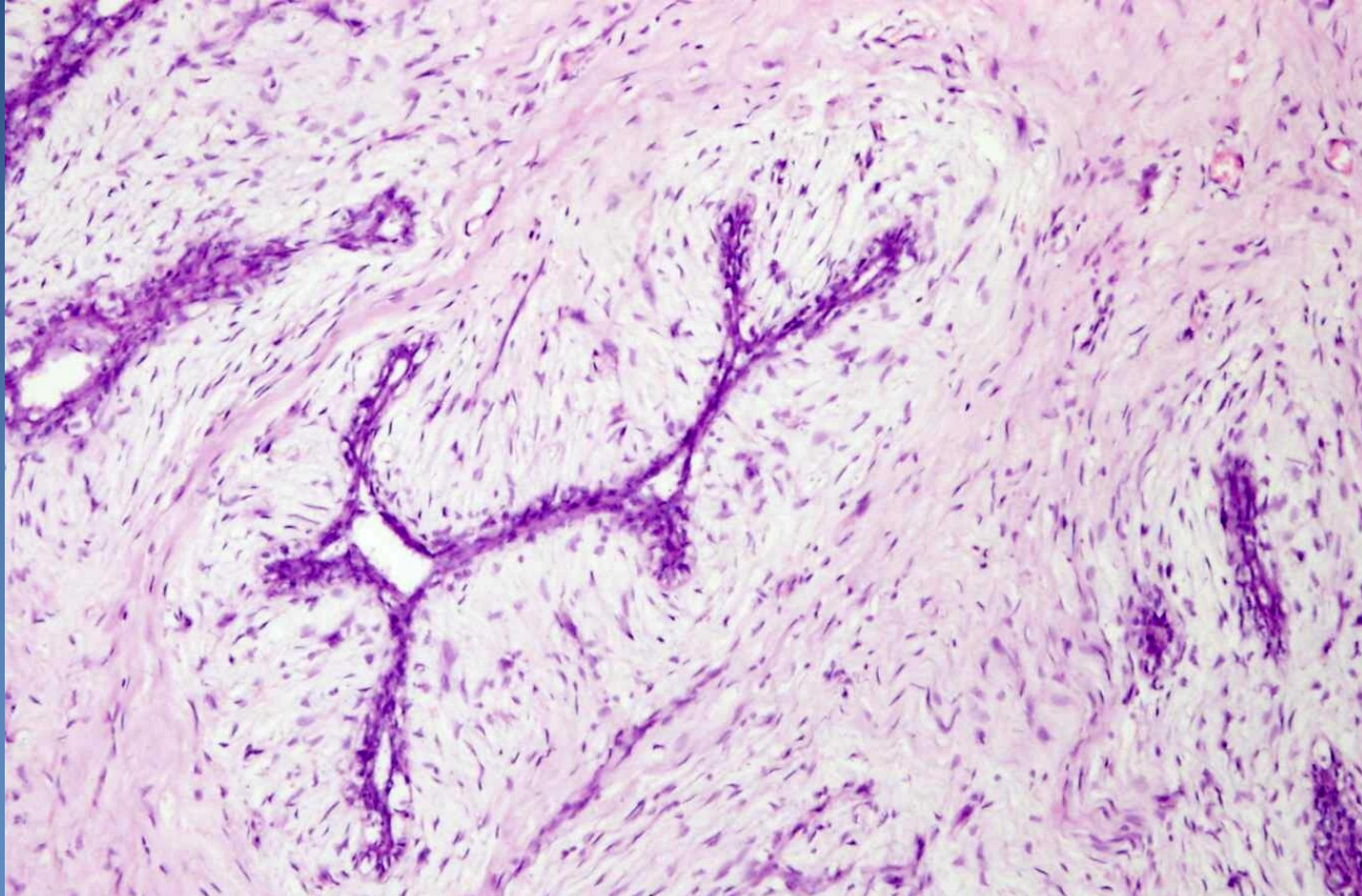
 - ⇒ *most common breast tumor in young females*

 - ⇒ *benign, circumscribed, mobile, rubbery*

 - ⇒ *proliferating ducts + increased amount of stroma (edematous or hyalinised)*

 - ⇒ *pericanalicular, intracanalicular growth*

Fibroadenoma



Slit-like newly formed ducts compressed by edematous stroma

Fibroepithelial (mixed) tumors



x Phyllodes tumor

⇒ *rare (<1% of all breast tumors)*

⇒ *gross – leaflike structure and cysts (cystosarcoma phyllodes)*

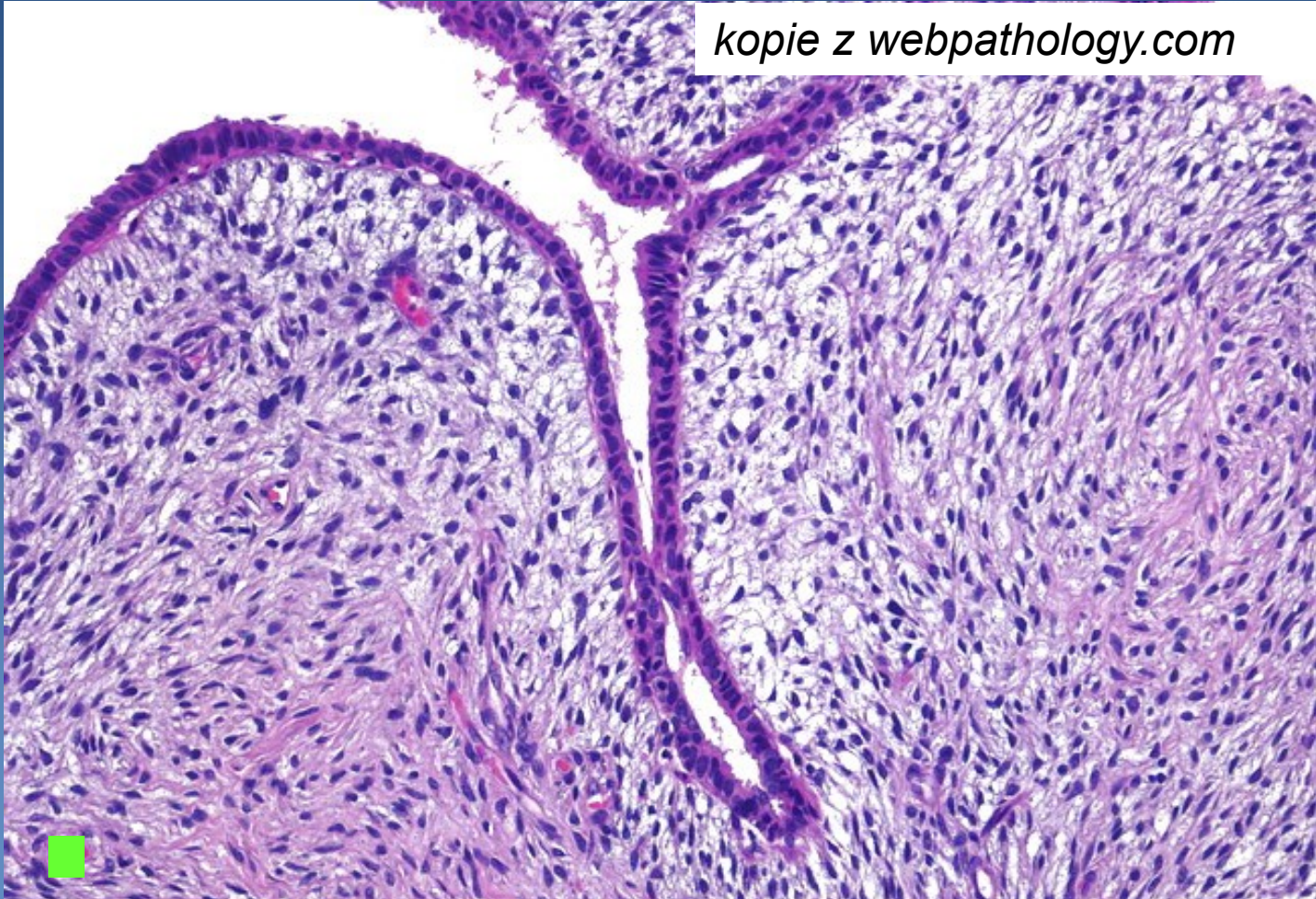
⇒ *micro similar to FA, increased stromal cellularity*

- *stromal component benign / with atypias / malignant (sarcoma)*
- *biologic behaviour:*
 - *benign*
 - *broderline*
 - *malignant*

Phyllodes tumor



kopie z webpathology.com



Hypercellular stroma compressing ducts

Male breast pathology



x gynecomastia

⇒ *most common*

- up to 30% adult males, commonly bilateral

⇒ *enlarged subareolar gland*

⇒ *hyperthyroidism, liver cirrhosis, CHRI, chronic respiratory failura, hypogonadism, hormone therapy.*

x carcinoma

⇒ *rare, hereditary risk possible (BRCA2)*

⇒ *worse general prognosis (usually late dg.)*