

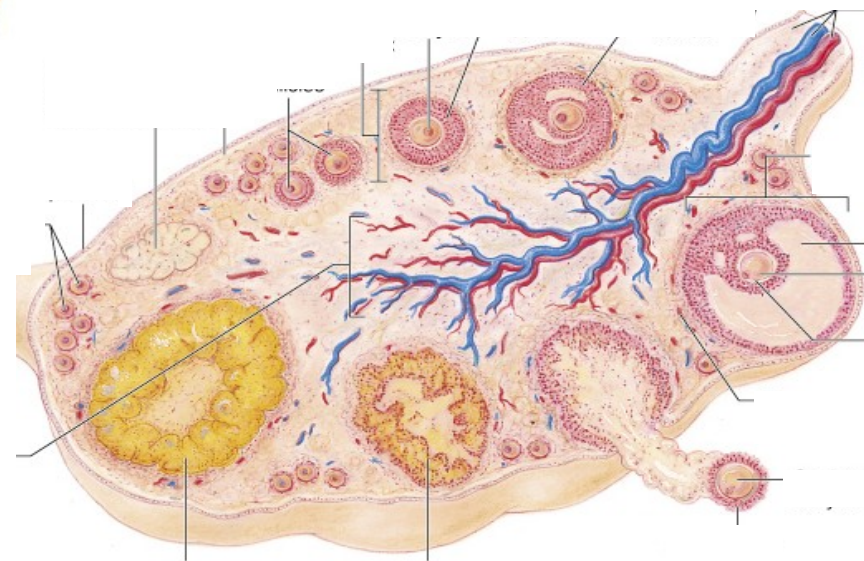
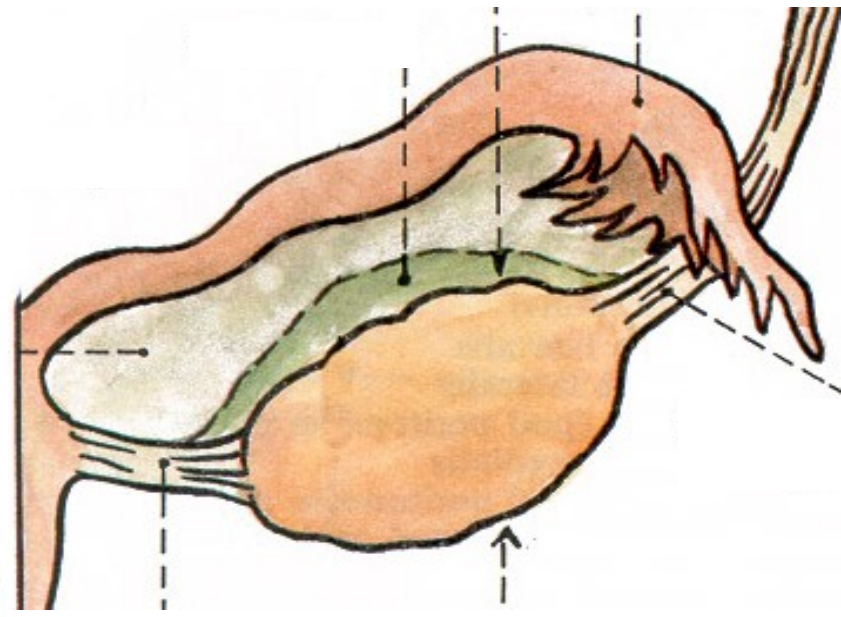
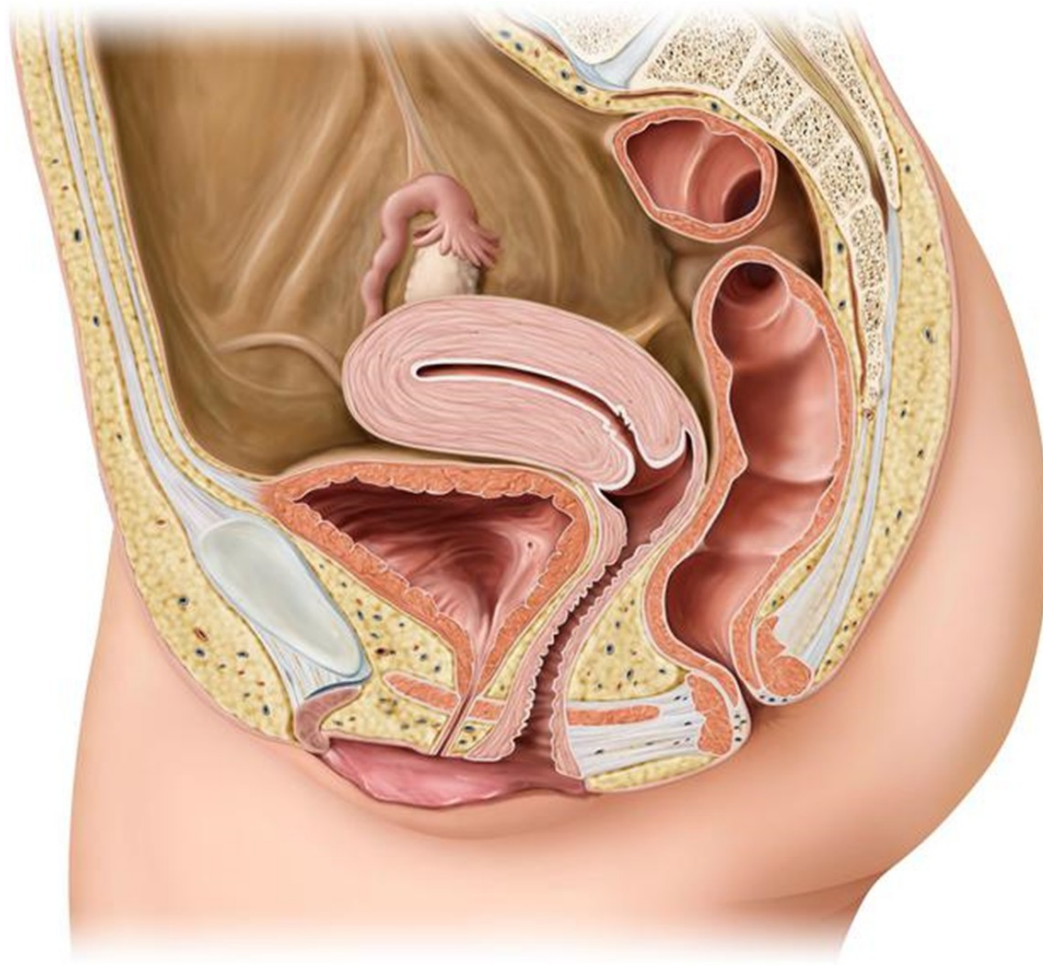


# ŽENSKÝ POHLAVNÍ SYSTÉM

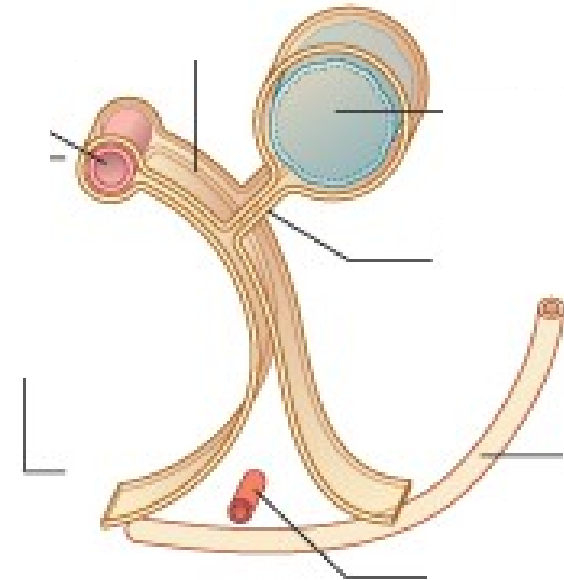
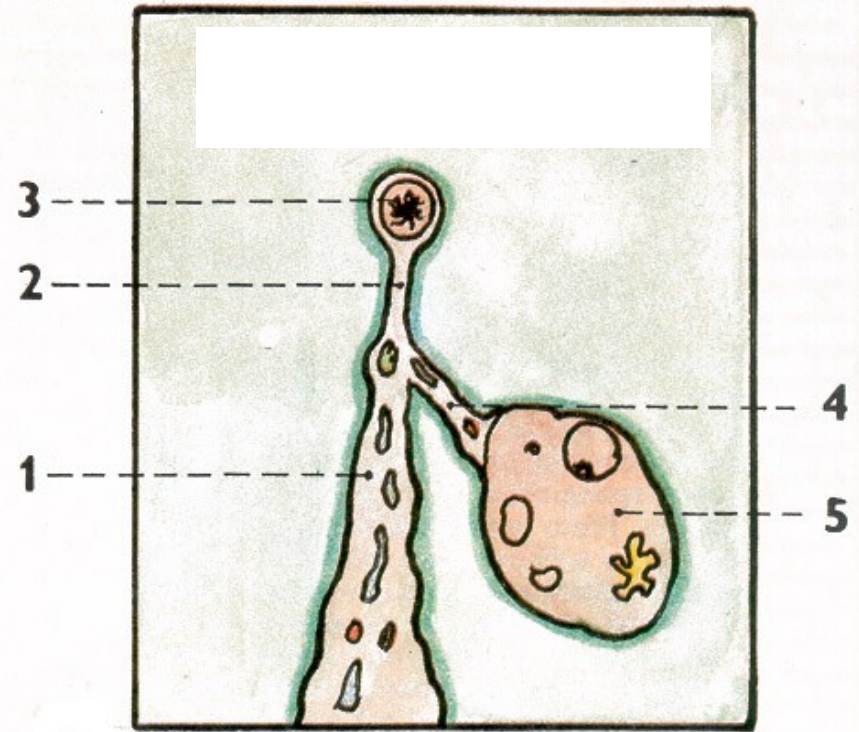
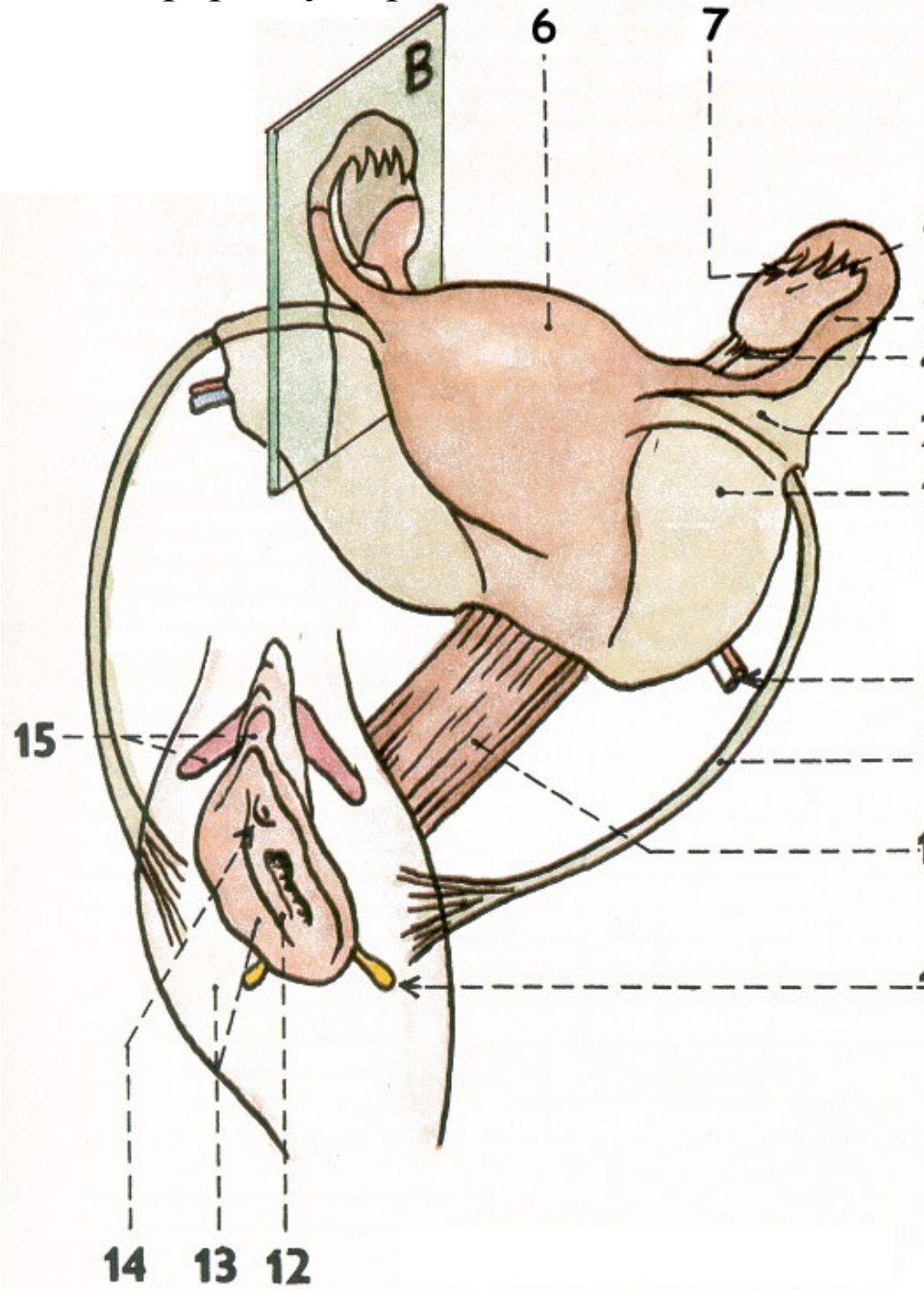


101. Vaječník, zevní popis, vaskularizace, syntopie



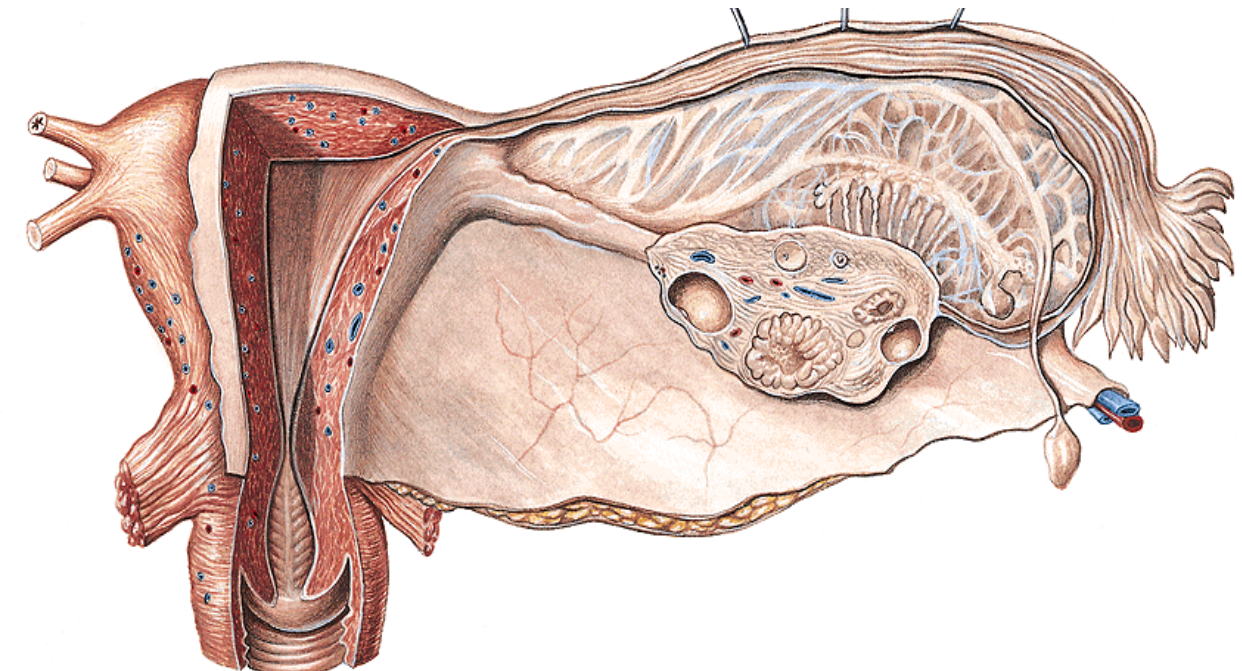
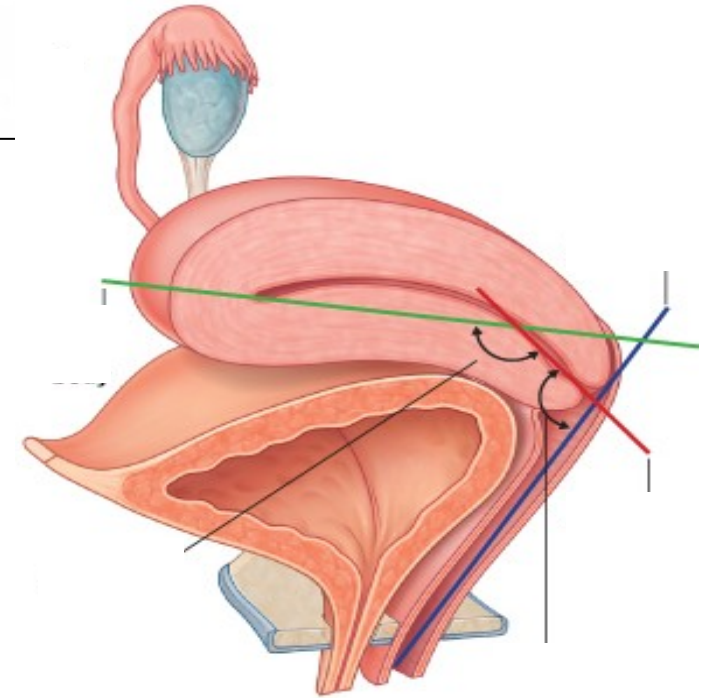
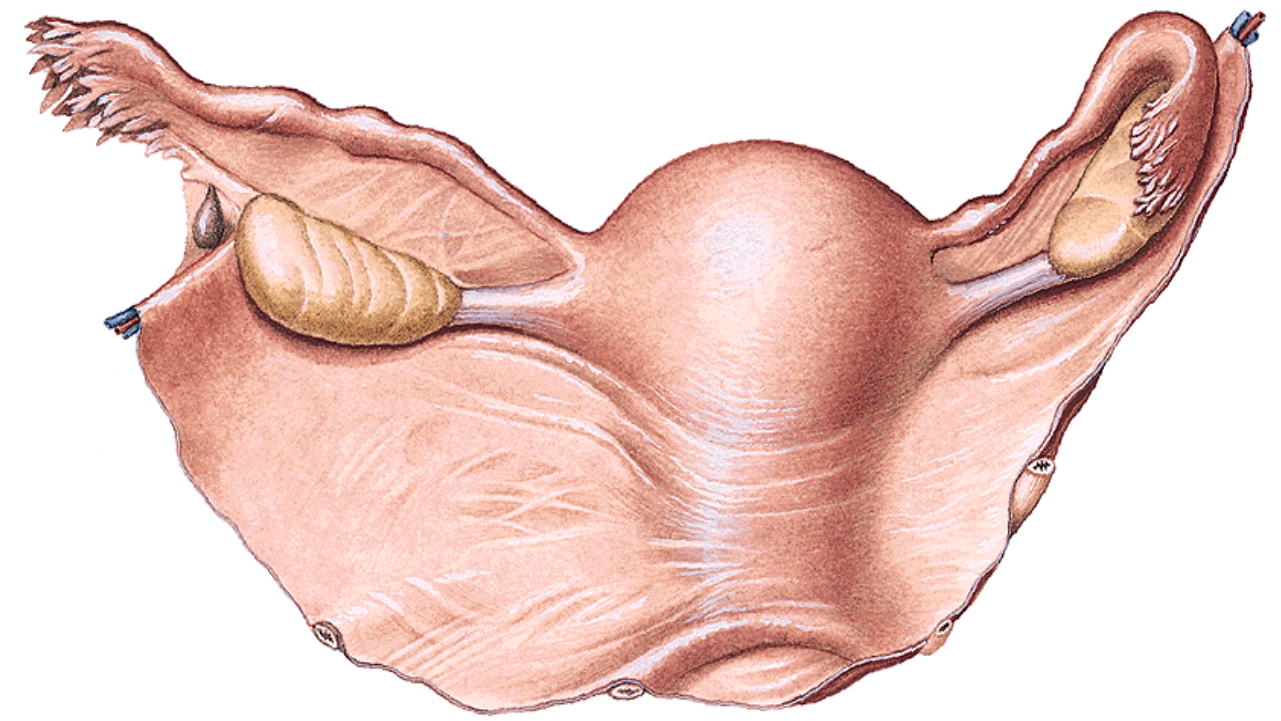
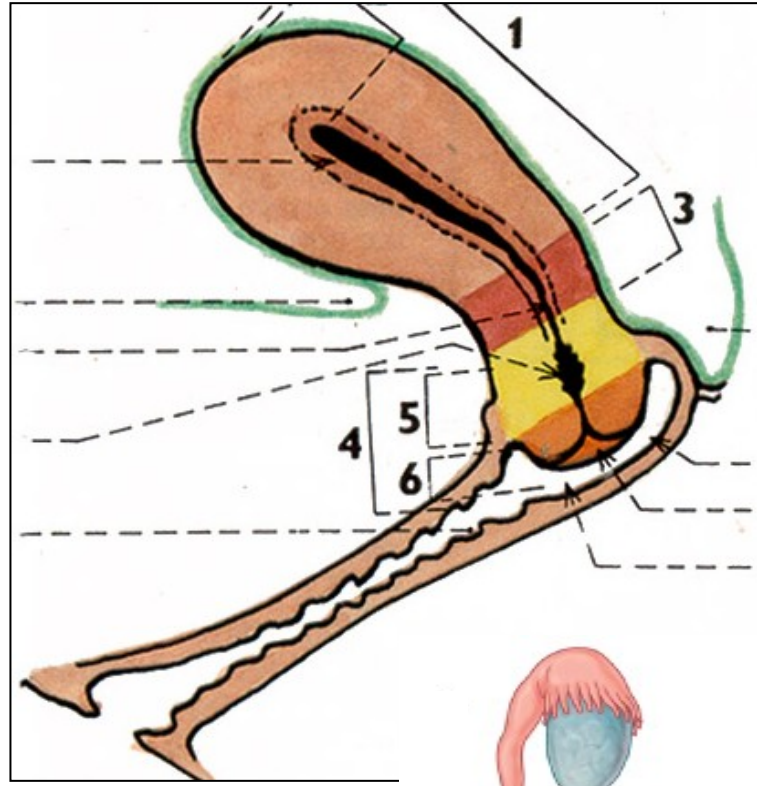


102. Vejcovod, zevní popis, syntopie



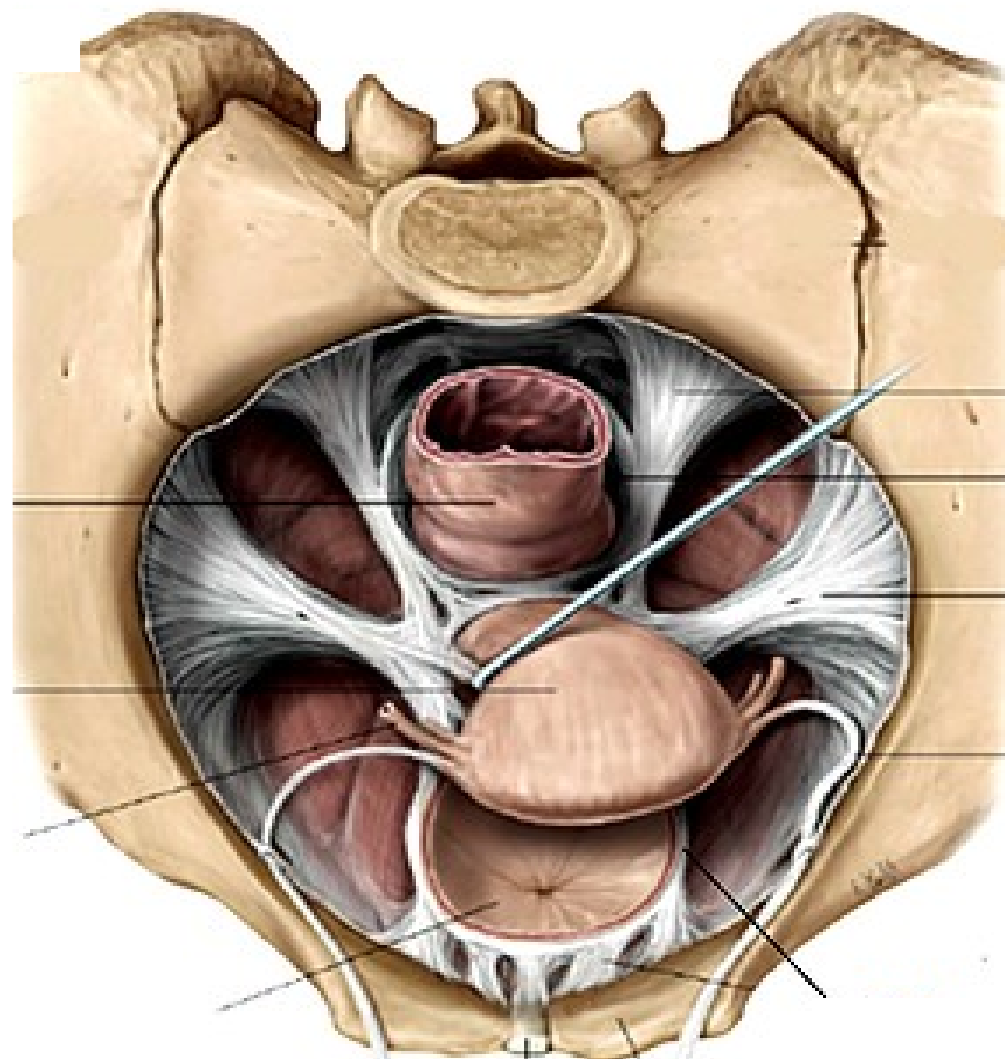
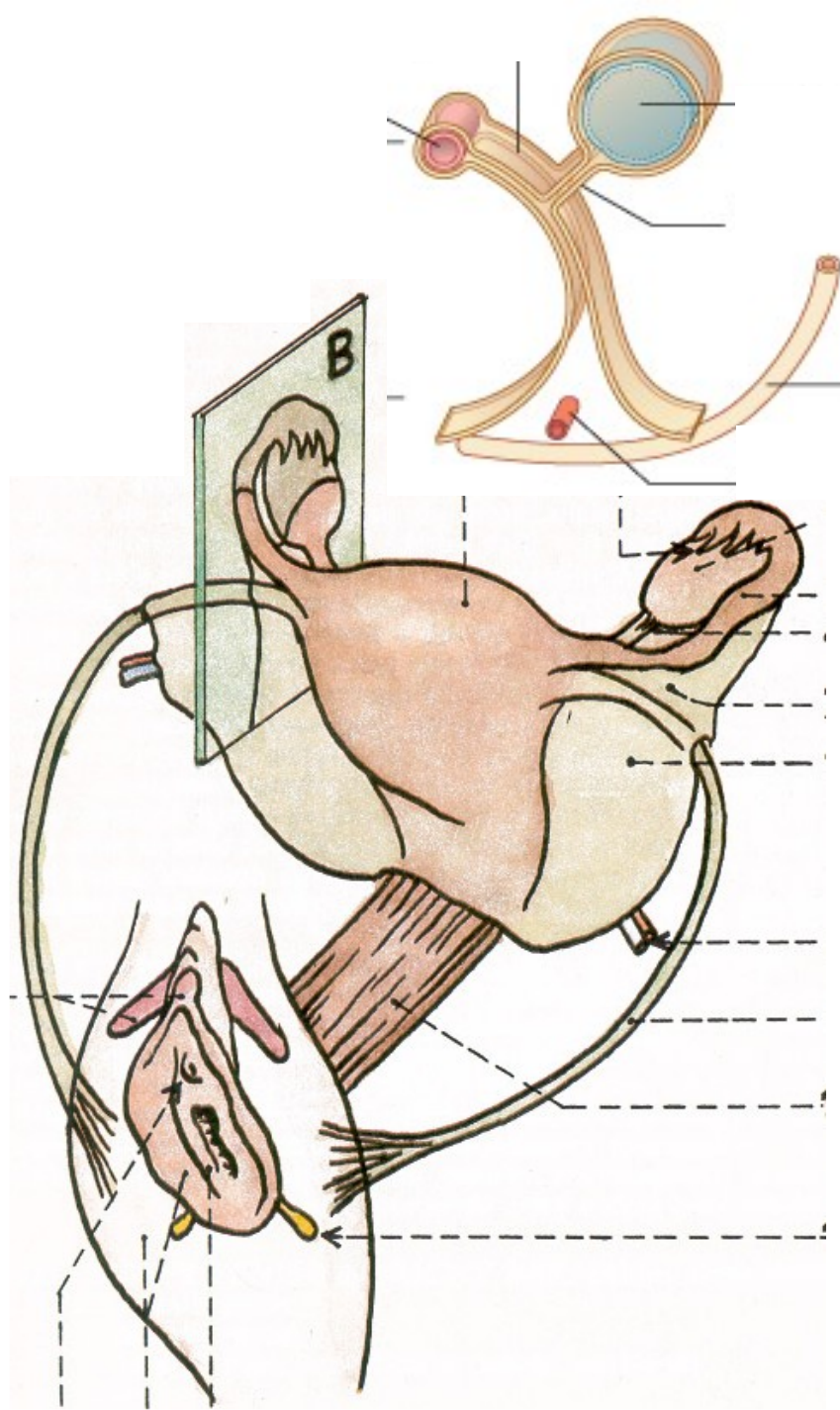


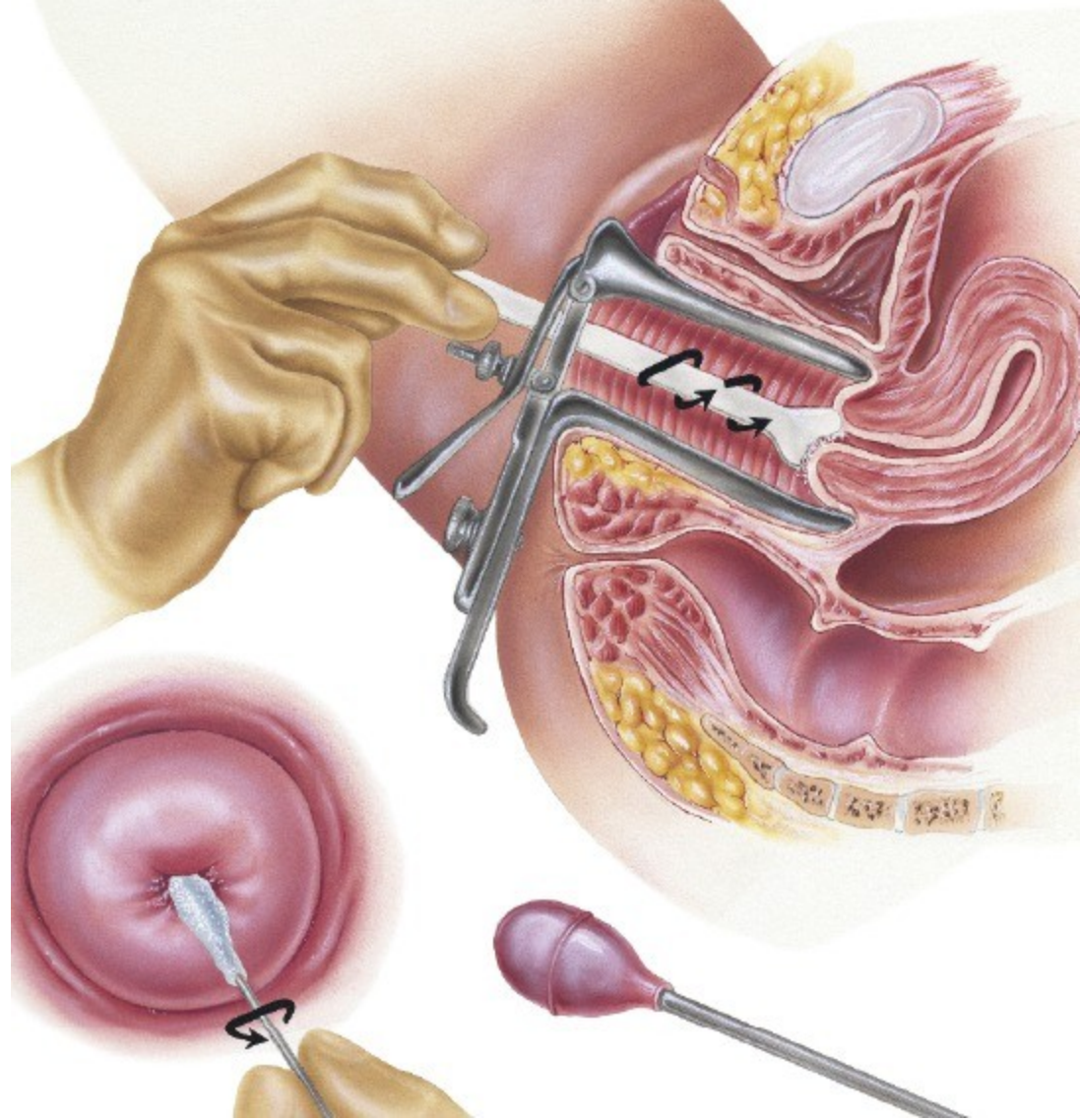
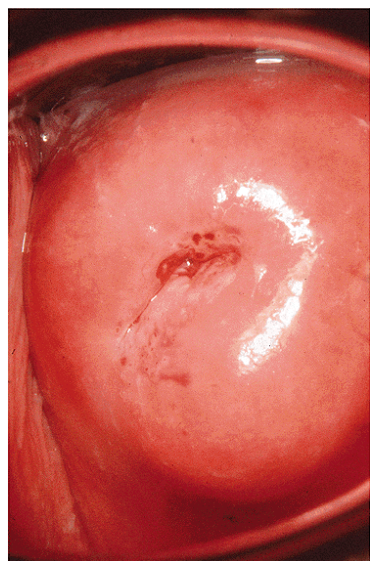
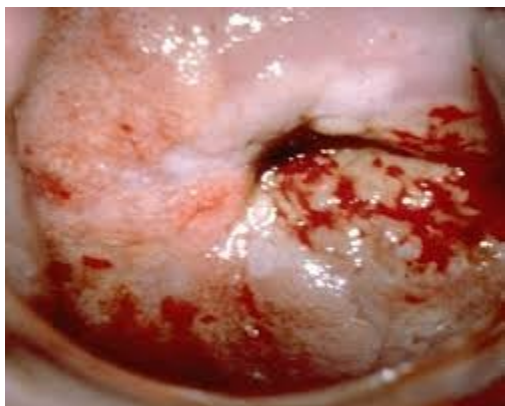
103. Děloha, zevní popis, vaskularizace, syntopie





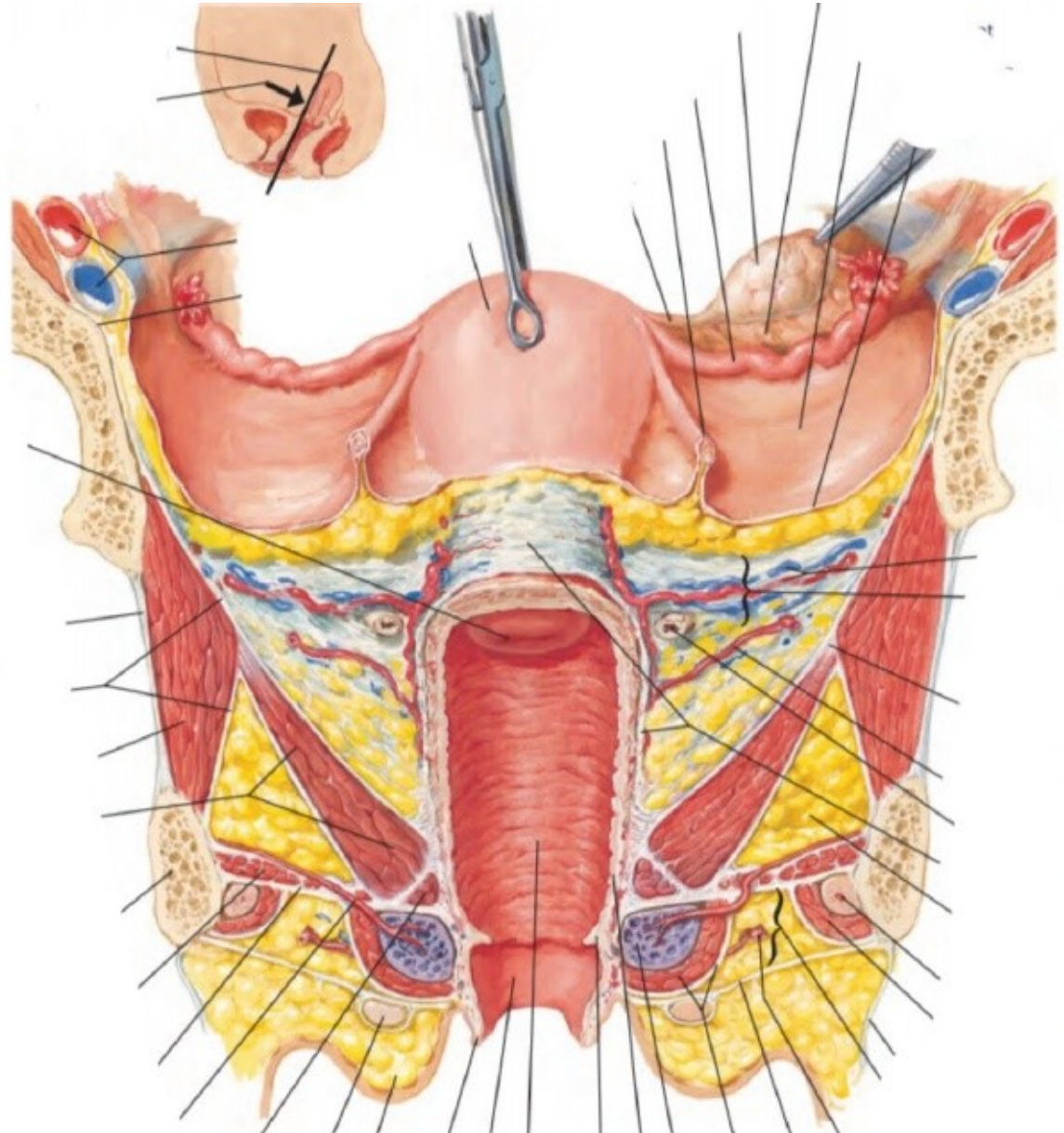
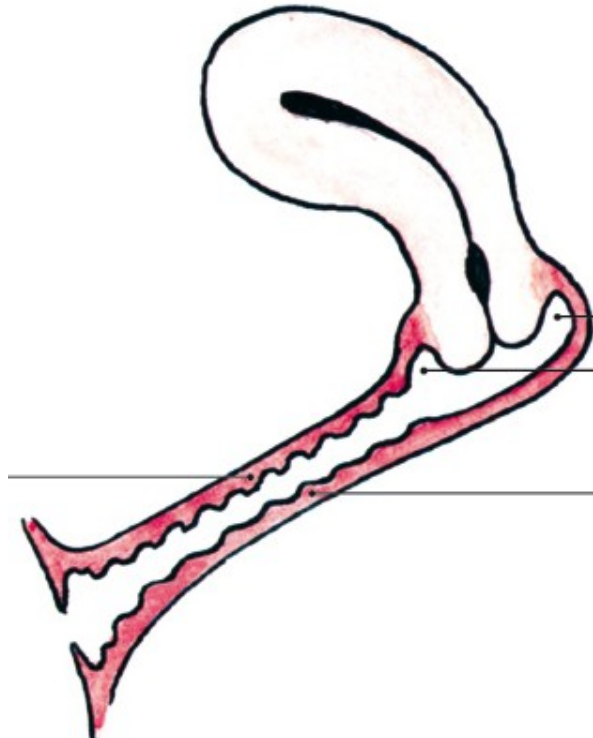
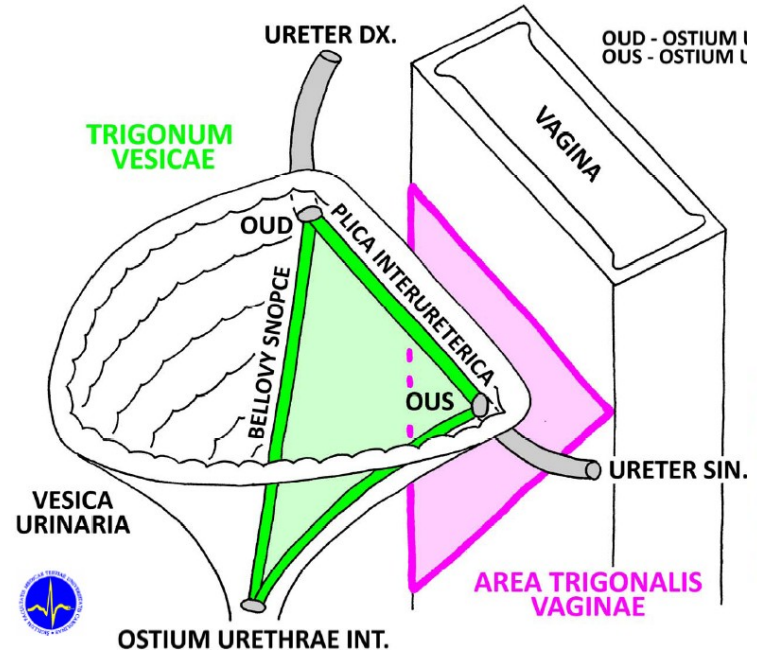
104. Děloha, stavba, závěsný aparát

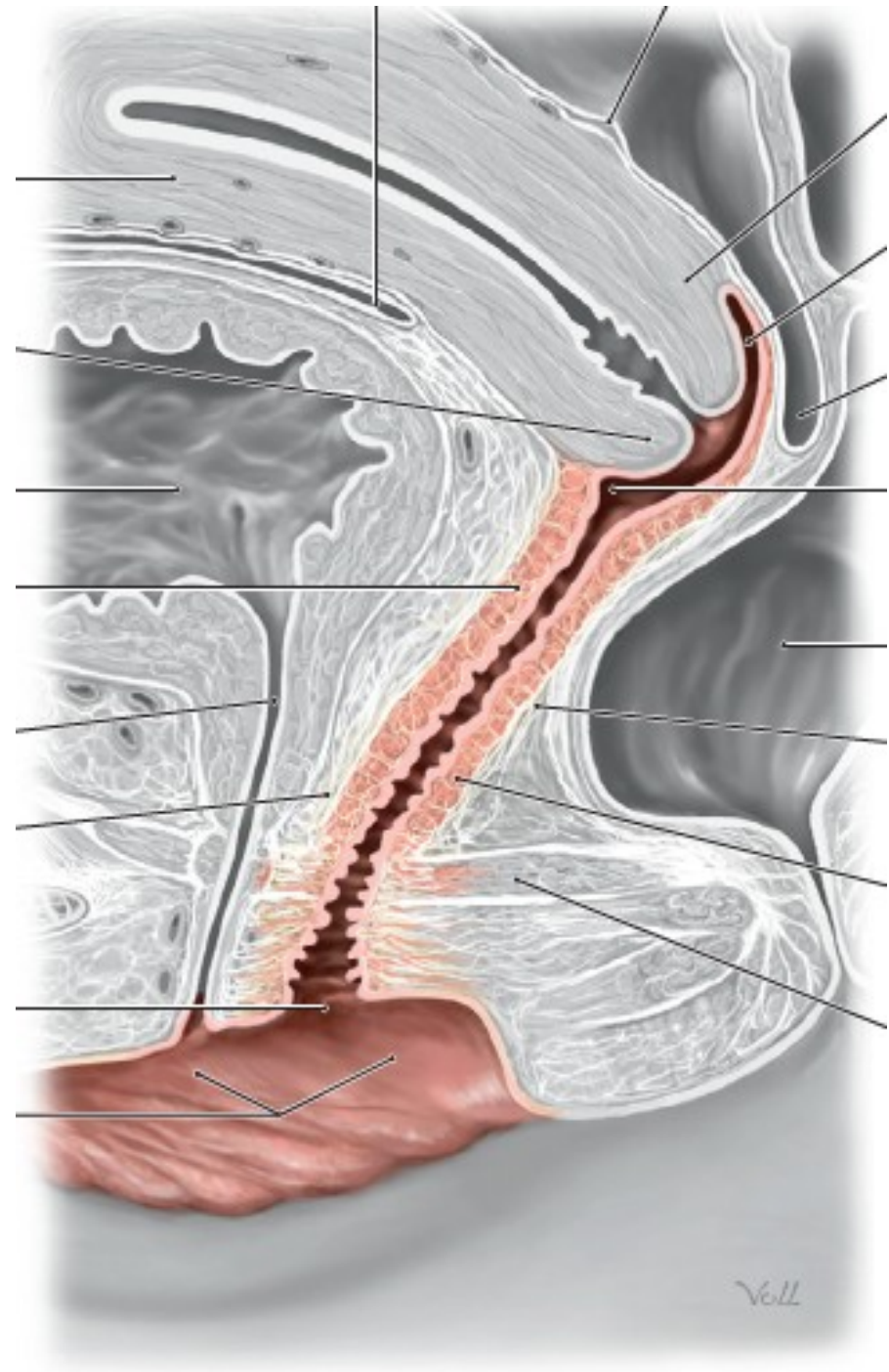






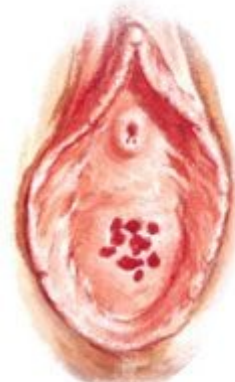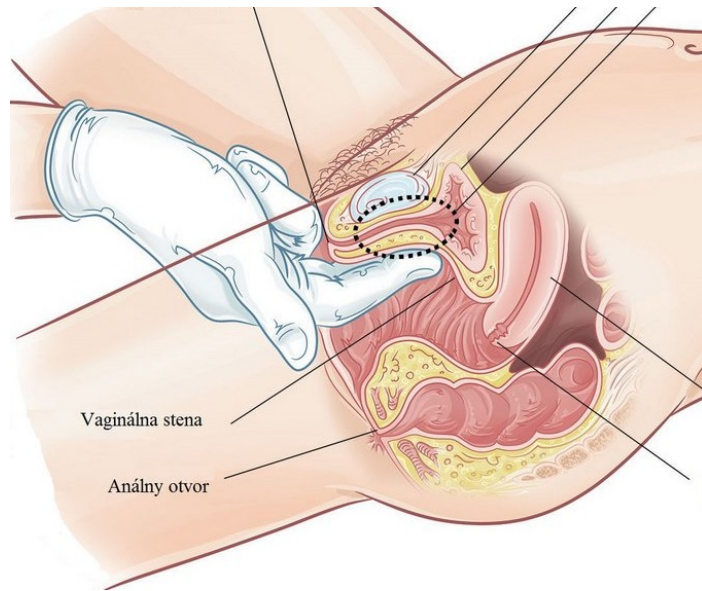
# 105. Pochva



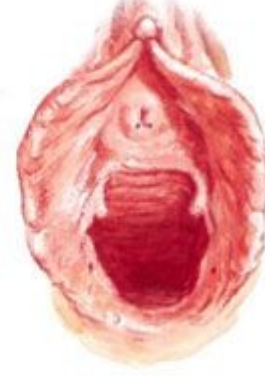

Voll

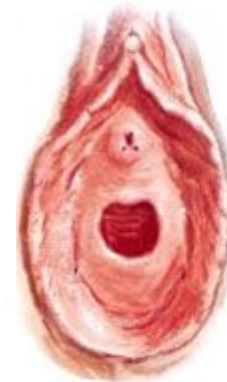



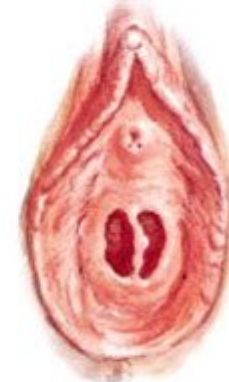Hymen cribriformis



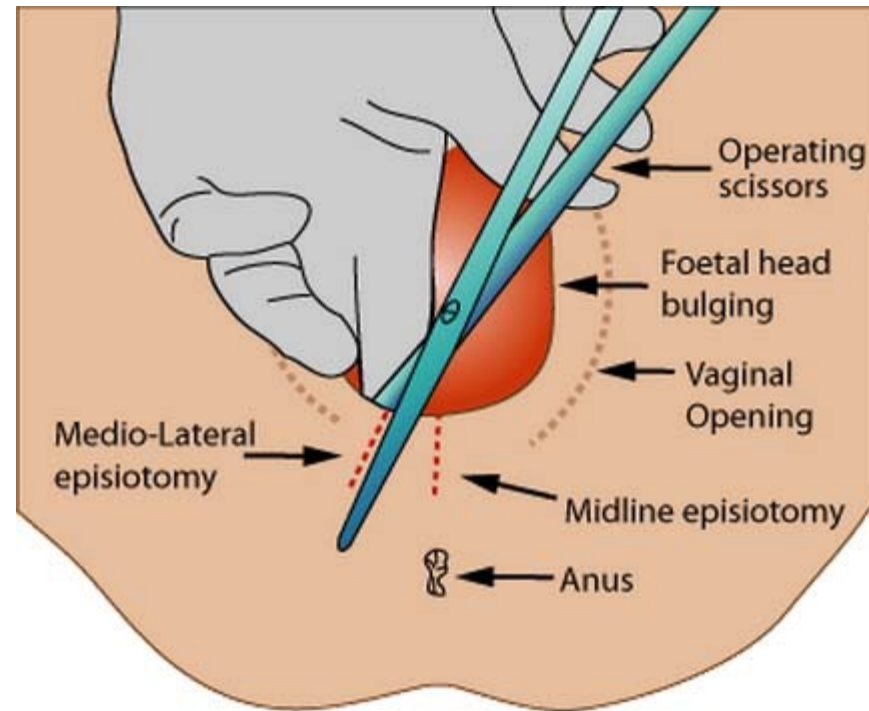
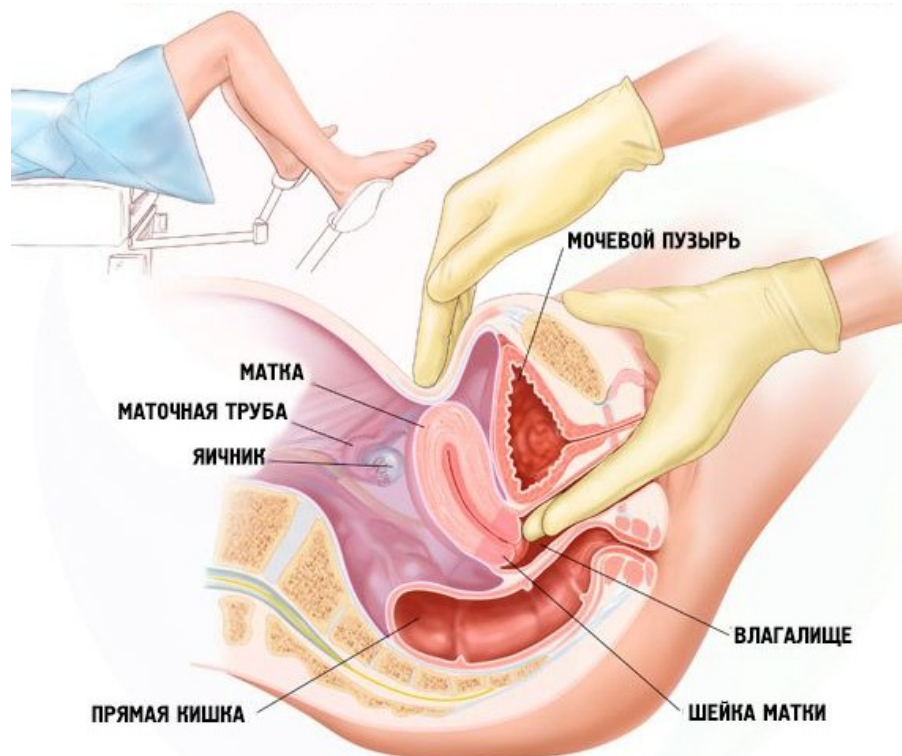
Ostium vaginae (porus introitus)



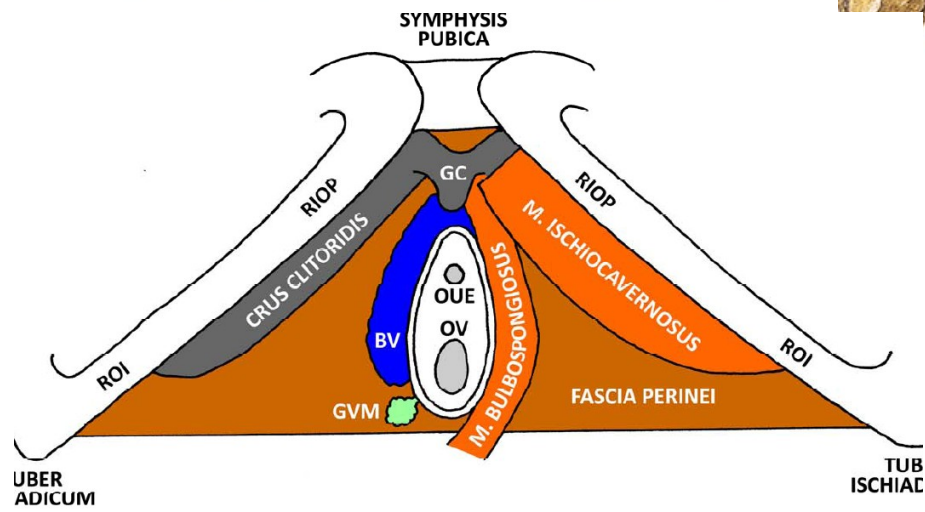
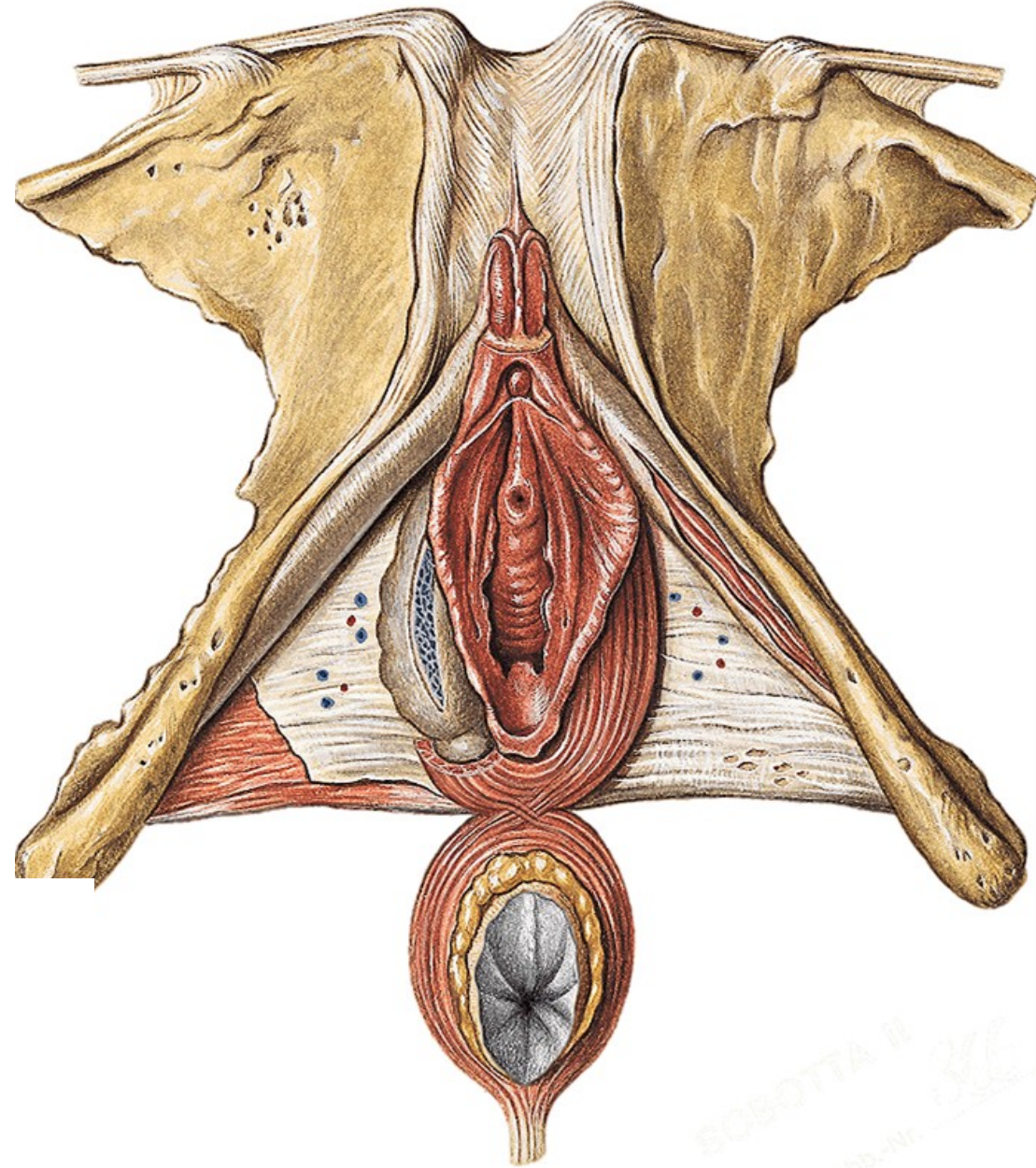
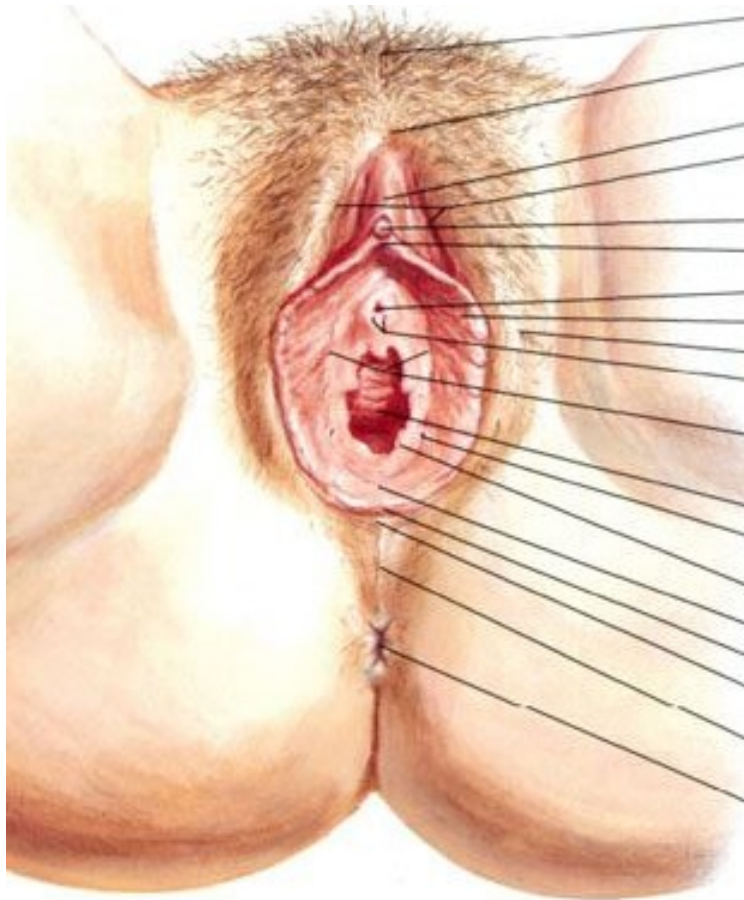
Hymen anularis



Hymen septus





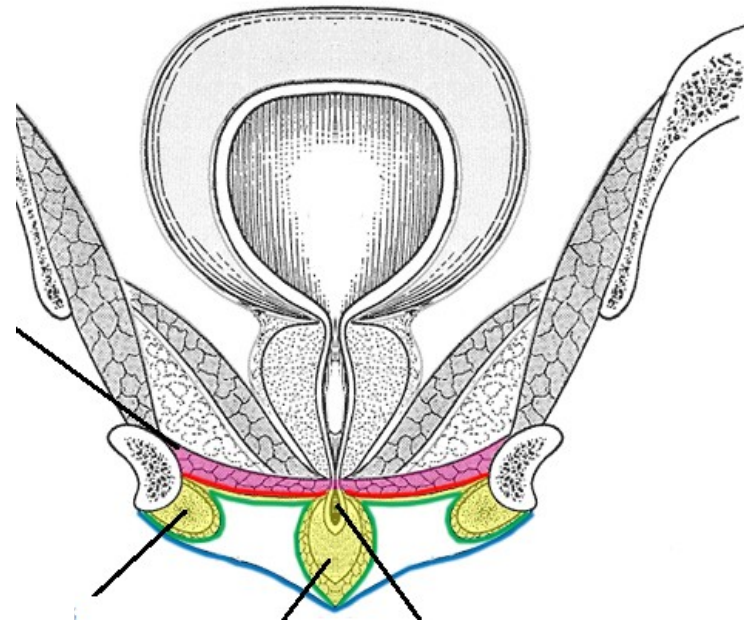
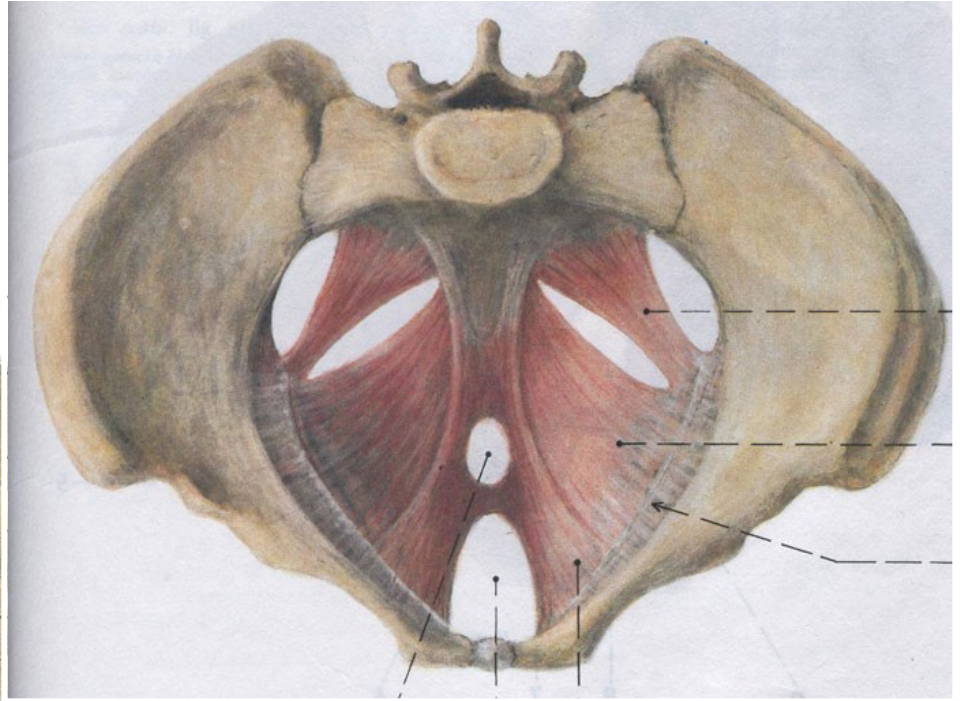
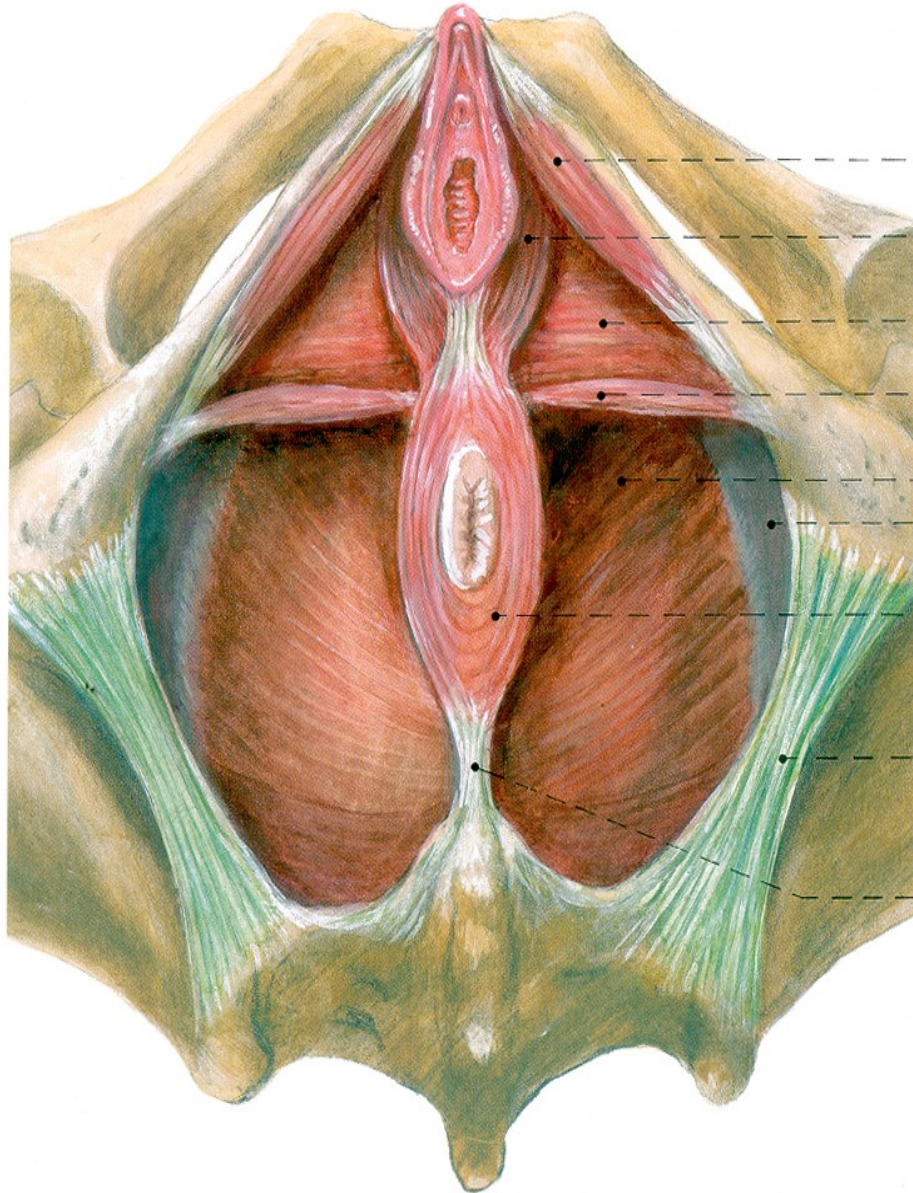


107. Zevní rodidla



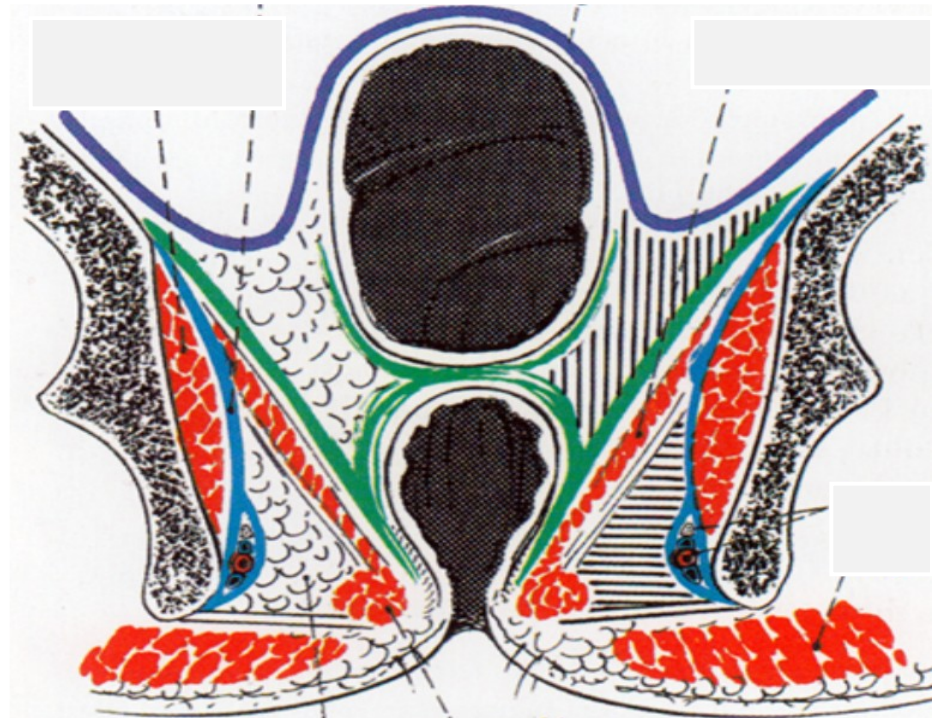
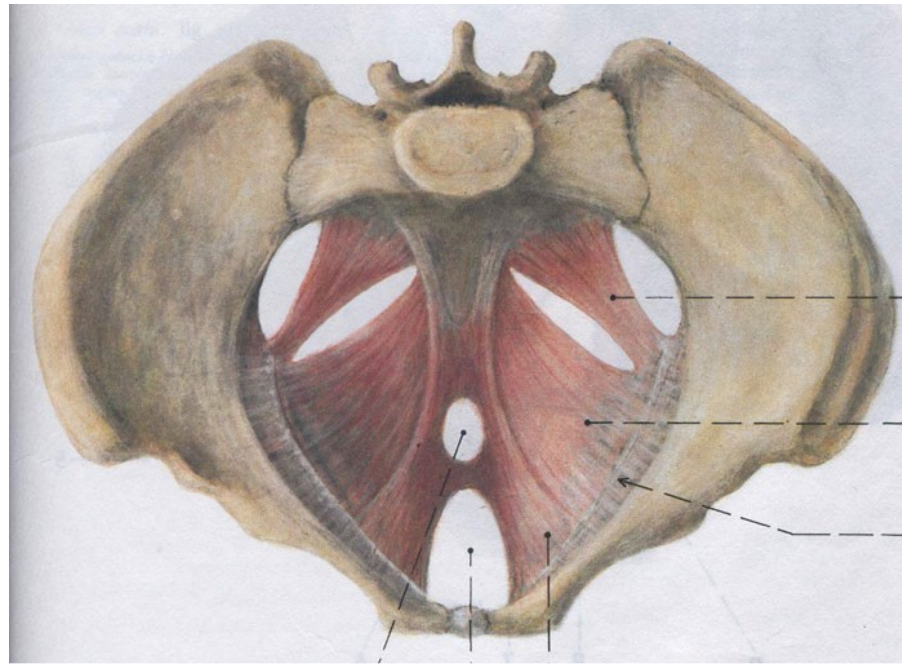
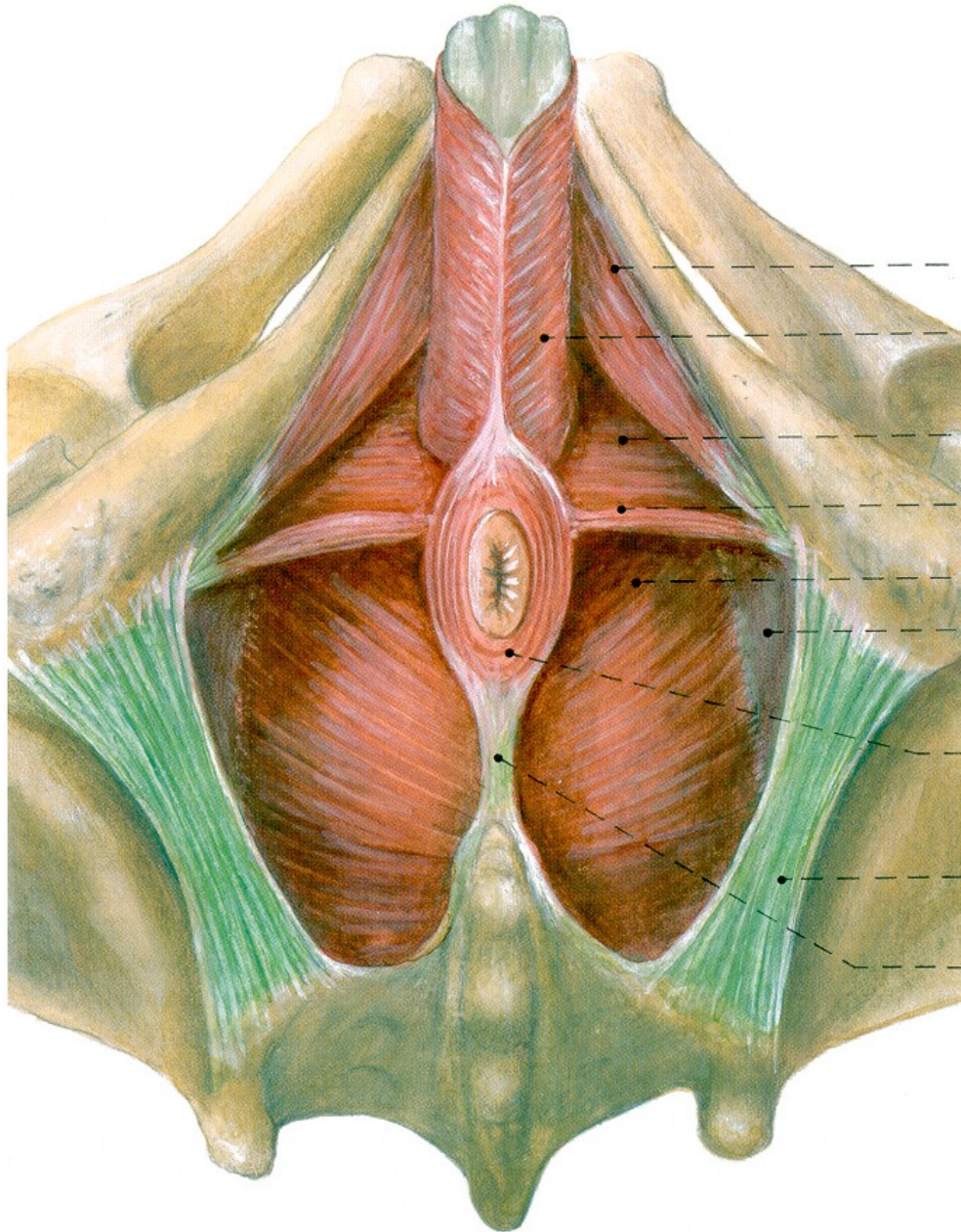
109. Diaphragma urogenitale femininum, svaly zevních pohlavních orgánů ženy

110. Diaphragma pelvis

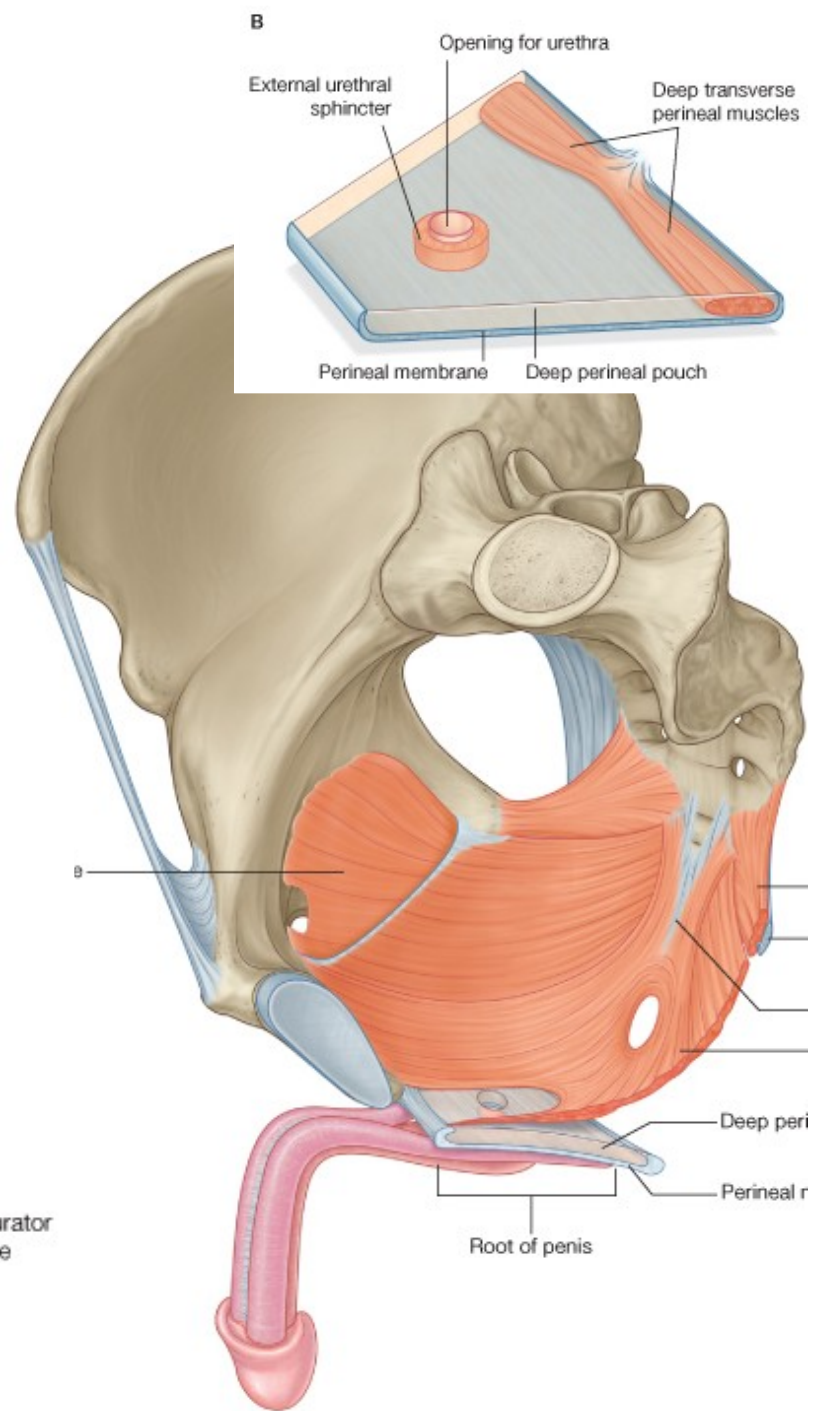
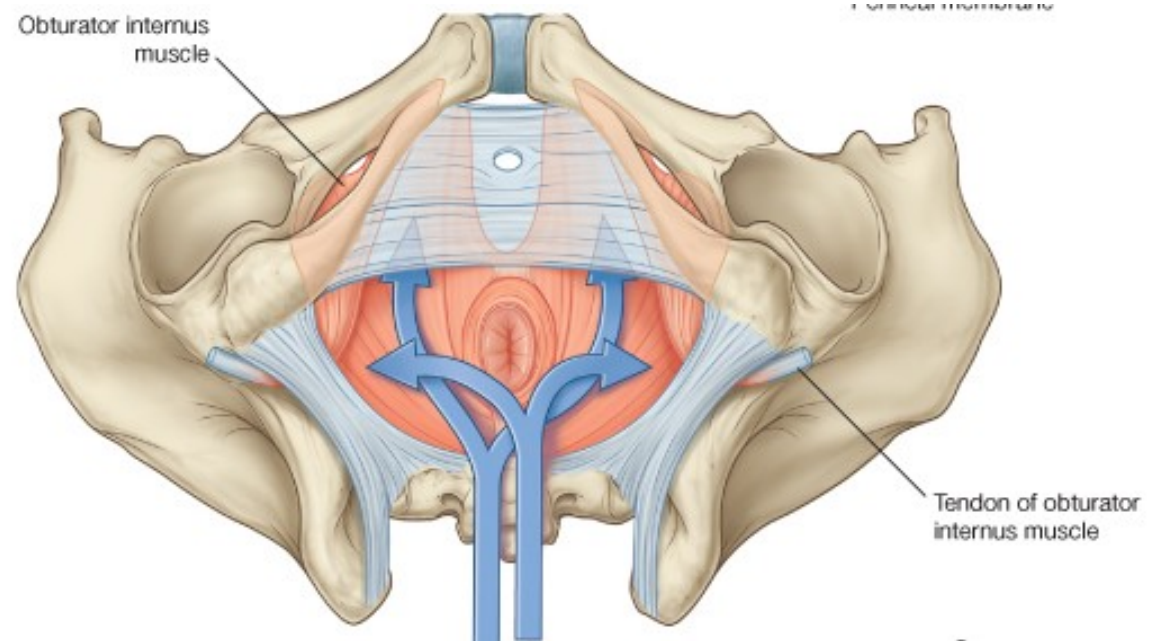
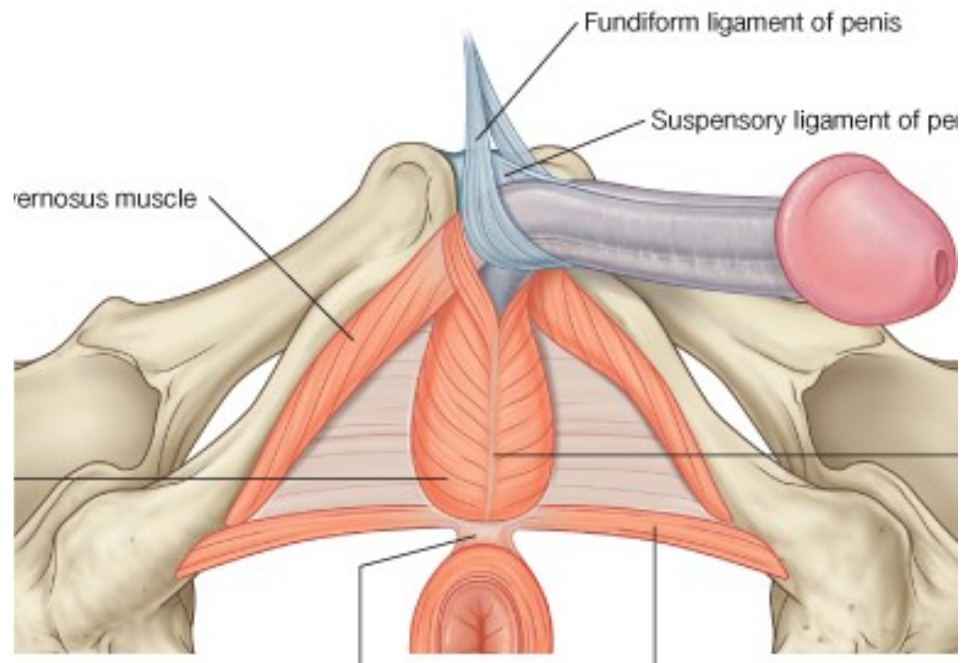


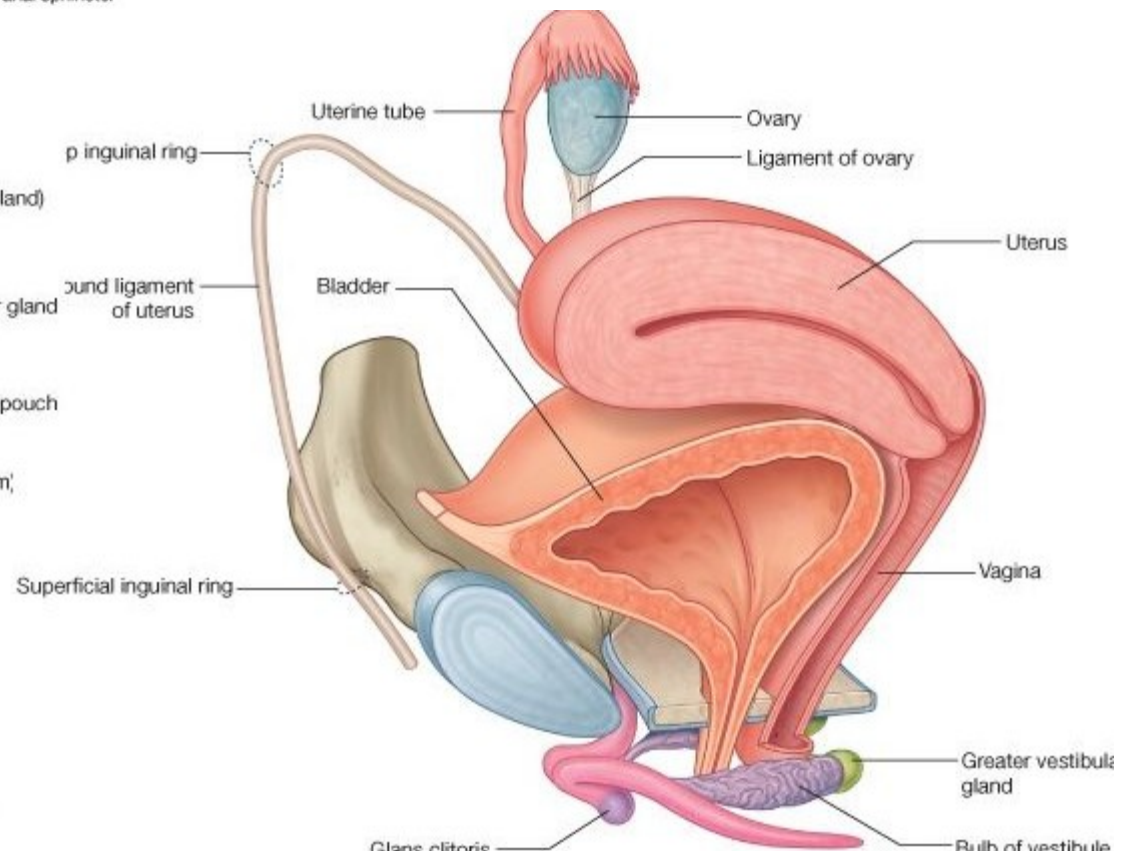
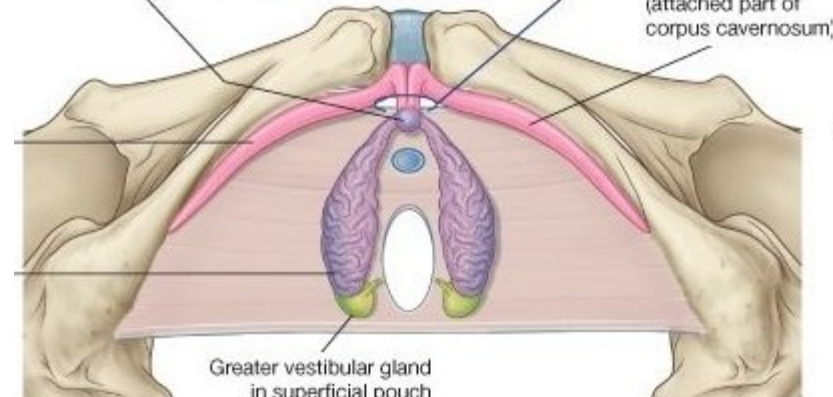
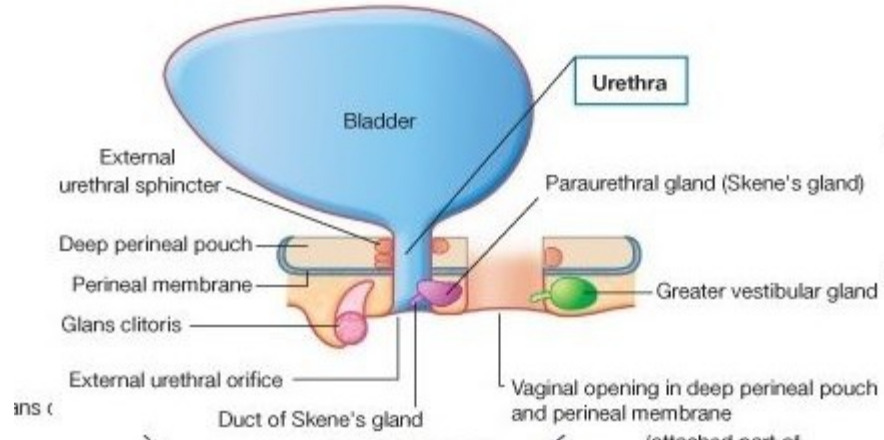
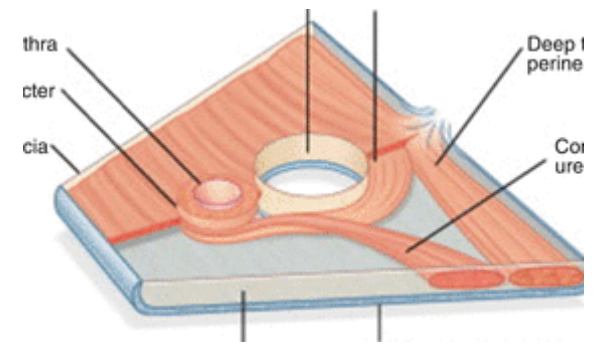
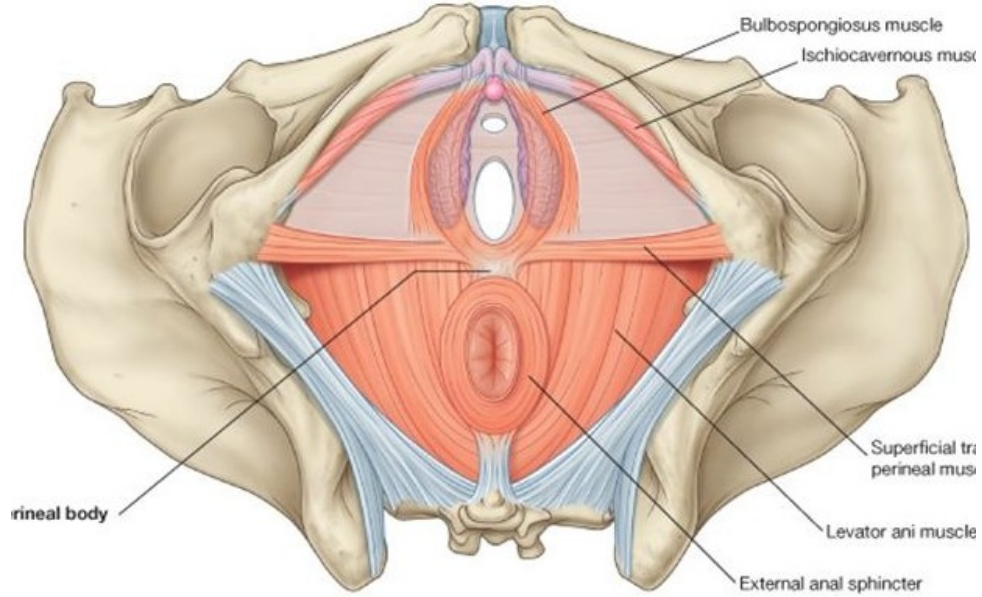


108. Diaphragma urogenitale masculinum, svaly zevních pohlavních orgánů muže

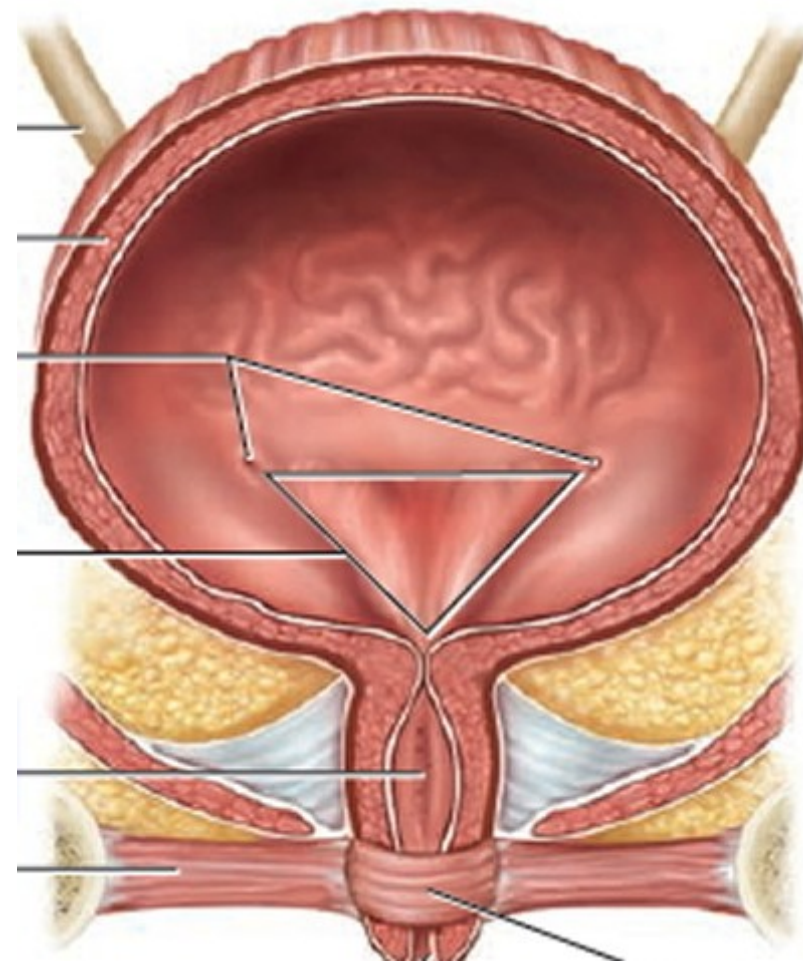
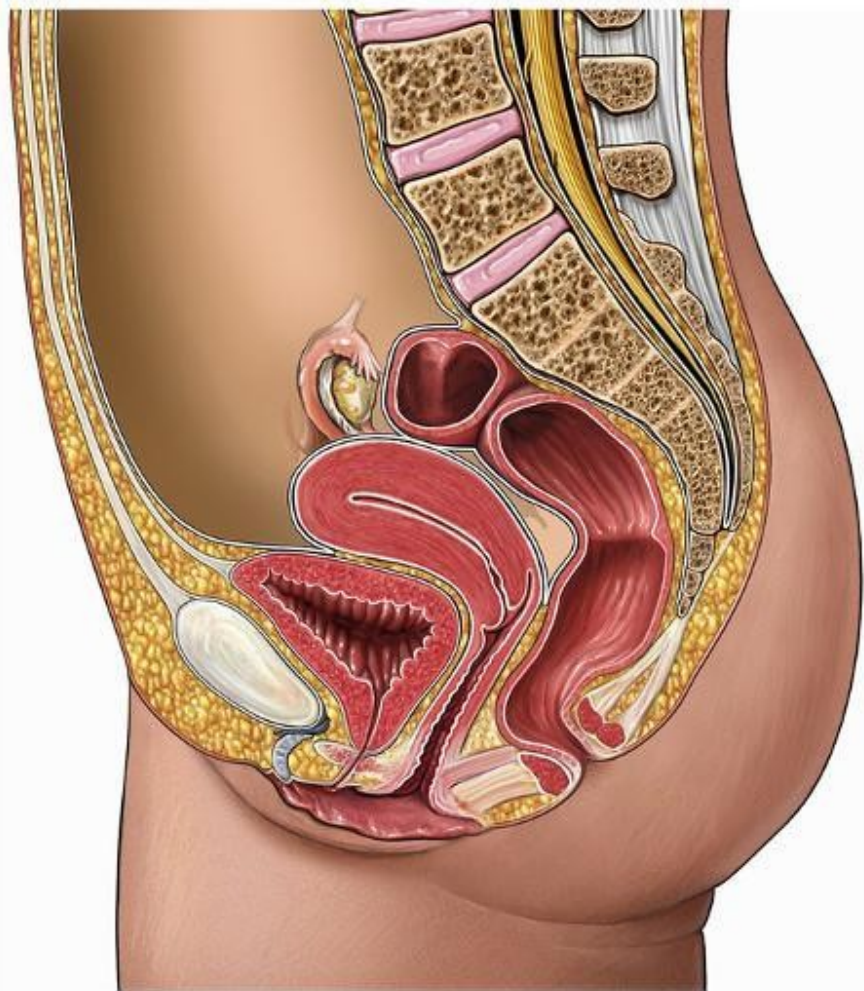








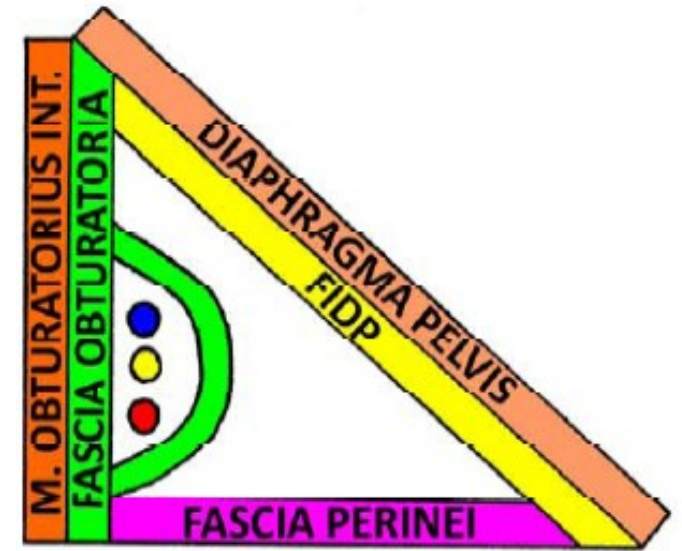
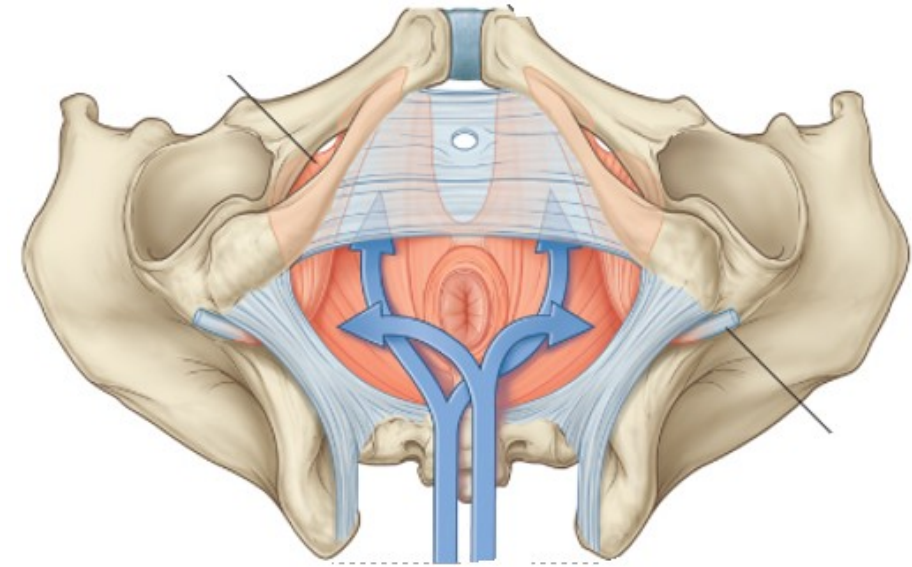
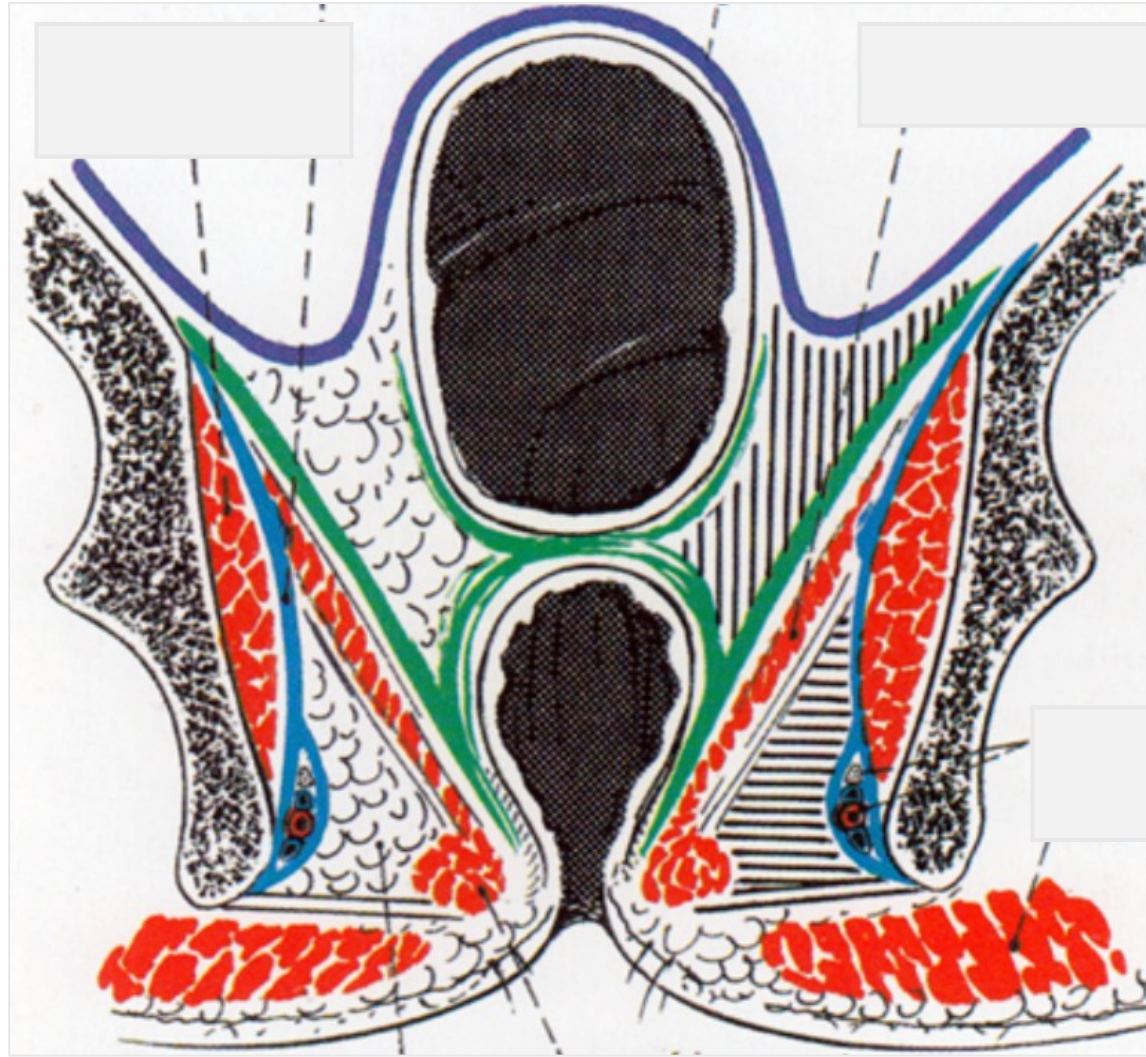




106. Ženská močová trubice

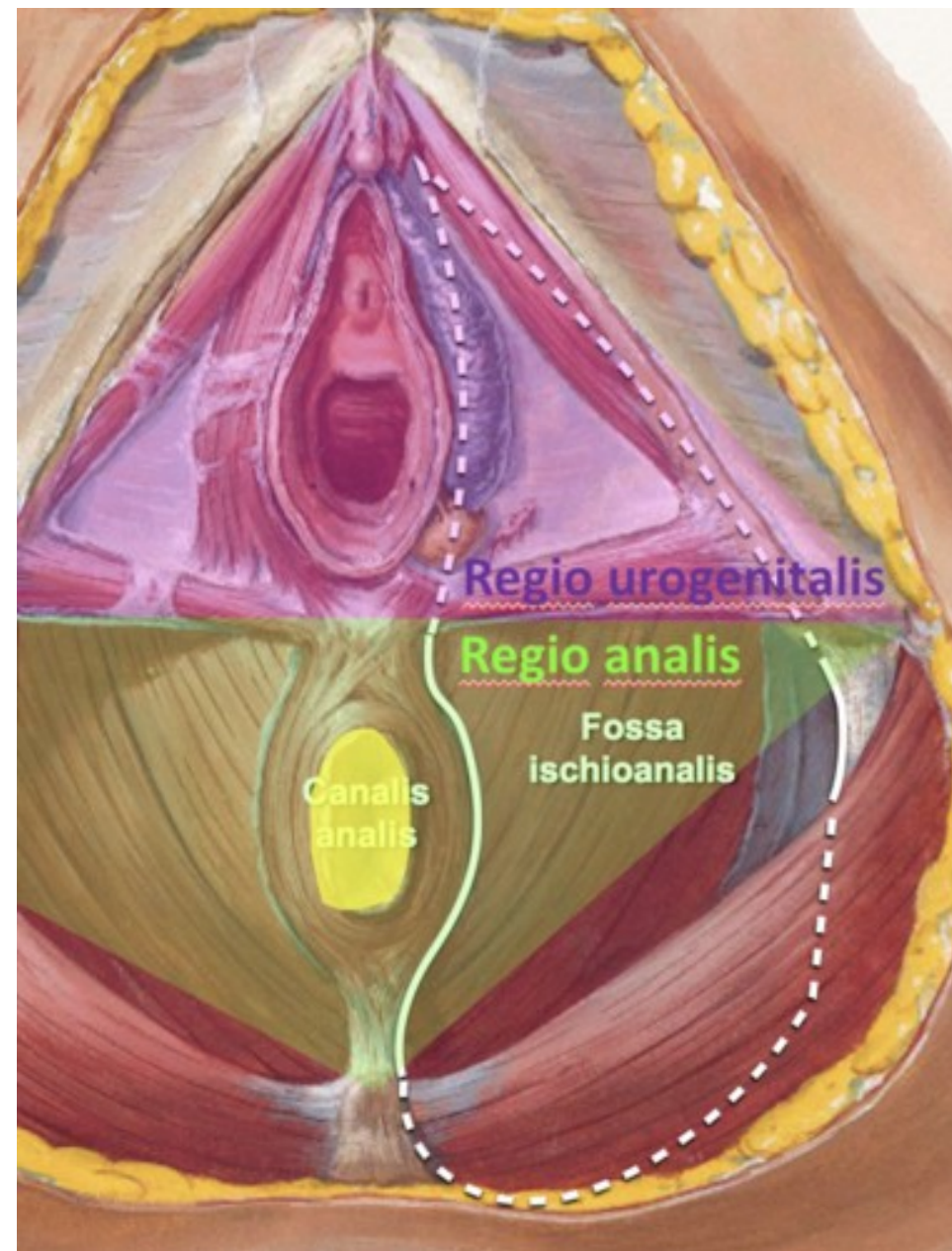


### 43. Fossa ischiorectalis





- 42. Povrchová a vnitřní hranice malé a velké pánve
- 44. Reg. urogenitalis muže
- 45. Reg. urogenitalis ženy
- 46. Reg. analis



## 42. Povrchová a vnitřní hranice malé a velké pánve

Povrchové krajiny patřící k pánvi, ale popisující se u jiných částí těla:

- regio glutea
- regio sacralis
- regio inguinalis

Povrchové krajiny popisující se přímo u pánve:

- regio pubica
- regio perinealis

Vnitřní hranice malé a velké pánve:

Linea terminalis – promintorium, linea arcuata, horní okraj symfýzy.



#### **44.,45. Reg. urogenitalis muže/ženy**

- rozděleno pomocí diaphragma urogenitale na povrchovou část se zevními pohlavními orgány a jejich svaly a hlubokou část – recessus pubicus fossae ischiorectalis

Vrstvy (od povrchu):

- kůže, podkoží a fascia perinei superficialis (pokračování Scarpovy fascie)
- řídké vazivo, crura penis/clitoridis, bulbus penis/vestibuli, m. ischiocavernosus et bulbospongiosus
- fascia diaphragmatis urogenitalis inferior
- diaphragma urogenitale – lig. transversum perinei, m. transversus perinei profundus et superficialis
- fascia diaphragmatis urogenitalis superior
- recessus pubicus fossae ischiorectalis
- fascia diaphragmatis pelvis inferior

#### **46. Reg. analis**

- anus – glandulae circumanales

- m. sphincter ani externus (septum anococcygeum)

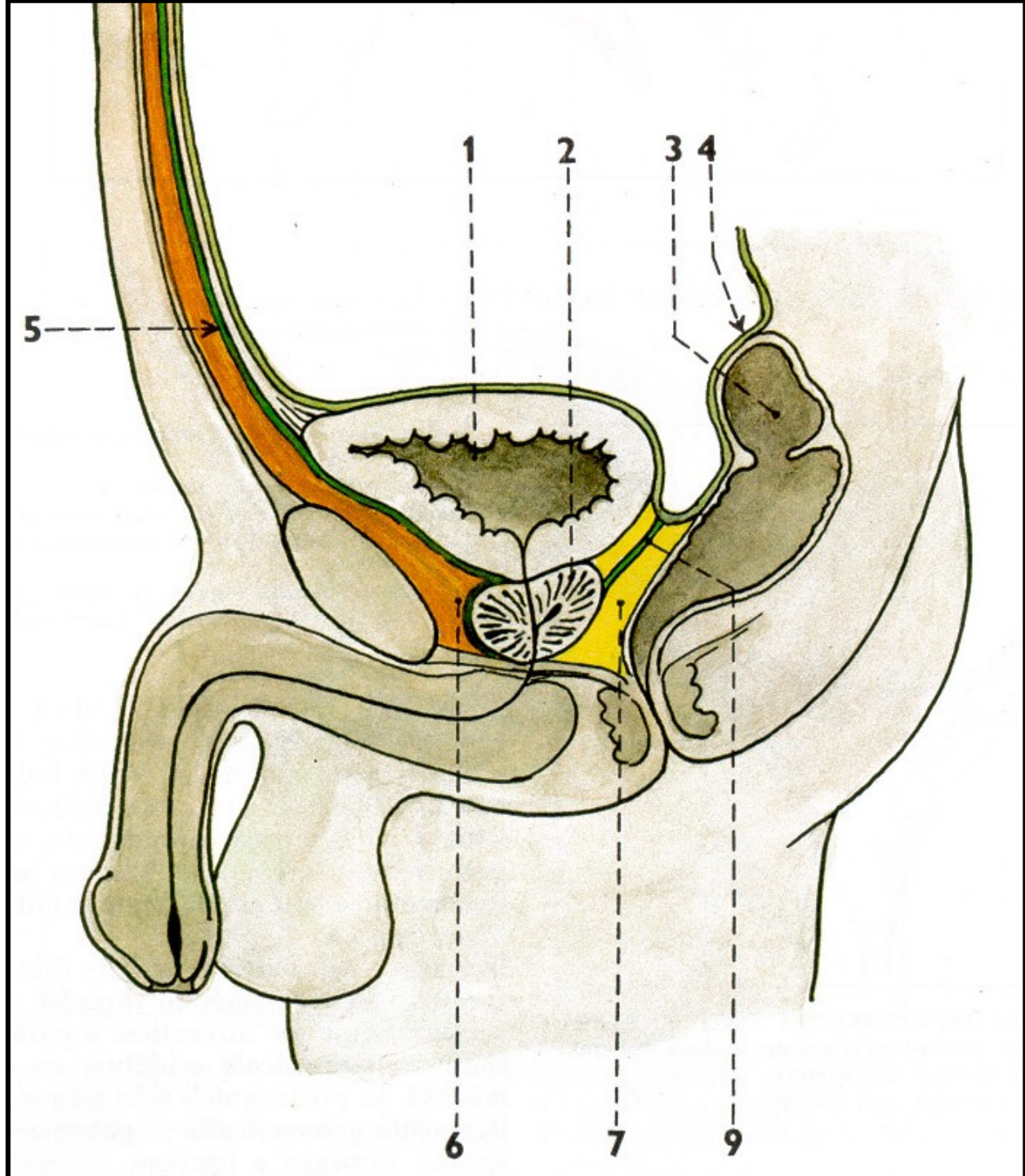
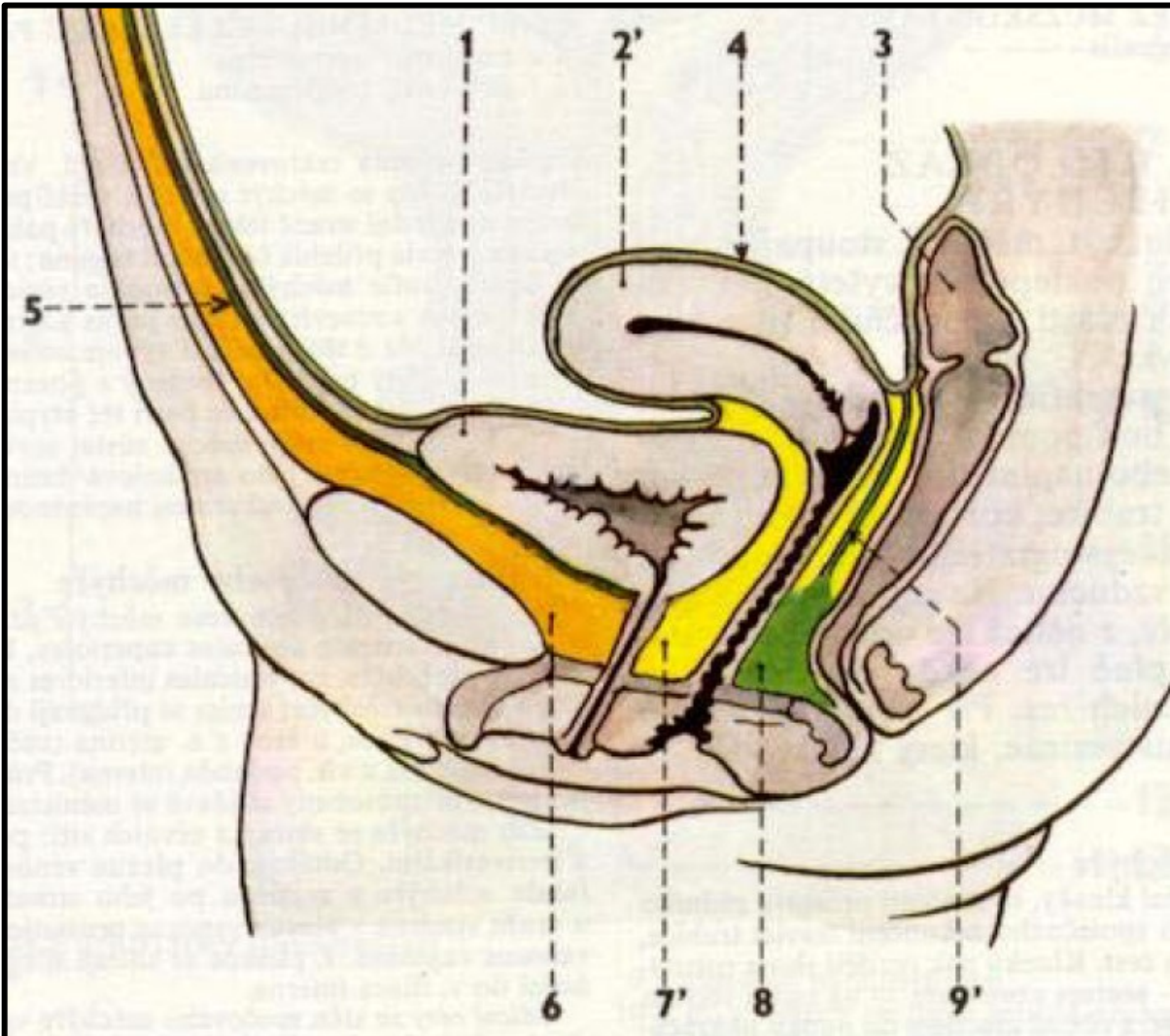
- raphae perinei- centrum perineale (perineální klín) - hráz

- fossa ischiorectalis (ischioanalis) – dorsálně – m. gluteus maximus

- ventrálně – recessus pubicus

- laterálně – fascia m. obturatorii interni – canalis pudendalis – vasa pudenda interna, n. pudendus.

47. Cavum pelvis infraperitoneale muže  
 48. Cavum pelvis infraperitoneale ženy





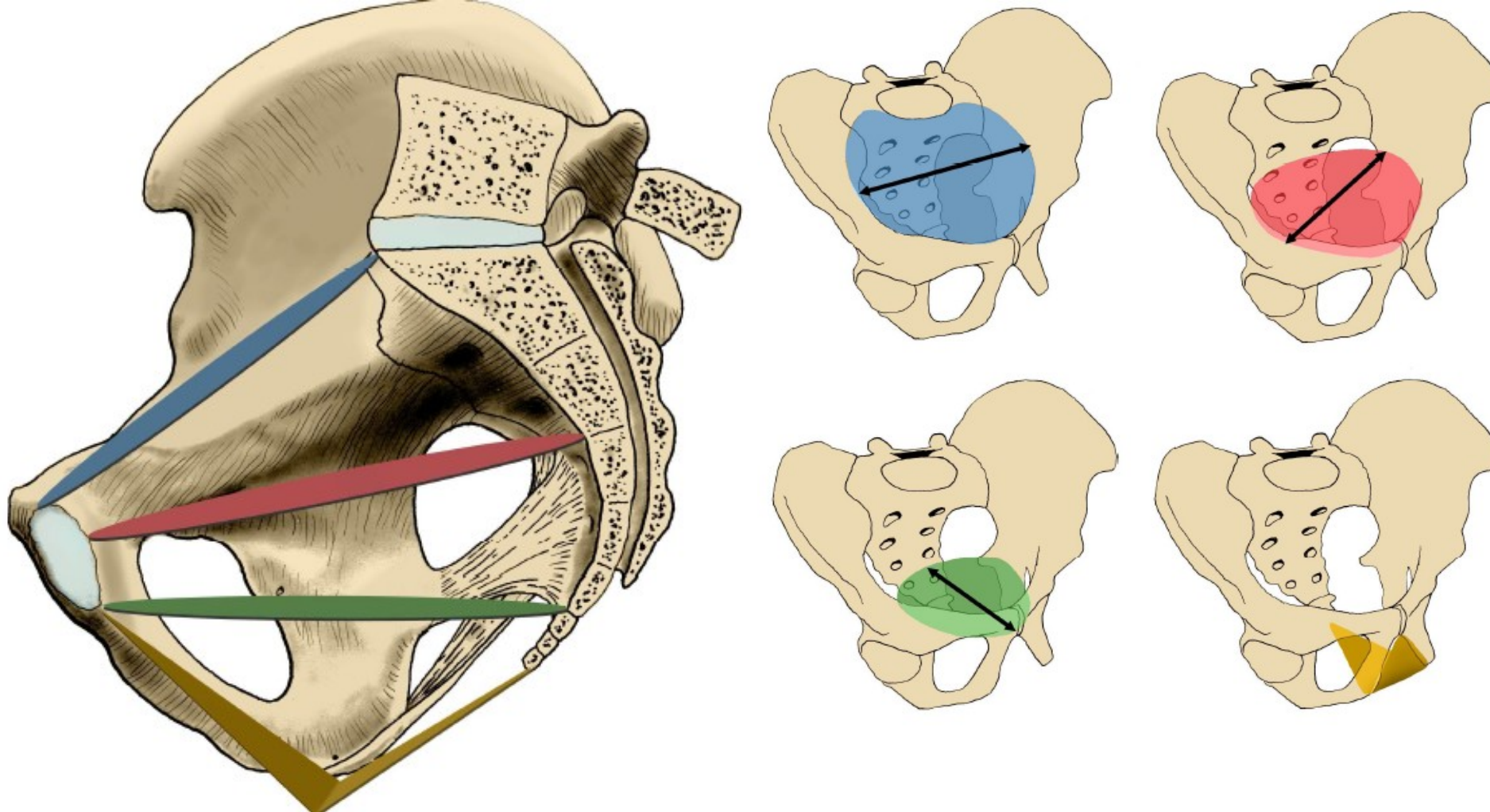
#### **47. Cavum pelvis infraperitoneale muže**

- konečník
- močový měchýř s uretery
- prostata
- vesiculae seminales
- ductus deferens
- větve vasa iliaca interna, vasa sacralis mediana
- plexus sacralis
- trunci sympathici a autonomní nervové pleteně
- řídké vazivo
- excavatio rectovesicalis

#### **48. Cavum pelvis infraperitoneale ženy**

- konečník
- močový měchýř s uretery
- cervix uteri
- vagina
- větve vasa iliaca interna, vasa sacralis mediana
- plexus sacralis
- trunci sympathici a autonomní nervové pleteně
- řídké vazivo
- excavatio vesicouterina, rectouterina (Douglasův prostor)

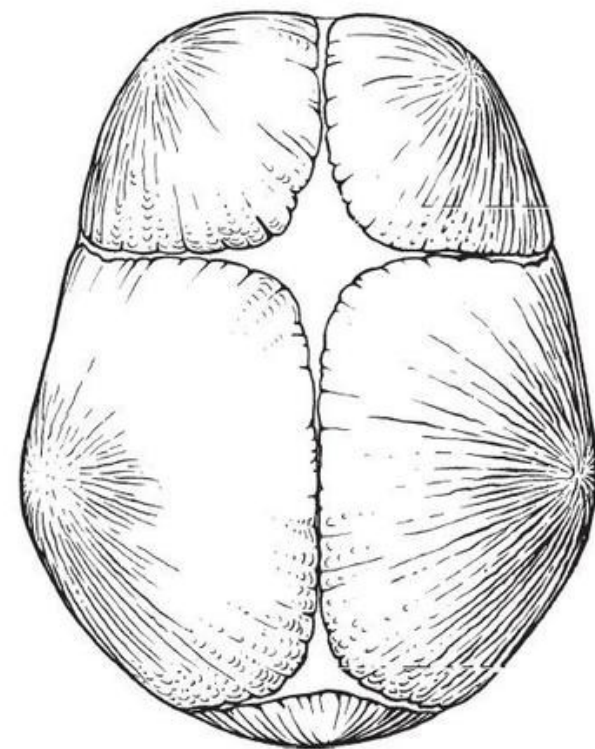
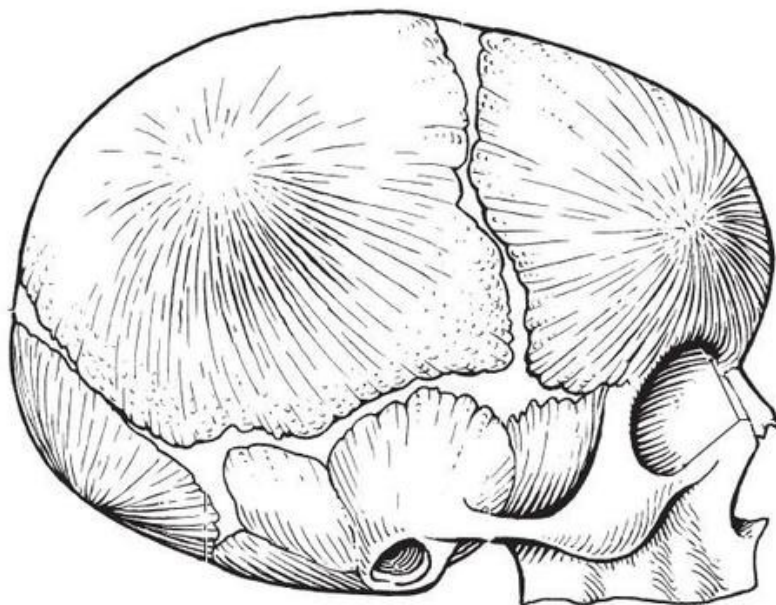
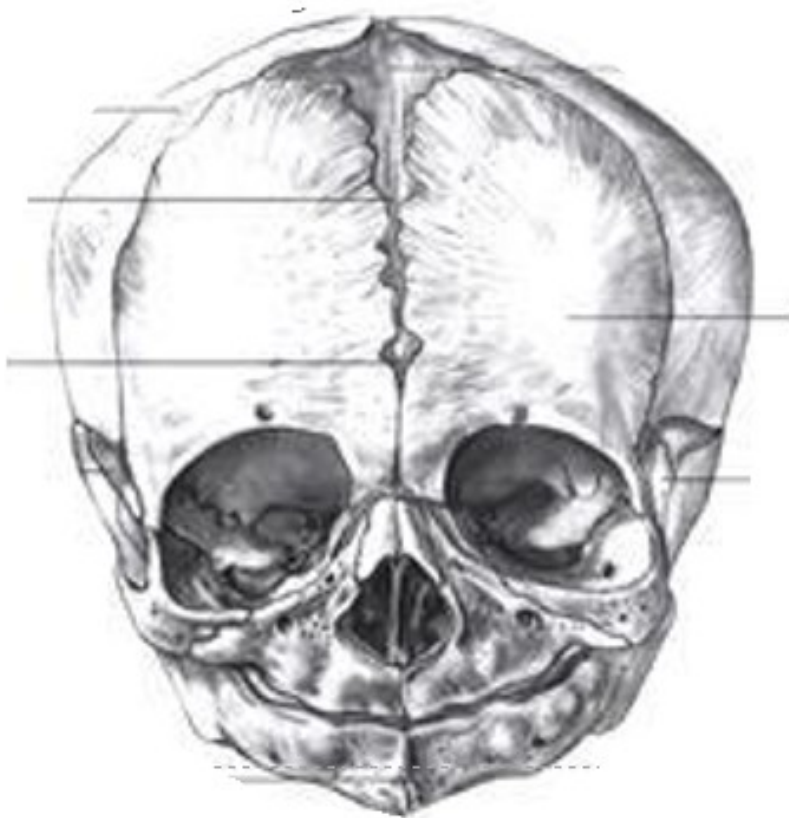




122. Roviny pánevní 1 – aditus et amplitudo pelvis

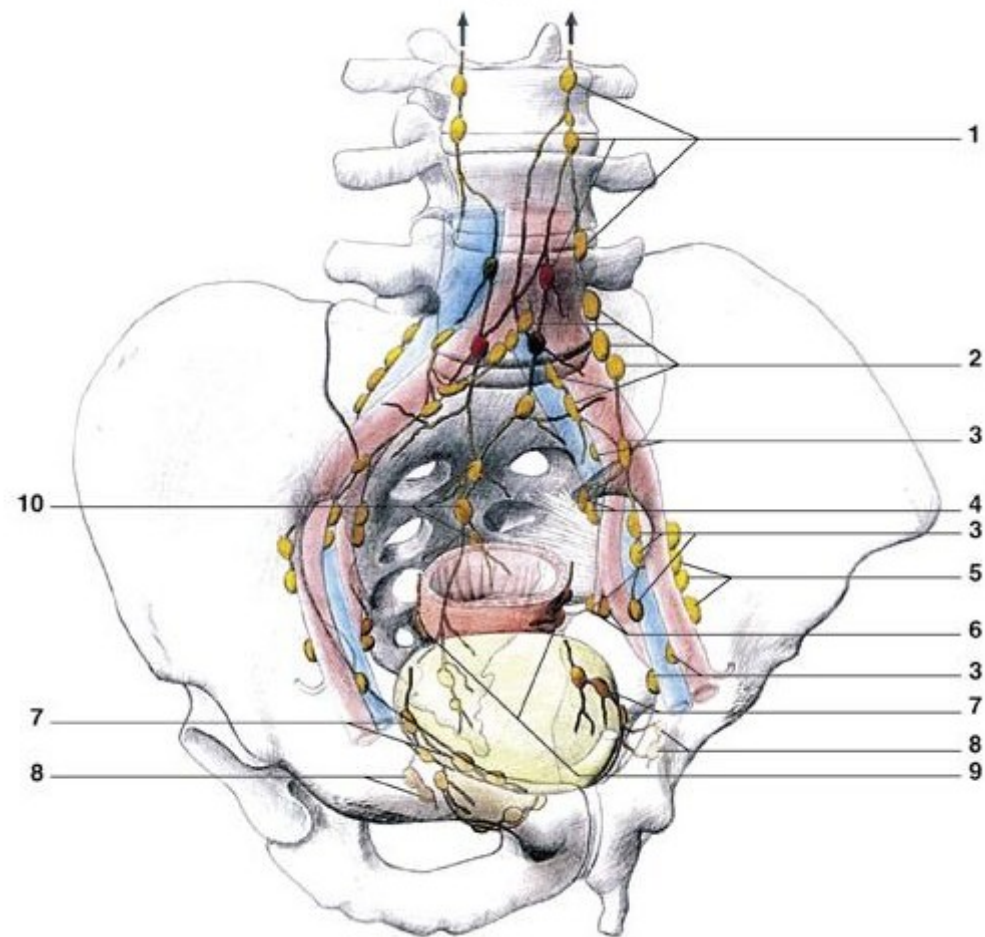
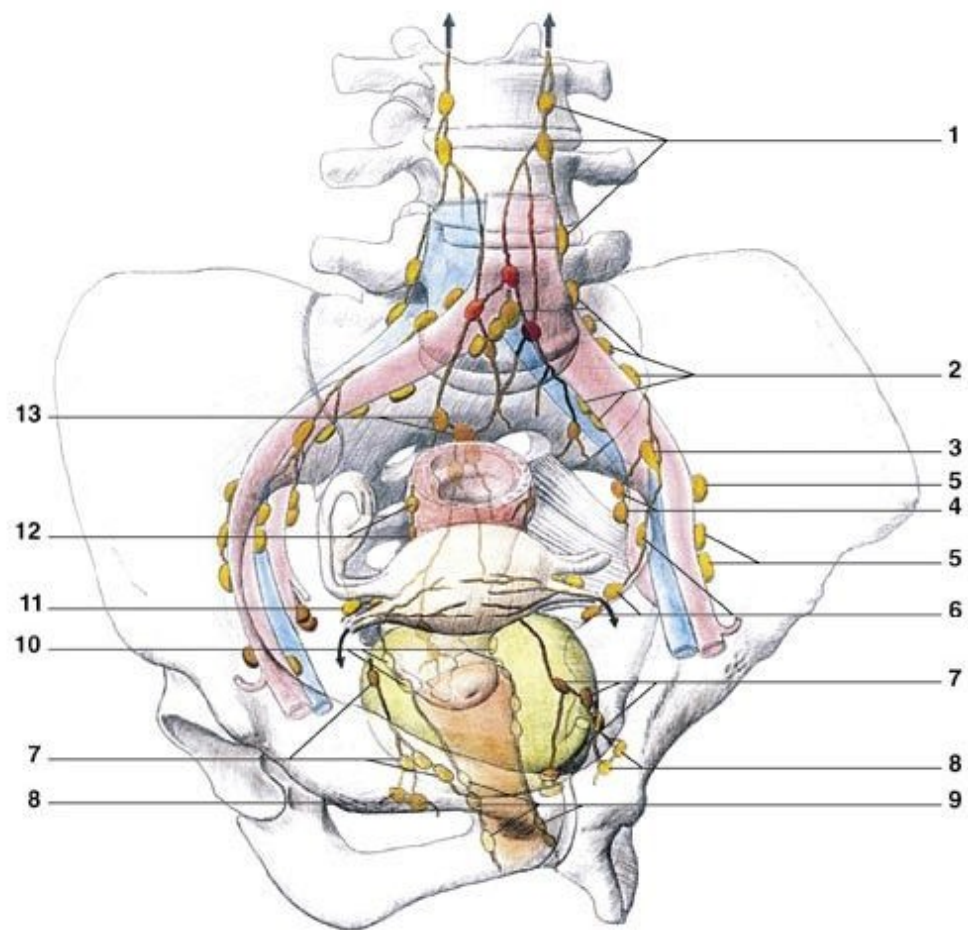
123. Roviny pánevní 2 – angustia et exitus pelvis

### 32. Lebka novorozenca

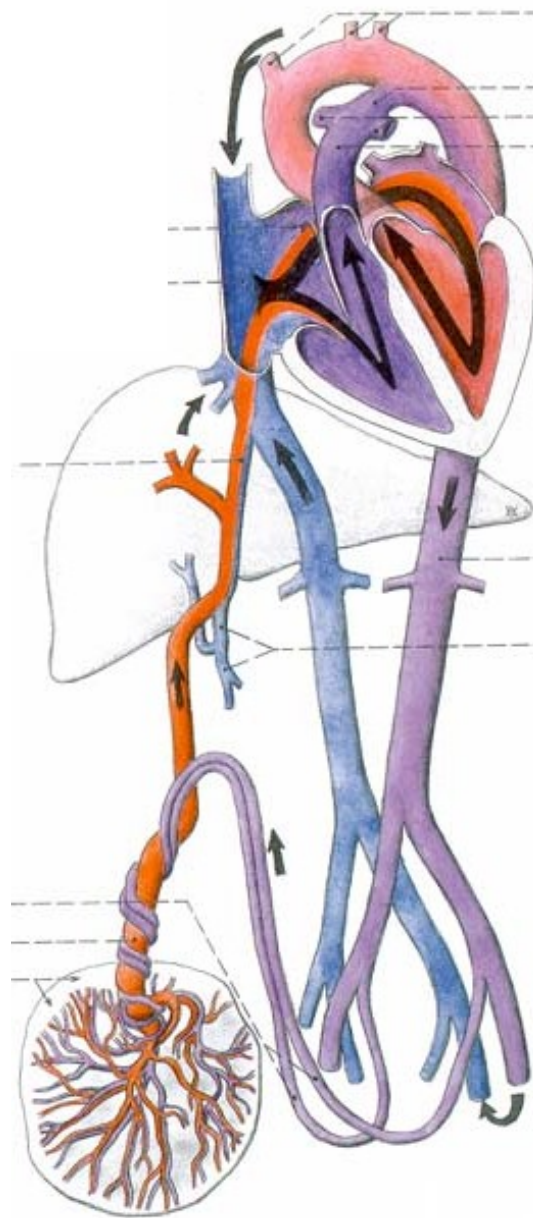




### 43. Mízní uzliny a cévy pánve



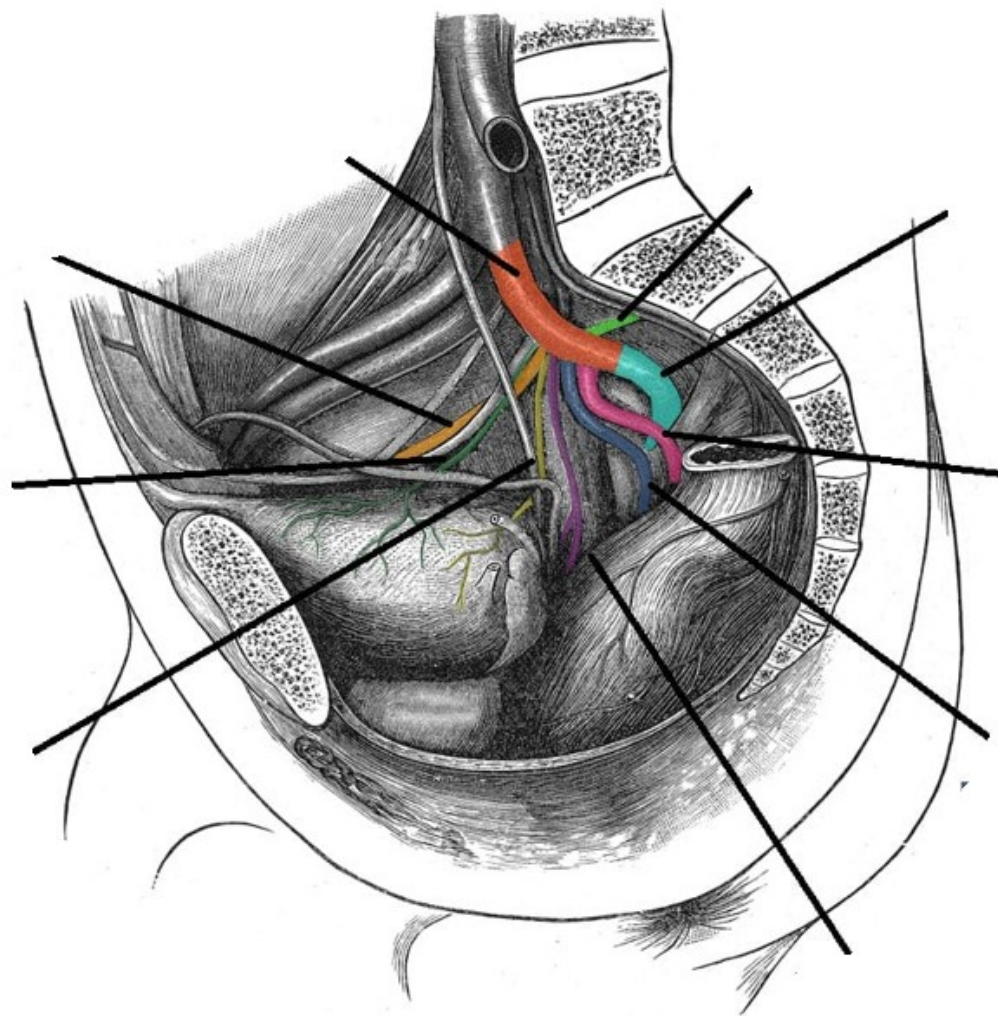
### 30. Fetální oběh





18. Arteria iliaca communis, Arteria iliaca interna, průběh, základní větve a oblast zásobení

19. Arteria iliaca externa



73. Nn. iliohypogastricus, ilioinguinalis, genitofemoralis, průběh a jejich inervační oblasti
74. N. femoralis, n. obturatorius, průběh a jejich inervační oblasti
75. N. gluteus sup. et inf., n. cutaneus femoris post., průběh a jejich inervační oblasti
76. N. ischiadicus, po rozdělení na n. tibialis a n. fibularis communis
77. N. tibialis, průběh a jeho inervační oblasti
78. N. fibularis communis, průběh a jeho inervační oblasti
79. N. pudendus, průběh a jeho inervační oblasti

