

# Nephropathology

V. Žampachová

I. ÚP

# Anatomical remarks

- **Vessels** - 90% of blood flow through the cortex
- Afferent arteriole → glomerular capillaries → efferent arteriole → peritubular capillary plexus (from superficial glomeruli) or vasa recta for medulla (from juxtamedullary glomeruli)
- terminal arteries
- glomerular damage commonly leads to damage of peritubular blood flow – risk of ischemia

# Possible clinical signs

- Weight gain, edema – fluid retention
- Thirst – chronic renal failure, DM
- Fatigue – acute/chronic renal failure (RF)
- Fever – urinary tract infection (UTI)
- Headache – hypertension, RF
- Hematuria – UTI, glomerulonephritis, tumor, stone
- Polyuria – DM, tubular disorders

**Renal diseases commonly clinically silent!**

# Clinical features

- Diminished renal reserve – GFR  $\sim$  50% of normal
- Renal insufficiency - GFR 20-50% of normal
- Azotemia – increase of blood urea and creatinine due to decreased glomerular filtration (20-30%), or extrarenal cause
- Uraemia - azotemia together with several clinical and biochemical abnormalities: metabolic, endocrine, ...
  - uremic gastroenteritis/colitis + IS dysregulation, malnutrition;
  - hypertension, fibrinous pericarditis, AS acceleration, arrhythmias
  - pneumonia, pleuritis
  - dermatitis, itching
  - renal osteodystrophy, osteoporosis, muscle loss
  - peripheral neuropathy,



# Clinical features

- Renal failure - GFR less than 20-25%, oedema, uraemia; causes: *prerenal, postrenal, renal (vascular, glomerular, tubulointerstitial)*; acute r.f. (oliguria→anuria) chronic r.f.
- End-stage renal disease - GFR less than 5% of norm
- Anuria <100ml/24hrs

# Clinical features

- **Nephritic syndrome** due to acute glomerular disease; hematuria + mild proteinuria + hypertension; oliguria + azotemia + mineral dysbalance
- **Rapidly progressive glomerulonephritis** – very rapid (days - a few weeks) nephritic syndrome
- **Nephrotic syndrome:** usually chronic gl. dis., severe proteinuria (>3,5 g/d) + hypoalbuminemia/oedema + hyperlipidemia + lipiduria; possible ↑ infections (IgG loss); hypercoagulative state – loss of coagulation proteins, ↑ blood viscosity



# Clinical features

- Asymptomatic hematuria and/or proteinuria – commonly mild glomerular lesion
- Polyuria + nocturia + electrolyte disorders – renal tubular defects
- Bacteriuria + pyuria – urinary tract infection (UTI)
- Renal colic + hematuria - nephrolithiasis

# Renal diseases

- congenital anomalies
- glomerular diseases
- vascular diseases
- tubulointerstitial diseases
- tumors

# Congenital anomalies

- 10% of all people
- hereditary or acquired developmental defect
- decreased volume of renal tissue (e.g. agenesis)
- disorders of differentiation (dysplasia)
- anatomical abnormalities (ectopy)
- metabolic disorders (cystinuria)

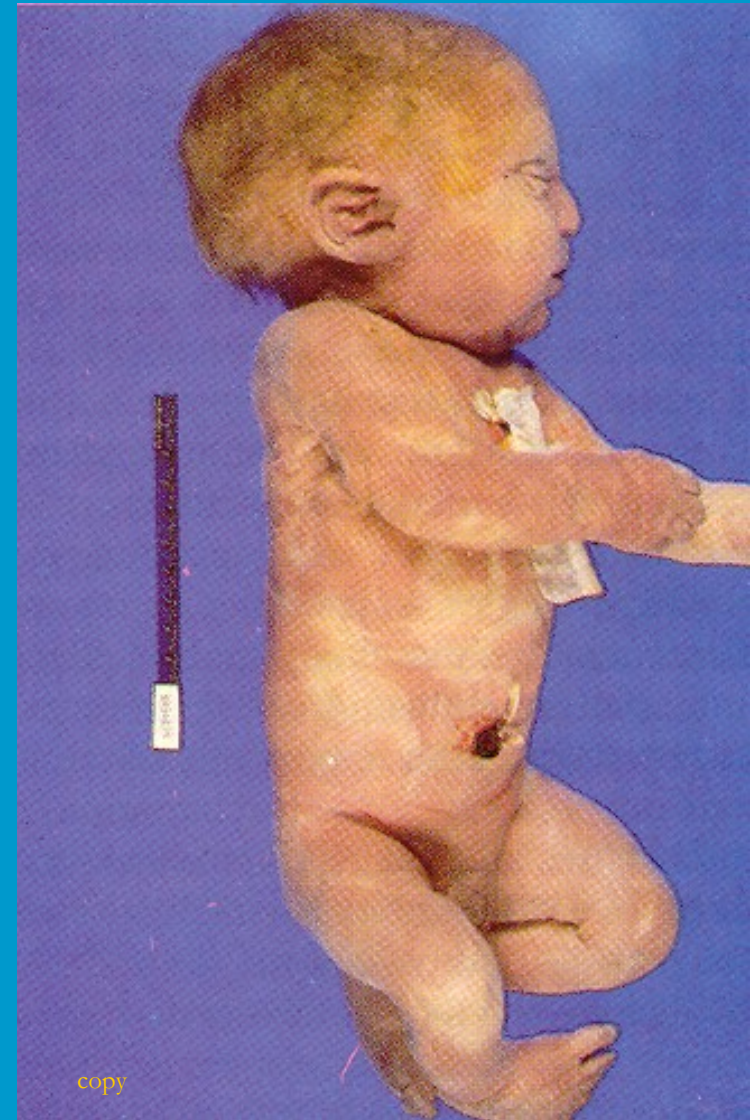# Agenesis

- Bilateral agenesis – 1:6000, incompatible with independent life, usually stillborn, accompanied by characteristic appearance (Potter's syndrome), commonly associated with other congenital defects
- Unilateral agenesis – infrequent, the opposite kidney enlarged by compensatory hypertrophy

# Oligohydramnion (Potter's syndrome)

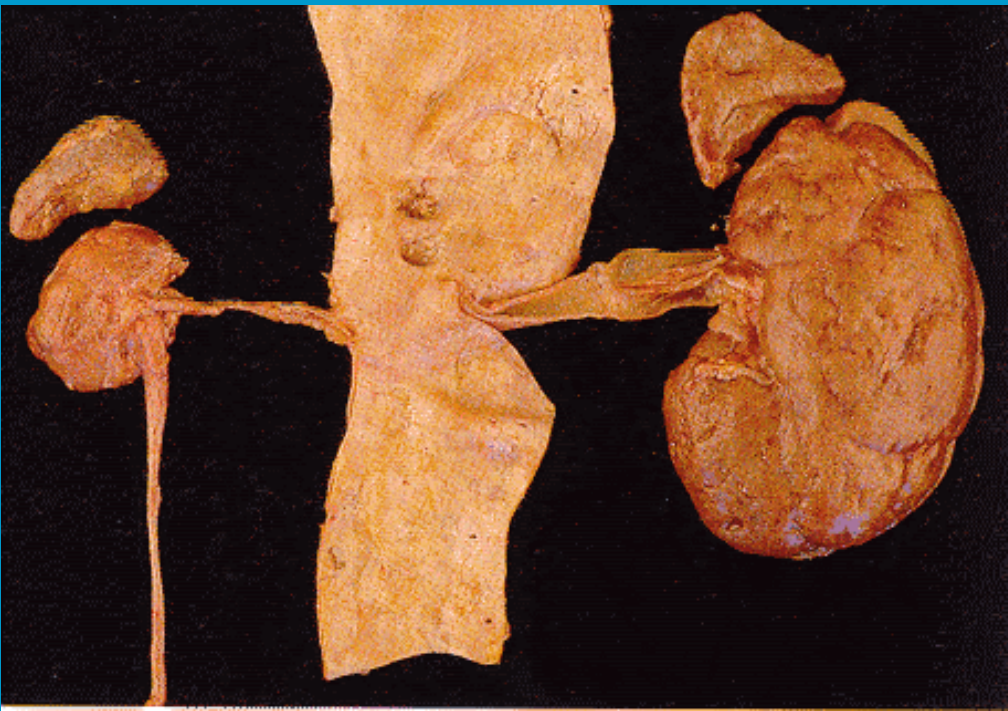
decreased amount of amniotic fluid (placental abnormalities, renal agenesis or malformation)

flat face, lung hypoplasia, limb deformities, ...



# Hypoplasia

- Abnormally small kidneys (x atrophy)
- reduced number of lobes and pyramids





# Renal ectopy

- Abnormal site, usually in pelvis, due to migration stop of the *metanephros*
- *A. renalis* - from lower aorta or *a. ilica communis*
- Short ureter

# Ren migrans, ren mobilis

- Not a malformation, normal *a. renalis*
- Secondary renal descensus, usually due to loss of adipous capsule
- Long ureter, risk of obstruction and infection

# Other inborn defects

## ■ **Tuberous sclerosis**

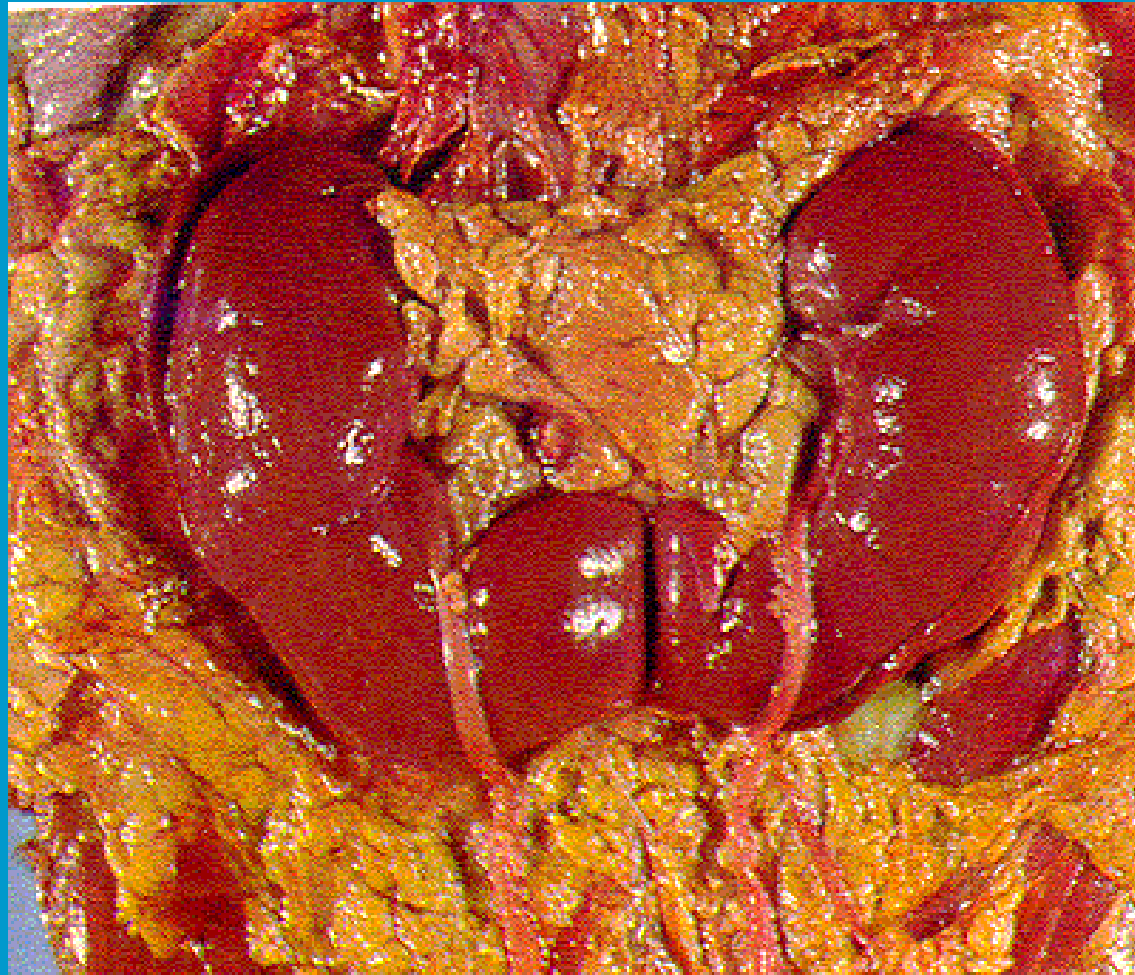
- AD, 1:5800; multiple benign proliferations/tumors in the brain, heart, kidney
- in 50 % kidney lesions incl. cysts (→CHRI), angiomyolipomas, hamartomas, rare carcinomas

## ■ **Sy von Hippel – Lindau**

- AD, multiorgan disorders (eyes, CNS, pancreas, kidney – tumors benign / malignant; common kidney cysts, possible → ca)

# Horseshoe kidney

- Renal pole fusion
- Ureteral obstruction

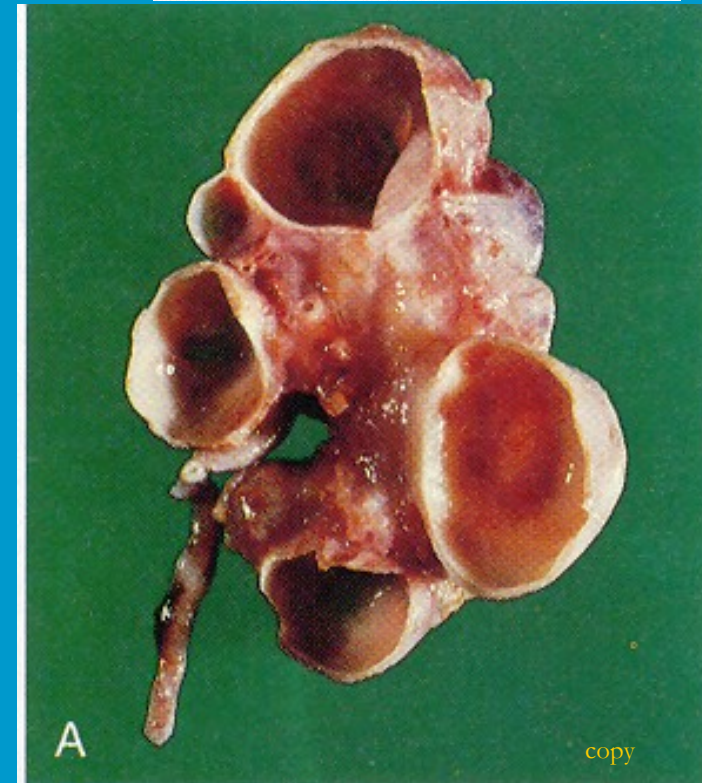
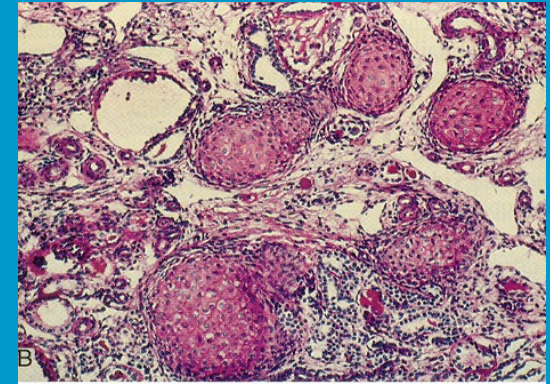


# Cystic renal disease

- Hereditary, congenital nonhereditary, acquired
- Pathogenesis: primary defect of tubular epithelial cells and their growth, resulting in tubular dilatation
- Secondary tubular obstruction (oxalate crystals etc.)
- Multiple or solitary
- Affects the whole kidney, or mostly cortex or medulla

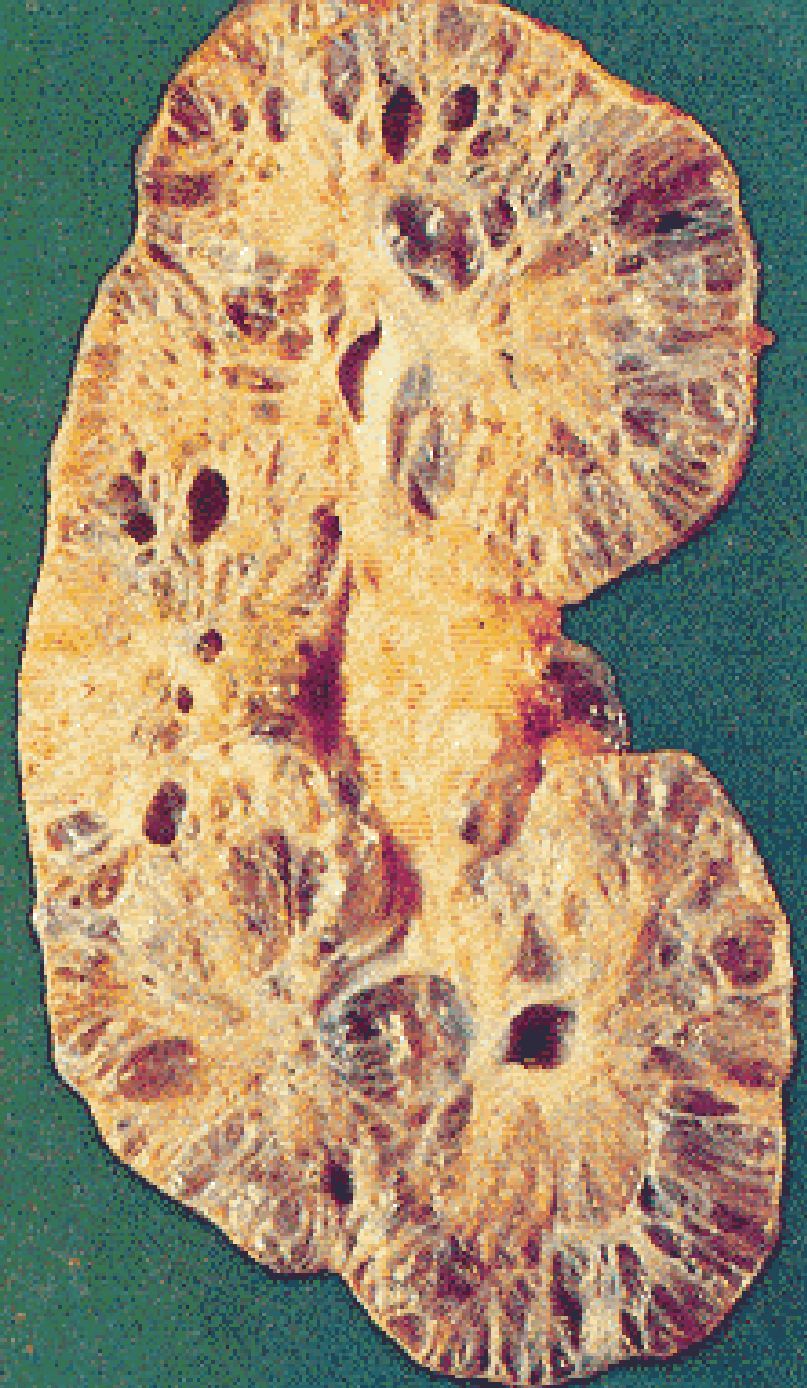# Cystic dysplasia

- Uni- or bilateral
- Enlarged multicystic kidney
- Cysts mm-cm.
- Islands of undifferentiated mesenchyme, immature tubules
- Commonly cartilage
- Bilateral - renal insufficiency

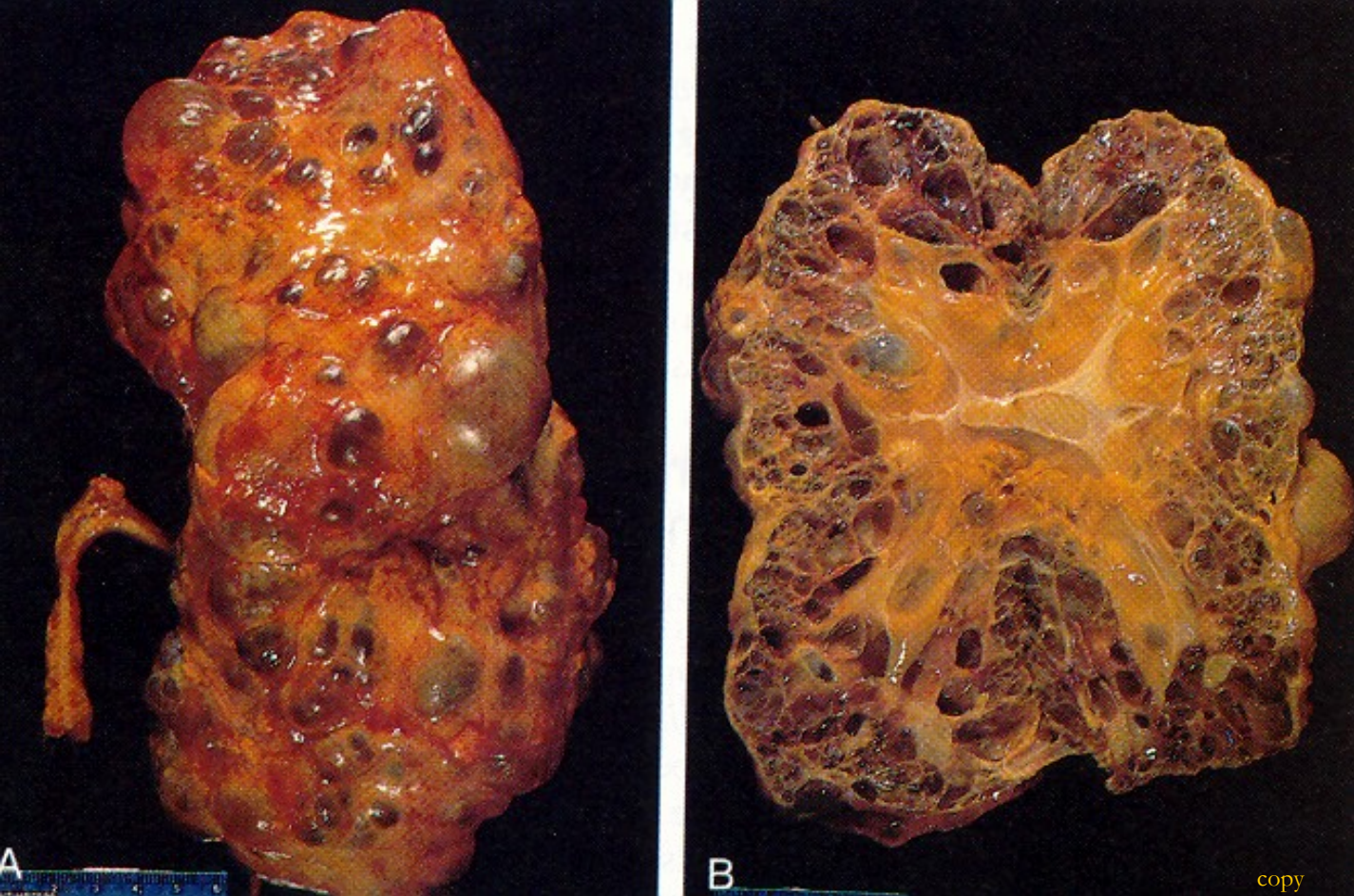


# Polycystic kidney - autosomal recessive

- Infants
- Enlarged kidney at birth, smooth surface, microcystic
- Radial elongated cysts and channels
- Congenital hepatic fibrosis
- RF in childhood





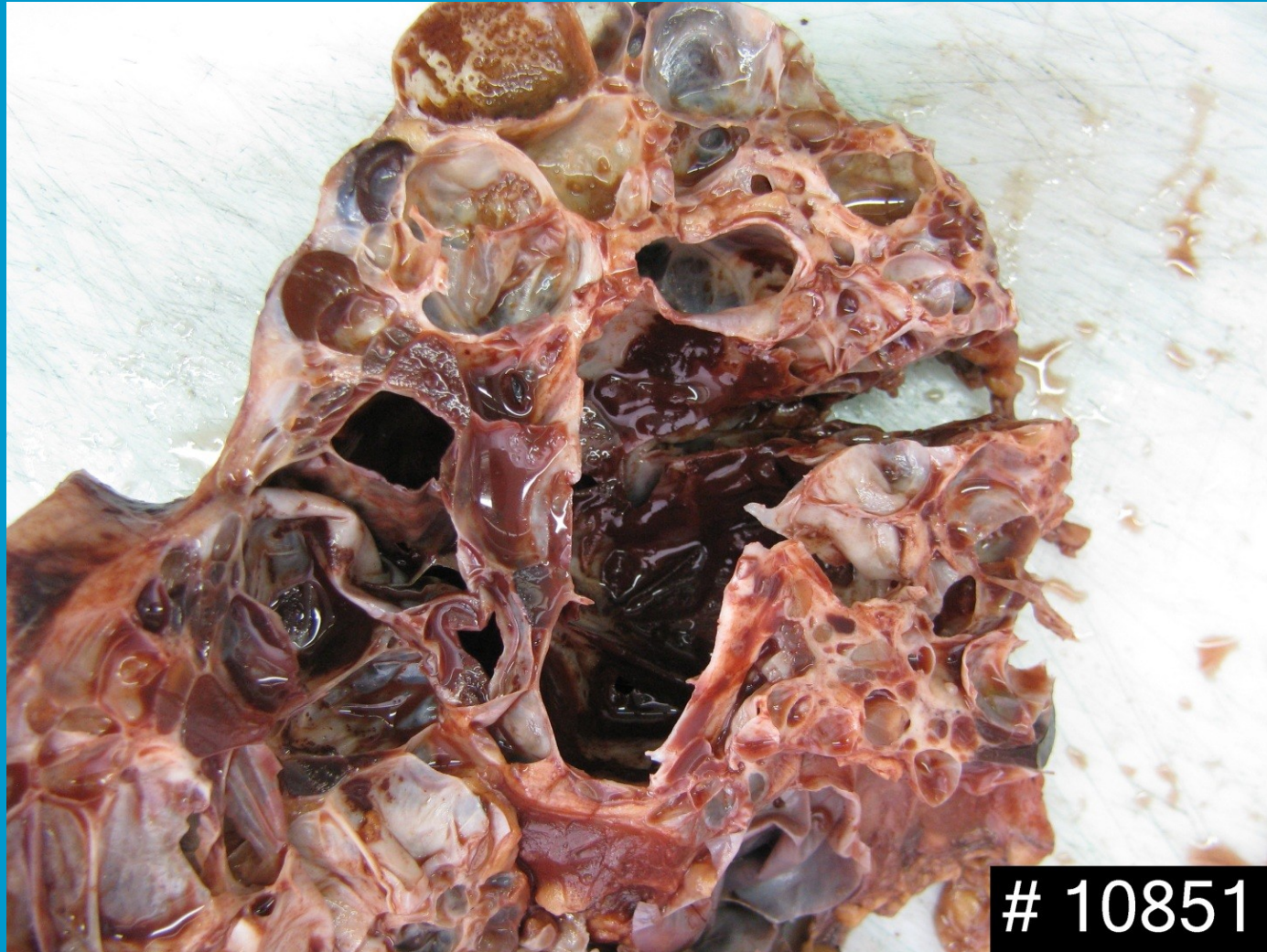

## **Adult polycystic kidney disease (APKD)**

Autosomal-dominant, liver cysts, berry aneurysms. 1:500-1:1000. Pain, hematuria, UTI, stones, hypertension, slow progression, chronic RF at 40-60 yrs. ↑risk of ca



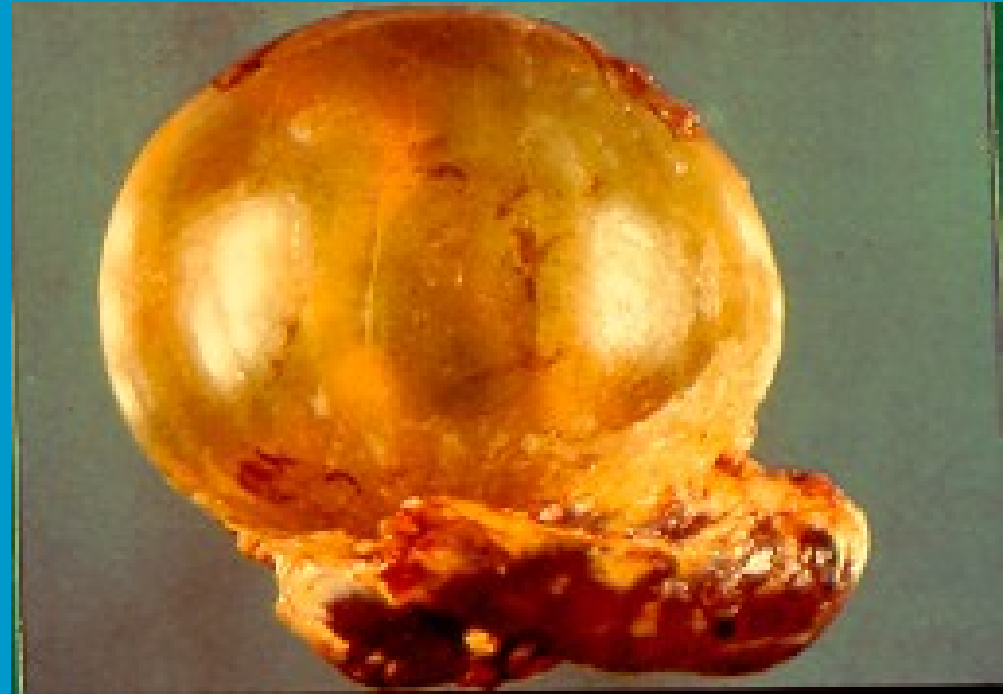# Adult polycystic kidney



# 10851

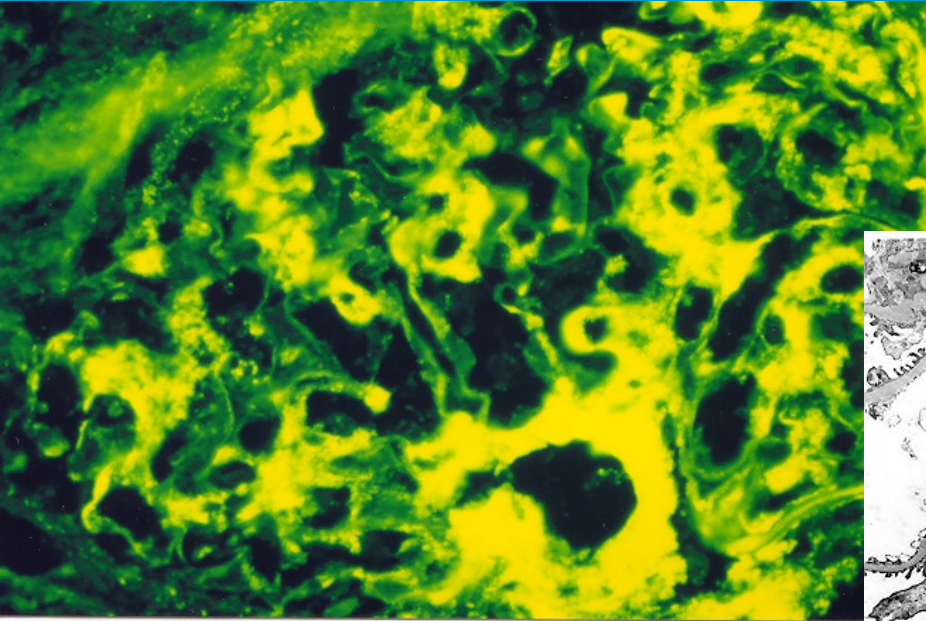
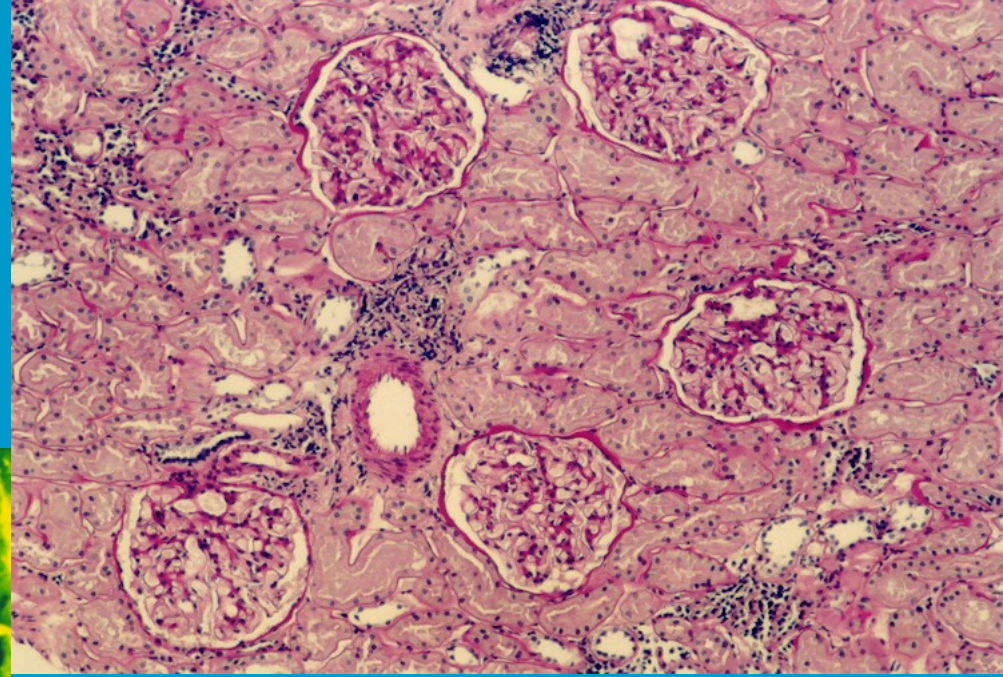
# Simple cyst

- Single or multiple
- Up to 10 cm
- Haemorrhage possible
- Differential diagnosis x cystic tumors
- „Complicated“ cyst – with regressive changes, diff. dg. x ca

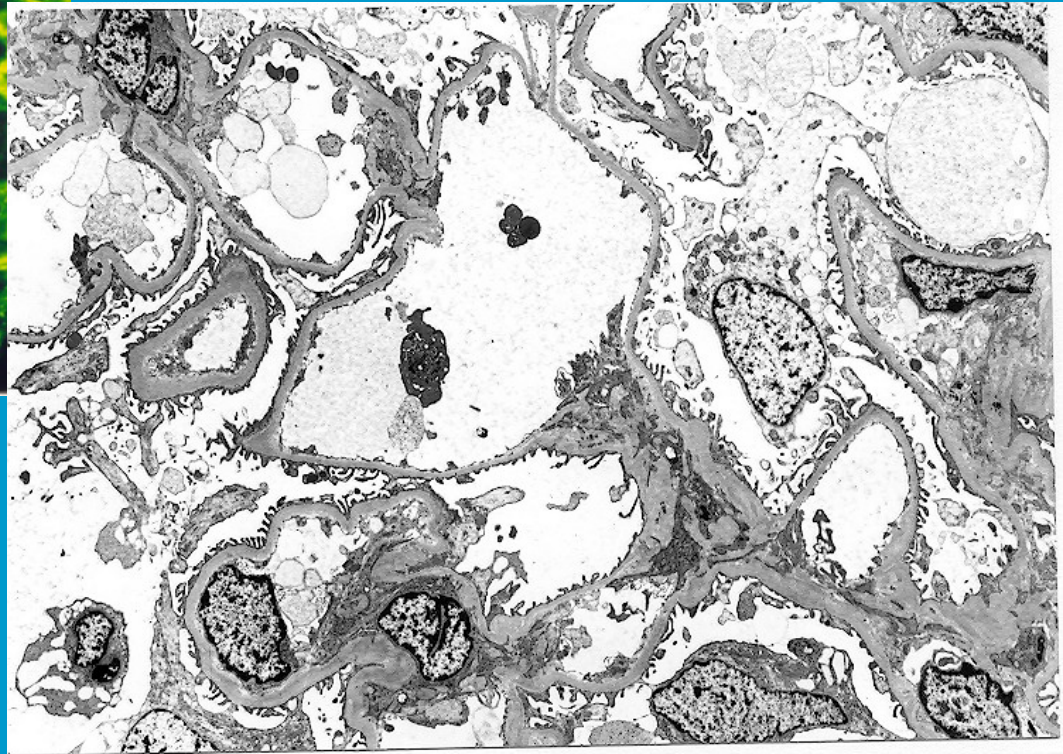




# Renal biopsy

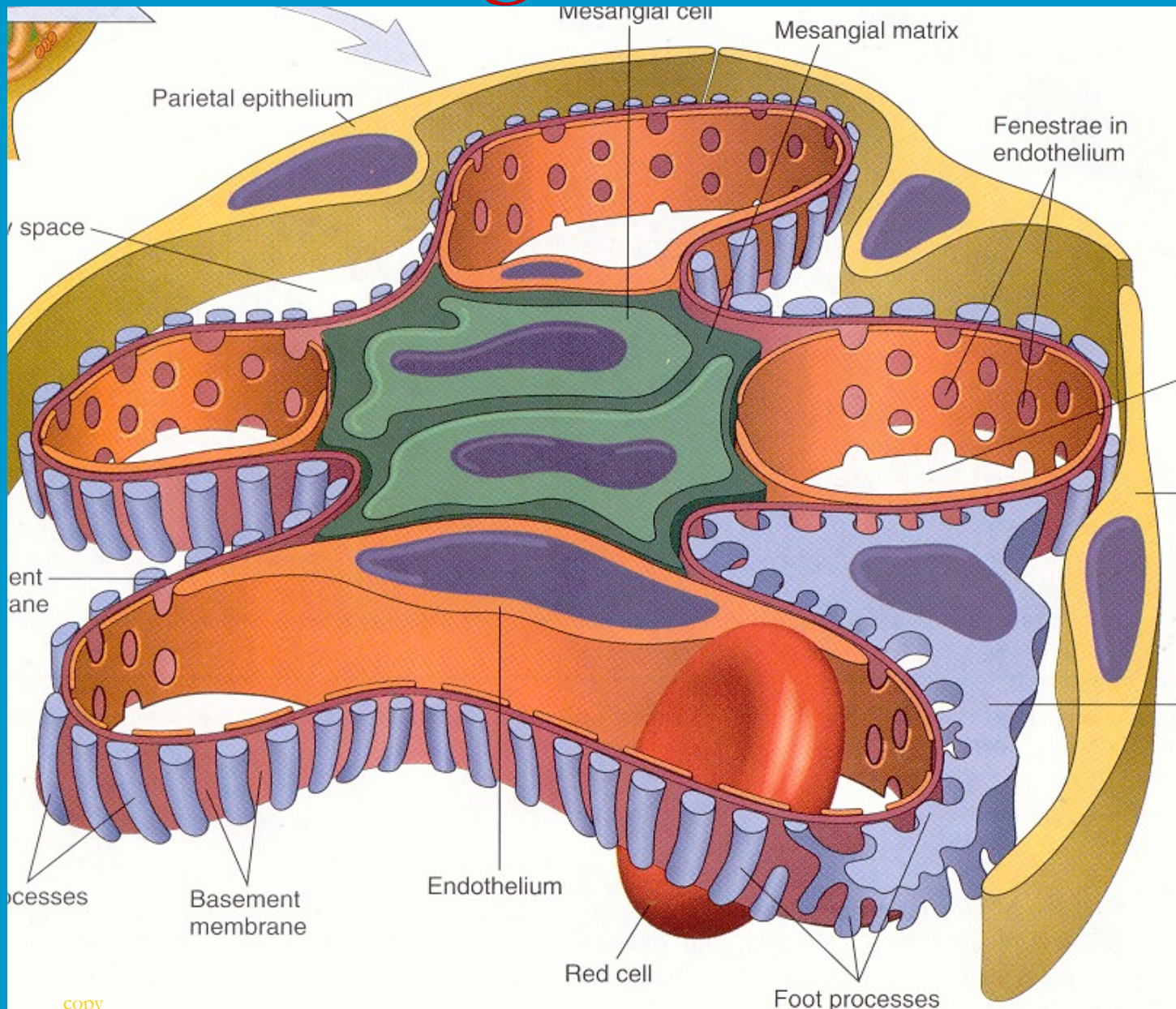


Direct  
immunofluorescence  
Electron  
microscopy



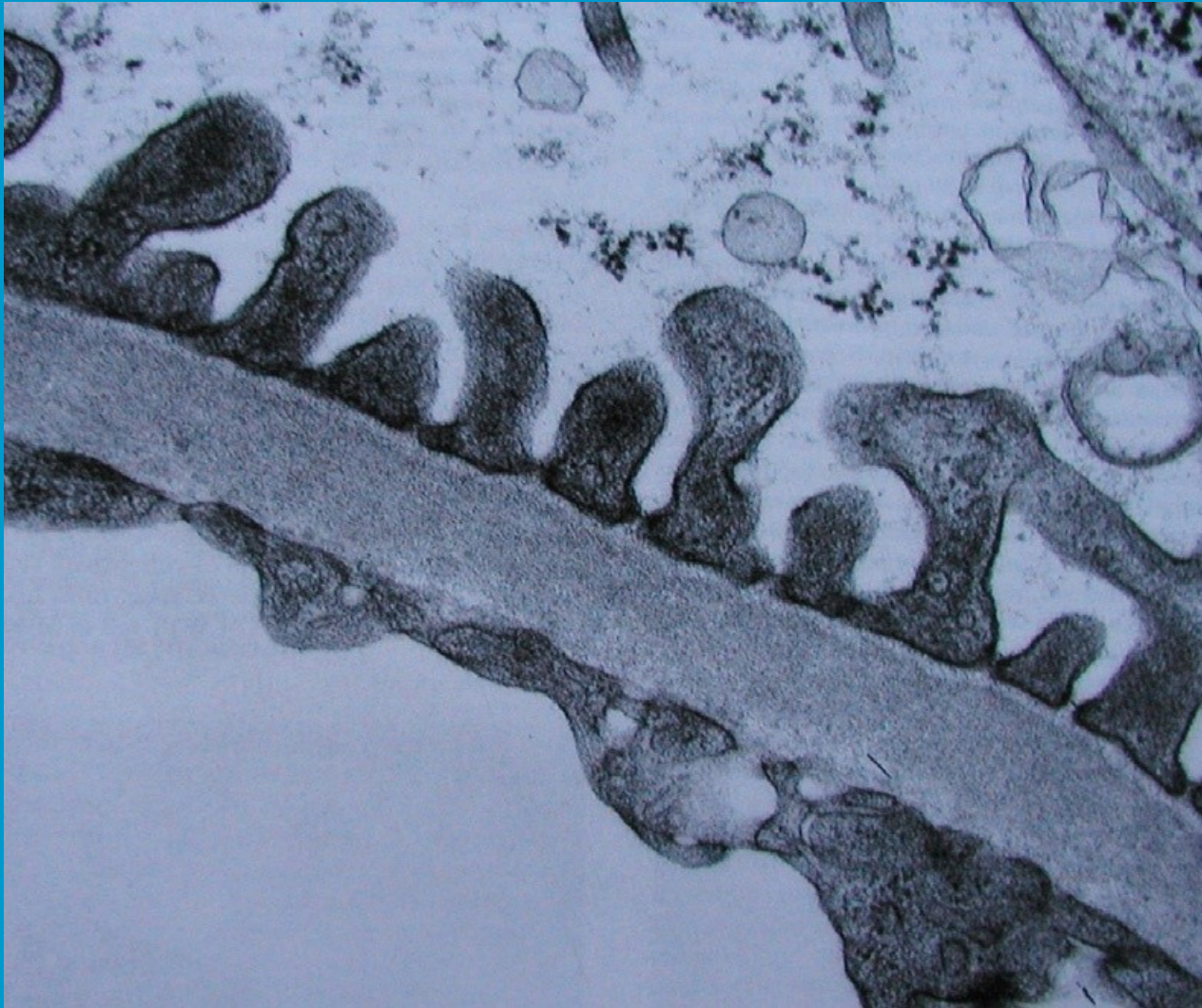

# Normal glomerulus





# Glomerular filtration barrier



# Glomerular diseases

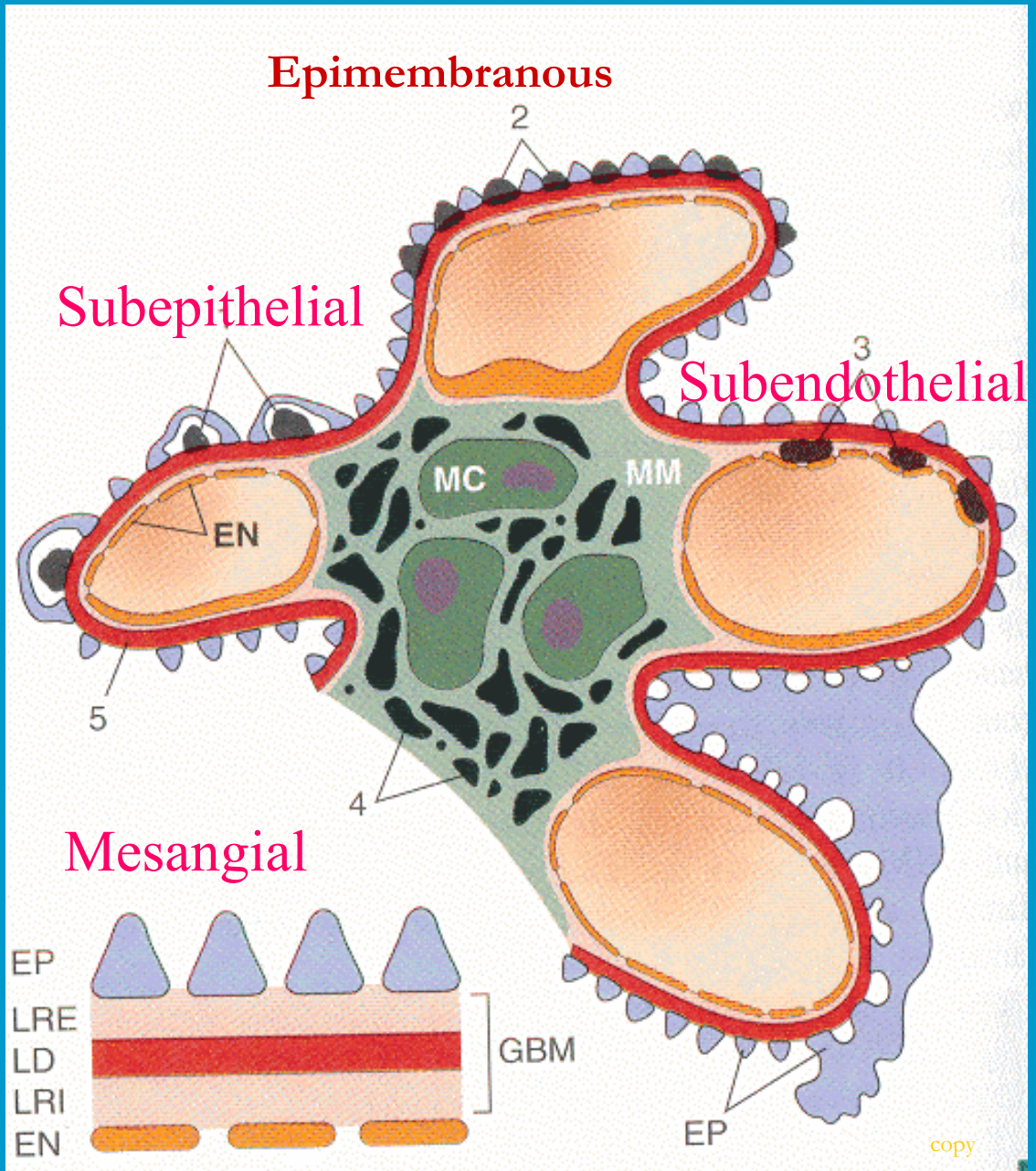
- Classification by aetiology and mechanisms of injury (primary x secondary; immunological x non-immunological)
- Histological classification (patterns of injury – proliferative, membranous change, membranoproliferative, crescentic, hyalinisation + sclerosis)
- One disease may have variable morphology/pattern (SLE)
- One pattern may be seen in variable disorders

# Glomerular diseases

## Immune mediated lesions

- circulating immune complexes
- in situ immune complexes
- anti-GBM antibodies
- autoantibodies (ANCA)

# IC localisation





# Glomerular diseases

## Non-immune mediated lesions

### vascular

- hemodynamic factors
- hypertension
- ischemia

# Patterns of glomerular injury

- **Proliferative** – increased glomerular cellularity, combination of endogenous proliferation and exogen. infiltration
- **Membranous change** – thickening of loops due to BM expansion + IC deposition
- **Membrano-proliferative**
- **Crescentic** – florid prolif. of cells in Bowman's capsule + infiltration, later fibrotic changes
- **Hyalinisation** – extracellular/intramural amorphous material w. plasmatic proteins + lipids, PAS+, silver impregnation -
- **Sclerosis** – extracellular collagenous matrix, membranes, PAS+, impregn. +

# Glomerular injury distribution

- **Diffuse** – almost all glomeruli affected (> 50-80%)
- **Focal** – only some glomeruli
- **Global** – affecting the whole glomerulus
- **Segmental** – affecting only part of the glomerulus

# Clinical presentations

- Nephritic syndrome – acute gl. damage, rapid start, hematuria, variable proteinuria, oliguria, edema, hypertension, azotemia, mineral dysbalance
- Nephrotic syndrome - heavy proteinuria  $> 3,5$  g/daily, generalised edema, hypoalbuminemia, hyperlipidemia, lipiduria; hypercoagulative state (loss of coagulation proteins, increase in blood viscosity)

# Glomerular diseases

- Nephritic syndrome, rapidly progressive GN: inflammation +/- endothelial damage; ↑ gl. cellularity
- usually immune mediated
  - Immune complex deposition (acute proliferative GN, SLE)
  - Antibodies x glomerular basement membrane (Goodpasture sy)
  - Systemic noninfectious vasculitis: autoantibodies p-ANCA, c-ANCA; (polyangiitis with granuloma)
  - immune mediated abnormalities of complement system regulation (C3)

# Glomerular diseases

- **Nephrotic syndrome:** malfunction/leakage of barrier-filtration system - ↑ increased permeability

Capillary wall: thickening by in situ IC deposits (membranous glomerulopathy; primary, sec.), abnormal substances (DM, amyloid)

Epithelial cells: loss of normal structure (detachment + loss of podocytes, compensatory hypertrophy of remaining cells, fusion of foot processes in minimal change disease; disruption in focal segmental glomerulosclerosis)

# Other clinical presentations

## ■ Isolated proteinuria

- sometimes asymptomatic
- glomerular – damage to filtration membrane
  - selective – proteins w. low-middle molecular weight (albumin)
  - nonselective – more damage, high weight proteins – Ig
- tubular
  - problem in tubular resorption of LMW proteins

## ■ Isolated hematuria

- microscopic x macroscopic

# Progression in glomerular disease

- ↓ GFR (30-50% of normal) → independent progression to RF – ablation nephropathy
- Focal segmental glomerulosclerosis – adaptation – compensatory glomerular hypertrophy (glomerular + systemic hypertension → proteinuria → mesangial proliferation + matrix accumulation → sclerosis)
- Tubulointerstitial fibrosis – proteinuria + ischemia → tubular damage + interstitial inflammation

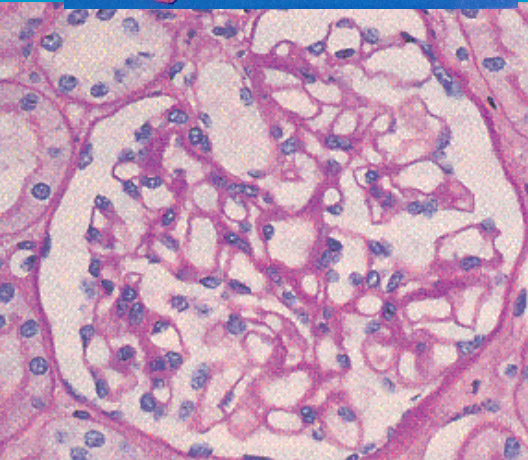
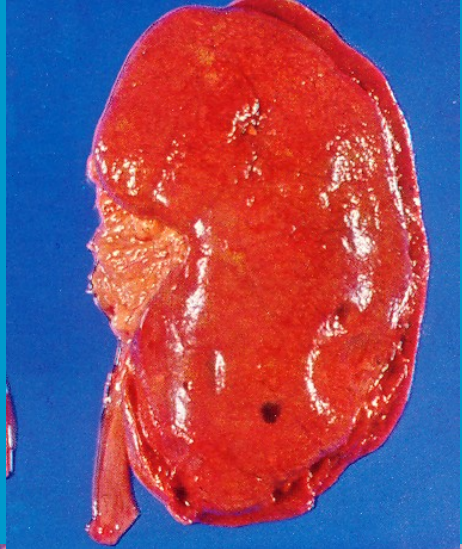


# Clinical presentations


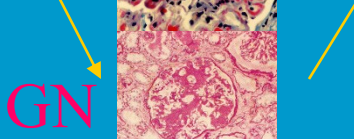
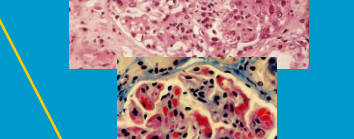
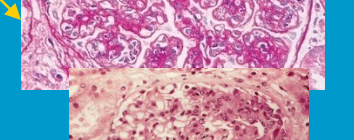
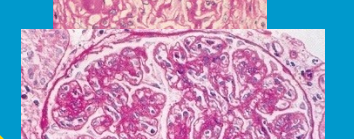
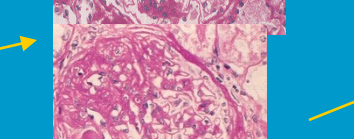
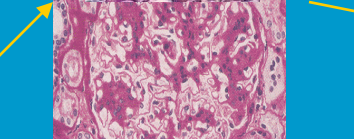
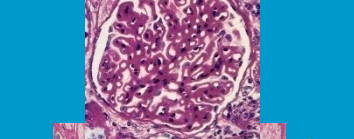
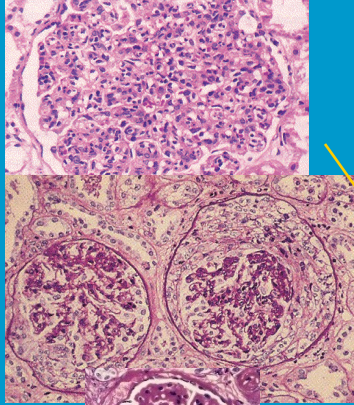
- Acute renal failure – progressive oliguria to anuria, azotemia, metabolic acidosis;
  - prerenal – renal – postrenal
  - with according therapy usually return to function
- Chronic renal failure - prolonged symptoms of uremia, anemia, nausea
  - chronic uremia in irreversible damage
  - most commonly due to DM, hypertension, AS

# GLOMERULAR DISEASES

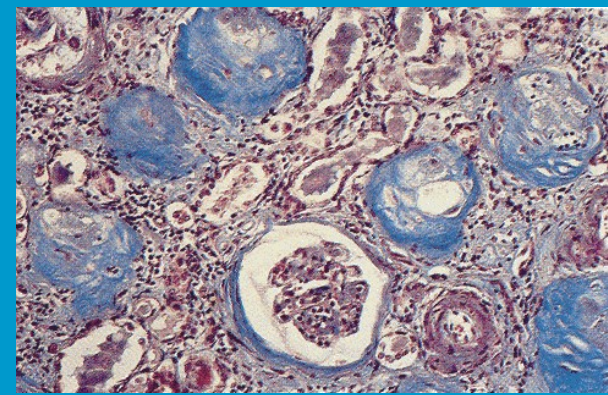
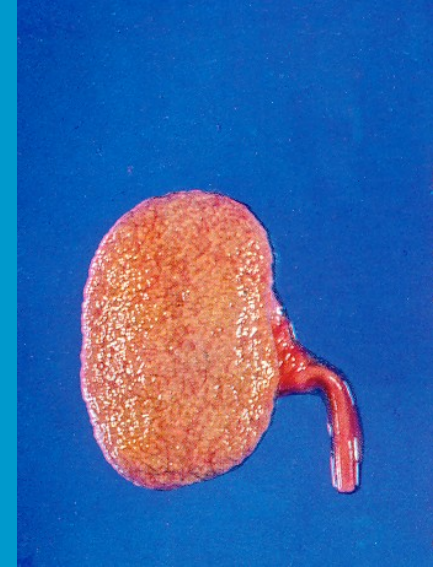
- **PRIMARY GLOMERULAR DISEASE:** kidney as a main affected organ, other clinical signs due to impaired renal function (i.e. minimal change disease)
- **SECONDARY GLOMERULAR DISEASE:** renal injury only a part of systemic disease affecting multiple organs (lung, joints, skin), i.e. SLE, infections (hepatitis C), vascular disorders (vasculitis, HT), tumors, inborn disorders



Normal kidney



GN



Chronic sclerosing GN

# Glomerulopathy

- One histological type may have variable clinical presentation, i.e. membranoproliferative lesion may present as glomerulonephritis with nephritic sy, glomerulopathy with nephrotic sy, or isolated hematuria

# Glomerulopathy with:

- Proteinuria or nephrotic syndrome
- Isolated or predominant hematuria
- Hematuria + proteinuria combined w. renal failure
- Glomerulopathy due to vascular diseases
- Glomerulopathy in systemic lupus
- Chronic glomerulopathy



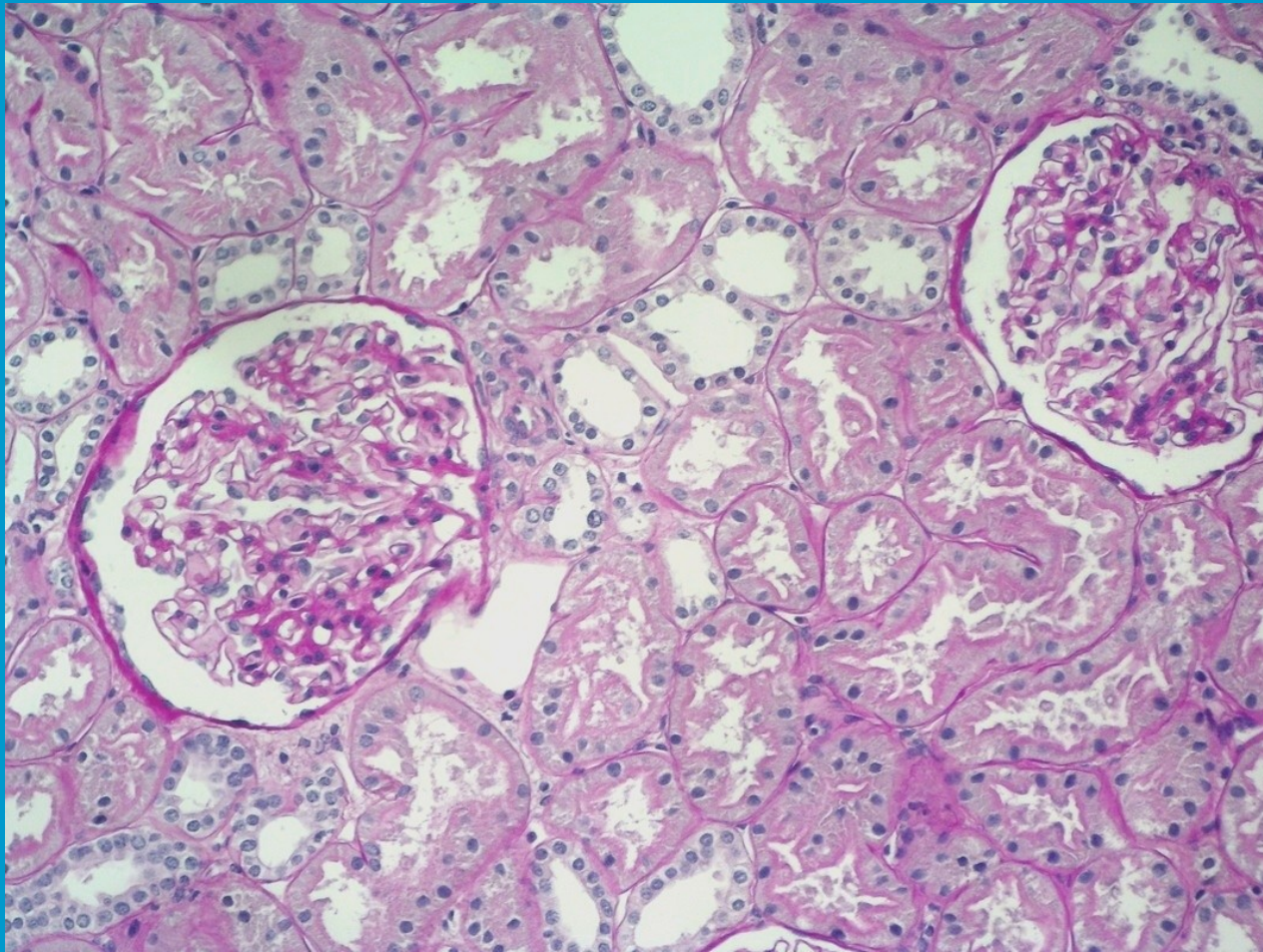
# Glomerulopathy with proteinuria or nephrotic syndrome

- Minimal glomerular change disease
- Focal segmental glomerulosclerosis
- Membranous glomerulopathy
- Amyloidosis
- Diabetic nephropathy

# Minimal change disease

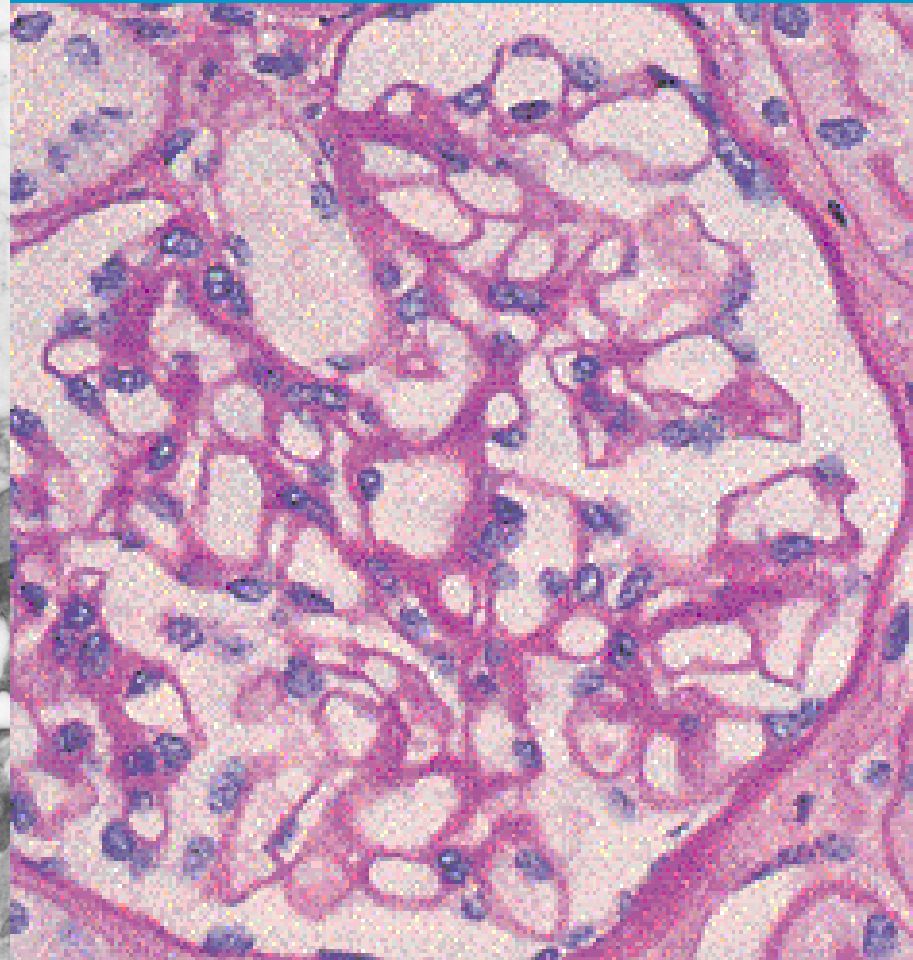
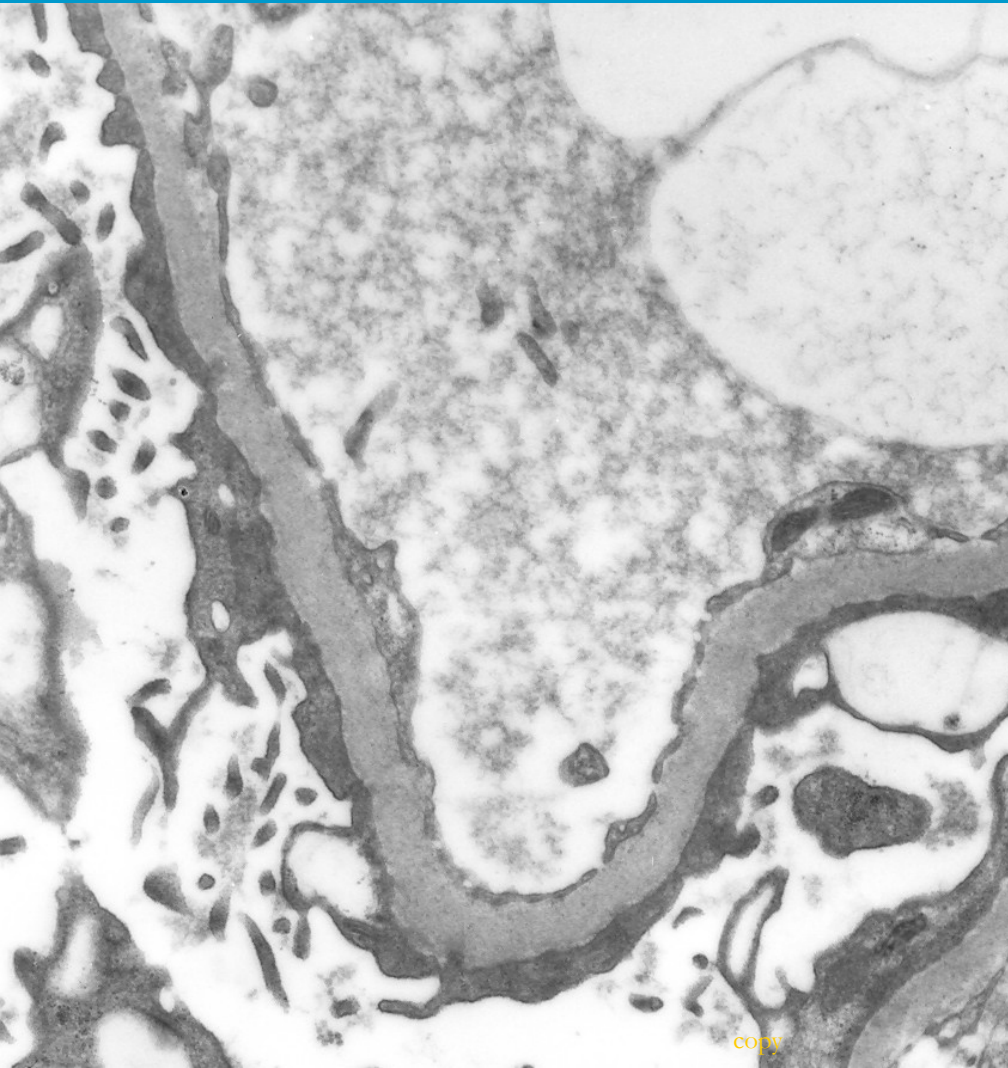
- Most common cause of nephrotic sy in children
- heavy selective proteinuria - albuminuria
- mostly in children  $\leq 5$  yrs
- in adults commonly associated w. NSAID, ML
- Light microscopy + IMF normal
- Genetic predisposition + immunological basis (association with respiratory infection, atopy, Hodgkin lymphoma)
- Epithelial cell injury – effaced foot processes
- Steroid therapy, good prognosis in children, in adults necessity of biopsy – dif. dg.

# Minimal change disease



# Minimal change disease

Loss of epithelial foot processes in elmi, fat in tubular epithelia  
(„lipoid nephrosis“)





# Focal segmental glomerulosclerosis

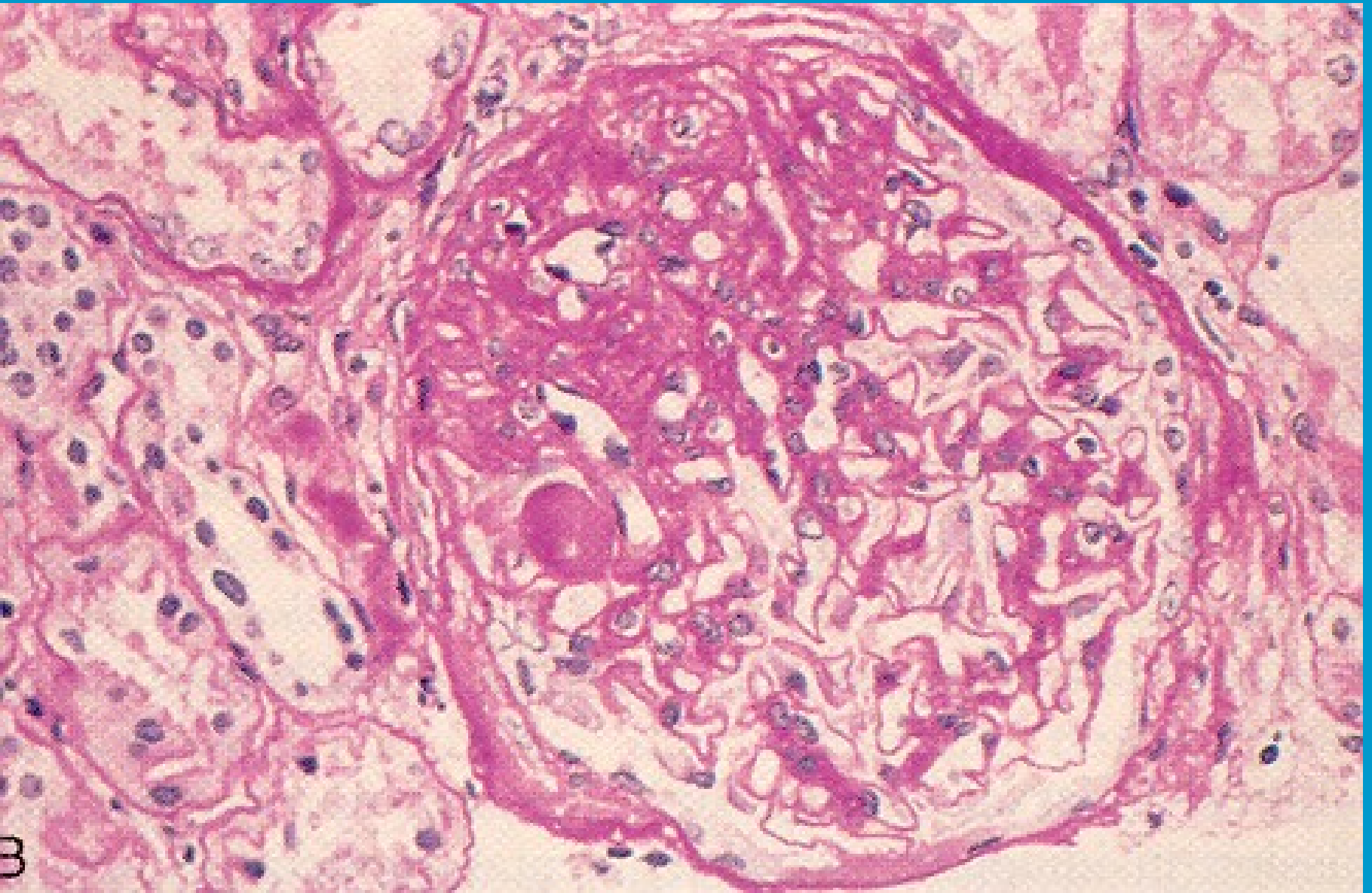
- Nephrotic sy, ↑ incidence, any age
- Hematuria, ↓ GFR, proteinuria non-selective
- Progression usual – 50% → RF in 7 years, steroid-resistant
- Primary
  - idiopathic,
  - variable podocyte protein mutations, plasma factor ↑ permeability (soluble urokinase receptor?), apolipoprotein L1 mutations (black African descent)
- Secondary: late part of adaptive response to preexisting renal disease (renal ablation - reflux nephropathy, hypertension, glomerulopathies – IgA, SLE,...)
- Association with other diseases (HIV, obesity, toxins – heroin, drugs)



# FSGS

- epithelial damage
- hyalinosis (plasma protein leakage), foamy macrophages
- segmental sclerosis (mesangial matrix production, capillary loops collapse)
- No immune deposits on IF
- Podocyte injury on EM

# Focal segmental glomerulosclerosis



# Membranous glomerulopathy

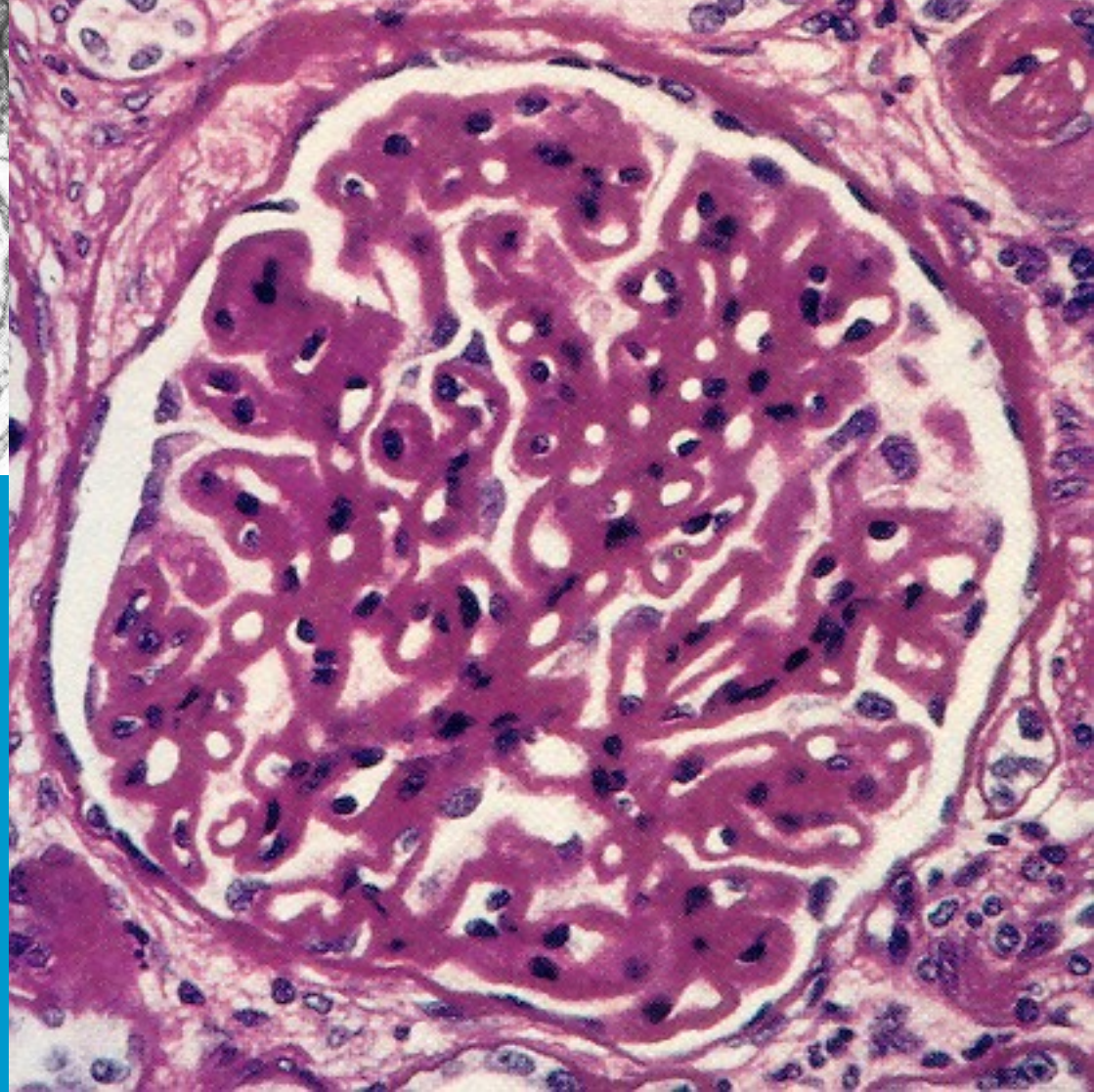
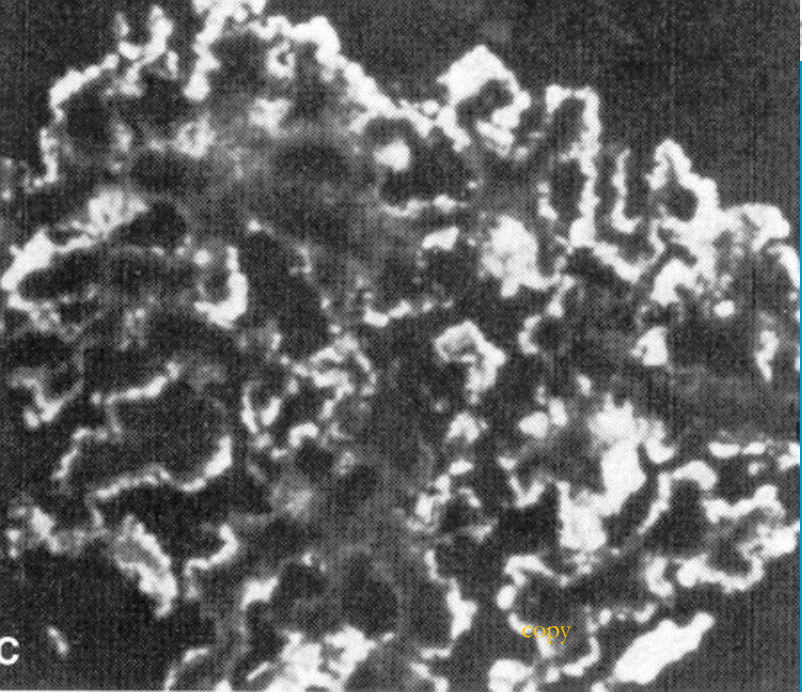
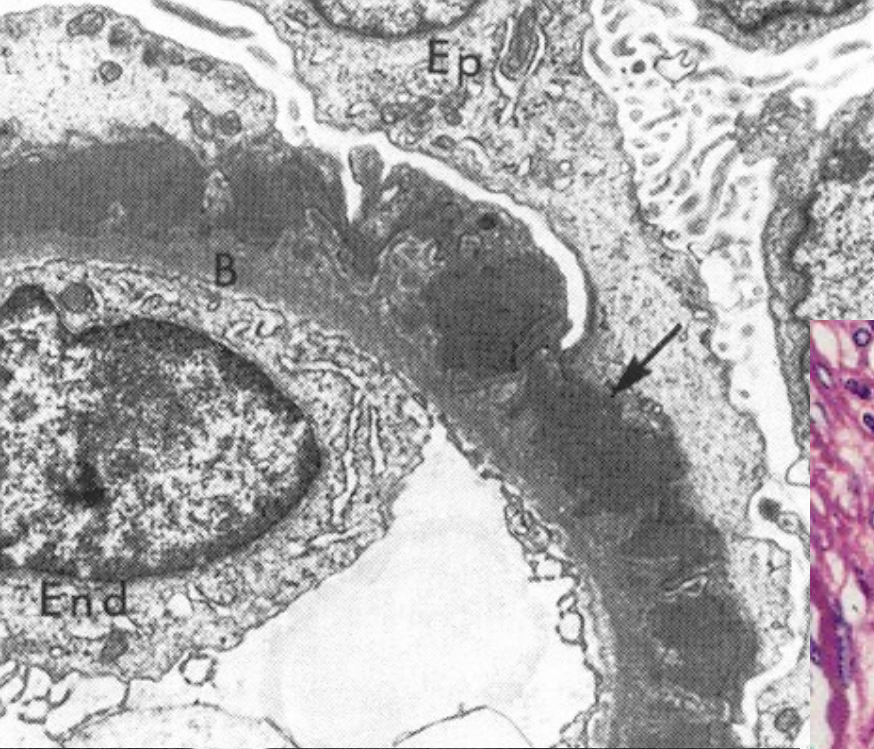
- primary: autoimmune
- mostly older adults – most common nephrotic sy in this age group
- Ab x specific receptor in podocytic membrane antigen – phospholipase A2 receptor
- proteinuria or nephrotic sy, variable course, 1/3 RF
- diffuse global glomerulopathy
- thickening of capillary wall, subepithelial IC deposits, „spikes“ - BM material in impregnation
- no increased glomerulus cellularity

# Membranous glomerulopathy

- secondary – infections (HBV, HCV, syphilis, malaria)  
tumors (lung ca, colorectal ca, melanoma), drugs (NSAID),  
autoimmune diseases (SLE, thyroiditis)
- ! older patients may have both tumor **AND** autoimmune  
MGN



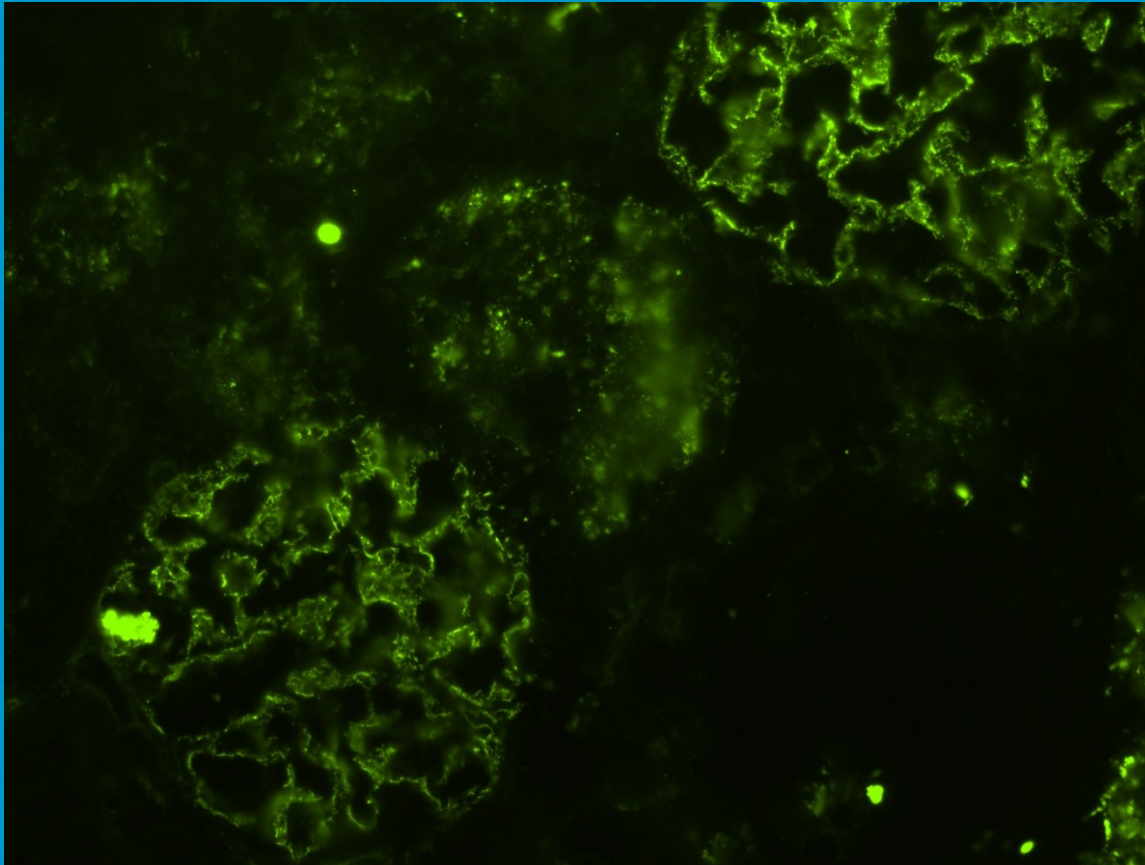
# Membranous glomerulopathy





# Membranous glomerulopathy

granular IgG deposits



# Diabetes mellitus and kidneys

- **Nonenzymatic glycosylation** of proteins – accumulation of irreversible glycosylation products in BM of vessel walls, **metabolic defect** – increased collagen synthesis, **hemodynamic changes**
- **Diabetic microangiopathy** in kidney (glomerulosclerosis) and retina (diabetic retinopathy). Diffuse thickening of capillary BM leads to ischemic changes, simultaneously increased plasmatic proteins permeability, PAS+ mesangial matrix increase; glomerular enlargement

# Diabetic nephropathy

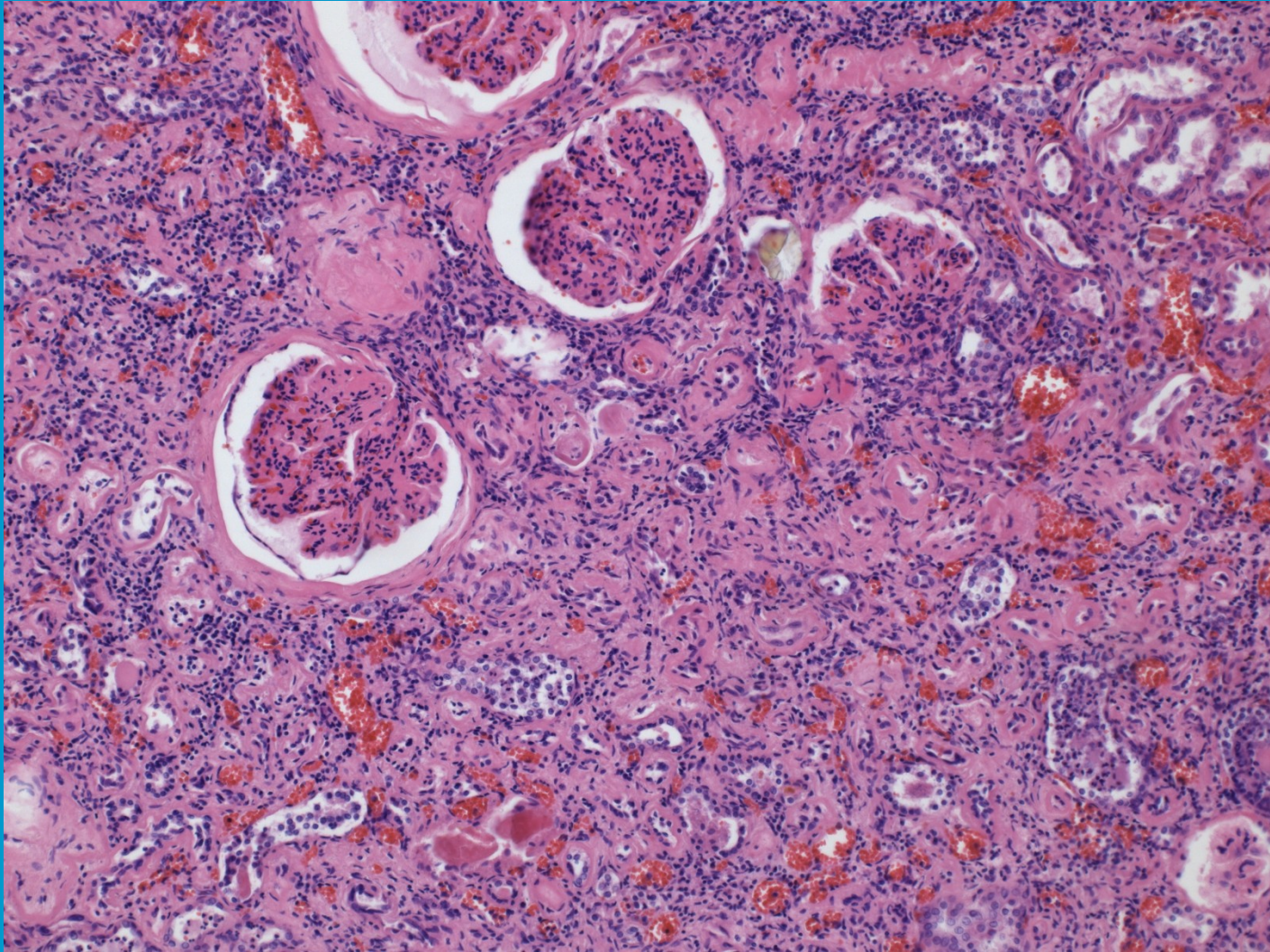
- **Diabetic microvascular disease**
- **Clinically:** non-nephrotic proteinuria, nephrotic syndrome, chronic renal failure
- **Morphology:** glomerulosclerosis (diffuse mesangial, nodular), hyalinizing arteriolar sclerosis, tubulointerstitial lesions (steatosis and glycogenation of tubular epithelium, pyelonephritis, papillary necrosis)
- the most common causes of chronic RF
- 40 % of diabetics will have nephropathy

# Diabetic glomerulosclerosis

- **Diffuse glomerulosclerosis** – GBM thickening, increase in mesangial matrix + cellularity
- **Nodular glomerulosclerosis** - (Kimmelstiel-Wilson) after 10-15 yrs; PAS+ nodular acellular material deposits at the tips of capillary loops; leads to chronic renal insufficiency
- no immune deposits in IMF

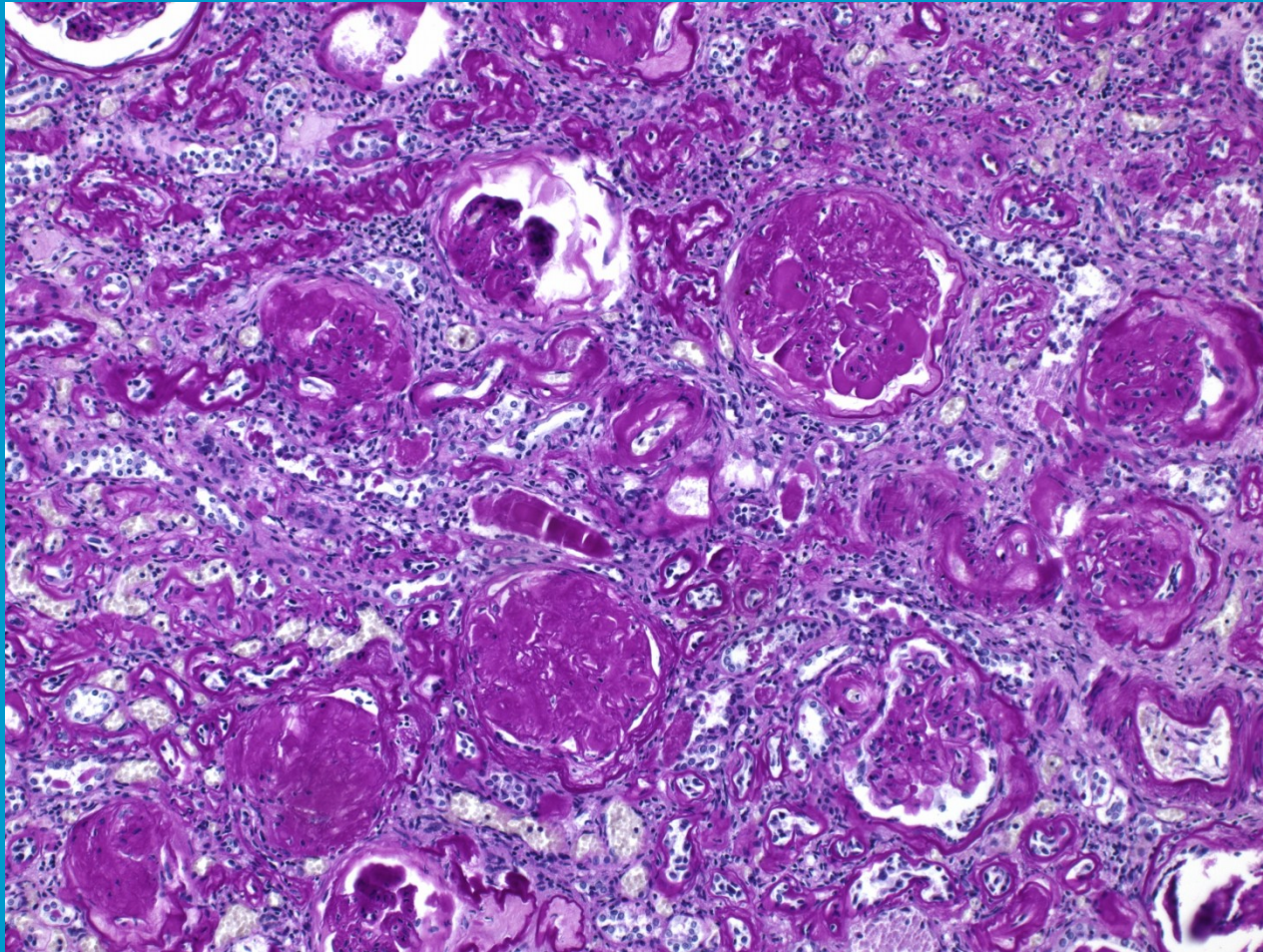


# Diabetic glomerulosclerosis



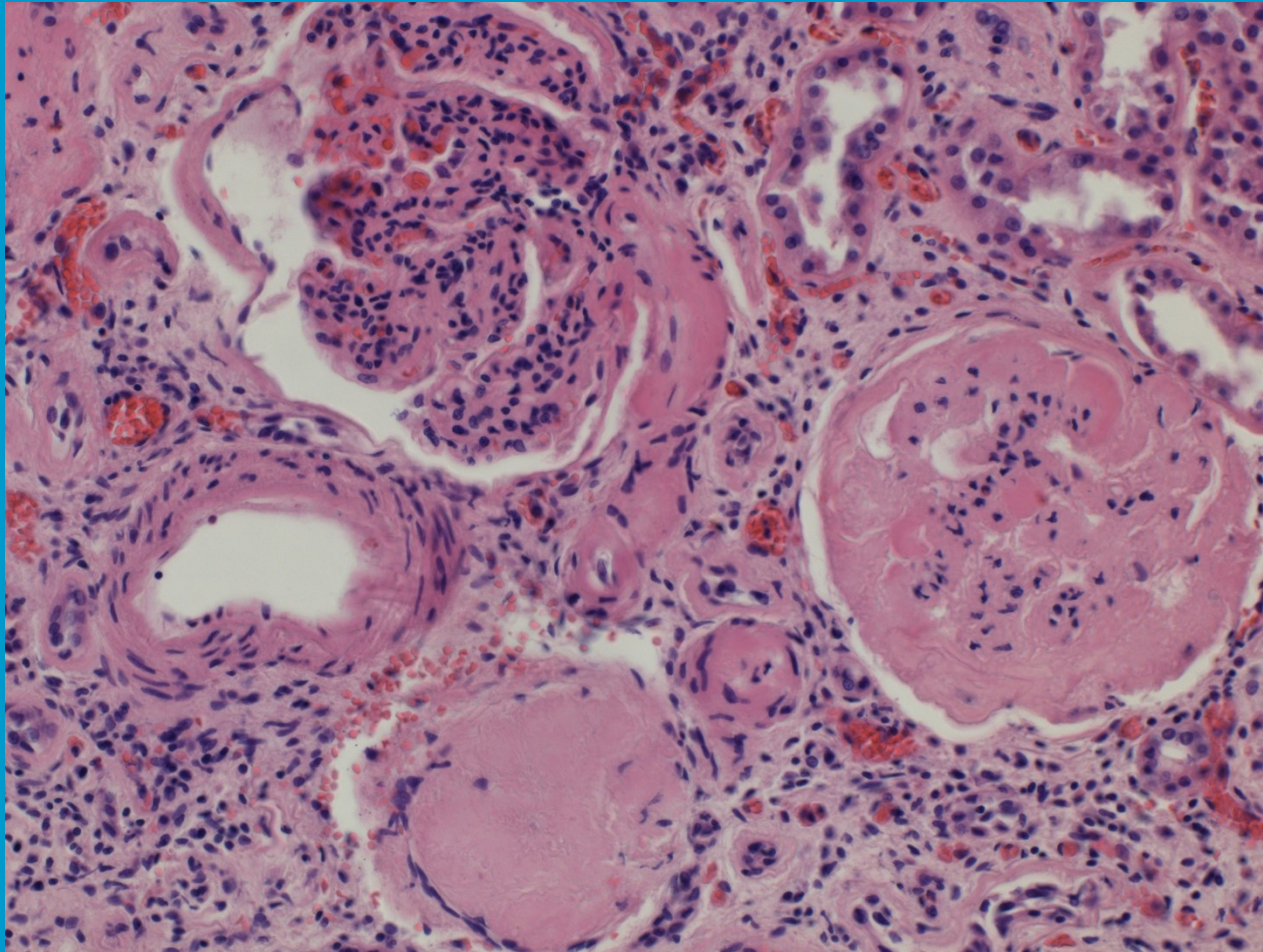


# Diabetic glomerulosclerosis

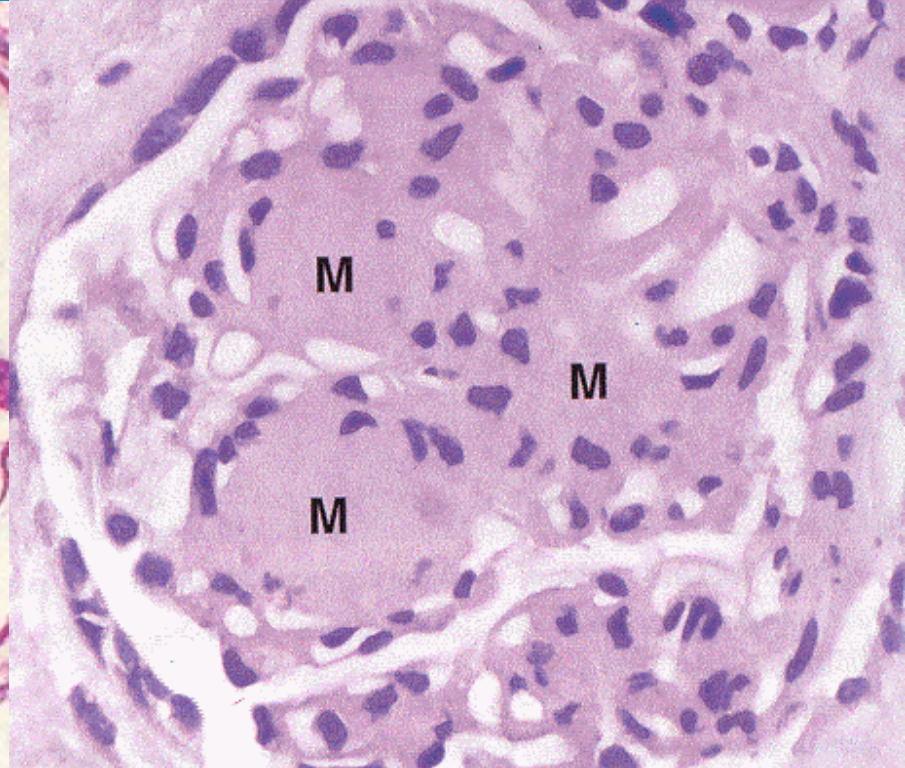
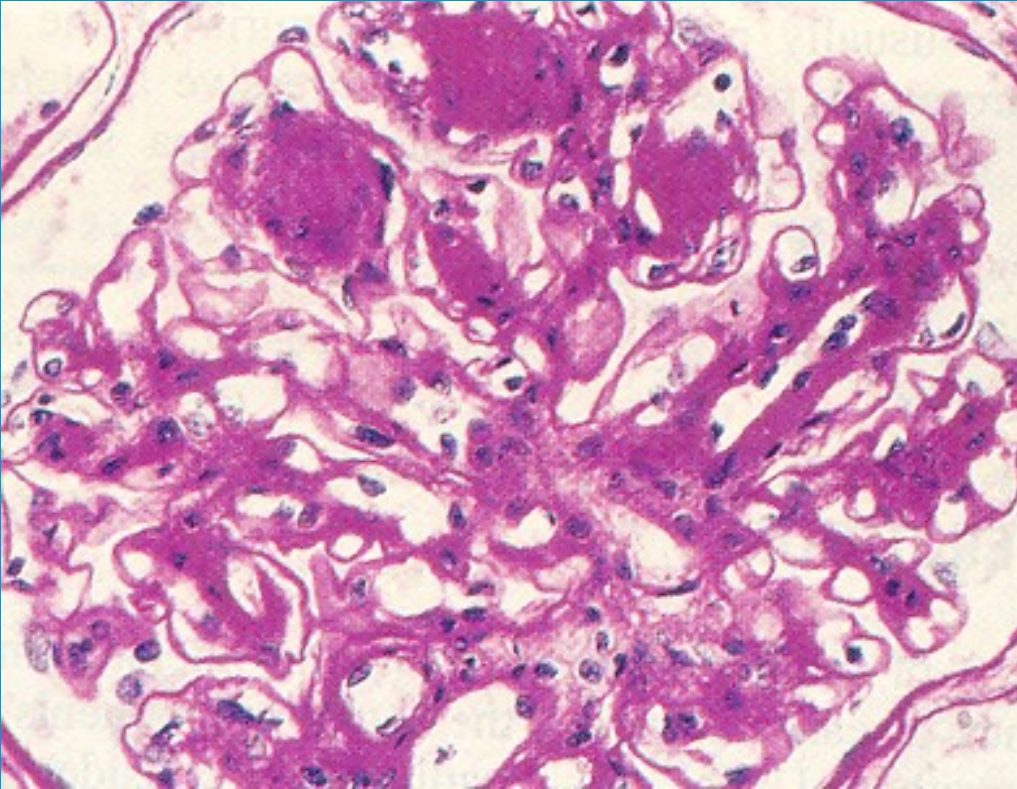




# Diabetic glomerulosclerosis







### Diabetic glomerulosclerosis

Further renal complications in diabetics

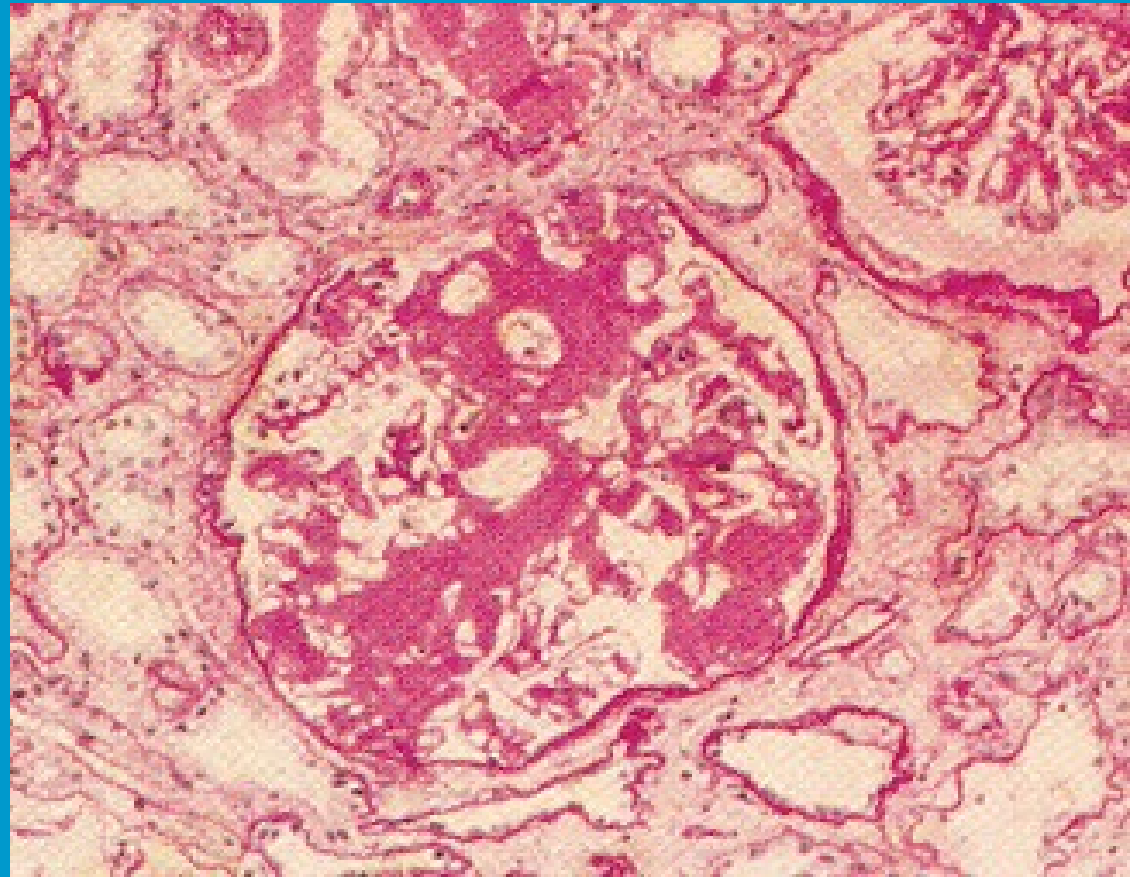
- accelerated arteriolosclerosis and arteriosclerosis, hypertension
- Pyelonephritis
- Renal papillary necrosis in acute PN

# Renal amyloidosis

- Amyloidosis – pathologic deposits of abnormal microfibrillary (8-10nm) proteinaceous acellular material
- Eosinophilic in HE, Kongo red +, green dichroism in polarised light
- Firm pale enlarged kidney in macroscopy

# Renal amyloidosis

- Amyloid deposits in glomerular mesangial matrix and capillary walls; glomerular obliteration
- Peritubular and blood vessel walls
- Proteinuria
- Nephrotic syndrome
- CHRI



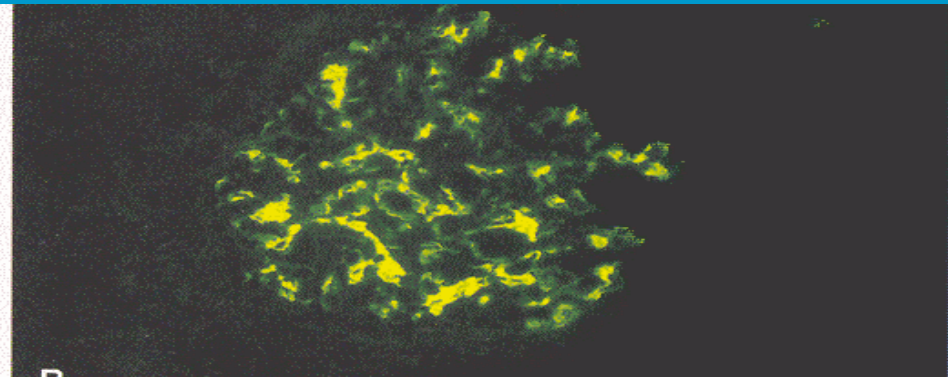
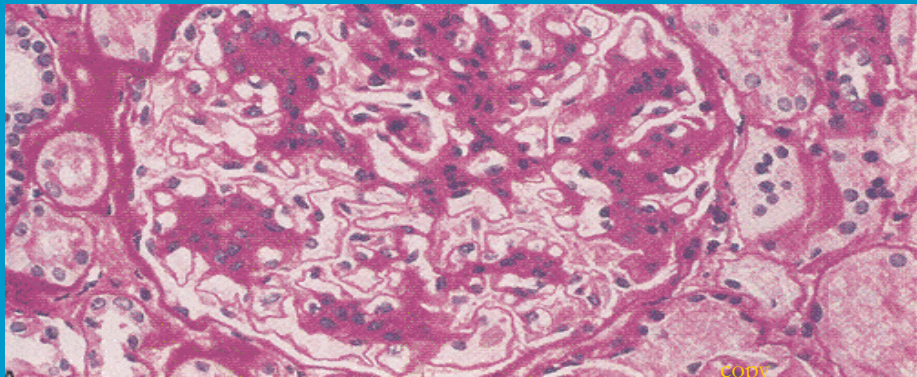


# Glomerulopathy with hematuria

- **Primary:** IgA nephropathy (Berger's disease)
  - Alport syndrome / thin basement membranes sy
- **Secondary (systemic):** some types of SLE
  - Henoch-Schönlein purpura

# IgA nephropathy

- Recurrent hematuria, children and young adults w. genetic predisposition, after GIT, respiratory tract, urinary tract infections, may → RF; most common cause of RF in primary glomerulopathies
- variable course, recurrence after kidney transplantation
- IgA and C3 mesangial deposition, mesang. cells and matrix proliferation, segmental glomerulosclerosis
- Abnormal increase/pathologic form of IgA production, AAxIgA – IC; ↓ clearance of IC in cirrhosis



# IgA nephropathy

- changes of IgA nephropathy present in Henoch-Schönlein purpura – IgA vasculitis
- preexisting respiratory infection
- purpura due to vasculitis w. IgA deposits (+ skin rash, GIT hemorrhage, arthritis)
- in children regeneration, in adults possible RF

# Alport syndrome

- Part of collagen IV glomerulopathies
- genetic disorder, 90% X-linked, AR or AD
- abnormal basement membranes (lamina densa), later FSGS, tubular atrophy, interstitial fibrosis
- manifestation mostly in kidney (hematuria – nephritis, proteinuria), RF;
- HD, transplantation
- ear – deafness
- eye – lens + cornea disorders, cataract

# Thin basement membrane

- benign familial hematuria, no progression to RF
- common inherited lesion – hereditary nephropathy
- heterozygous carriers of collagen IV mutations or less dangerous collagen IV mutations
- without other problems (ocular, ...)
- differential diagnosis



# Glomerulopathy w. acute nephritic sy

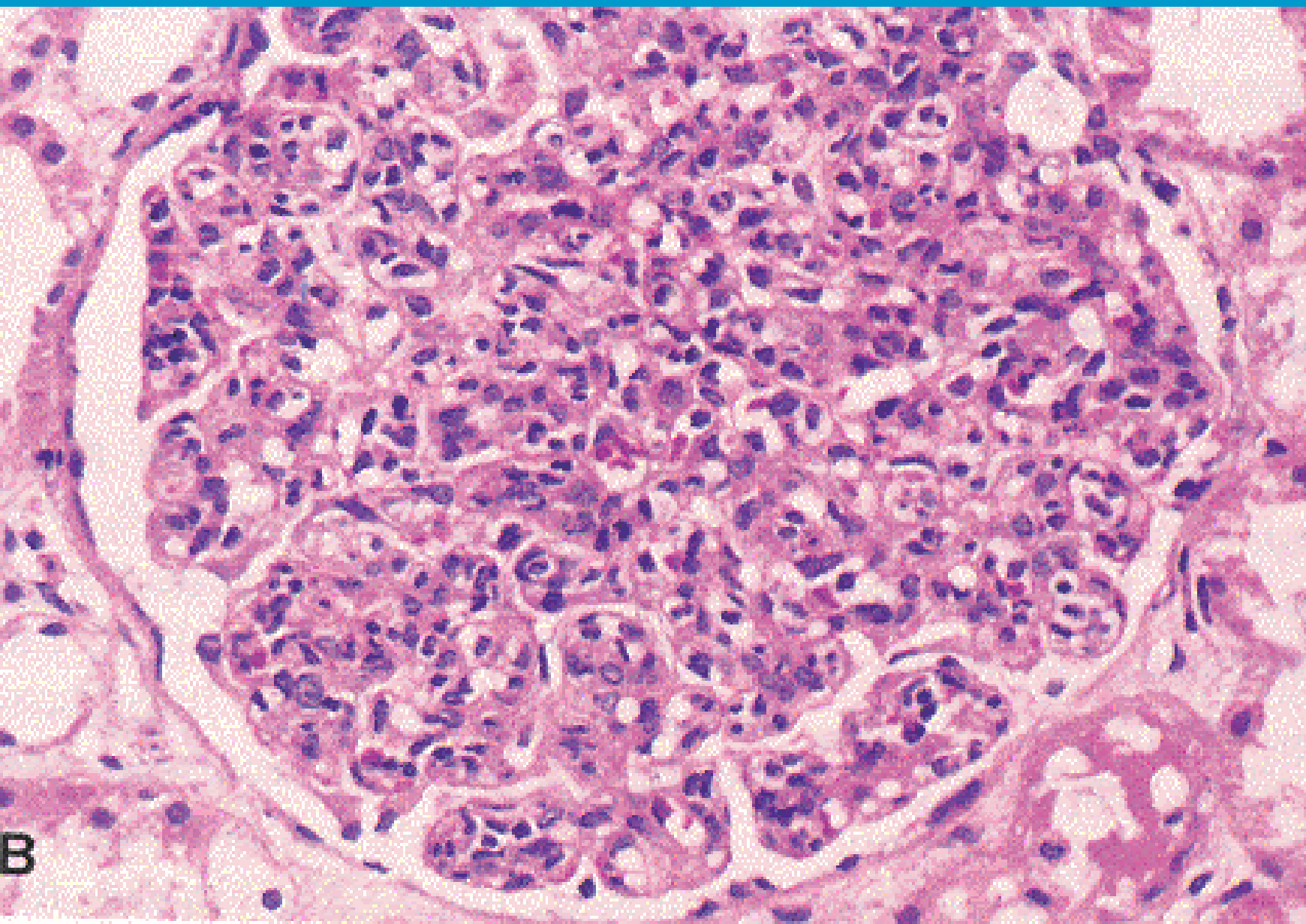
proliferative GN w. increased mesangial/ endocapillary cellularity, commonly crescentic

- acute (diffuse endocapillary) proliferative GN
- membranoproliferative GN (C3, prim. IC),
- rapidly progressive GN
- secondary mostly in vasculitis – SLE, microscopic polyangiitis  
granulomatosis with polyangiitis (Wegener)





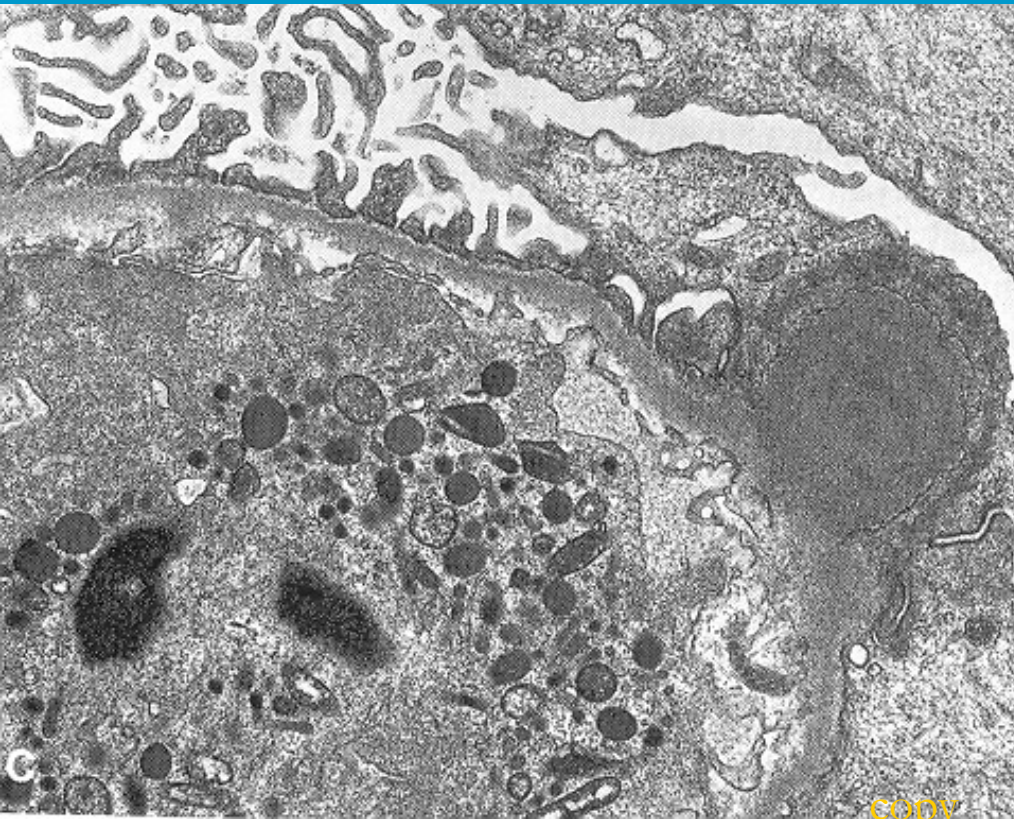
# Diffuse proliferative GN



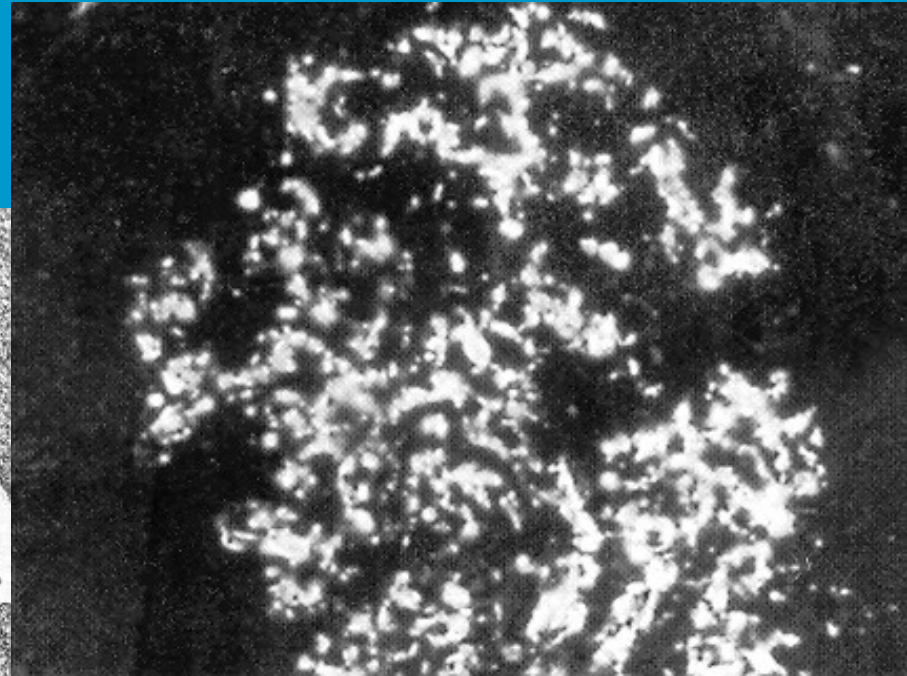
# Diffuse proliferative GN

subepithelial immune complex deposition,  
postinfective

Elmi  
„humps“



Immunofluorescence



granular deposits in IgG and C3

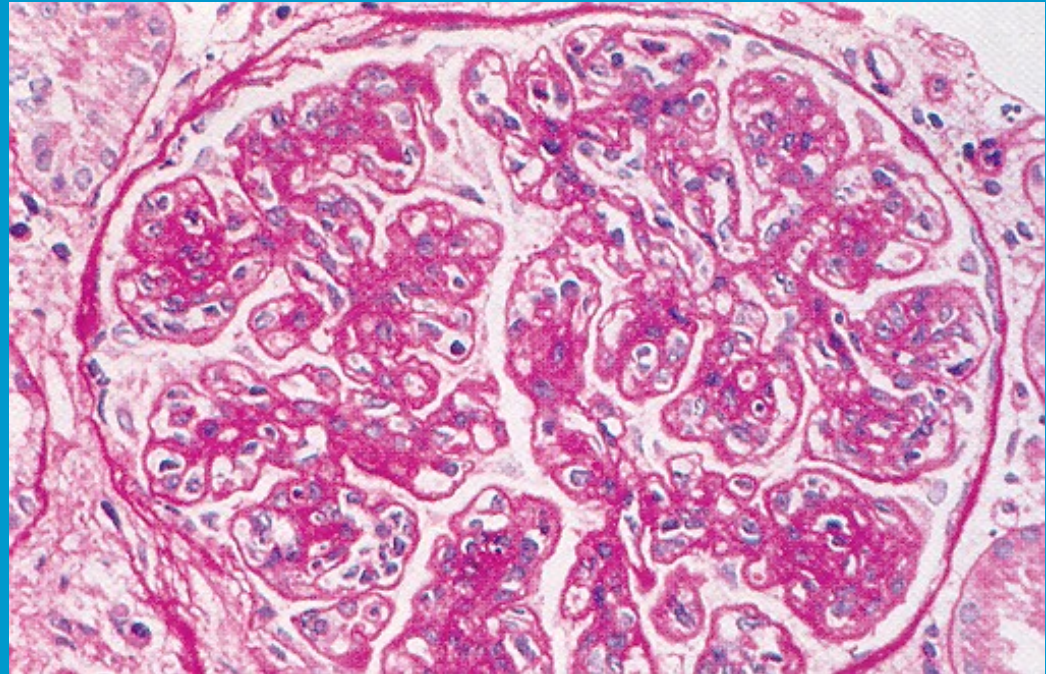


# Membranoproliferative GN

- formerly type I-III MPGN
- **Now:** a group of disorders w. complement abnormalities
  - C3 part of complement present in biopsy, dysregulation, inflammation
- Immune complexes GN
  - inflammatory diseases w. proliferative GN, IMF IgG+, C3+
  - IC: cryoglobulinemia (80% due to HCV); SLE, HIV; malignancy (CLL, ML), alpha1- AT deficiency),
- C3 nephropathy (C3 GN and dense deposit disease)
- young, poor progn., CHRI, recurrent in graft

# Membranoproliferative GN

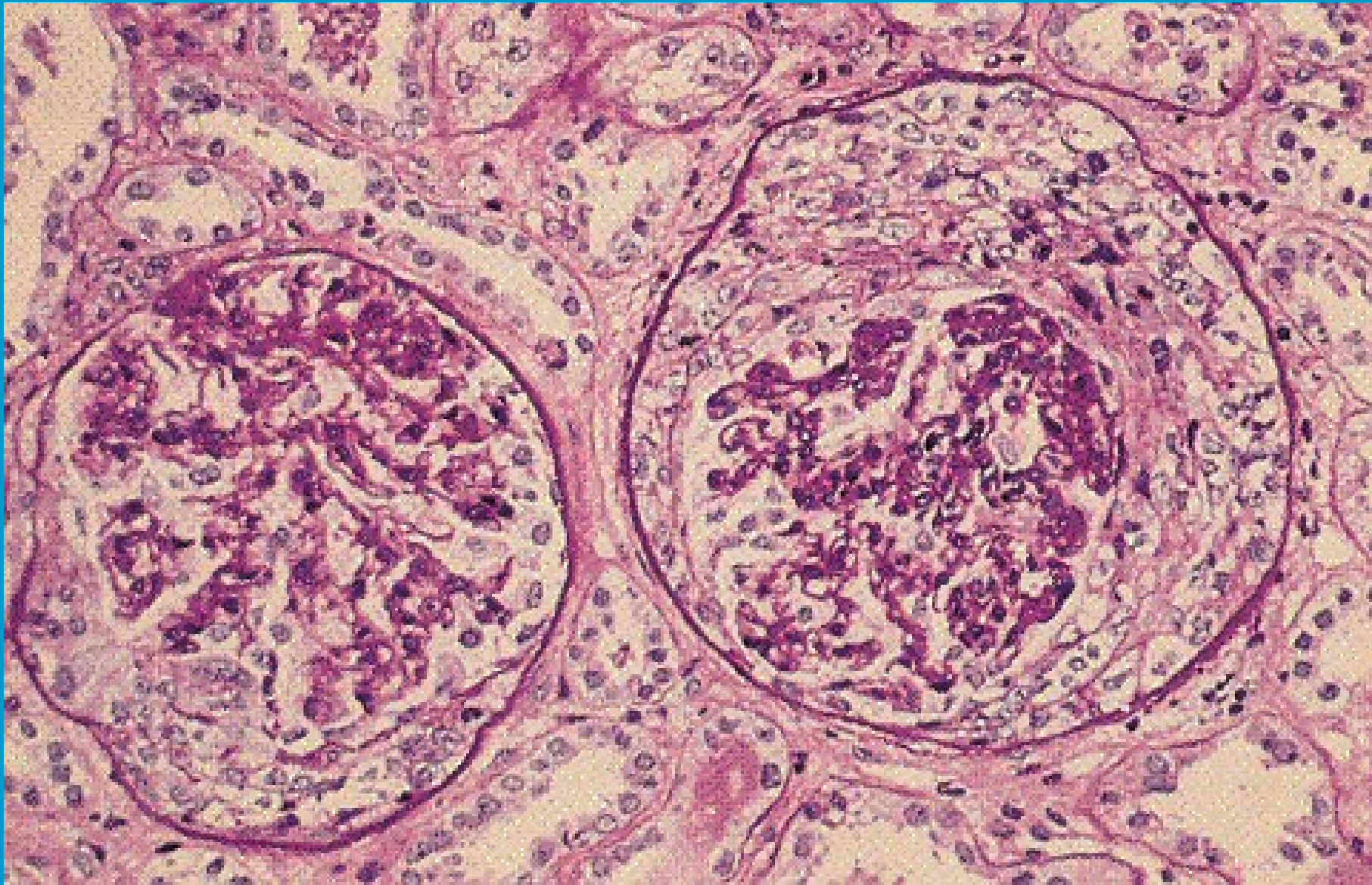
- diffuse mesangial + endothelial cells activation and proliferation (mesangiocapillary GN), mesangial matrix expansion, BM thickening – „duplication – tram-track“



# Rapidly progressive (crescentic) GN

- clinically rapidly progressive GN,
- various etiology (immune-complex mediated incl. IgA, pauci-immune + ANCA, anti-GBM)
- small vessel vasculitis, SLE,...
- necrotising GN – capillary rupture, exudation – extracapillary proliferation - crescentic
- Immunosuppression in active lesion + plasma exchange in known circulating AB (anti-GBM)
- No direct therapy in fibrosing lesion

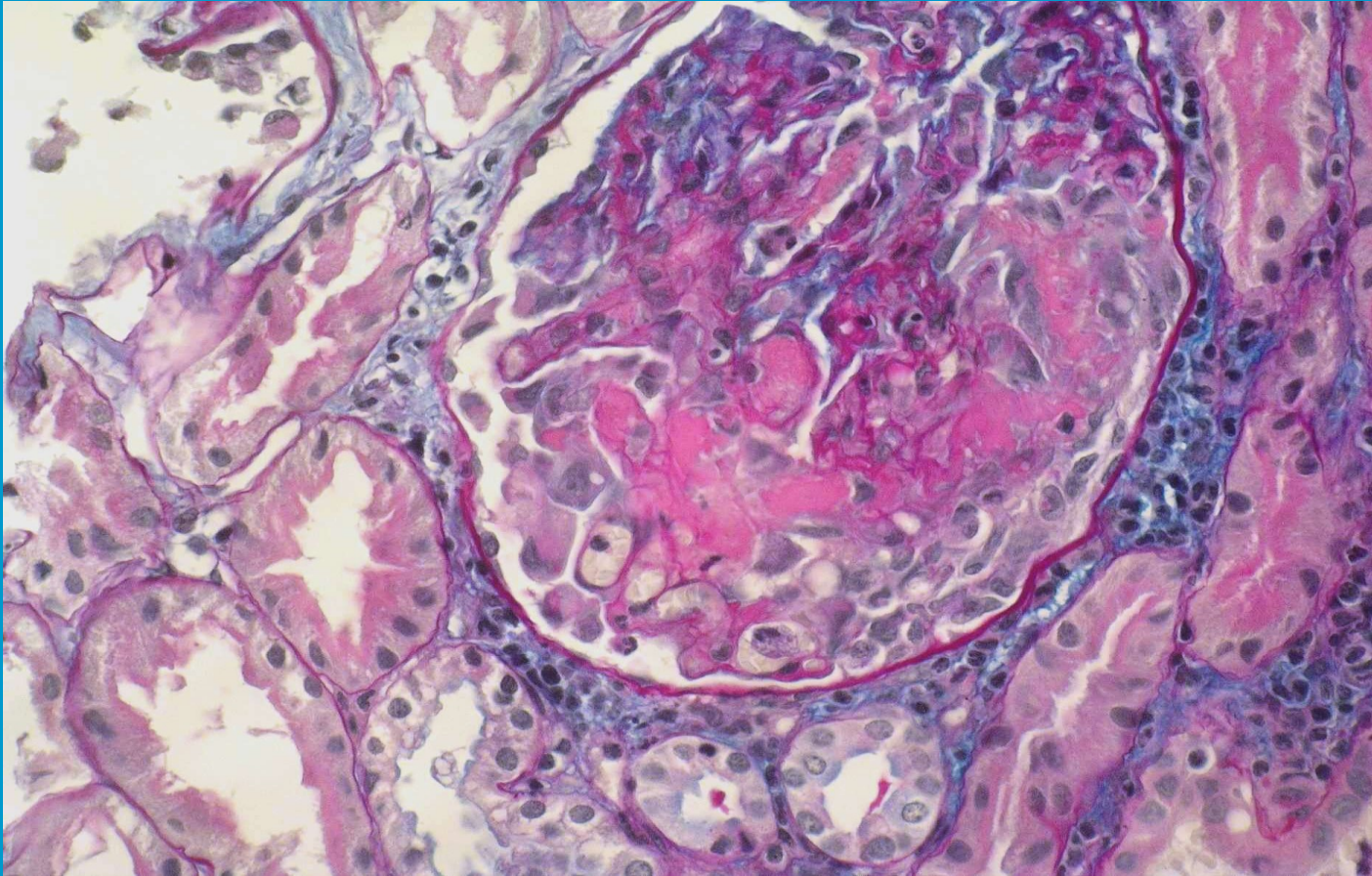
# Rapidly progressive (crescentic) GN





# Rapidly progressive (crescentic) GN

fibrinoid necrosis, fibrin in a cellular crescent





# Anti-GBM disease

- uncommon
- rapidly progressive renal failure +/- hemoptysis (Goodpasture sy)
- linear deposits of IgG

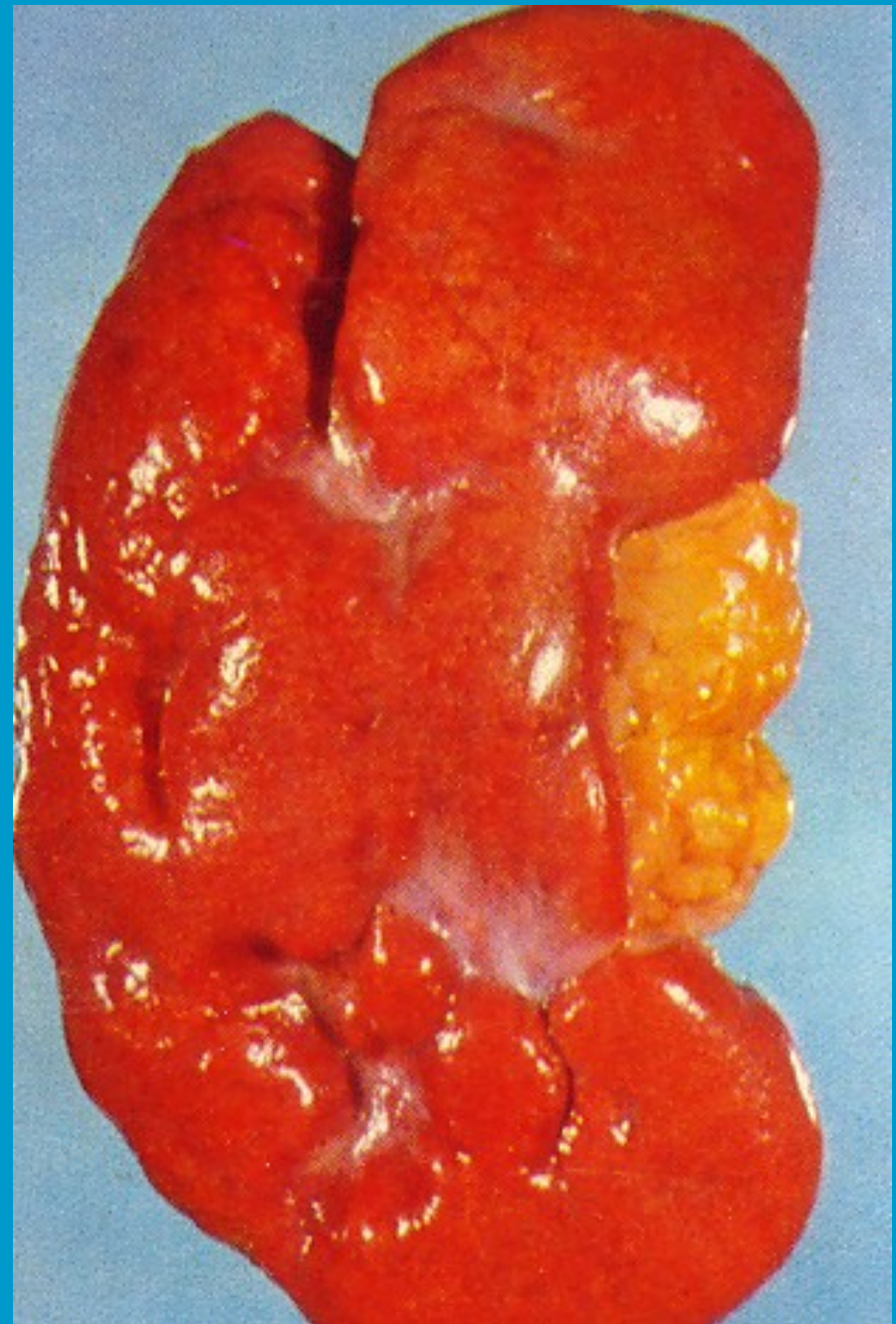
# Glomerulopathy due to vascular disorders

- in hypertension
- renal infarction
- renal artery stenosis
- thrombotic microangiopathy (HUS, thrombotic thrombocytopenic purpura)
- systemic vasculitis (ANCA+, microscopic polyangiitis, anti-GBM GN)

# Nephropathy in hypertension

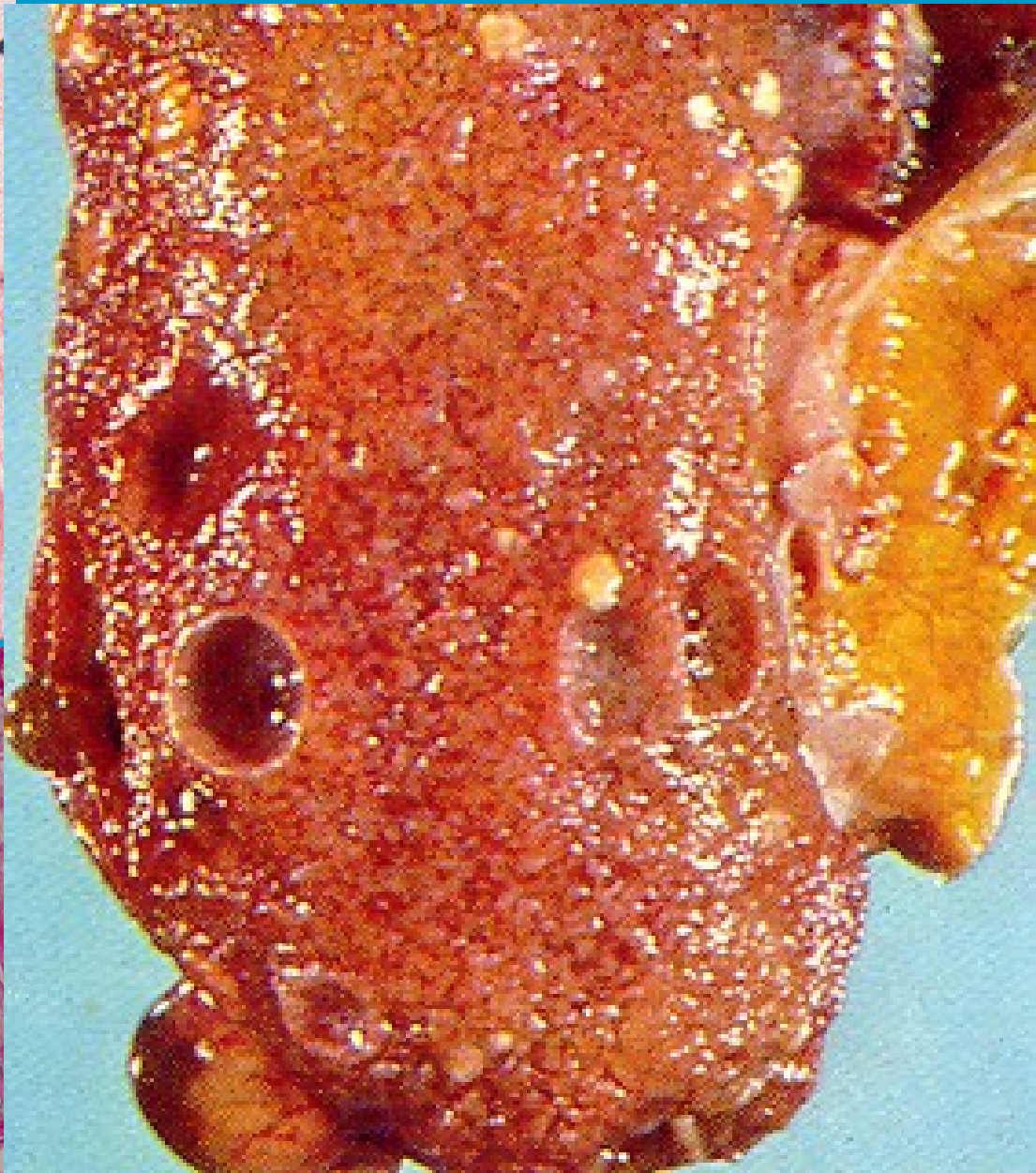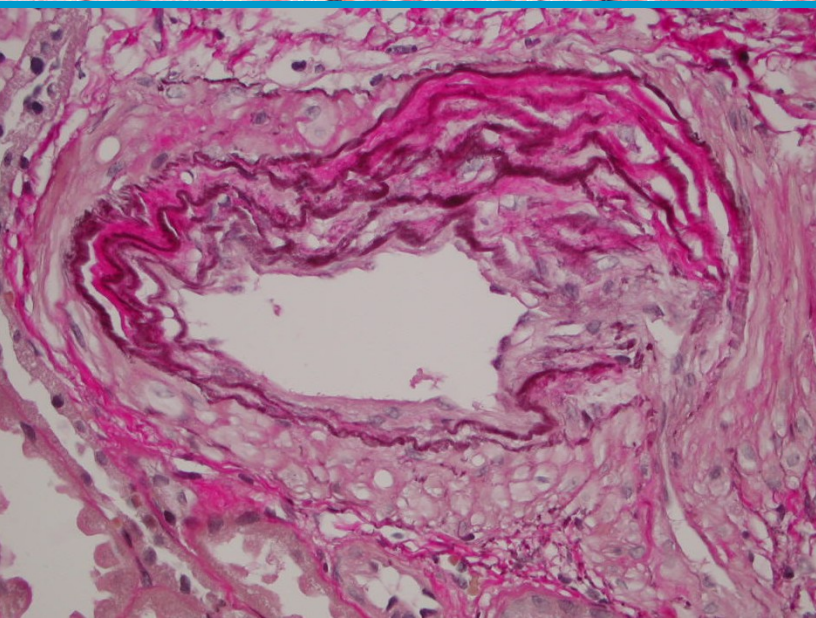
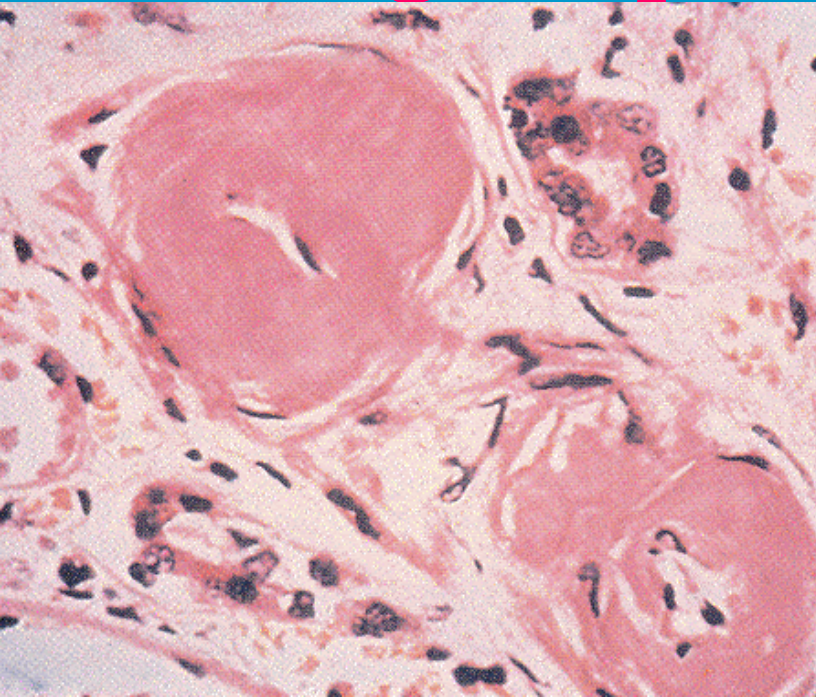
- Benign nephrosclerosis= compensated hypertension
  - macro: decreased size, granulated surface, atrophic cortex 2-3 mm
  - micro: hyaline insudation on arteriolar wall, arteries w. hypertrophic media, intimal sclerosis, glomerular ischemic changes + loss, tubular atrophy, interstitial fibrosis
  - GBM wrinkling

# Benign nephrosclerosis



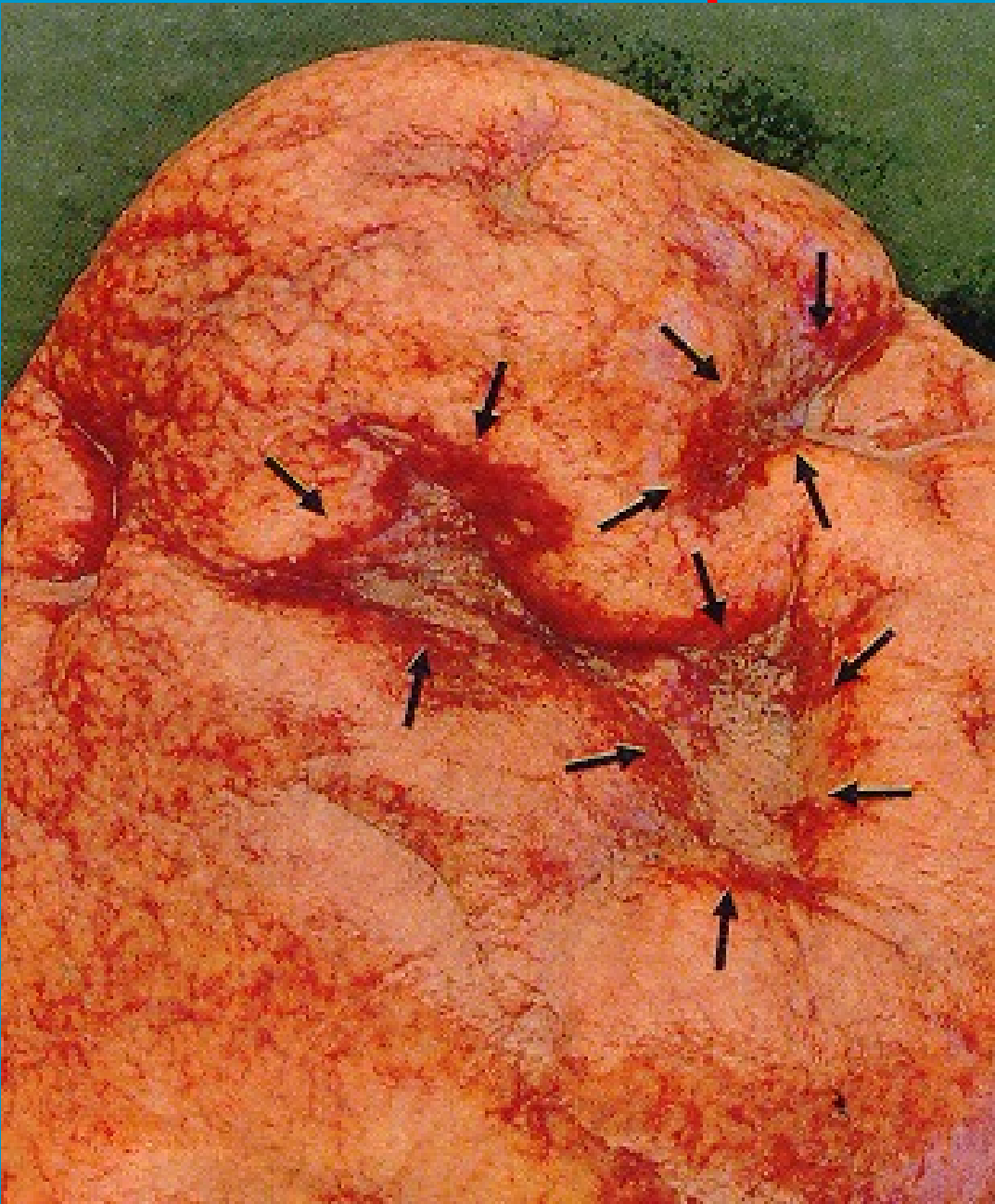


# Benign nephrosclerosis arteriolosclerotic



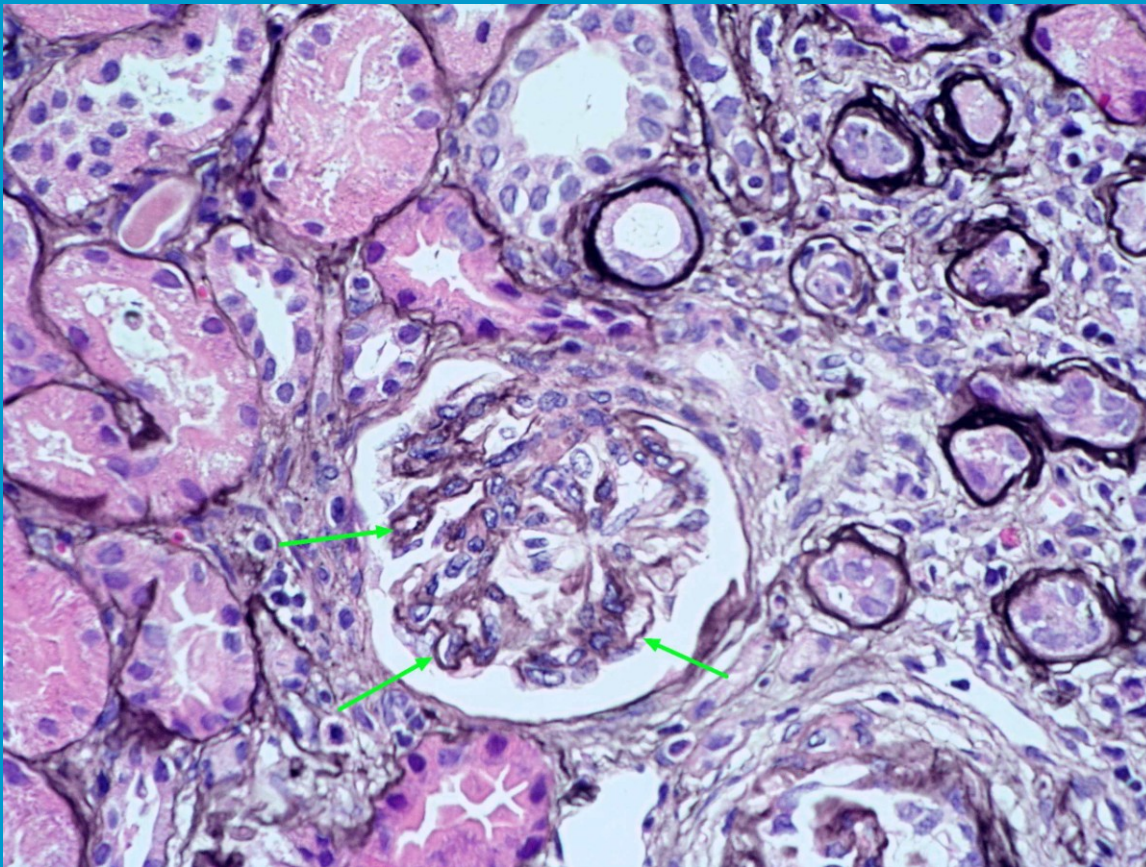


# Nephrosclerosis



granulations  
and post-infarct  
scars

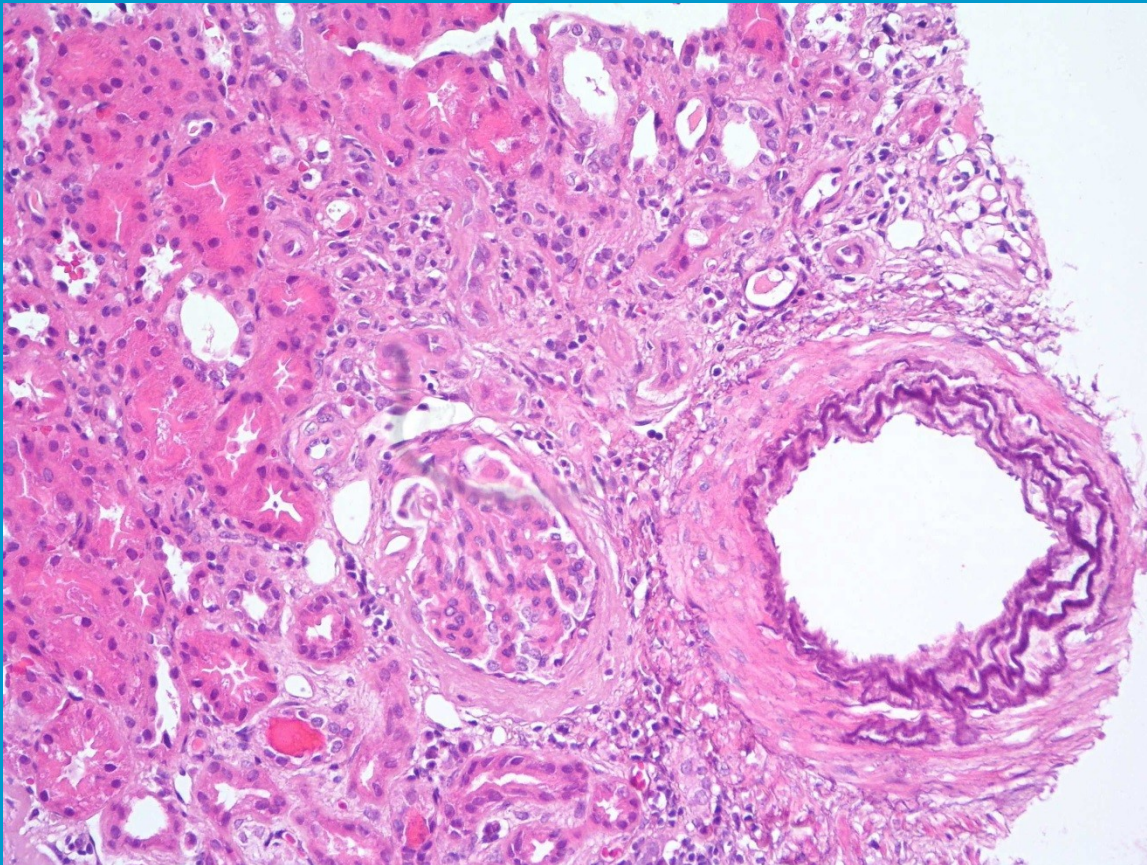
# Nephrosclerosis



GBM  
wrinkling, G  
ischemic  
changes



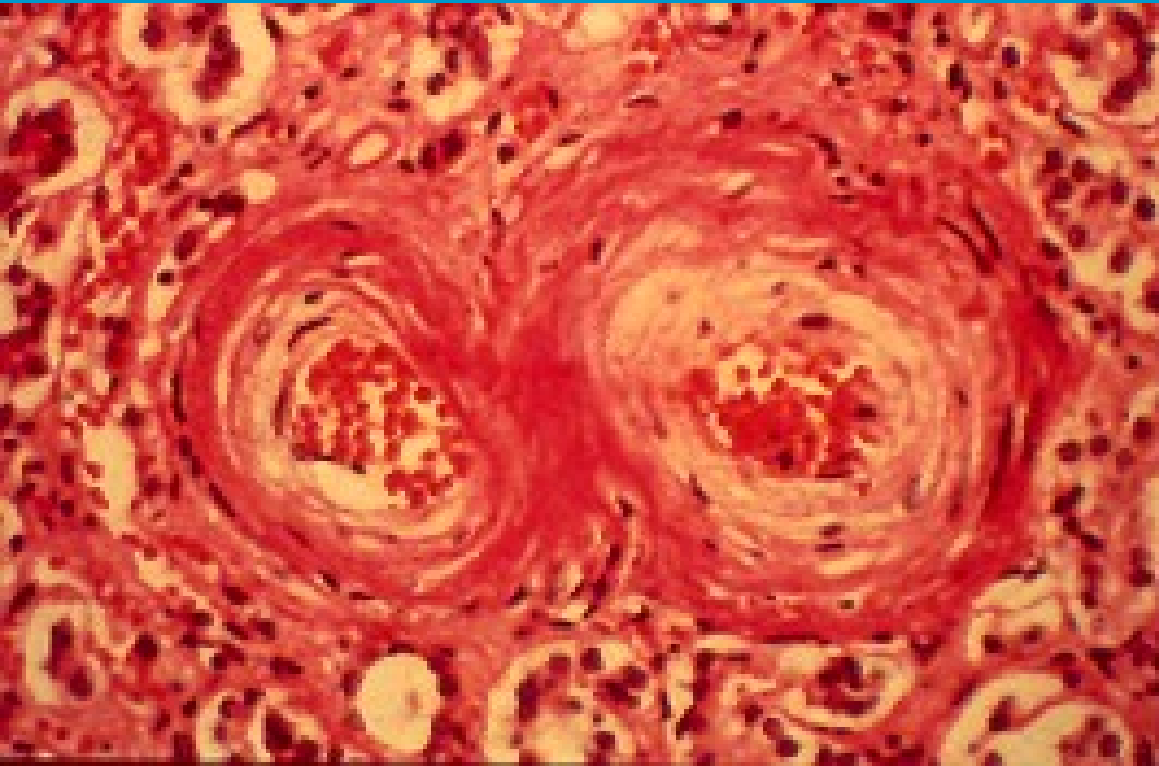
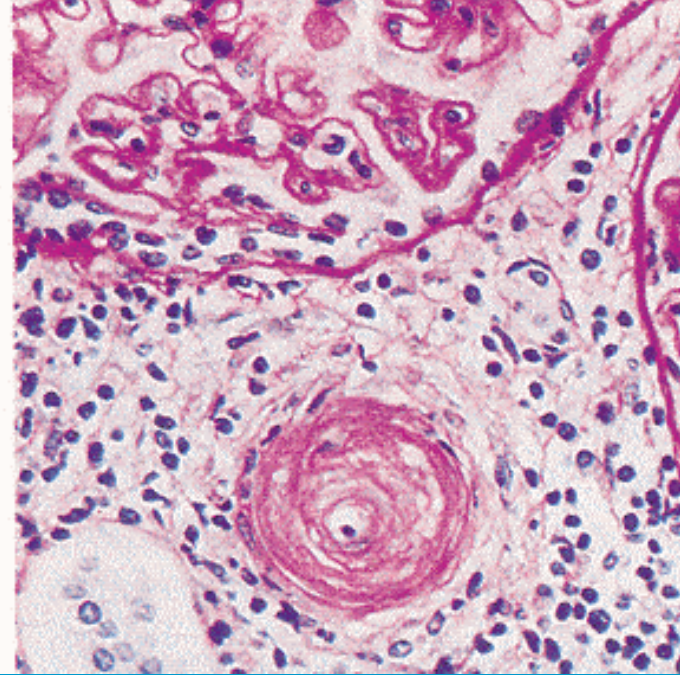
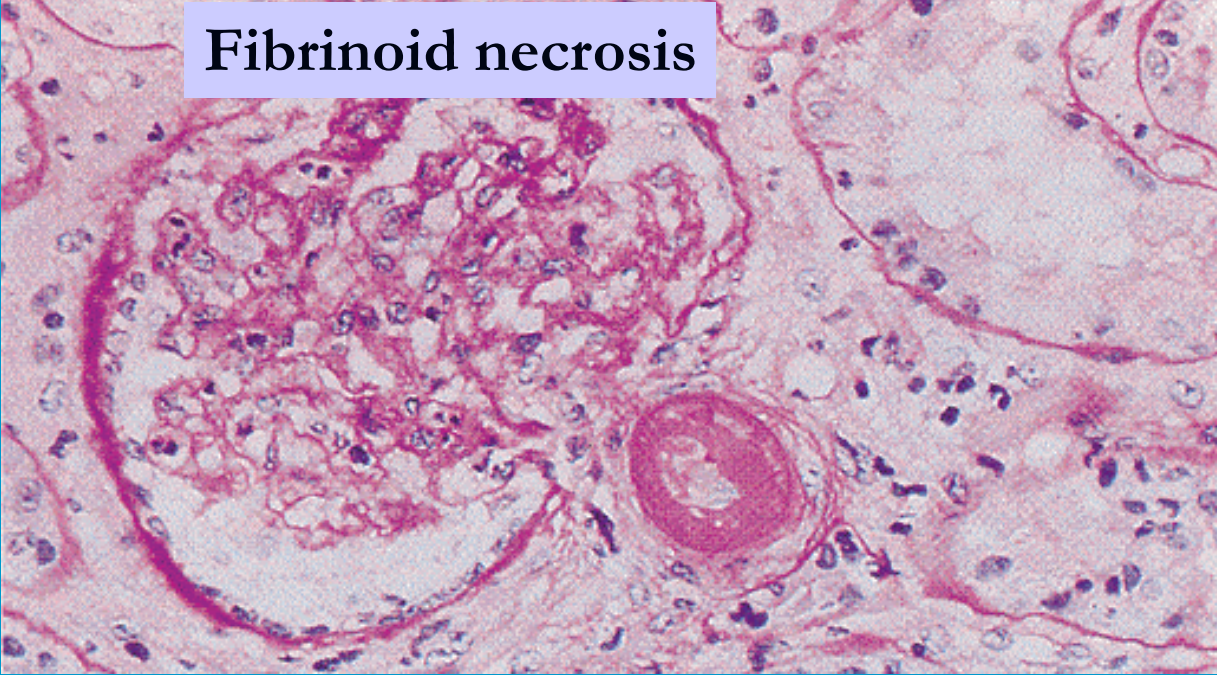
# Nephrosclerosis



arterial wall  
fibrointimal  
thickening



## Fibrinoid necrosis



## Onion-skin

formations – hyperplastic  
arteriosclerosis +/-  
arteriolonecrosis;  
hyaline arteriosclerosis  
hypertension

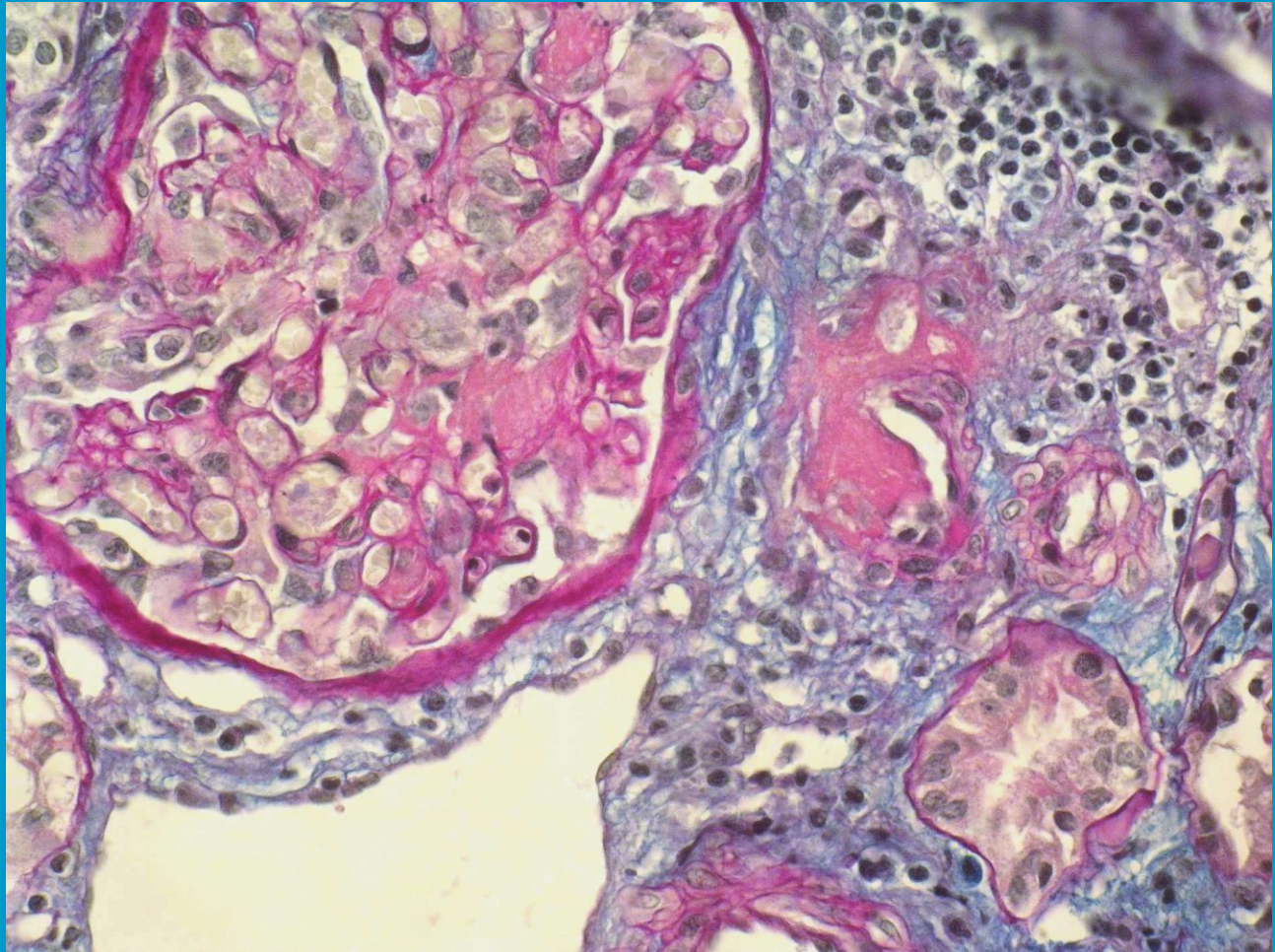
# Nephropathy in hypertension

- Malignant nephrosclerosis = accelerated hypertension (190/130 mm Hg)
  - approx. 5 % HT
  - emergency, radical antihypertensive th. necessary
  - high risk of RF, heart failure, brain haemorrhage
  - endothelial damage
    - macro edema, pinpoint bleeding, infarctions
    - micro edema, fibrinoid necrosis, possible thrombi, haemorrhagic necrosis or oschemic collapse of glomeruli



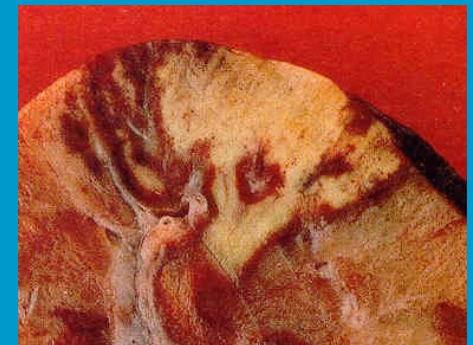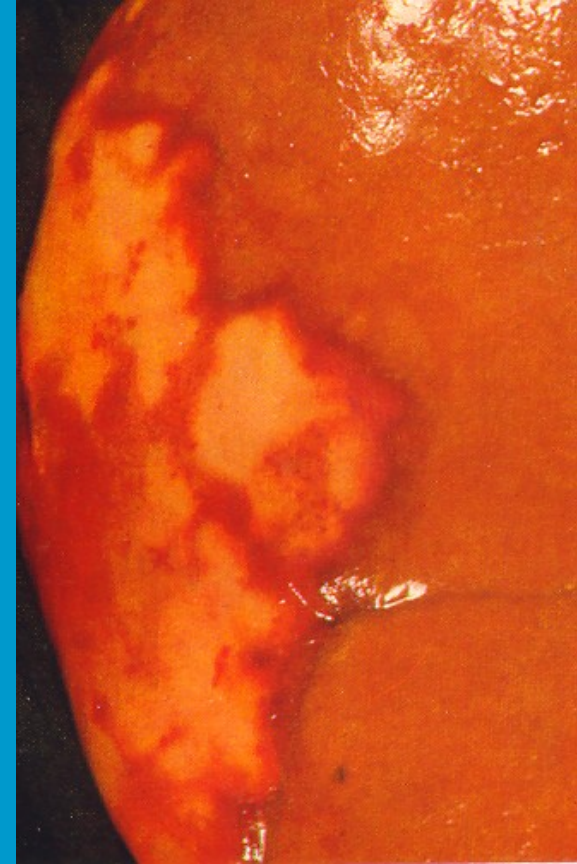
# Nephropathy in hypertension

arteriolar fibrinoid necrosis



# Renal infarction

- Causes of renal artery branches obstruction
  - thrombembolia;
  - thrombosis
  - vasculitis
  - aneurysm of abdominal aorta



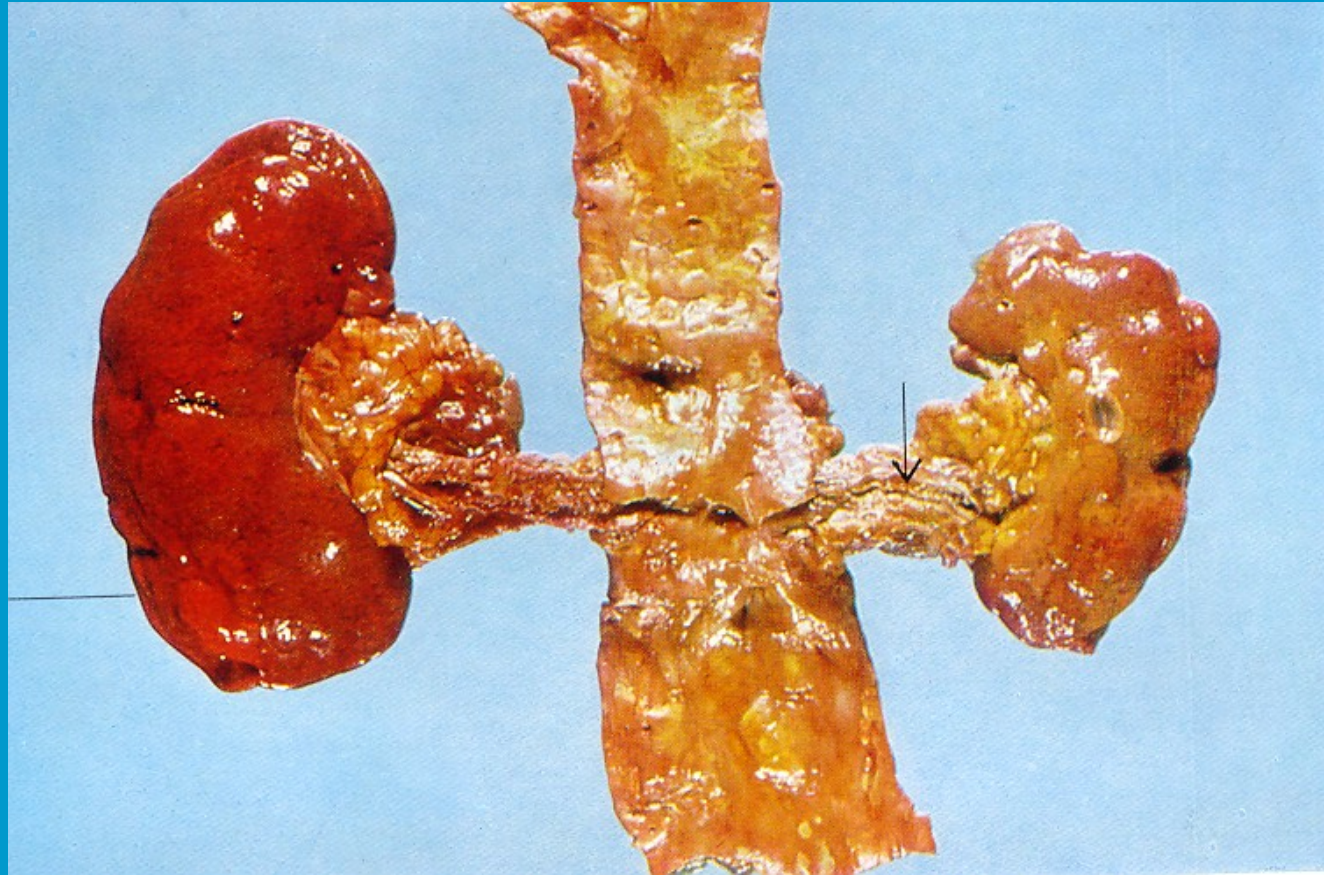# Renal artery stenosis

- cause of renovascular hypertension
  - ↓ of blood pressure in afferent arteriole
  - activation of renin-angiotensin system →
  - ↑ BP, atrophy in longer duration
  - hypertension in contralateral kidney



# Benign nephrosclerosis – hypertensive nephropathy

- a. renalis stenosis, renal atrophy and hypertension (Goldblatt)



# Thrombotic microangiopathy

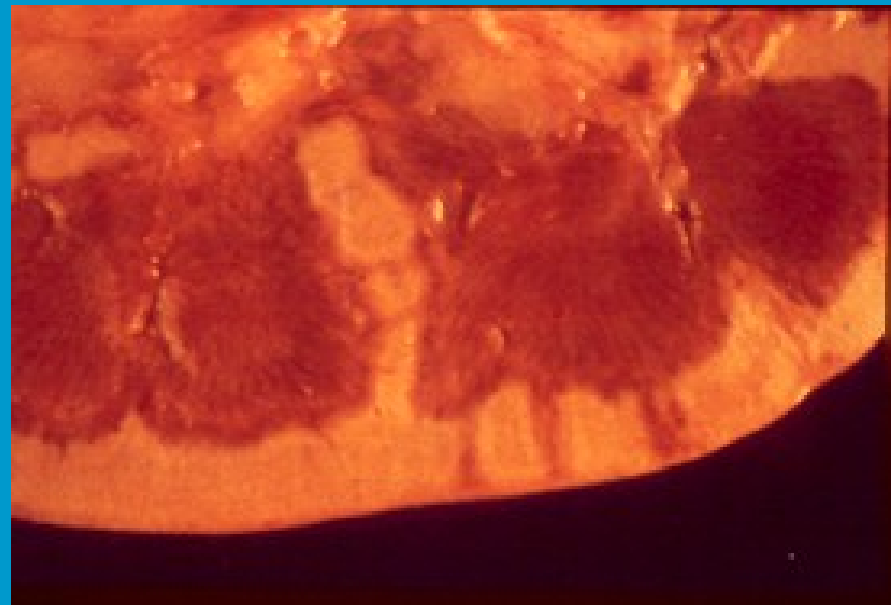
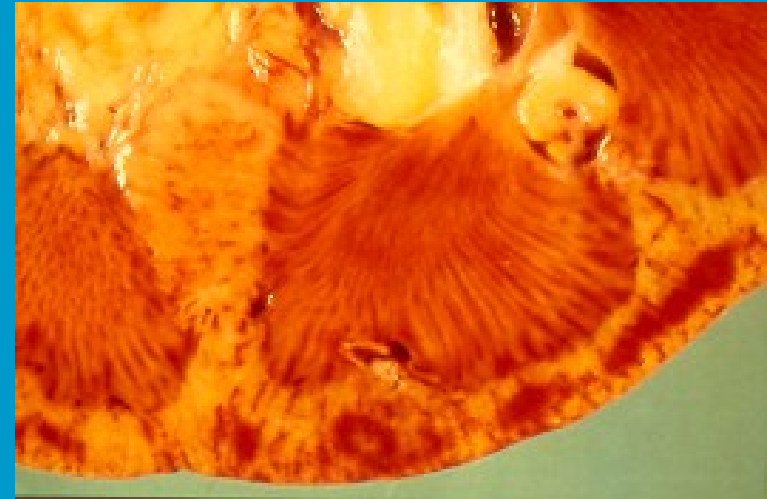
- Endothelial damage → microthrombi → damage of erythrocytes + platelets → hemolytic anaemia
  - fibrinoid necrosis without vasculitis
- Hemolytic-uremic sy (typical – epidemic – Shiga toxin; atypical – antiphospholipid antibodies, malignant hypertension, pregnancy, drugs, irradiation, = in complement dysregulation)
- Thrombotic thrombocytopenic purpura
  - genetic deficiency in von Willebrand-cleaving factor
  - acquired (AI, therapy) sudden, CNS, heart damage
- Pregnancy complications: pre- eclampsia



# Hemolytic-uremic syndrome

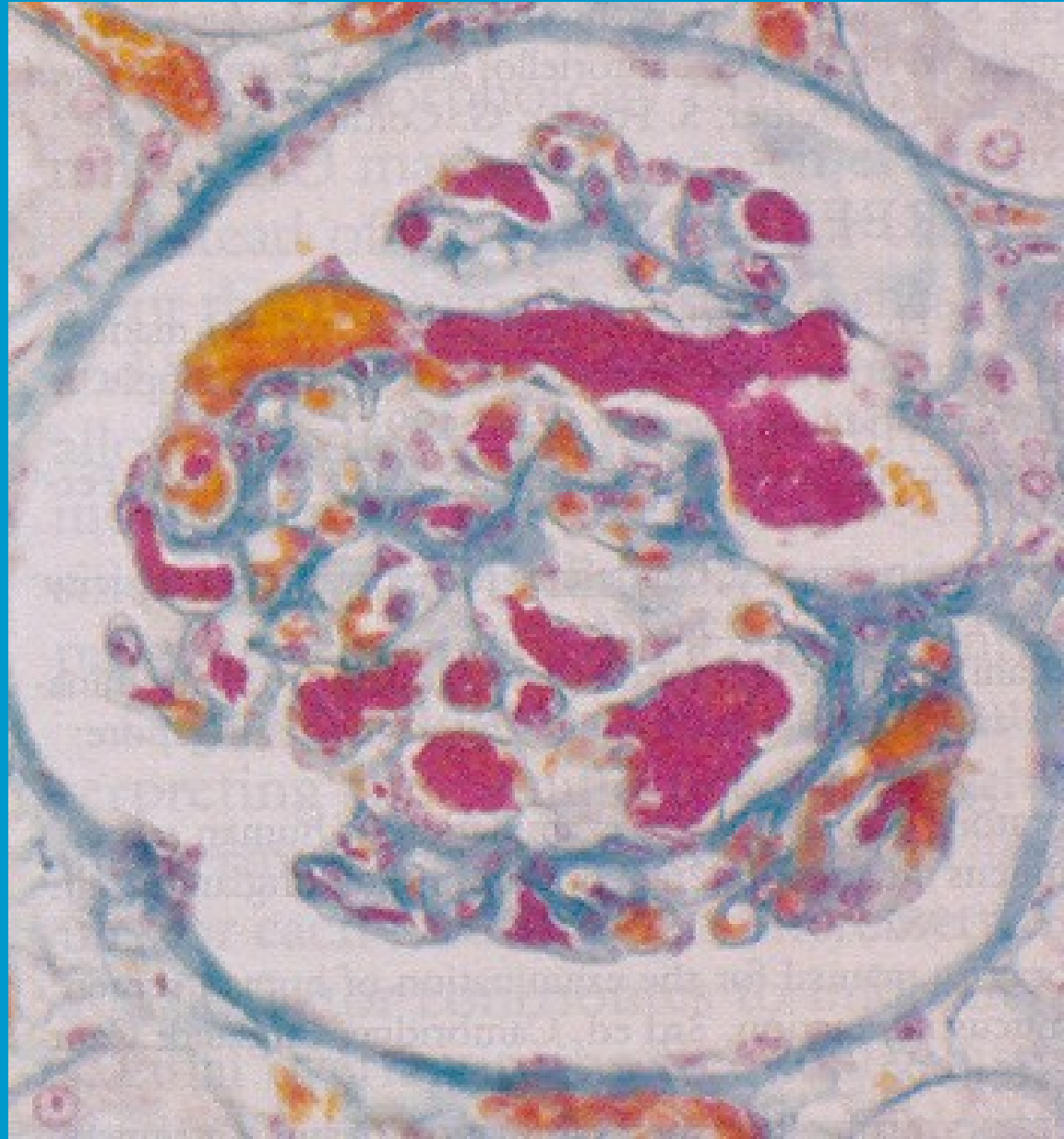
- 1) Ischemic cortical changes with tubular dilatation
- 2) Disperse focal hemorrhages, necroses

Acute nephropathy  
+ haemolysis  
thrombocytopenia



# Hemolytic-uremic syndrome

- Microtrombi in glomerular capillaries (endothelial injury + platelet activation)
- Thickening of capillary walls
- Necrosis and intimal hyperplasia of small arteries



# Systemic vasculitis

## ■ 3 main types

- vasculitis directly caused by autoantibodies
  - anti-GBM glomerulonephritis – Goodpasture sy
- immune complex vasculitis
  - Henoch-Schönlein purpura
- ANCA vasculitis
  - granulomatosis w. polyangiitis (Wegener v.) c-ANCA
  - microscopic polyangiitis p-ANCA
  - Churg-Strauss eosinophilic granulomatosis w. polyangiitis

# Systemic vasculitis c-ANCA

- Small vessel vasculitis
- Incidence ↑ with age
- High mortality
- Renal or multiorgan
- Rapidly progressive GN, hematuria, proteinuria, red cell casts

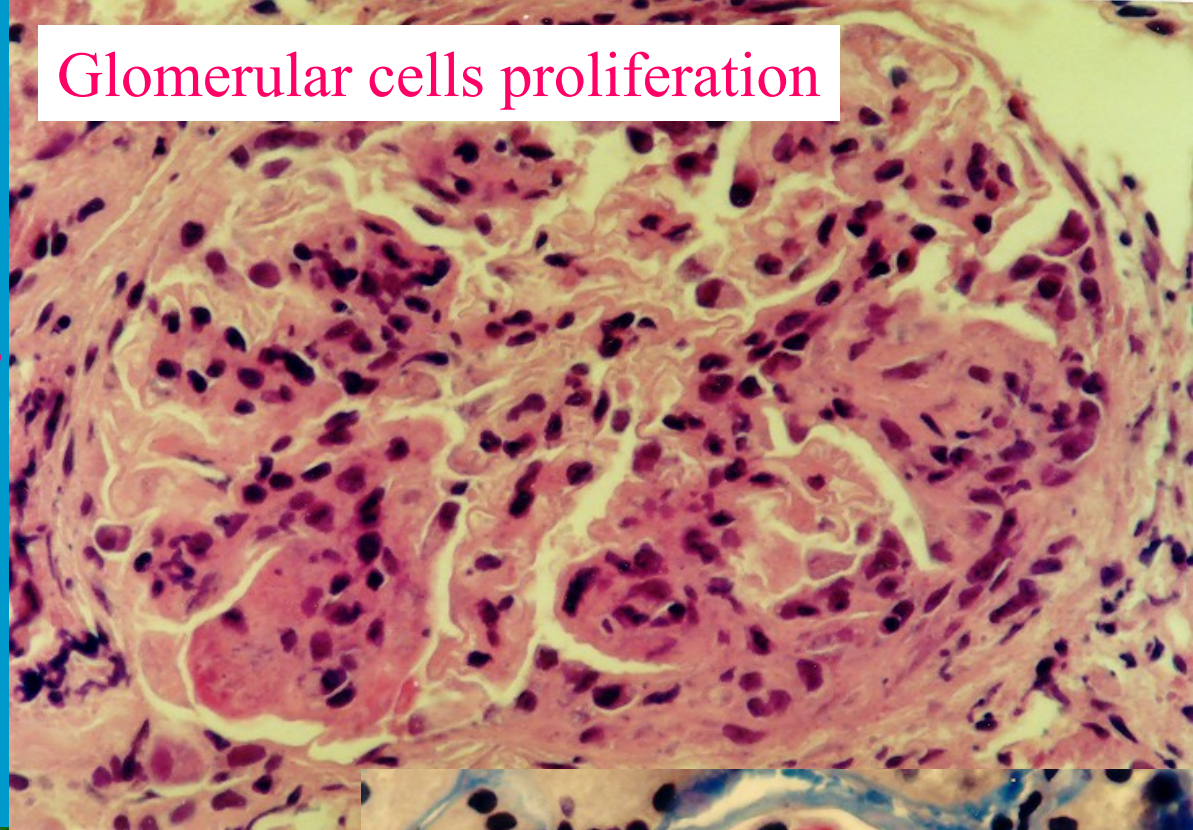


# Glomerulopathy in SLE

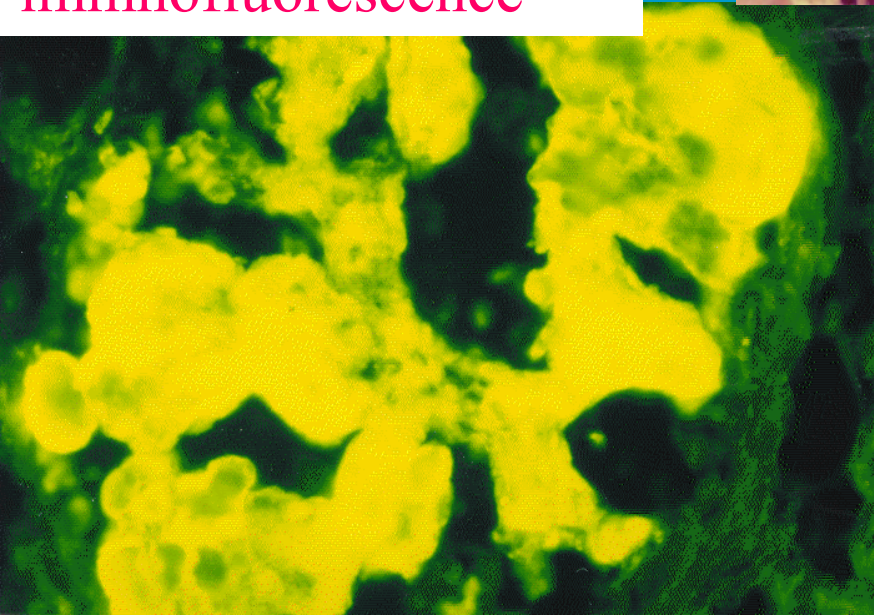
- Multiorgan AI disease
- Variable autoantibodies
- Kidney damage in 80 %
- Variable presentation and/or type of kidney damage
  - asymptomatic hematuria + proteinuria
  - nephrotic sy
  - RPGN
- 6 classes of lupus nephritis

# Lupus nephritis

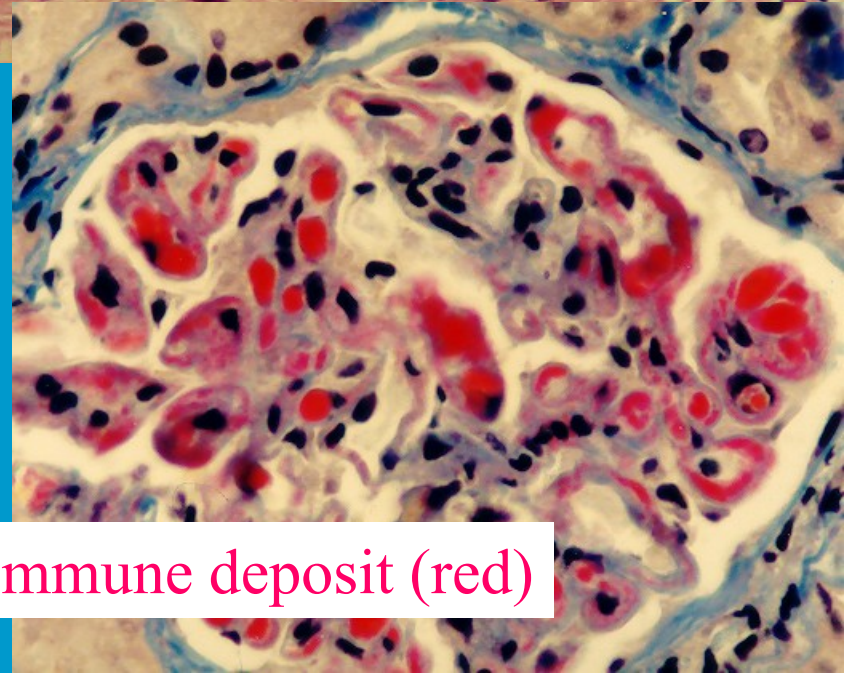
Glomerular cells proliferation



Deposits in direct immunofluorescence



Immune deposit (red)



# Chronic glomerulonephritis

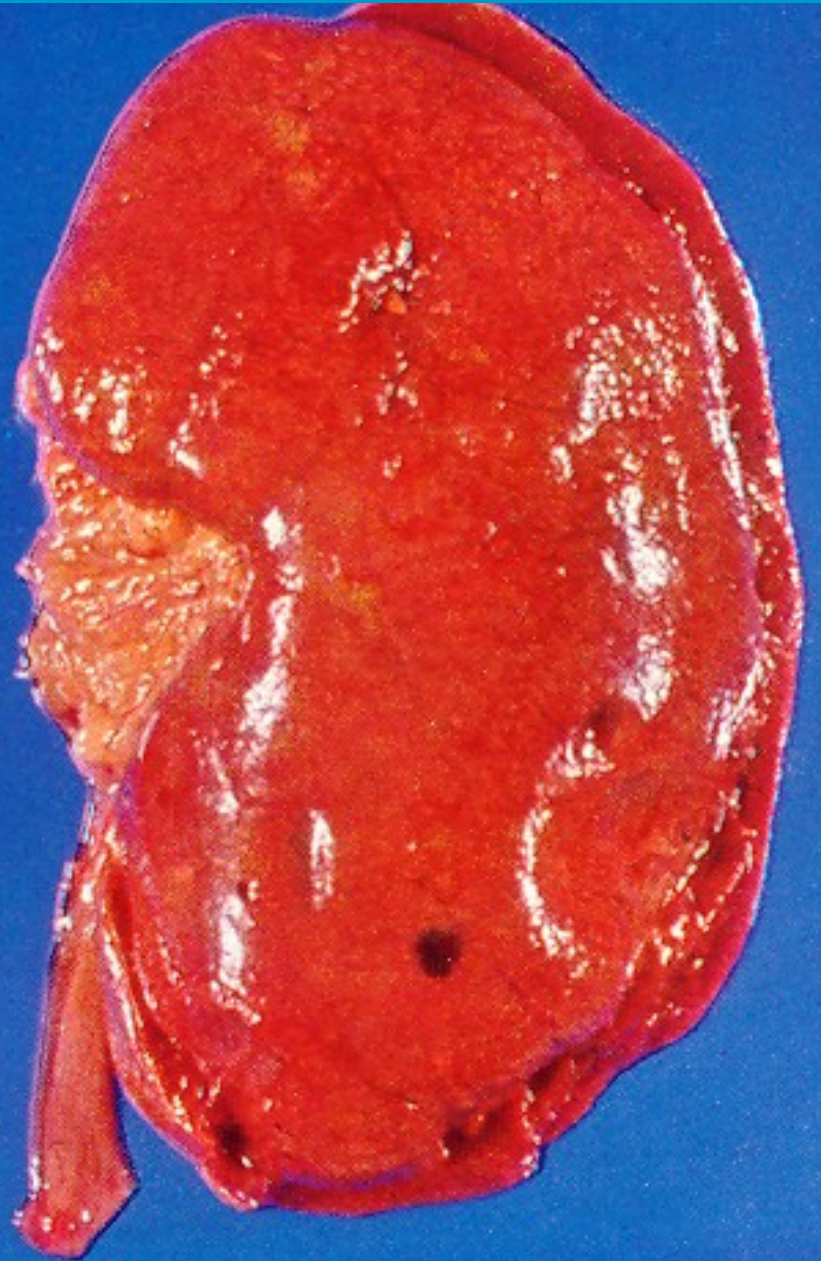
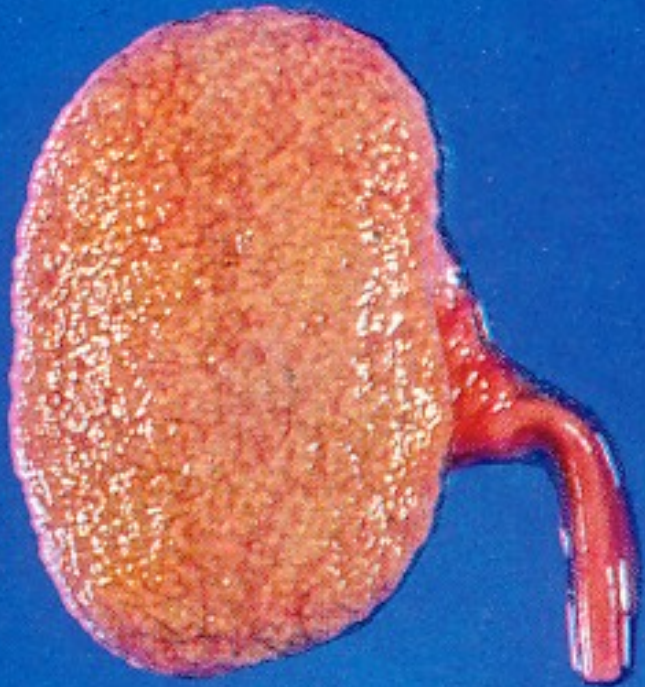- end stage of variable glomerular disease
- commonly no more identifiable
- different rate of progression in different diseases
- FSGS 50-80%
- RPGN, membranous, membranoproliferative ~ 50%
- poststreptococcal 1-2%

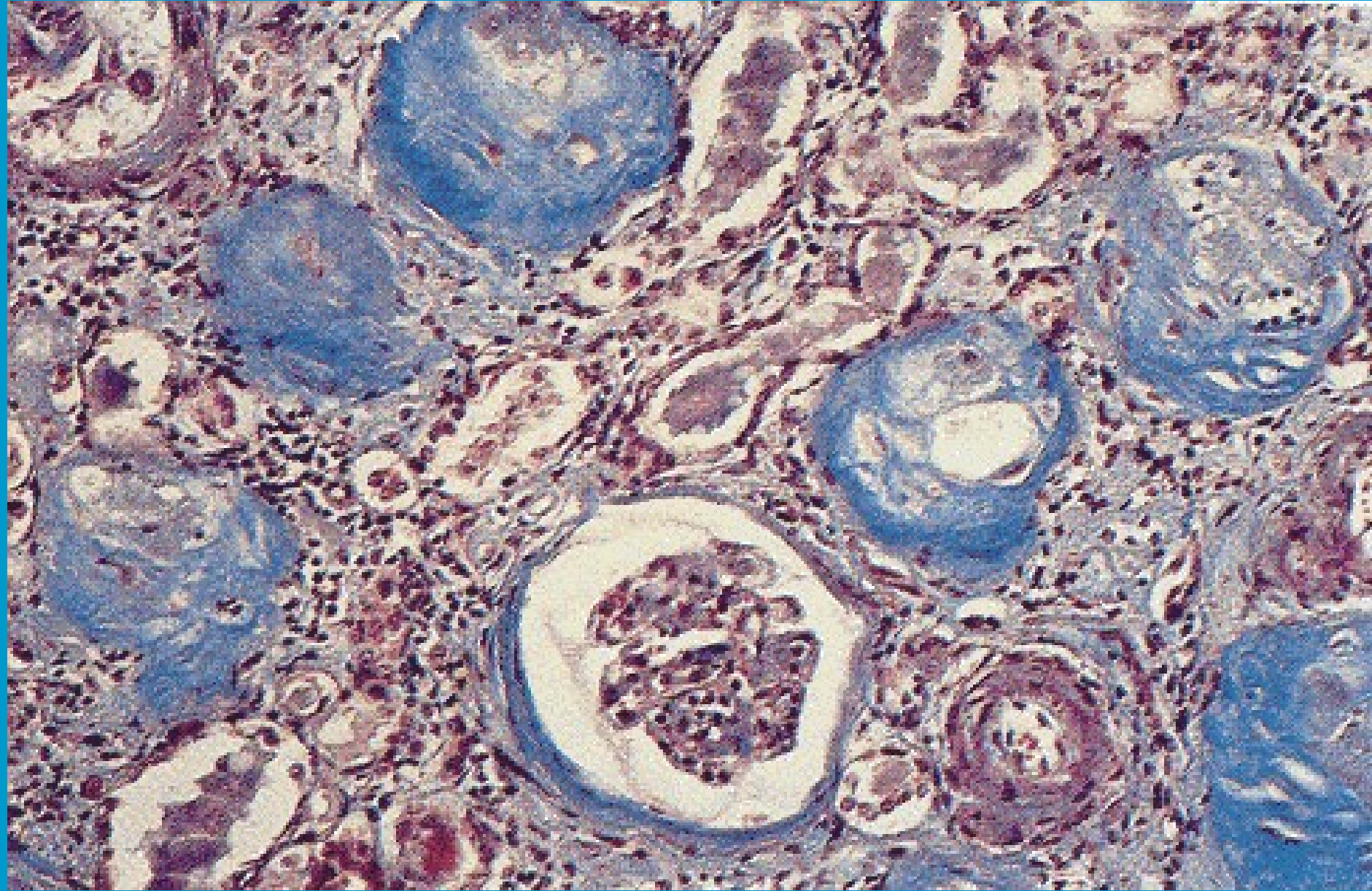
# Chronic glomerulonephritis

- granular surface (!x chronic interstitial nephritis, nephrosclerosis, diabetic nephropathy,...)
- thin cortex
- obliterated glomeruli, arterio- and arteriolosclerosis (hypertension), tubular atrophy



Chronic GN – end-stage kidney





# Tubulo-interstitial disorders

- Concurrent damage to the tubular epithelium and interstitium
- Usually no glomerular damage, or only secondary (e.g. glomerulosclerosis)

# Tubulo-interstitial disorders - groups

## TUBULOINTERSTITIAL NEPHRITIS (TIN)

Acute pyelonephritis

Chronic pyelonephritis, reflux nephropathy

Abacterial interstitial nephritis (drugs, etc.)

## ISCHEMIC AND TOXIC INJURY

Acute tubular necrosis

OTHERS (e.g. obstructive uropathy, tbc, myeloma, urate nephropathy, immunologic reaction AI, posttransplant)



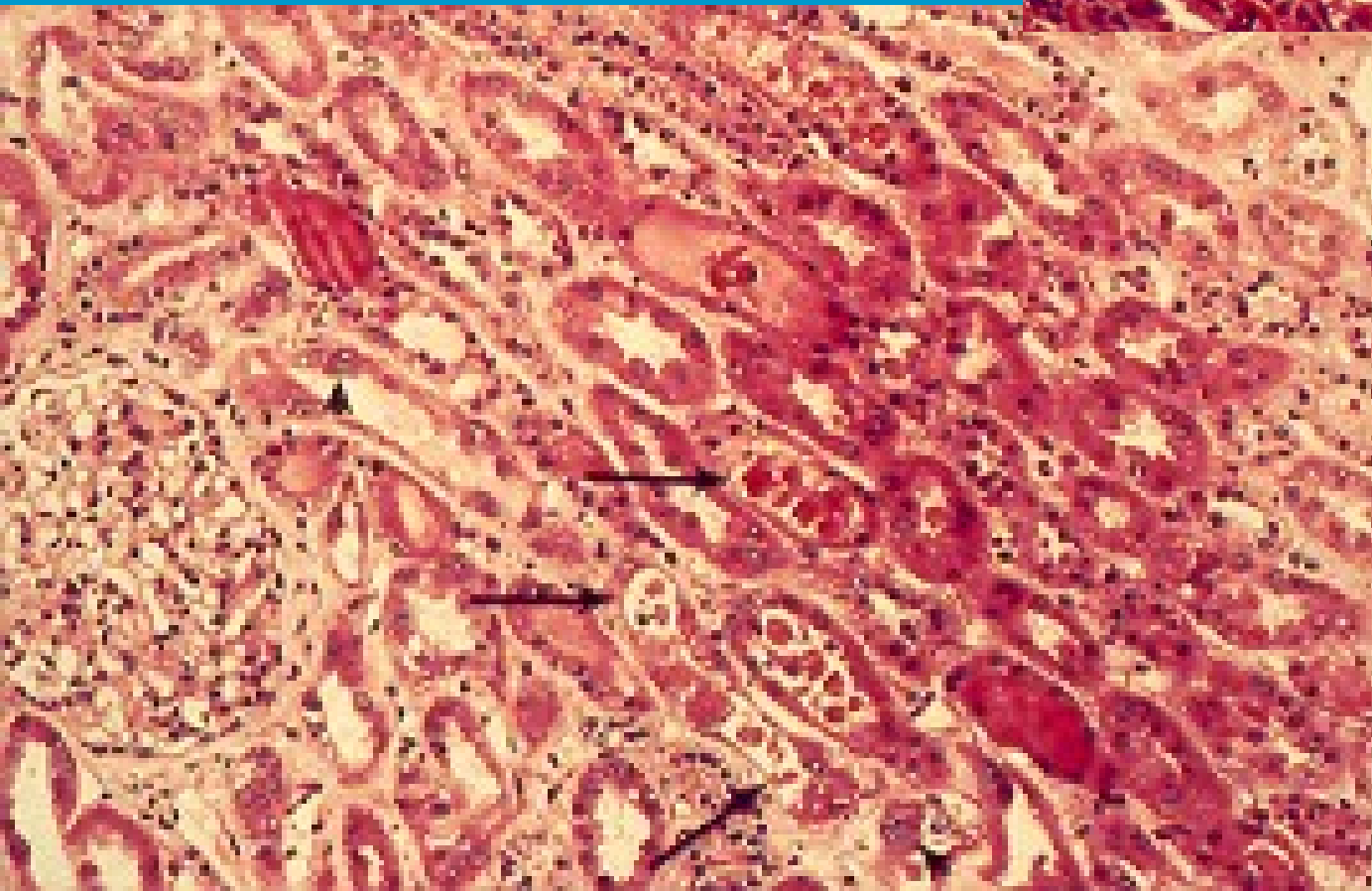
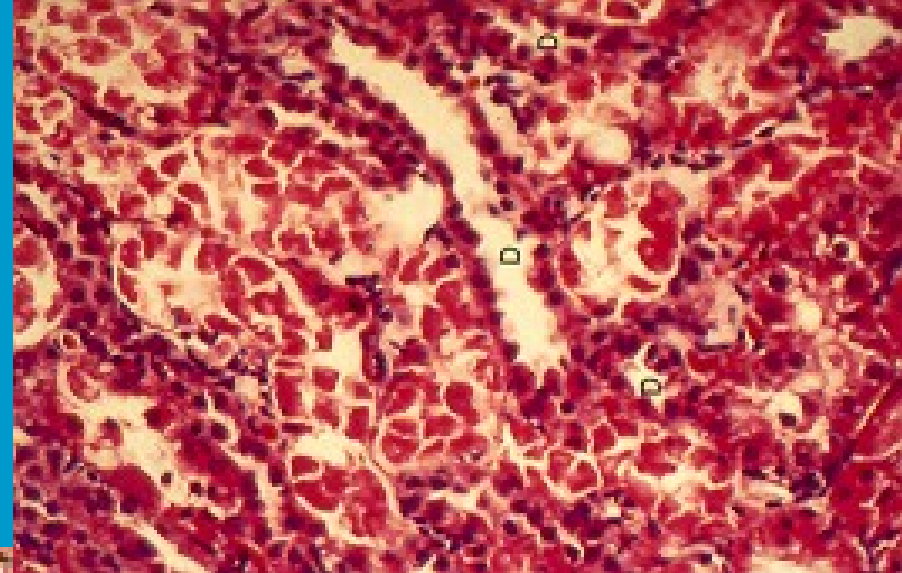
# Acute tubular necrosis (ATN)

- Destruction/injury of tubular epithelium, leading to acute diminution or loss of renal function
- **Ischemic ATN** – due to decreased or interrupted blood flow, e.g. in shock, trauma, acute pancreatitis, polyarteritis nodosa, haemoglobinuria (haemolysis), myoglobinuria (crush), etc.
- **Nephrotoxic ATN** – direct toxic injury to the tubules by drugs, heavy metals (mercury), organic solvents (carbon tetrachloride), ethylene glycol

# Acute tubular necrosis (ATN)

- Morphology: **ischemic ATN** with loss of proximal epithelial brush border, cell flattening, focal tubular epithelial necrosis along the whole nephron, BM rupture, occlusion by casts; interstitial oedema, inflammatory infiltrate
- Later epithelial regeneration starting from uninjured parts
- **Toxic ATN**: extensive tubular necrosis/cytotoxic changes along the proximal tubules

# Acute tubular necrosis (ATN)



# Tubulointerstitial nephritis induced by drugs and toxins (hypersensitivity nephritis)

- Sulfonamids, synthetic penicilins, some diuretics, NSAIDs
- 7-15 days after exposure fever, eosinophilia, rash, hematuria, proteinuria, leukocyturia, cca 50% acute renal failure with oliguria
- Late-phase reaction of an IgE-mediated hypersensitivity (type I)
- Oedema and mononuclear **interstitial infiltration**, commonly with **eosinophils**, giant cell **granulomas** may be present. Tubulitis and tubular regressive changes.



# Analgesic nephropathy

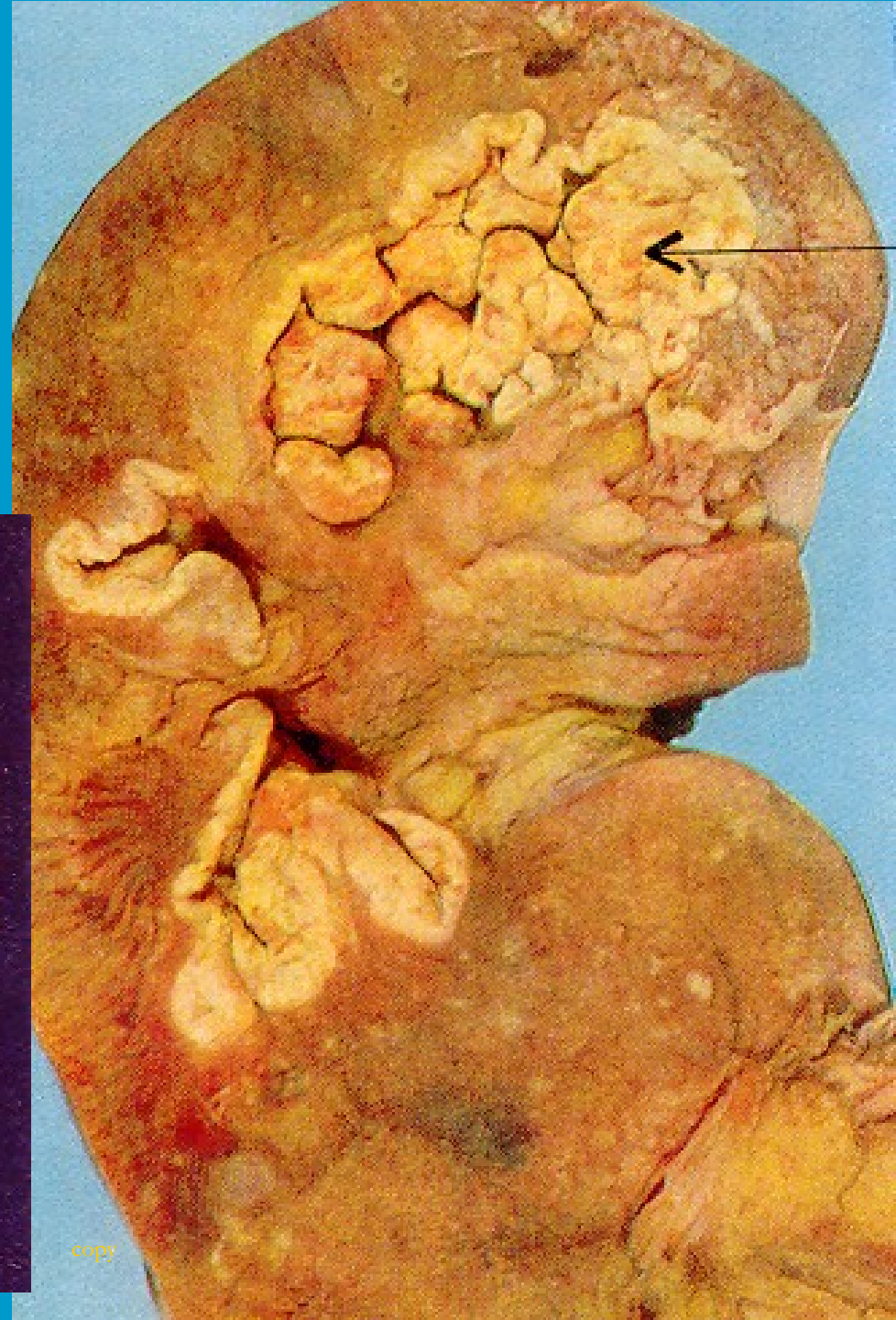
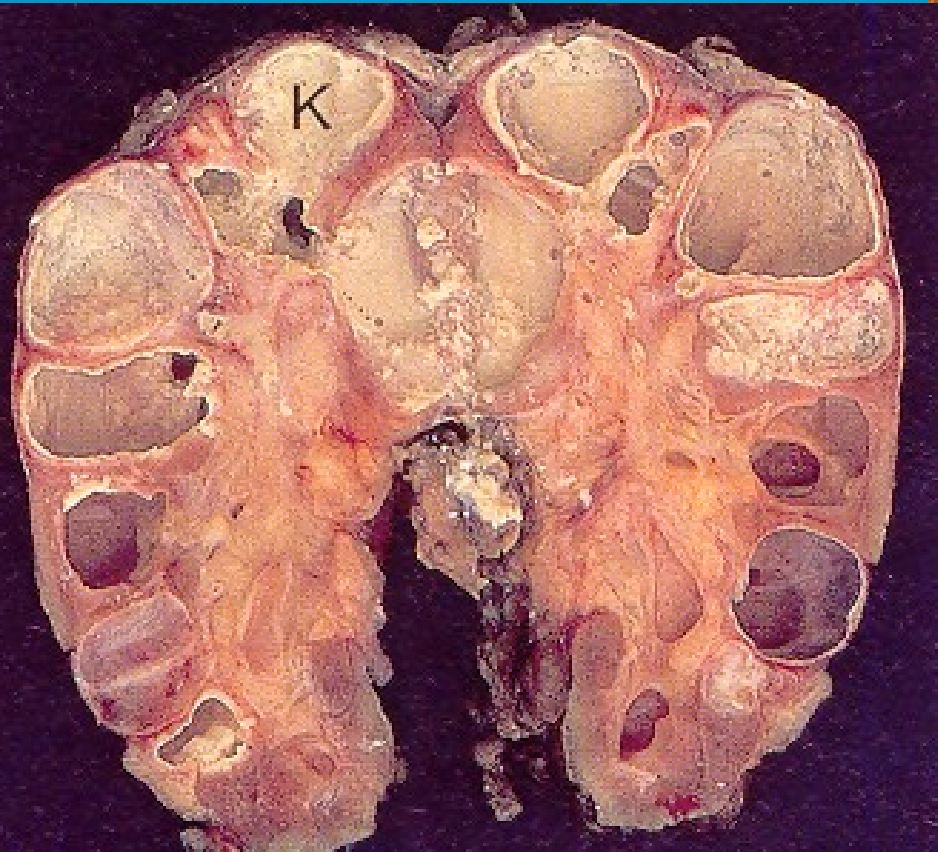
- Chronic renal disease due to excessive use of analgesic mixtures
- Form of chronic tubulointerstitial nephritis with renal papillary necrosis
- Combination effects of aspirin (papillary ischaemia), phenacetin (toxic metabolites)

# Renal TBC

- Part of miliary spread
- Solitary postprimary tbc lesion
- Gross: caseous-cavernous mass with fibrous capsule (closed tbc) or rupture and drain into pelvis (open tbc), possible infection of urinary tract.

# Renal TBC

Caseation

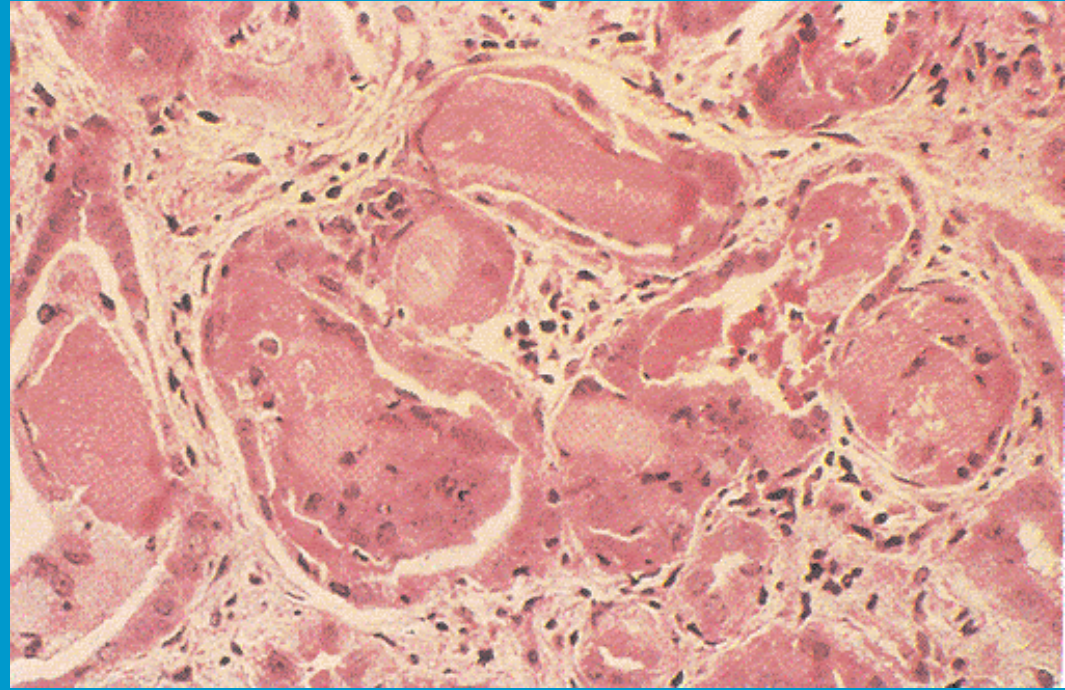


# Urate nephropathy

- Hyperuricemic disorders (urate crystals formation) may lead to 3 forms of injury:
- **Acute urate nephropathy** in patients with haematologic malignancies, commonly during chemotherapy (extensive cell breakdown – release of nucleic acids – urate crystals in tubules – acute renal failure)
- **Chronic urate nephropathy** – in gout. Urate crystals surrounded by foreign body giant cells, tubulo-interstitial nephritis
- **Urate stones**



# Multiple myeloma



- Amyloidosis
- Myeloma nephrosis: tubular casts formed by precipitated Bence-Jones protein, nephrohydrophilia  
giant cell reaction

# Renal tumors

# WHO histological classification of renal tumors

- Renal cell tumours
- Metanephric tumours
- Nephroblastic tumours
- Mesenchymal tumours
- Mixed mesenchymal and epithelial tumours
- Neuroendocrine tumours
- Haematopoietic and lymphoid tumours
- Germ cell tumours
- Metastatic tumours

# WHO classification of renal cell tumors

- Clear cell renal cell carcinoma
- Multilocular cystic renal neoplasm of low malignant potential
- Papillary renal cell carcinoma
- Hereditary leiomyomatosis and renal cell carcinoma (HLRCC)-associated renal cell carcinoma
- Chromophobe renal cell carcinoma
- Collecting duct carcinoma
- Renal medullary carcinoma
- MiT Family translocation carcinomas
- Succinate dehydrogenase (SDH)-deficient renal carcinoma
- Mucinous tubular and spindle cell carcinoma
- Tubulocystic renal cell carcinoma
- Acquired cystic disease associated renal cell carcinoma
- Clear cell papillary renal cell carcinoma
- Renal cell carcinoma, unclassified
- Papillary adenoma
- Oncocytoma



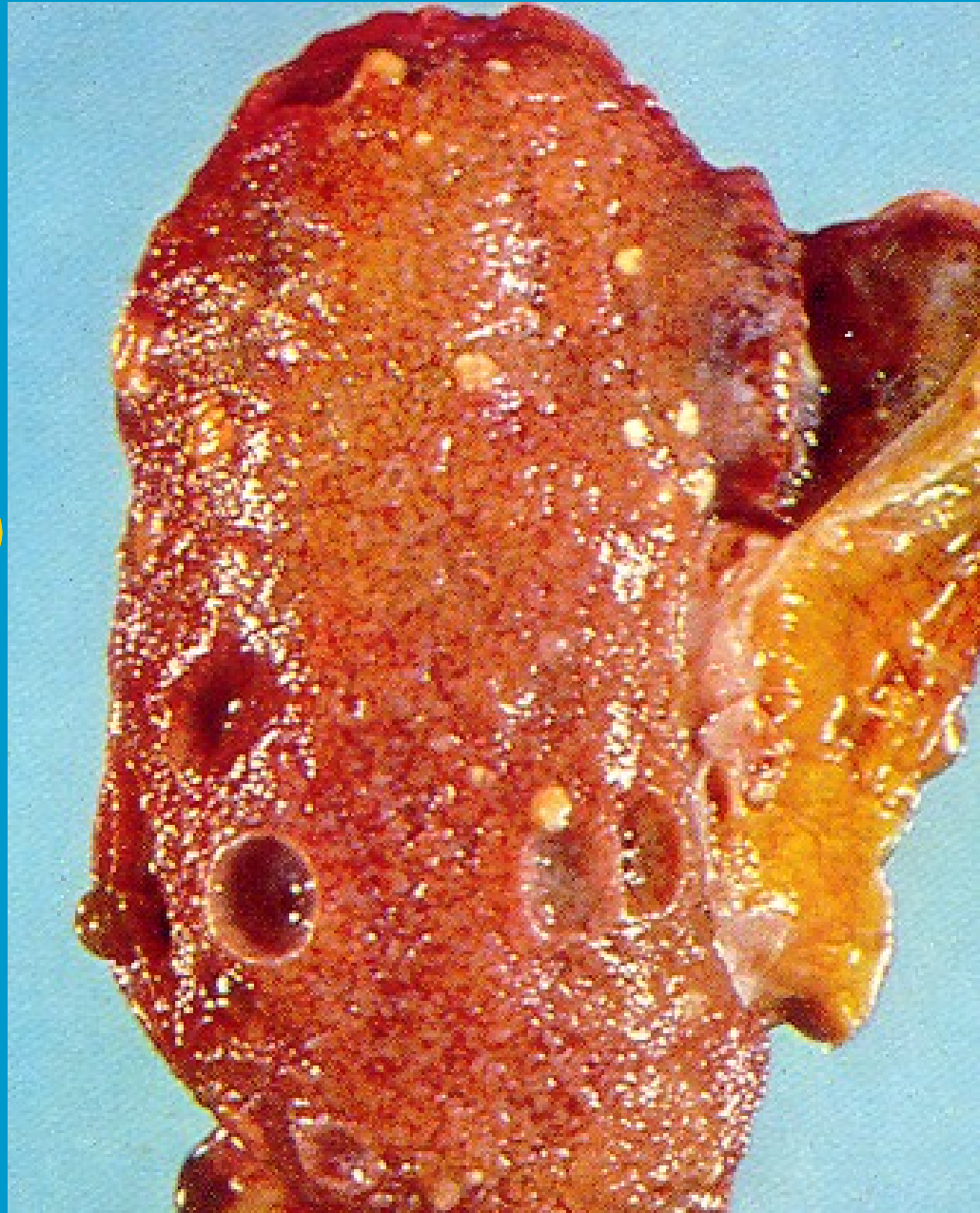
# WHO classification of renal cell tumors 2021

- **Clear cell renal tumours**
- 8310/3 Clear cell renal cell carcinoma
- 8316/1 Multilocular cystic renal neoplasm of low malignant potential
- **Papillary renal tumours**
- 8260/0 Papillary adenoma
- 8260/3 Papillary renal cell carcinoma†
- **Oncocytic and chromophobe renal tumours**
- 8290/0 Oncocytoma
- 8317/3 Chromophobe cell renal carcinoma
- Other oncocytic tumours of the kidney
- **Collecting duct tumours**
- 8319/3 Collecting duct carcinoma
- **Other renal tumours**
- 8323/1 Clear cell papillary renal cell tumour‡
- 8480/3 Mucinous tubular and spindle cell carcinoma
- 8316/3 Tubulocystic renal cell carcinoma
- 8316/3 Acquired cystic disease-associated renal cell carcinoma
- 8311/3 Eosinophilic solid and cystic renal cell carcinoma
- 8312/3 Renal cell carcinoma, NOS
- **Molecularly defined renal carcinomas**
- 8311/3 *TFE3*-rearranged renal cell carcinomas
- 8311/3 *TTEB*-altered renal cell carcinomas
- 8311/3 *ELOC* (formerly *TCEB1*)-mutated renal cell carcinoma
- 8311/3 Fumarate hydratase-deficient renal cell carcinoma
- 8311/3 Hereditary leiomyomatosis and renal cell carcinoma (HLRCC) syndrome-associated renal cell carcinoma
- 8311/3 Succinate dehydrogenase-deficient renal cell carcinoma
- 8311/3 *ALK*-rearranged renal cell carcinomas
- 8510/3 Medullary carcinoma, NOS
- 8510/3 SMARCB1-deficient medullary-like renal cell carcinoma
- 8510/3 SMARCB1-deficient undifferentiated renal cell carcinoma, NOS
- 8510/3 SMARCB1-deficient dedifferentiated renal cell carcinomas of other specific subtypes

# Benign renal tumors

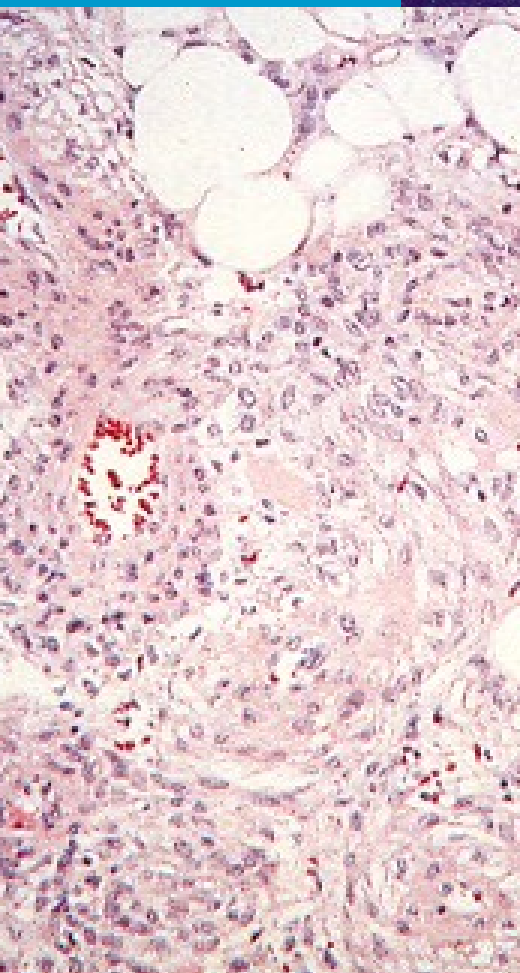
## Cortical papillary adenoma

- Small tumors (1-15 mm)
- May be multiple
- Papillary structure



# Benign renal tumors

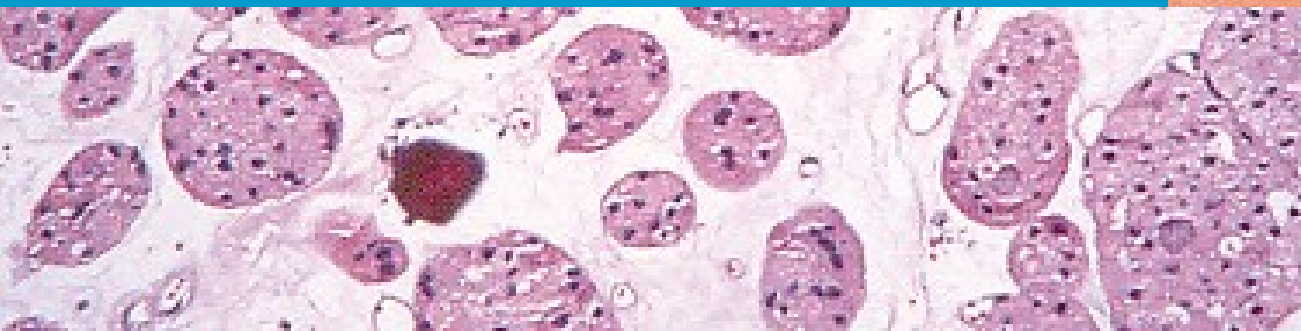
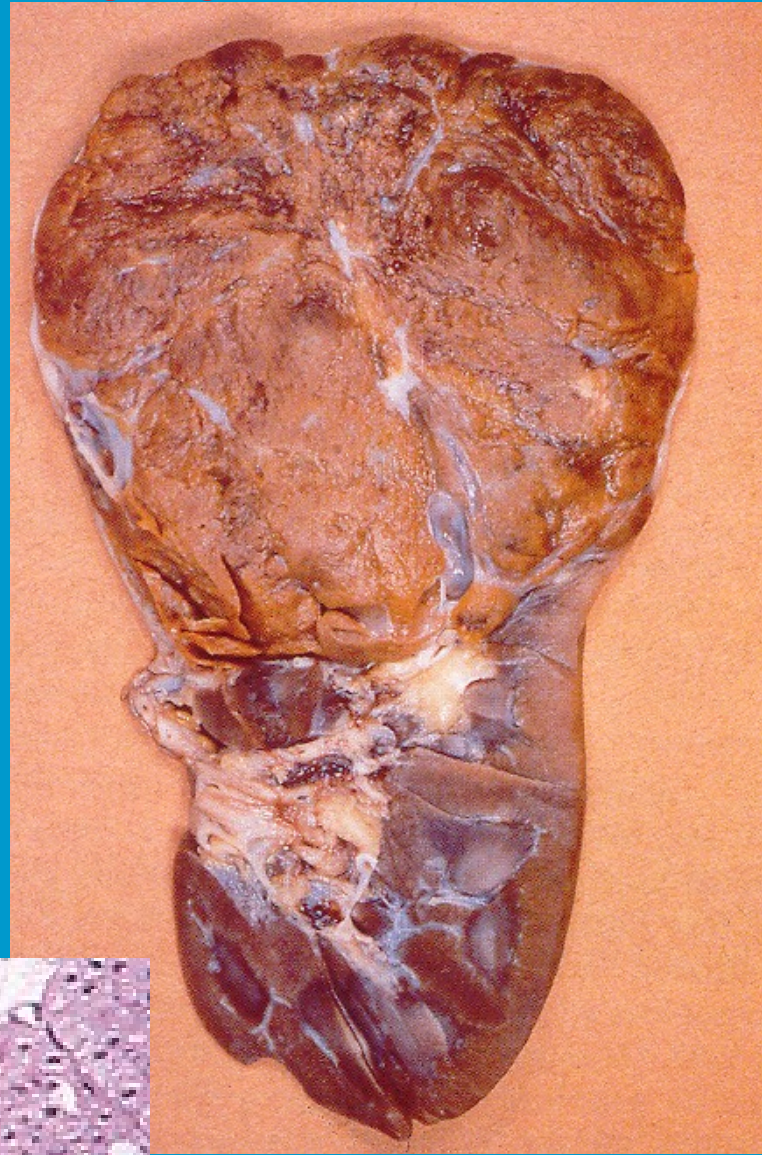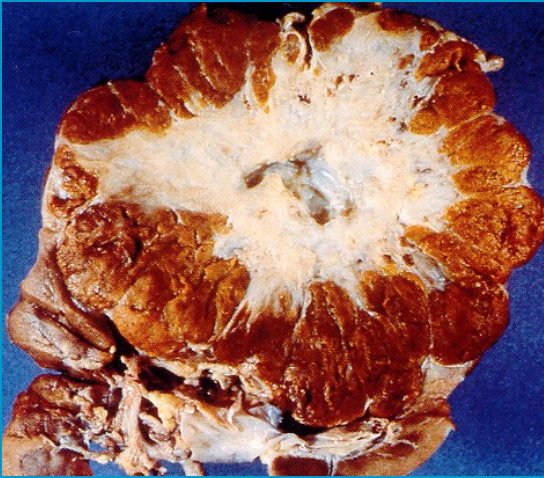- **Angiomyolipoma (PEComa), mesenchymal**





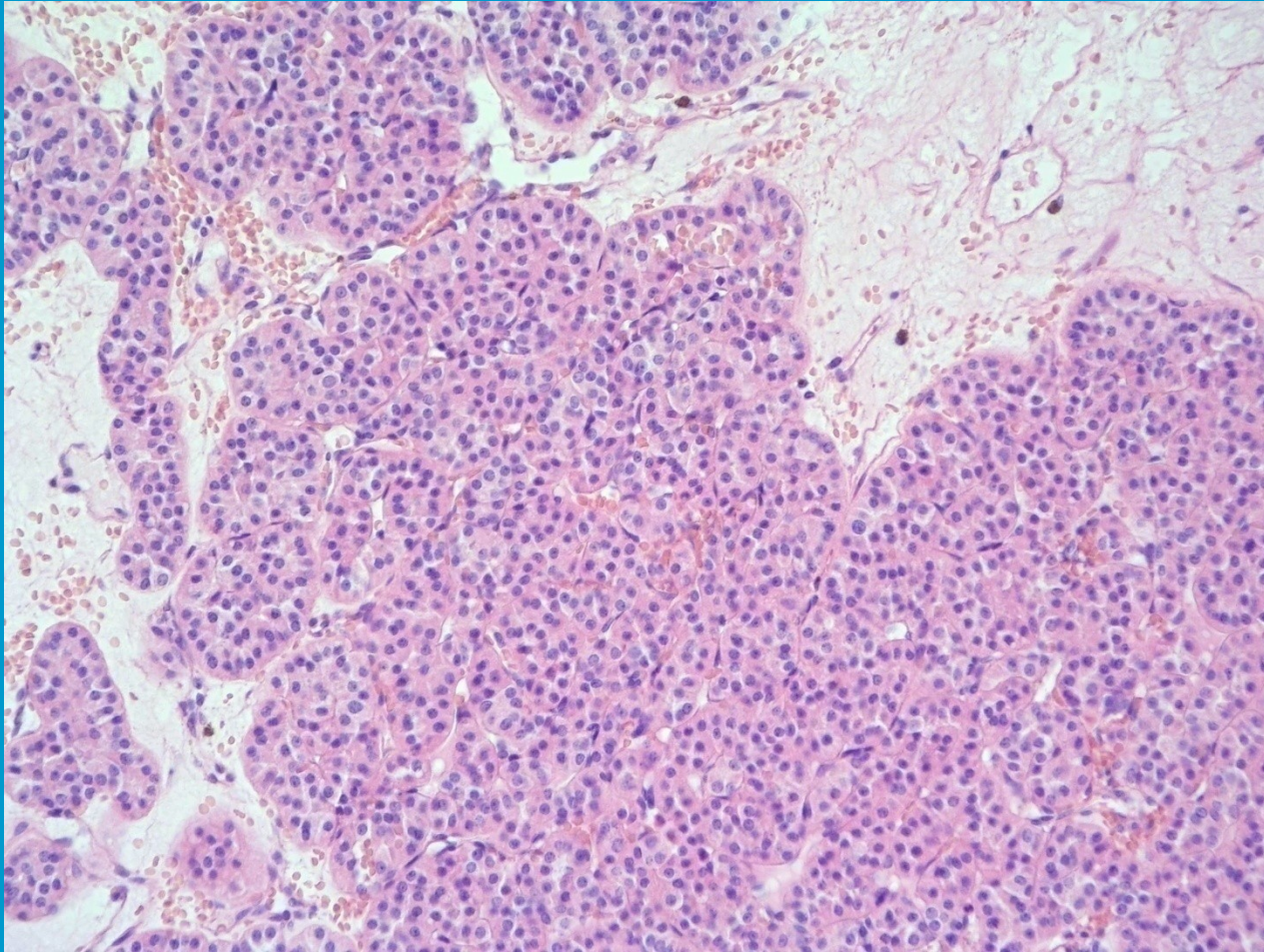
# Benign renal tumors

- Oncocytoma epithelial, asymptomatic





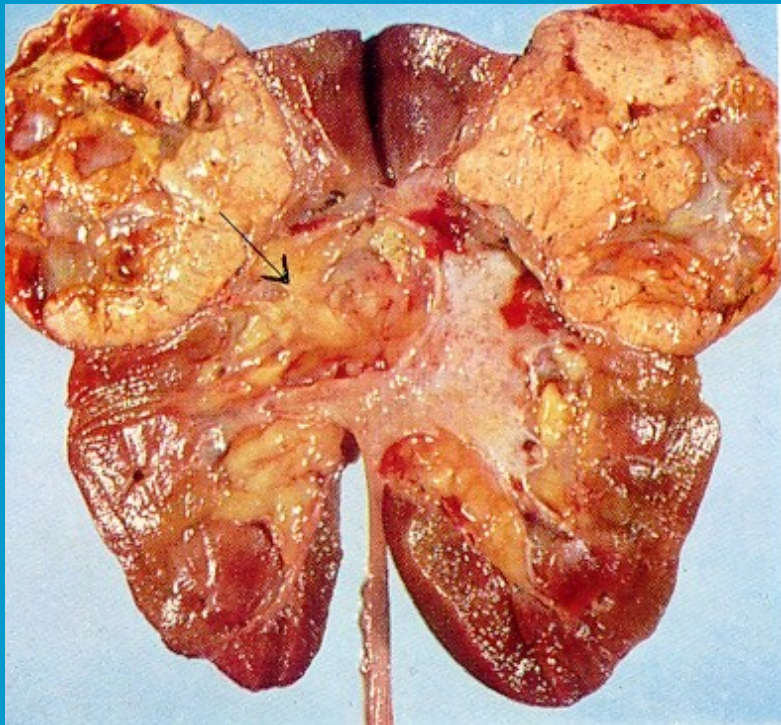
# Renal oncocytoma





# Renal cell carcinoma

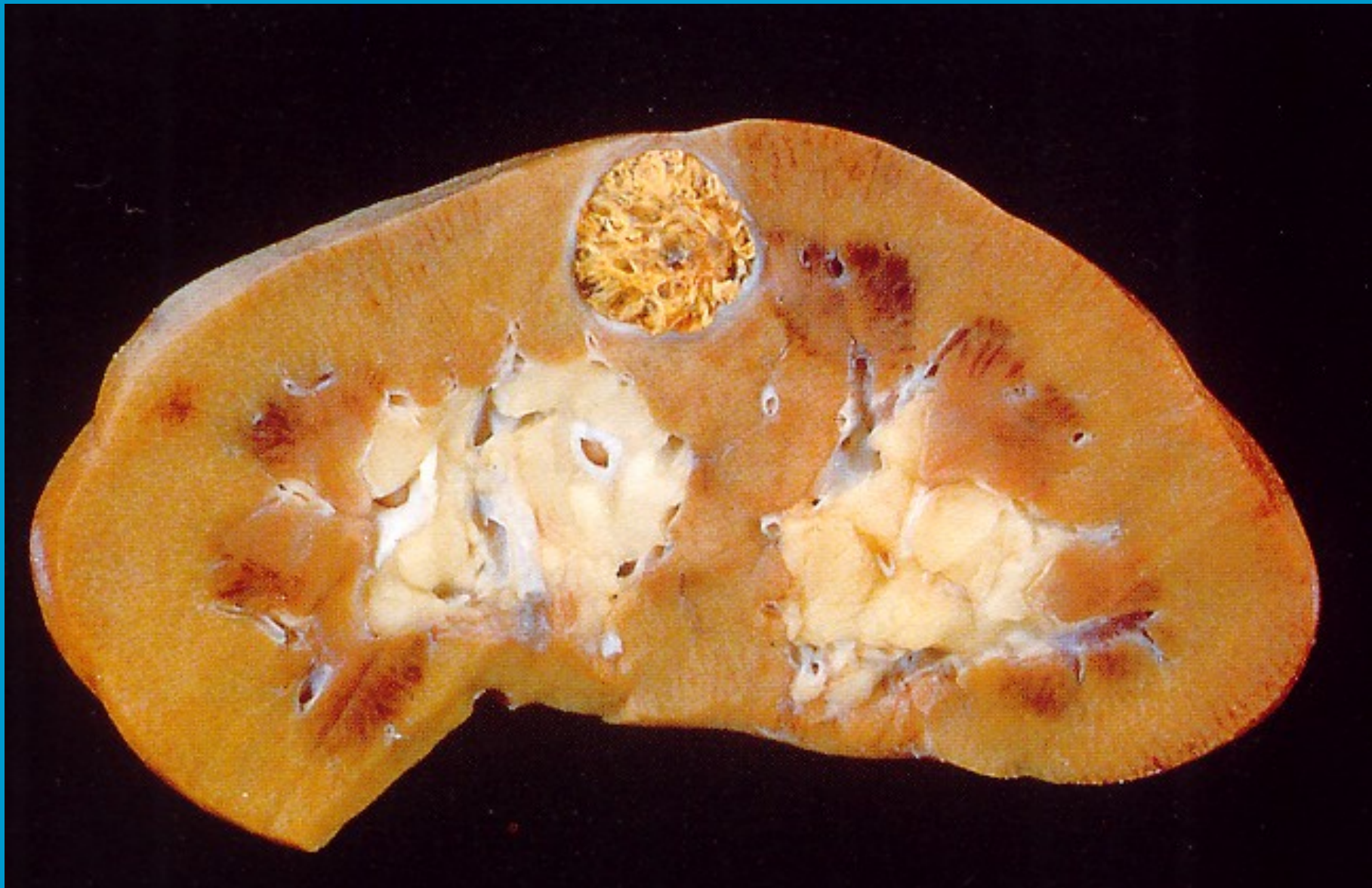
- Adenocarcinoma from tubular epithelium (clear cell - Grawitz )
- 85% of renal malignancies



# RCC

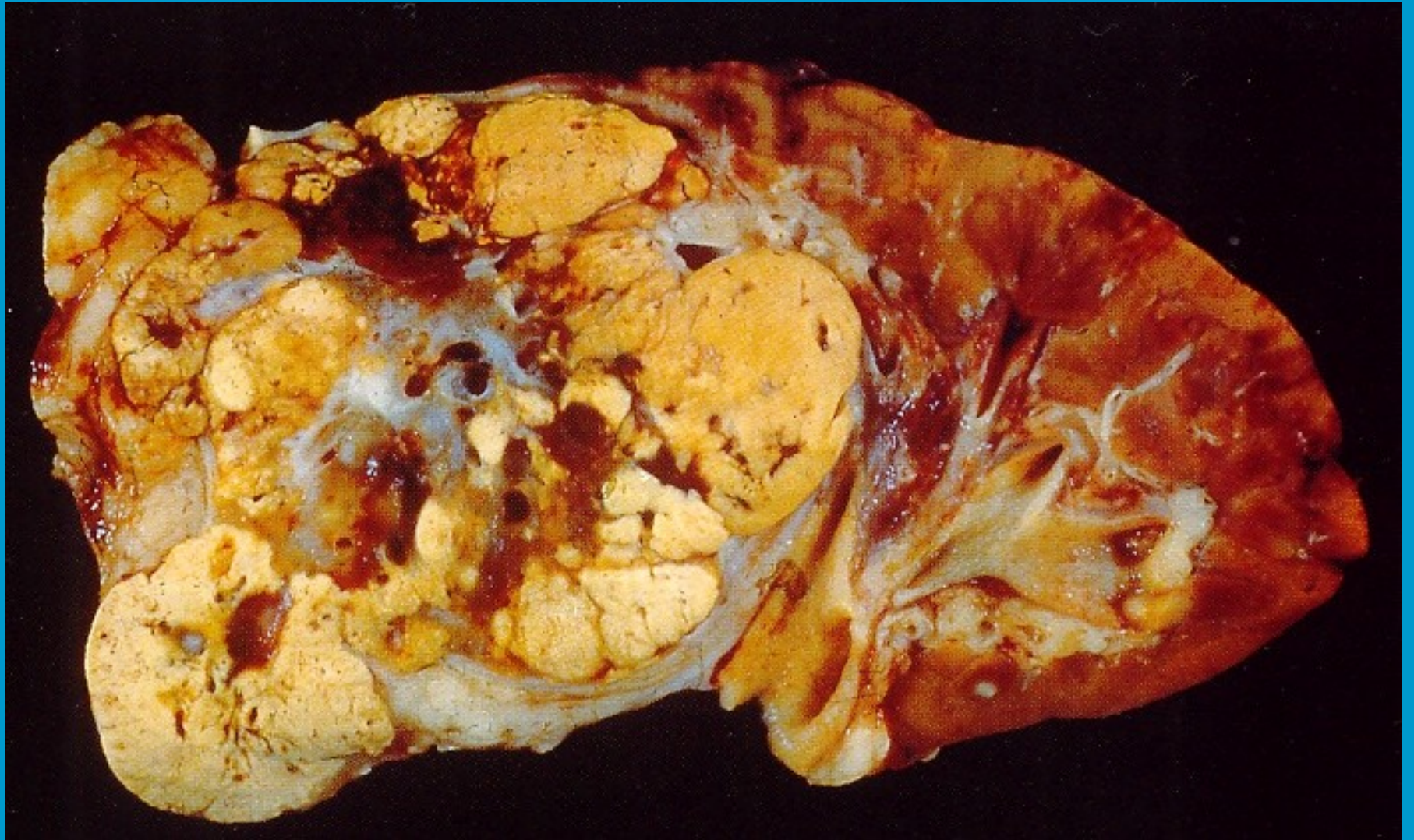- Clear cell (conventional) RCC (80%)
  - Chromophobe RCC
  - Papillary RCC
- 
- Risk f.: smoking, obesity, HT, genetic factors, industrial pollution, chemicals (asbestos, arsenic, organic diluents, ...)
  - Incidental finding, hematuria, metastasis

# Renal cell carcinoma



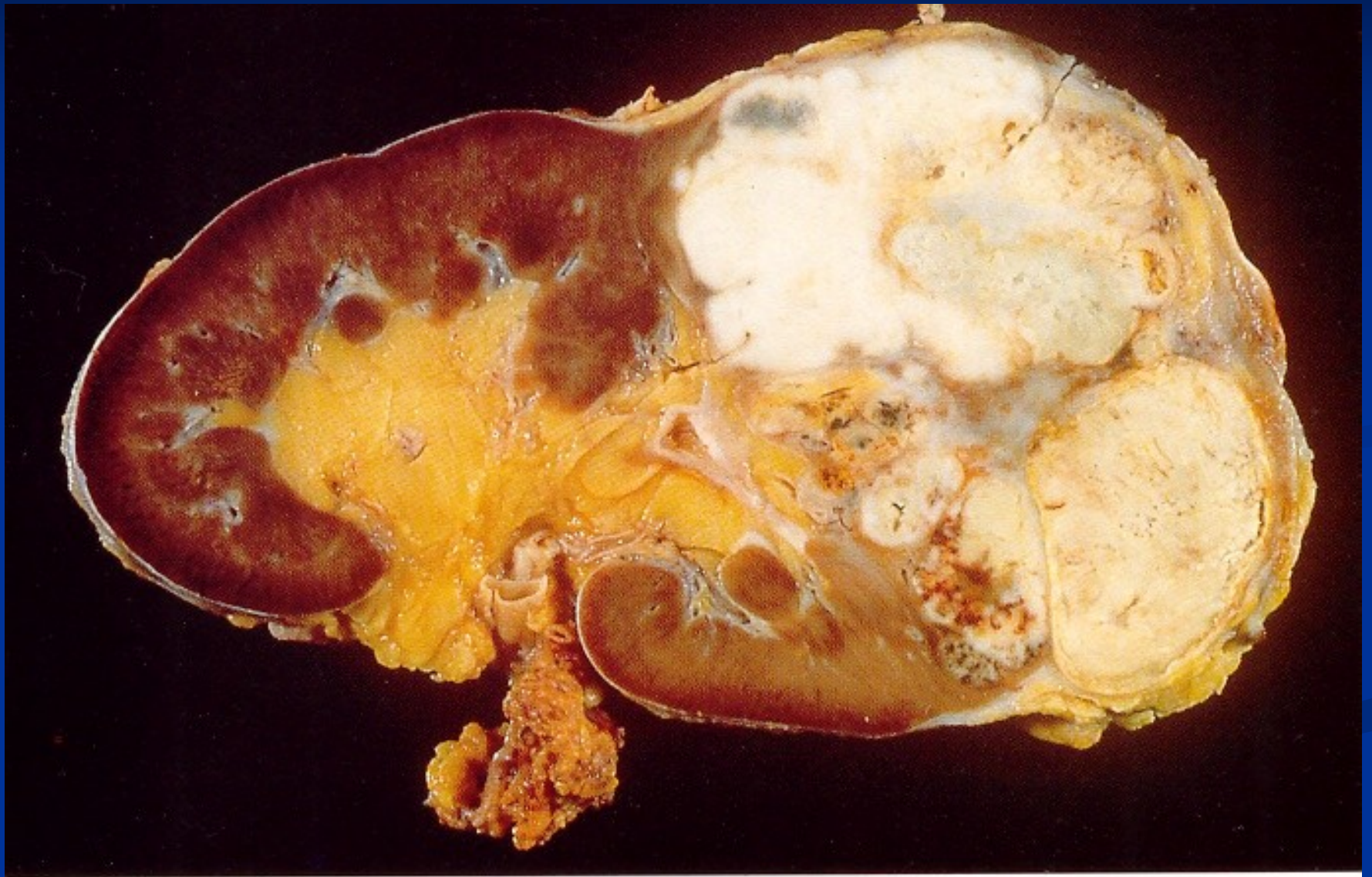


# Renal cell carcinoma



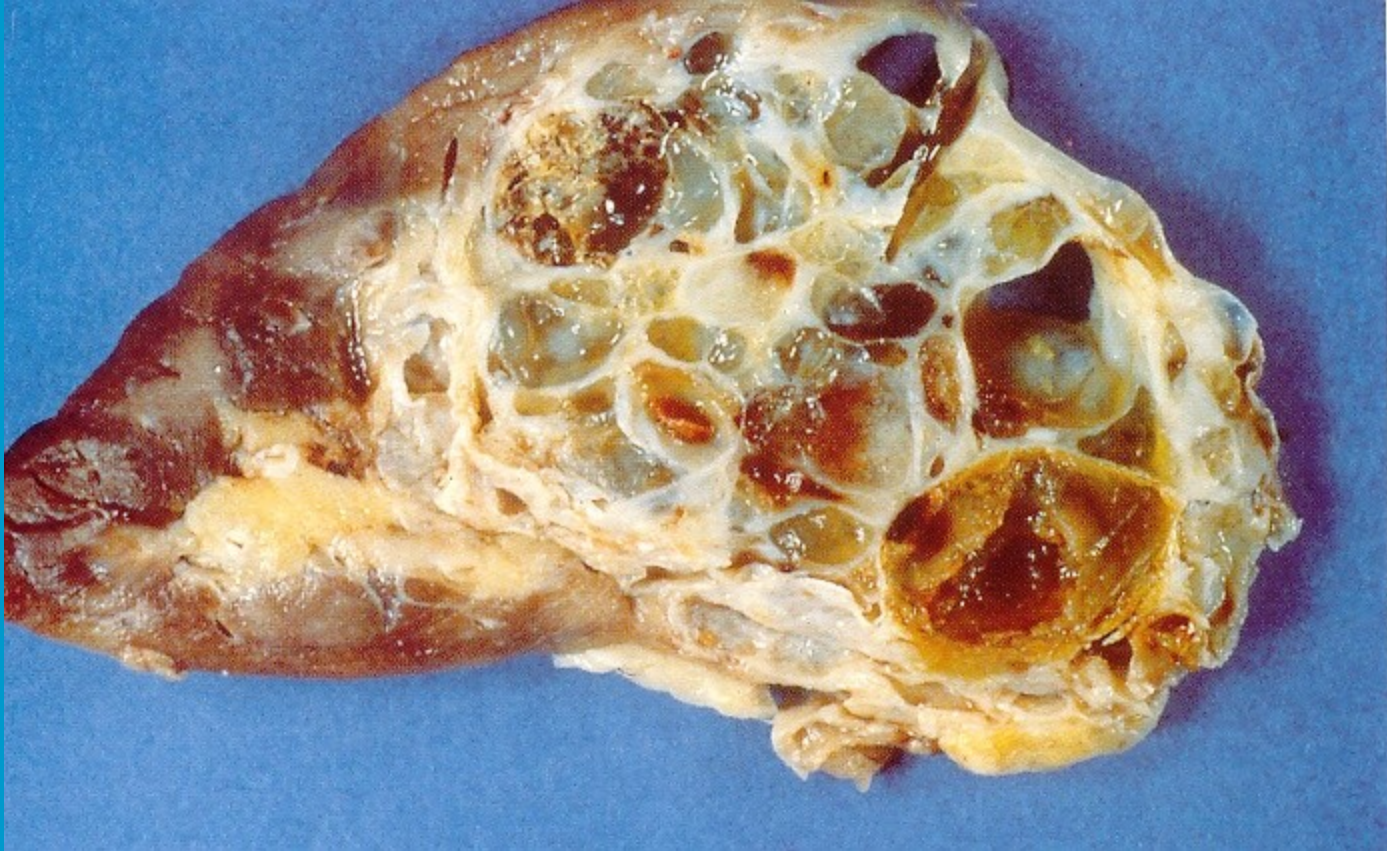

# Renal cell carcinoma





# Renal cell carcinoma

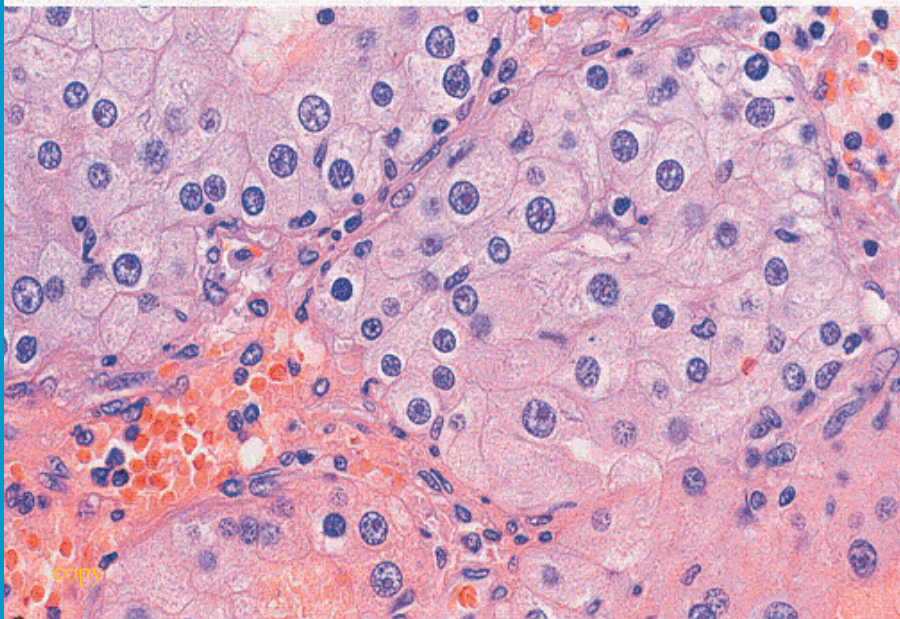
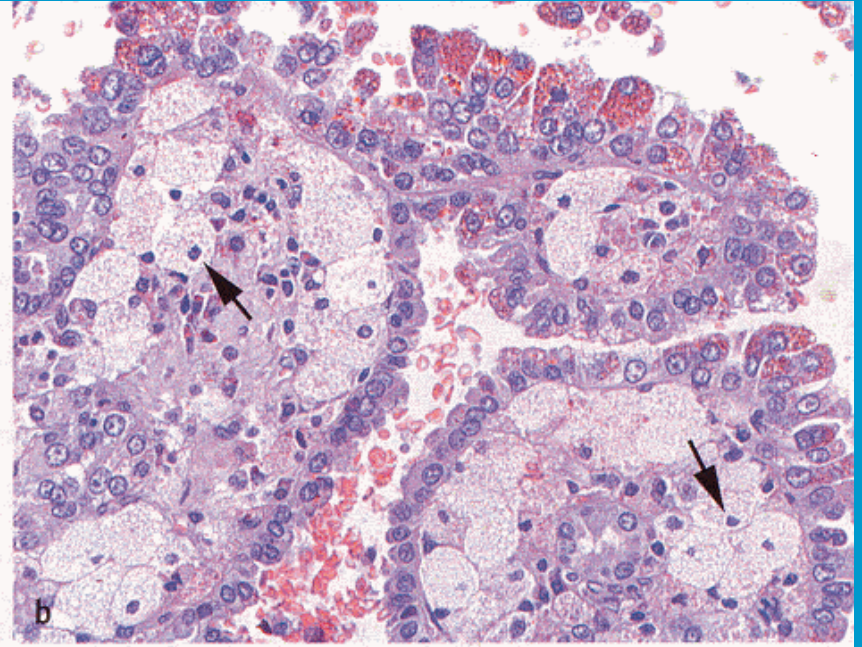
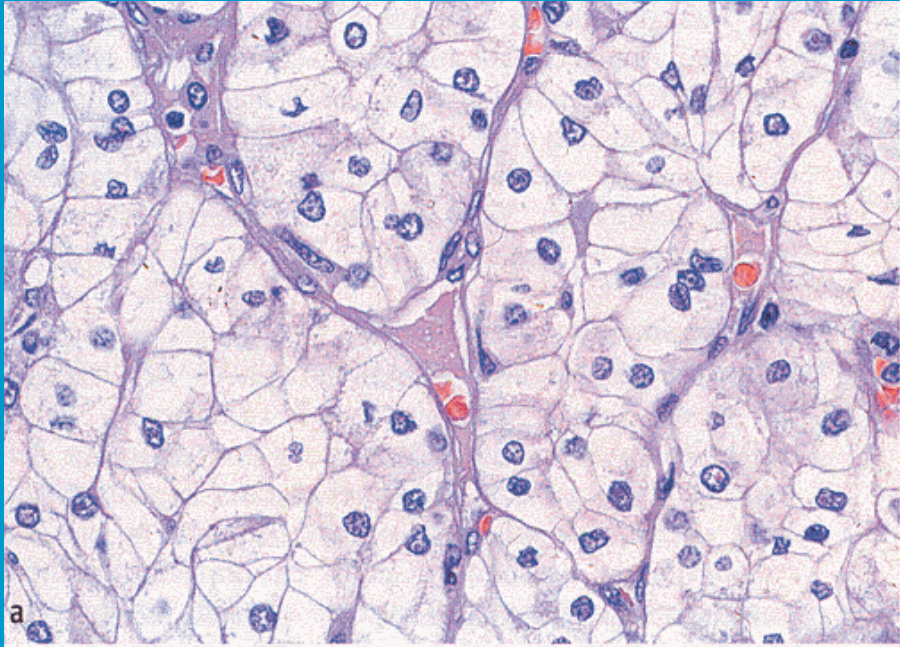


# RCC

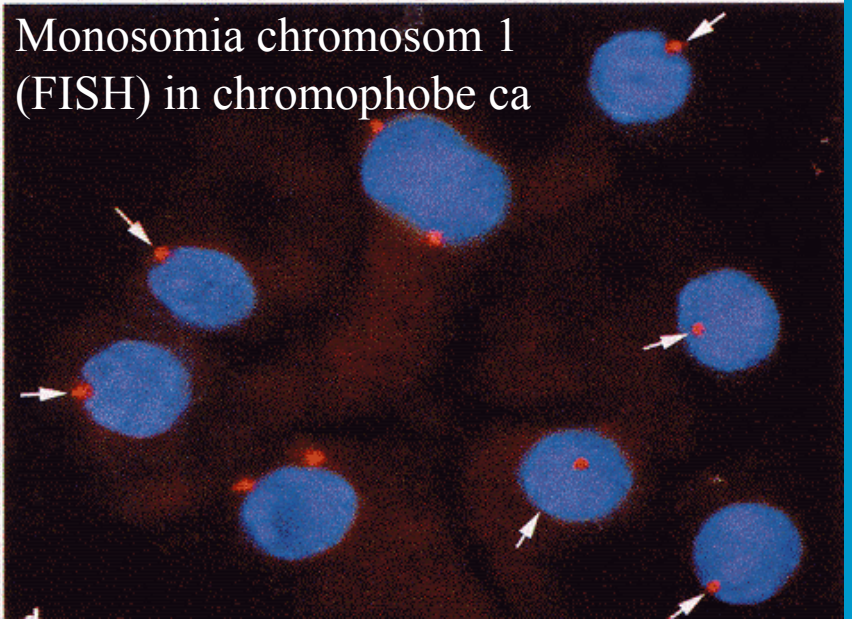
- Clear cell (conventional) RCC (80%)
  - glycogene + lipids in cytoplasm, common regressive changes, venous invasion, may have late metastasis
    - nuclear grading
- Chromophobe RCC 5 %
  - very good prognosis, eosinophilic granular cytoplasm
- Papillary RCC: 15 %,
  - commonly multifocal / bilateral, stromal foam macrophages



# Renal cell carcinoma

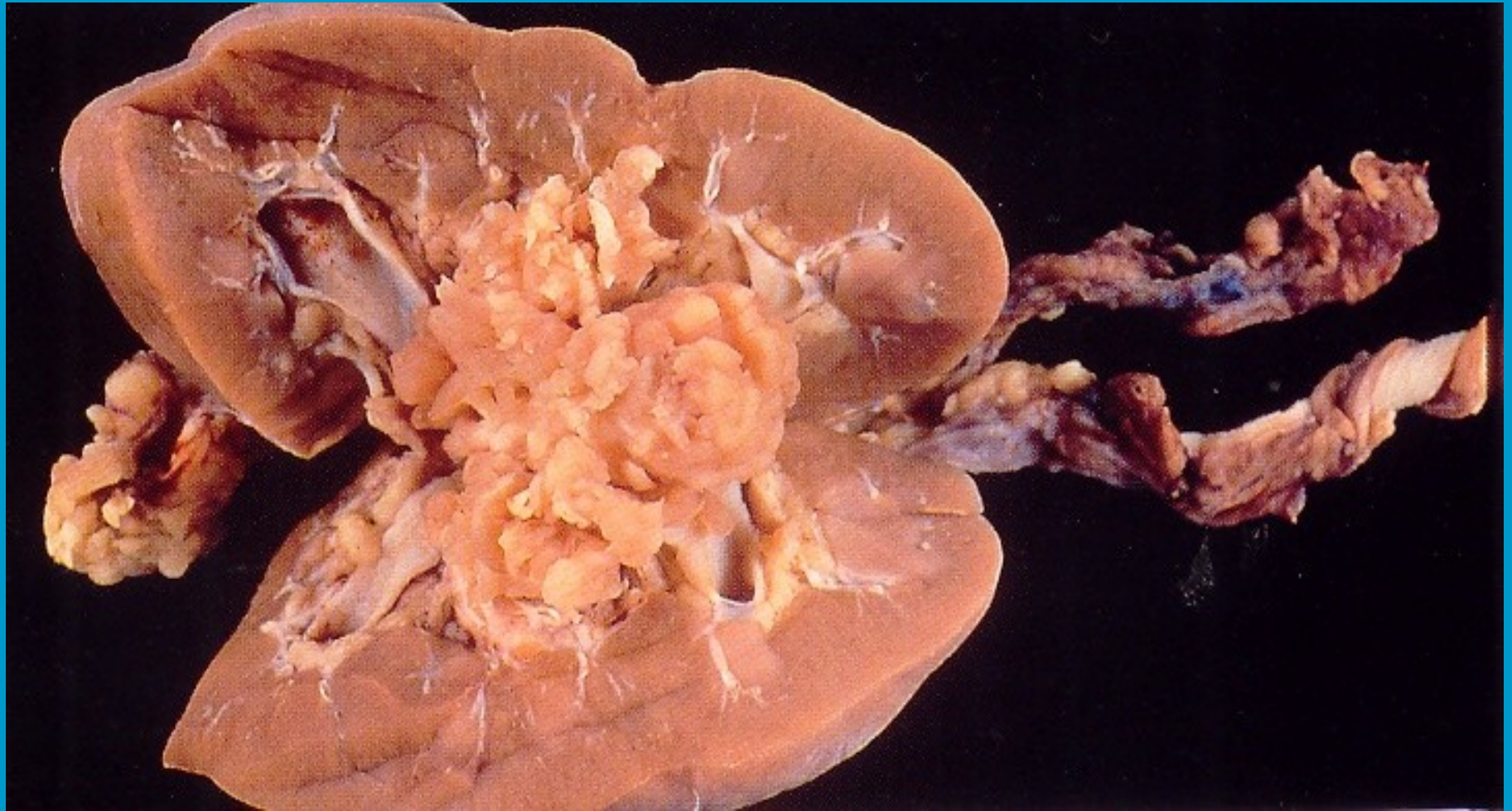


Monosomia chromosom 1  
(FISH) in chromophobe ca

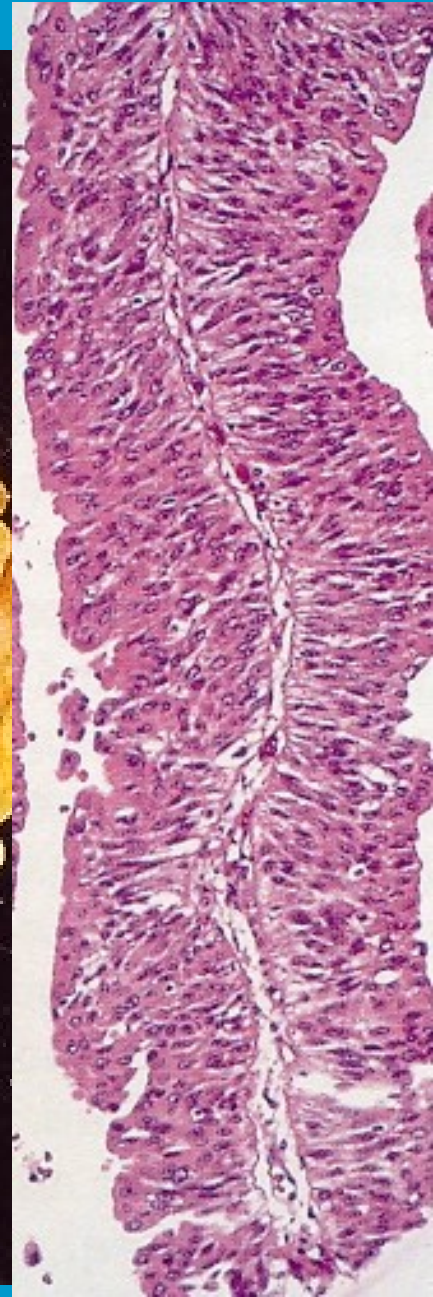
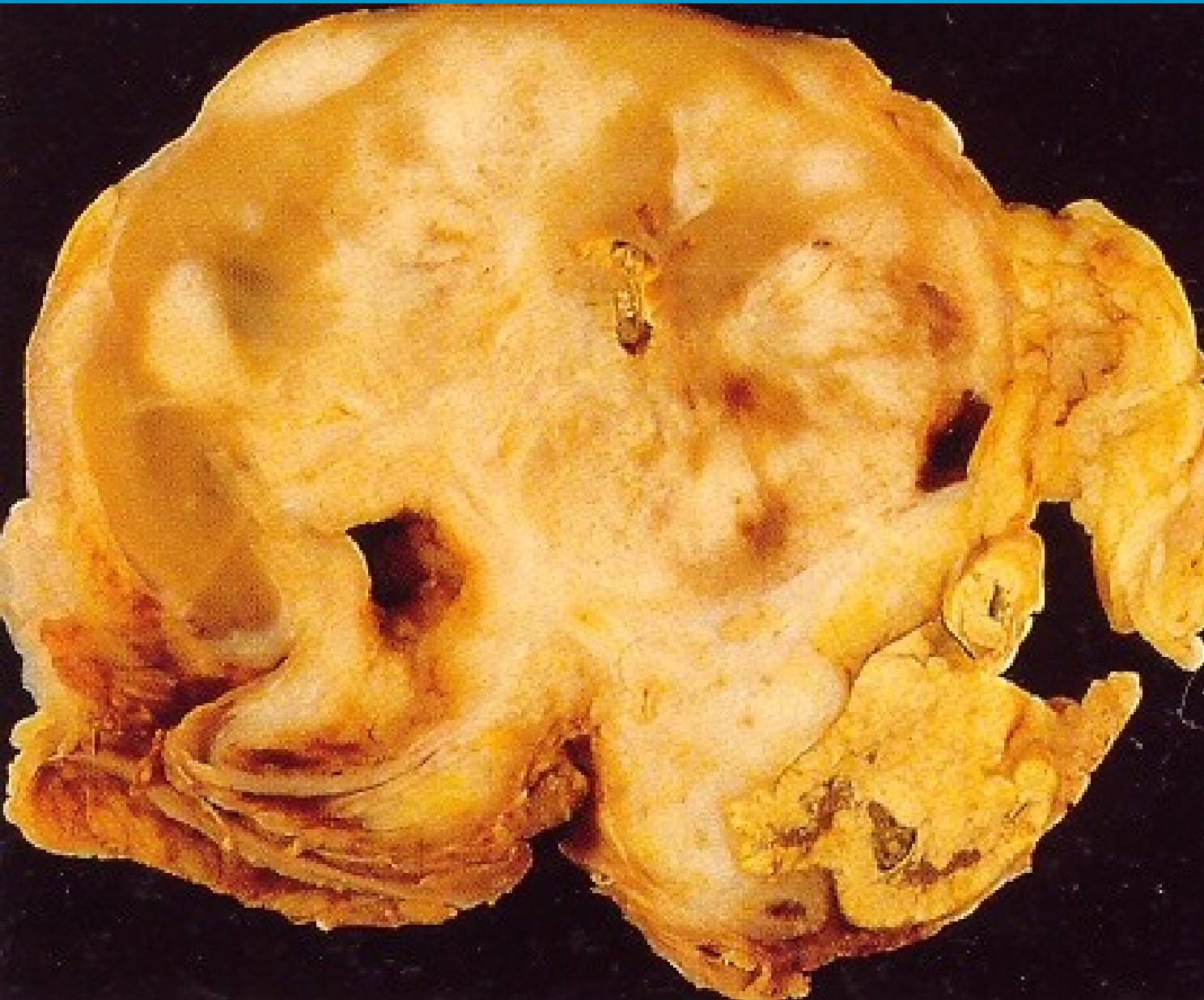



# Transitional cell ca of the renal pelvis



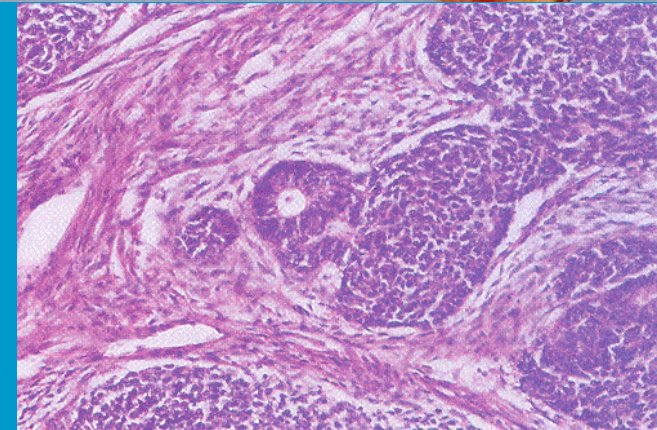
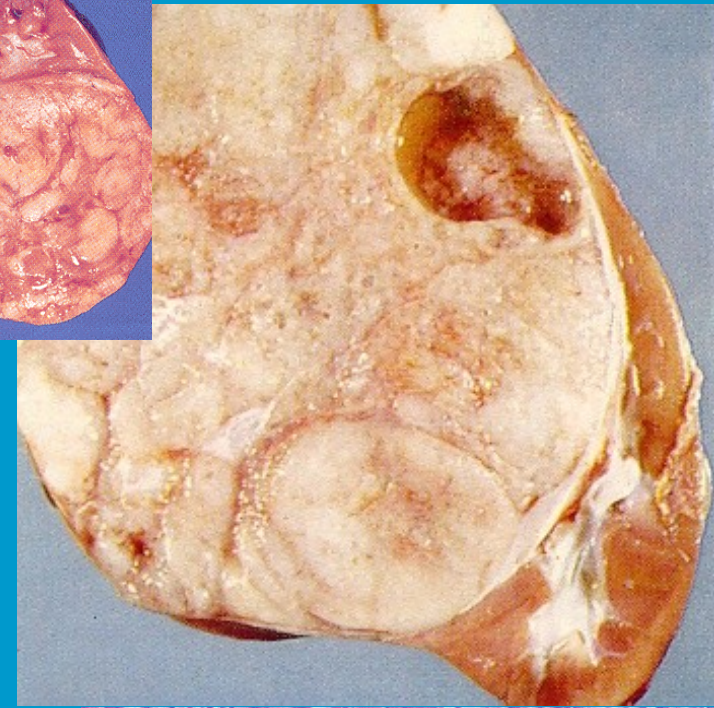
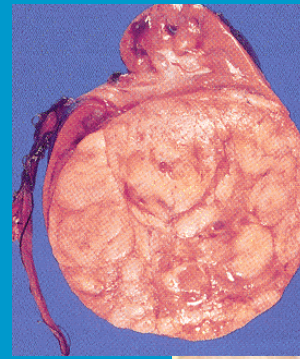
# Transitional cell ca of the renal pelvis





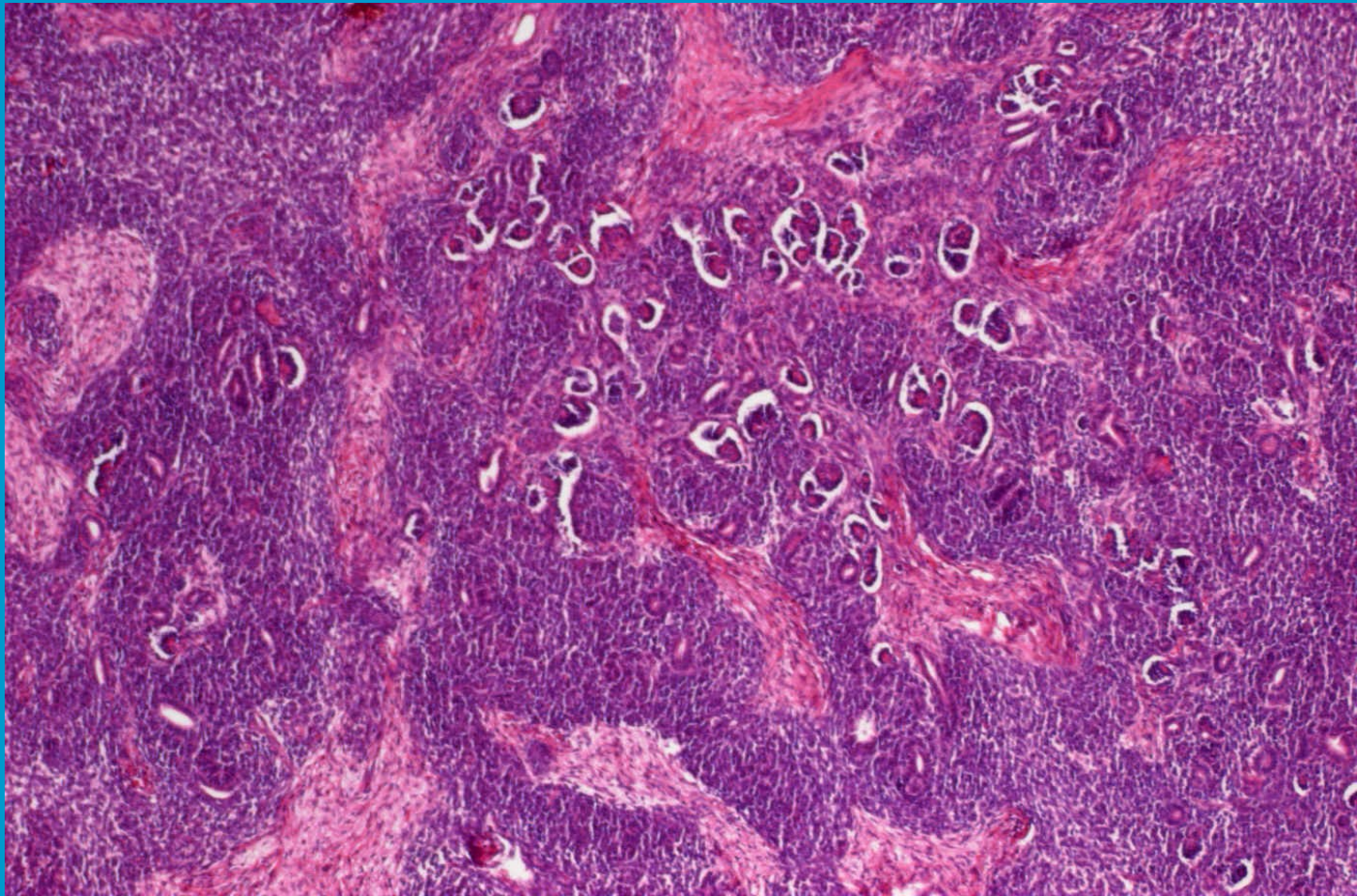
# Wilms' tumor - nephroblastoma

- Malignant embryonal tumor arising from metanephrogenous blastema
- Peak incidence 1-4 yrs
- 3rd most common ch. malignancy, treatable
- hematuria, local compression
- Suppressor gene WT1 (11p13), WT2 (11p15)
- MACRO: large, soft
- MICRO blastic cells, immature **epithelial, mesenchymal** differentiation





# Wilms' tumor - nephroblastoma



# Secondary tumors

- Local spread (adrenals, pancreas, liver)
- Lung carcinoma
- Malignant lymphoma
- Others

