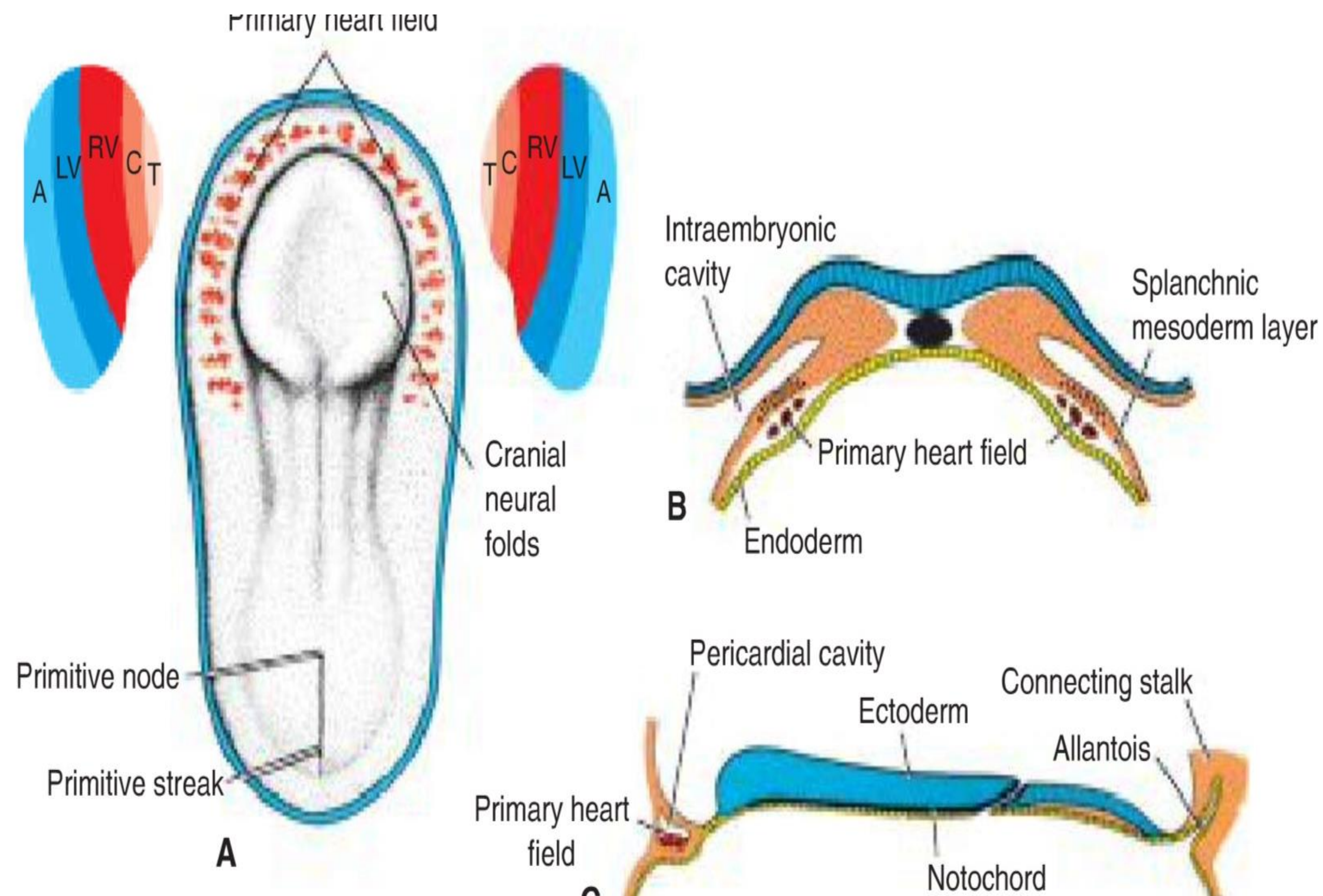


# Development and teratology of cardiovascular systems

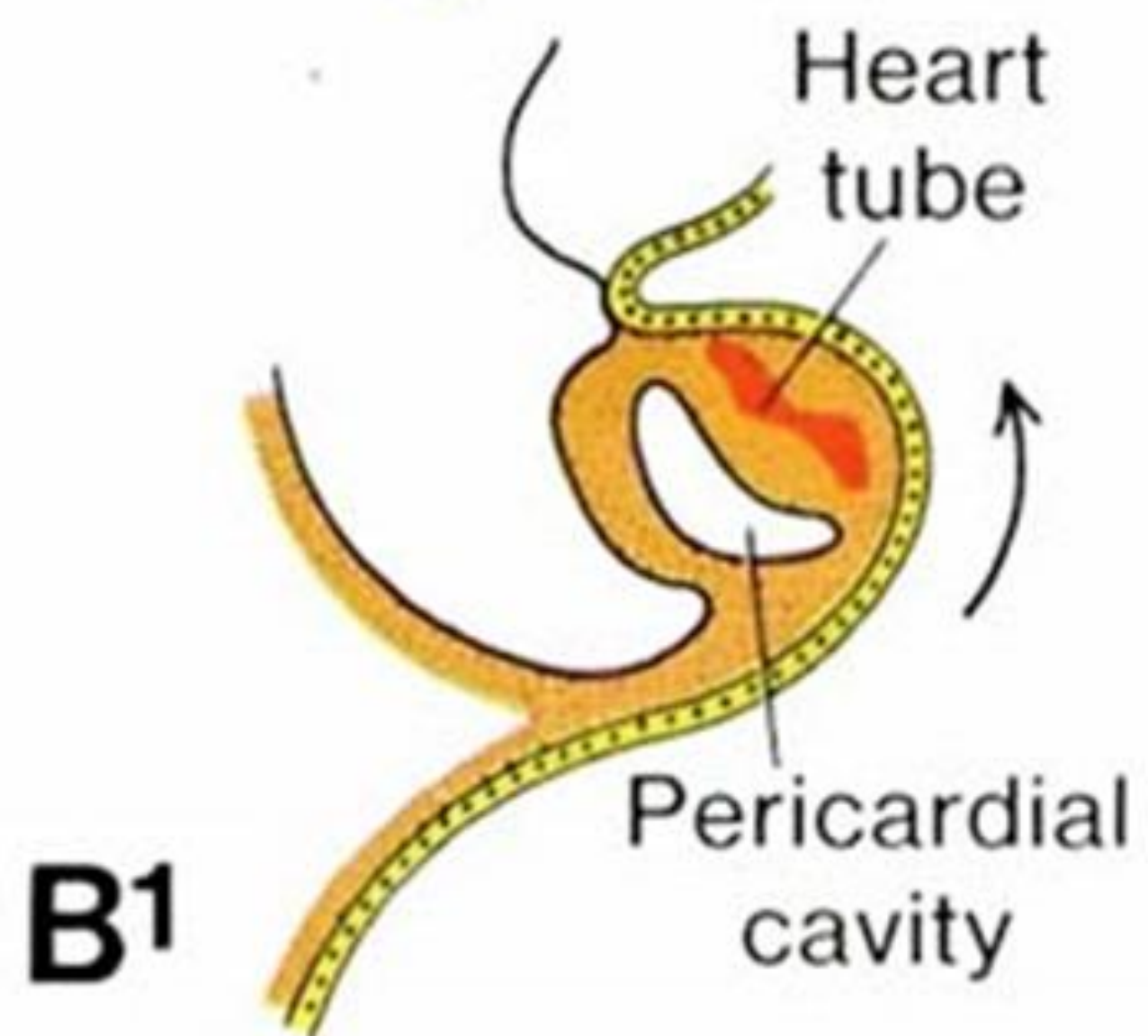
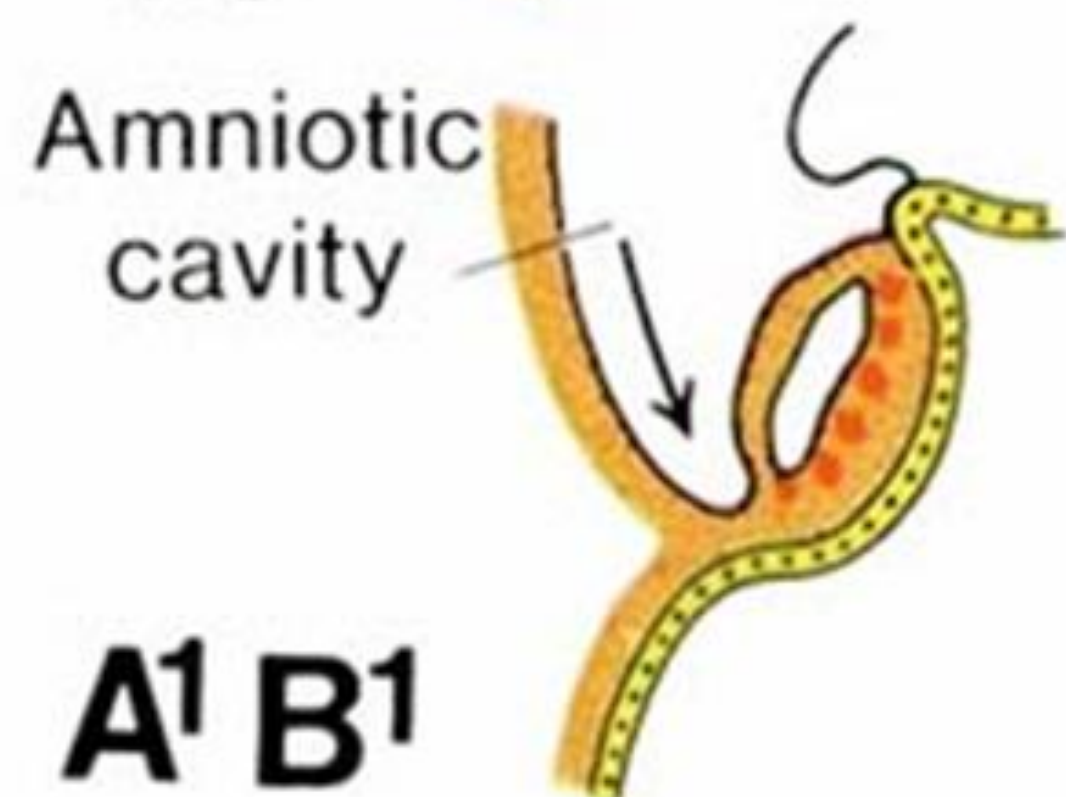
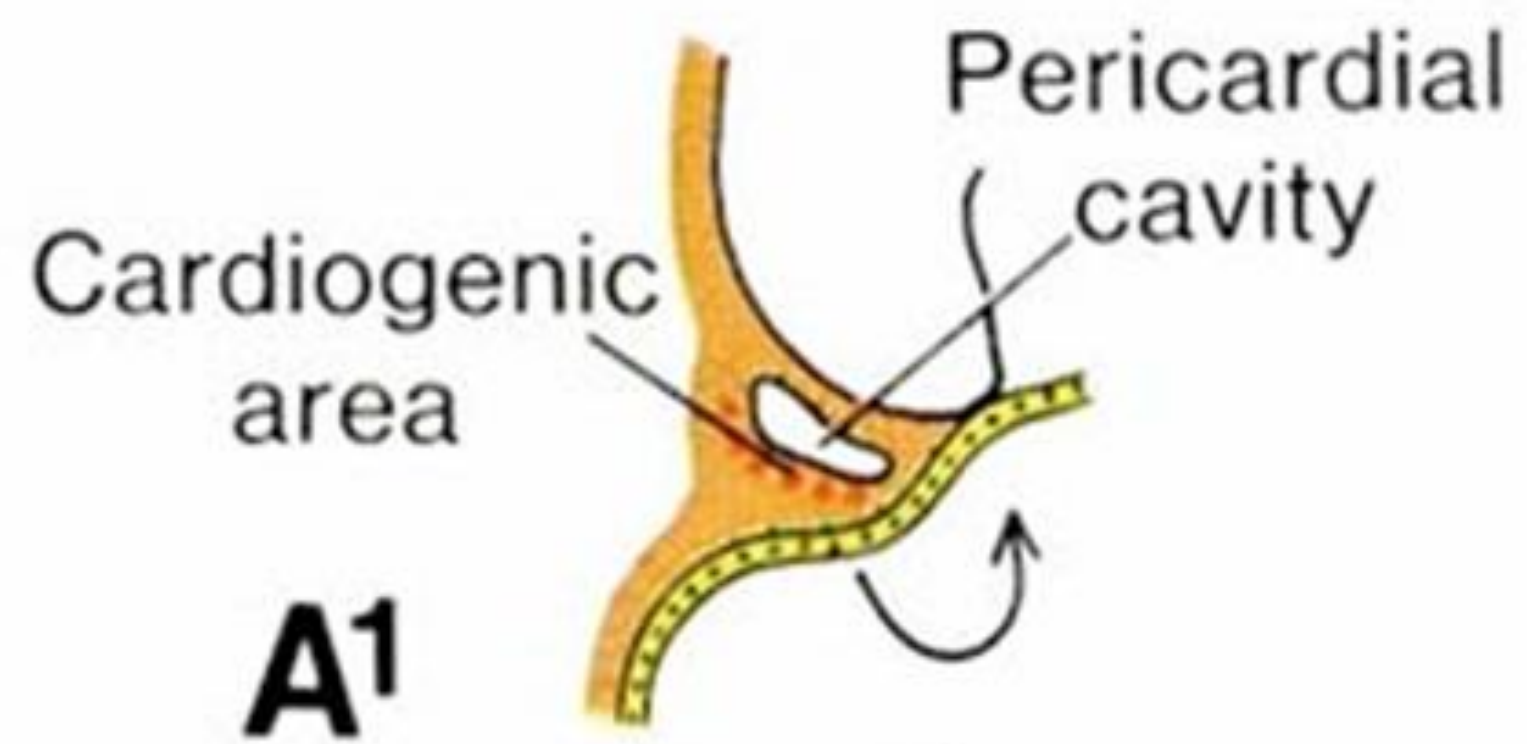
19.2.2024

Anna Mac Gillavry Danylevska

# Formation of primary heart field

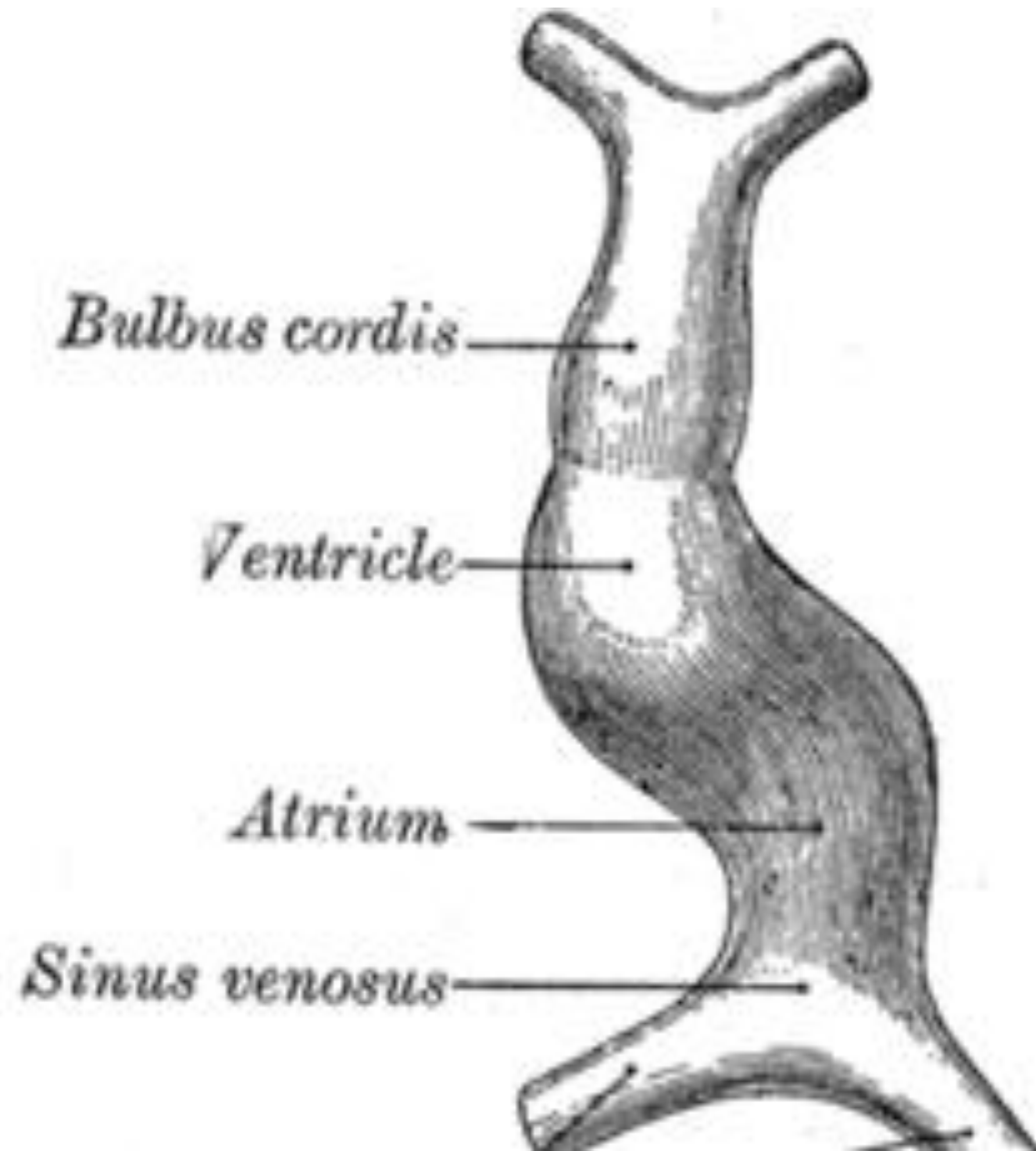


- WHEN? - middle of the 3rd week (day 16)
- WHAT? - progenitor heart cells
- WHERE? - from epiblast through the primitive streak to the visceral layer of lateral plate mesoderm
- DO WHAT? - form PHF



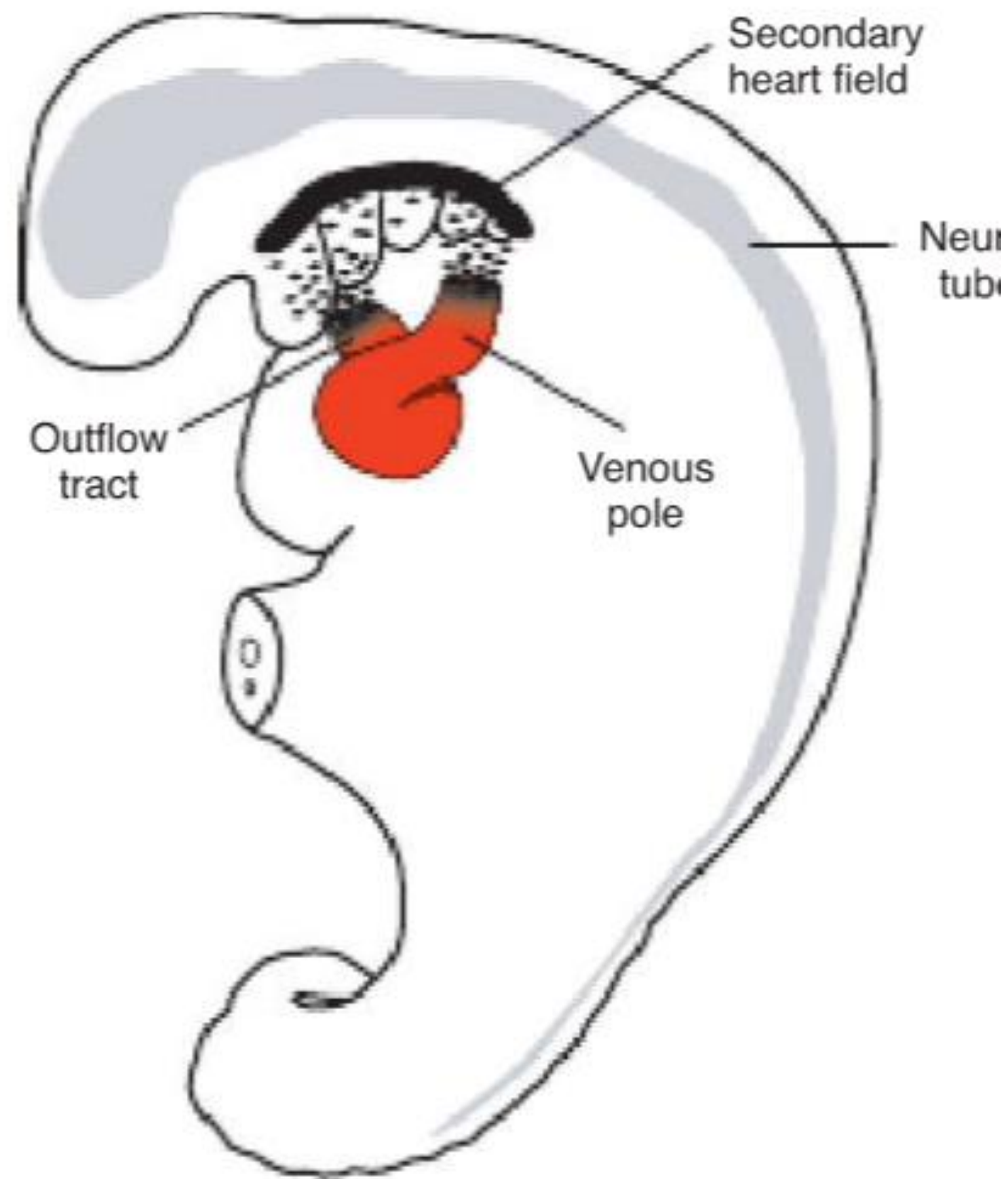


# Formation of the heart tube

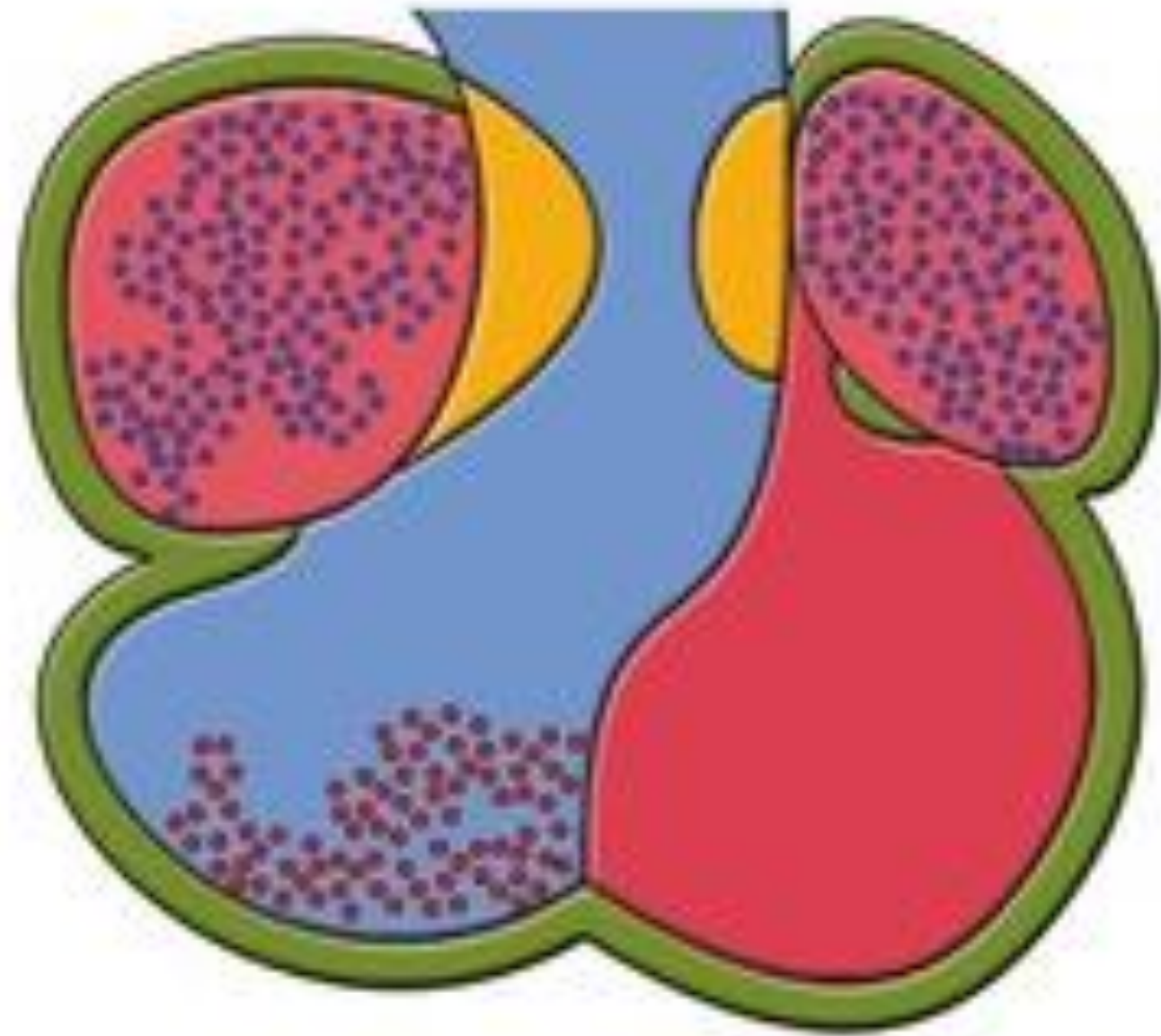


- WHEN? - day 22-28
- WHAT? – cells of the PHF
- DO WHAT? – form cardiac myoblasts and the blood islands ---> the horseshoe-shaped endothelial-lined tube surrounded by myoblast (=cardiogenic region/field), further the caudal portion fuse except for the caudal most part

# The heart tube lengthening



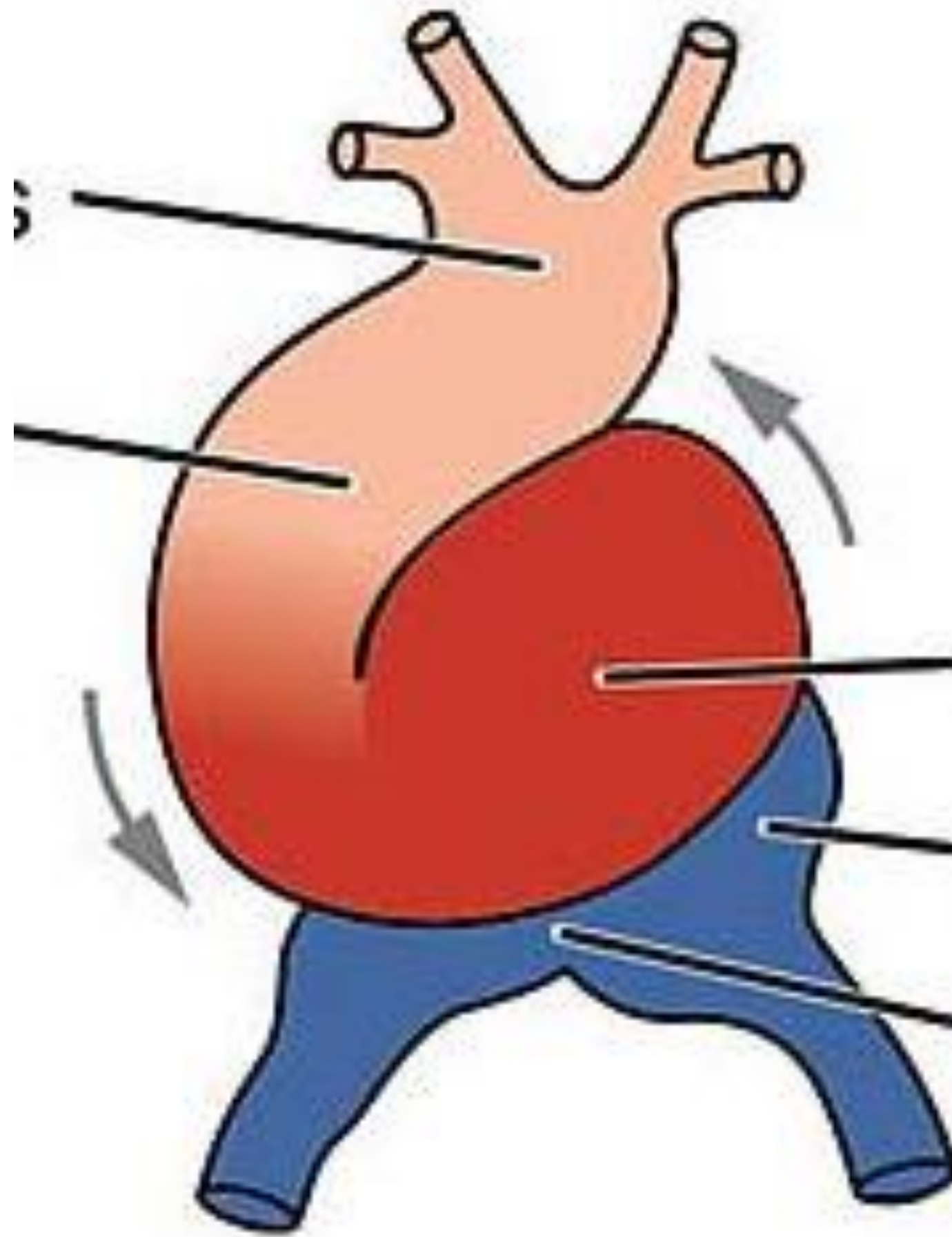
- WHEN? - day 22-28
- WHAT? – SHF in splanchnic mesoderm ventrally to the posterior pharynx
- WHERE? - thoracic region
- DO WHAT? – provides cells to lengthen both poles of the heart tube: atria and sinus venosus, right ventricle, conus cordis and truncus arteriosus



- First heart field
- Second heart field
- Neural crest
- Proepicardial organ



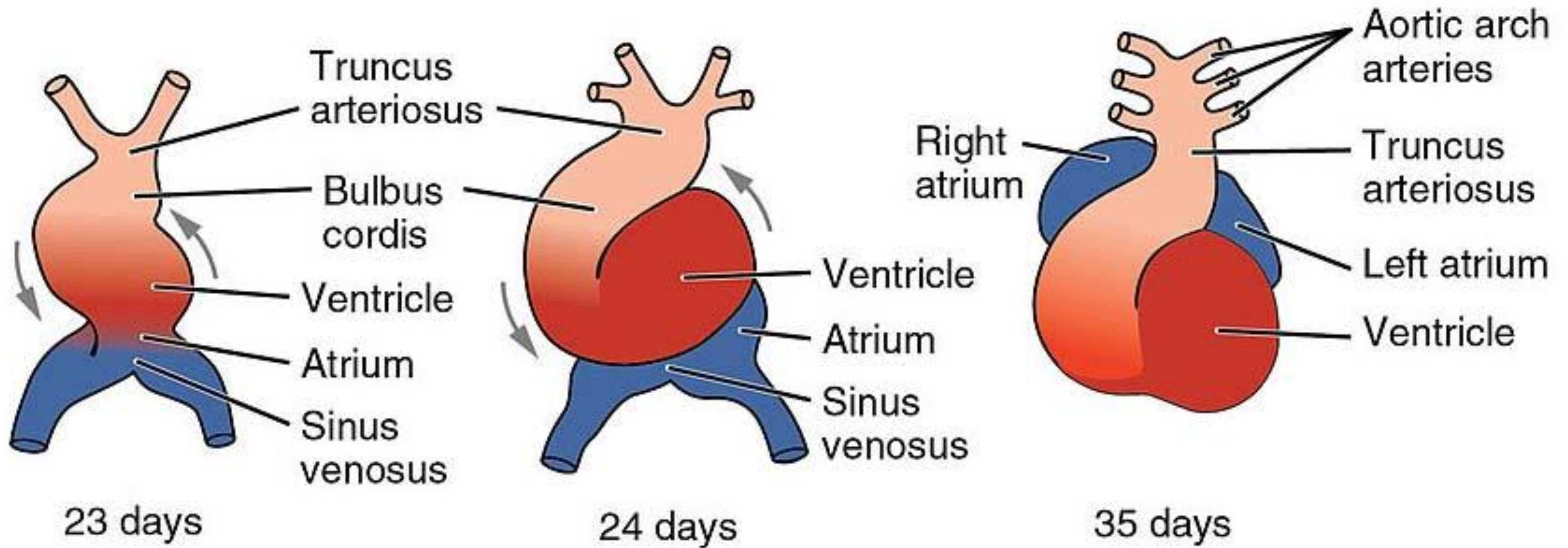
# Looping of the heart



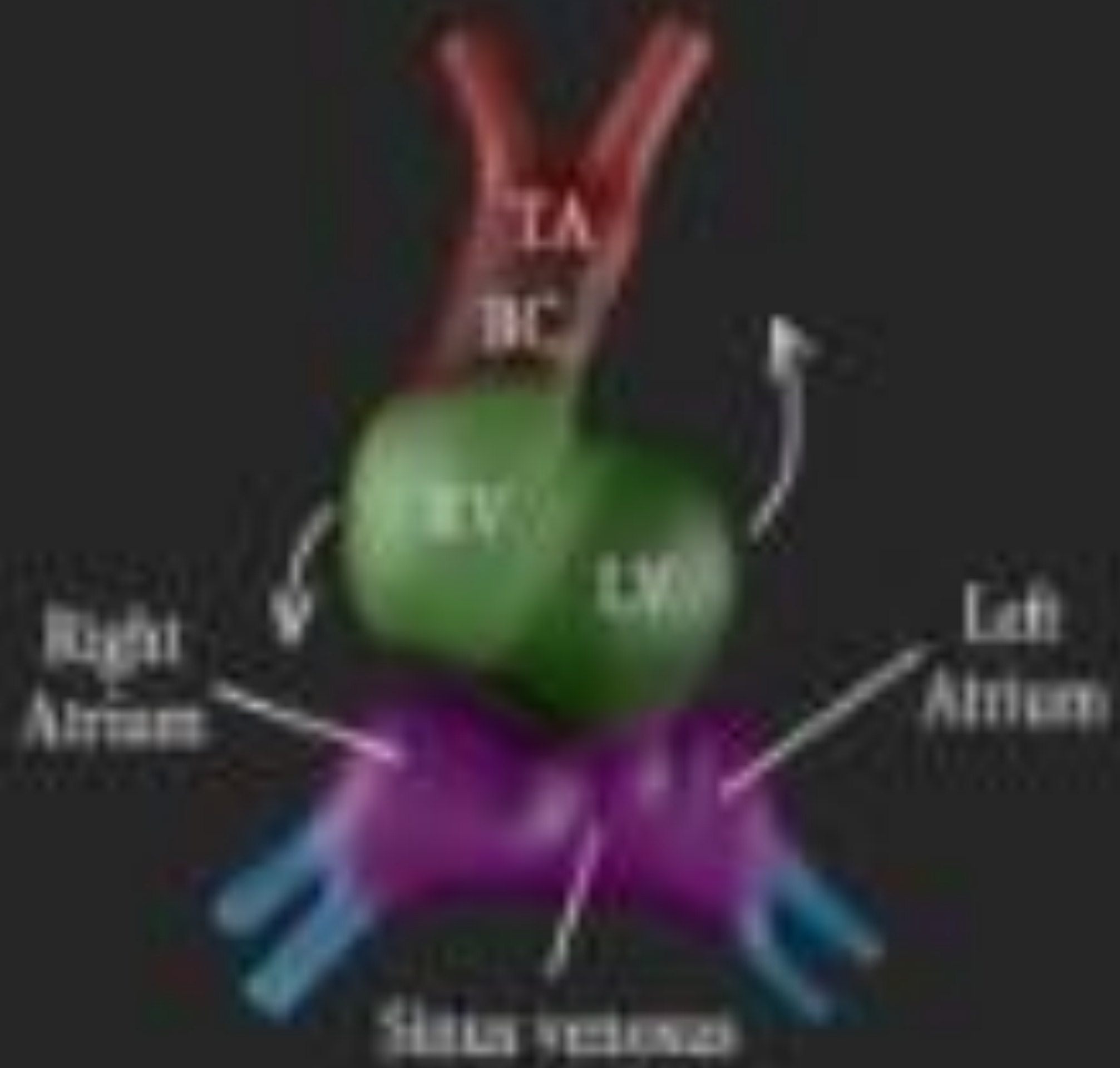
24 days

- WHEN? - day 23-28
- WHAT? - the primitive heart tube
- DO WHAT? - cephalic portion bends ventrally, caudally and to the right; caudal portion bends dorsally, cranially and to the left







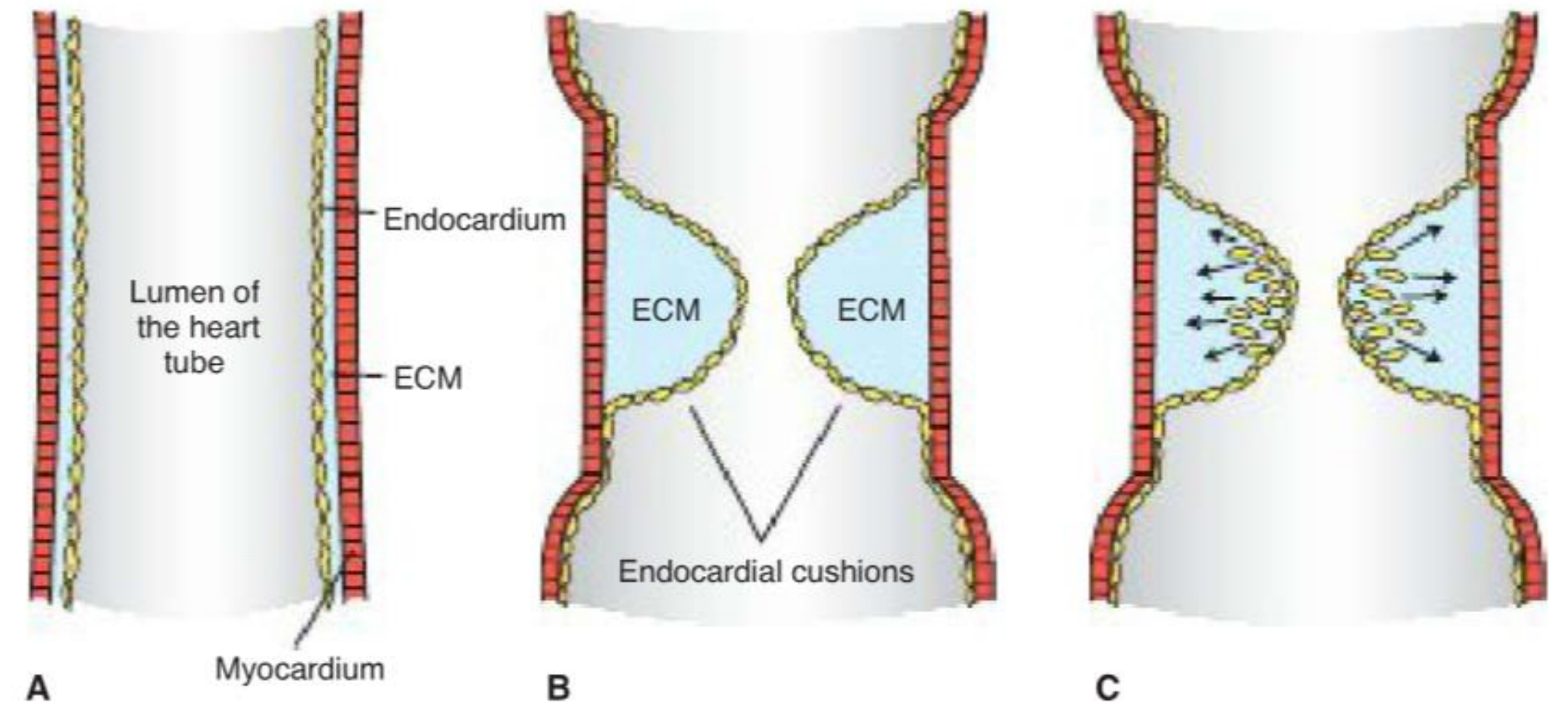
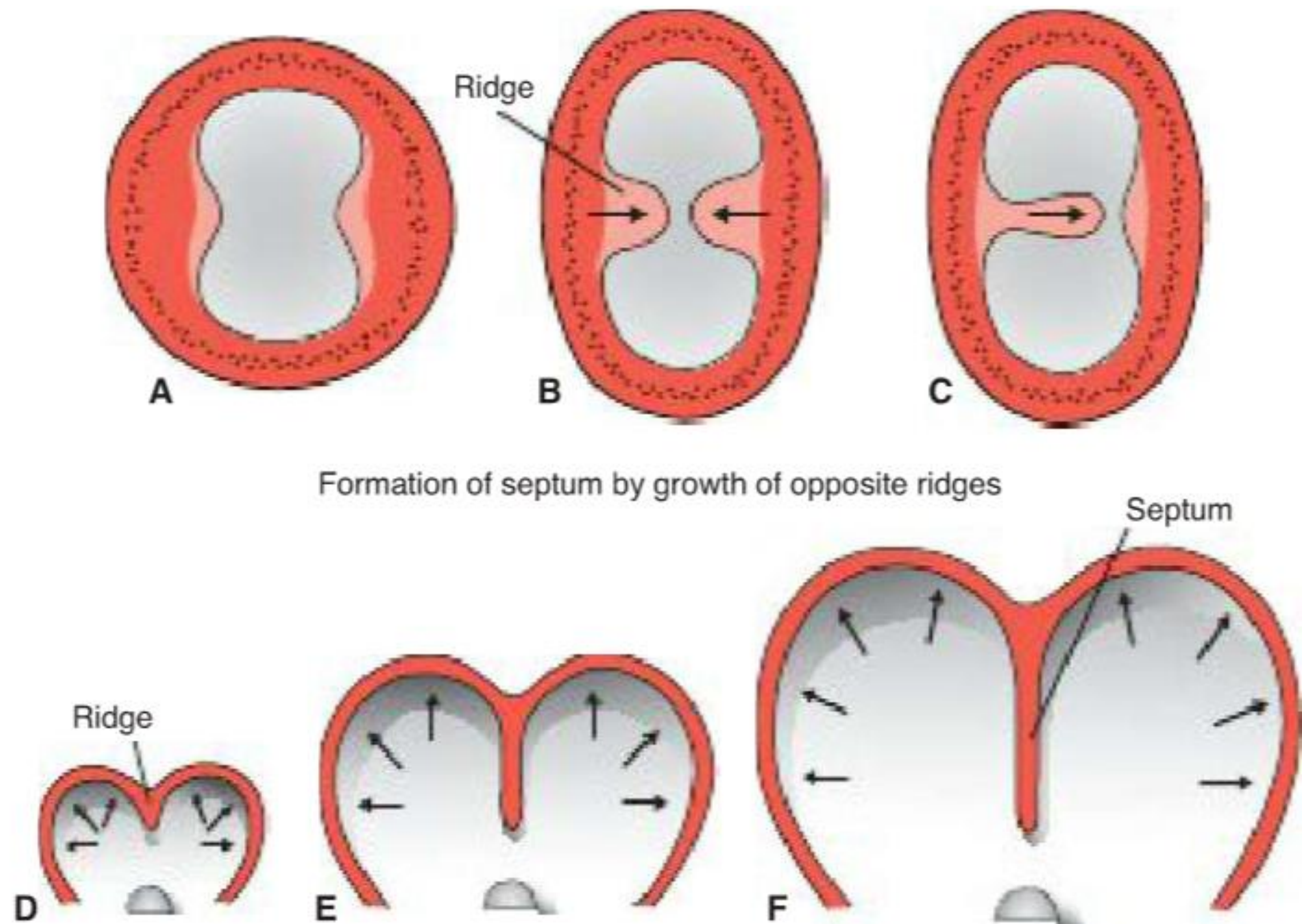


# Formation of the cardiac septa

- WHEN? - day 27-37 (size of the embryo 5-16 mm!)
- WHAT? – septum in the common atrium
  - septum in the atrioventricular canal
  - septum in the truncus arteriosus and conus cordis
  - septum in ventricles

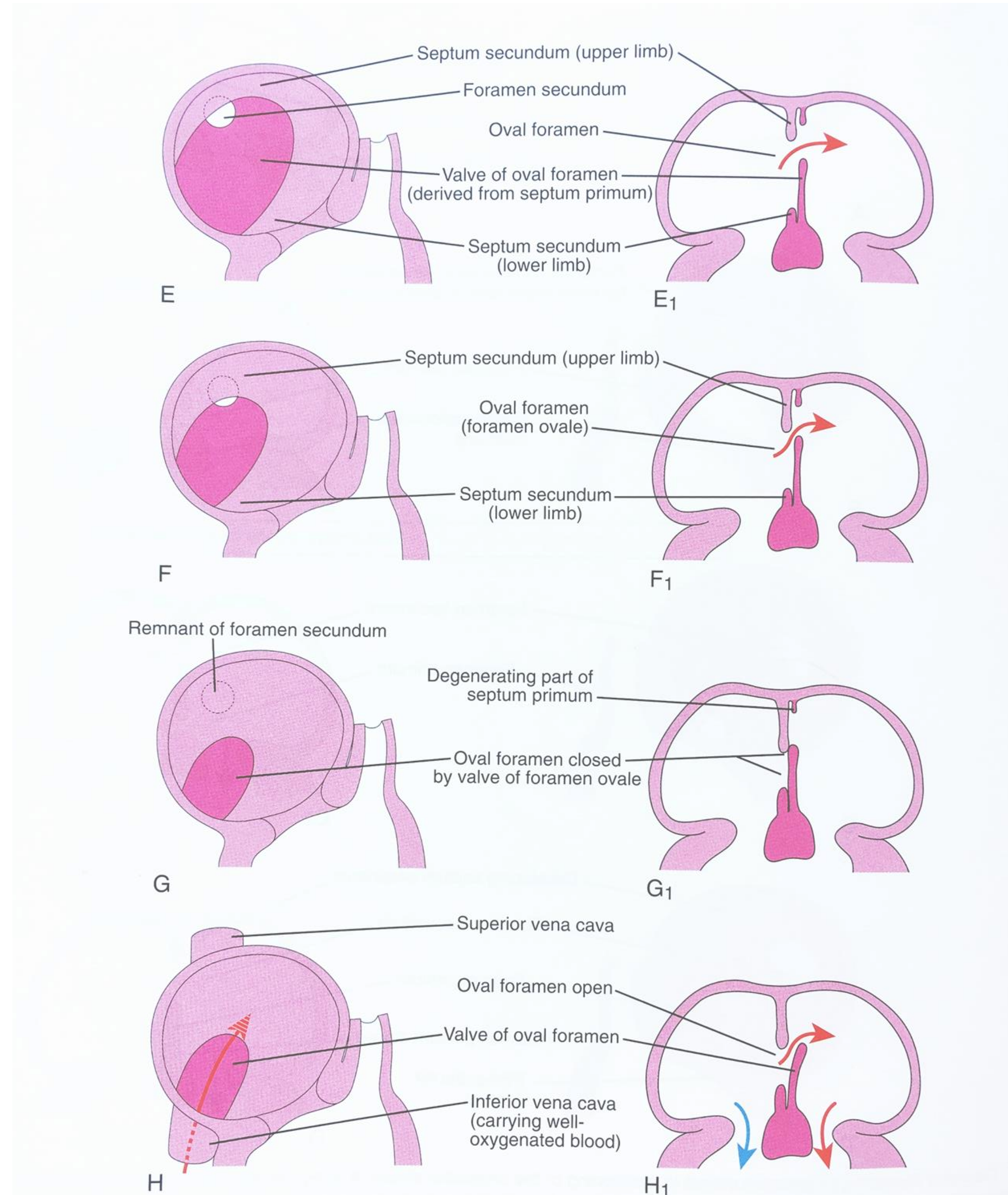
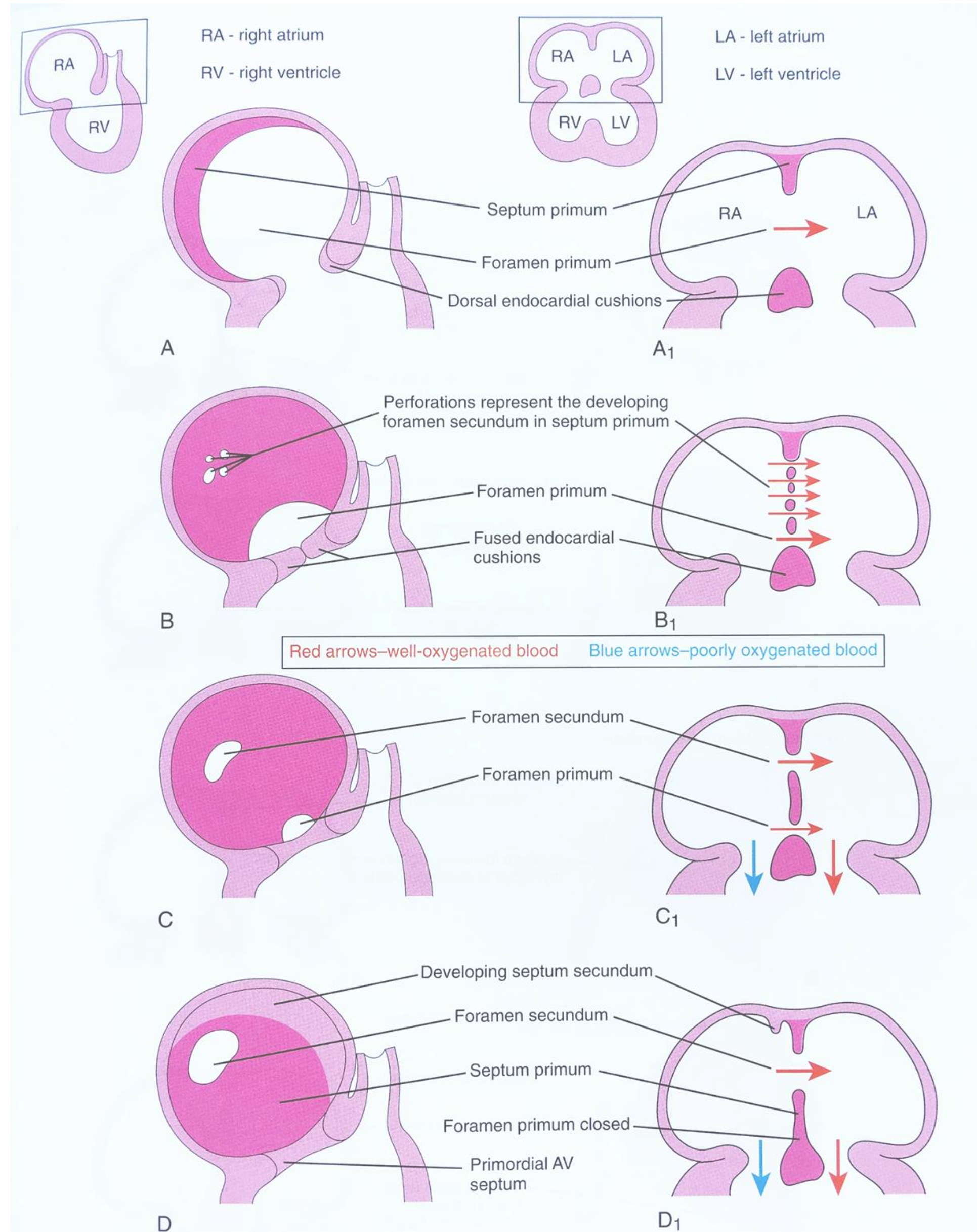


# Formation of the cardiac septa





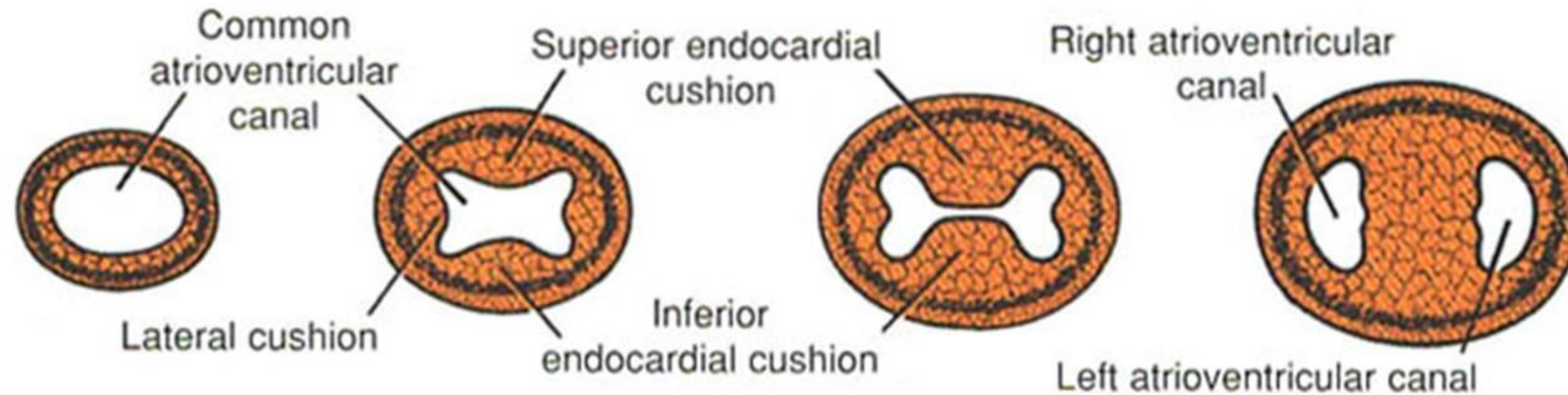
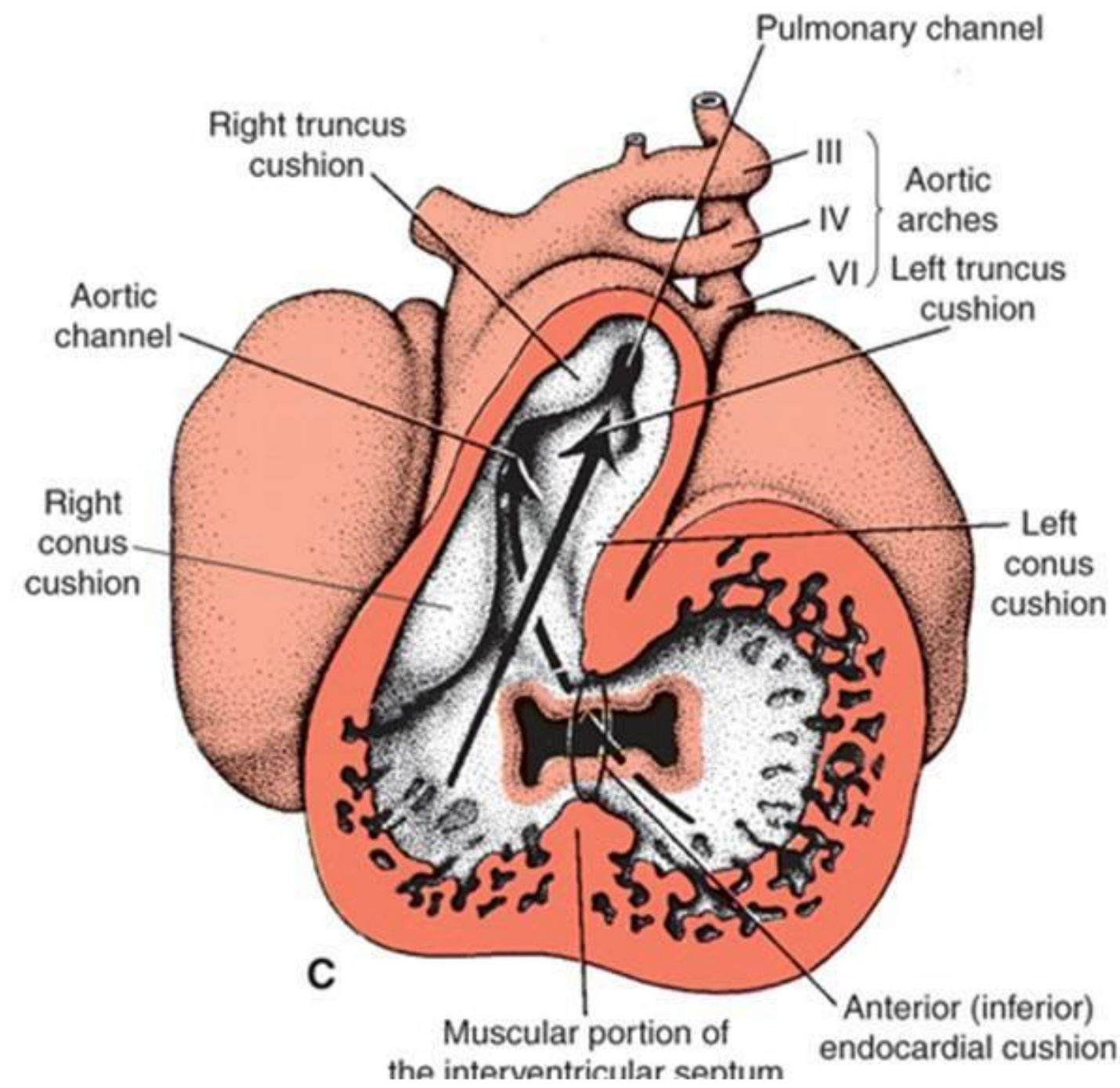
# Septum in the common atrium





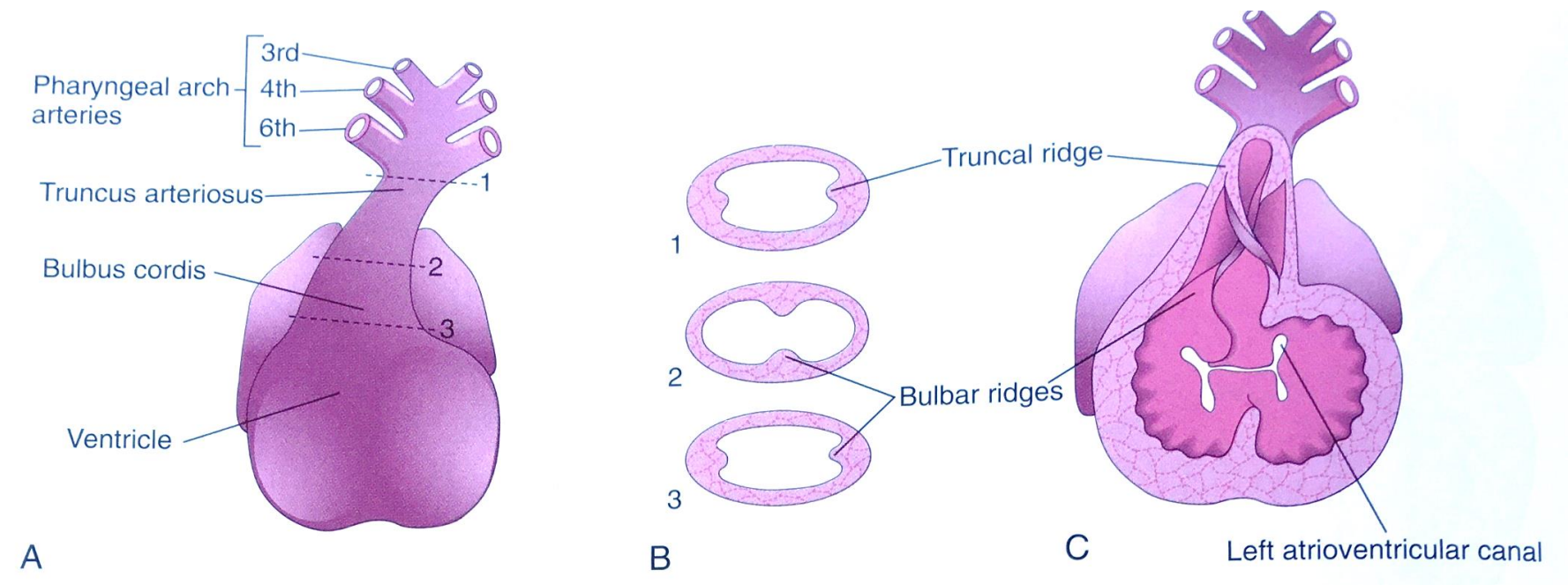
# Septum in the atrioventricular canal

End of the 4th till end of the 5th week



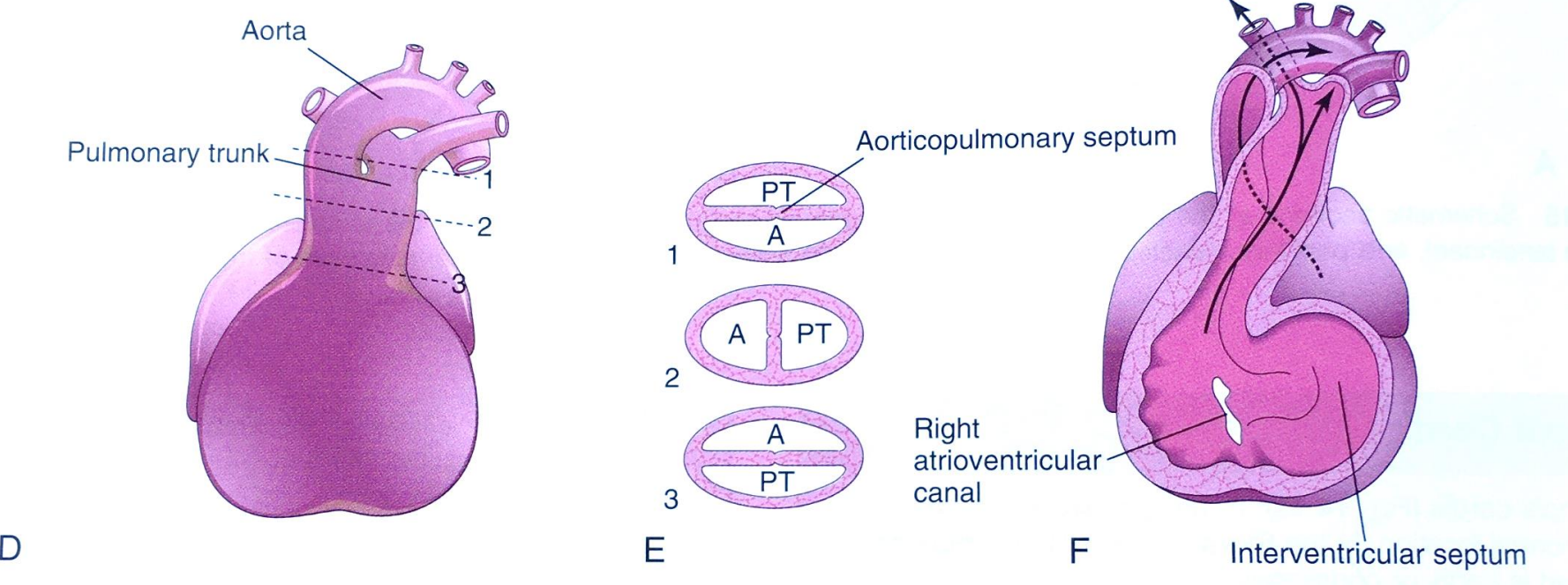


# Septum in the truncus arteriosus and conus cordis

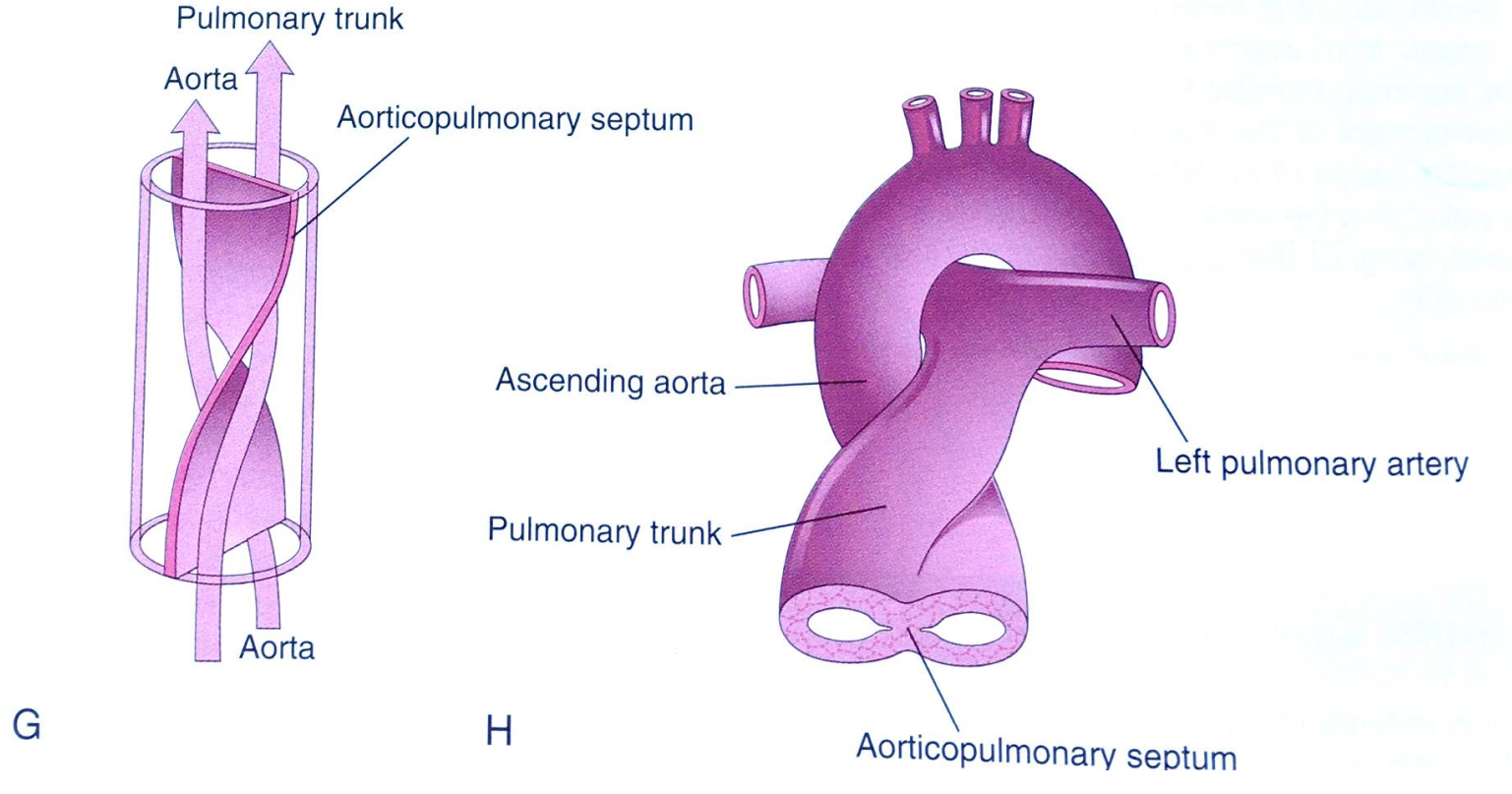


5th week – **truncus swellings**: **right superior** –grows distally to the left  
**left inferior** – grows distally to the right

**conus swellings** – grow towards each other and distally to fuse with the truncus swellings



## NEURAL CREST CELLS



K. Moor, Before we are born

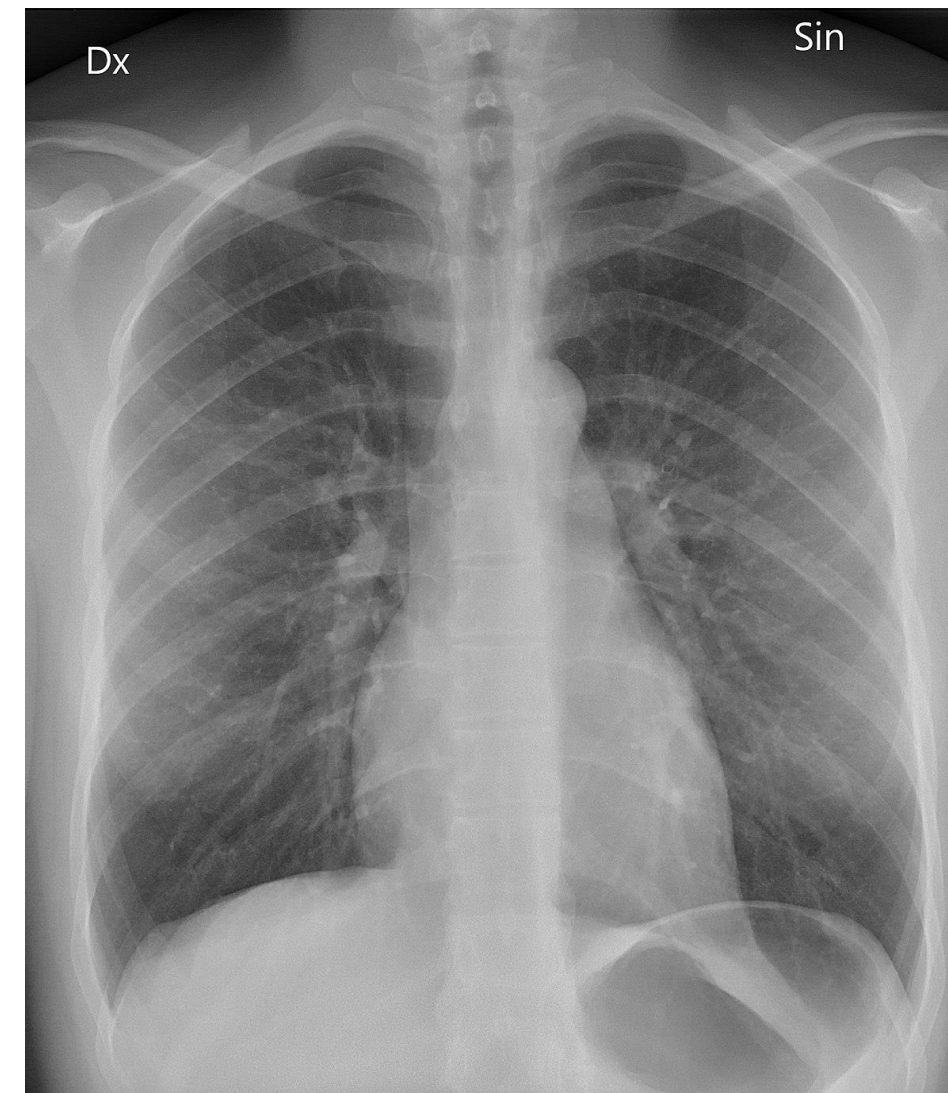

# Congenital heart defects (CHDs)

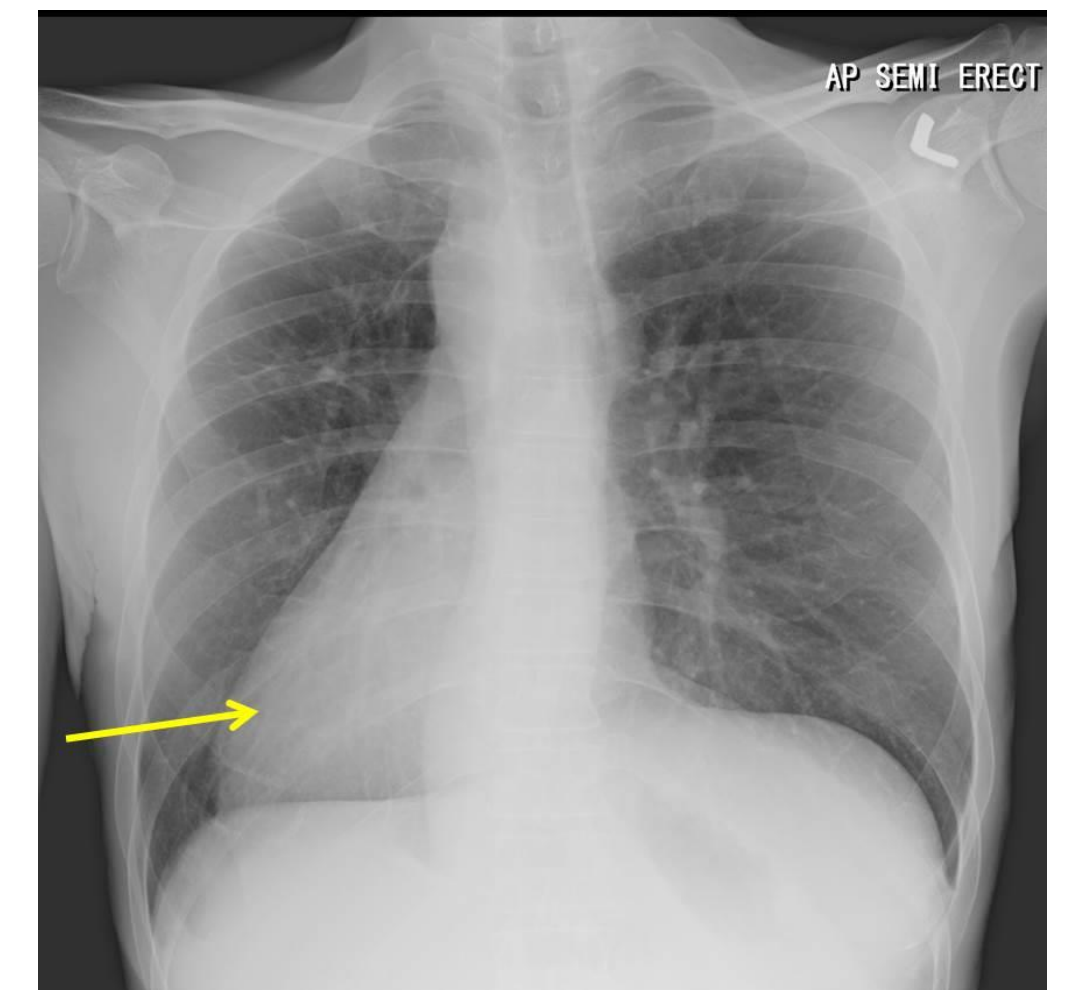
in 1% of live born infants; Rubella, thalidomide, RA, alcohol, maternal insulin-dependent diabetes

**Laterality** – during the gastrulation, signaling cascade includes serotonin, thus the SSRI class antidepressants are linked to the increase in heart defects:

- dextrocardia (situs inversus, heterotaxy)
- ventricular septal defects (VSDs)
- atrial septal defects (ASDs)
- double outlet right ventricle (DORV)
- transposition of the great vessels
- pulmonary stenosis
- atrial/ventricular isomerism
- inversions



[https://en.wikipedia.org/wiki/Chest\\_radiograph](https://en.wikipedia.org/wiki/Chest_radiograph)



<http://radiologycases.my/2020/08/08/isolated-dextrocardia/>

# Atrial septal defects (ASDs)

6,4/10 000; 2:1 prevalence in F to M; acyanotic

**Patent foramen ovale** in 10-20% of population

4 clinically significant ASD:

- **ostium secundum ASDs** (90% cases; 10-15% of all CHDs)
- **endocardial cushion defects with a foramen primum** (in 25% of patients with Down syndrome)
- **sinus venosus ASDs**
- **common atrium** (*cor triloculare biventriculare*) - combination of the above

extra blood volume goes to the right side of the heart (delay in the pulmonary valve closure – splitting of the S2 sound), paradoxical embolism

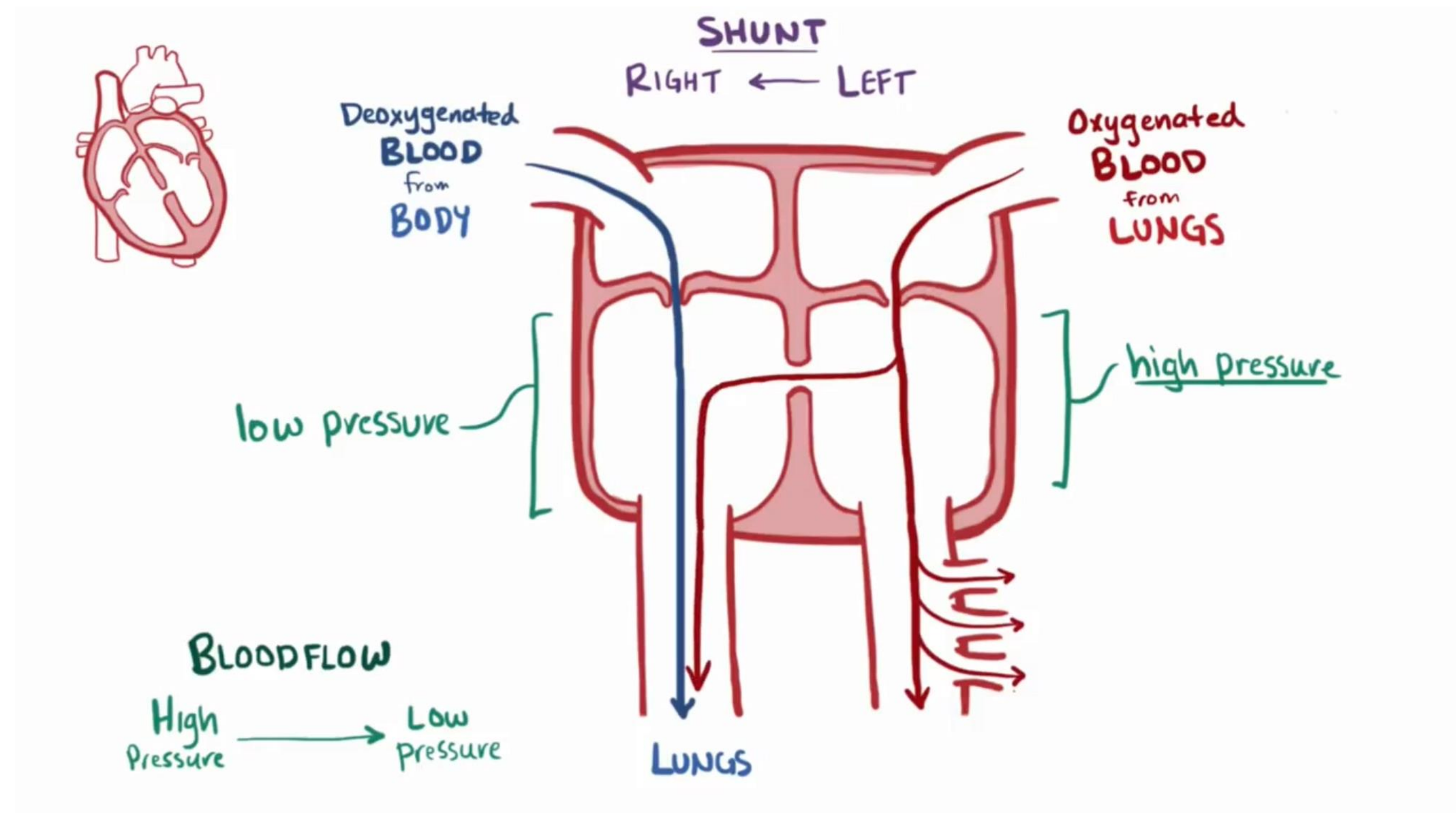


# Ventricular septal defects (VSDs)

most common CHDs 12/10 000; acyanotic; 80% in the muscular region and resolve during the childhood

membranous part defects are more severe and associated with other abnormalities

the blood volume carried by pulmonary artery increases (can be 1,2-1,7 times more than aorta) leading to the pulmonary hypertension and can cause Eisenmenger syndrome



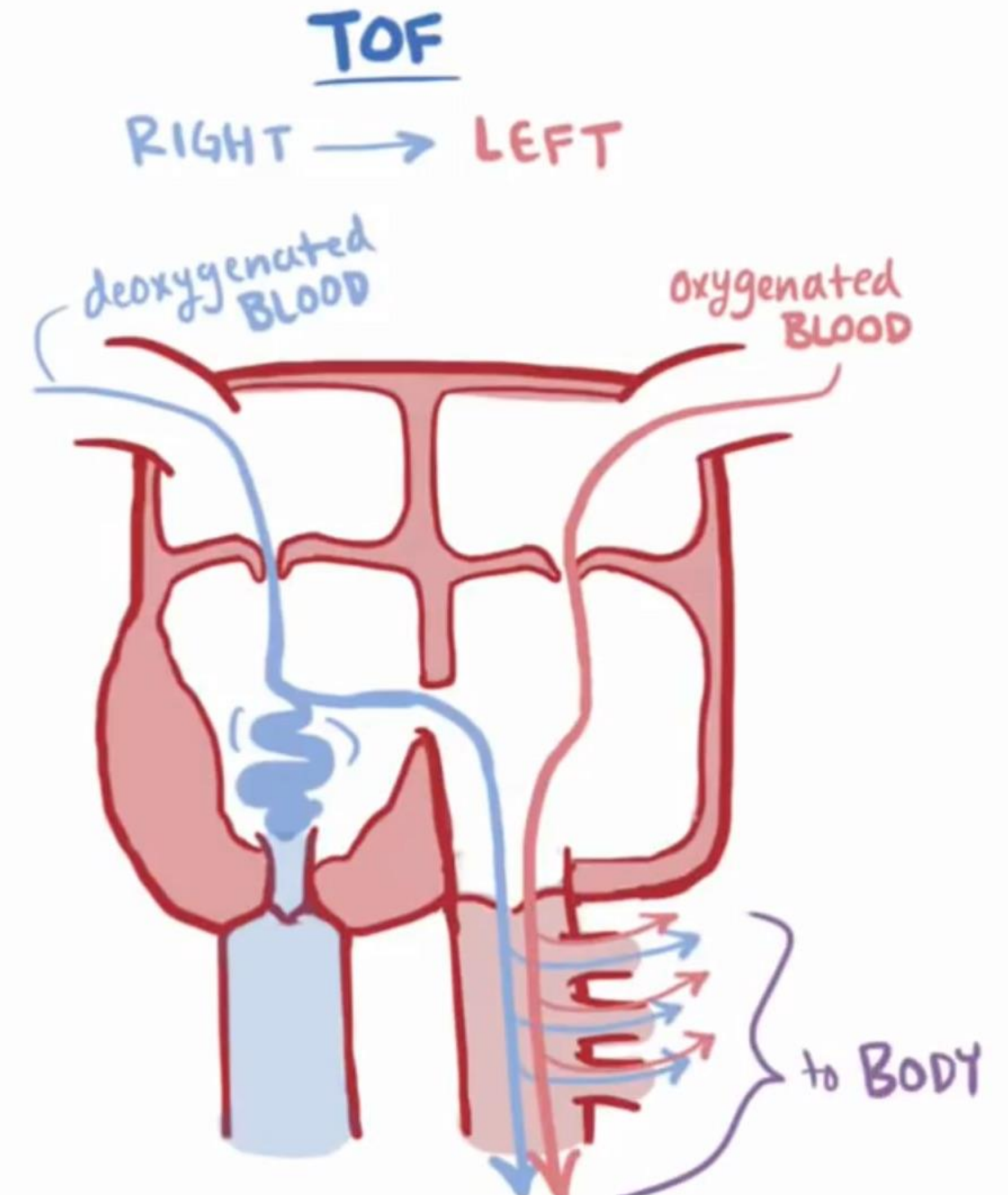
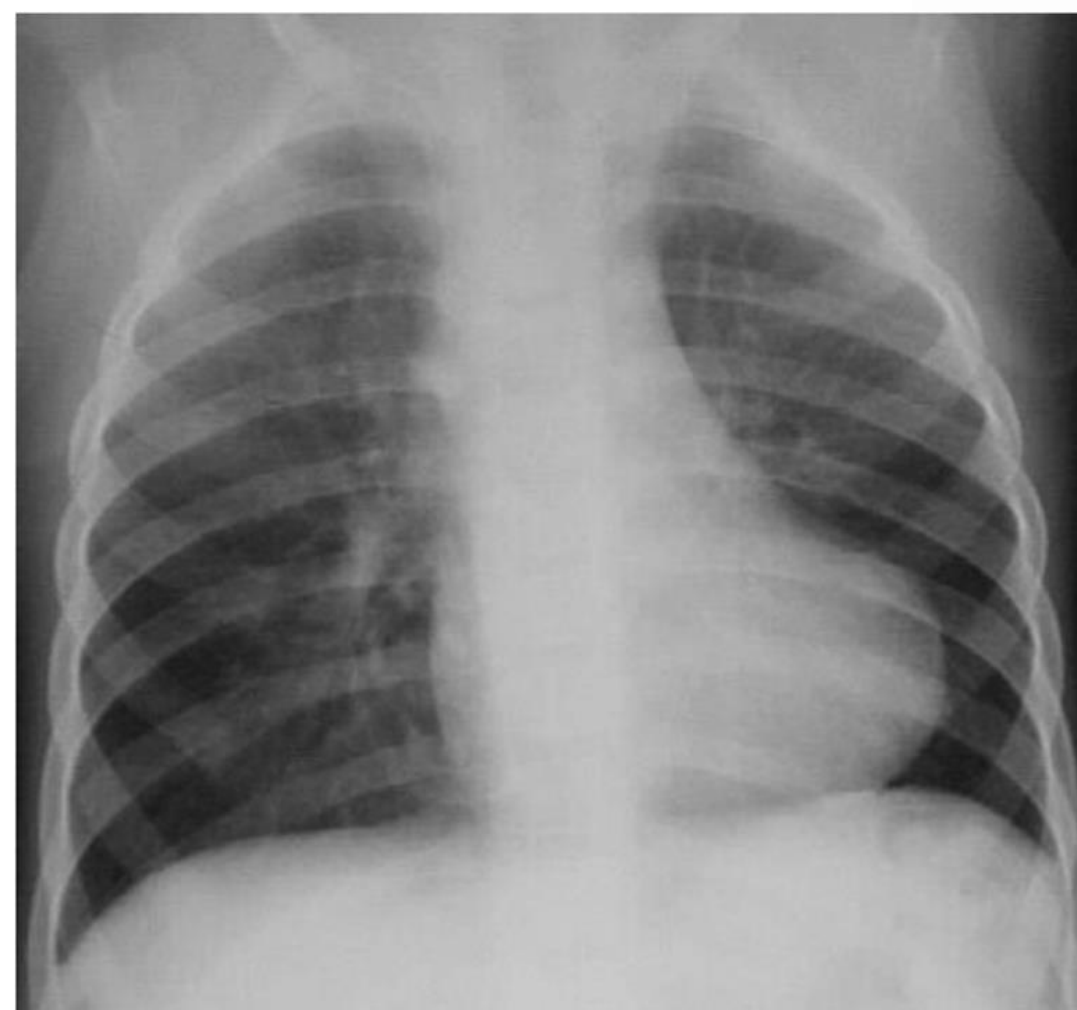
# Tetralogy of Fallot (TOF)

results from anterior displacement of conotruncal septum

9,6/100000; 10% of all CHDs; cyanotic

leading to 4 abnormalities:

1. Pulmonary infundibular stenosis
2. VSD
3. overriding aorta
4. hypertrophy of the right ventricle



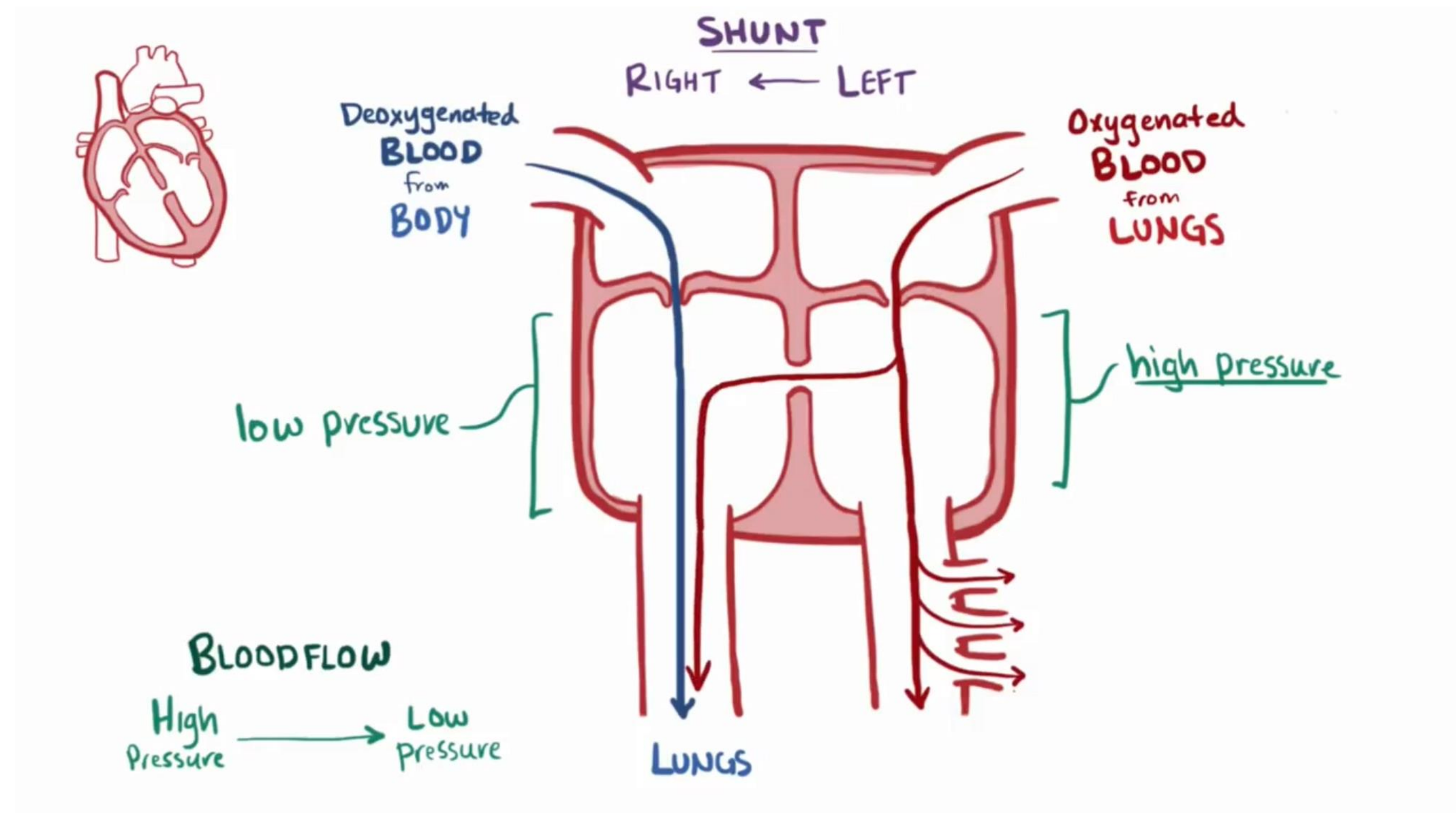


# Ventricular septal defects (VSDs)

most common CHDs 12/10 000; acyanotic; 80% in the muscular region and resolve during the childhood

membranous part defects are more severe and associated with other abnormalities

the blood volume carried by pulmonary artery increases (can be 1,2-1,7 times more than aorta) leading to the pulmonary hypertension and can cause Eisenmenger syndrome





# Congenital heart defects (CHDs)

Ectopia cordis – ventral body wall defect

Persistent truncus arteriosus – (0,8/10 000) – always present with VSD

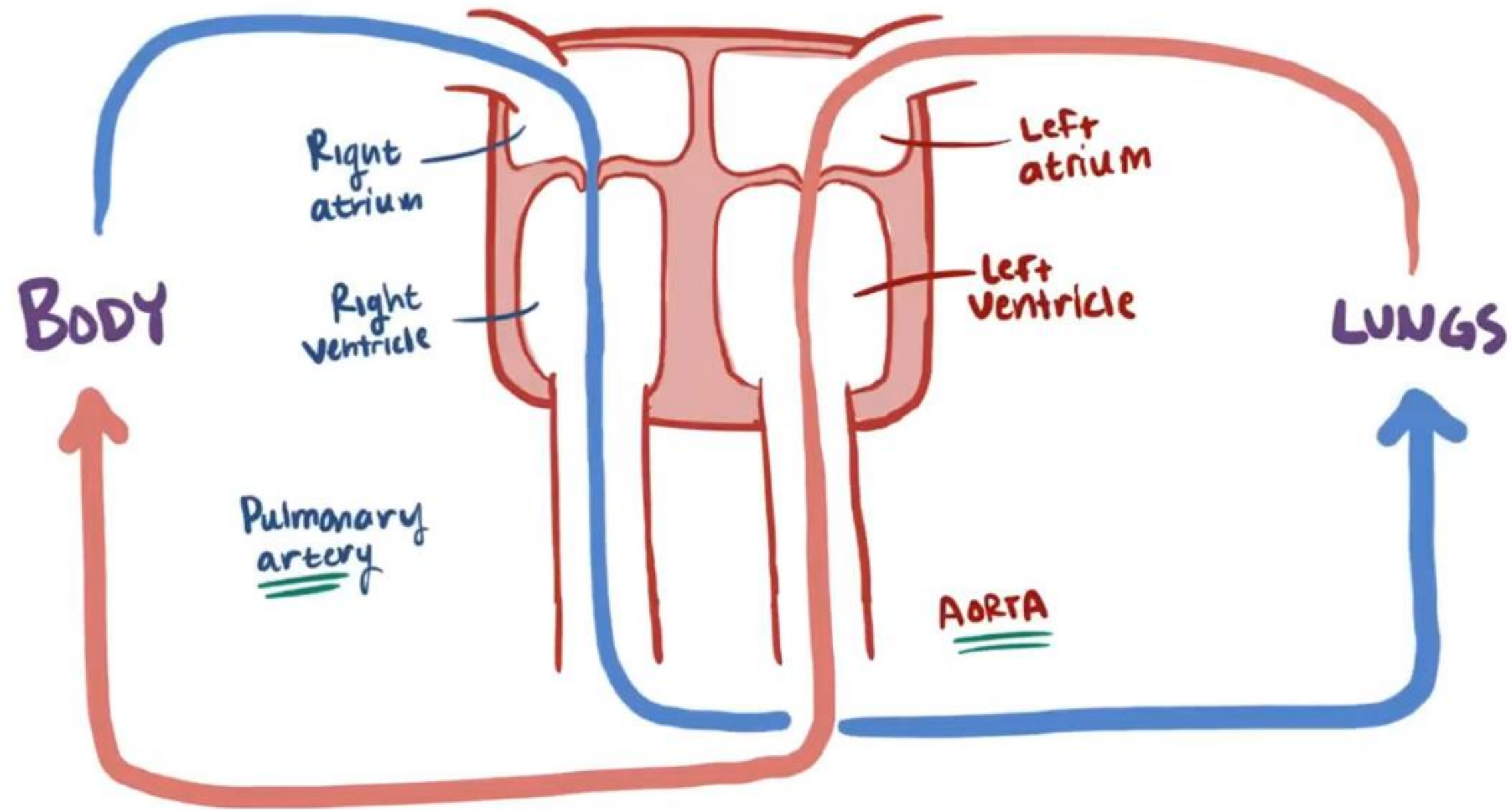
Transposition of great arteries (4,8/10 000)

Aortic stenosis and aortic atresia

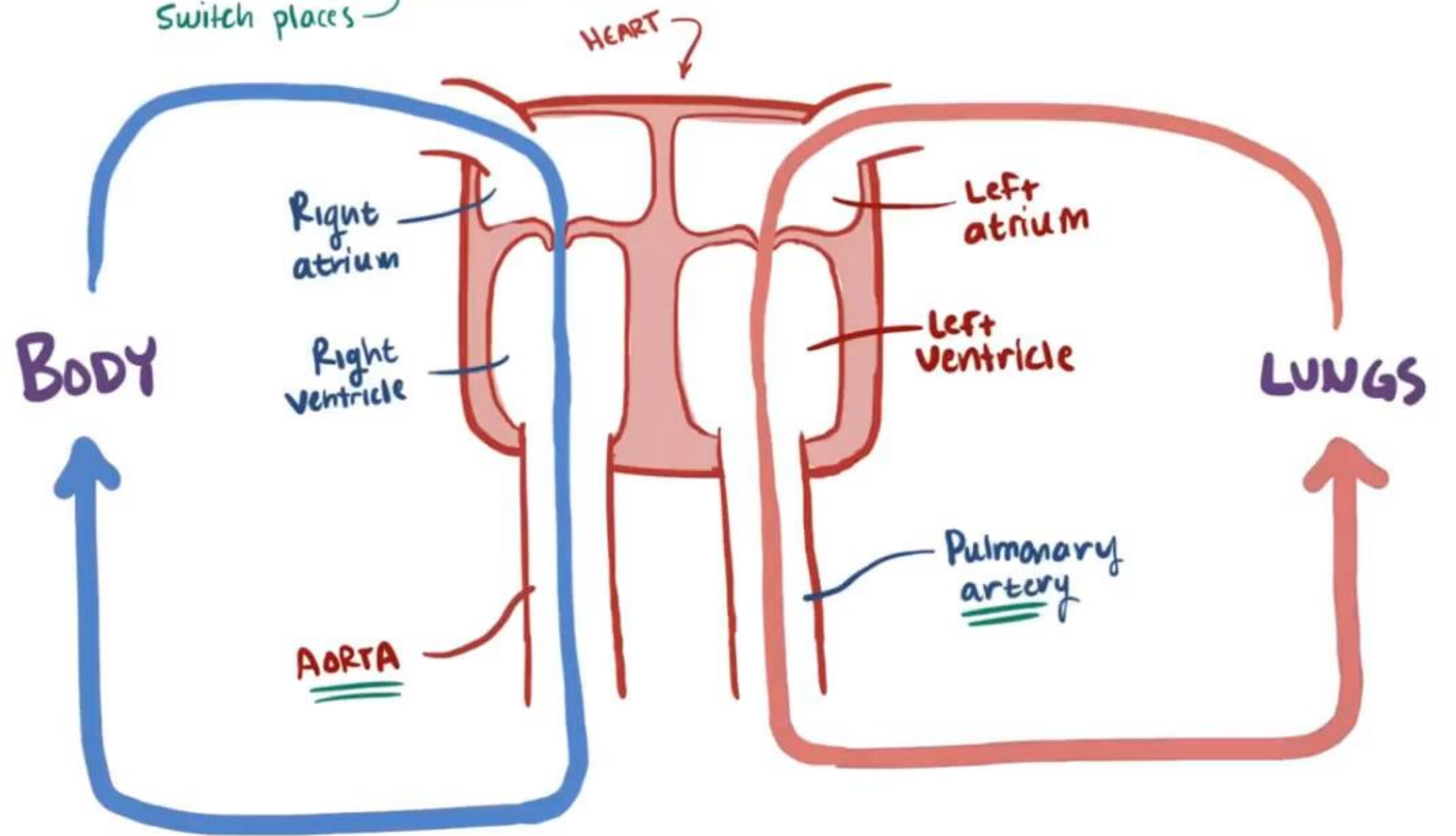
Pulmonary stenosis and pulmonary atresia

Unequal division of TA

# Transposition of great arteries

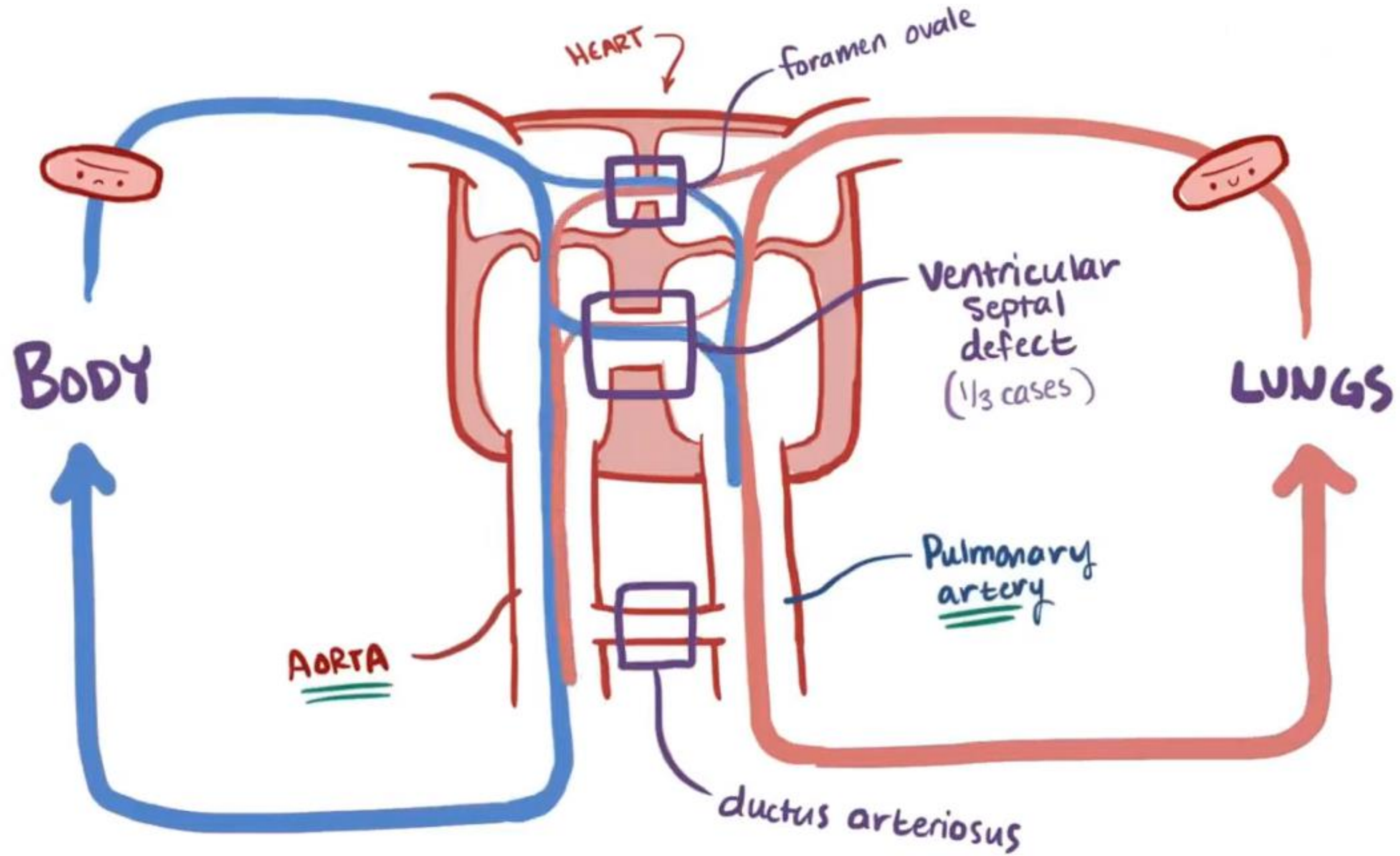


TRANSPOSITION OF THE GREAT ARTERIES  
Switch places





# Transposition of great arteries





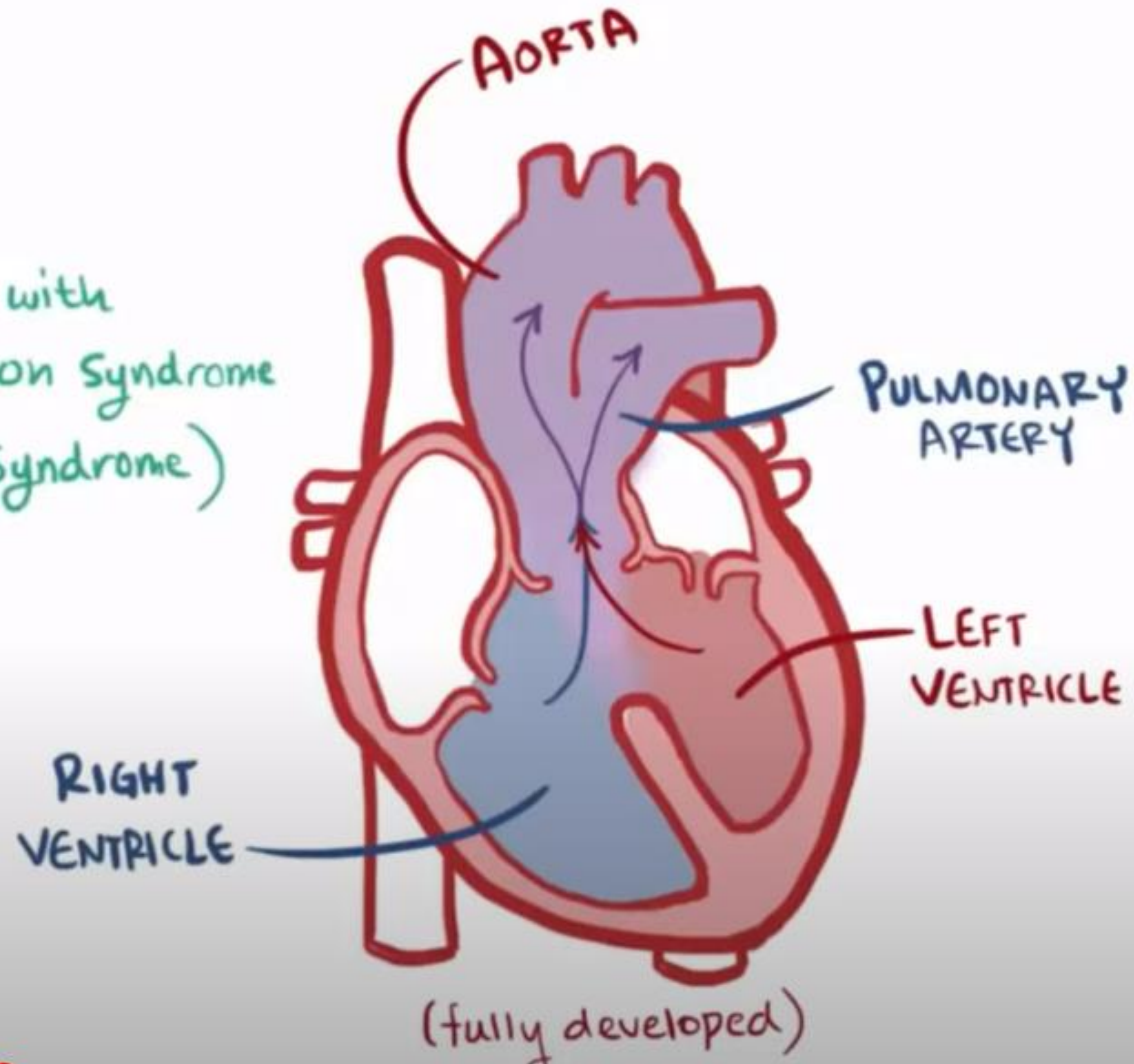
# Persistent truncus arteriosus

## TRUNCUS ARTERIOSUS (TA)

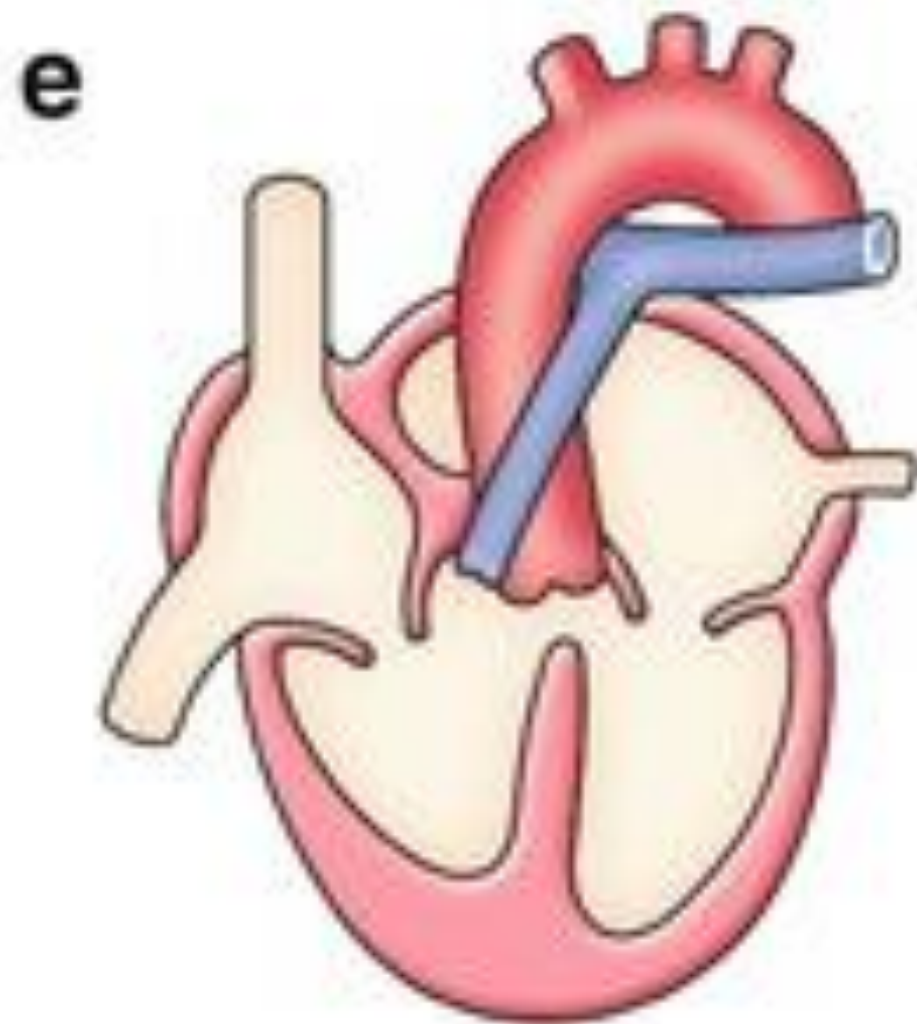
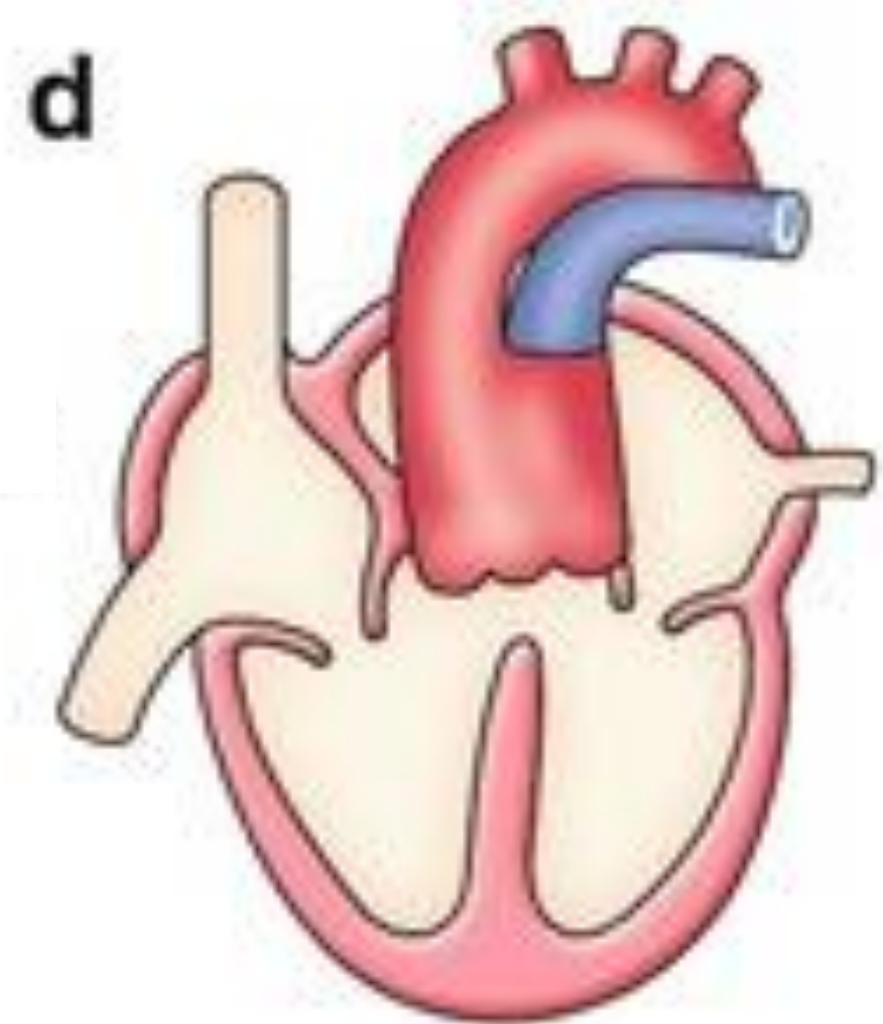
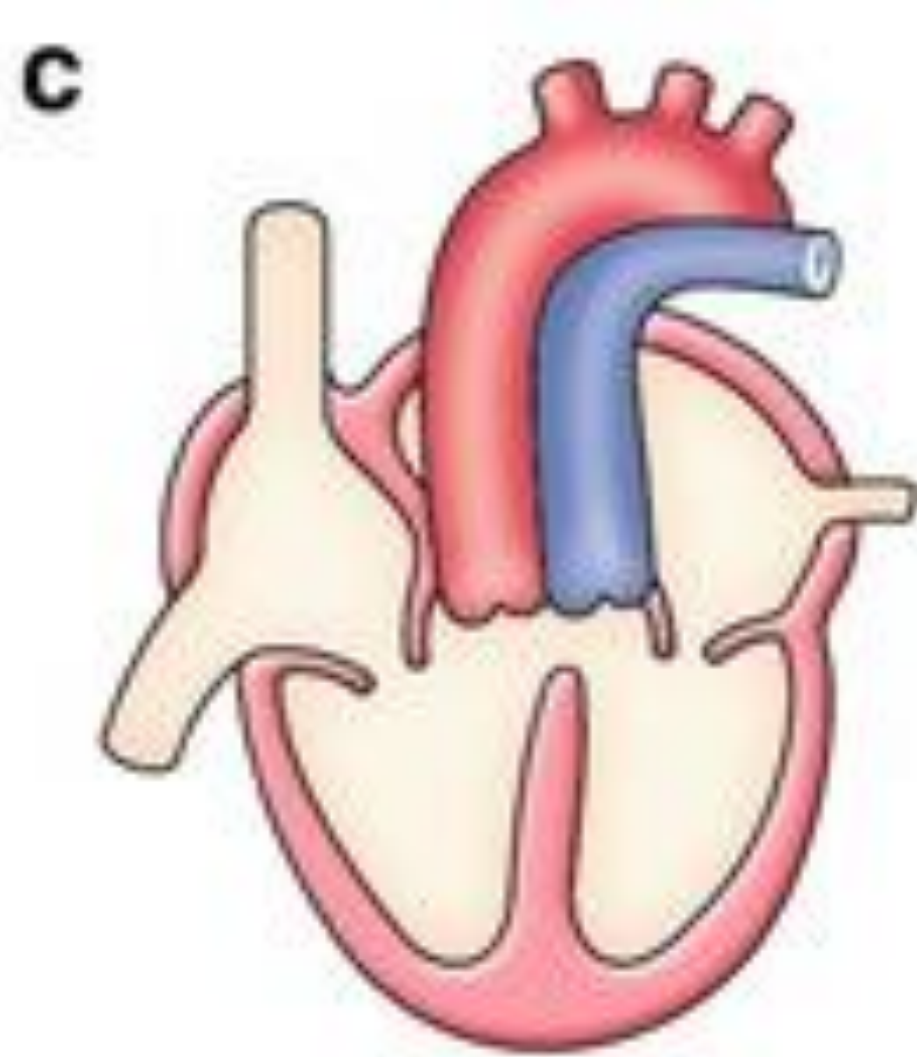
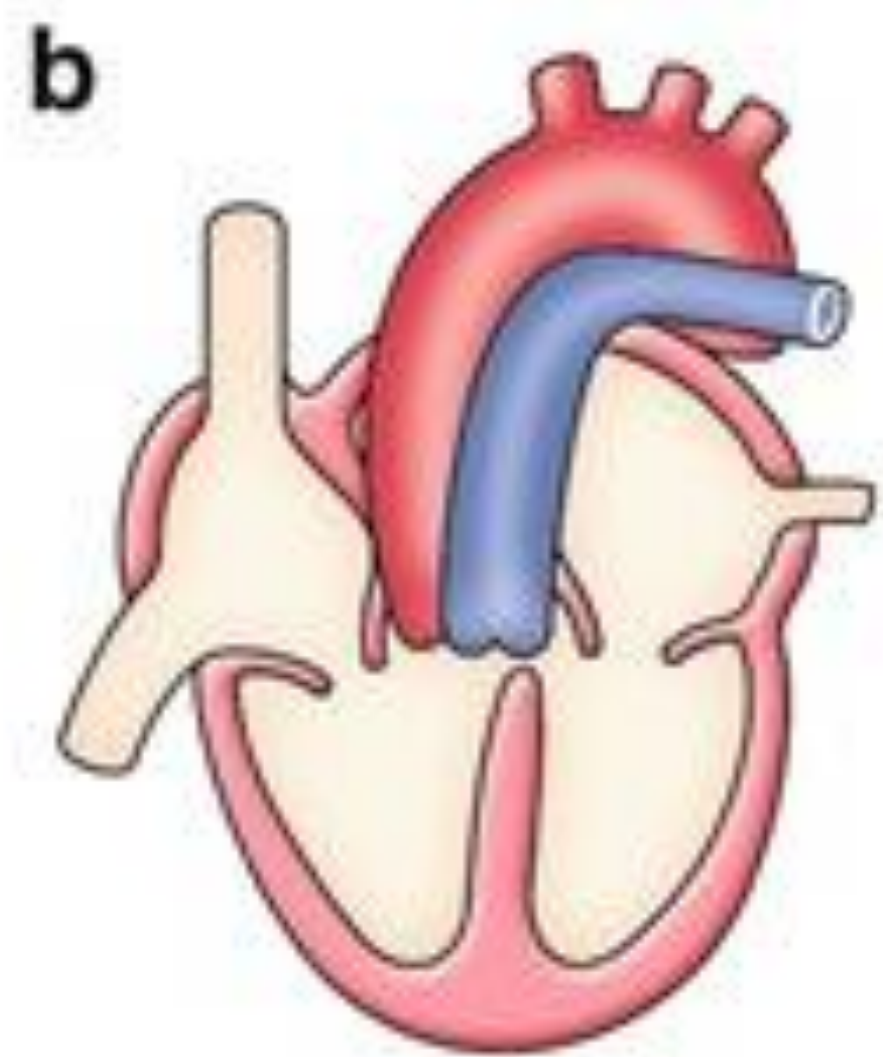
### CAUSE

\* UNKNOWN

↳ associated with  
22q11.2 deletion Syndrome  
(DiGeorge Syndrome)

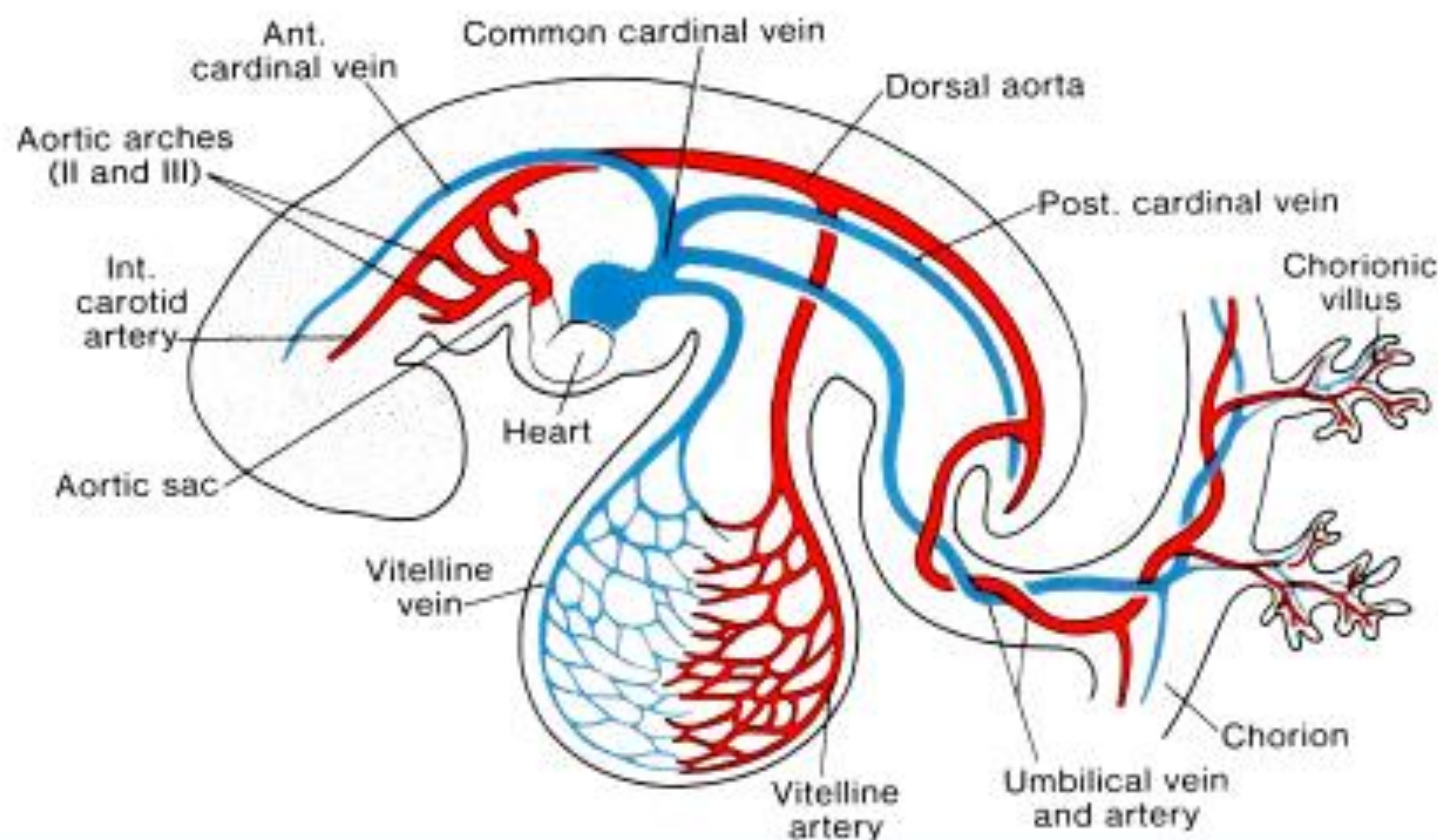








# Primitive blood circulation



- ⇒ in the wall of yolk sac (aa. et vv. omphalomesentericae)
- ⇒ in the chorion and connecting stalk (aa. et vv. umbilicales)
- ⇒ in embryo (primary blood circulation – *heart tube, dorsal aortae, cardinal veins*)



# Foetal blood circulation

