

MUNI  
MED

FAKULTNÍ  
NEMOCNICE  
BRNO



NEUROLOGICKÁ  
KLINIKA  
LF MU a FN BRNO

# DISORDERS OF PERIPHERAL NERVES POLYNEUROPATHIES, MONONEUROPATHIES

Eva Vlčková, Department of Neurology, University Hospital Brno



# PERIPHERAL NEUROPATHIES

Common neurological problems caused by disordered function and structure of peripheral motor, sensory, and autonomic nerves.

The clinical presentations is highly variable:

- Mononeuropathies/ multiple mononeuropathies/ plexopathies or radiculopathies/ polyneuropathies
- Motor and/or sensory and/or autonomic

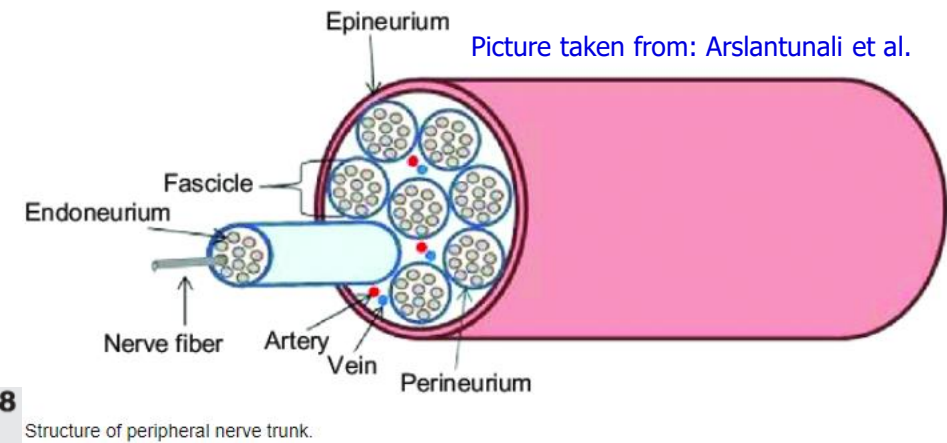
The causes are disparate and include:

- entrapment and trauma;
- inherited disorders;
- diabetes, and other metabolic diseases;
- inflammatory demyelinating conditions;
- vasculitis and rheumatic diseases;
- paraneoplastic conditions;
- deficiency states;
- infections; and toxins.

# PATHOLOGICAL PROCESSES IN PERIPHERAL NERVES

- Despite the large number of causes for neuropathy, the pathological reactions of peripheral nerves to various insults remain limited and include:
  - (1) axonal degeneration or axonopathy (see next slides) including:
    - wallerian degeneration (degeneration of axons and their myelin sheath distal to the site of transection) = the response to axonal interruption, recovery depends on the continuity of the nerve sheaths;
    - primary neuronal (perikaryal) degeneration or neuronopathy (Either lower motor neurons or dorsal root ganglion cells may be affected leading to motor neuron diseases or sensory neuronopathy. Little or no recovery takes place particularly in the latter one);
  - (2) segmental demyelination (see next slides)
  - in many neuropathies, axonal degeneration and segmental demyelination COEXIST.
- Following characteristics help to establish the underlying pathological change:
  - The patient's symptoms + the pattern of distribution of signs
  - Nerve conduction studies and needle EMG

# CLASSIFICATION OF NERVE INJURIES



**Classification of Nerve Injuries Described by Seddon<sup>6</sup> and Sunderland<sup>8</sup>**

Seddon	Sunderland	Injury	Neurosensory Impairment	Recovery Potential
Neurapraxia	I	Intrafascicular edema with conduction block and possible segmental demyelination	Neuritis and paresthesia	Full/good; 1 wk to 2 mo
Axonotmesis	II	Axon severed, endoneurial tube intact	Paresthesia, episodic dysesthesia	Full/fair; 2–4 mo
Axonotmesis	III	Endoneurial tube torn	Paresthesia, dysesthesia	Incomplete/fair; 12 mo
Axonotmesis	IV	Only epineurium intact	Hypoesthesia, dysesthesia, neuroma formation	Incomplete/poor; neuroma in continuity
Neurotmesis	V	Loss of continuity	Anaesthetic, intractable pain, neuroma formation	None

Adapted with permission from Juodzbalys G, Wang HL, Sabalys G: Injury of the inferior alveolar nerve during implant placement: A literature review. *J Oral Maxillofac Res* 2011;2(1):e1.

No need to know the information in detail 😊 - just that it exists

Adopted from: Poage C, Roth C, Scott B. Peroneal Nerve Palsy: Evaluation and Management. *J Am Acad Orthop Surg*. 2016;24(1):1-10..

Originally published by: Seddon HJ: A classification of nerve injuries. *Br Med J* 1942;2(4260):237-239.

Sunderland S: A classification of peripheral nerve injuries producing loss of function. *Brain* 1951;74(4):491-516.

Picture taken from: Arslantunali D, Dursun T, Yucel D, Hasirci N, Hasirci V. Peripheral nerve conduits: technology update. *Med Devices (Auckl)*. 2014;7:405-24.

# PATHOLOGICAL PROCESSES IN PERIPHERAL NERVE

- **AXONOPATHY**: the **most frequent** one,
- presumably caused by **metabolic derangement** within neurons – metabolic or toxic,
- **starts at the most distal part** of the nerve fiber and progresses toward the nerve cell body, hence the term **dying-back or length-dependent neuropathy**
- clinically presents with **distal symmetrical** polyneuropathy
- axonal **regeneration** proceeds at a maximal rate of 2 to 3 mm per day, recovery may be delayed and is often incomplete
  
- **DEMYELINATION**: injury of **myelin sheaths or Schwann cells**, resulting in breakdown of myelin with **sparing of axons** → **no major atrophies** despite the presence of weakness.
- In **immune-mediated, some hereditary and compression** neuropathies.
- <sup>5</sup> – **Remyelination** may occur (even within days or weeks)



# DIAGNOSTIC APPROACH

A diagnostic approach to neuropathies consists of:

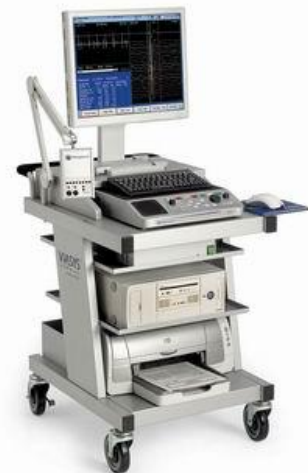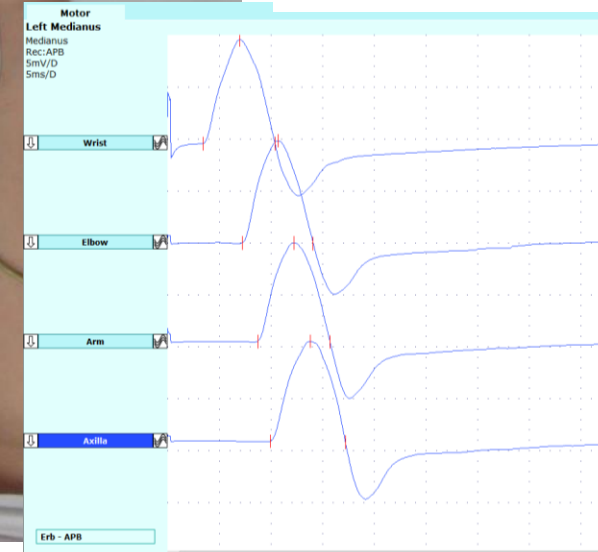
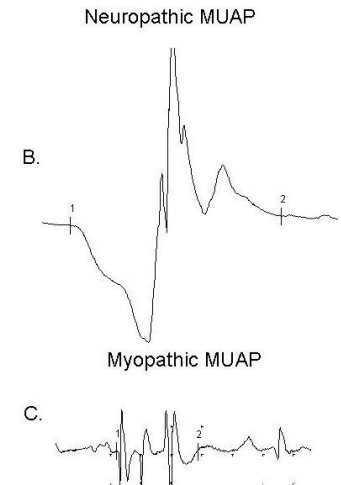
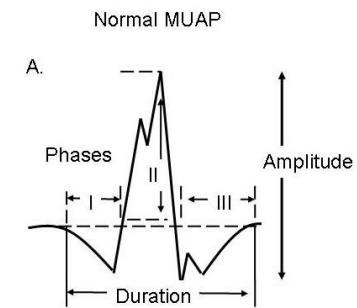
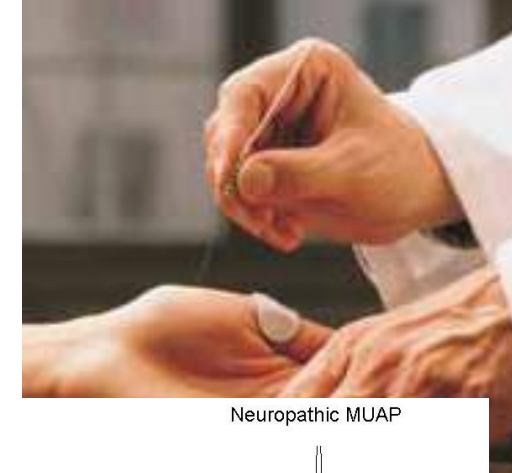
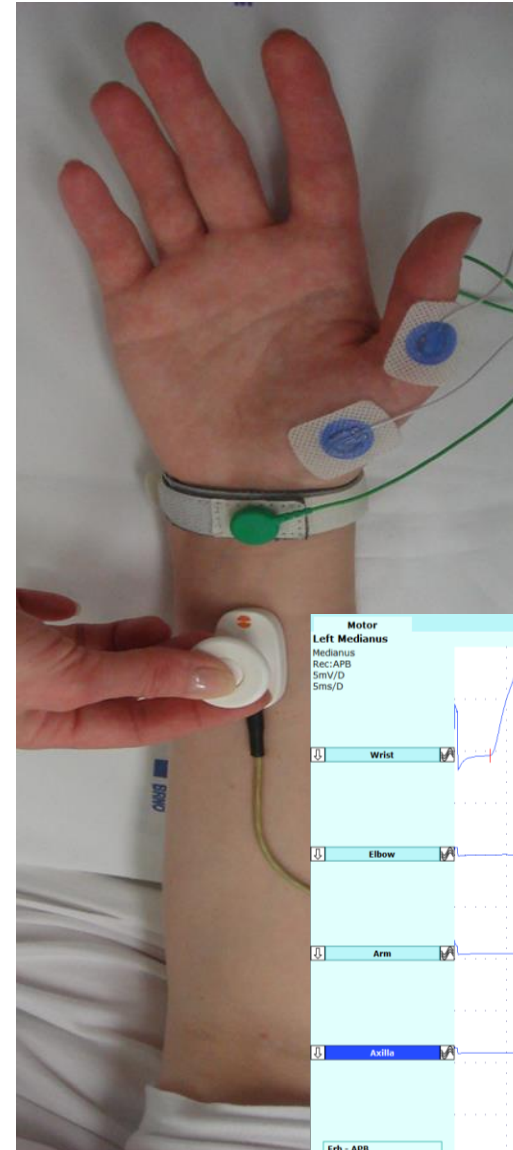
- (1) careful **history**,
- (2) detailed physical and neurological **examination**,
- (3) **electrophysiological studies**, which not only confirm the presence of a peripheral nerve disorder but also shorten the list of diagnostic possibilities,
- (4) later, **further laboratory studies** to determine a specific diagnosis are usually performed based on the outcome of the initial evaluation (blood tests, nerve biopsy, skin biopsy...)

It is possible to establish a specific diagnosis in up to 75% of patients evaluated in tertiary referral centers by experts in neuromuscular disorders.

# ELECTROPHYSIOLOGICAL STUDIES

## NCS/ EMG

- Confirm the presence and clinical **distribution** of neuropathy (and disclose **subclinical** abnormalities)
- Distinguish between **pure sensory/ pure motor/ sensory-motor abnormalities**
- Disclose the presence and extent of **axonal/ demyelinating** changes (see next slides)
- A needle EMG of distal muscles may show **acute, subacute or chronic** denervation/reinnervation changes
- 7 Only **LARGE FIBERS** (see next slide 😊 )



# SENSORY NERVE FIBERS – REMINDER 😊

- small myelinated and unmyelinated fibers (A-delta + C) are **NOCICEPTIVE** and responsible for thermal perception (both warm and cold) – prominent impairment of these nerve fibers leads to **SMALL FIBER NEUROPATHY (SFN)**
- large-diameter myelinated fibers (A-alfa, A-beta) are **NON-NOCICEPTIVE** (proprioception, vibration sense, discriminative touch, pressure) – impairment leading to **LARGE FIBER NEUROPATHY**

CLASS (OLDER TERMINOLOGY)	DIAMETER	CONDUCTION VELOCITY	MODALITIES
Ia (A $\alpha$ ) (myelinated)	12-20 $\mu$ m	70-100 m/sec	Proprioception (muscle spindles)
Ib (A $\alpha$ ) (myelinated)	12-20 $\mu$ m	70-100 m/sec	Proprioception (Golgi tendon organs)
II (A $\beta$ ) (myelinated)	5-12 $\mu$ m	30-70 m/sec	Touch and pressure from skin; proprioception from muscle spindles
III (A $\delta$ ) (myelinated)	2-5 $\mu$ m	10-30 m/sec	Pain and temperature; sharp sensation; joint and muscle pain sensation
IV (C, unmyelinated)	0.5-2.0 $\mu$ m	0.5-2.0 m/sec	Pain, temperature

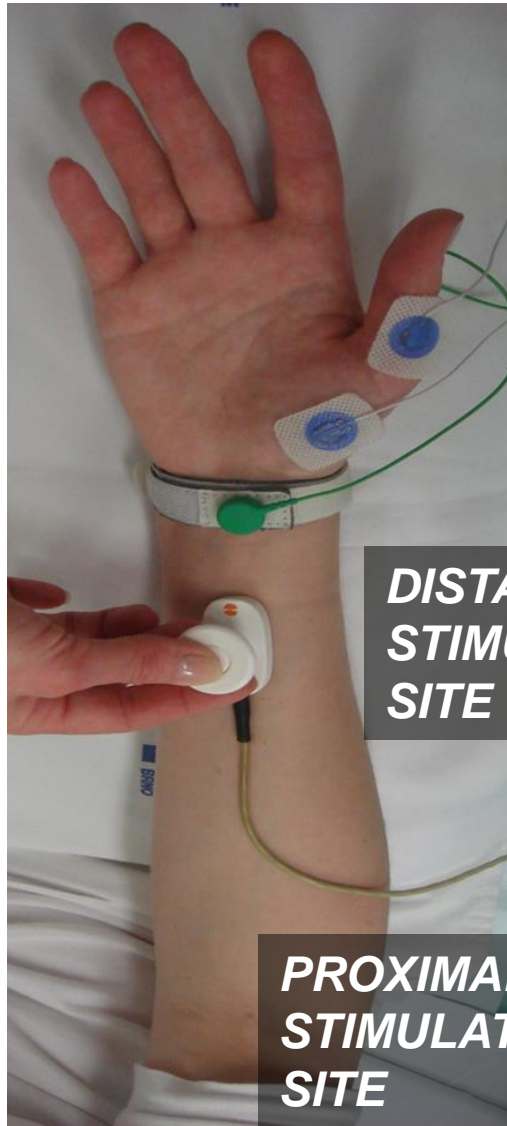No need to know it in detail (just to know the basic classification and get some idea about the principles 😊)





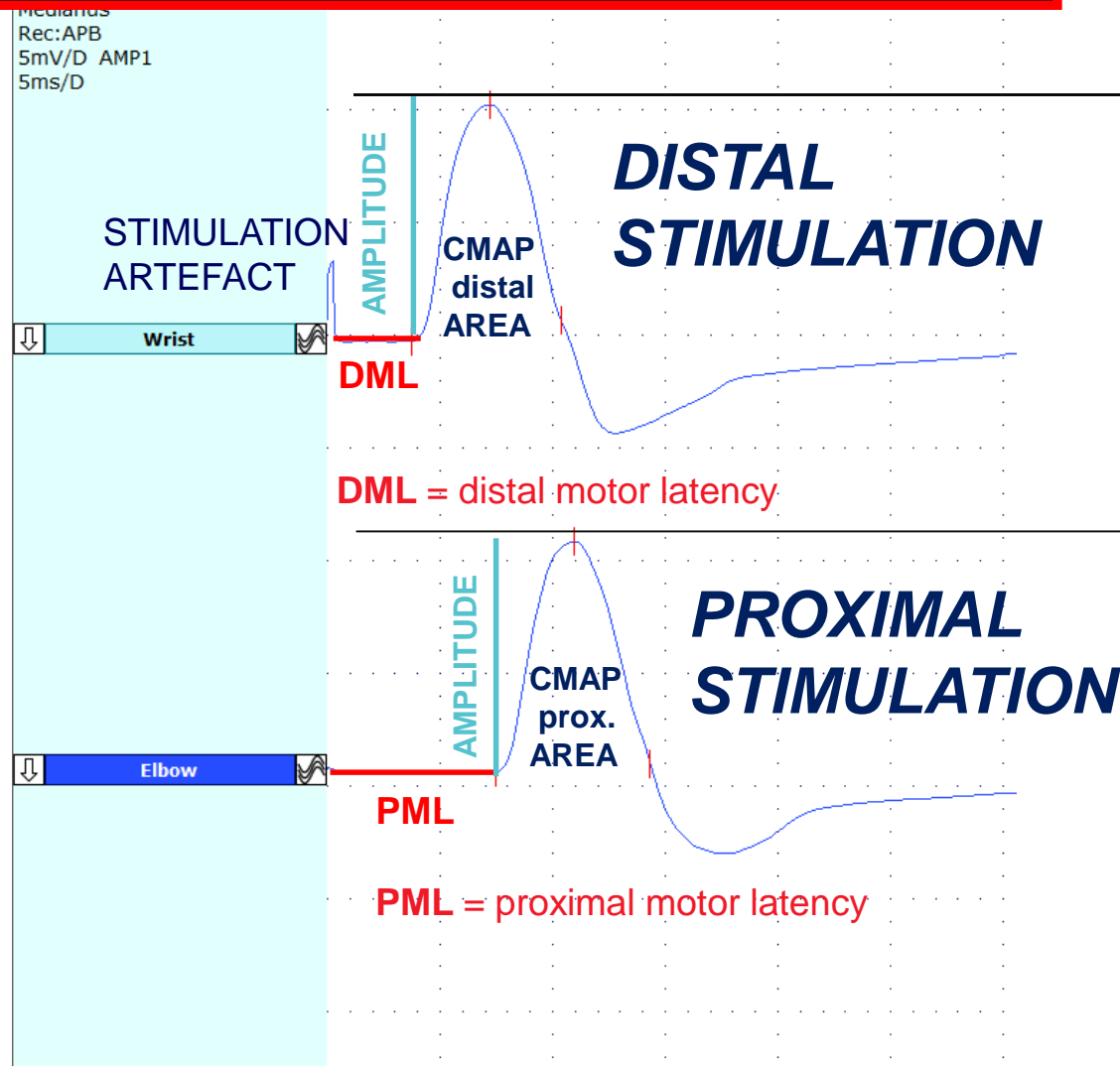
# MOTOR NERVE CONDUCTION STUDIES

The response to the electrical stimulation = ***ACTION POTENTIAL*** (mV) = ***CMAP*** (compound muscle AP)



**DISTAL STIMULATION SITE**

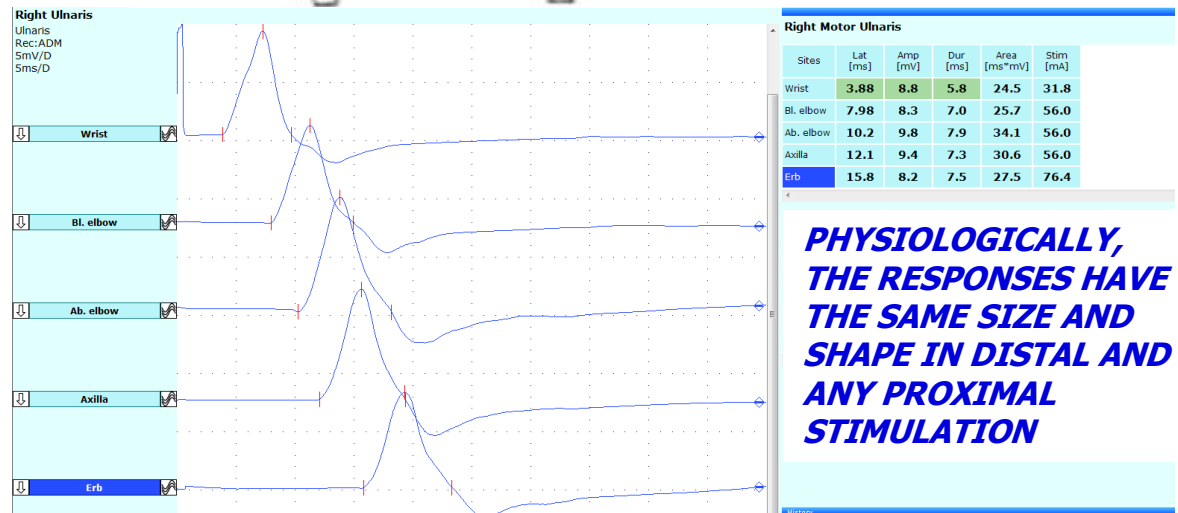
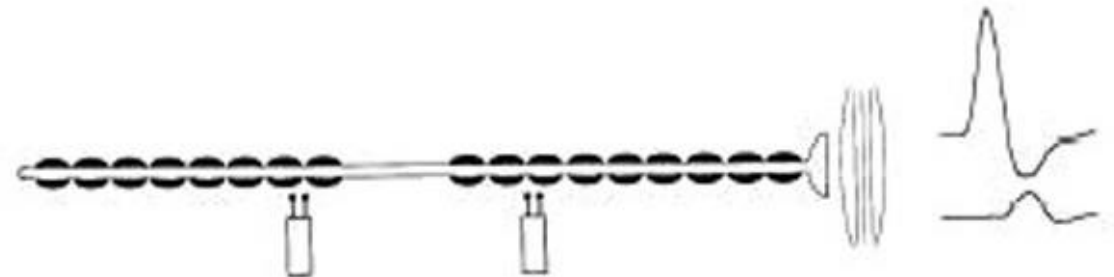
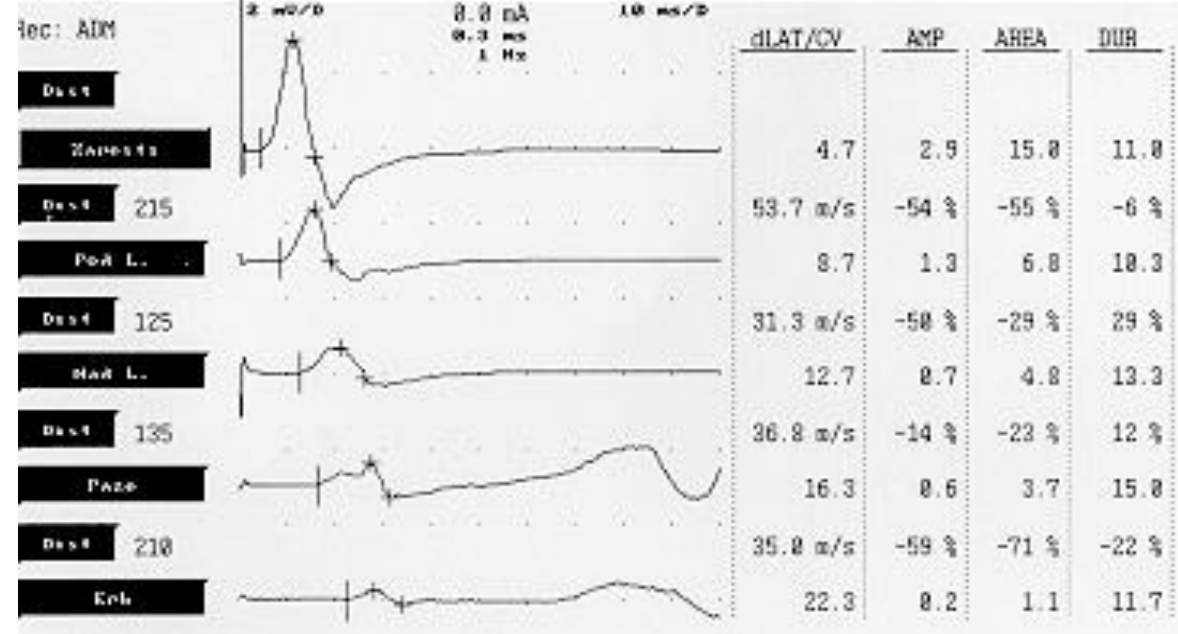
**PROXIMAL STIMULATION SITE**



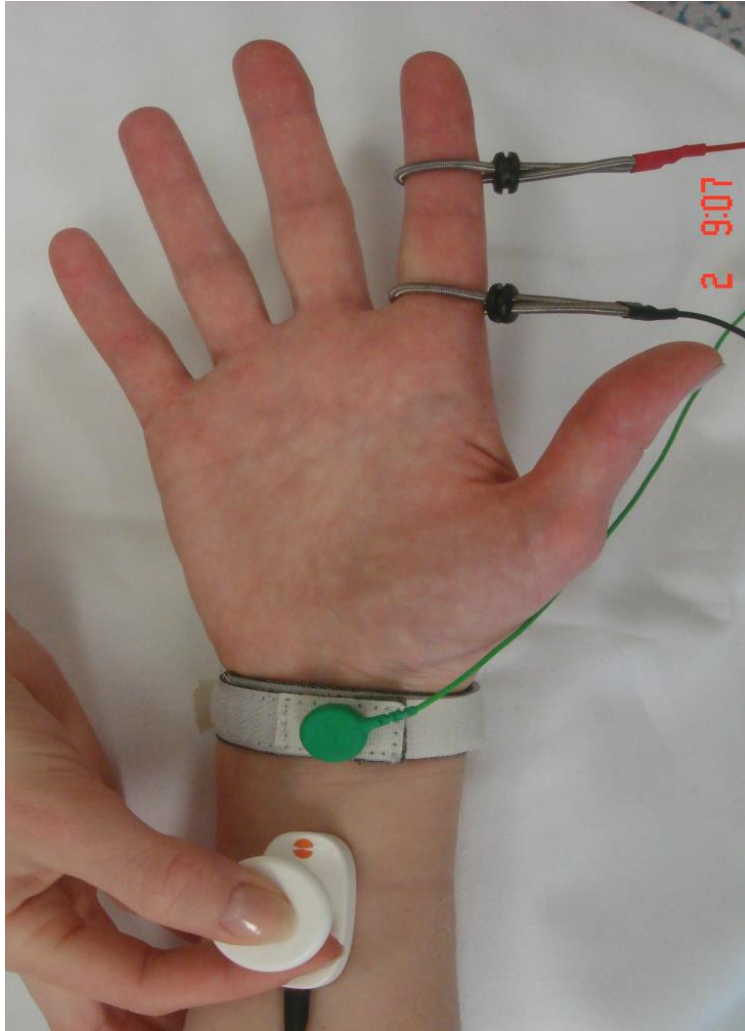
**THE NERVE CONDUCTION VELOCITY** is computed from the difference between PML and DML and the distance between distal and proximal stimulation site

# MOTOR NCS – CONDUCTION BLOCK

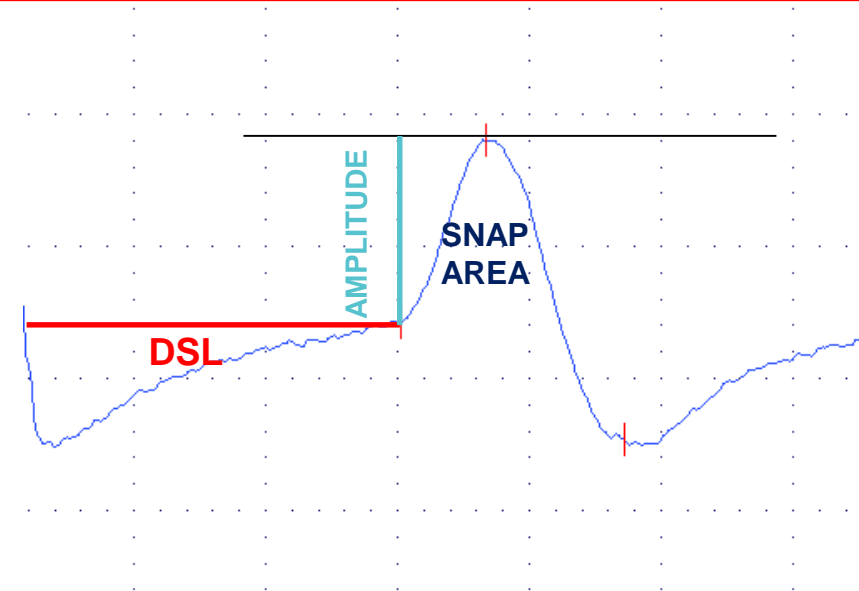
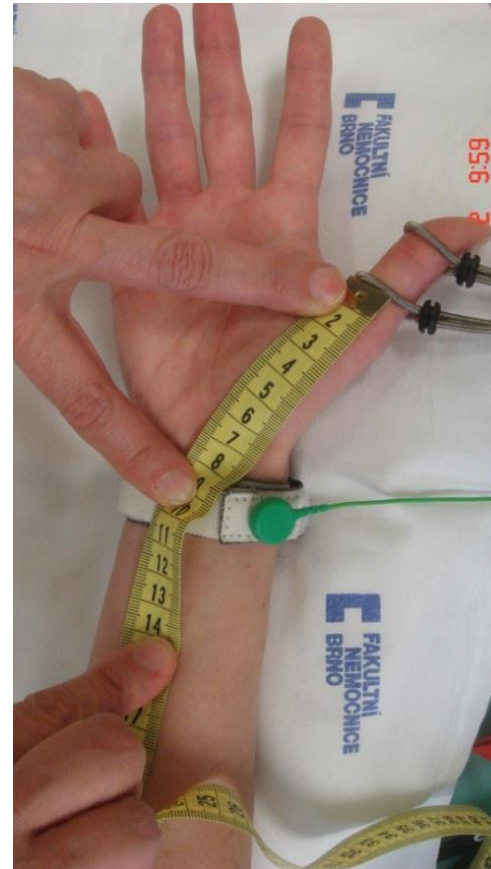
- In acquired demyelination (i.e., inflammatory or compression demyelination, but not hereditary myelinopathies) the presence conduction block and temporal dispersion of CMAP represent typical abnormality
- Conduction block is defined as a reduction of either amplitude or area of the compound motor action potential elicited by proximal vs. distal motor nerve stimulation
- The block results in a loss of the ability of the nerve AP to reach the muscle, thereby producing weakness, though the axon remains intact (= little muscle atrophy)



# SENSORY NERVE CONDUCTION STUDIES

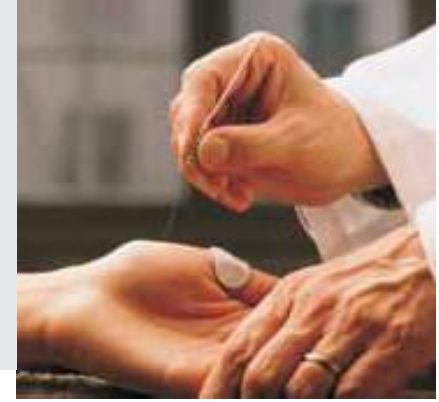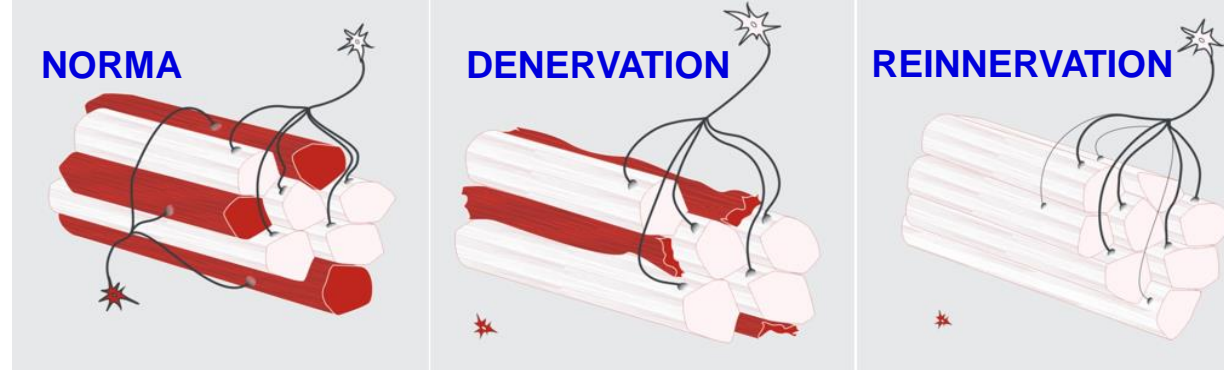


The response to the electrical stimulation = ***ACTION POTENCIAL*** (mV) = ***SNAP*** (sensory nerve AP)


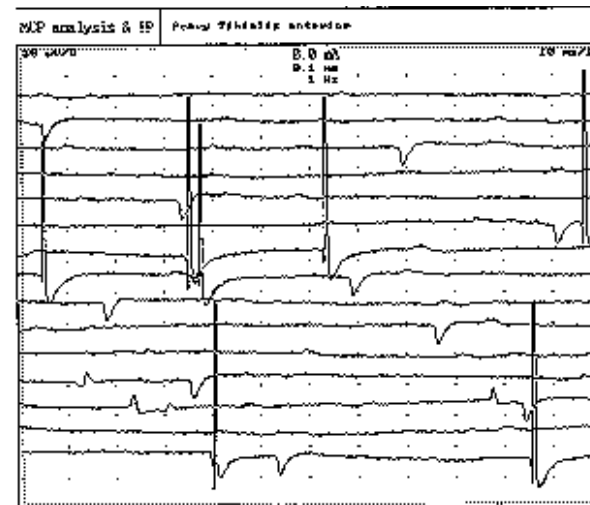
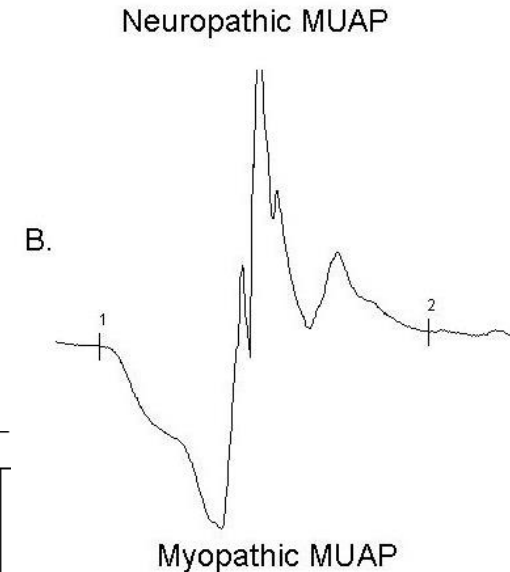
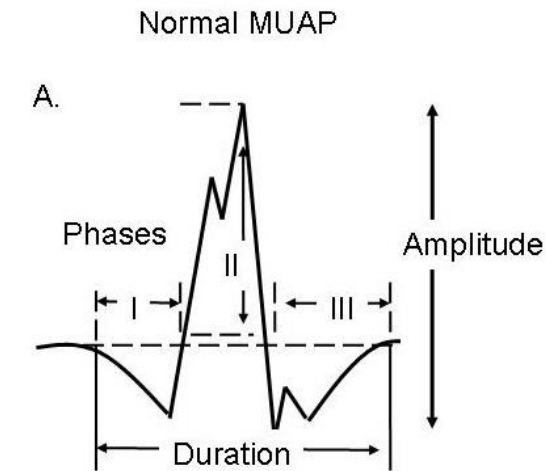


**THE NERVE CONDUCTION VELOCITY** is computed from the DSL and the distance between the active electrode and the stimulation site

# NEEDLE EMG



- detects the electric potential generated by muscle cells at rest or during the activity (muscle unit potentials – MUPs, MUAPs).
- Evaluation of MUP parameters helps to distinguish between myopathic/ neuropathic changes (reinnervation)
- Evaluation of the presence/ absence of spontaneous activity at rest may disclose denervation changes, myotonic discharges, fasciculations and other specific abnormalities

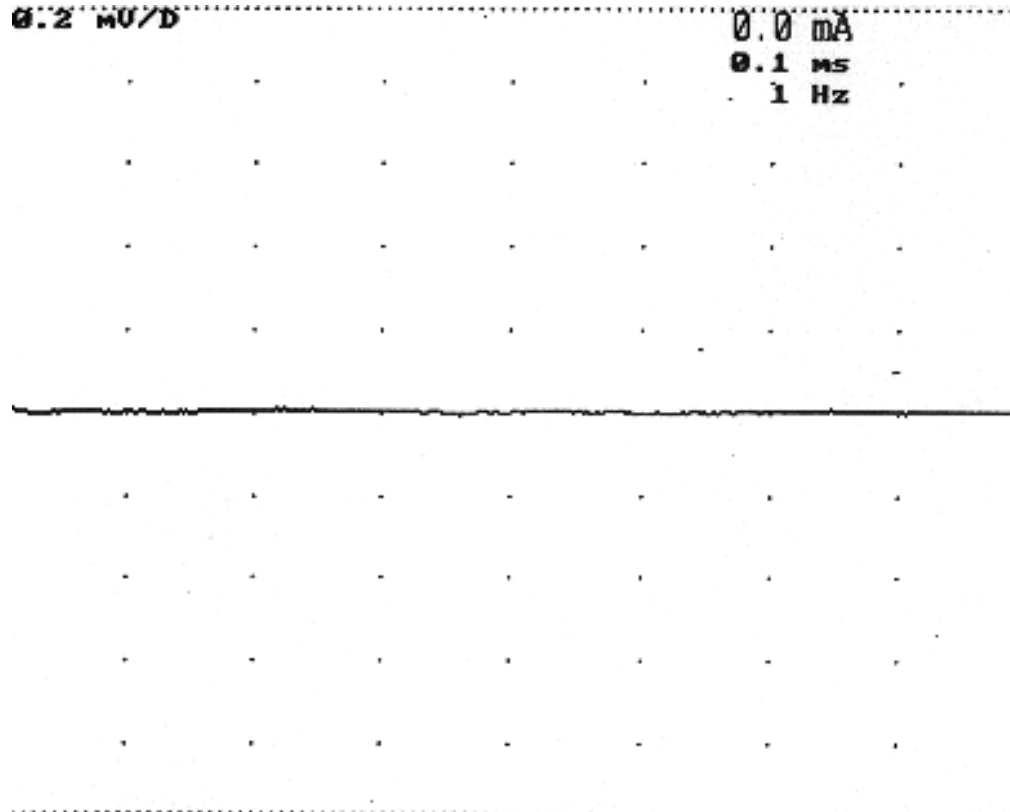




# NEEDLE EMG - AT REST (IN RELAXED MUSCLE)

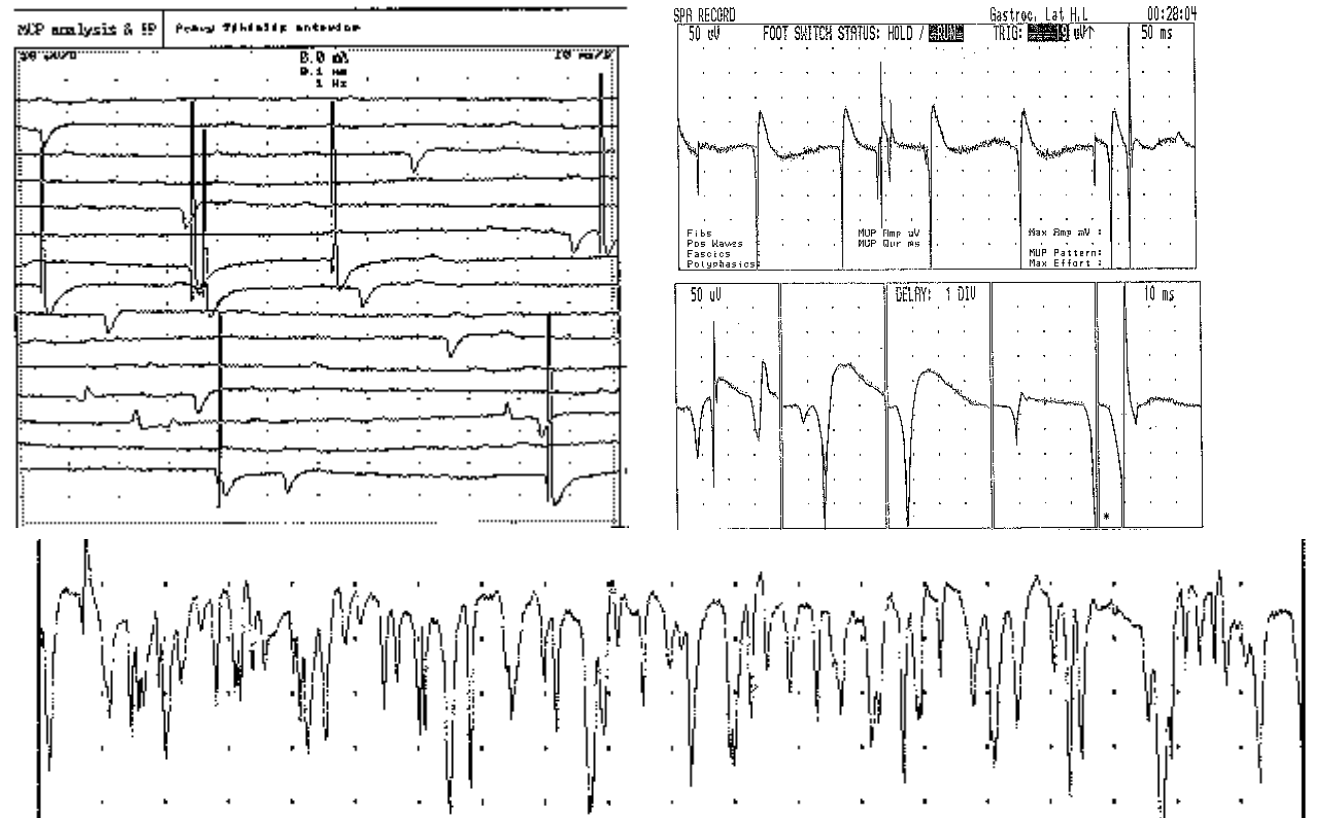
## PHYSIOLOGICAL CONDITIONS

No electrical activity



## ACUTE DENNERVATION (AXONAL LESION)

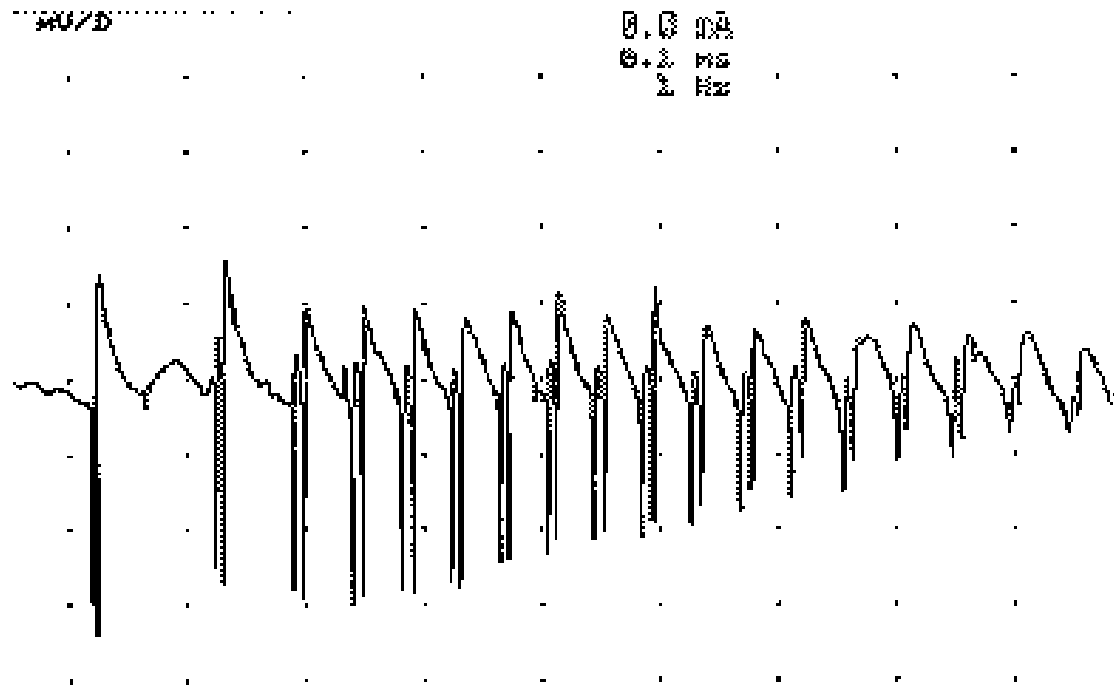
Abnormal spontaneous activity – **fibrillations**, **positive sharp waves (PSW)**



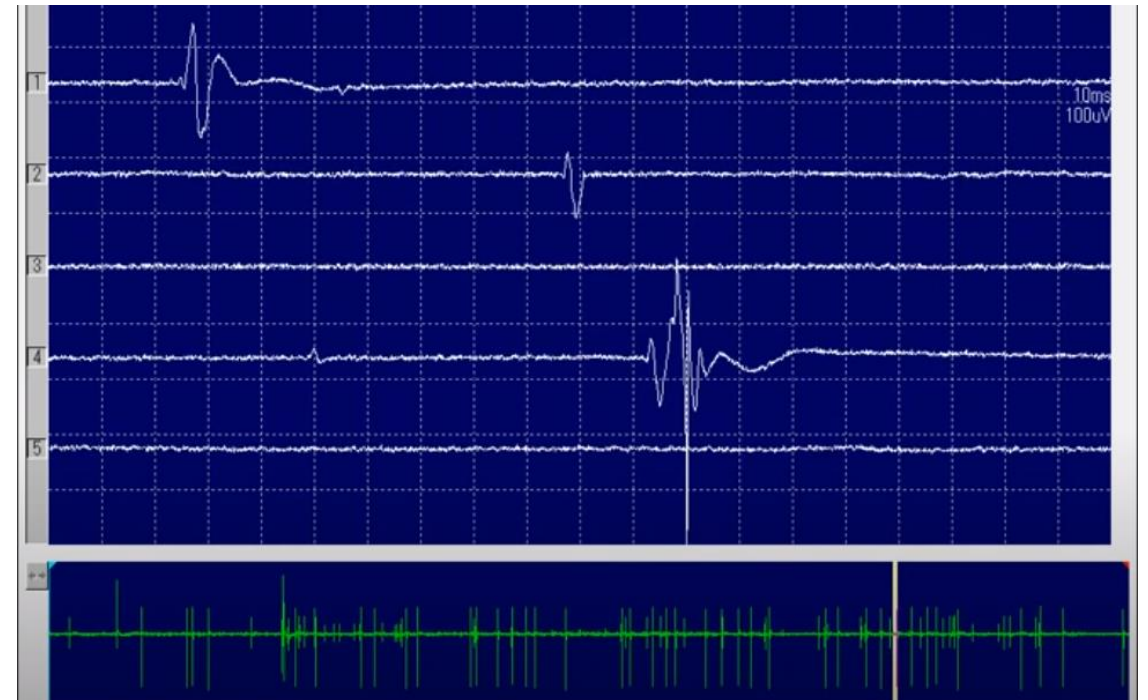


# NEEDLE EMG: ABNORMAL SPONTANEOUS ACTIVITY

## MYOTONIC DISCHARGE



## FASCICULATIONS



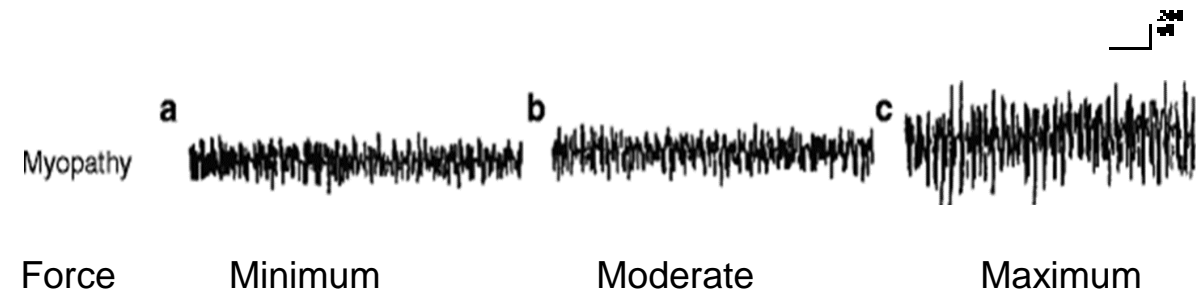
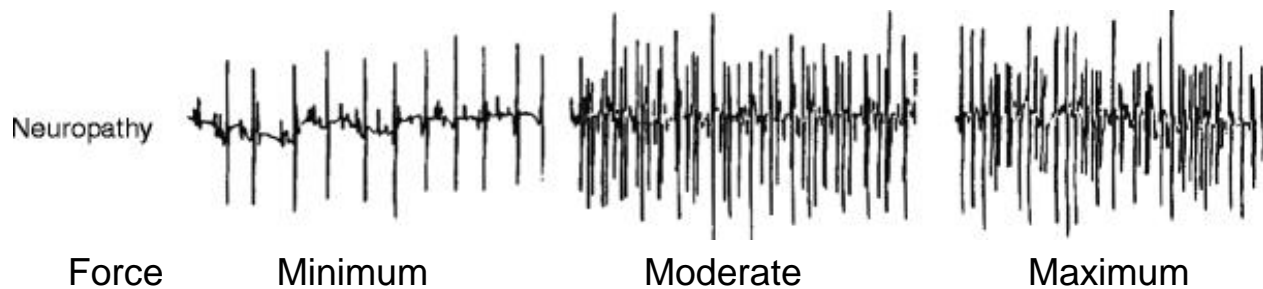
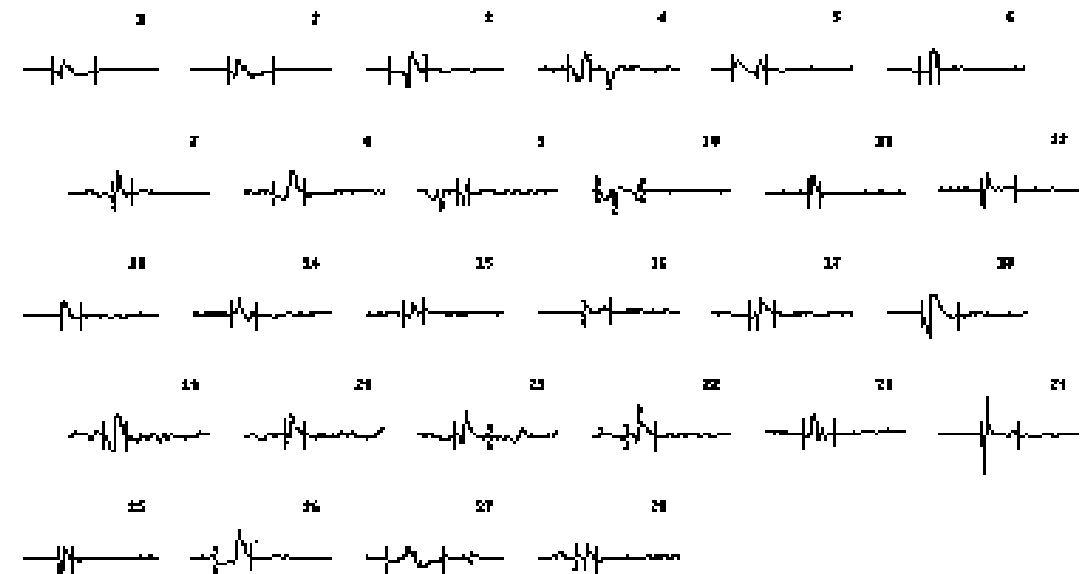
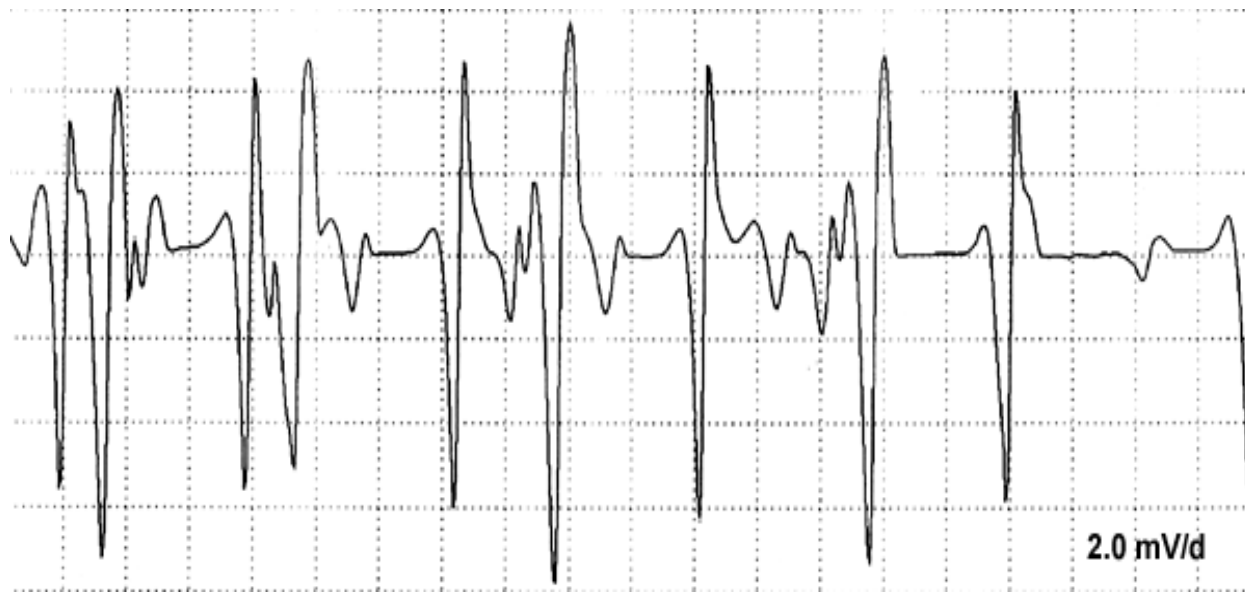
[https://www.youtube.com/watch?v=6-3PP\\_S-Q8I](https://www.youtube.com/watch?v=6-3PP_S-Q8I)

# NEEDLE EMG – DURING ACTIVITY

The evaluation of MUPs (motor unit potentials) and the interference pattern

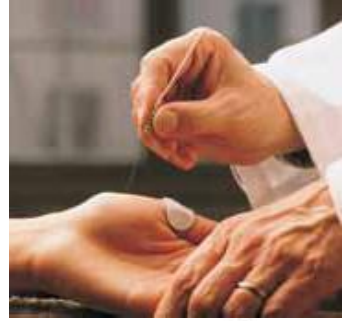Reinnervation (chronic neurogenic changes)

Myogenic changes

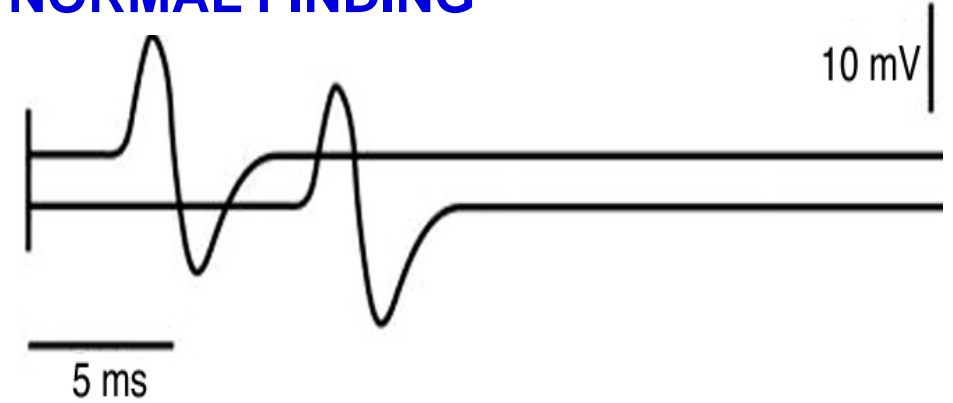


# AXONAL NCS/EMG CHANGES


- Axonopathies result in **low-amplitude** sensory nerve action potentials (SNAPs) and compound muscle action potentials (CMAPs) with no major impact on latencies and velocities.
- denervation/ reinnervation changes are proven by **needle EMG**.



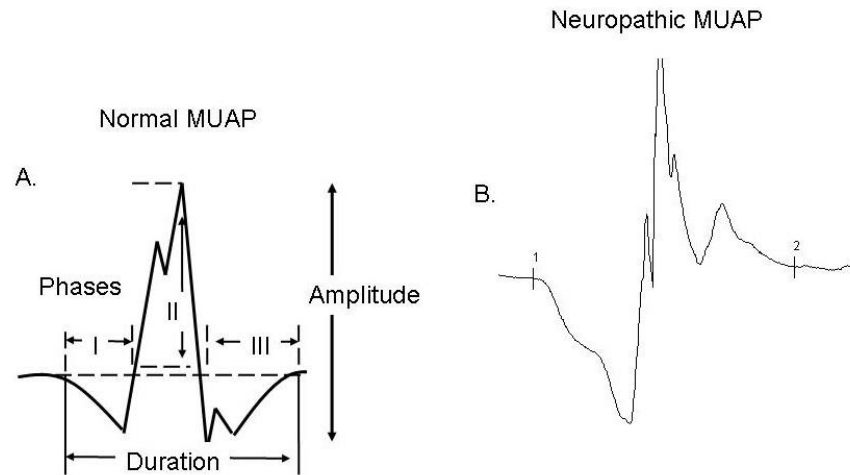
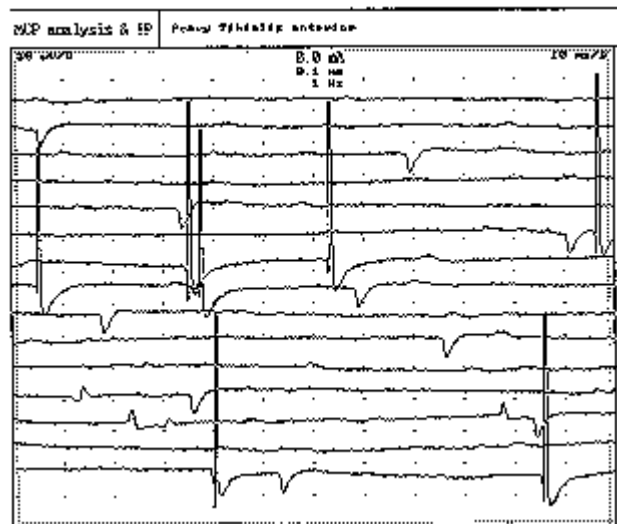
## NORMAL FINDING



## DEMYELINATION CHANGES



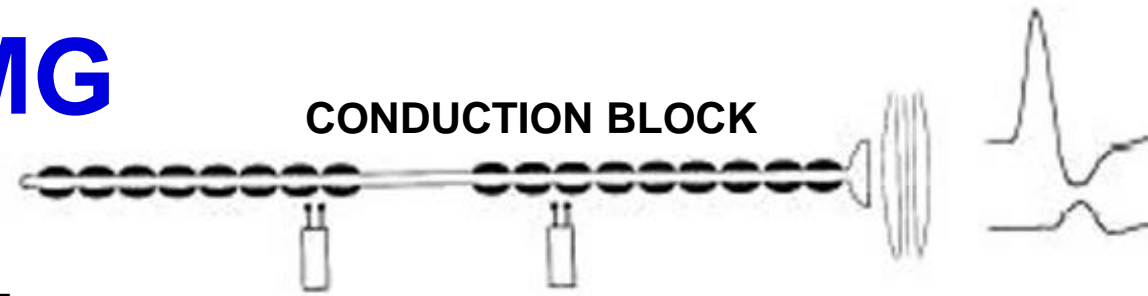

## AXONAL DEGENERATION



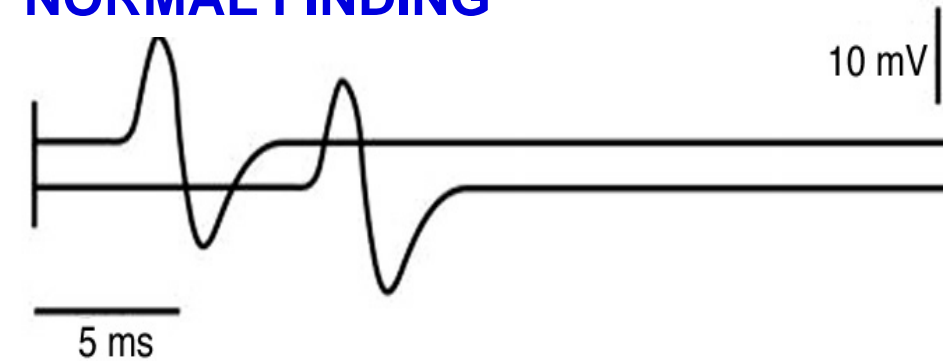
# DEMYELINATING NCS/EMG CHANGES

Demyelination results in:

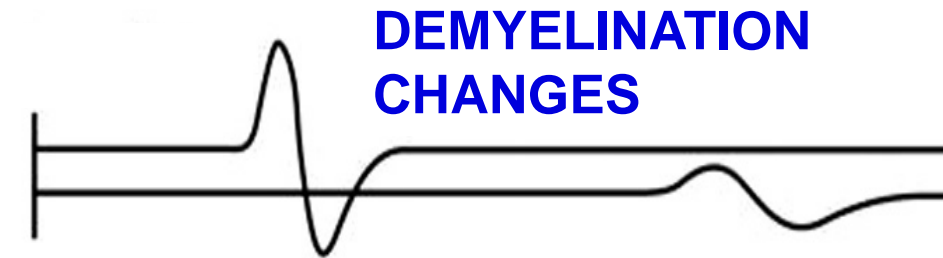
- the reduction of motor and sensory nerve conduction velocities (NCVs) with relative preservation of response amplitudes.
- marked prolongation of distal motor/sensory latencies
- In acquired demyelination the presence conduction block (and temporal dispersion of CMAP) represent typical abnormalities
- No major needle EMG changes unless there is secondary axonal damage



## NORMAL FINDING



## DEMYELINATION CHANGES



## AXONAL DEGENERATION



# LABORATORY TESTS

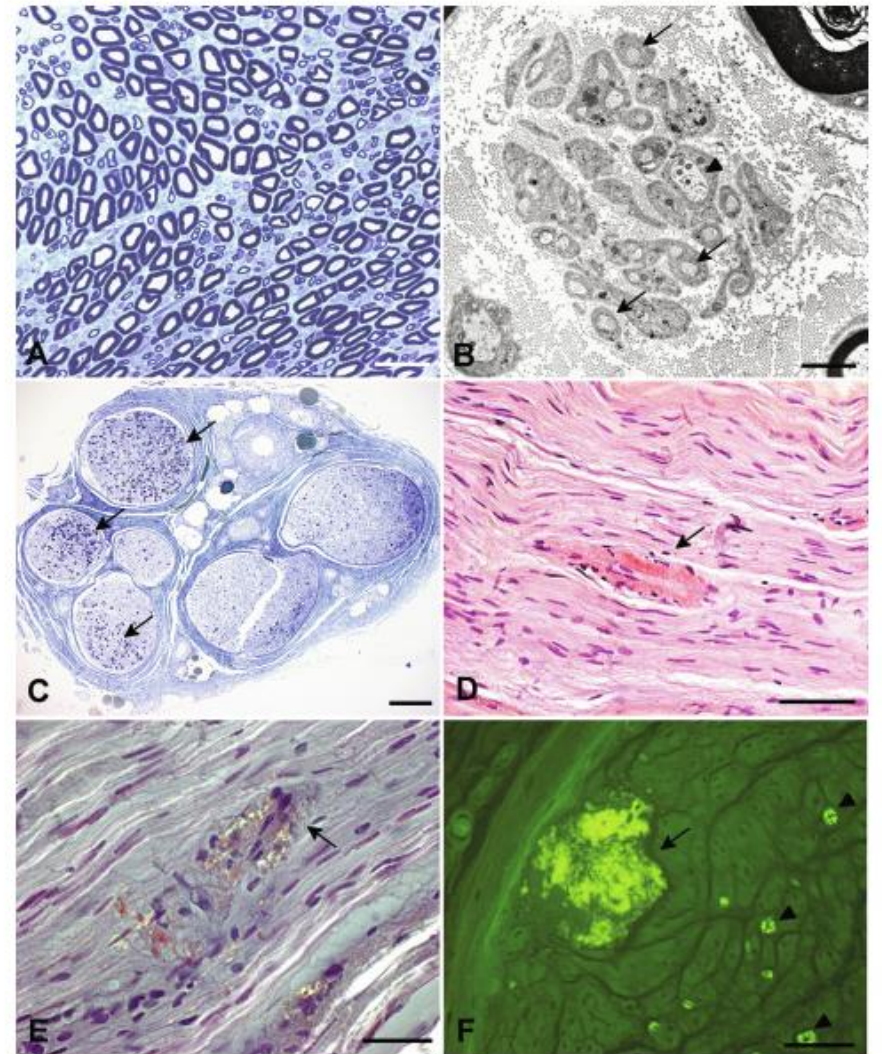
- The clinical neuropathic patterns and the results of electrodiagnostic studies guide the experienced clinician to select the most appropriate laboratory tests
- Some laboratory tests should be obtained routinely in all patients with peripheral neuropathy. These include:
  - complete blood count
  - sedimentation rate (or C-reactive protein)
  - chemistry profile (fasting blood sugar, thyroid studies, vitamin B<sub>12</sub> level, and serum protein electrophoresis with immunofixation electrophoresis).
- If inherited neuropathy is considered, an ever-increasing number of molecular genetic tests is available.
- Cerebrospinal fluid (CSF) examination is helpful in the evaluation of suspected demyelinating neuropathies and polyradiculopathies related to meningeal carcinomatosis or lymphomatosis



# NERVE BIOPSY

- Not performed routinely
- Mainly important in asymmetric forms causing significant functional disability (weakness or sensory deficit), deteriorate rapidly and is not explained by other methods
- Most frequently sural nerve (tibial, superficial peroneal, superficial radial or obturator)
- Used mainly to confirm/ (exclude):
  - Vasculitis, perineuritis
  - Systemic disorders (amyloidosis, leprosy, sarcoidosis)
  - Demyelinating or some hereditary neuropathies

(mostly not needed)

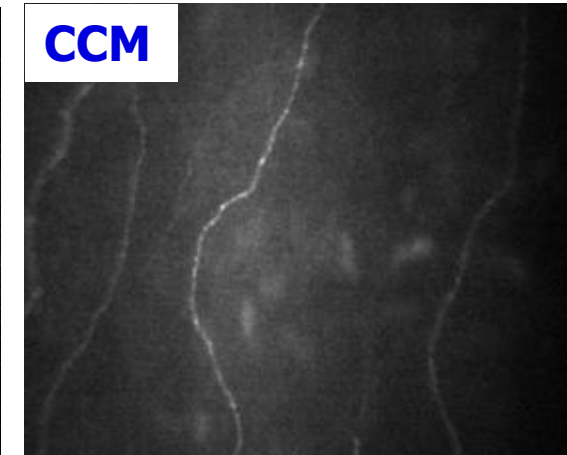
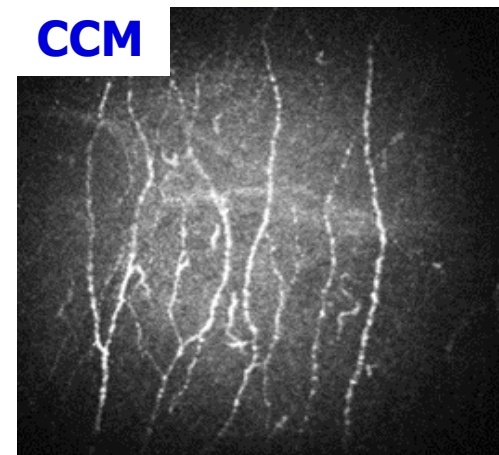
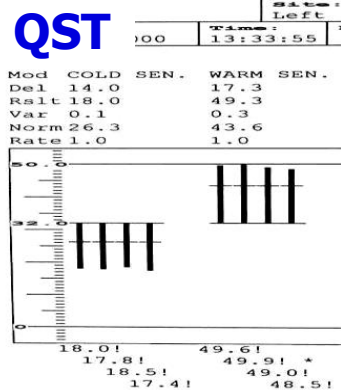


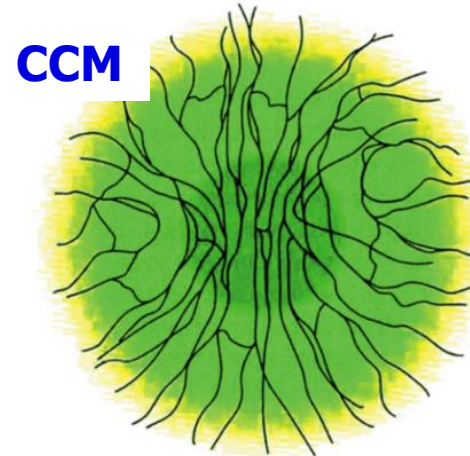
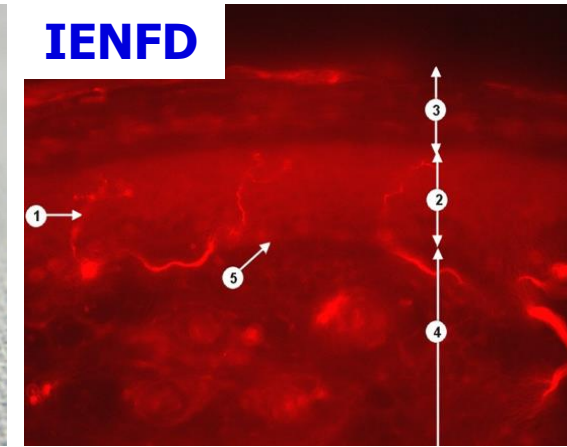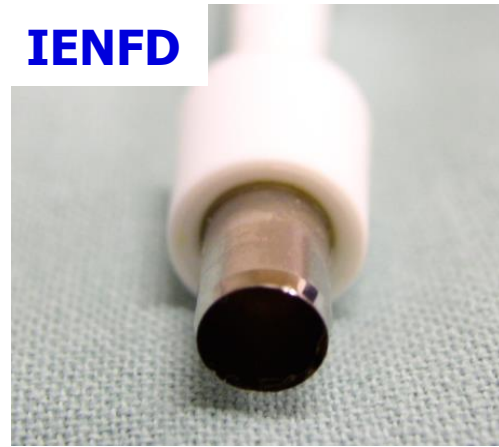


Picture taken from: <https://www.sciencedirect.com/topics/medicine-and-dentistry/nerve-biopsy>

Fig. 31.1. (A) Normal sural nerve with many large and small myelinated fibers. Semithin section, toluidine blue. Scale bar = 20  $\mu\text{m}$ . (B) Empty collagen pockets (arrows) with a single remaining unmyelinated axon (arrowhead). Electron microscopy. Scale bar = 4  $\mu\text{m}$ . (C) Focal loss of myelinated fibers in a nerve biopsy from a patient with vasculitis. Semithin section, toluidine blue. Arrows: areas with preserved myelinated fibers. Scale bar = 100  $\mu\text{m}$ . (D) Congo red staining of nerve biopsy labels amyloid within a blood vessel wall (arrow). Scale bar = 100  $\mu\text{m}$ . (E) Congo red staining of perivascular amyloid deposit (arrow) under polarized light showing green birefringence. Scale bar = 50  $\mu\text{m}$ . (F) Thioflavin S staining (green) highlights a subperineurial amyloid deposit (arrow). Myelin sheaths of several remaining axons show unspecific staining (arrowheads). Scale bar = 50  $\mu\text{m}$ .

# SMALL FIBER NEUROPATHY TESTING

- A gold standard to document small fiber neuropathy = skin biopsy with the evaluation of intraepidermal nerve fiber density (IENFD, loss of small nerve fibers in skin)
- Thermal threshold testing (TTT/QST) – see the presentation on sensory system
- Corneal confocal microscopy (CCM) – direct visualisation of corneal small nerve fibers





# THE CLINICAL MANIFESTATION

The first step in the examination of patients with neuropathy is to determine the anatomical pattern and localization of the disease process (see next slides), and whether motor, sensory, or autonomic nerves are involved.

Both the POSITIVE AND NEGATIVE symptoms may occur.

- Positive symptoms of motor dysfunction: muscle cramps, fasciculations, myokymia
- Negative motor symptoms include weakness (in polyneuropathies, negative sensory symptoms usually start with early distal toe and ankle extensor weakness, resulting in tripping on rugs or uneven ground. If the fingers are weak, patients may complain of difficulty in opening jars or turning a key in a lock).
- Positive sensory symptoms include paresthesias, dysesthesias, and neuropathic pain (and possibly allodynia).
- Negative sensory symptoms include the numbness and sensory ataxia (which contributes to the walking difficulty)

# THE CLINICAL MANIFESTATION – AUTONOMIC SYMPTOMS

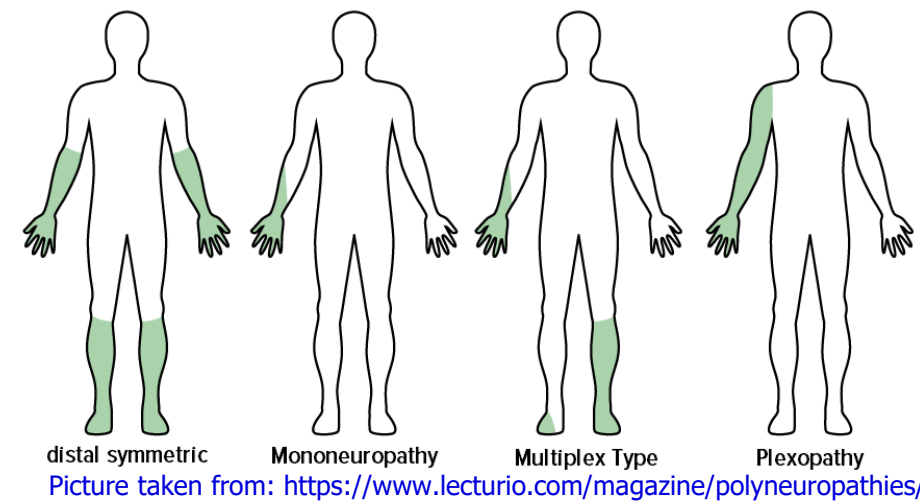
Their presence can be helpful in directing attention toward specific neuropathies that have prominent autonomic symptoms (HSAN, GBS, some of the diabetic neuropathies).

It is important to ask the patient about:

- the symptoms of orthostatic intolerance (lightheadedness), repeated faintness or fainting spells as symptoms of the cardiovascular autonomic neuropathy,
- reduced or excessive sweating, and heat intolerance
- well as bladder, bowel, and sexual dysfunction
- anorexia, early satiety, nausea, and vomiting are symptoms suggestive of gastroparesis
- The degree of autonomic involvement can be documented by noninvasive autonomic function studies

# ANATOMIC PATTERNS

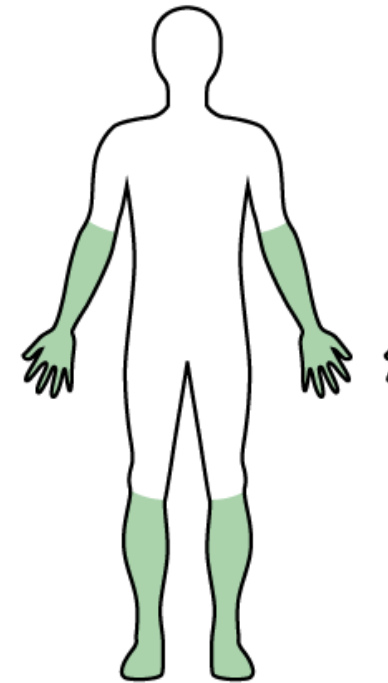
- **MONONEUROPATHY** means focal involvement of a single nerve and implies a local process (most frequently trauma or compression/entrapment...)
- **MULTIPLE MONONEUROPATHY, OR MONONEUROPATHY MULTIPLEX**, signifies simultaneous or sequential damage to multiple noncontiguous nerves. Usually axonal. The most frequent cause is vasculitis or diabetic microangiopathy.
- Single nerve root (**MONORADICULOPATHY**) is a typical manifestation of spondylogenic disorders and similar to brachial or lumbar **PLEXOPATHIES**, they may be caused also by infectious diseases or diabetes mellitus....
- **POLYNEUROPATHY** is most commonly characterized by symmetrical, distal motor and sensory deficits that have a graded increase in severity distally and by distal attenuation of reflexes. Wide range of causes should be considered with diabetes mellitus as the most prominent one in „western world“.





# POLYNEUROPATHIES

- most commonly characterized by symmetrical deficits that have a graded increase in severity distally
- most polyneuropathies produce mixed sensorimotor deficits and some degree of autonomic dysfunction.
- Typical clinical features:
  - Distal (or even general) attenuation of reflexes.
  - The sensory deficits generally follow a length-dependent stocking-glove pattern.
  - Predominantly small/ large or both types of nerve fibers may be affected (see the presentation focused on sensory deficits) leading to the dominant impairment of pain + temperature sensation or vibration sense + proprioception (+ sensory ataxia) or both
  - Motor weakness is greater in extensor muscles than in corresponding flexors (walking on heels is affected earlier than toe walking in most polyneuropathies).
  - Autonomic symptoms mentioned above may also be present in some polyneuropathies.



distal symmetric

# POLYNEUROPATHIES

– classified according to several criteria. Vice versa, these aspects may help to establish what's causing neuropathy.

– Classification based on the DURATION OF SYMPTOMS:

– acute (the symptoms develop within few days up to 4 weeks)

– subacute (4-12 weeks)

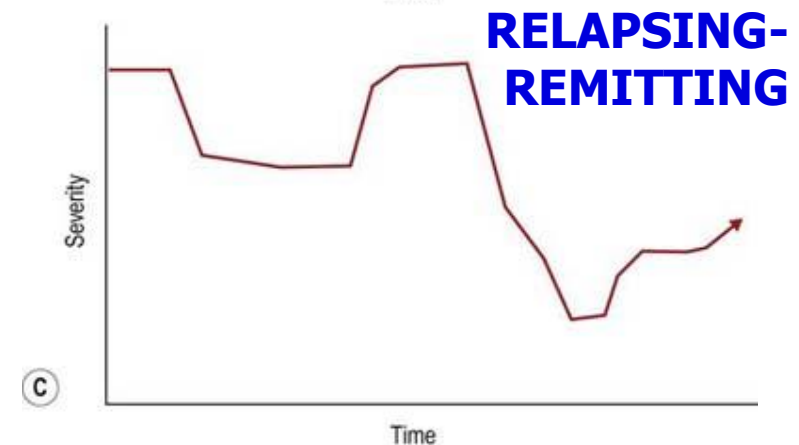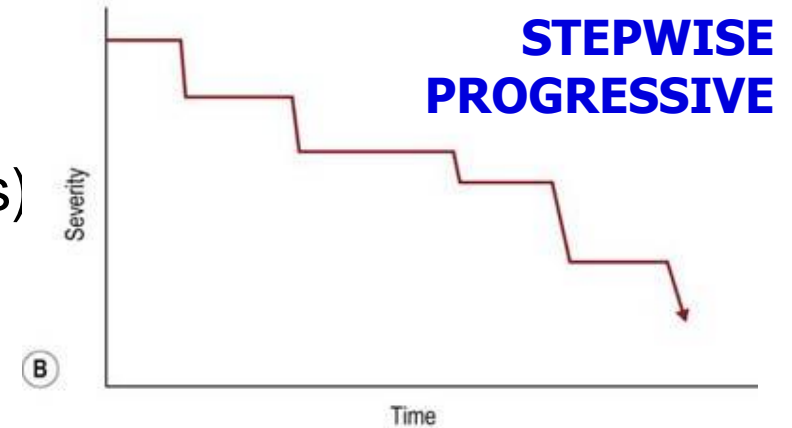
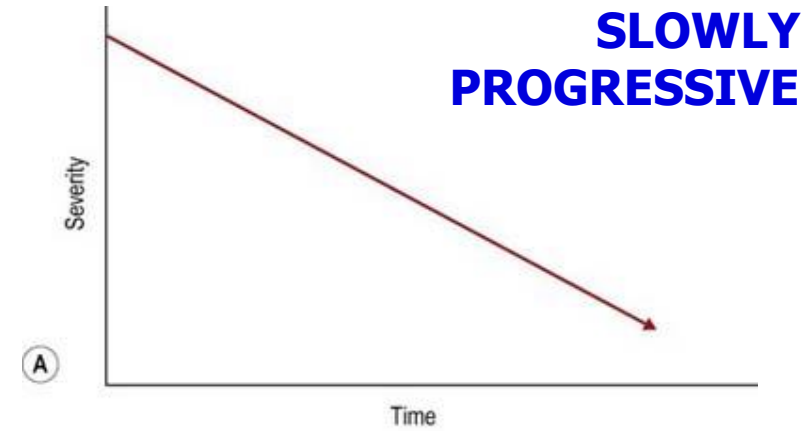
– chronic (the symptoms develop more than 12 weeks)

– Classification based on the COURSE OF THE DISEASE:

– monophasic

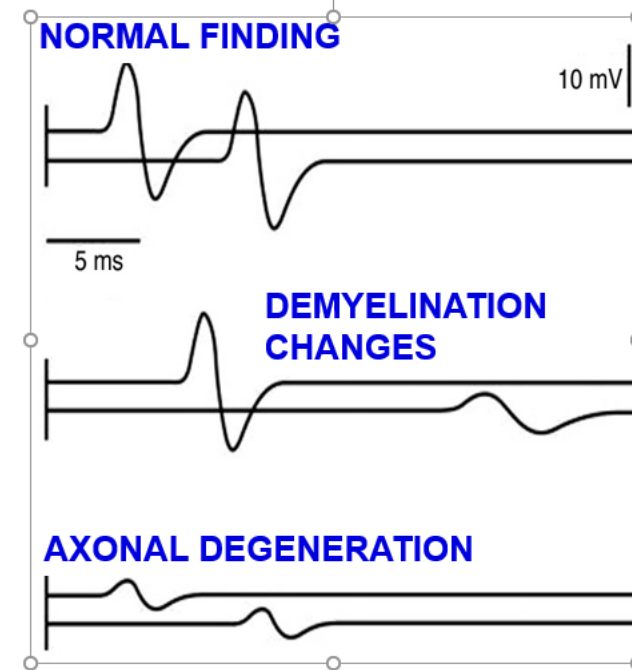
– relapsing

– progressive (slowly / rapidly / stepwise)

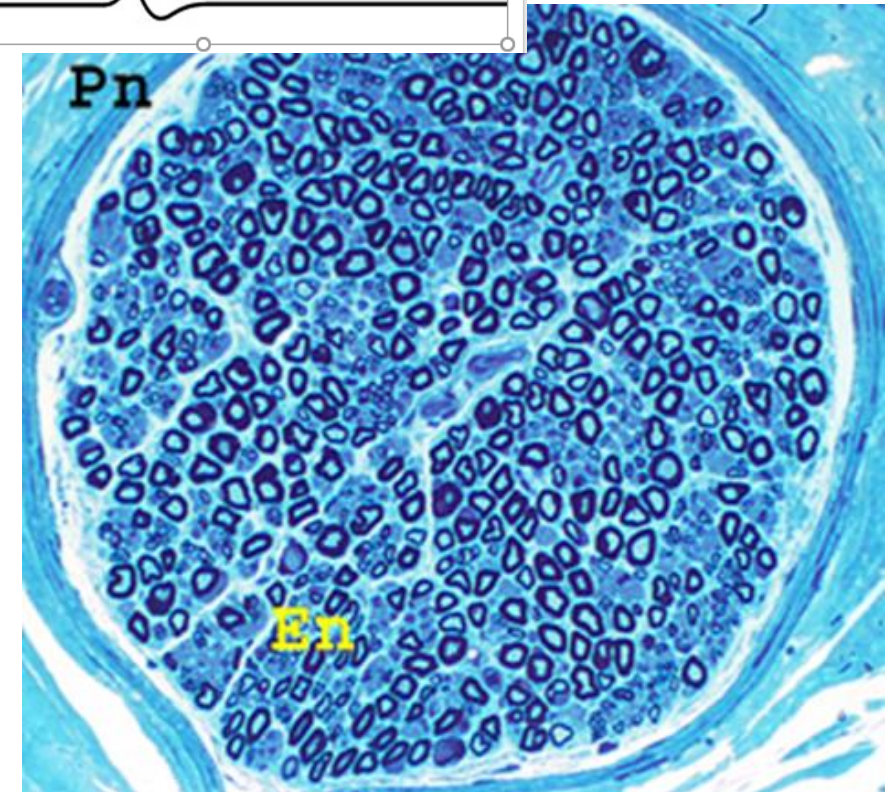


# POLYNEUROPATHIES

- Classification based on the **PREDOMINANT PATHOLOGICAL PROCESS** in peripheral nerves:
  - **Axonal** (more frequent, limited treatment options)
  - **Demyelinating** = autoimmune inflammatory (less frequent, treatable) or hereditary
  
- Classification based on the **TYPE OF THE NERVE FIBERS AFFECTED:**
  - **Small fiber** neuropathies
  - **Large fiber** neuropathies (among others most demyelinating neuropathies, where the small fibers are relatively preserved)
  - **Mixed fiber** neuropathies



Sural nerve biopsy, transverse section, toluidine blue staining = 55-68% of the nerve fibers are small (those without dark blue edging) ↓↓



# ACUTE POLYNEUROPATHIES – GBS

The most frequent acute PNP = Guillain-Barré syndrome (GBS)

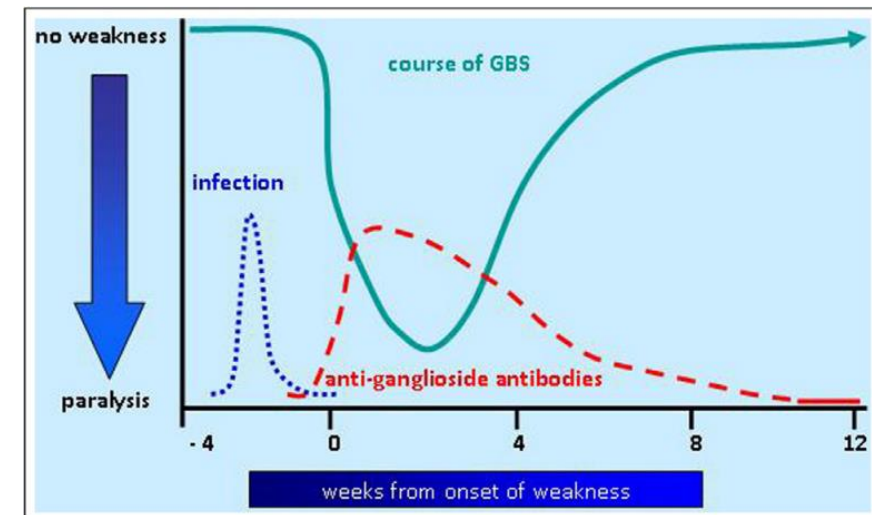
- an immune-mediated rapidly progressive polyneuropathy whose aetiology and pathogenesis are not yet fully understood
- Usually preceded by infection (campylobacter, viruses) or vaccination, auto-antibodies against nerve gangliosides are suggested to play a central role in the pathogenesis
- incidence of GBS increases linearly with age, peaking at 70-80 years, with a maximum of 4-5 cases per 100,000 person years
- GBS can be subclassified into a number of variants, depending on clinical presentation and electrophysiological findings:
  - Demyelinating forms (Acute Inflammatory Demyelinating Polyneuropathy/polyradiculoneuropathy, AIDP).
  - Axonal forms (Acute Motor or Motor/Sensory Axonal Neuropathy – AMAN or AMSAN)

# ACUTE POLYNEUROPATHIES - GBS

## AIDP x AMAN/AMSAN clinical picture:

- rapid progression (over days to 4 weeks)
- symmetrical weakness of both legs and arms (**flaccid para- or tetraparesis**)
- in the peak phase of the disease, about 75% of patients can no longer walk unaided, 30% are tetraparetic, 35-50% show cranial nerve involvement, and 15-20% have respiratory failure and/or autonomic dysfunction.
- up to 70% suffer from neuropathic pain

**Recovery begins 2-4 weeks** after progression ceases even in non-treated patients (sooner in treated patients)



Picture taken from:  
Pieter A. van Doorn. Diagnosis, treatment and prognosis of  
Guillain-Barré syndrome (GBS). La Presse Médicale 2013; 42(6).

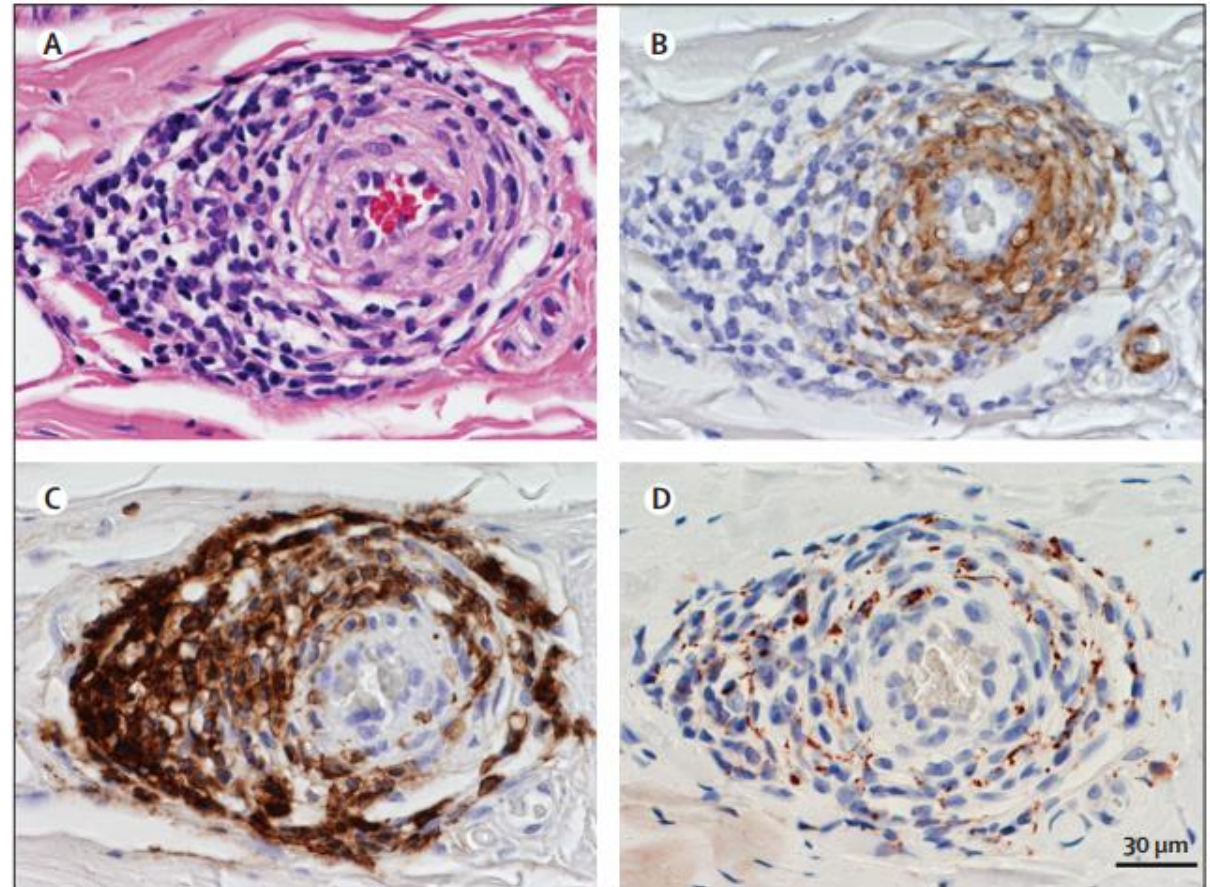


# ACUTE POLYNEUROPATHIES - GBS

- Diagnosis: clinical picture, NCS/EMG (AIDP/AMAN) and CSF (albuminocytological dissociation)
- Treatment:
  - Immunomodulatory therapy with plasmapheresis (PE) or intravenous immunoglobulins (IVIG) has been proven effective in GBS, namely by accelerating the improvement of weakness.
  - No response to corticosteroids
  - Improvement follows a plateau phase that ranges from days to weeks and runs an extremely variable course, regardless of whether a specific therapy has been applied or not
  - Physical therapy, venous thromboembolism prophylaxis, nursing

# ACUTE POLYNEUROPATHIES - OTHER

- Other acute neuropathies (very rare!!!)
  - Acute porphyria
  - Some types of diabetic neuropathy or some toxic neuropathies
  - Vasculitic neuropathy can cause hyperacute (multiple) mononeuropathies usually occurring by 24–72 h



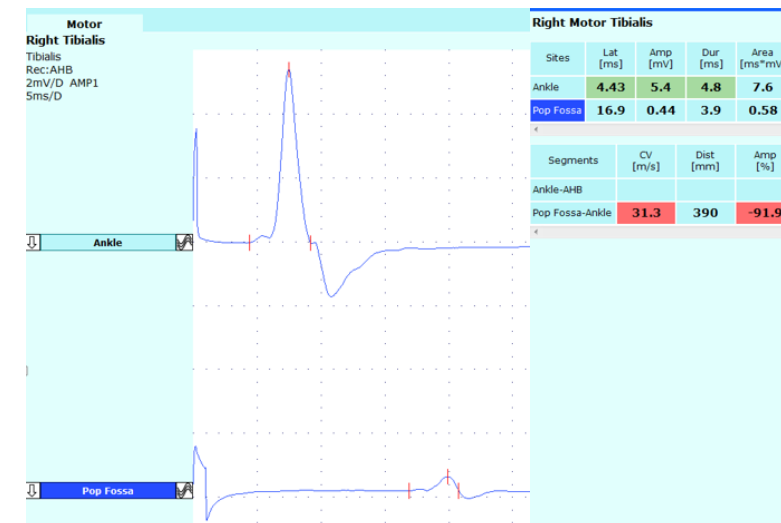
Vasculitic neuropathy, picture taken from Gwathmey KG, Burns TM, Collins MP, Dyck PJB. Vasculitic neuropathies. *Lancet Neurology*. 2014;13(1):67-82

# CHRONIC POLYNEUROPATHIES - CAUSES

- **diabetes mellitus** – the most common cause in the western world (see next slides);
- **other metabolic** diseases (thyroid disorders, liver or kidney diseases);
- **inflammatory demyelinating** conditions
  - Chronic inflammatory demyelinating polyneuropathy (CIDP);
  - Multifocal motor neuropathy (MMN)
- **vasculitis and rheumatic diseases** (mostly asymmetric, nerve biopsy needed);
- **paraneoplastic** (S-M, axonal, ~5% of cancer patients, or autonomic or sensory neuronopathy), antibodies in some);
- **deficiency states** (B12 – posterior columns dysfunction, folic acid, B1, B2, B6);
- **infections** (leprosy, lyme disease, varicella zoster virus, HIV, hepatitis C, Zika - AMAN);
- **toxins** (see next slides);
- **inherited** polyneuropathies (see next slides).

# CHRONIC INFLAMMATORY DEMYELINATING POLYNEUROPATHY (CIDP)

- Rare neurological disorder, **suspected autoimmune basis**
- Caused by the inflammation of nerve roots and peripheral nerves and destruction of the myelin sheath of the nerve fibers = **demyelinating**
- The prevalence of CIDP ranges from 1 to 2 per 100,000
- Seen at all ages, with the peak incidence in the fifth and sixth decades
- **Similar to GBS (AIDP)**, but:
  - (1) the clinical course is more protracted in CIDP
  - (2) CIDP is rarely associated with preceding infections
  - (3) there is a response to corticosteroids in CIDP patients



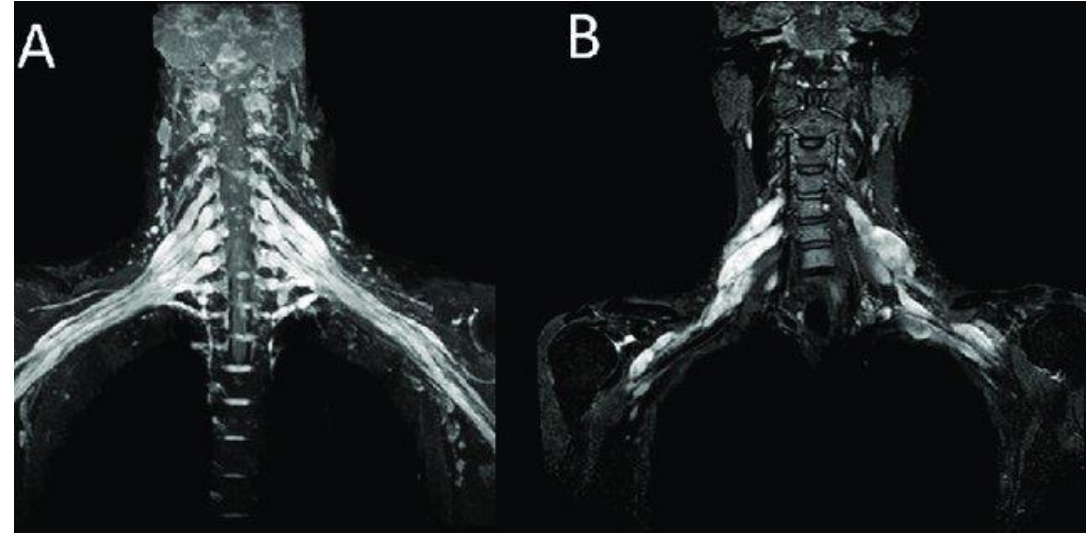
# CIDP: CLINICAL PICTURE

- **symmetrical weakness** of both legs and arms (**flaccid para- or tetraparesis**)  
Muscle wasting is rarely pronounced, **generalized hyporeflexia/areflexia** is the rule  
Proximal limb weakness is almost as severe as distal limb weakness, indicating a nonlength dependency of the neuropathy (note difference from other types of PNP!)
- **sensory disturbance** is frequent (but some cases with predominantly motor involvement)  
Numbness or tingling in stocking-glove distribution, pain occurs less frequently
- The degree of severity and the course of disease **may vary** from person to person.
- Two **patterns of temporal evolution** of CIDP can be seen:
  - continuous or stepwise progressive course over months to years (> 60%)
  - relapsing course with partial or complete recovery between recurrences (1/3)



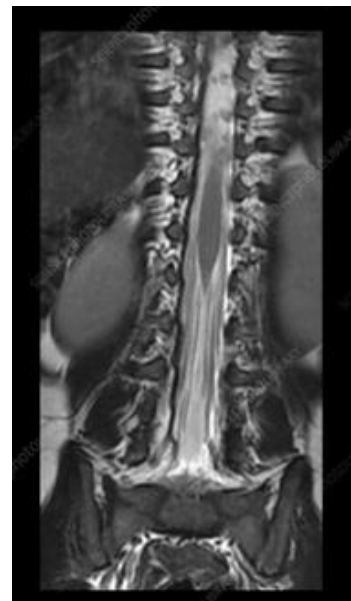# CIDP: DIAGNOSTICS

- clinical picture
- NCS/EMG (demyelination!!!)
- CSF (albuminocytological dissociation)
- ultrasound: nerve enlargement of at least 2 proximal sites and/or the brachial plexus
- MRI: enlargement and/or increased signal intensity of nerve root(s) on T2 MRI
- response to treatment (IVIg, plasma exchange, corticosteroids)
- Sural nerve biopsy suggesting demyelination



Lehmann HC, Burke D, Kuwabara S. Chronic inflammatory demyelinating polyneuropathy: update on diagnosis, immunopathogenesis and treatment. J Neurol Neurosurg Psychiatry 2019;90(9):981-987.

<https://www.sciencephoto.com/keyword/mri-of-cidp>



# CIDP: TREATMENT

- Daily single-dose **oral prednisone** (started at 60 to 80 mg, improvement can be anticipated within 2 months; by 3 months 88% improve. Following improvement, the dose may be converted to an alternate-day, single-dose schedule)
- Alternative treatment with **high-dose, intermittent, intravenous methylprednisolone**
- **Therapeutic plasma exchange** (improvement faster – within days)
- **IVIG** using 0.4 g/kg/day on 5 consecutive days (improvement already during the first week, maximal in 6 weeks). When secondary deterioration occurs, patients are retreated with single IVIG infusions (0.4 to 1.0 g/kg), depending on the severity of the relapse
- **Alternative forms of immunosuppressive** treatment should be considered for patients with CIDP who are refractory to corticosteroids, plasma exchange, and IVIG, or as used as corticosteroid-sparing, adjunctive agents (no control trial available)

# DIABETIC NEUROPATHY

- **Microvascular complication**
- Earlier and slightly higher prevalence in type 2 DM vs. type 1
- **Prevalence depends on the confirmatory methods used:**
  - 7.5% at the disease onset
  - 50% 25 years after onset
- **Risk factors** for developing diabetic neuropathy
  - Glycemic control: Higher glycosylated hemoglobin
  - Cardiovascular risk factors = Metabolic syndrome (hypertension, smoking, obesity, high triglyceride levels)
  - Presence of the cardiovascular disease
  - Type 2 diabetes

# TYPES OF NEUROPATHY IN DM PATIENTS

## – Symmetric neuropathies

### – **Chronic**

Distal sensory/autonomic

Autonomic

Sensory-motor

### – **Acute**

Painful

Reversible

## – Immune PN: predisposition

### – CIDP

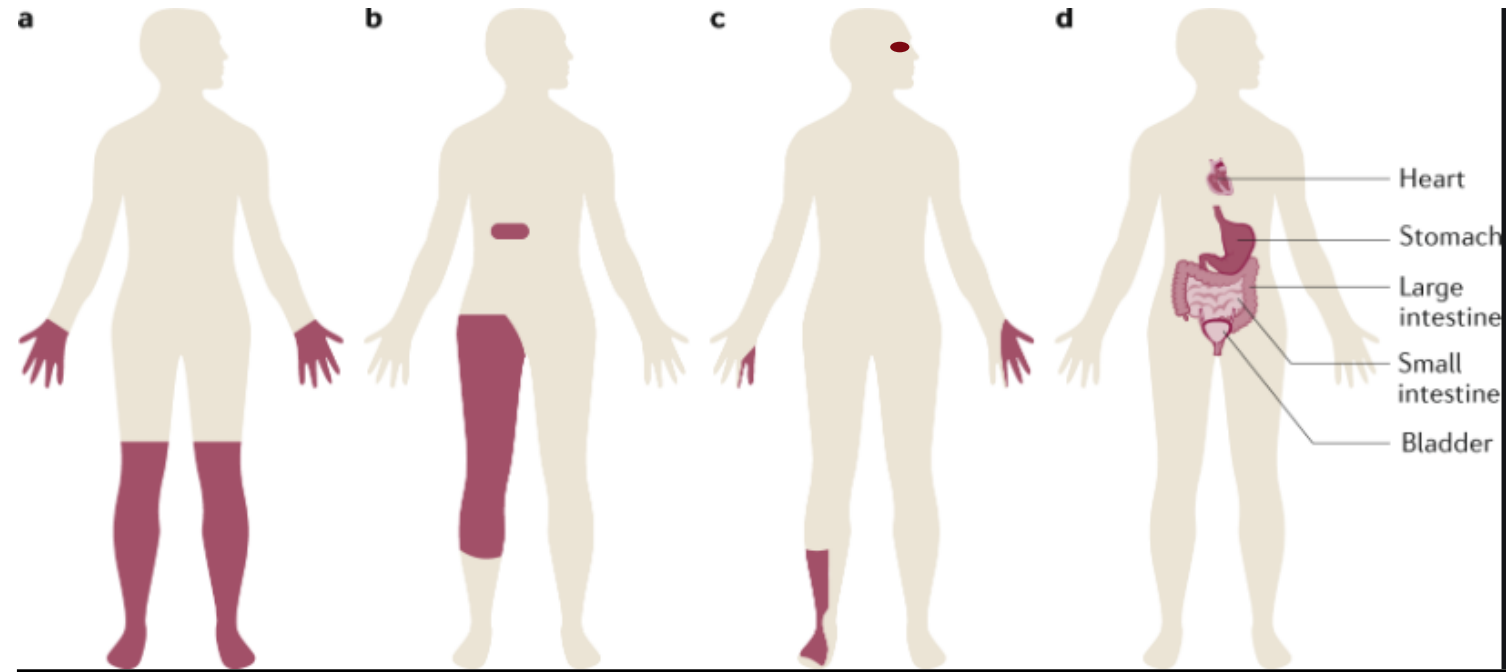
## – Asymmetric neuropathies

### – Lumbosacral plexopathy

### – Radiculopathies

### – Mononeuropathies (acute e.g cranial or ↑ susceptibility to entrapment)

### – Mononeuritis multiplex



Distal symmetric polyneuropathy (small/large fibers)	Radiculopathy (truncal) Plexopathy (lumbosacral)	Mononeuropathies (acute or entrapment)	Autonomic neuropathy
--	--	--	----------------------

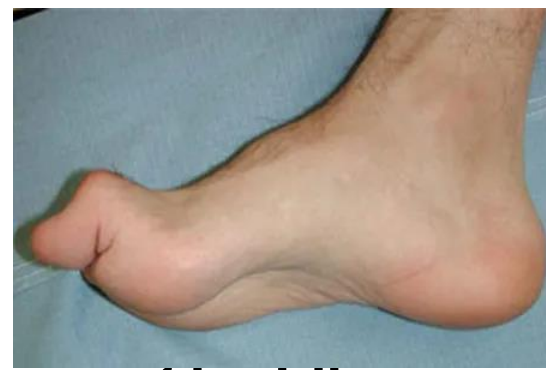Picture taken from: Feldman EL, Callaghan BC, et al. Diabetic neuropathy. Nat Rev Dis Primers. 2019;5(1):41.

# TOXIC NEUROPATHIES

- Many agents, **mostly axonal**
- **Alcoholic** = direct toxic effect + nutritional deficiency (mainly B1 - associated also with Wernicke's (acute delirium + ataxia + ocular palsy) – Korsakoff's encephalopathy (chronic psychosis).
- Frequent in **anticancer chemotherapy** (vinca-alcaloids, taxanes, cisplatin, oxaliplatin, thalidomide, bortezomib, brentuzumab vedotin...)
- Rarely others
- including rare side effect of some **other medicines** (amiodarone, chloroquine, chloramphenicol....)
- or **metallic poisoning** (lead – mostly industrial exposure, motor neuropathy) (lithium, arsenic, cobalt...)

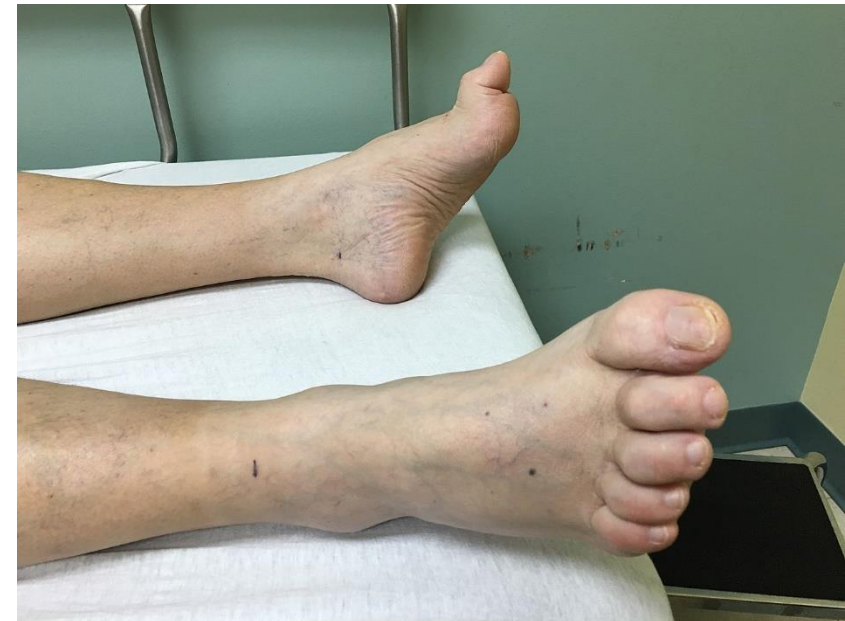

# HEREDITARY NEUROPATHIES



Heterogeneous group of diseases, which usually share the clinical features of insidious onset and indolent course over years to decades.

- Typical skeletal abnormalities such as hammer toes, high arches, or scoliosis
  - Common paucity of positive symptoms - may not be aware of any problem for many years
  - → The diagnosis is frequently established in adulthood
  
  - The most frequent types are autosomal dominant  
less frequently autosomal recessive or X-linked
  - Mostly positive family history, sometimes new mutations
  - Typical electrophysiological abnormalities in particular types  
(demyelinating x axonal x intermediate)
- 39 Diagnosis confirmed by genetic testing



# HEREDITARY NEUROPATHIES

## Charcot-Marie-Tooth Disease (Hereditary Motor and Sensory Neuropathy) (CMT, HSMN)

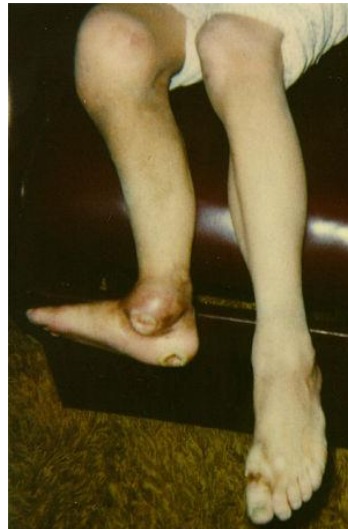- Type I demyelinating, type II axonal, others rare
- Large fibers - common paucity of positive symptoms, peroneal weakness
- Frequent skeletal abnormalities (hammer toes, high arches, or scoliosis)

## Hereditary Neuropathy with Liability to Pressure Palsies (HNPP) - quite frequent, AD

- condition leading to increased peripheral nerve susceptibility to mechanical traction or compression
- Patients have recurrent episodes of isolated mononeuropathies, typically affecting, in order of decreasing frequency, the common peroneal, ulnar, brachial plexus (painless!), radial, and median nerves.

## Hereditary Sensory and Autonomic Neuropathy (HSAN)

- Rare!!!, affects small fibers - pain or paresthesias in some (not all) patients
- Sensory loss: initially pain + temperature (with progression to all modalities)
- unnoticed, recurrent trauma, leading to neuropathic (Charcot) joints,
- 40 nonhealing ulcers, infections, and osteomyelitis resulting in acral mutilations



# HEREDITARY MOTOR SENSORY NEUROPATHIES (HMSN; CMT) \*

**CMT & HMSN: Demyelinating**

**Dominant**

**CMT 1A:** PMP-22; 17p12  
**CMT 1B:** P<sub>0</sub> protein; 1q23  
**CMT 1C:** LITAF; 16p13  
**CMT 1D:** EGR2; 10q21  
**CMT 1E (Deafness)**  
**PMP-22:** 17p12  
**P<sub>0</sub> protein:** 1q23  
**CMT 1F:** NEFL; 8p21  
**CMT 1G:** PMP2; 8q21  
**CMT1:** FBLN5; 14q32  
**CMT1:** c1orf194; 1p13  
**HNPP**  
**PMP-22 (Deletion or Point);** 17p12  
**KARS;** 16q23  
**HMSN 3 (Dejerine-Sottas)**  
**PMP-22; P<sub>0</sub>; 8q23; EGR2**

**Thermosensitive**

**PNS & CNS hypomyelination:** SOX10; 22q13  
**Sensory PN + Hearing loss:** GJB3; 1p34  
**Hypomyelination:** ARHGEF10; 8p23  
**CMT-DIE:** GNB4; 3q26  
**HMSN:** HARS; 5q31

**Recessive: Also AR-CMT1**

**CMT 4A:** GDAP1; 8q21  
**CMT 4B1:** MTMR2; 11q22  
**CMT 4B2:** SBF2; 11p15  
**CMT 4B3:** SBF1; 22q13  
**CMT 4C:** SH3TC2 (KIAA1985); 5q32  
**CMT 4D (Lom):** NDRG1; 8q24  
**CMT 4E:** EGR2; 10q21  
**CMT 4F:** Periaxin; 19q13  
**HMSN-Russe (4G):** HK1; 10q22  
**CMT 4H:** FGD4; 12q12  
**CMT 4I:** FIG4; 6q21  
**CMT 4K:** SURF1; 9q34  
**HMSN 3 (Dejerine-Sottas)**  
**P<sub>0</sub>; PMP-22; EGR2; Periaxin**

**HMSN + Juvenile glaucoma**

**Cataracts (CCFDN):** CTFD1; 18qter  
**Cockayne's:** 5

**Congenital hypomyelinating**  
**P<sub>0</sub>; PMP-22 & EGR-2**

**Farber lipogranulomatosis:** ASAH; 8p22  
**CDG1a:** PMM2; 16p13  
**Krabbe:** GALC; 14q31  
**MLD:** ARSA; 22q13  
**PMP-22 point mutations**

**Refsum's disease**  
**Childhood:** PHYH; 10pter-p11.2  
**Adolescent-Adult:** PEX7; 6q22  
**Infant:** PEX1; 7q21  
**PHARC:** ABHD12; 20p11  
**PBD8B:** PEX16; 11p11

**HMSN +**  
**CNS:** Heterogeneous  
**Neurodegeneration:** DNAJC3; 13q32

**X-linked**  
**CMTX1 (Males):** GJB1 (CX32); Xq13  
**CMTX3:** Xq27  
**Pyramidal signs**

**CMT & HMSN: Axonal**

**Dominant**

**CMT 2A2A:** MFN2; 1p36  
**7 CMT 2A1:** KIF1B; 1p36  
**CMT 2B:** RAB7; 3q21  
**CMT 2C:** TRPV4; 12q24  
**CMT 2D:** GARS; 7p14  
**CMT 2E:** NEFL; 8p21  
**CMT 2F (Distal HMSN):** HSPB1; 7q11  
**CMT 2G:** See **CMT 2F**  
**CMT 2I:** P<sub>0</sub>; 1q22  
**CMT 2J:** P<sub>0</sub>; 1q22  
**CMT 2K:** GDAP1; 8q21  
**CMT 2L:** HSPB8; 12q24  
**CMT 2M:** DNMT2; 19p13  
**CMT 2N:** AARS; 16q22  
**CMT 2O:** DYNC1H1; 14q32  
**CMT 2P:** LRSAM1; 9q33  
**CMT 2Q:** DHTKD1; 10p14  
**CMT 2U:** MARS; 12q13  
**CMT 2V:** NAGLU; 17q21  
**CMT 2W:** HARS; 5q31  
**CMT 2Y:** VCP; 9p13  
**CMT 2Z:** MORC2; 22q12  
**CMT 2CC:** NEFH; 22q12  
**CMT 2DD:** ATP1A1; 1p13  
**HMSN:** BAG3  
**HMSN + Deafness**  
**P<sub>0</sub>**  
**Connexin-31 (GJB3)**  
**Eye + Ear dysfunction**  
**HMSN + Optic atrophy**  
**HMSN6A:** MFN2; 1p36  
**HMSN-Proximal:** TFG; 3q12  
**CMT2 + Pyramidal**  
**HMSNs:** 4q34  
**MFN2:** 1p36  
**KIF5A:** 12q13  
**HSMN + Ulcero-mutilation**  
**HMSN:** SPTLC3; 20p12  
**HSMN + Ataxia:** IFRD1; 7q31  
**HMN 5B:** BSCL2; 11q13  
**CFEOM3:** TUBB3; 16q24  
**HSAN I**  
**SPTLC1:** 9q22  
**SPTLC2:** 14q24

**Recessive**

**AR-CMT2**  
**A (B1):** Lamin A/C; 1q22  
**B (B2):** PNKP; 19q13  
**PNKP:** 19q13  
**F/Distal HMSN:** HSPB1; 7q11  
**H/Pyramidal signs:** 8q21  
**K/Hoarseness:** GDAP1; 8q21  
**P:** LRSAM1; 9q33  
**R:** TRIM2; 4q31  
**S:** IGHMBP2; 11q13  
**I:** MME; 3q25  
**X:** SPG11; 15q21  
**A2B:** MFN2; 1p36  
**EE:** MPV17; 2p23  
**AHNAK2:** 14q32  
**EGR2:** 10q21  
**HS1/DNAJB2:** 2q35  
**MCM3AP (GANP):** 21q22  
**PRPH:** 12q13  
**SACS:** 13q12

**Acrodyostrophy:** ATSV; 2q37  
**Andermann:** KCC3; 15q13  
**Ataxia + Neuropathy**  
**Cough + Sensory**  
**Hepato-Cerebellar:** SCYL1; 11q13  
**SCAN**

**Early onset**  
**CMT:** SC02; 22q13  
**Lethal Neonatal**  
**NBIA2A:** PLA2G6; 22q13  
**Ouvrier**  
**Optic:** MFN2; 1p36  
**Respiratory failure**  
**REEP1:** 2p11  
**MFN2:** 1p36  
**Severe:** NEFL; 8p21  
**Episodic:** SGPL1; 10q22  
**Giant axonal:** Gigaxonin; 16q23  
**Neuromyotonia:** HINT1; 5q31  
**Optic neuropathy (HMSN6)**  
**HMSN6A:** MFN2; 1p36  
**HMSN6B:** SLC25A46; 5q22  
**HMSN6C:** PDXK; 21q22  
**HMSN = Deaf**  
**Mitochondrial**

**Syndromes: HMSN+**  
**Childhood onset**  
**CNS**  
**Deafness**

**X-linked**

**Semi-Dominant**  
**1:** GJB1 (CX32); Xq13  
**6:** PDK3; Xp22

**Recessive**  
**2:** Xp22.2  
**3:** Xq27  
**4 (Cowchock):** AIFM1; Xq26  
**5:** PRPS1; Xq22  
**Sensory PN + Deaf:** Xq26

**Mitochondrial: MT-ATP6**

**CMT + Intermediate NCV**

**Dominant**

**CMT-DIA:** 10q24  
**CMT-IB:** DNMT2; 19p13  
**CMT-DIC:** YARS; 1p35  
**CMT-DID:** P<sub>0</sub>; 1q22  
**CMT-DIE:** INF2; 14q32  
**CMT-DIF:** GNB4; 3q26  
**CMT-DIG:** NEFL; 8p21  
**CMT-DI:** c1orf194; 1p13  
**CMT-DJ:** EBP50; 17q25.1  
**CMT-X (Semi-dominant):** GJB1  
**CMT 1C:** LITAF; 16p13  
**CMT 2E:** NEFL; 8p21  
**Hypomyelination:** ARHGEF10; 8p23

**Recessive**

**CMT RIA:** GDAP1; 8q21.1  
**CMT RIB:** KARS; 16q23  
**CMT RIC:** PLEKHG5; 1p36  
**CMT RID:** COX6A1; 12q24  
**CMT XI:** DRP2; Xq22

**Other related names or disorders**

**α-Methylacyl-CoA racemase (AMACR)**  
**Brachial plexopathy; Hereditary**  
**Childhood onset neuropathies**  
**CNS & Cranial nerve disorders**  
**Complex clinical syndromes**  
**Congenital Hypomyelinating**  
**EGR2:** 10q21  
**P<sub>0</sub>:** 1q22  
**PMP-22:** 17p11  
**ARHGEF10:** 8p23  
**Connective tissue:** EMILIN1; 2p23  
**Cowchock:** AIFM1; Xq26  
**Dejerine-Sottas (HMSN 3)**  
**Focally folded myelin sheaths**  
**CMT 4B:** MTMR2; 11q23  
**CMT 4B2:** SBF2; 11p15  
**CMT 4E:** EGR2; 10q21  
**CMT 4F:** Periaxin; 19q13  
**P<sub>0</sub>:** 1q22  
**Juvenile glaucoma**

**Hereditary**  
**Motor neuropathies**  
**Distal (dHMN)**  
**Sensory neuropathies (HSN; HSAN)**  
**Metabolic abnormalities**  
**Minifascicles & Gonadal dysgenesis**  
**HSN:** DHH; 12q12  
**Myelin disorders:** Recessive

**Recurrent**  
**Brachial plexopathy**  
**Pressure palsies (HNPP):** PMP-22  
**Neuropathy:** 21q21  
**SCA + Neuropathy:**  
**SMARD**  
**SPG + Neuropathy**  
**Vertical talus:** HOXD10; 2q31

**Charcot-Marie-Tooth (CMT)**

**Features**

[Associated](#)  
[Childhood](#)  
[Childhood CMT](#)  
[Comparative](#)  
[General](#)  
[Molecules](#)  
[Pathology](#)  
[Myelin proteins](#)  
**External links**  
[Mutation database](#)  
[Mutations](#)



**Charcot (left) & Babinski at the Salpêtrière clinic.**



# CURRENT LIST OF HSMN TYPES

- With particular genetic defects
- No need to know – just to get an idea, how heterogenetic the disease is 😊.

Adopted from:  
<https://neuromuscular.wustl.edu/time/hmsn.html>

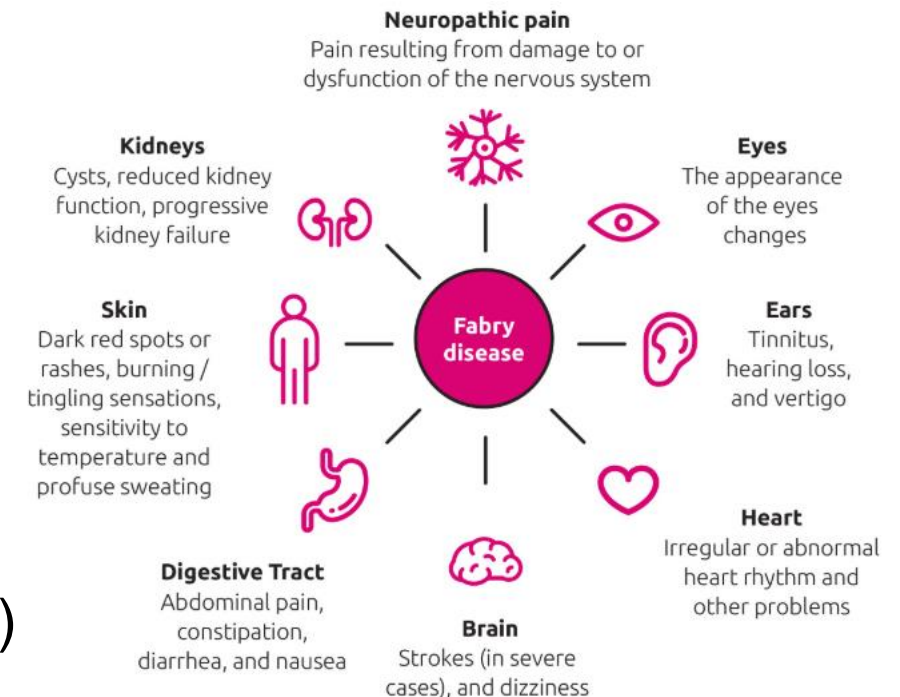
# OTHER INHERITED DISEASES PRESENTING (AMONG OTHERS) WITH NEUROPATHY

Mostly the storage diseases – multisystem involvement (cardiac, renal, ocular... etc.)

- Some of them treatable! (enzyme replacement therapy – mainly prevents further progression, partial regression of the symptoms/signs is also possible)

Some examples:

- Familial transthyretin (TTR) amyloid neuropathy (AD, polyneuropathy (frequent autonomic symptoms) + CTS + ❤️)
- Fabry disease (XR,  $\alpha$ -Galactosidase deficiency, males affected, painful feet, precipitated by fever or hot weather or physical activity + other organs →→→)





# TREATMENT OPTIONS IN POLYNEUROPATHIES

- In demyelinating inflammatory neuropathies: corticosteroids, IVIG, plasmaferesis, other immunosuppressive drugs (see above)
- In axonal neuropathies – management of the underlying disease (if possible)
  - In DM: good compensation + lifestyle interventions + vascular risk factor management
  - In others: substitution of vitamine deficiency, cessation of toxine exposure, treatment of particular infecious disease (leprosis, HIV, lyme.....).....
  - In inherited neuropathies only symptomatic
    - In some storage diseases (TTR amyloidosis, Fabry) enzyme replacement therapy
- Symptomatic treatment
  - Neuropathic pain treatment (antiepileptics or antidepressants or opioids)
  - Physical therapy (to restore, or maintain muscle strength, and prevent muscle shortening and deformity)
  - Orthotic management (angle-foot orthosis in peroneal palsy), orthopedic surgery (CMT)
  - The prevention of painless traumas in SFN



# MONONEUROPATHIES

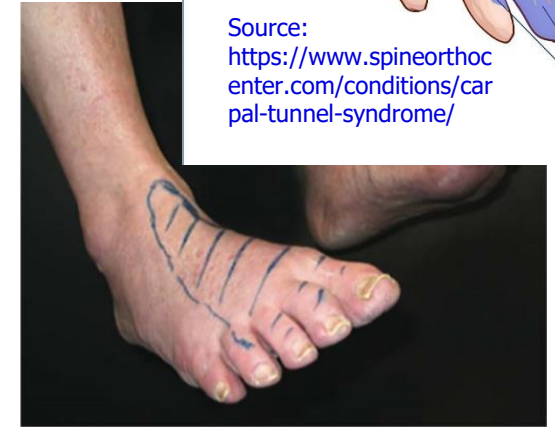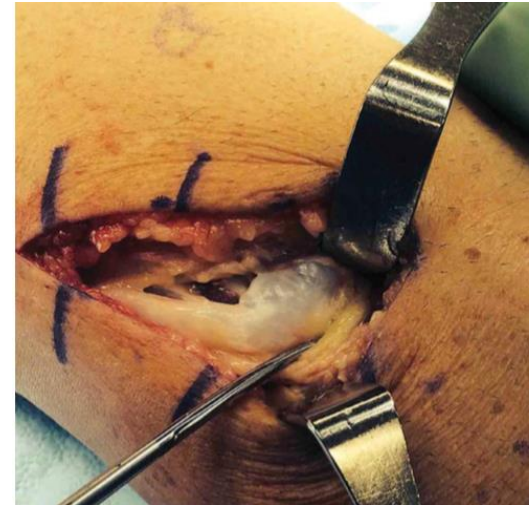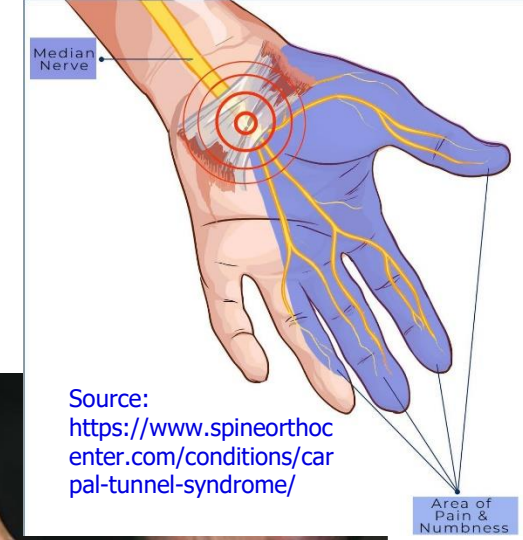
## – THE MOST COMMON CAUSES:

- direct trauma,
- compression or entrapment,
- vascular lesions,
- neoplastic compression or infiltration.

## – SYMPTOMS AND SIGNS limited to the distribution of one peripheral nerve

## – ELECTROPHYSIOLOGICAL STUDIES:

- provide a more precise localization of the lesion than may be possible by clinical examination
- can separate axonal loss from focal segmental demyelination.
- may reveal a more widespread change, indicating an underlying neuropathy that has made the nerve susceptible to entrapment as occurs in diabetes mellitus, hypothyroidism, acromegaly, alcoholism, and HNPP.



Poage C, Roth C, Scott B. Peroneal Nerve Palsy: Evaluation and Management. J Am Acad Orthop Surg 2016;24(1):1-10.

# ENTRAPMENT NEUROPATHY

- defined as a focal neuropathy caused by restriction or mechanical distortion of a nerve within a fibrous or fibro-osseous tunnel (or less commonly by other structures such as bone, ligament, other connective tissues, blood vessels, or mass lesions).
- Far the most frequent cause of peripheral mononeuropathies
- compression, constriction, angulation, and stretching are important mechanisms that produce nerve injury at certain vulnerable anatomical sites (see next slides).
- In chronic entrapment, mechanical distortion of the nerve fibers leads to focal demyelination or, in severe cases, to wallerian degeneration
- In contrast, ischemia plays a more significant role in nerve injury associated with acute compression secondary to space-occupying lesions such as hematoma or compartment syndromes.

# ENTRAPMENT NEUROPATHIES OF UPPER LIMBS

NERVE	SITE OF COMPRESSION	PREDISPOSING FACTORS	MAJOR CLINICAL FEATURES
Median	Wrist (carpal tunnel syndrome)	Tenosynovitis, arthritis, etc.	Paresthesia, pain, thenar atrophy
	Anterior interosseous	Strenuous exercise, trauma	Abnormal pinch sign, normal sensation
	Elbow (pronator teres syndrome)	Repetitive elbow motions	Tenderness of pronator teres, sensory loss
Ulnar	Elbow (cubital tunnel syndrome)	Elbow leaning, trauma	Clawing and sensory loss of fourth and fifth fingers
	Guyon's canal	Mechanics, cyclists	Hypothenar atrophy, variable sensory loss
	Axilla	Crutches	Wrist drop, triceps involved, sensory loss
Radial	Spiral groove	Abnormal sleep postures	Wrist drop, sensory loss
	Posterior interosseous	Elbow synovitis	Paresis of finger extensors, radial wrist deviation
	Superficial sensory branch	Wrist bands, hand cuffs	Paresthesias in dorsum of hand
Suprascapular	Suprascapular notch	Blunt trauma	Atrophy of supraspinatus and infraspinatus muscles
Dorsal scapular	Scalene muscle	Trauma	Winging of scapula on arm abduction
Lower trunk of the brachial plexus or C8/T1 roots	Thoracic outlet	Cervical rib, enlarged C7 transverse process	Atrophy of intrinsic hand muscles, paresthesias of hand and forearm

No need to know all of them - just those in the blue boxes (will be described more in detail later)

# ENTRAPMENT NEUROPATHIES OF LOWER LIMBS

NERVE	SITE OF COMPRESSION	PREDISPOSING FACTORS	MAJOR CLINICAL FEATURES
Sciatic	Sciatic notch	Endometriosis, intramuscular injections	Pain down thigh, footdrop, absent ankle jerk
	Hip	Fracture dislocations	
	Piriformis muscle		
	Popliteal fossa	Popliteal Baker's cyst	
Fibular	Fibular neck	Leg crossing, squatting	Footdrop, weak levators, sensory loss in dorsum of foot
	Anterior compartment	Muscle edema	Footdrop
Posterior tibial	Medial malleolus (tarsal tunnel syndrome)	Ankle fracture, tenosynovitis	Sensory loss over sole of foot
Femoral	Inguinal ligament	Lithotomy position	Weak knee extension, absent knee jerk
Lateral femoral cutaneous	Inguinal ligament (meralgia paresthetica)	Tight clothing, weight gain, utility belts	Sensory loss in lateral thigh
Ilioinguinal	Abdominal wall	Trauma, surgical incision	Direct hernia, sensory loss in the iliac crest, crural area
Obturator	Obturator canal	Tumor, surgery, pelvic fracture	Sensory loss in medial thigh, weak hip adduction

47 No need to know all of them - just those in the blue boxes (will be described more in detail later)

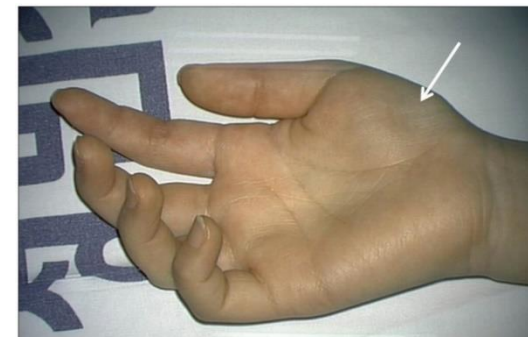
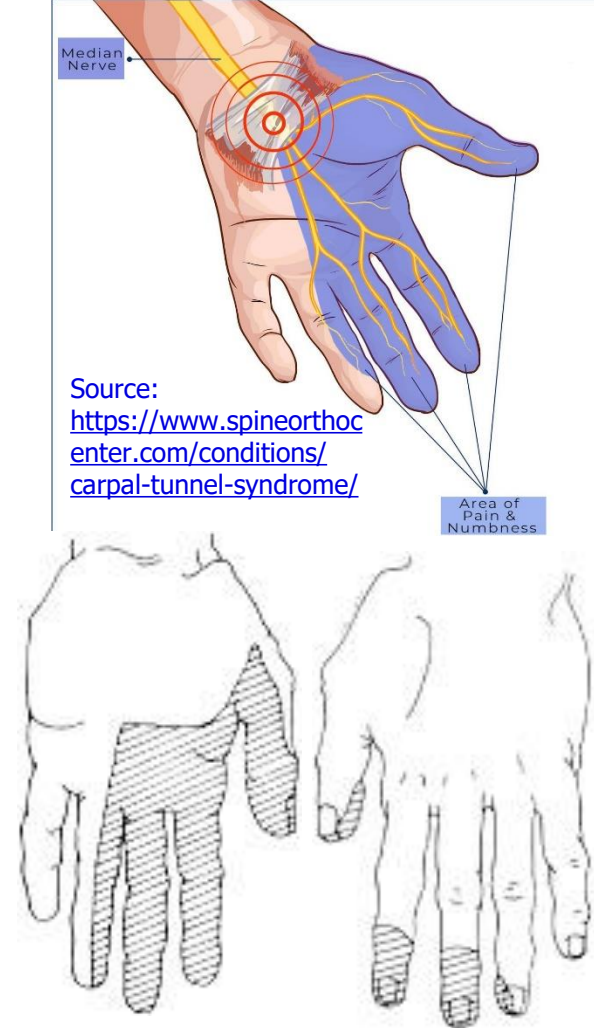
# ENTRAPMENT NEUROPATHIES

- **DIAGNOSIS** – mainly based on **history + neurological examination**
- Confirmed by **NCS/EMG** - either short segment **conduction slowing or conduction block** across the site of entrapment. **Secondary axonopathy is frequently** present.
- **Imaging methods** (US, MR, CT) may help for exact localisation of the lesion, and a diagnosis of possible underlying lesions (tumor...), but in typical cases, they are not necessary.
- **TREATMENT: splints in neutral position, physical therapy, NSAIDs** (and possibly local corticosteroid injection or local anesthetic block of the nerve) often suffice.
- Some lesions typically **recover spontaneously** (radial nerve compression)
- In patients with positive sensory symptoms – **neuropathic pain treatment**
- 48– **In severe cases surgical nerve release**



# CARPAL TUNNEL SYNDROME

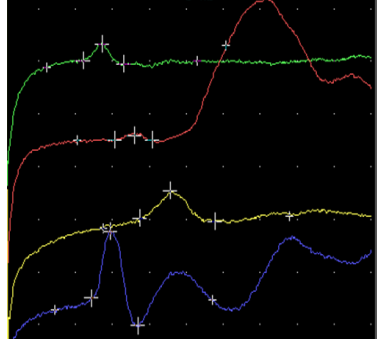
- by far the most common entrapment neuropathy
- lifetime prevalence about 3-5% of the general population
- Several predisposing factors had been identified (see next slide)
- entrapment occurs at wrist in the tunnel through which the median nerve and flexor digitorum tendons pass under the transverse carpal ligament (more frequent in tenosynovitis or arthritis in this area)
- Symptoms consist of nocturnal pain and paresthesias, most often confined to the thumb, index, and middle fingers.
- Patients complain of tingling numbness and burning sensations, often awakening them from sleep.
- Referred pain may radiate to the forearm and even to the shoulder.
- Symptoms are often worse after excessive use of the hand or wrist



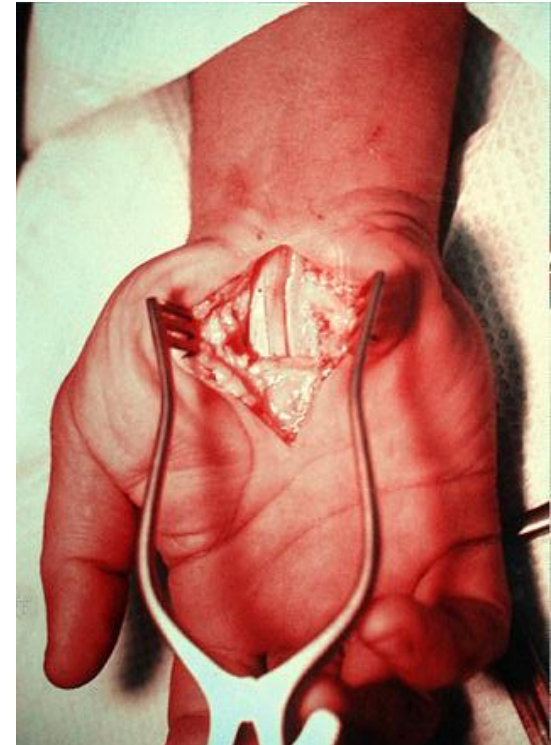
# CTS – PREDISPOSING FACTORS

- Diseases and conditions that have been found to **predispose to the development** of CTS include pregnancy, diabetes, obesity, age, rheumatoid arthritis, hypothyroidism, amyloidosis, gout, acromegaly, certain mucopolysaccharidoses, arteriovenous shunts for hemodialysis, old fractures at the wrist, and inflammatory diseases involving tendons or connective tissues at the wrist level.
- More frequent in **certain in work settings** (repetitive forceful grasping or pinching, awkward positions of the hand and wrist, direct pressure over the carpal tunnel, and the use of hand-held vibrating tools) – meat packers, butchers, dental hygienists...
- Also **a familial predisposition**.
- The syndrome is frequently **bilateral** and usually of greater intensity **in the dominant hand**.

# CARPAL TUNNEL SYNDROME

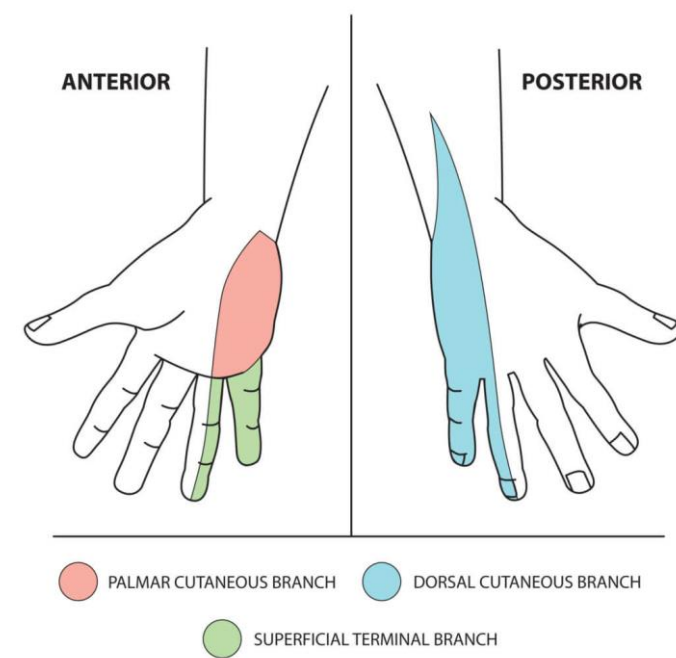


- objective **sensory changes** may be found in the distribution of median nerve
- **thenar** (abductor pollicis brevis muscle) **atrophy** may be present with prolonged entrapment
- **Tinel's sign** (percussion of the nerve at the wrist causes paresthesias in the distribution of the median nerve)
- **Phalen's maneuver** (flexing patient's hand at wrist for 1 min. reproduce the symptoms)
- **reversed Phalen's maneuver** (the same with the hyperextension of the wrist)
- **Diagnosis confirmed** by NCS/ EMG (mostly demyelinating for a long time from onset)
  
- In cases with **only mild sensory symptoms**, treatment with **splints in neutral position, NSAIDs** (and possibly local corticosteroid injection) often suffice.
- **Severe sensory loss** and thenar atrophy suggest the need for **surgical carpal tunnel release - fiberoptic techniques** are usually performed, with more than 90% of patients having prompt resolution of pain and paresthesias (open surgical sectioning of the volar carpal ligament is much less frequent).

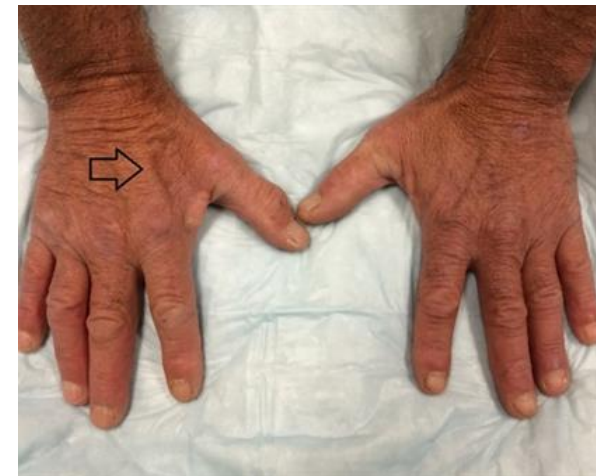

# ULNAR NERVE ENTRAPMENT

- the **second most common** compression mononeuropathy
- Causes: Compression of the nerve by a thickened fibrotic flexor carpi ulnaris aponeurosis at the entrance of the elbow's cubital tunnel, more frequent in **some occupations + following traumas**
- **External pressure to the nerve** (resting of the flexed elbow on a hard surface)
- Clinical picture: Prominent **atrophy of the first dorsal interosseous muscle, with clawing of the fourth and fifth fingers** (the result of lumbrical weakness, with secondary hyperextension of the metacarpophalangeal joints).
- **Sensory loss** or hypoesthesia involves the fifth finger, part of the fourth finger, and the hypothenar eminence and extends to the dorsum of the hand (but does not extend above the wrist).



Picture adopted from:  
<https://www.medicalexamprep.co.uk/uppe-r-limb-nerve-lesions-part-4-ulnar-nerve/>



# ULNAR NERVE ENTRAPMENT

- The sensory loss may be associated with paresthesias and pain
- A Tinel's sign at the elbow may be elicited
- The weakness of the flexor carpi ulnaris, flexor digitorum profundus of the IV. and V. fingers, and the intrinsic hand muscles. Grip strength is reduced. Weakness of the interossei muscles results in an inability to forcefully extend the interphalangeal joints. Abduction and adduction of the fingers becomes more difficult.
- NCS/EMG: Focal ulnar nerve slowing +/- conduction block in the elbow segment
- Mostly also the reduction in the ulnar CMAP amplitude and needle EMG changes – frequent axonal loss (present together with the demyelinating changes or even predominant)
- MRI of the elbow or US may reveal abnormal structures compressing the nerve and/or thickening of the nerve

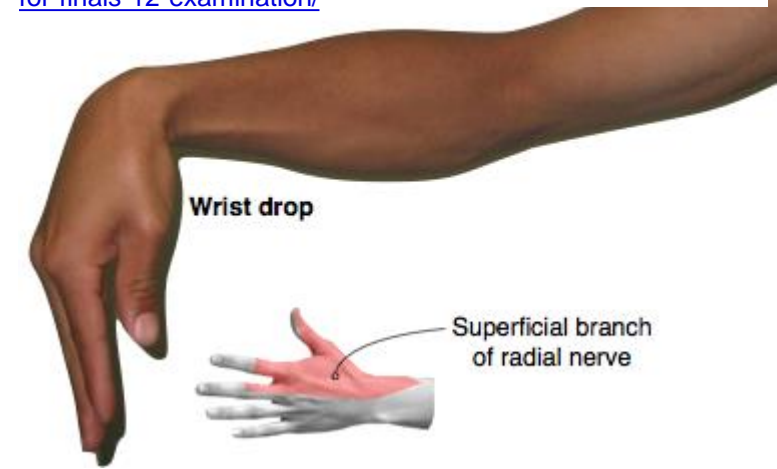

# ULNAR NERVE ENTRAPMENT

- Conservative treatment should be attempted in patients with mild symptoms - elbow protectors + avoidance of repetitive elbow flexion and extension or direct pressure on the elbow may alleviate the symptoms.
- Surgical approaches: include simple release of the flexor carpi ulnaris aponeurosis, anterior transposition of the nerve trunk, and resection of the medial epicondyle.
- Only approximately 60% of patients (especially those with symptoms of less than 1 year's duration), benefit from surgery and some experience worsening of symptoms.

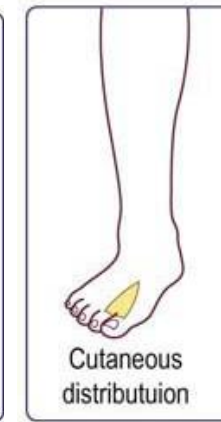
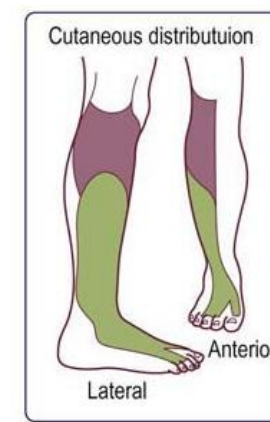
# RADIAL NERVE ENTRAPMENT

- compression in the axilla may result from crutches or from the weight of a sleeping partner's head (honeymoon palsy)
- weakness of the triceps brachii, brachioradialis, supinator, and extensor muscles of the wrist and fingers
- compression at the spiral groove of the humerus (midupper arm) during drunken sleep wherein the arm is draped over a chair (Saturdaynight palsy)
  - the triceps brachii is spared, resulting in weakness confined to the brachioradialis, wrist, and finger extensors = wrist drop
- Hypoesthesia over the dorsum of hand, thumb, index finger, and middle finger in both
- Compressive radial nerve lesions caused by pressure lead to a conduction block in NCS/EMG and usually improve in 6 to 8 weeks.
- must be differentiated from radial nerve injury caused by fractures of the humerus, because the prognosis for recovery is poorer in the latter case (due to axonopathy)



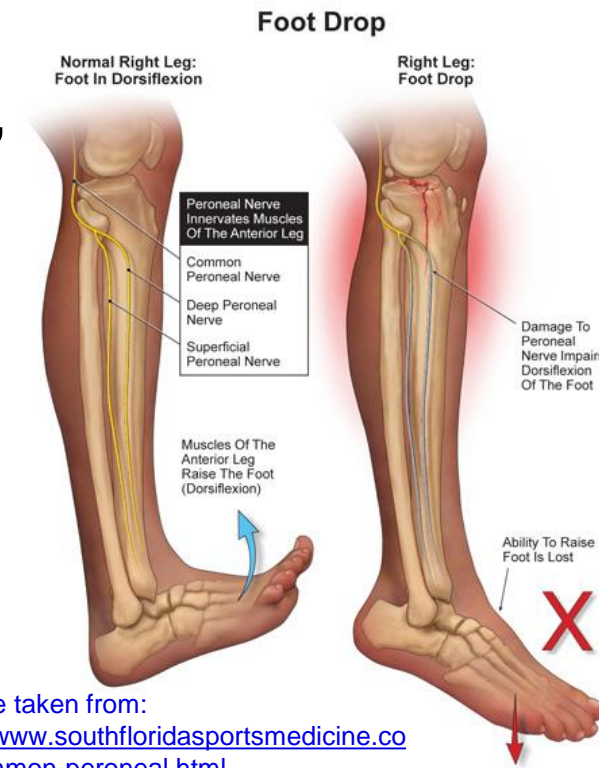
# COMMON FIBULAR (PERONEAL) NERVE ENTRAPMENT

- the most frequent entrapment neuropathy in the leg
- Nerve is vulnerable in the **region of the fibular neck** as it passes through the origin of the fibularis (peroneus) longus muscle. Near this opening, the nerve **divides into two main terminal divisions: the superficial and deep fibular** nerves
- lesion leads to weakness of foot and toe extension and foot eversion, **and steppage gait.**
- **Sensory impairment** is found over the lateral aspect of the lower leg and the dorsum of the foot.
- Caused by a **direct pressure to the fibular head area** (long taking squatting or kneeling position, habitual leg crossing, improperly applied plaster casts or unrecognized pressure on the nerve in debilitated or unconscious patients)



Picture taken from: <https://clinicalgate.com/peroneal-neuropathy/>

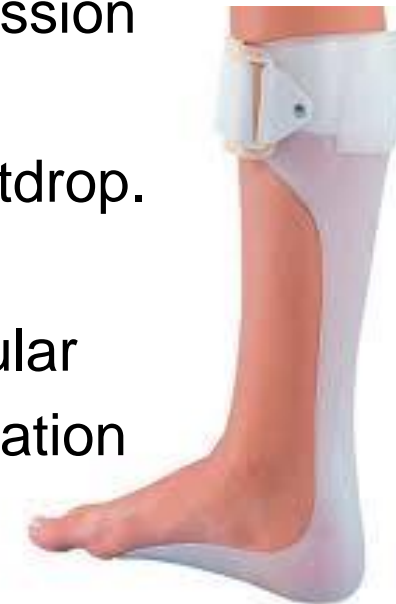- Lateral cutaneous nerve of the knee (a branch of the common peroneal nerve)
- Superficial peroneal
- Deep peroneal



Picture taken from: <http://www.southfloridasportsmedicine.com/common-peroneal.html>

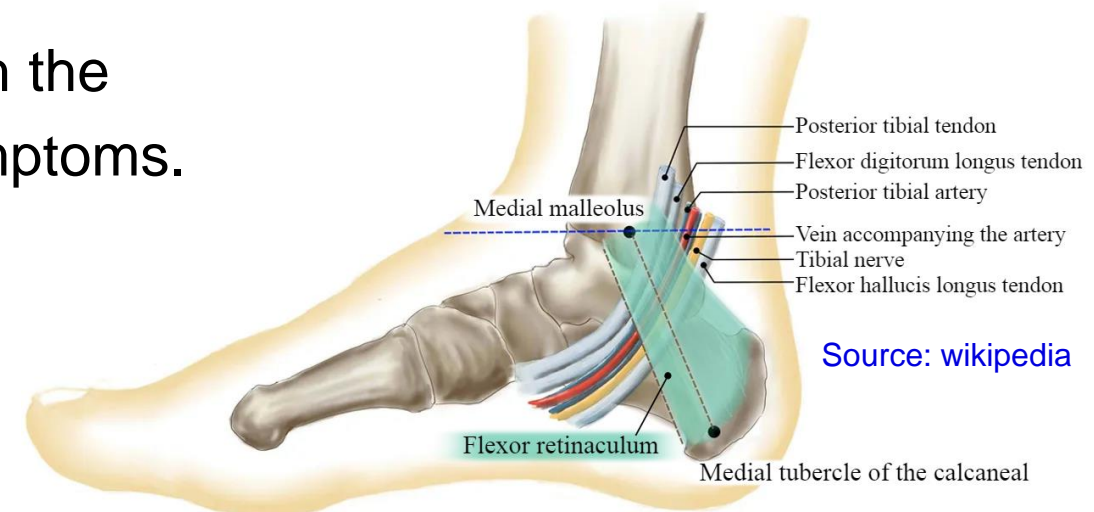
# COMMON FIBULAR (PERONEAL) NERVE ENTRAPMENT

- NCS/EMG: frequently focal **conduction block or localized conduction slowing** in the region of the fibular head (suggesting **demyelinating** process)
- the most frequent pathophysiological process is **axonal loss** regardless of the cause.
- EMG demonstrates the **denervation potentials** in anterior (or anterolateral) calf muscles
- The prognosis is **uniformly good** in cases of acute compression
- bracing with a custom-made plastic **ankle-foot orthosis** is necessary to improve the gait in the presence of severe footdrop.
- The few patients who do not improve spontaneously after 3 months, or those who have pain or a slowly progressive fibular nerve lesion, may require **MRI studies and surgical** exploration



# POSTERIOR TIBIAL NERVE ENTRAPMENT (TARSAL TUNNEL SYNDROME)

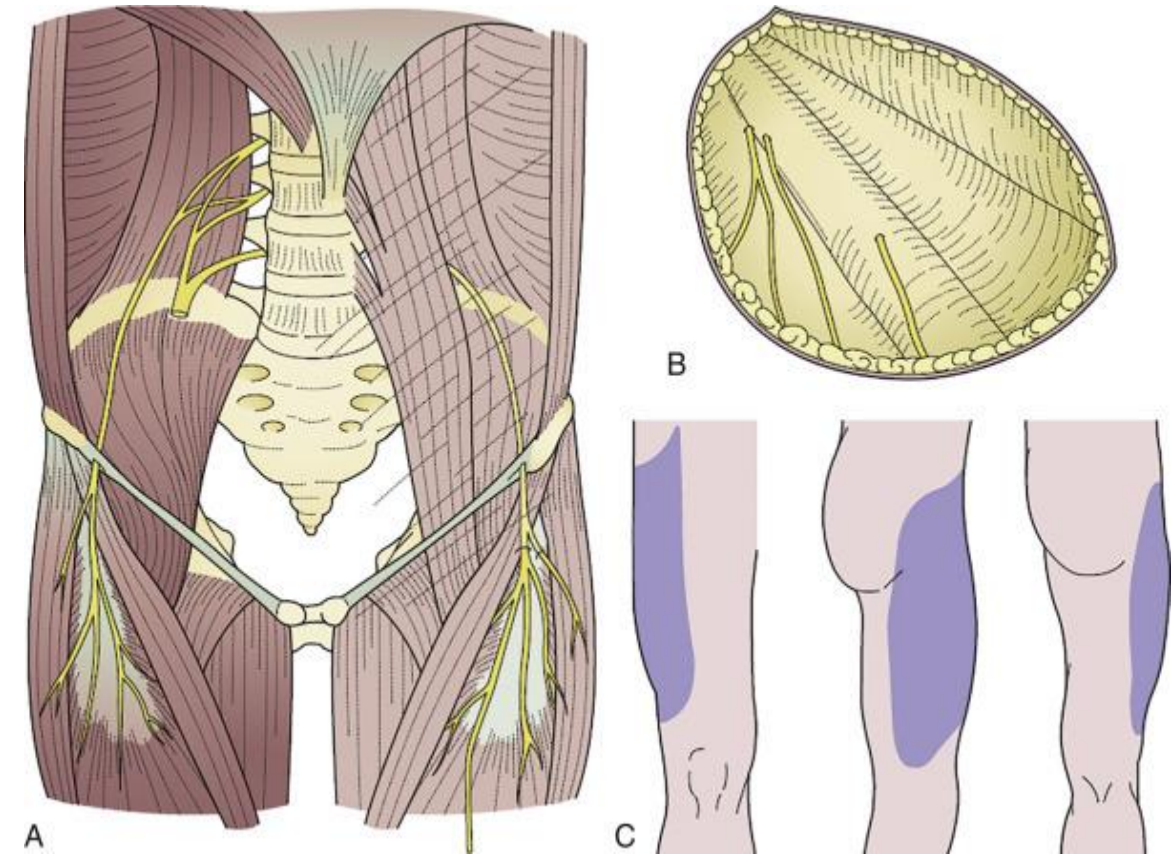
- occurs behind and immediately below the medial malleolus (in tarsal tunnel).
- Burning pain occurs in the toes and the sole of the foot
- Examination usually reveals plantar sensory impairment and wasting of the intrinsic foot muscles + positive Tinel's sign
- Confirmed by NCS/EMG (which also excludes other possible cases – e.g. polyneuropathy)
- Local injection with corticosteroids underneath the laciniated ligament may temporarily relieve the symptoms.
- Surgical decompression is mostly needed for permanent results.





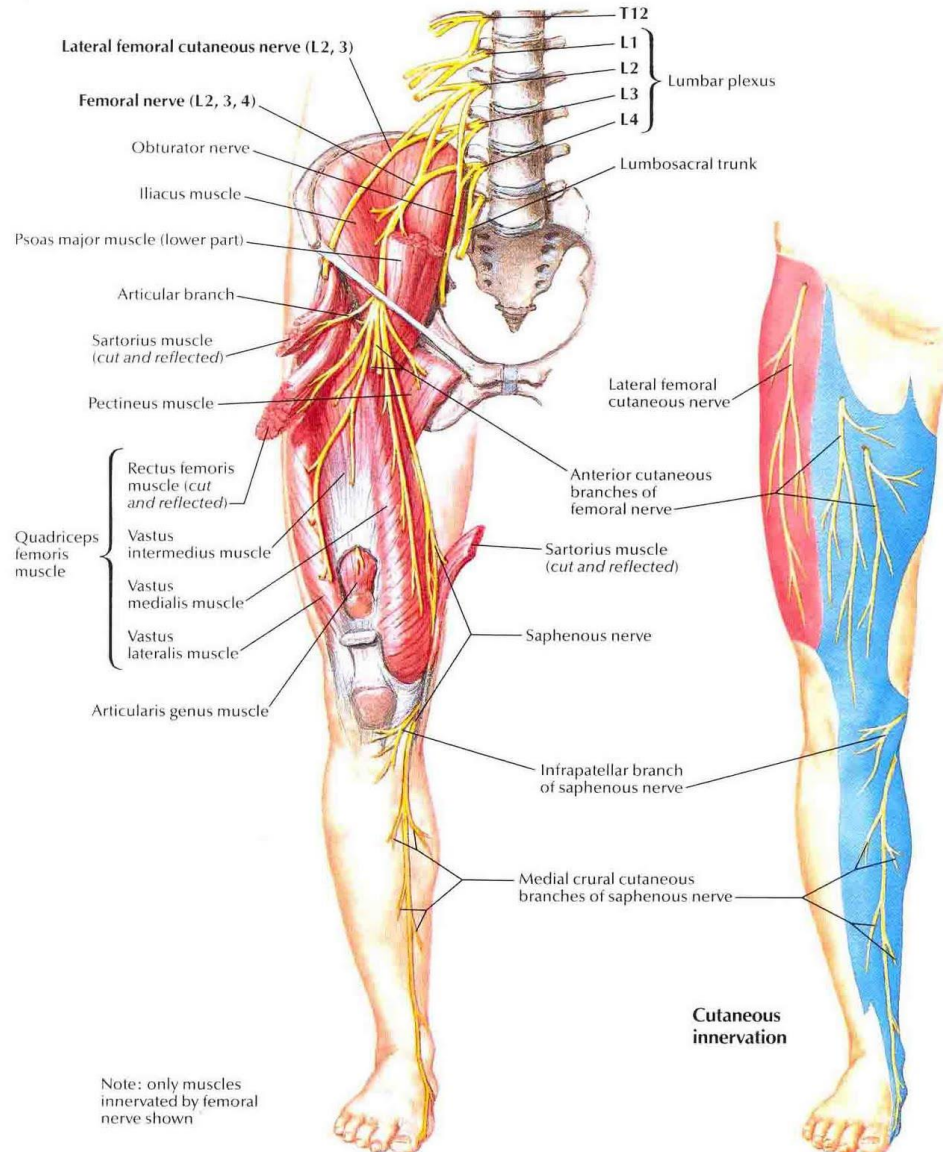
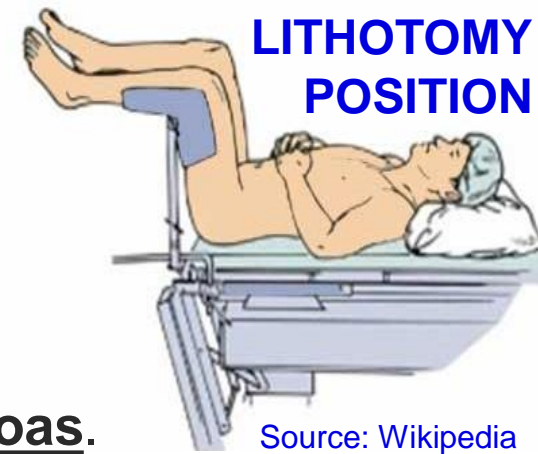# LATERAL FEMORAL CUTANEOUS NERVE ENTRAPMENT (MERALGIA PARESTHETICA)

- pure sensory nerve
- passes medial to the anterior superior iliac spine under the inguinal ligament (usual site of entrapment) to enter the thigh under the fascia lata that it penetrates to supply the skin of the anterolateral part of the thigh.
- association with obesity, pregnancy, ascites...
- patients develop numbness, painful burning, and itching over the anterolateral thigh.
- Treatment consists of rest, analgesics (against neuropathic pain), and weight loss. Neurolysis is rarely beneficial.



Picture taken from: <https://www.sciencedirect.com/topics/medicine-and-dentistry/meralgia-paraesthetica>

# FEMORAL NERVE LESIONS



- The lesion leads to the weakness of m. quadriceps femoris and m. iliopsoas.
- Patients complain of difficulty in walking and of knee buckling (, depending on the severity of injury.
- There is also a numbness and/or positive sensory symptoms in anterior aspect of the thigh and anteromedial aspect of the calf.
- Causes: Sometimes seen as a complication of hip arthroplasty or other procedures performed in lithotomy position, or after direct trauma or in diabetic patients...
- Prognosis (with the exception of total transections) is quite good with almost complete recovery

# OTHER CAUSES OF PERIPHERAL MONONEUROPATHIES/RADICULO-/PLEXOPATHIES

- **Much less frequent** comparing with entrapment
- **Direct traumatic nerve injury** (exclude from history and clinical examination) – the prognosis depends on the extent of trauma and nerve continuity – loss of continuity prevents from recovery
- **Vasculitis** (very rare, consider particularly in multiple mononeuropathy with very acute development and in patients with other symptoms/signs of autoimmune disease. Nerve biopsy may be necessary to confirm the diagnosis).
- **Infectious diseases**
  - Neuroborreliosis – frequently presents with radiculo/neuropathy (Banwarth syndrome - lymphocytic meningoradiculitis) – often facial nerve or nerve roots
  - Leprosy
  - Herpes zoster (radiculitis) – may result in postherpetic neuralgia

# MAIN SOURCES OF INFORMATION

- Harati Y, Bosch PE. CHAPTER 80 – Disorders of Peripheral Nerves. In Bradley WG, Daroff RB, Fenichel GM, Jankovic J. Neurology in Clinical Practice, 5th ed. London: Elsevier 2008.
- <https://www.lecturio.com/magazine/polyneuropathies>
- <https://neuromuscular.wustl.edu/>

**THANKS FOR YOUR ATTENTION 😊**