

GLAUCOMA

Part 1: glaucoma essentials

GLAUCOMA ESSENTIALS

- **Glaucoma \neq elevated IOP!!**
- **BUT**, glaucoma is usually associated with high IOP (x normal tension glaucoma)
- Late symptoms onset
- Affects 60.5 million people worldwide

GLAUCOMA ESSENTIALS

- accounts for 8% of all cases of blindness and is **the leading cause of irreversible blindness worldwide**
- Early detection is essential



Normal Vision



Early Glaucoma

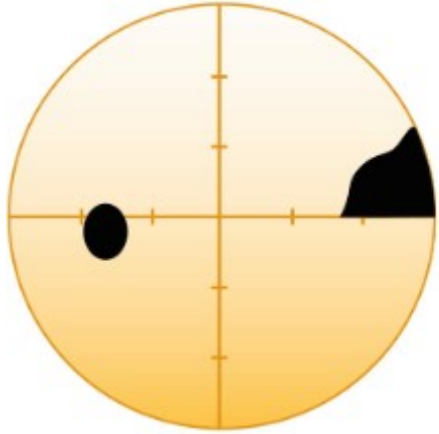


Advanced Glaucoma

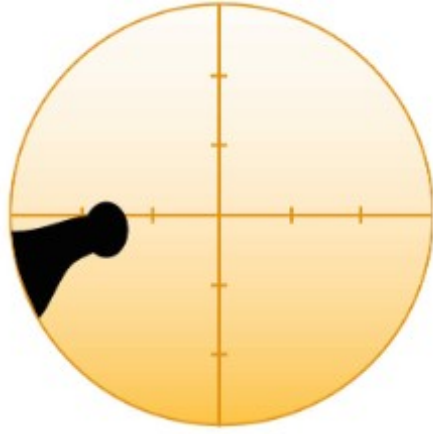

End Stage Glaucoma

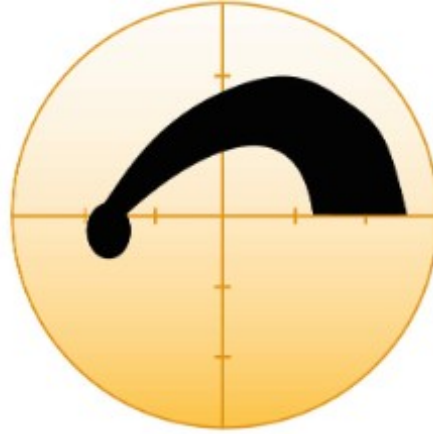GLAUCOMA ESSENTIALS (OS)



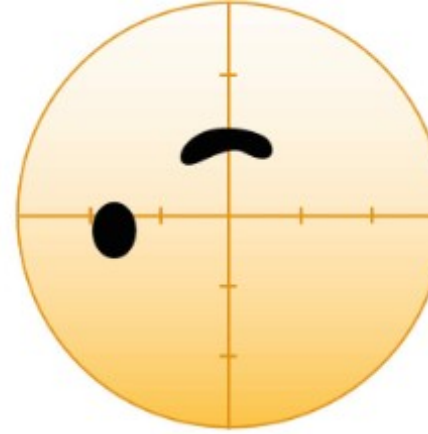
(a) nasal step



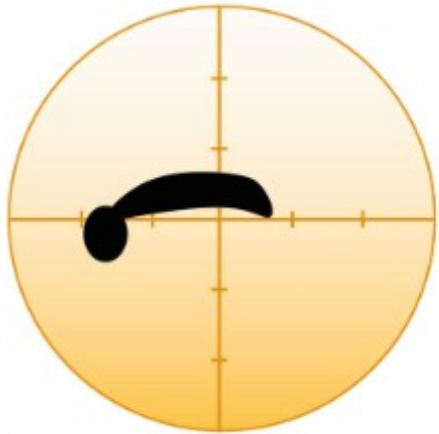(b) temporal wedge



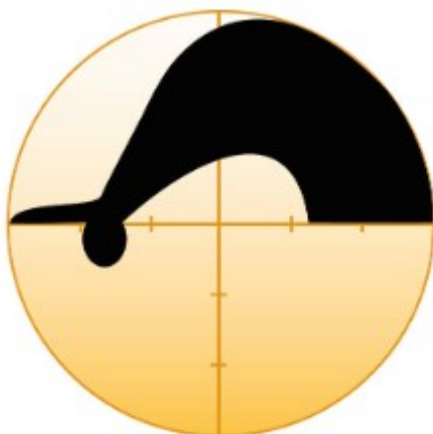(c) established superior arcuate defect




(d) early superior paracentral defect at 10°



(e) superior, fixation-threatening paracentral defect



(f) superior arcuate with peripheral breakthrough and early inferior defect



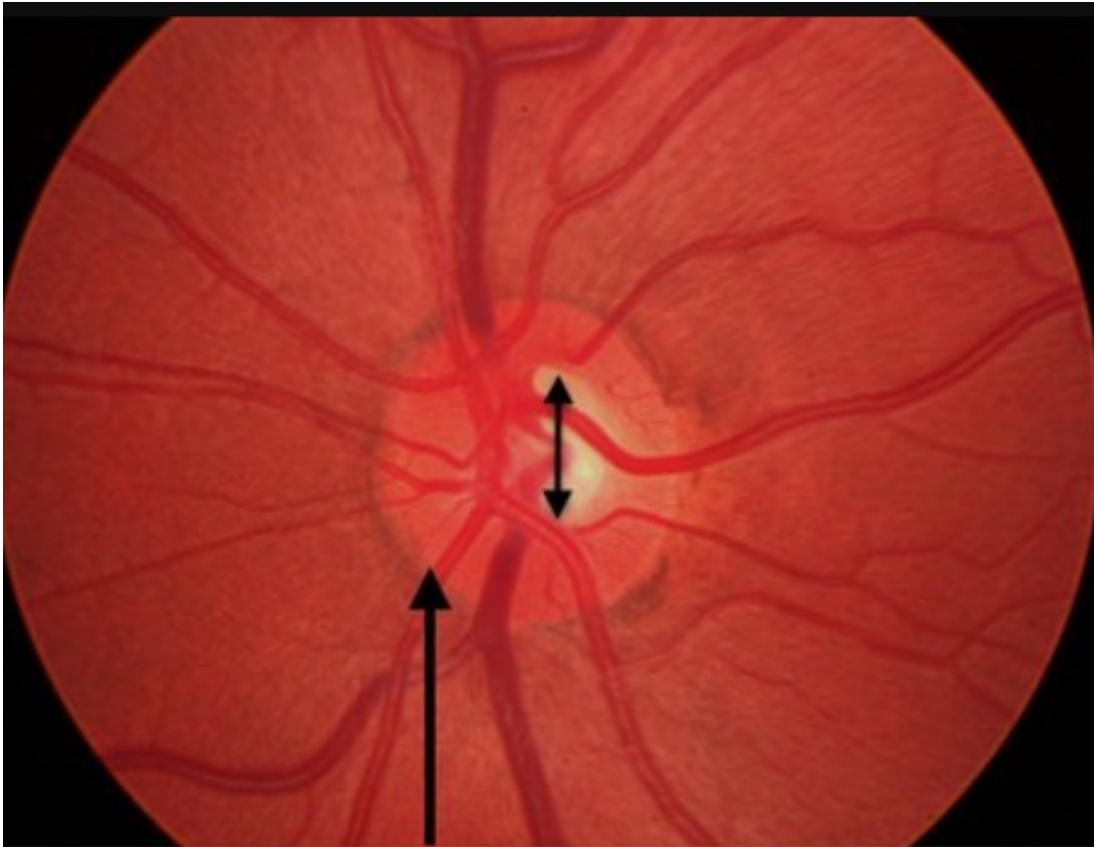
(g) tunnel vision defect with temporal crescent sparing



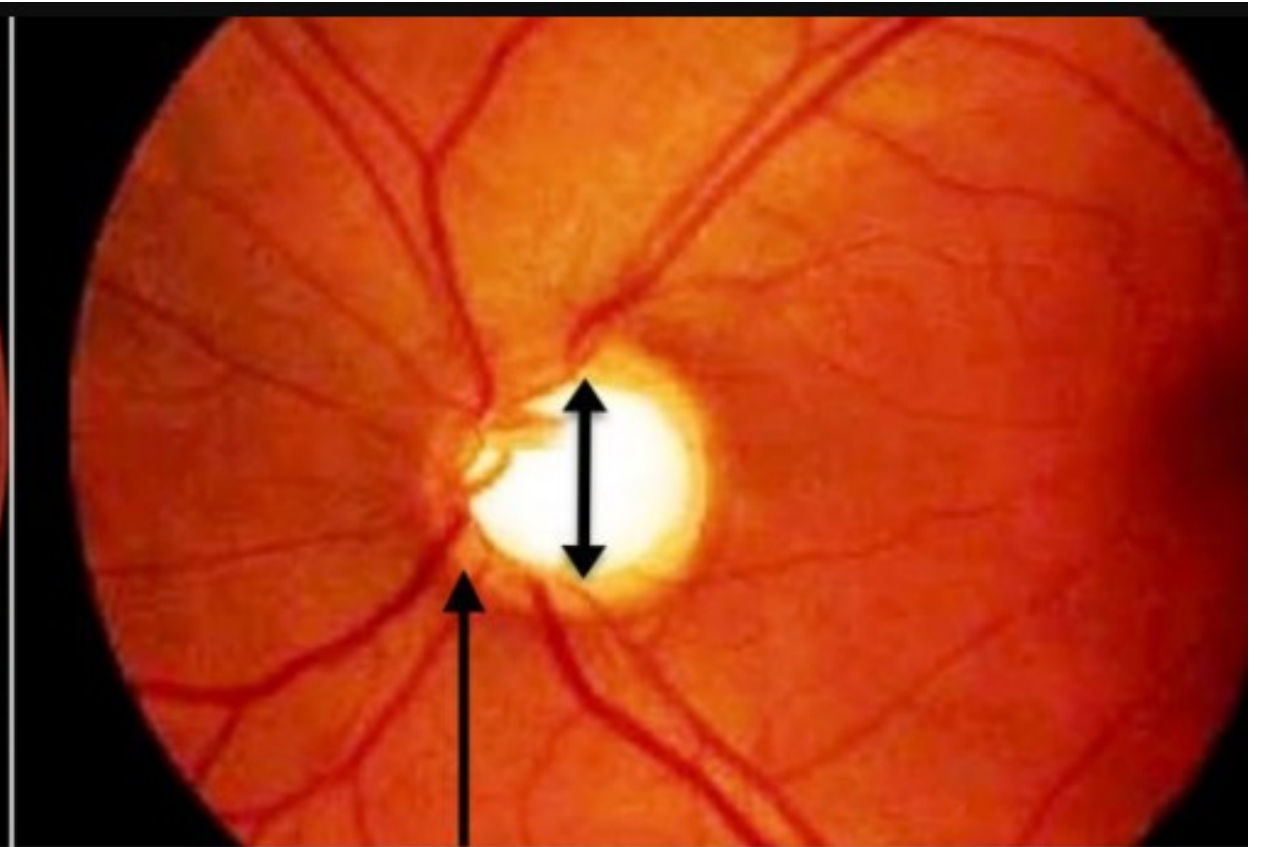
(h) end stage, complete field loss

GLAUCOMA ESSENTIALS

- Optic nerve damage.



Normal optic nerve head



Glaucomatous cupping

GLAUCOMA ESSENTIALS

Part 2: definition, anatomy, patophysiology

Definition

- a group of diseases defined by a characteristic **irreversible optic neuropathy**
 - remodeling of the connective tissue elements of the optic nerve head
 - loss of neural tissue (ganglion cells)
 - associated with the eventual development of visual dysfunction.
- intraocular pressure (IOP) level is one of the primary risk factors for development of glaucoma, **BUT does not have a role in the definition of the disease**
- **Glaucoma ≠ elevated IOP!!**

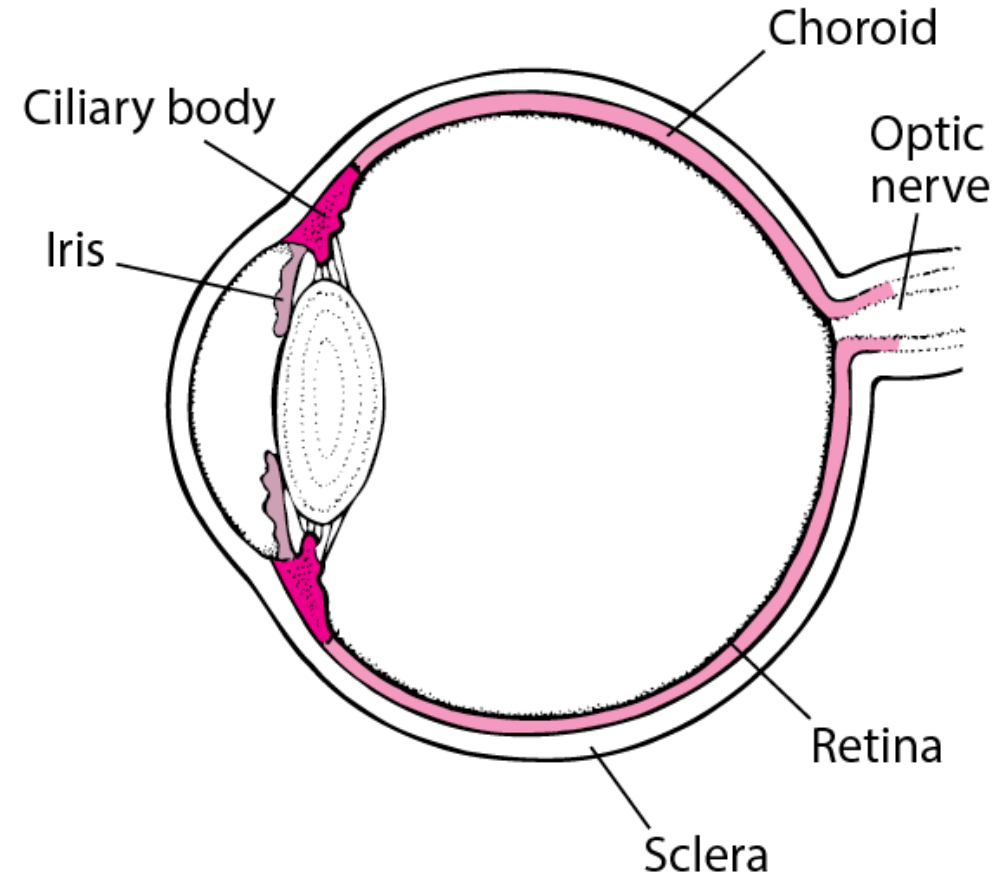
Glaucoma is not fully understood

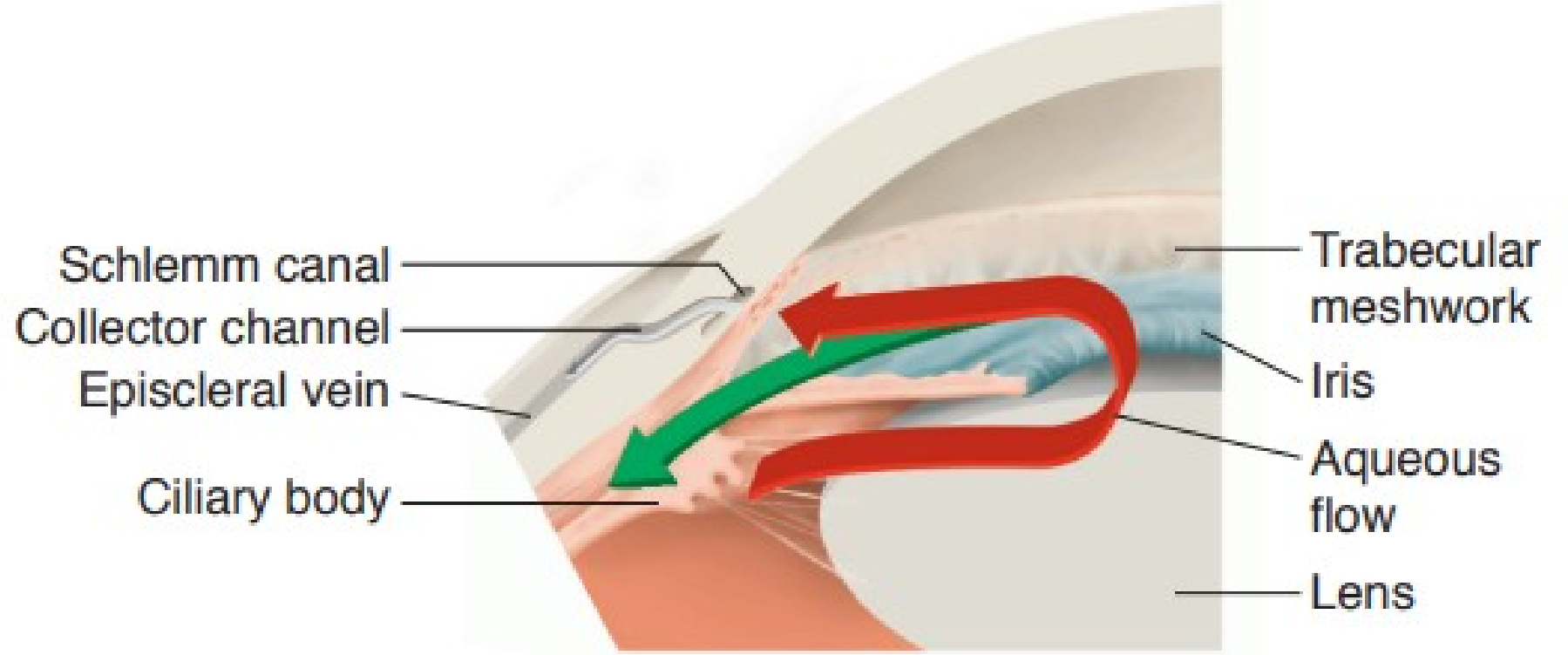
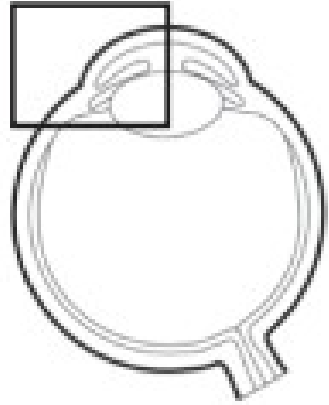
Susceptibility to glaucoma

- determined by the **resilience of the optic nerve** to the multiple pathogenic mechanisms involved in the neuropathy
- progressive injury **may occur at low IOP levels whereas in other cases with higher pressures, injury never occurs.**
 - the optic nerve may continue to be damaged despite decreasing the IOP

Aqueous Humor Dynamics

- aqueous humor composition:
 - is **protein free** (optical clarity)
- production: **ciliary body** - 80 ciliary processes, rich supply of fenestrated capillaries
- 3.6 ml per day





Normal Aqueous Flow

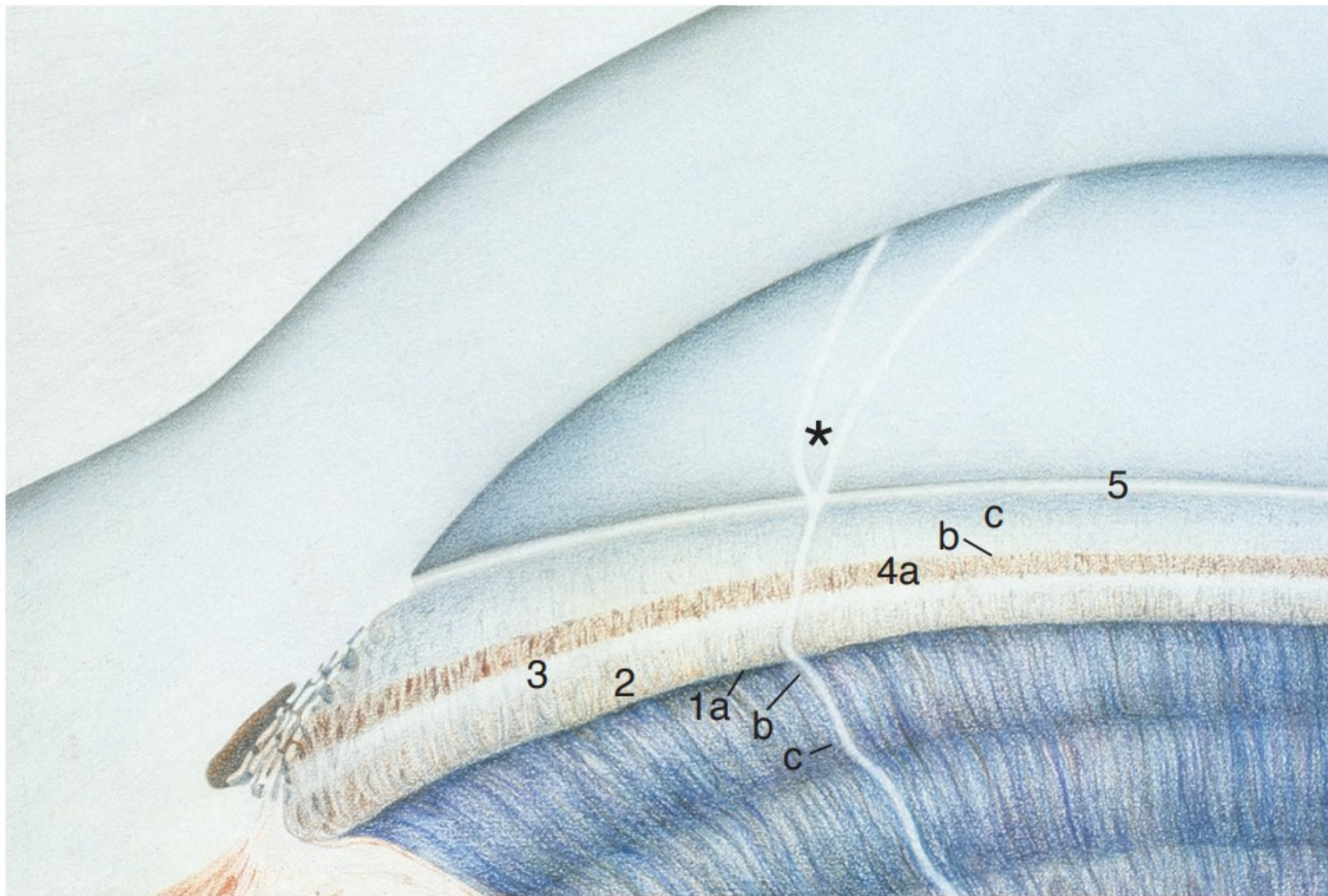


Figure 3-1 Gonioscopic appearance of a normal anterior chamber angle. 1, Peripheral iris: *a*, insertion; *b*, curvature; *c*, angular approach. 2, Ciliary body band. 3, Scleral spur. 4, Trabecular meshwork: *a*, posterior; *b*, mid; *c*, anterior. 5, Schwalbe line. *Asterisk*, Corneal optical wedge.

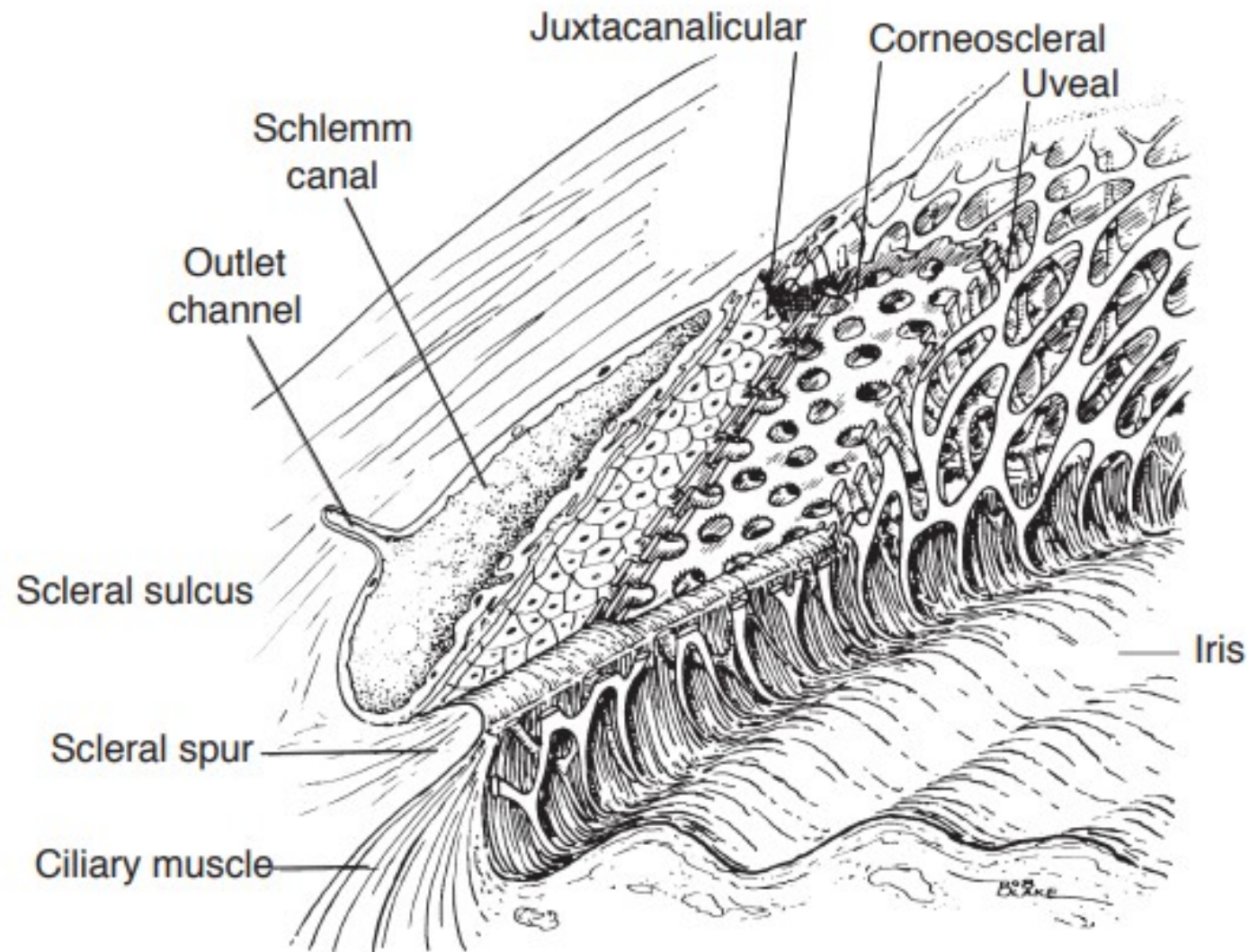
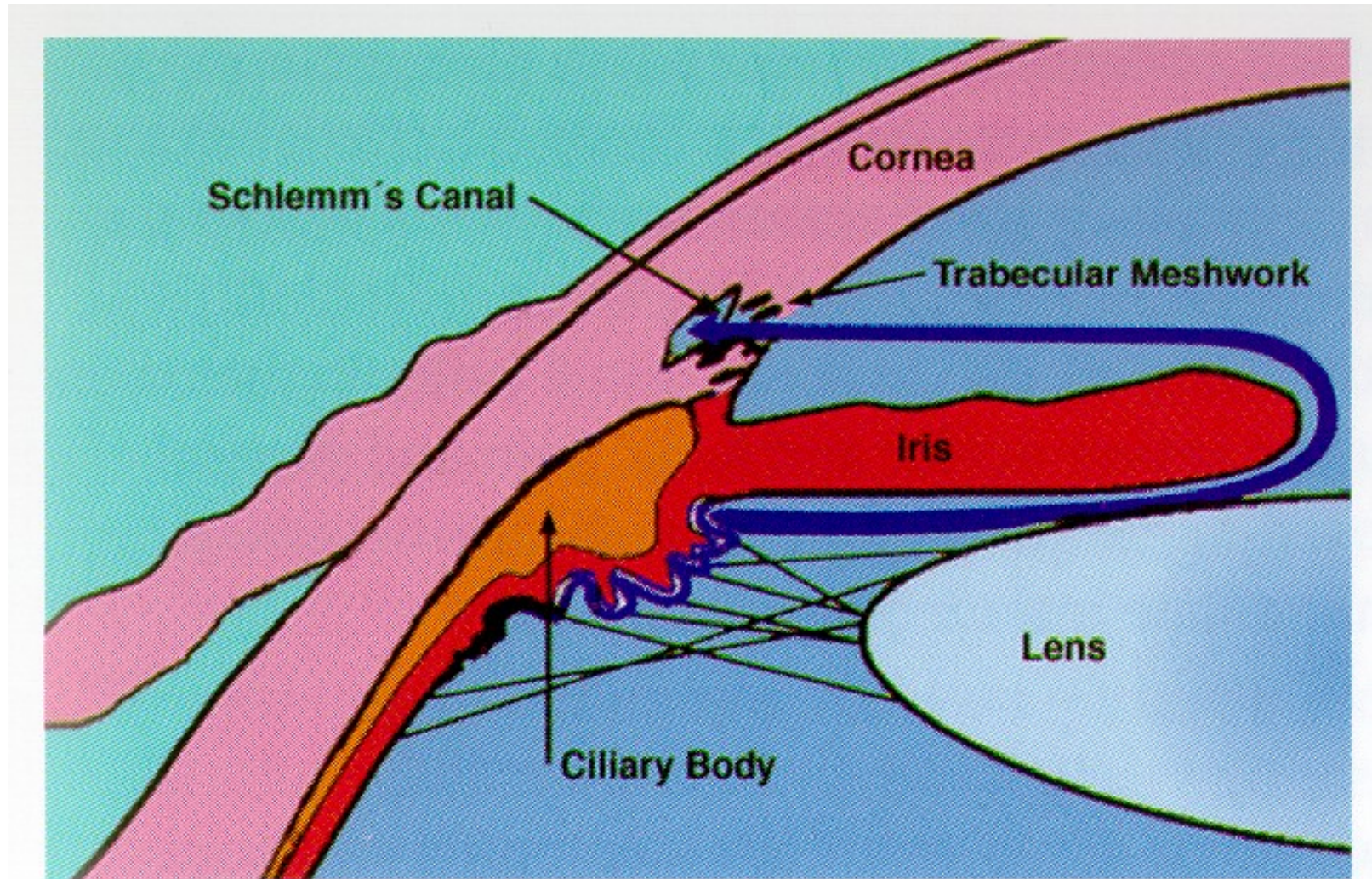


Figure 2-3 Three layers of the trabecular meshwork (shown in cutaway views): uveal, corneoscleral, and juxtacanalicular. (Modified with permission from Shields MB. Textbook of Glaucoma. 3rd ed. Baltimore: Williams & Wilkins; 1992.)

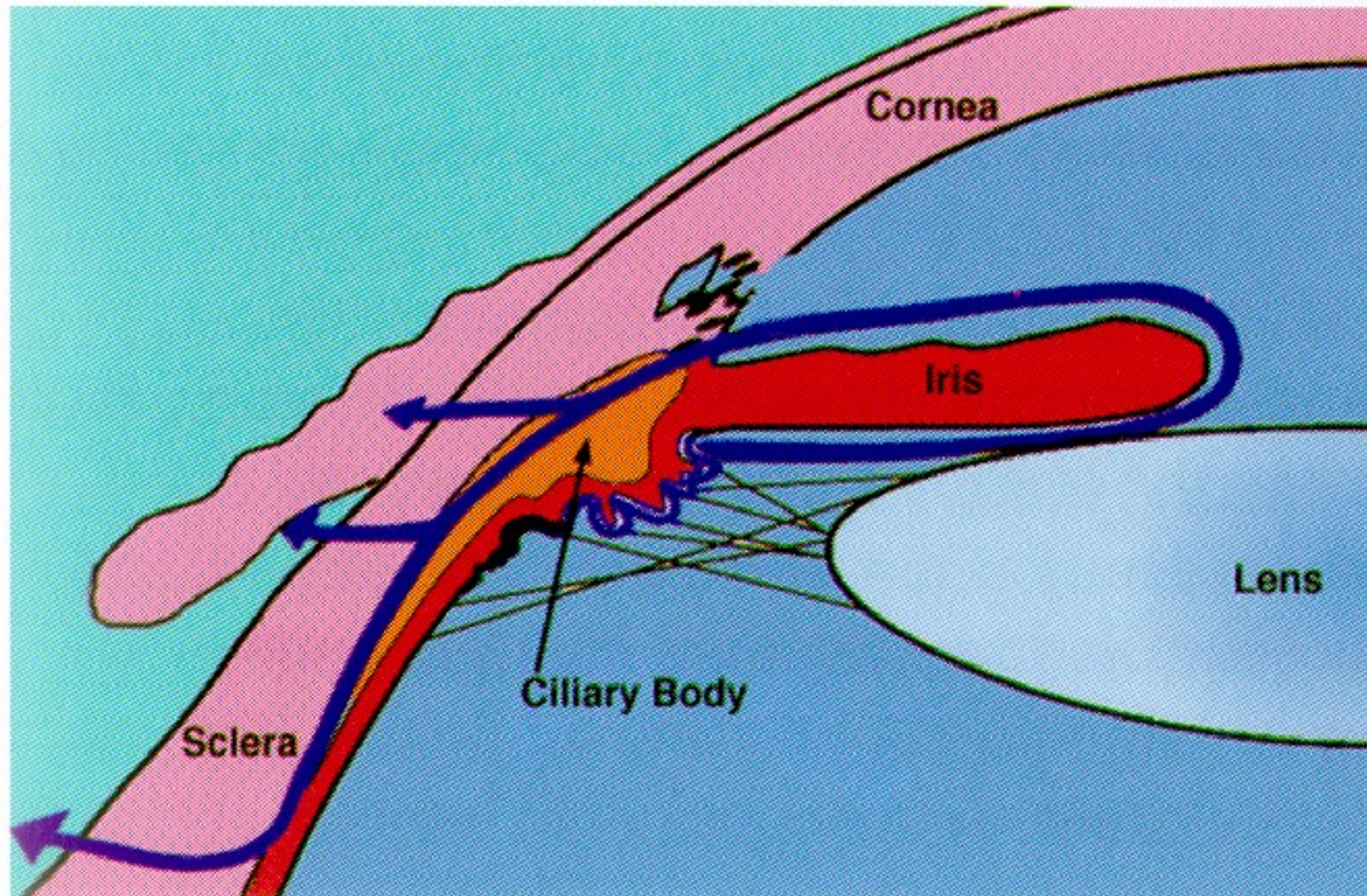
Aqueous Humor Dynamics

- Trabecular Outflow
 - pressure-sensitive outflow and functions as a one-way valve
- Uveoscleral Outflow
 - **up to 45%** of total aqueous outflow.
 - pressure-insensitive outflow
 - aqueous passage **from the anterior chamber into the ciliary muscle and then into the supraciliary and suprachoroidal spaces**
 - decreases with age and is reduced in patients with glaucoma
 - increased by cycloplegia, adrenergic agents, and prostaglandin analogues but decreased by miotics

Trabecular outflow



Uveoscleral outflow



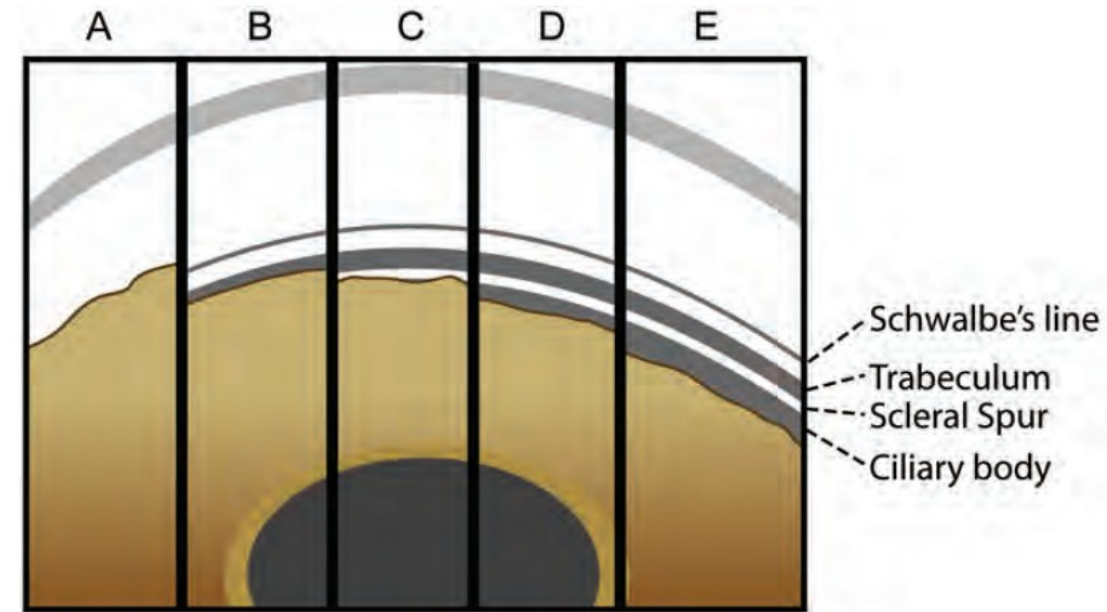
Part 3: Classification

Glaucoma classification

- Main classification
 - Open angle glaucoma
 - Angle closure gl.
 - Childhood gl.
- By cause
 - Primary, secondary
- By time
 - Acute
 - Chronic
 - Intermittent

Open angle gl.

- Primary (more common)
 - POAG – primary open angle gl.
 - NTG – normal-tension gl.
 - JOAG – juvenile open angle gl.
 - OHT – ocular hypertension
 - Glaucoma suspect
- Secondary
 - Pigmentary, pseudoexfoliation, uveitic...



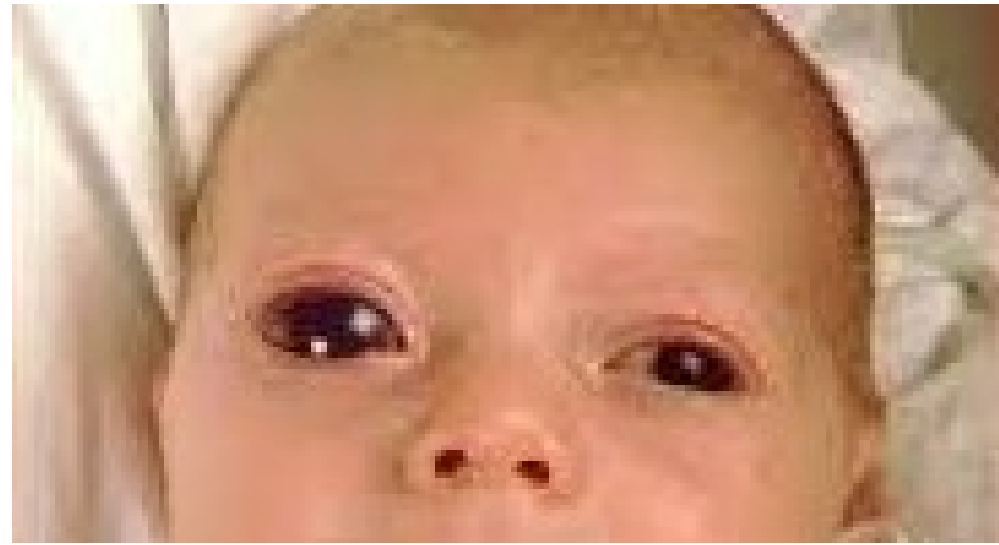Angle closure gl.



- Primary
 - **PACS** – primary angle closure suspect - narrow angle no nerve damage
 - **PAC** – primary angle closure - narrow angle, elevated IOP, no nerve damage
 - **PACG** – primary angle closure glaucoma - elevated IOP, nerve damage
 - **Primary angle closure without pupillary block** (plateau iris)
 - **Chronic angle closure** (angle permanently closed by PAS)
- Secondary
 - **With pupillary block**
 - Other mechanism than anatomical configuration (intumescent lens, secluded pupil..)
 - **Without pupillary block**
 - Pushing forward (choroideal tumor)
 - Pulling forward (NV glaucoma)

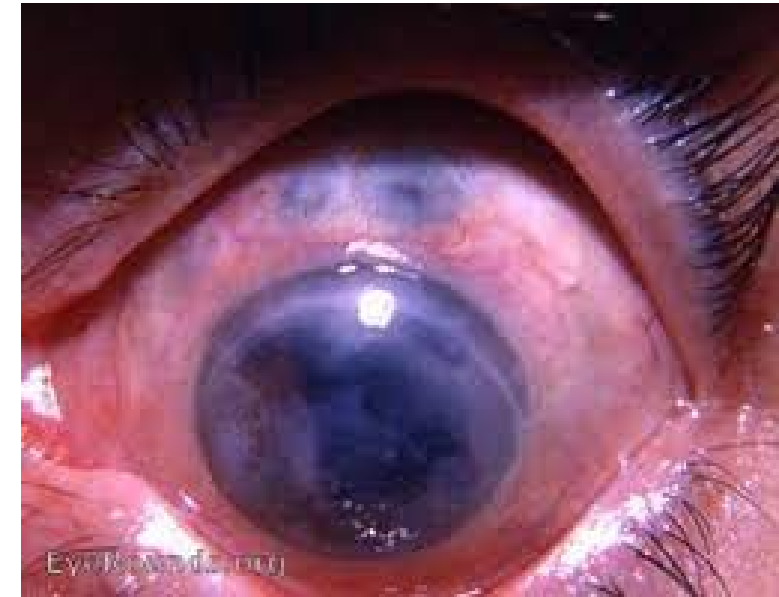Childhood gl.

- PCG
 - presents within the first few years of life
- Glaucoma associated with congenital anomalies
 - Associated with local (aniridia) or systemic (neurofibromatosis..) disorders
- Secondary glaucoma in infants and children
 - Inflammation, retinoblastoma, trauma..



Terminology: absolute glaucoma

- Any type of glaucoma at its terminal phase – practical or total blindness
- Main goal of therapy = **pain elimination**
 - Cyclocryo/photocoagulation
 - Retrobulbar alcohol application – sensitive innervation block
 - Enucleation



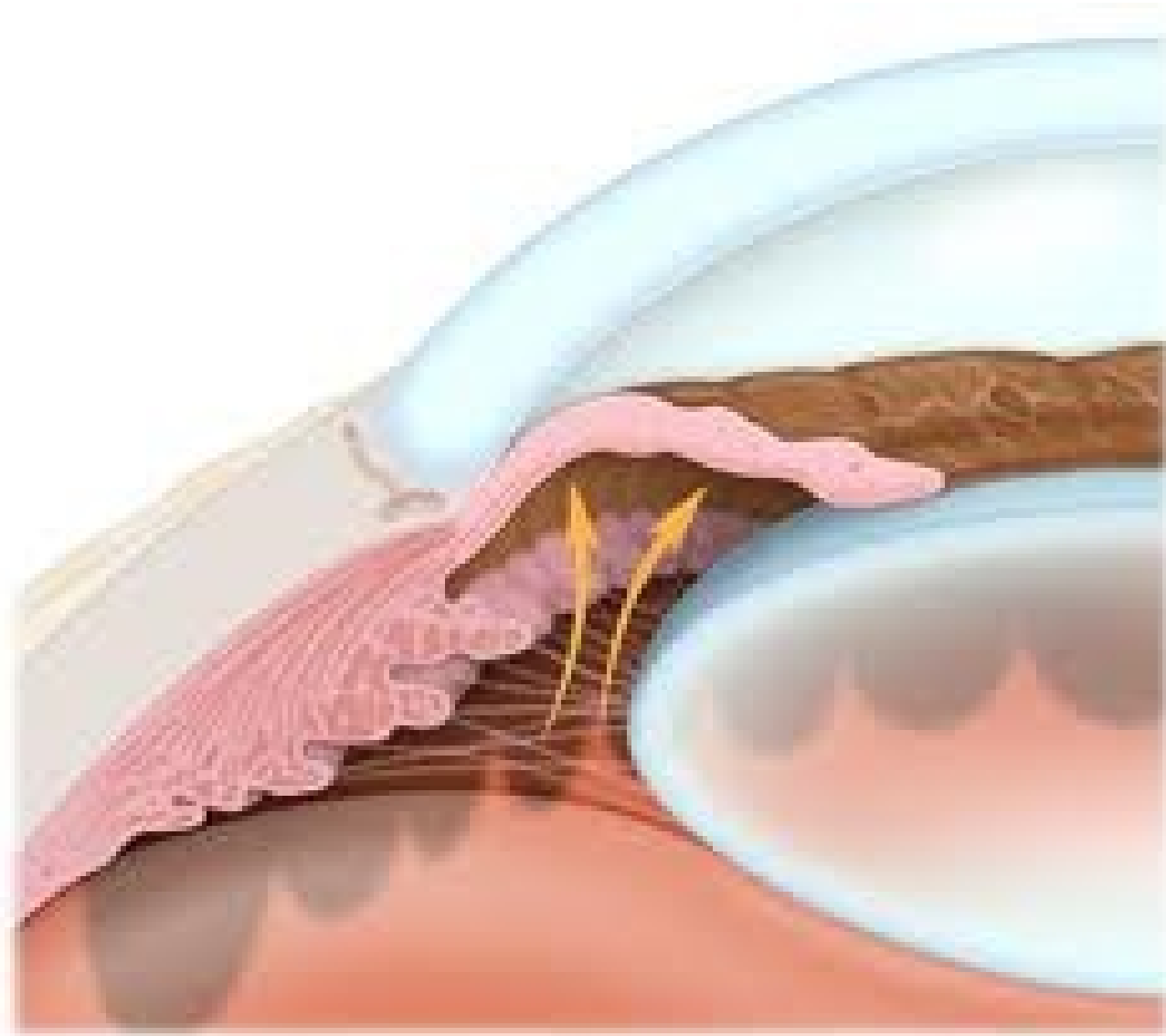
Part 4: Emergency cases: acute angle closure + malignant glaucoma

ACUTE ANGLE CLOSURE

Pupillary block

- the most common mechanism leading to **acute angle-closure** (glaucoma)
 - the flow of aqueous humor from the posterior chamber to the anterior chamber is. **obstructed by a functional block between the pupillary portion of the iris and the lens**
 - **Iris root is then pushed against trabecular meshwork**
- Risk factors:
 - Narrow angle, hypermetropia, age related lens swelling (cataract)
 - Mydriasis
 - Nighttime (less light)
 - Emotions

Pupillary block



Pupillary block

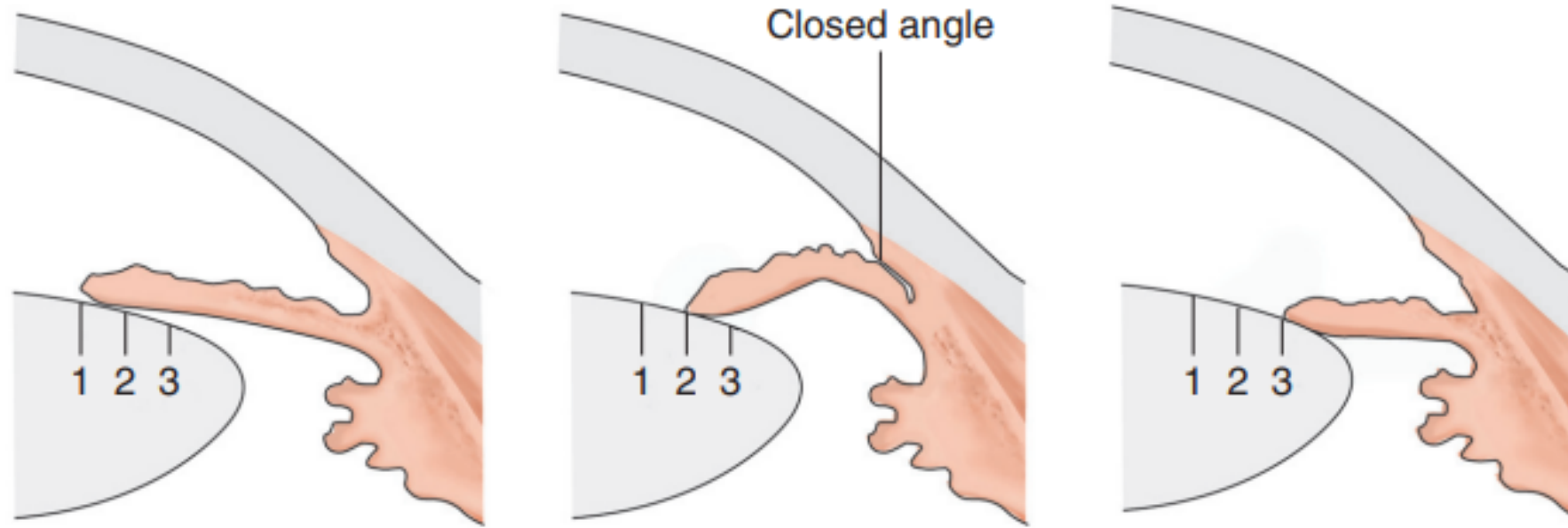
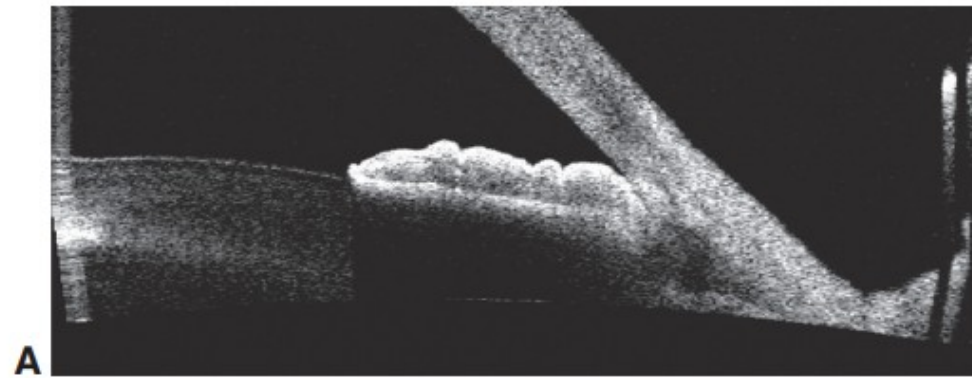
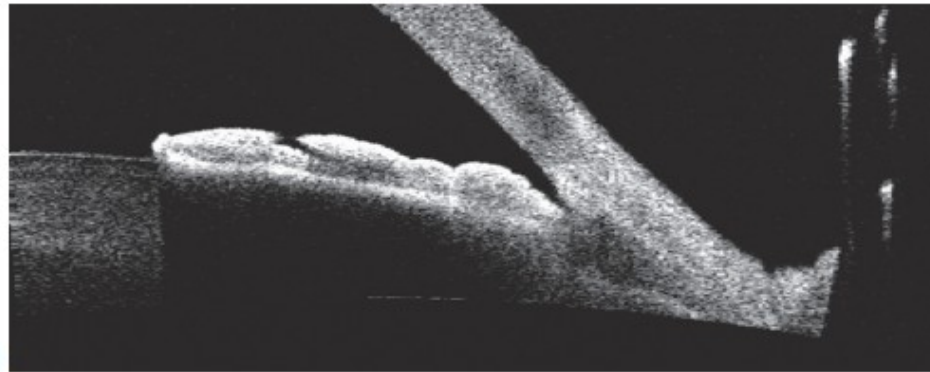


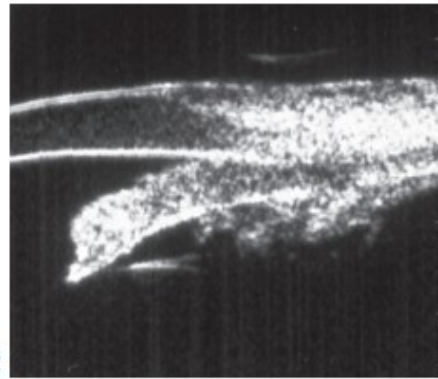
Figure 1-1 1, The pupil is constricted and the angle is open. 2, The pupil is in the mid-dilated position. Pupillary block is maximal in this position and, as a result, the iris is bowed anteriorly and the angle narrows. 3, The pupil is completely dilated, and pupillary block is diminished, with a return to a flatter iris configuration. If full-blown angle closure occurs, the iris may stay in the mid-dilated position until the angle-closure attack is broken. (Illustration by Cyndie C. H. Wooley.)



A



B

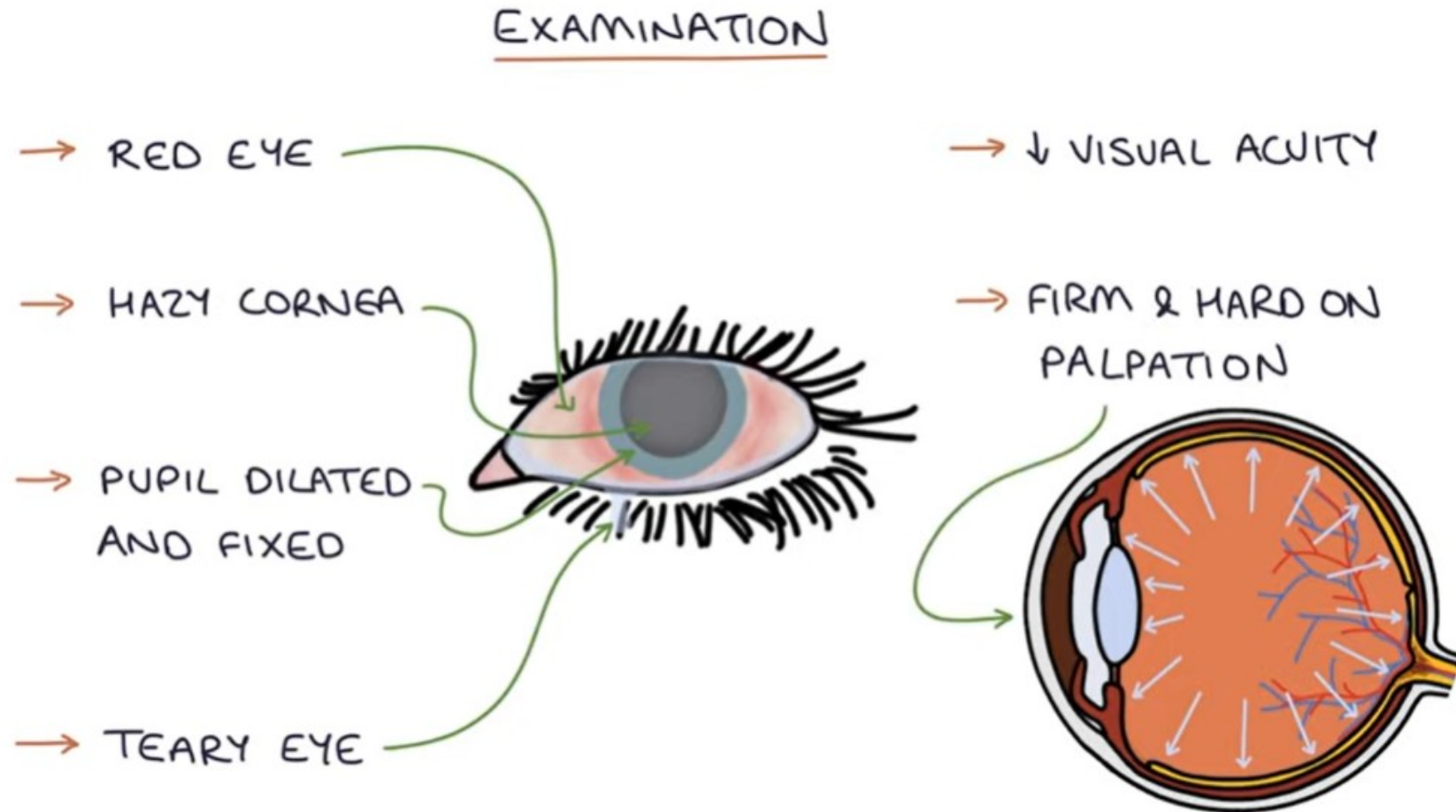


C

Figure 5-1 Ultrasound biomicroscopy (UBM) of a narrow angle. **A**, Angle closure is evident when the angle is imaged with lights off. **B**, The same angle is much more open when it is imaged with lights on. **C**, UBM of a narrow angle due to plateau iris. (Parts A and B courtesy of Yaniv Barkana, MD; part C courtesy of Wallace L. M. Alward, MD.)

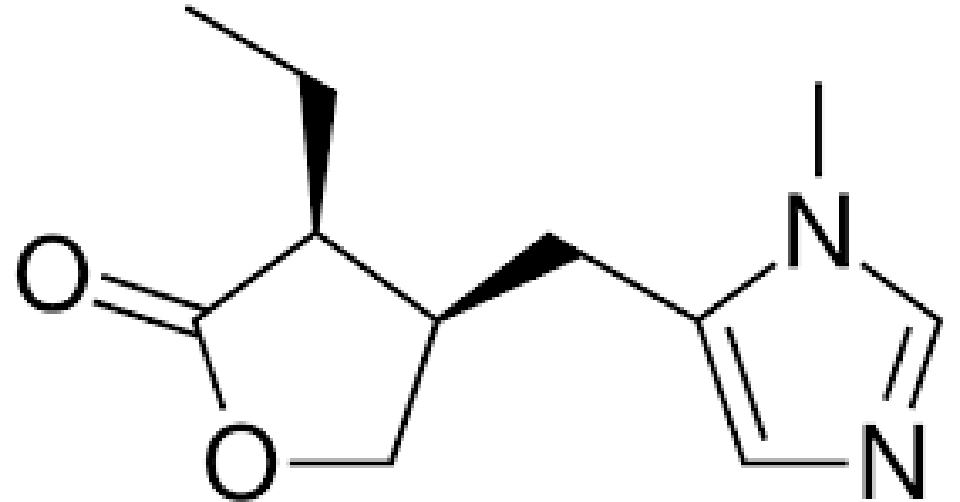
Acute angle closure - signs

- Unilateral (usually)
- IOP (usually) over 60 mmHg



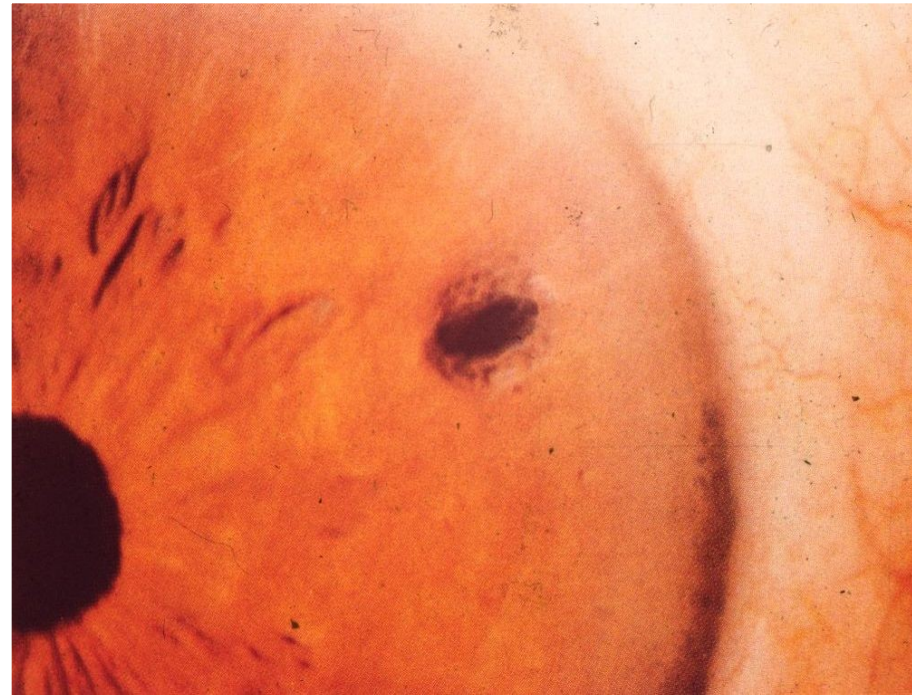
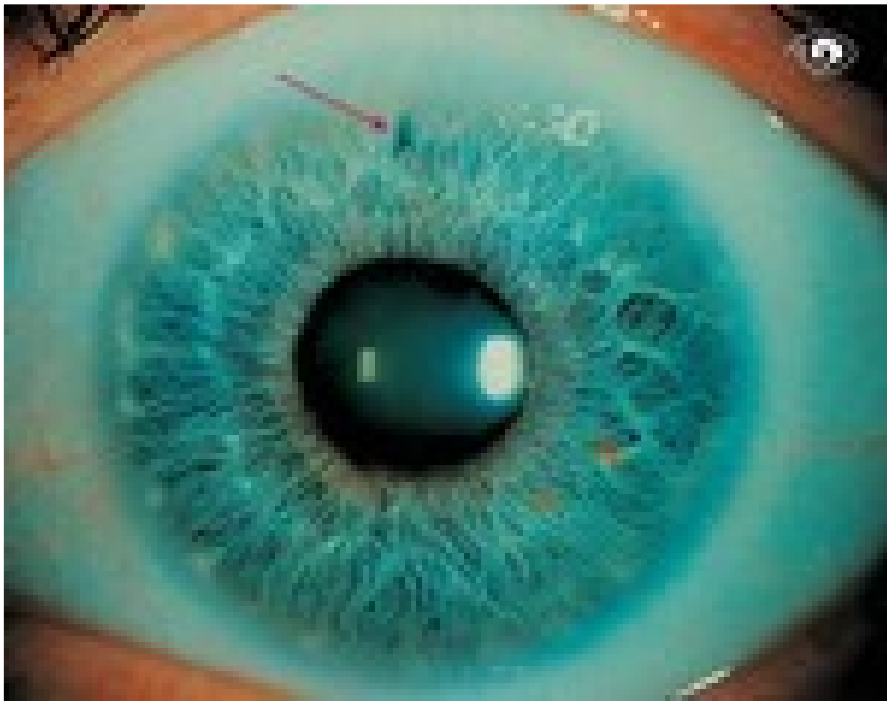
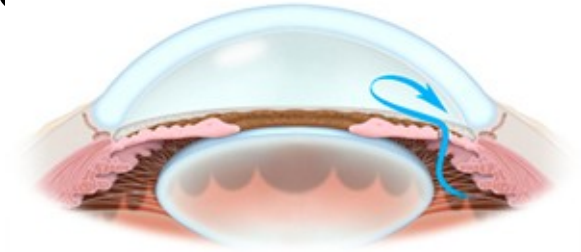
Acute angle closure – primary care

- Miotics
- Other local antiglaucomatics
- Systemic therapy:
 - Osmotics
 - Carbonanhydrase inhibitors
 - Analgetics
 - Antiemetics



Acute angle closure – secondary care

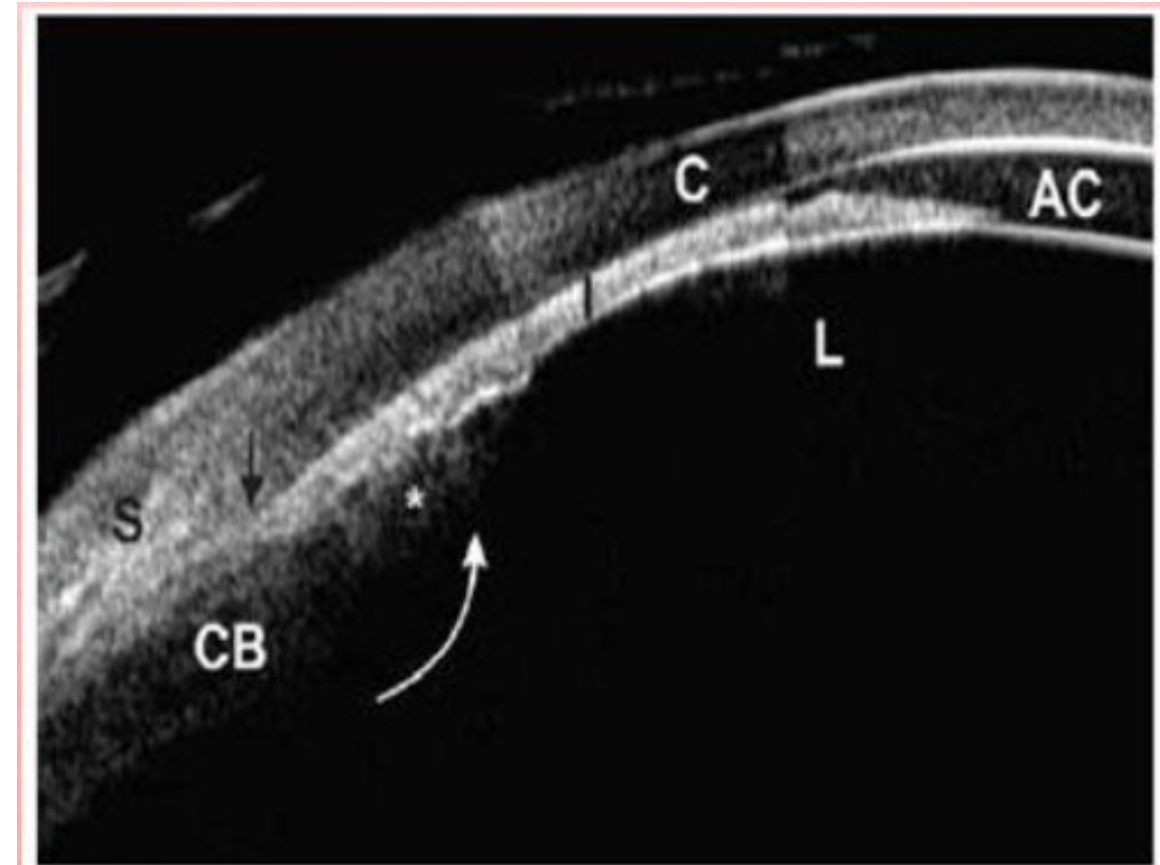
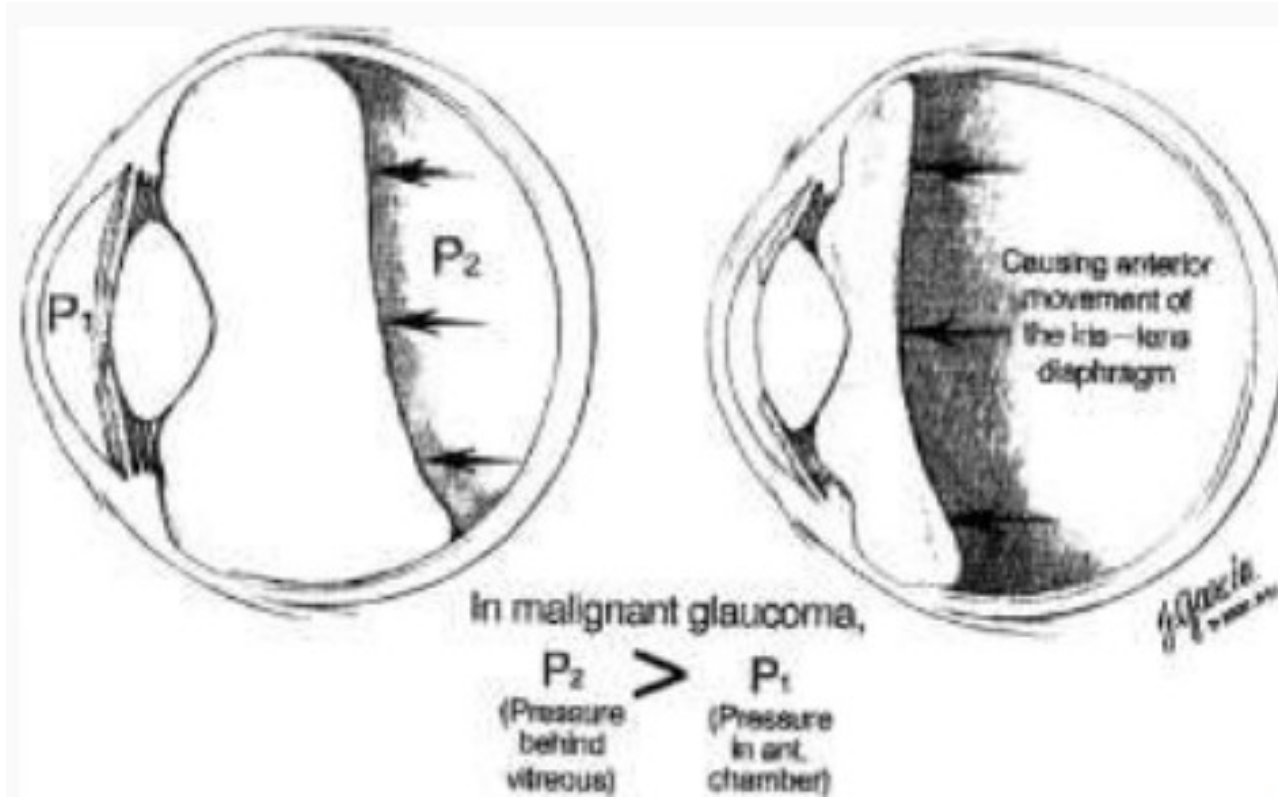
- Laser iridotomy (Nd:YAG laser)
 - (neodymium-doped yttrium aluminum garnet)
 - Little hole in the iris periphery
 - Help to equal the pressures between posterior and anterior eye segment
- Cataract extraction



Laser iridotomy video

- <https://www.youtube.com/watch?v=pNpzdYA3TqI>

Special case: Malignant glaucoma



Part 5: Examination

Examination in glaucoma

- History
- Slit lamp examination
 - gonioscopy
- IOP measurement
- Perimetry
- Imaging
 - OCT RNFL
 - Ganglion cells
 - HRT

Medical history in glaucoma

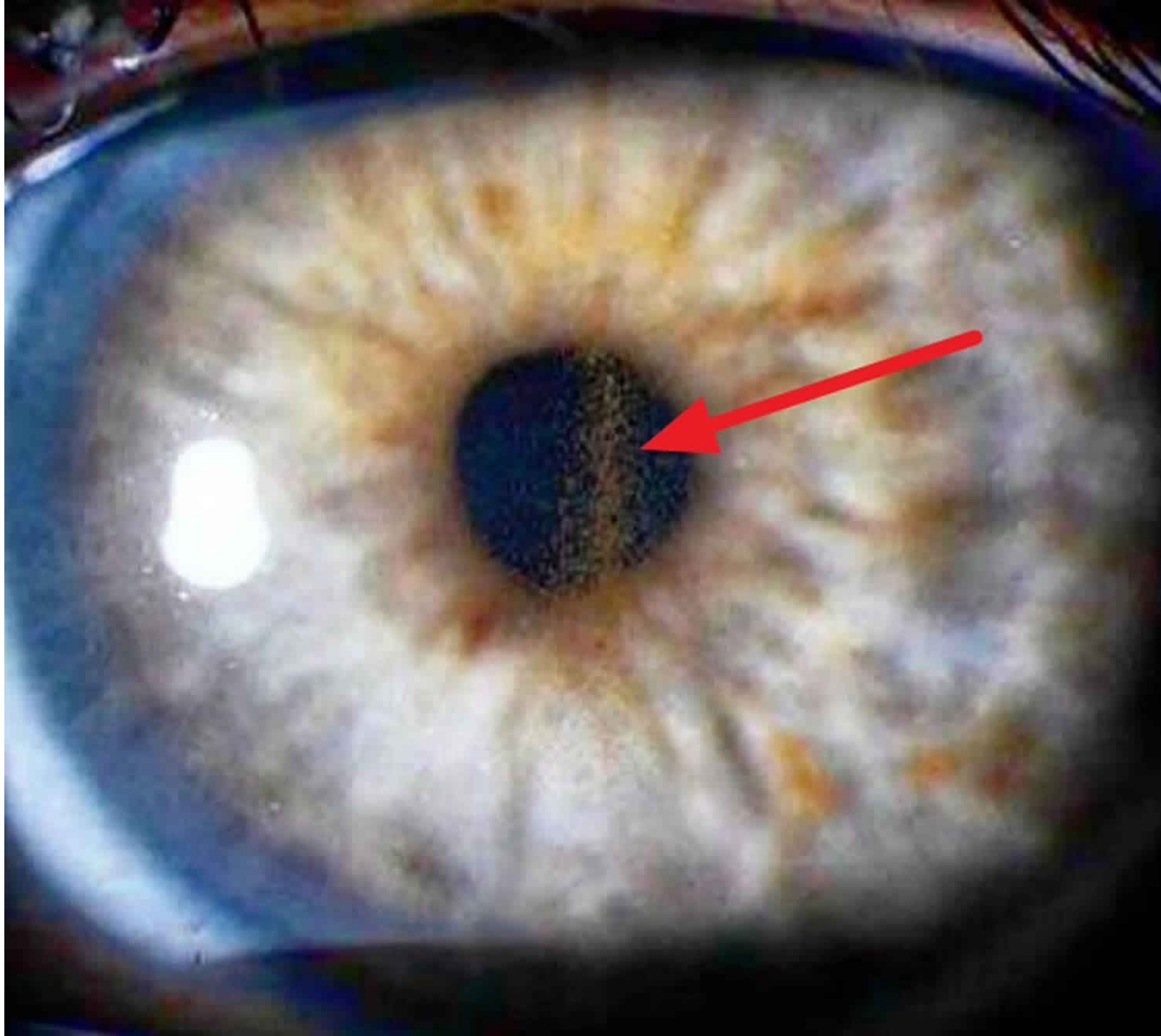
- Typically no symptoms for chronic glaucoma in early stages
- Risk factors:
 - age, family history, high IOP, hyperopia, DM, previous eye injury, thin cornea, race
- Important in medical history
 - Past ocular surgery
 - Refractive error
 - General medical history (corticosteroid use – steroid induced gl.)
 - Past medical history (DM, AB, AI, heart diseases, raynauds phenomenon)
 - Glaucoma in family

Slit lamp examination

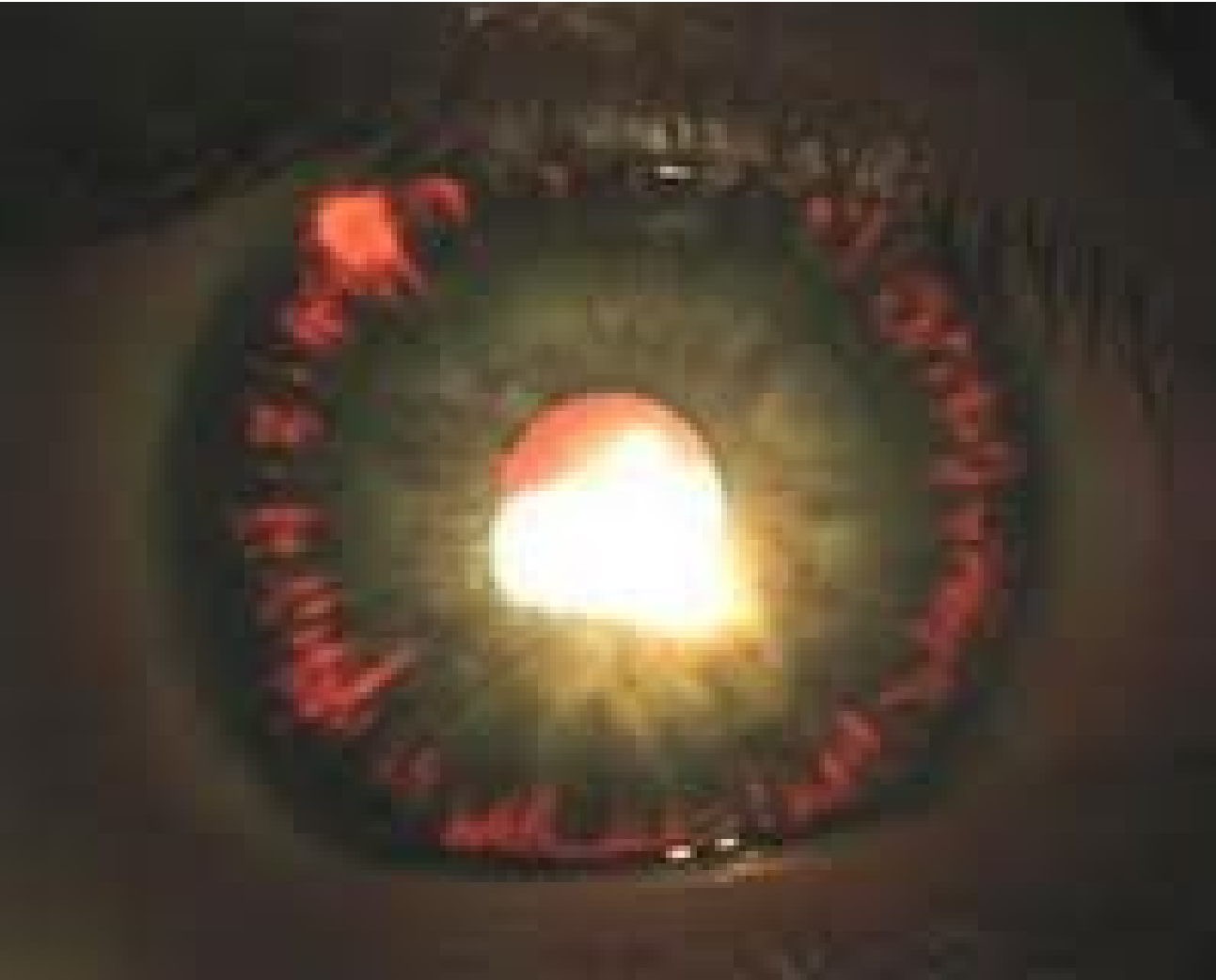
- External adnexae (lashes)
- Pupils – may differ in size
- Conjunctiva – hyperaemia, scarring due to decreased tear production..
- Cornea – epithelopathy (mediacal toxicity), microcystic oedema (IOP), Kruckenberg's spindle (pigmentary gl.), precipitates (uveitic gl.)
- AC – van Herick method (width)
- Iris – translumination defects (pigmentary gl), ectropion uveae, rubeosis iridis..
- Lens – intumescent cataract, pseudoexfoliation, subluxation...
- Fundus – optic nerve head, retinal haemorrhages, masses...

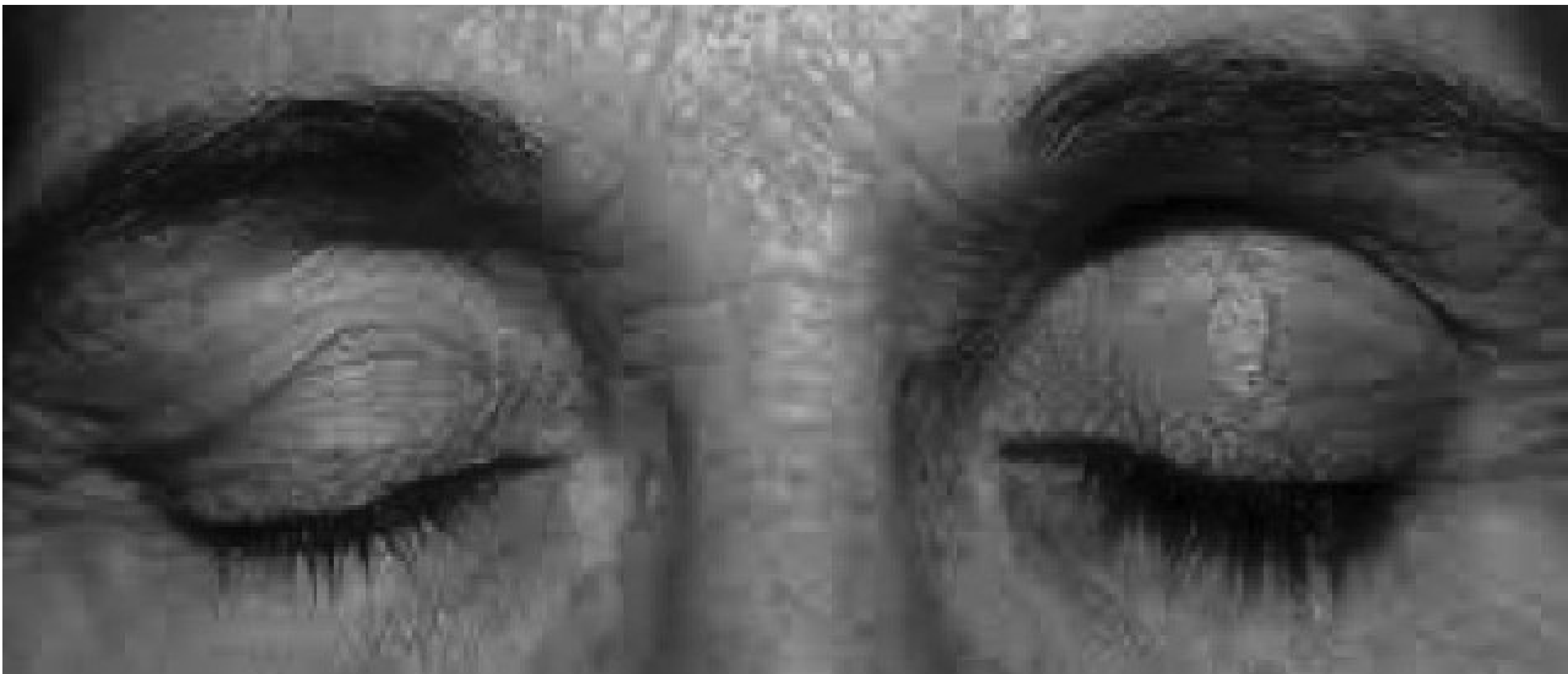

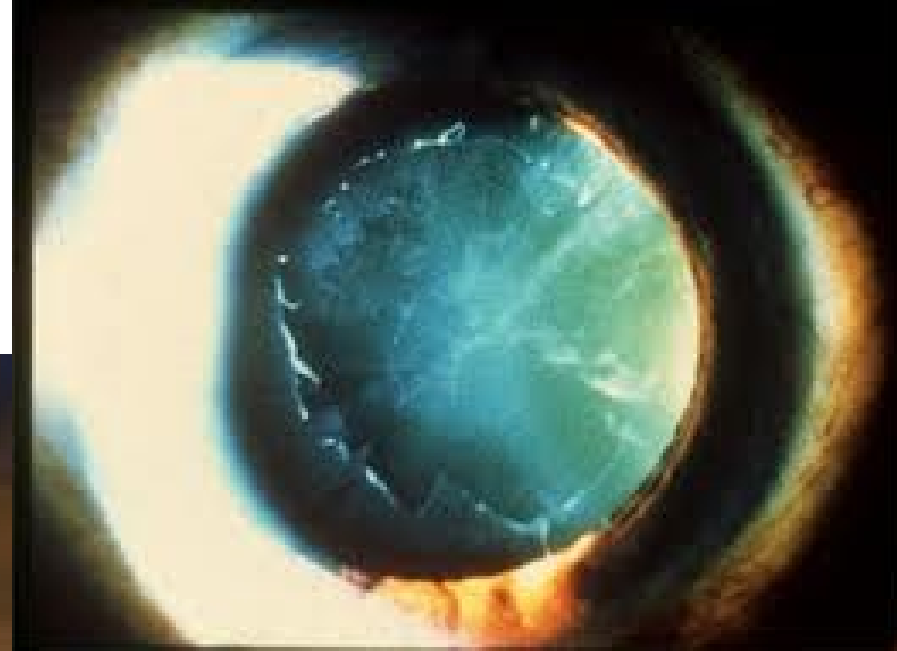
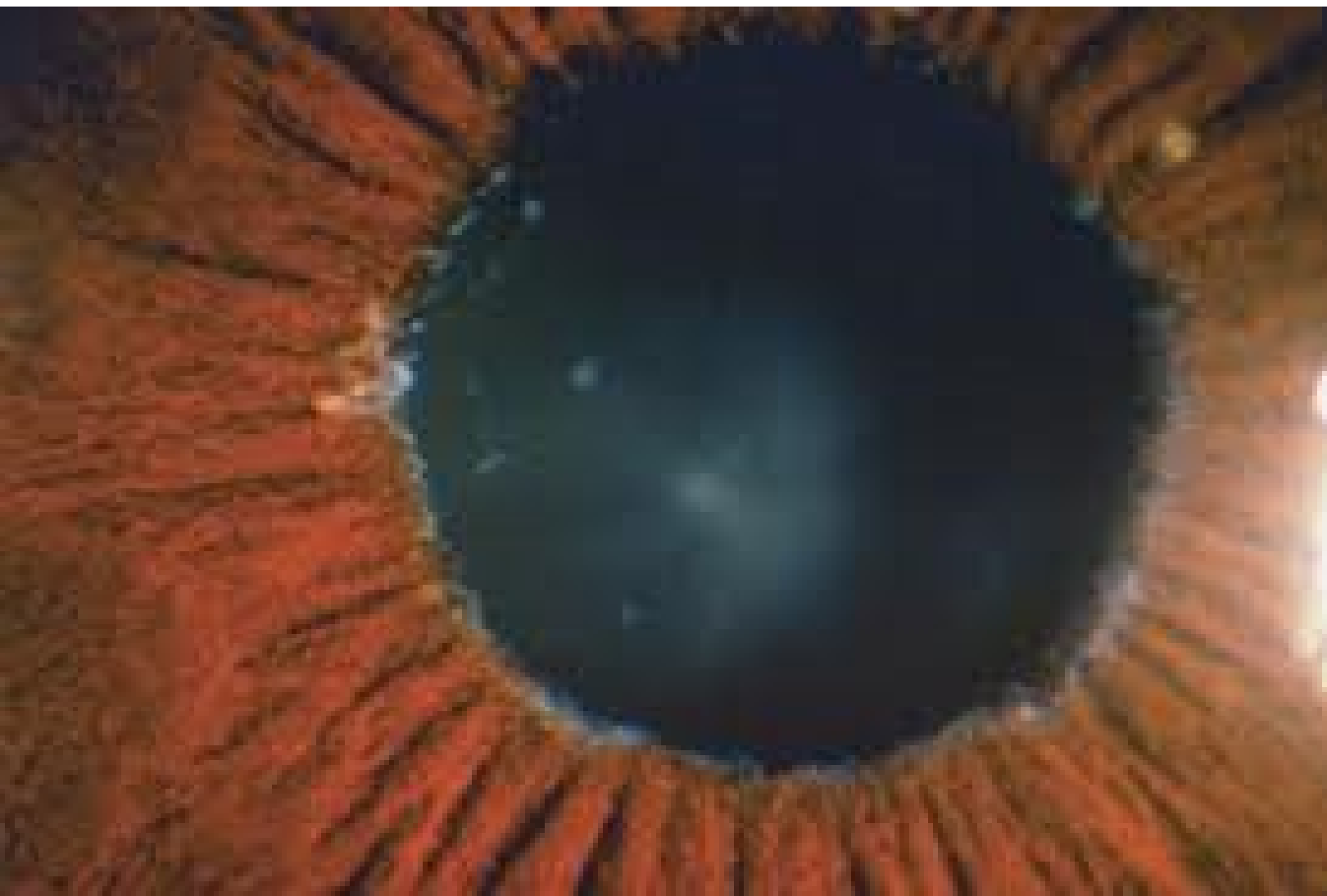Fig 2: Hypertrichosis in a patient on bimatoprost in Left eye



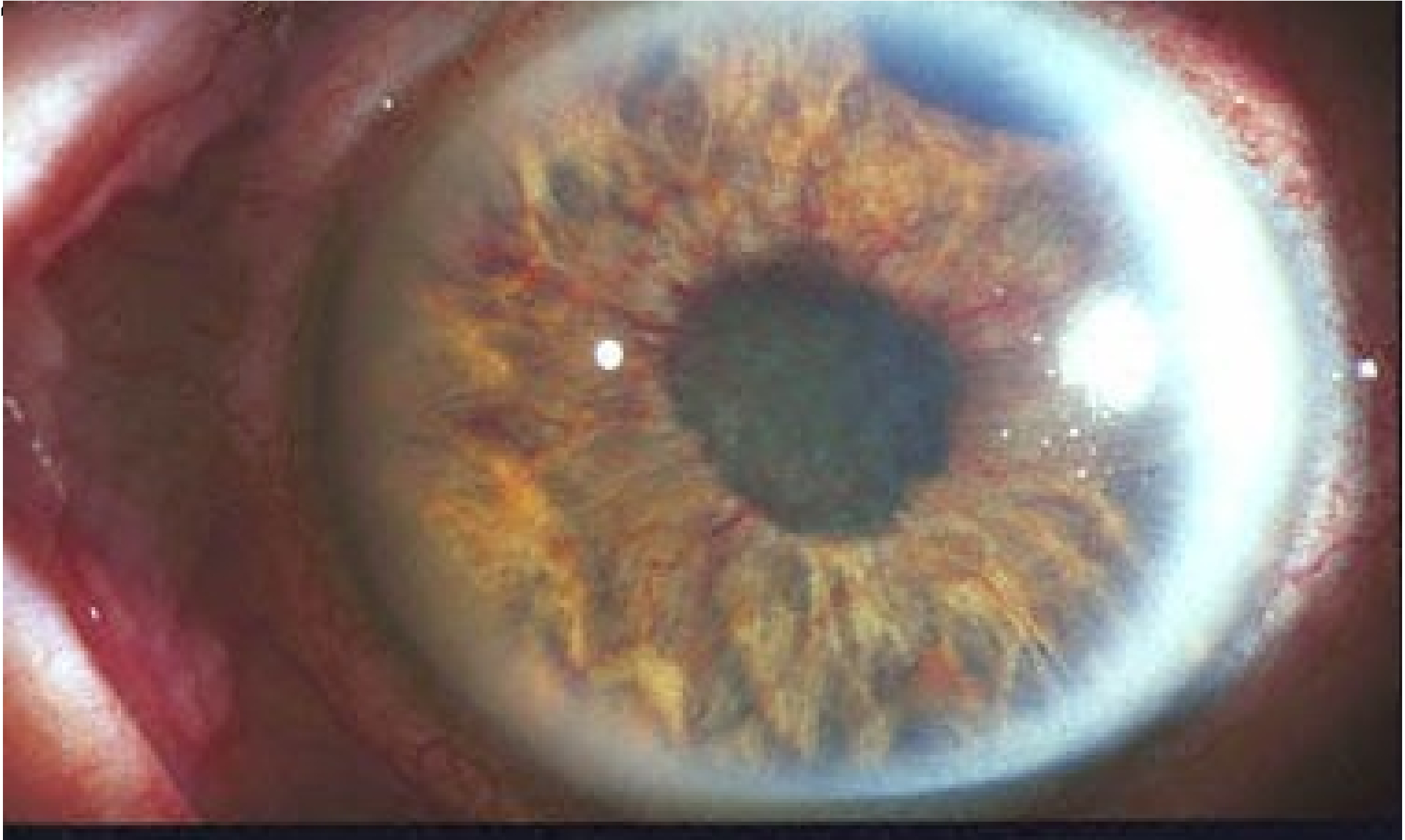Pigmentary glaucoma (secondary open angle)



PEX glaucoma (secondary open angle)




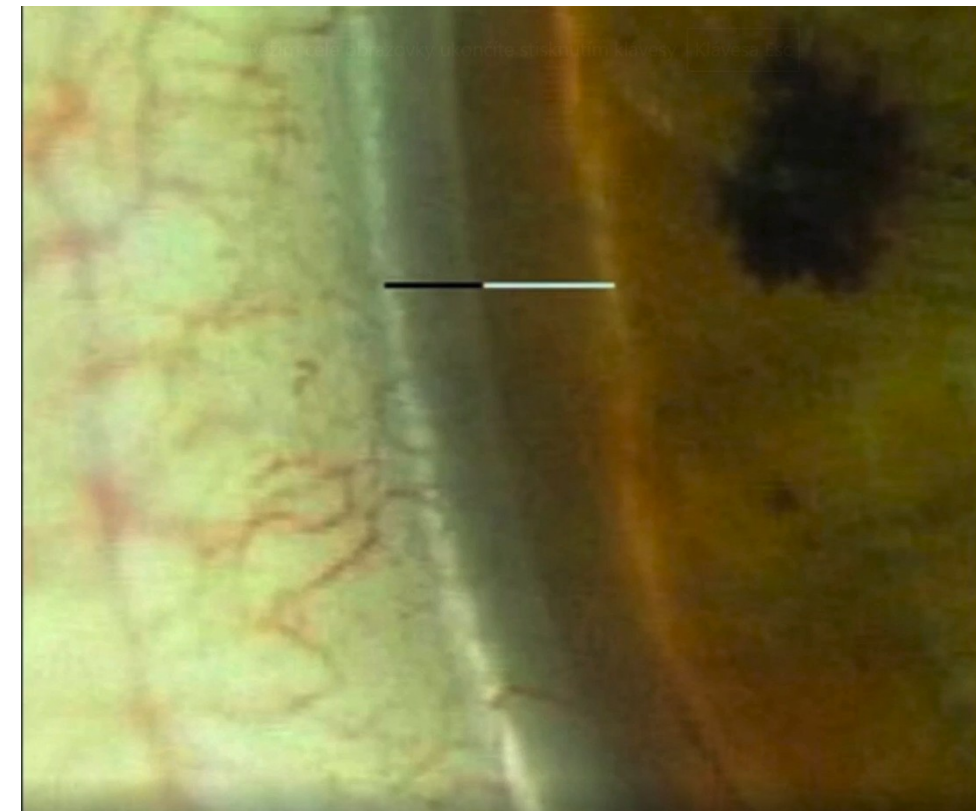
Neovascular gl. (secondary angle closure)



Van Herick grading

AC Depth	Grade
\geq cornea	4
$\frac{1}{4}$ - $\frac{1}{2}$ cornea	3
$\frac{1}{4}$ cornea	2
$< \frac{1}{4}$ cornea	1
Dangerously narrow	Slit

Under $\frac{1}{4}$ = high risk of angle closure



Slit lamp examination

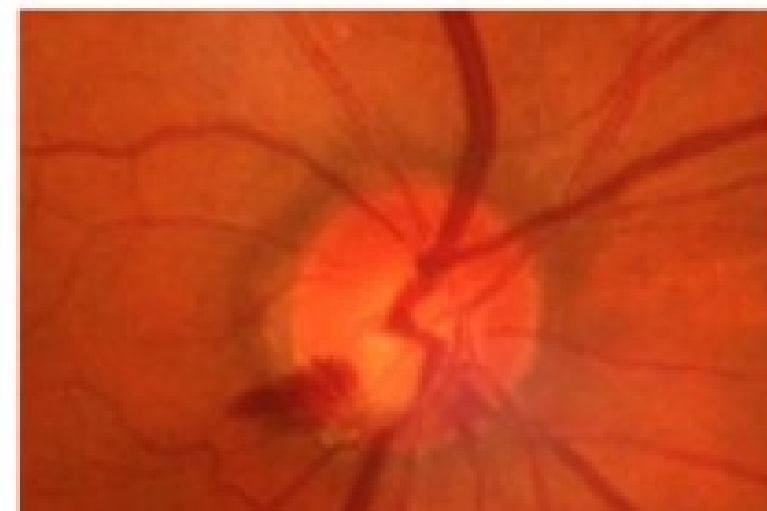
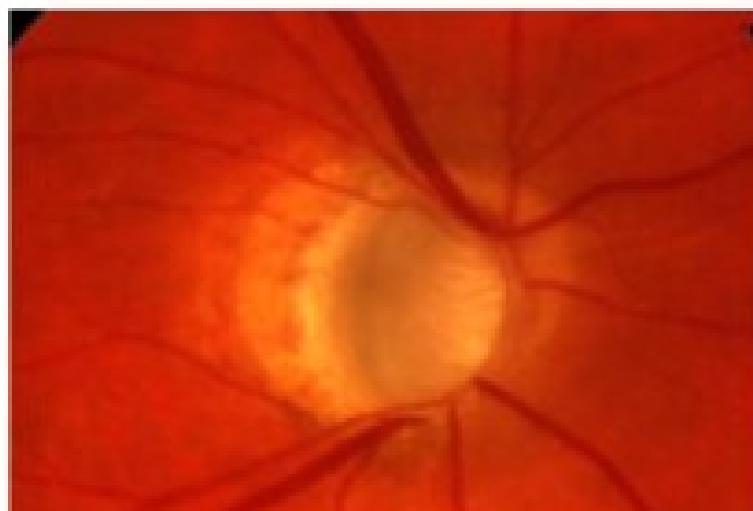
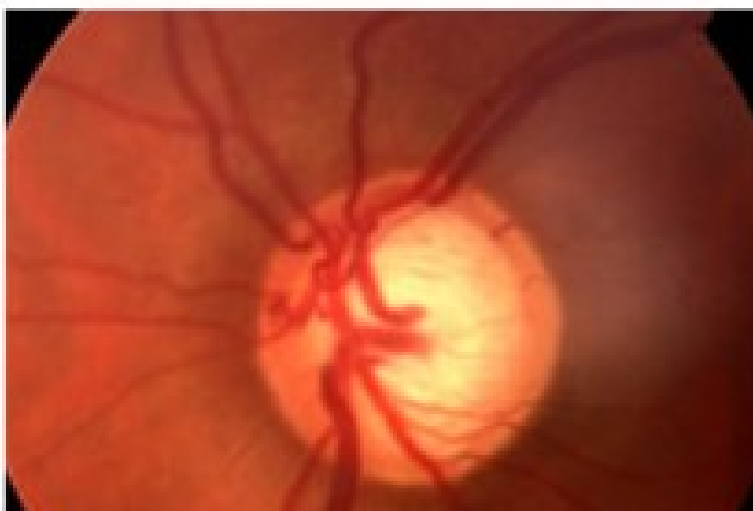
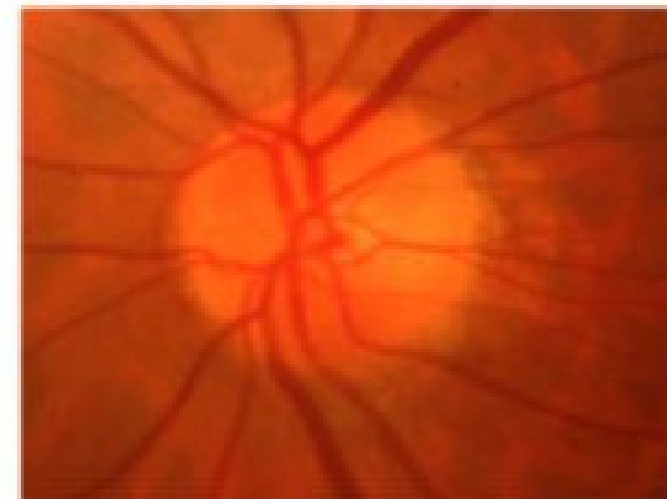
Signs of glaucoma atrophy of ONH:

Excavation of papilla of ONH

Nasalization (nasal shift of vessels)

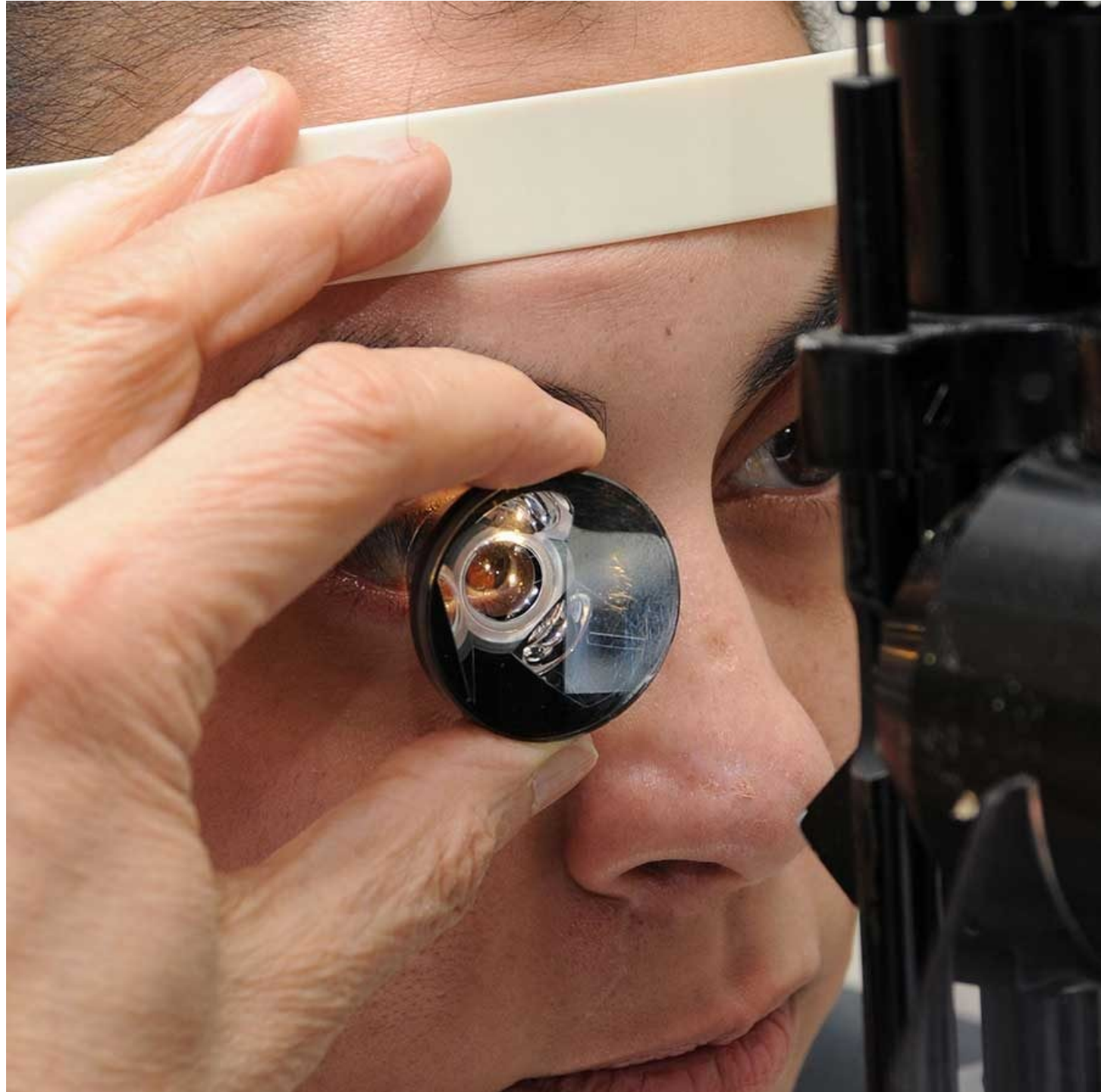
Peripapillary choroidal atrophy

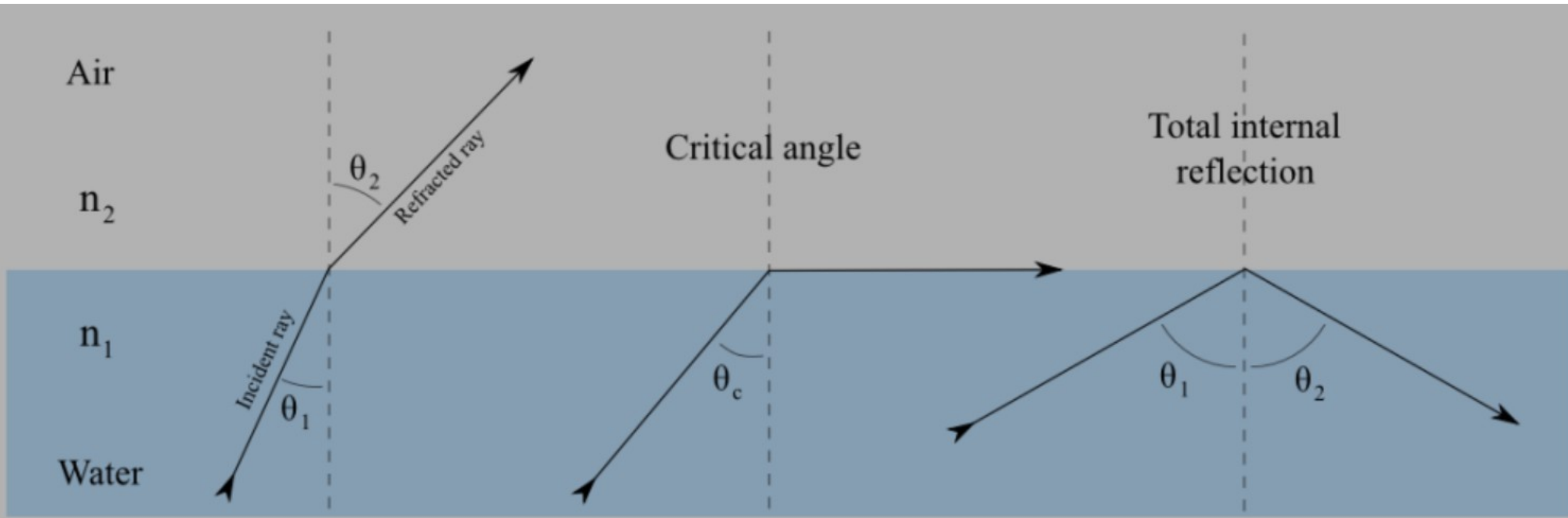
Disc hemorrhage



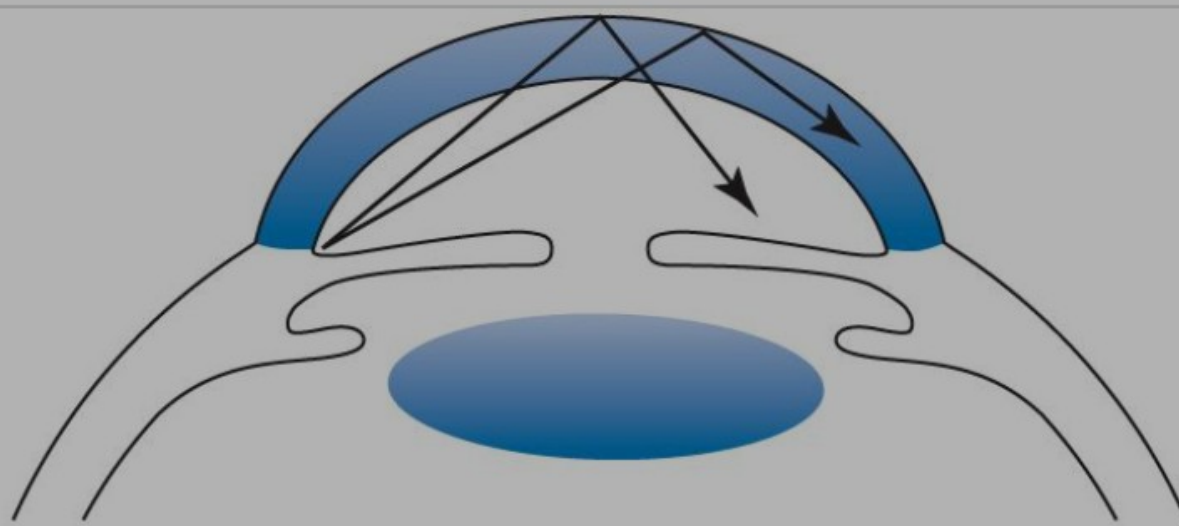
Gonioscopy

- Visualisation of the anterior chamber angle

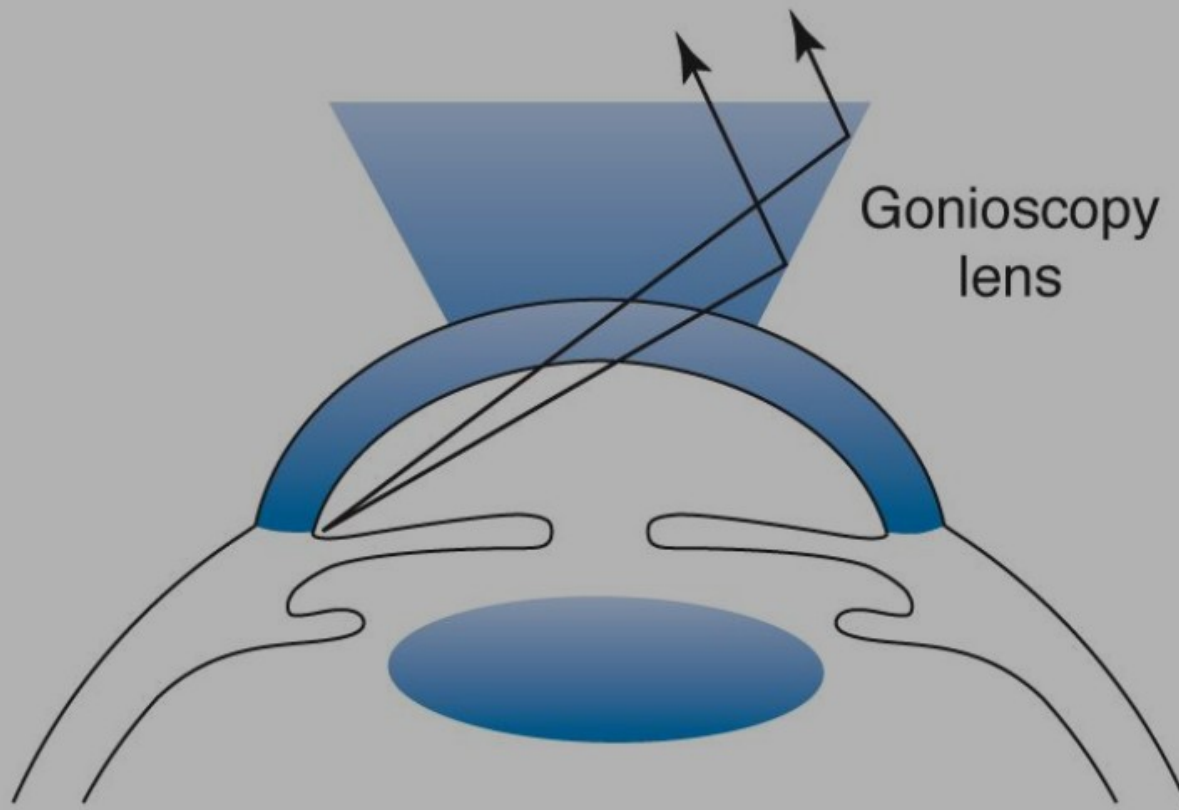





A



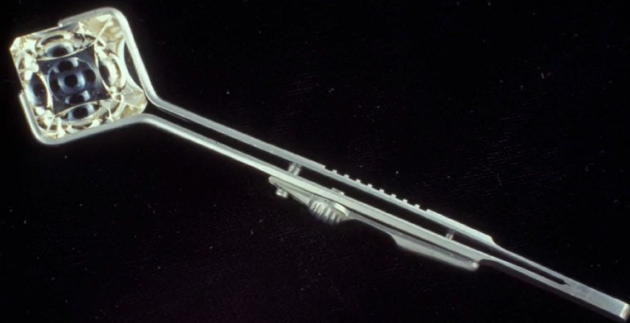B



Indirect Gonioscopy Lenses



Goldmann-style



Zeiss-style



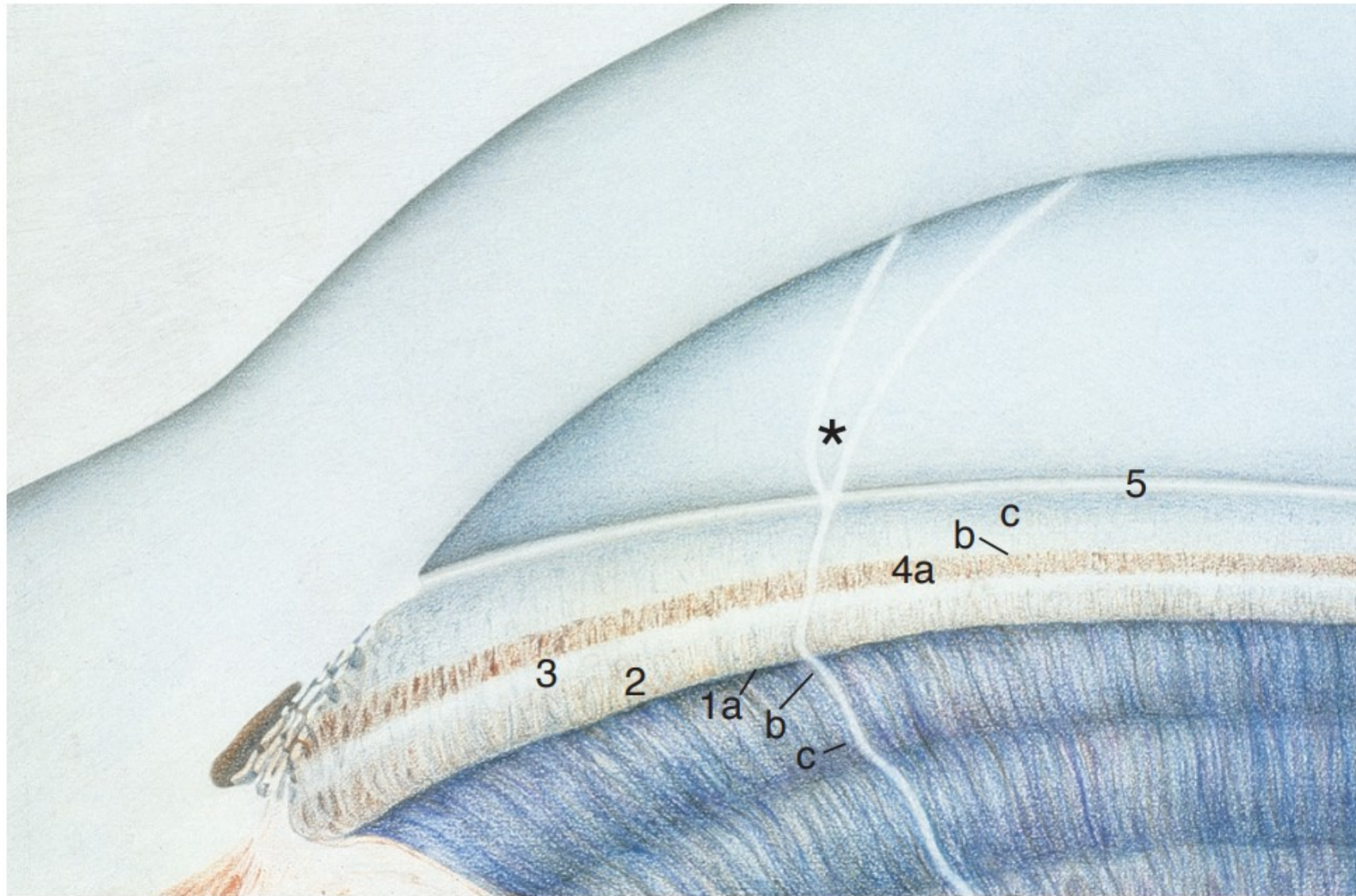


Figure 3-1 Gonioscopic appearance of a normal anterior chamber angle. 1, Peripheral iris: *a*, insertion; *b*, curvature; *c*, angular approach. 2, Ciliary body band. 3, Scleral spur. 4, Trabecular meshwork: *a*, posterior; *b*, mid; *c*, anterior. 5, Schwalbe line. *Asterisk*, Corneal optical wedge.

Spaeth grading system

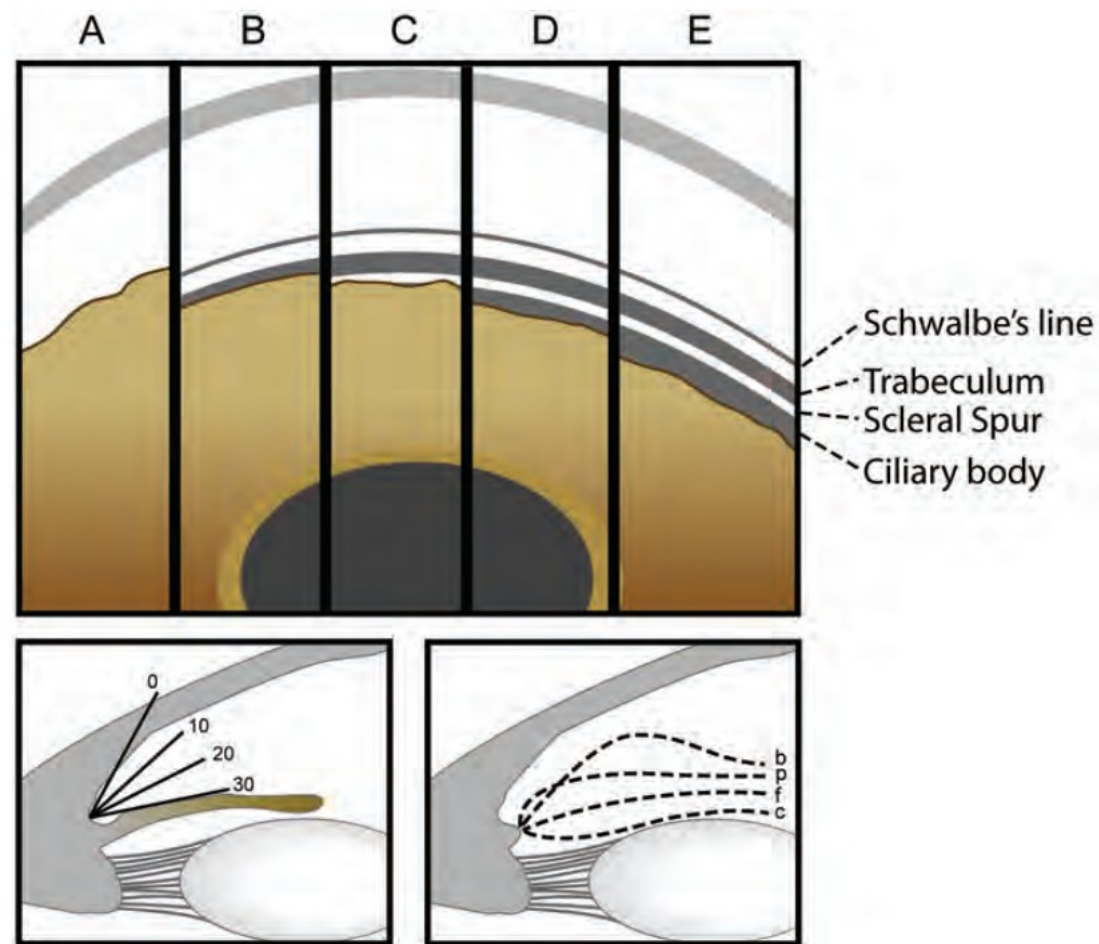


FIGURE A.14.1. Spaeth angle classification.

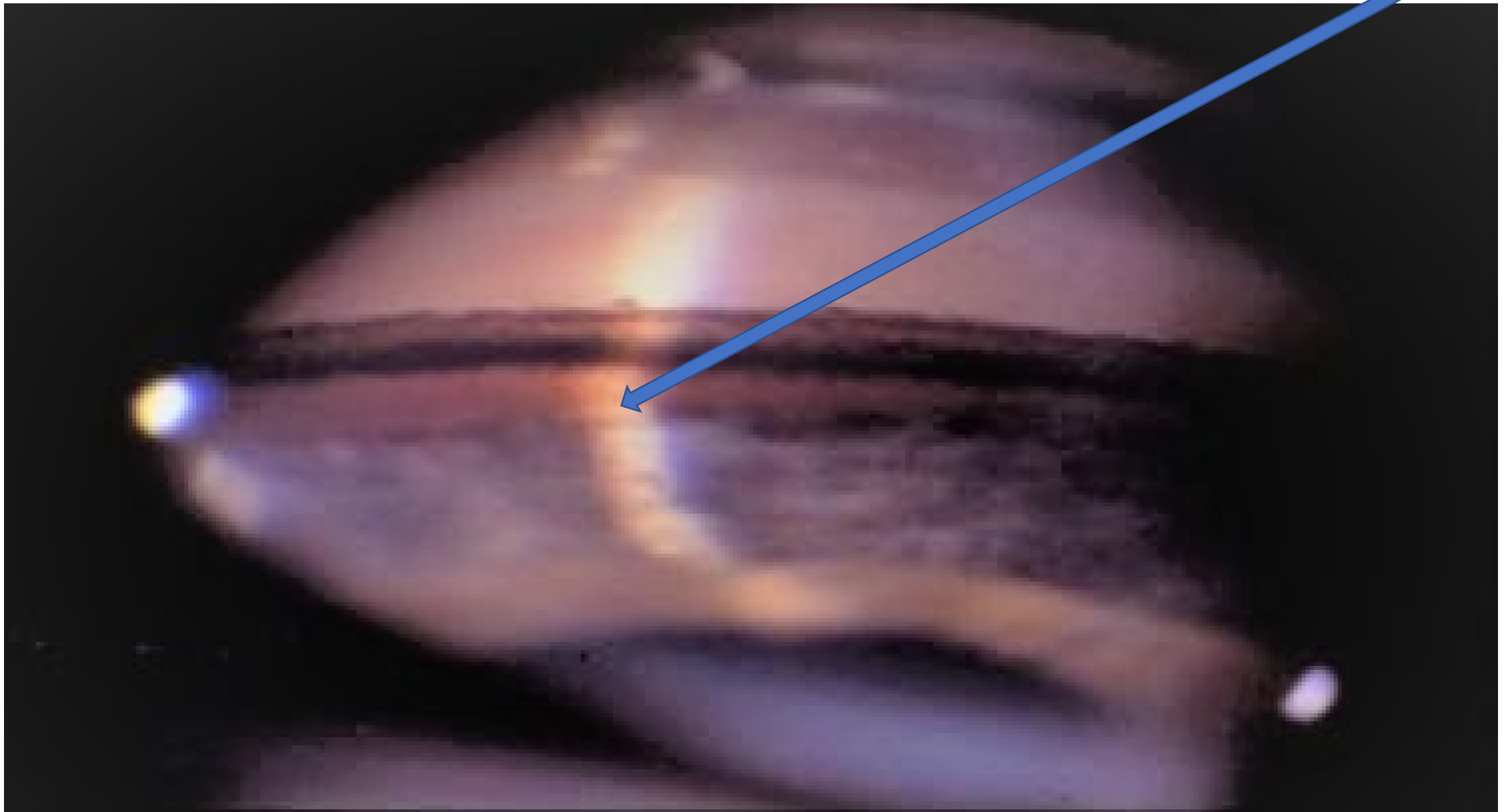
TABLE 4. SPAETH GONIOSCOPIC GRADING SYSTEM*


Iris Insertion	Angular Approach	Peripheral Iris		Pigmentation of Trabecular Meshwork
		r regular	f flat	
A Anterior to Schwalbe's line	0° to 50°	s steep	b bowed anteriorly	0 no pigment
B Between Schwalbe's line and scleral spur			p plateau iris	1+ minimal
C Scleral spur visible		q queer	c concave	2+ mild
D Deep with ciliary body visible				3+ moderate
E Extremely deep with >1 mm of ciliary body visible				4+ intense

*Evaluating iris insertion, angular approach, peripheral iris configuration, and degree of trabecular meshwork pigmentation.

Pigmentary glaucoma: E60c 4+ ptm

CB



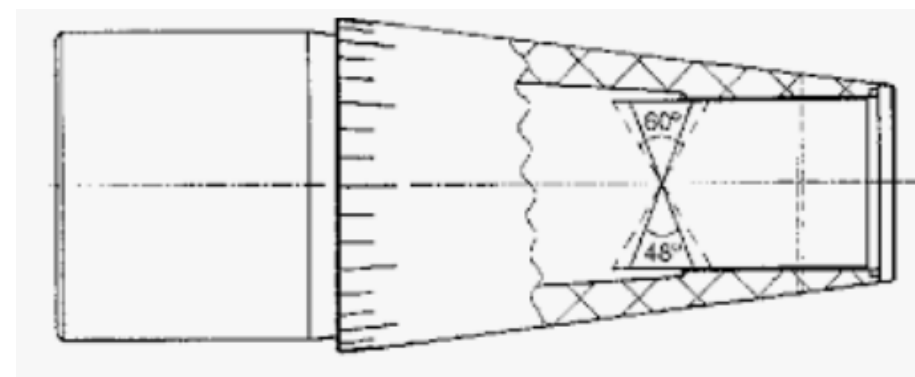
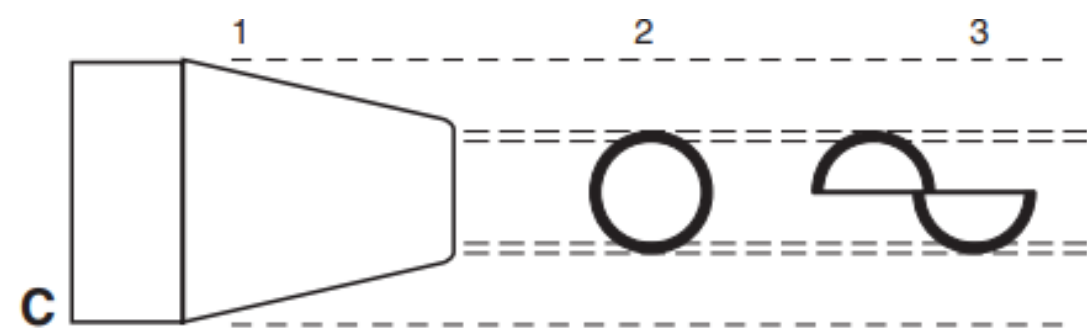
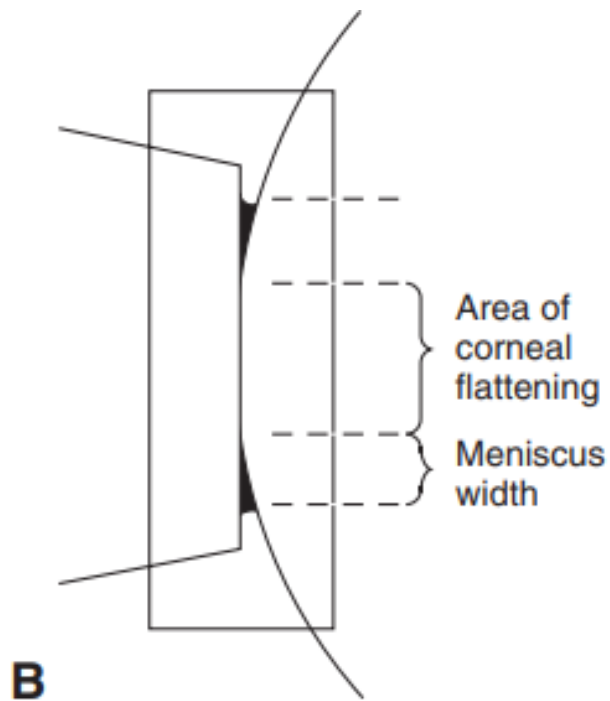
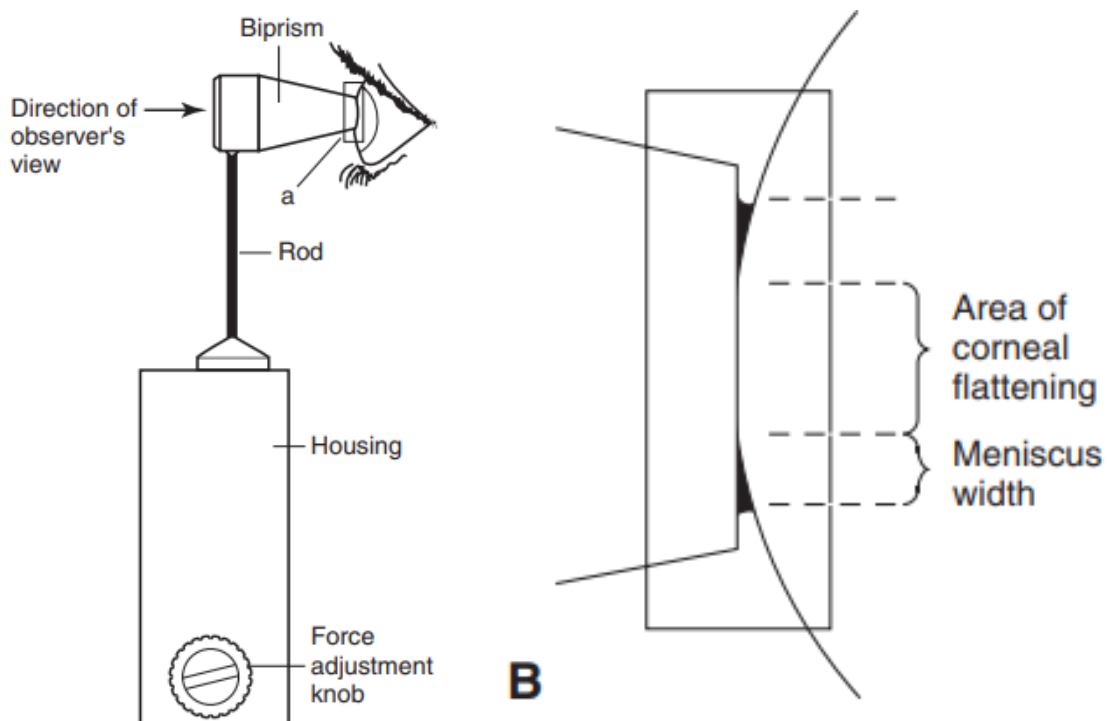


IOP MEASUREMENT - „NORMAL“ IOP?

- in the general population of Europe: approximately 15.5 mm Hg, with a standard deviation of 2.6 mm Hg
- Circadian variation: IOP varies by 2–6 mm Hg over a 24-hour period, peak is individual, often in the morning
- High IOP is often first sign of glaucoma
- factors that may increase intraocular pressure:
 - Playing a wind instrument, Valsalva maneuver, Blepharospasm, Corticosteroids...
- Factors that may decrease intraocular pressure
 - Pregnancy, alcohol, cannabis, aerobic exercise...

IOP measurement

- Goldmann applanation tonometer
 - the most widely used method
 - Imbert-Fick principle: pressure inside an ideal dry, thin-walled sphere equals the force necessary to flatten its surface divided by the area of the flattening
 - Circular meniscus is converted into 2 semicircles by the prism

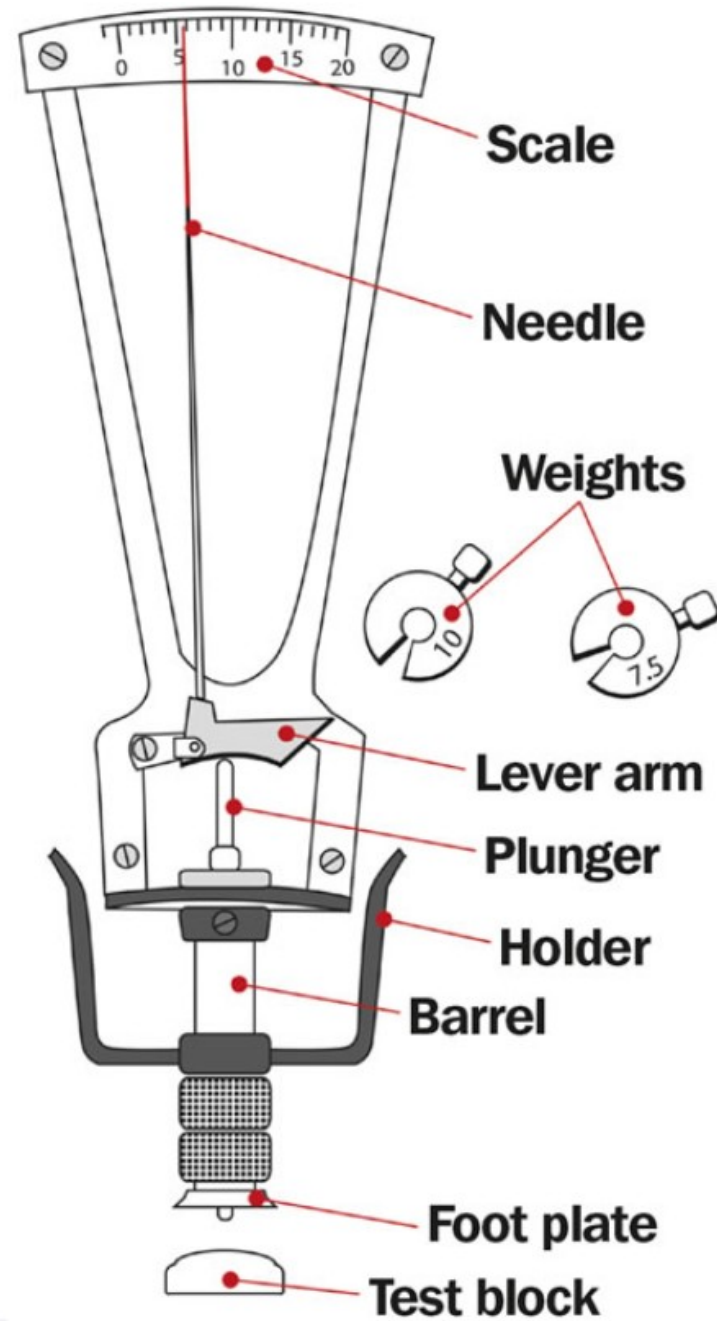
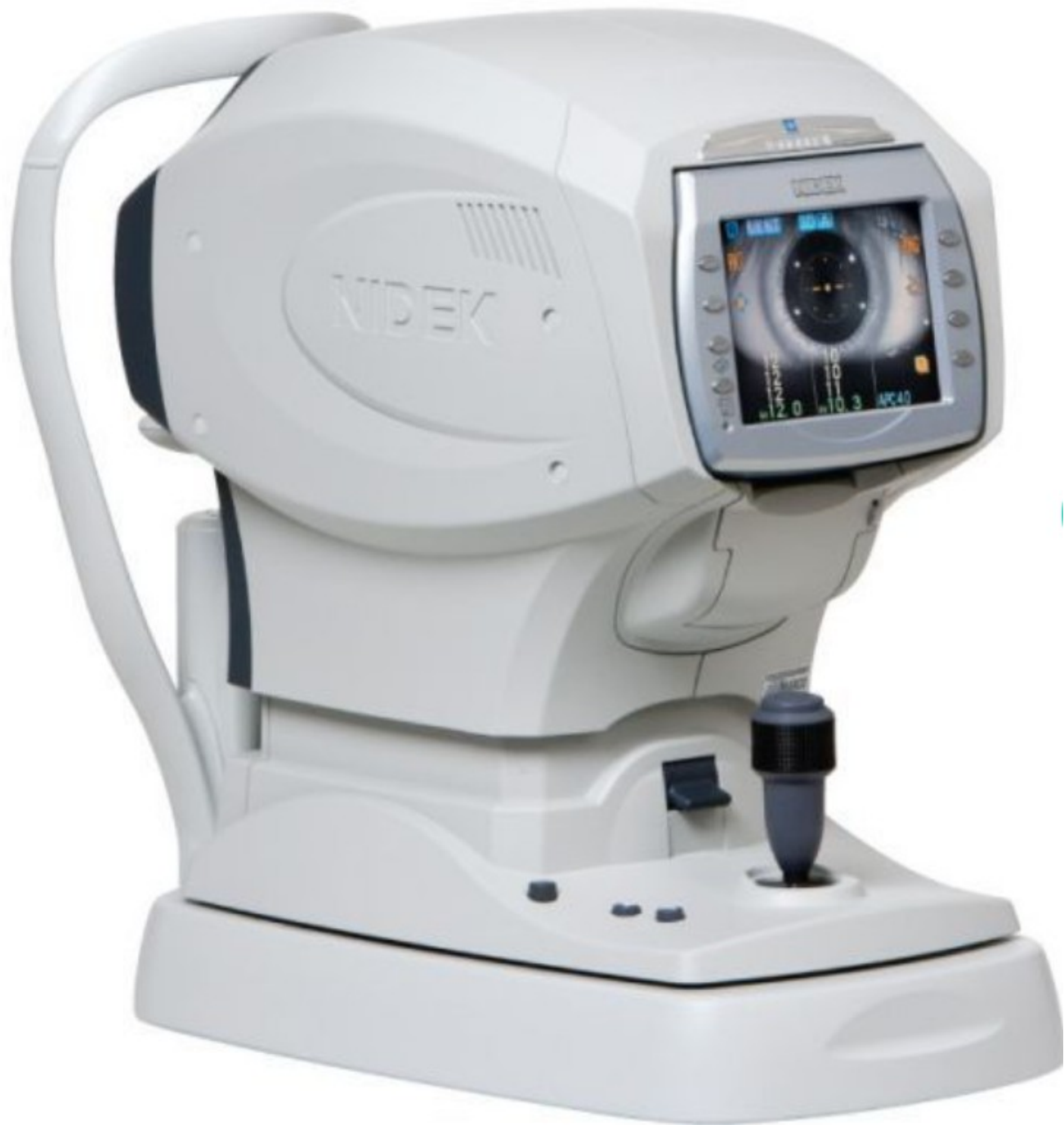

Aplanation tonometry - video

- https://www.youtube.com/watch?v=KOHe9wzM4ns&embeds_euri=https%3A%2F%2Fhubblecontent.osi.office.net%2F&source_ve_path=MjM4NTE&feature=emb_title&ab_channel=EyeDoc

IOP measurement

- Noncontact (air-puff) tonometers
 - measuring the force of air required to indent the cornea to a fixed point
 - Pachymetry
 - Corneal hysteresis
 - Advantage: no risk of infection, no need of local anaesthesia
 - Disadvantage: less accurate
- Schiøtz tonometry
 - The amount of indentation is read on a linear scale on the instrument and converted to mm Hg by a calibration table
 - Due to a number of practical and theoretical problems, Schiøtz tonometry is now **rarely used in the developed world.**



Perimetry

- Kinetic perimetry
 - Older method, still used in terminal cases
- Static (computer) perimetry
 - More accurate
 - Absolute/relative scotomas
 - Usually takes several tries to learn
 - Indicates false positive, false negative responses and fixation loss
 - Special glaucoma indexes and evaluation (GHT, MD..) to map the progression

OD full field 120p

Eye: Right

Name:	DOB:
ID:	

Full Field 120 Point Screening Test

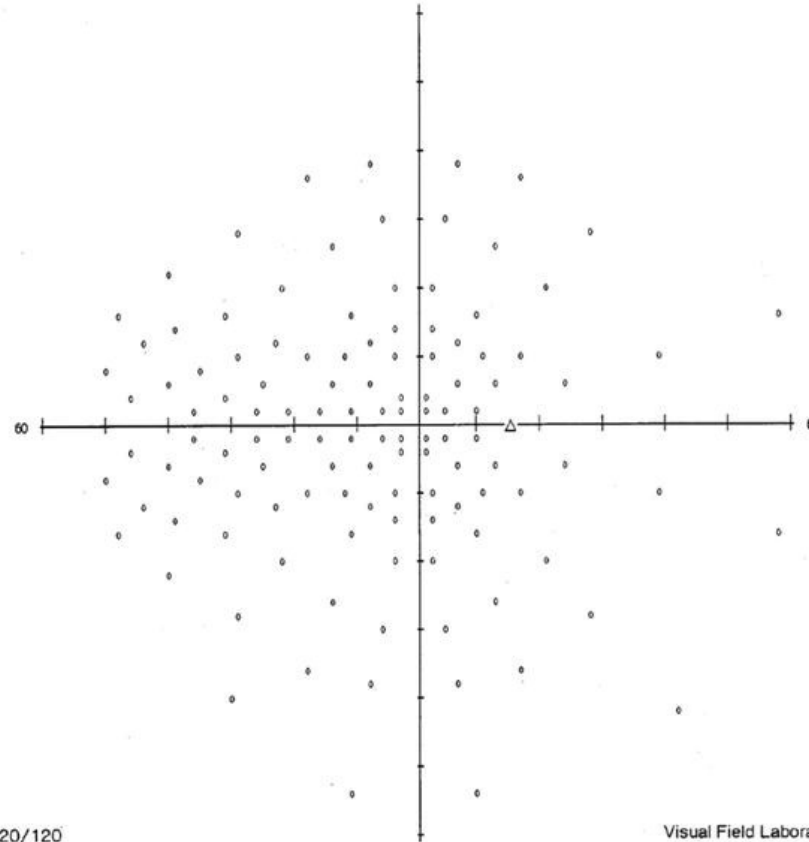
Fixation Monitor: Gaze/Blind Spot
Fixation Target: Central
Fixation Losses: 0/13
False POS Errors: 0/11
False NEG Errors: 0/11
Test Duration: 04:26

Stimulus: Ill, White
Background: 31.5 ASB
Strategy: Three Zone
Test Mode: Age Corrected

Pupil Diameter: 6.2 mm
Visual Acuity:
RX: DS DC X


Date: 05-16-2008
Time: 10:26 AM
Age:

Central Reference: 32 dB
Peripheral Reference: 32 dB



- Seen 120/120
- x Defect 0/120
- Not Seen 0/120
- △ Blind Spot

Visual Field Laboratory
University of Iowa
College of Medicine
Iowa City, IA
(319) 356-1611



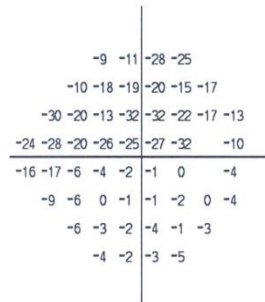
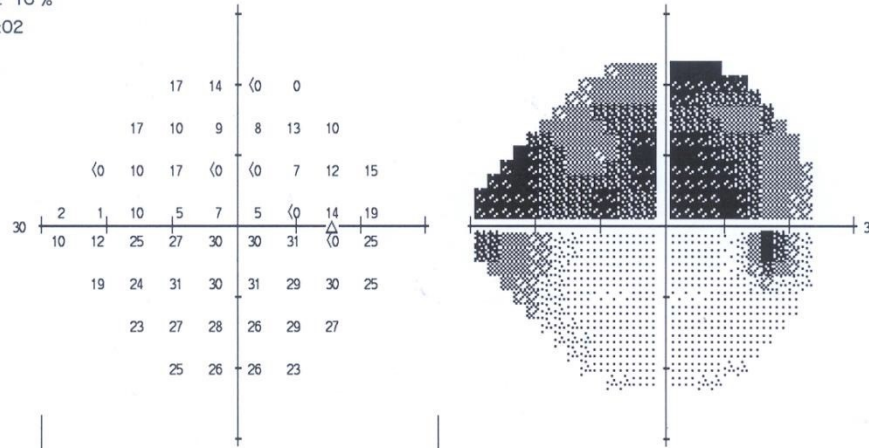
OD threshold 24-2

Central 24-2 Threshold Test

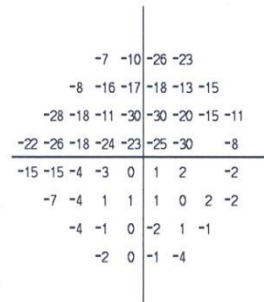
Fixation Monitor: Gaze/Blind Spot
 Fixation Target: Central
 Fixation Losses: 1/13
 False POS Errors: 9 %
 False NEG Errors: 16 %
 Test Duration: 06:02
 Fovea: OFF

Stimulus: III, White
 Background: 31.5 ASB
 Strategy: SITA-Fast

Pupil Diameter: 6.7 mm
 Visual Acuity:
 RX: +3.75 DS -1.75 DC X 105 Age: 79
 Date: 12-10-2008
 Time: 4:38 PM



Total Deviation



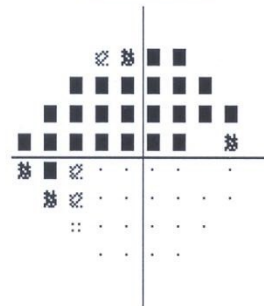
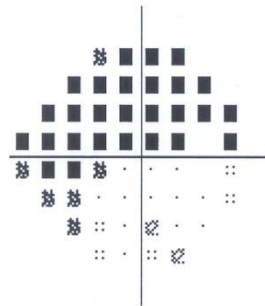
Pattern Deviation

GHT
 Outside normal limits

VFI 60%

MD -12.47 dB P < 0.5%

PSD 10.86 dB P < 0.5%



:: < 5%
 ☒ < 2%
 ☒ < 1%
 ■ < 0.5%

BLIND SPOT

RELATIVE SCOTOMA

ABSOLUTE SCOTOMA

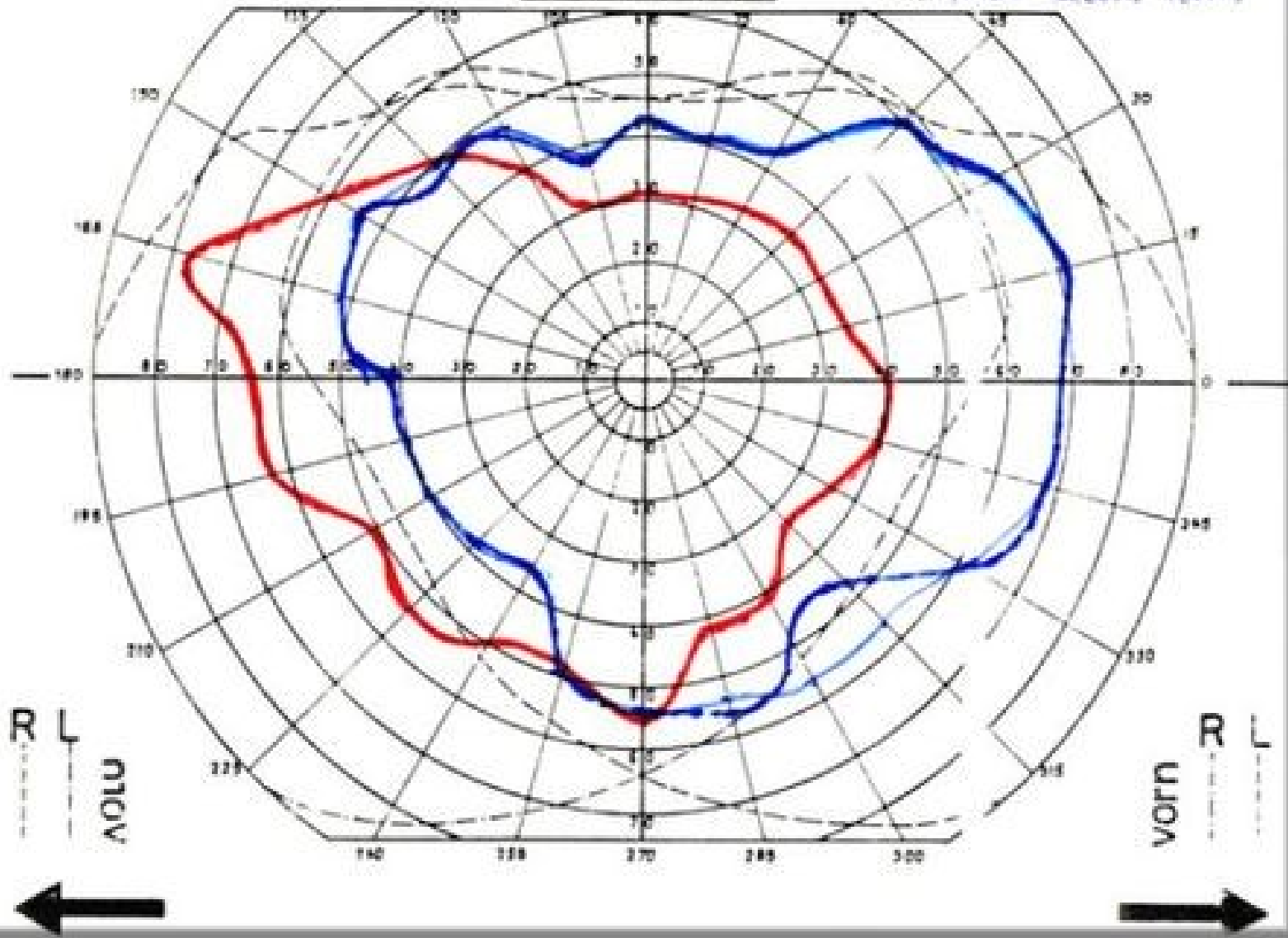
NORMAL SENSITIVITY



Kugel-Perimeter R/L

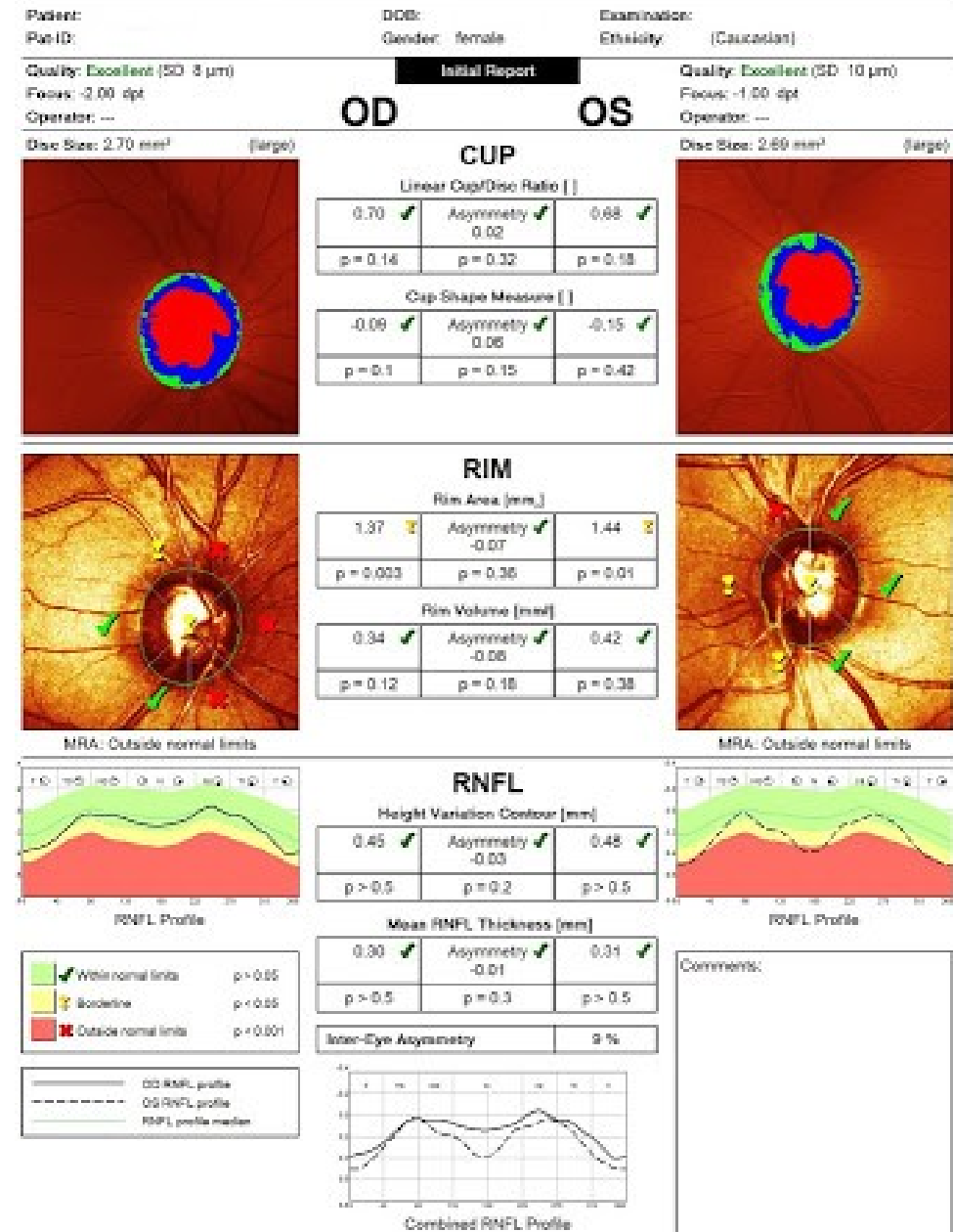
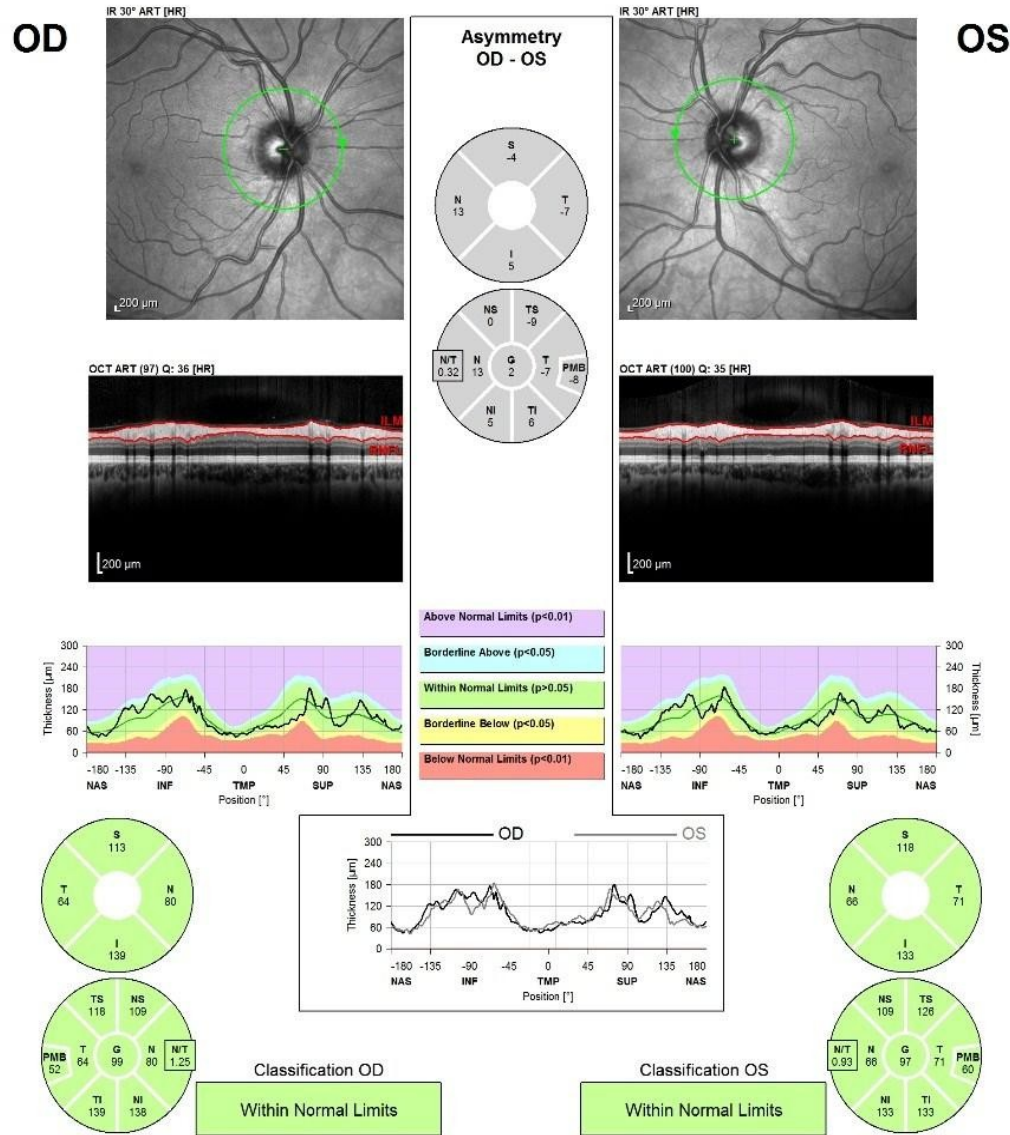
No.	4	3	2	1	P	G
0						
I						
II						
III						
IV						
V						

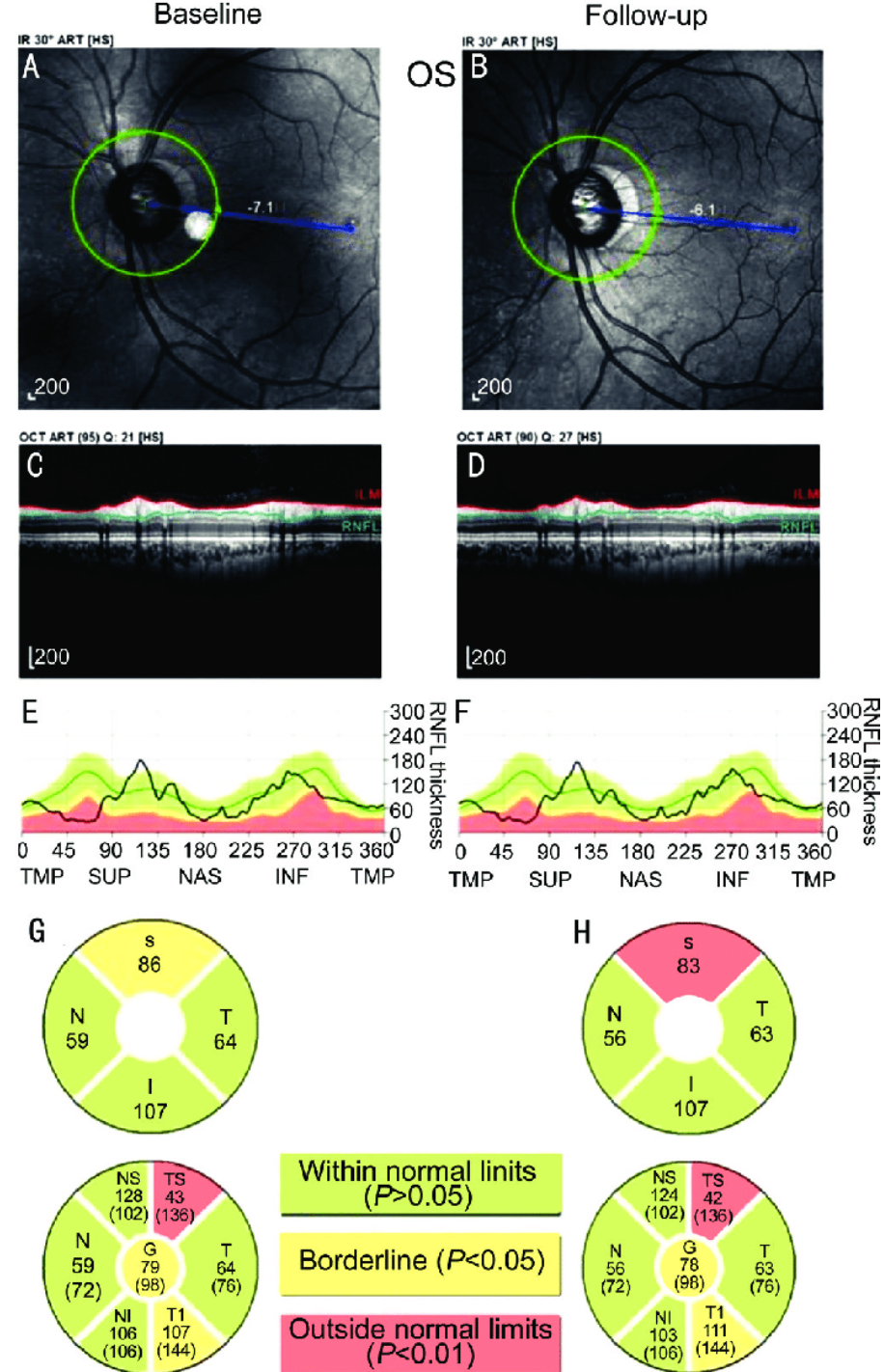
Name _____
 Pupillweite _____
 Korrektion _____ m _____
 Datum *11. VI. 1937*
 Arzt *M. Dr. Kubina Tsch. I.*



Imaging

Patient ID: --- Exam.: 24.10.2012
 Diagnosis: --- Comment: ---





Part 6: Therapy

Therapy = lowering IOP

- **Pharmacotherapy**
 - Antiglaucomatics
 - Neuroprotectin (Citikolin)
- **Surgery**
- **Laser therapy**

- Therapy selection depends on glaucoma type:
 - Open angle
 - Pharmacotherapy
 - Surgery
 - Angle closure
 - Surgery
 - Pharmacotherapy (pilocarpine)

Antiglaucomatics

- For local use
 - Monotherapy/combined therapy (**up to 4**)
- For systemic use
 - Carbonanhydrase inhibitors
 - decrease of aqueous humor production
 - CI: kidney/liver failure, gravidity
 - Osmotics
 - Vitreuous dehydration – leads to retraction of iridocorneal diaphragma backwards – anterior chambre deepening)
 - CI: heart/kidney failure

Antiglaucomatics

- Prostaglandins
 - **Drug of first choice**
 - Used once a day (evening), long effect, best compliance, 30% IOP decrease
 - Mechanism – **higher outflow through uveoscleral pathway**
 - Contraindication: inflammation, surgery...

Antiglaucomatics

- Beta-blockers (nonselective)
 - Mechanism: **decrease of aqueous humor production** (vasoconstriction – beta 1 and 2 rcp)
 - Contraindications: arrhythmia, COPD, AB
 - 1-0-1
- Beta-1 selective betablockers

Antiglaucomatics

- Alpha-2 selective agonists
 - **decrease of aqueous humor production** (vasoconstriction in ciliary body), increase of uveoscleral outflow
 - CI: IMAO use, children

Antiglaucomatics

- Parasympathomimetics (pilocarpine)
 - **Increase of a.h. outflow by contracting ciliary body**
 - **Increase of a.h. outflow by „angle opening“ (miosis)**
 - **CI: uveitis, bradycardia, hypotension, recent heart attack, gastrointestinal ulcers, epilepsy, parkinson disease**

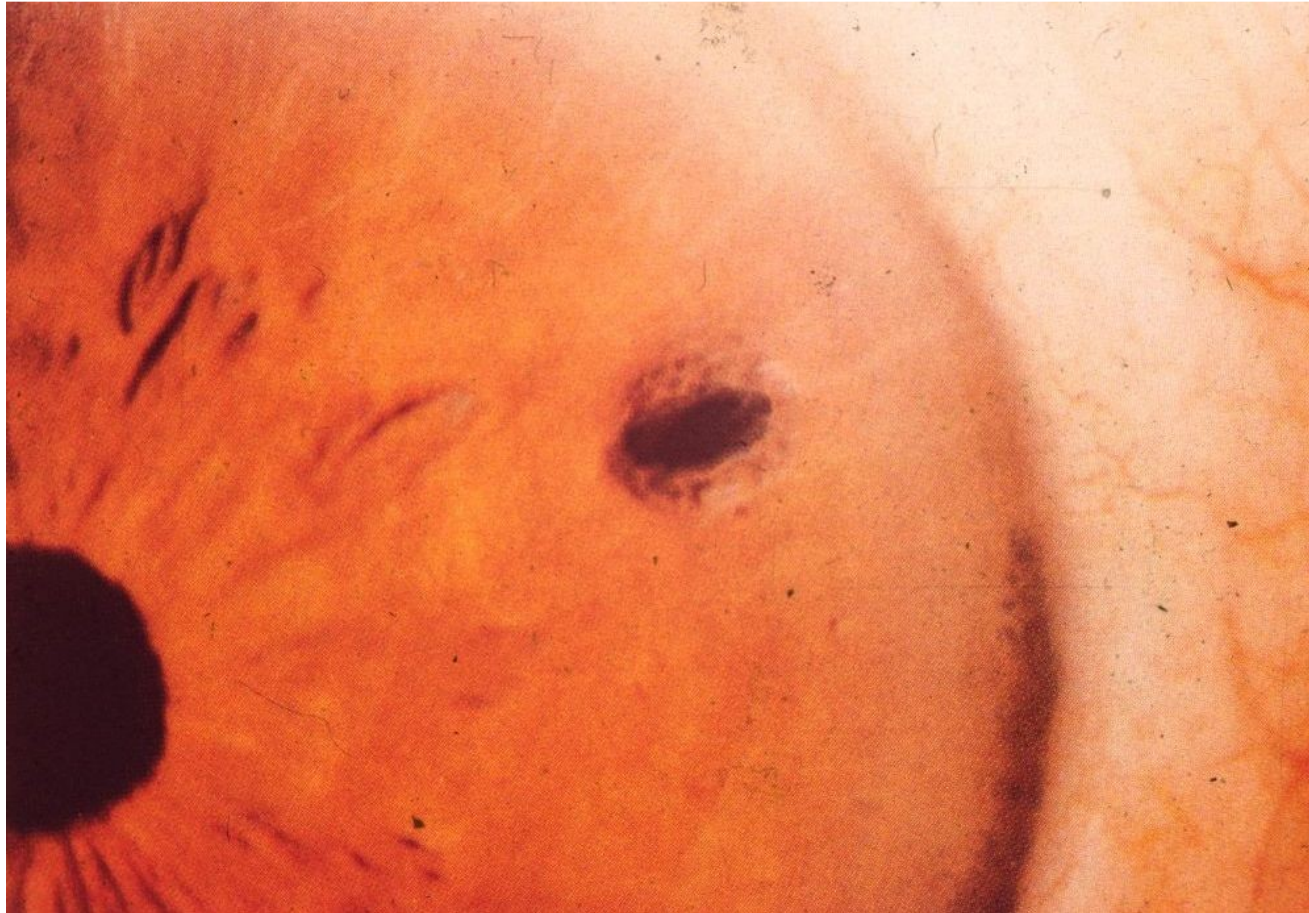
Antiglaucomatics

- Carboanhydrase inhibitors
 - **decrease of aqueous humor production** (CA is an enzyme in ciliary body processes)
 - CI: cornea diseases (endothelial cells decrease)

Antiglaucomatics

- RHO kinase inhibitors
 - New drugs, targeting TM
 - Unavailable in CZ

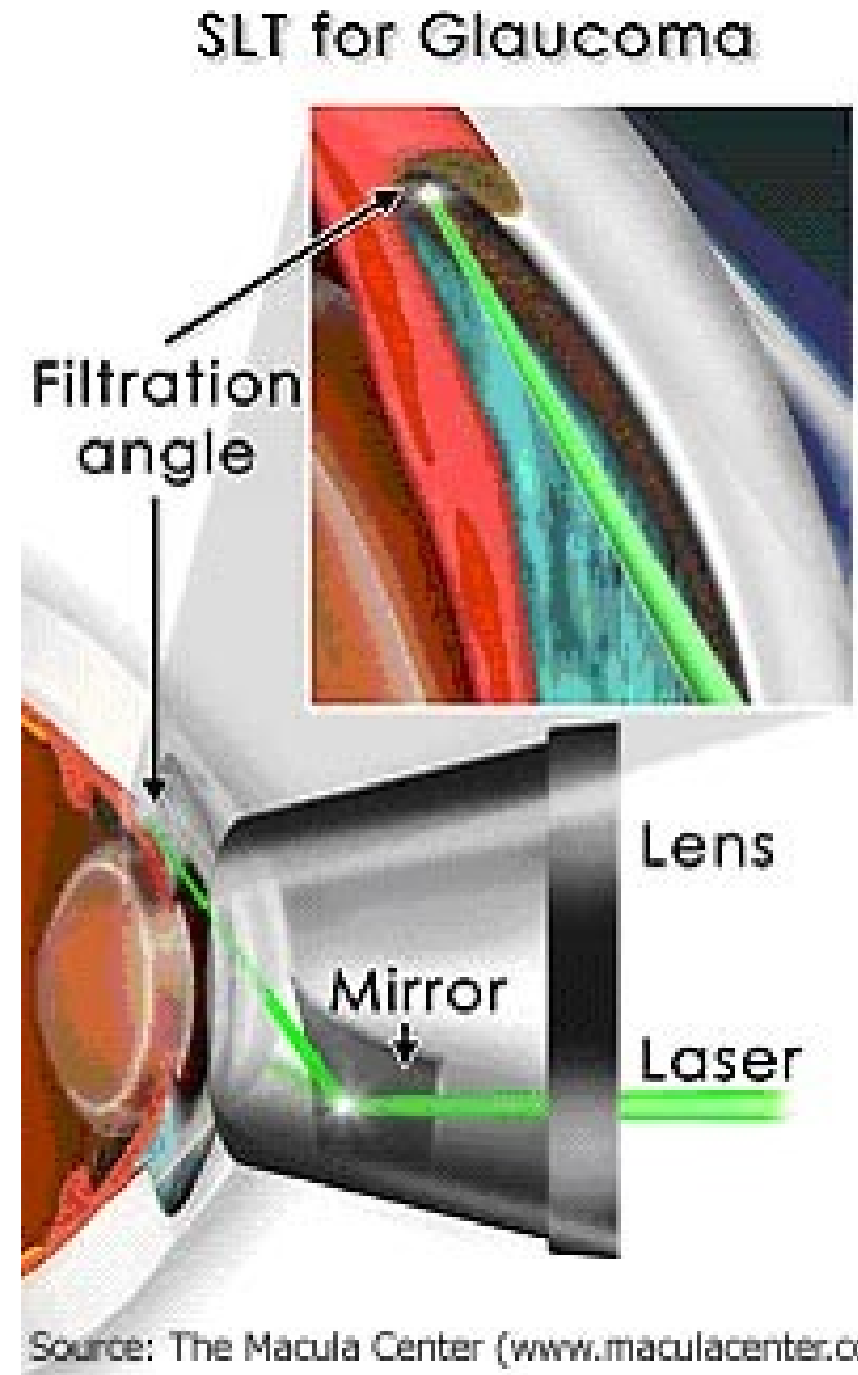
LASER THERAPY



LASER IRIDOTOMY

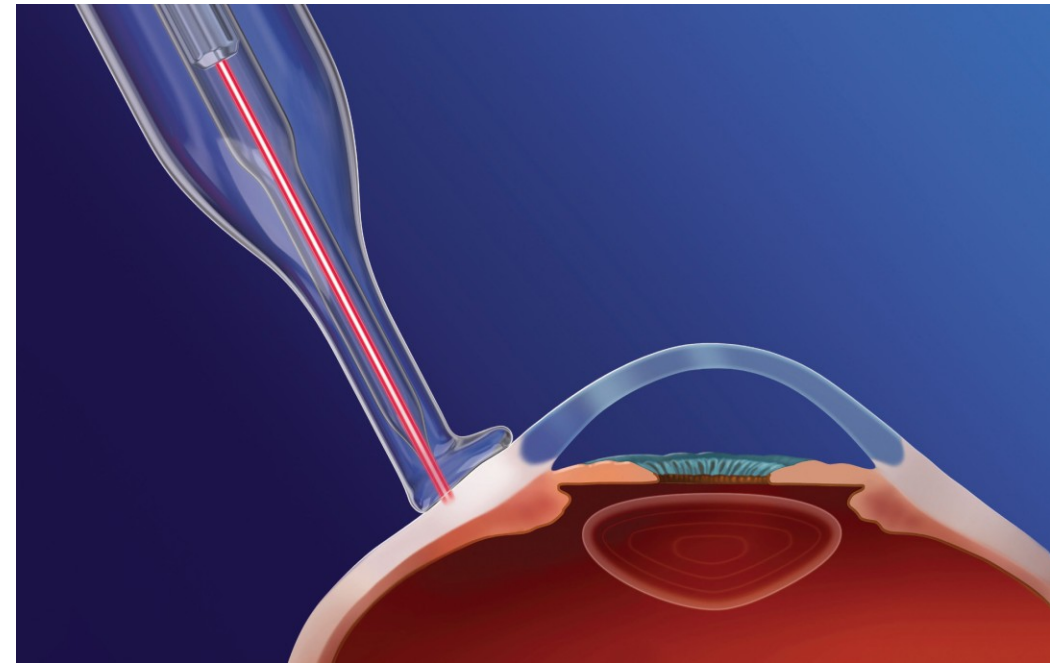
Laser trabeculoplasty

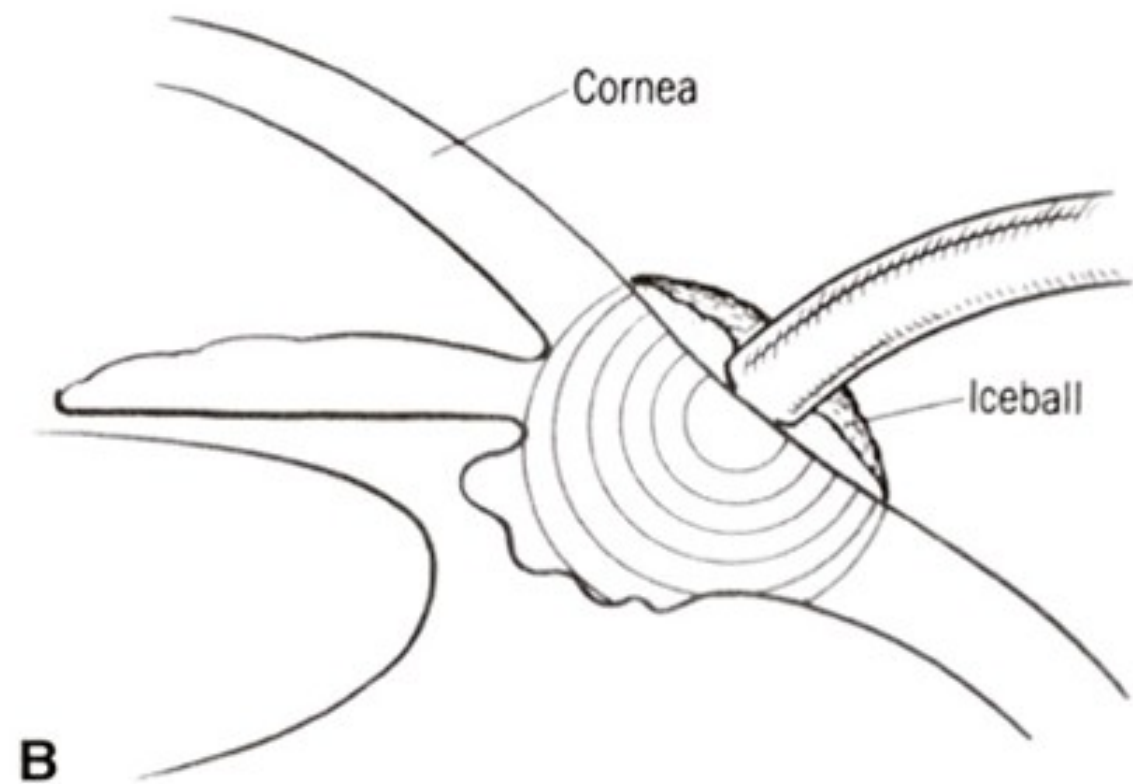
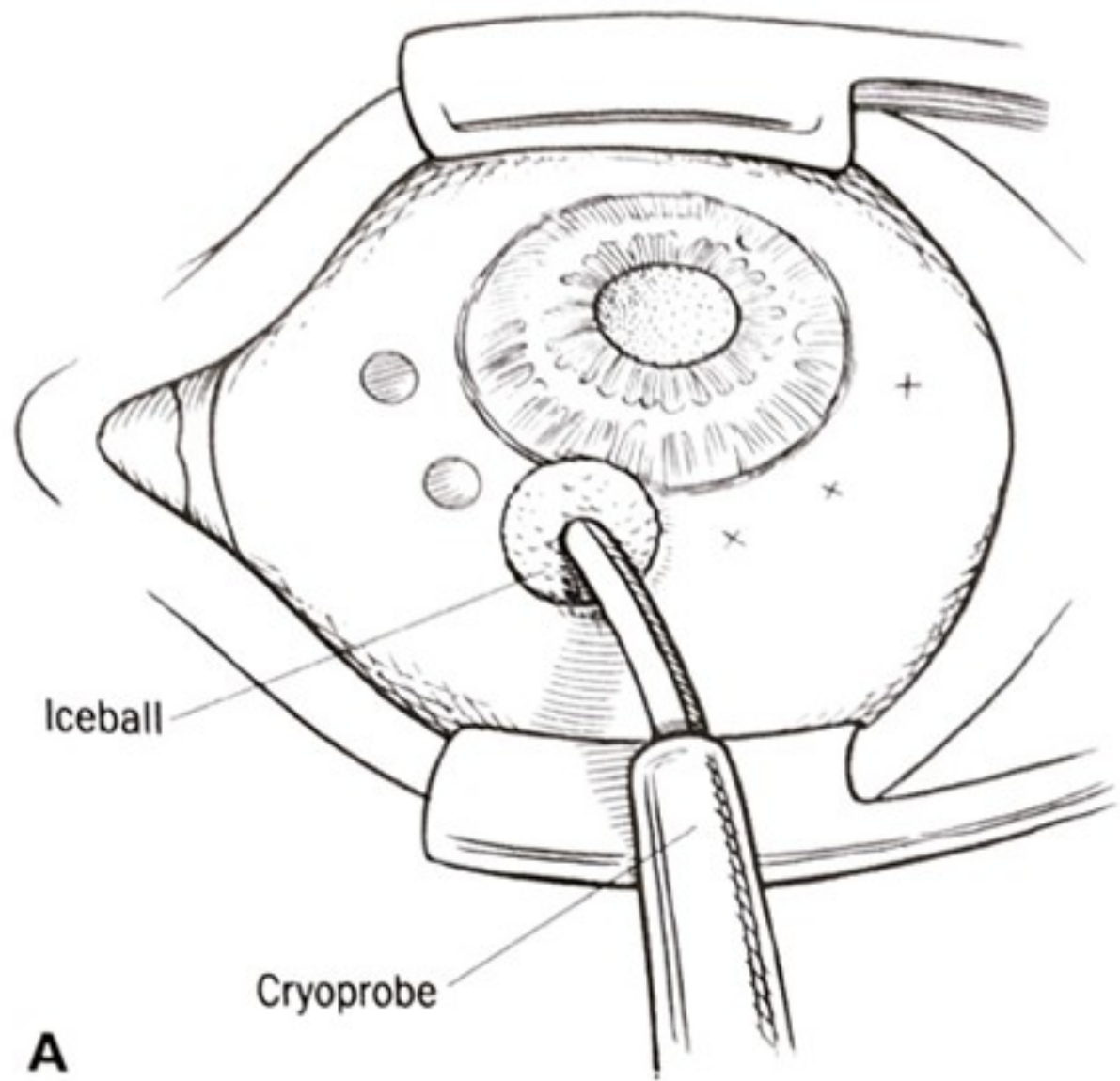
- Argon laser
- 50-100 strikes into the trabeculum in order to make it more permeable for a.h.
 - A space between the strikes is left intact so it opens a little



Cyclophotocoagulation

- a laser procedure that helps lower the eye pressure by targeting the part of the eye that produces fluid (ciliary processes)
 - Destroying part of the ciliary body by laser coagulation
 - Transscleral application of laser beam
 - Indicated in most advanced cases with poor prognosis of vision
- Cyclocryocoagulation
 - Even stronger
- Retrobulbar alcohol application
 - Terminal cases



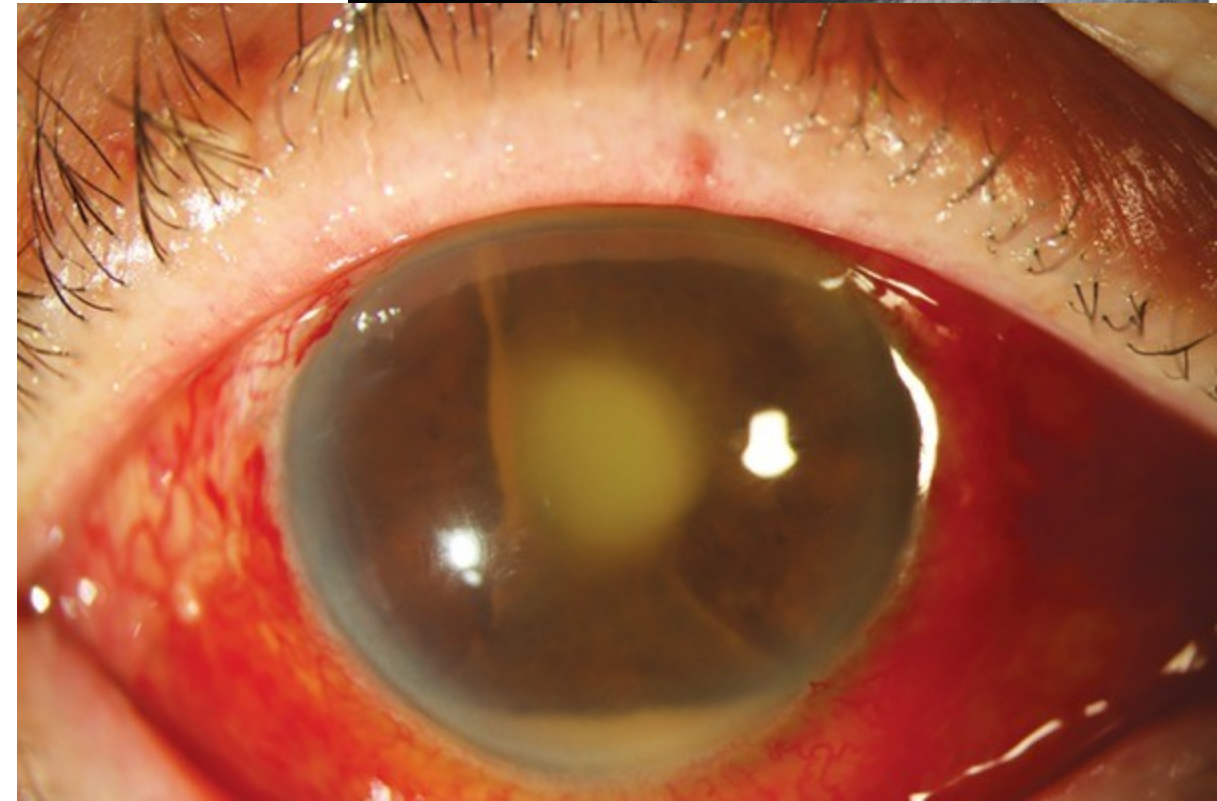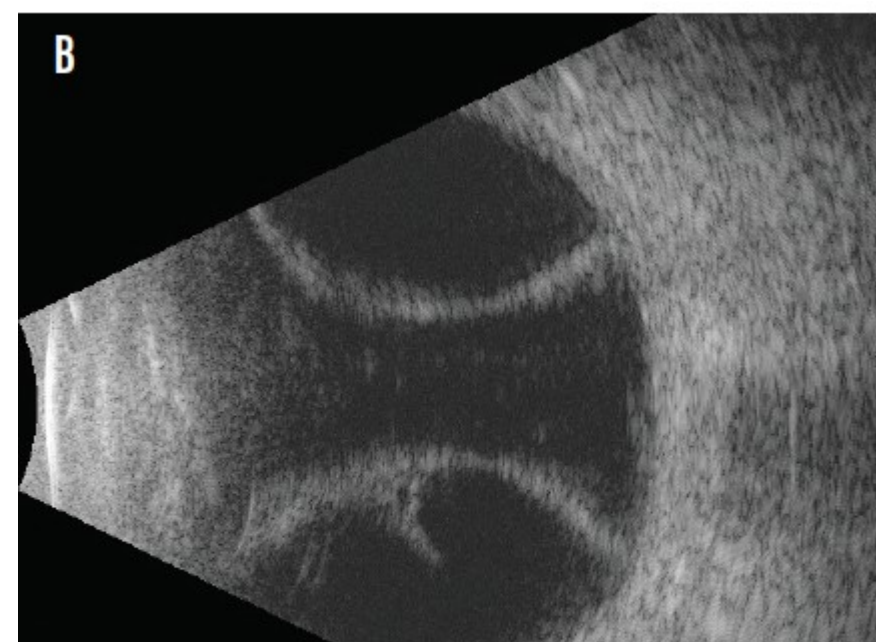


Cyklocryocoagulation - video

- <https://www.youtube.com/watch?v=D5CRcJO3U9M>

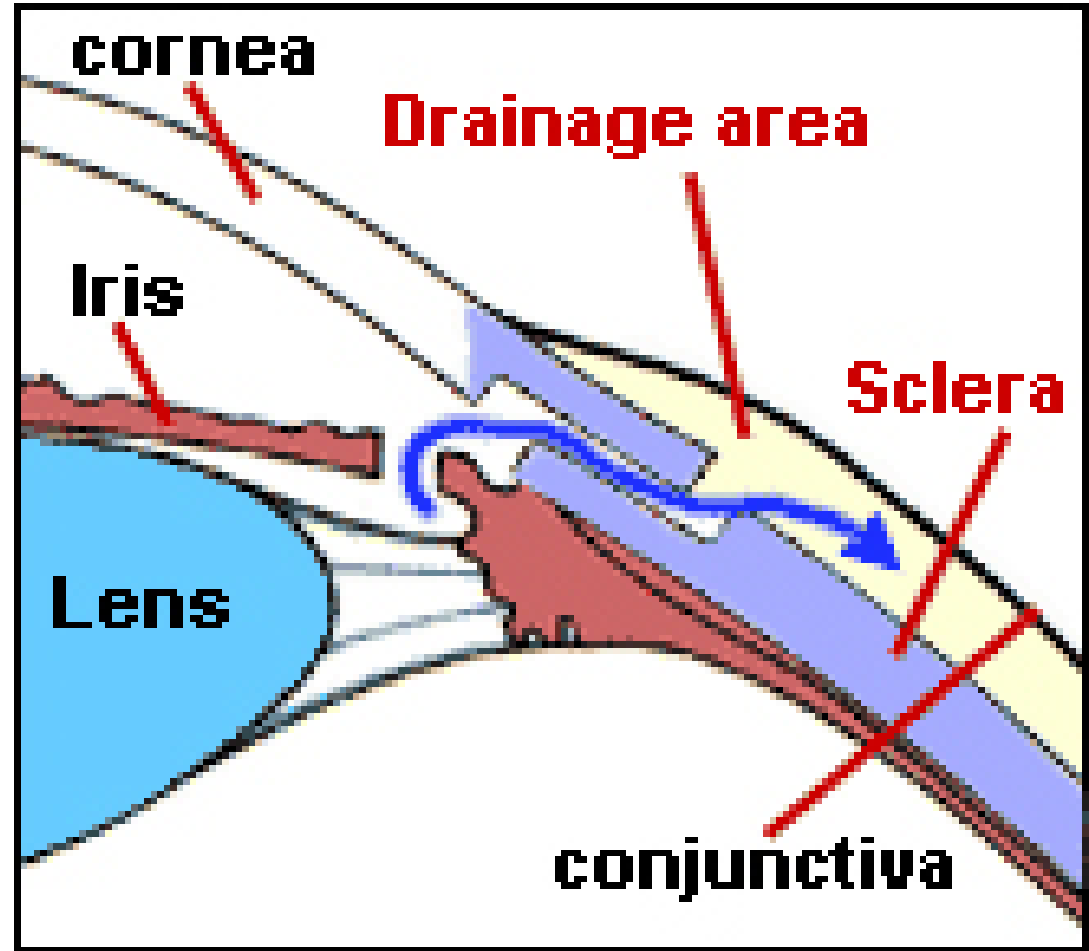
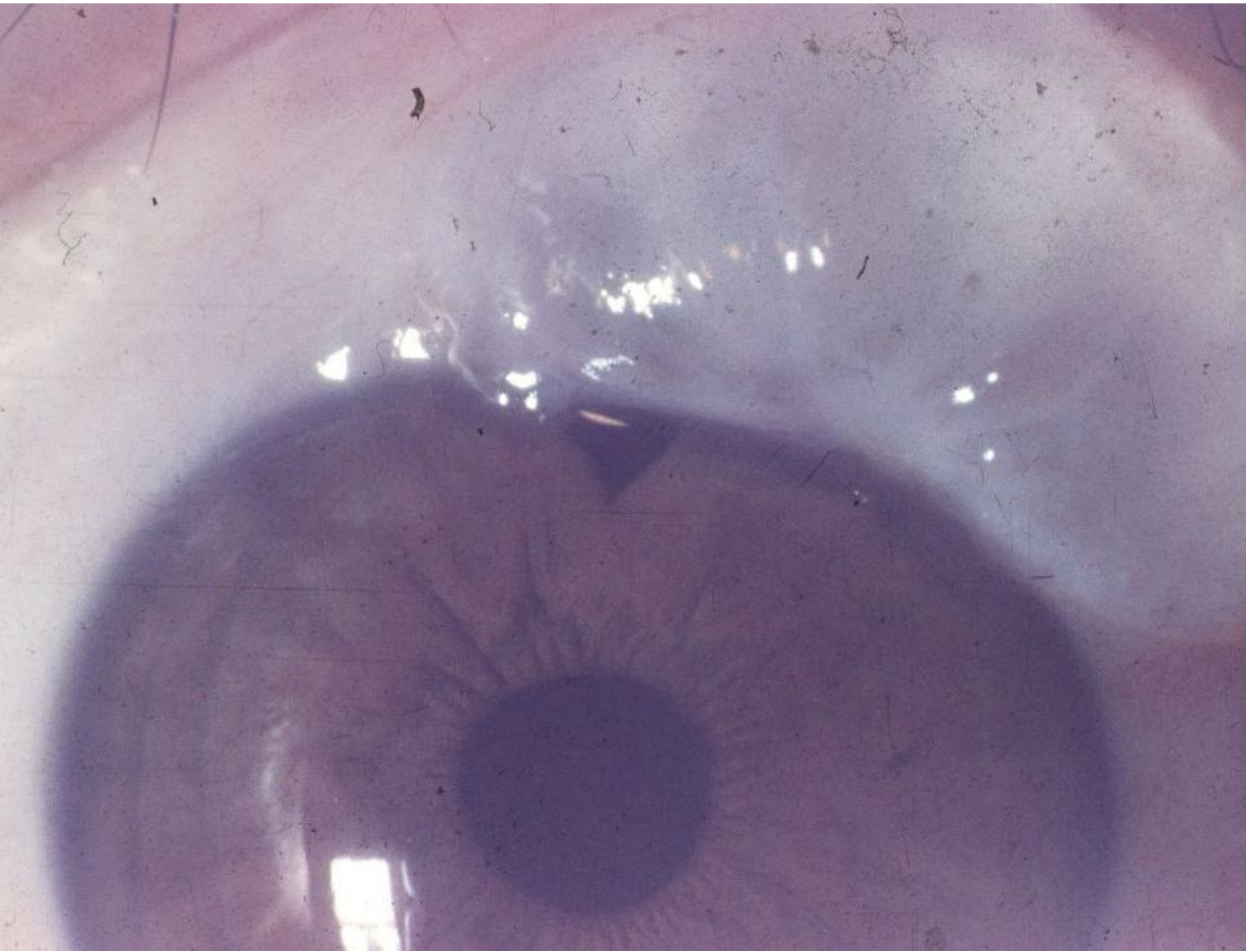
Surgery

- Classical filtration surgery
 - Trabeculectomy
 - Filtration implants
 - Deep sclerectomy (non penetrating)
- MIGS
 - High safety profile
 - Minimal disruption of normal anatomy
 - Ab interno approach

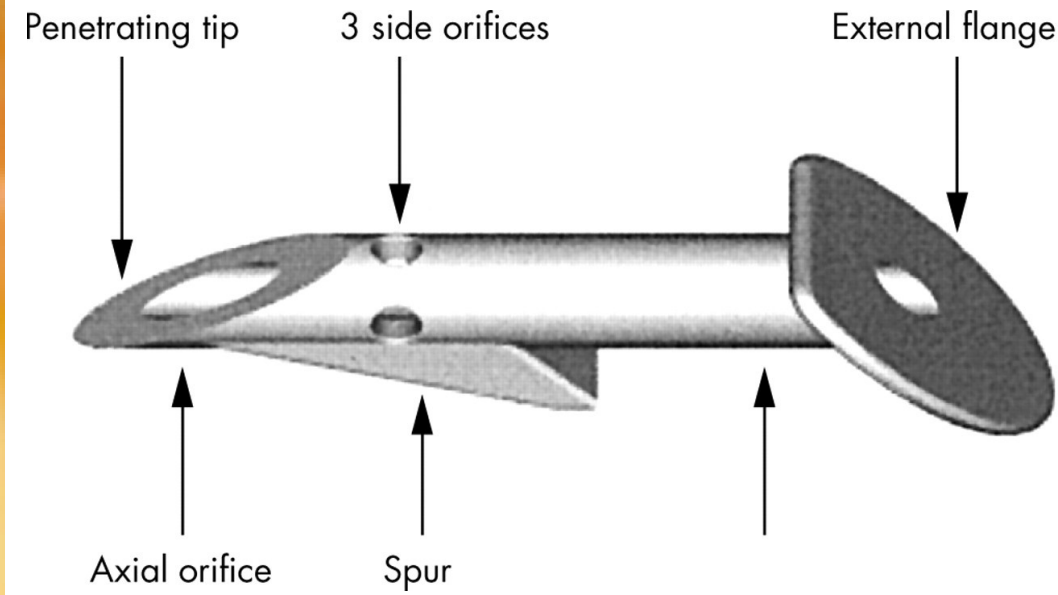
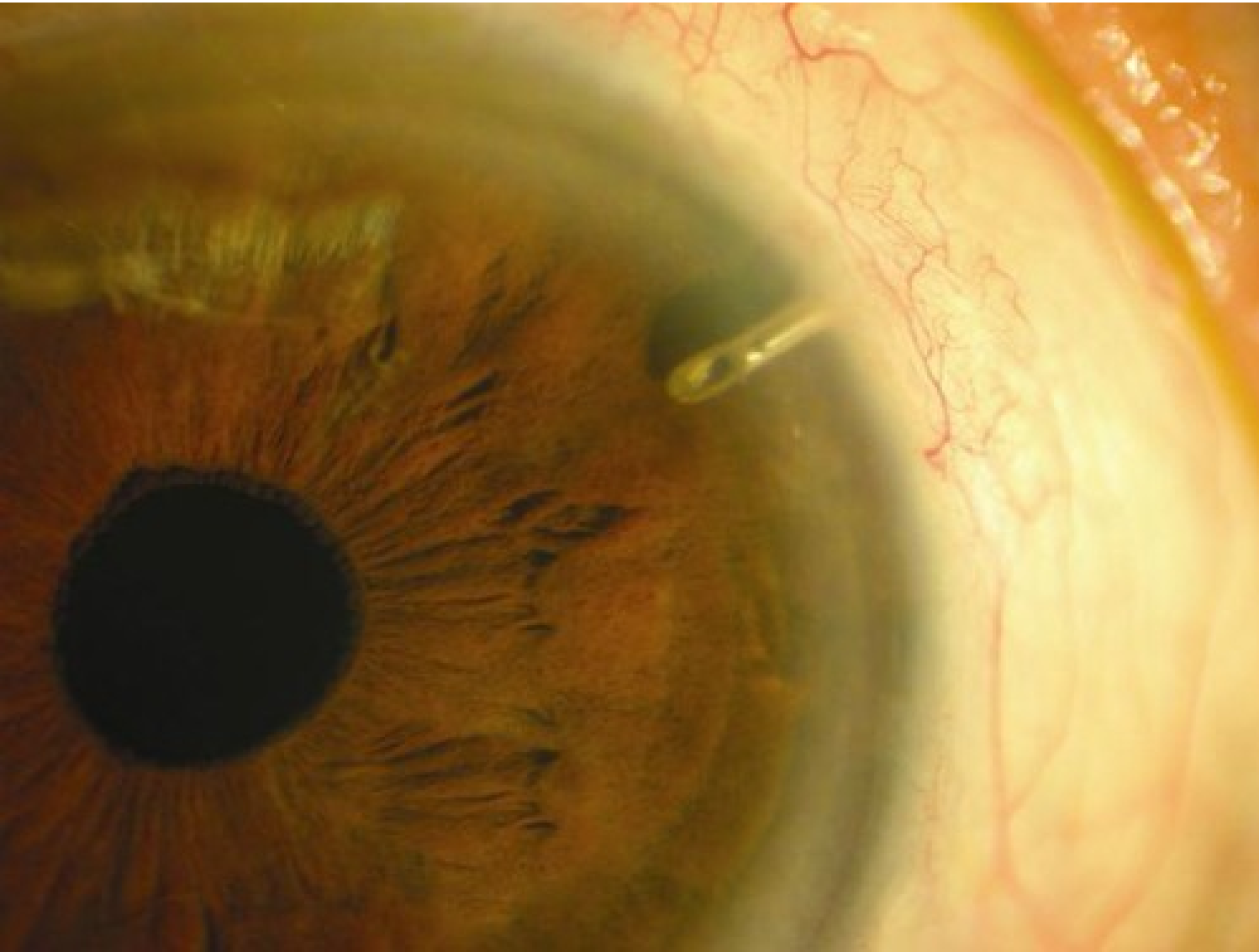


Trabeculectomy

- Main goal is to make arteficial pathway for the a.h. outside of the eye



Express implant

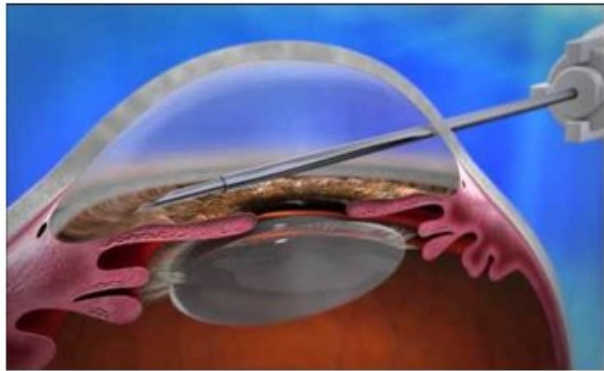


Express implant - video

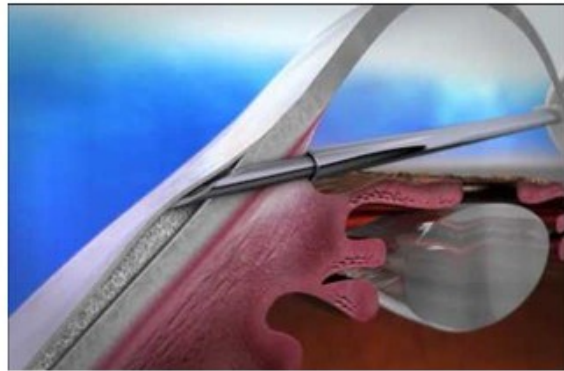
- https://www.youtube.com/watch?v=Eay9oxuCosM&ab_channel=Dr.Adri%C3%A1nHern%C3%A1ndezMart%C3%ADnez

MIGS – Xen implant

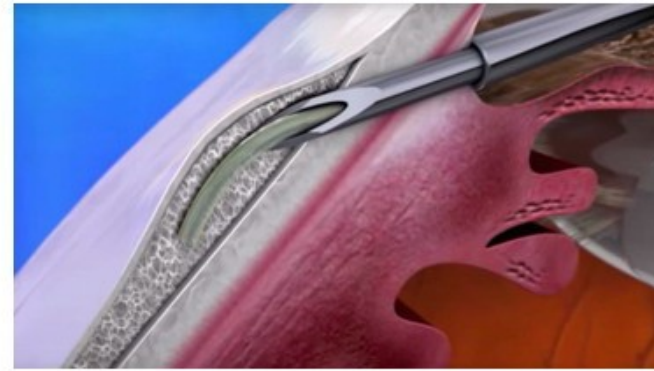
Simple Steps of Implanting XEN Glaucoma Tube at PVSC



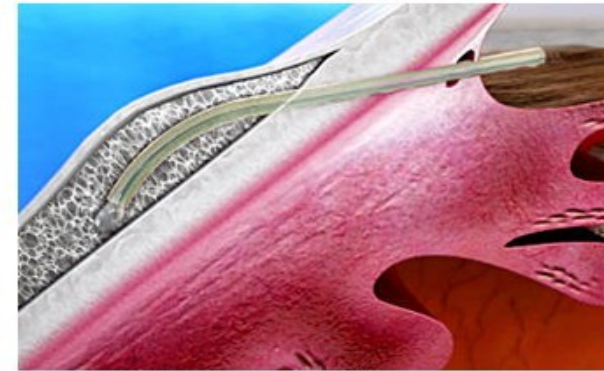
Step 1: The XEN injector is passed through the Anterior Chamber



Step 2: The XEN injector is passed through the Sclera into the Subconjunctival space

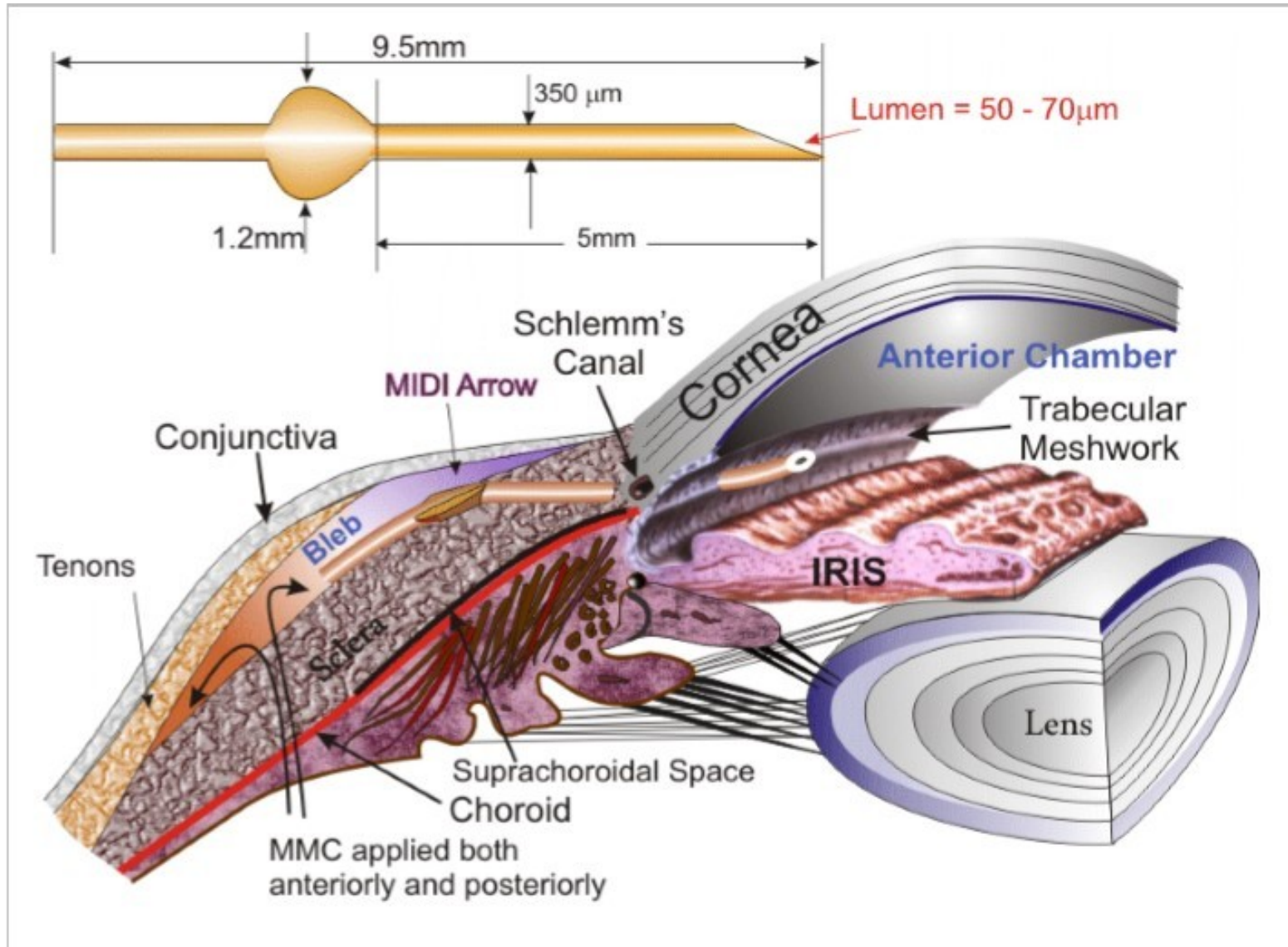


Step 3: The XEN Tube is pushed into the Subconjunctival Space to connect it to the Anterior Chamber



Final The XEN Tube is in proper position draining the Anterior Chamber fluid into the Subconjunctival space

MIGS – Preserflo implant



Part 7: glaucoma essentials

GLAUCOMA ESSENTIALS

- **Glaucoma \neq elevated IOP!!**
- **BUT**, glaucoma is usually associated with high IOP (x normal tension glaucoma)
- Late symptoms onset
- Affects 60.5 million people worldwide

GLAUCOMA ESSENTIALS

- accounts for 8% of all cases of blindness and **is the leading cause of irreversible blindness worldwide**
- Early detection is essential
 - Educate patients with positive family history



Normal Vision



Early Glaucoma



Advanced Glaucoma



End Stage Glaucoma

GLAUCOMA ESSENTIALS

Thank you