

# ORBIT

MUDr. Veronika Matušková,  
Ph.D., FEBO

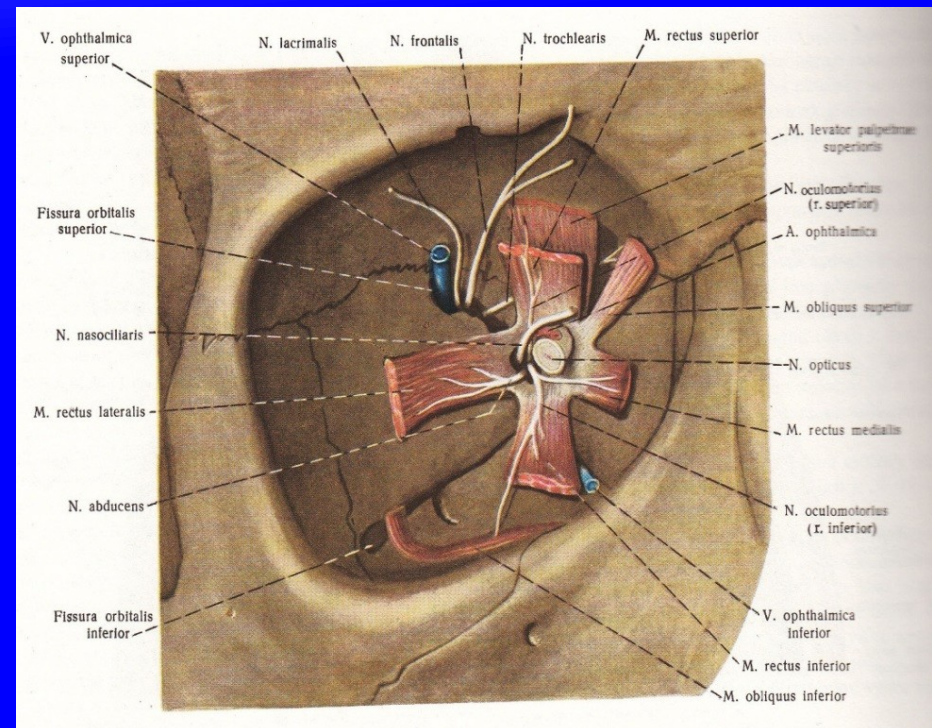
# Fractura orbitae

## Anatomy

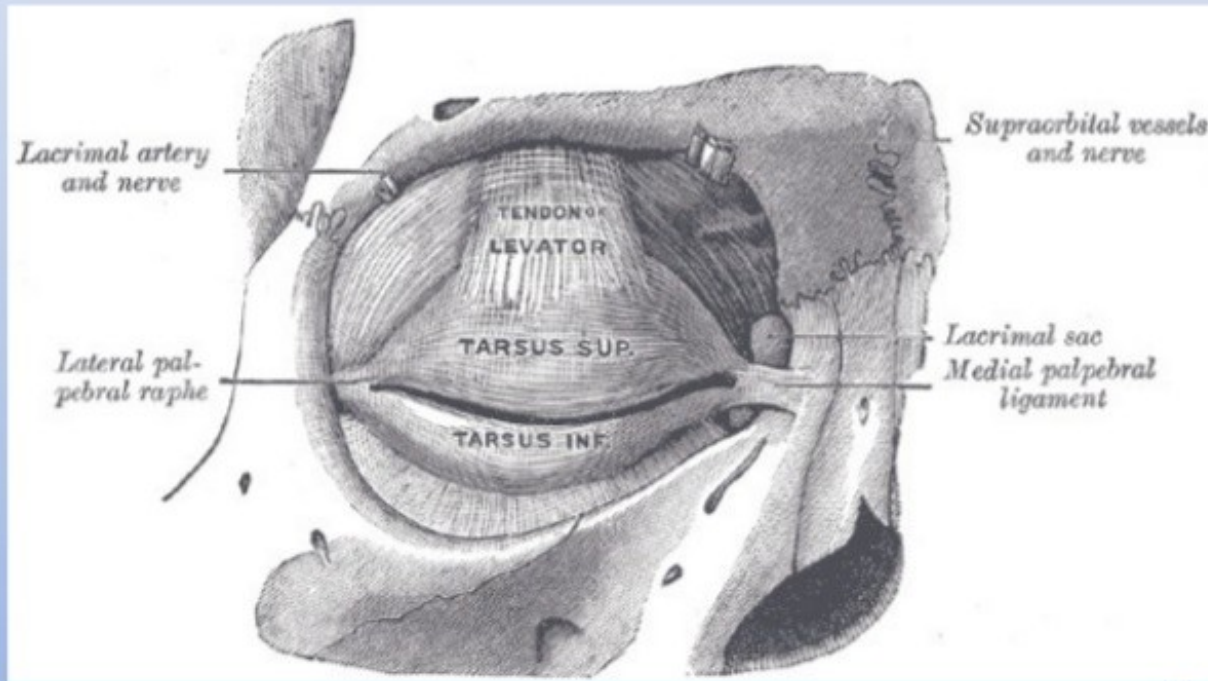
Canalis opticus

Fissura orbitalis superior

Fissura orbitalis inferior



# Orbital septum



# Fracturae of orbit

- ❖ Roof - frontobasal, orbitofrontal
- ❖ Lateral wall – orbitozygomatic
- ❖ Medial wall – orbitoetmoideal
- ❖ Floor – retromarginal, „blow out fracture“

# Fracture of roof

❖ Cause – falling on a sharp object, blow to the Forehead (head in bend)

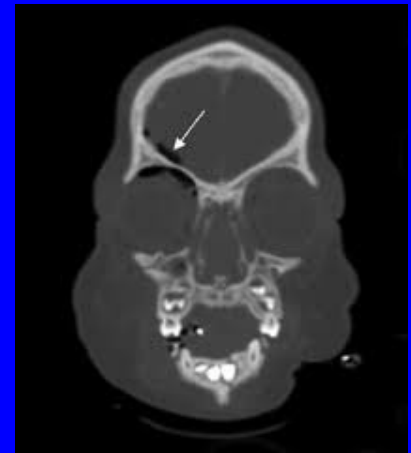
Signs: hematoma of the upper eyelid, disturbance of craniofacial bones

Small fractures require no treatment

Fractures extending into the anterior cranial fossa - competence NCH

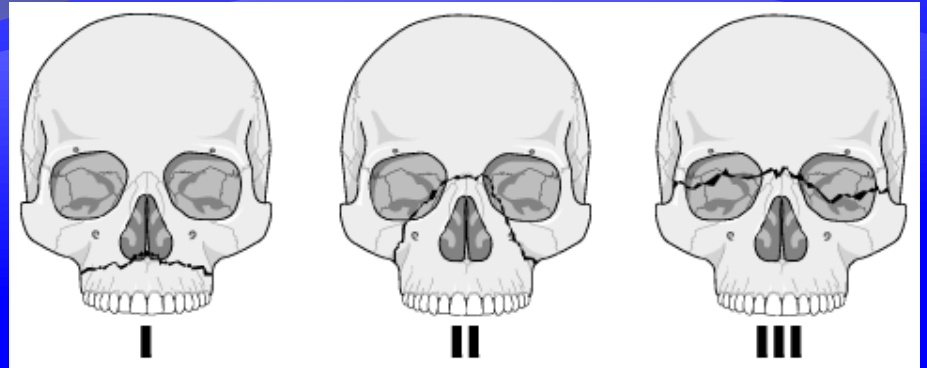
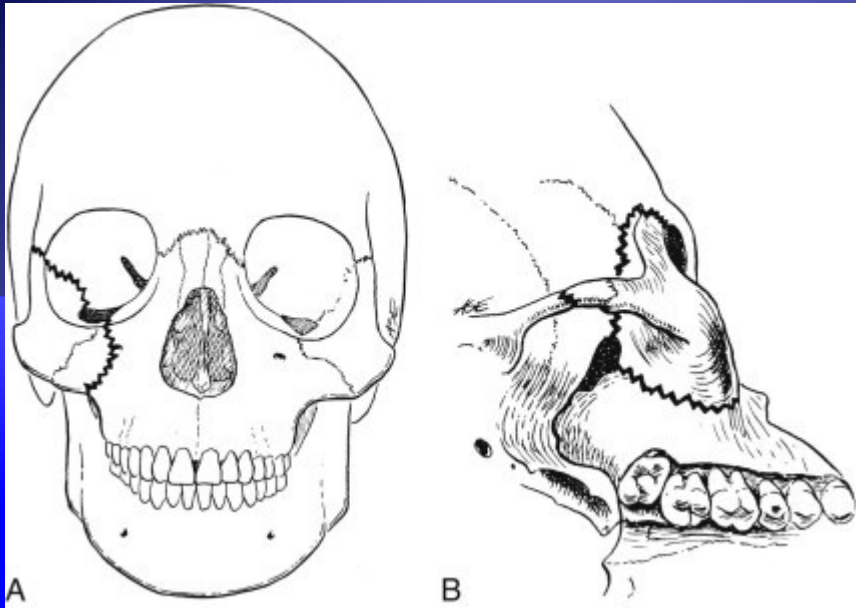
Damage visual functions - ischemic neuropathy n. II

Therapy ischemic neuropathy: decompression optical channel or megadoses of methylprednisolone



# Fracture of lateral wall

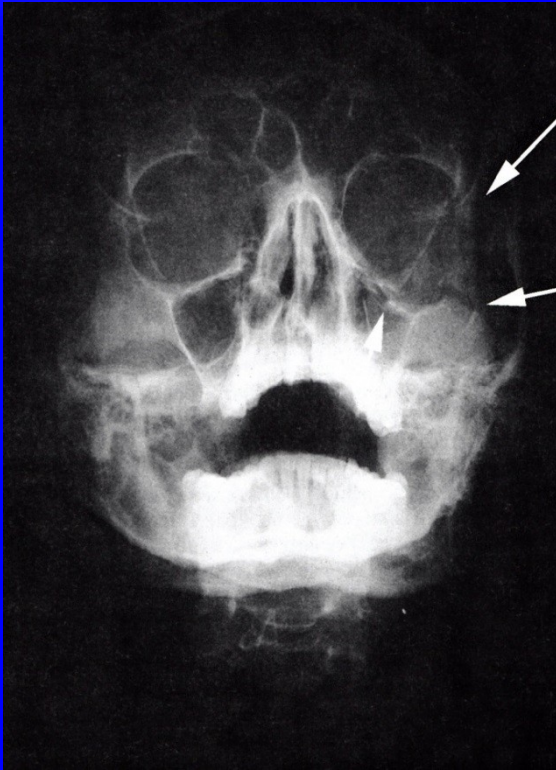
- ◆ Cause - blunt trauma on cheekbones
- ◆ Usually part of zygomaticomaxilárniho complex (ZMK)
- ◆ Symptoms: pain, hematoma of eyelids, conjunctiva chemosis, visual disturbances and eyeball displacement (diplopia, enophthalmos)
- ◆ Dg. - CT, NMR
- ◆ Treatment - Indications for surgery is persistent diplopia, limited mouth opening and flattening of the facial region



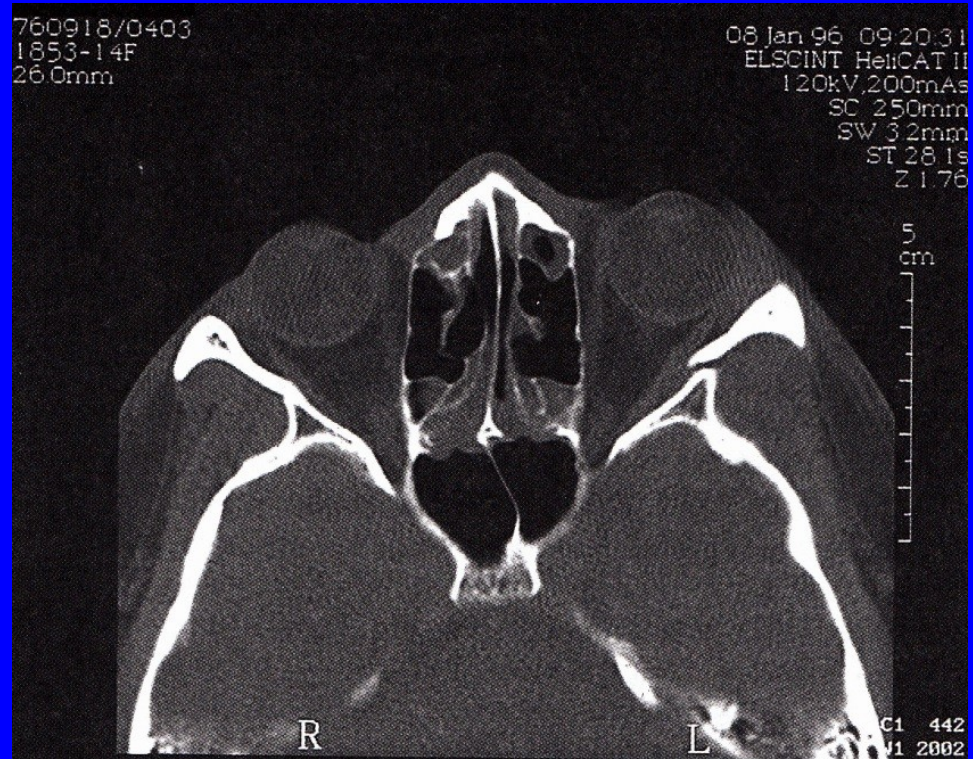


# Orbit fracture

Fractura of ZMK



Isolated fracture of lateral wall





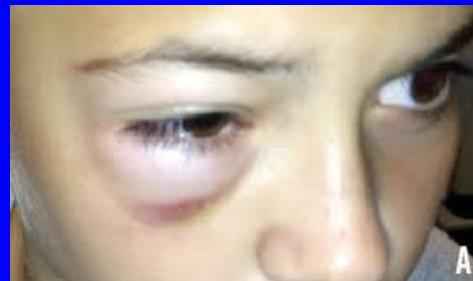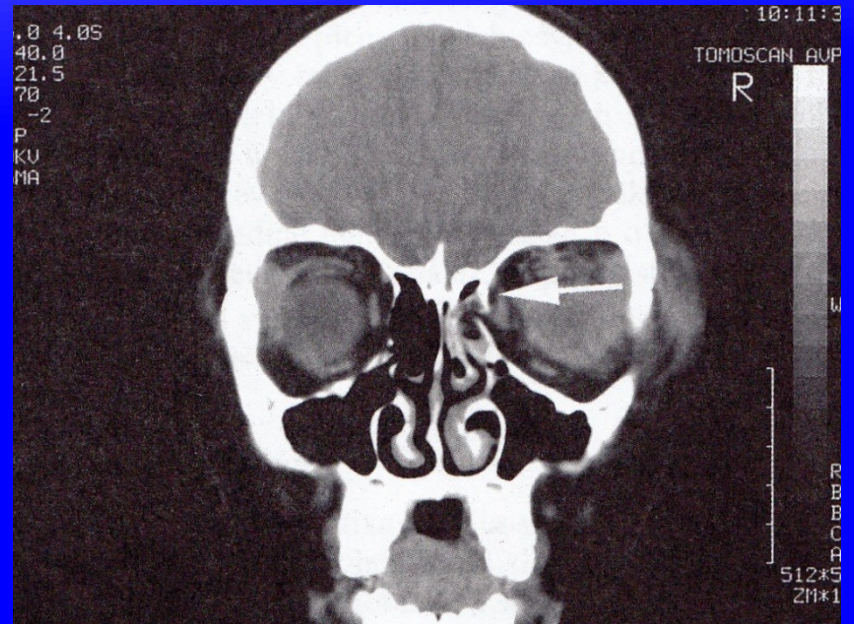
# Medial wall fracture

Cause - blunt trauma

Symptoms - hematoma eyelid,  
subcutaneous emphysema  
develops on blowing nose

Dg. - CT

Treatment – conservative

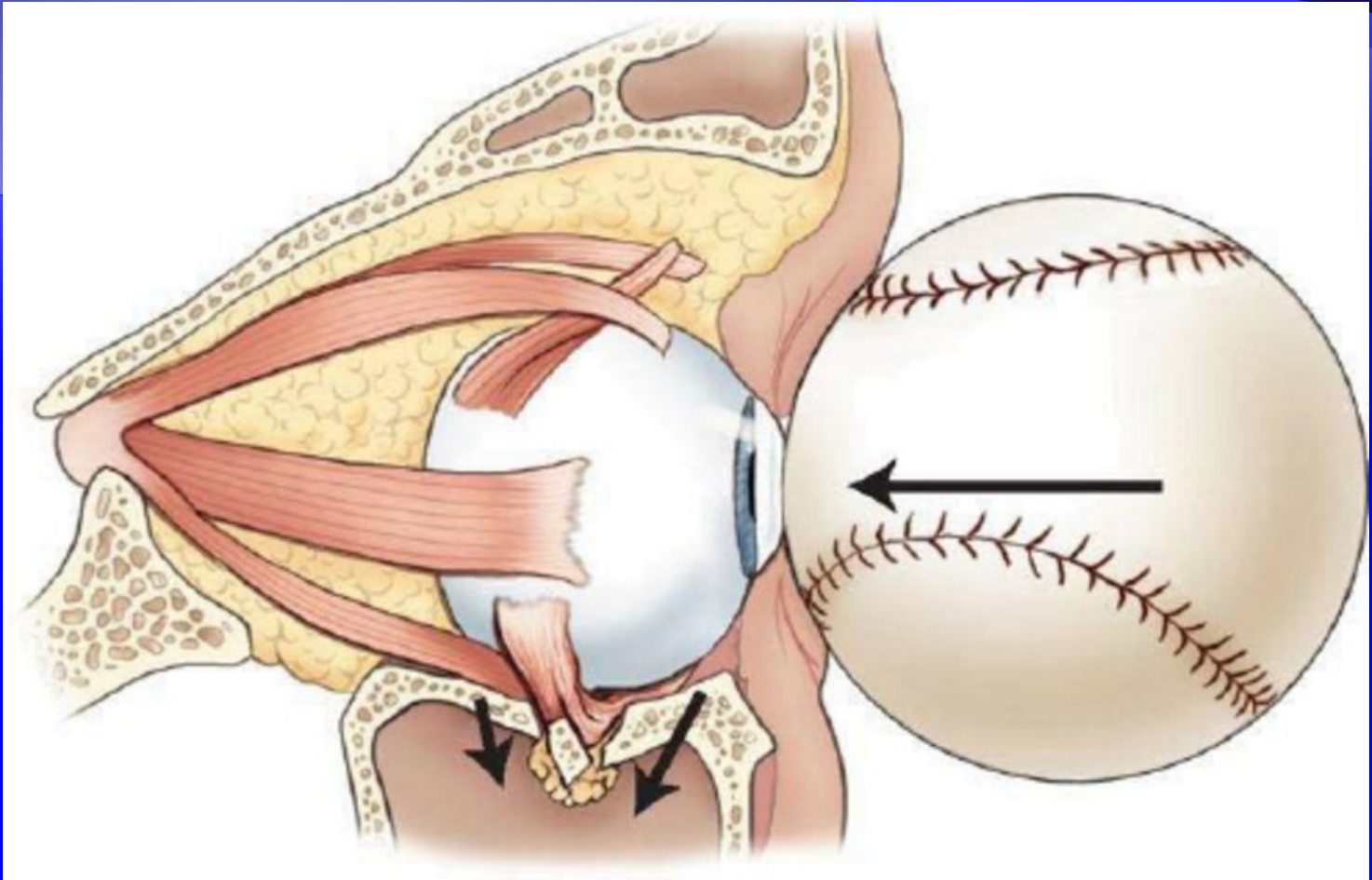


# Blow out orbital floor fracture

Cause – sudden increase in the orbital pressure by a striking object ( larger than 5 cm)

The symptoms - swelling, hematoma of eyelids  
pseudoptóza, diplopia, inability to move the eyeball  
upwards (seriously elevation).

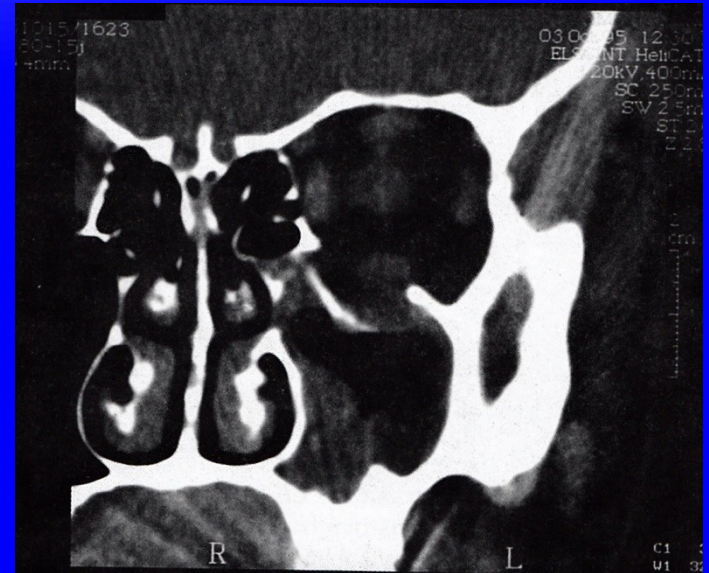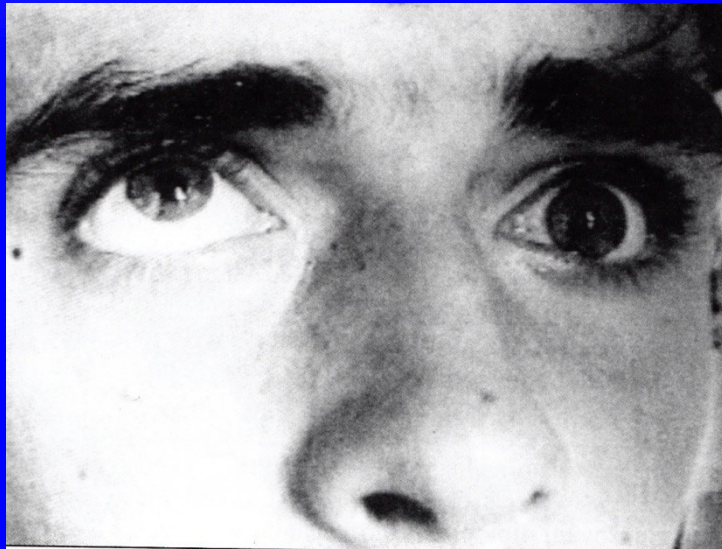
Paresthesia, hypoesthesia in n.infraorbitalis.



# Blow out orbital floor fracture

- ◆ Dg. - X-ray orbit, CT
- ◆ Symptom - hammock - wide breaking orbital floor. Significant enophthalmos, without incarceration of m.r. inf.  
Symptom - hanging drop - fissure fracture with soft tissue entrapment
- ◆ Double diplopia  
Test passive duction  
Treatment - Surgery – in case of entrapment (in 3-5 days -resolved orbital hematoma).

# Blow out orbital floor fracture





# Disease of lacrimal gland

**Acute dacryadenitis** – rare, in isolation

S: swelling of the lateral aspect of the eyelid –  
characteristic „S“ shaped ptosis

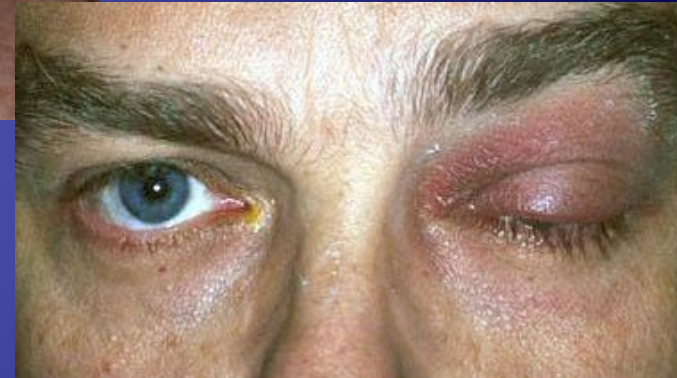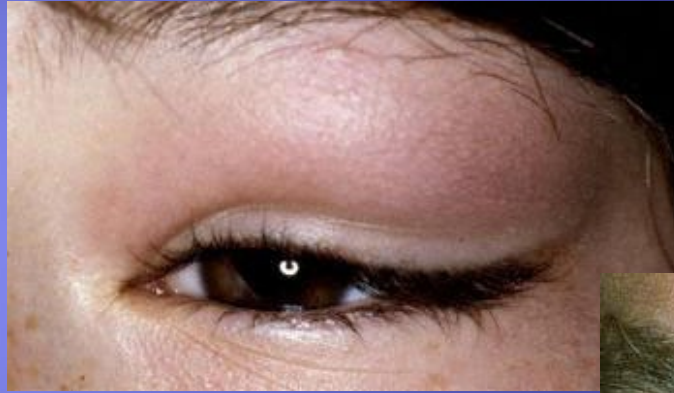T: usually is not required

**Tumors:** Lacrimal gland carcinoma - high  
mortality and morbidity

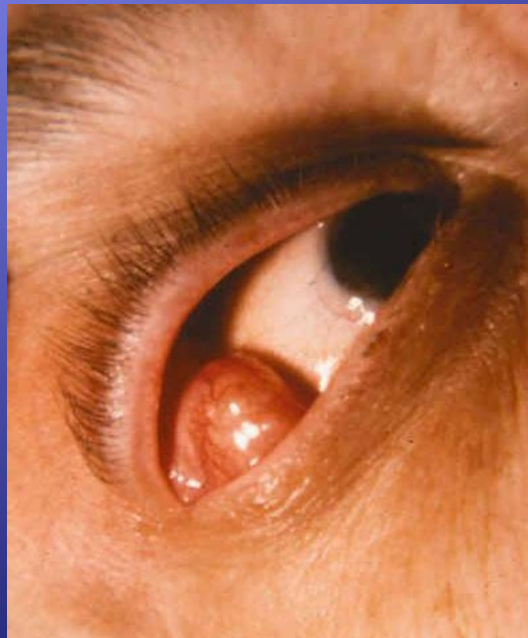T: surgery and radiotherapy

# Disease of lacrimal gland

❖ Dacryadenitis

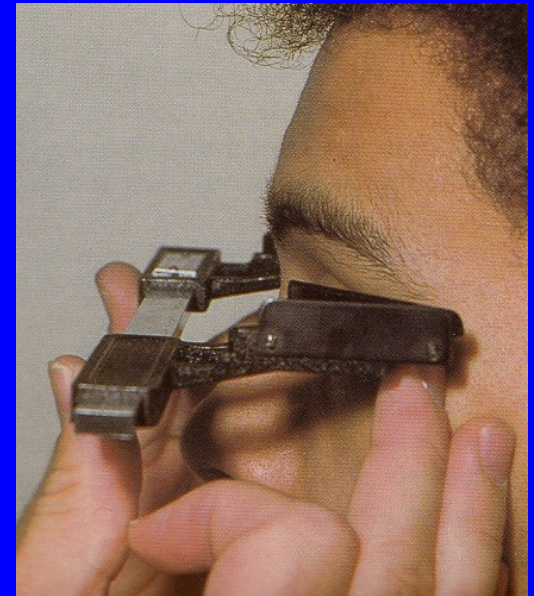


❖ Pleomorphic adenoma



# Helter exophthalmometr

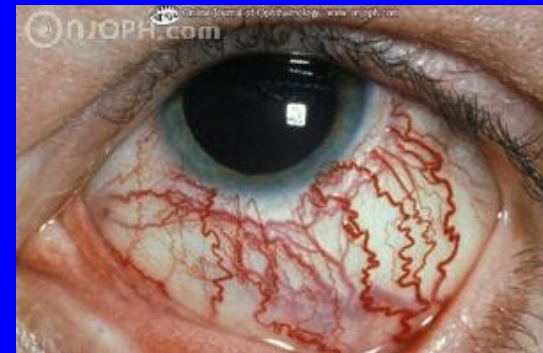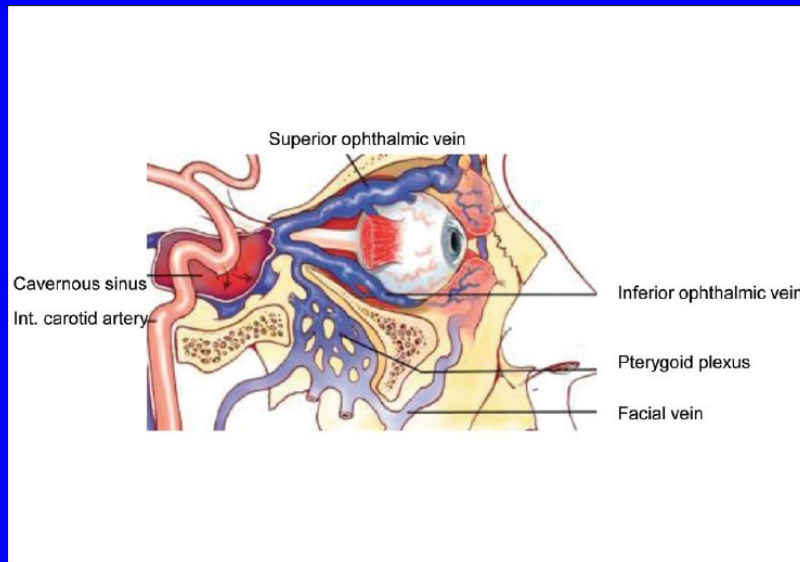
- ◆ Measurement of the position of the eye  
Hertel exoftalmometr measures the distance corneal apex - the external edge of the bony orbit (diameter 17 mm, above 20 - pathology)
- ◆ Side difference to 2 mm - physiological
- ◆ Always should be recorded the distance of the outer edges of the orbits





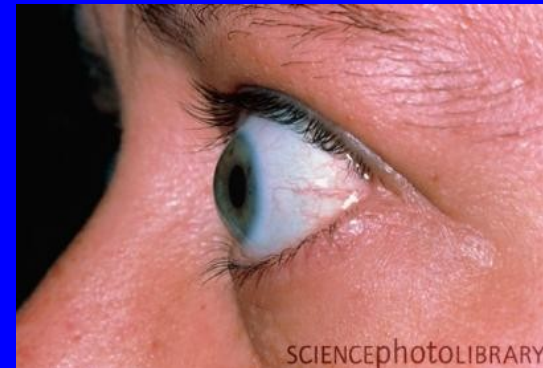# Disease of orbit

- ◆ Pulsatile proptosis - the carotid cavernous fistula – abnormal communication btw vein and artery ( carotid artery and orbital cavernous sinus vein )



# Disease of orbit

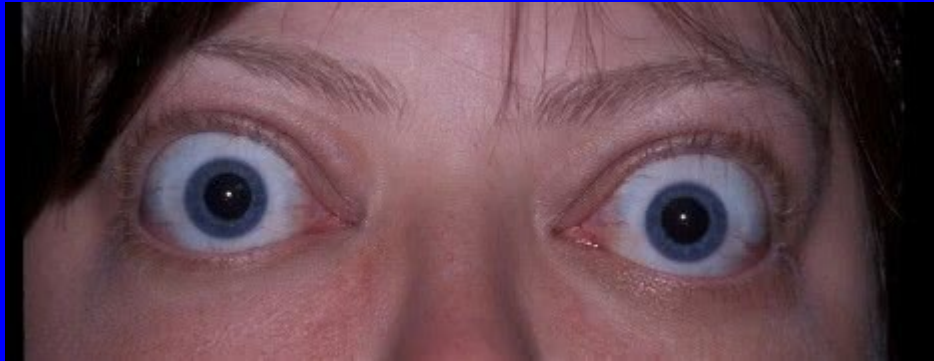- ◆ Intermittent proptosis - a symptom of vascular malformations in orbit (varix) - Valsalva maneuver
- ◆ Pseudoproptosis - high axial myopia enophthalmos





# Disease of orbit

- ❖ Axial proptosis - only in the sagittal plane (Graves' disease, orbitocellulitis )
- ❖ Paraaxial proptosis - lesions of peripheral lateral space (lacrimal gland tumors, frontoetmoidal mucocele, tumors of PN sinus)
- ❖ Bilateral proptosis - thyreotoxicosis and EO



# Examination of orbit

- ❖ X ray
- ❖ Ultrasound
- ❖ CT
- ❖ NMR

# Inflammation of orbit

## Etiopatogenesis:

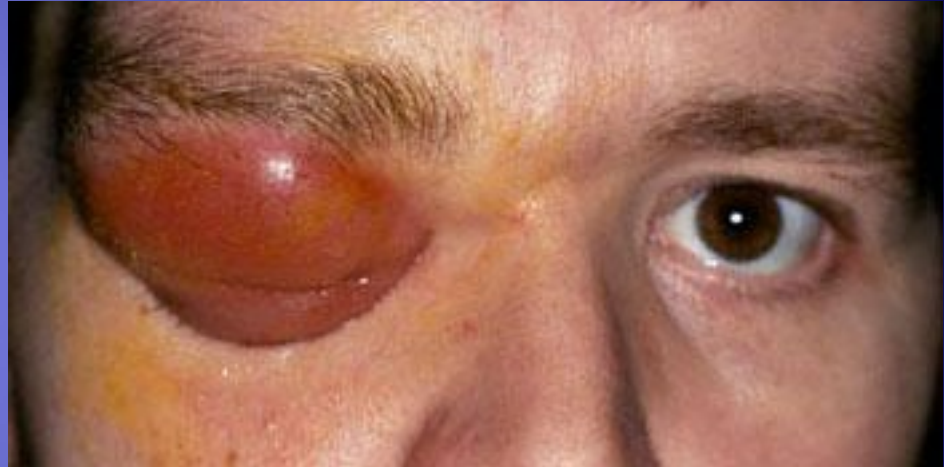Microbial infection  
Immune responses  
hyperergická-allergic-  
type  
Endocrine  
ophthalmopathy (Graves  
disease)

## Microbial infections:

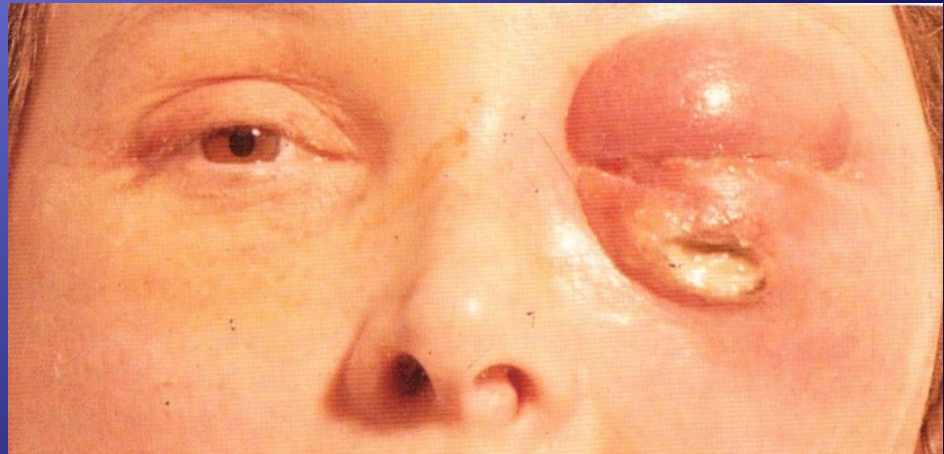orbitocellulitis  
phlegmone orbit  
abscess of orbit  
Tenonitis  
myositis orbitalis  
Inflammatory  
pseudotumor of the orbit

# Inflammation of orbit

❖ Orbitocelulitis



❖ Abscess of orbit

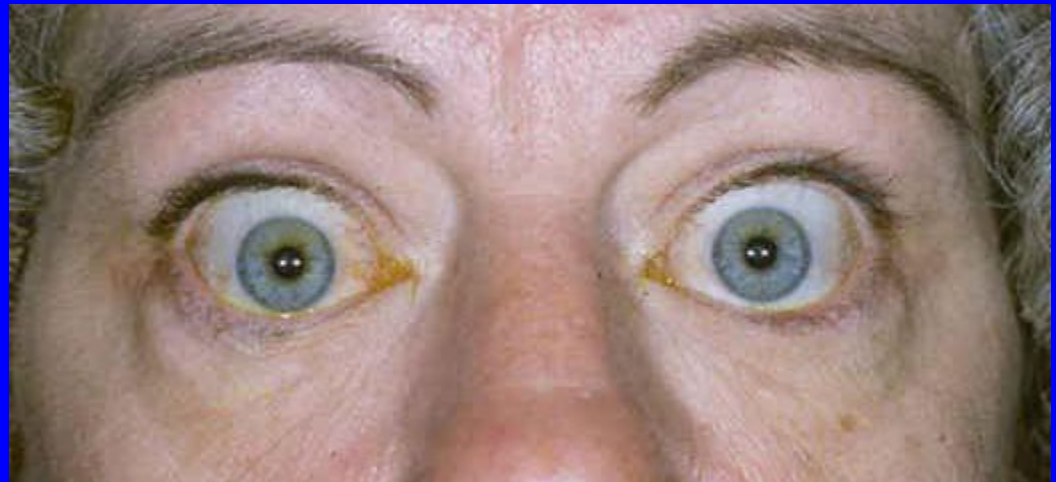
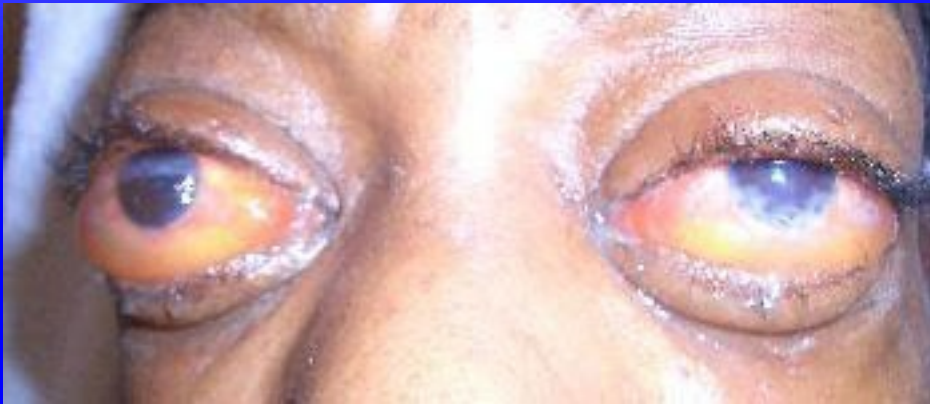

# Endocrine orbitopathy (EO)

- ❖ Autoimmune disease with the formation of a binding antibodies on cells of thyroid gland
  - Orbital fat
  - Subcutaneous tissue front of the lower leg
- ❖ **Clinical picture:**
  - Eyelid symptoms
  - Eye movement disorder
  - Pseudoglaukom
  - Exophthalmus
  - Neuropathy n.II



# Endocrine orbitopathy (EO)



# Endocrine orbitopathy (EO)

Diagnosis:

laboratory findings

Imaging (ultrasound B scan, NMR, CT)

Test passive duction (muscle fibrosis)

Complications of EO - the cornea exposure, elevated intraocular pressure, changes in the orbit (neuropathy)

❖ Treatment:

Endokrinologist

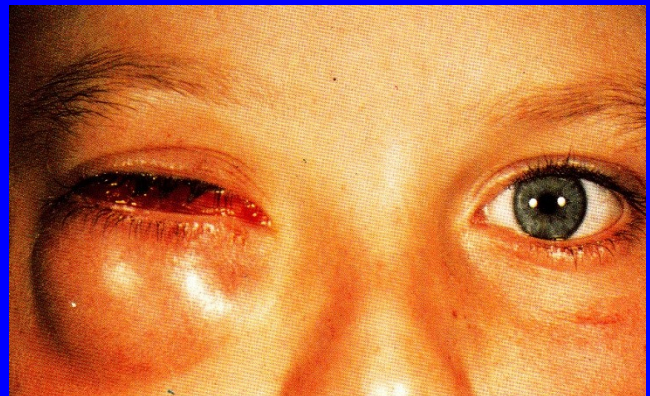
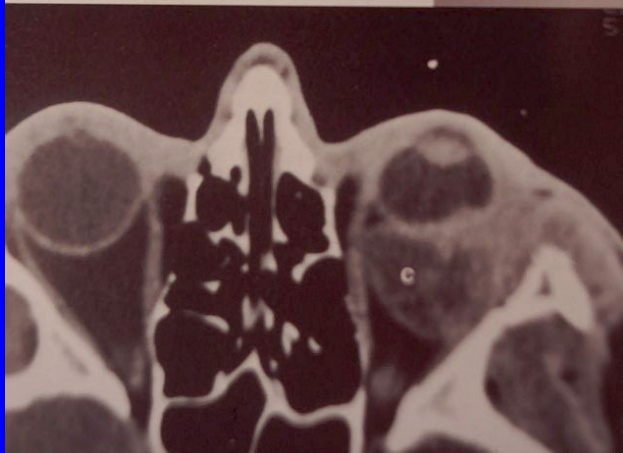
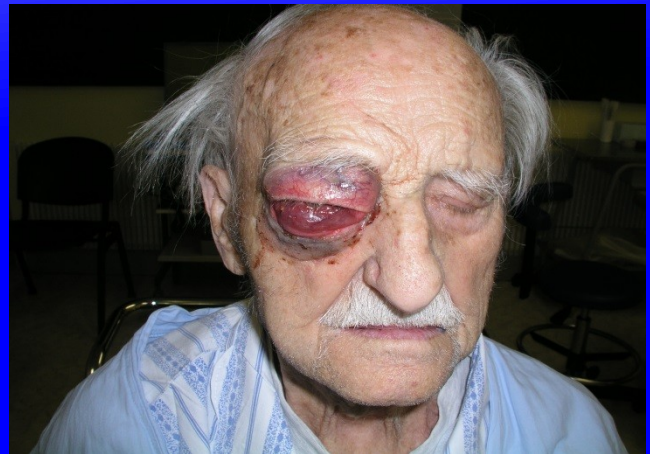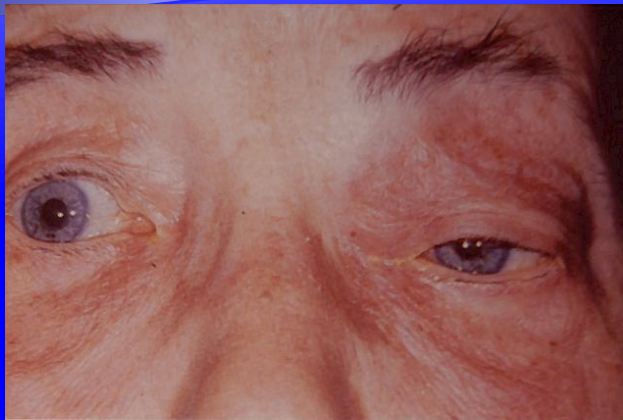❖ Ophthalmologist - serious ocular complications - megadoses of steroids, orbital decompression, the treatment of ocular disorders

# Tumours of orbit

- ❖ Benign and malignant
  - primary
  - secondary
  - metastatic

Primary  
vascular tumors  
dermoid cyst  
nerve tumors  
lacrimal gland tumors  
meningiomas orbit  
malignant lymphomas  
rhabdomyosarcoma

# Tumours of orbit

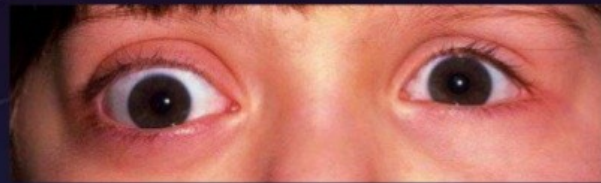

# Tumours of orbit

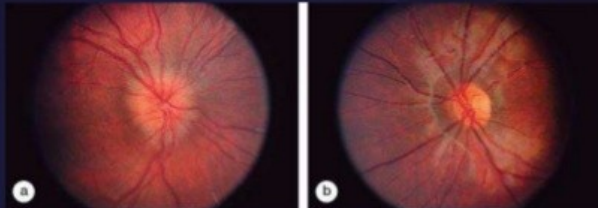
Secondary  
tumors of PN sinuses  
carcinomas of the eyelids  
Extrabulbar expansion of  
intraocular tumors  
metastatic -  
Adenocarcinomas (breast,  
lung, prostate, colon,  
pancreas, testis)

Treatment  
According to type, location  
and size of the tumor.  
Interdisciplinary  
cooperation  
Anterior, lateral, and  
transcranial transetmoidální  
orbitotomy.  
Orbital decompression,  
exenteration of the orbit.

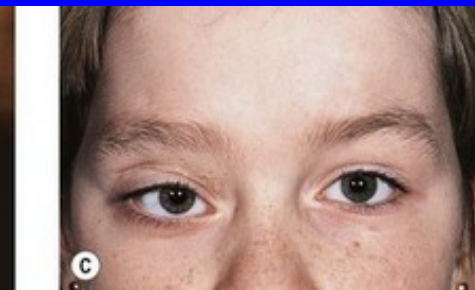
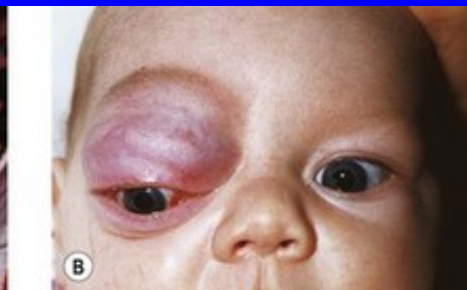
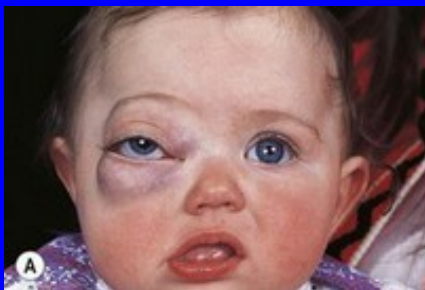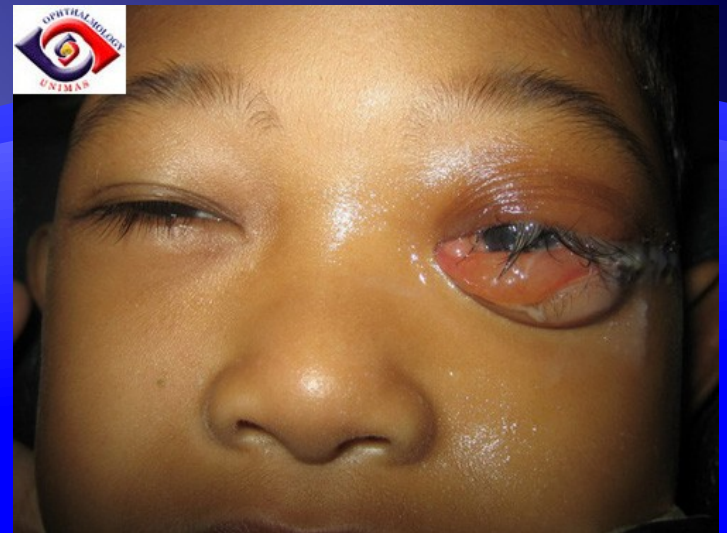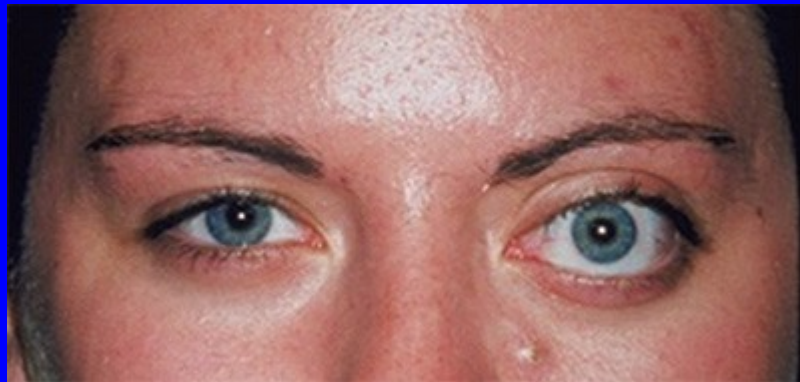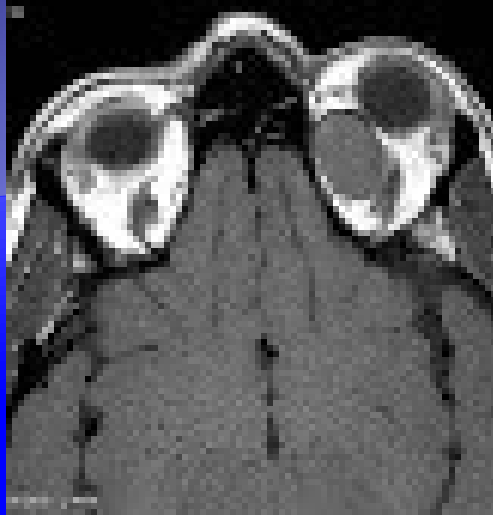


Face photo of a 5-year-old girl who developed noticeable proptosis OD and found to harbor an optic nerve glioma.



(a) The right fundus of a 5-year-old girl with a right optic nerve glioma reveals an optic nerve with mild edema. Her visual acuity was moderately to severely reduced. (b) The left nerve was normal.



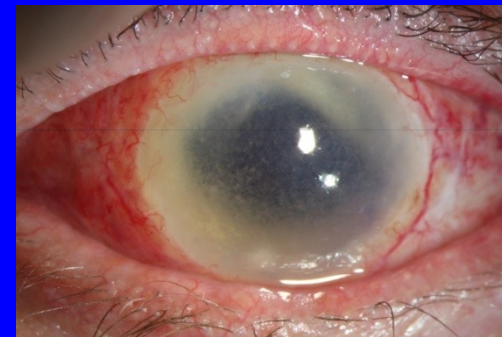
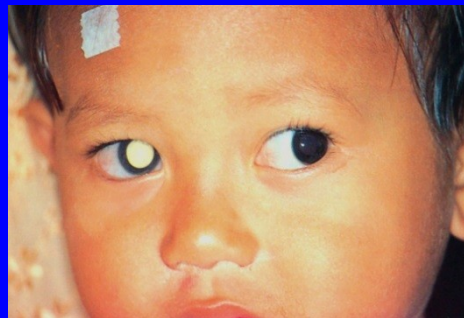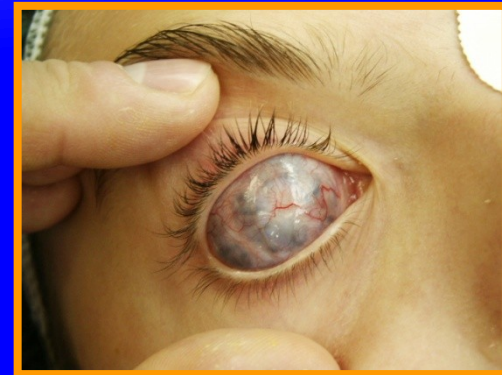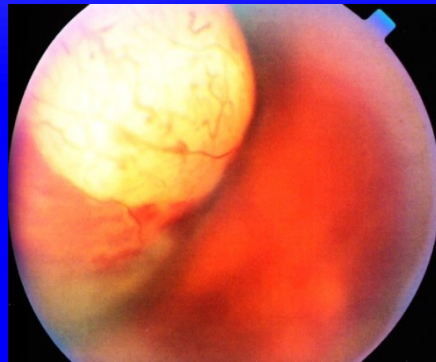


# Enucleation and exenteration

Enucleation of the eyeball –

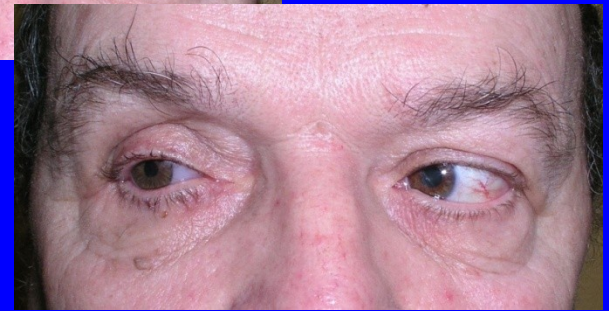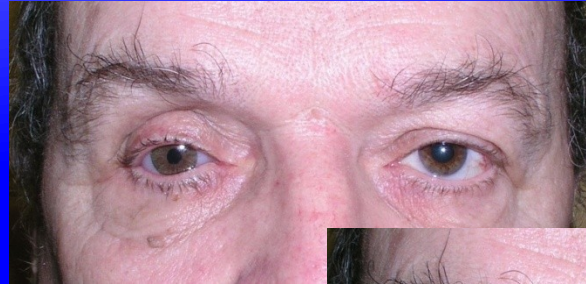Removing the whole globe after  
( transection of eye ocular  
muscles and optic nerve)

Indications:  
malignant intraocular tumors  
without extrabulbární promotion  
painful blind bulbus  
cosmetically unsightly blind  
bulbus  
devastating eye injury (primary  
enucleation)  
sympathetic ophthalmia



# Enucleation and exenteration

Enucleation of the eyeball  
surgical procedure  
without orbital implant  
orbital implant





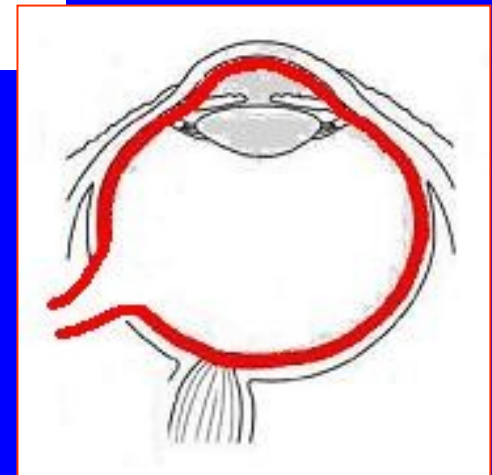
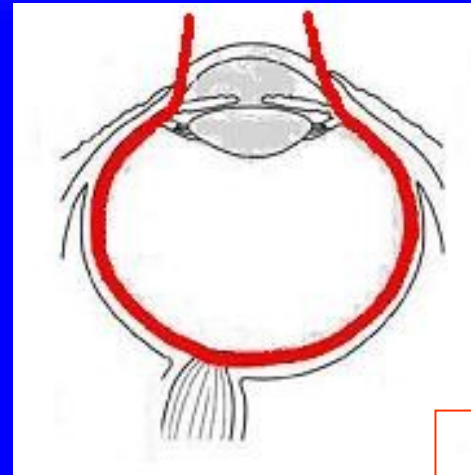
# Exenteration of bulbi

Evacuating of the contents of the eyeball, leaving its packaging.

Indications:

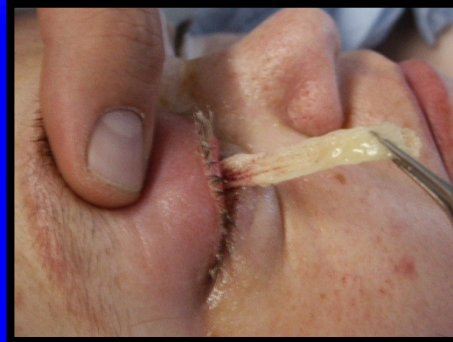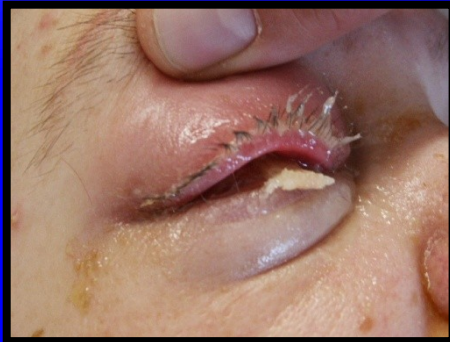Endophthalmitis (panoftalmitida)

The devastating trauma of the globe with the evacuation of its contents


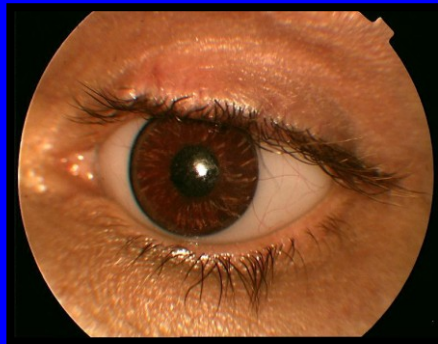
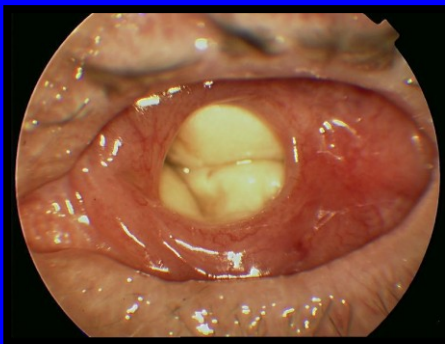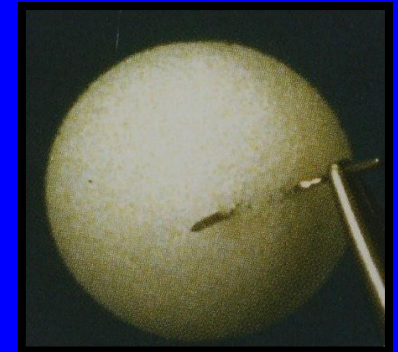
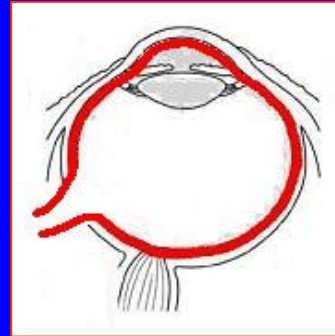


# Enucleation and exenteration

Without implant



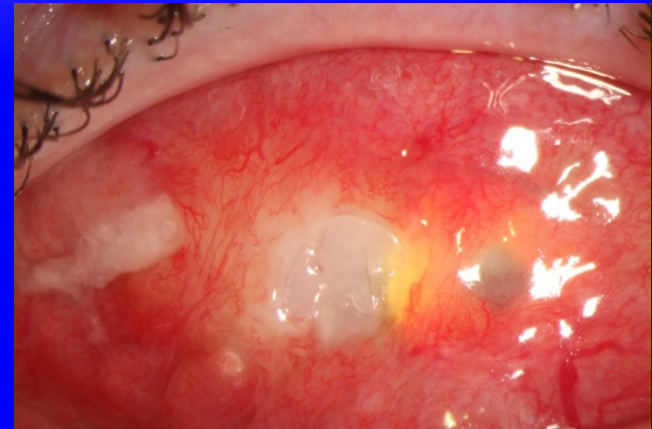
With implant



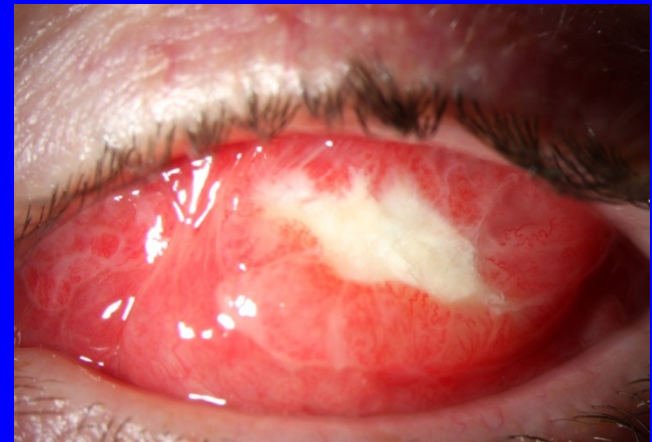

# Enucleation and exenteration

Benefits of implant:  
good motility of the globe  
satisfactory cosmetic  
effect

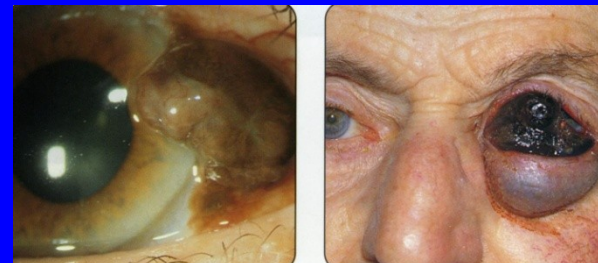
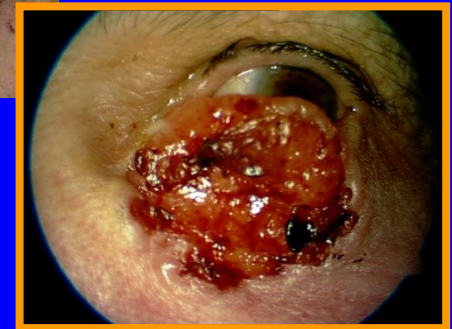
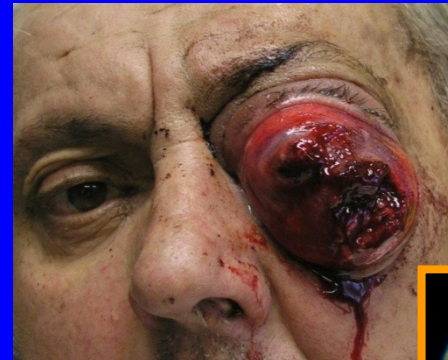
Disadvantages of  
implant:  
elimination of implant  
the possibility of infection



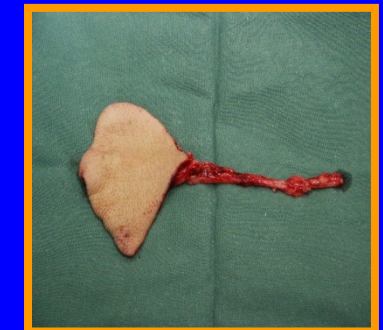
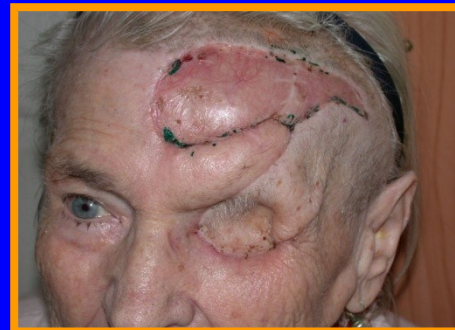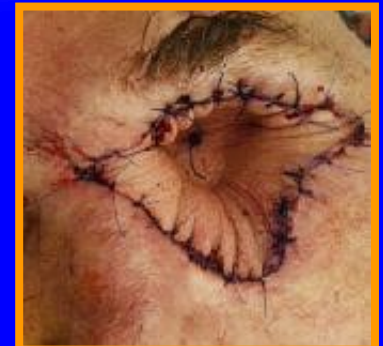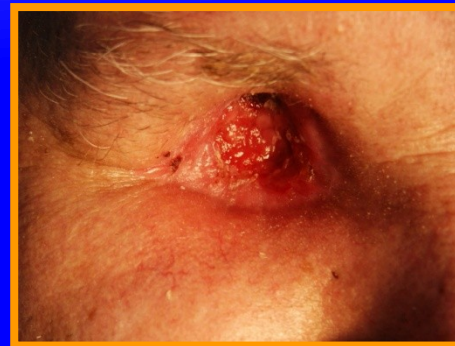# Exenteration of the orbit

- ◆ Removing the entire contents of the orbit and the periosteum without retaining caps, preserving eyelid  
indications:
  - tumors of the orbit
  - tumors of the eyelids and eyeball with propagation into orbit
  - intractable infectious processes
  - trauma (devastating injuries with extensive tissue necrosis)



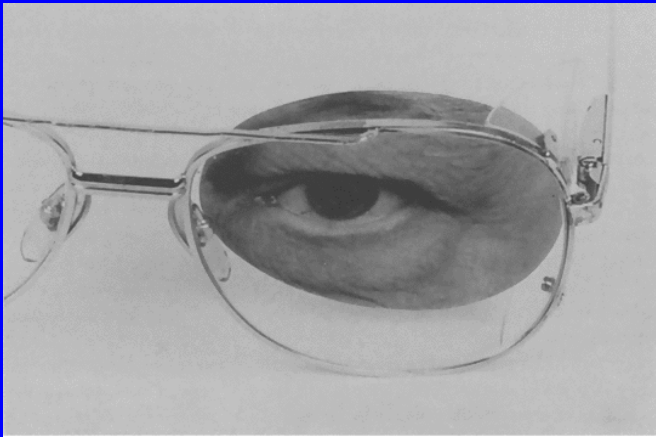
# Exenteration of the orbit

Ways of dealing with the defect:  
healing granulation tissue  
free skin graft  
tissue flap with pedicle (muscle,  
fat, skin)



# Exenteration of the orbit

Permanent Cosmetic Solutions:  
Spectacle ectoprothesis  
(prostheses)



Fixed implants

