

Back pain

Rozkydal, Z.

Chaloupka, R.

Liskay, J.

Back pain

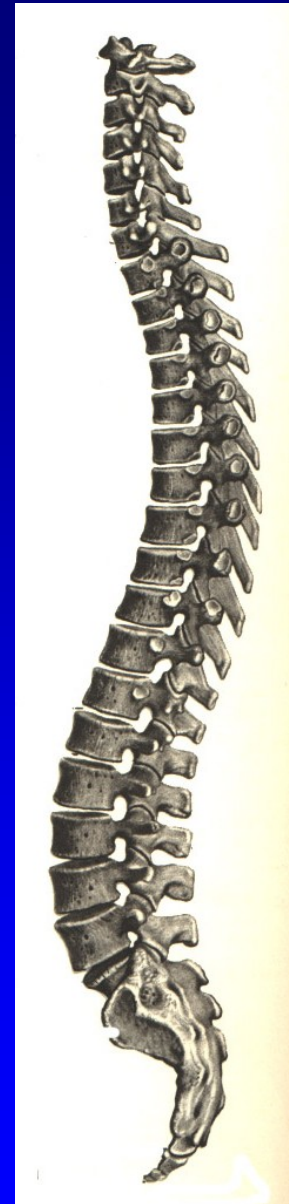- I. Pain from spinal structures
- II. Pain from visceral organs into the spine

I. spine

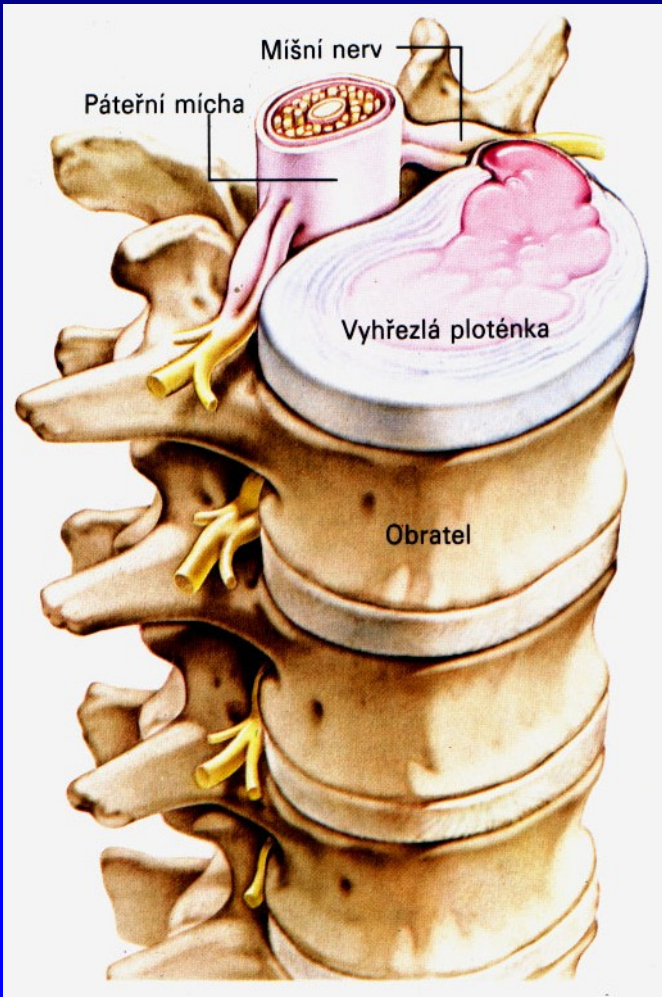
Lumbosacral spine

Thoracic spine

Cervical spine



Anatomy



Spinal segment

- two vertebral bodies and intervertebral disc

Low back pain

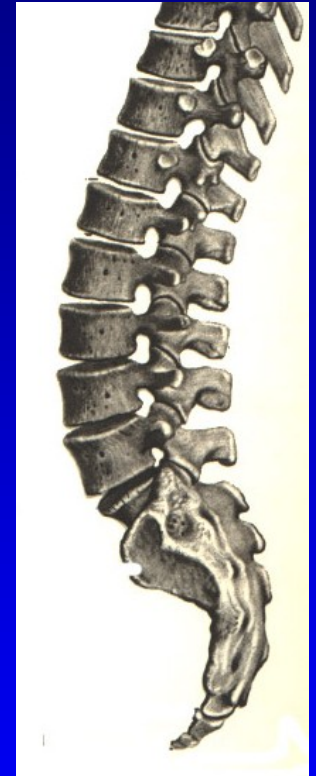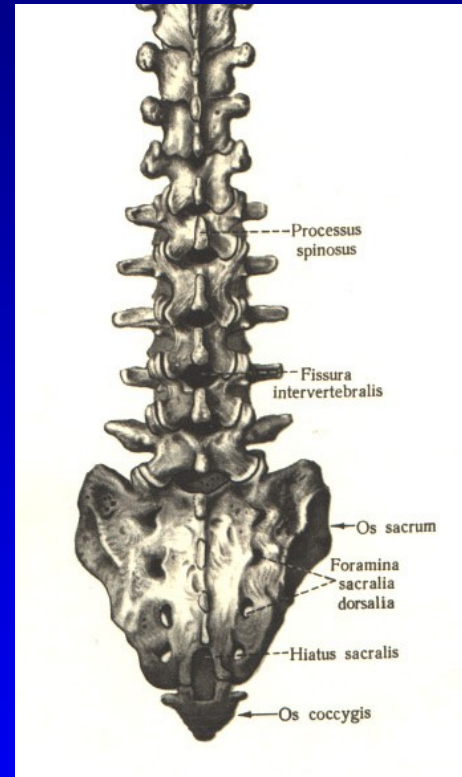
Lumbago

Lumbalgia

Sciatica

SI joints

Coccygodynia



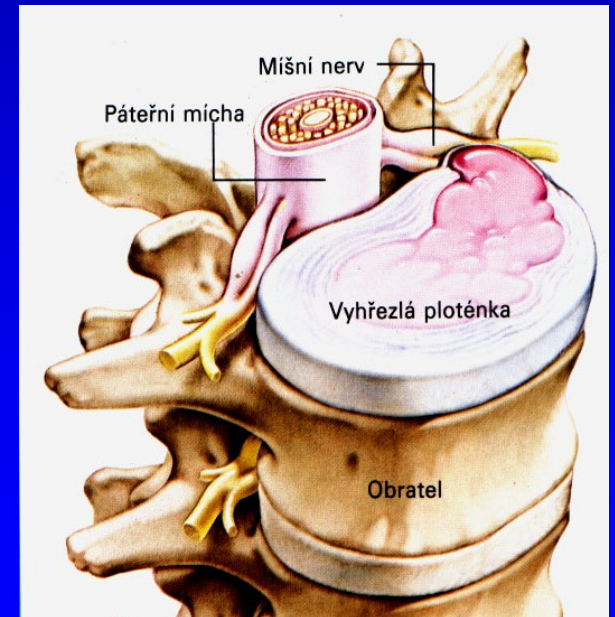
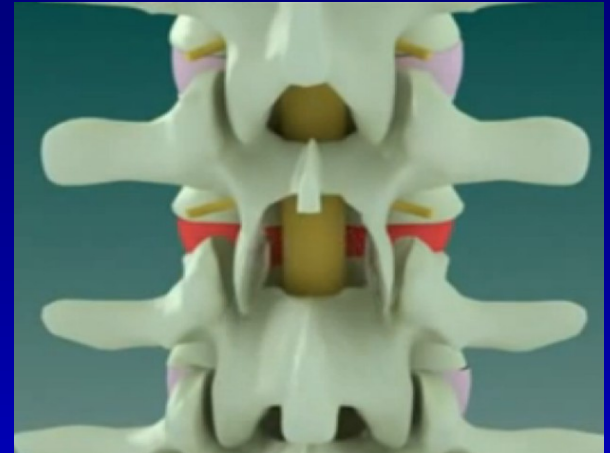
Lumbago – acute back pain

Causes

- meniscoids of intervertebral joints
- subluxation in IV joint
- slight protrusion of disc

Acute onset, muscle spasm

Therapy: rest, warm
analgetics
myorelaxans



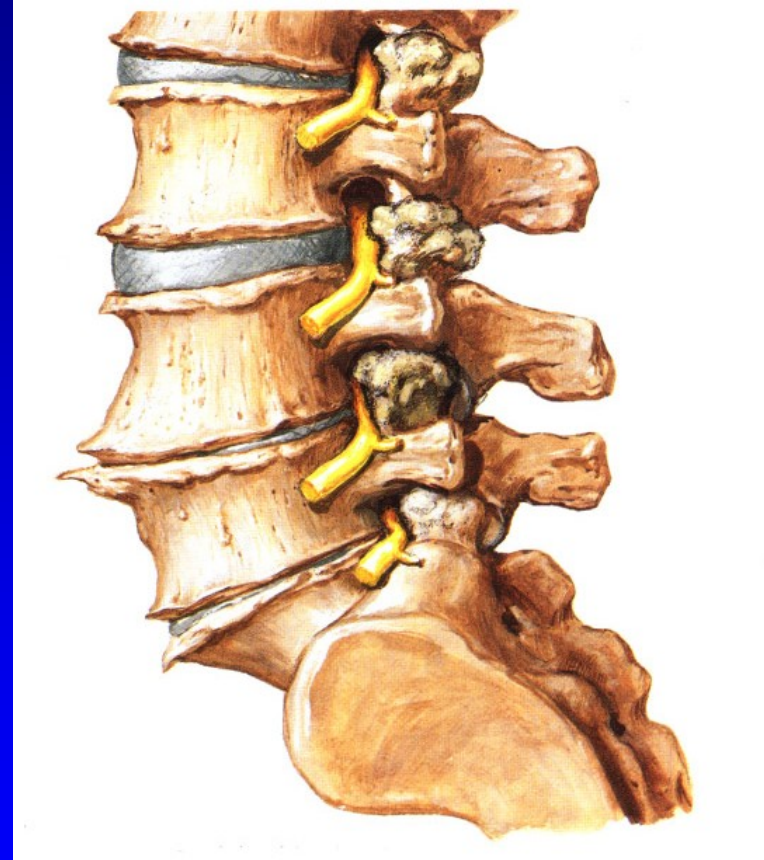
Lumbalgia

Chronic pain

Osteochondrosis disci

Spondylosis deformans

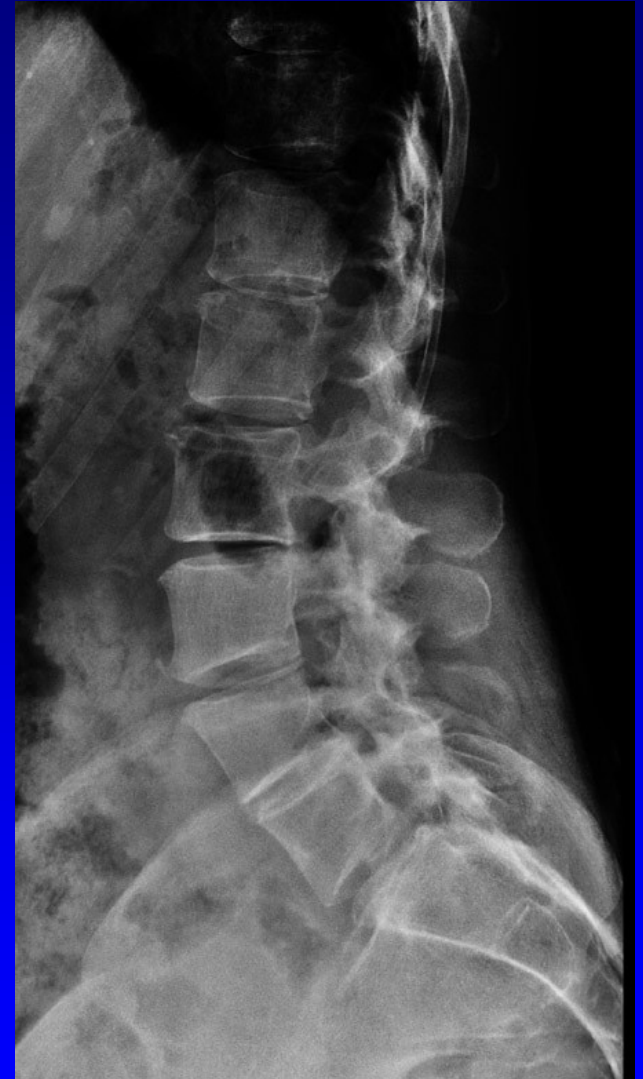Spondylarthrosis deformans



Osteochondrosis disci

Degeneration of the disc
Narrowing, sclerosis
Irregular contours

Th.- rest, NSAID
physical therapy
fysiotherapy



Spondylosis deformans

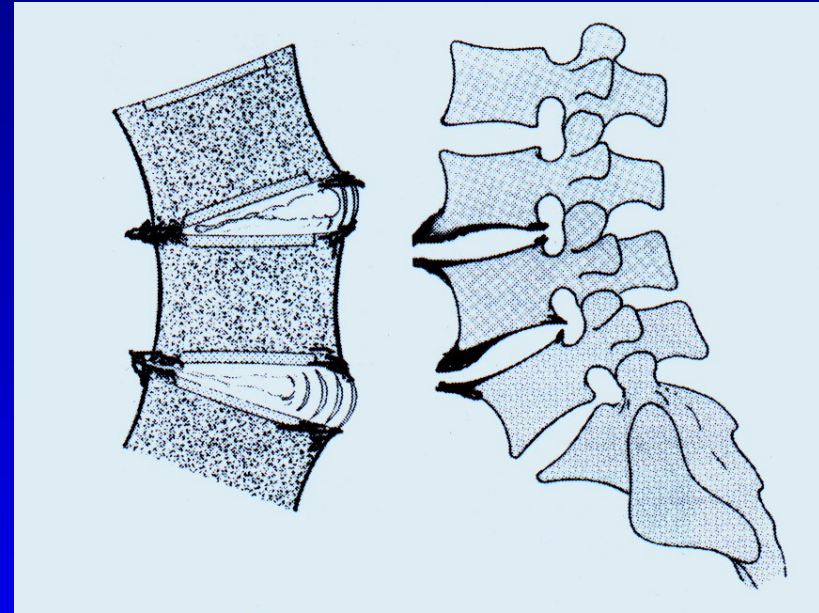
Degeneration between vertebral bodies

X- ray

Osteophytes, sclerosis
narrowing, instability

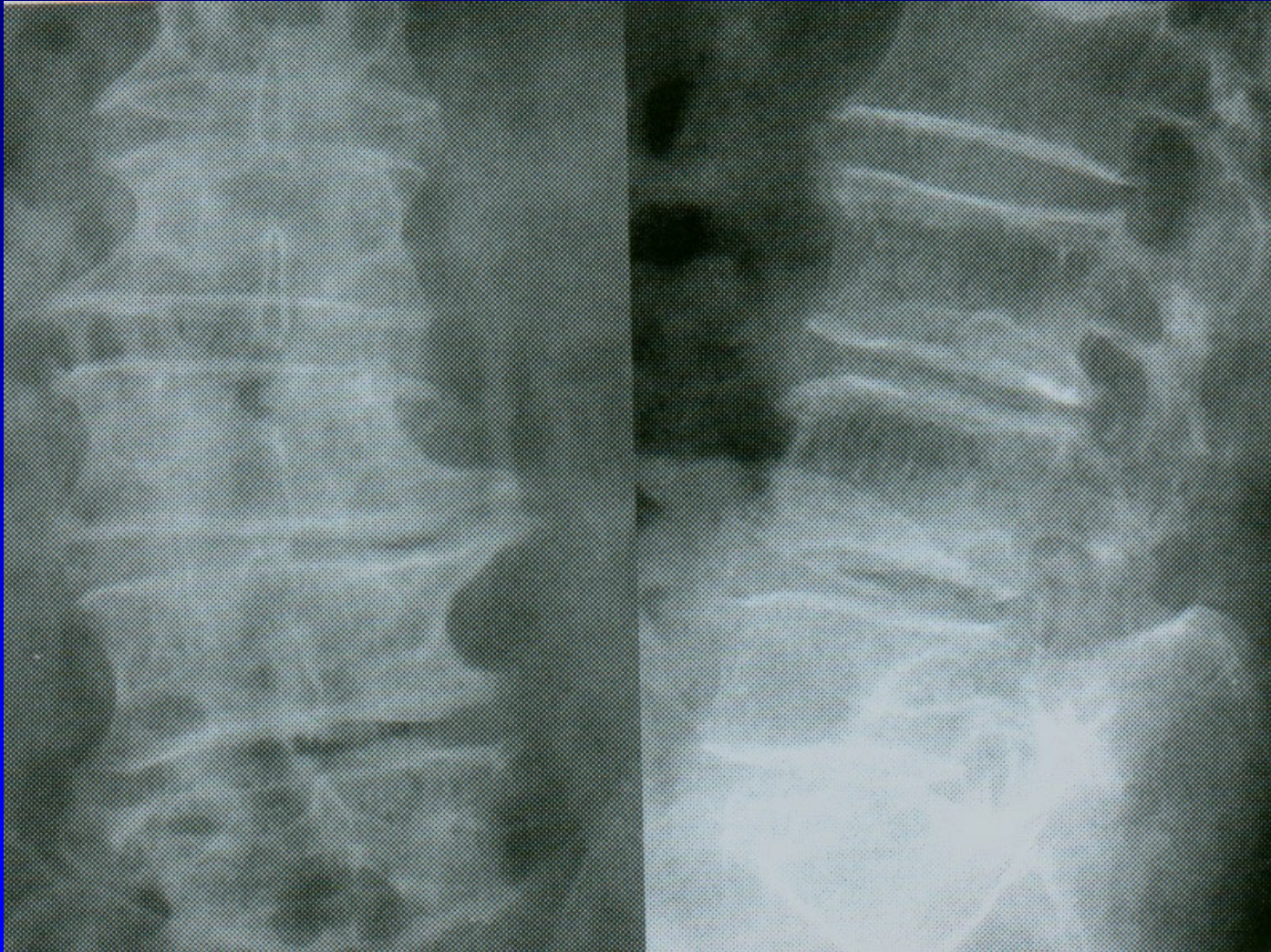
Therapy. rest

NSAID, fysical therapy



Obr. 2

Spondylosis deformans



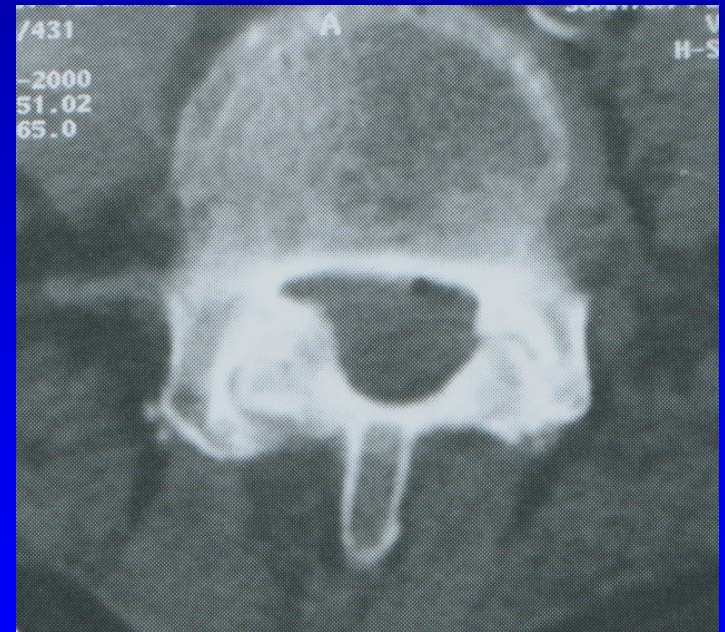
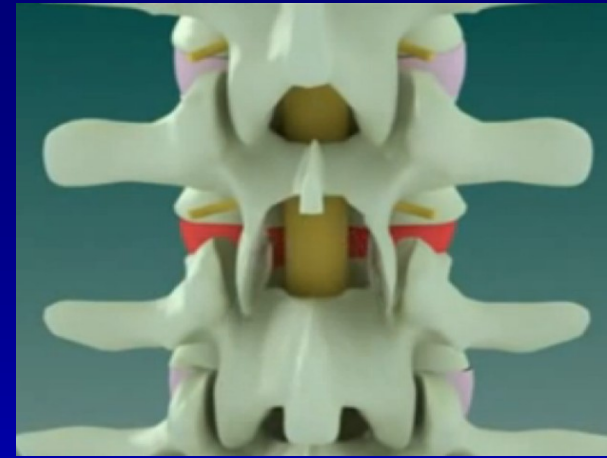
Obr. 3

Spondylarthrosis deformans

Osteoarthritis of intervertebral joints

Back ache, limited movements

Th: rest, NSAID, analgetics
fysiotherapy, chondroprotectives

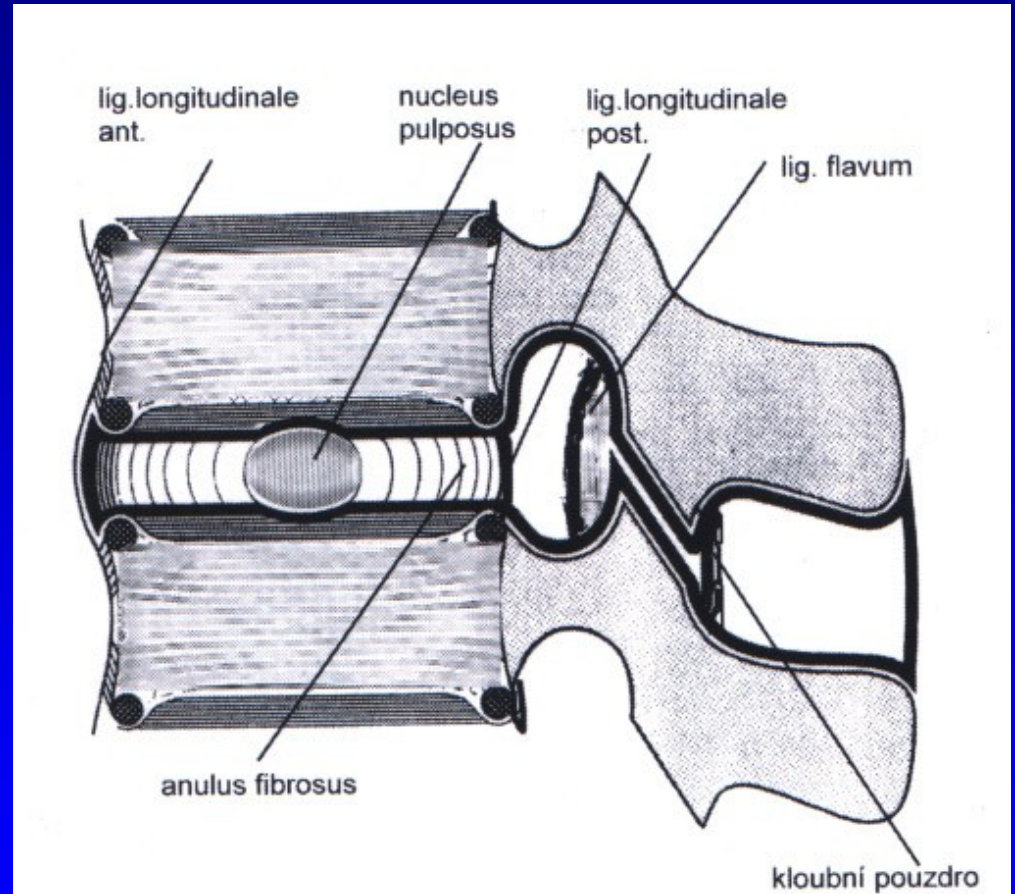


Sciatica

- Pain in lumbosacral region with limited function and irradiating into lower extremities
- roots L5-S2
- roots L2-L4

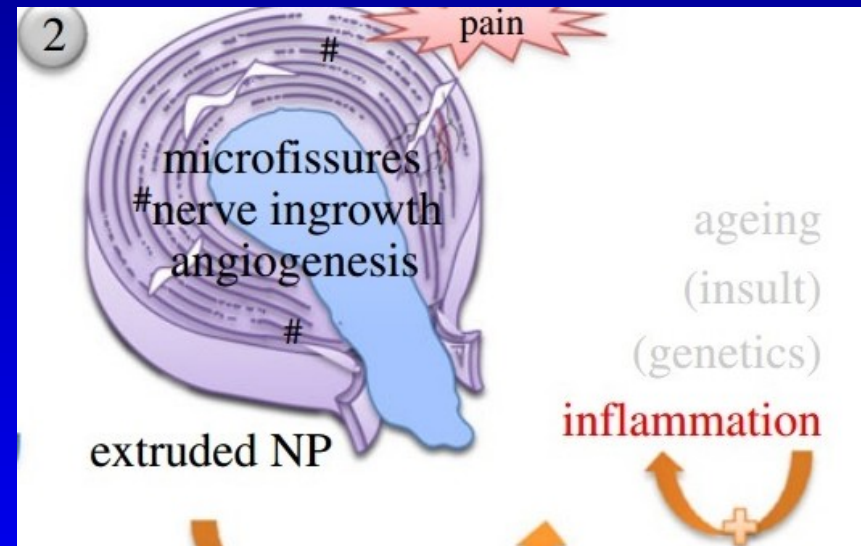
Intervertebral discs

Upper layer
Nucleus pulposus
Anulus fibrosus
Lower layer

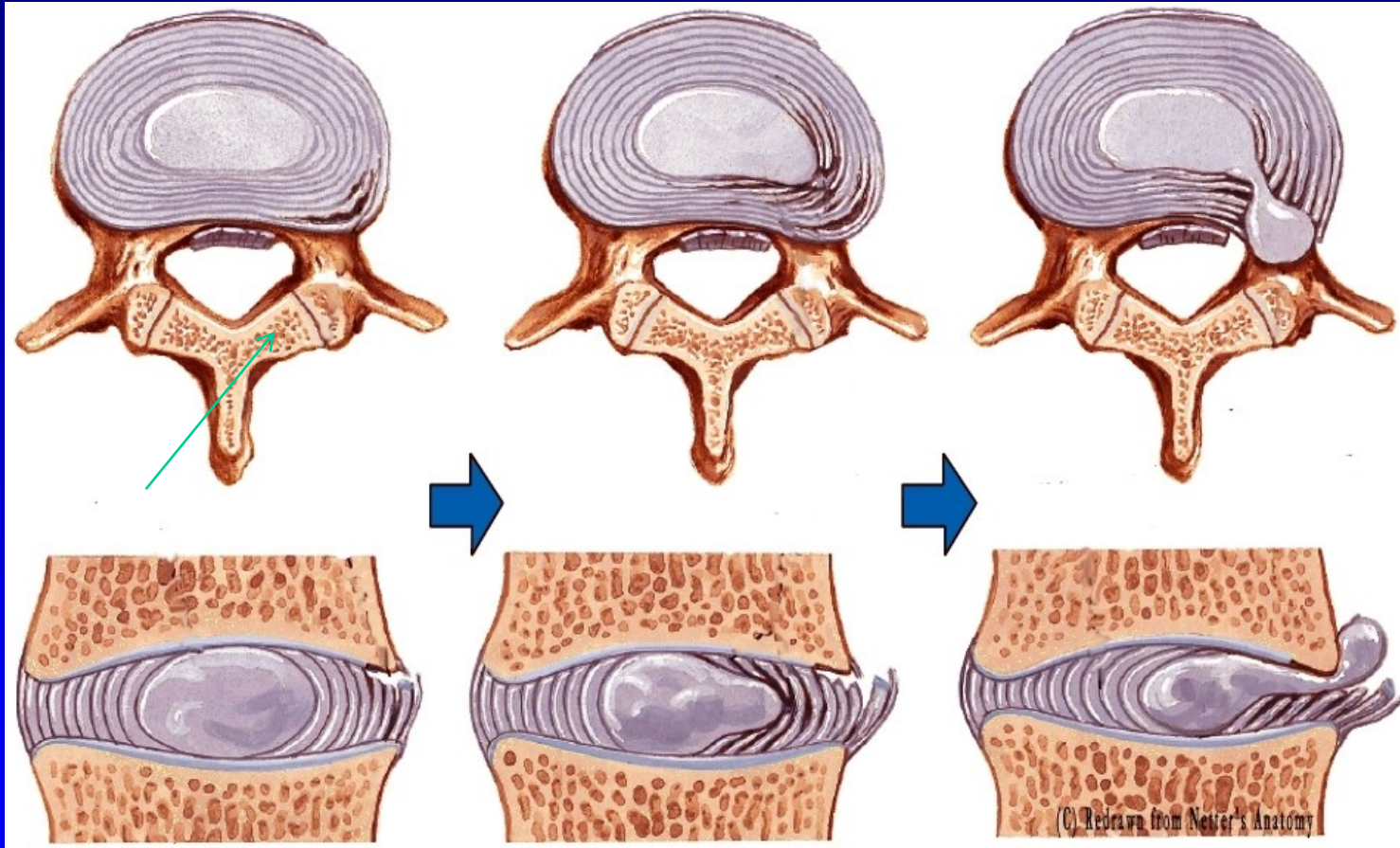


Pathophysiology

- Less turgor in nucleus pulposus
- Degeneration of the disc with protrusion or extrusion of nucleus pulposus
- Microruptures in anulus fibrosus
- Tear in anulus fibrosus
- Tear of posterior longitudinal ligament

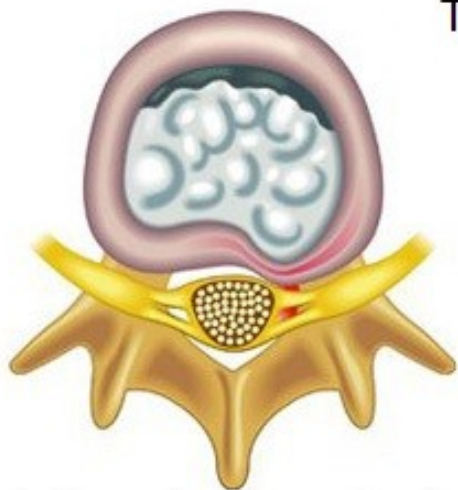

Tears

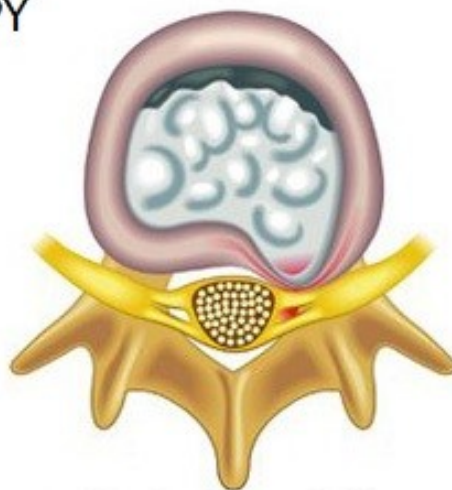


Types

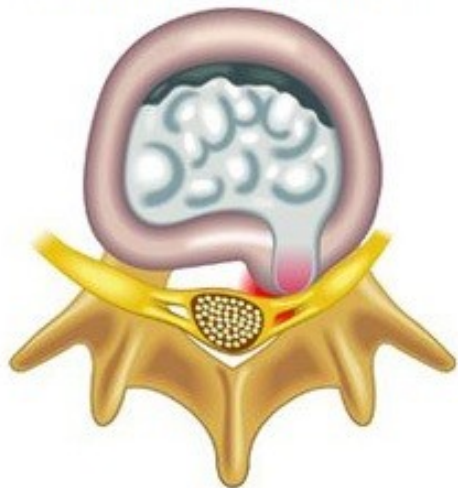TYPY



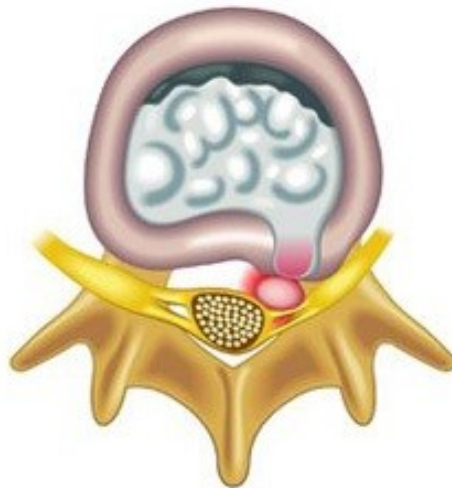Bulging - vyklenutí



Protruze



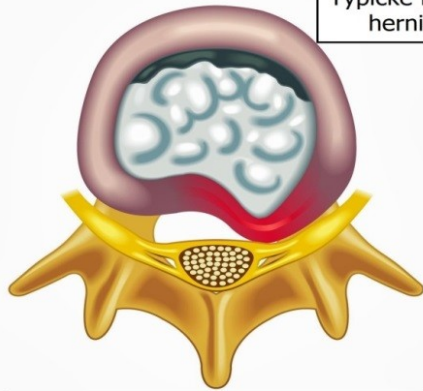
Extruze



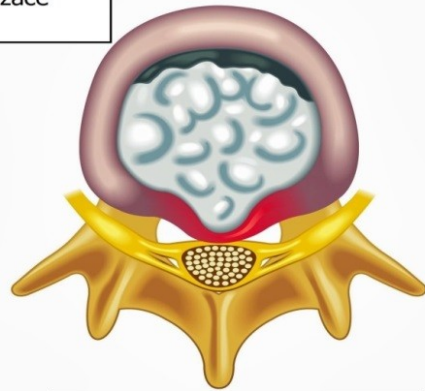
Volný fragment

Localisation

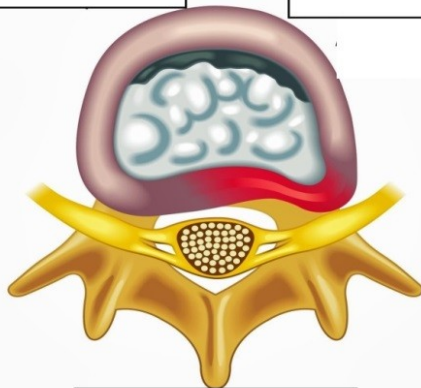
Typické lokalizace
herniace



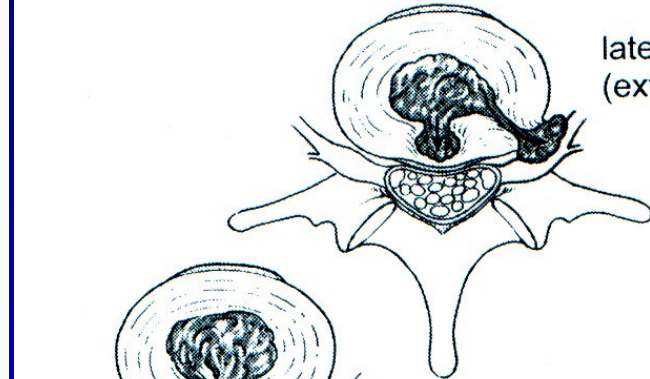
POSTEROLATERÁLNÍ



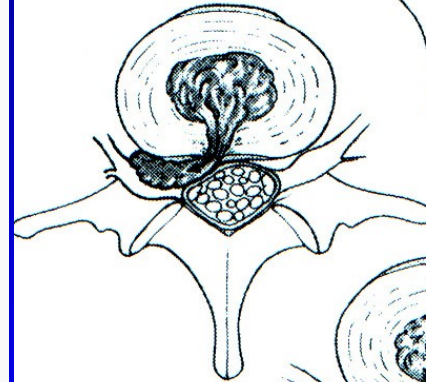
CENTRÁLNÍ



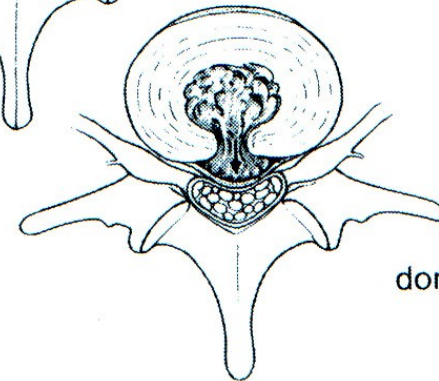
FORAMINÁLNÍ



laterální
(extraforaminální)



foraminální



dorzální

Incidence

- 30-50 years
- Hereditary succesibility in younger age
- Mostly segment L5-S1
- 2-3% of population have radicular symptoms
- 70 -85 % of population suffer from bach ache at least once on their lives

Symptoms S1

- Pain on dorsal aspect of the extremity
- Changes in sensation on dorsal aspect
- Achilles tendon reflex
- Not able to stand tip toe
- Lasegue maneuver

Symptoms L5

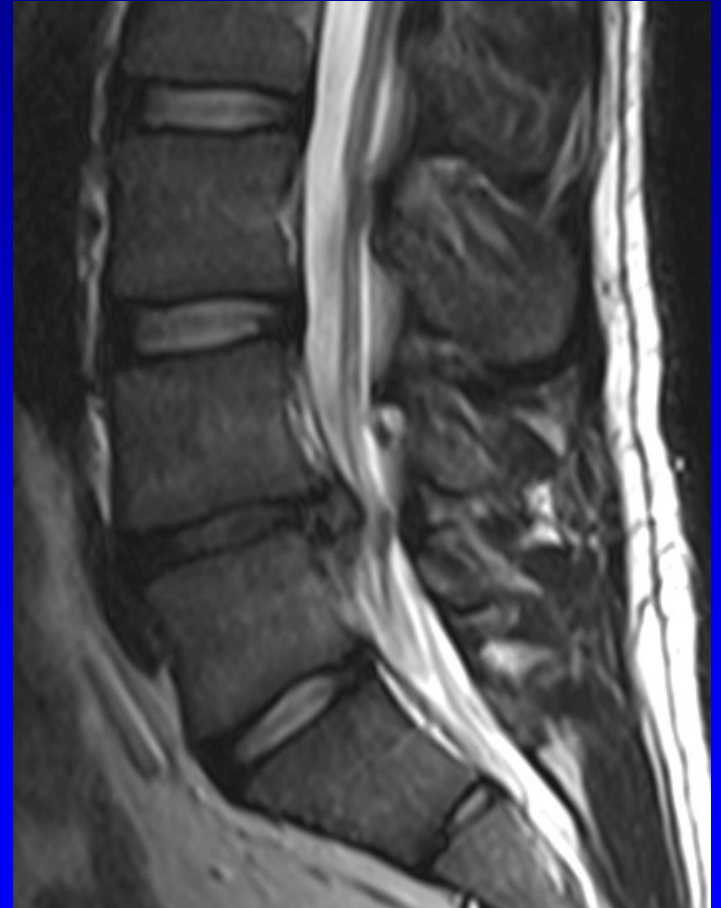- Pain on lateral aspect of the extremity
- Changes in sensation
- Not able to stand on heels
- Lasegue maneuver positive
- Limited dorsiflexion of the ankle and toes

Symptoms L4

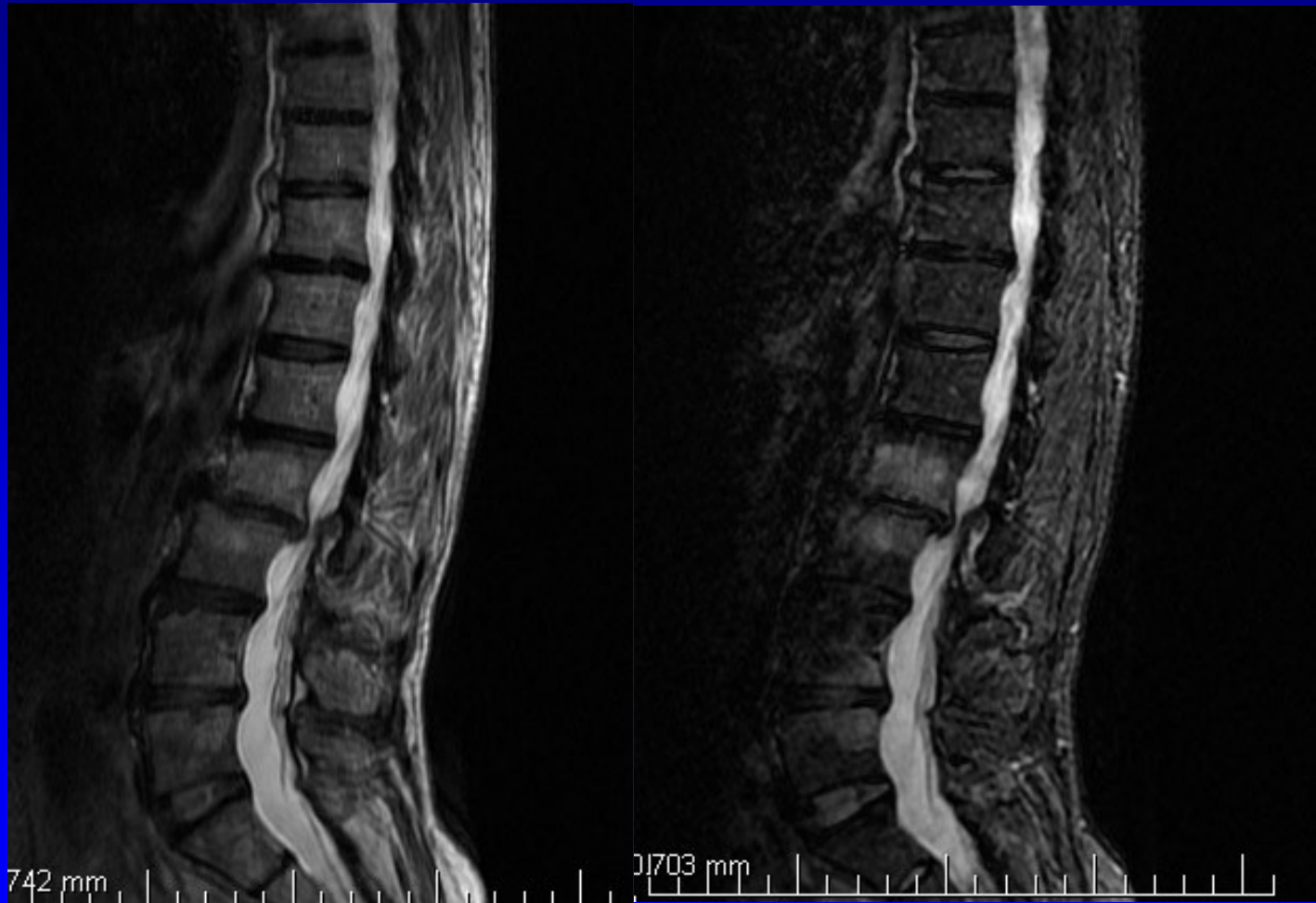- Pain on anterior aspect
- Changes in sensation
- Patellar tendon reflex
- Weak active extension of the knee

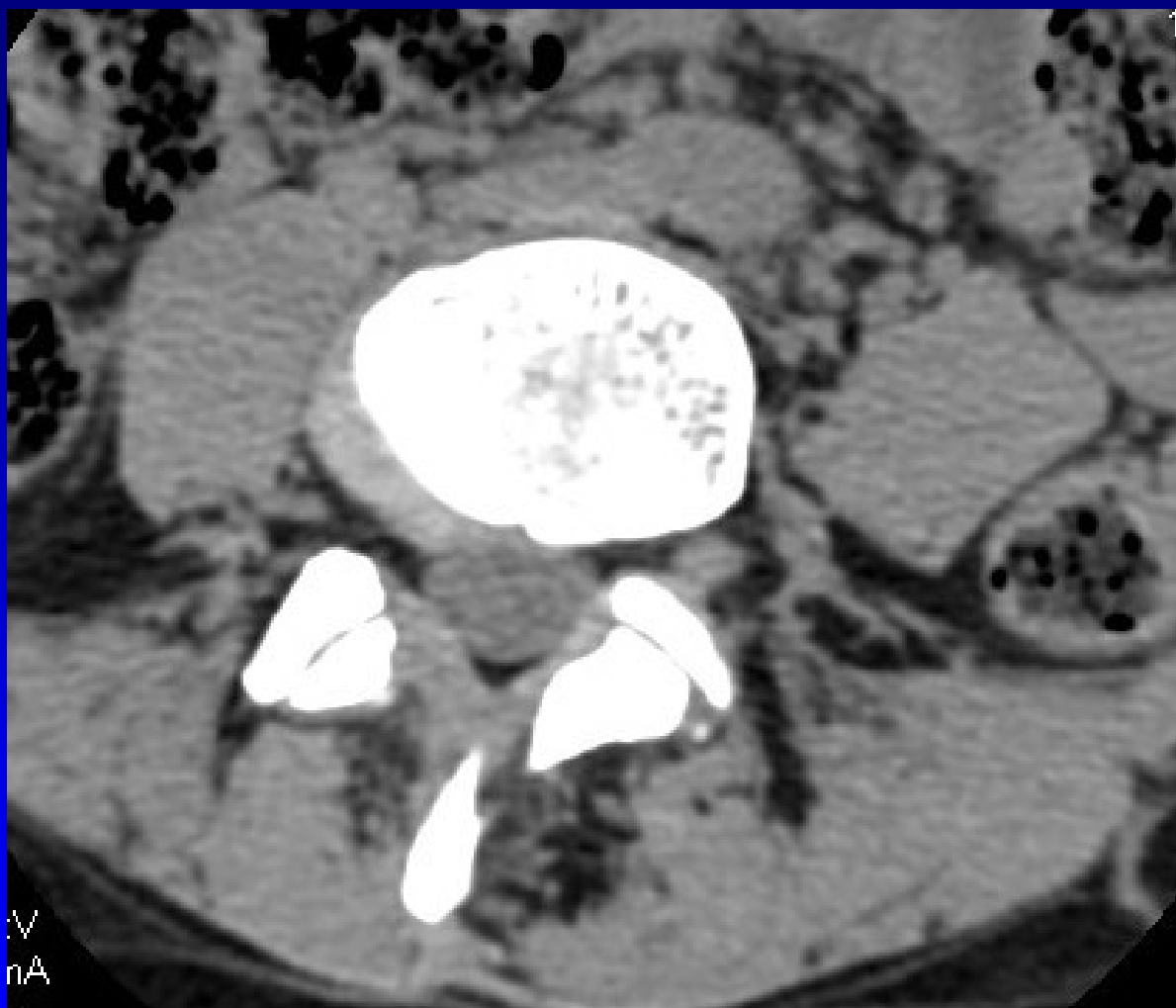
Imaging methods

- X-ray
- MRI
- CT scann
- CT myelography



Hernia disci





Hernia disci

Therapy- conservative

NSAID, myorelaxans, analgetics, rest

Periradicular therapy (corticoids, morfin, marcain)

Drips with NSAID

Fysiotherapy

Effect 80-90 %

Therapy- surgery

Indication

- cauda equina syndrom
 - motor dysfunction – conservative treatment not succesful
 - timing- soon, at least up to 6 weeks
-
- Protrusion up to 5 mm is not indication to surgery

Cauda equina syndrom

The spina cord terminates at L1

Nerve roots are L2-S4

Supply bladder and rectal sphincter

Supply muscles of the lower limb and sensation of the perineum

Symptoms:

Back pain, lower limb flaccid paralysis, loss of reflexes

Paresthesia of the perineum, loss of anal tonus, faecal incontinence

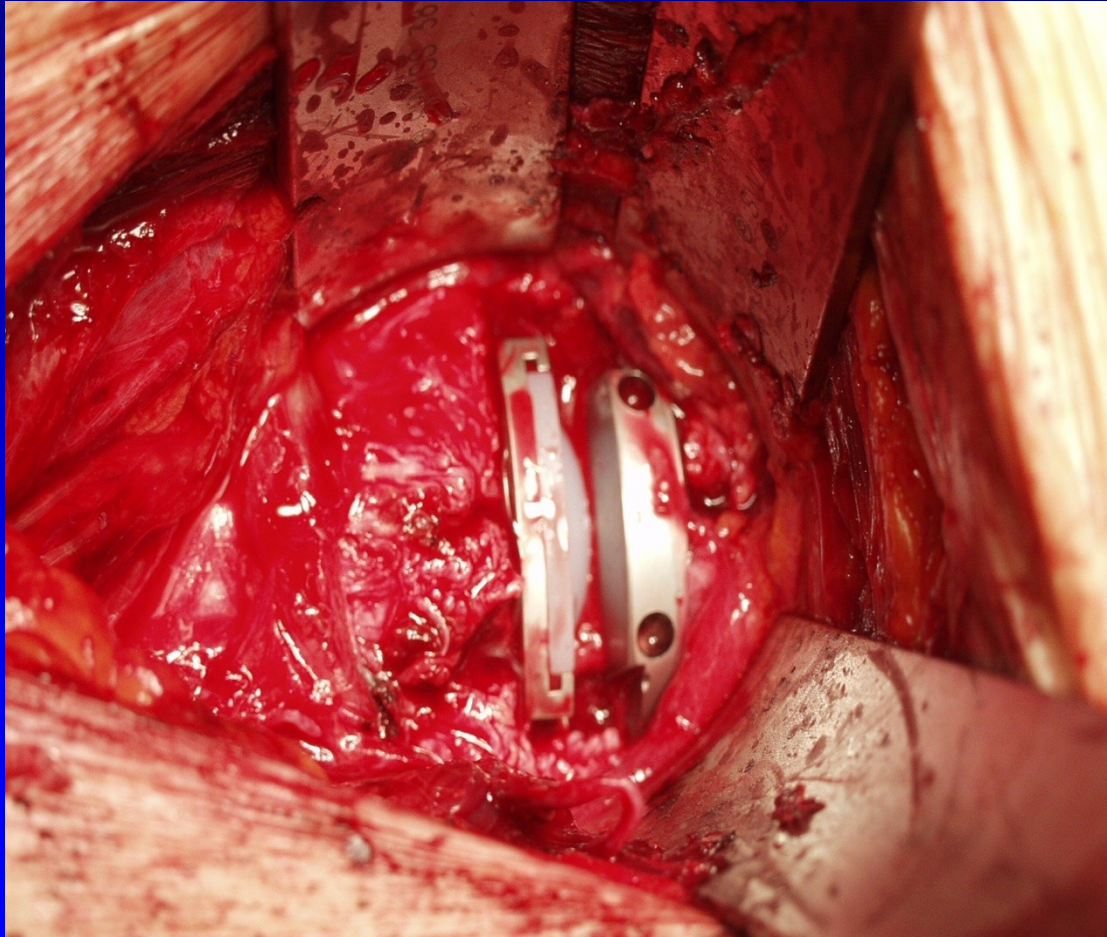
Retention of urine

Cauda equina = emergency

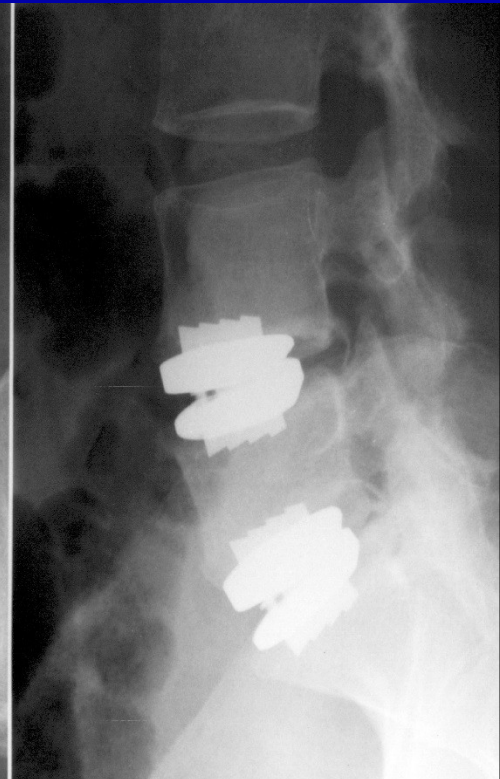
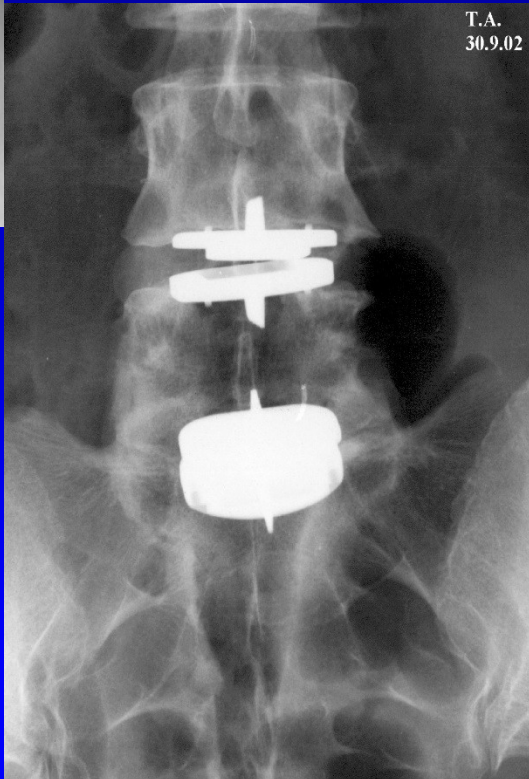
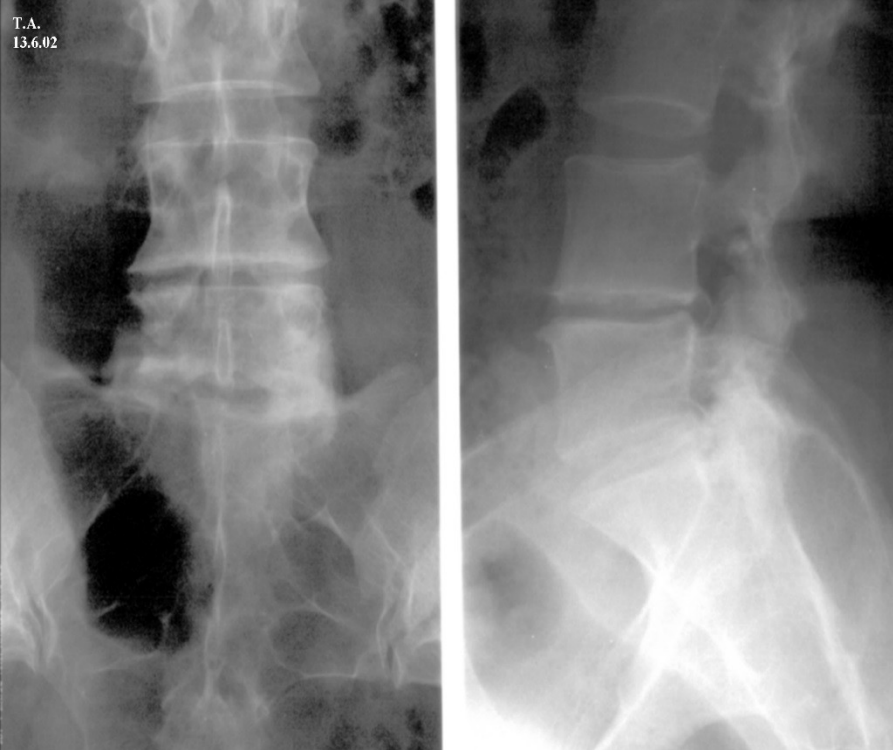Therapy - surgery

- Hemilaminectomy, decompression of the nerve root
- Microdiscectomy
- Percutaneous discectomy

Intervertebral disc replacement



T.A.
13.6.02



Complications

- Nerve root lesion
- Some part of the sequestrum left
- Infection
- Recurrence
- Instability
- Failed back surgery syndrom

Failed back surgery syndrom

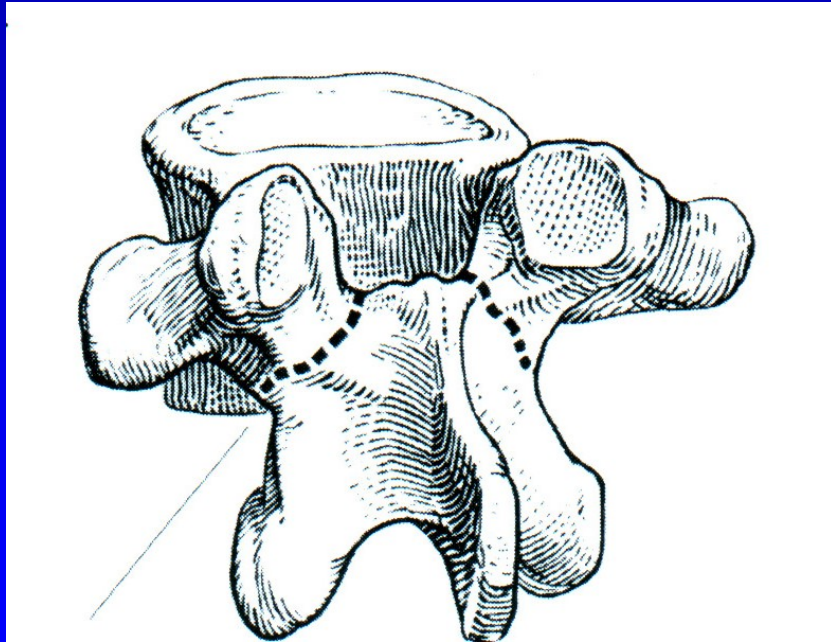
Failure of surgery

causes: epidural fibrosis, infection
arachnoiditis
instability of the spinal segment
spinal stenosis
psychological problems

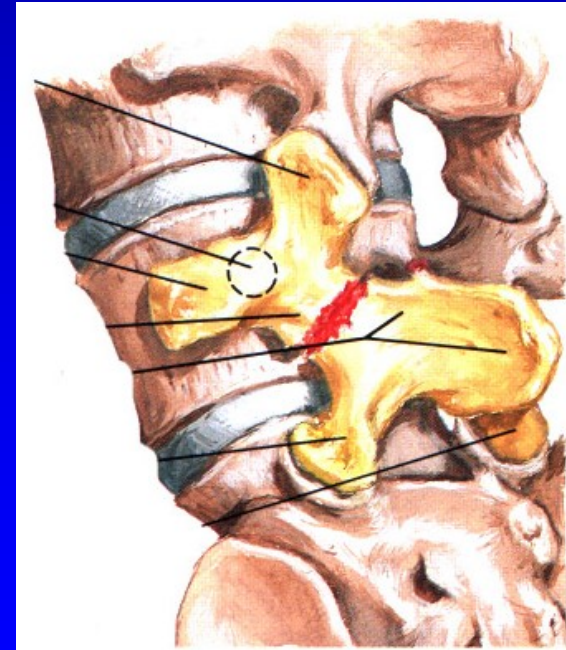
Therapy: decompression , stabilisation, instrumentation
conservative treatment

Spondylolysis

Fibrous tissue in pars interarticularis
Th- conservative
surgery



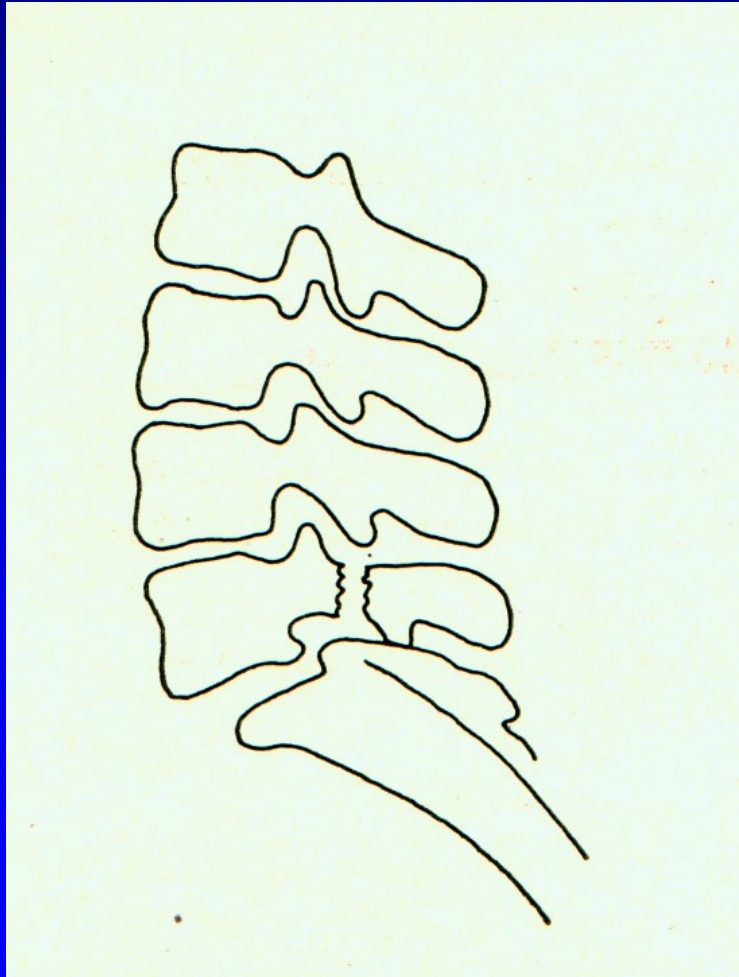
Obr.13



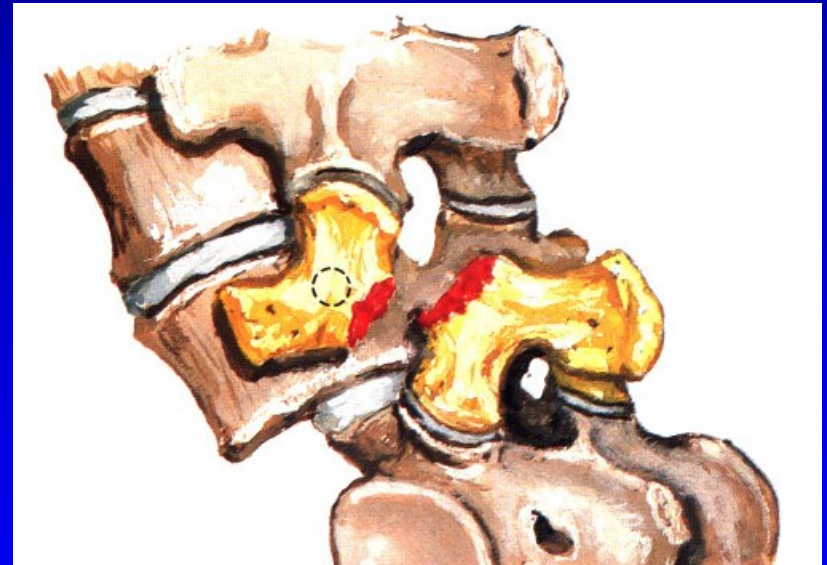
Obr. 14

Spondylolisthesis

Slip of vertebral body in isthmic region anteriorly

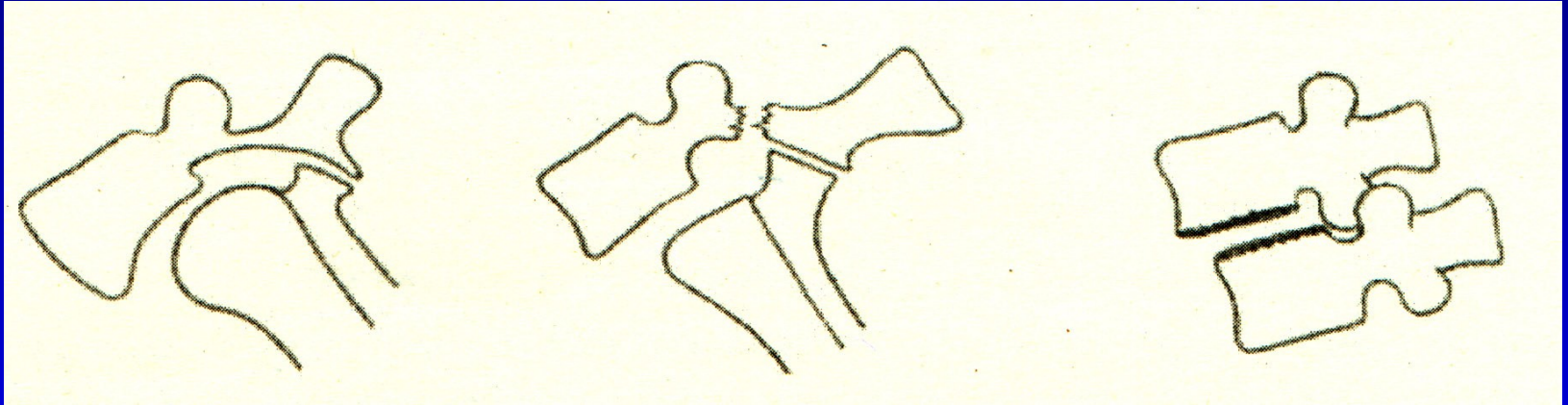


Obr. 15



Obr. 16

Spondylolisthesis



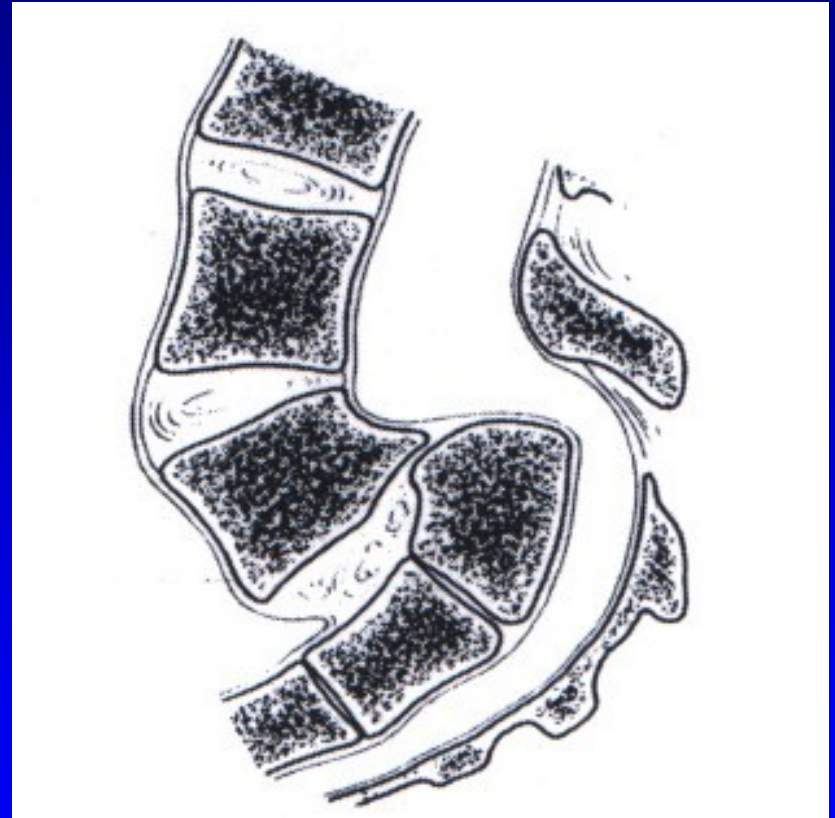
1. dysplastic

2. isthmic

3. degenerative

Stages of spondylolisthesis

- I. 25 %
- II. 50%
- III. 75 %
- IV. 100 %
- V. spondyloptosis



Obr. 18 Spondyloptosis

Spondylolisthesis

Low back pain

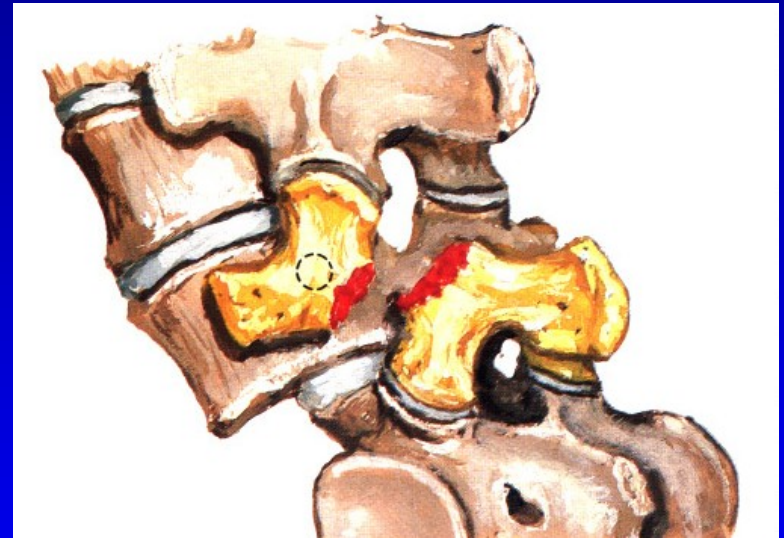
Sciatica

Muscle spasms

Th: fysioth, analgetics

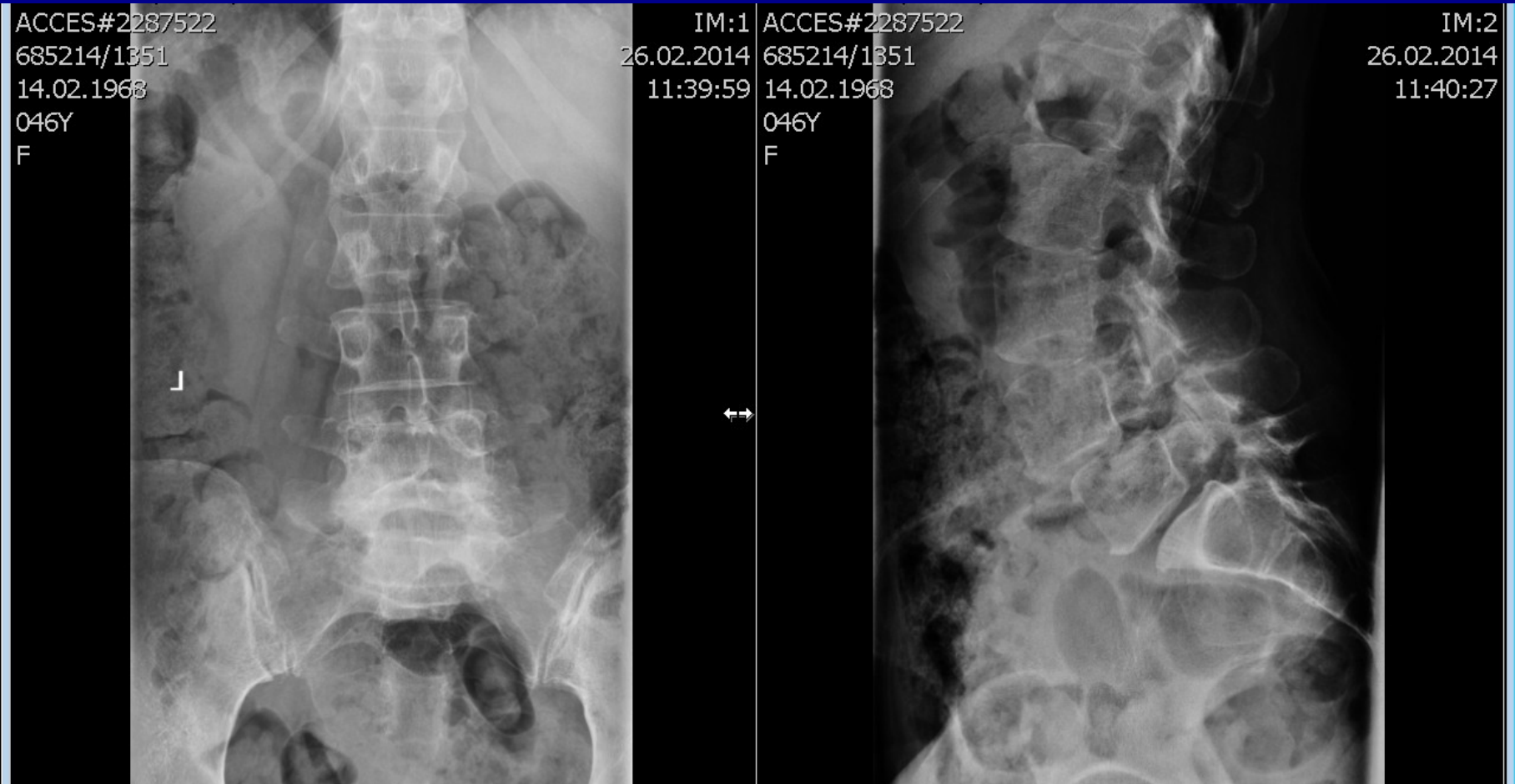
Op: decompression, reduction,
anterior or posterior fusion

PLIF - TLIF, ALIF



Obr. 19

Spondylolisthesis



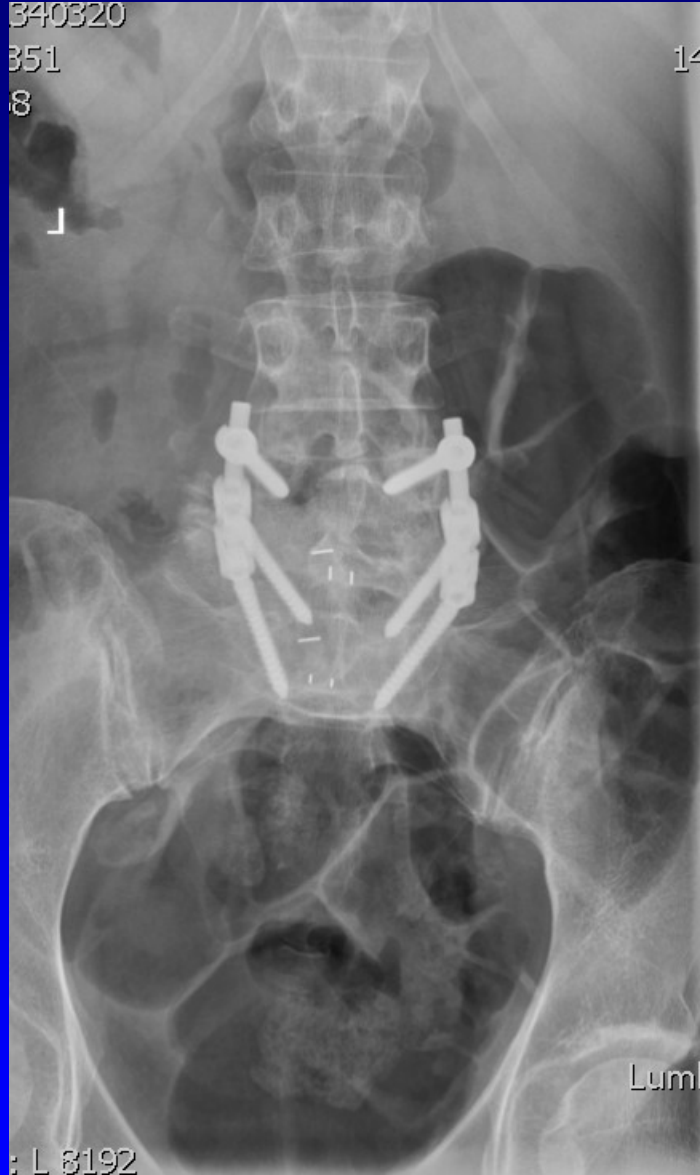340320

351

8

J

: L 8192



IM:1

14.05.2014

08:58:12

ACCES#2340320

685214/1351

14.02.1968

046Y

F

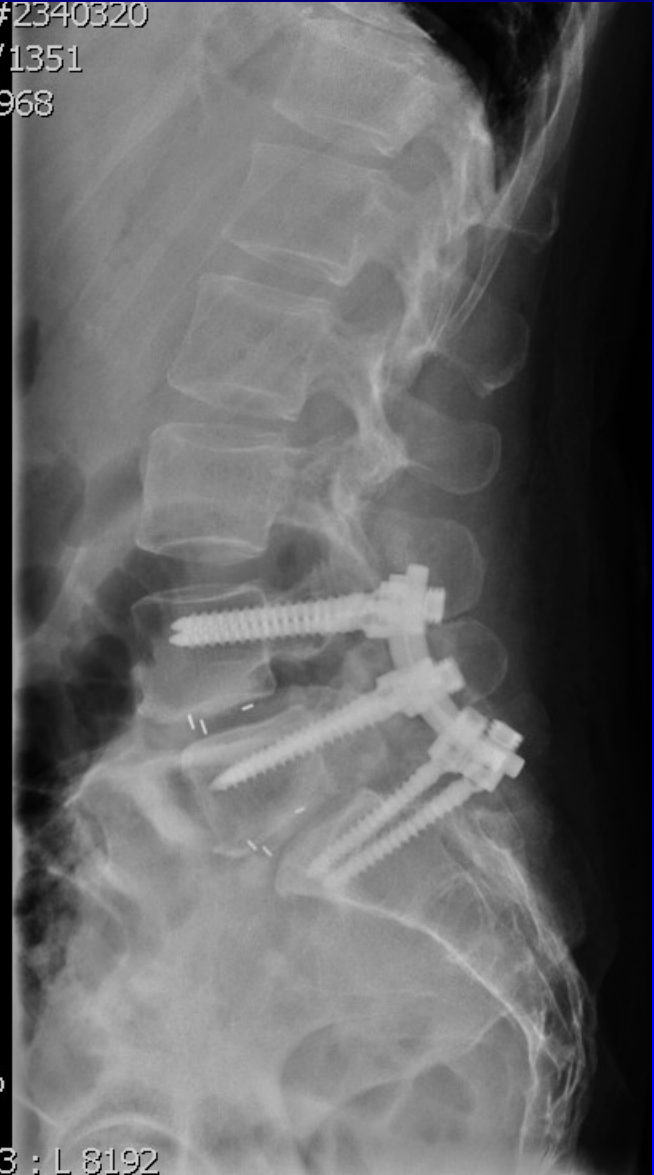↔

Lumbar-spine

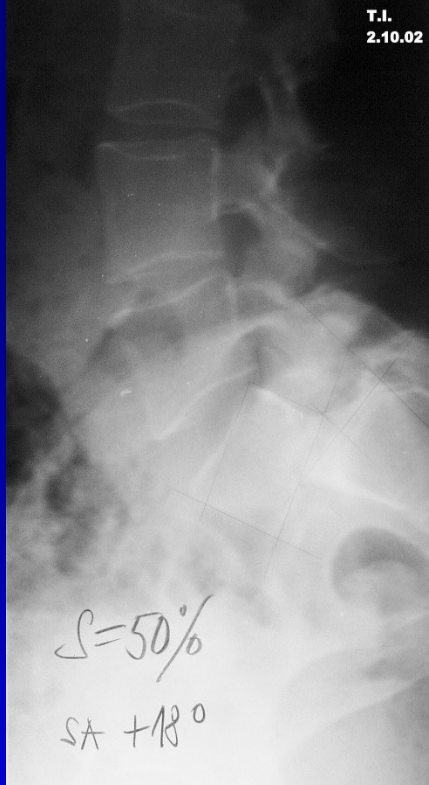L4/5

FN Brno

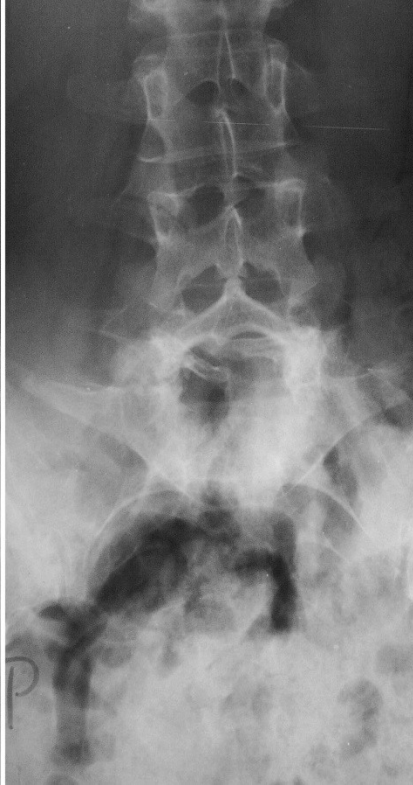W 16383 : L 8192



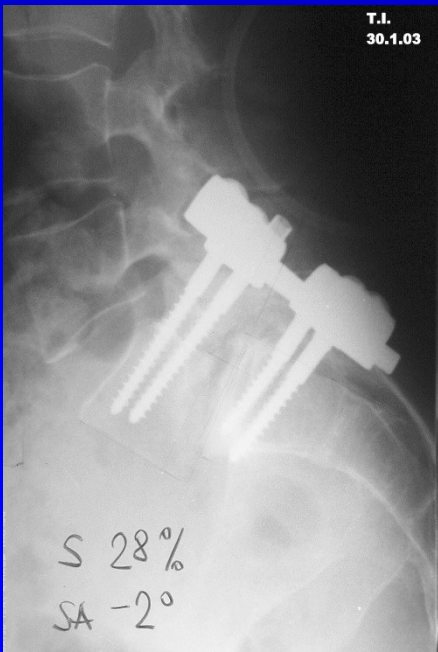
T.I.
2.10.02



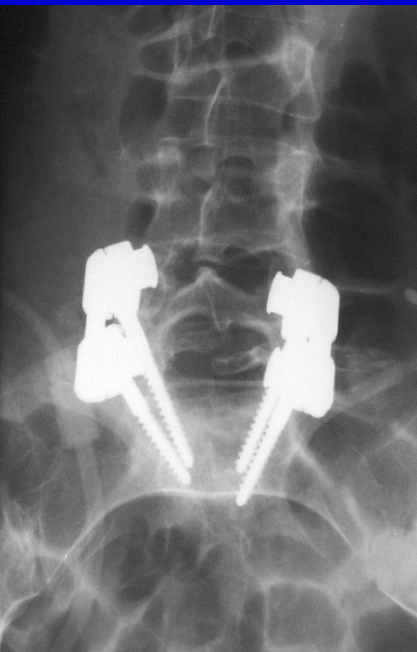
S=50%
SA +18°



T.I.
30.1.03



S 28°
SA -2°



IVANA 398/03

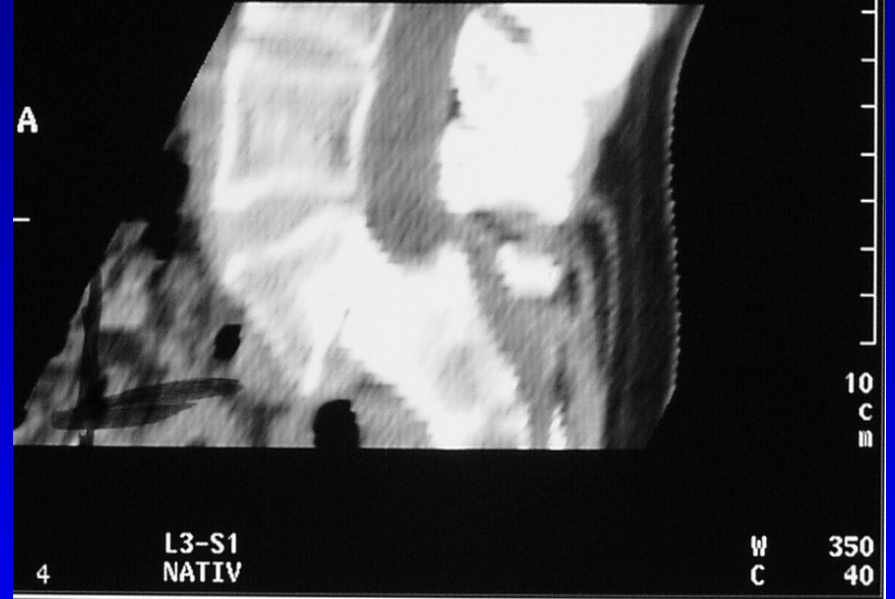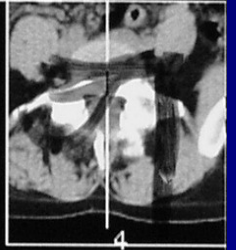
675218/1018

H

21-JAN-2003

IMA 44

Ref Scan 3
Ref TP -882.5



A

10
C
M

L3-S1
NATIV

W 350
C 40

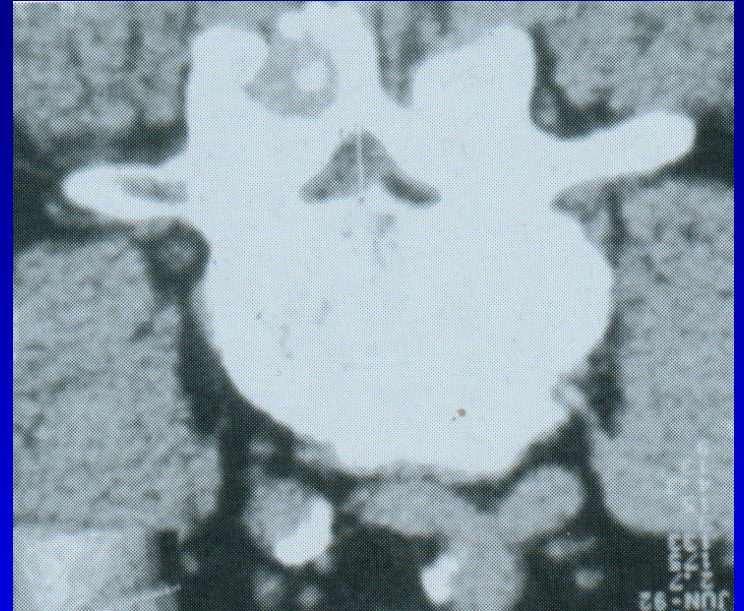
4

Spinal stenosis

Narrow spinal canal

Advanced spondylosis and
spondylarthritis

Compression of dural sack



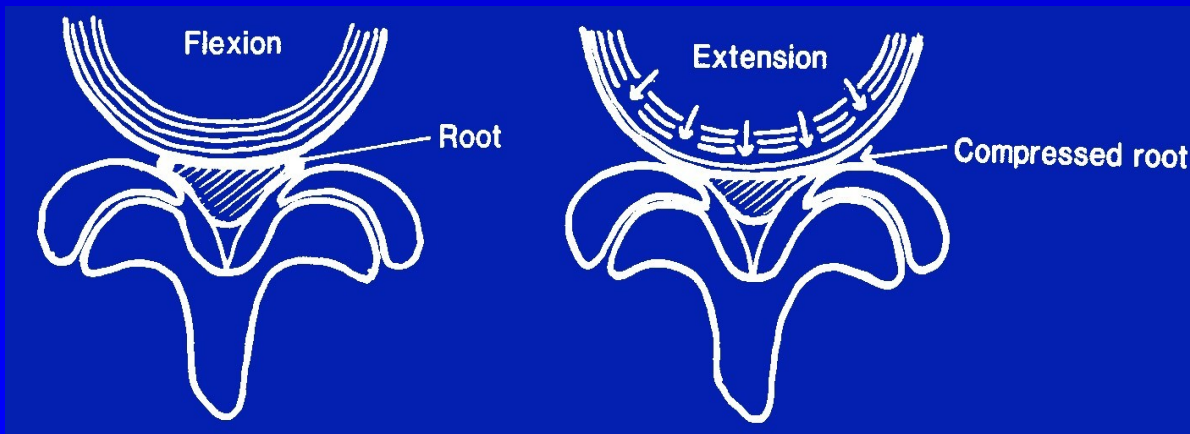
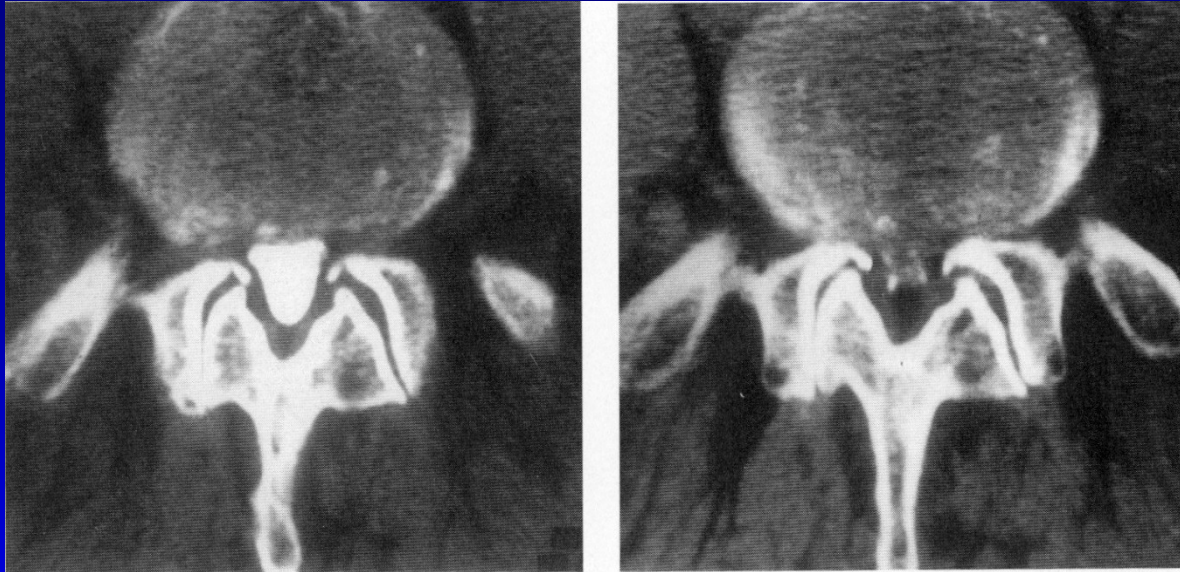Normal width of spinal canal 17 mm

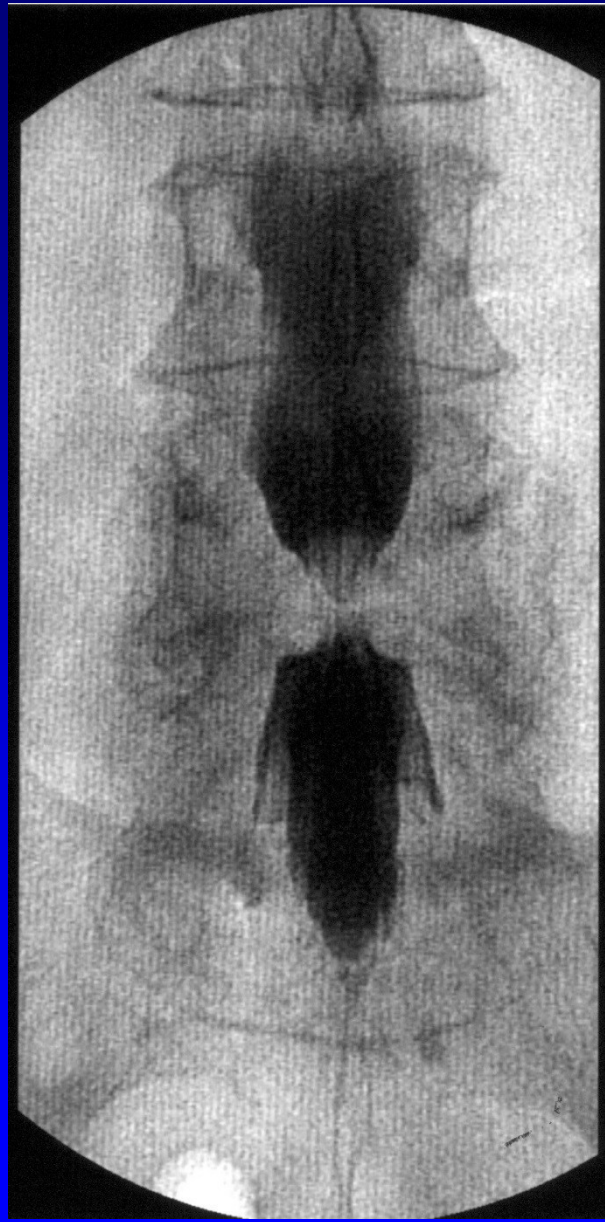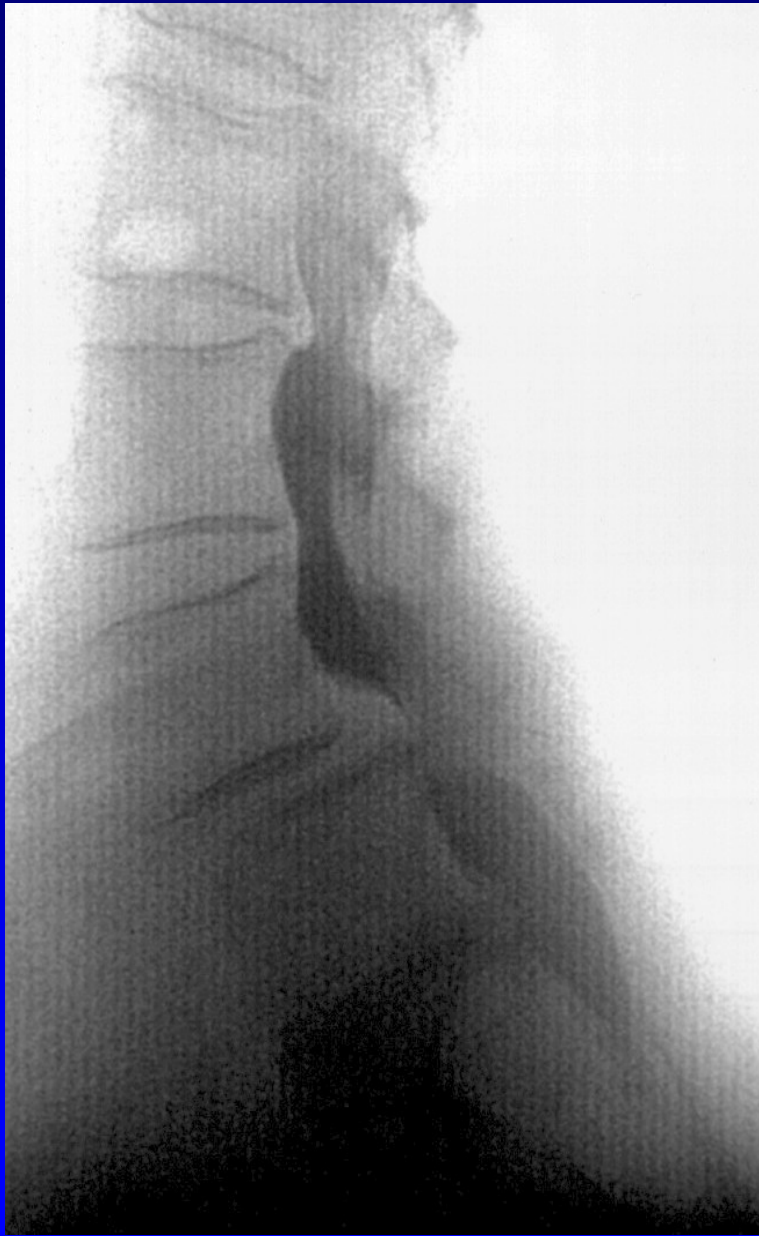Narrowing below 10 mm - myelopathy

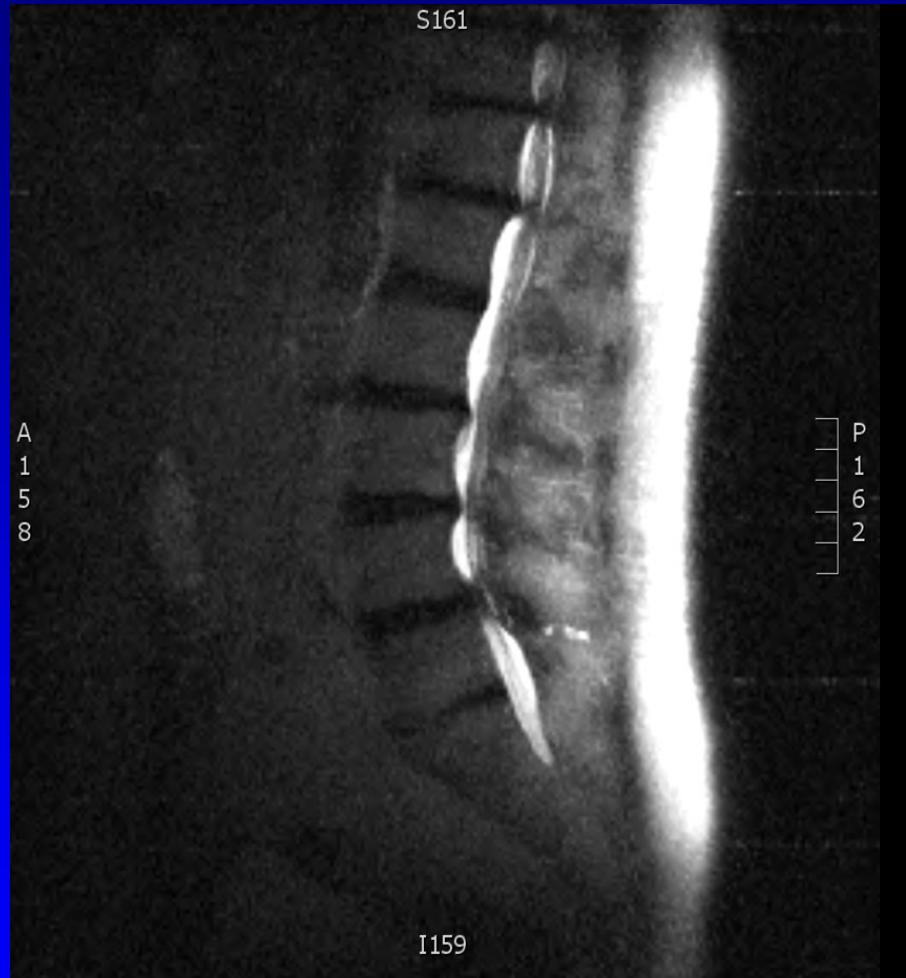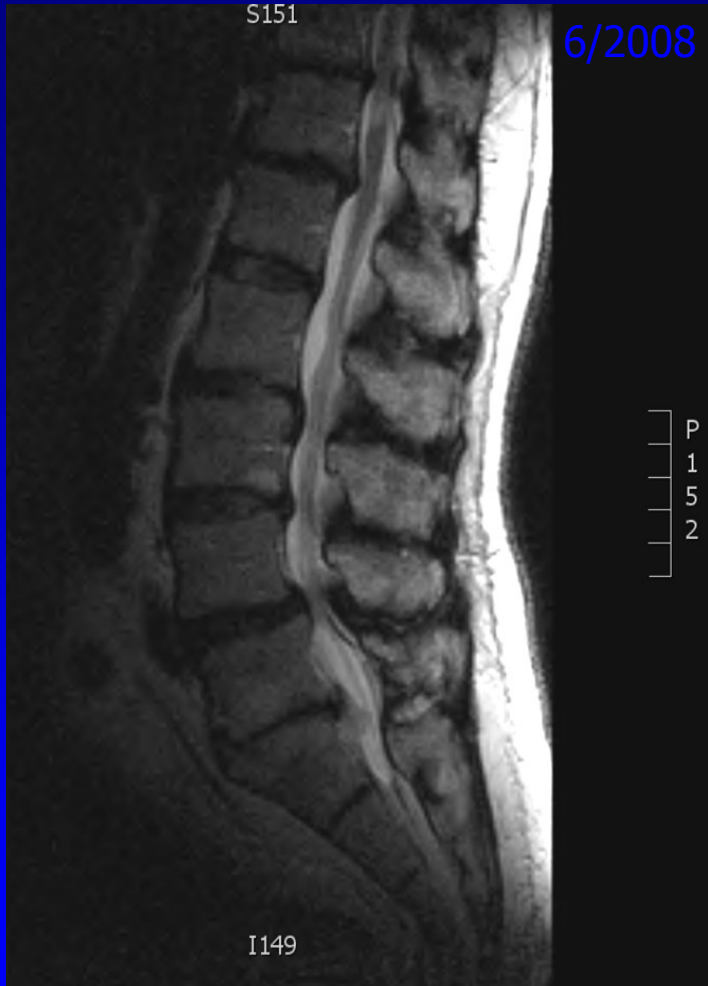Symptoms

- mild pain
- nerve root compression
- cauda equina syndrom
- neurogenic claudications

Flexion- extension







Therapy

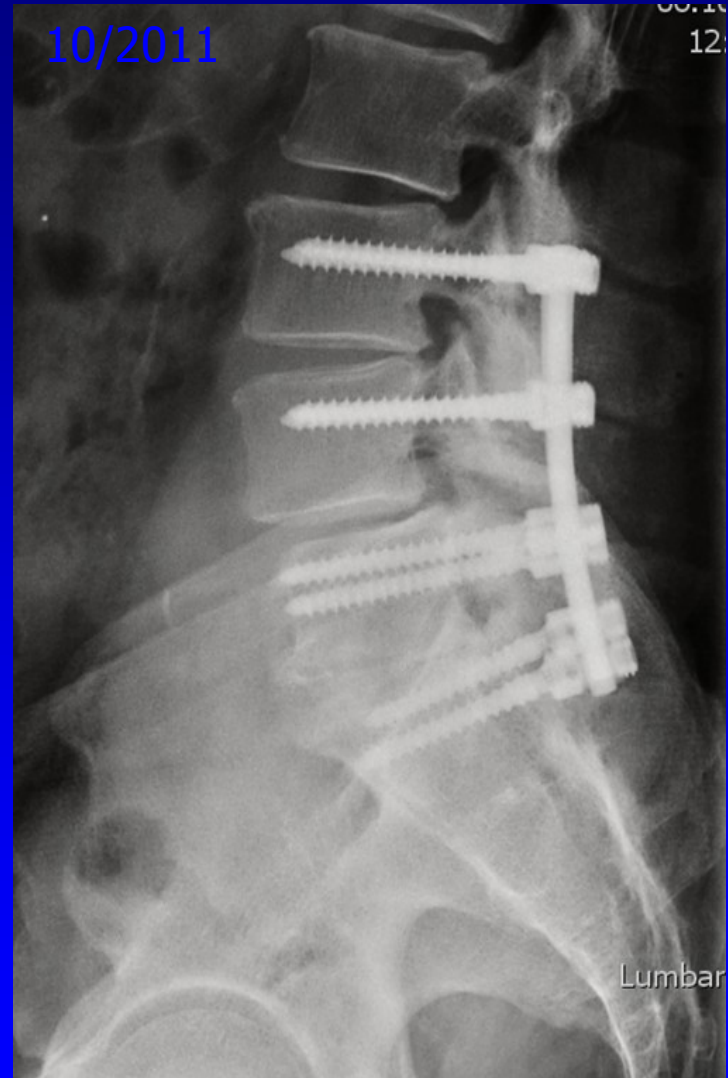
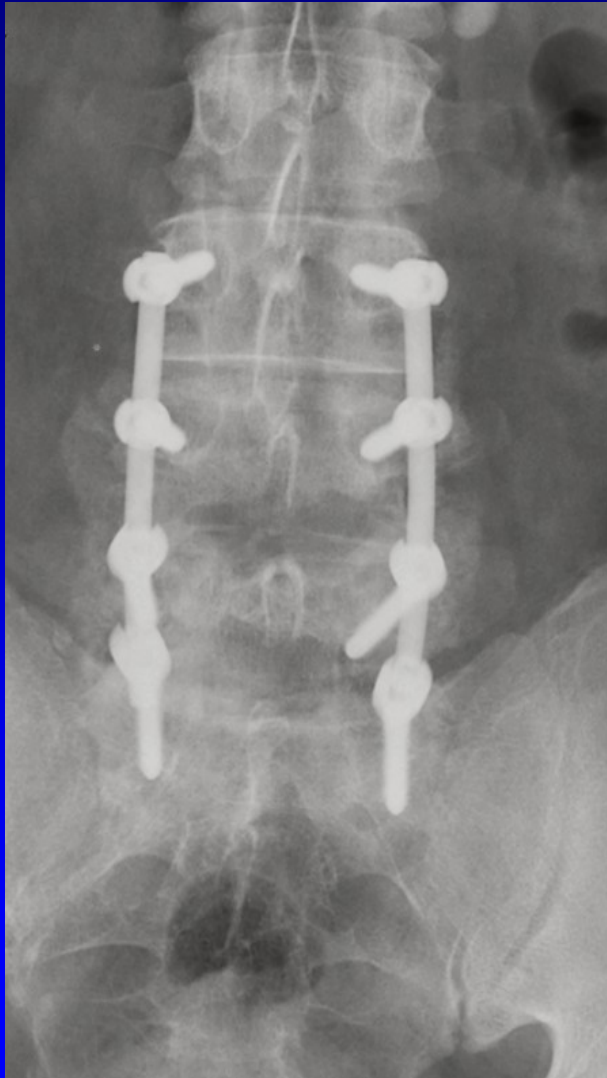
Conservative:

Orthesis, epidural applications of steroids

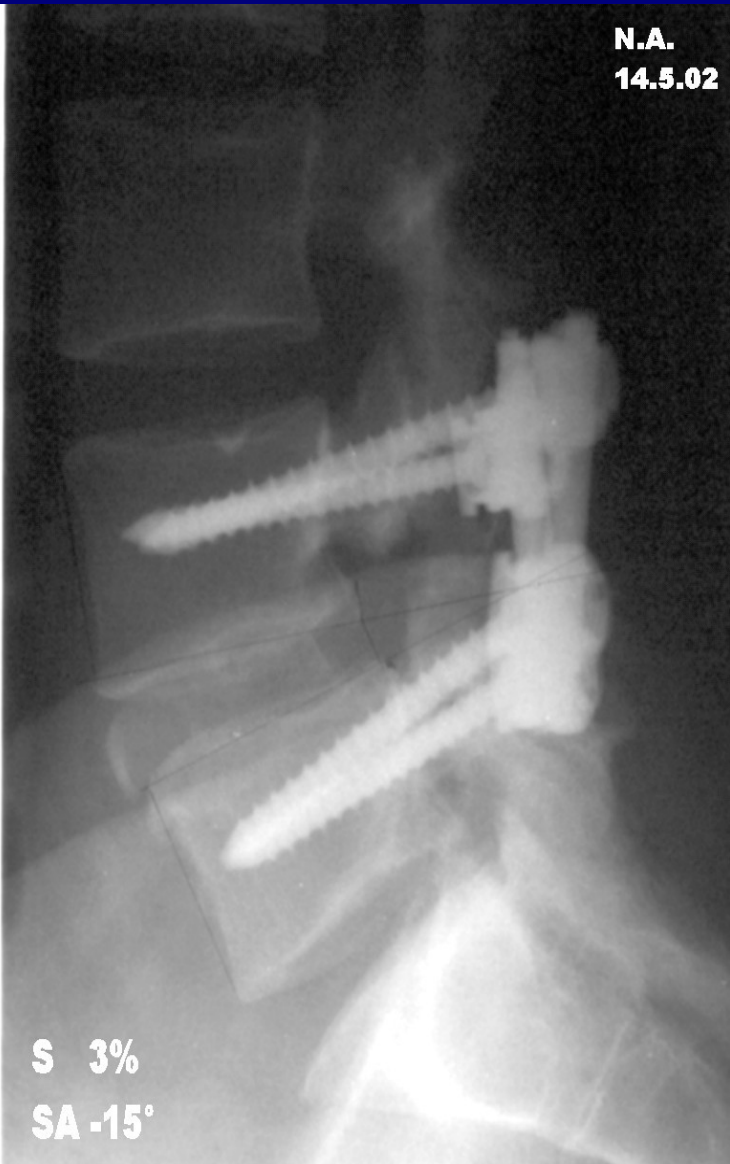
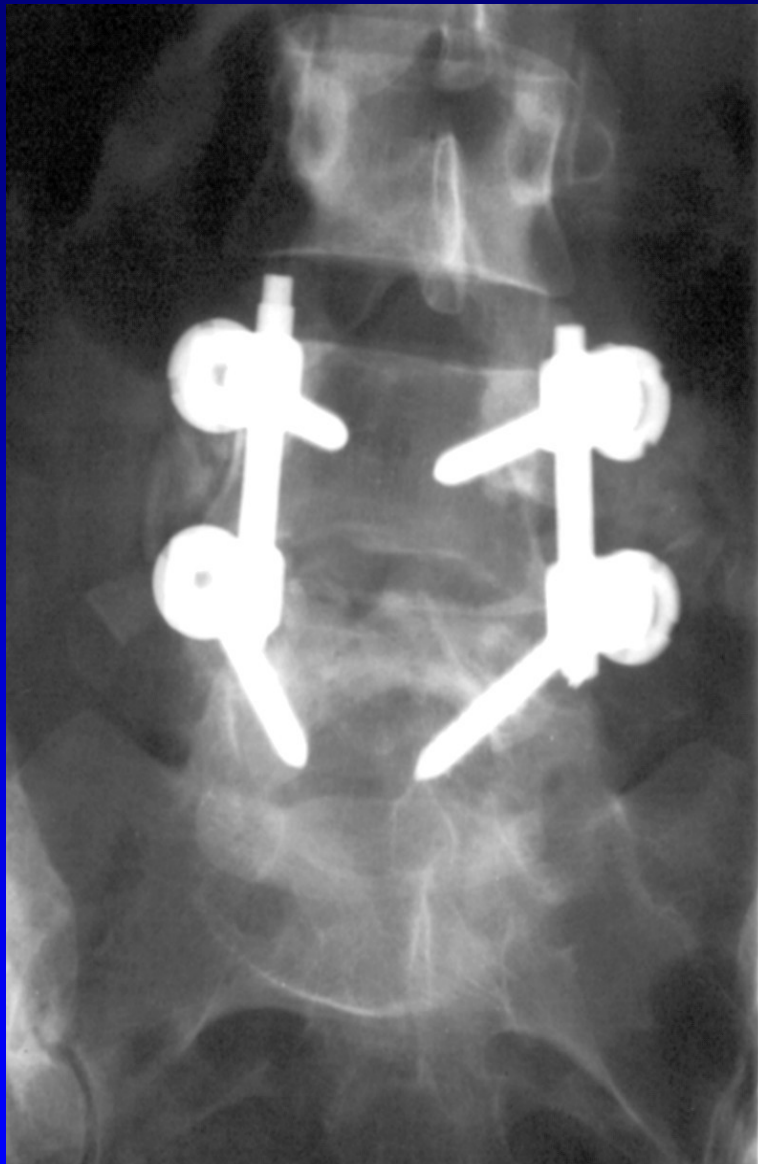
Pain department, exercise

Operative: decompression, instrumentation

Decompression, fusion, transpedicular screws

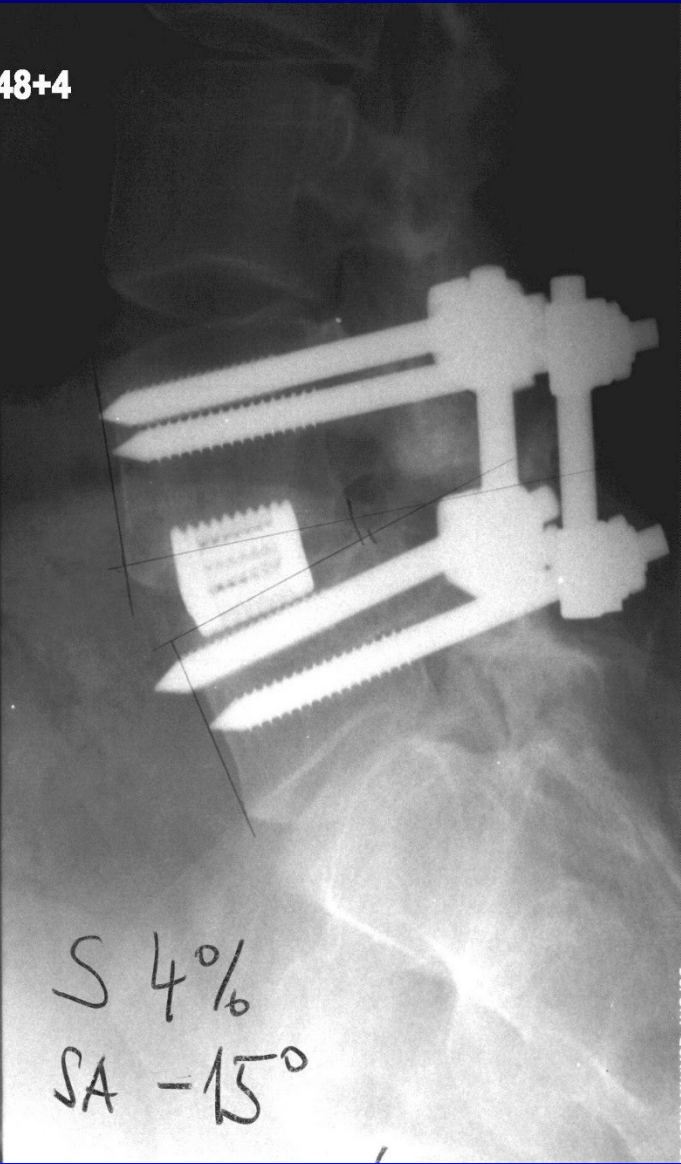
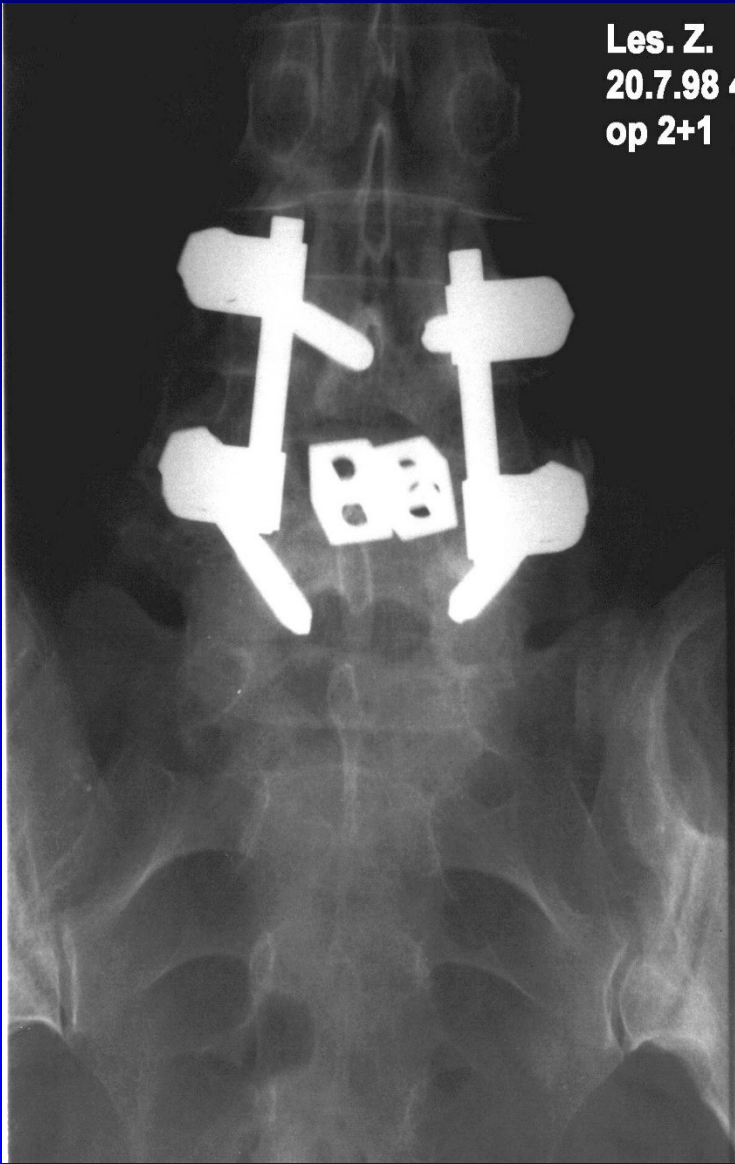


N.A.
14.5.02



S 3%
SA -15°

Les. Z.
20.7.98 48+4
op 2+1



S 4°
SA -15°

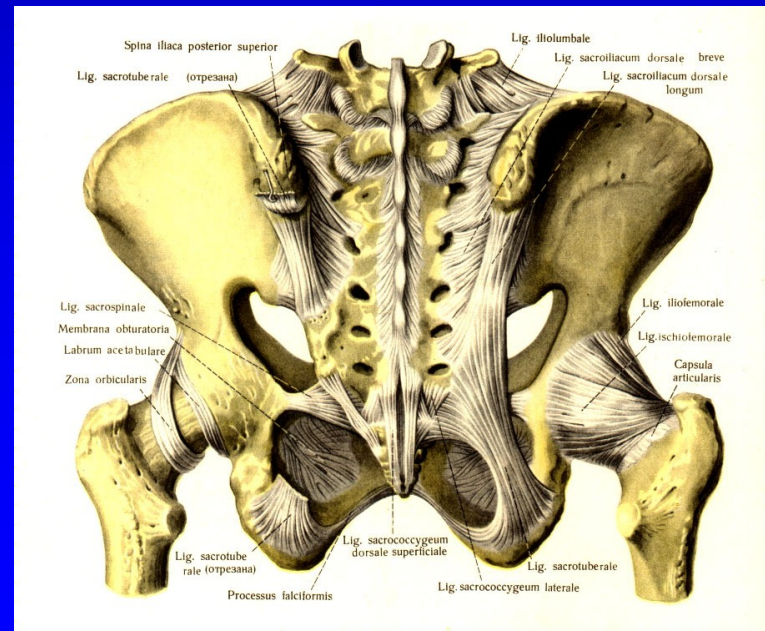
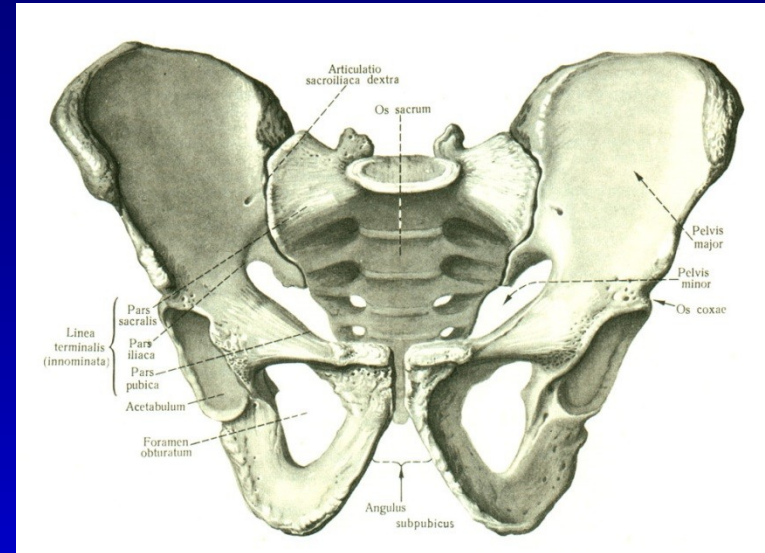
Pain from SI joint

Sacroileitis

Blockage

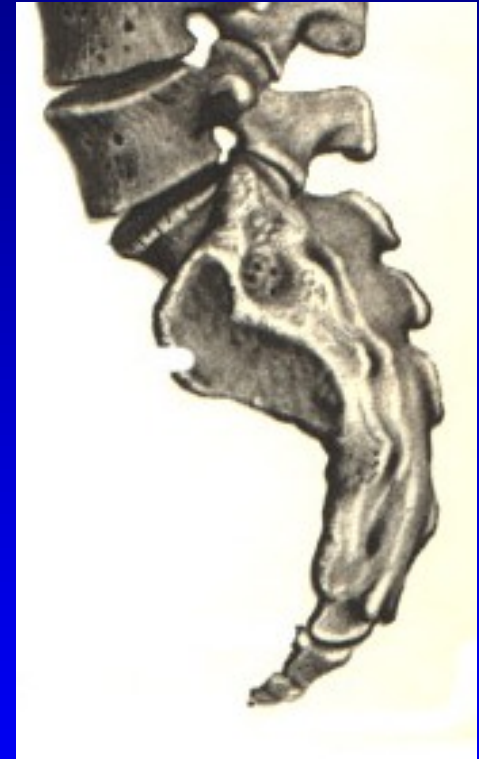Osteoarthritis

Posttraumatic conditions

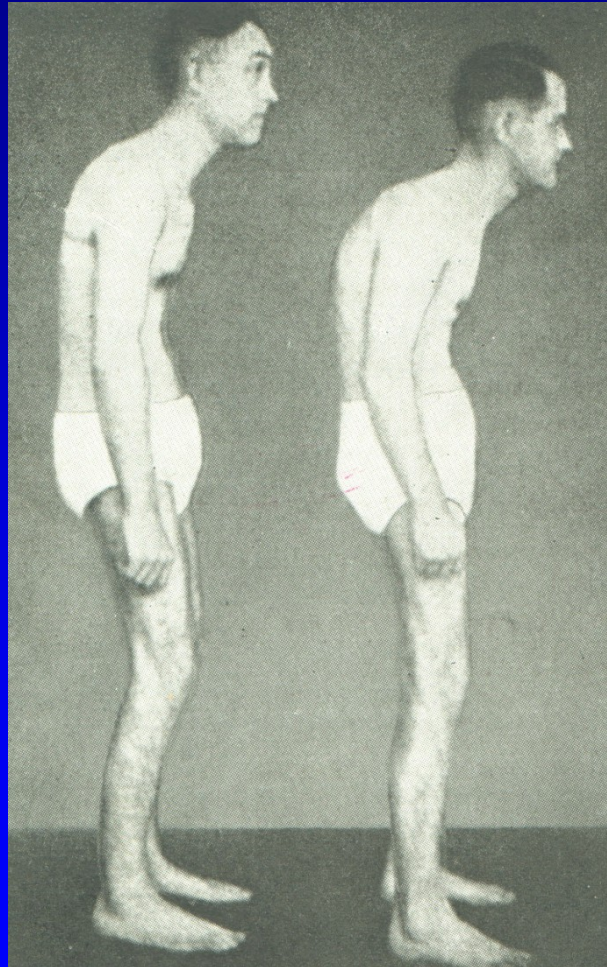


Coccygodynia

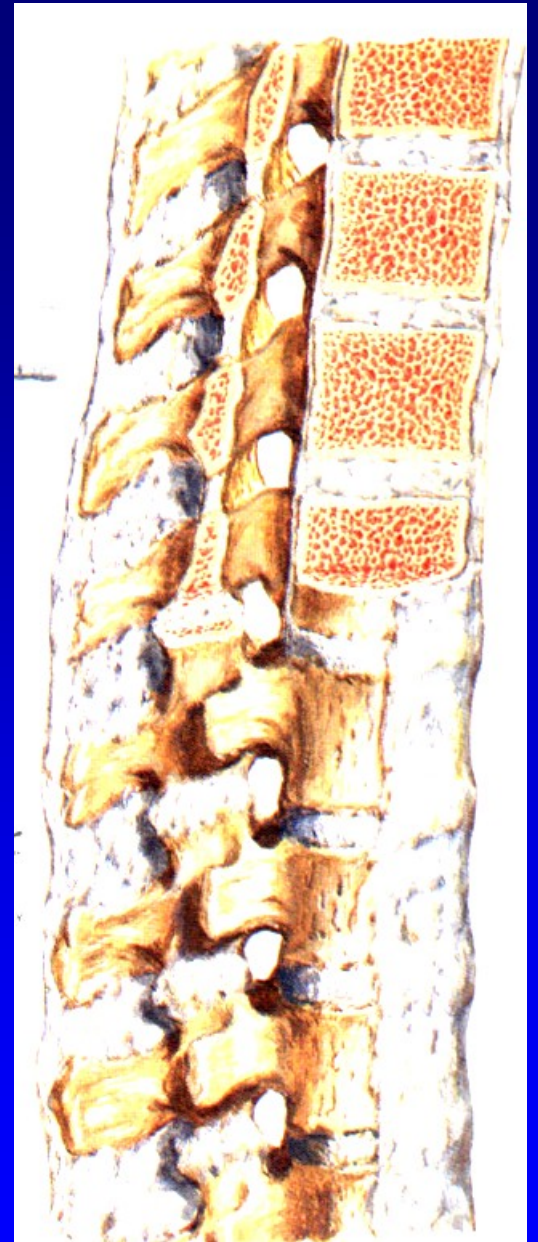Irritation of nerves around the bone
Ventral angulation
Hypermobility
Posttraumatic conditions
Irradiation from lumbosacral spine



M. Bechtěrev - spondylitis ancylopoetica ankylosing spondylitis

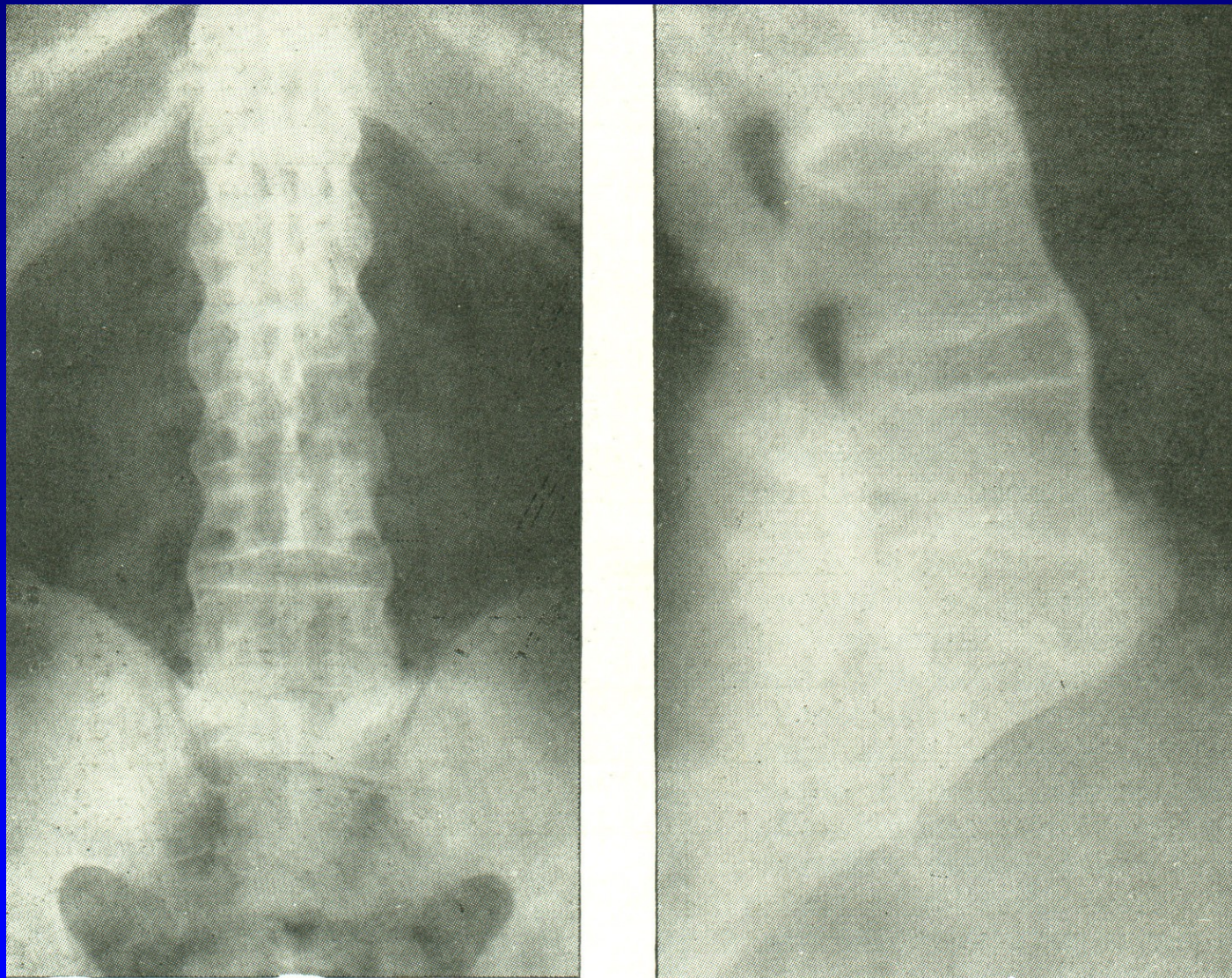


Obr. 20



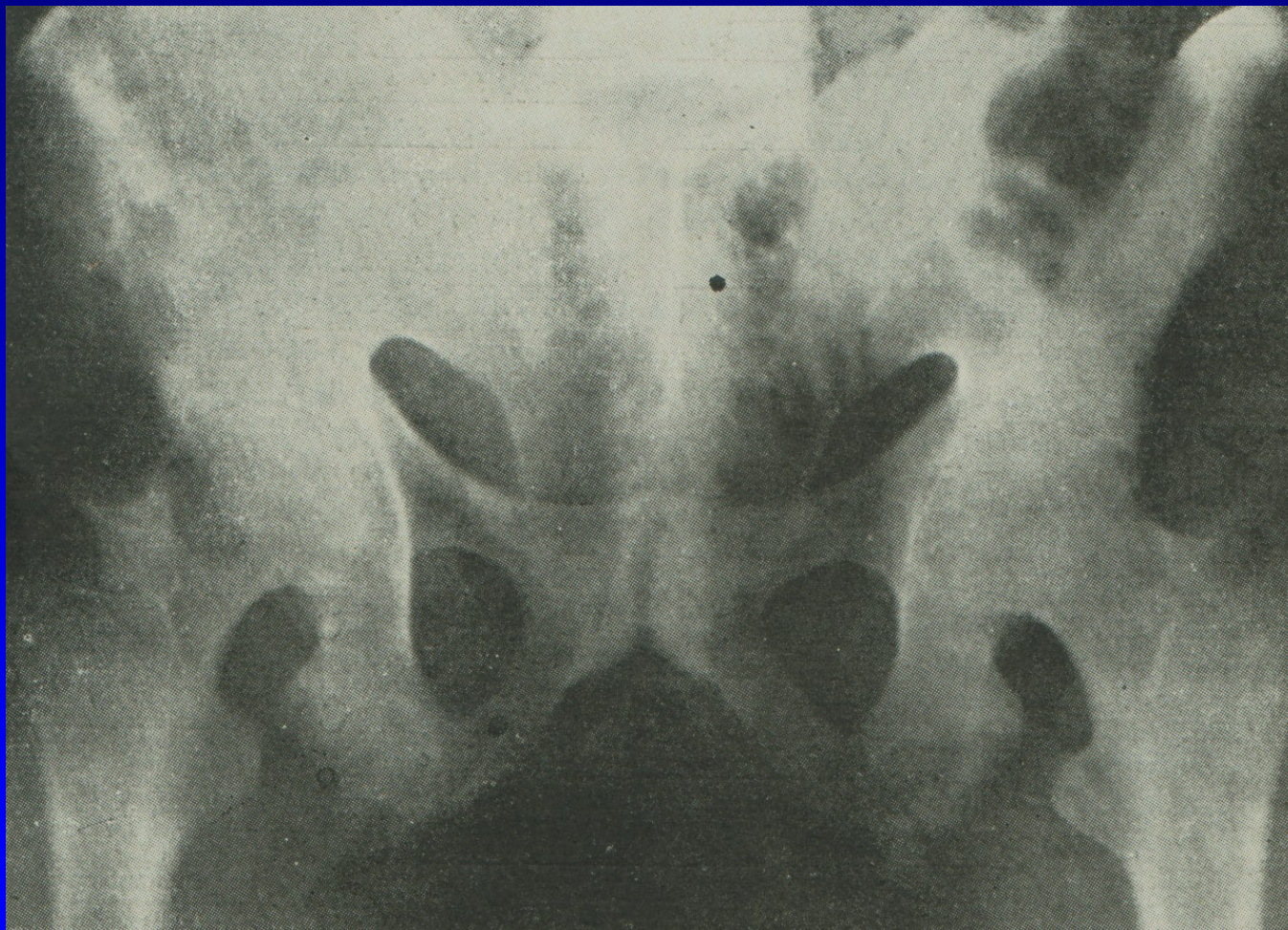
Obr. 21

M. Bechtěrev



Obr. 22, obraz bambusové tyče

M. Bechtěrev



Obr. 2

Therapy

Rheumatology, physiotherapy

Total hip replacement

Thoracic spine

Osteochondrosis disci

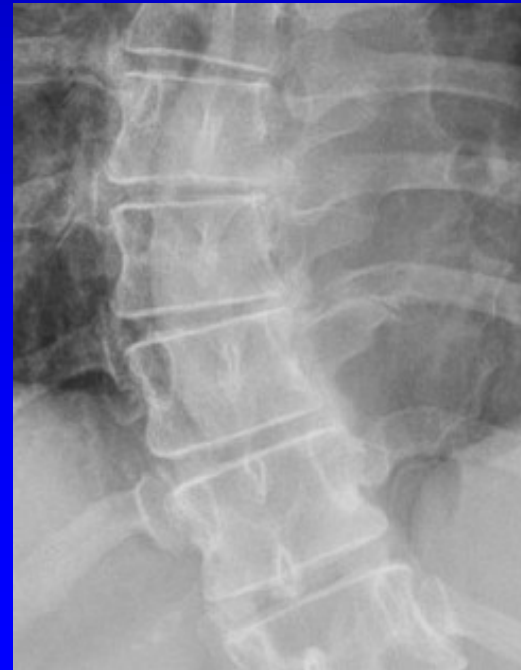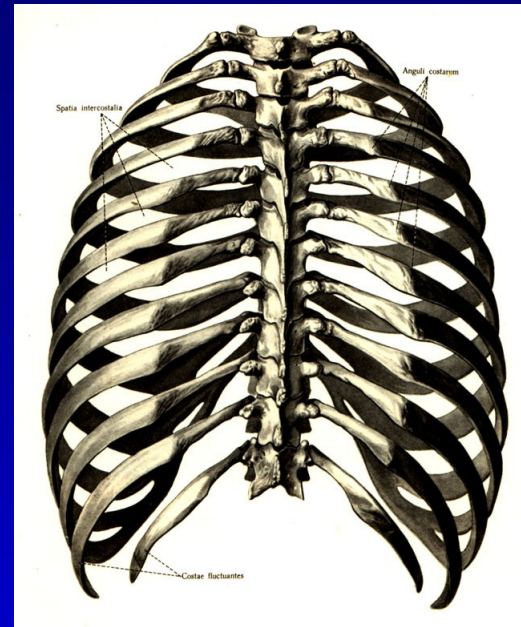
Spondylosis deformans

Spondylarthrosis deformans

Arthrosis costovertebralis

Hyperkyphosis

Scoliosis



Cervical spine

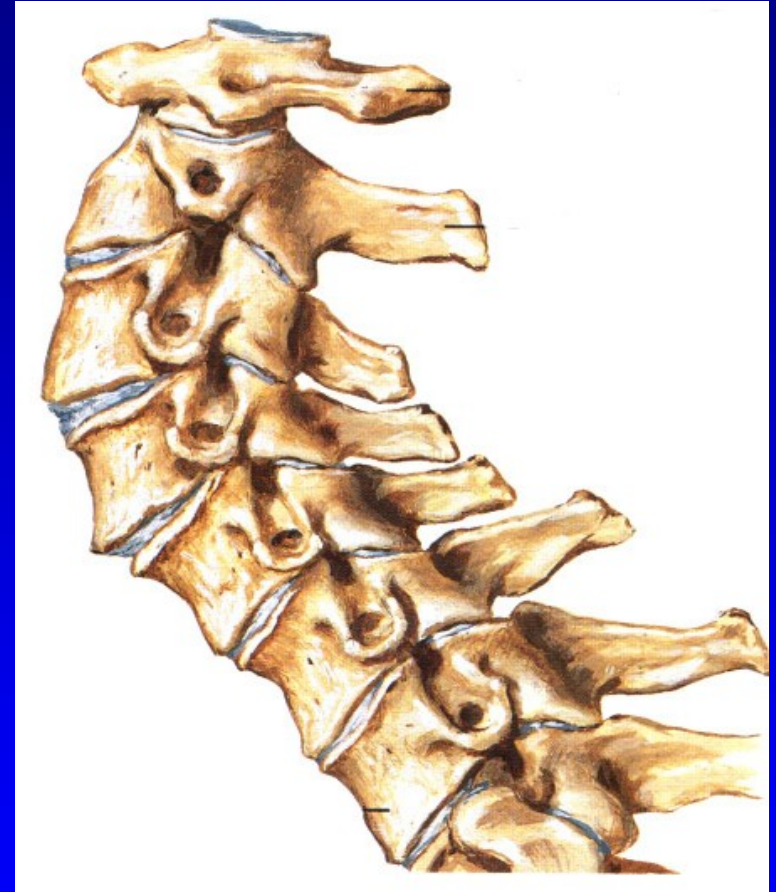
Osteochondrosis disci

Hernia disci

Spondylosis deformans

Spondylarthrosis intervertebralis

Spondylarthrosis uncovertebralis



Neck pain

Torticollis

Chronic neck pain

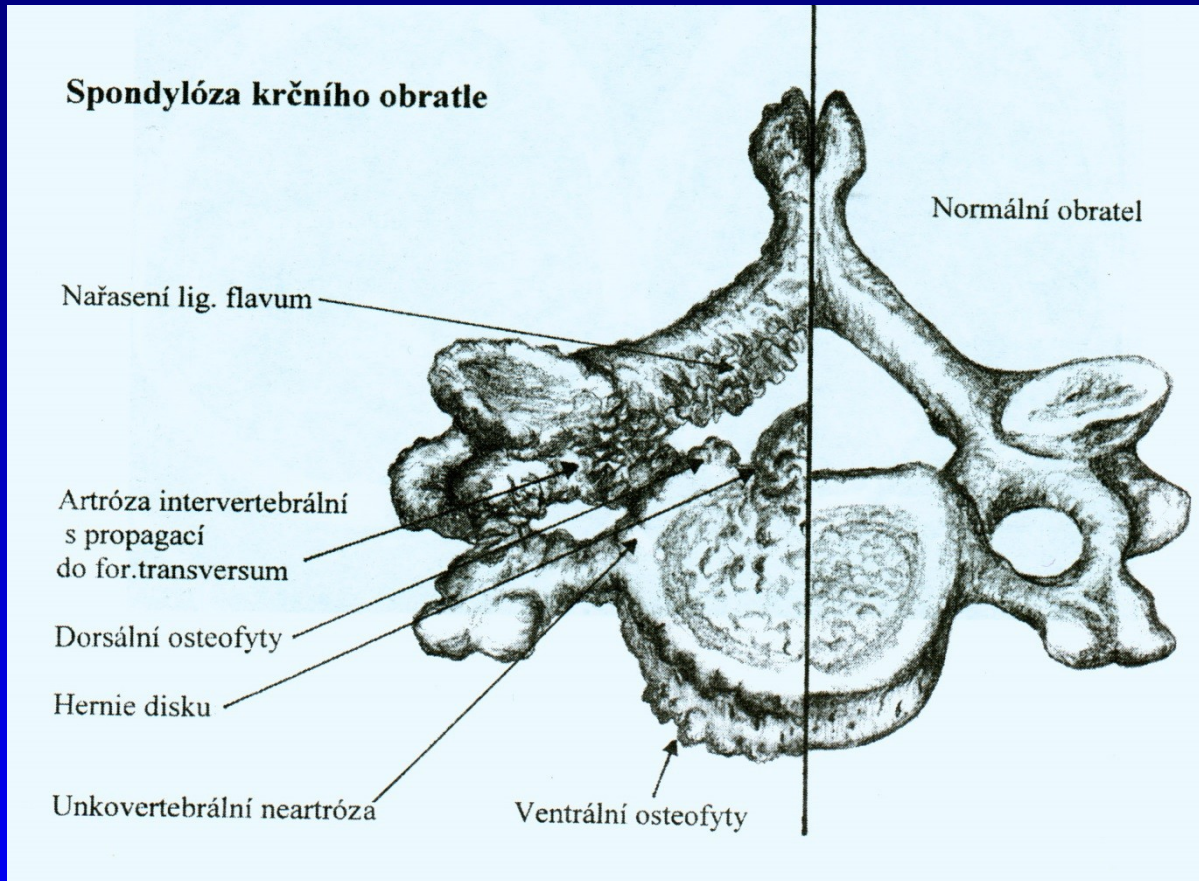
Cervicocranial syndrom

Cervicobrachial syndrom

Nerve roots syndroms

Spondylogenic myelopathy

Spondylosis in cervical spine

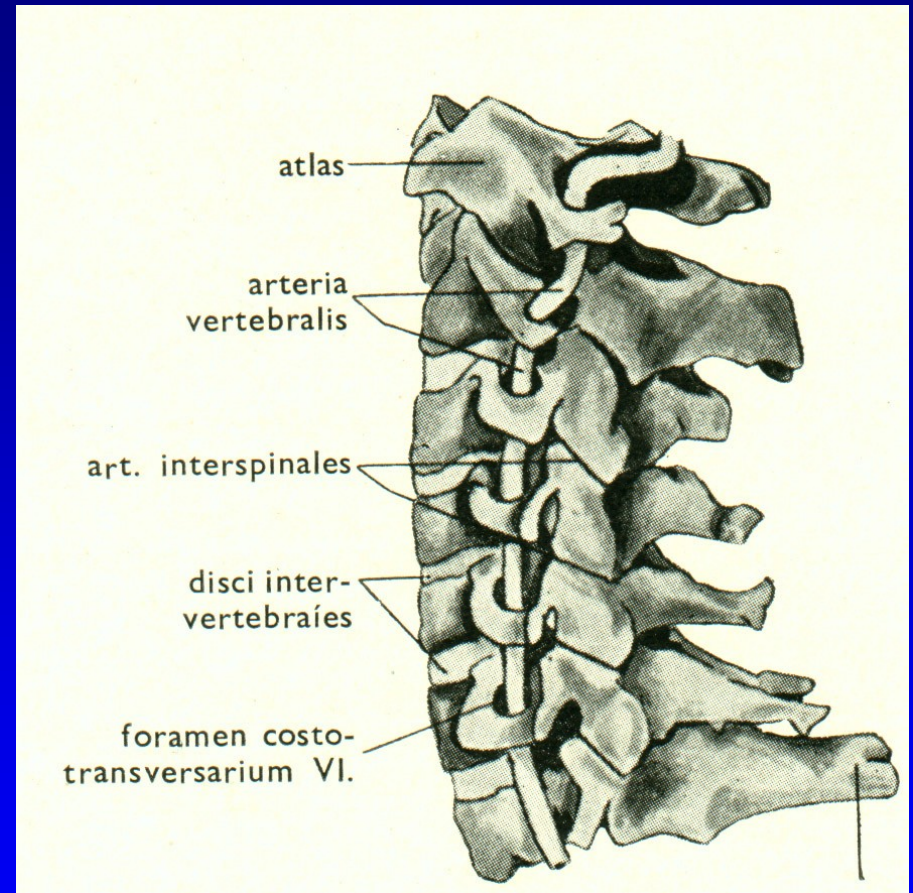


Obr. 26. Foramen costotransversarium with vertebral artery

Cervicocranial syndrom

Neck pain
Irradiation in to head and forehead
Muscle hypertonus
Nausea, vomiting, sweating
Dizziness

Cause:
Irritation of posterior sympatic cord
along vertebral artery



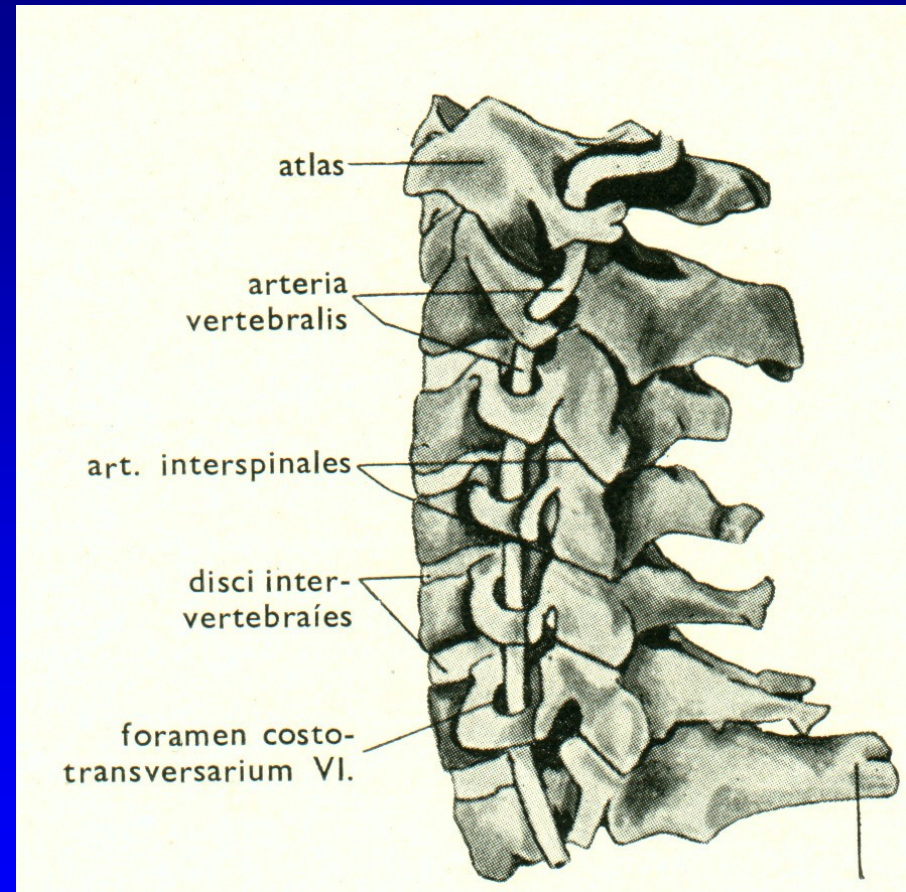
Obr. 27

Cervicobrachial syndrom

Neck pain irradiating into
upper extremity up to fingers

Diffuse localisation

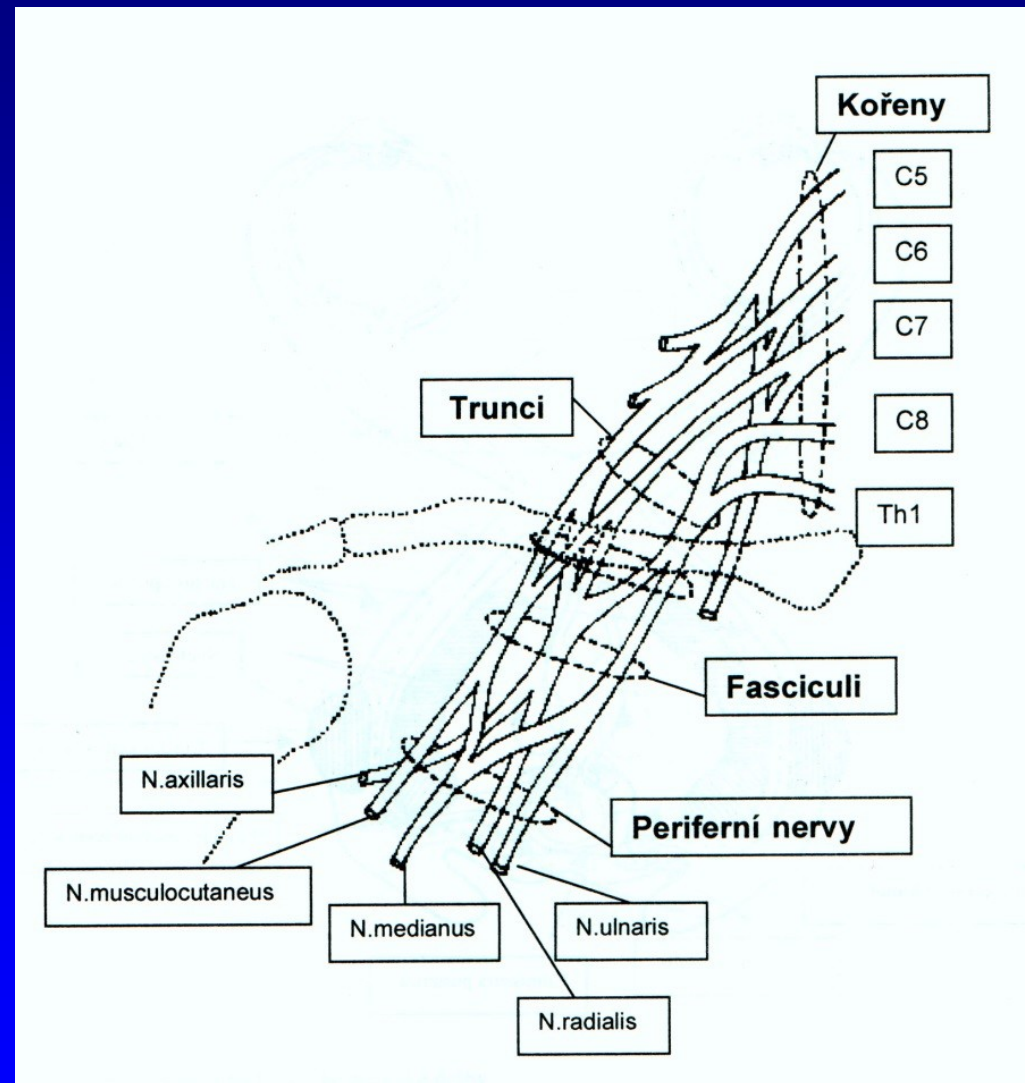
No nerve root localisation



Nerve roots cervical syndroms

Compression of nerve roots
Often C6 and C7
Motor and sensor deficit

The cause:
Herniation of disc



Spondylogenic cervical myelopathy

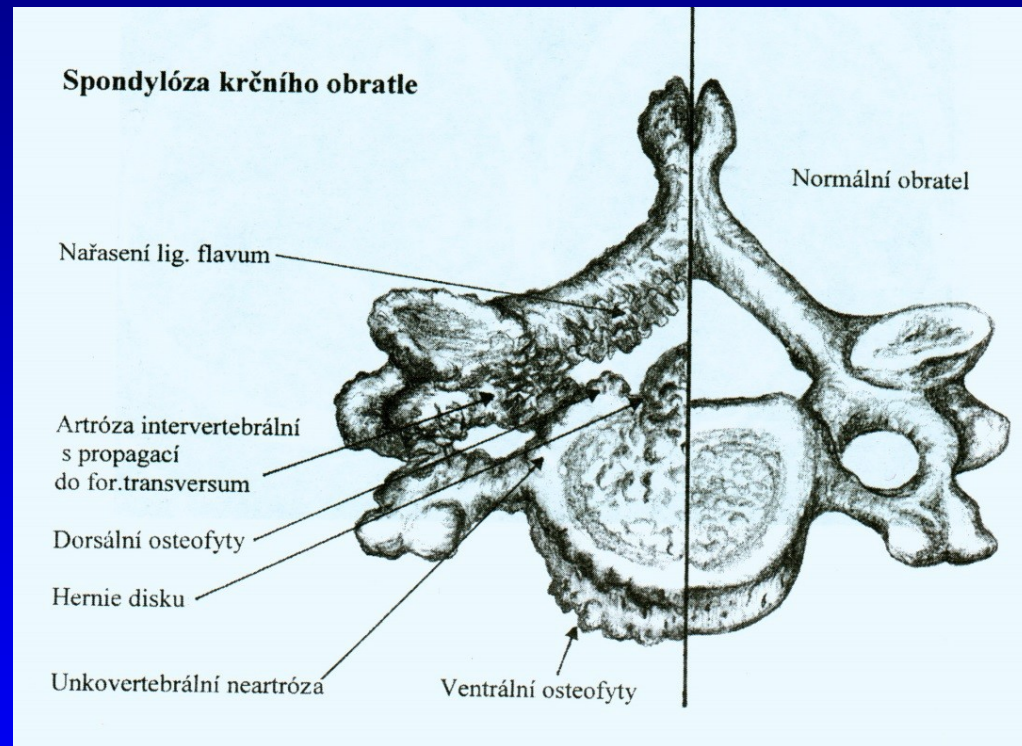
Narrow spinal canal

Direct compression of the spinal cord

Ischemia of spinal cord

Mixed palsy of upper and lower extremity

Impaired gait

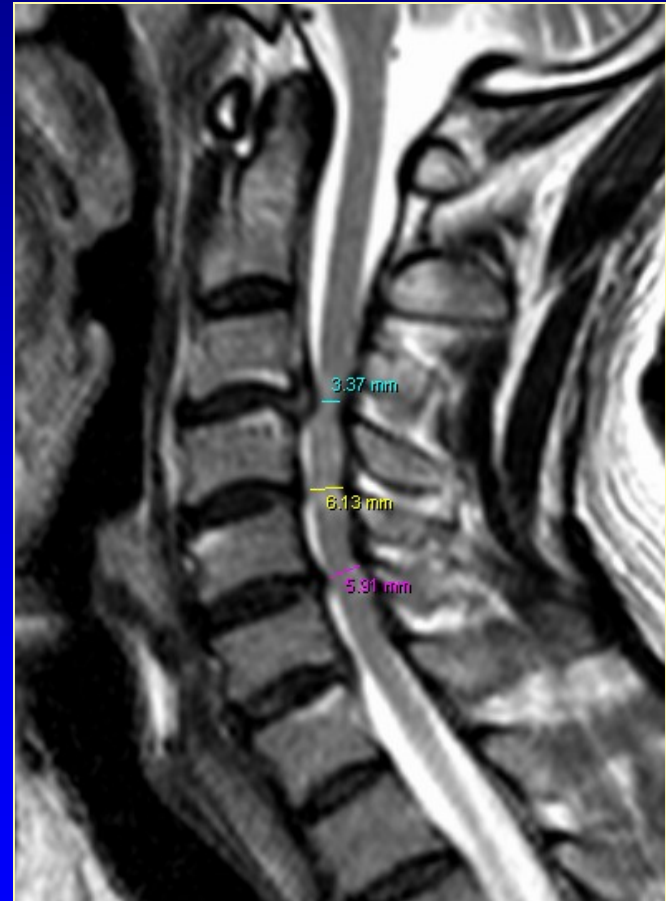

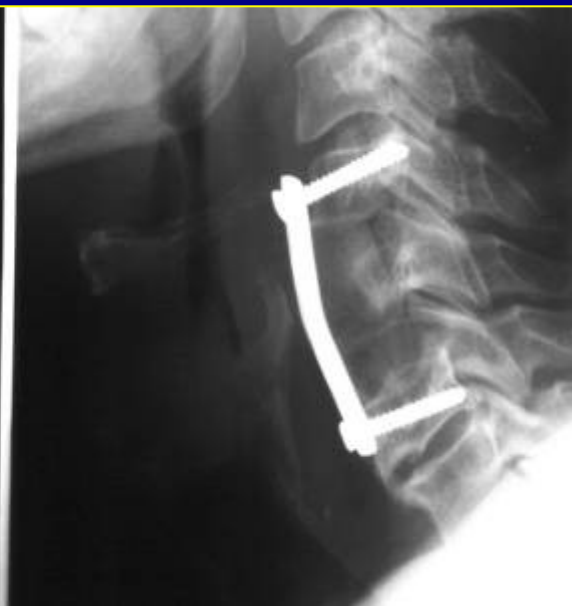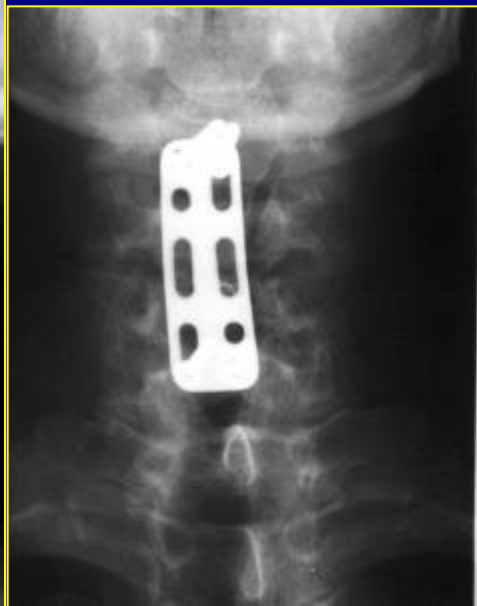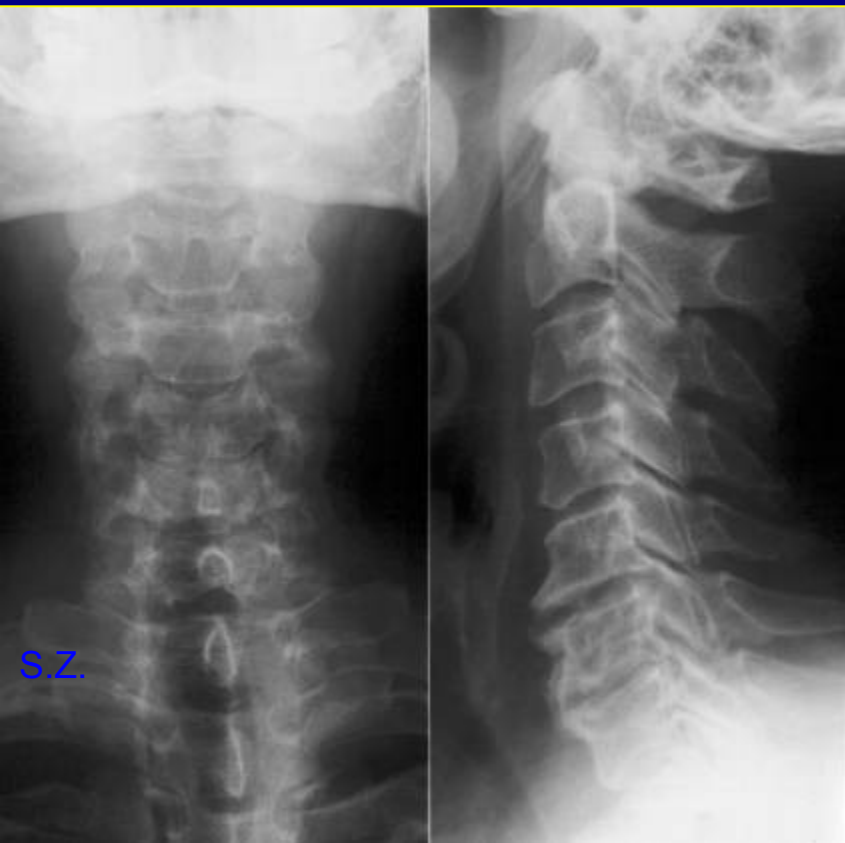Therapy of spondylogenic myelopathy

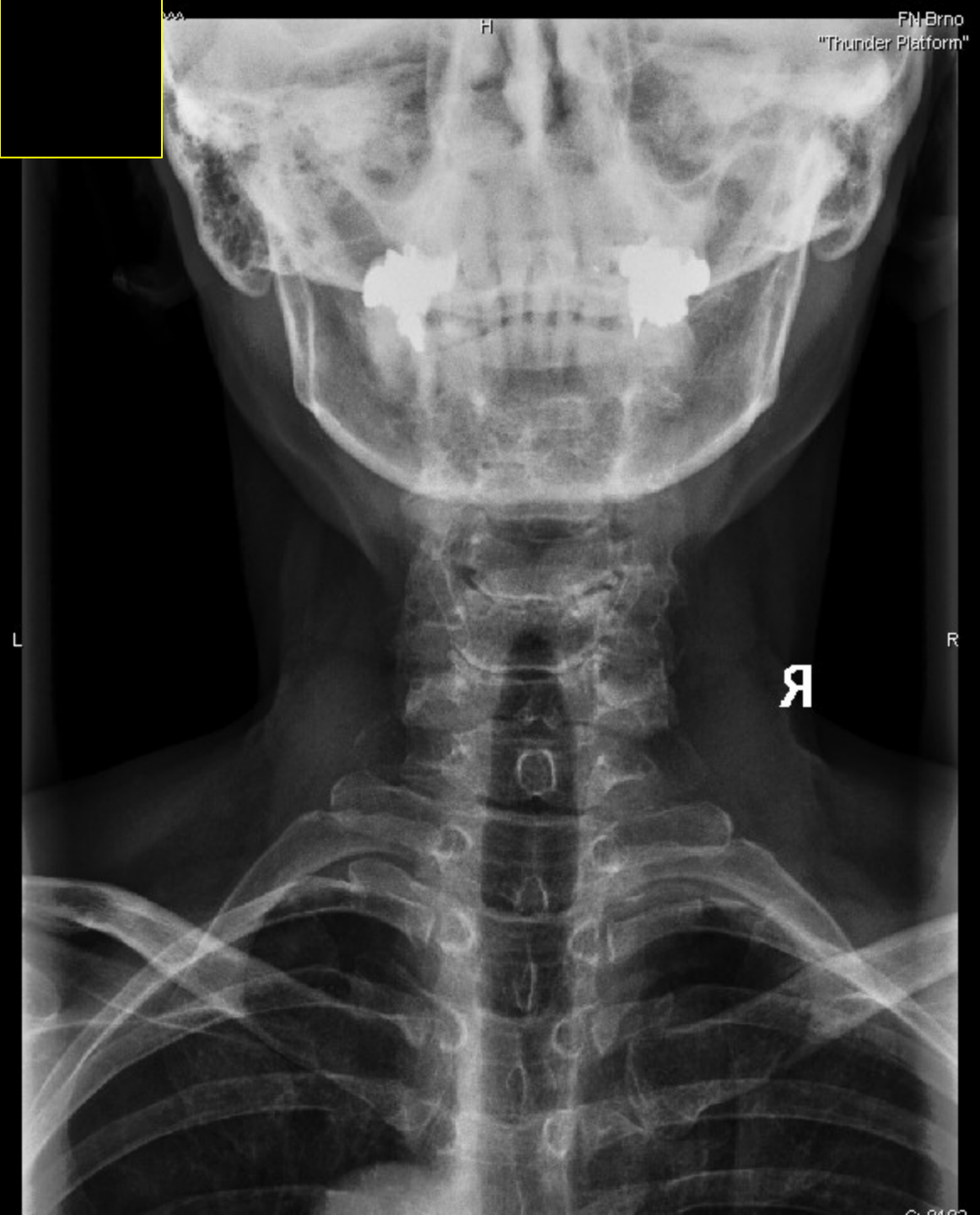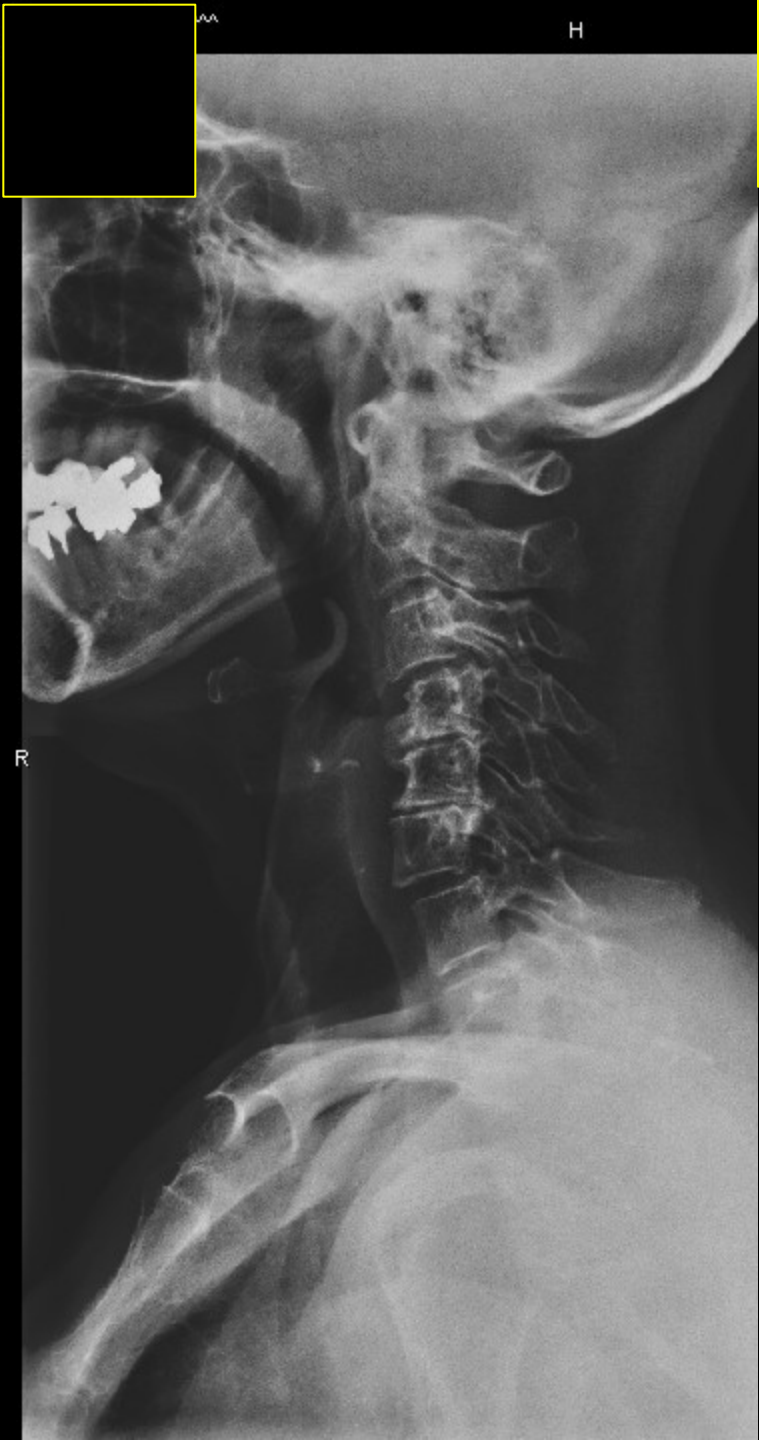Anterior approach

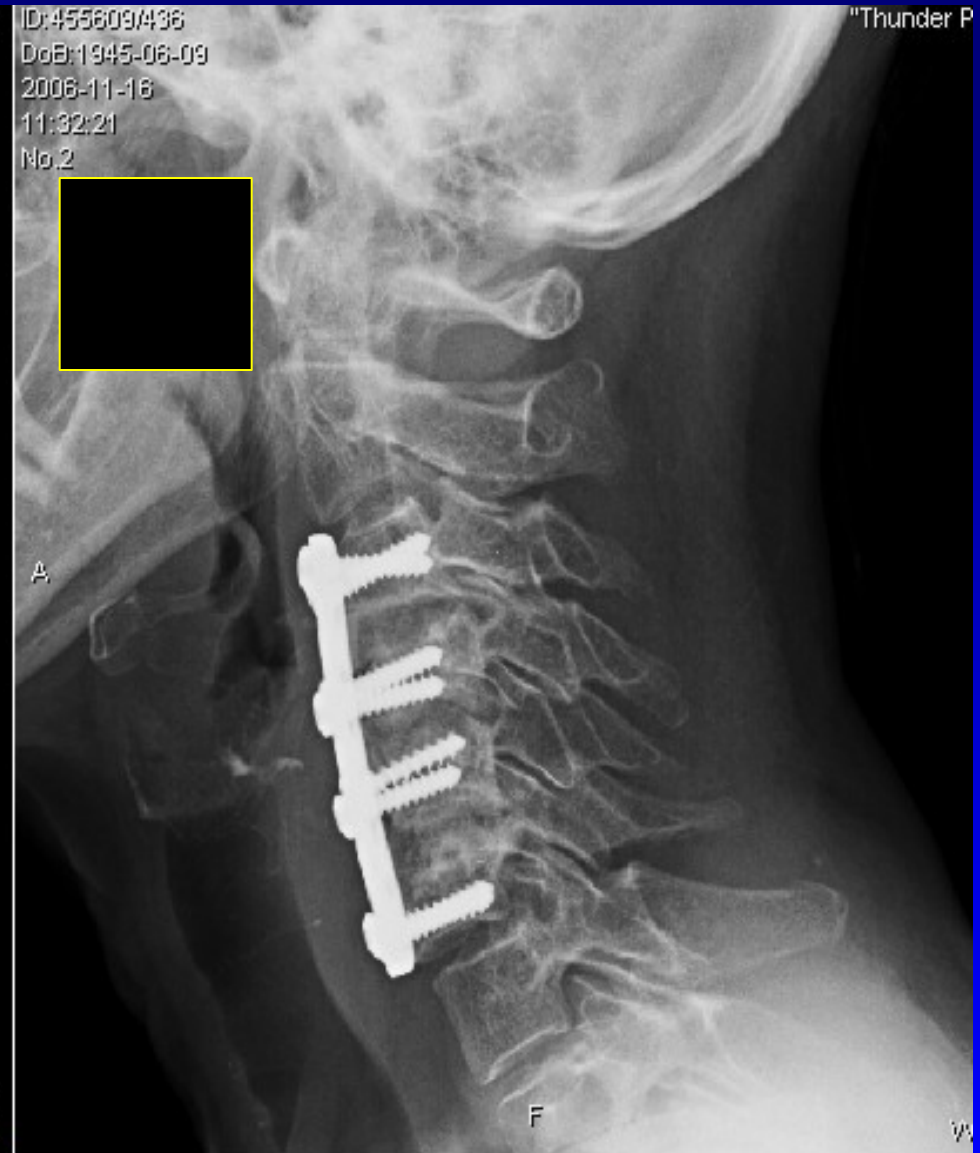
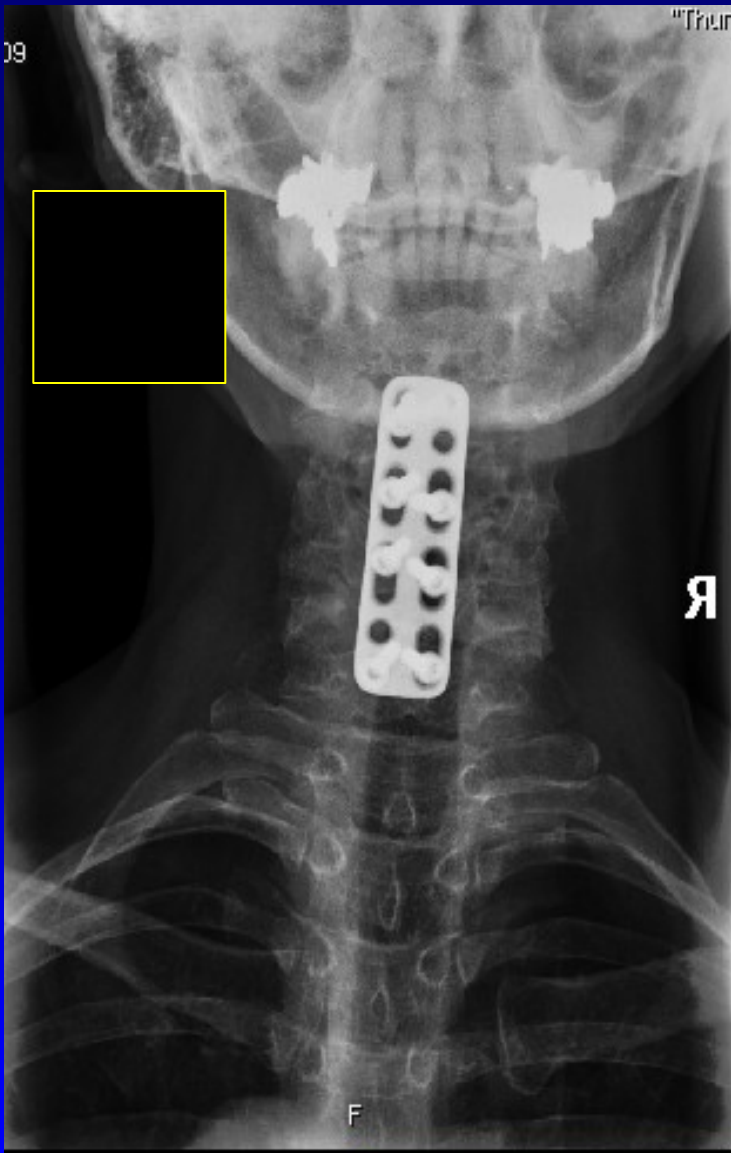
Posterior approach

Combined approaches

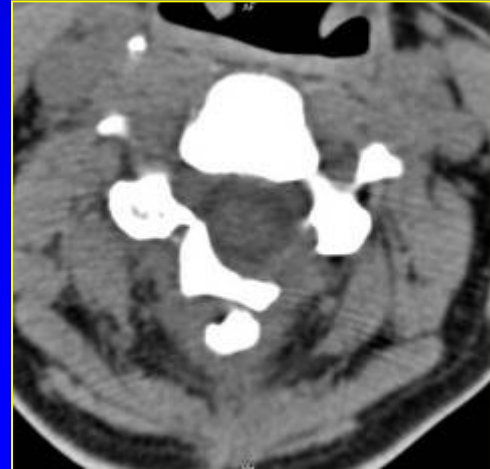
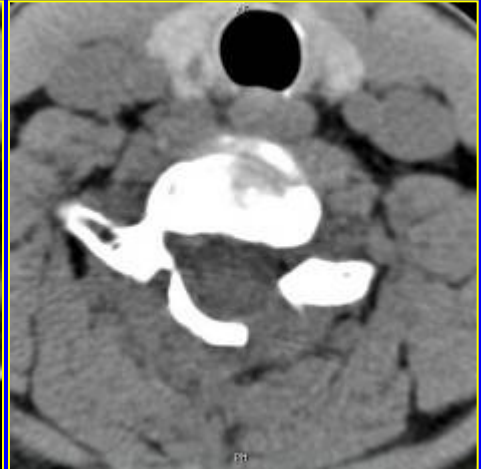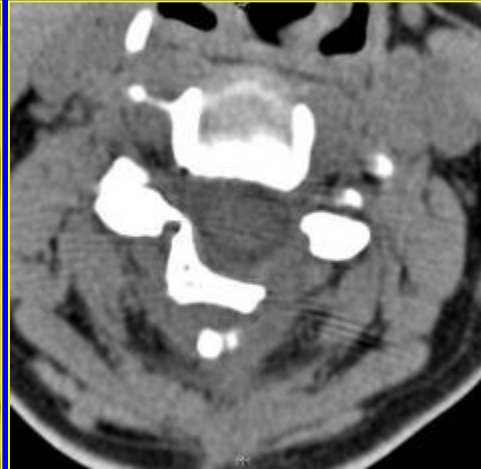
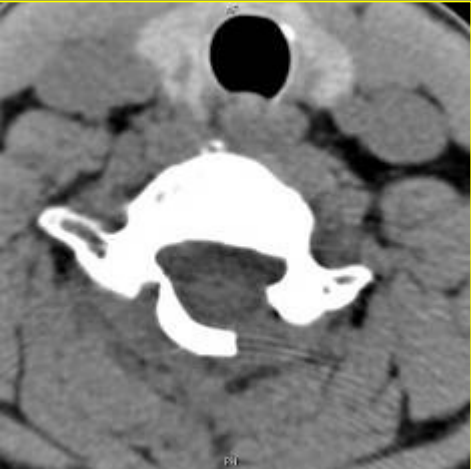

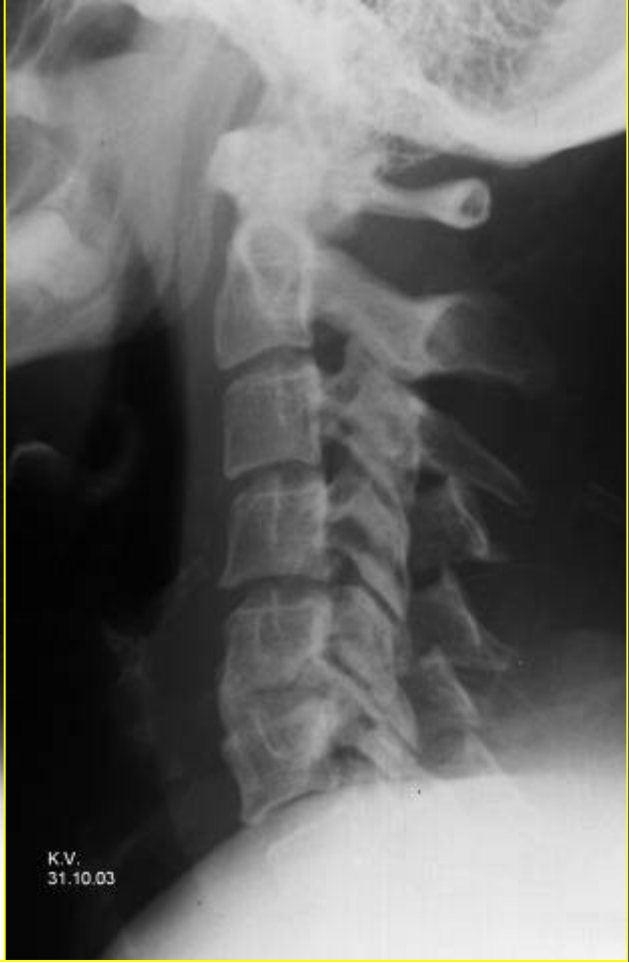
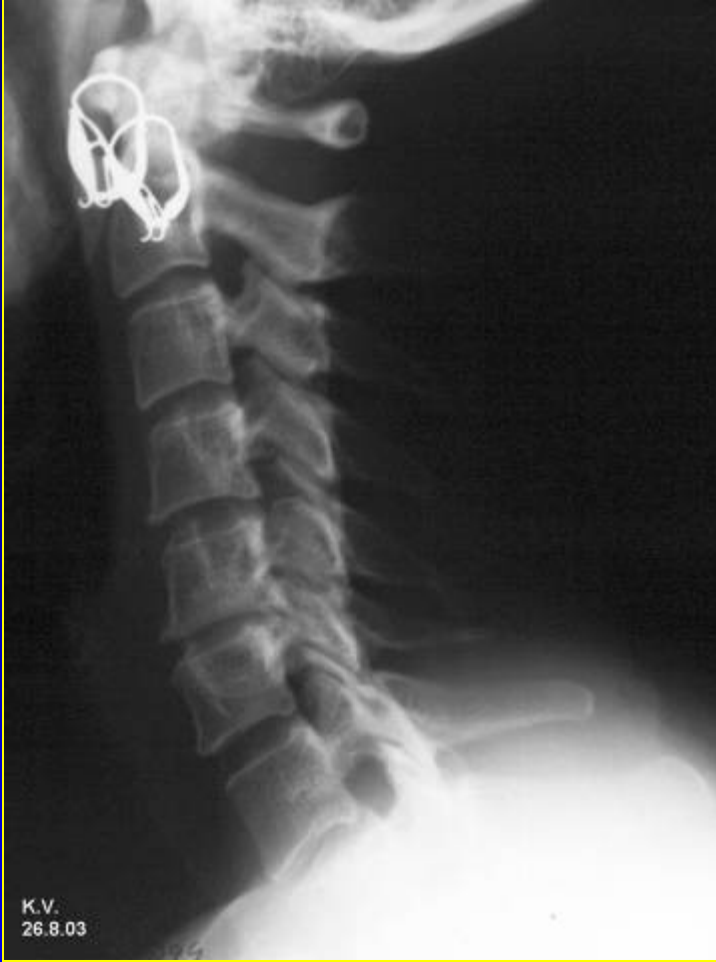


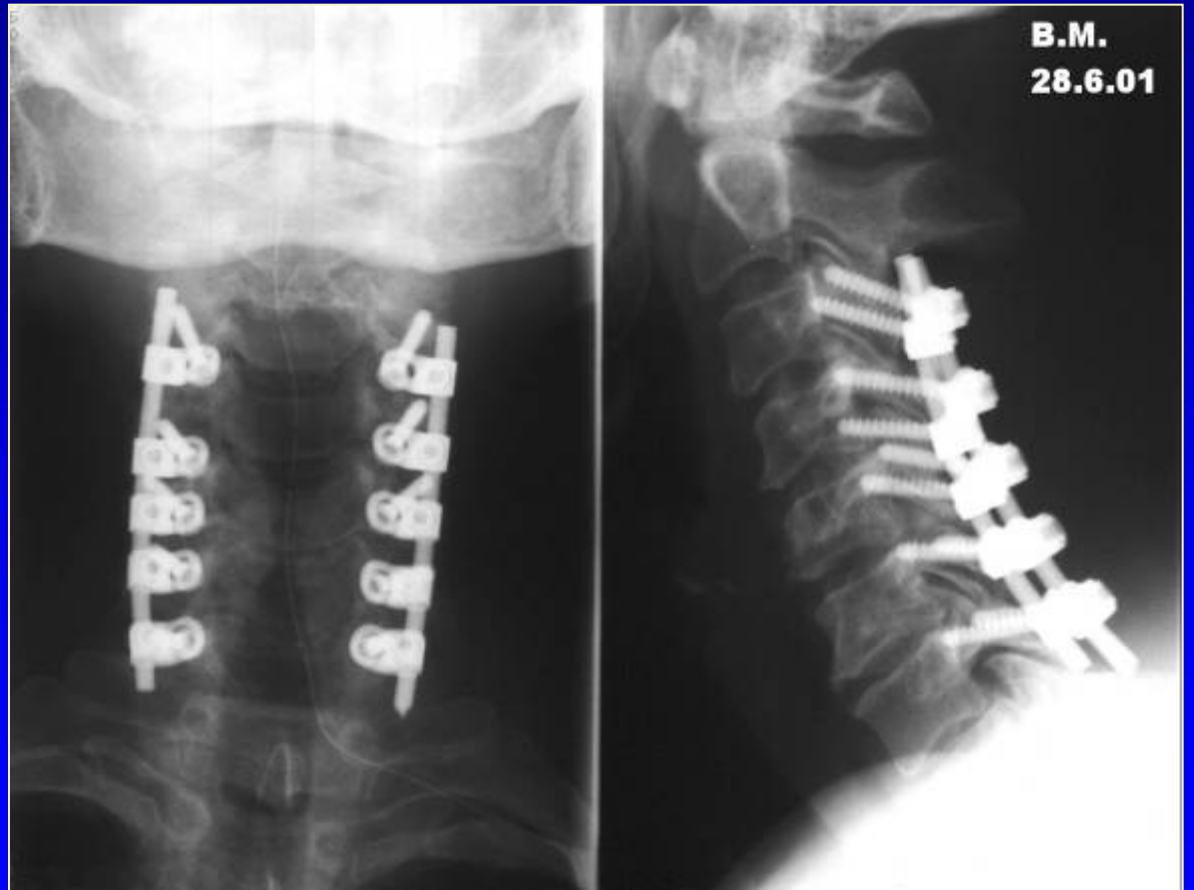
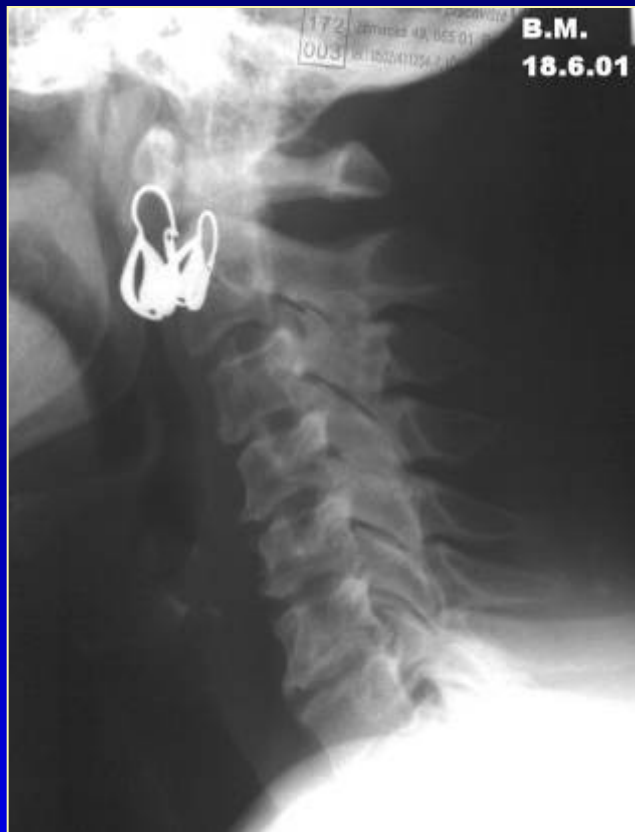

Open door
laminoplasty
and fusion





Differential diagnosis

R.A.

Ancylosis spondylitis

Tumors

Myeloma

Entesopathy

Osteoporosis

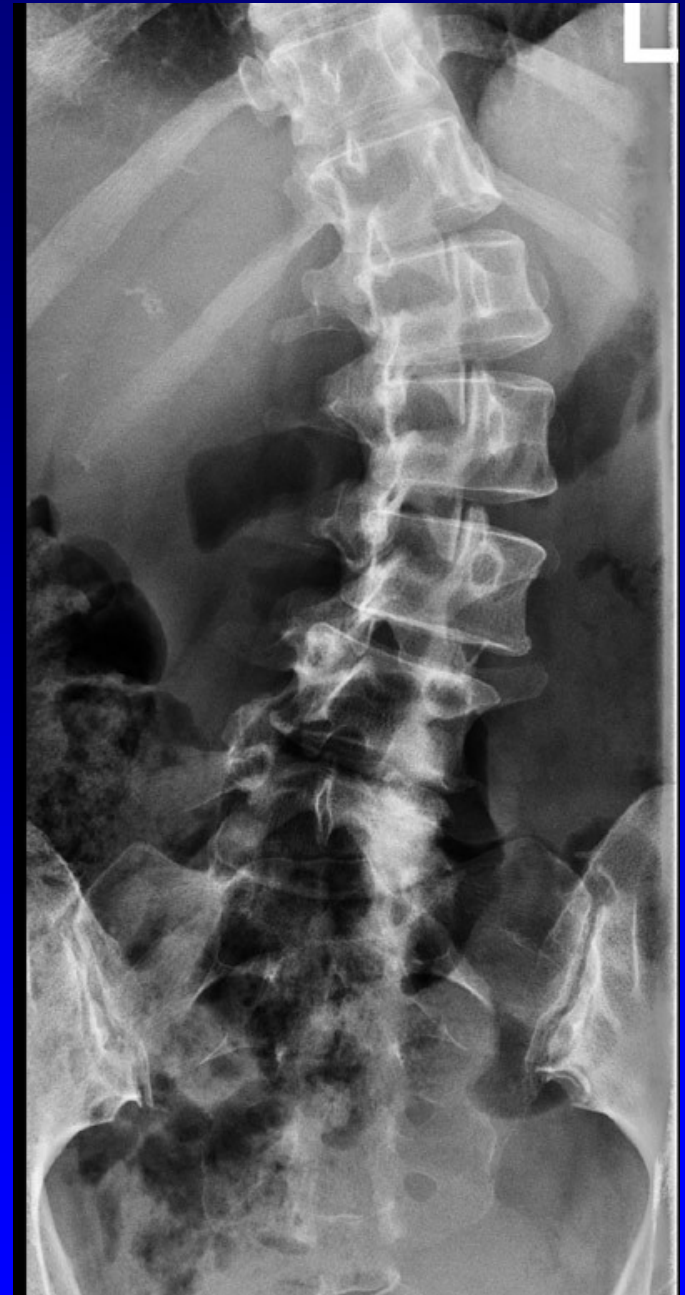Fractures

Herpes zoster

Peripheral neuropathy

Deformities of the spine

Spondylodiscitis



II. Pain from visceral organs

Larynx, pharynx, lymphonodes

Pleura, lungs, diaphragma

Gall bladder, liver, pancreas, duodenum

Retroperitoneum, kidney, ureter

Gynecological region

Urinary bladder, prostate