

# Pathology of the Liver and Biliary Tract

V. Žampachová

I. ÚP

# Hepatopathy

- prediagnostic stage, some suspicious signs present
- detailed diagnosis necessary, varied examination possibilities
- clinical findings
- laboratory findings
- imaging procedures
- morphological findings

# Diagnostic steps

- primary x secondary liver disease
- diffuse x focal liver disease
- if icterus present → pre-, intra-, posthepatic
- type of pathologic change: hepatitis, fibrosis, advanced - cirrhosis, cholestasis, focal lesion, tumor, ...

# Diagnostic steps

- **etiology**: genetic, metabolic, toxic, immunologic, vascular, infection, ...
- **stage**: prodromal, acute, chronic (> 6 months), cured
- **activity** of the process, **course** (regressive, stationary, progressive), **prognosis**

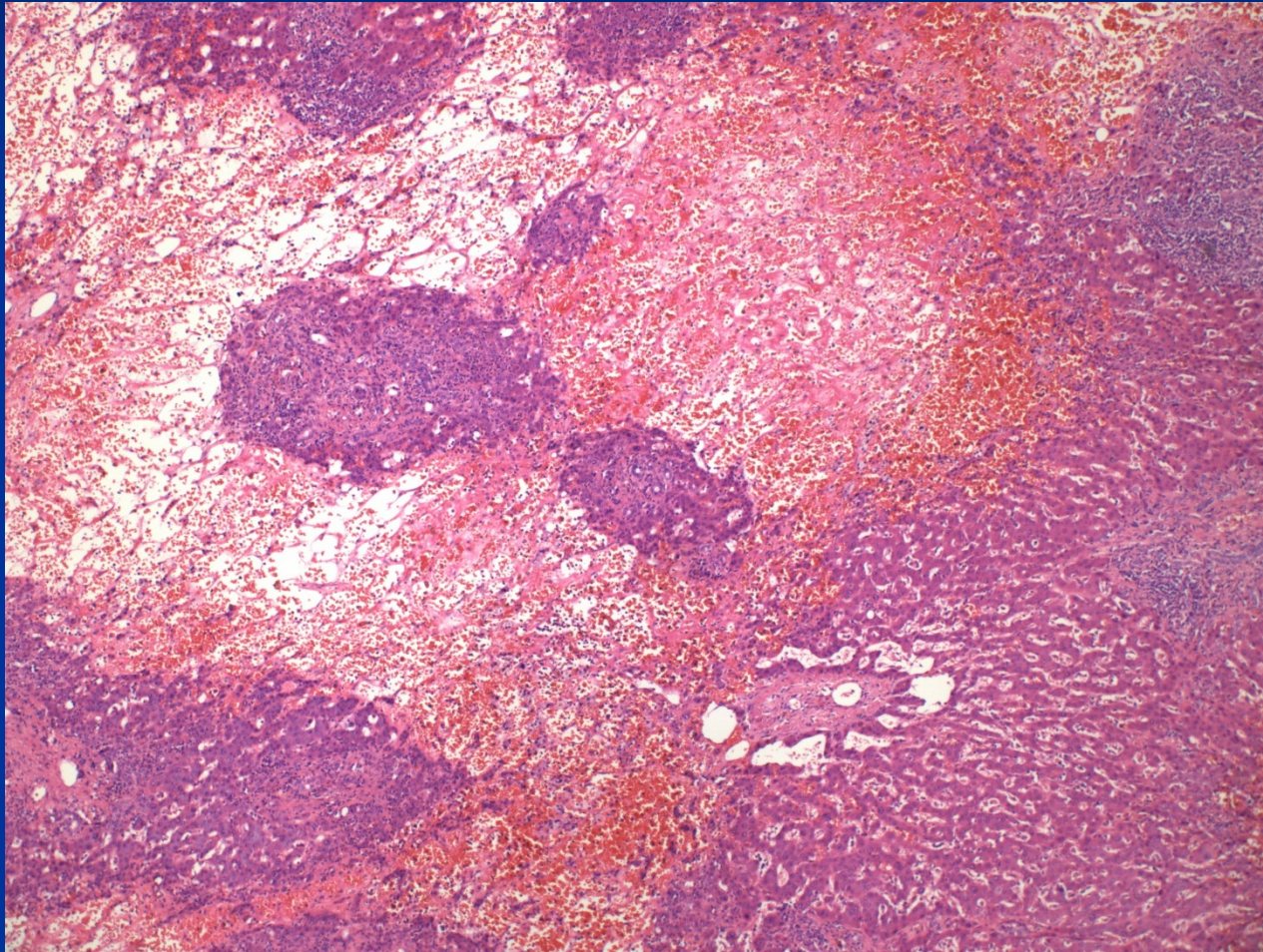
# Remarks on pathophysiology

- different forms of blood flow
  - portal arteries, portal veins
  - sinusoids lined by fenestrated endothelial cells + limited amount of extracellular matrix, incomplete BM: slow, low-pressure mixed blood flow → enough time for adequate contact of plasma substances with hepatocytes → physiological solute exchange with resorption, excretion
  - central veins: low-pressure venous blood

# Remarks on pathophysiology

- Pathological conditions with blood flow/resistance alteration → hepatocyte dysfunction:
  - ↑ blood pressure in central veins (thrombosis, heart failure, etc.) → ↑ BP in sinusoids → transformation of lining cells, loss of fenestration → ↓ solute exchange → hepatocyte dysfunction
  - inflammation → activation of ECM producing cells → deposition of collagen between endothelial cells and hepatocytes → ↓ solute exchange → hepatocyte dysfunction
  - shunts between arteries and veins → bypass of lobules

# Haemorrhagic liver necrosis



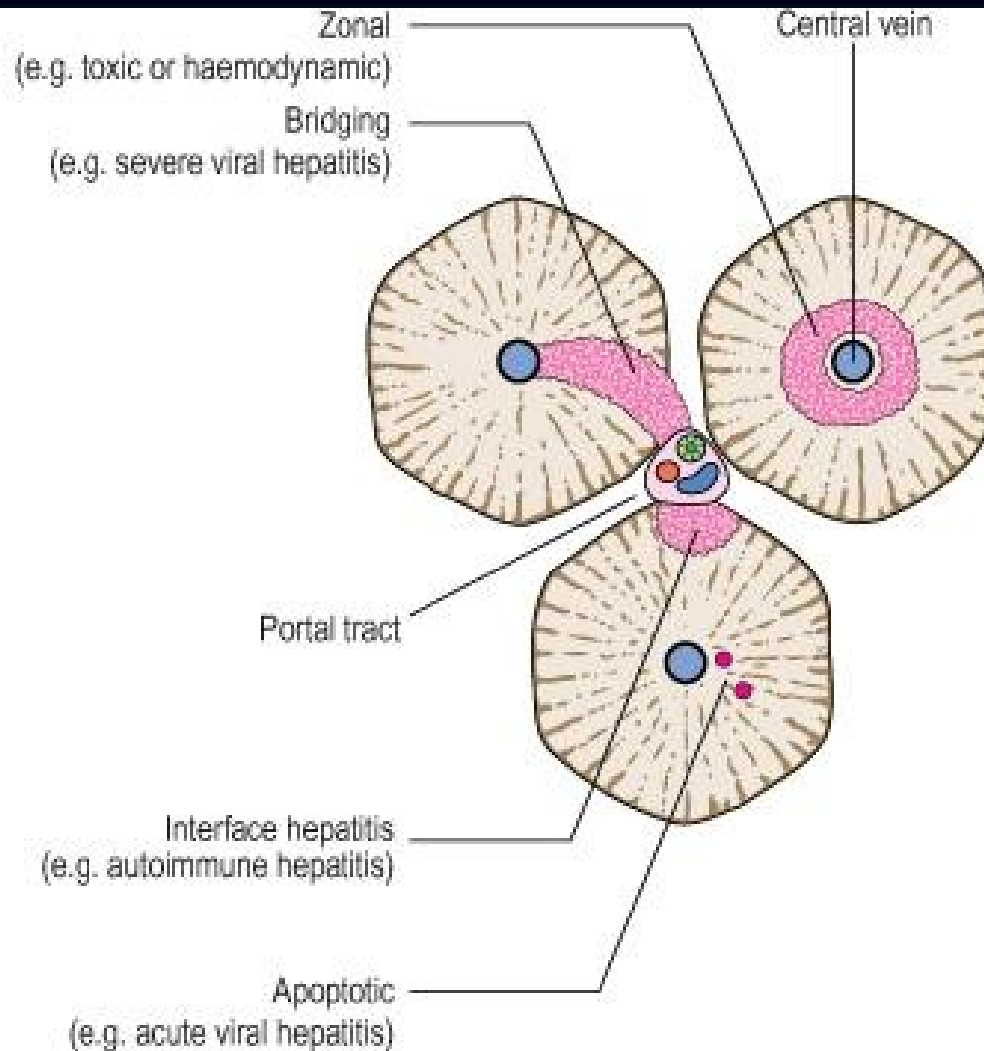
# Patterns of hepatic injury

- hepatocyte degeneration and/or pathologic intracellular accumulation (i. e. fatty liver, pigment, ...)
- hepatocyte necrosis, apoptosis
- vascular remodeling
- inflammation
- regeneration
- fibrosis
- neoplasia



# Histopathology

- Histological evidence of:
  - liver cell degeneration or death
  - inflammatory reaction
  - regenerative changes
  - others
- Diagnostic changes only partially specific to the causative agent.
- Pattern and type of liver cell damage important



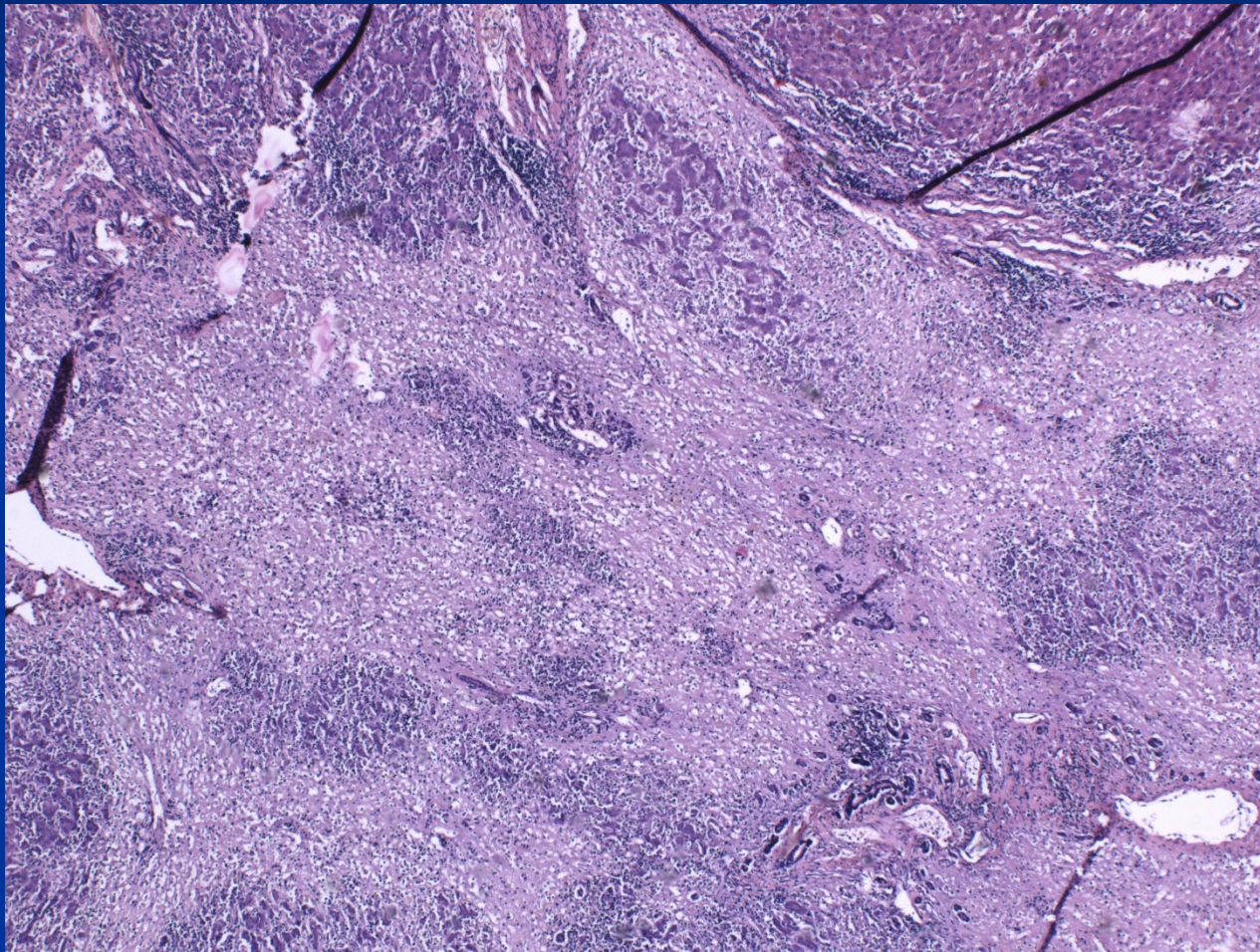
copy

## Patterns of liver cell death

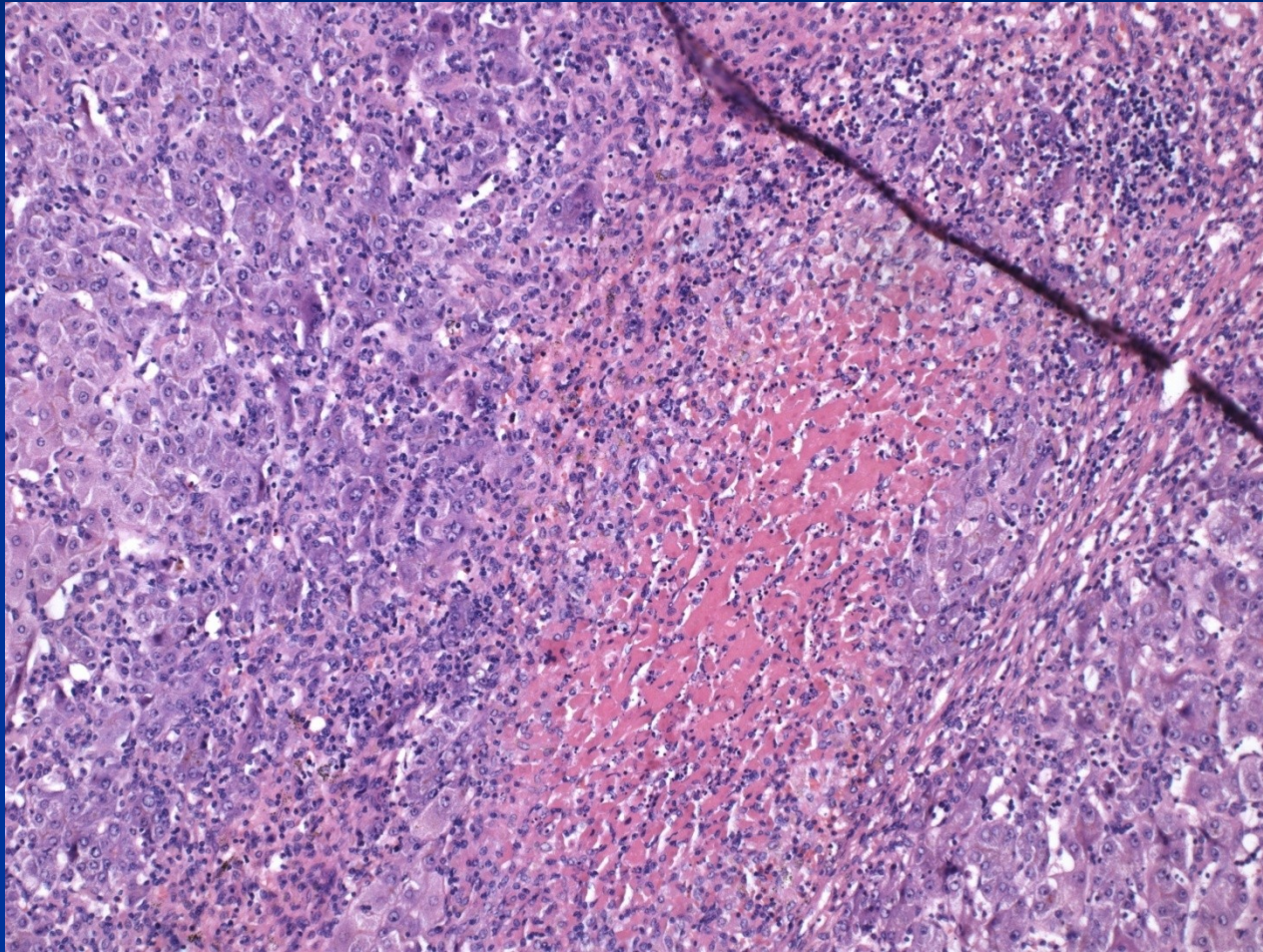
# Necrosis distribution

- Interface hepatitis (piecemeal necrosis) - periportal hepatocytes, mostly in chronic hepatitis, ↑ risk of cirrhosis
- Centrilobular → necrosis around central vein (ischaemia; toxins; drugs)
- Bridging - severe inflammation or toxins
  - Portal-to-portal
  - Portal-to-central
  - Central-to-central
- Panacinar necrosis
  - entire acinus
  - diffuse → liver failure, risk of immediate death.

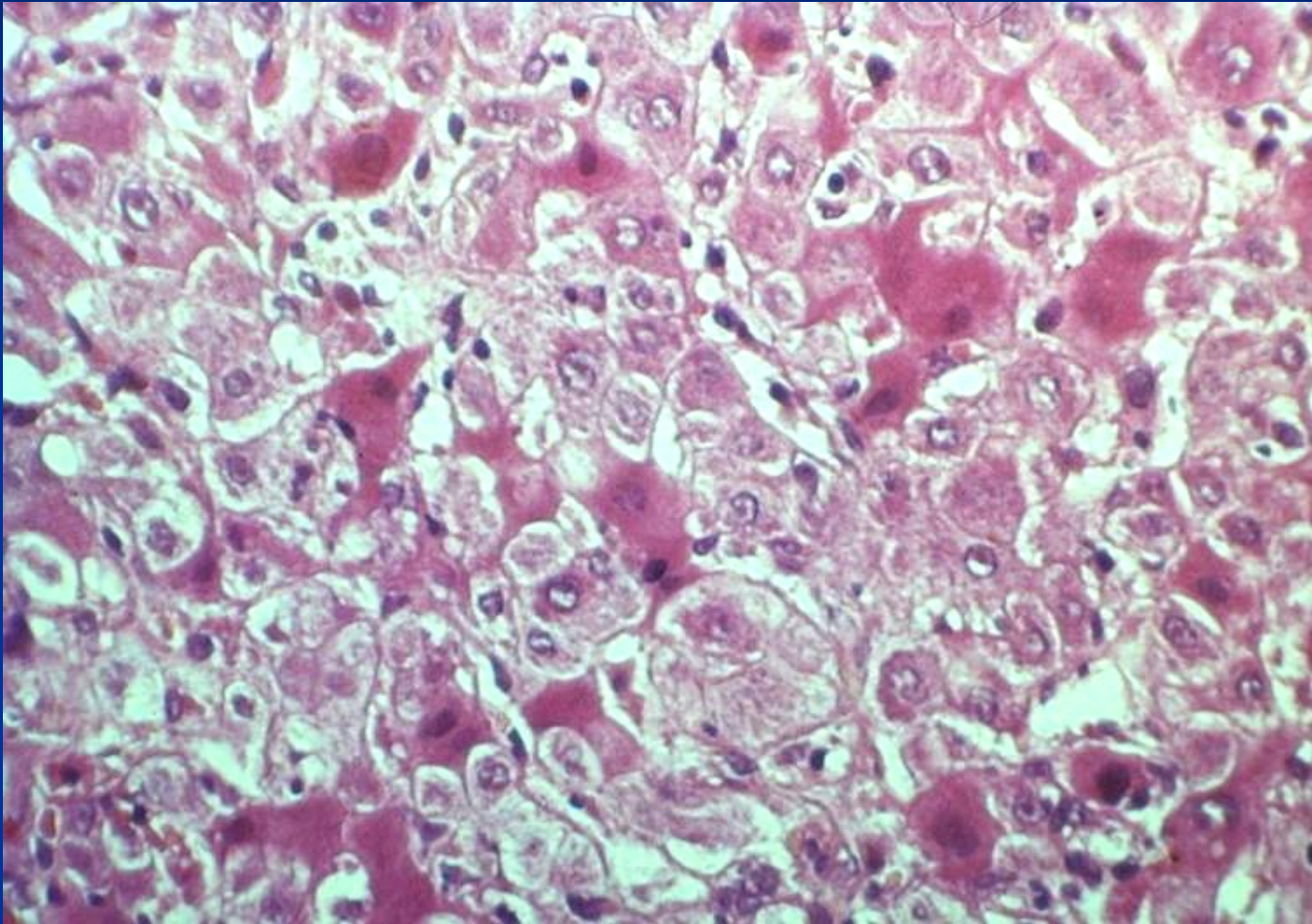
# Liver necrosis (acetaminophen)



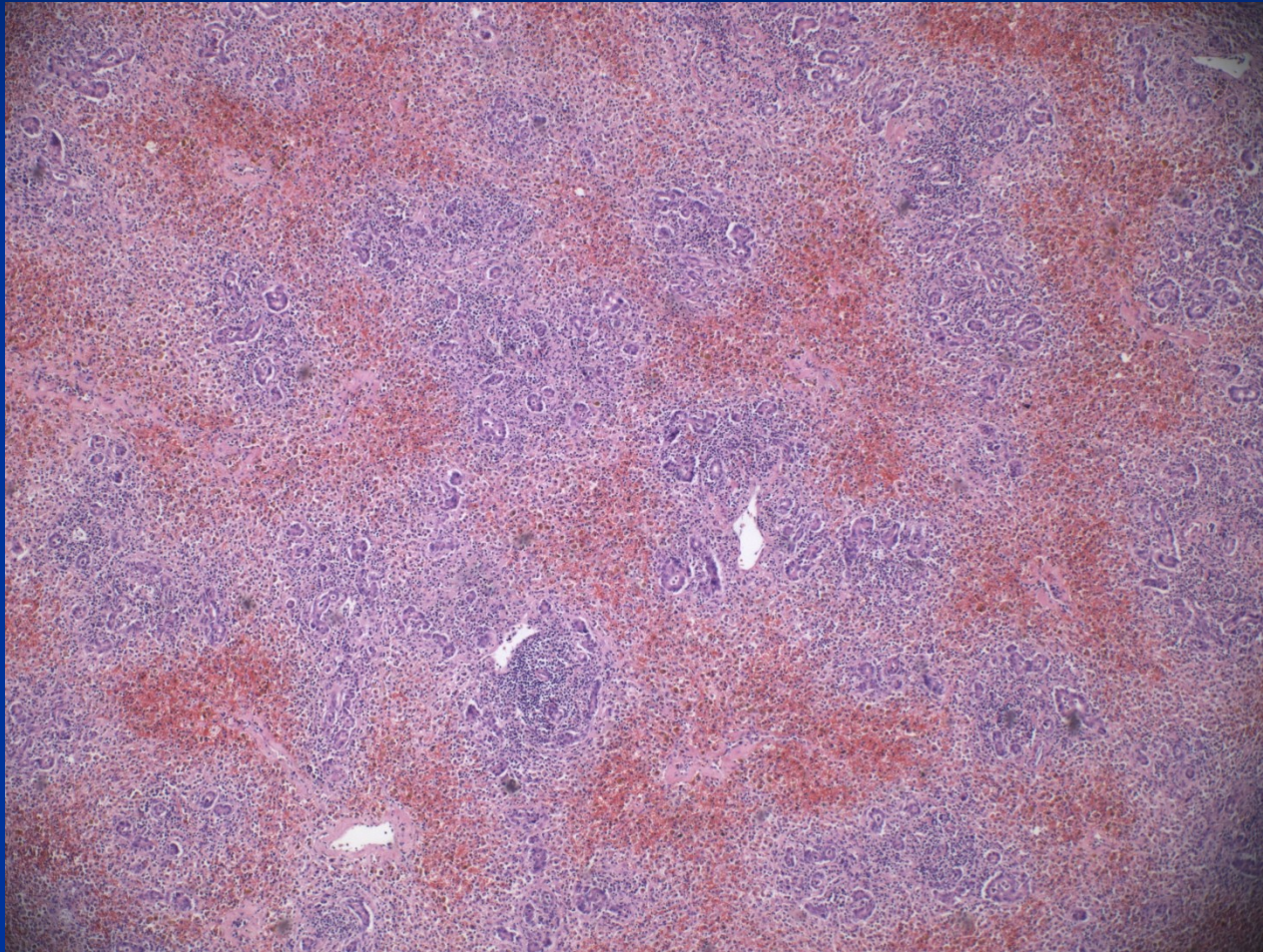
# Liver necrosis (acetaminophen)



# Hepatocyte necrosis



# Necrosis - repair



# Necrosis

- Coagulative → eosinophilic hepatocytes without nuclei (ischaemia)
- Apoptosis → death of individual liver cells, pyknosis
  - most frequent pattern in viral hepatitis
  - usually possible recovery
  - toxic; immunologic
- Lytic necrosis → hepatocytes swell and rupture



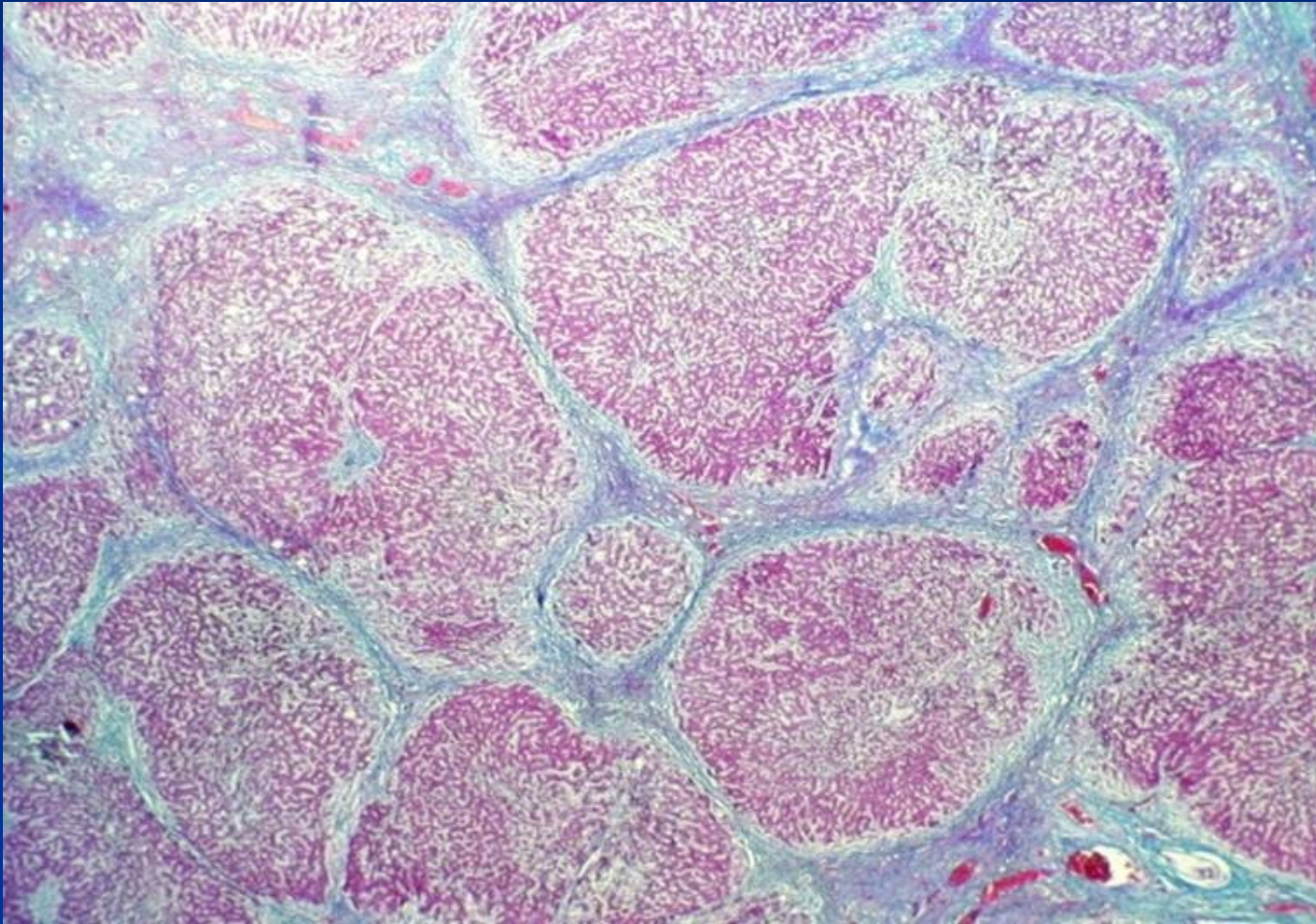
# Fibrosis

- Response to inflammation
- Mostly irreversible (under favorable conditions reversible to some extent)
- Intrasinusoidal deposition of collagen → effects on hepatic metabolism and blood flow
- In/around portal tracts or central veins → spreads → links other regions (bridging fibrosis)
- Basic lobular architecture partially preserved

# Advanced stage of chronic liver disease („cirrhosis“)

- Complete loss of original architecture
- Regenerating groups of hepatocytes surrounded by fibrotic scar tissue
- Due to continued parenchymal injury and fibrosis
- Commonly late/end form of severe liver disease
- A process, possible reparative/regenerative changes and/or worsening of the lesion

# Advanced stage of chronic liver disease („cirrhosis“)



# Liver failure

- Most severe clinical consequence of liver disease
- **Result of:**
  - Sudden and massive hepatic destruction
  - End-point of progressive liver damage (insidious or repeated)
- **Results in:**
  - Inadequate synthesis of albumin, clotting factors, etc.
  - Failure to eliminate endogenous products (e.g. ammonia, bilirubin; hormones)
- Often triggered by intercurrent disease:
  - Systemic infections
  - Electrolyte disturbances
  - Stress (e.g. surgery)
  - GIT bleeding

# Liver failure

- **Acute liver failure:** acute illness → encephalopathy + coagulopathy  $\leq$  6 months (fulminant  $\leq$  2 weeks). Massive hepatic necrosis and/or massive steatosis.
  - Fulminant hepatitis (viral, autoimmune)
  - Drugs and chemicals, e.g., acetaminophen, carbon tetrachloride, mushroom poisoning. Alcohol.
  - Biliary obstruction, commonly due to gallstones.
  - Direct physical injury to the liver (e.g. laceration in a road traffic accident)
  - Vascular lesion

# Acute liver failure

- Possible recovery from acute liver injury (focal or diffuse) due to the capacity of the organ for cellular regeneration.
- Loss of a part of the liver – regrowth, regeneration
- Loss of the basic structure - repair
  
- The same agent may produce either an acute or a chronic illness, commonly without any preceding clinically evident acute phase.

# Chronic liver failure

- **Chronic liver disease** → advanced stage of chronic hepatitis, biliary diseases, ...
- Massive neoplastic infiltration.
- Functional stage important
  - well compensated
  - partially decompensated
  - decompensated

# Hepatic signs

- **Hepatomegaly** – hepatitis, intracellular accumulation, focal lesion
- **Jaundice** – hyperbilirubinemia un-conjugated, + event. dark urine, acholic pale faeces, pruritus
- **Oedema** - ↓ protein synthesis, hypoalbuminemia
- **Ascites** – portal hypertension + hypoalbuminemia
- **Splenomegaly** - portal hypertension + immune reactions, possible → anemia, thrombocytopenia



# Hepatic signs

- **Bleeding** - ↓ clotting factors + fibrinolysis inhibitors synthesis
- **Varices** (oesophagus, cardia, caput Medusae) - portal hypertension
- **Spider naevi, gynecomastia, impotence, palmar erythema** – hyperoestrogenism
- **Hepatorenal syndrome** - idiopathic renal failure (cortical vasoconstriction, acute tubular necrosis)
- **Encephalopathy** - ↓ detoxification, complex metabolic disorder of the CNS, neuromuscular synapses
  - Elevated blood ammonia level and deranged neurotransmission
  - Rigidity, hyperreflexia, seizures

# Portal hypertension

## ■ Prehepatic

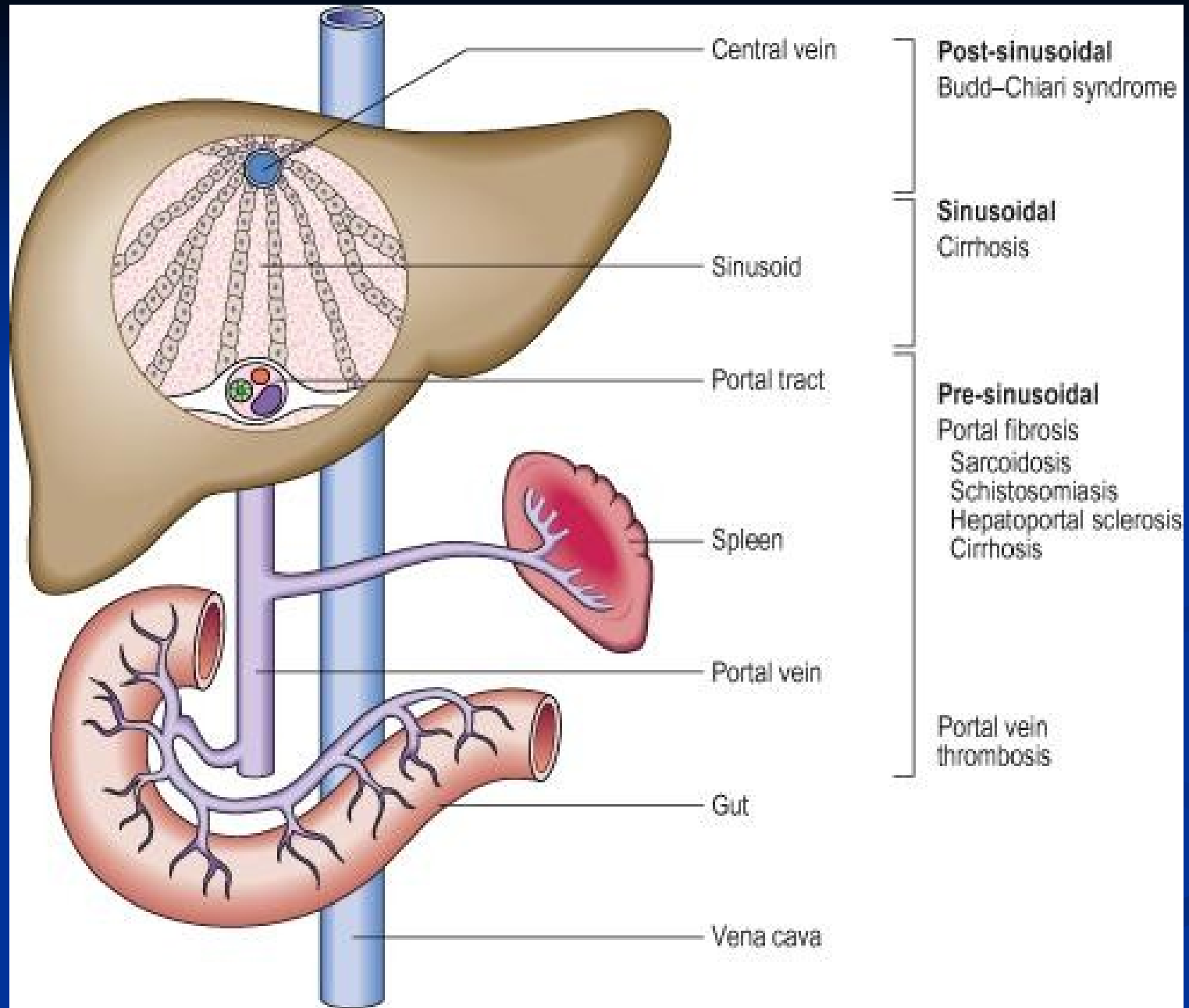
- Occlusive thrombosis (tumor, drugs), narrowing of the portal vein (inborn, acquired external pressure...)

## ■ Intrahepatic

- Advanced stage of liver disease (cirrhosis)
- Schistosomiasis, massive fatty change, diffuse granulomatous diseases (sarcoidosis, miliary TB), massive neoplastic infiltration

## ■ Posthepatic

- Right-sided heart failure, constrictive pericarditis, hepatic vein outflow obstruction



# Portal hypertension complications

- **Varices** (+ rupture, shunting of toxic products into systemic circulation – ammonia, bacterial by-products – hepatic foetor)
- **GIT venous congestion** → gastric, intestinal phlegmona
- **Ascites** commonly + infection - peritonitis
- **Hepatopulmonary sy** – dyspnoea, respiratory insufficiency

# Cholestasis

## Results from:

- Hepatocellular dysfunction
- Biliary obstruction

## Signs:

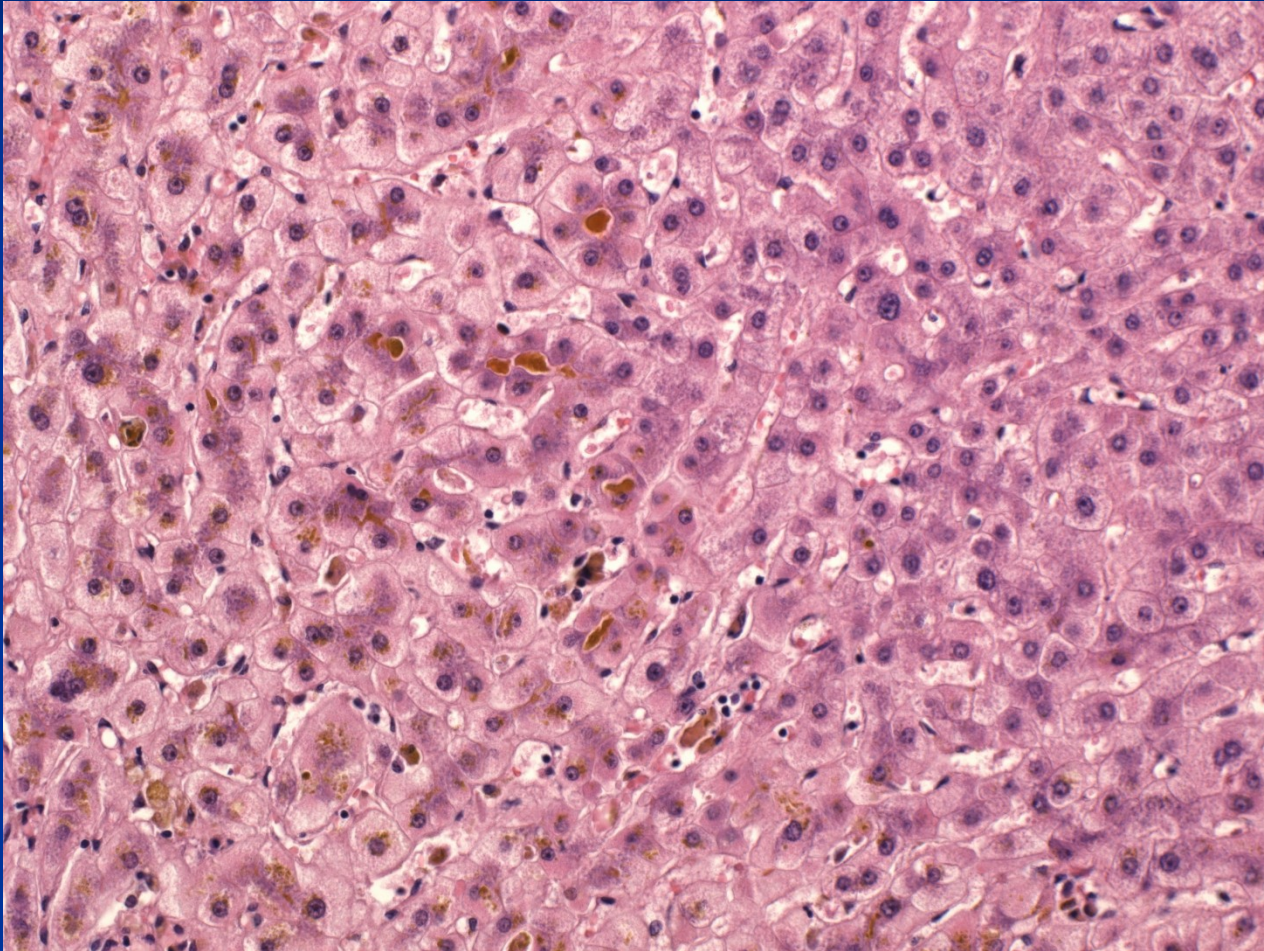
- Pruritus (↑ serum bile acids)
- Hyperlipidaemia → skin xanthomas (focal cholesterol accumulation)
- Malabsorption → ↓ fat soluble vitamins (A; D; K)
- ↑ serum alkaline phosphatase

# Cholestasis

## Morphology:

- Accumulation of bile pigment in hepatic parenchyma
- Elongated green plugs of bile visible in dilated canaliculi → rupture → extravasion of bile into sinusoids → phagocytosed by Kupffer cells
- Oedema, periductal neutrophilic infiltrates in portal tract
- Prolonged obstruction → portal tract fibrosis → biliary cirrhosis

# Cholestasis



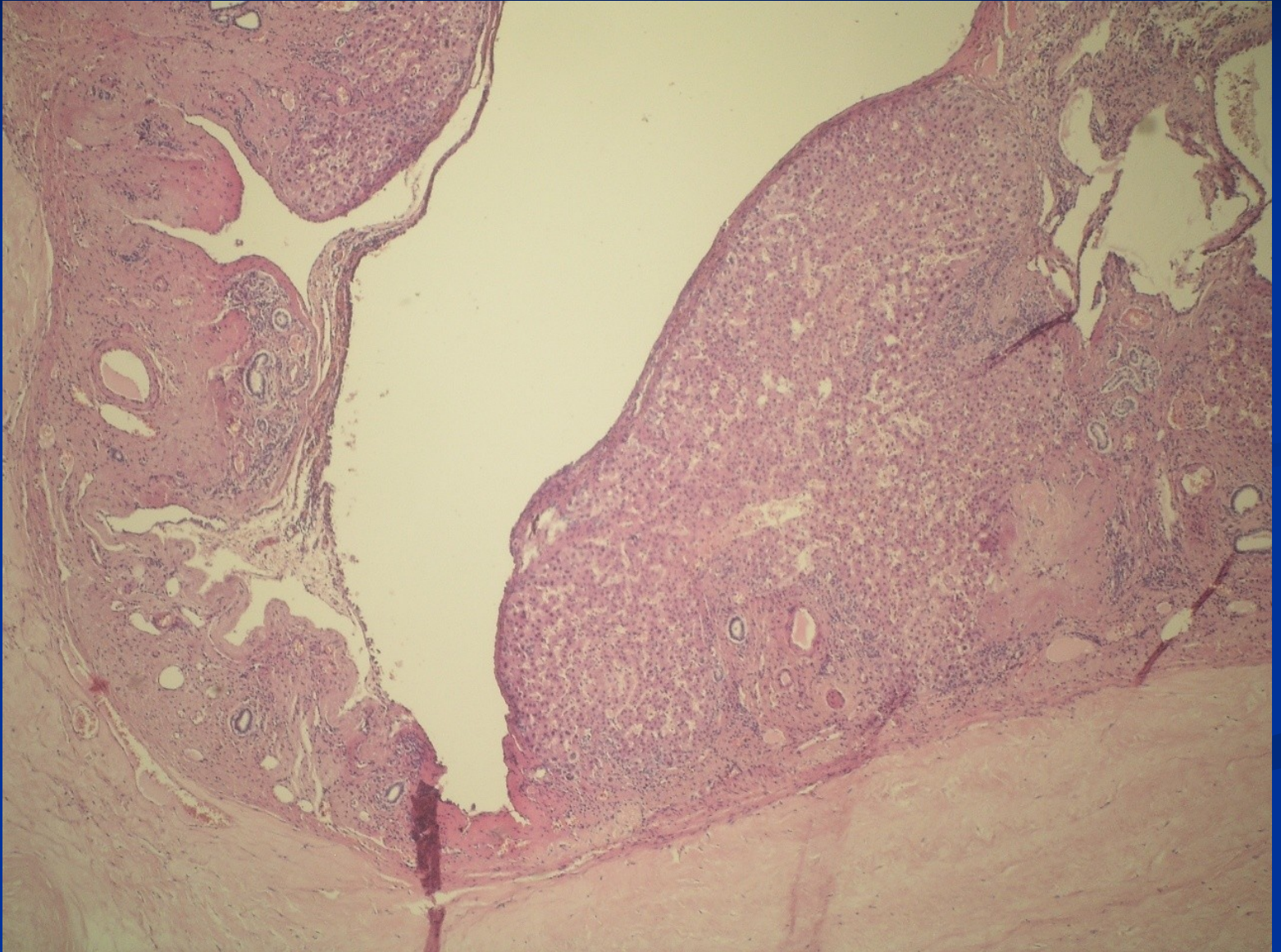
# Developmental abnormalities

## ■ Bile-duct anomalies

- biliary atresia – mostly extrahepatic, possible fetal viral infection, treatment by anastomosis or transplantation
- congenital dilatation of the bile duct – **cysts**, autosomal polycystic disease (recessive x dominant)
- biliary hamartoma – small lesion, slow growth/dilatation, commonly superficial - *pseudotumor*



# Polycystic disease



# Metabolic disorders

- Commonly **genetic** enzymatic defects (Wilson disease, hemochromatosis, porphyria, etc.).
  - **Primary hepatic** manifestation (accumulation of a metabolite due to an enzymatic defect – i.e.  $\alpha$ -1-antitrypsin inclusions).
  - **Secondary hepatic** manifestation (liver changes resulting from extrahepatic pathology).
- Possible **acquired** accumulation of various substances (i.e. secondary hemosiderosis, amyloidosis).

# Metabolic liver diseases

- **Hemochromatosis** – iron overload
- **Wilson disease** – copper overload
- **Bilirubin metabolism defects**
- **$\alpha$ 1-antitrypsin deficiency**
- **Storage disorders** (glycogenoses, mucopolysaccharidoses, lipidoses,...)

# Hemochromatosis

- Primary or hereditary hemochromatosis

- HLA-linked autosomal recessive disease

Primary defect in regulation of intestinal absorption of dietary iron, iron accumulation of 0.5 to 1.0 g/yr (total body iron ~ 2-6g), heterozygous → increased Fe absorption, homozygous → dangerous levels

- Heterozygous: 8-10% of West-, North-, Middle Europe
- Homozygous: incidence approx. 1 : 300-400
- Possible accelerated progression of other chronic liver diseases (alcohol liver disease, etc.)
- Therapy: venesection

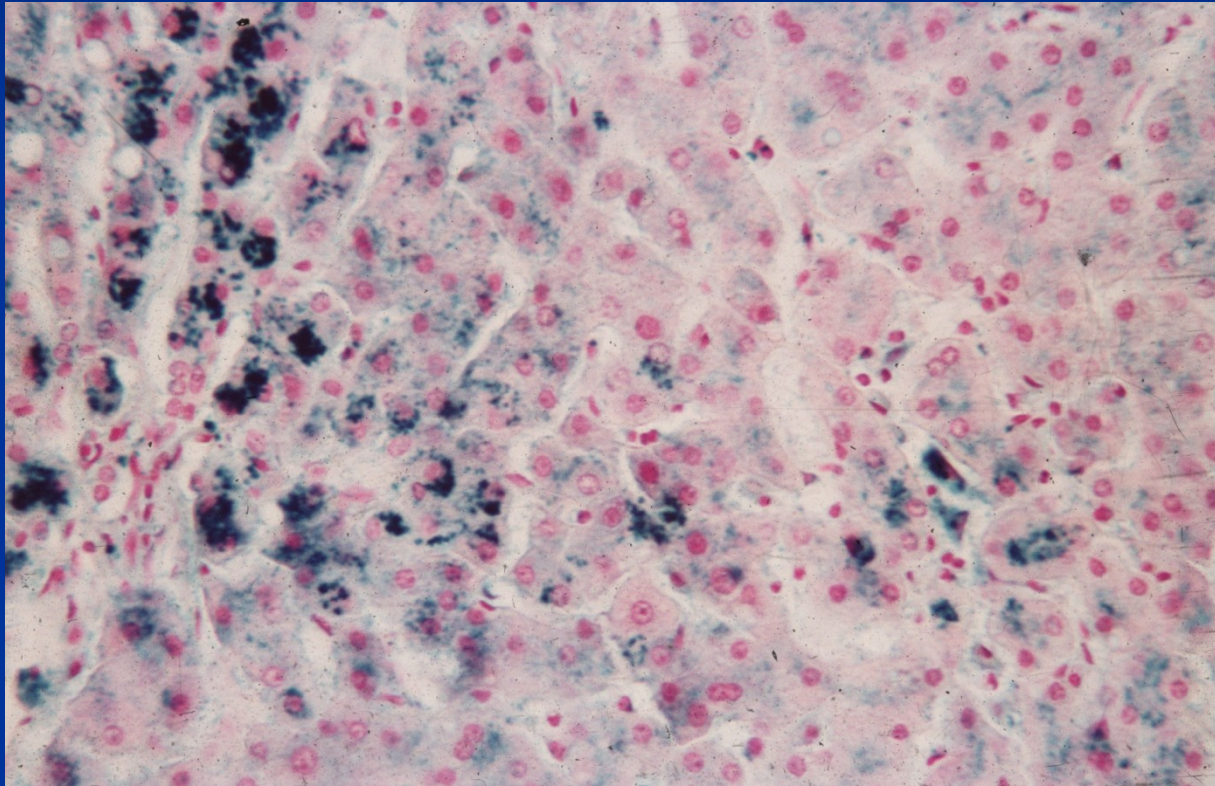
# Hemochromatosis

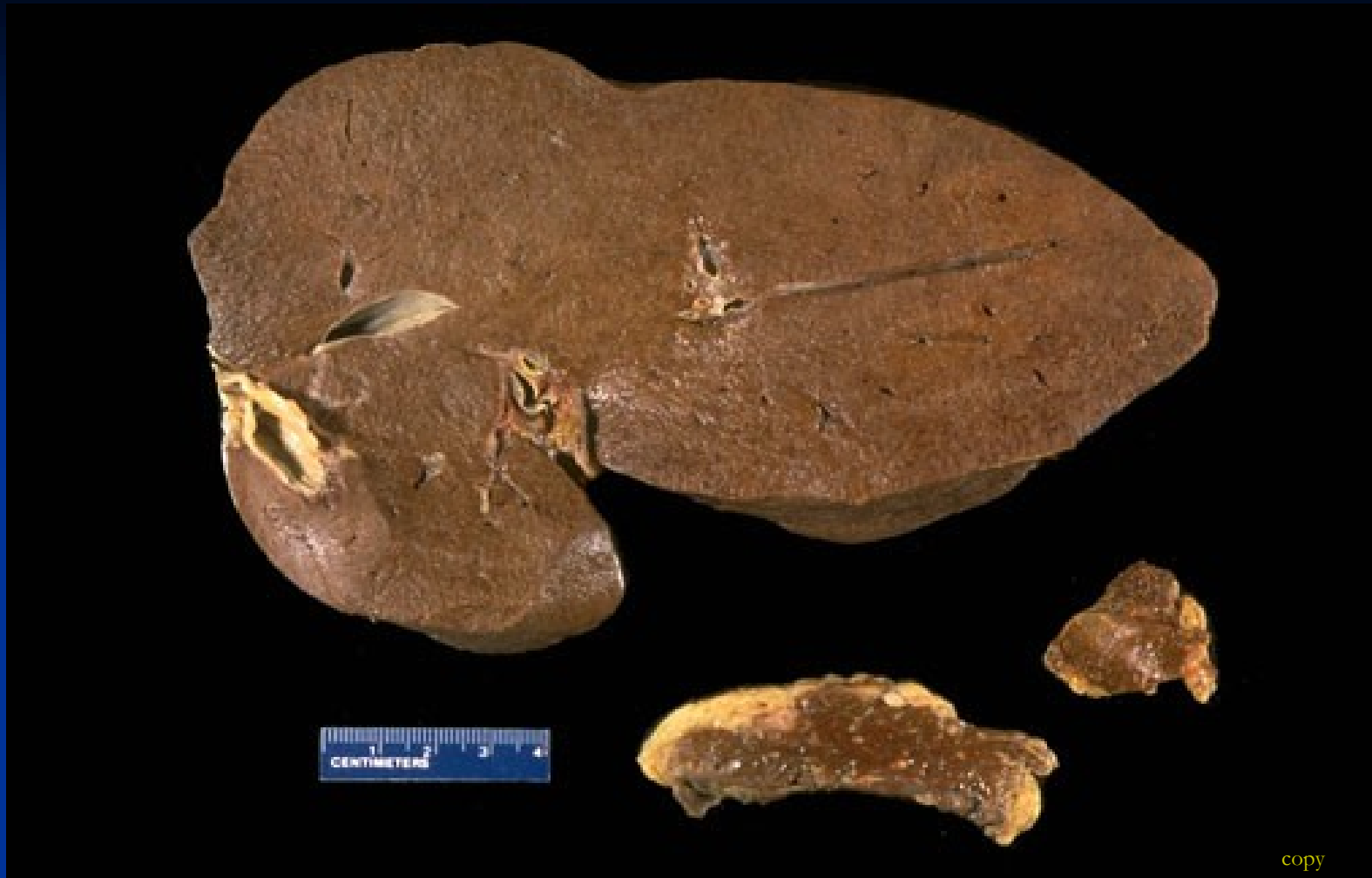- Deposition of hemosiderin in the liver, pancreas, myocardium (congestive heart failure), pituitary, adrenal, thyroid and parathyroid glands, testes, joints (arthritis), and skin („bronze diabetes“)
- Chronic hepatitis → micronodular cirrhosis
- Significant risk for HCC (hepatocellular carcinoma)
- Pancreatic interstitial fibrosis and parenchymal atrophy → DM

# Secondary hemosiderosis

- Transfusion dependent
- Ineffective erythropoiesis with increased erythroid activity
- Excessive oral Fe intake (supplements)
- Chronic liver disease (alcohol hepatitis - ↑ Fe absorption, chronic hepatitis C)

# Hemochromatosis





The dark brown color of the liver, the pancreas, lymph nodes due to extensive iron deposition in **hereditary hemochromatosis**



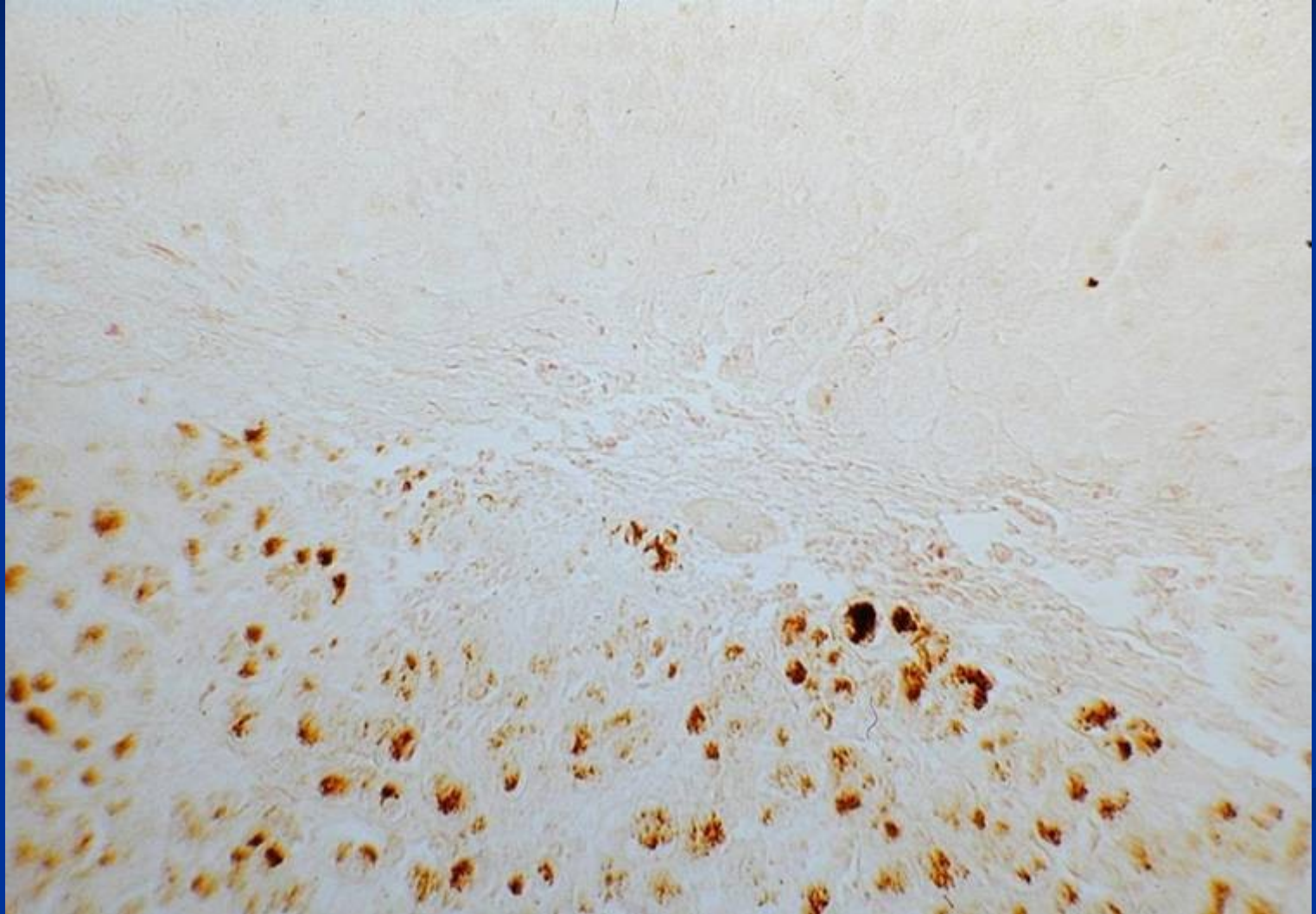
# Wilson disease

- Hepatolenticular degeneration
- Autosomal recessive disorder of copper metabolism
- Failure to excrete copper into bile
- Copper → progressive liver injury
- Affects brain, cornea, kidneys, bones, joints, and parathyroid glands
- Dg: ↓ serum ceruloplasmin, ↑ hepatic copper content, ↑ urinary copper

# Wilson disease - clinical

- Manifestations rare before 6 yrs
- Acute or chronic liver disease – most common
- Neuropsychiatric manifestations
- Possible haemolytic attack
- Copper chelation therapy with D-penicillamine
- Liver transplantation

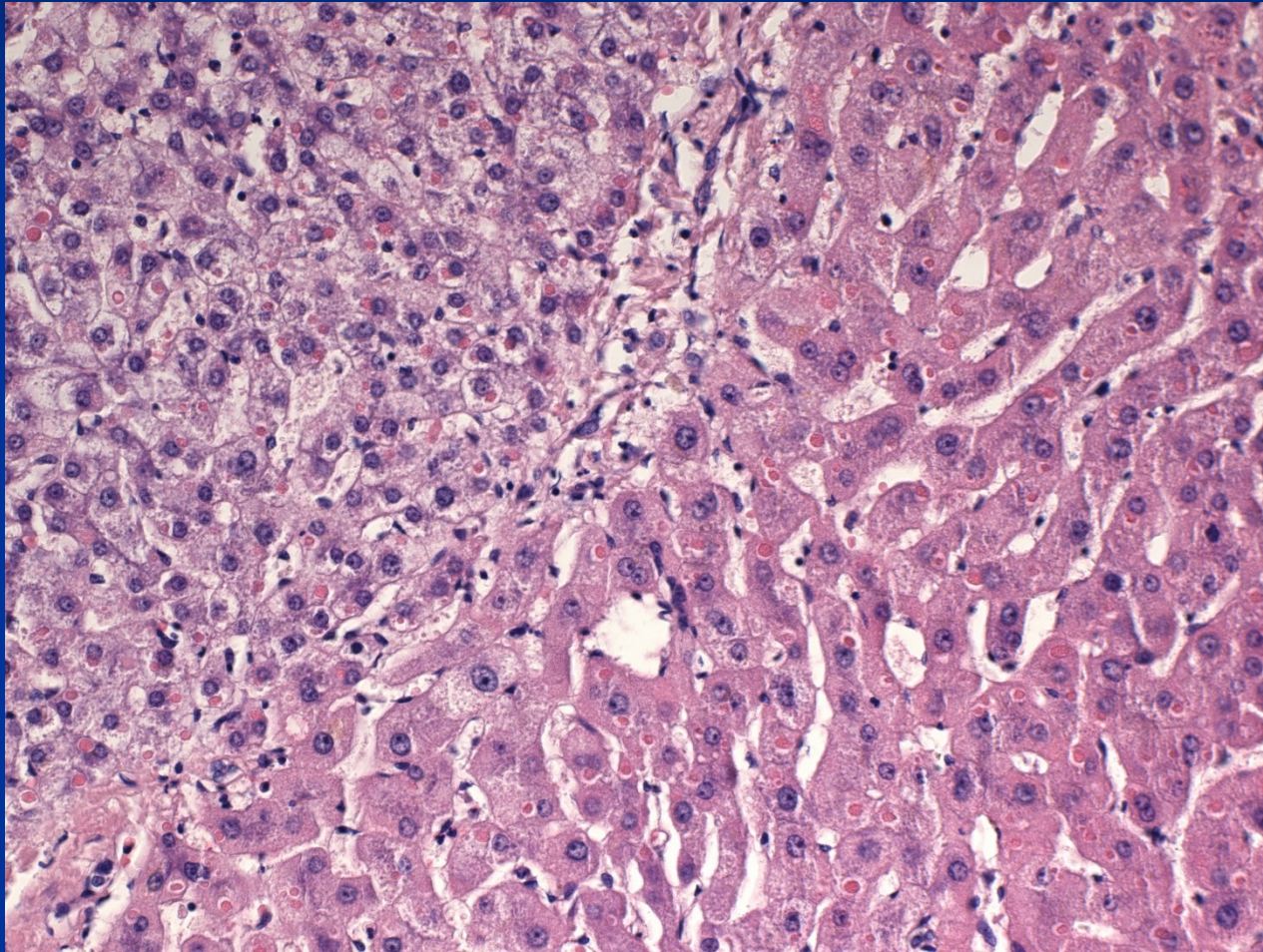
## Wilson's disease : Cu pigment



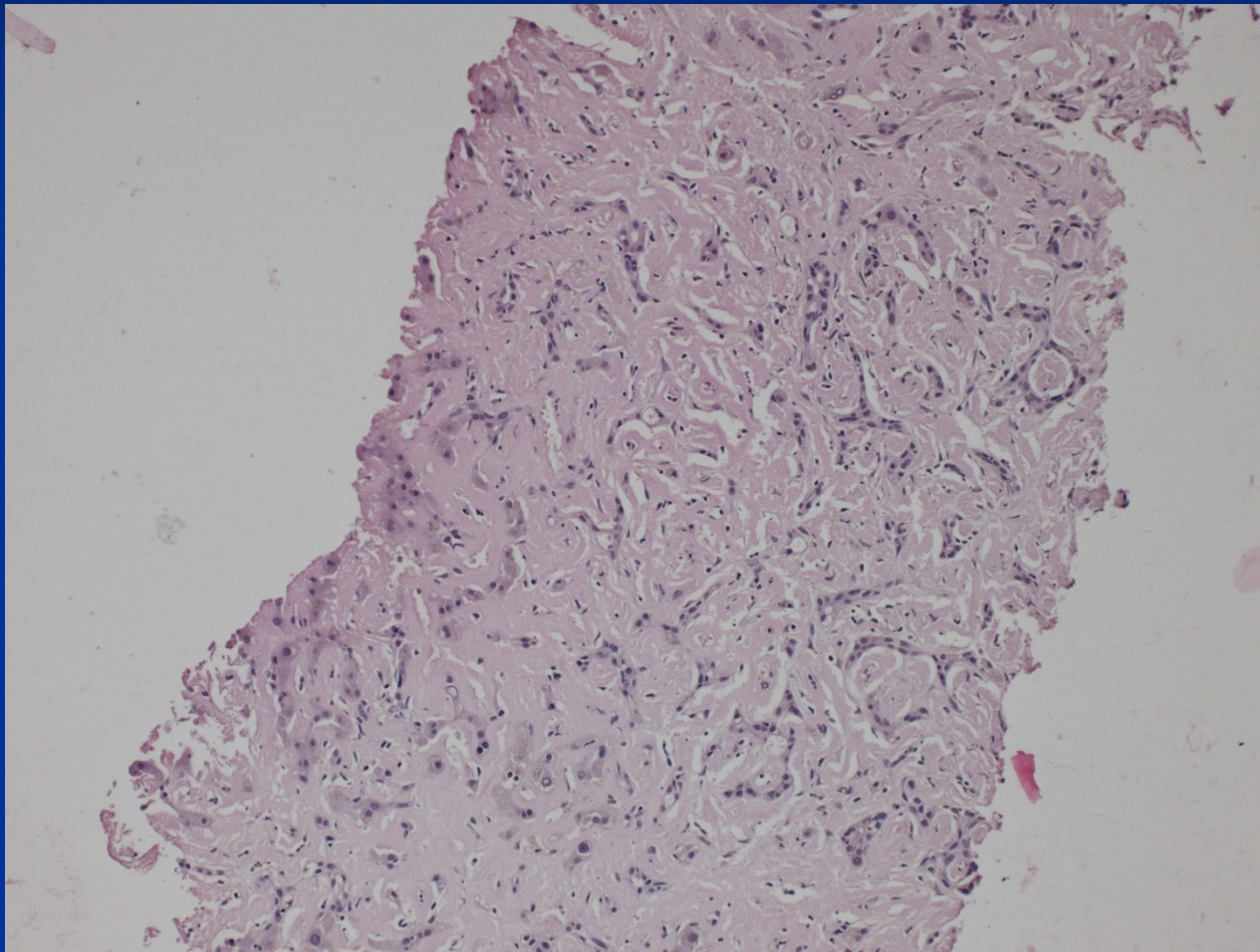
# $\alpha_1$ -antitrypsin deficiency

- Autosomal recessive disorder
- AAT - a protease inhibitor, particularly neutrophil elastase released at sites of inflammation
- Liver changes (cholestasis + necrosis even in newborns, children or adults – chronic hepatitis → cirrhosis, ↑ risk of hepatocellular carcinoma)
- Pulmonary emphysema due to tissue destructive enzymes (!combination of factors in smokers)

# $\alpha_1$ -antitrypsin deficiency + HCC




# Liver AL amyloidosis



# Liver AL amyloidosis

Kappa light chain  
IHC



# Hepatitis: etiology

## **Infectious (acute, chronic)**

**viruses** (most common, hepatotropic - hepatitis viruses; systemic – EBV, CMV, HSV, yellow fever – similar to „viral hepatitis“, rubella, enteroviruses, ...)

**bacteria** (pyogenic bacteria, TBC, malaria, salmonellosis, leptospirosis,...)

**parazites** (ecchinococcus, schistosoma, ...)

**protozoal** (amebiasis)

## **Non-infectious (acute, chronic)**

autoimmune

metabolic

drug induced

cryptogenic



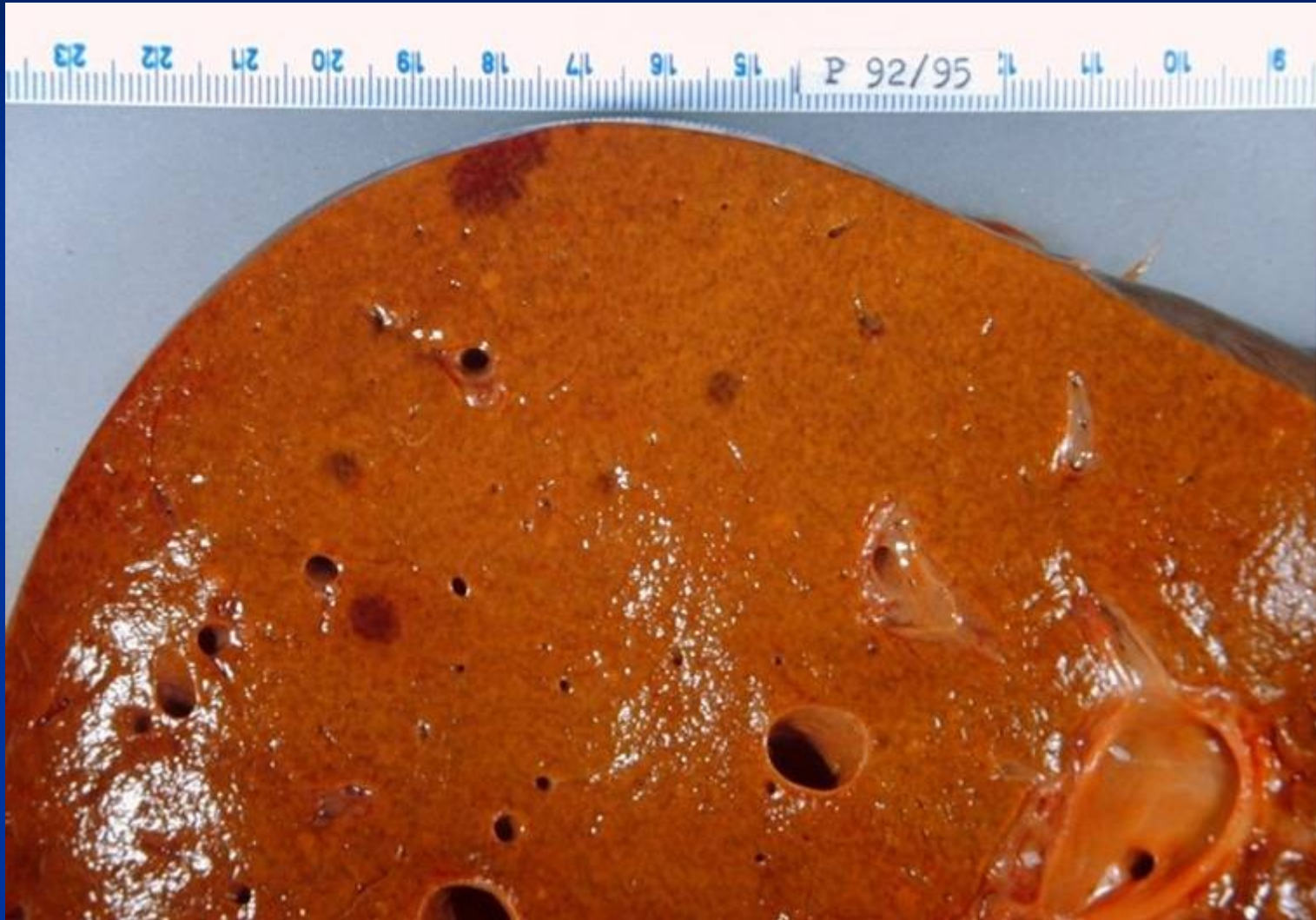
# Viral hepatitis

- hepatitis viruses immunologically distinct → infection usually confers life-long immunity to the specific type/subtype of the infecting virus but not to the others
- exceptions - HCV
- Ab detection: IgM → acute disease;  
IgG → memory cells

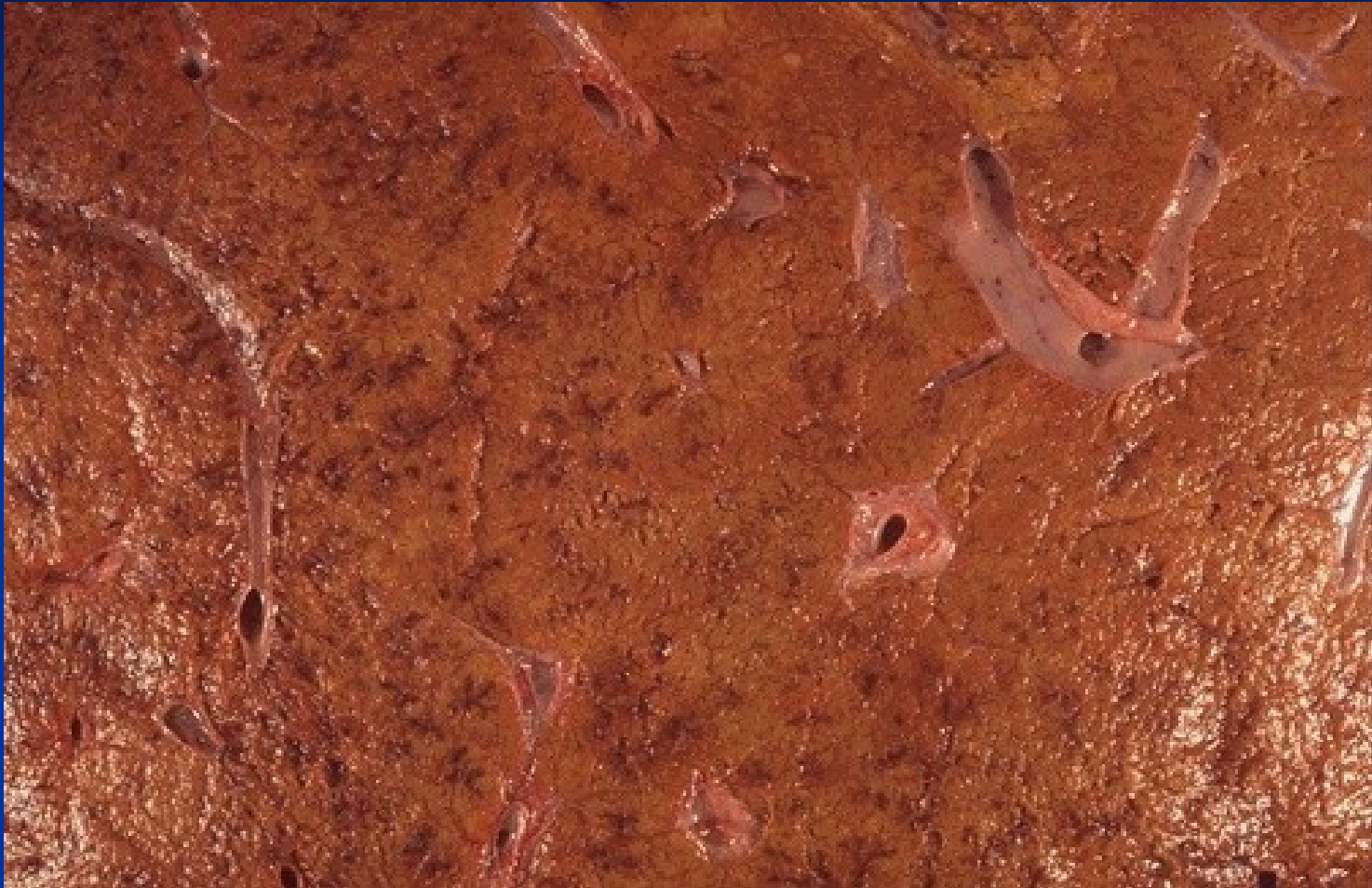## Viral hepatitis: course

- **Acute** (HAV, HBV, HCV, HDV, HEV)
- **Fulminant** (HAV, HBV, HEV)
- **Chronic** (HBV, HBV + HDV, HCV; rare HEV, exceptional HAV)
  - *risk of advanced stage disease/cirrhosis development*
  - *risk of hepatocellular carcinoma development*

# Acute hepatitis: HBV



# Morphology - gross



Edema, hyperemia. Necrosis and lobular collapse - areas of hemorrhage and irregularities on the cut surface of the liver.

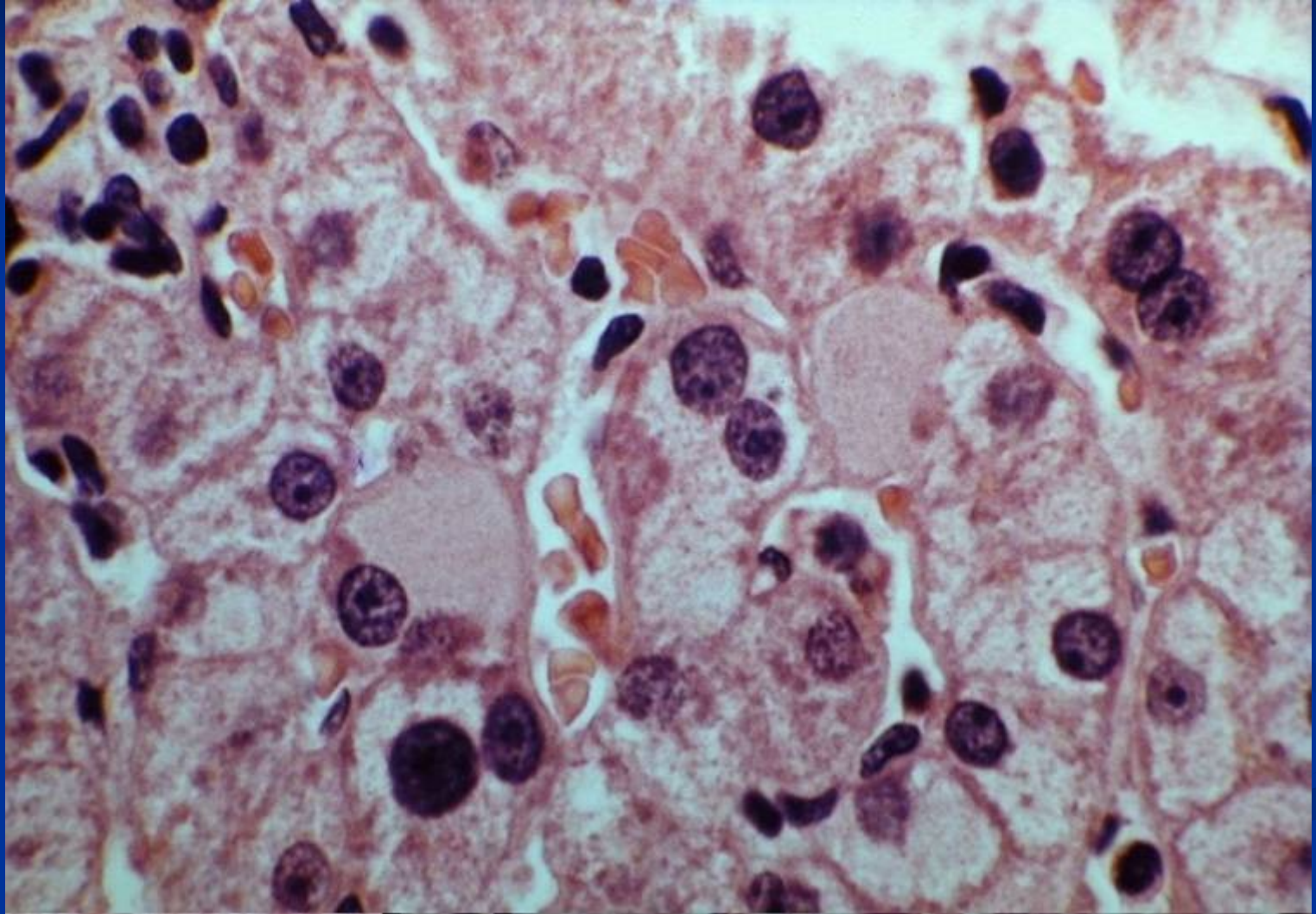
# Morphology

- Hepatocyte degenerative changes – ballooning
- Hepatocyte apoptosis (eosinophilic bodies)
- Portal inflammatory infiltrate + edema
- Interface hepatitis – infiltrate + death of periportal hepatocytes
- Possible confluent/bridging necrosis
- Possible cholestasis in hepatocytes and/or bile canaliculi
- Kupffer cell reaction + hyperplasia
- Regenerative changes

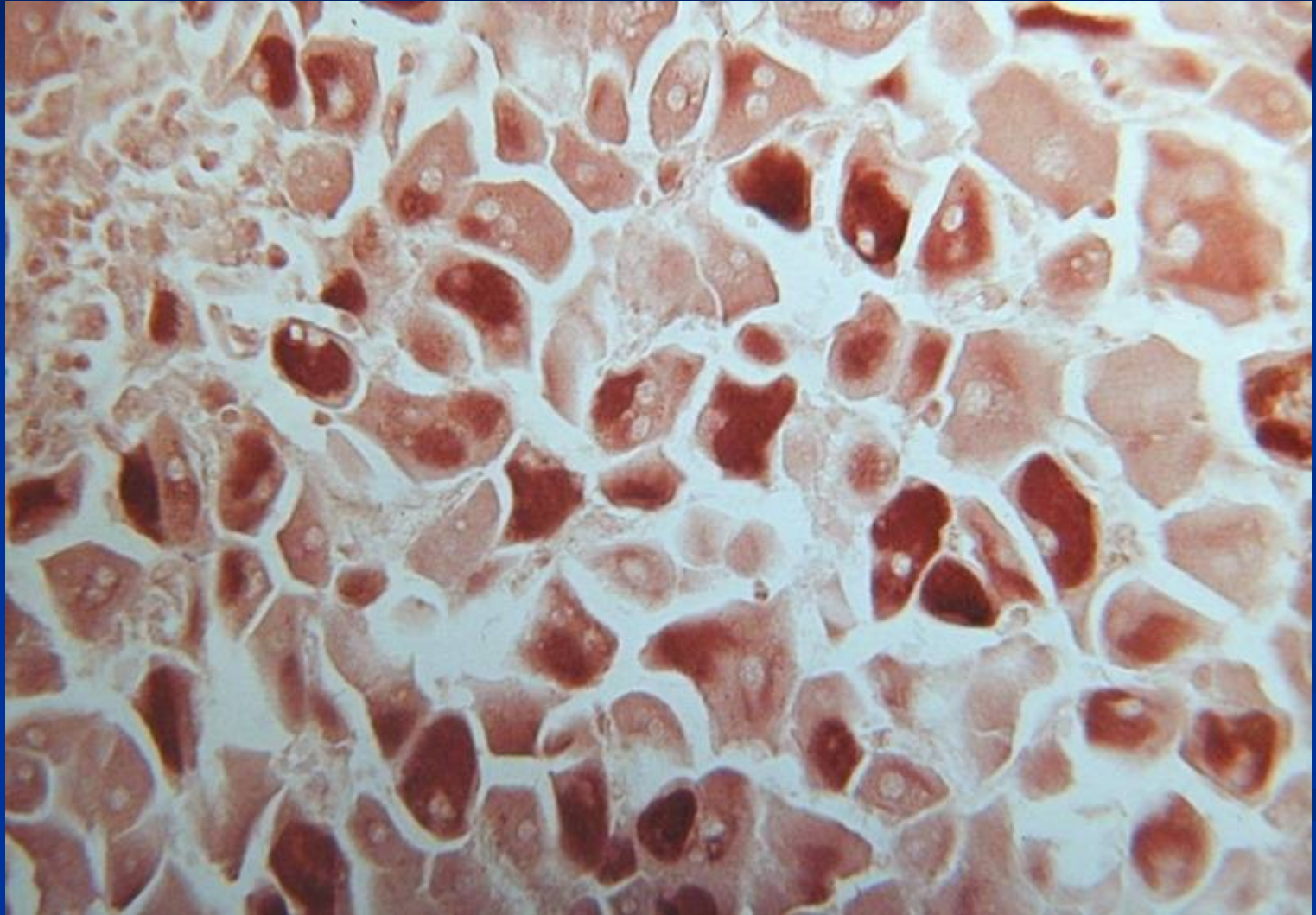
# Morphology

- *HAV* – numerous plasmacytes
- *HBV* – ground-glass hepatocytes
- *HCV* – hepatocyte fatty change, ductal damage, lymphocytic aggregates in portal spaces

## Viral hepatitis: HBsAg, ground glass

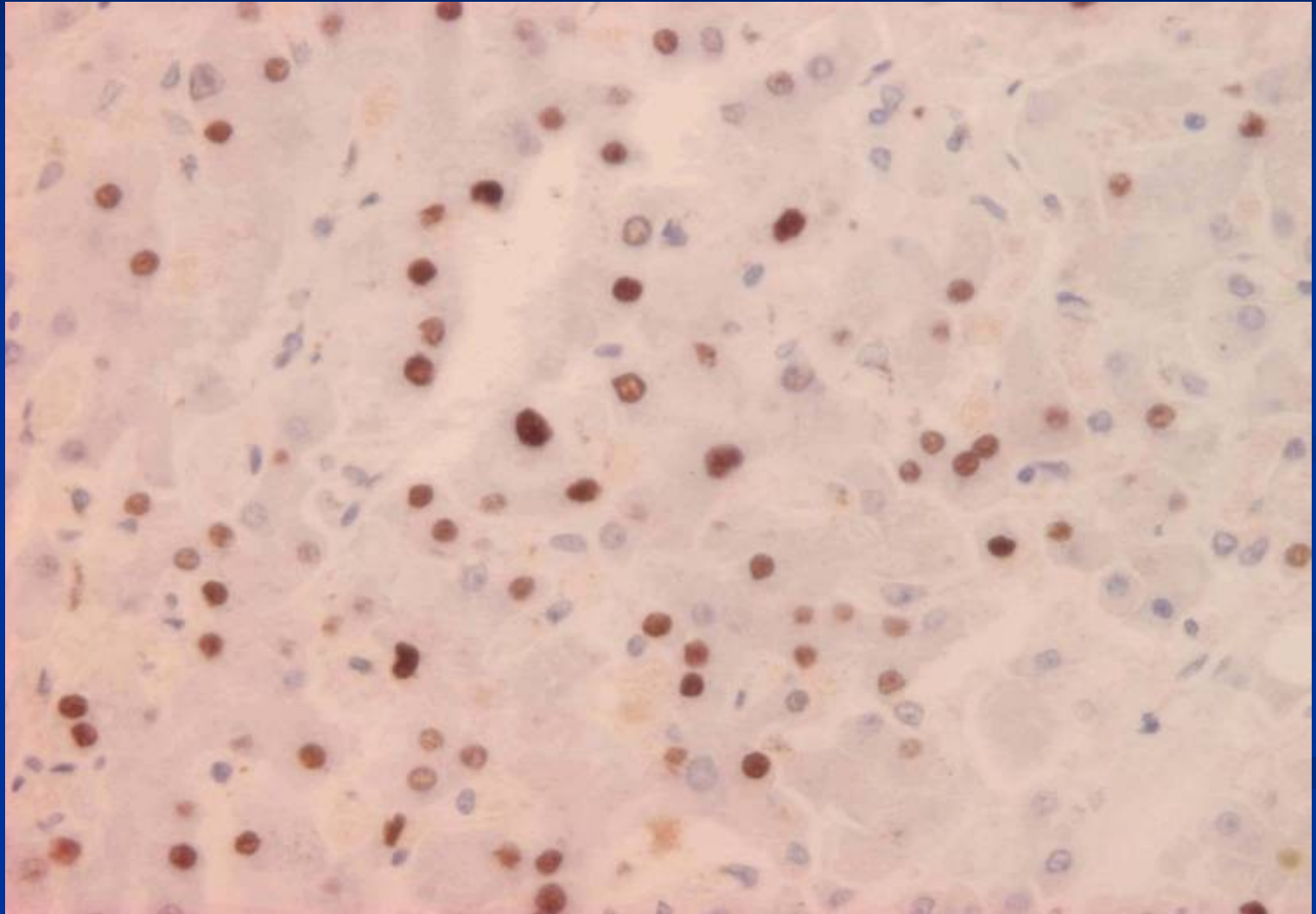


## Viral hepatitis: HBsAg, Orcein staining

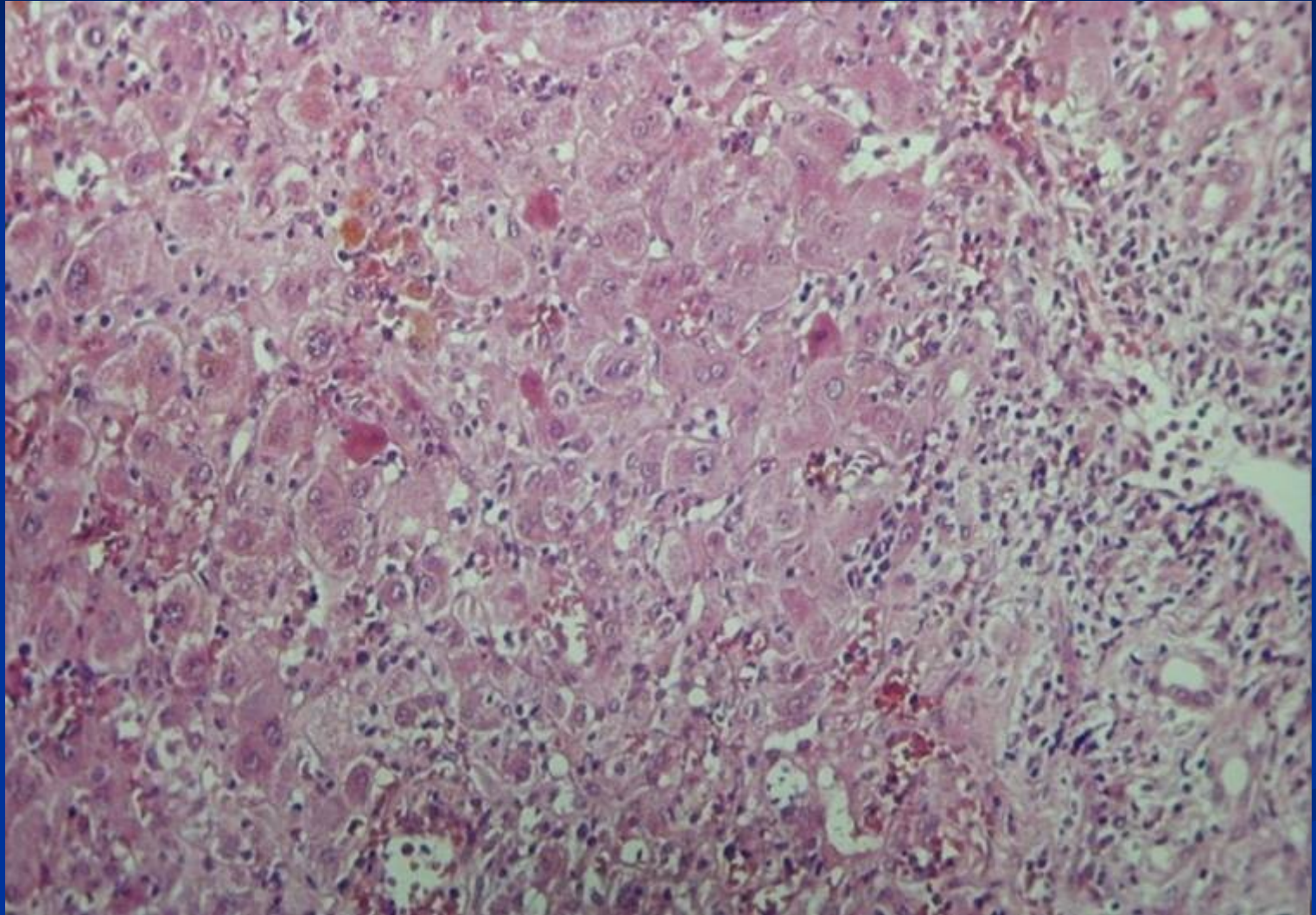




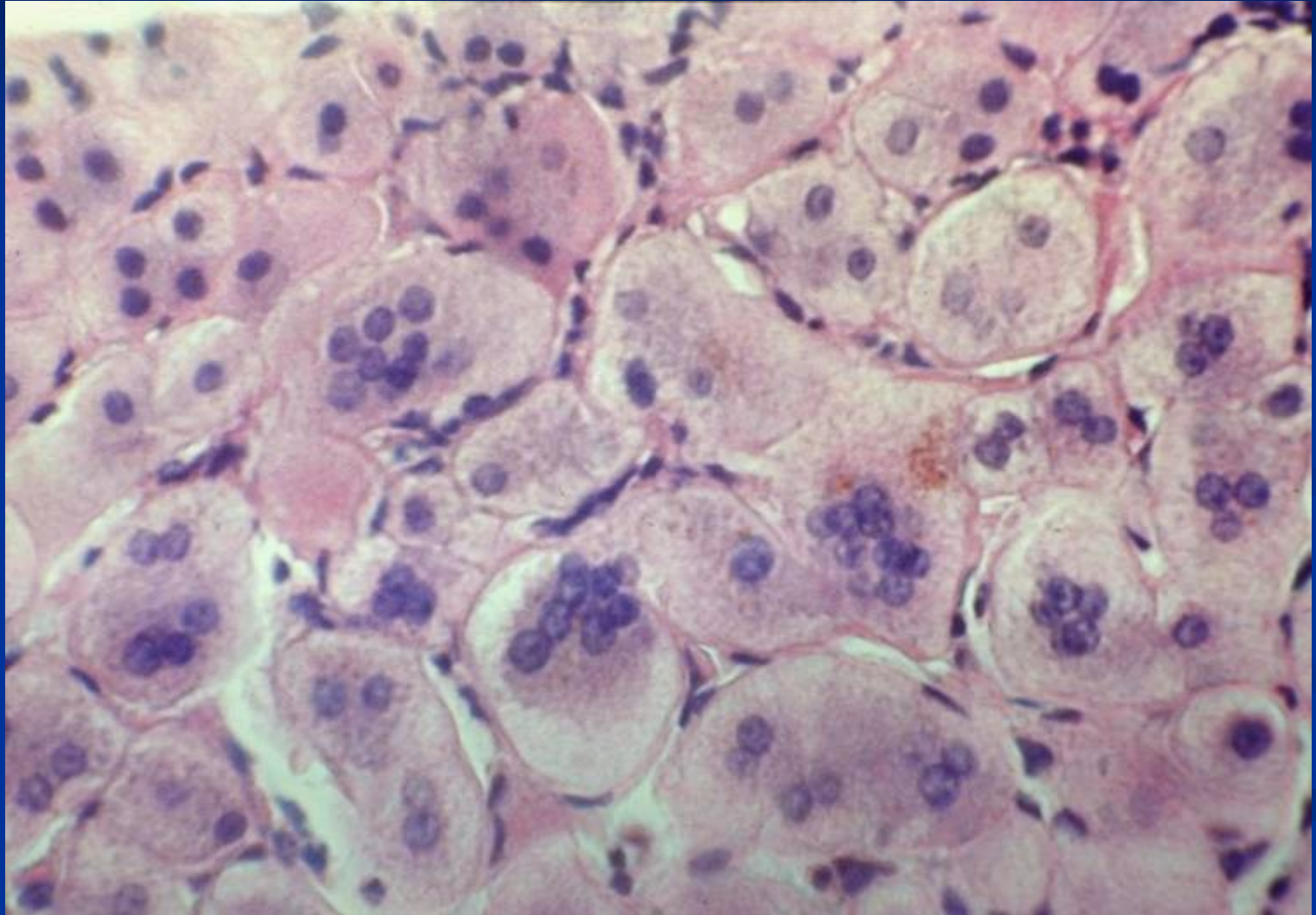
# Viral hepatitis: HBcAg, immunohistochemistry



# Acute hepatitis



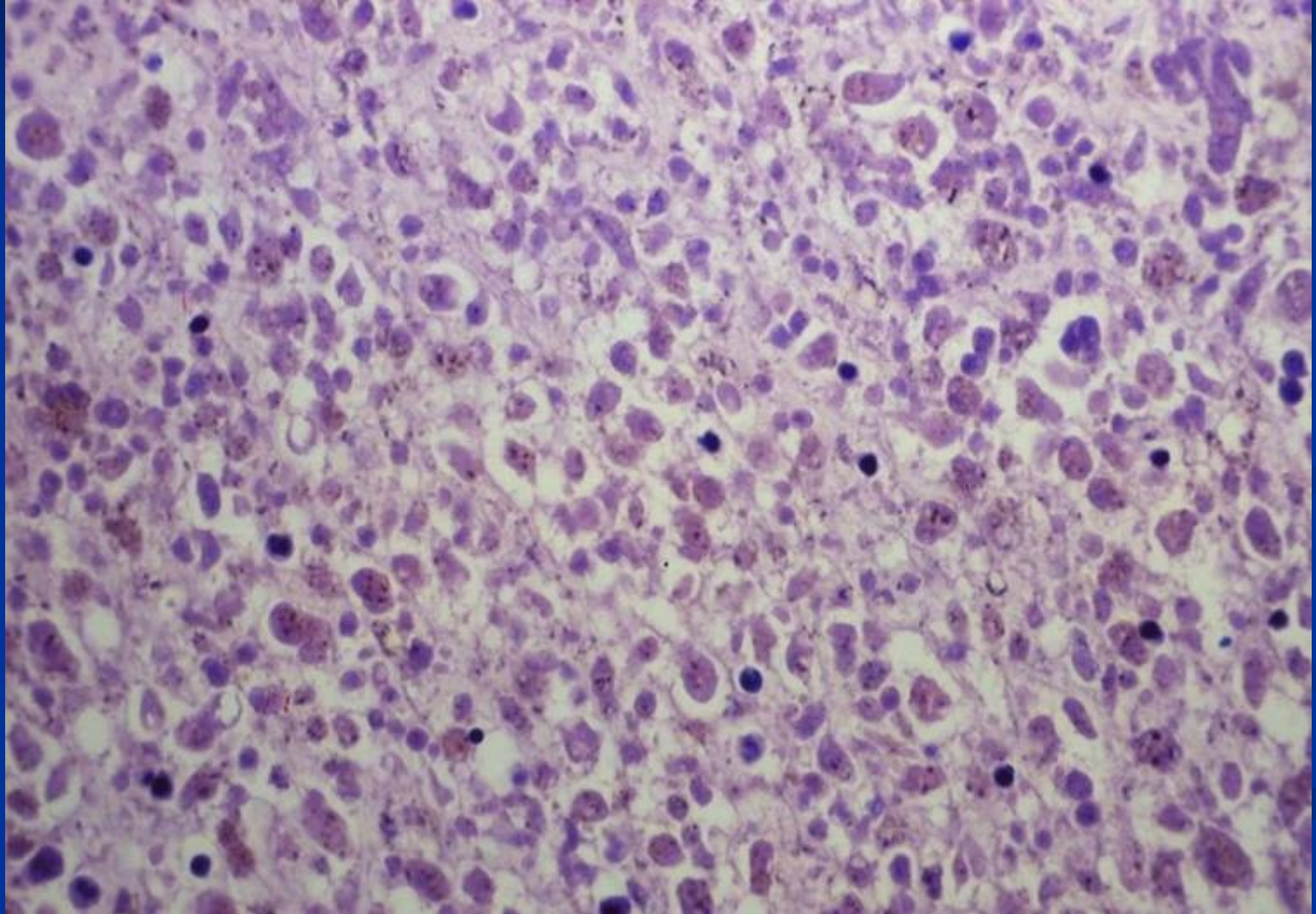
## Acute hepatitis: regeneration



# Fulminant hepatitis

- Grossly: soft consistency
- Microscopic: complete necrosis of parenchyma
- Course:
  - liver failure - coma - death
  - transplantation
  - regeneration – postnecrotic cirrhosis

# Fulminant hepatitis: HBV



# Other infections

- Viruses – EBV, CMV (in immunosuppressed)
- Malaria
- Schistosomiasis
- Leishmania

# Liver abscess

- Low-income countries
  - Parasitic liver abscesses more common
  - E.g. amoeba; helminthic
- High-income countries
  - Bacterial or fungal origin more common
  - Complication of infections elsewhere or systemic
- Organisms reach liver via
  - Ascending infection in biliary tract (ascending cholangitis)
  - Vascular seeding → portal or arterial
  - Direct liver invasion from nearby source
  - Penetrating injury

# Liver abscess

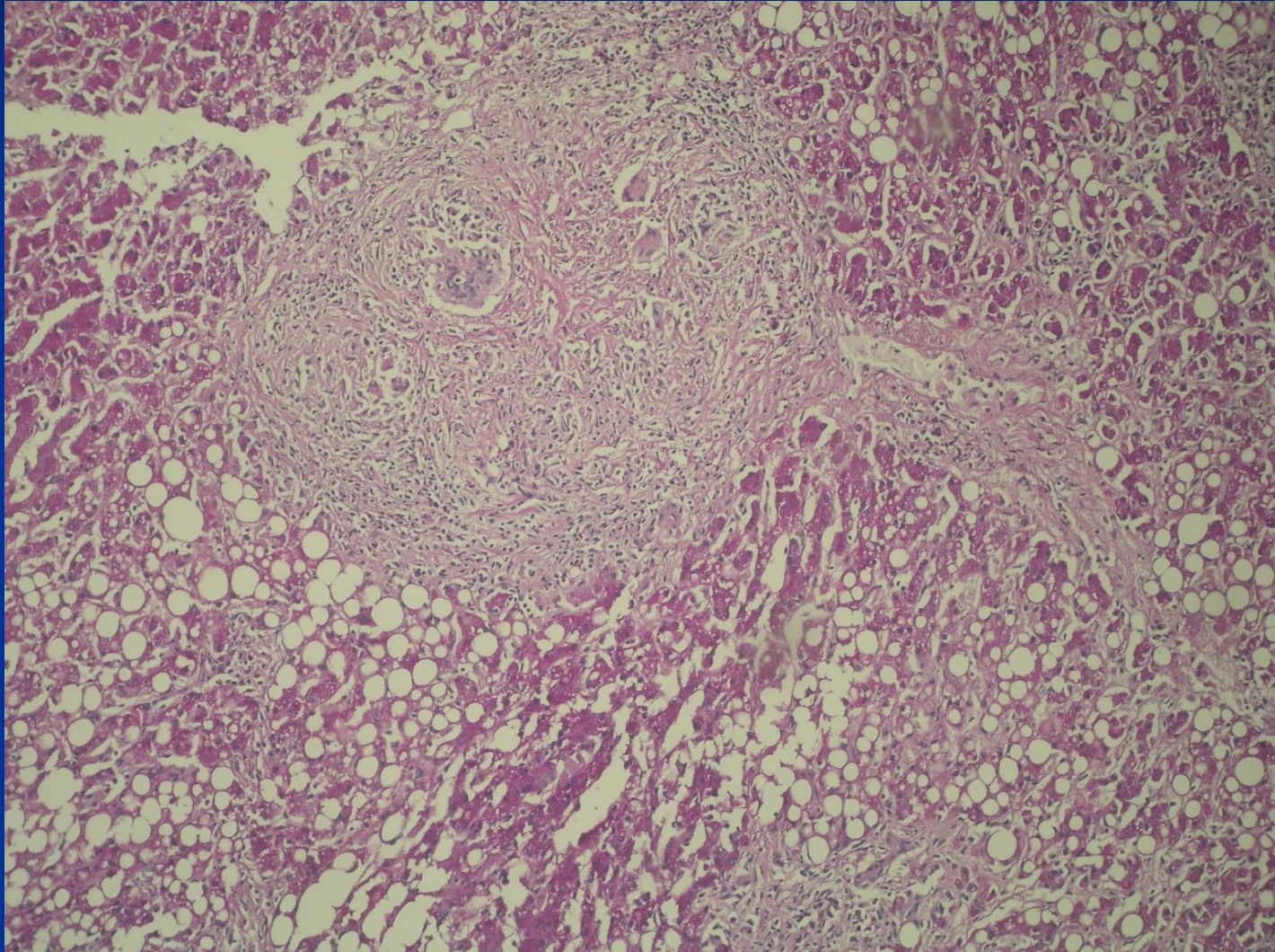
- Risk factors: debilitating disease with immunodeficiency:
  - Immunocompromised
  - Chemotherapy
  - Old age
  - Bone marrow failure
- Pyogenic bacteria hepatic abscesses
  - Solitary or multiple lesions
  - Small to massive in size



# Granulomatous inflammation

- **Infections** – tbc, typhoid, 3rd stage of syphilis, fungal, parasitic
- **Sarcoidosis**
- **Granulomas as part of other diseases** (primary biliary cholangitis, drug reaction,...)

# Sarcoidosis



# Chronic hepatitis: etiology

**Hepatotropic viruses**

**Steatotic liver disease** – alcoholic, non-alcoholic NASH / MASLD – metabolic dysfunction-associated steatotic liver disease; MetALD – MASLD + ↑ alcohol intake

**Autoimmune**

**Drug induced**

**Metabolic** (Wilson disease, hemochromatosis,  $\alpha$ 1-antitrypsin deficiency)

**Cryptogenic**

# Chronic hepatitis: clinical definition

Clinical symptoms of hepatitis more than:

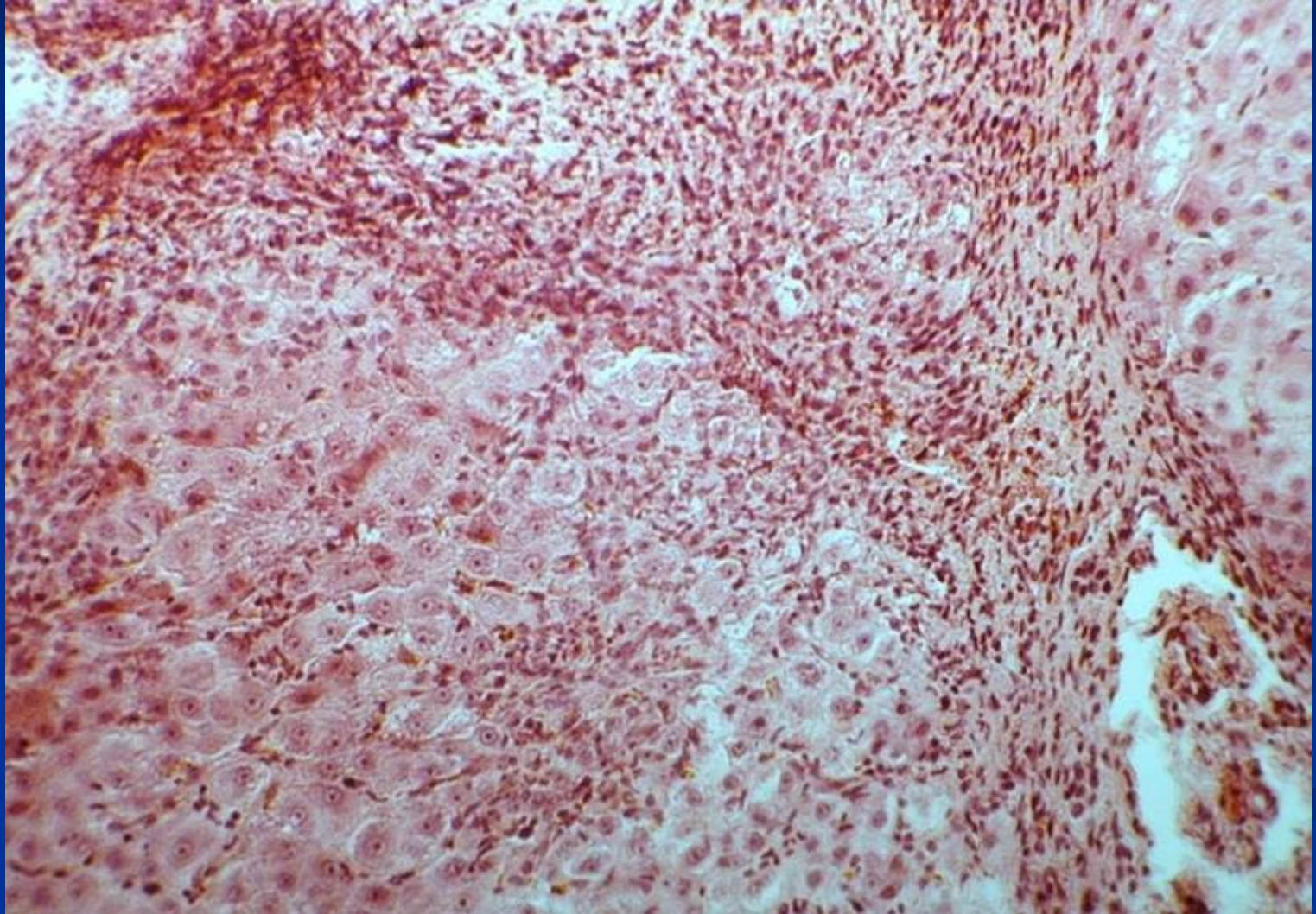
6 months

12 months in HCV

# Chronic hepatitis - histopathology

- **Disease activity:** grade of necroinflammatory changes in portal spaces and lobules (interface activity; type, grade and localisation of necrosis; grade of inflammatory infiltrate)
- **Disease stage:** stage of fibrosis and architectural changes (portal fibrotic expansion, bridging fibrosis, nodularity → advanced stage/cirrhosis)

## Chronic hepatitis: high grade



# Toxic and drug induced liver damage: effect

Most substances completely or partially metabolized in liver → wide area for possible pathologic reactions and changes

- Injury due to
  - Direct toxicity
  - Conversion of drug/non-endogenous substance to active toxin
  - Immune mechanisms → drug/toxin acting as a haptenAcute or chronic.
- **Expectable (intrinsic):** typical reaction, known for drug/dose/patient (i.e. acetaminophen)
- **Non-expectable (idiosyncratic):** atypical immunologic reaction, non-preventable, often combination of multiple factors

# Toxic and drug induced liver damage

- **Anorganic substances**
- **Organic substances**
- **Industrial substances**
- **Poisons/venoms**
- **Drugs**
- **Alcohol**



# Toxic and drug induced liver damage : forms

Generally any form of damage possible (diff. dg.!)

- **Necrosis** (acetaminophen/paracetamol)
- **Steatosis**
  - macrovesicular (alcohol, corticoids)
  - microvesicular (tetracyclin, aspirin)
- **Cholestasis** (steroids-anabolic, contraceptives)
- **Hepatitis mild** (aspirin, synthetic penicilines)
- **Hepatitis serious** (halotan)
- **Chronic periportal hepatitis** (sulphonamides)

# Toxic and drug induced liver damage : forms

- **Granulomatous hepatitis** (phenylbutazone)
- **Vascular lesions** (contraceptives, cytostatics)
- **Hyperplasia, neoplasia** (contraceptives)

# Alcoholic liver disease (ALD)

- **Steatosis (90%)**
- **Acoholic steatohepatitis**
- **Alcoholic cirrhosis**
- **Hepatocellular carcinoma**

Diff. dg: NAFLD/NASH (non-alcoholic fatty liver disease/ non-alcoholic steatohepatitis)

## MetALD

weekly alcohol intake 140– 350 g (F), 210–420 (M)

daily 20-50 F, 30-60 M

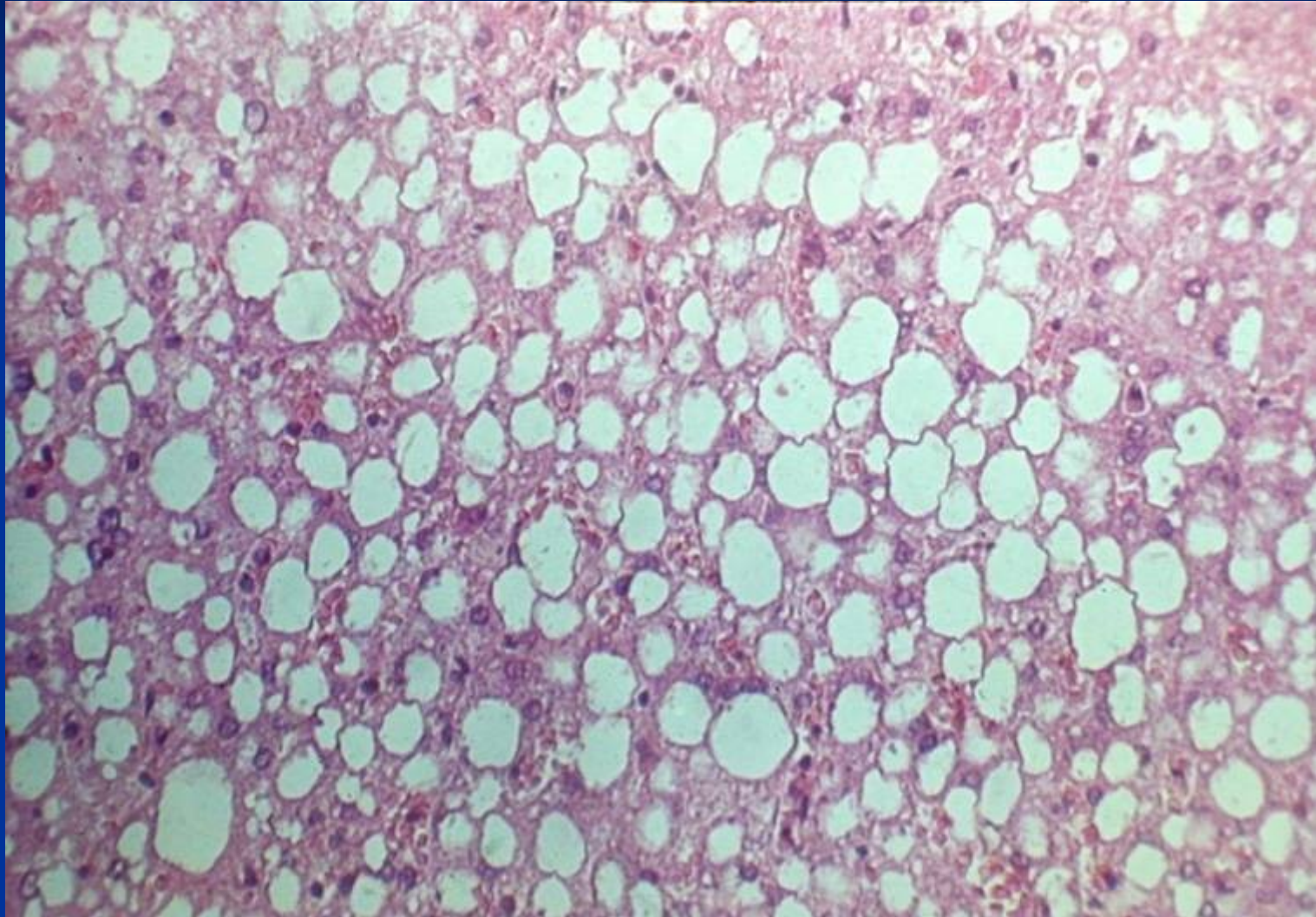
# Alcoholic liver disease

- Alcohol abuse: common cause of serious liver disease in Western societies
- Asymptomatic people who drank moderate-to-heavy amounts of alcohol: prevalence of alcoholic hepatitis - 25-30%.
- the 1-year mortality rate after hospitalization for acute alcoholic hepatitis is approximately 40%.

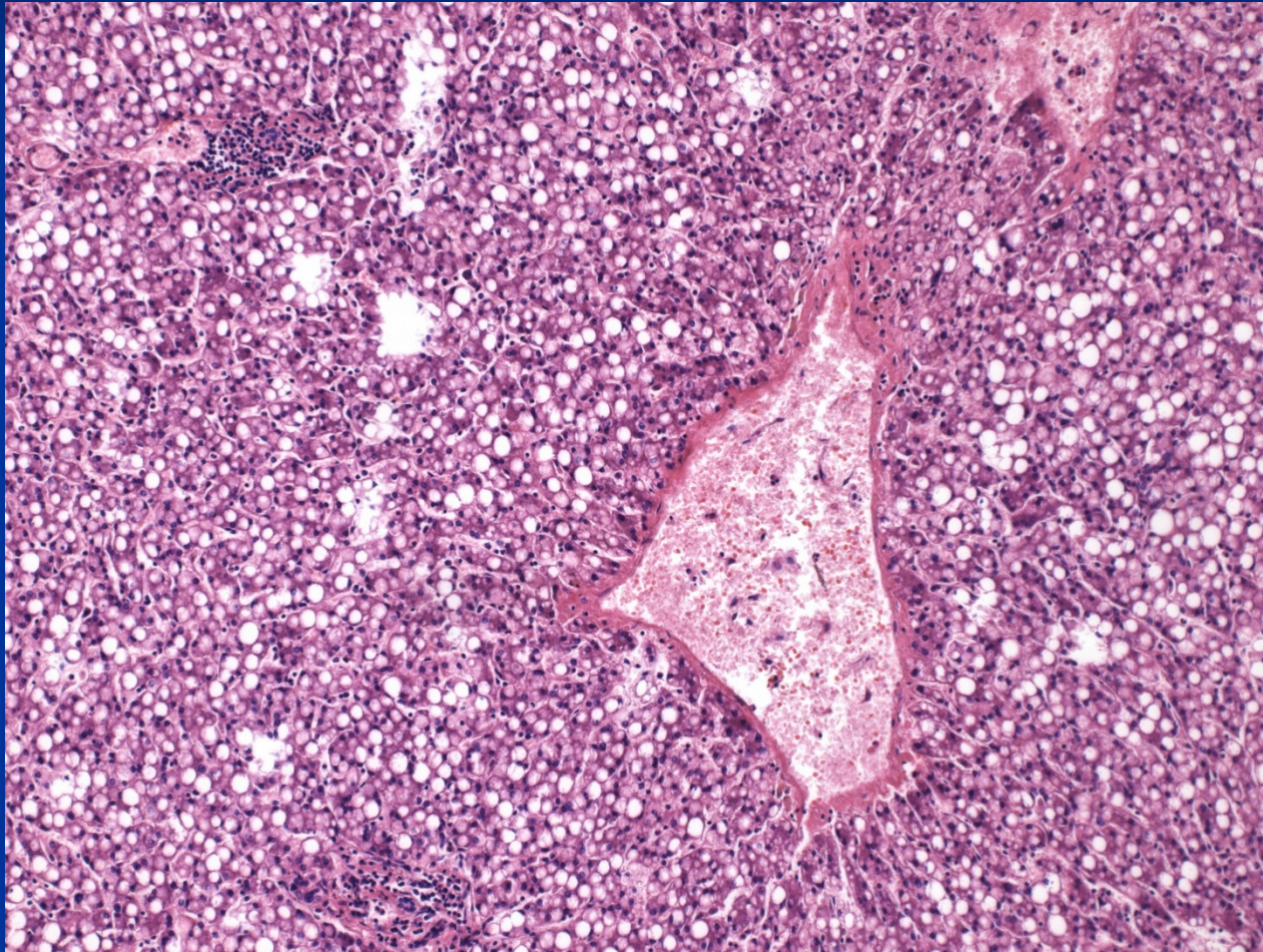
# Alcoholic liver disease

- Estimated minimum daily ethanol intake required for the development of cirrhosis:
  - 40 g for adult males
  - 20 g for adult females
  - different individual susceptibility (genetic, environmental)
- Patients who continue to drink after a diagnosis of alcoholic liver disease:
  - 5-year survival rate ~ 30% for females
  - 70% for males

## Alcoholic liver disease (ALD) : steatosis



# Steatohepatitis



# Alcoholic hepatitis

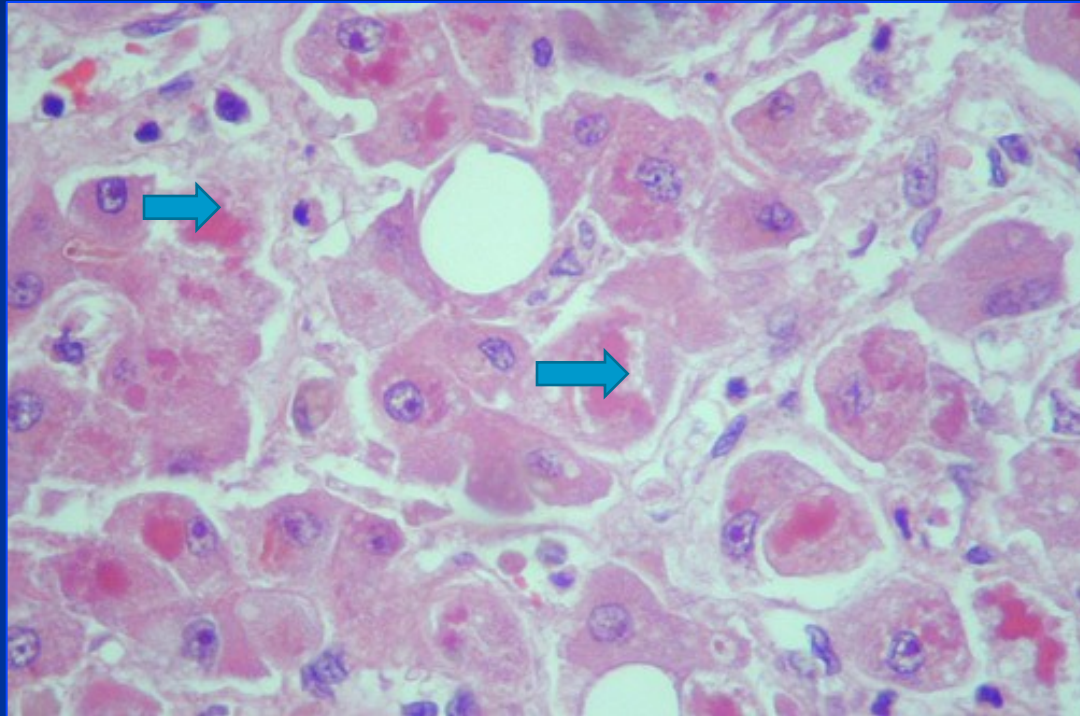
- syndrome of progressive inflammatory liver injury associated with long-term heavy intake of ethanol
- subacute onset of *fever*, hepatomegaly, leukocytosis, marked *impairment of liver function* (eg. jaundice, coagulopathy), and manifestations of *portal hypertension* (eg, ascites, hepatic encephalopathy, variceal hemorrhage).



# Alcoholic hepatitis

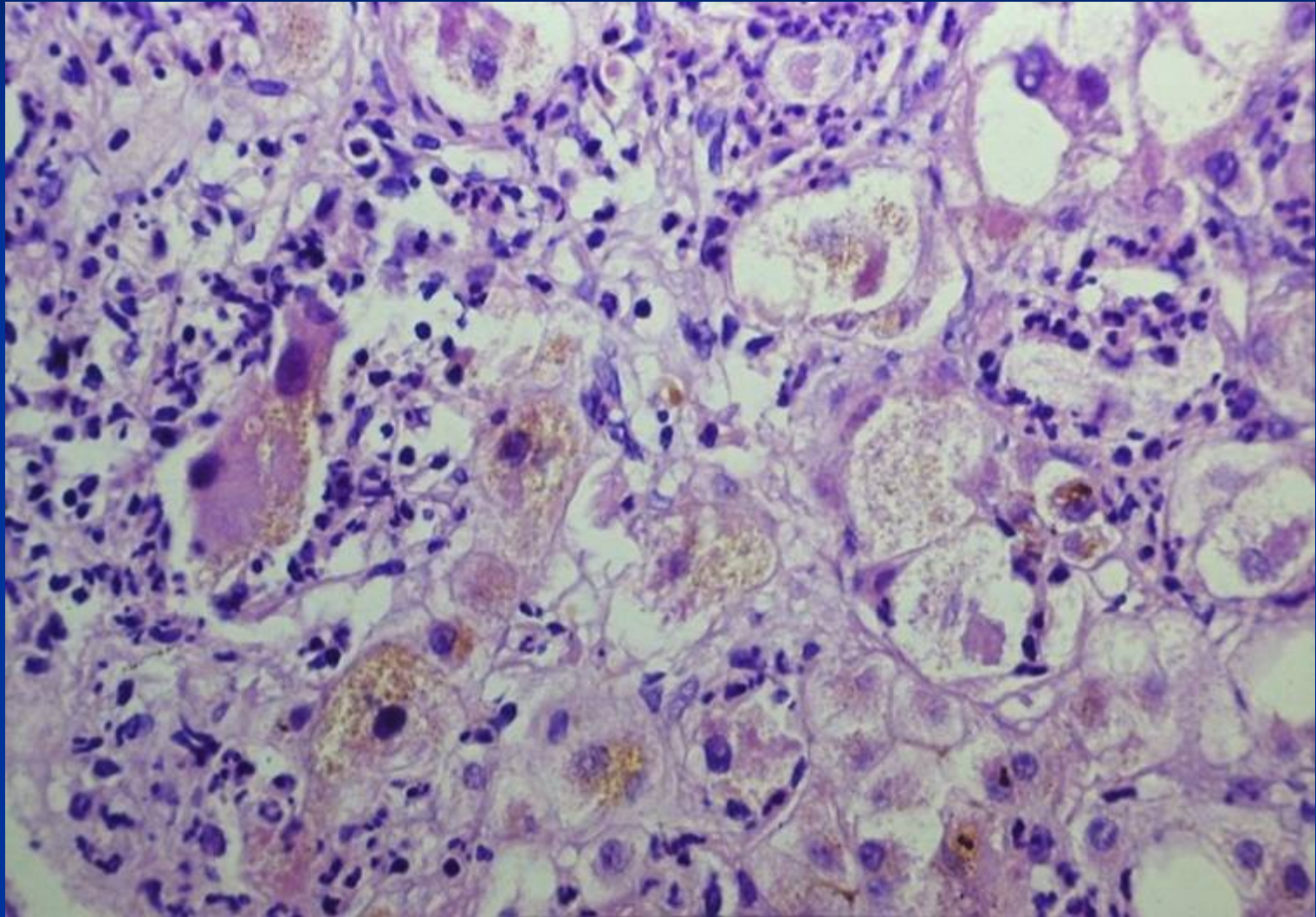
- Centrilobular ballooning necrosis of hepatocytes, neutrophilic infiltration, Mallory hyaline inclusions. Steatosis and cirrhosis frequent.
- Usually persists and progresses to advanced stage/cirrhosis if heavy alcohol use continues
- Alcohol consumption may exacerbate injury caused by other pathogenic factors, incl. hepatitis viruses.

# Alcoholic hepatitis



**Mallory-Denk bodies:** globular red hyaline material within hepatocytes, not entirely specific for alcoholic etiology.

# Alcoholic hepatitis : steatohepatitis, cholestasis, Mallory-Denk bodies



# NAFLD/NASH/MASLD: non- alcoholic (metabolic dysfunction assoc. fatty liver disease/steatohepatitis Spreading silent epidemics

In many countries the most common chronic liver disease

Patients with metabolic/insulin resistance syndrome:

„male-type“ obesity (intraabdominal fat accumulation  
– waist size)

hyperlipidemia

DM of II type, hyperglycaemia

# **NASH: non-alcoholic steatohepatitis**

## **Other diseases related to NASH**

**Acquired metabolic diseases** (parenteral nutrition)

**Inherited metabolic diseases**

(abetalipoproteinaemia, tyrosinaemia)

**Surgery** (jejunoileal bypass, extensive resections of small intestine...)

**Drugs, toxins** (amiodarone, glucocorticoids, tamoxifen, synthetic estrogens...)

# **NASH: non-alcoholic steatohepatitis**

**Hepatomegaly**

**Increase of aminotransferases (ALT>AST)**

**Histology** – similar to alcoholic hepatitis without alcohol consumption, glycogenated „clear“ nuclei of hepatocytes, ...

**Natural history** – may lead to advanced stage/cirrhosis, etc.

# Autoimmune hepatitis - AIH

- Chronic disease of unknown cause, continuing hepatocellular inflammation and necrosis → advanced stage/cirrhosis
- Immune serum markers (autoantibodies ANA, ...) frequently present, common association with other autoimmune diseases.
- Response to steroid and/or immunosuppressive therapy
- In progressive + relapsing disease - transplantation

# AIH

- 70-80% of patients are women
- acute hepatitis, chronic hepatitis, or well-established advanced stage/cirrhosis.
- symptoms of acute hepatitis marked by fever, hepatic tenderness, and jaundice.
- non-specific signs: pruritus, skin rash, myalgia, diarrhea, etc.



# Advanced stage liver disease/Cirrhosis

- Alcoholic liver disease (60%, rising tendency)
- Cryptogenic (hidden) cirrhosis, usually former NASH (10-15%, ↑)
- Viral hepatitis → HBV, HCV (10%, HBV ↓, HCV expected ↓ - antivirotics)
- Hereditary haemochromatosis
- Autoimmune liver disease
  - Autoimmune hepatitis
  - Primary biliary cholangitis (PBC)
- Recurrent biliary obstruction (5-10%)
- Wilson disease; AAT deficiency (rare)

# Pathogenesis

- Hepatocellular death → regeneration → recurrent death → nodularity lacking zonal structure
- Progressive stimulus for synthesis + deposition of collagen (chronic inflammatory cytokine production, direct stimulation of stellate cells) → fibrosis
- Shunts develop → sinusoids become high pressure, fast flowing vascular channels → no solute exchange

# Morphology

## Micronodular cirrhosis

Nodules <3mm diameter, common in alcoholic hepatitis; may be a late stage of cirrhosis with low activity

## Macronodular cirrhosis

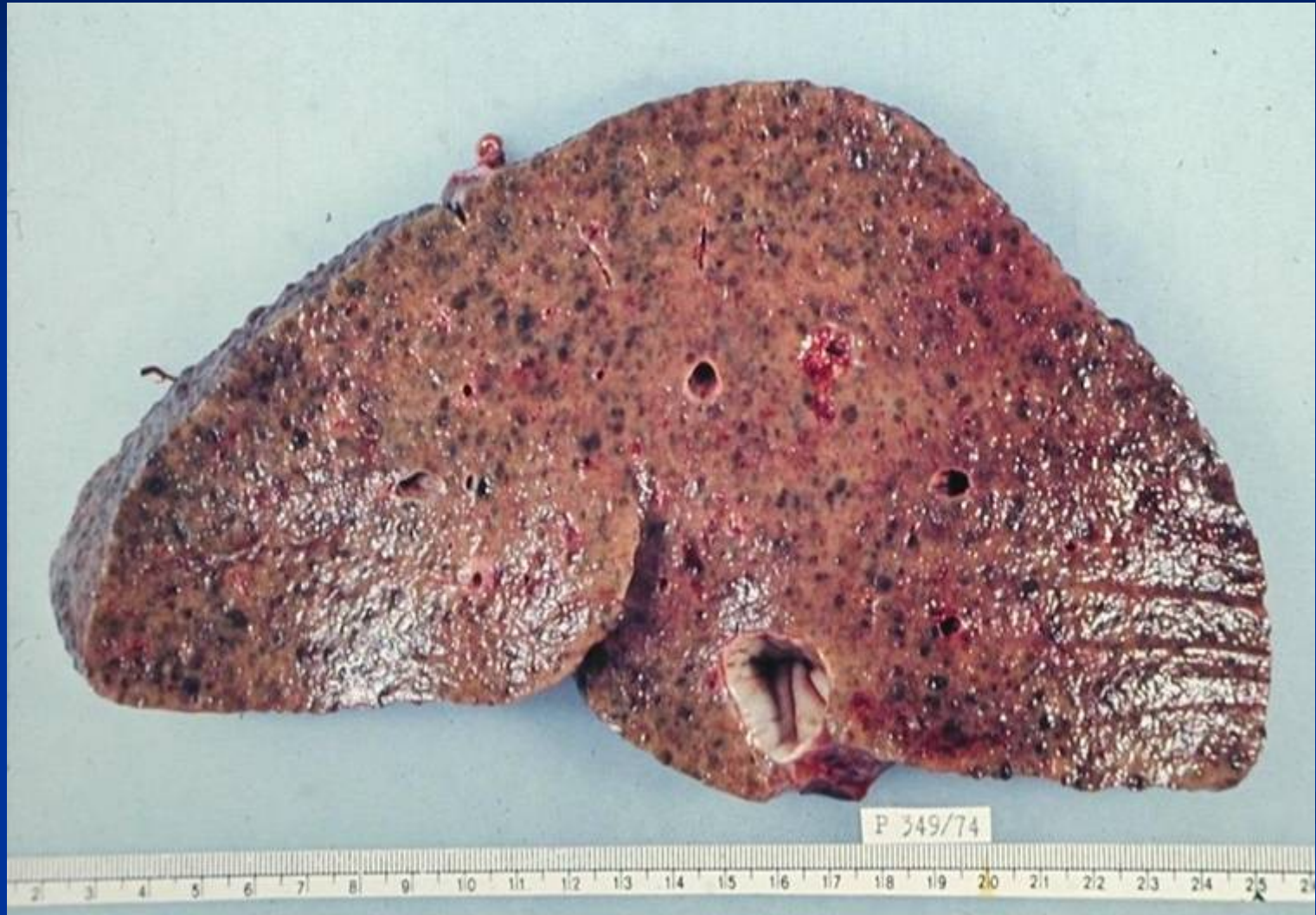Nodules >3mm diameter, uneven changes, early stage of active cirrhosis

## Mixed cirrhosis

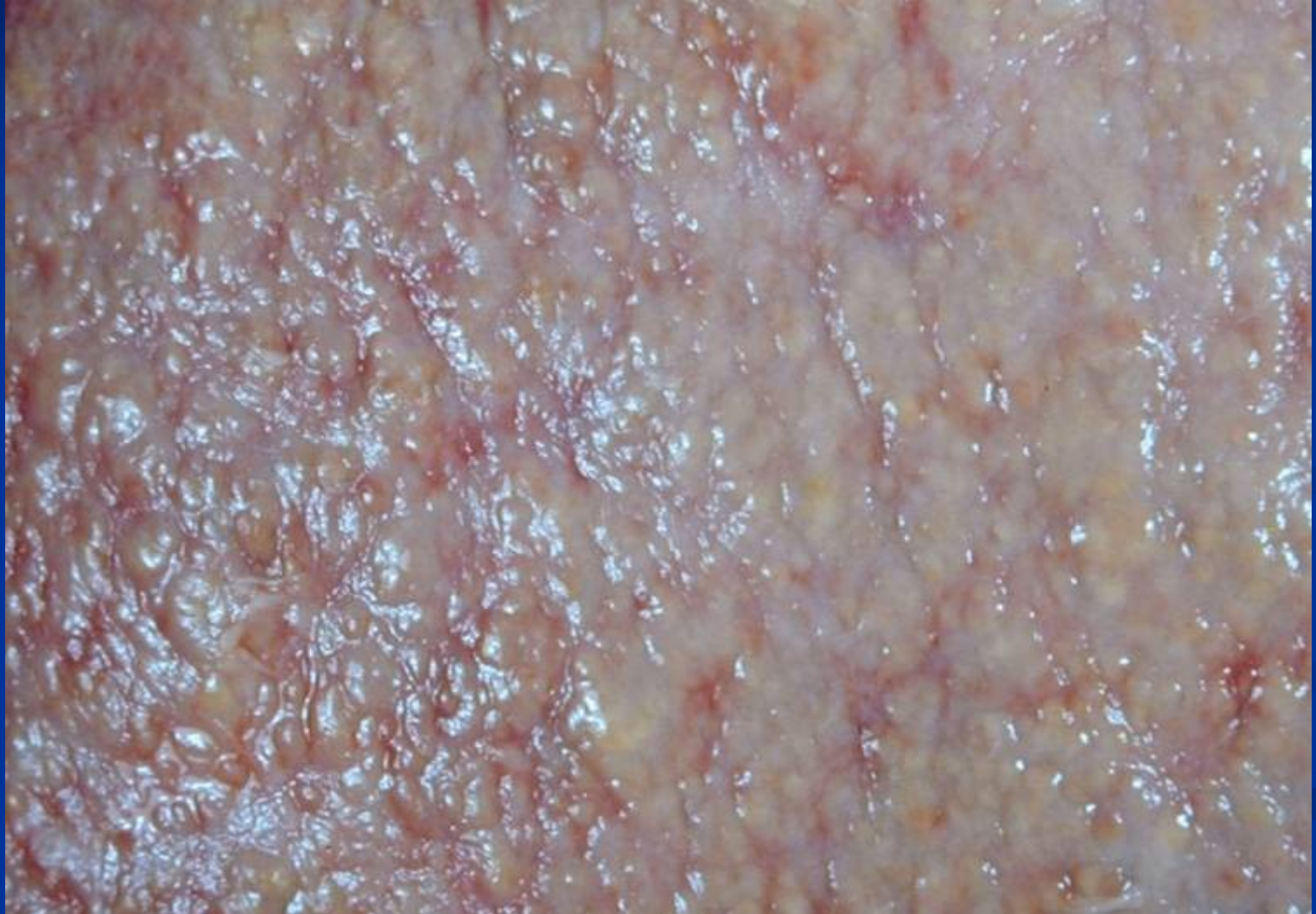Intermediate between the above categories, in progression

Pattern not stable, possibility of progression and/or regression

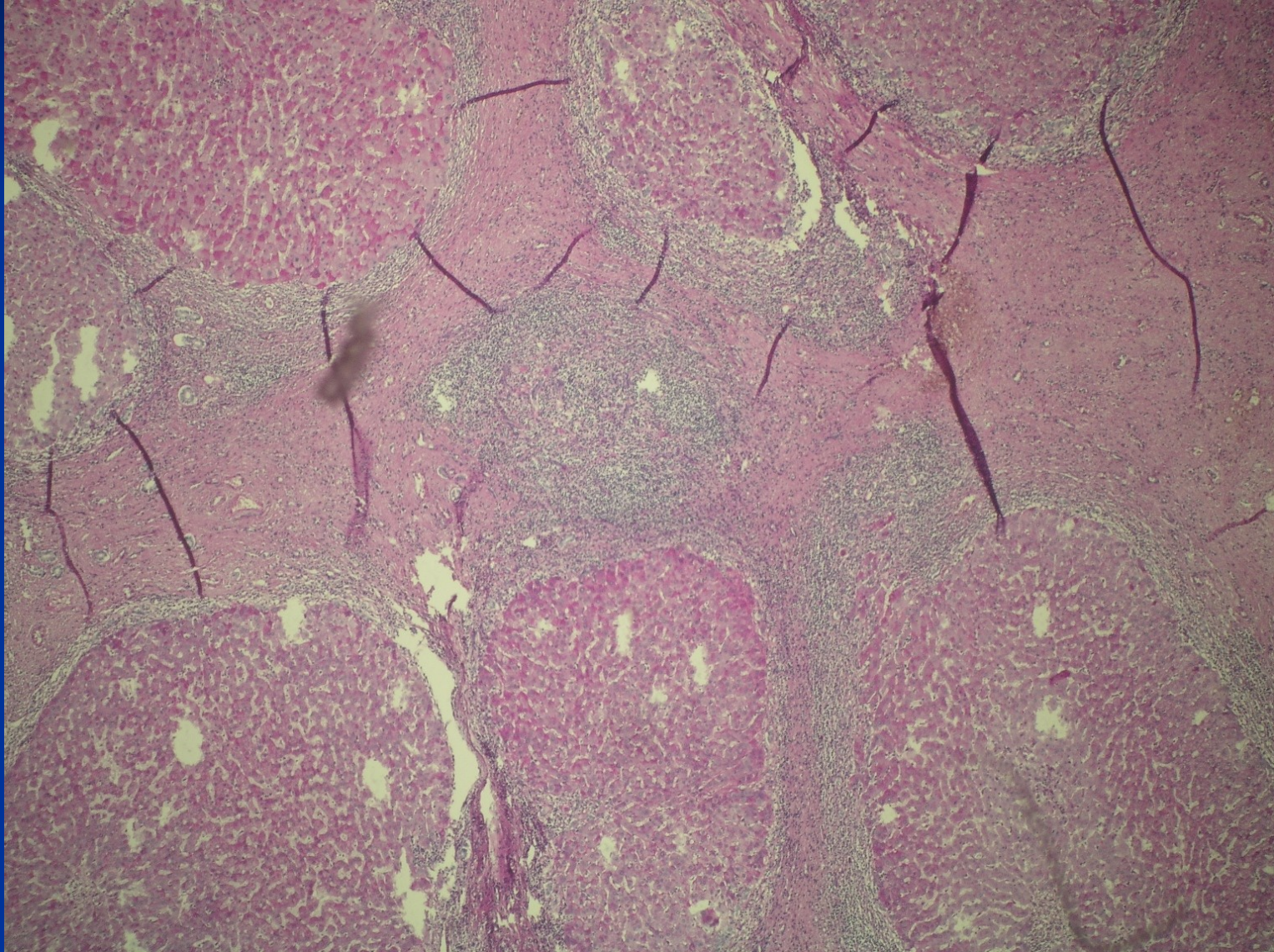
# Advanced stage / Cirrhosis



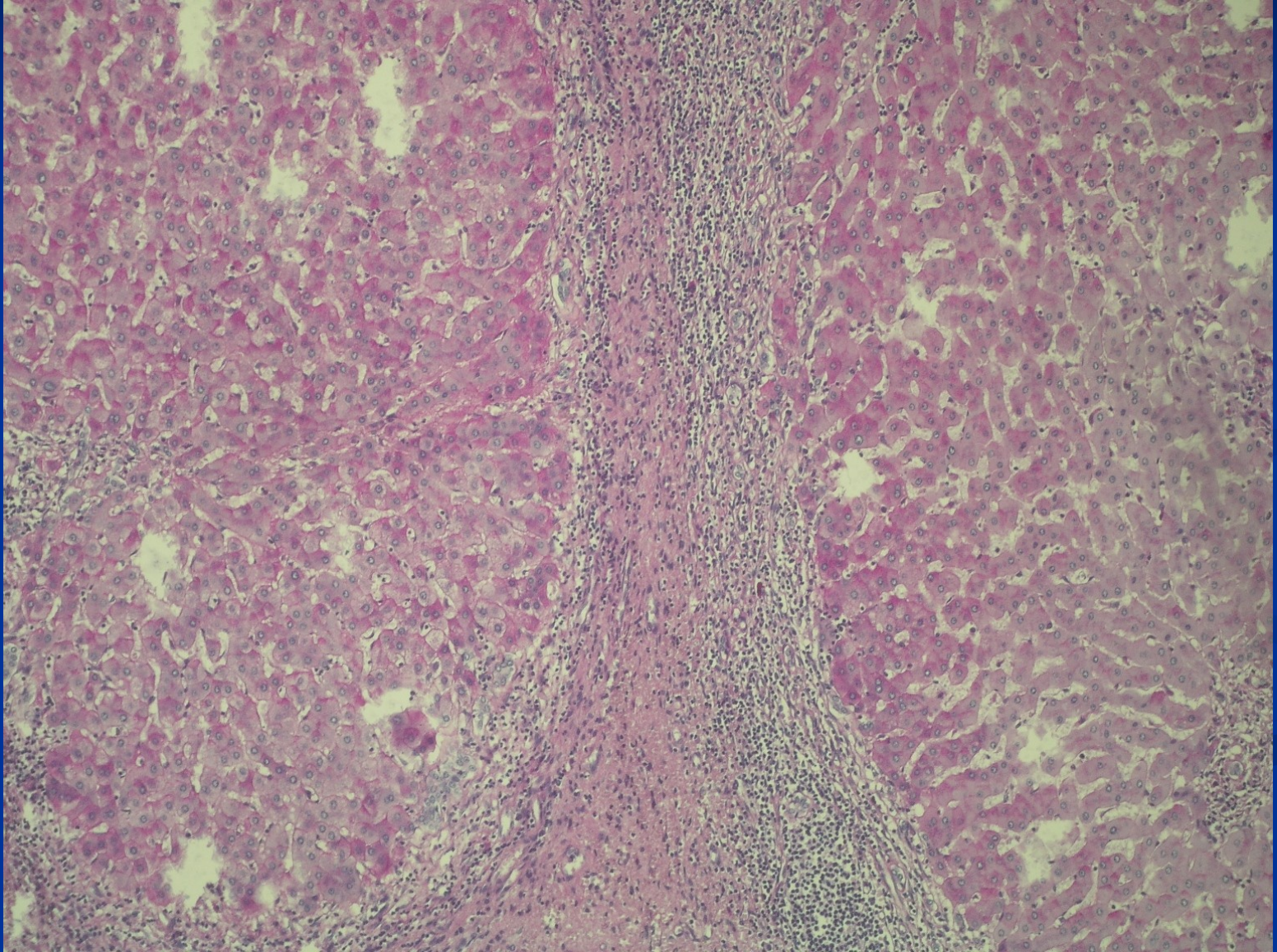
## Advanced stage / Cirrhosis



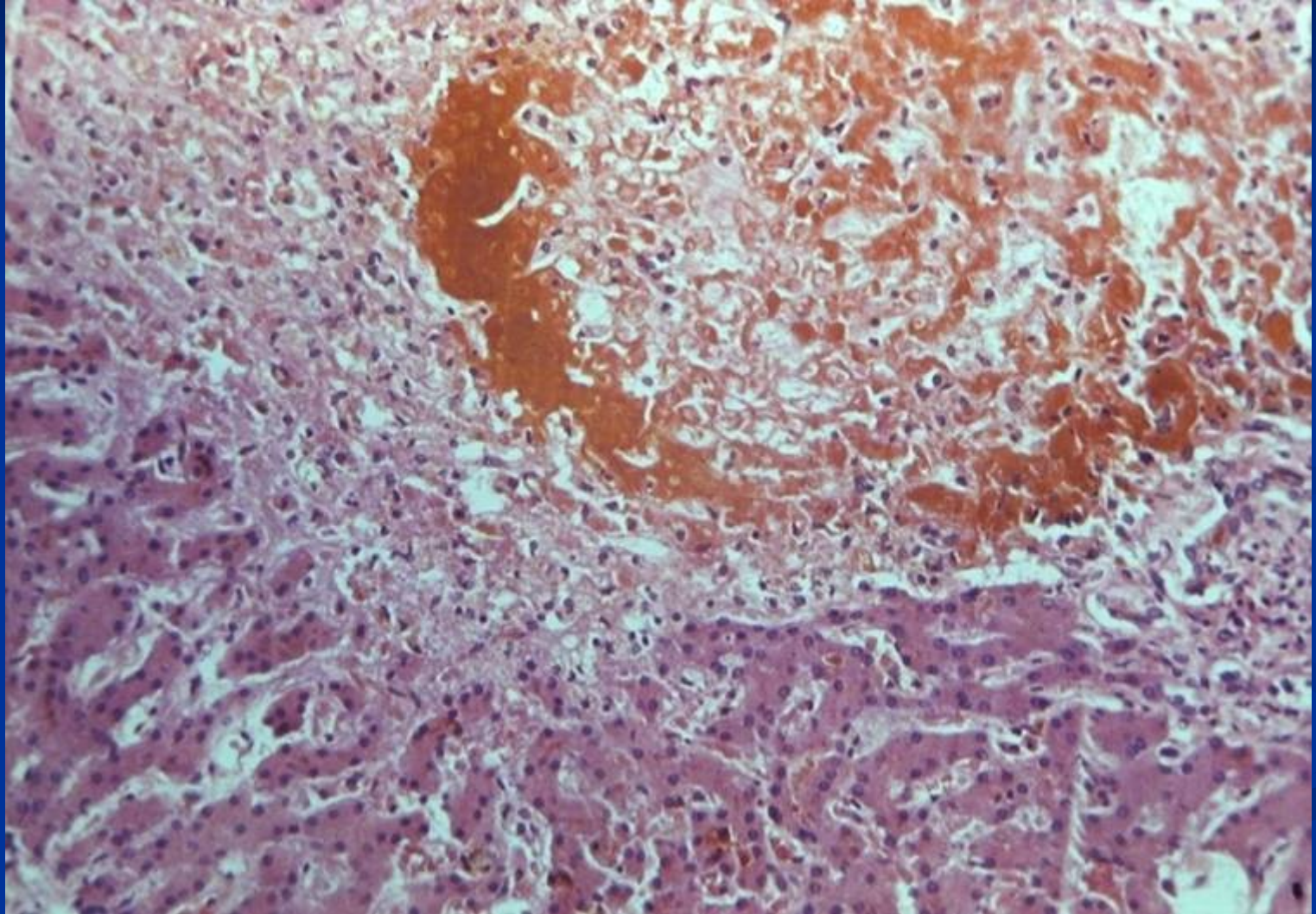
# Advanced stage / Cirrhosis



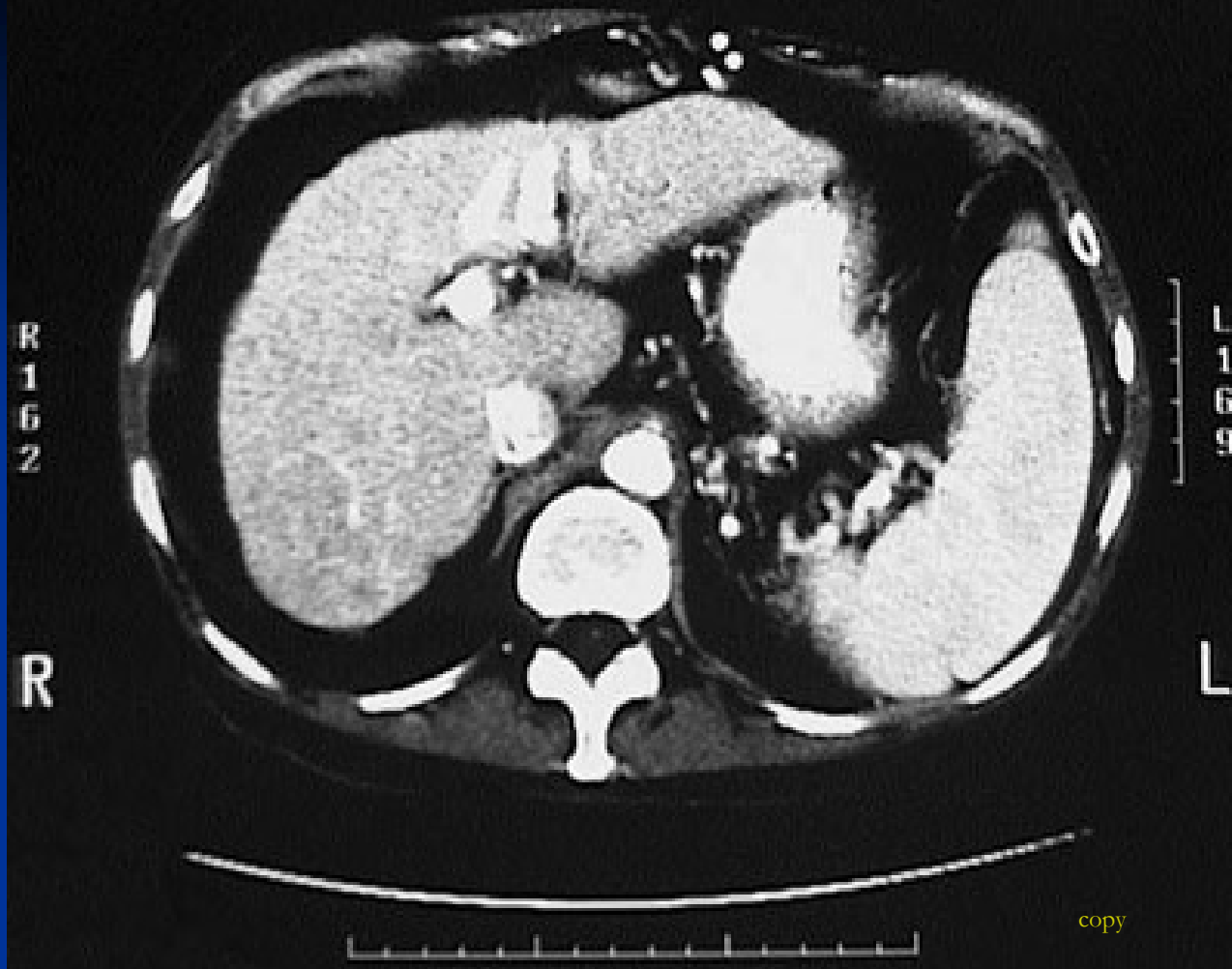
# Advanced stage / Cirrhosis



## Advanced stage / Cirrhosis: biliary







CT scan with contrast of the abdomen in transverse view demonstrates a **small liver with cirrhosis**. The spleen is enlarged from portal hypertension.

# Pathology of intrahepatic bile ducts

- Inborn defects
- Cholelithiasis
- **Inflammation – infection** – cholangitis, usually ascending.  
Secondary biliary cirrhosis

## Immunologically mediated inflammatory disorders

- Primary biliary cholangitis (PBC)
- Primary sclerosing cholangitis (PSC)

## Preneoplastic lesions + tumors

# Cholangitis

- infection of the biliary tract
- choledocholithiasis → biliary tract obstruction → cholangitis.
- biliary tract interventions and stents - common causes of cholangitis.
- hepatobiliary malignancies

# Cholangitis

- Triad of fever, jaundice, and right upper quadrant pain.
- Multiple organisms in 60% of patients. Aerobic *Escherichia coli*, *Klebsiella*, *Enterococcus*; anaerobic *Bacteroides fragilis*.

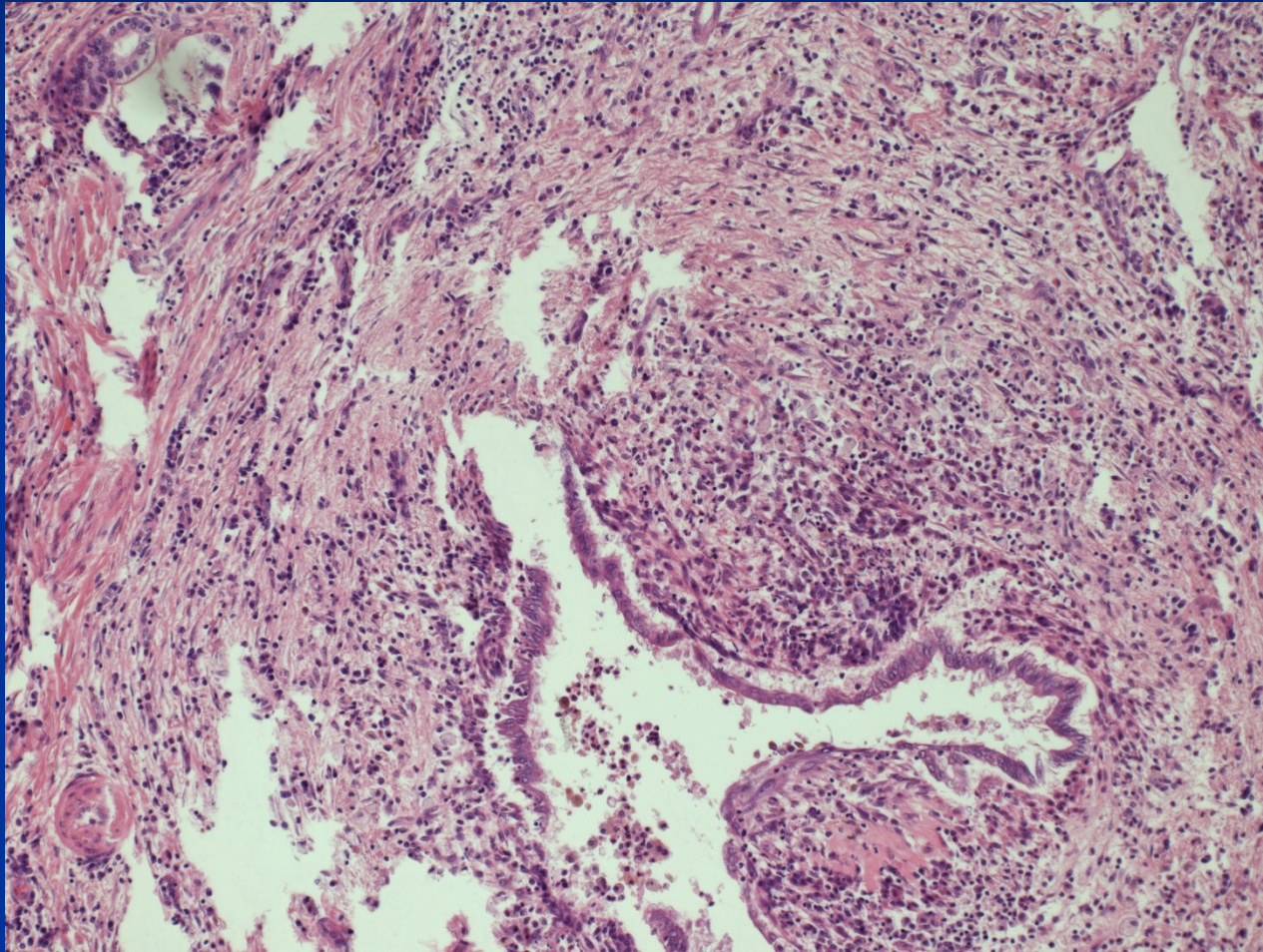
# Primary sclerosing cholangitis - PSC

- progressive chronic liver disease - cholestasis with inflammation and fibrosis of the intrahepatic and extrahepatic bile ducts → cirrhosis
- unknown etiology
- autoimmune mechanism
- some cases part of IgG4-associated systemic sclerosing disease
- 75-90% of patients with PSC have inflammatory bowel disease (IBD).
- exposure of genetically predisposed individuals to an environmental antigen that subsequently elicits an aberrant immune response

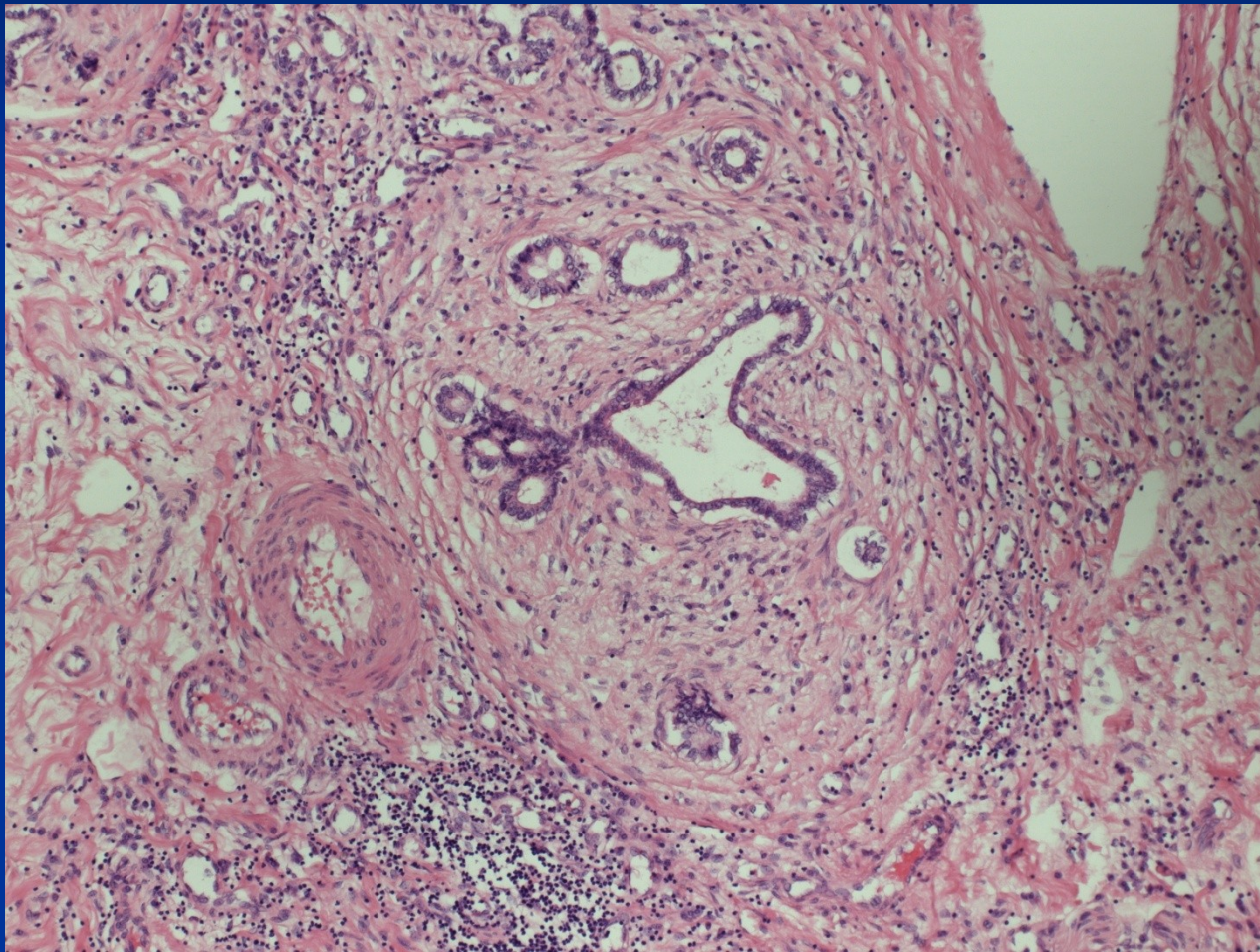
# Primary sclerosing cholangitis - PSC

- The median length of survival from diagnosis to death ~ 12 years.
- 70% of patients with PSC males,
- Mean age of diagnosis around 40 years
- Histology: inflammation and obliterative fibrosis of large intrahepatic/extrahepatic bile ducts. Concentric periductal fibrosis.
- Risk of cholangiocellular carcinoma (diff. dg.!)

# PSC – duct destruction



# PSC – peribiliary fibrosis

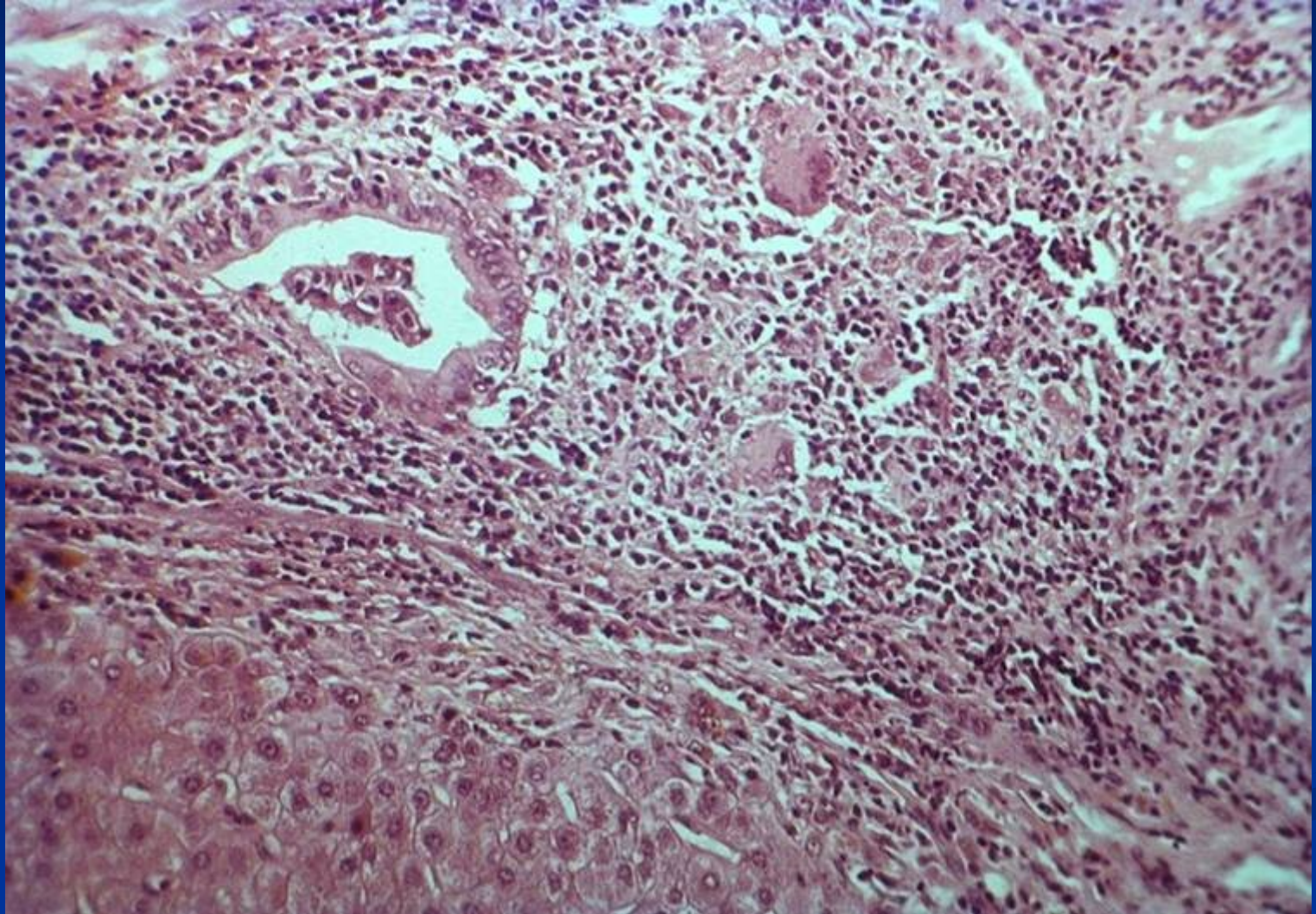




# Primary biliary cholangitis PBC

- Middle-aged women
- M:F = 1:10
- Autoimmune (AMA), + other AI -Sjögren sy., arthritis, thyroiditis, vasculitis
- Insidious onset, usually pruritus, hepatomegaly
- Hyperbilirubinemia, jaundice, cirrhosis late
- ↑ alkaline phosphatase, cholesterol
- Nonsuppurative, granulomatous destruction of medium-sized intrahepatic bile ducts = florid duct lesion

## PBC: duct lesion



# Secondary biliary cirrhosis

**Obstruction of extrahepatal bile ducts: atresia, lithiasis, tumor, iatrogenic**

- Most common cause is extrahepatic cholelithiasis
- Biliary atresia, malignancies of the biliary tree and head of the pancreas, and strictures

Cholestasis

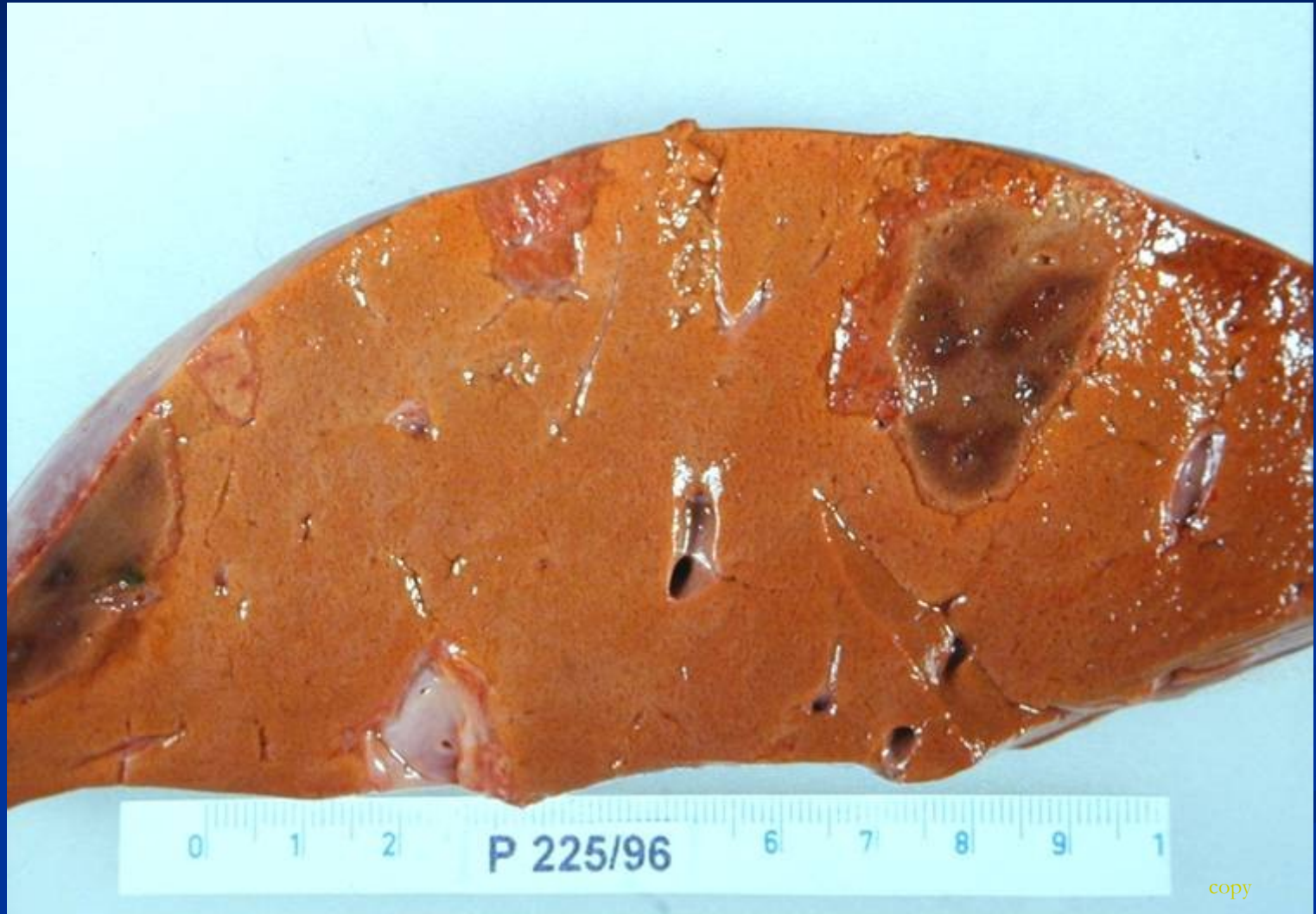Bile duct proliferation with surrounding neutrophils

Periportal fibrosis

# Circulatory disorders of the liver

- **Disorders of arterial system** (liver infarct, ...)
- **Disorders of portal system** (portal vein occlusion)
- **Disorders of venous system** (hepatic vein thrombosis, ...)
- **Disorders of sinusoids**

# Liver infarct

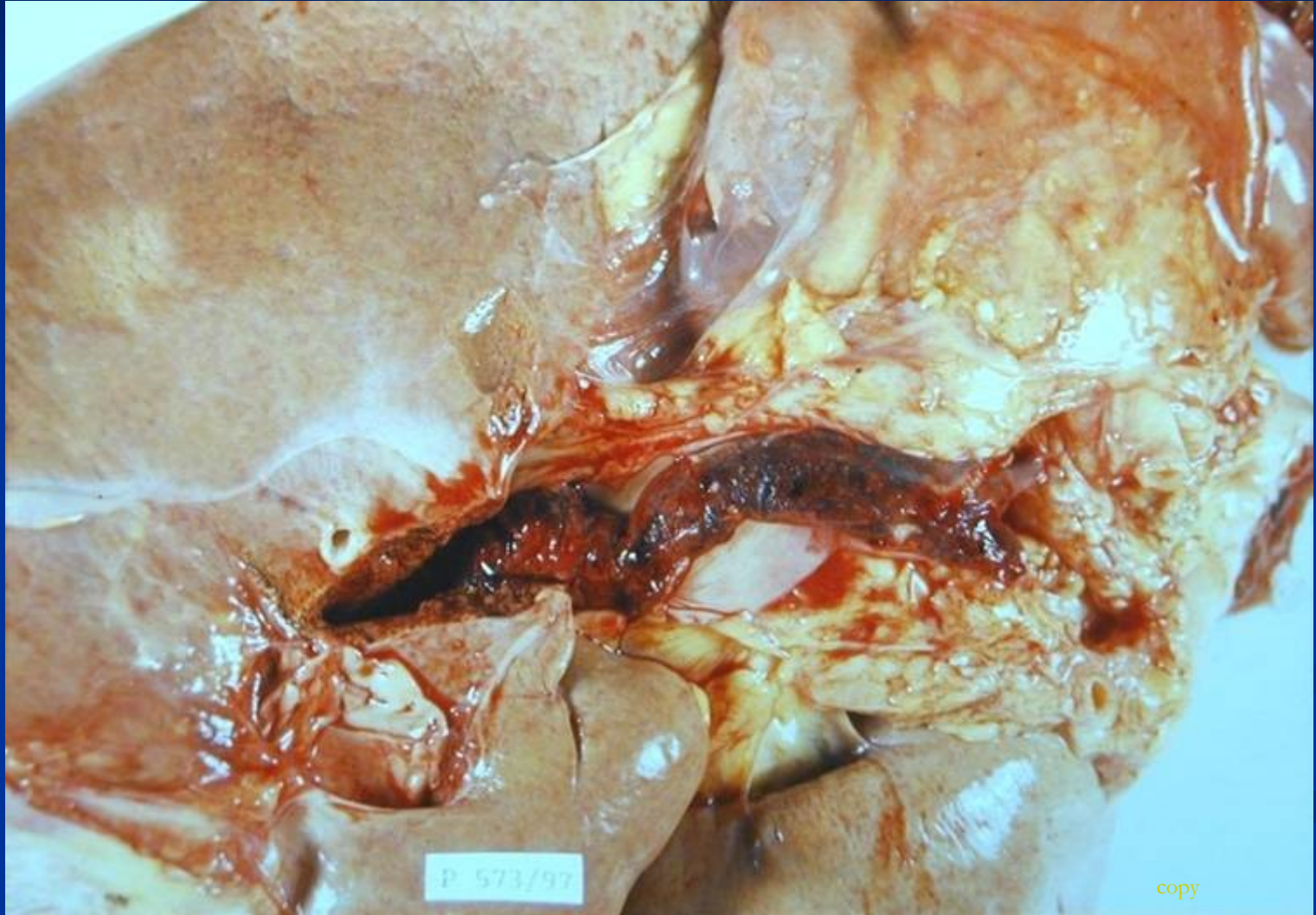

# Disorders of portal system

## Thrombosis and occlusion of v. portae

- **Extrahepatal** (phlebitis, pancreatitis, surgery, trauma)
- **Intrahepatal** (invasion of tumor). No ischemic infarction, area of red-blue discoloration (infarct of Zahn).

# Thrombosis of v.portae



# Disorders of sinusoids

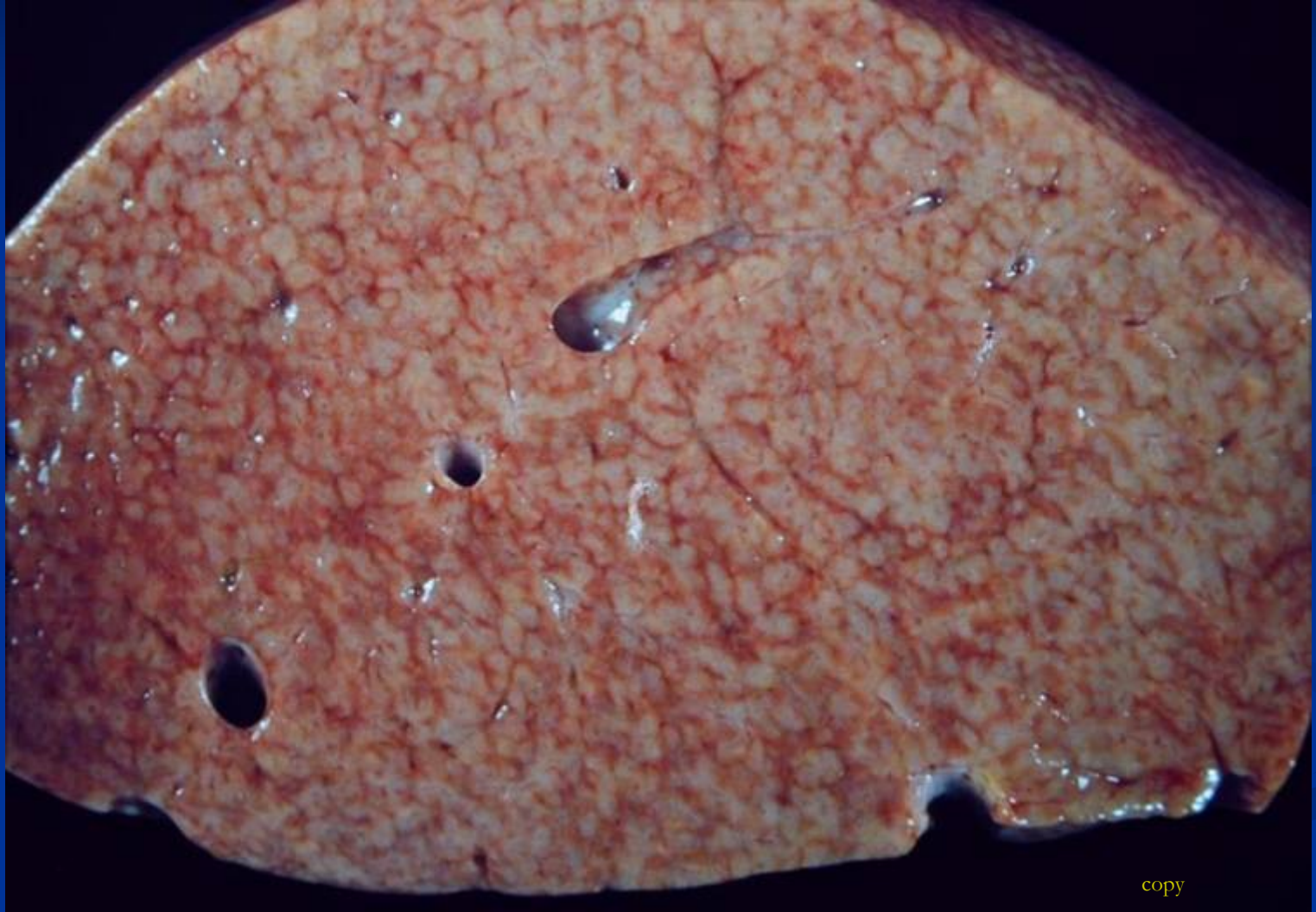**Occlusion of sinuses:** cirrhosis, eclampsy (DIC), sickle cell anaemia

**Systemic circulation:** right-sided heart failure → congestion of centrilobular sinusoids, nutmeg liver (venostasis/steatosis)

Left-sided heart failure → hypoperfusion and hypoxia → centrilobular necrosis



# Congestion



copy

# Focal lesions and tumors

- Tumor-like lesions
- Benign tumors
- Malignant tumors: primary, secondary

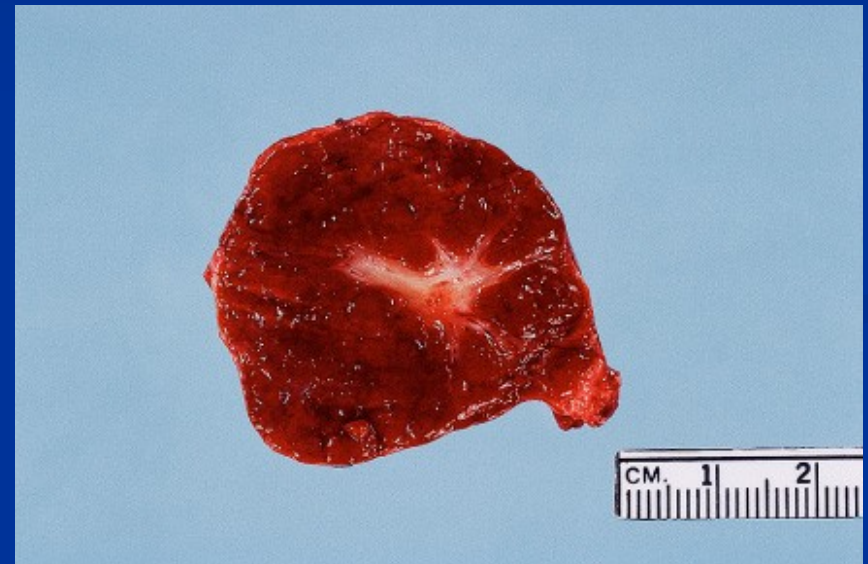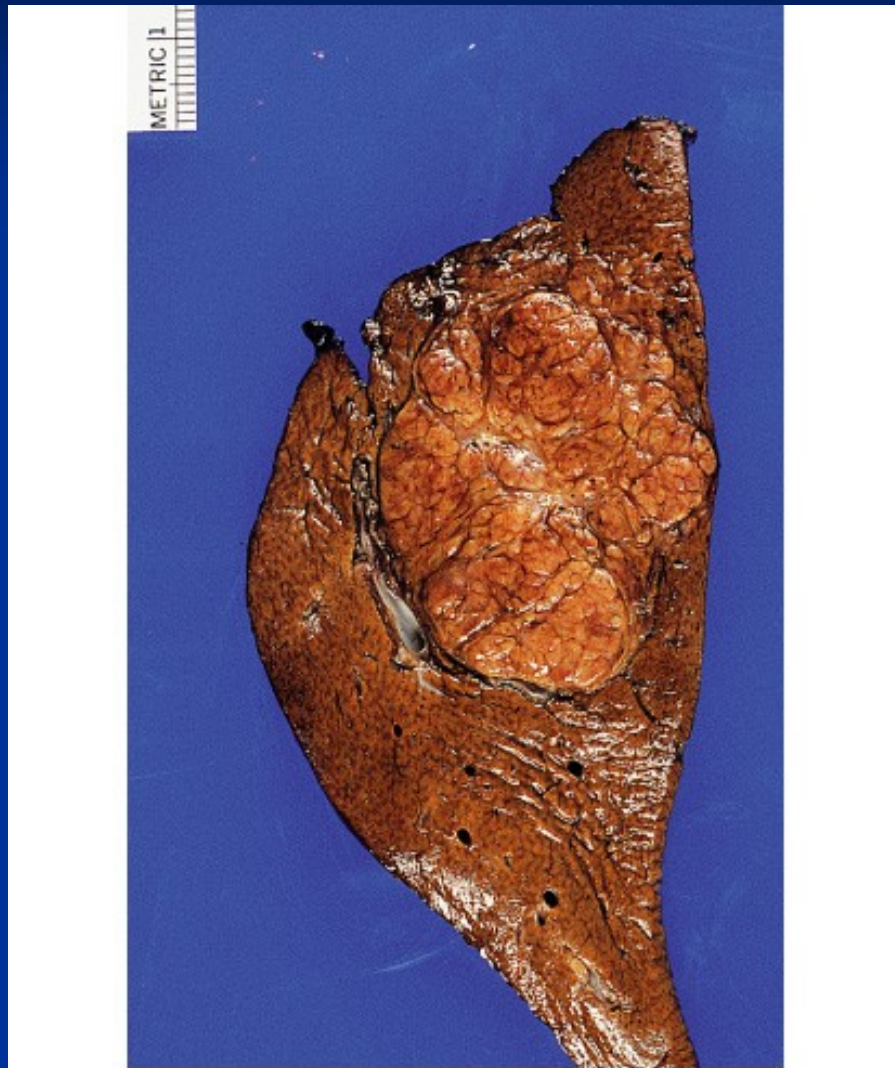
# Tumor-like lesions

- Focal nodular hyperplasia
- Nodular regenerative hyperplasia (lack of fibrosis)
- Cysts
- Biliary hamartoma (von Meyenburg complex)

# Focal nodular hyperplasia

- Localized benign hepatocellular nodules with central stellate fibrous scar
- Single or multiple
- Due to focal increased blood flow - hypertrophy of well-vascularized lobules
- More common in females, oral contraceptives – estrogens
- Diff. dg. x tumors

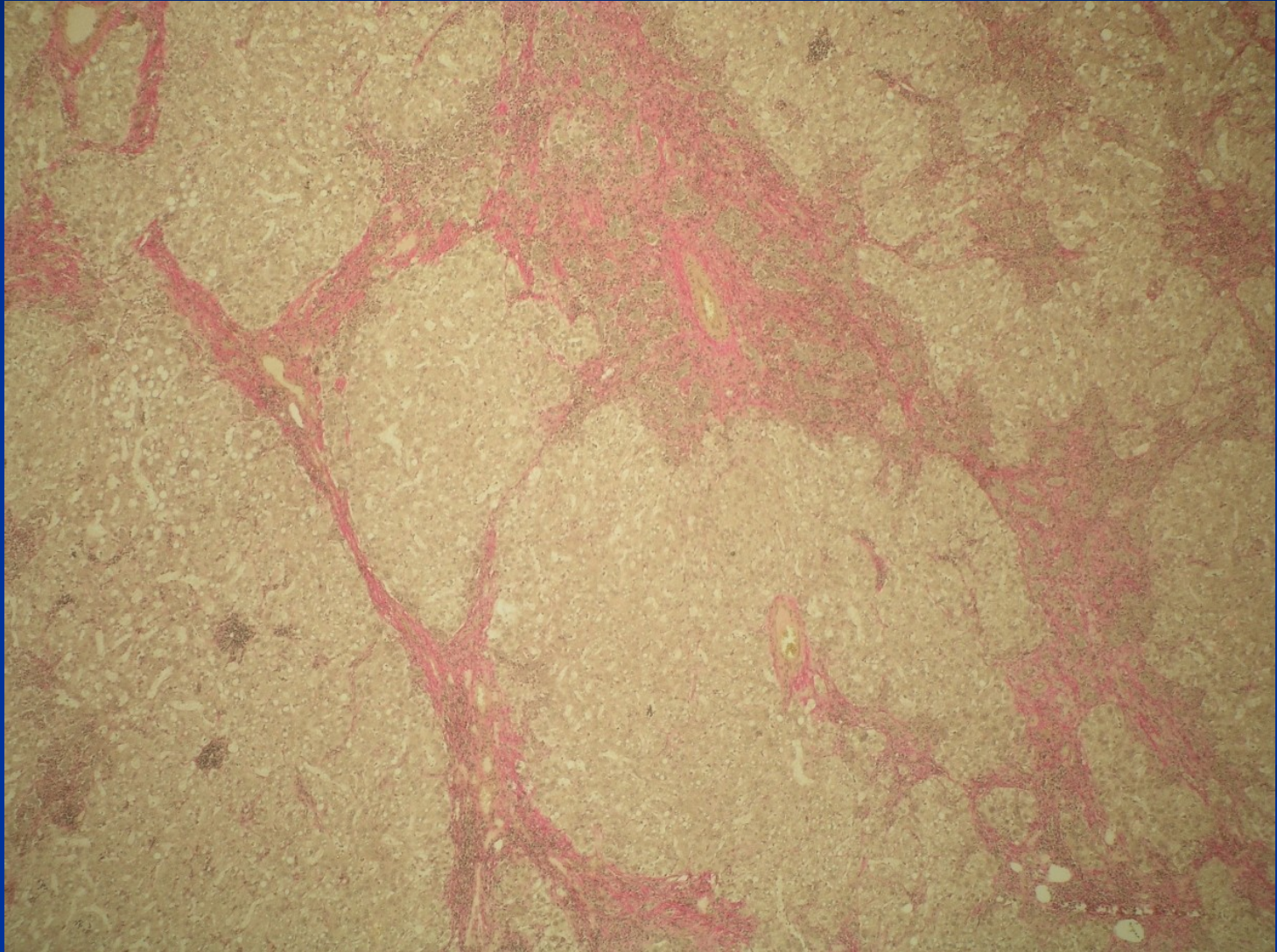
# Focal nodular hyperplasia



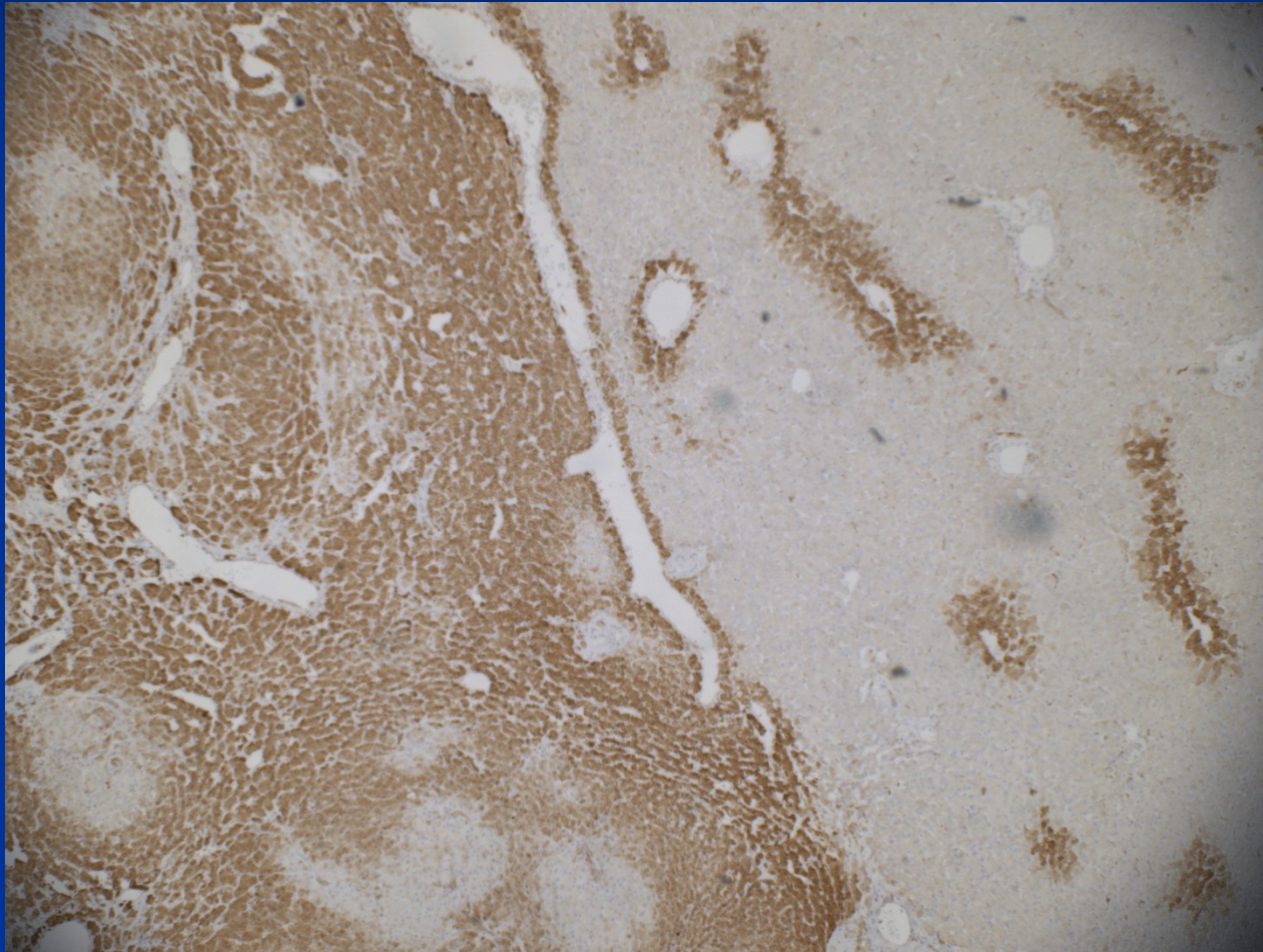
© Elsevier Inc 2004 Rosai and Ackerman's Surgical Pathology 9e

© Elsevier Inc 2004 Rosai and Ackerman's Surgical Pathology 9e

# FNH



# FNH - IHC

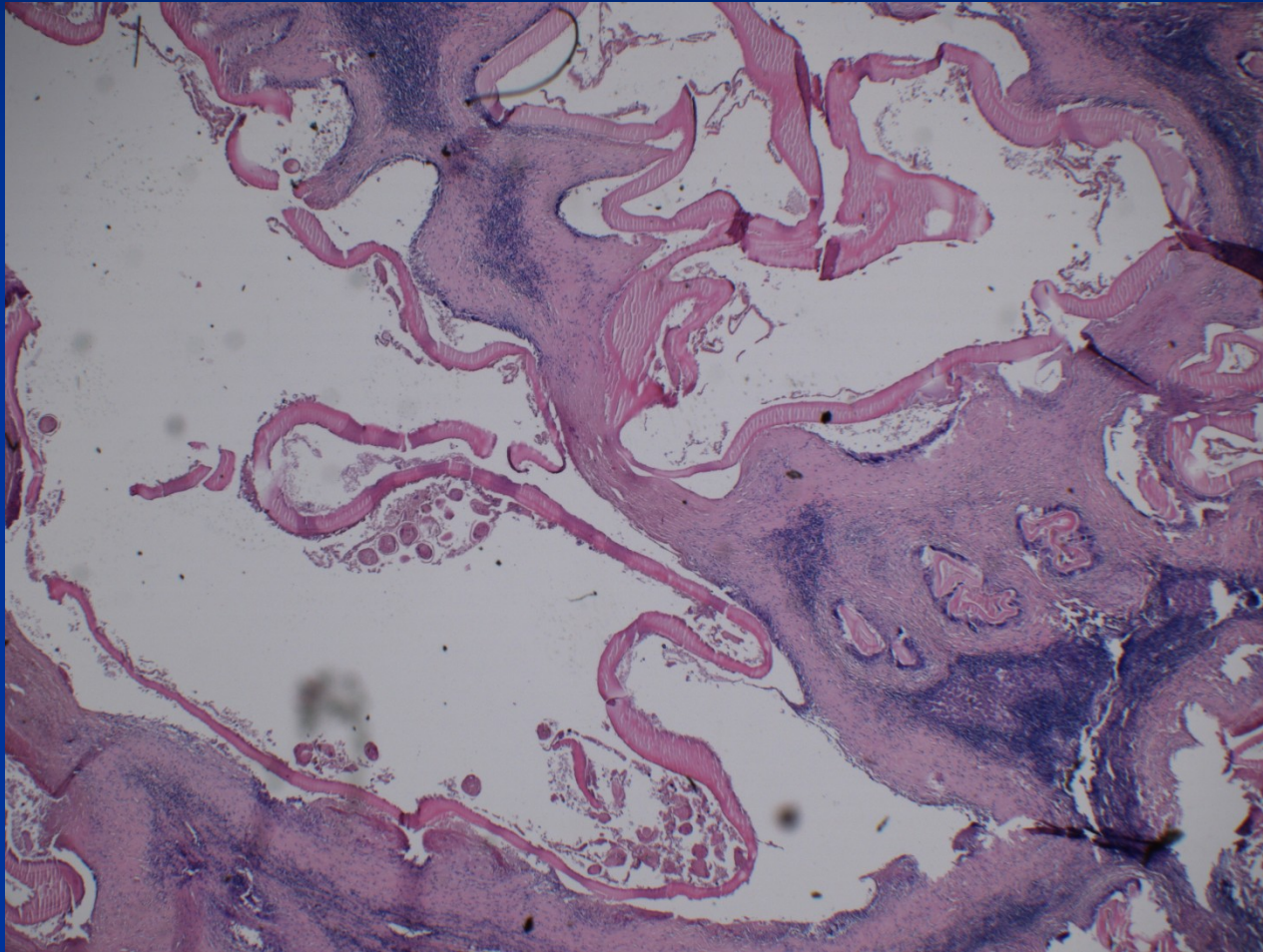


# Cysts

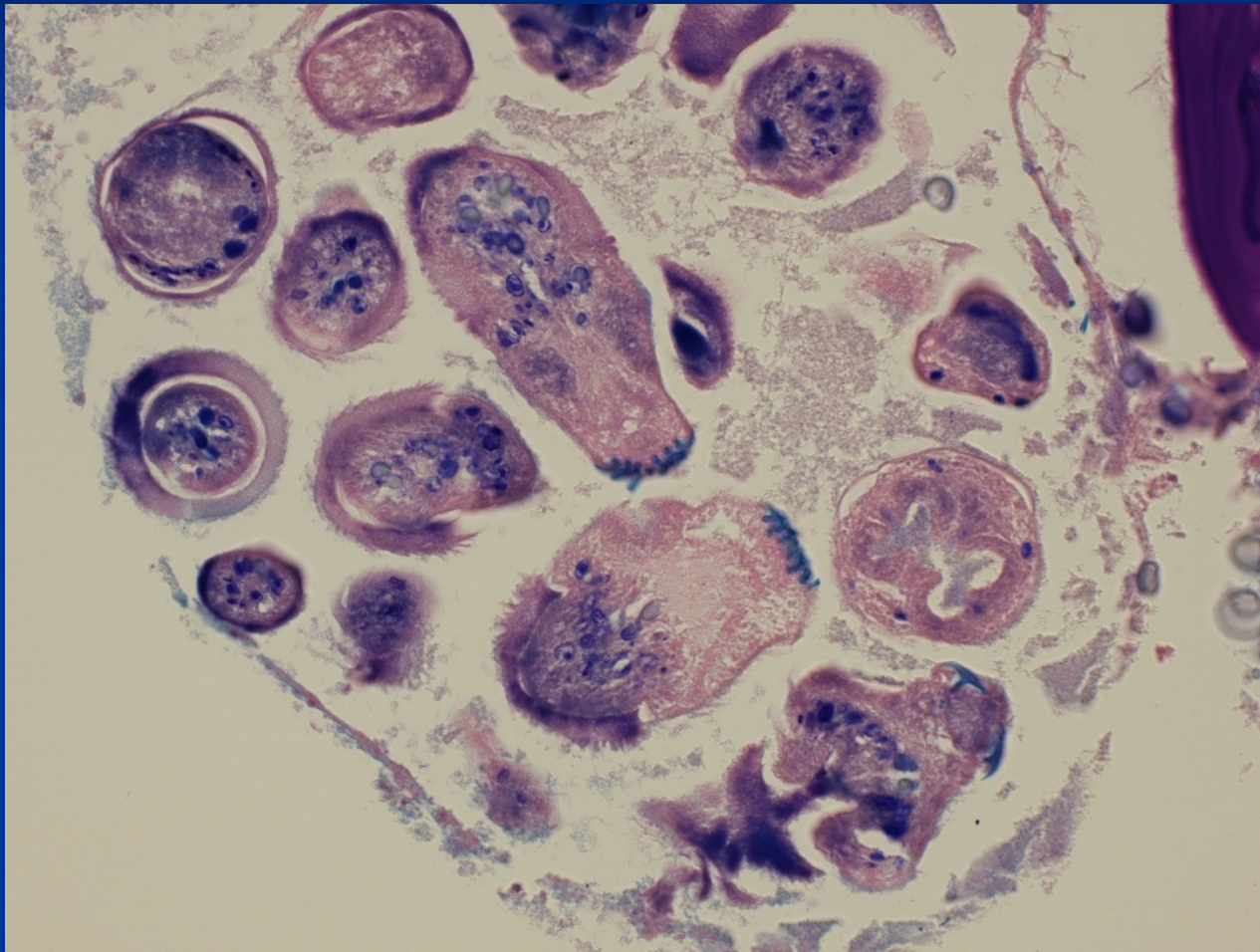
- inborn (polycystic disease etc.)
- acquired simple biliary cyst
- parasitic cyst
- ! cystic tumors



# Parasitic hydatid cyst – alveolar echinococcosis



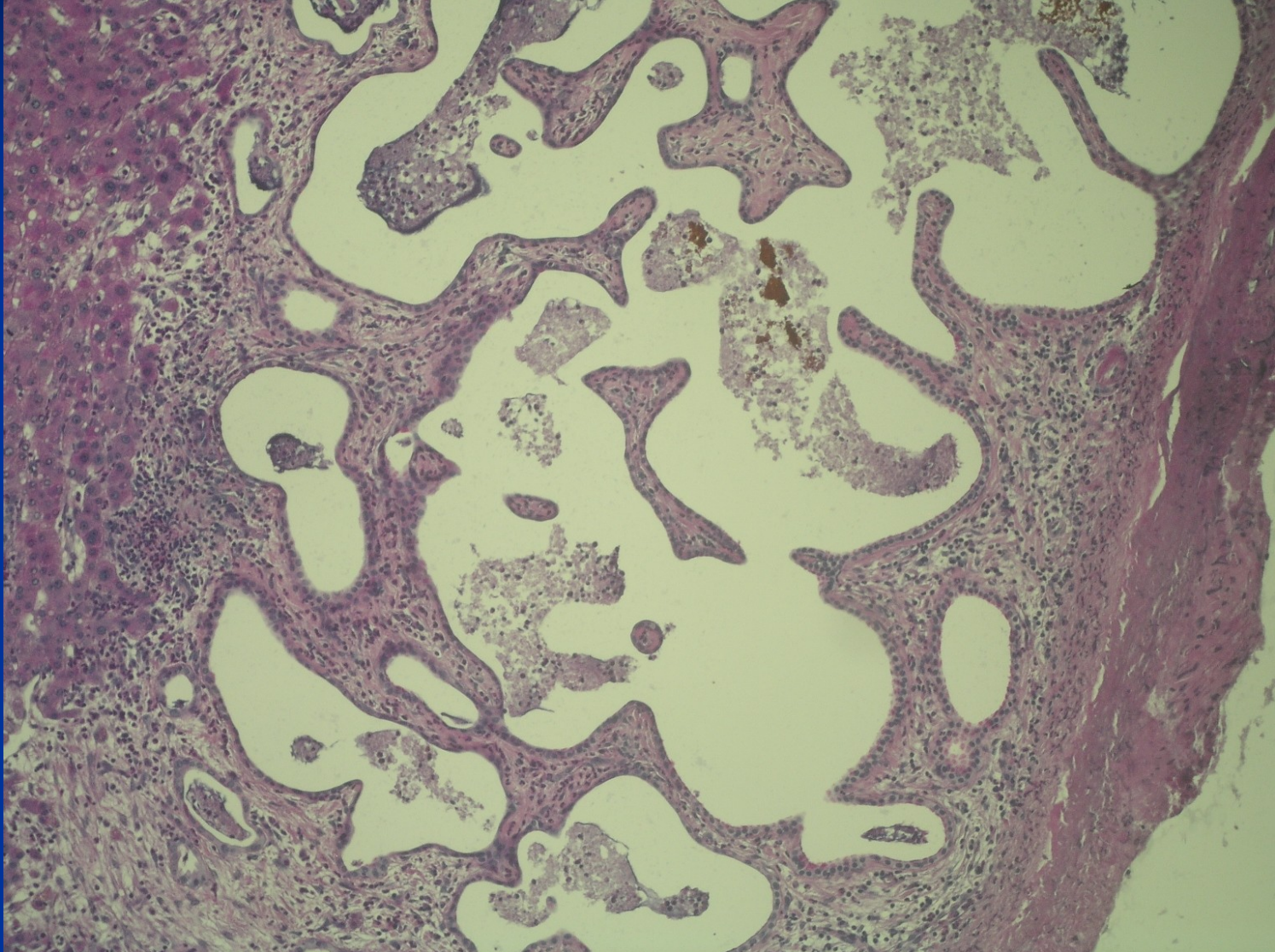
# Hydatid cyst – alveolar echinococcosis



# Biliary hamartoma

- Foci of dilated biliary ducts – cysts
- Subcapsular, commonly multiple
- Benign condition, abortive polycystic disease
- Diff. dg. x metastatic spread

# Biliary hamartoma



# Benign tumors

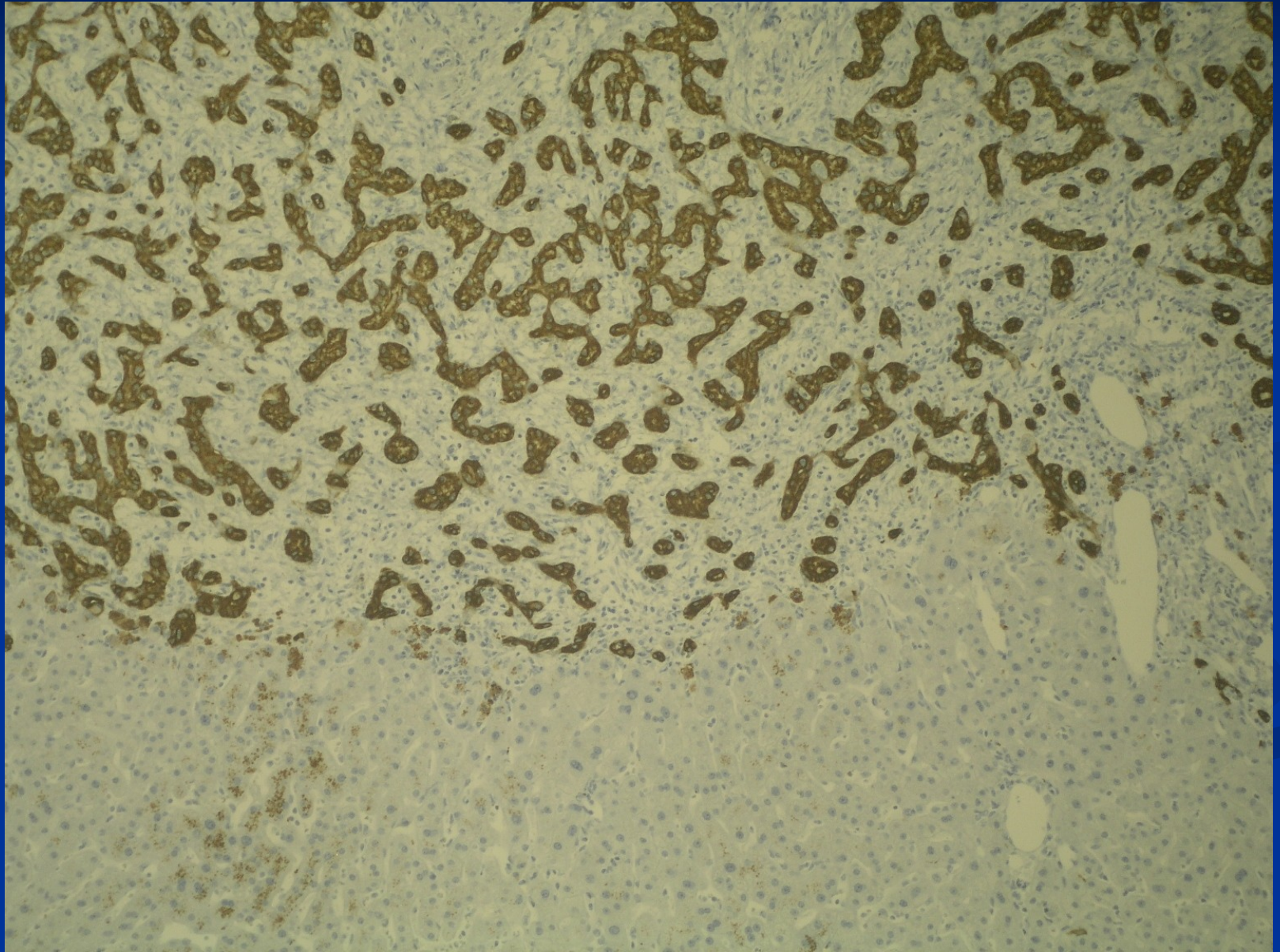
## Adenoma

- **hepatocellular** (lack of portal tracts, risk of bleeding/necrosis, different subtypes, some with ↑ risk of carcinoma) , dif. dg. x HCC, FNH; may be multiple
- **cholangiocellular** - biliary ( accumulation of regular ducts, lack of bile production, <1cm, subcapsular)
- **cystadenoma** (mucinous, rare)

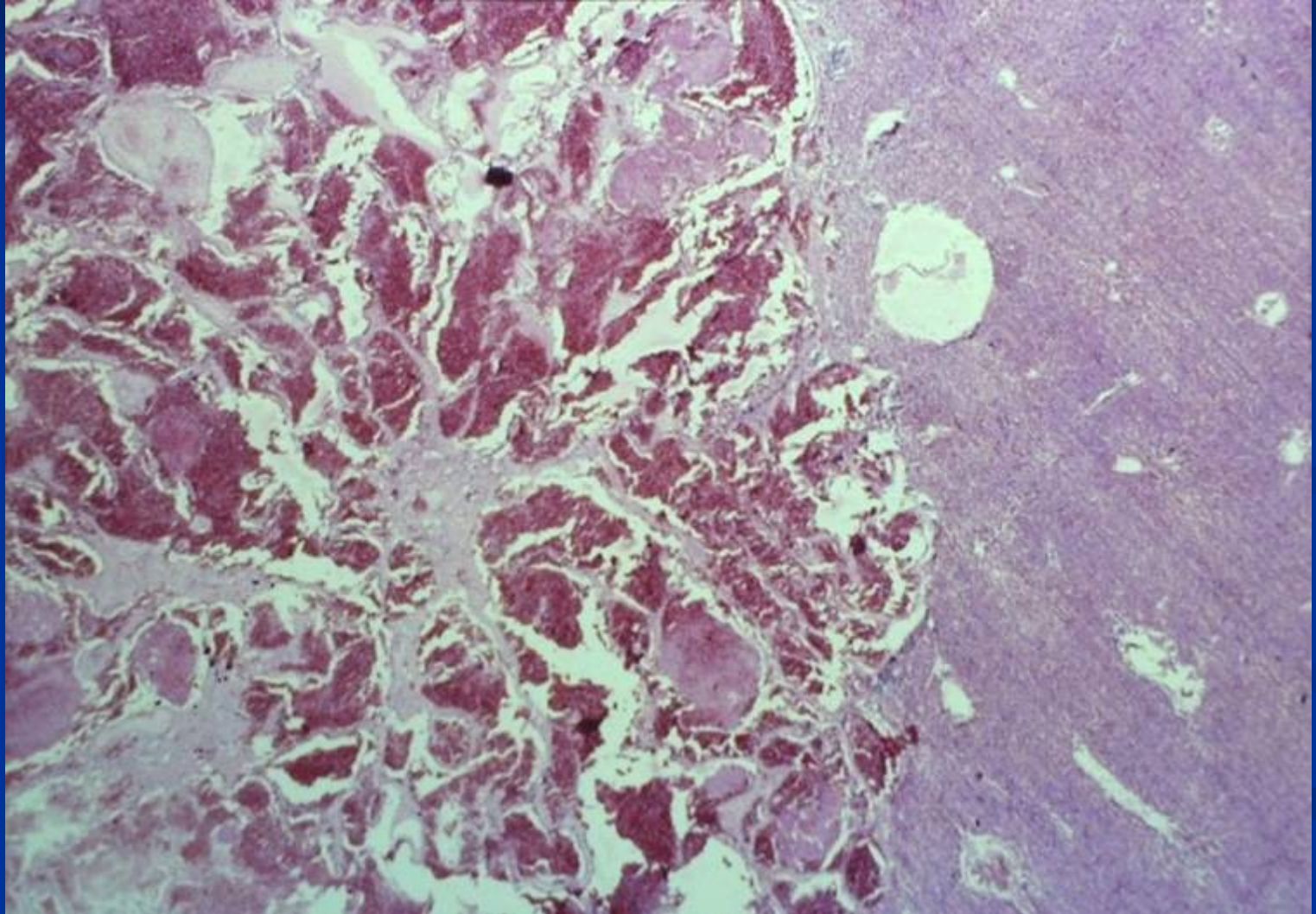
## Haemangioma

- **cavernous** (subcapsular, bleeding risk during puncture!)
  - size up to 15 cm,
  - regressive changes possible – alteration of usual picture on imaging

# Biliary adenoma



# Cavernous haemangioma



# Malignant tumors

## ■ Primary

- Hepatocellular carcinoma (majority)
- Cholangiocarcinoma (↑ incidence)
- Mixed hepato-cholangiocellular ca
- Hepatoblastoma – children
- Angiosarcoma – very rare



# Malignant tumors

## ■ Secondary

- Metastatic carcinomas – most common (GIT incl. pancreatic/biliary, lung, breast, kidney,...), other metastatic tumors (melanoma,...)
- Hemopoietic neoplasms – leukemia infiltrates, lymphomas

# Hepatocellular carcinoma

- Different incidence due to the cause

Lower in Europe, America, associated with cirrhosis, commonly alcoholic, NASH, HCV,

High in eastern Asia, HBV carrier since infancy = 200x risk, inactivation of p53;

High in Africa – aflatoxin

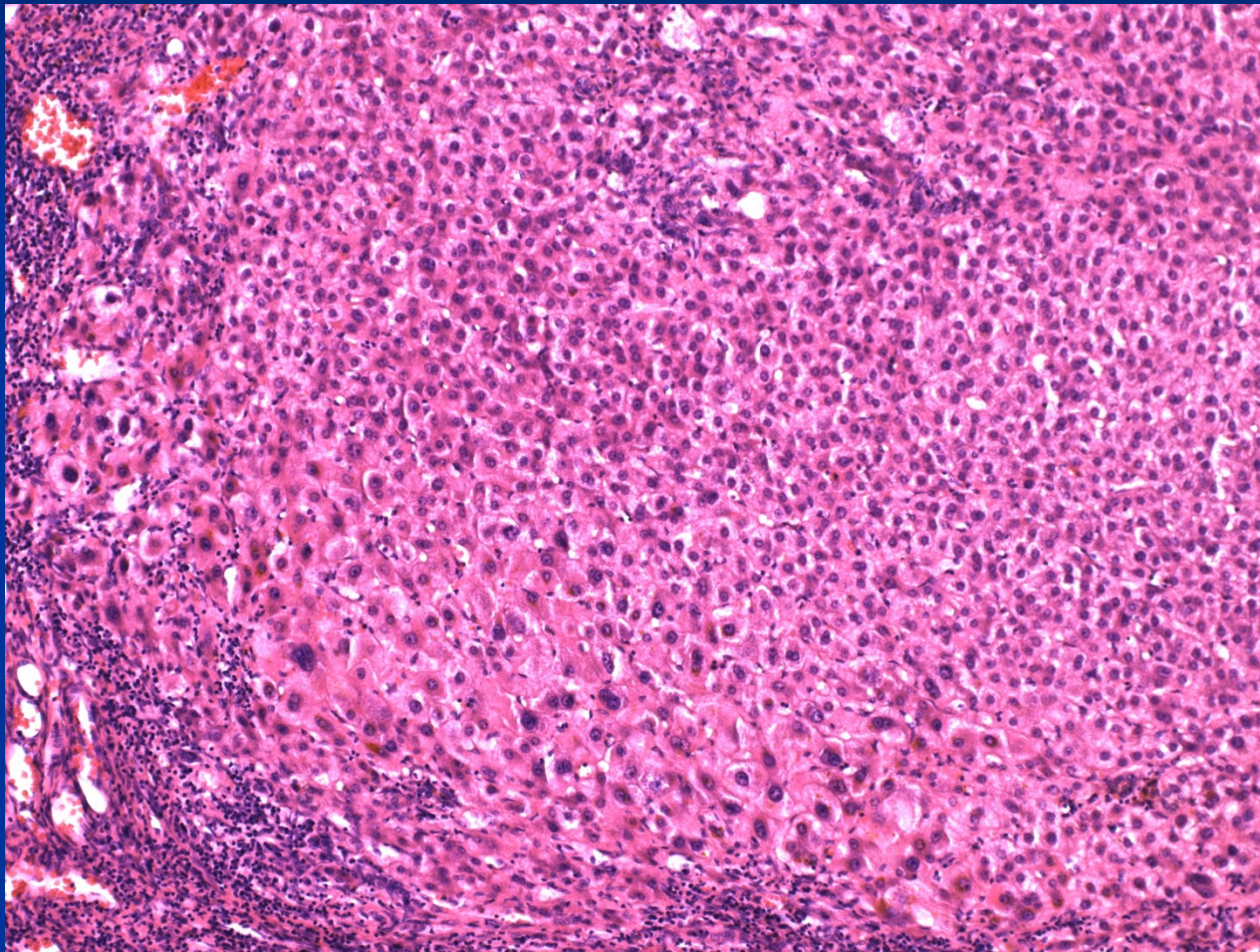
- Most of future HCC could be prevented

- HBV vaccination
- HCV treatment
- Life style (alcohol, NASH)
- Non-contaminated food

# Preneoplastic changes

- **Liver cell dysplasia** – low grade, high grade  
usually in cirrhosis, small foci or nodules, microcellular  
– smaller cells with less cytoplasm + bigger nuclei  
Diff. dg. x well diff. HCC

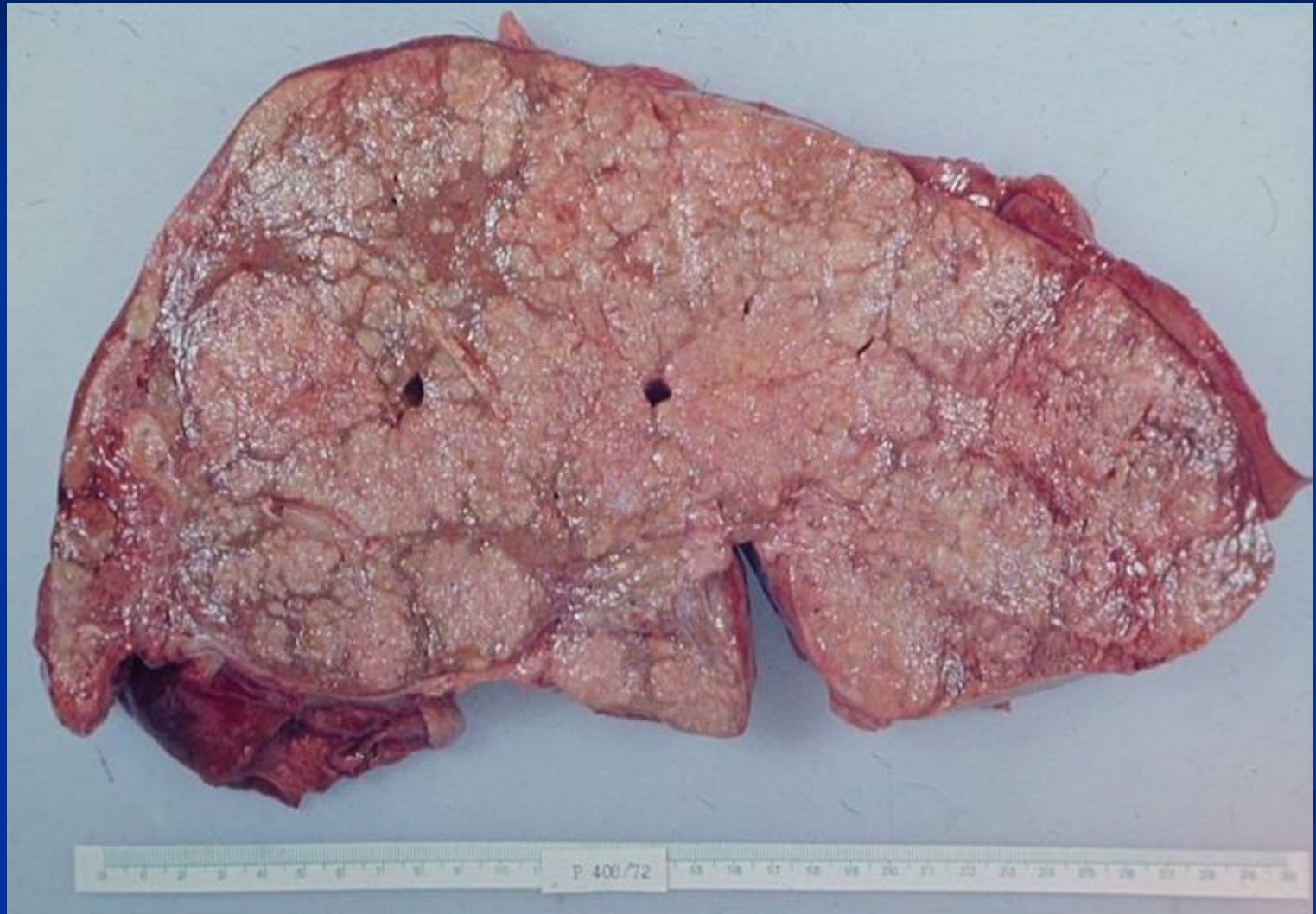
# Microcellular change/dysplasia



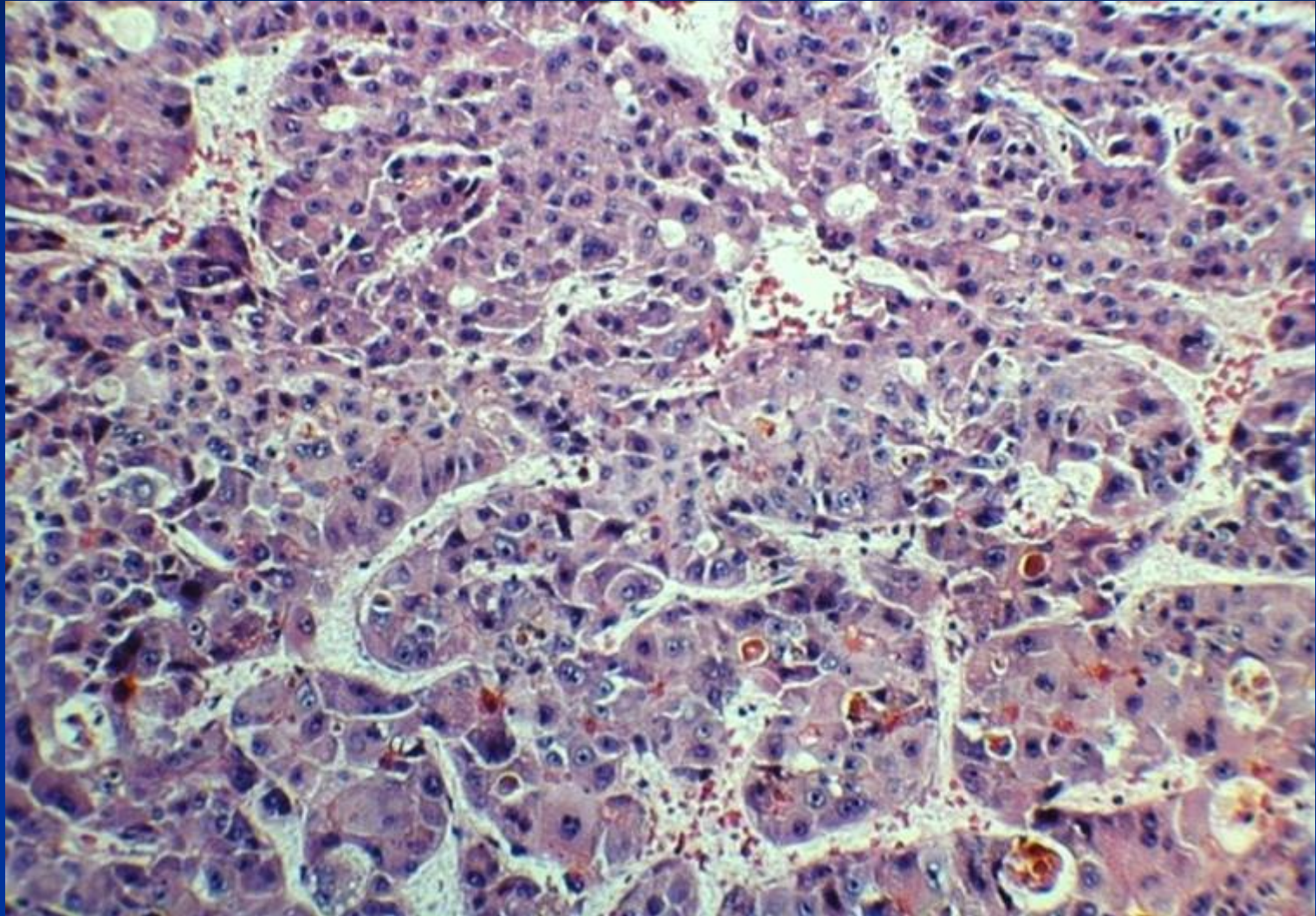
# Morphology of HCC

- **Clinical** hepatomegaly, right upper quadrant pain, weight loss
- Unifocal, multifocal, or infiltrative growth
- Strong propensity for vascular invasion
- Well-differentiated – intracellular bile
- Trabecular, acinar, pseudoglandular, solid
- Usually scant stroma → soft
- Metastasizes to LN, lung, bone, adrenals, ...
- Commonly serologic increase of AFP

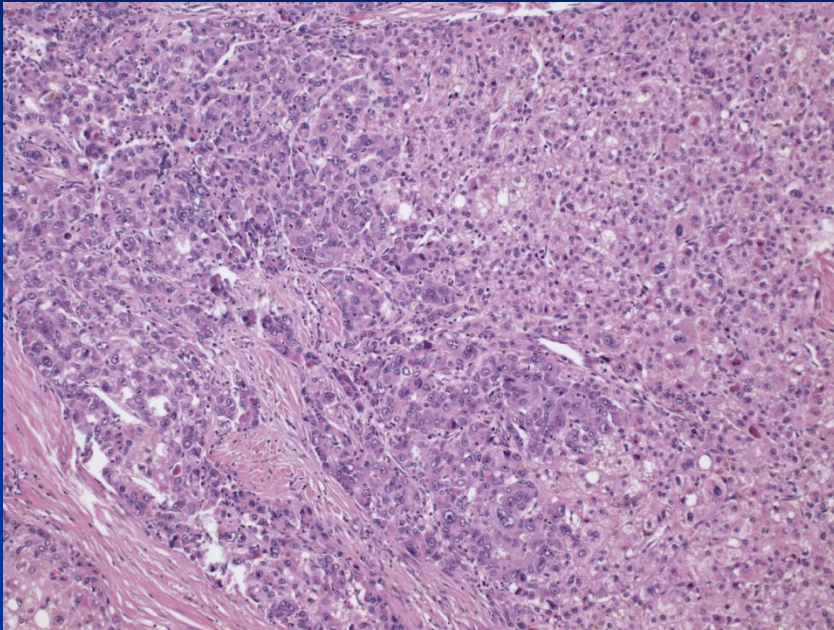
# HCC



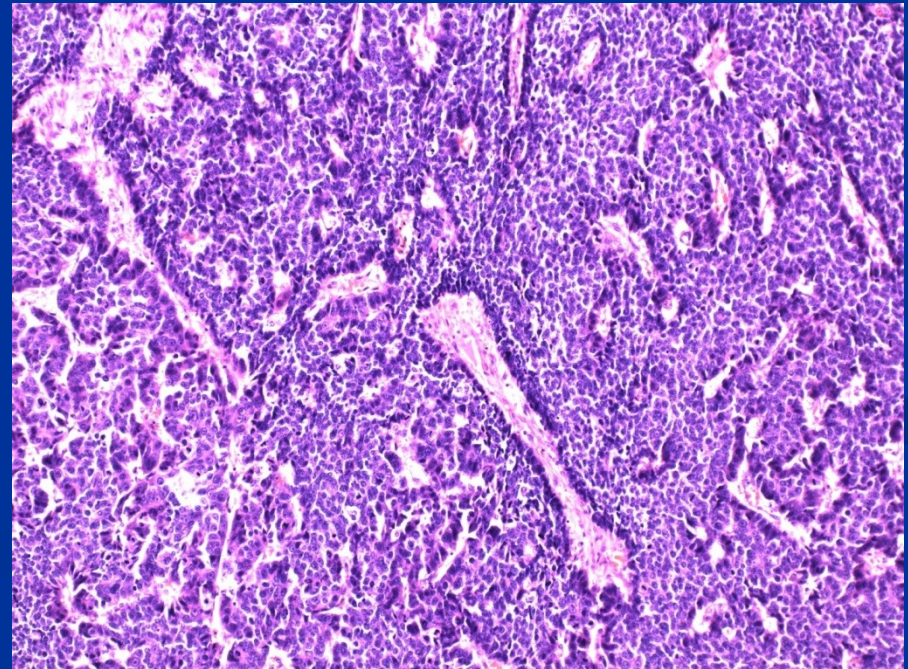
## HCC – bile production by tumor cells



# HCC – variable morphology

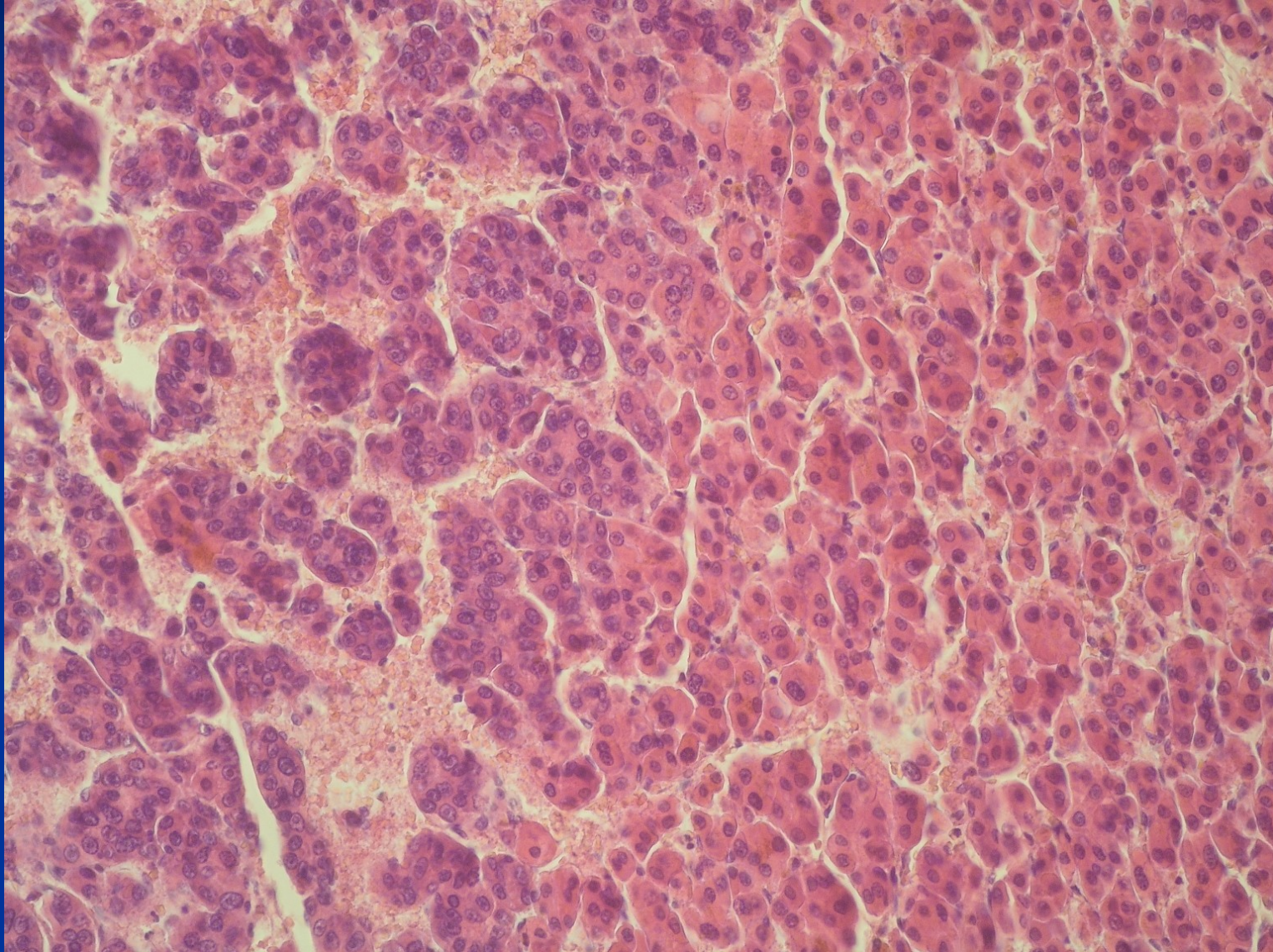


One patient, the same  
tumor

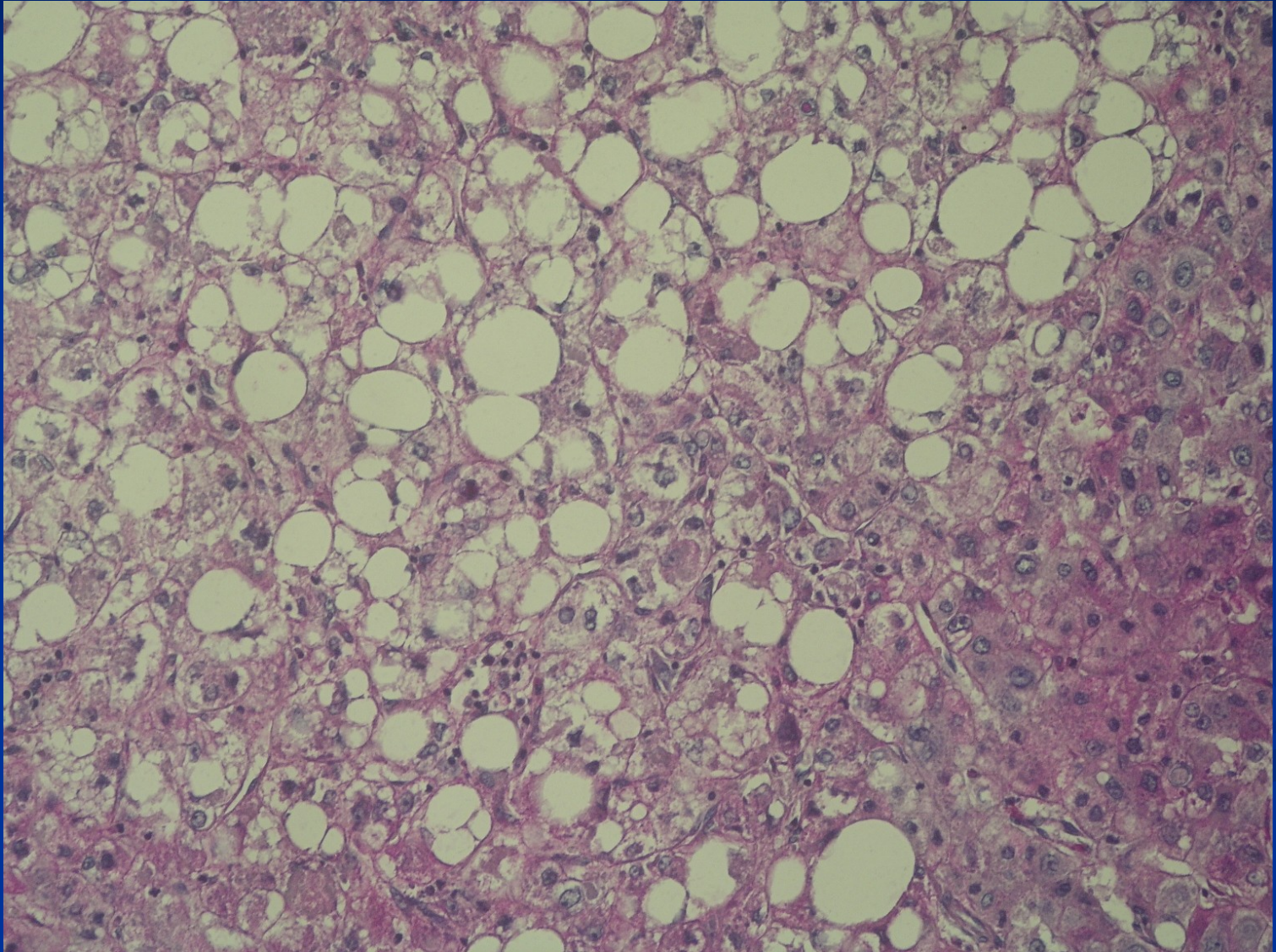




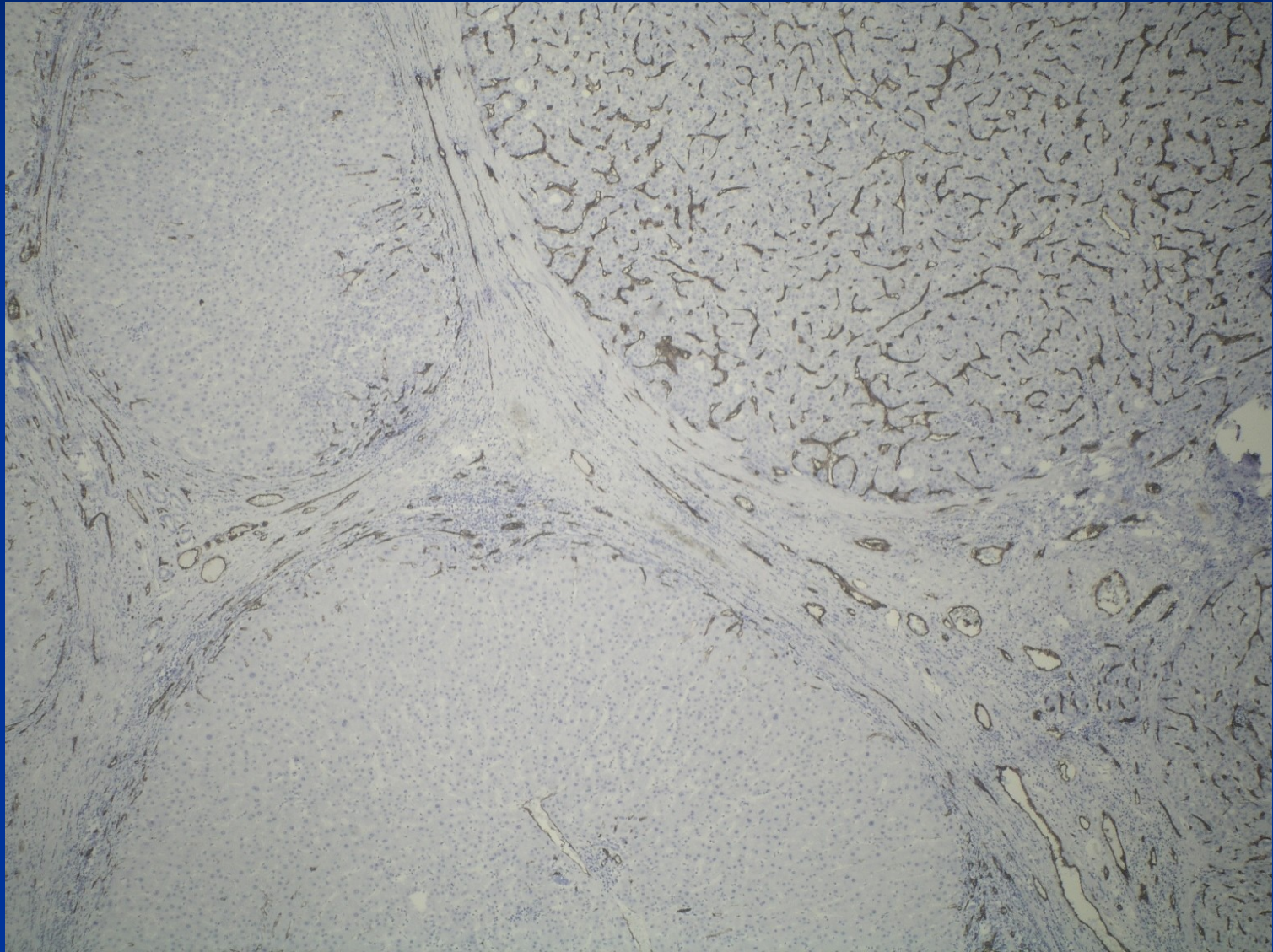
# HCC – variable morphology



# HCC – variable morphology



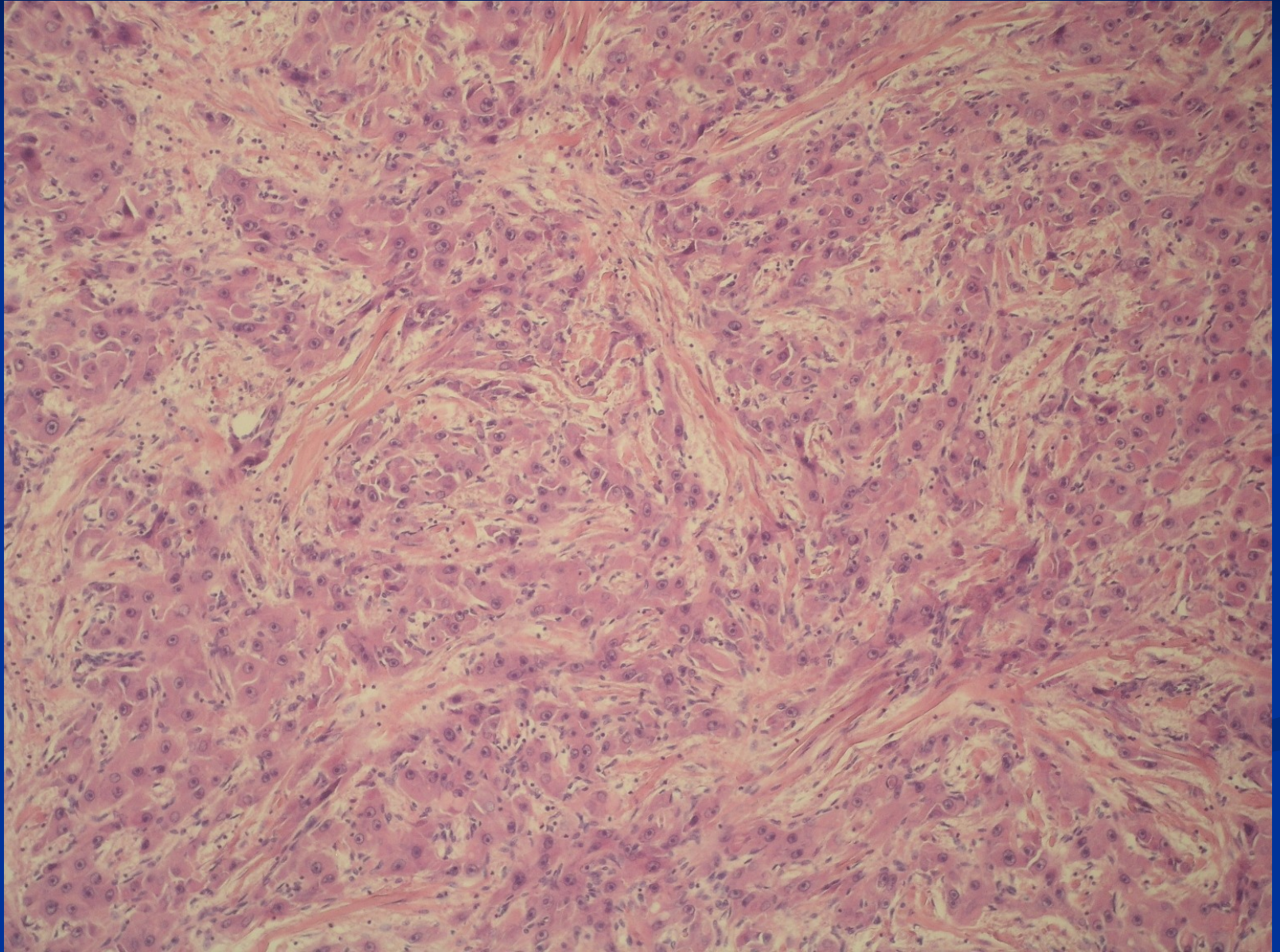
# HCC – CD34+ capillaries



# Fibrolamellar carcinoma

- 20-40 yrs, M=F
- Uncommon
- No assoc. with cirrhosis or other risk factors
- Single, resectable, 5 year survival = 60%,
- PAS + inclusions (hyaline globules)
- Tumor cells separated by dense parallel collagen strands
- Better prognosis

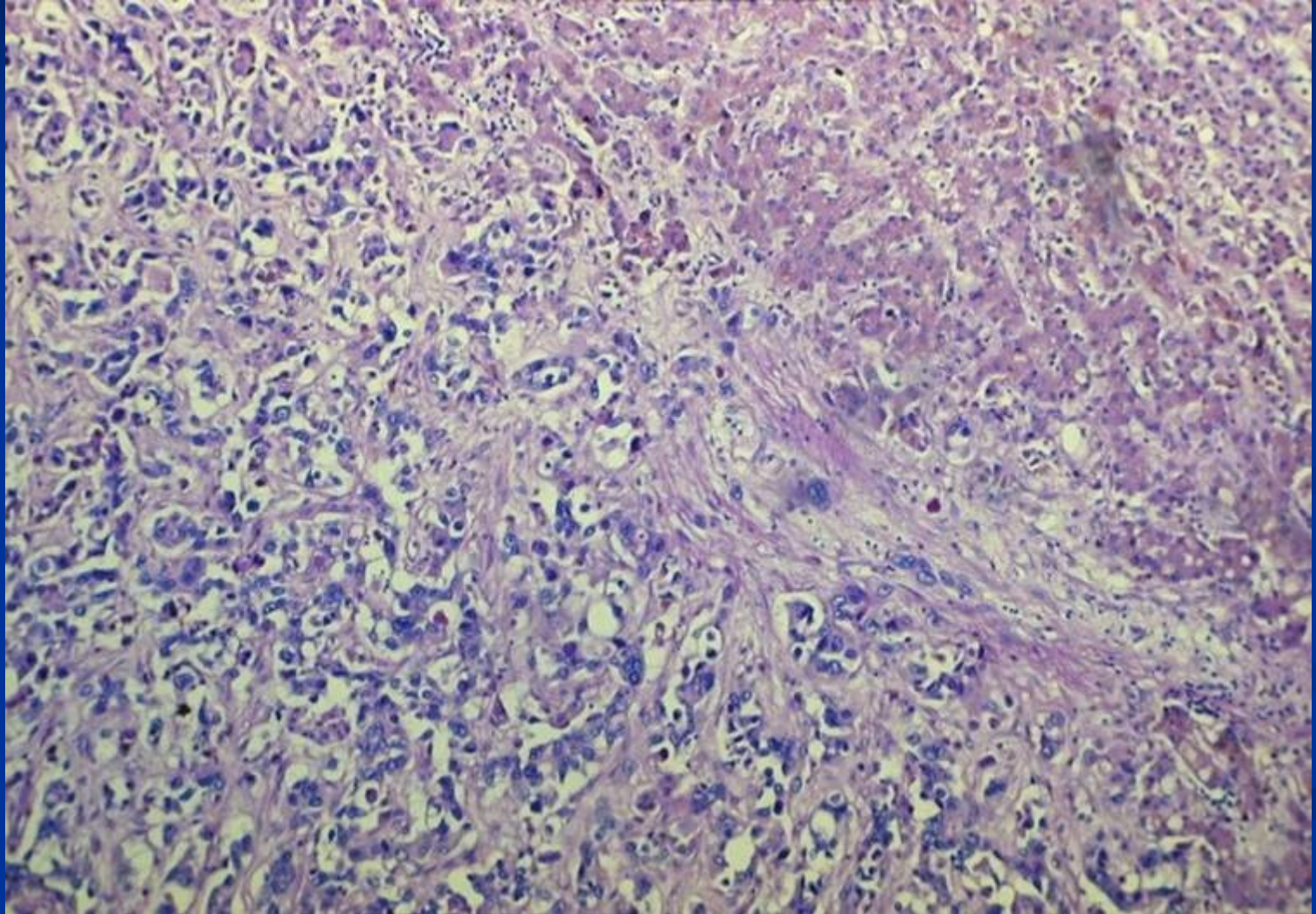
# Fibrolamellar carcinoma



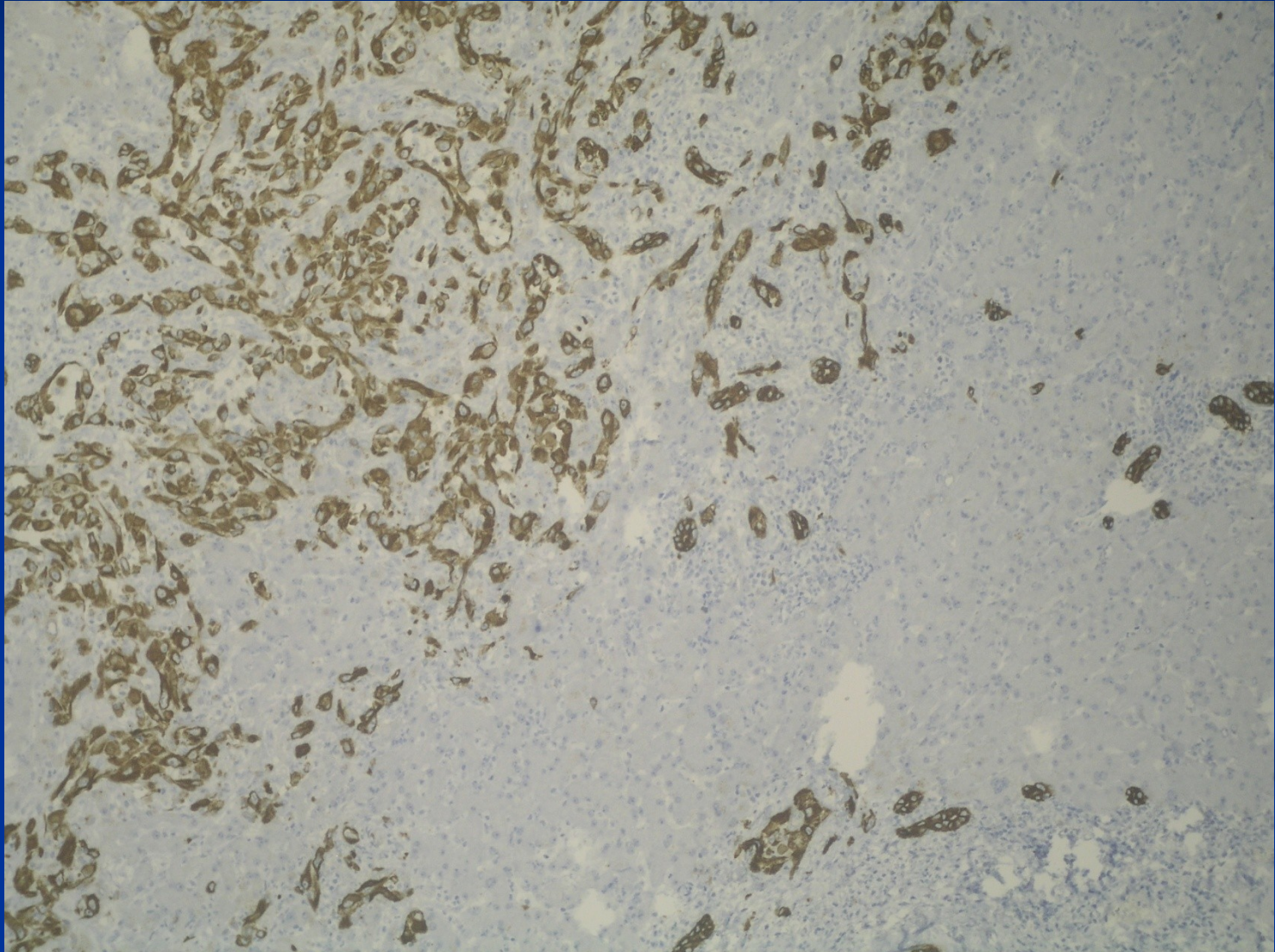
# Cholangiocarcinoma

- From intrahepatic biliary ducts
- ↑ risk in PSC, HCV cirrhosis, some parasitic infections (Clonorchis), polycystic disease
- mucin secretion, mostly no bilirubin pigment
- irregular ducts, strands of cells
- commonly dense or myxoid stroma
- diff. dg. x metastatic or direct spread – gallbladder, pancreas, colorectal ca
- mostly bad prognosis

# Cholangiocellular carcinoma



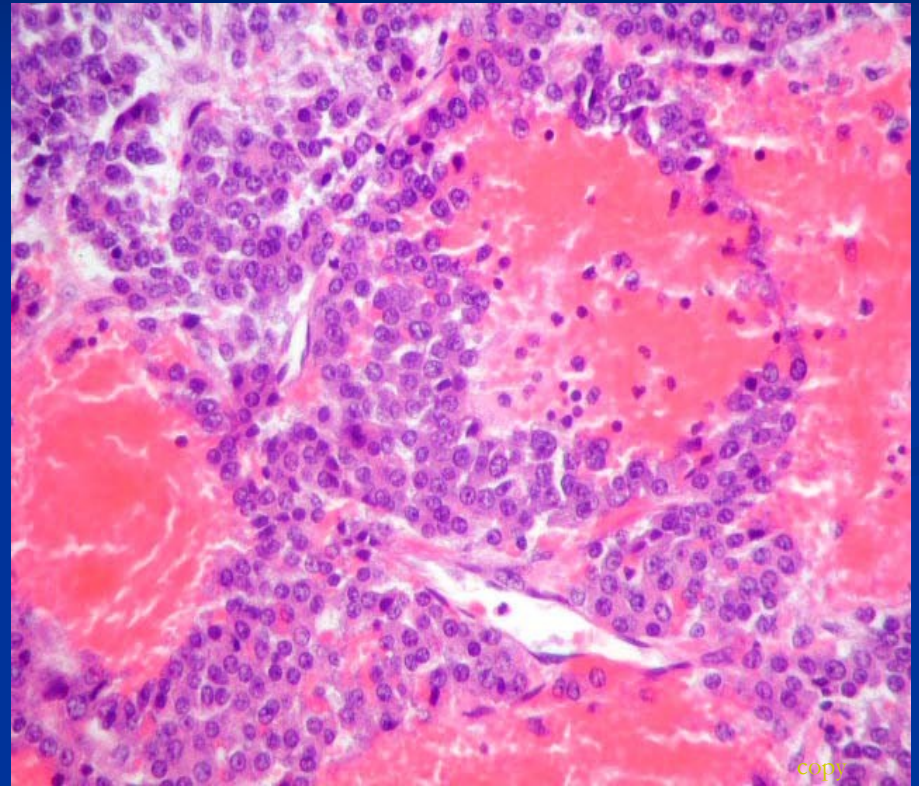
# Cholangiocellular carcinoma IHC CK7





# Hepatoblastoma

- from primitive – stem cells
- resembles embryonal/fetal liver
- heterogenous elements (cartilage, bone, muscle, ...)
- infants, children



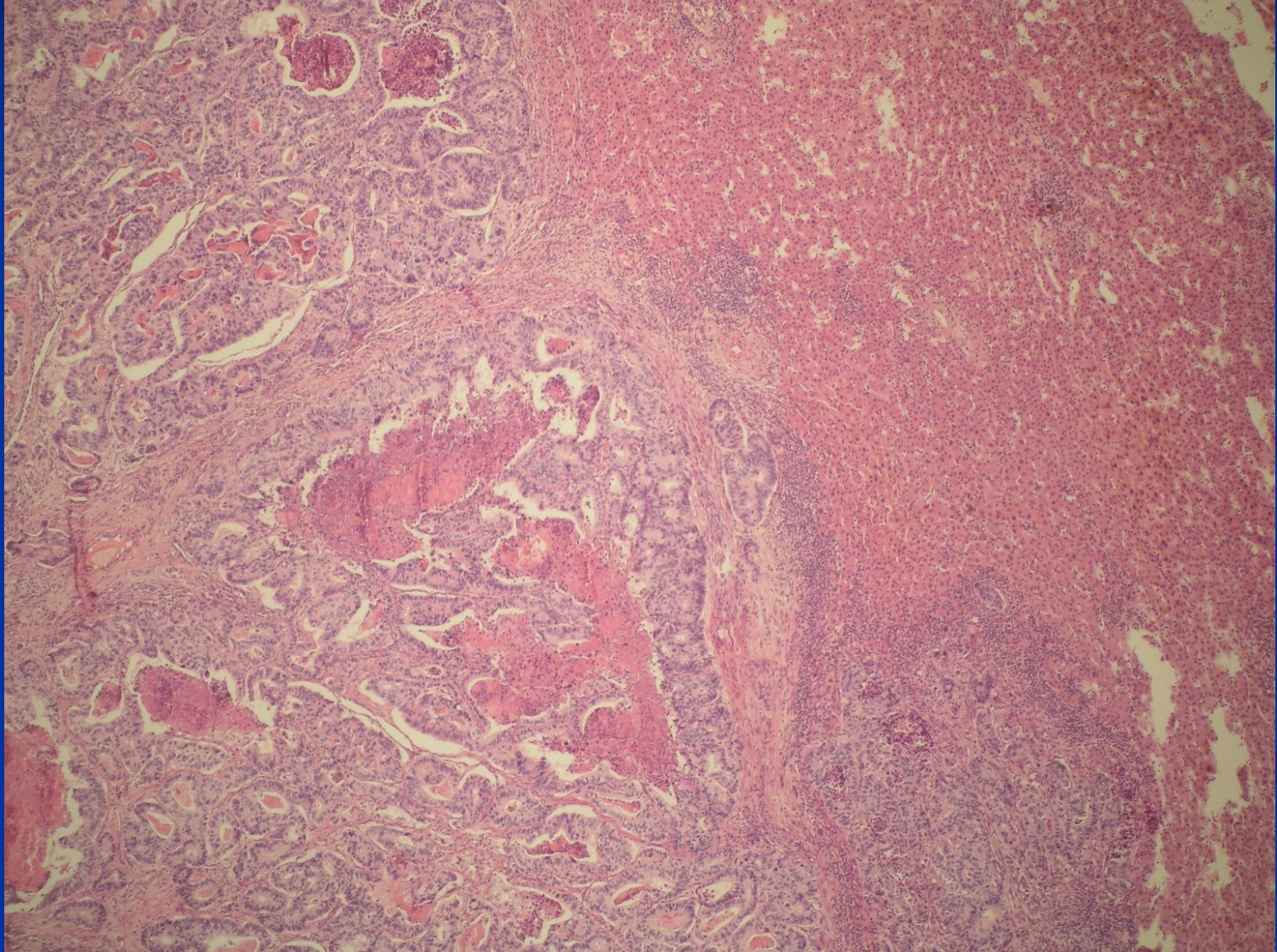
# Malignant vascular tumors

- **Angiosarcoma** – highly malignant, very rare, but most common liver sarcoma, associated with professional risk (vinylchloride in plastic industry), thorocontrast exposure
- **Epithelioid hemangioendothelioma** – less malignant, transplantation event. possible

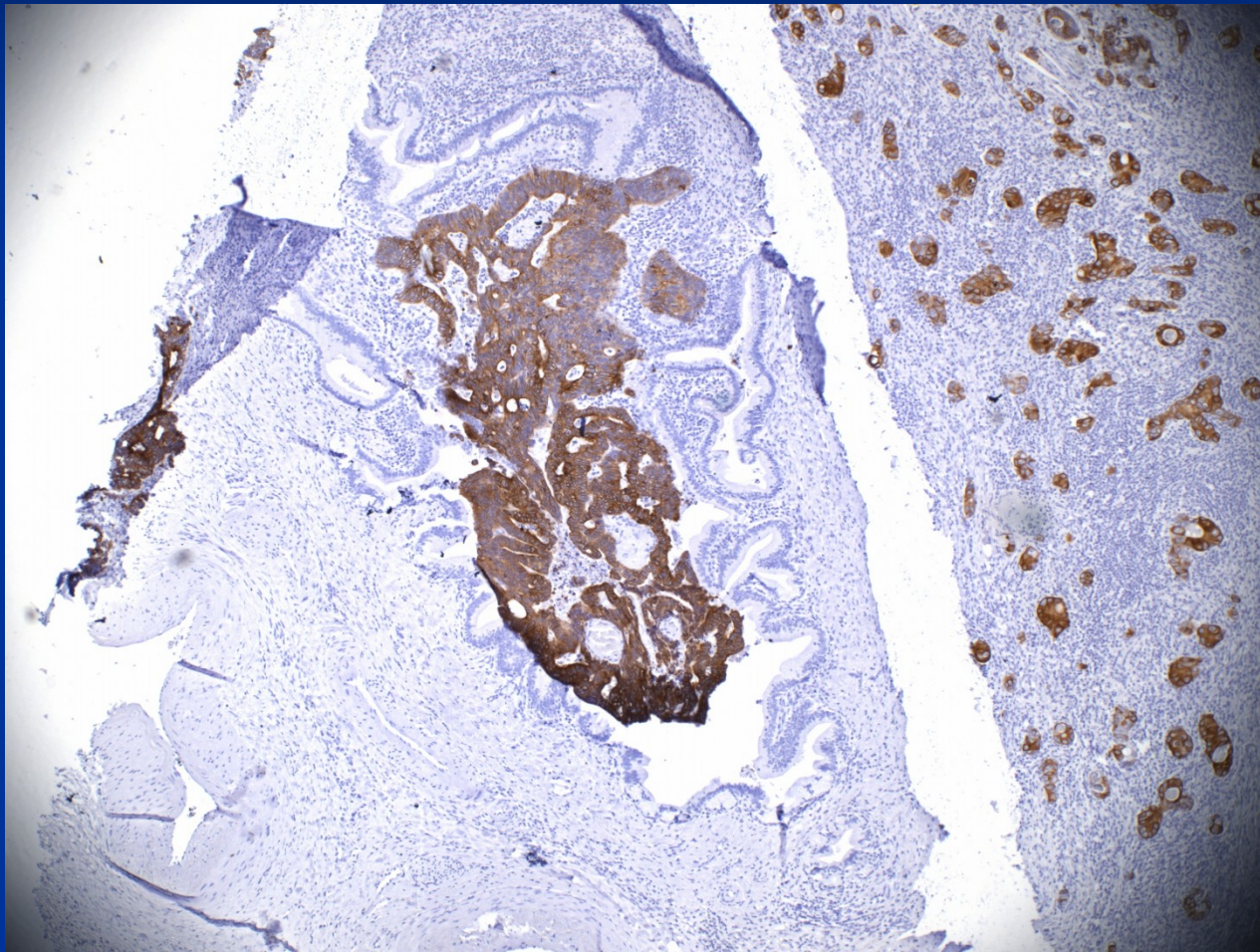
# Secondary tumors

- more common than primary
- usually multiple
- treatment by surgical excision, thermal ablation, alcohol injection; chemotherapy in lymphomas/leukemias

# Colorectal ca metastasis

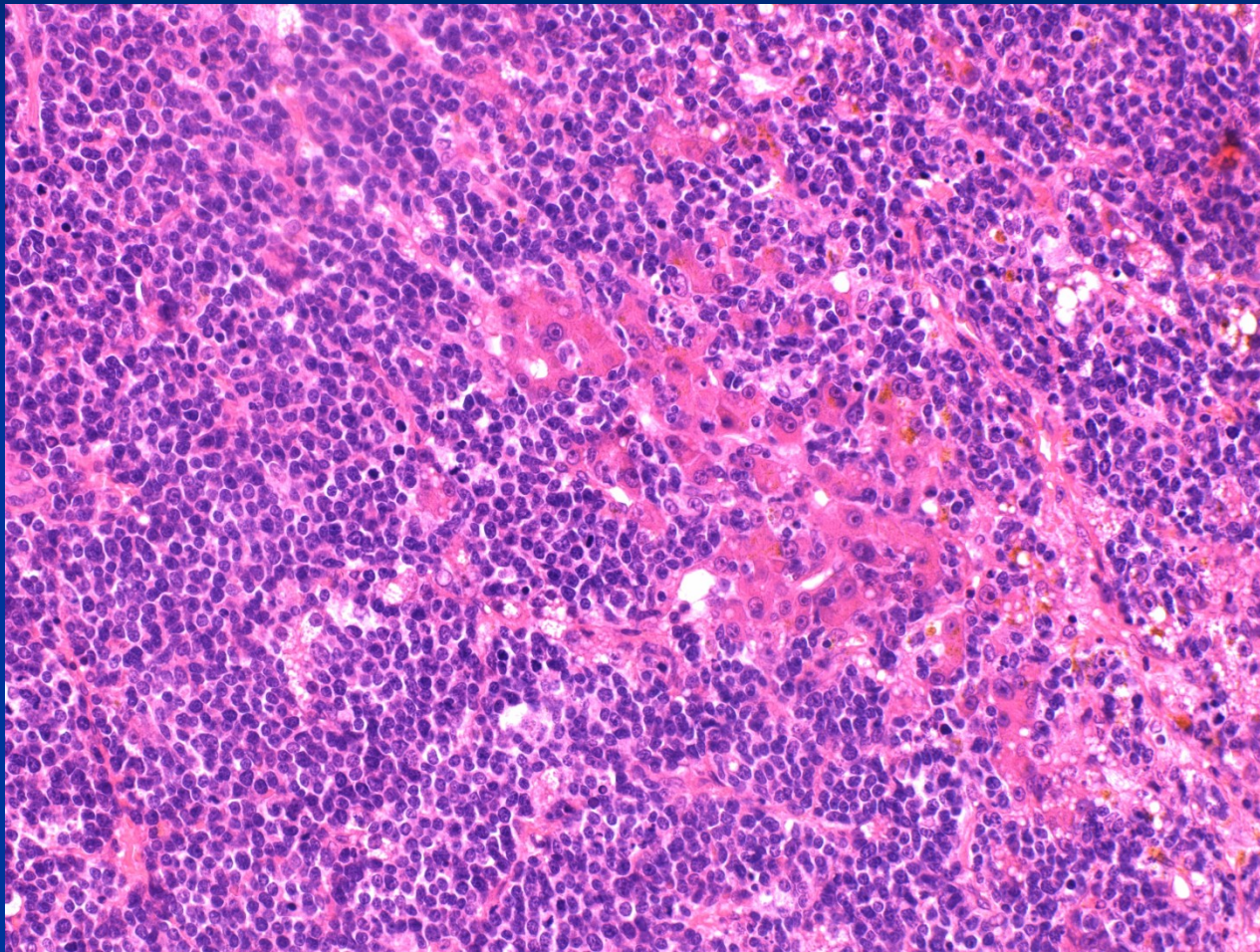


# Colorectal ca metastasis

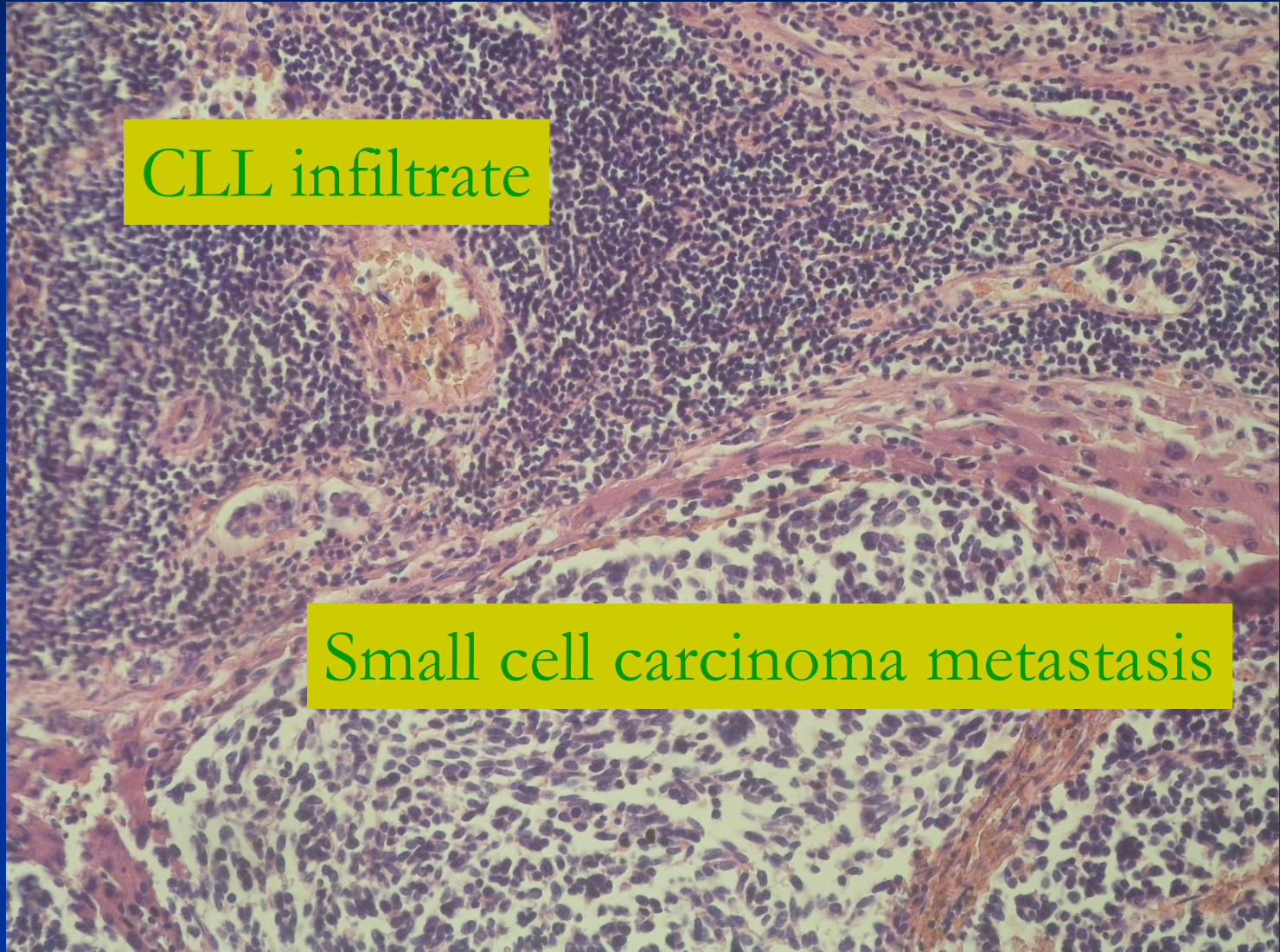


IHC CK20+ tumor in a CK20 neg. biliary duct

# HG malignant lymphoma in liver



# Two secondary liver neoplasias

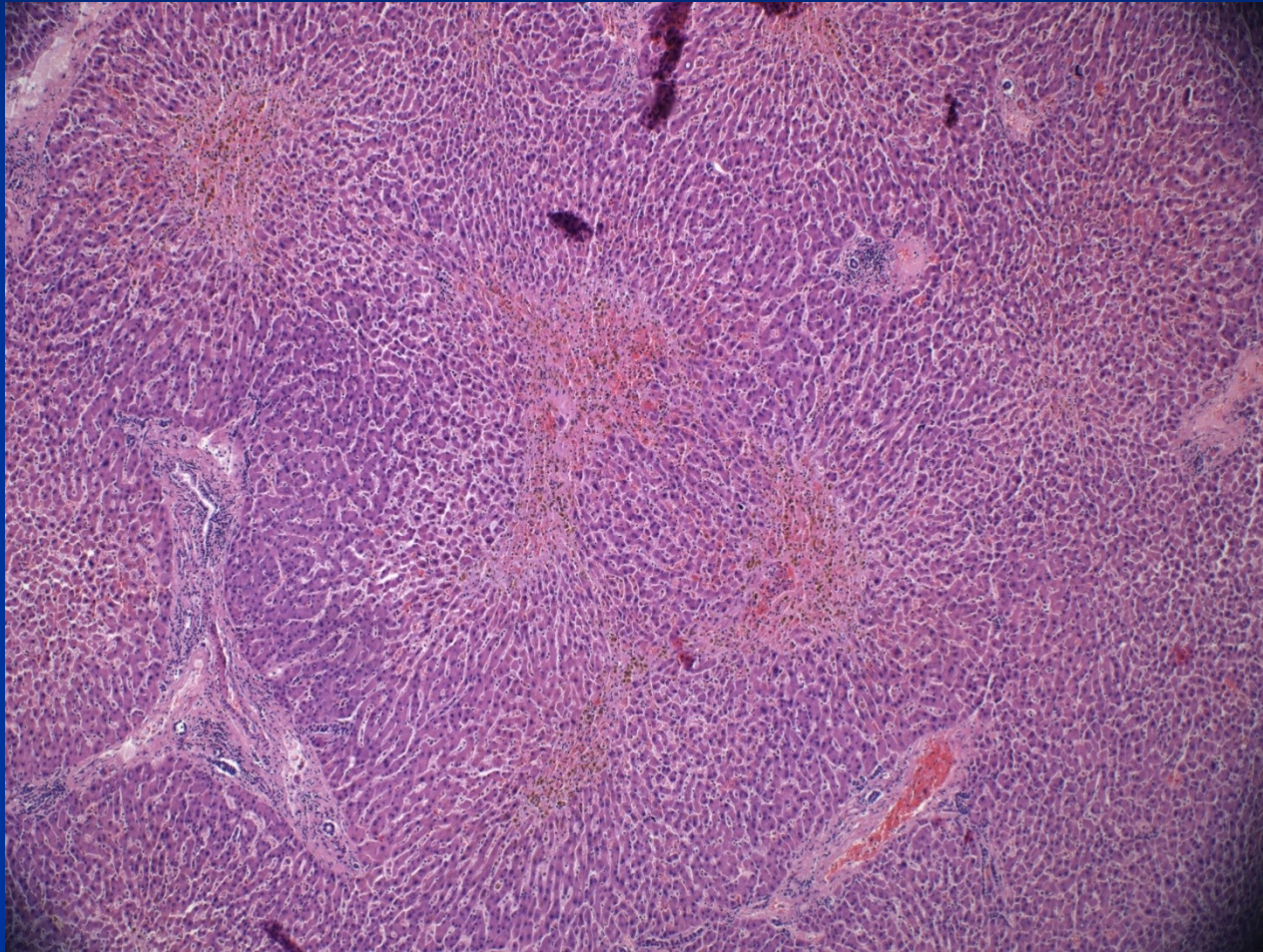


# Liver involvement in systemic disease

- Liver affected by diseases of single organs in the vicinity
  - pancreas, bile ducts – obstruction
  - heart - congestion,
  - lungs - hypoxemia,
  - systemic metabolic diseases (DM, amyloidosis)
  - systemic infections incl. sepsis
- extramedullary hematopoiesis
- acute fatty liver of pregnancy



# Central necrosis in heart failure



# Liver and transplantation

## Indication for transplantation

- inborn defects (biliary atresia)
- irreversible stages of chronic liver diseases - hepatitis, PBC, PSC
- acute liver failure (toxic, vascular, trauma)
- some tumors (small/solitary HCC; EHE, large complicated hemangiomas); some focal lesions – FNH, parasitic cysts, ...



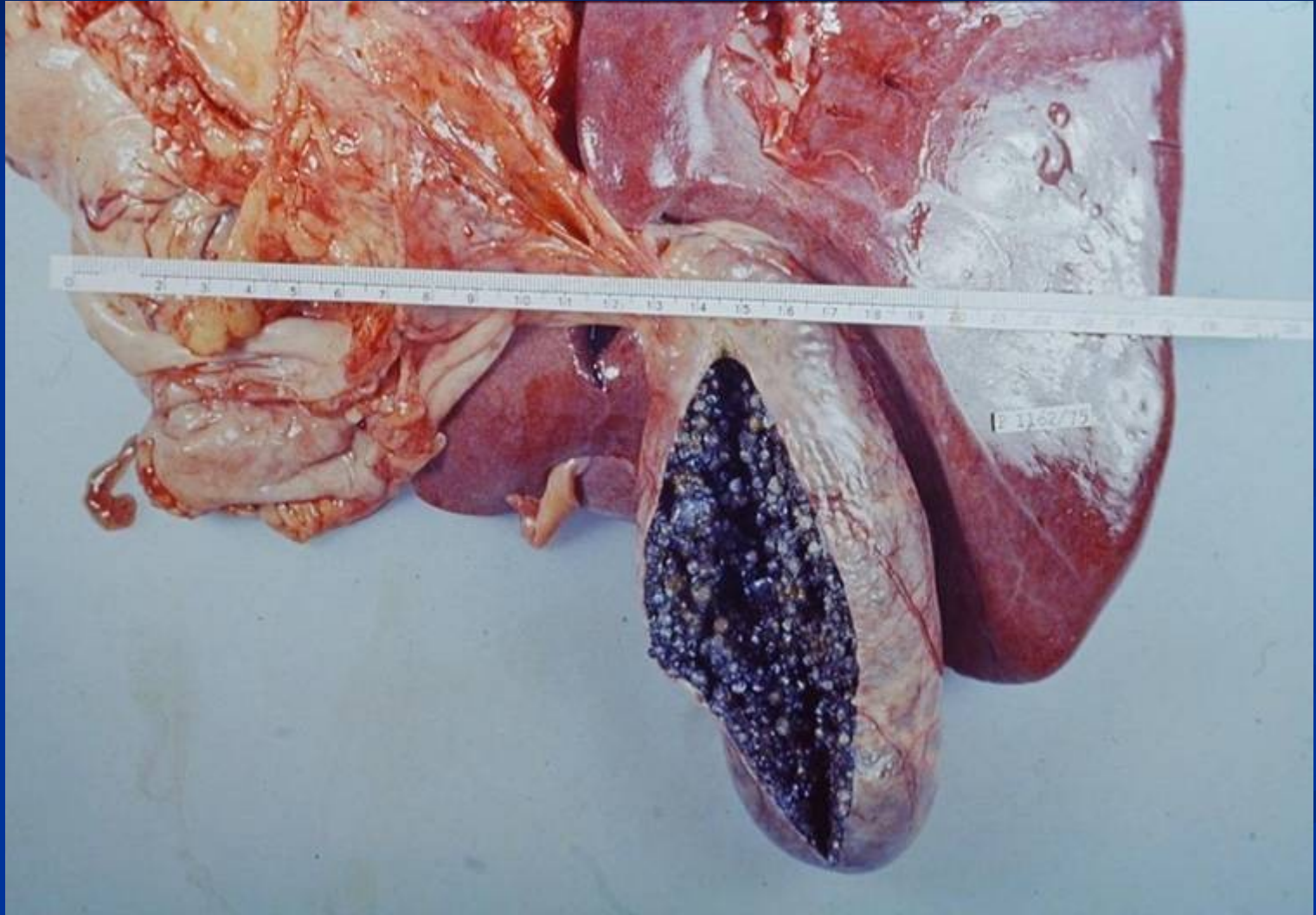
# Cholelithiasis

- Very common
- Cholesterol stones
  - Bile is supersaturated with cholesterol
  - Gallbladder stasis
  - F>M
  - Obesity
  - Advancing age
- Pigment stones – calcium bilirubinate salts
  - Asian more than Western
  - Chronic hemolytic syndromes

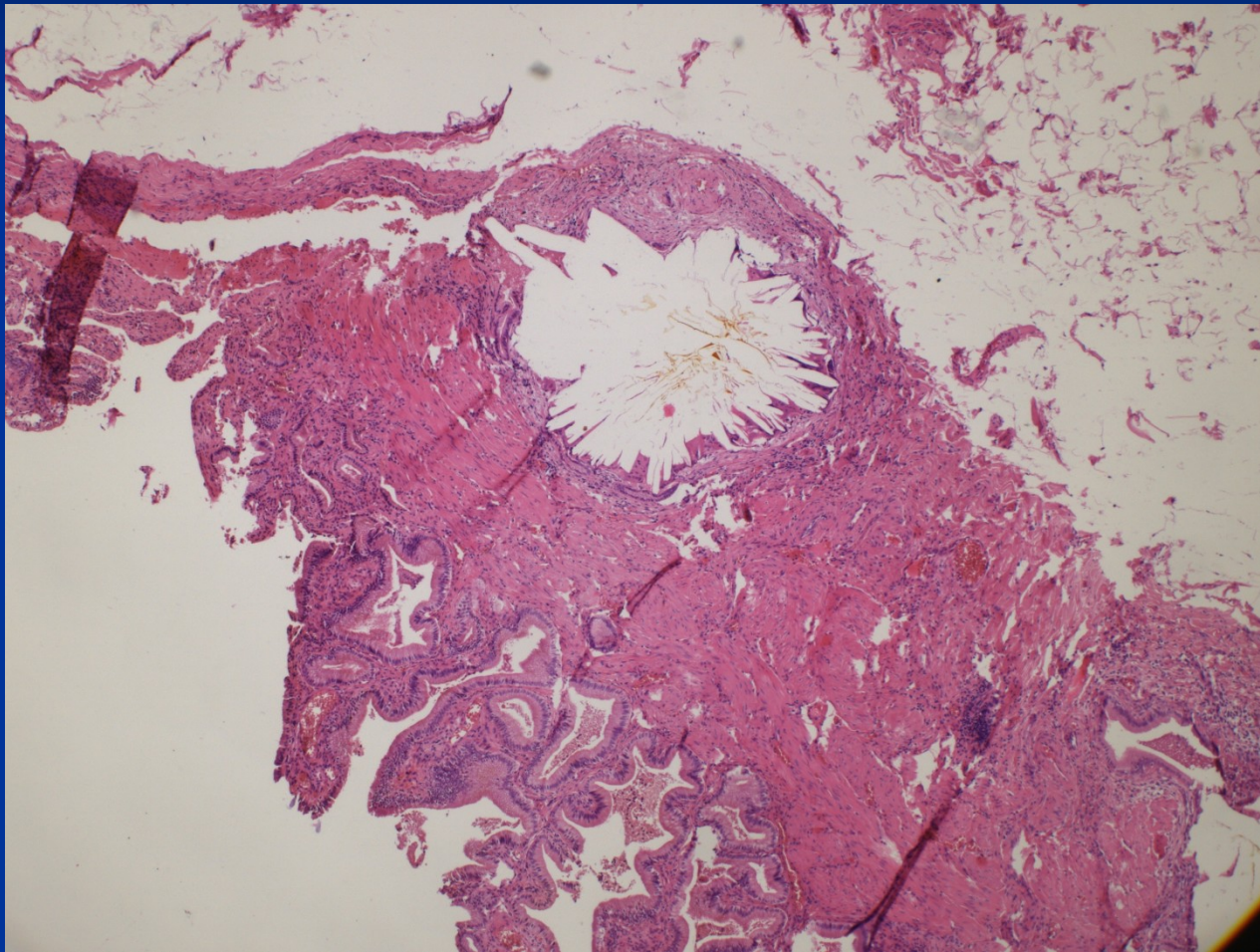
# Clinical features

- *Asymptomatic*
- *Biliary colic*
- *Cholecystitis*
- *Perforation, fistula*
- *Gallstone ileus*

# Cholecystolithiasis



# Intramural cholesterol stone



# Cholecystitis

## ■ Acute calculous

- Obstruction of GB neck or cystic duct
- Local pain radiating to right shoulder
- Fever, nausea, leukocytosis
- Potential surgical emergency

Empyema of the gallbladder

Gangrenous cholecystitis



# Cholecystitis

- **Acute acalculous** – seriously ill patients (postoperative, trauma, burns, sepsis,...)
- **Chronic**
  - Recurrent attacks of pain
  - Nausea and vomiting
  - Associated with fatty meals

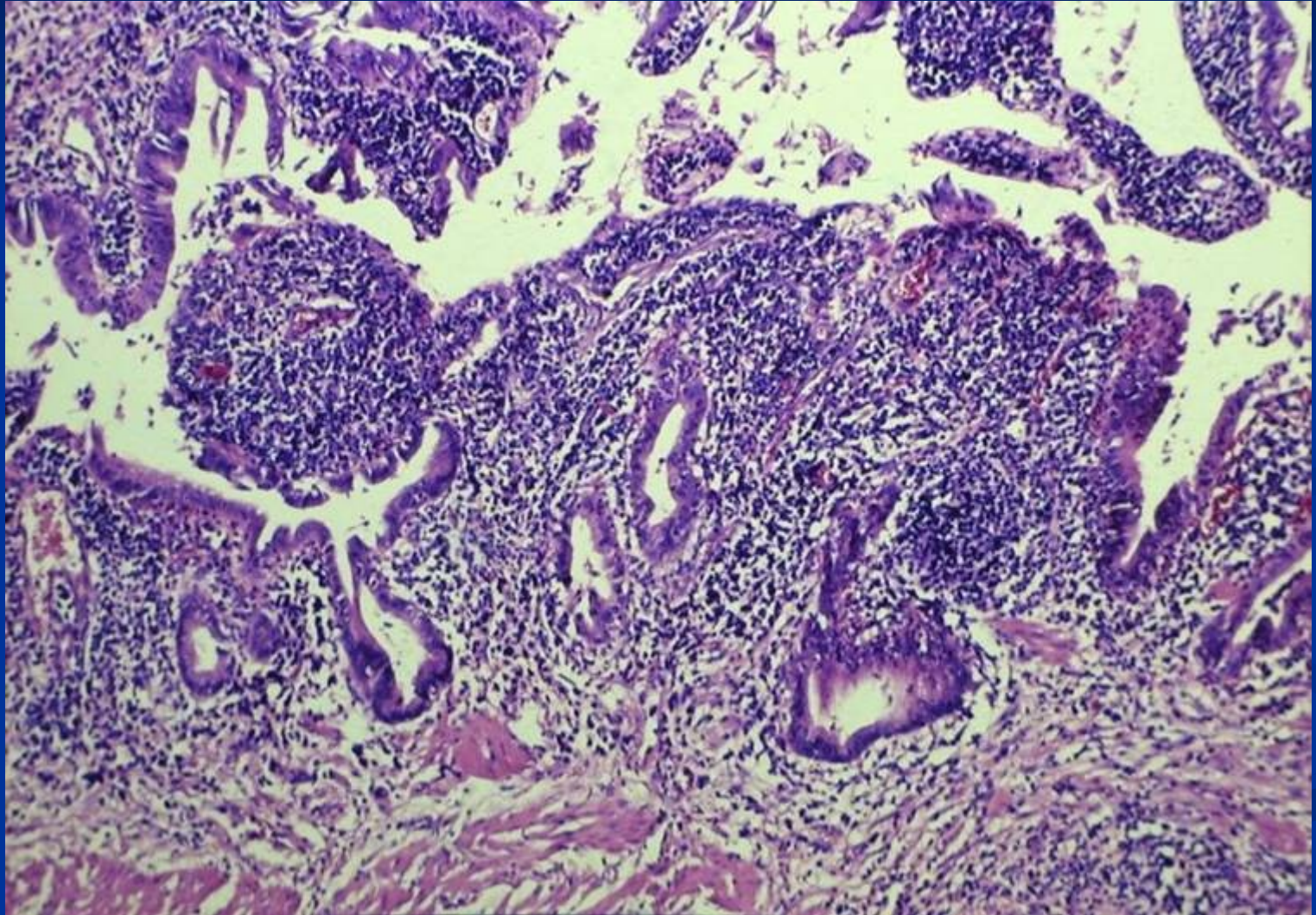
Fibroproduction (thickening of the wall, adhesions)

Chronic inflammation (risk of carcinoma development)

Dystrophic calcification

Hydrops

## Active chronic cholecystitis



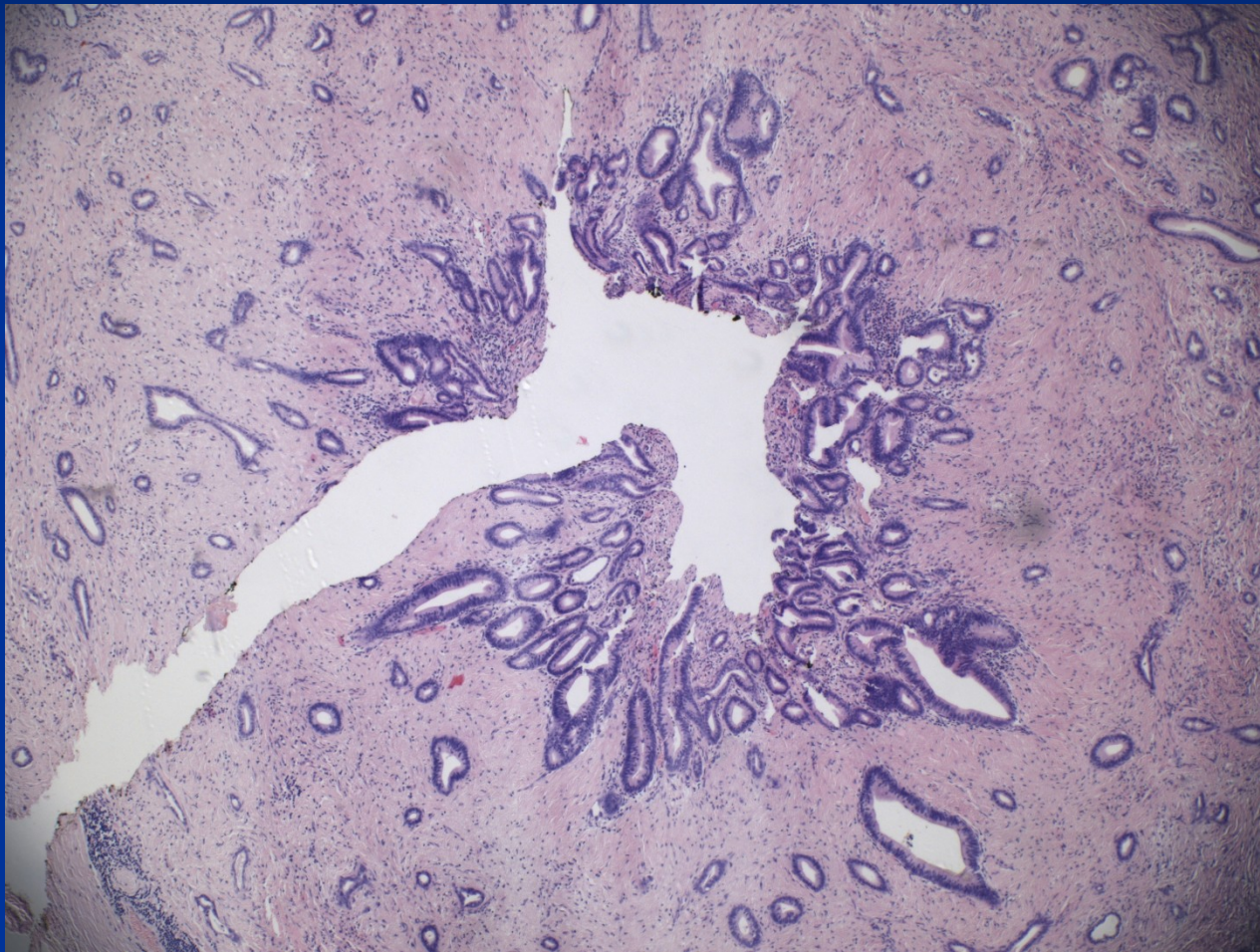
# Choledocholithiasis

- Stones within the biliary tree
- West – from gallbladder
- Asia – primary ductal and intrahepatic stone formation
- Symptoms due to:
  - Biliary obstruction
  - Pancreatitis
  - Cholangitis
  - Hepatic abscess

# Biliary intraepithelial neoplasia

- Precursor lesions for carcinoma
- Variable grade of cellular and architectural atypia
- BilIN 1 low grade, BilIN 2 intermediate grade
- BilIN 3 high grade, commonly already associated with invasive carcinoma
- Not visible by imaging methods
- Incidental finding in biopsy/cholecystectomy

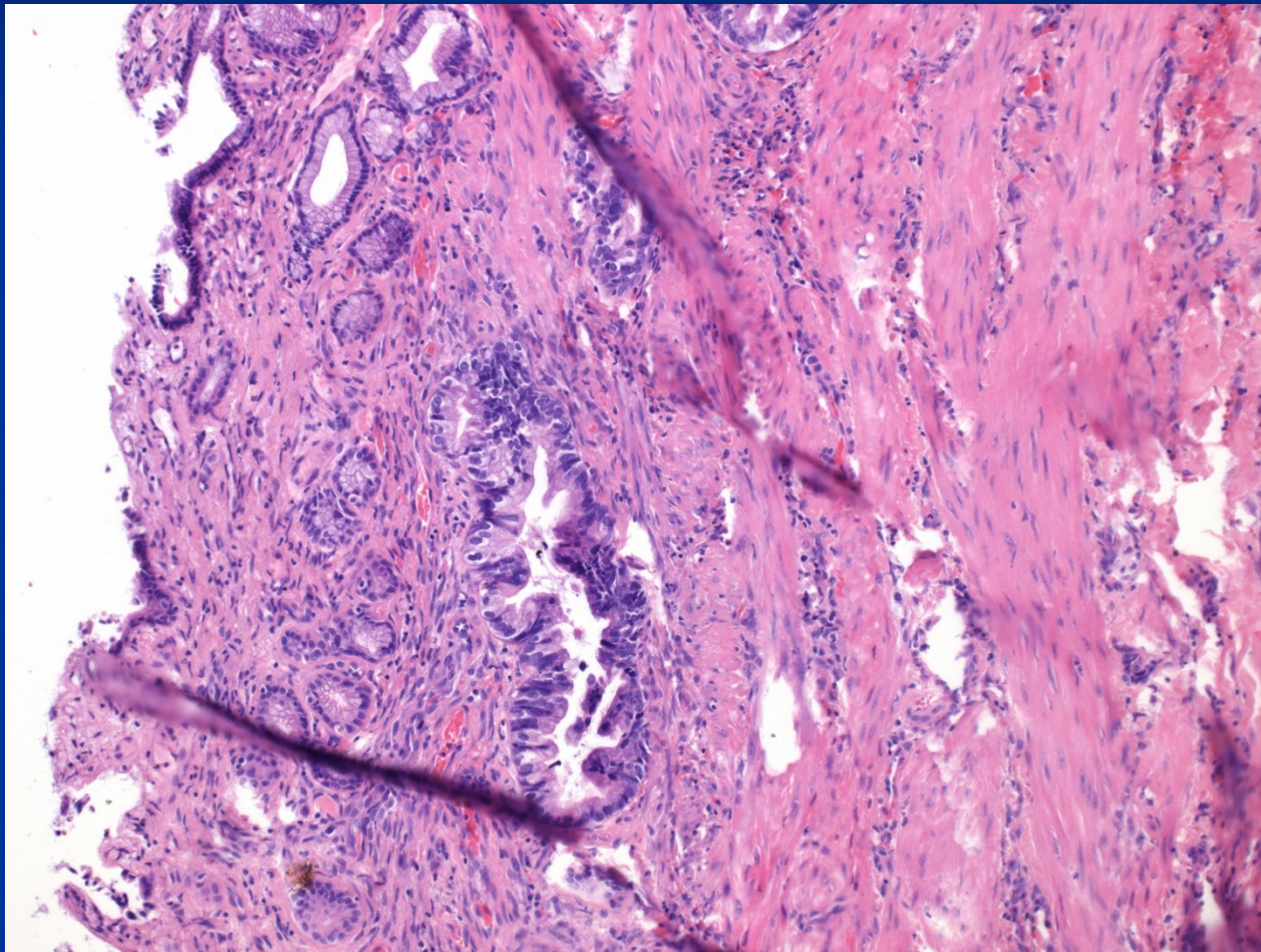
# BiIN 3 + invasive carcinoma



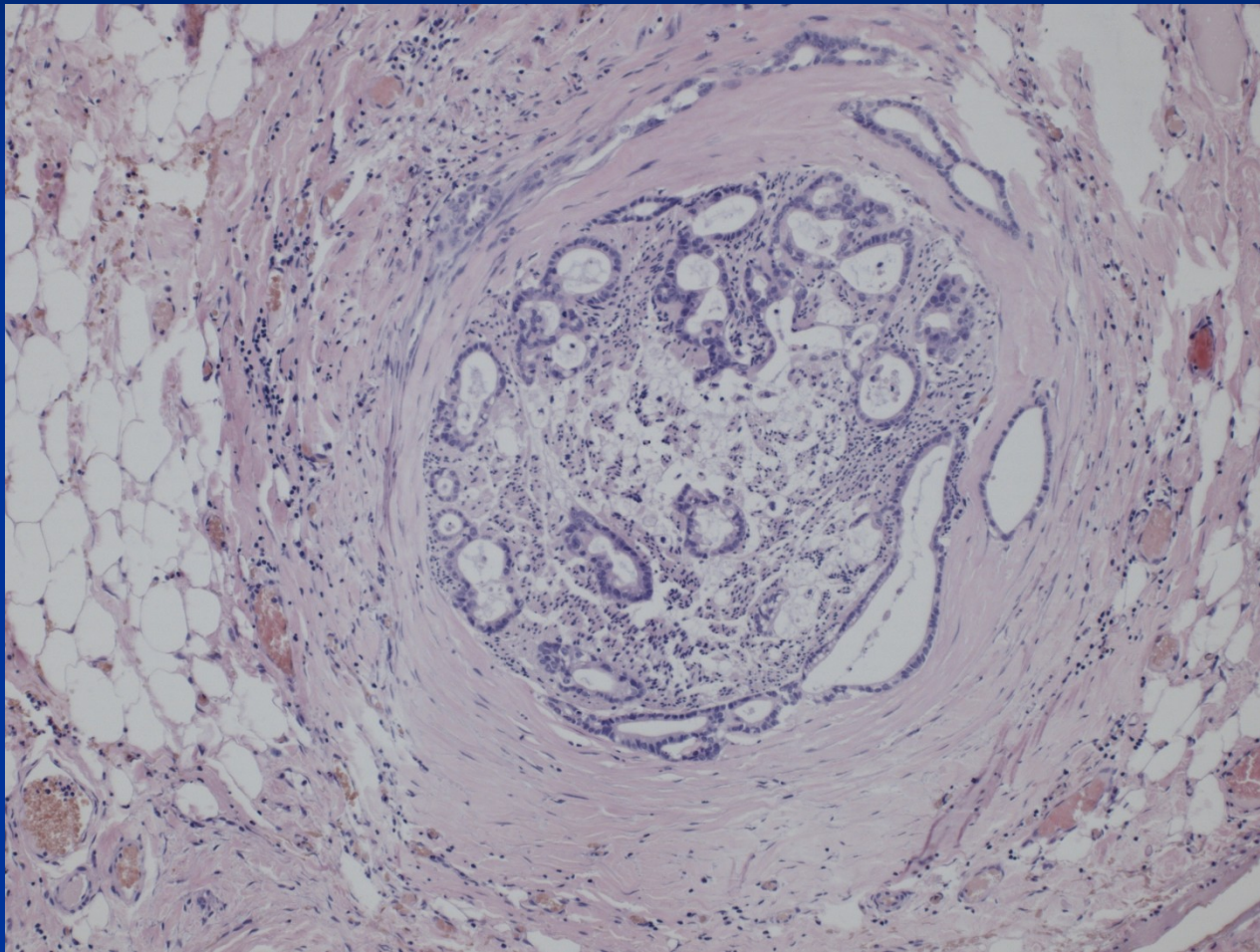
# Gallbladder carcinoma

- Seventh decade
- F>M
- Discovered at late stage, usually incidental
- Exophytic and infiltrating types
- Adenocarcinoma
- Local extension into liver, cystic duct, portal LN
- Mean 5 yrs survival 1%

# Neoplastic + non-neoplastic glands

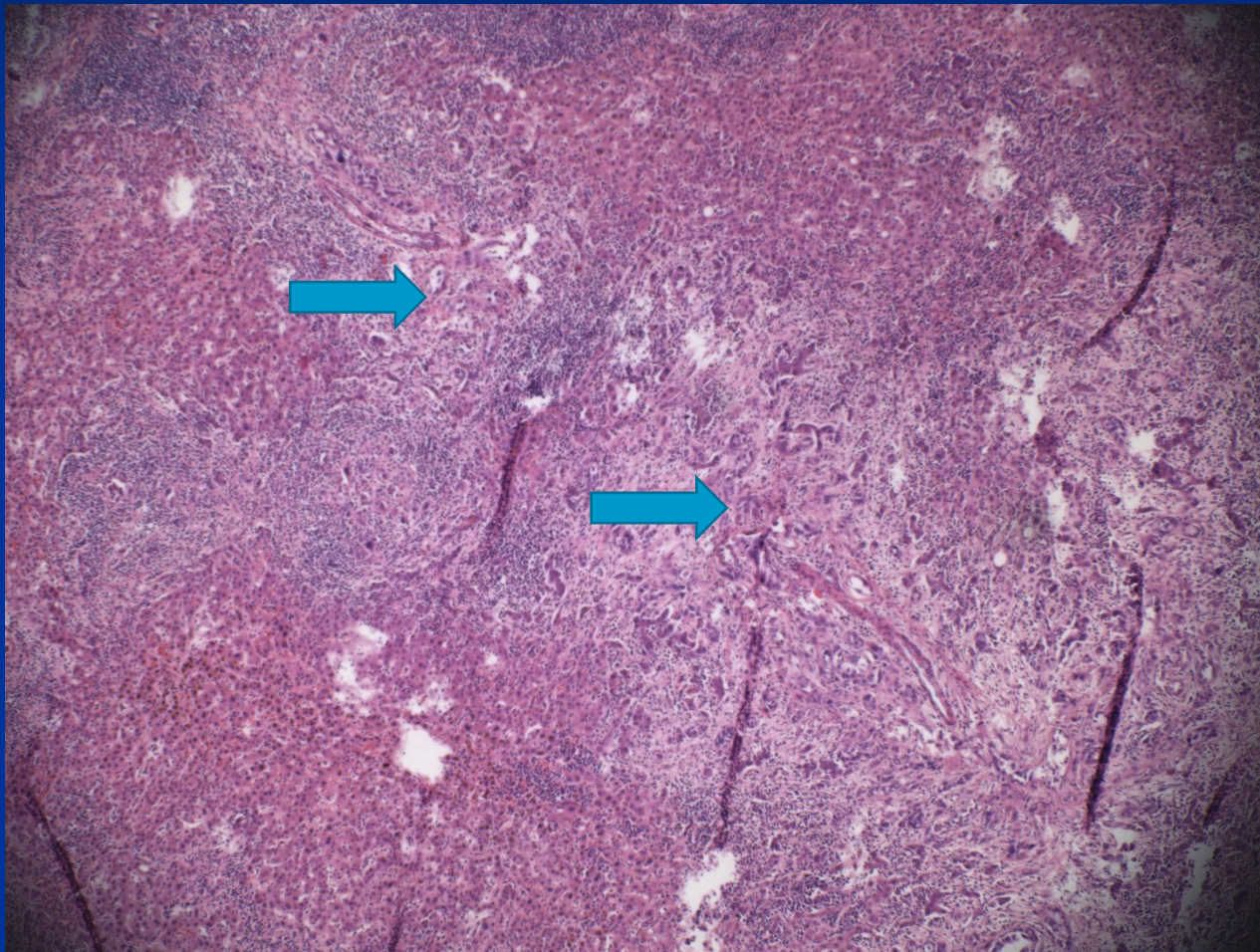


# Peri- and intraneural invasion

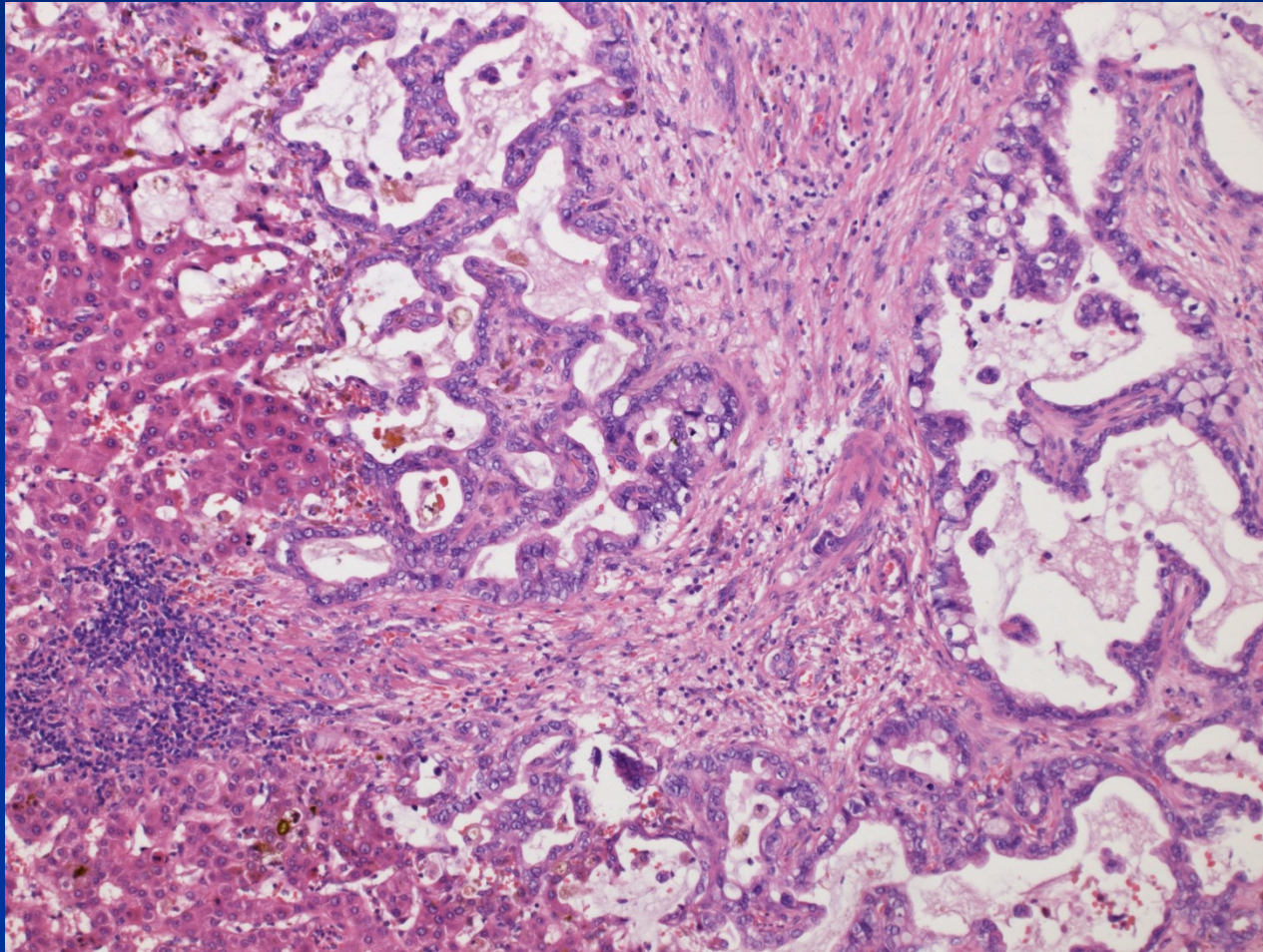




# Liver invasion



# Liver invasion



## Other disorders of extrahepatic biliary system

- Atresia of bile ducts (unclear etiopathogenesis, inborn disorder, rapid progression, cirrhosis)
- Primary sclerosing cholangitis - PSC
- Cholesterolosis (strawberry gallbladder)
- Tumors of papilla Vateri (ampuloma, periampular carcinoma – difficult diagnosis)

