

- **Tissue concept and classification**
- **Epithelial tissue**

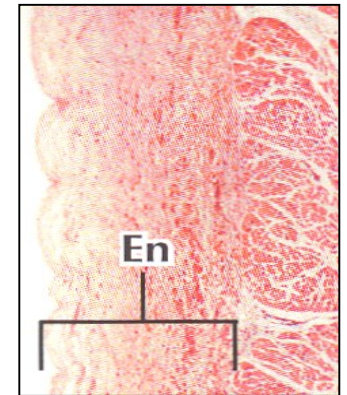
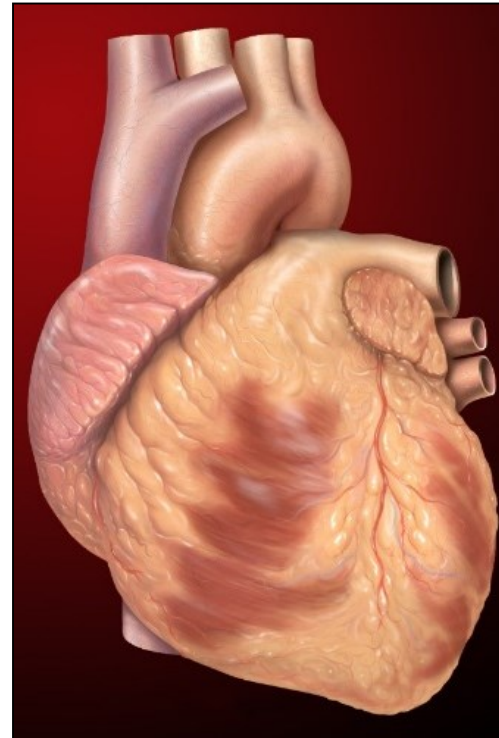
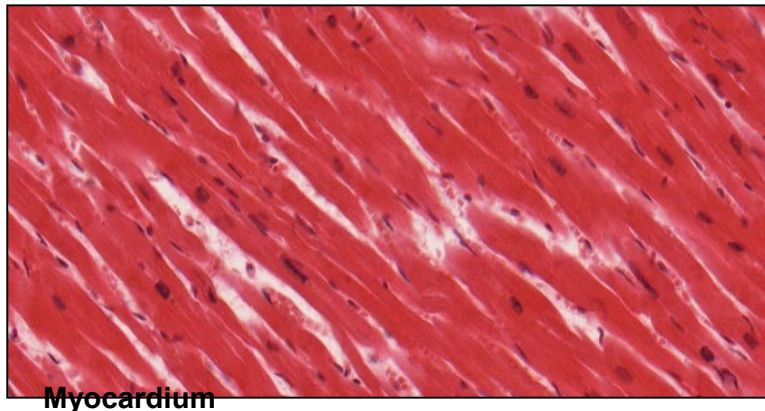
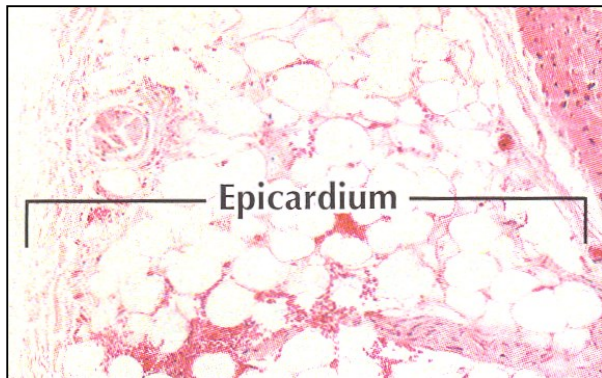
Petr Vaňhara

20 μ m

A histological micrograph showing a cross-section of stratified squamous epithelium. The tissue consists of multiple layers of cells. The surface layer is composed of flattened, squamous cells. The underlying layers are thicker and contain more rounded, polygonal cells. The nuclei are stained dark purple, and the cytoplasm and extracellular matrix are stained pink. A scale bar in the bottom left corner indicates 20 micrometers.

TISSUES AND ORGANS

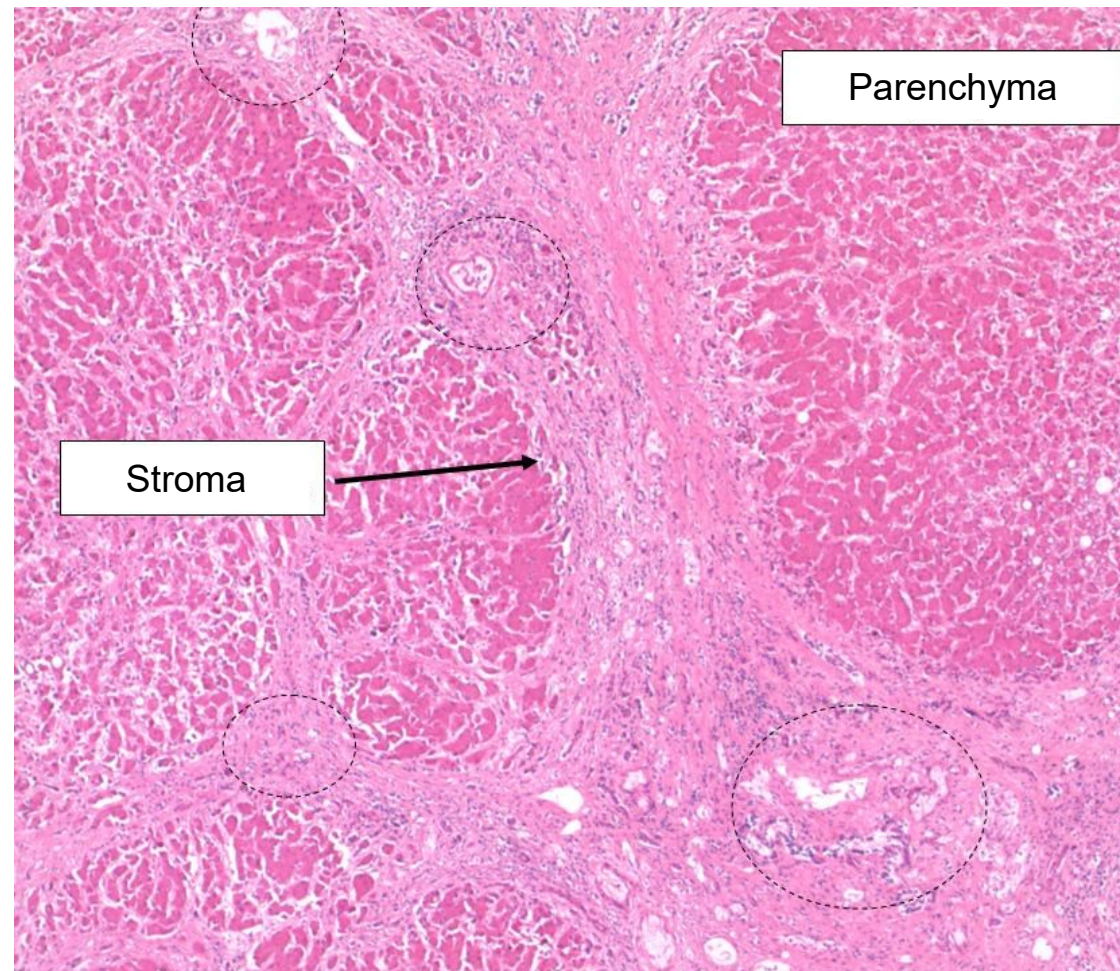
- 6×10^{13} CELLS of 200 different types
- cells form functional, three-dimensional, organized aggregations of morphologically similar cells and their products and derivatives - **TISSUES**
- tissues constitute **ORGANS** and organ systems



TISSUES AND ORGANS

Parenchyma: functional component of a tissue
(liver, lung, pancreatic, kidney parenchyma)

Stroma: surrounding, supportive tissue



LIVER

Parenchyma:

- Hepatocytes
- Sinusoids and adjacent structures

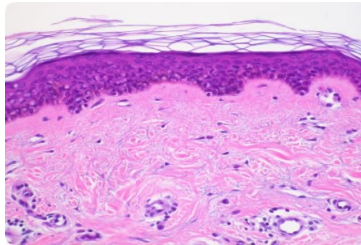
Stroma:

- Connective tissue and adjacent structures
- Vessels
- Nerves
- Bile ducts

CONTEMPORARY TISSUE CLASSIFICATION

Based on morphology and function:


Epithelium



Continual, avascular layers of cells with different function, oriented to open space, with specific junctions and minimum of ECM and intercellular space.

Derivates of all three germ layers

Muscle



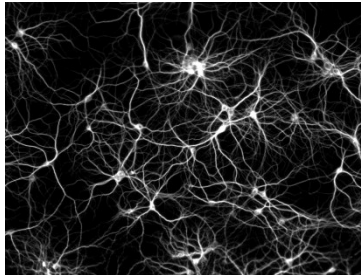
Myofibrils → contraction

Mesoderm – skeletal muscle, myocard, mesenchyme

– smooth muscles

Rarely ectoderm (eg. m. sphincter a m. dilatator pupillae)

Nerve

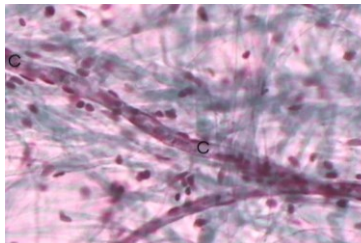


Neurons and neuroglia

Reception and transmission of electric signals

Ectoderm, rarely mesoderm (microglia)

Connective



Dominant extracellular matrix

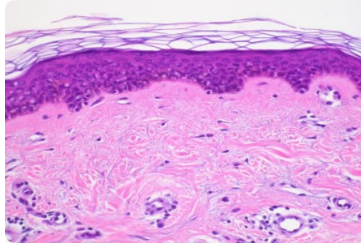
Connective tissue, cartilage, bone...

Mesenchyme

CONTEMPORARY TISSUE CLASSIFICATION

Based on morphology and function:


Epithelium



Continual, avascular layers of cells with different function, oriented to open space, with specific junctions and minimum of ECM and intercellular space.

Derivates of all three germ layers

Muscle

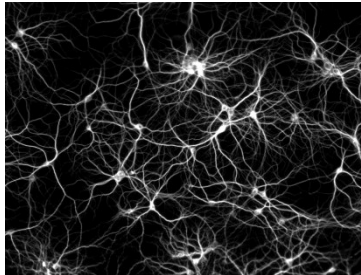


Myofibrils → contraction

Mesoderm – skeletal muscle, myocard, mesenchyme
– smooth muscles

Rarely ectoderm (eg. m. sphincter a m. dilatator pupillae)

Nerve

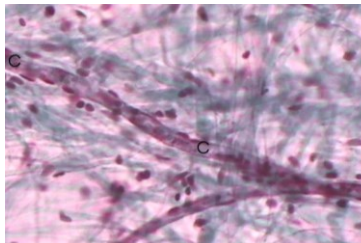


Neurons and neuroglia

Reception and transmission of electric signals

Ectoderm, rarely mesoderm (microglia)

Connective



Dominant extracellular matrix

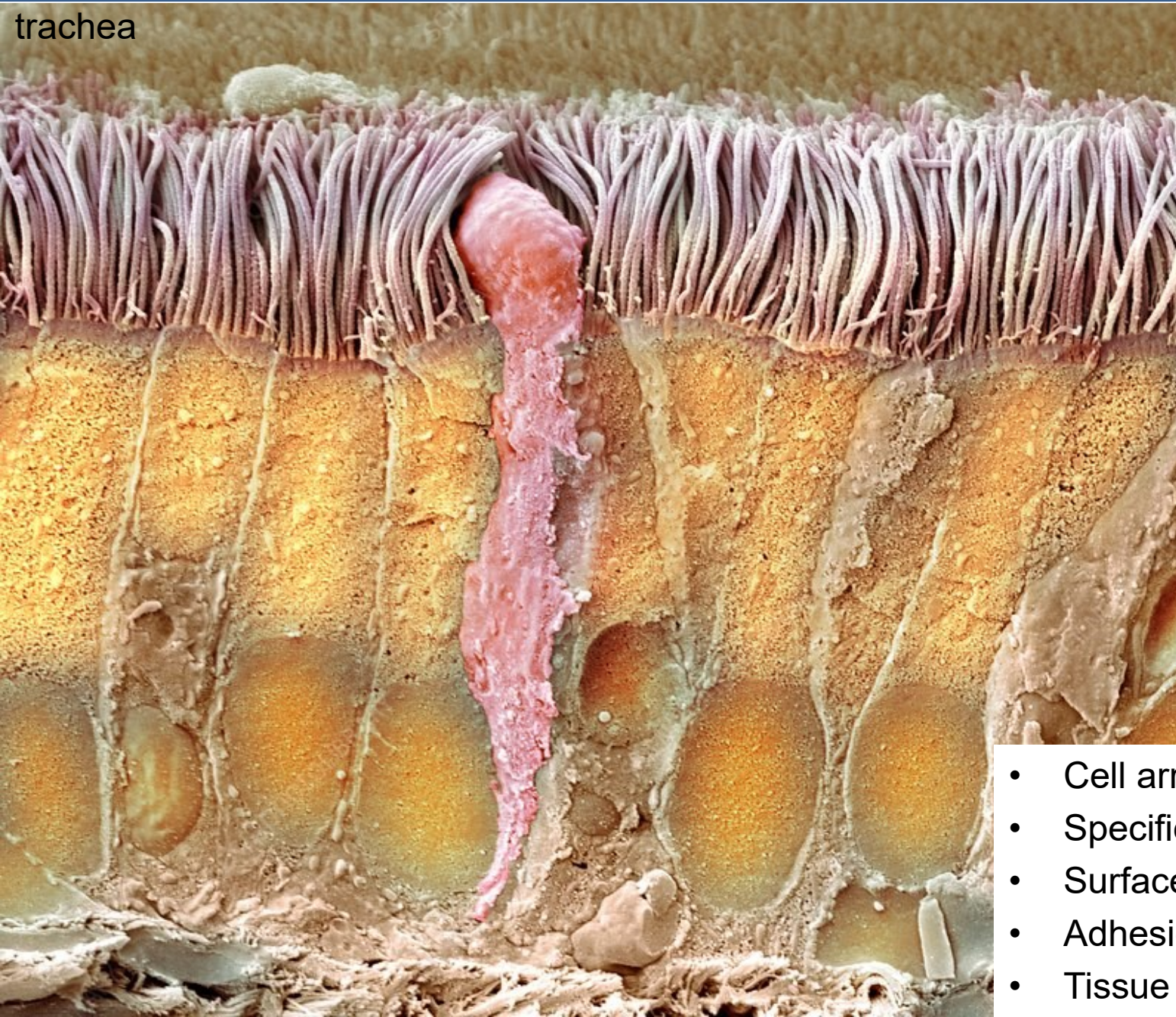
Connective tissue, cartilage, bone...

Mesenchyme

General characteristics

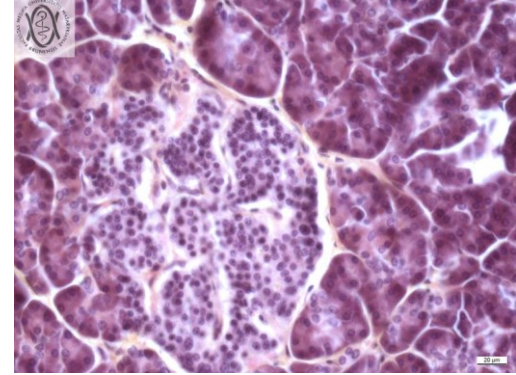
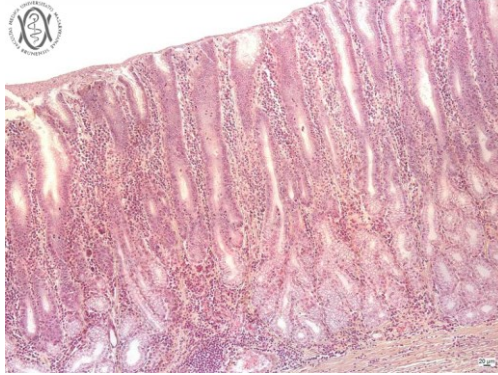
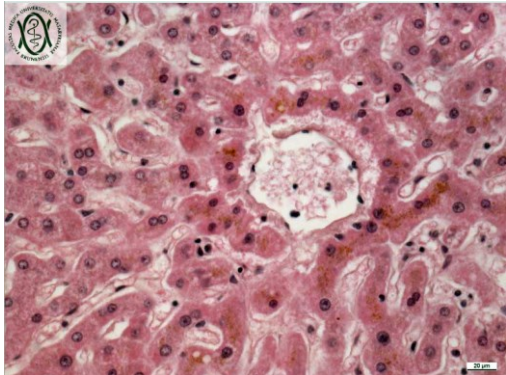
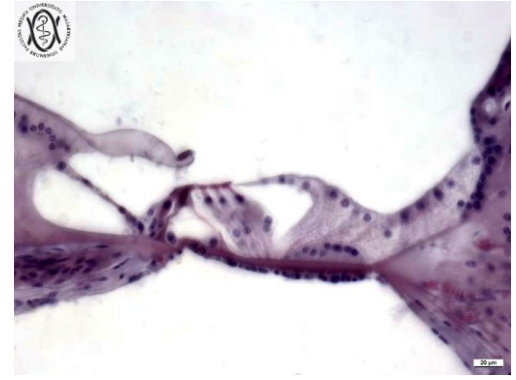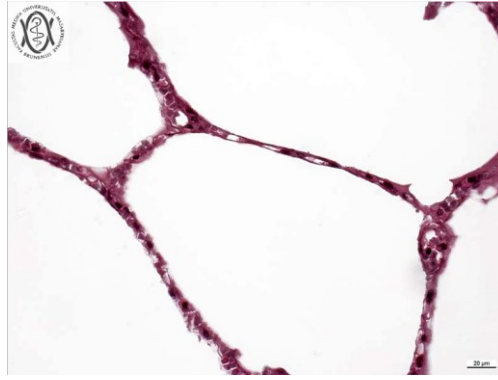
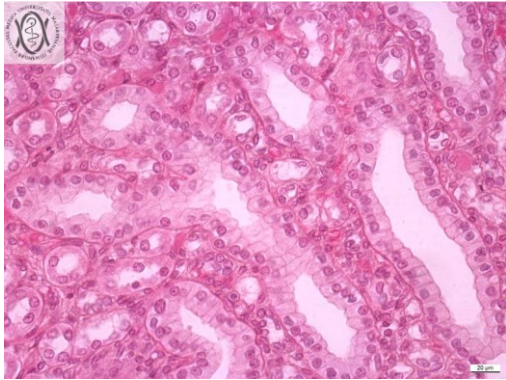
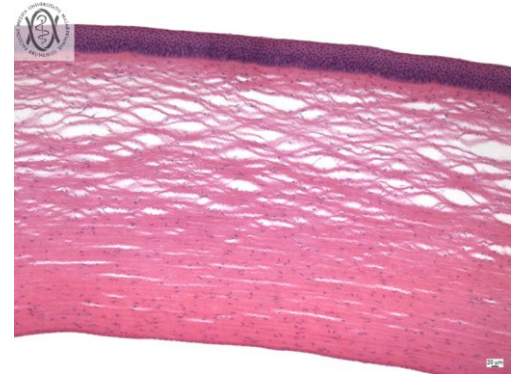
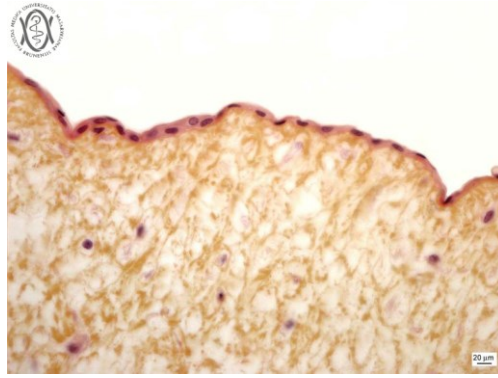
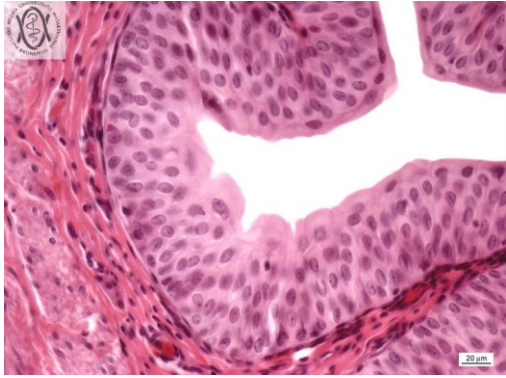
EPITHELIUM

trachea



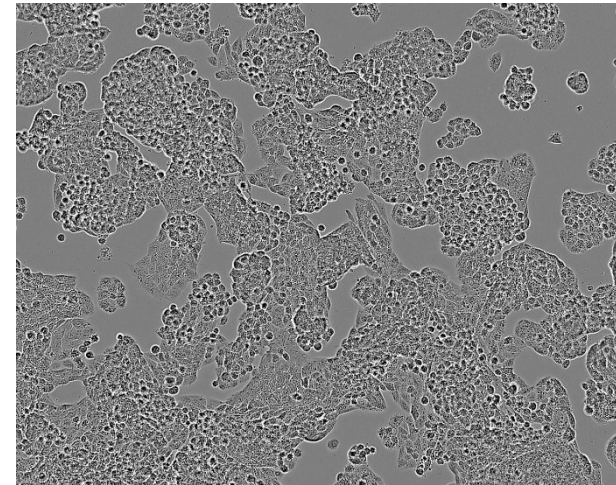
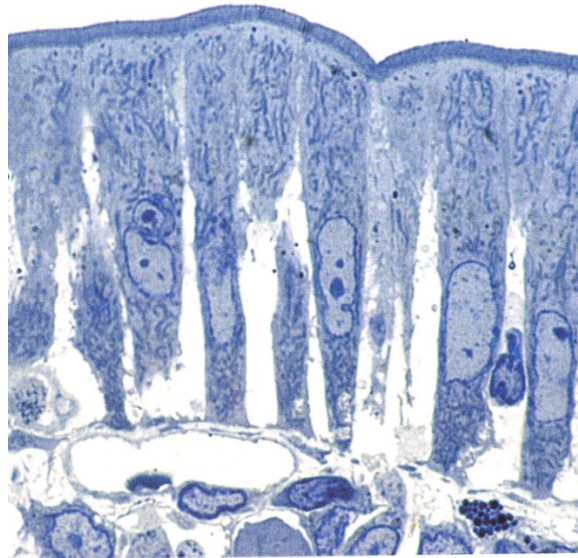
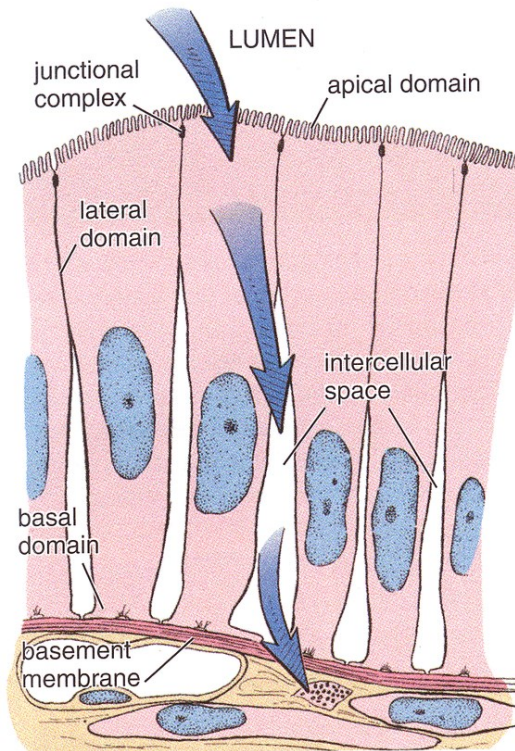
- Cell arrangement
- Specific morphology
- Surface modifications
- Adhesion
- Tissue barriers

EPITHELIAL VARIABILITY IN HUMANS

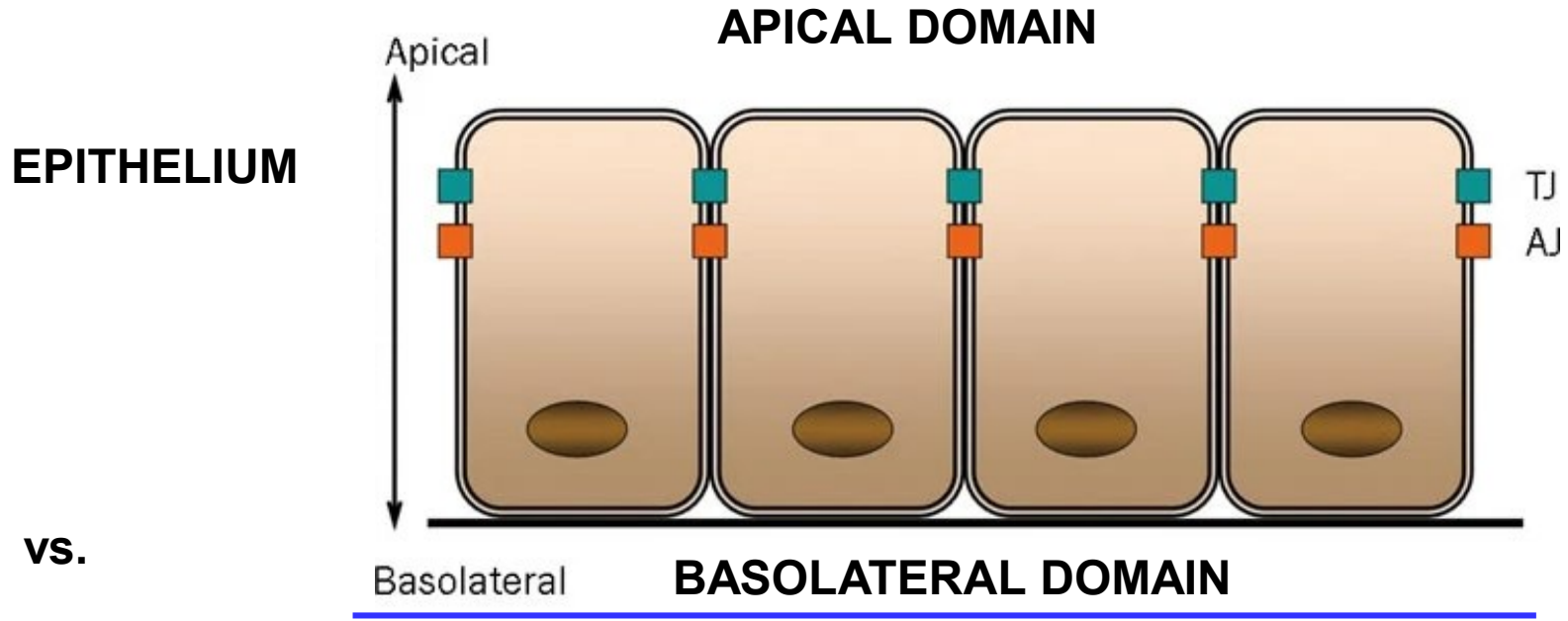


GENERAL CHARACTERISTICS OF EPITHELIAL TISSUE

- **Avascular** (without blood supply) – nutrition by diffusion from a highly vascular and innervated area of loose connective tissue (*lamina propria*) just below the basement membrane
- **Highly cellular** – cohesive sheet or groups of cells with no or little extracellular matrix
- Typical **morphology** and **cell connections**

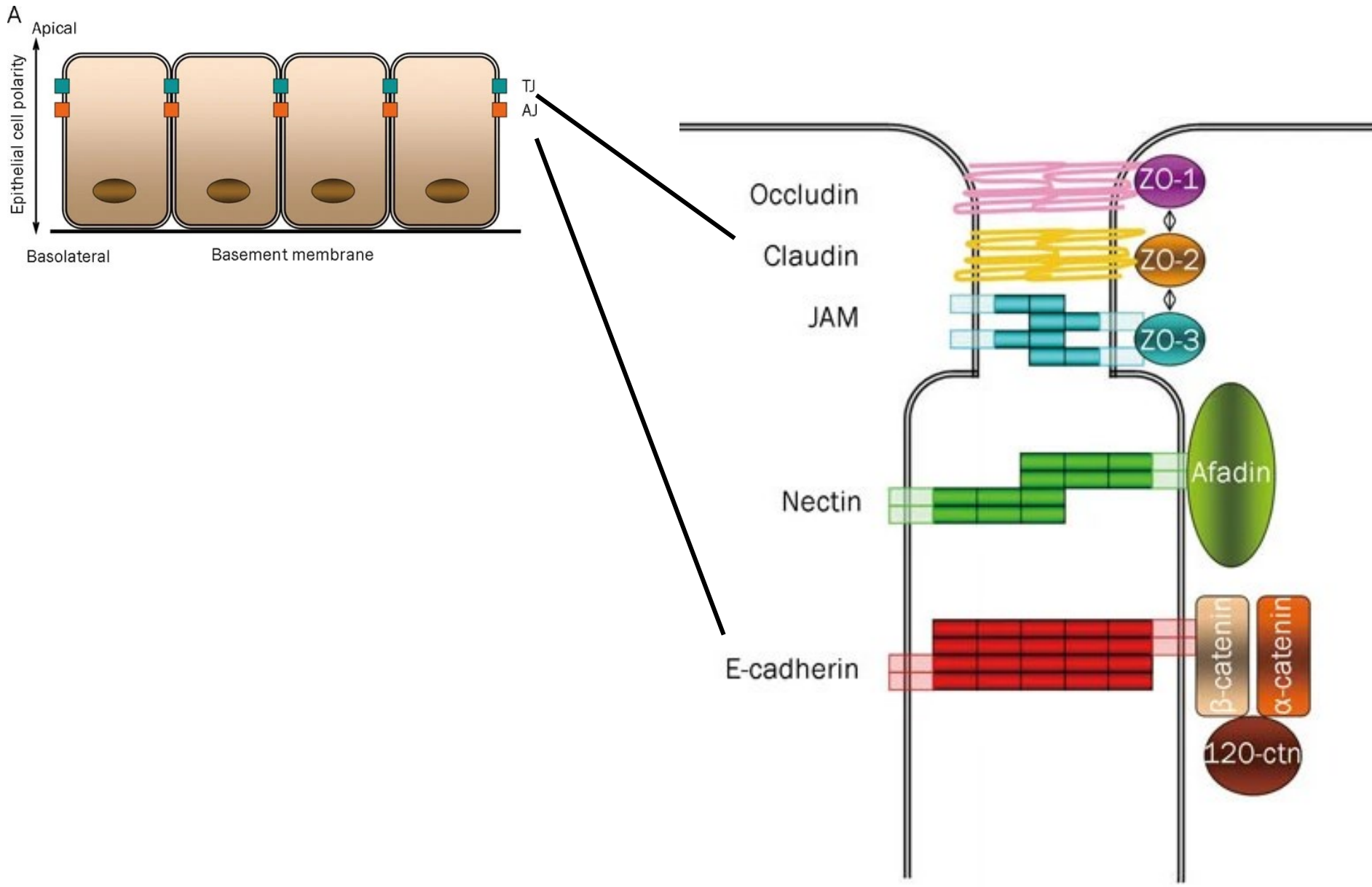


CELL POLARITY

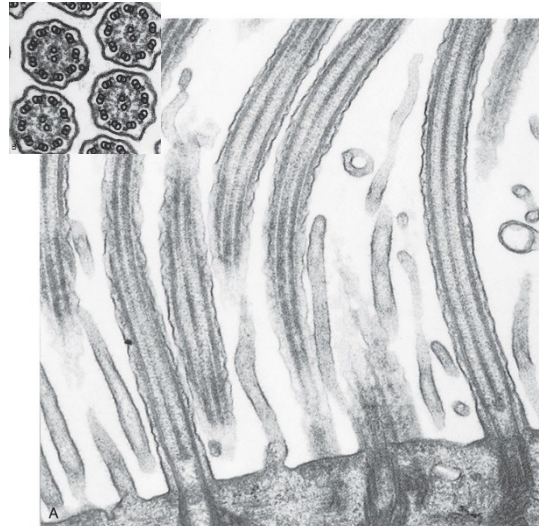
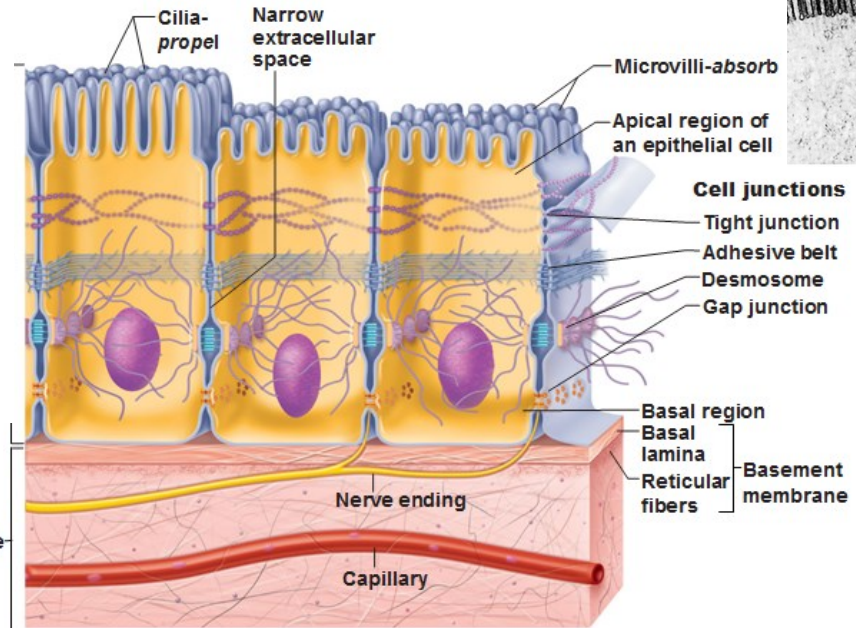
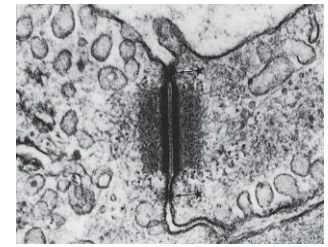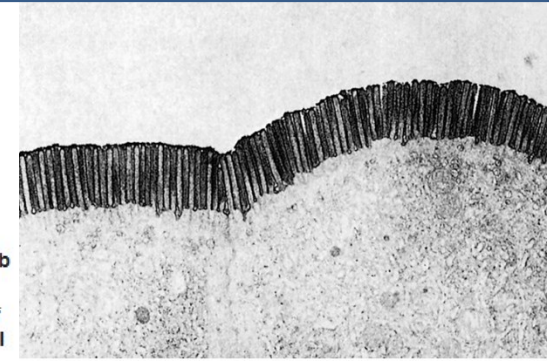


MESENCHYME

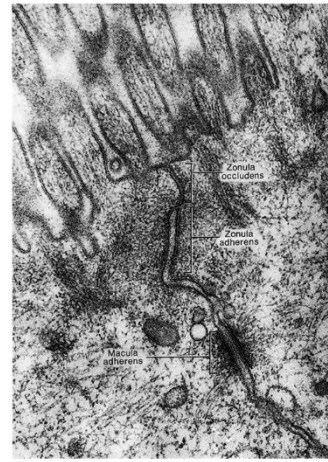
CELL POLARITY



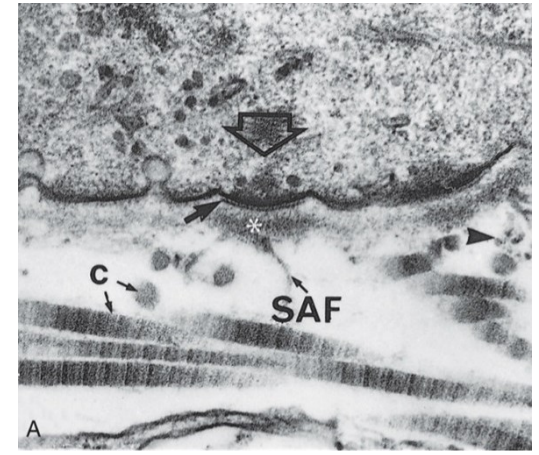
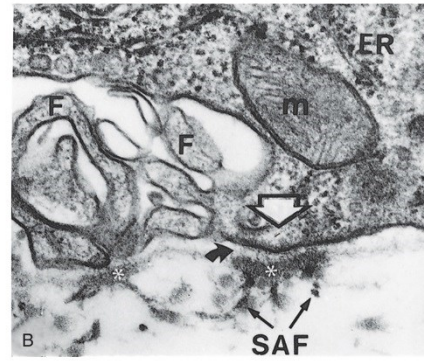
HALLMARKS OF A TYPICAL EPITHELIAL CELL



From Lesson TS, Lesson CR, Papero AA, Text/Atlas of Histology, Philadelphia: WB Saunders; 1988.

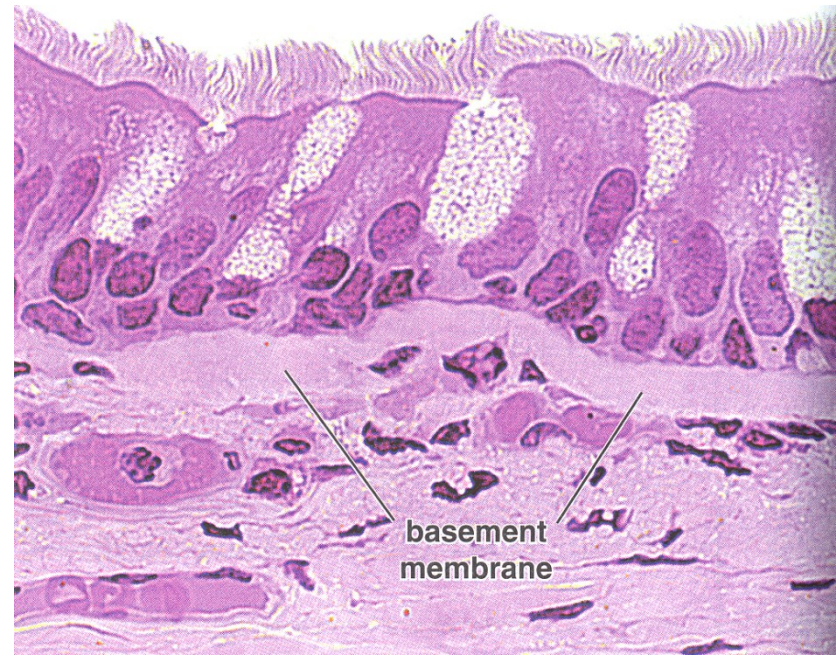
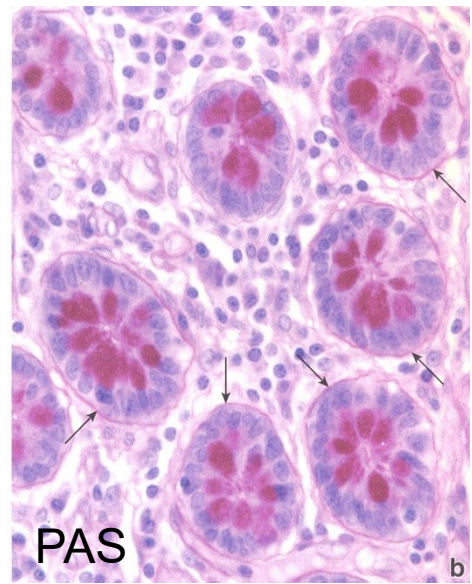
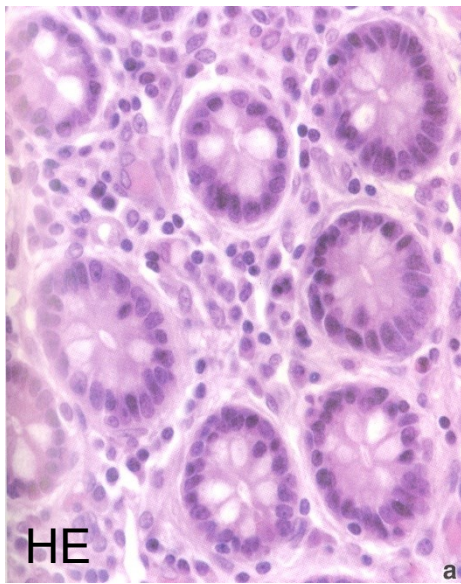
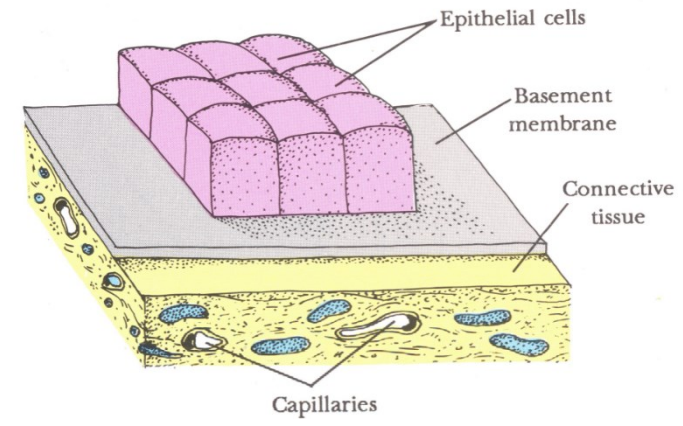


Connective tissue



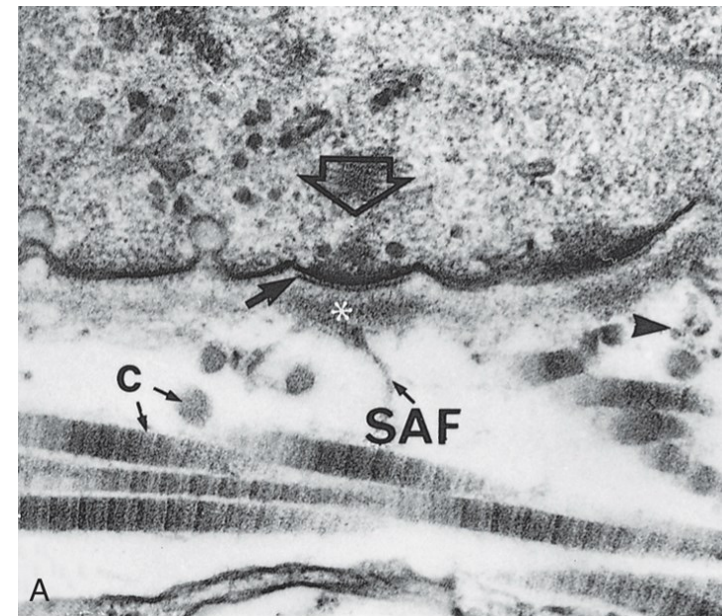
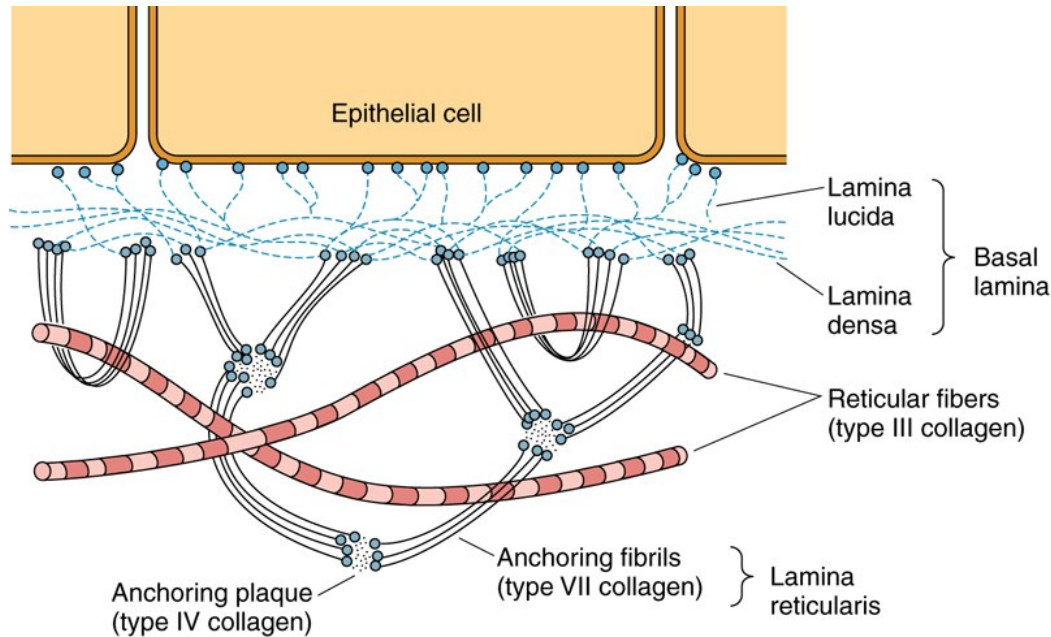
BASEMENT MEMBRANE

- Attachment of epithelium to underlying tissues
- Selective filter barrier between epithelial and connective tissue
- Communication, differentiation

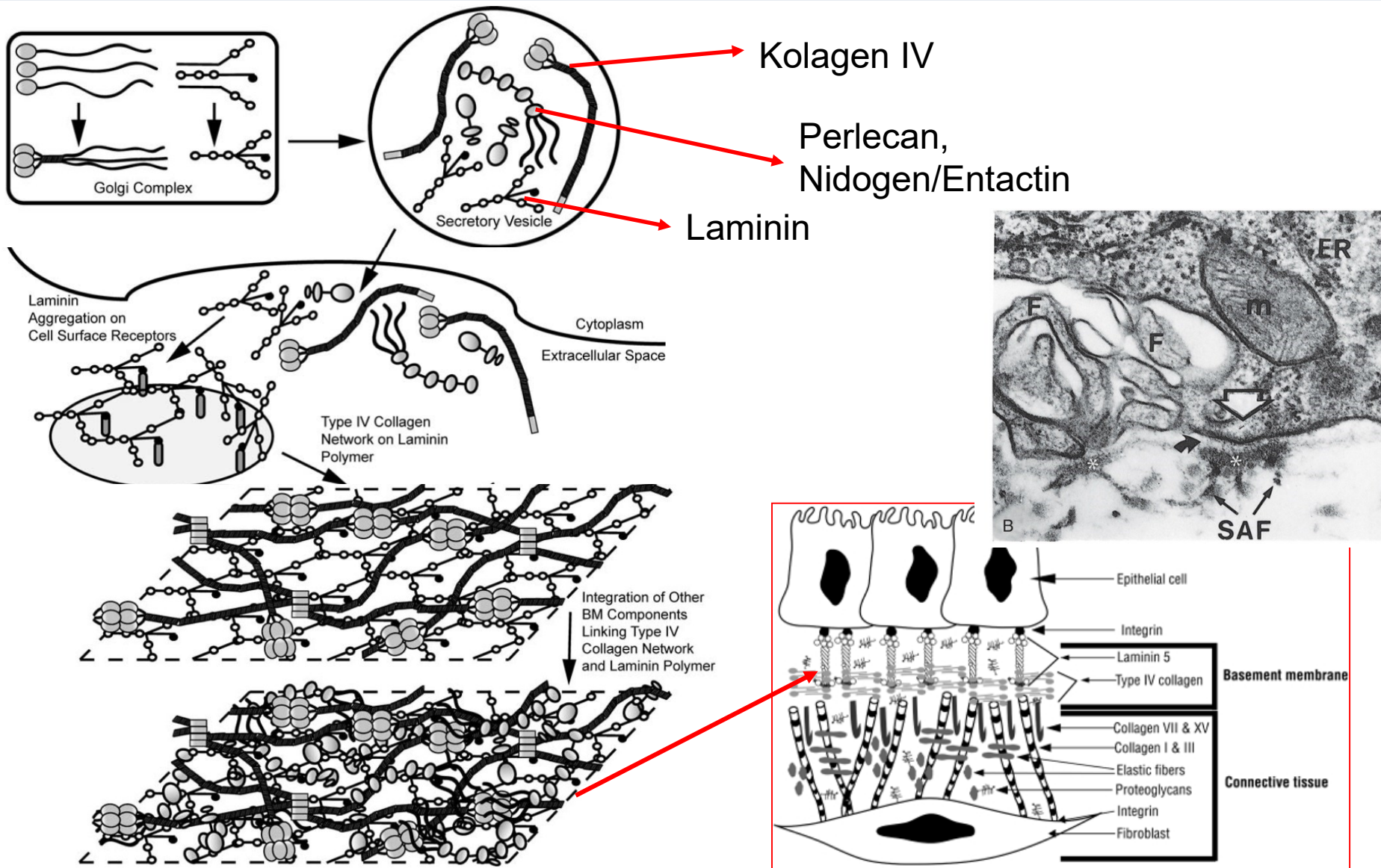


BASAL LAMINA vs. BASEMENT MEMBRANE

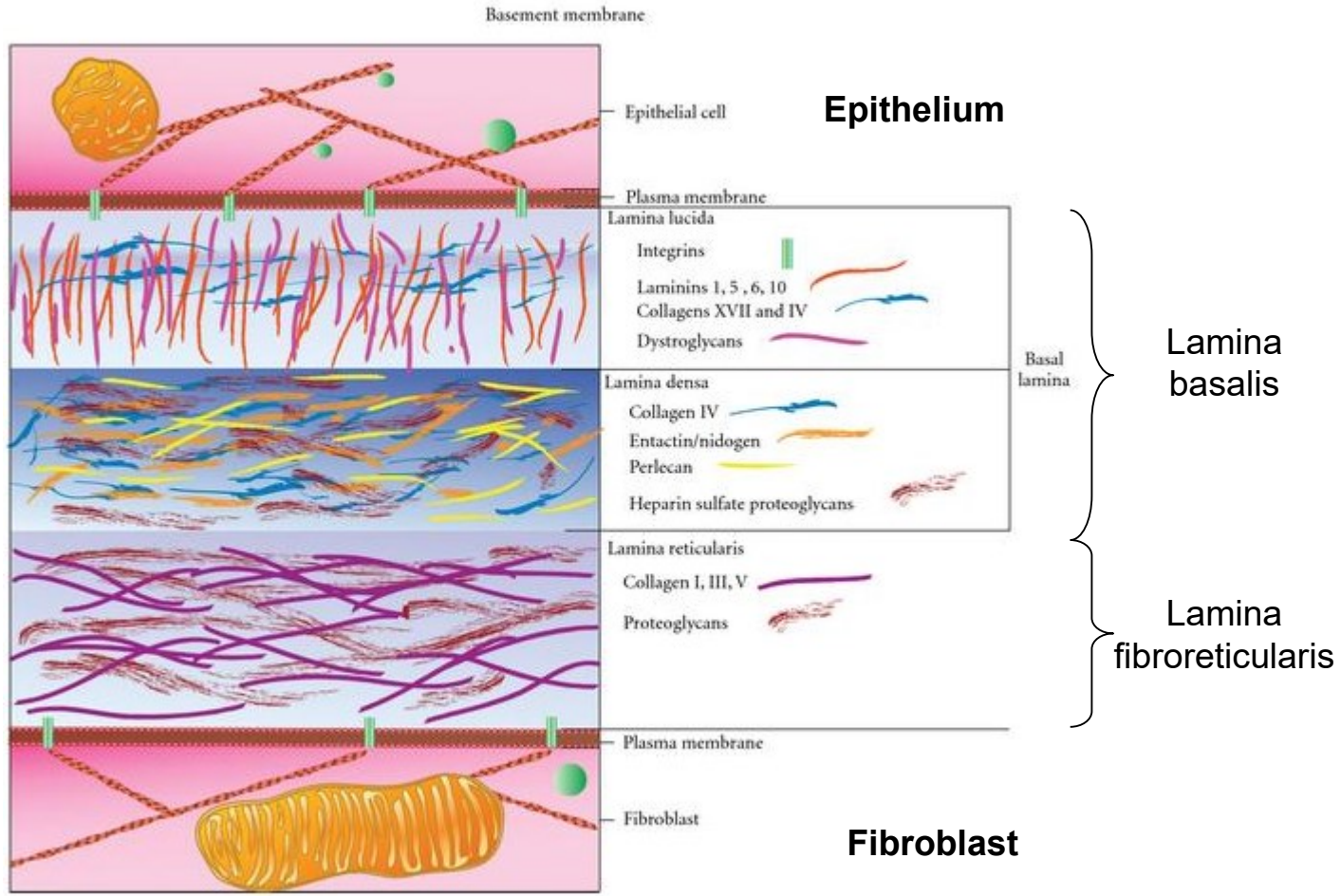
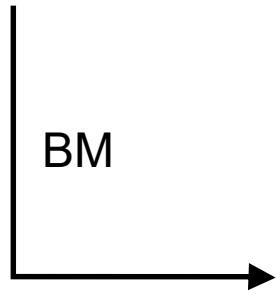
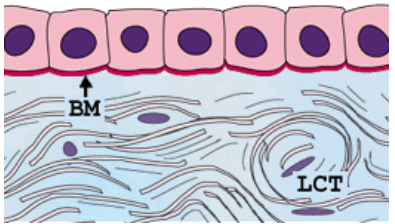
- 50-100nm
- Glycosaminoglycans – heparansulfate
- Laminin, collagen III, IV, VI,
- Nidogen/entactin
- Perlecan
- Proteoglycans



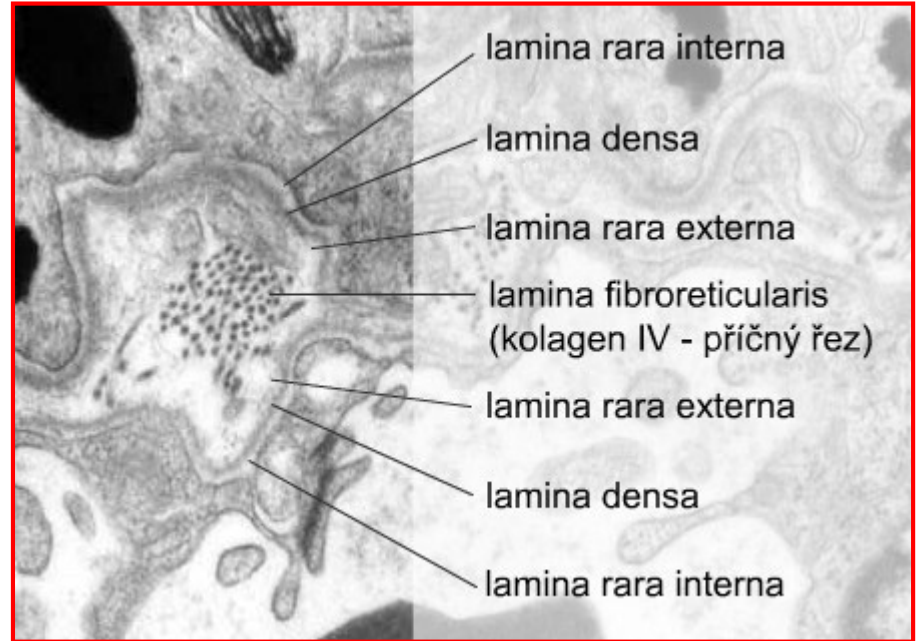
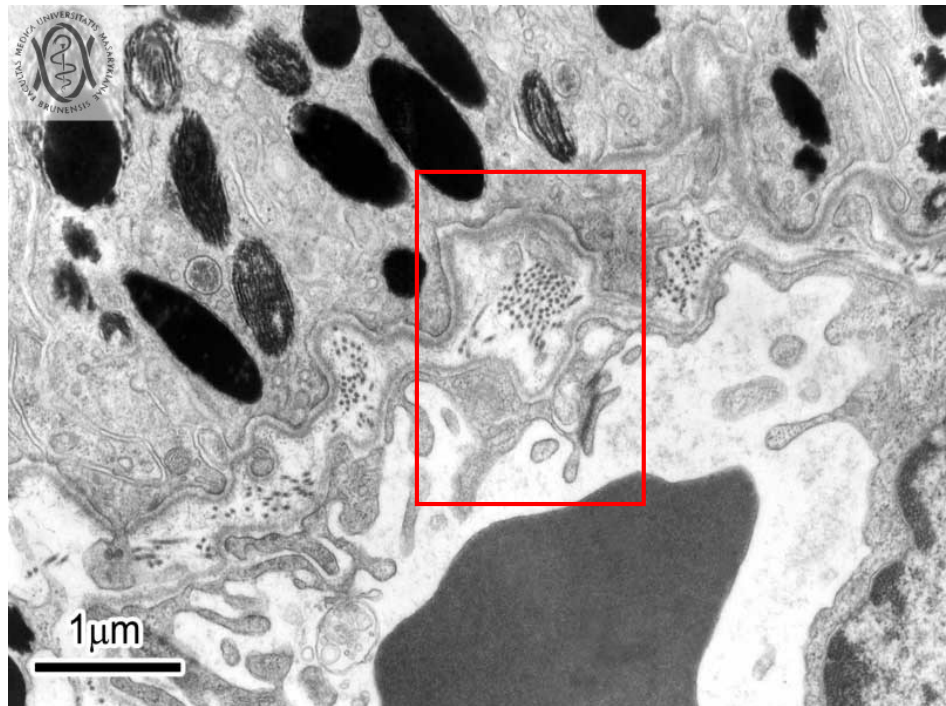
BASEMENT MEMBRANE



ARCHITECTURE OF BASEMENT MEMBRANE



MODIFICATIONS OF BASEMENT MEMBRANE



- **Two basic layers of basement membrane**

- lamina basalis
- lamina fibroreticularis

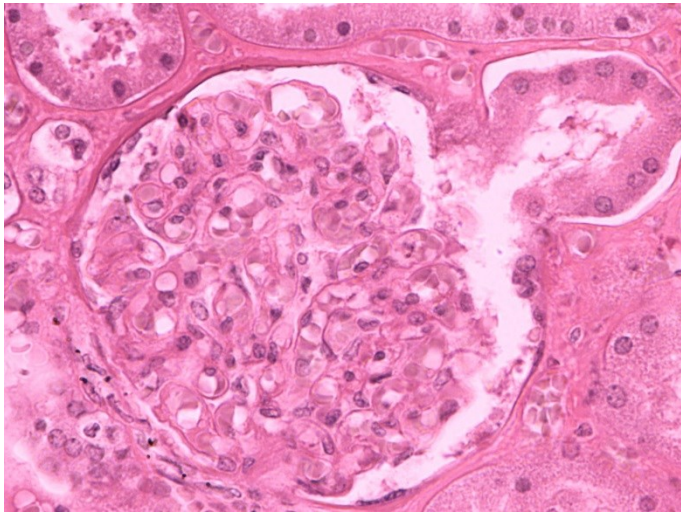
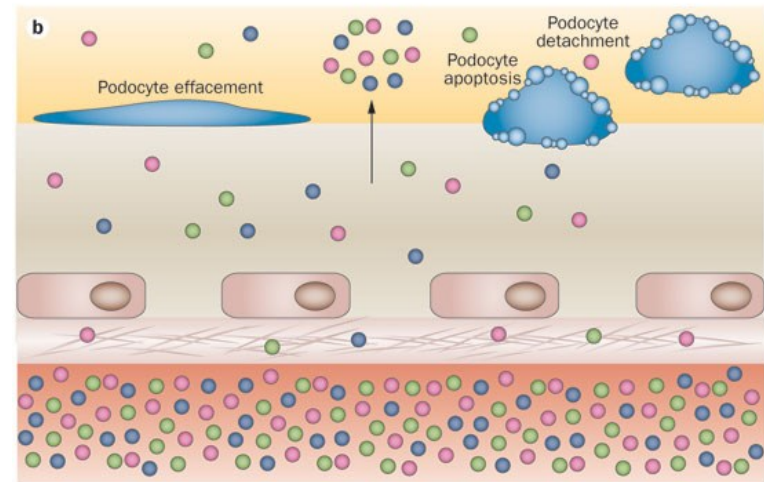
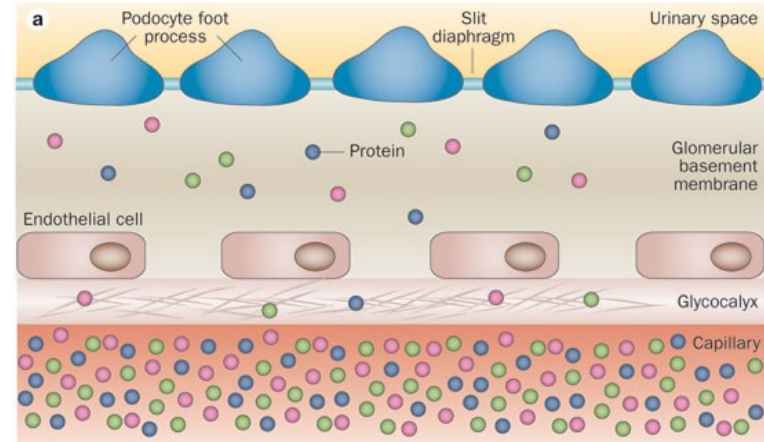
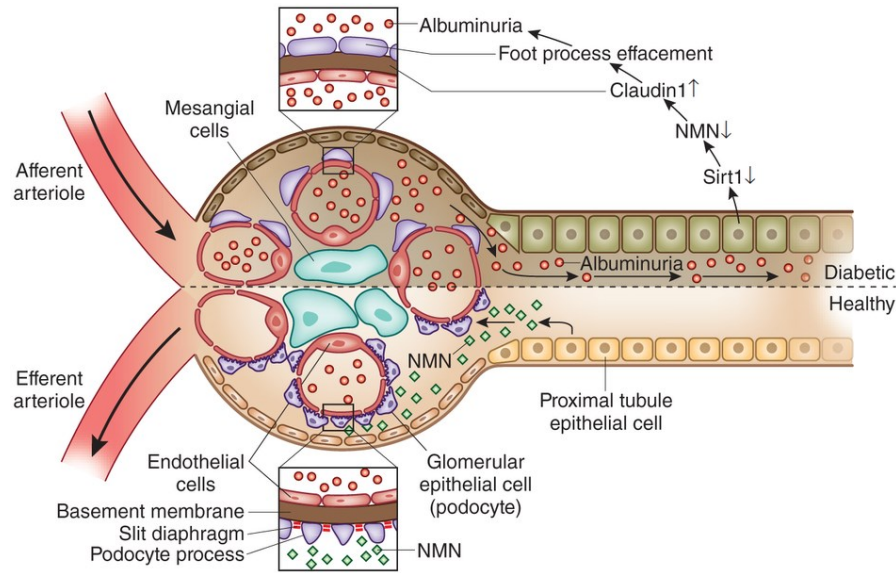
- **Contact of two epithelia (or with endothelium)**

- fusion of laminae basales
 - lamina densa
 - lamina rara (lucida) ext. et int.

- **Tissue specific modifications**

- Descemet membrane (cornea)
- Glomerular BM (Bowman's capsule)
- Part of Bruch's membran of retina
- ...

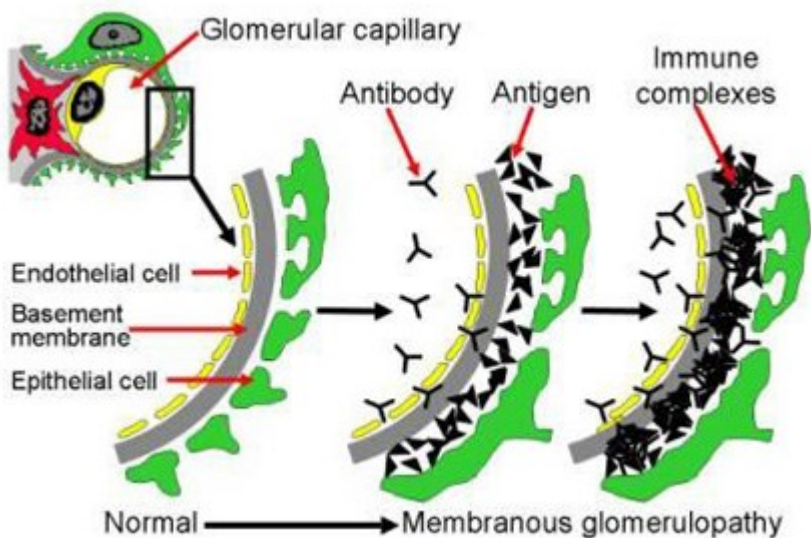
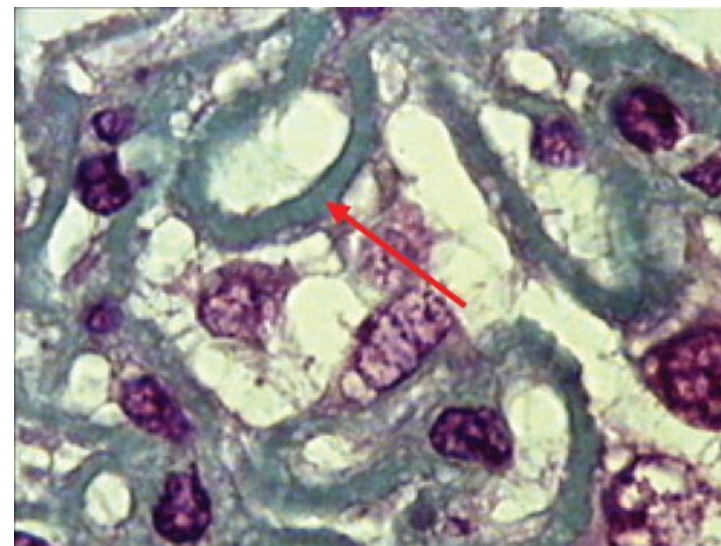
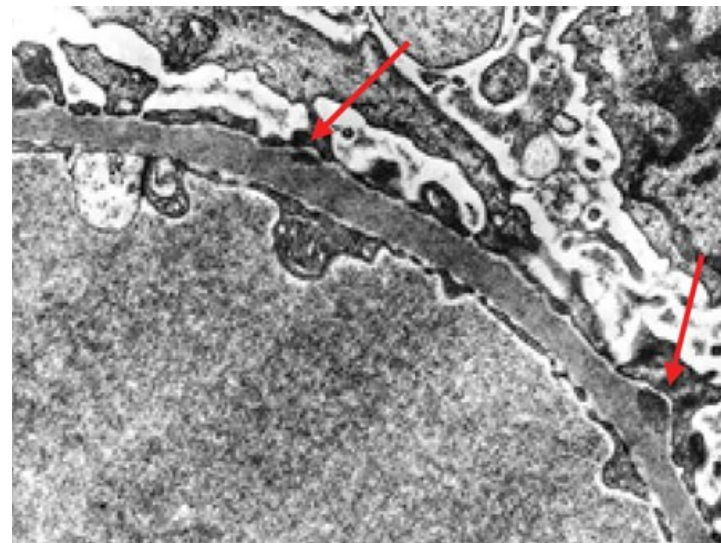
BASEMENT MEMBRANE IN CORPUSCULUM RENIS



BASEMENT MEMBRANE IN CORPUSCULUM RENIS

- **Clinical correlations – *membranous glomerulonephritis***

- circulating Abs bind to BM of capillary wall
- complement (C5b-C9) attacks glomerular endothelial cells
- filtration barrier compromised
- proteinuria, edema, hematuria, renal failure



EMBRYONIC ORIGIN OF EPITHELIAL TISSUE

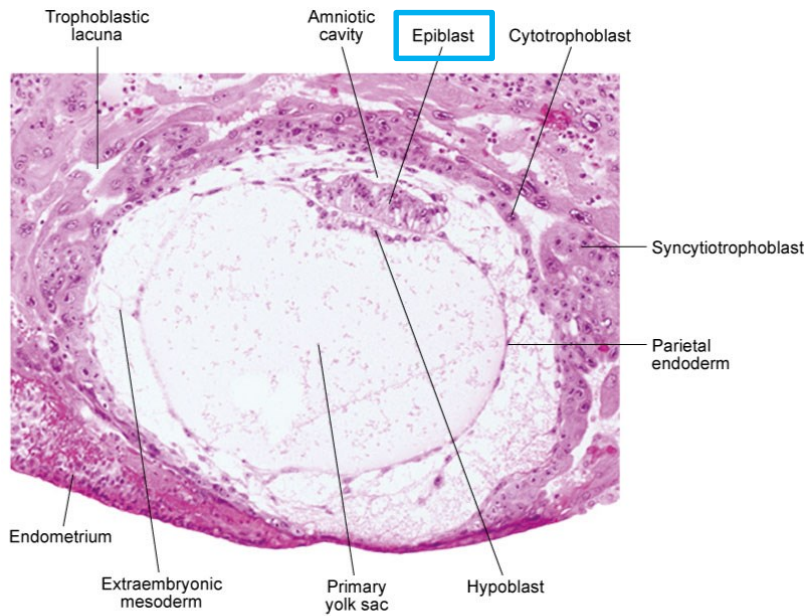


Fig. 5-3. Digital photomicrograph of a 12-day human embryo (Carnegie No. 7700) taken just as implantation within the endometrium is completed.

Courtesy of Dr. Ray Gasser.

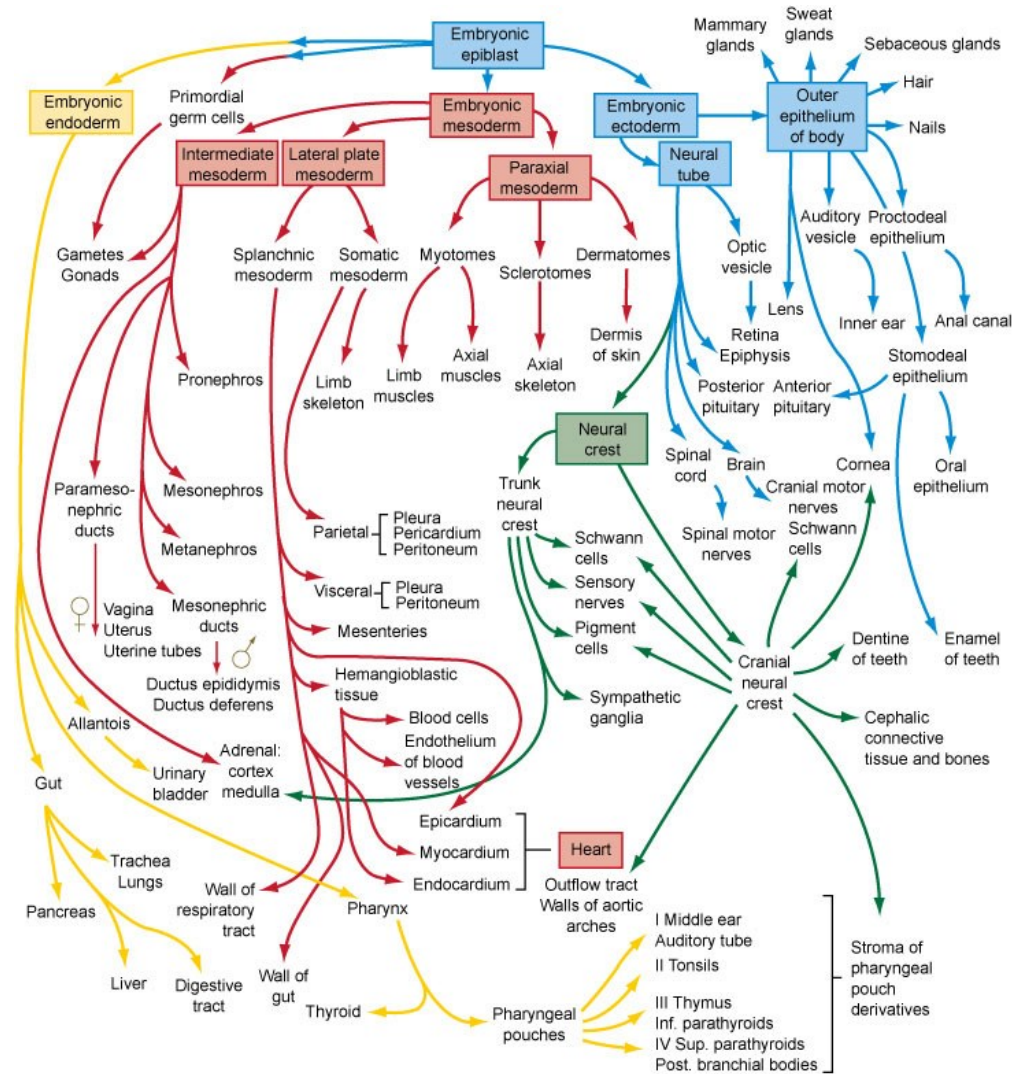


Fig. 6-27. Flow chart showing the formation of the organs and tissues of the embryo from the fundamental germ layers. The arrows are color-coded according to the germ layer of origin of the structure (see Fig. 4-1 for color code).

EMBRYONIC ORIGIN OF EPITHELIAL TISSUE

- **derived from all three germ layers**

Germ layer	Epithelial derivatives
Ectoderm	<ol style="list-style-type: none">1. Epidermis (stratified squamous keratinized epithelium)2. Sweat glands and ducts (simple and stratified cuboidal epithelium)3. Oral cavity, vagina, anal canal (stratified squamous non-keratinized epithelium)
Mesoderm	<ol style="list-style-type: none">1. Endothelium of blood vessels (simple squamous epithelium)2. Mesothelium of body cavities (simple squamous epithelium)3. Urinary and reproductive passages (transitional, pseudostratified and stratified columnar epithelium, simple cuboidal and columnar epithelium)
Endoderm	<ol style="list-style-type: none">1. Esophagus (stratified squamous non-keratinized epithelium)2. GIT (simple columnar epithelium)3. Gall bladder (simple columnar epithelium)4. Solid glands (liver, pankreas)5. Respiratory passages (ciliated pseudostratified columnar epithelium, ciliated simple columnar epithelium, cuboidal, squamous epithelium)6. Part of urinary system (cloaca-derived)

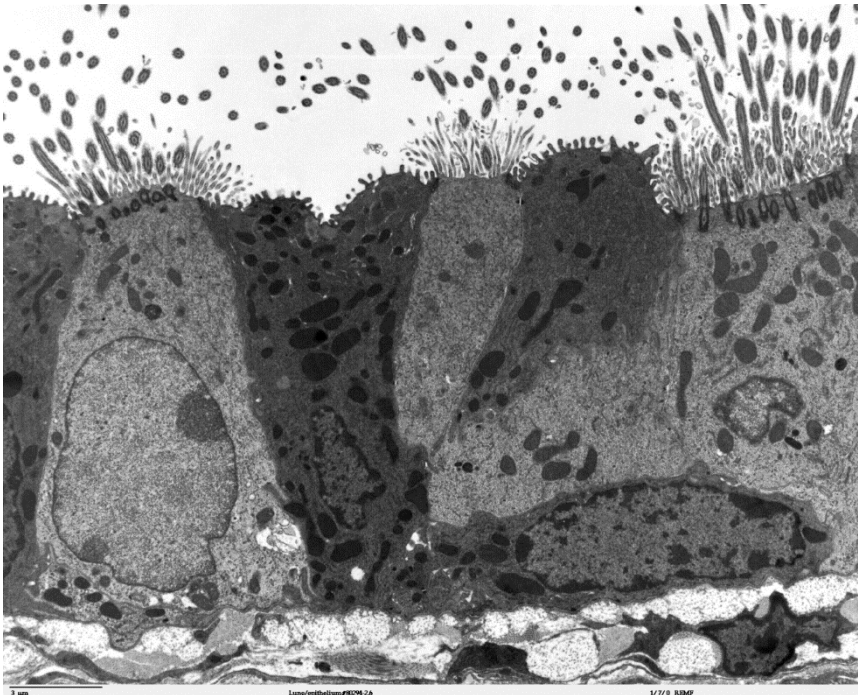
CLASSIFICATION OF EPITHELIAL TISSUE

According to

- 1) morphology
- 2) function

- Covering (sheet) epithelium
- Trabecular epithelium
- Reticular epithelium

- Covering
- Glandular
- Resorption
- Sensory
- Respiratory
- Alveolar
- Germinal
- ...

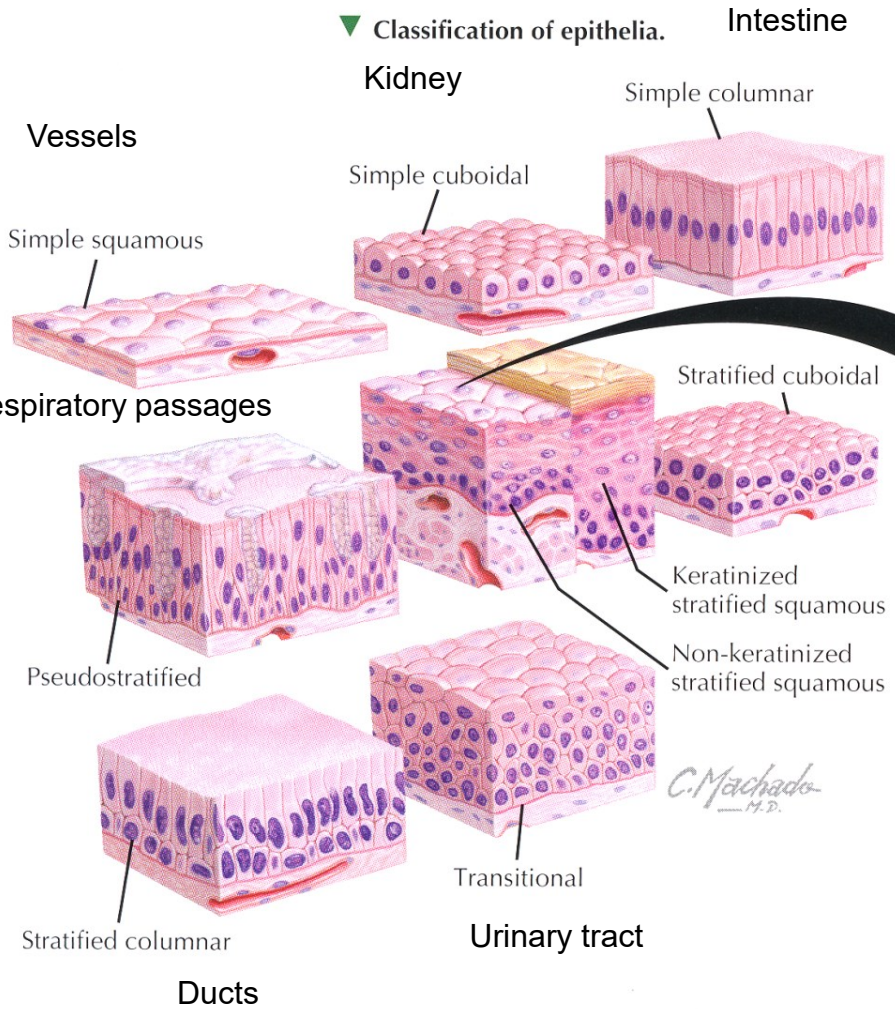


Classification by morphology

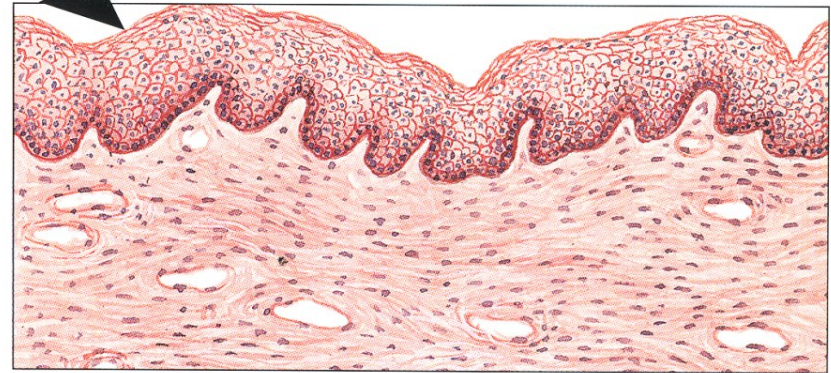CLASSIFICATION OF EPITHELIAL TISSUE

1) Covering (sheet) epithelia

▼ Classification of epithelia.



Skin
Oesophagus



▲ **Schematic of nonkeratinized stratified squamous epithelium as seen with the light microscope.** The epithelium acts as a protective barrier and is typical of wet surfaces—linings of the oral cavity, esophagus, anal canal, part of the urethra, and vagina. It also covers the cornea.

CLASSIFICATION OF EPITHELIAL TISSUE

■ Simple squamous epithelium

- Single layer of flat cells with central flat nuclei
- Capillaries
- Lung alveolus
- Glomerulus in renal corpuscle

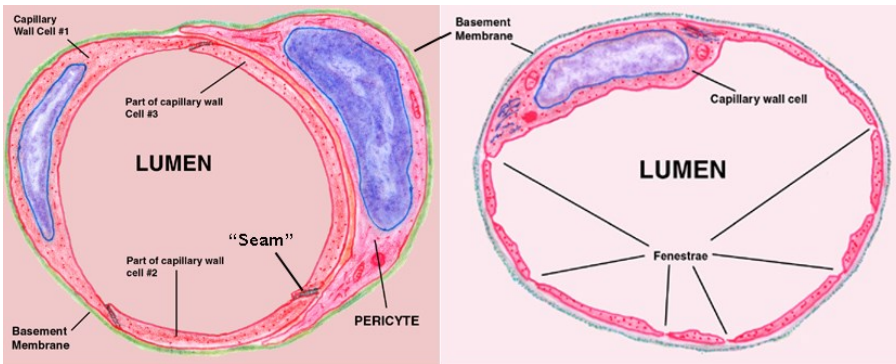
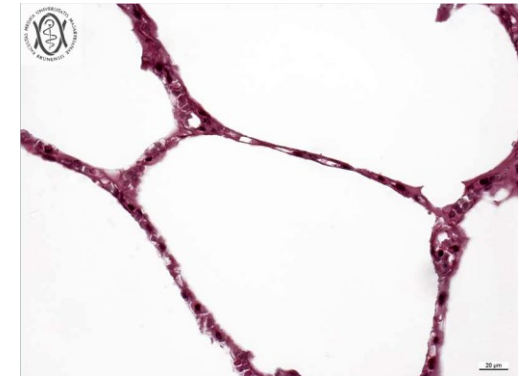
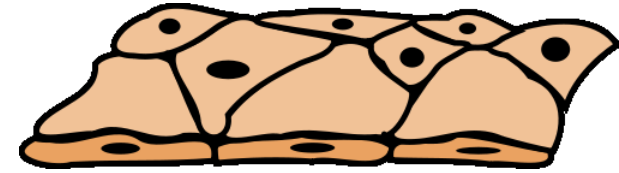
} **Selective permeability**

Endothelium

heart, blood, and lymphatic vessels.

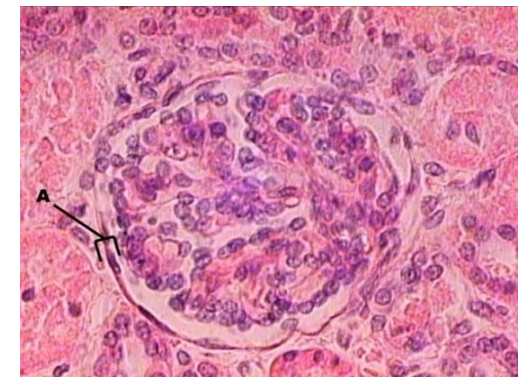
Mesothelium

serous membranes - body cavities

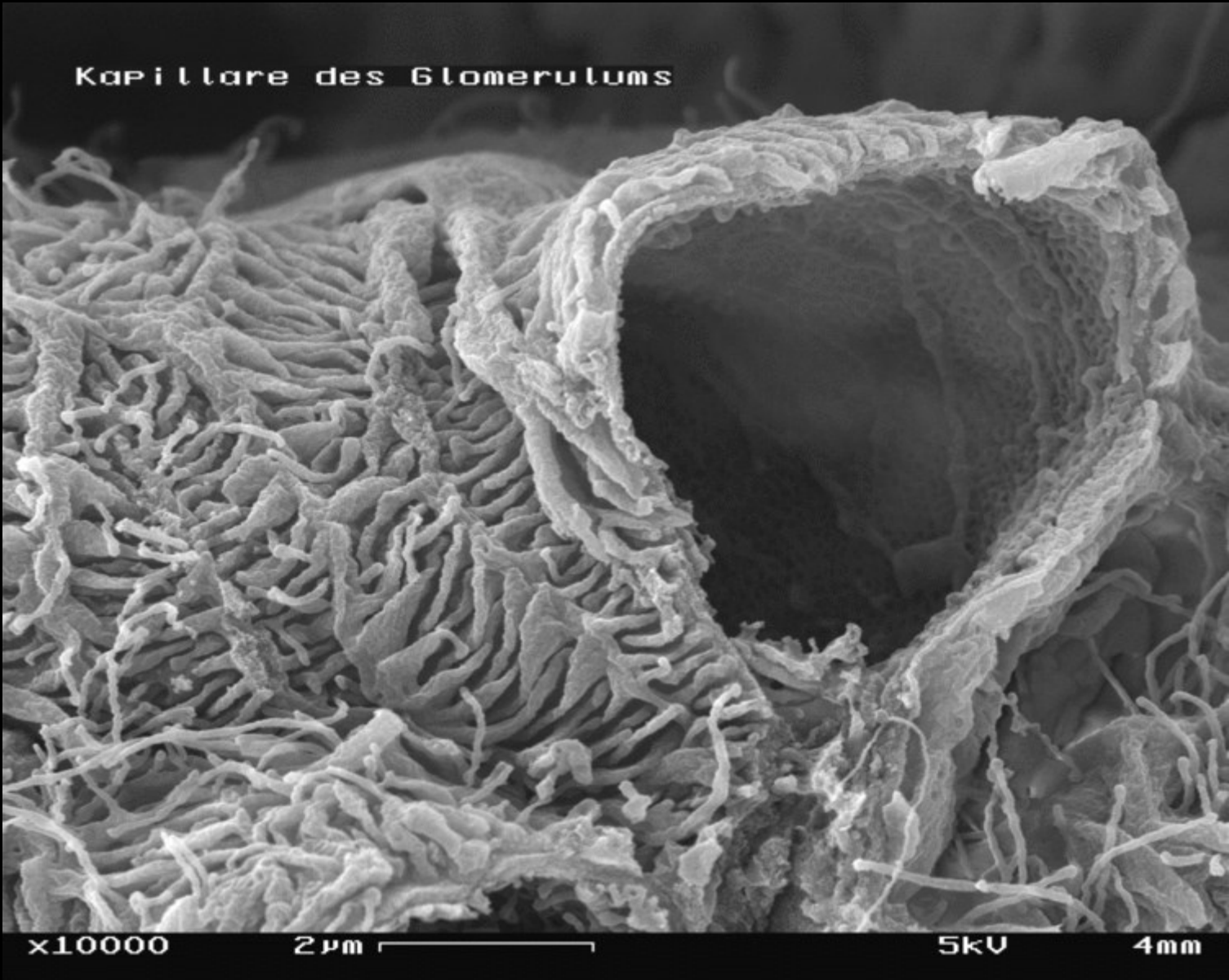


Closed or Continuous Capillary

Fenestrated Capillary



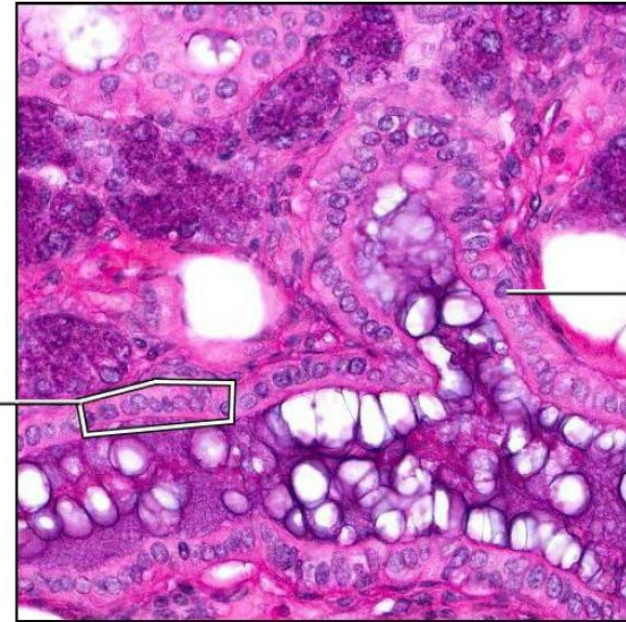
CLASSIFICATION OF EPITHELIAL TISSUE



CLASSIFICATION OF EPITHELIAL TISSUE

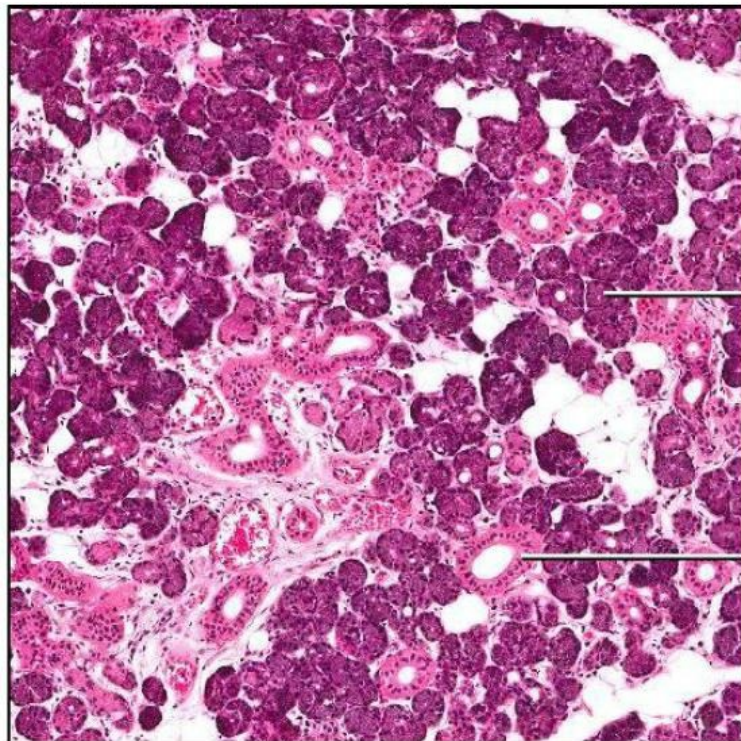
■ Simple cuboidal epithelium

- Single layer of cuboidal cells with large, spherical central nuclei
- Secretion or resorption



Nucleus of cuboidal epithelium cell

Simple cuboidal epithelium



Serous acini

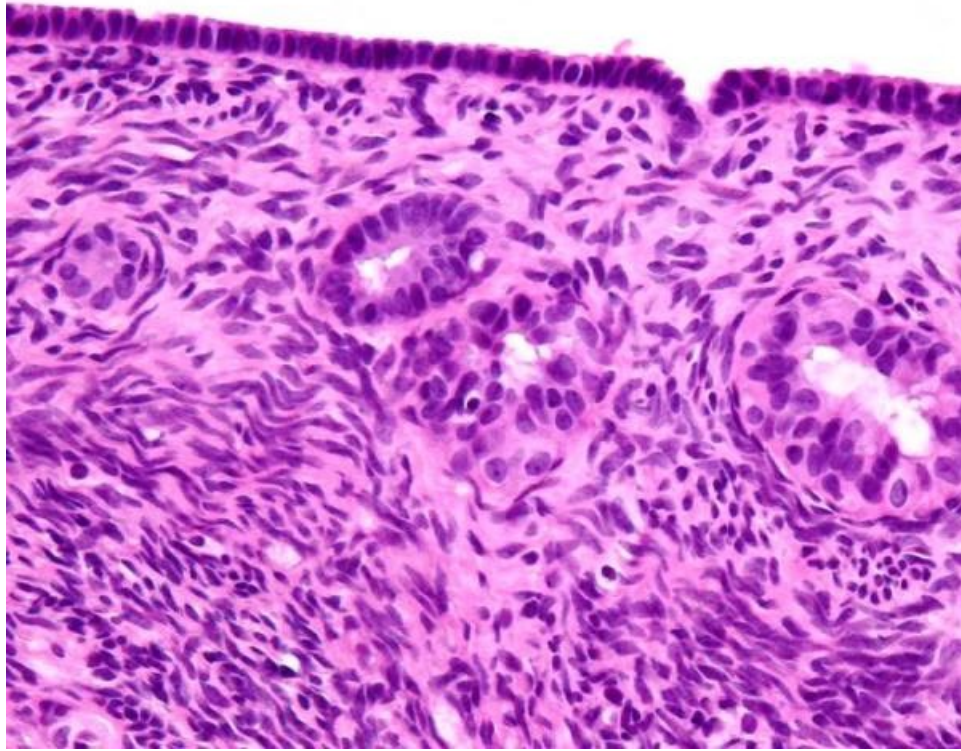
Simple cuboidal epithelium of intralobular duct

Examples:

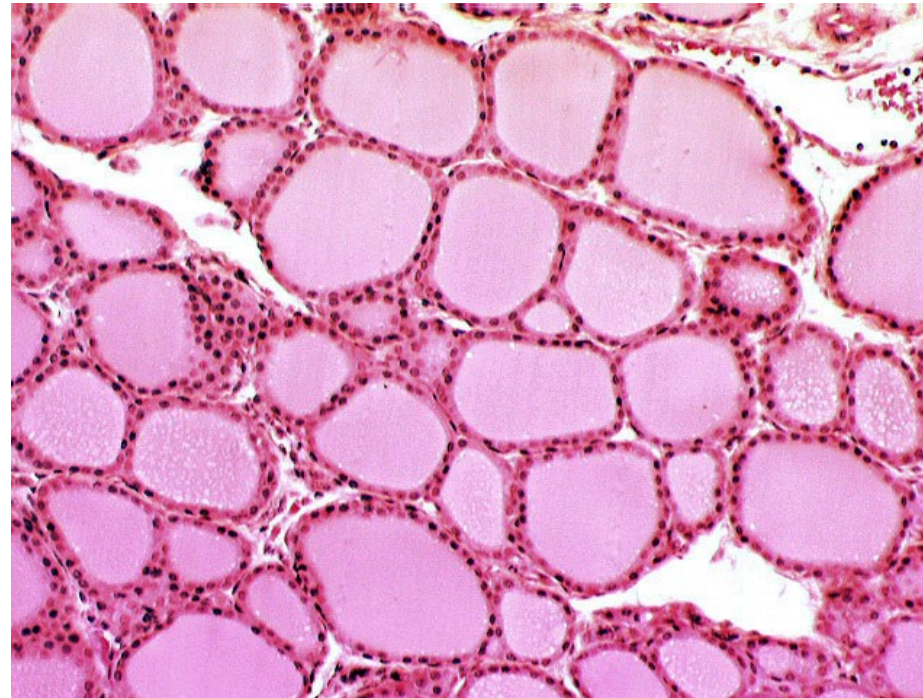
- Ovarian surface epithelium
- Renal tubules
- Thyroid
- Secretion acini

CLASSIFICATION OF EPITHELIAL TISSUE

Ovarian surface epithelium



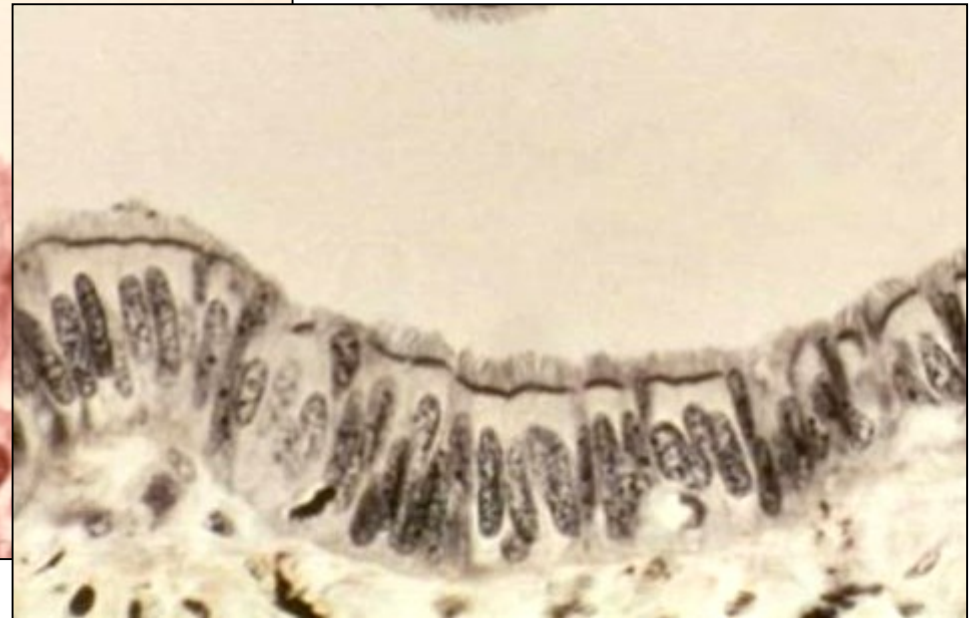
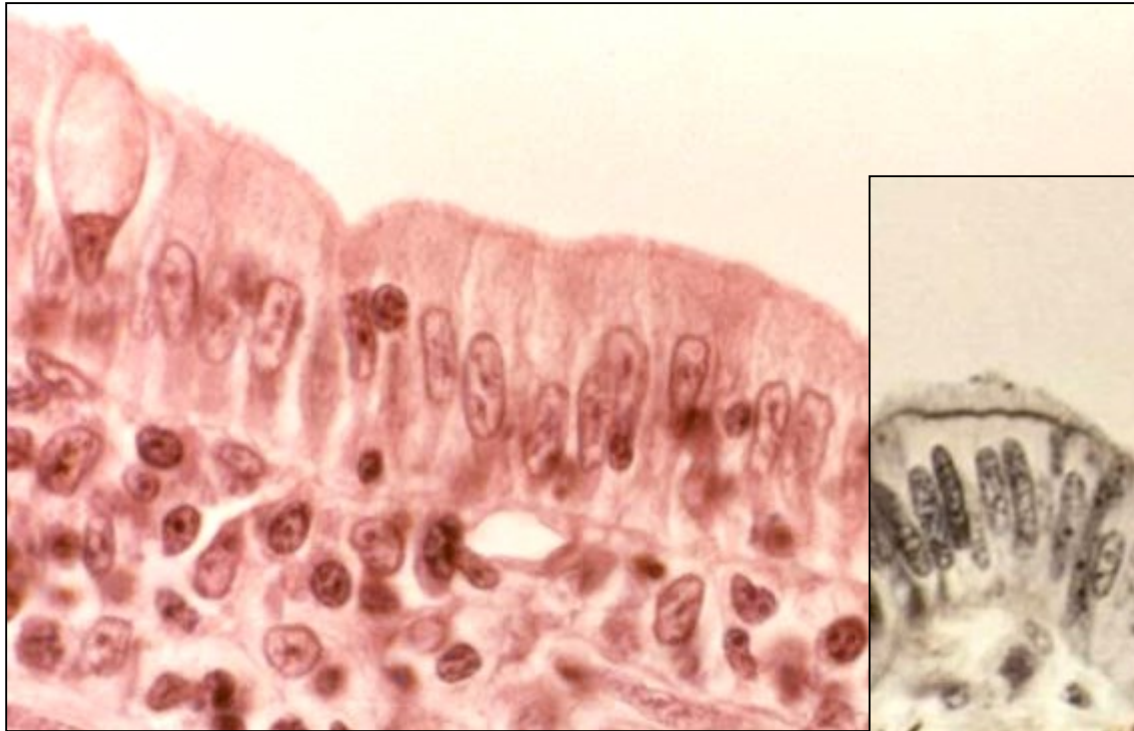
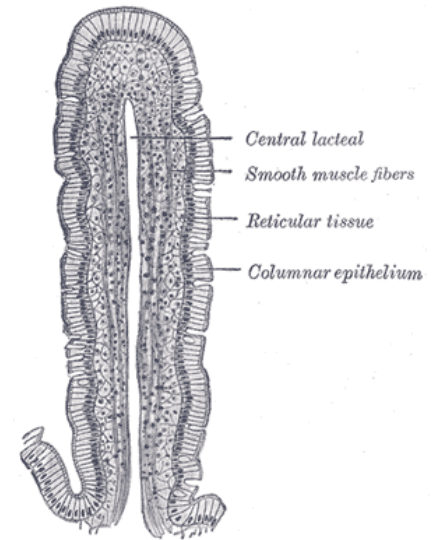
Thyroid follicles



CLASSIFICATION OF EPITHELIAL TISSUE

■ Simple columnar epithelium

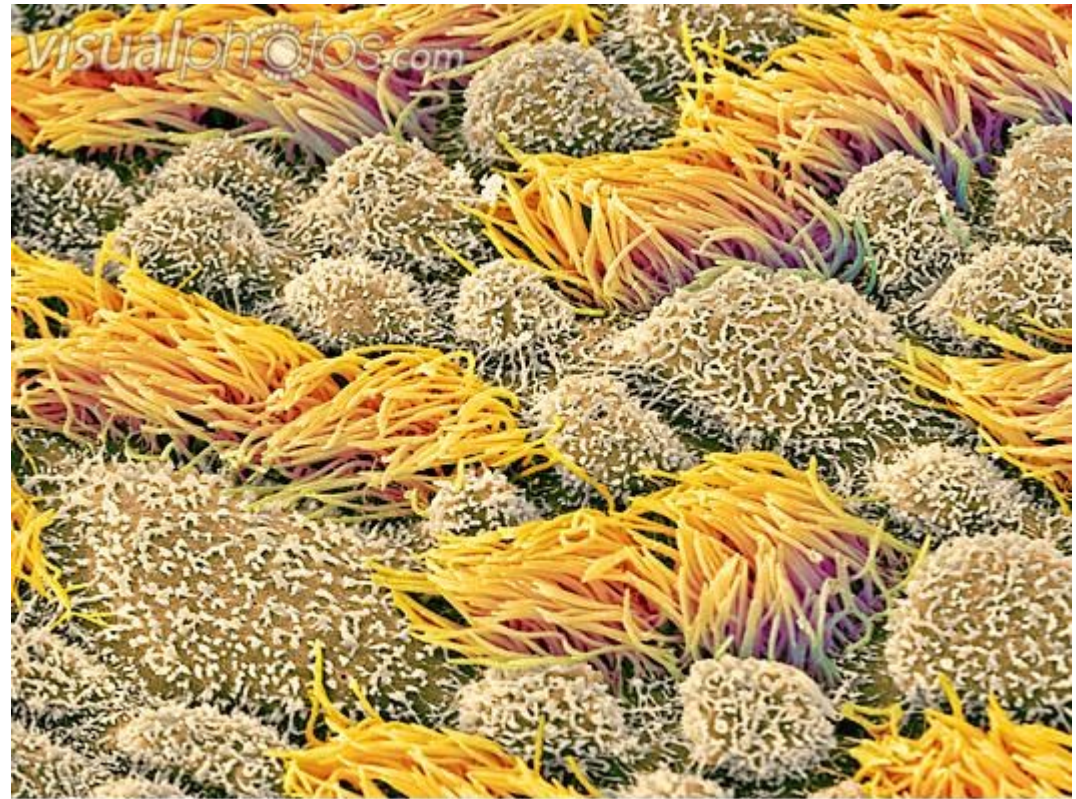
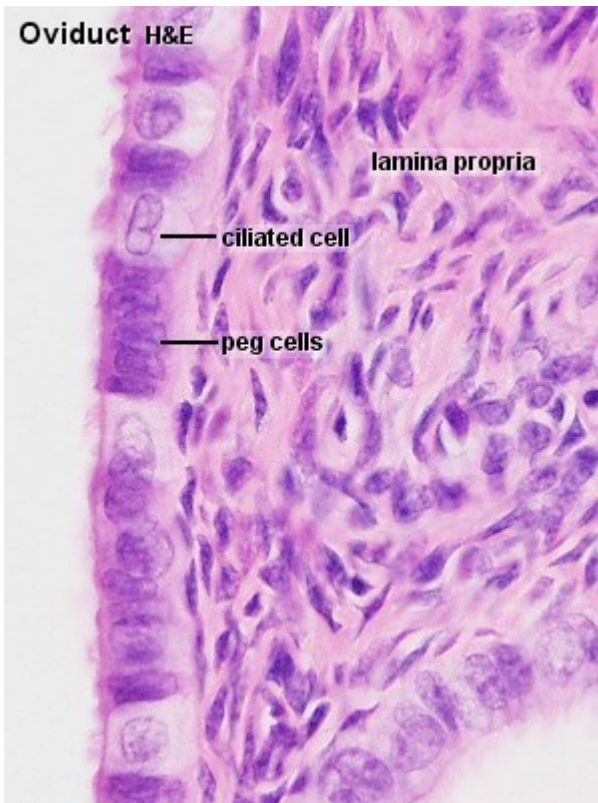
- Single layer of columnar cells with large, oval, basally located nucleus
- **Typical epithelium of GIT**
 - stomach
 - small and large intestine
 - gall bladder



■ Simple columnar epithelium with kinocilia

Uterine tube

- flow of the oocyte towards the uterus

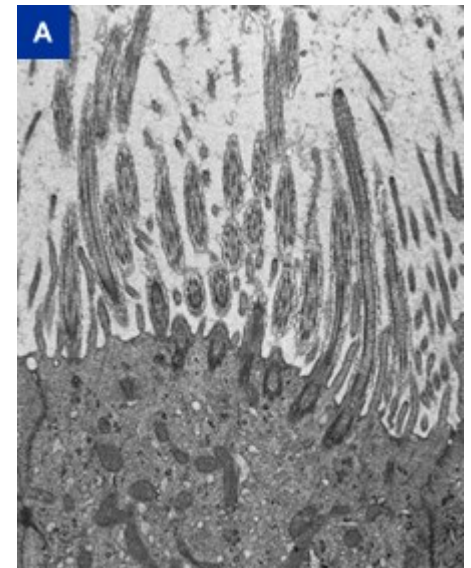
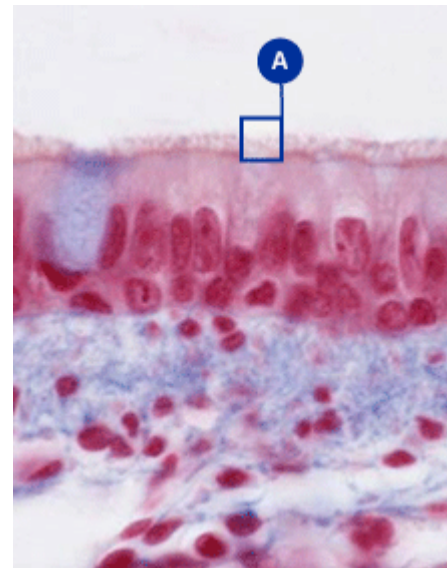
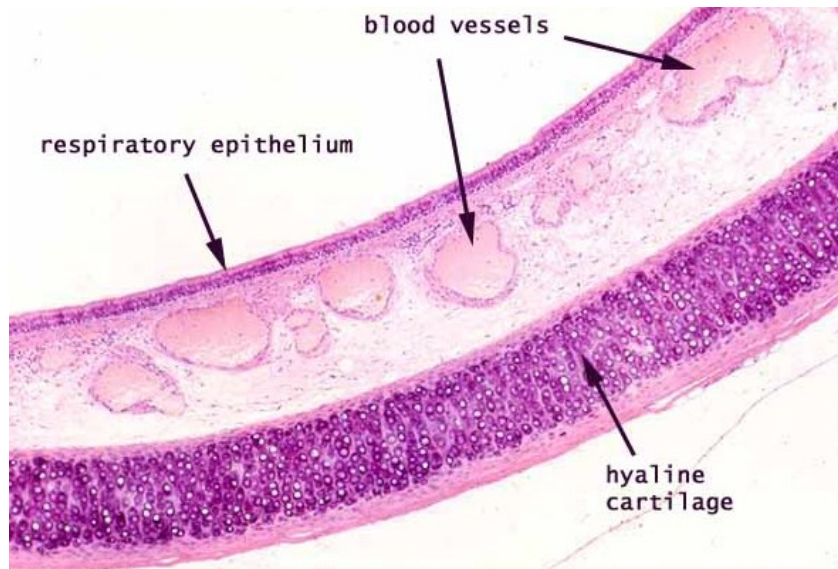


CLASSIFICATION OF EPITHELIAL TISSUE

■ Pseudostratified columnar epithelium with kinocilia and goblet cells

Upper respiratory passages

- Removal of mucus produced by epithelial glands

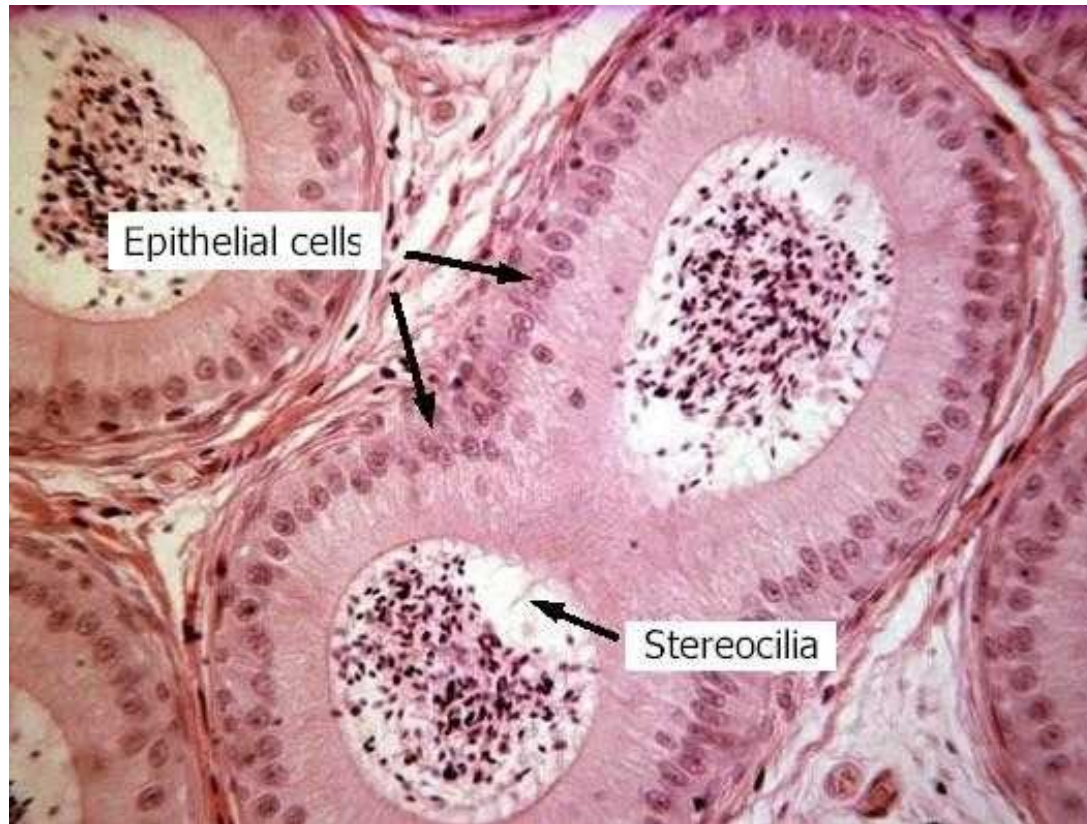


CLASSIFICATION OF EPITHELIAL TISSUE

■ Pseudostratified columnar epithelium with stereocilia

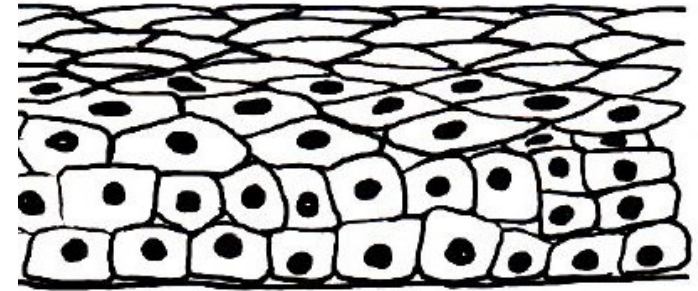
Male reproductive passages

- Epididymis
- Ductus deferens



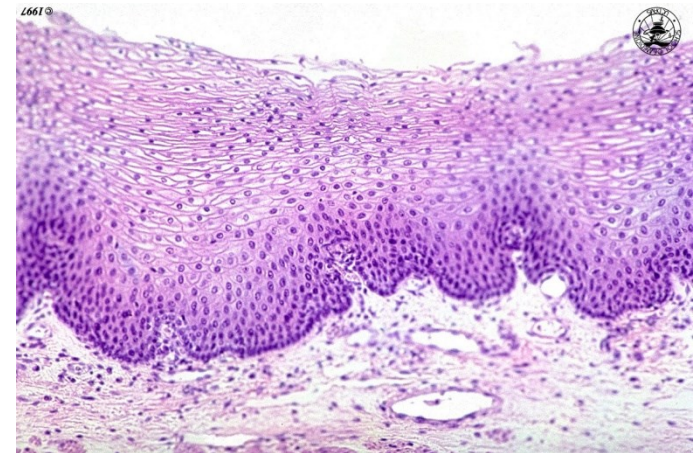
▪ Non-keratinized stratified squamous epithelium

- Multiple layers of cubic cells with centrally localized nuclei, flattening towards surface
 - Cells in the superficial layer viable
 - First layer in contact with BM, last layer – squamous
-
- Constant abrasion
 - Mechanical resilience
 - Protection from drying
 - Rapid renewal



Examples:

- Cornea
- Oral cavity and lips
- Esophagus
- Anal canal
- Vagina

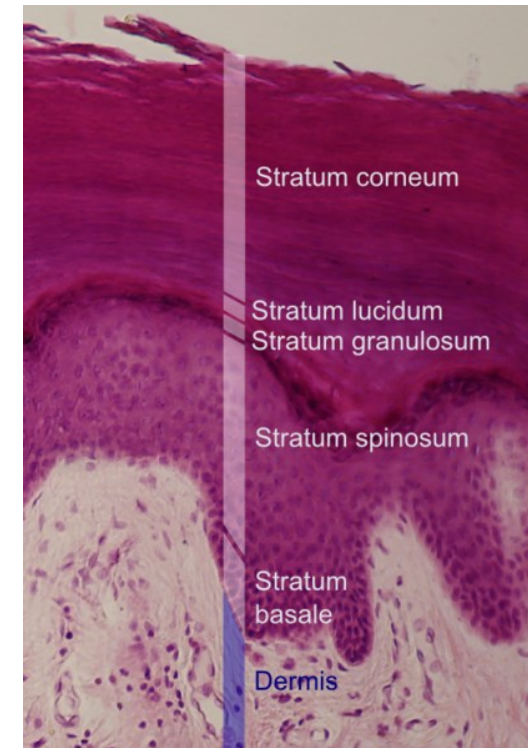
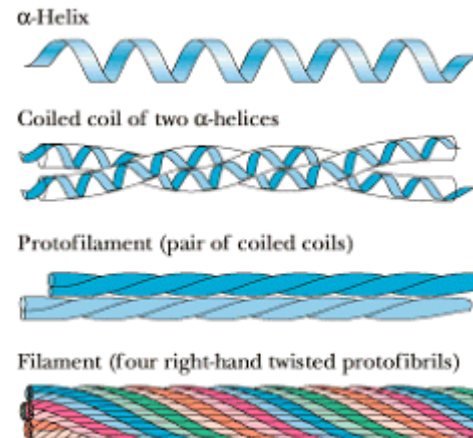
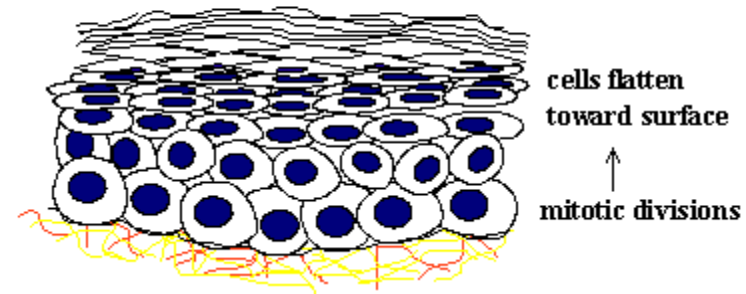


CLASSIFICATION OF EPITHELIAL TISSUE

■ Keratinized stratified squamous epithelium

- Cell in the superficial layer dead
- Skin (epidermis)
- Nail
- Keratins
 - Fibrous proteins, ~ 40 types
 - Intermediate filaments
 - Very stable, multimeric
 - Disorders of keratin expression – variety of clinical symptoms
 - e.g. Epidermolysis bullosa simplex (mutations in the genes encoding keratin 5 or keratin 14)

keratinized stratified squamous
dead, keratinized cells at surface

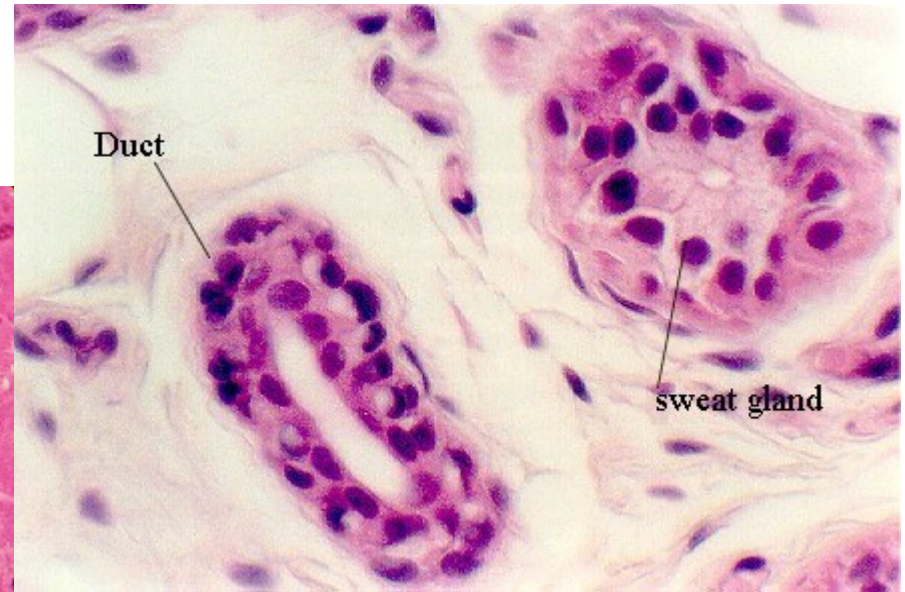
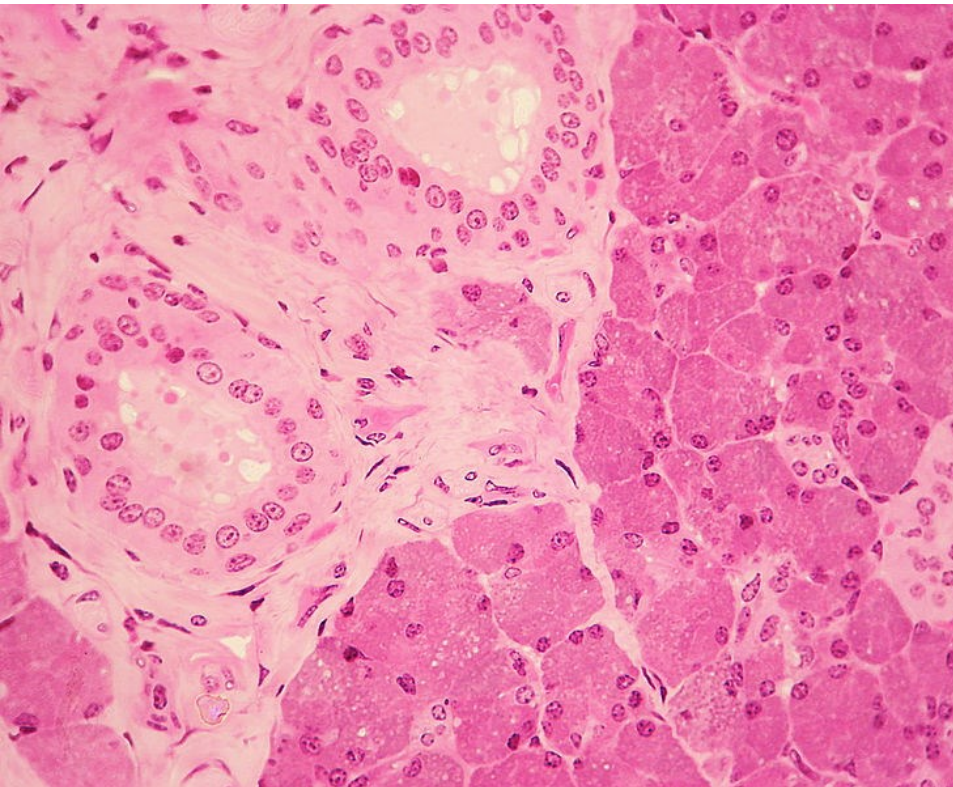


CLASSIFICATION OF EPITHELIAL TISSUE

■ Stratified cuboidal epithelium

Large ducts of:

- sweat glands
- mammary glands
- salivary glands



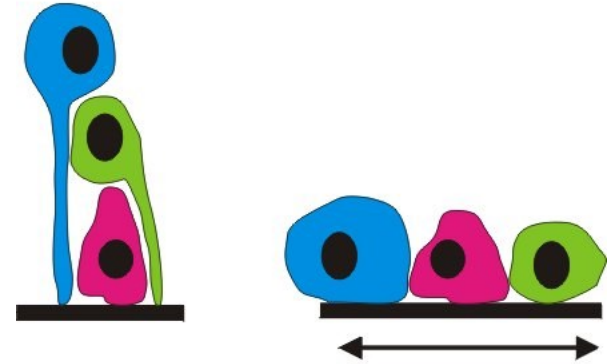
CLASSIFICATION OF EPITHELIAL TISSUE

■ Transitional epithelium (urothelium)

- fluctuation of volume
- organization of epithelial layers
- membrane reserve
- protection against hyperosmotic urine

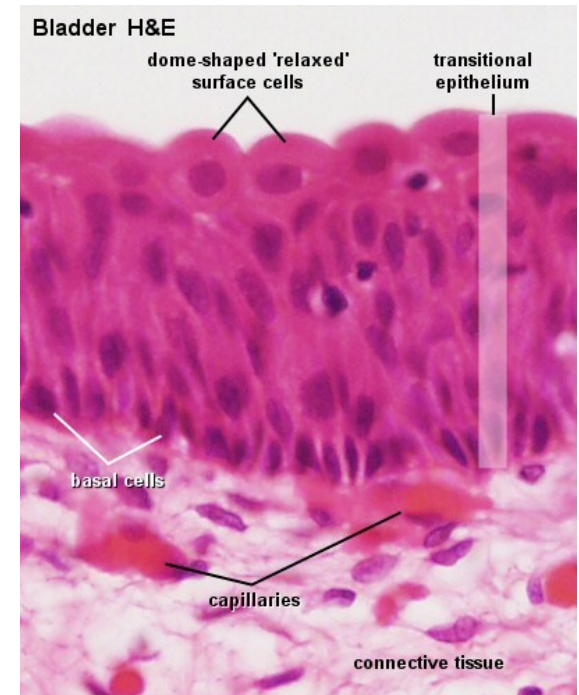
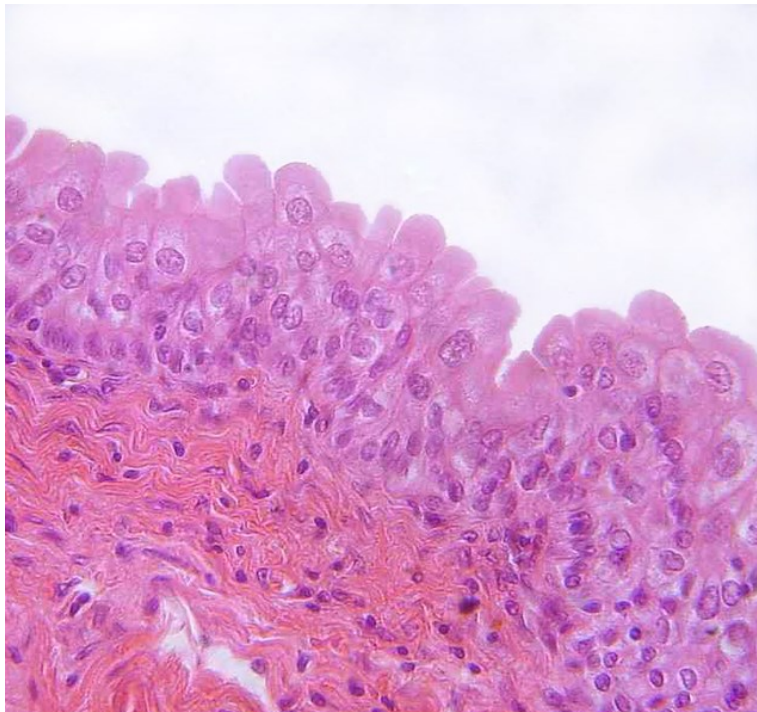
Urinary system

- urinary bladder, ureters, renal calyx and pelvis



Empty (relaxed): rather cuboidal cells with a domed apex
Full: flat, stretched

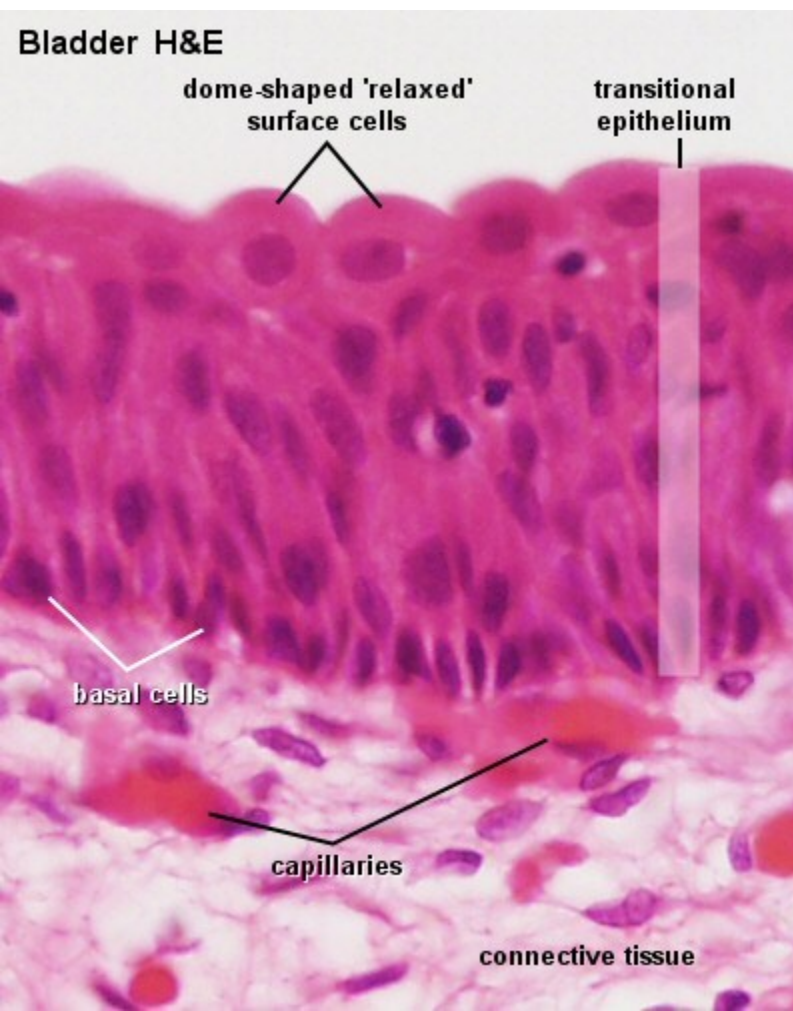
- Basal cells
- Intermediate layer
- Surface cells



CLASSIFICATION OF EPITHELIAL TISSUE

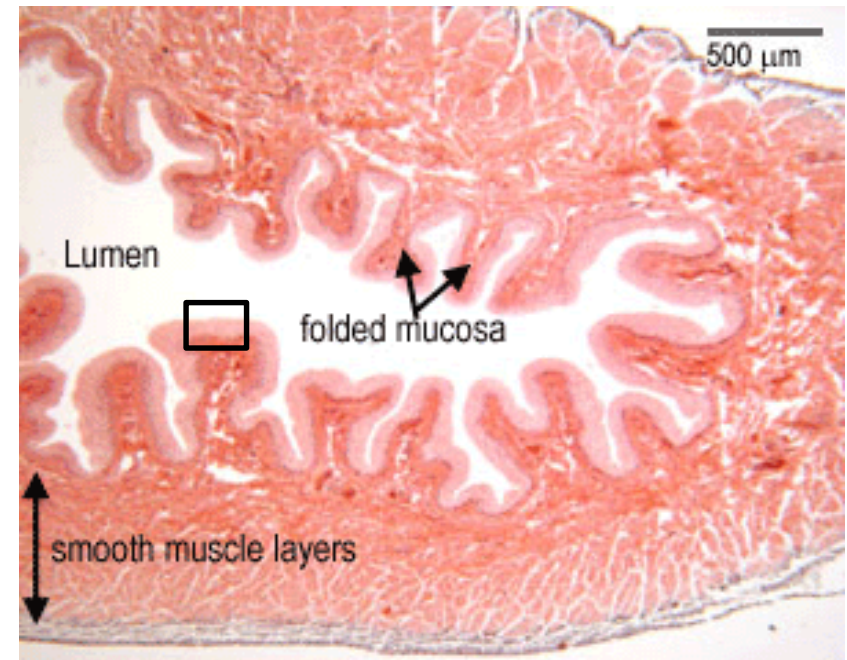
■ Transitional epithelium (urothelium)

- glycosaminoglycan layer (GAG) on the surface
- osmotic barrier
- antimicrobial properties



Barrier architecture:

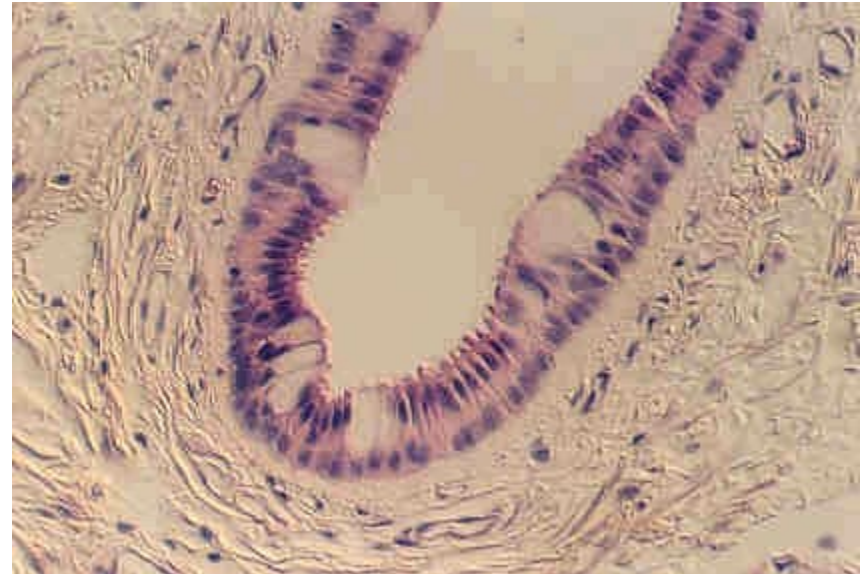
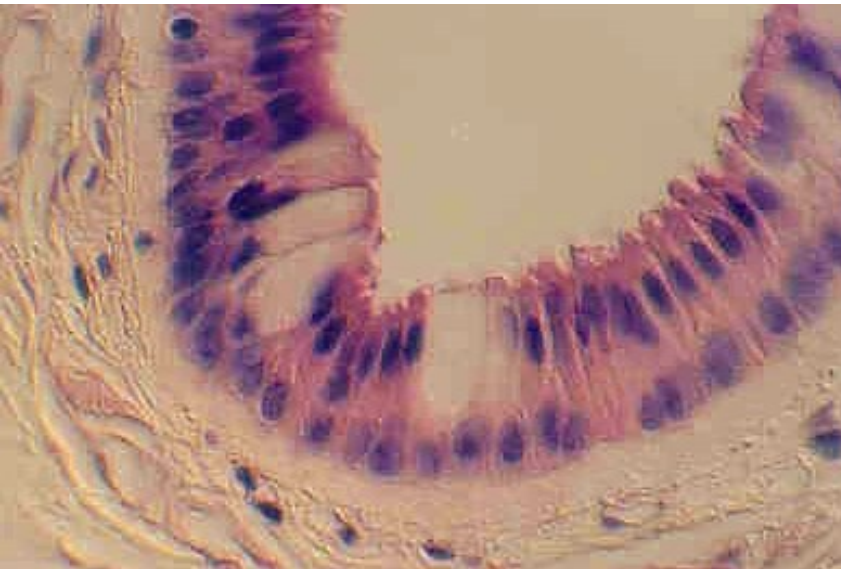
- GAG-layer
- surface cells (tight junctions), uroplakins proteins in the apical cell membrane
- subepithelial capillary network



■ Stratified columnar epithelia

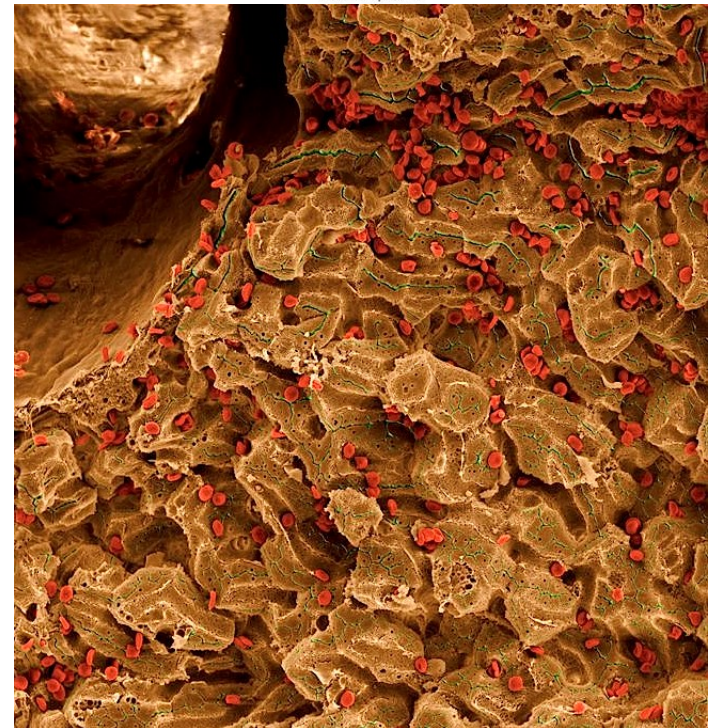
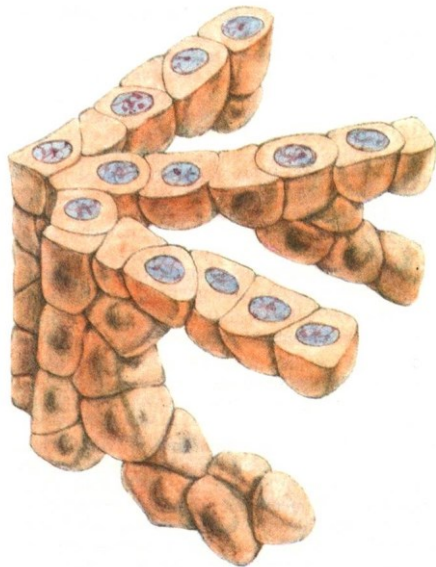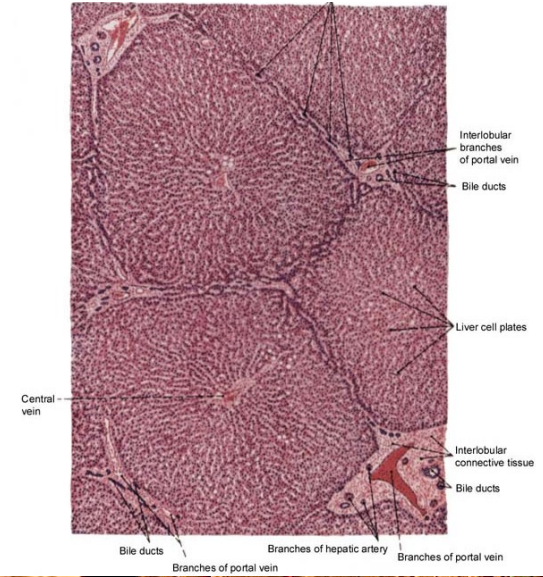
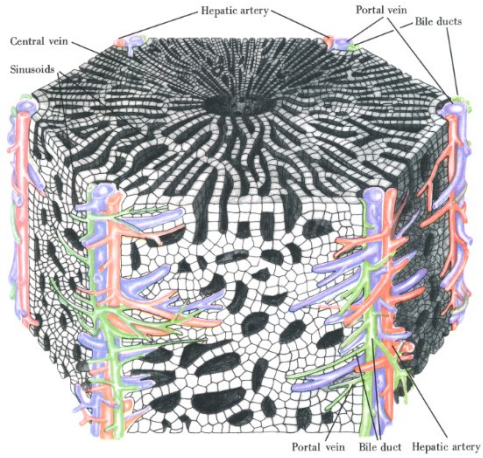
- several layers of columnar cells
- secretion / protection

- ocular conjunctiva
- pharynx, anus – transitions
- male urethra, vas deferens
- large ducts of salivary glands



CLASSIFICATION OF EPITHELIAL TISSUE

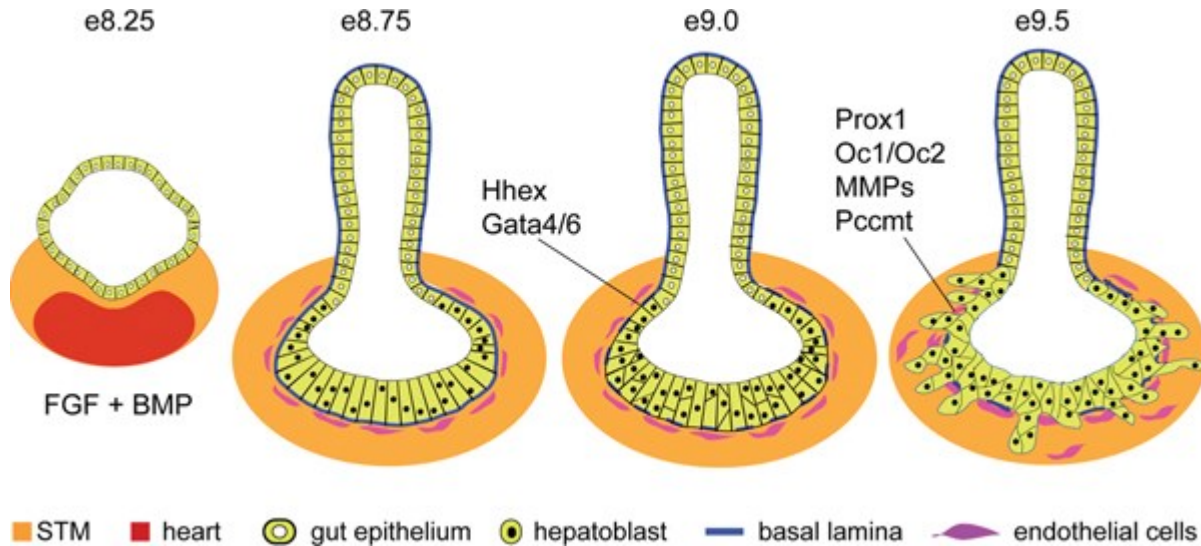
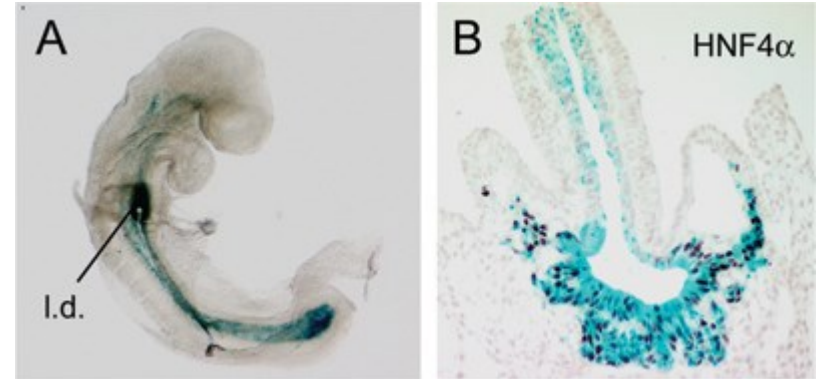
2) Trabecular epithelium



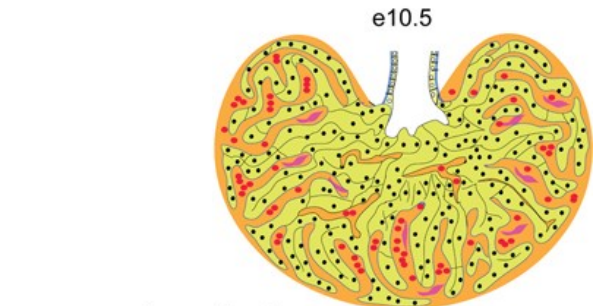
CLASSIFICATION OF EPITHELIAL TISSUE

▪ Liver

Trabecules of hepatocytes develop from sheet epithelial layer of primitive gut lining



hepatoblasts:
 BMPR, FGFR, c-Met, TGFR,
 Pi3K, Sek1/JNK, Elf5, Arf6, Raf1
 Smad2/3, β -catenin, c-jun, Tbx3, NF κ B
 Foxm1b, Xbp1, Mtf-1



mesenchyme signals:
 BMP, FGF, HGF, Wnt, TGF β , RA
 Gata4, WT1, N-myc, Hlx, Lhx2

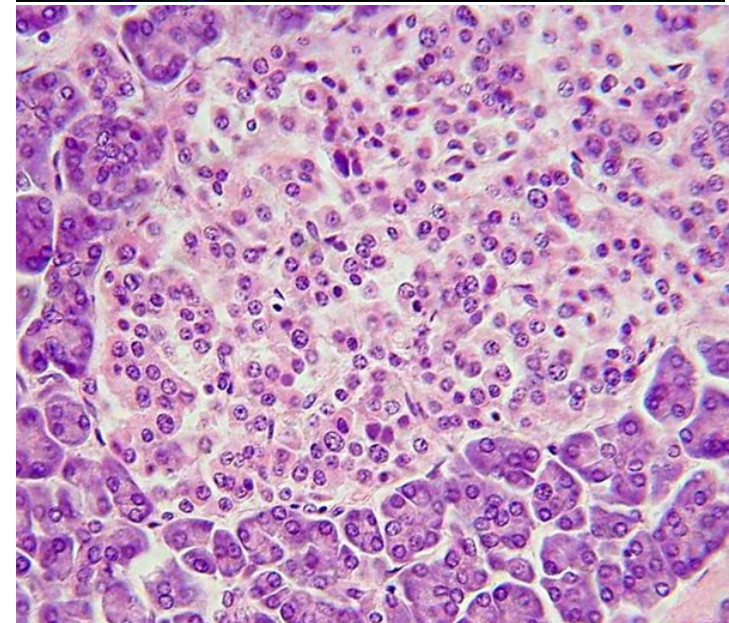
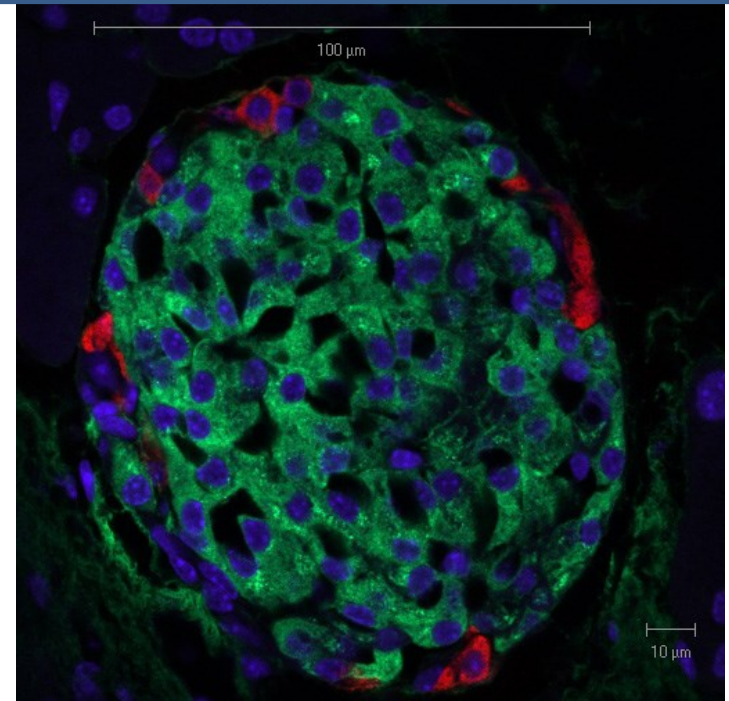
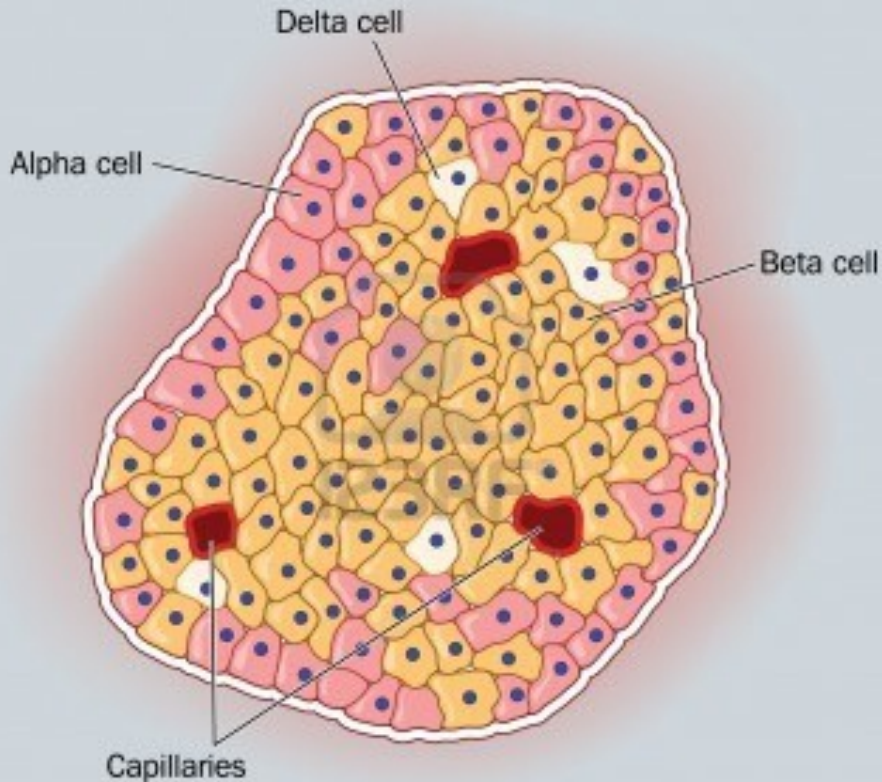
Legend for e10.5 diagram:
 orange STM, yellow hepatoblast, red blood cells, purple endothelial cells

CLASSIFICATION OF EPITHELIAL TISSUE

- Endocrine glands

Islets of Langerhans

Cords of endocrine active cells

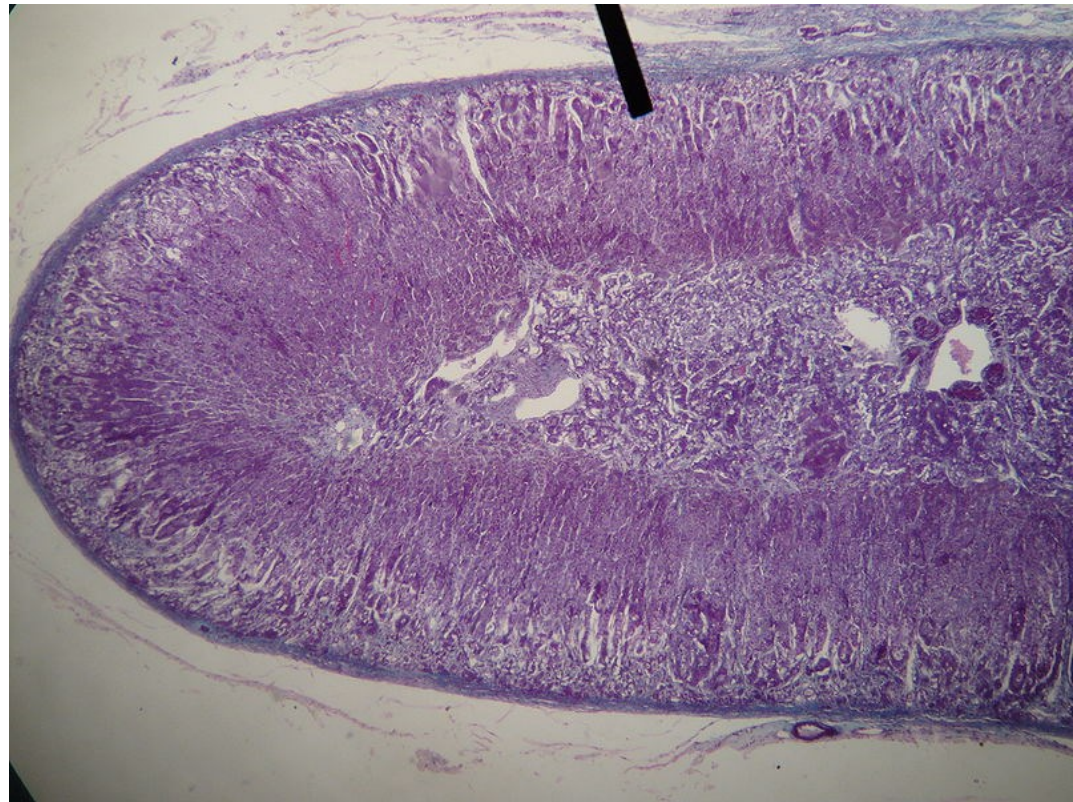
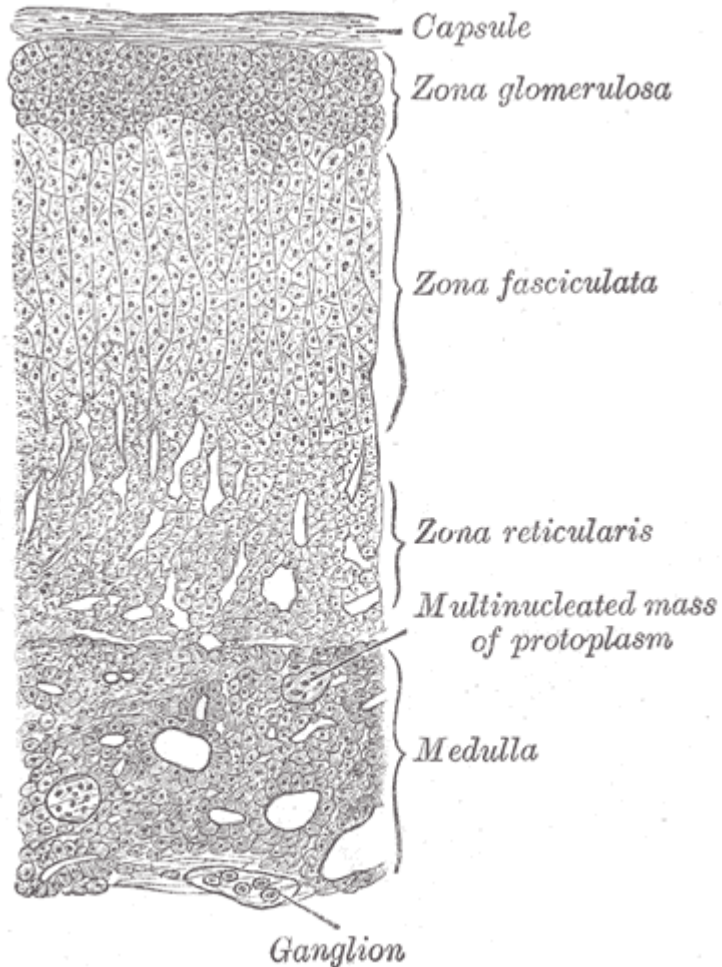


CLASSIFICATION OF EPITHELIAL TISSUE

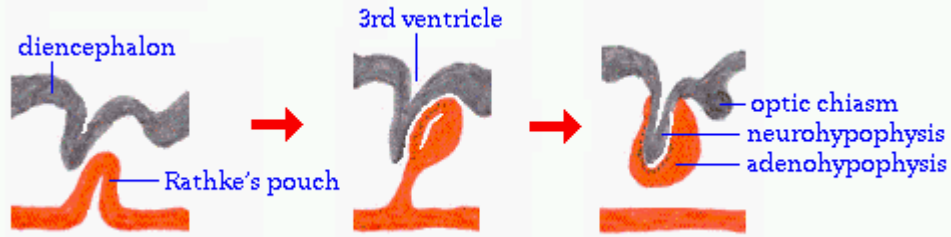
- **Endocrine glands**

Adrenal cortex

Cortex of adrenal gland – epithelial cells in cords secreting corticoid

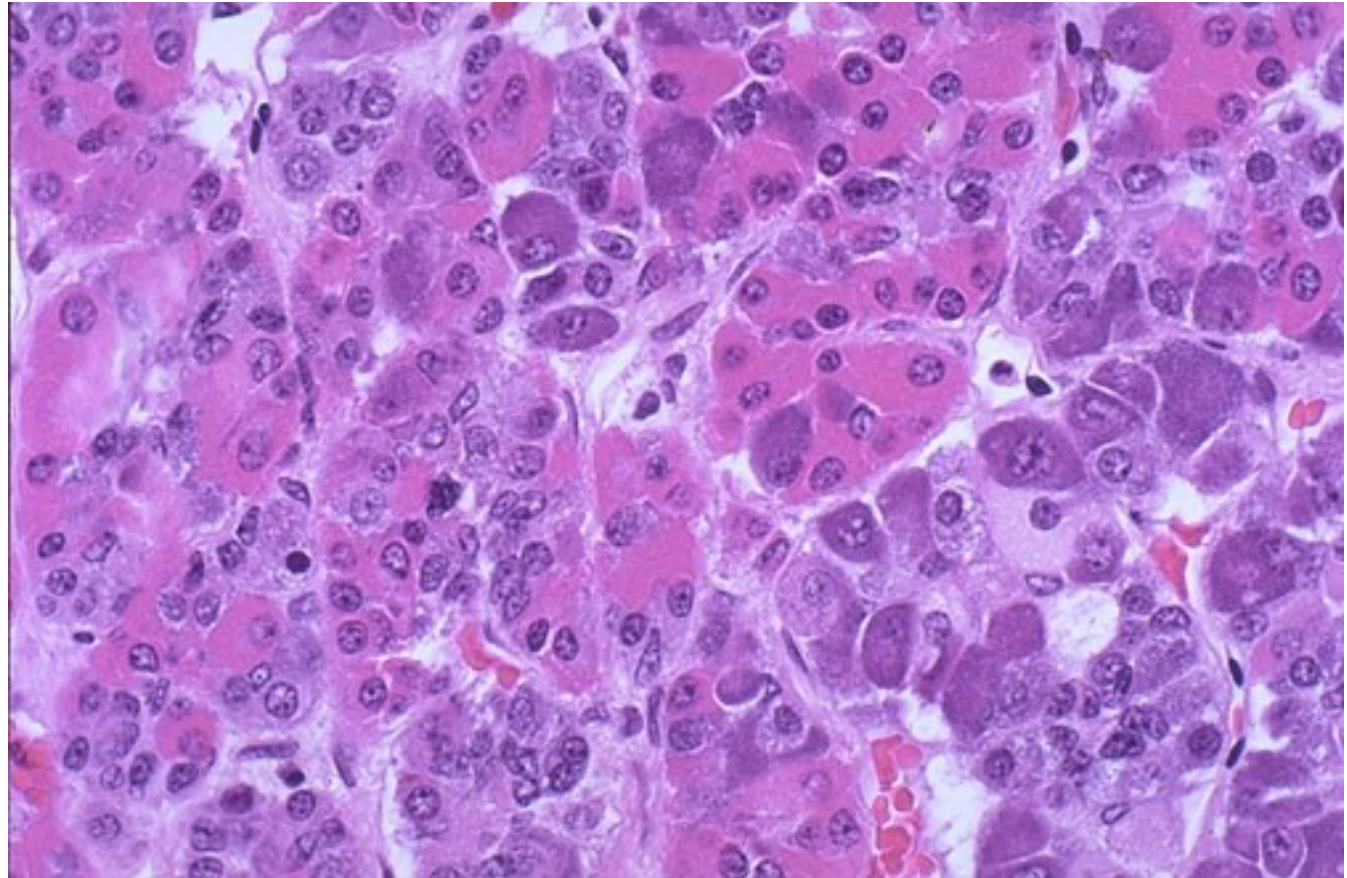


CLASSIFICATION OF EPITHELIAL TISSUE



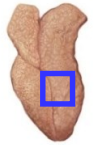
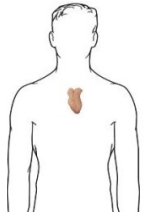
- **Endocrine glands**

Adenohypophysis – anterior pituitary

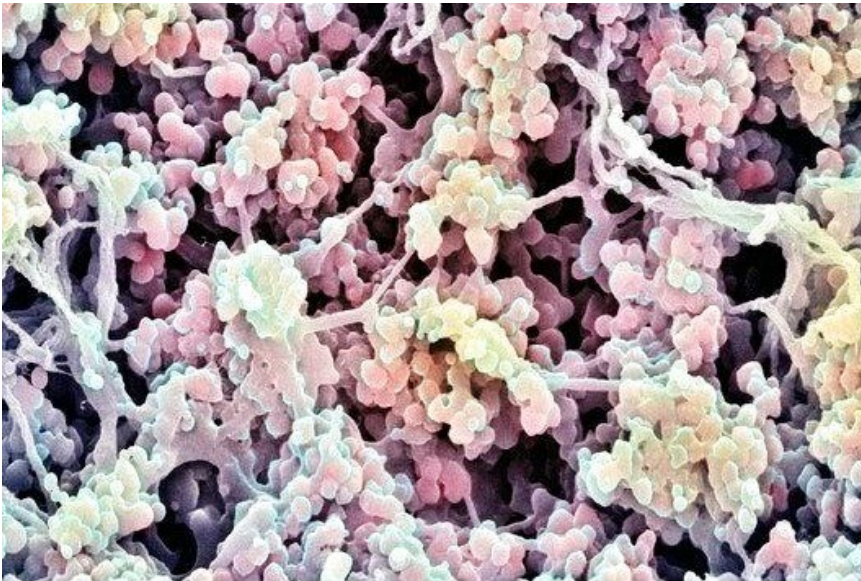
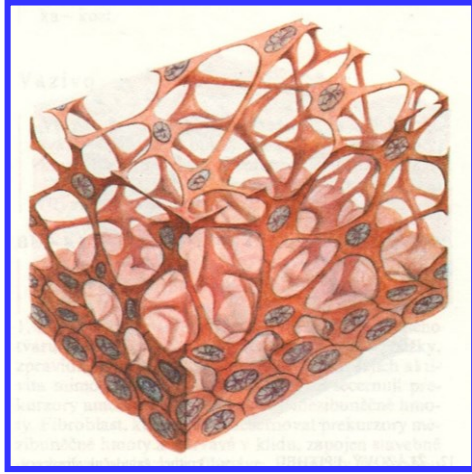


CLASSIFICATION OF EPITHELIAL TISSUE

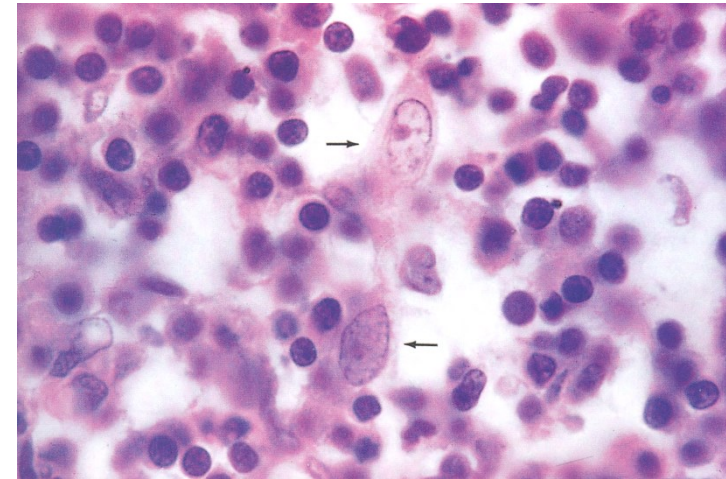
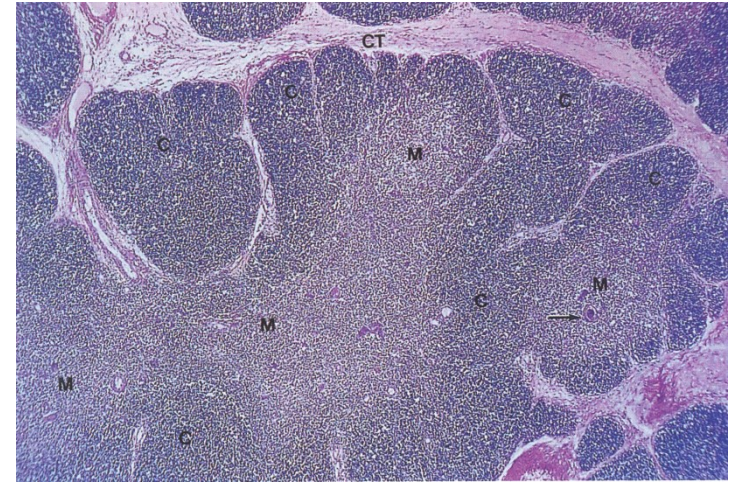
Thymus - cytotretikulum



Thymus gland

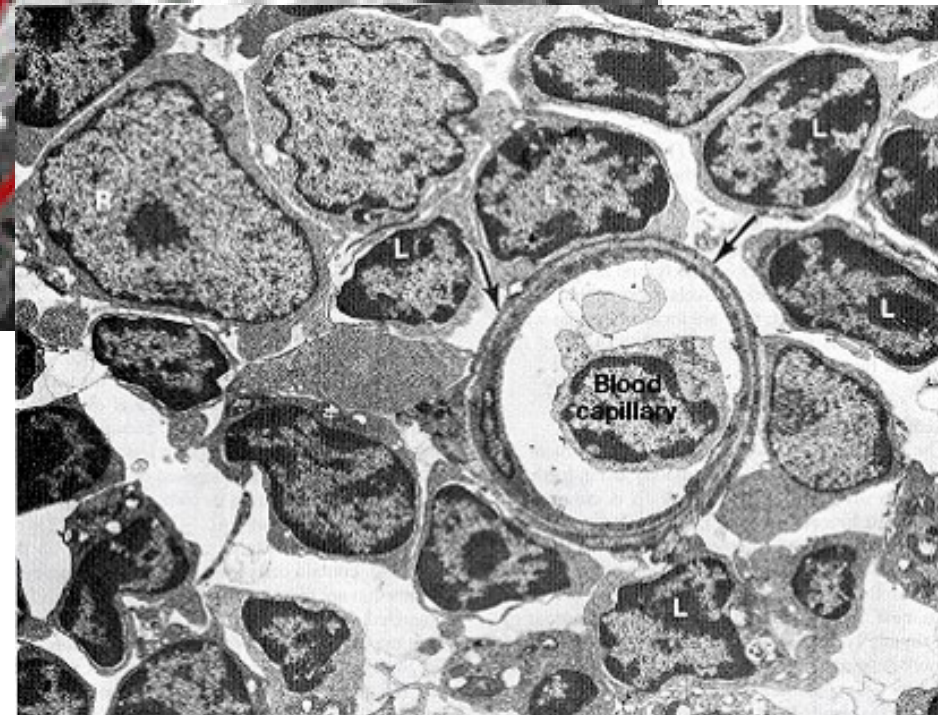



p248250 [RM] © www.visualphotos.com



- Compartments and microenvironment for T-cell development and selection
- Blood-thymus barrier

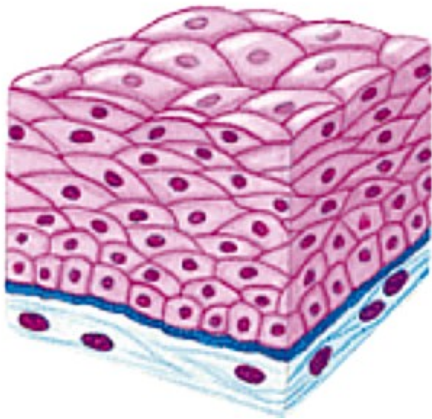
CLASSIFICATION OF EPITHELIAL TISSUE



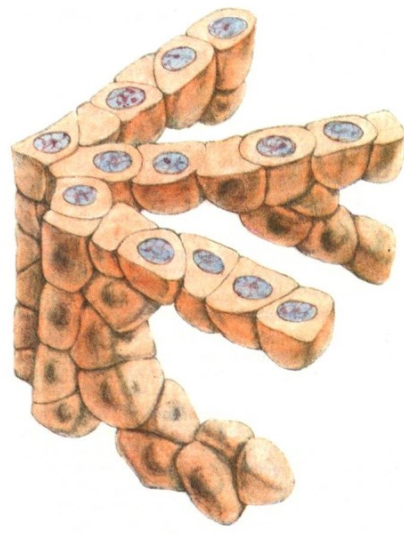Epithelial reticular (epithelioreticular) cells:

Structural and functional support for developing T-lymphocytes

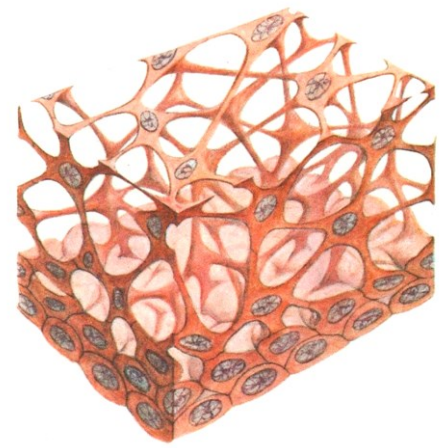
SUMMARY



Sheet



Trabecular



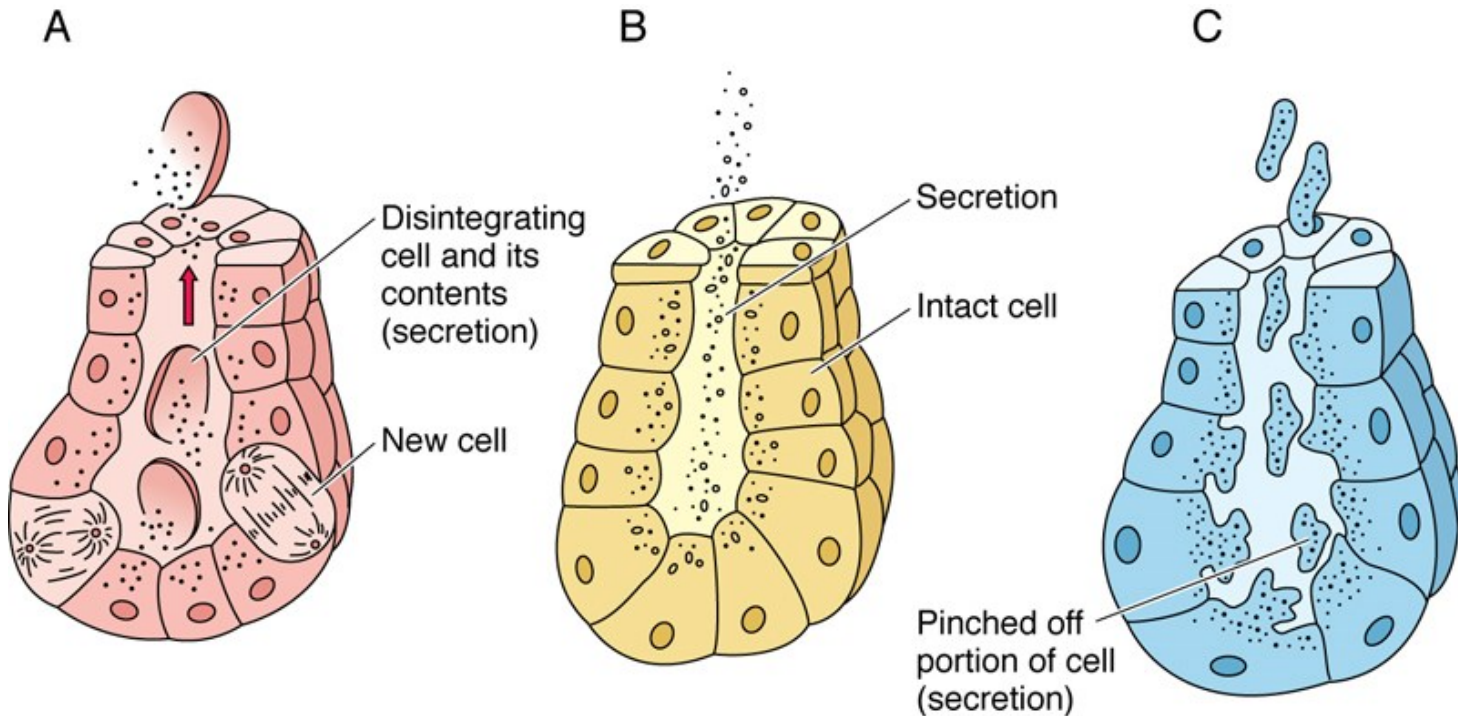
Reticular

Classification by function

CLASSIFICATION OF EPITHELIAL TISSUE

Ways of secretion

- Secretion ↔ excretion
- Process of secretion:

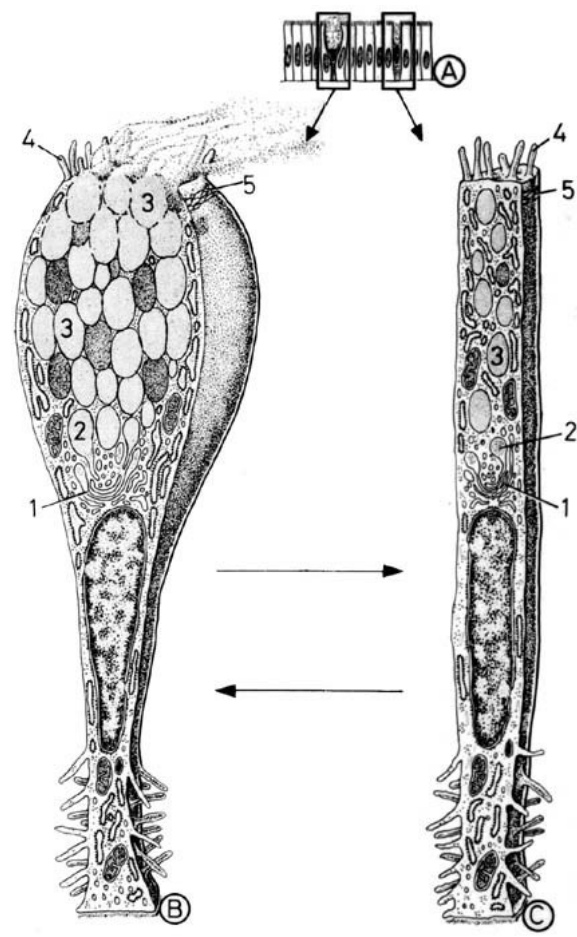
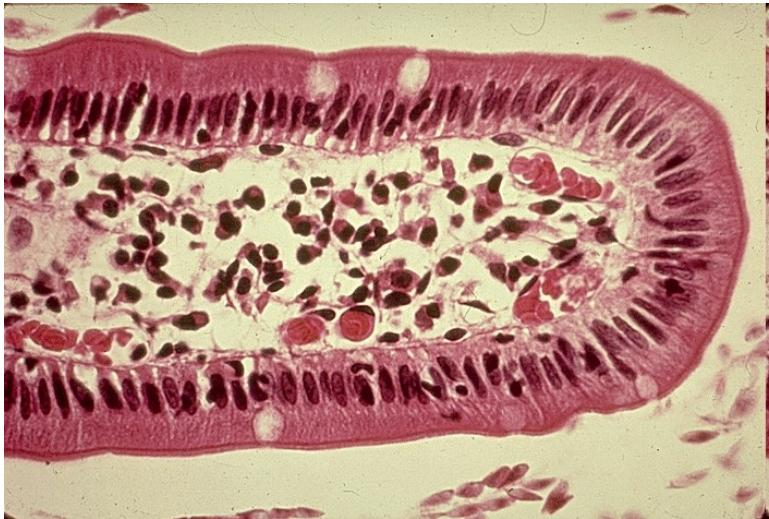


Holocrine × Merocrine × Apocrine

GLANDULAR EPITHELIUM

■ Single cell glands

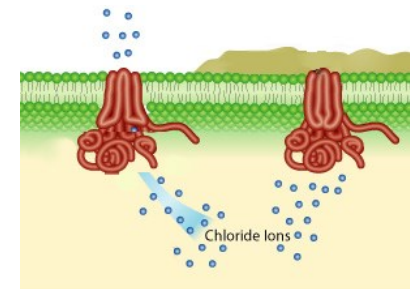
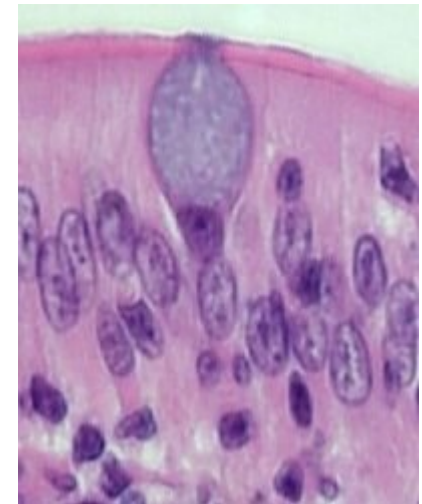
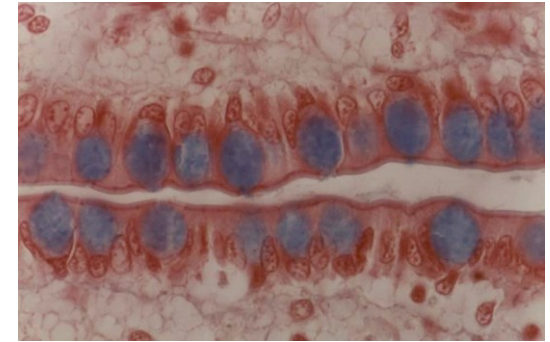
- Goblet
- Enteroendocrine



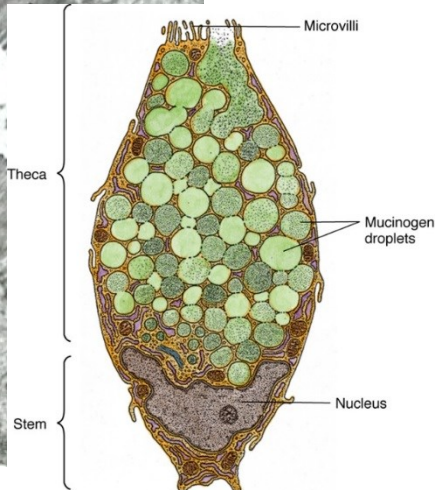
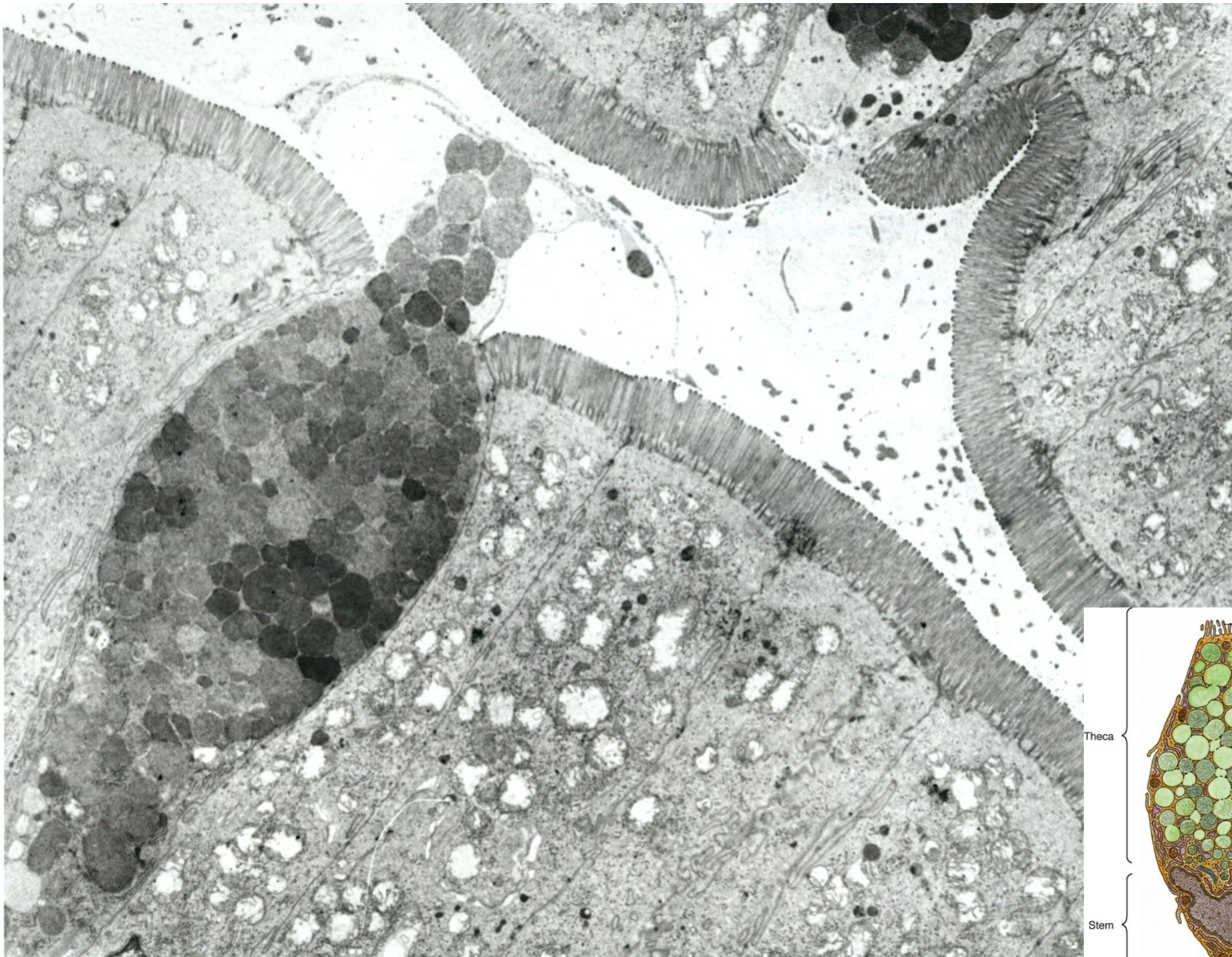
GLANDULAR EPITHELIUM

■ Goblet cells

- Mainly respiratory and intestinal tract
- Produce mucus = viscous fluid composed of electrolytes and highly glycosylated glycoproteins (mucins)
- Protection against mechanic shear or chemical damage
- Trapping and elimination of particular matter
- Secretion by secretory granules constitutive or stimulated
- After secretion mucus expands extremely – more than 500-fold in 20ms
- Dramatic changes in hydration and ionic charge
- Chronic bronchitis or cystic fibrosis – hyperplasia or metaplasia of goblet cells



GOBLET CELL

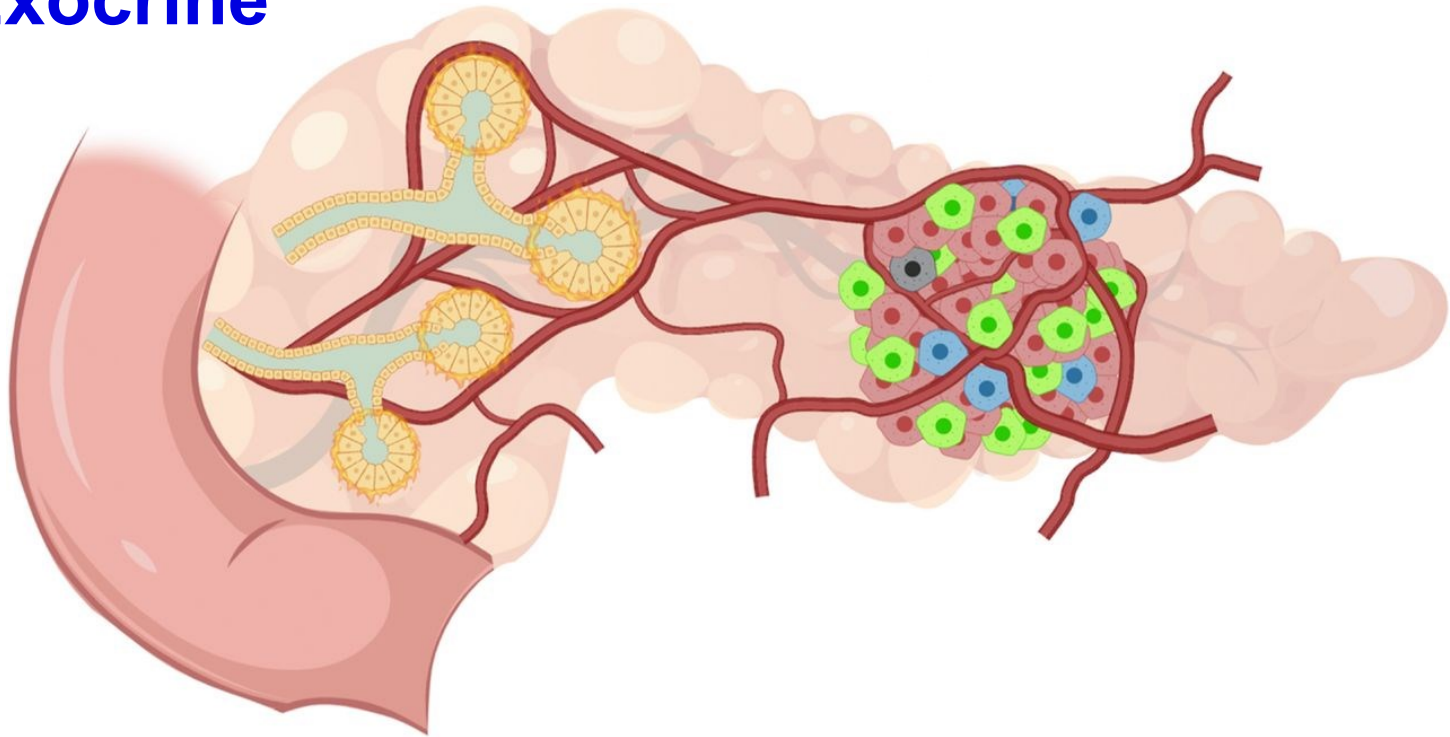


GLANDULAR EPITHELIUM

- Multicellular glands

Exocrine

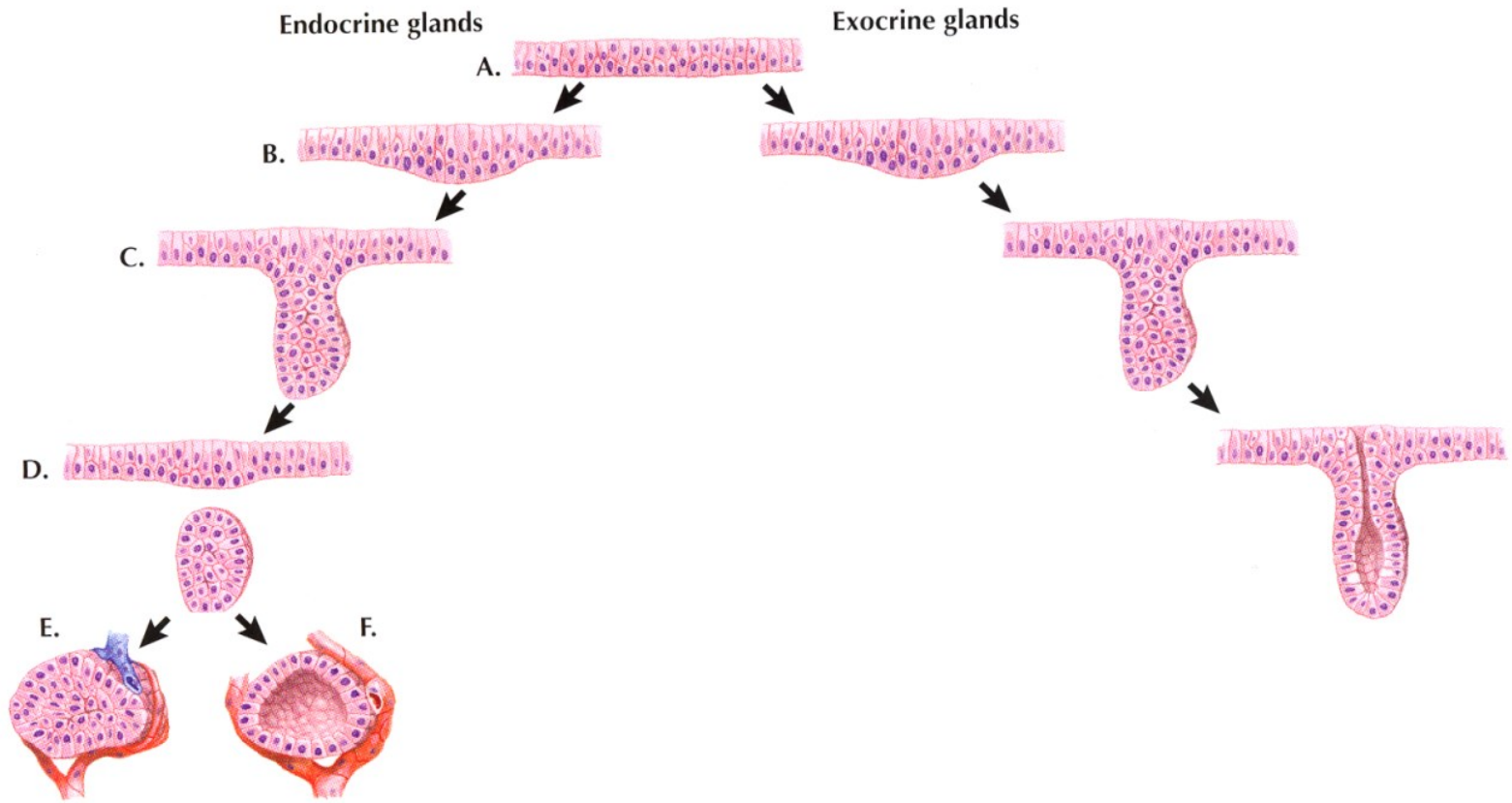
Endocrine



GLANDULAR EPITHELIUM

■ Development of multicellular glands

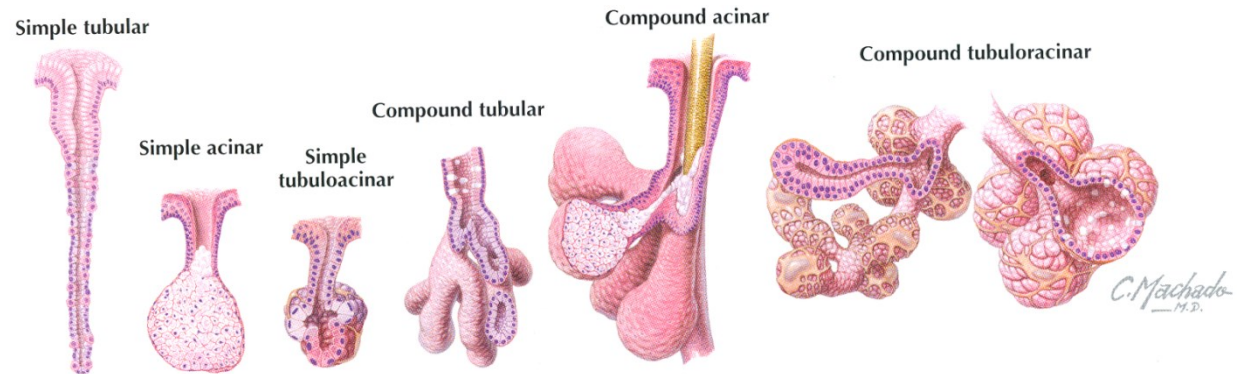
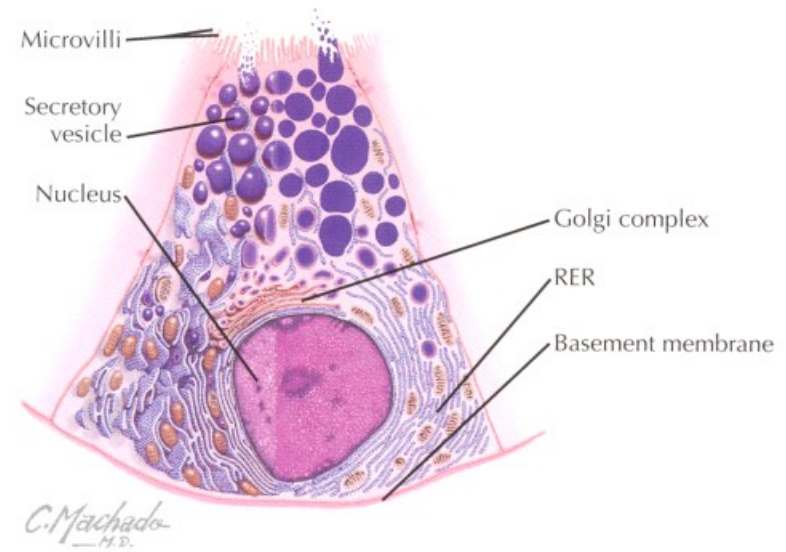
– Endocrine vs. exocrine



GLANDULAR EPITHELIUM

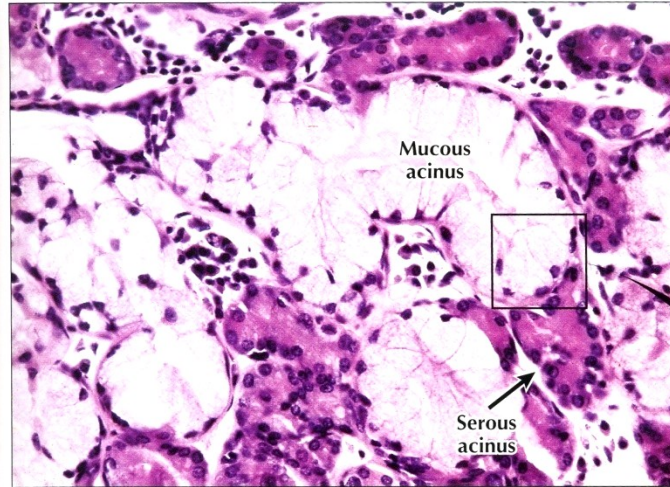
■ Exocrine multicellular glands

- Shape of secretion part
 - Alveolar (acinar)
 - Tubular
 - Tubuloalveolar (tubuloacinar)
- Branching
 - Simple
 - Branched
 - Compound
- Secretion
 - Mucous
 - Serous
 - Compound



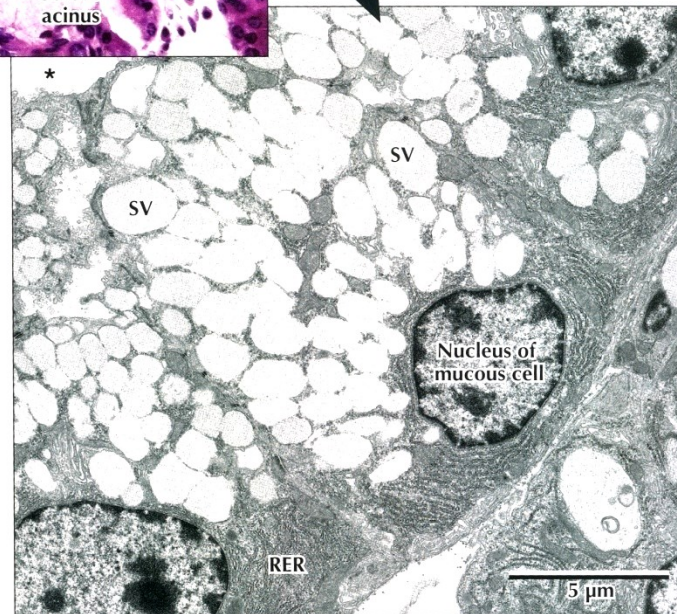
GLANDULAR EPITHELIUM

■ Mucous glands



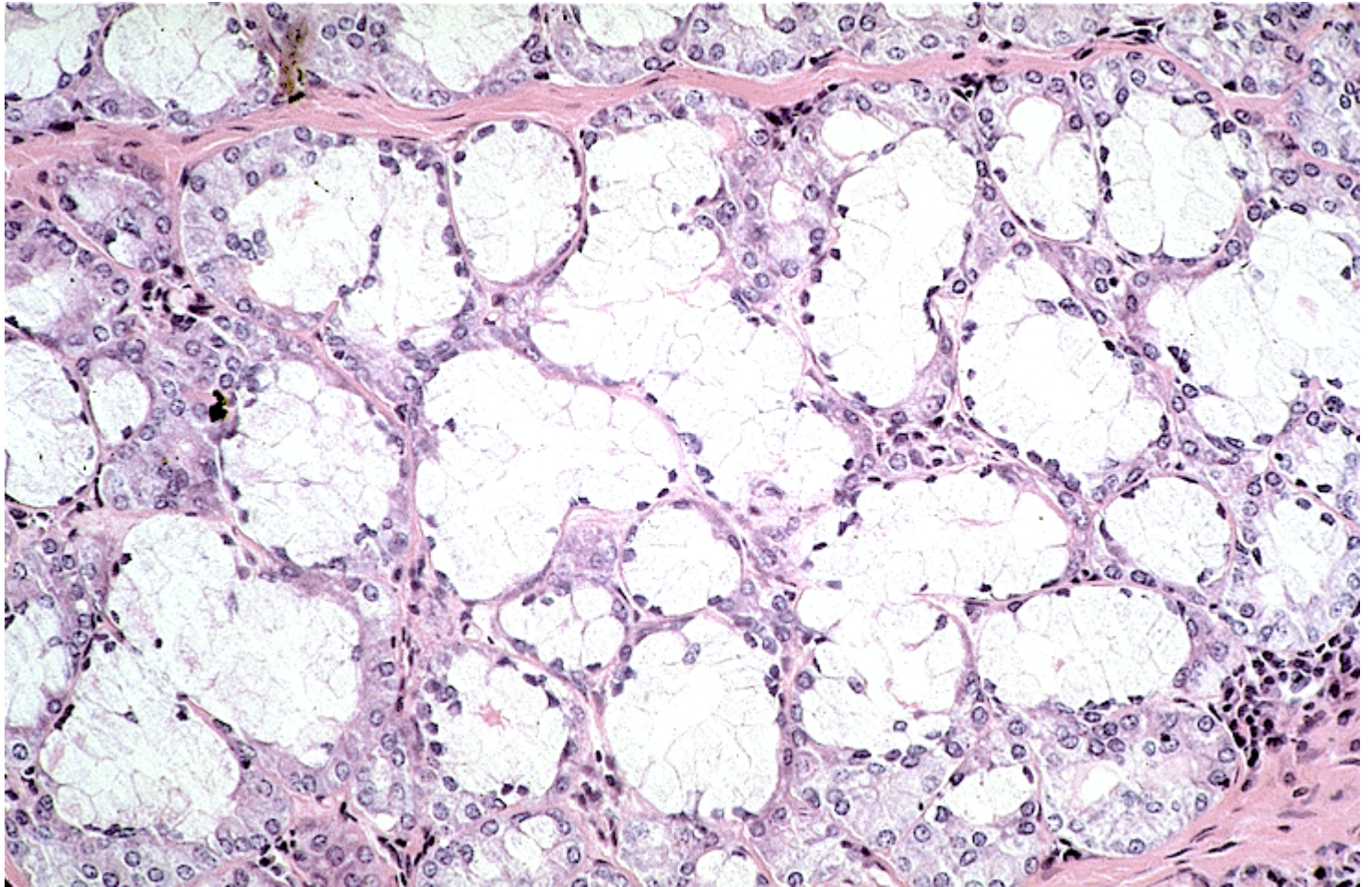
◀ **LM of part of a mixed seromucous gland in the trachea.** Several mucous acini with pale-stained mucous cells are seen. The basal nuclei are flat, and cells appear washed out because mucous droplets dissolved during specimen preparation. Darker stained serous cells in adjacent acini have more rounded basal nuclei. Serous cells are smaller than mucous cells. The square outlines the area of interest seen in the EM below. 295 \times . H&E.

▶ **EM of part of a mucous acinus in a mixed salivary gland.** Parts of three mucous cells line the acinus lumen (*). Euchromatic basal nuclei have prominent nucleoli. Basal cytoplasm contains many profiles of rough endoplasmic reticulum (RER). Many large, electron-lucent secretory vesicles (SV) dominating the remaining cytoplasm are discharged by exocytosis into the acinus lumen. 5400 \times .



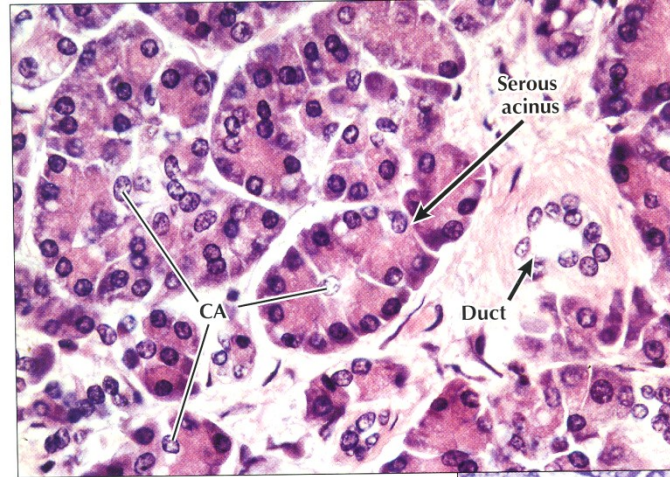
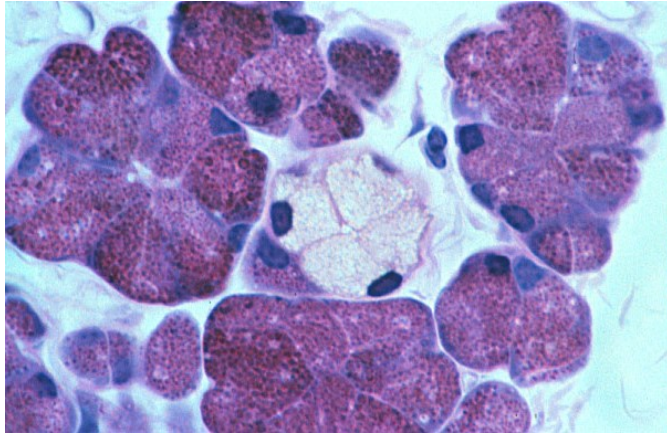
GLANDULAR EPITHELIUM

- Mucous glands

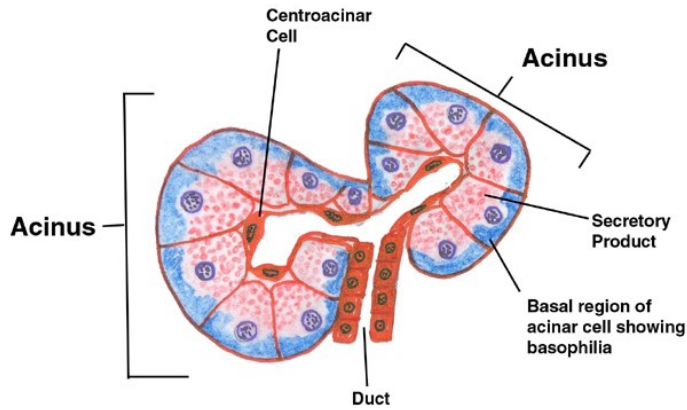


GLANDULAR EPITHELIUM

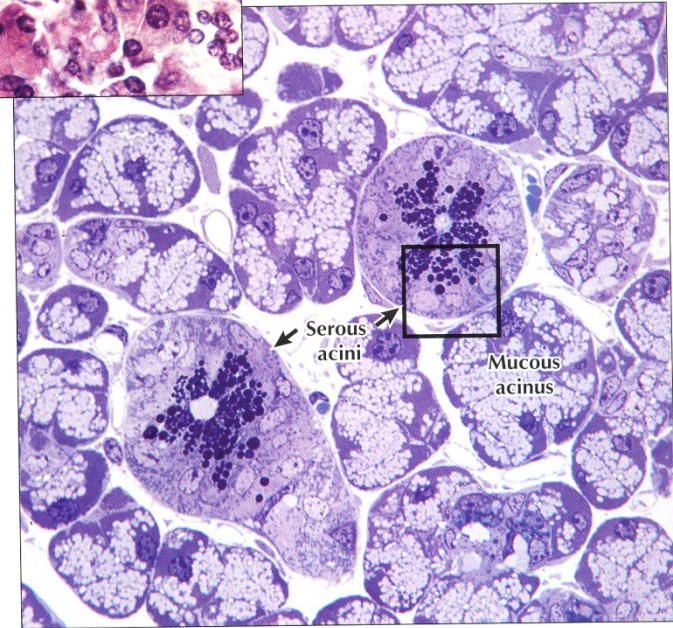
■ Serous glands



◀ **LM of part of the exocrine pancreas.** The exocrine part of the gland consists of closely packed spherical or pear-shaped serous acini. Several columnar to pyramidal acinar cells, with round basal nuclei, face a small central lumen in each **serous acinus**. Basal cytoplasm is basophilic; apical cytoplasm is more eosinophilic. Small clear centroacinar cells (**CA**) in acini centers help distinguish this purely serous gland from others, such as the parotid salivary gland. A small **duct**, in the connective tissue stroma, conveys secretions from acini to larger pancreatic ducts. 385 \times . H&E.

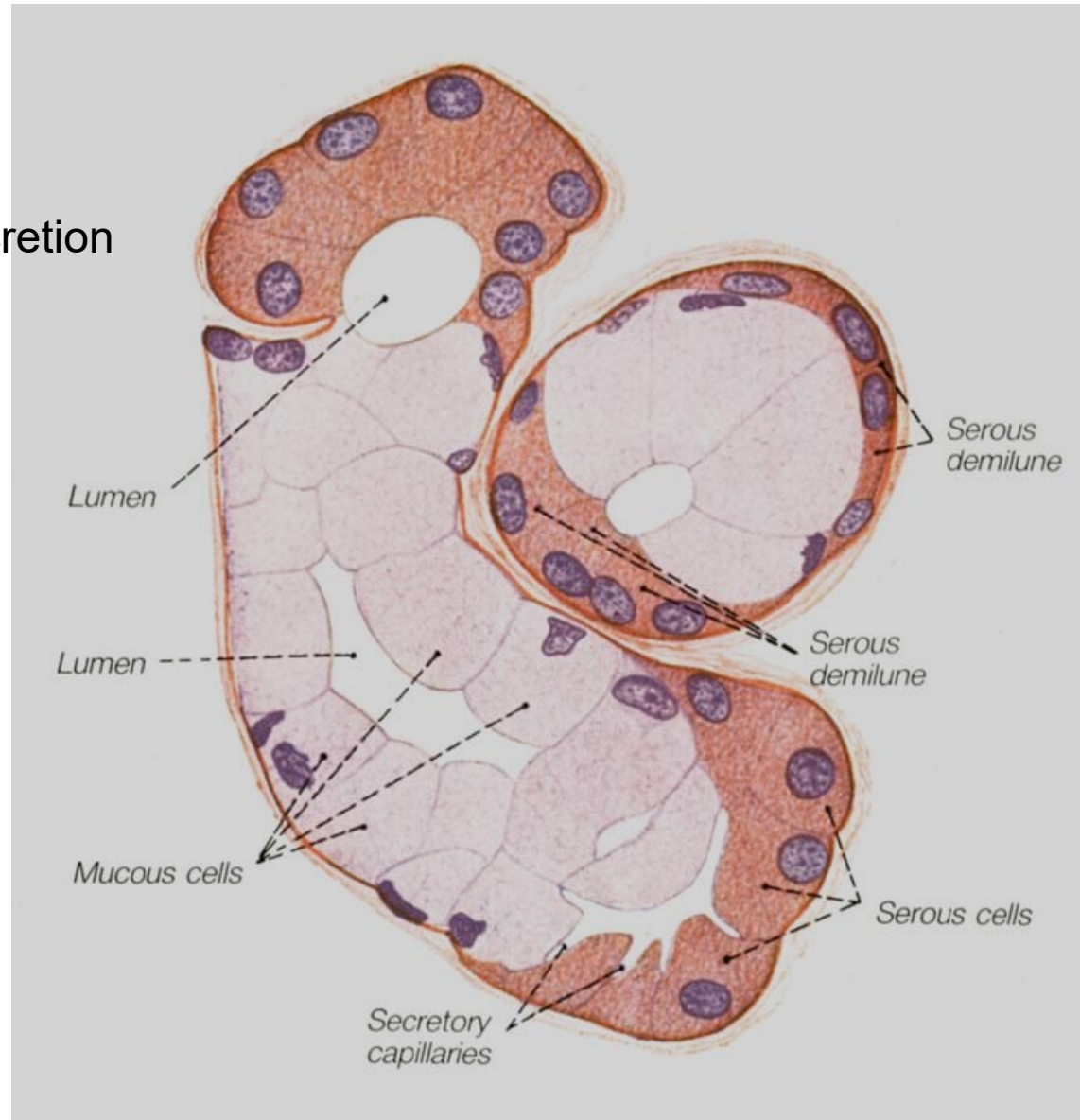


▶ **LM of part of a mixed salivary gland.** Several pale **mucous acini** surround two round **serous acini**. Serous cells have conspicuous, dark-stained secretory vesicles; mucous cells look vacuolated and washed out. EM in 2.15 shows the area in the square in detail. 600 \times . Toluidine blue, plastic section.

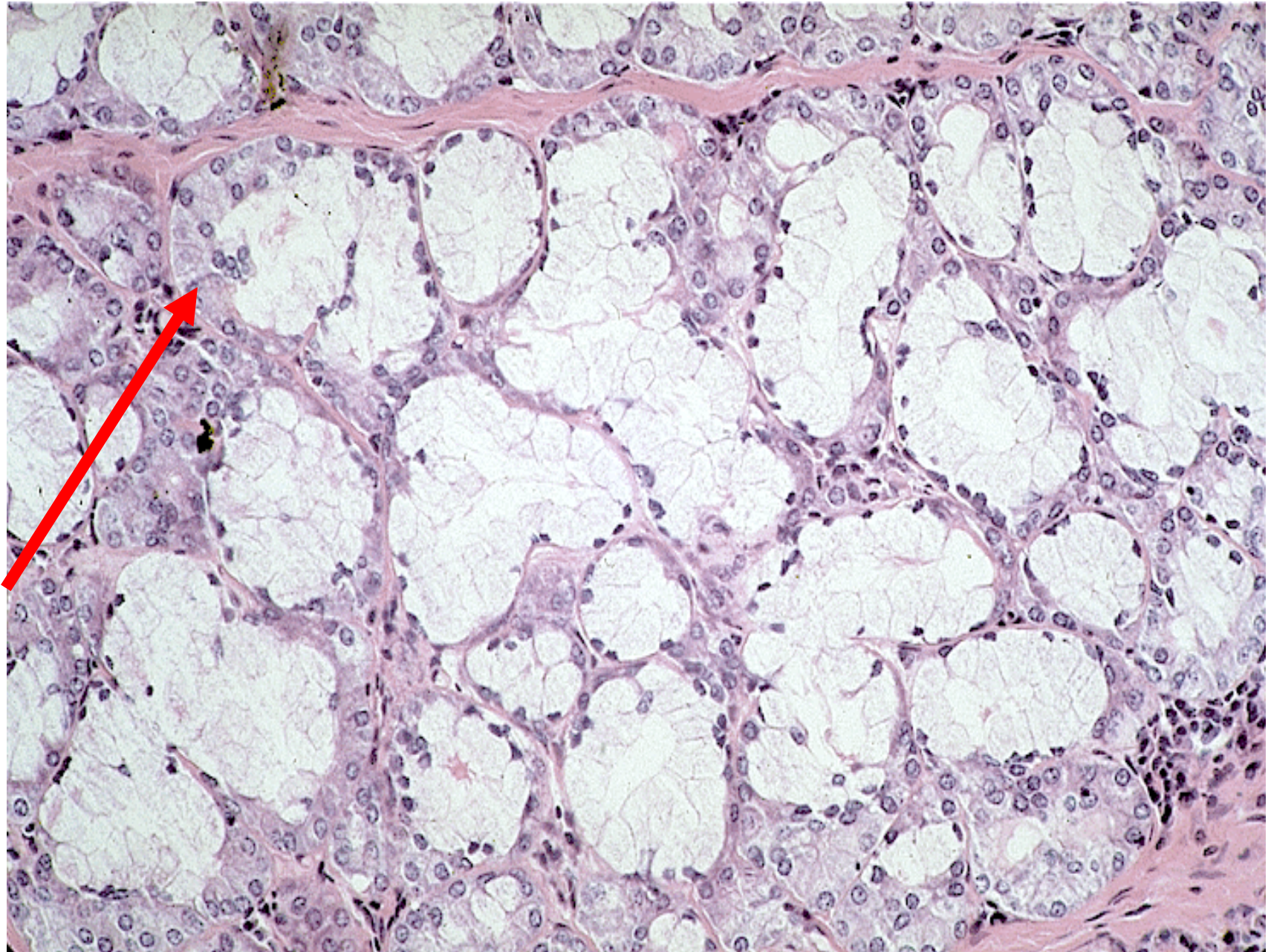


GLANDULAR EPITHELIUM

- **Mixed glands**
 - mixed serous and mucous secretion

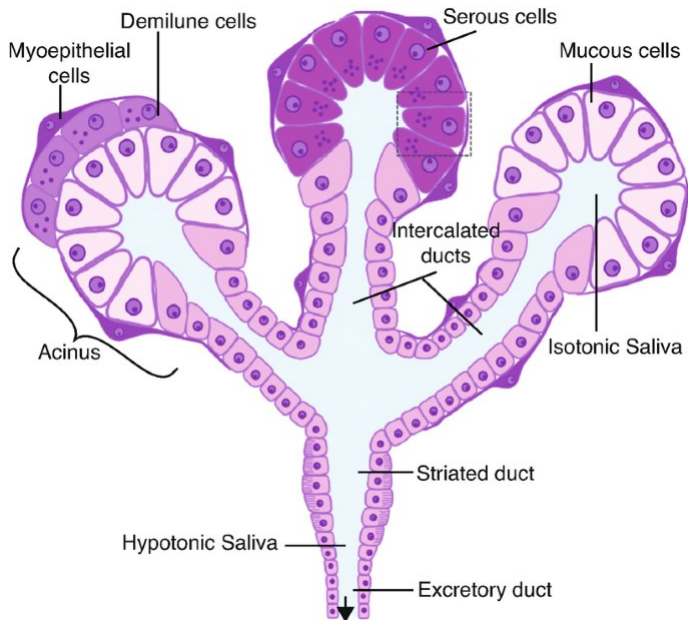
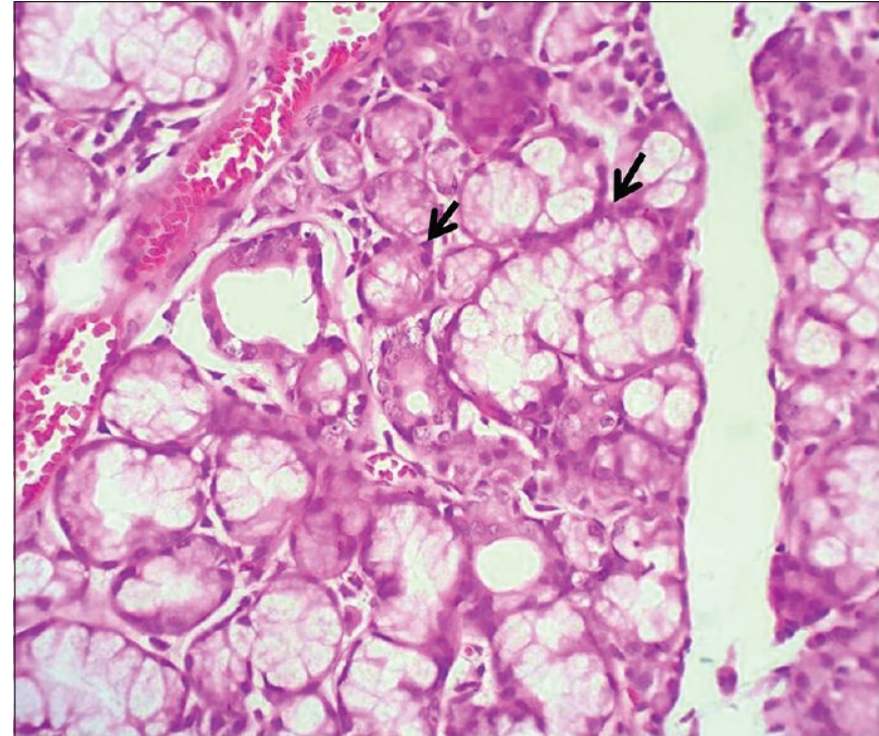


GLANDULAR EPITHELIUM



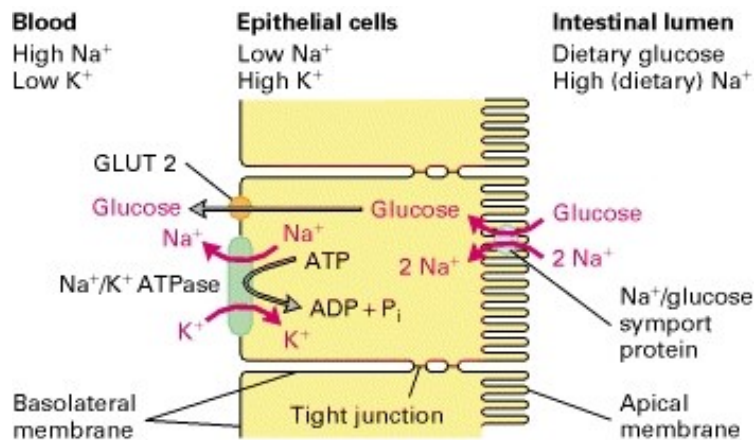
Myoepithelium

- star-like or spindle cells
- connected by nexus and desmosomes
- actin microfilaments, myosin and tropomyosin
- contraction
- sweat and salivary glands – enhancing secretion

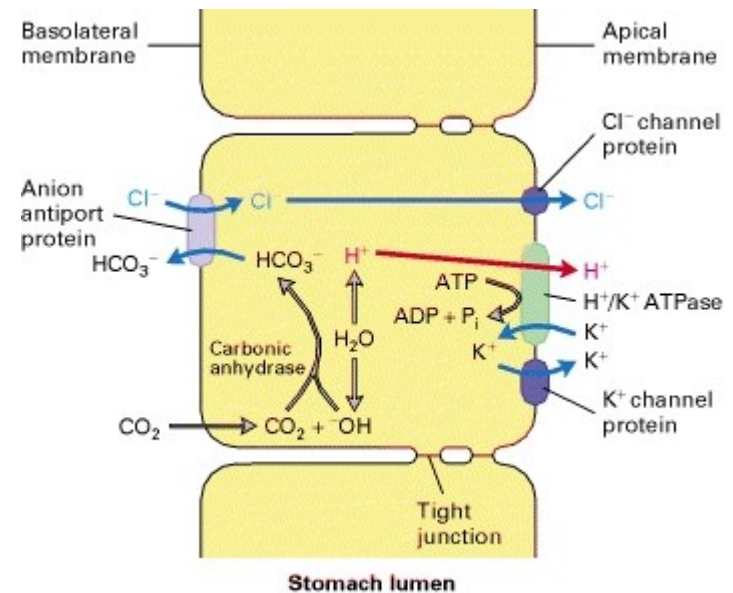


GLANDULAR EPITHELIUM

Transcellular transport through epithelial cells is driven by concentration and/or charge gradients



Glucose transport



HCl secretion in stomach

CLASSIFICATION OF EPITHELIAL TISSUE

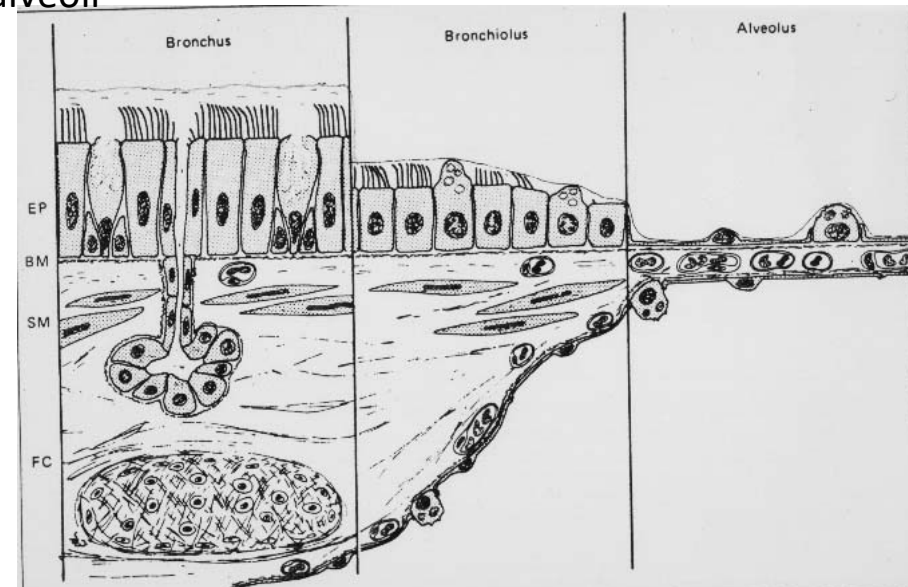
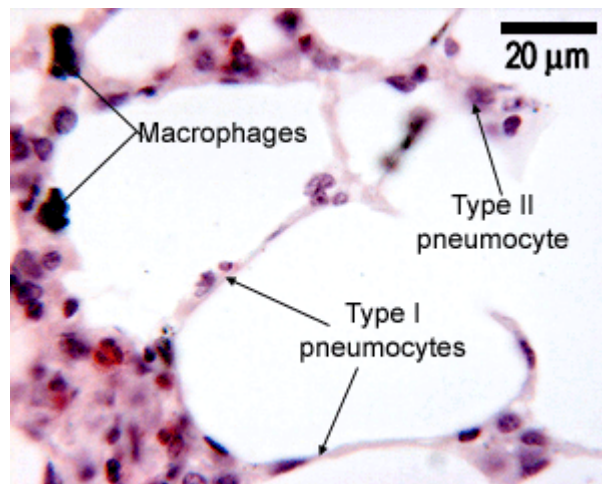
Respiratory epithelium

Epithelium of respiratory passages

- Moistening and protection against injury and pathogens
- Remove particles by mucociliary clearance
- Pseudostratified columnar epithelium with cilia
- Basal cells → epithelium renewal

Alveolar epithelium

- Gas exchange
- Surfactant
- Respiratory bronchioles, alveolar passages and alveoli
- Type I and II pneumocytes



CLASSIFICATION OF EPITHELIAL TISSUE

Sensory epithelium

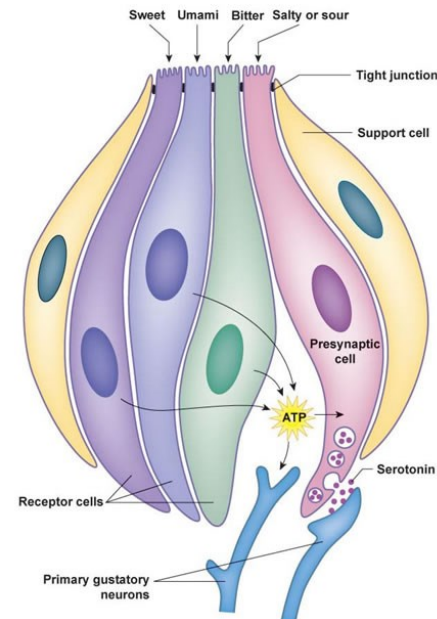
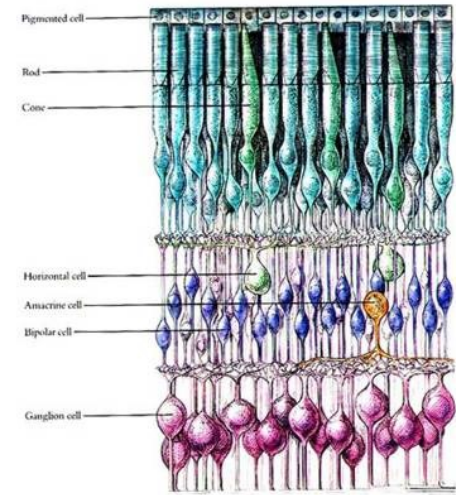
- Supportive and sensory cells

Primary sensory cells

- directly convert stimuli to membrane potential
- receptor region, body, axonal process
- olfactory epithelium (*regio olfactoria nasi*), rods and cones

Secondary sensory cells

- receptor region and the cell body
- signal is transmitted by adjacent neurons terminating on secondary sensory cell
- taste buds, vestibulocochlear apparatus

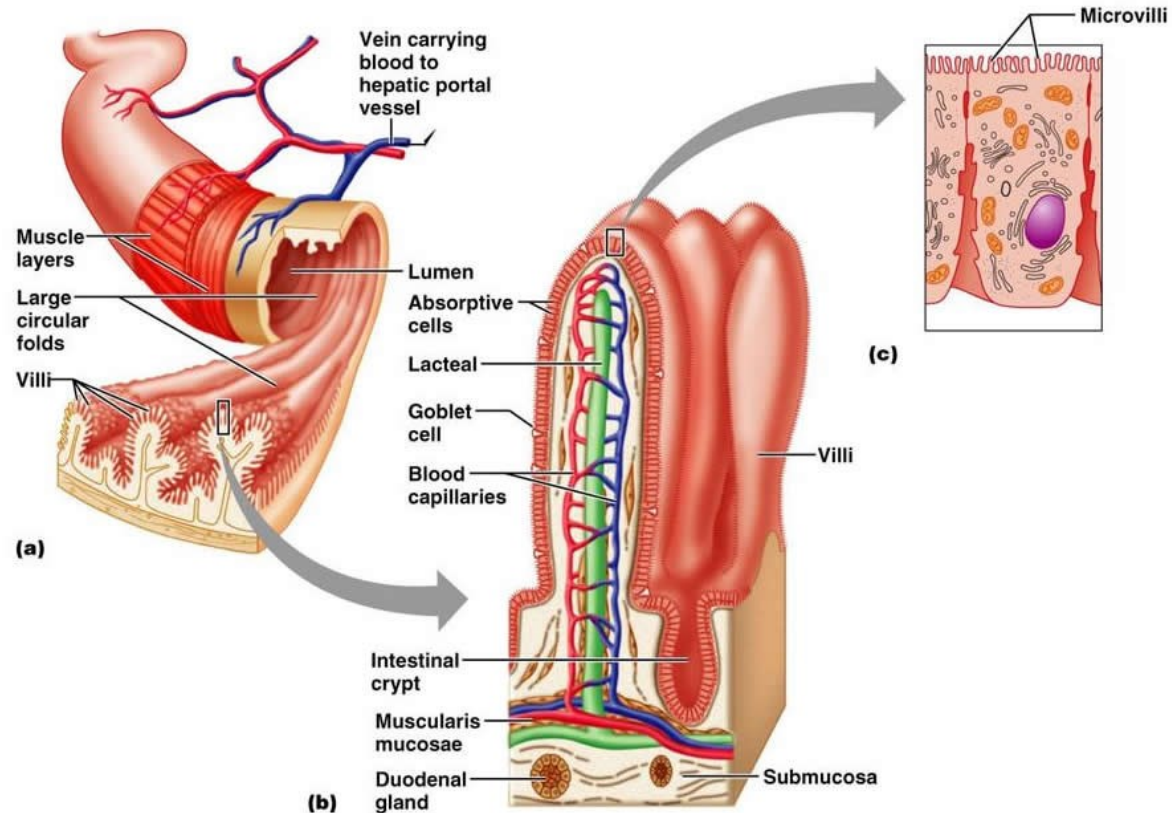


REGENERATION OF EPITHELIAL TISSUE

Renewal of epithelium

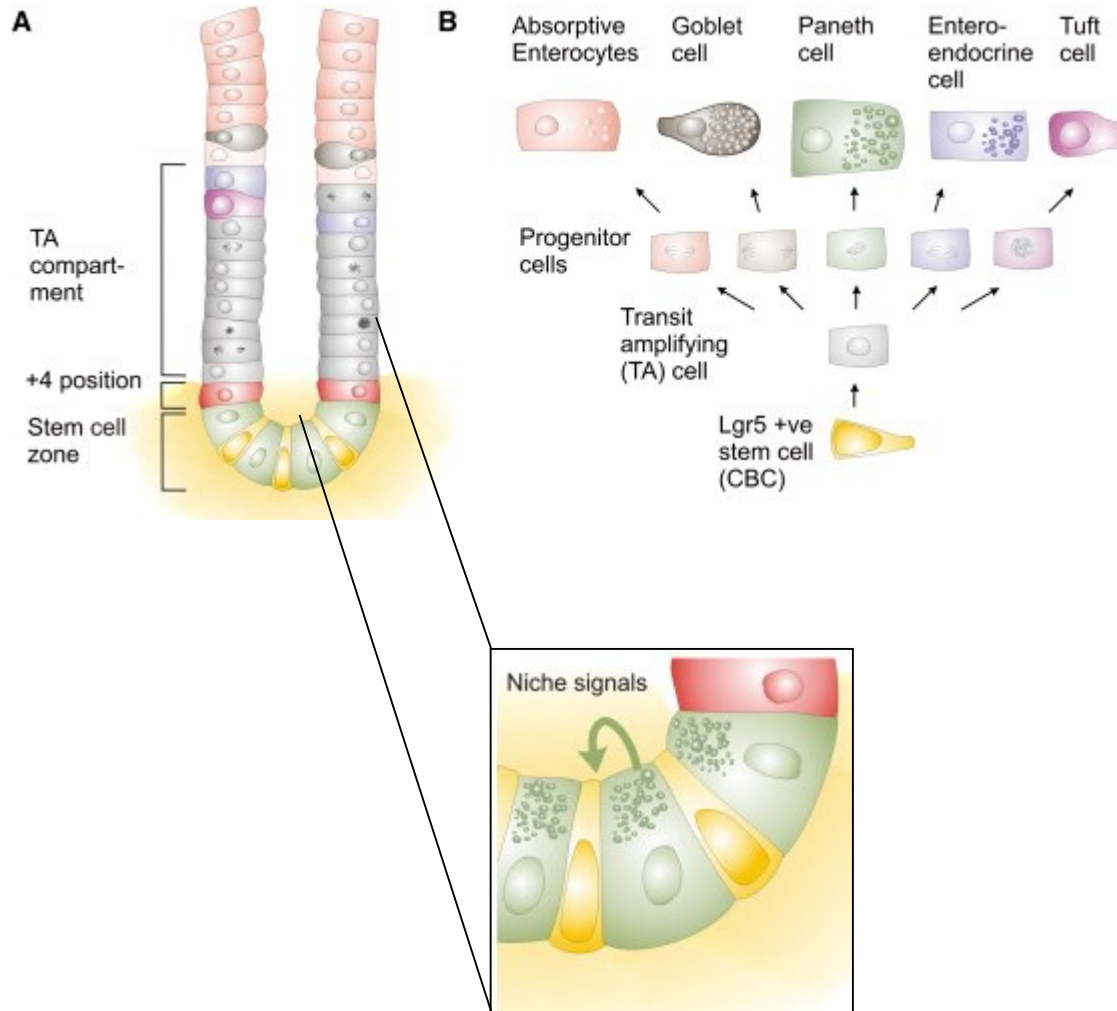
- different regenerative potential (epidermis × sensory epithelium of inner ear)
- multi- and oligopotent stem cells
- microenvironment – *stem cell niche*

Example: Regeneration of intestine epithelium

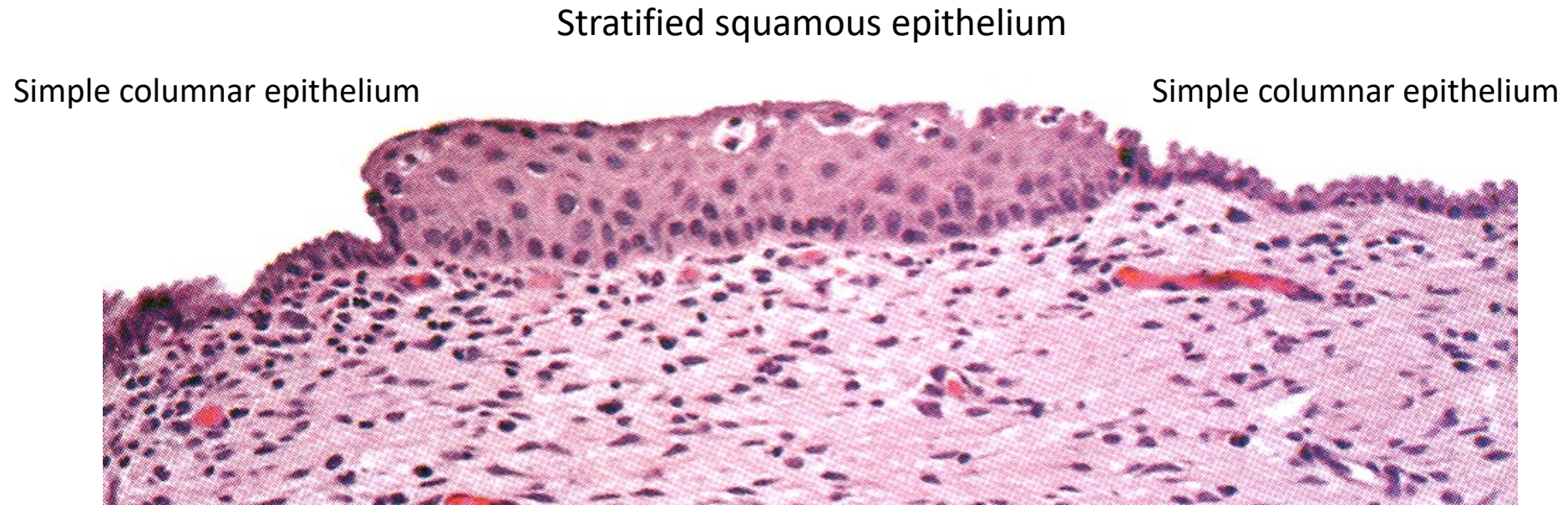


REGENERATION OF EPITHELIAL TISSUE

Example: Regeneration of intestine epithelium



Abnormal renewal: metaplasia

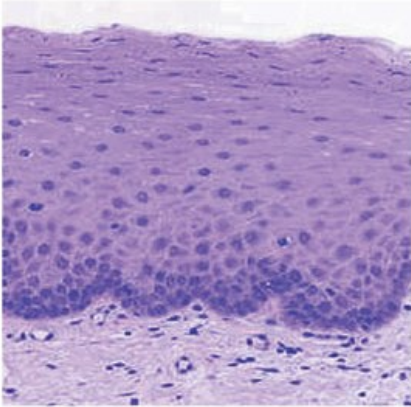


- squamous metaplasia of cervix uteri
- respiratory passages

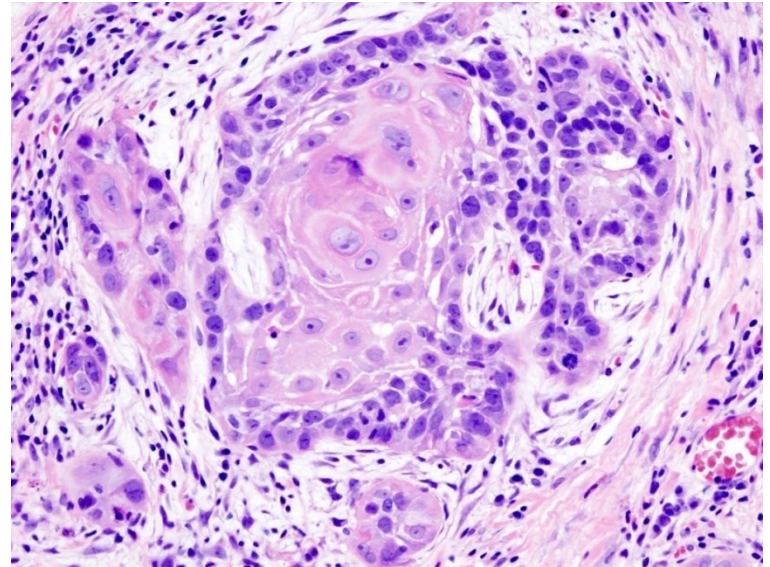
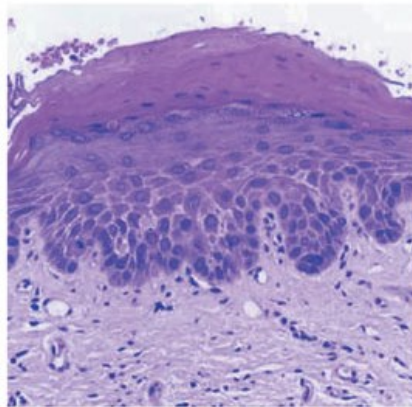
Abnormal renewal: metaplasia

- risk of development of precancerous lesions

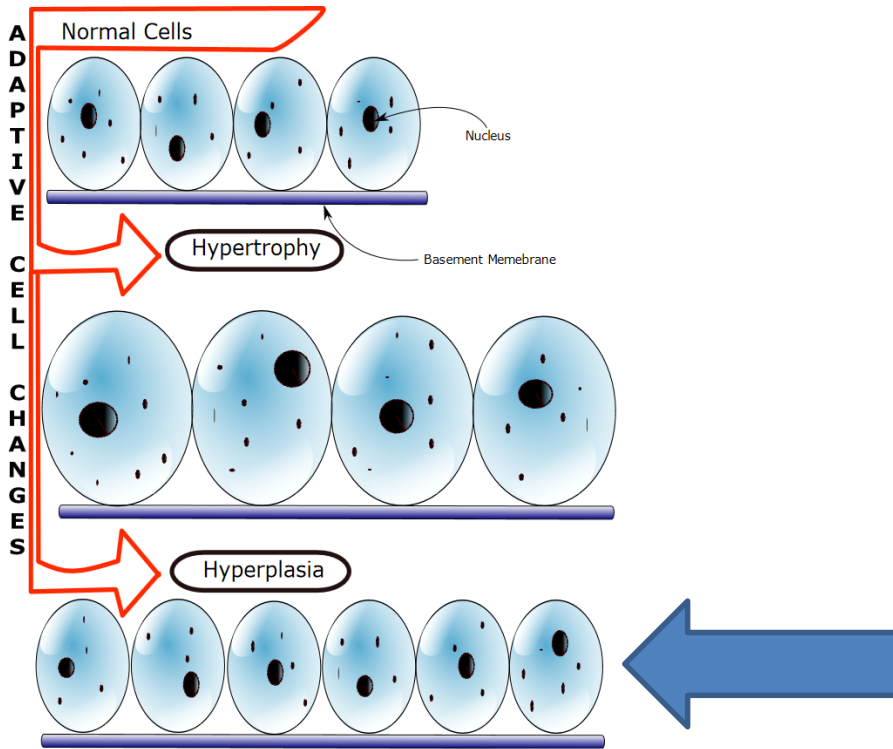
c Normal oral mucosa



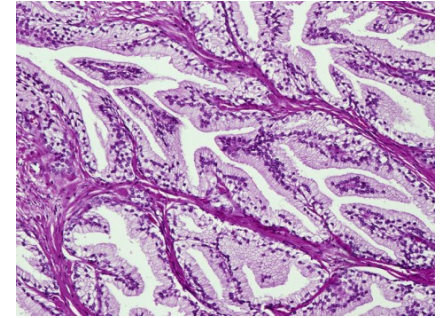
d Moderate dysplasia



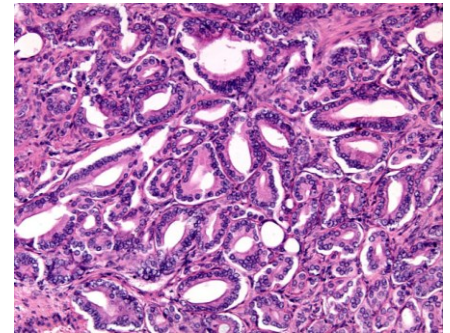
Abnormal renewal: hyperplasia



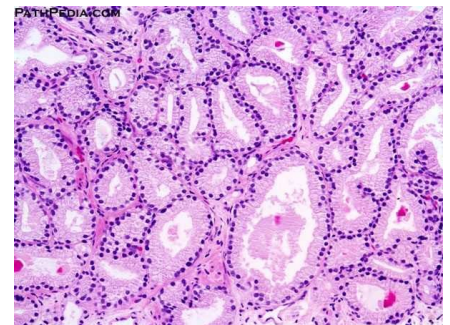
Normal prostate



Hyperplasia of prostate glandular epithelium

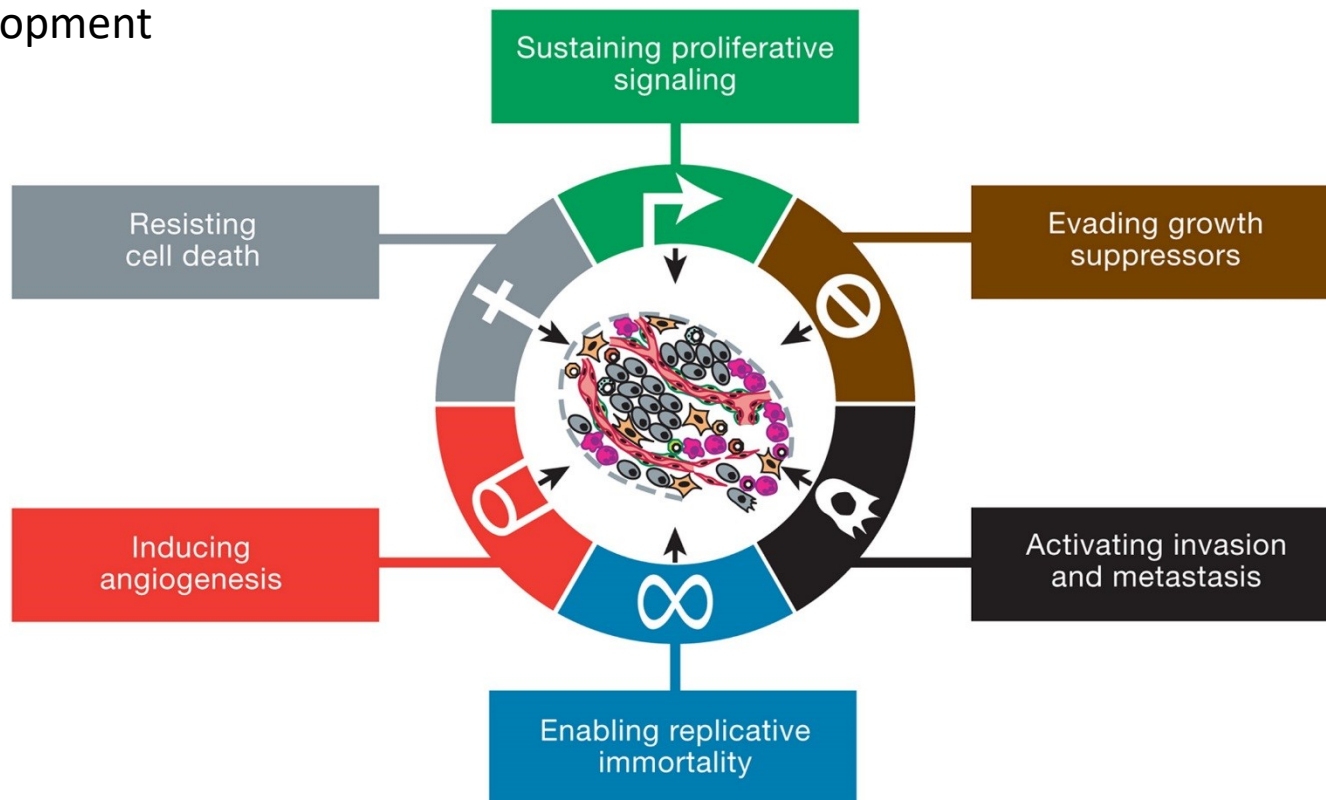


Prostate adenocarcinoma



Abnormal renewal: dysplasia and neoplasia

- uncoupling from regulatory mechanisms
- change in morphology and acquisition of new biological properties
- tumor development

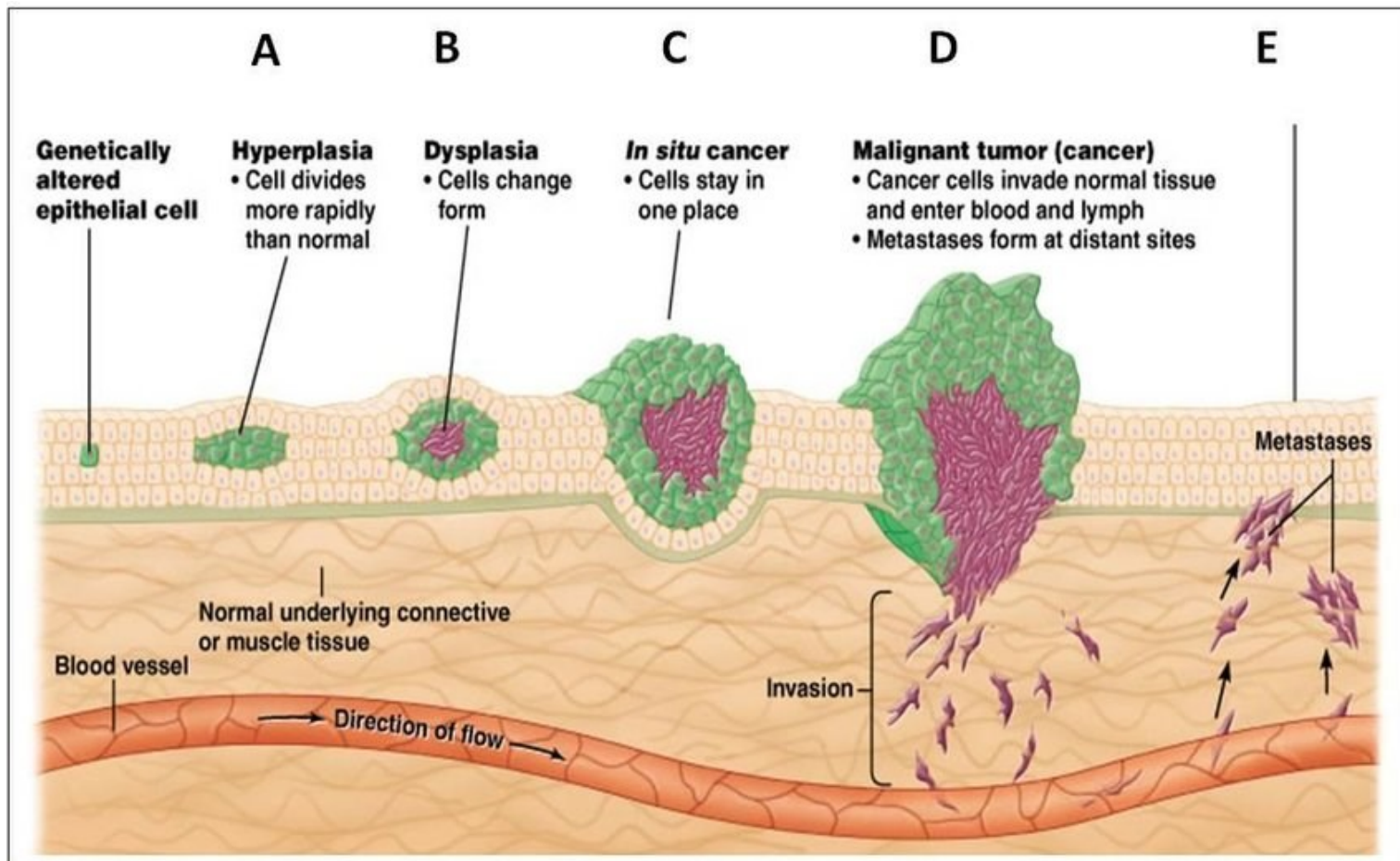


Hanahan & Weinberg, Cell 2011. The six hallmarks of cancer.

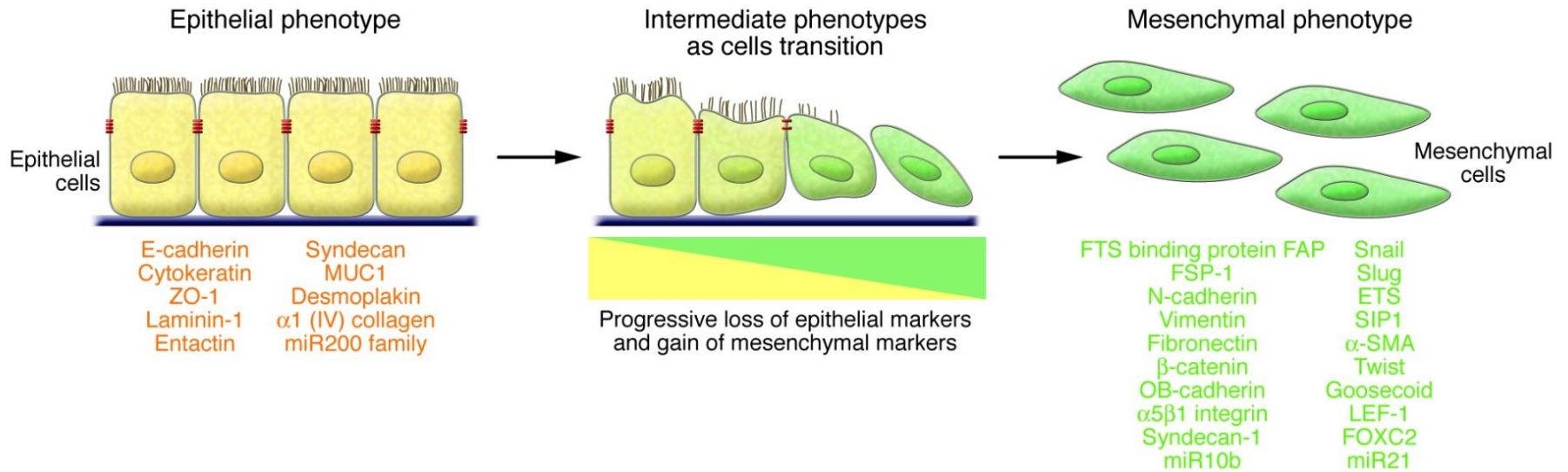
<https://doi.org/10.1016/j.cell.2011.02.013>

Abnormal renewal: neoplasia

- uncoupling from regulatory mechanisms
- tumor development

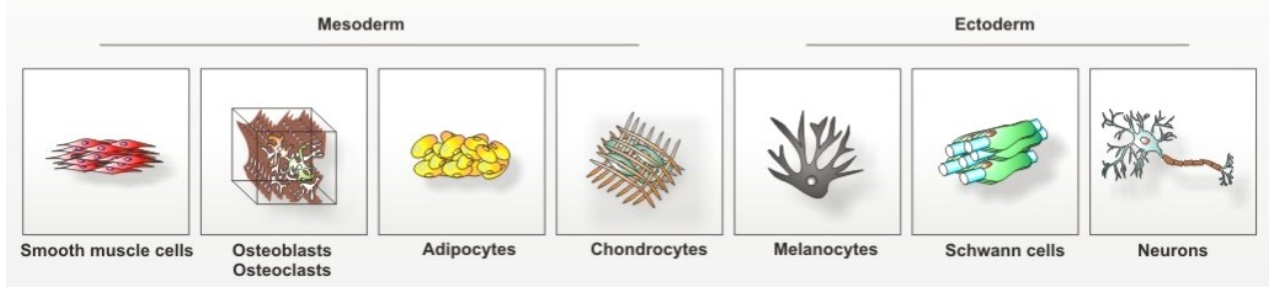
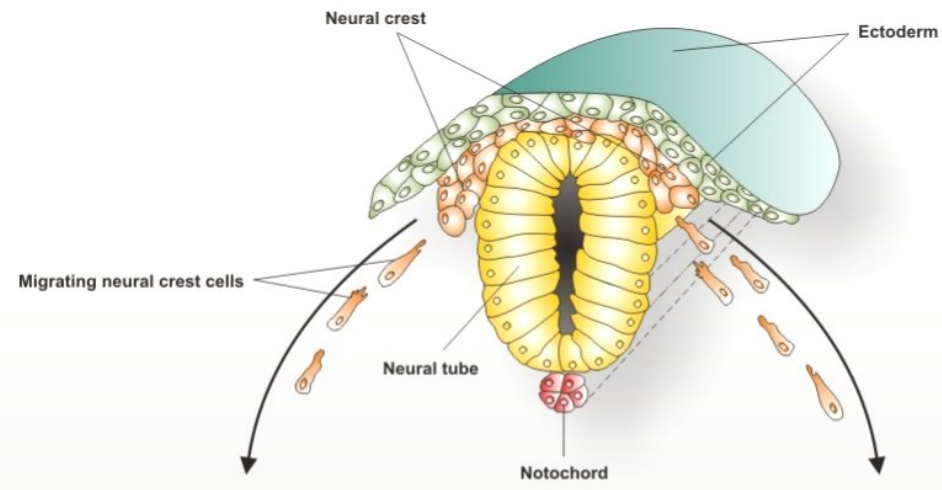
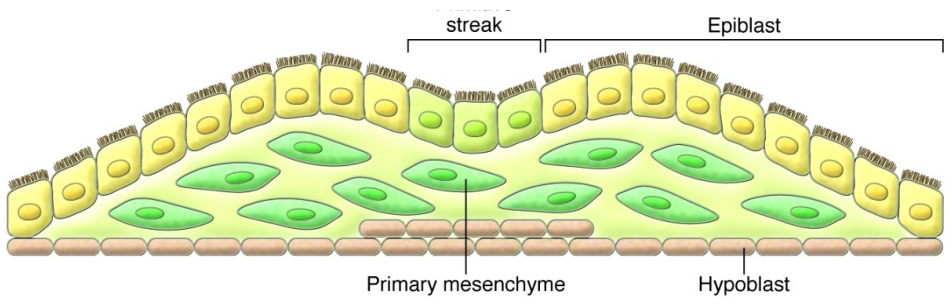


Epithelial to mesenchymal transition (EMT)

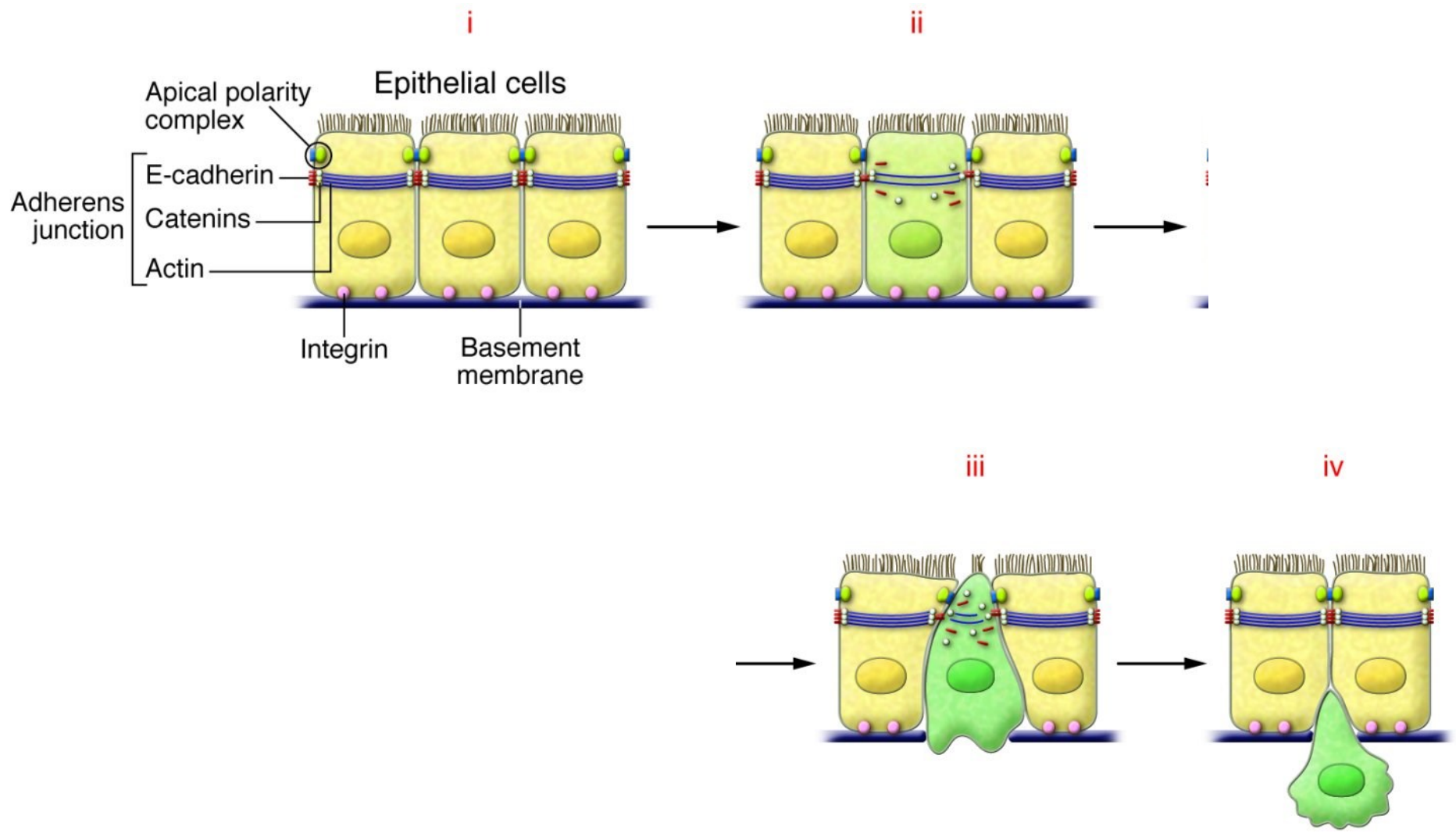


PLASTICITY OF EPITHELIAL TISSUES

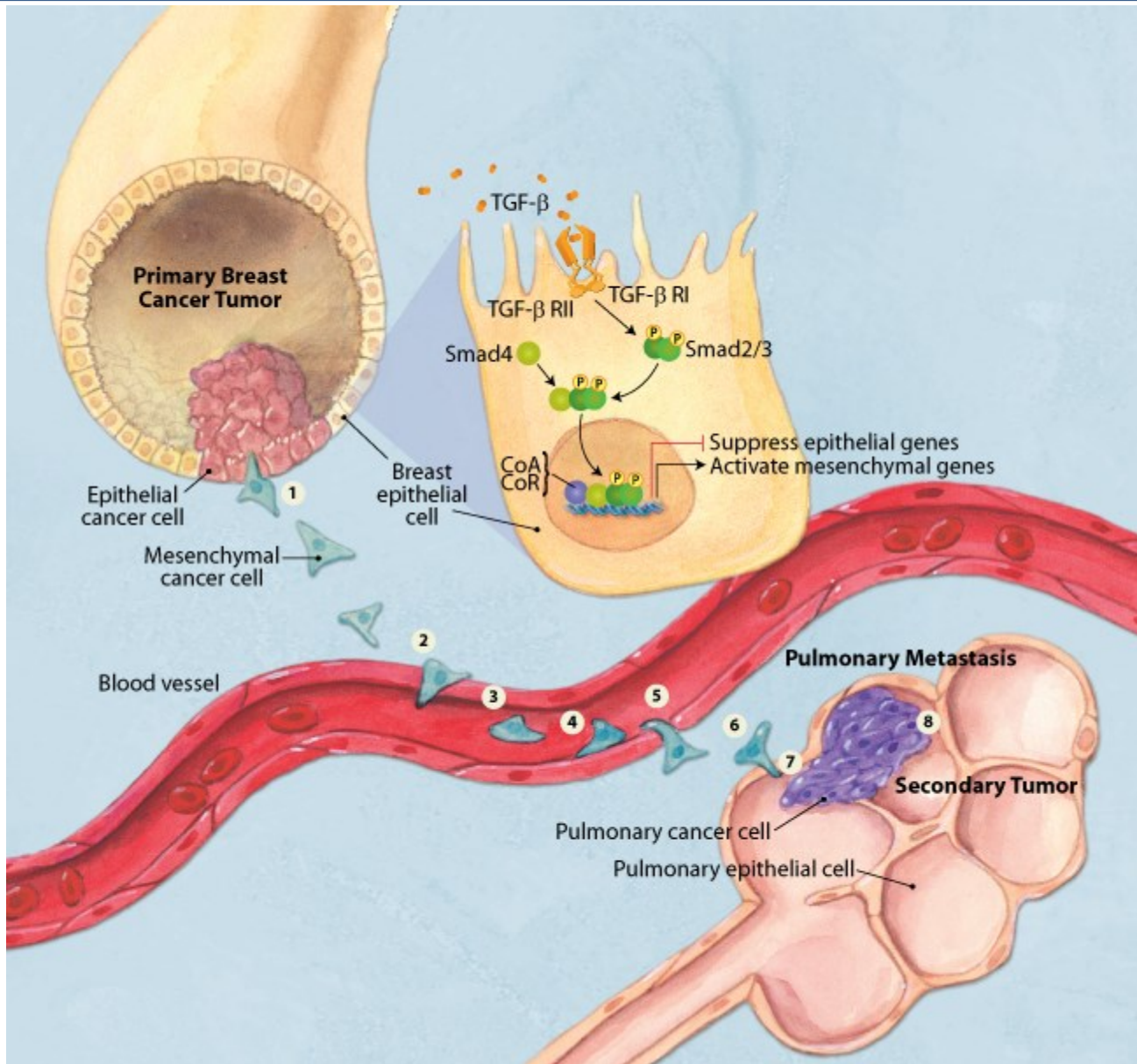
EMT in embryonic development



EMT in tumor dissemination

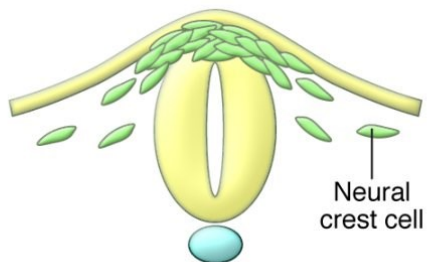


PLASTICITY OF EPITHELIAL TISSUES

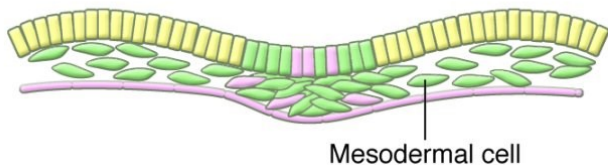


EMT overview

Embryos

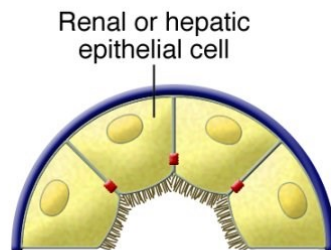


EMT inducers
Physiological expression

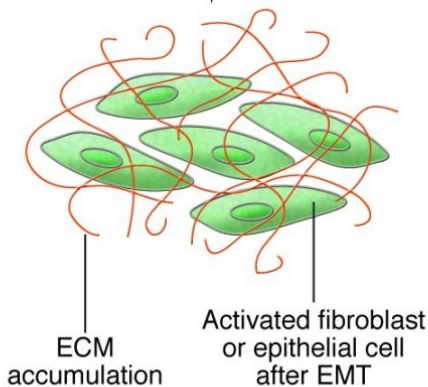


Epithelial cells
Mesenchymal cells

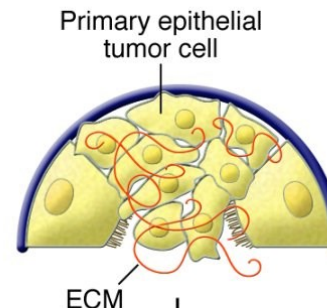
Fibrosis



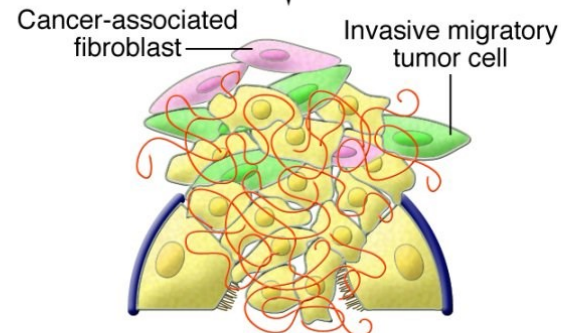
EMT inducers
Aberrant activation






Tumor progression




EMT inducers
Aberrant activation



FURTHER STUDY


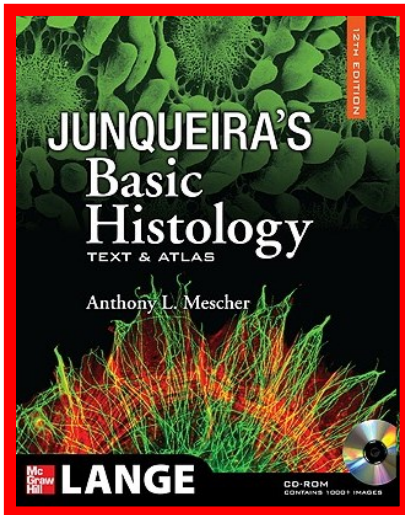




FACULTY OF MEDICINE

Guide to General Histology and Microscopic Anatomy

Petr Vaňhara, Miroslava Sedláčková,
Irena Lauschová, Svatopluk Čech, Aleš Hampl

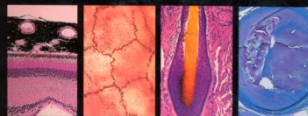



Includes 500 full-color **OVERSIZED** photomicrographs for use in the histology laboratory

SELF-ASSESSMENT section provides 60 test photomicrographs for identification of tissues and organs with similar morphologic features

HS 4.357-09

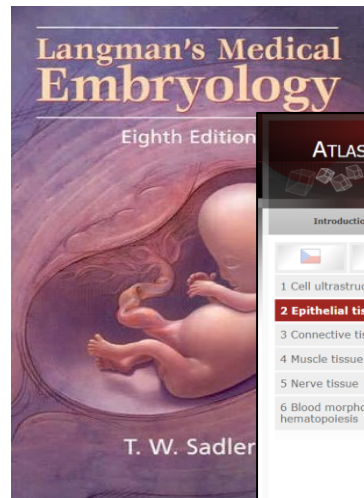
color atlas of basic histology



third edition

IRWIN BERMAN

LANGE




ATLAS OF HISTOLOGY FM MU

DEPARTMENT OF HISTOLOGY AND EMBRYOLOGY, FACULTY OF MEDICINE, MASARYK UNIVERSITY
PETR VAŇHARA ET AL.

Introduction	General Histology	Microscopic Anatomy	Practical test
<p>2 Epithelial tissue</p> <p>Cells of epithelial tissue are tightly arranged, most frequently into sheets. Apical part of the epithelial cell is oriented towards a free space or cavity and is equipped by various functional structures (microvilli, stereocilia, kinocilia, etc.). The basal part interacts with basement membrane. Epithelial cells are laterally connected by intercellular junctions (adhering, occluding, communicating). Epithelial tissue contains scarce extracellular matrix and is avascular.</p> <p>Based on the structure, epithelia are classified as sheet or covering (continuous planar structures), trabecular (cells form anastomosing cords – in liver or endocrine glands) and reticular epithelium (star-shaped cells form three dimensional network – in thymus). Based on the function, epithelia are classified as covering (epithelial membranes or sheets), glandular, absorptive, respiratory, sensory. The most common type of epithelial tissue is the covering epithelium, that is further classified according to the number of layers and cell morphology.</p>			
<p>1 Cell ultrastructure</p> <p>2 Epithelial tissue</p> <p>3 Connective tissue</p> <p>4 Muscle tissue</p> <p>5 Nerve tissue</p> <p>6 Blood morphology and hematopoiesis</p>	<p>2.1 Simple squamous epithelium - amniotic ectoderm of umbilical cord (HES)</p> <p>2.2 Simple squamous epithelium - pneumocytes in lung alveolus (HE)</p> <p>2.3 Simple cuboidal epithelium - kidney (AZAN)</p> <p>2.4 Simple columnar epithelium - gallbladder (AZAN)</p> <p>2.5 Simple columnar epithelium - oviduct (HE)</p> <p>2.6 Pseudostratified columnar ciliated epithelium - trachea (Iron-hematoxylin)</p> <p>2.7 Nonkeratinized stratified squamous epithelium - esophagus (HES)</p> <p>2.8 Keratinized stratified squamous epithelium - epidermis (HE)</p> <p>2.9 Transitional epithelium - ureter (HE)</p> <p>2.10 Pseudostratified columnar ciliated epithelium - trachea (HE)</p> <p>2.11 Serous acinus (alveolus) - lacrimal gland (HE)</p> <p>2.12 Mucous tubule - sublingual salivary gland (cross section, HE)</p> <p>2.13 Mucous tubule - sublingual salivary gland (longitudinal section, HE)</p> <p>2.14 Demilune of Gianuzzi - submandibular salivary gland (HE)</p> <p>2.15 Trabecular epithelium - liver parenchyma</p>		

Thank you for attention

Questions? Comments?



pvanhara@med.muni.cz

<http://www.histology.med.muni.cz>