

Clinical anatomy of the head, neck and nerve pathways



MANDIBULA

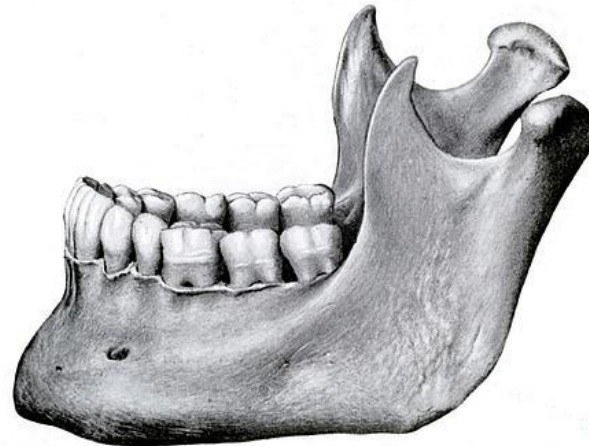
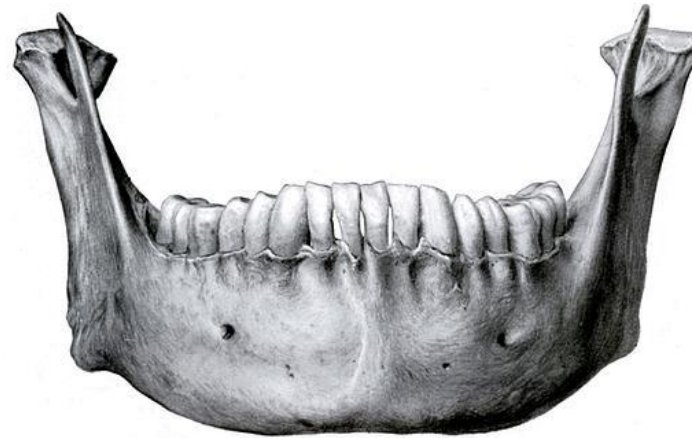Lower jaw



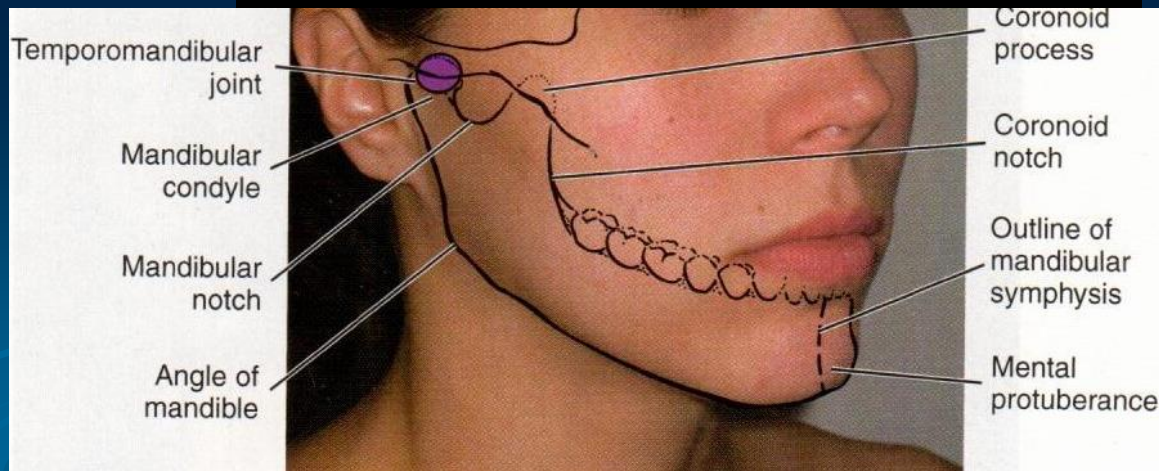
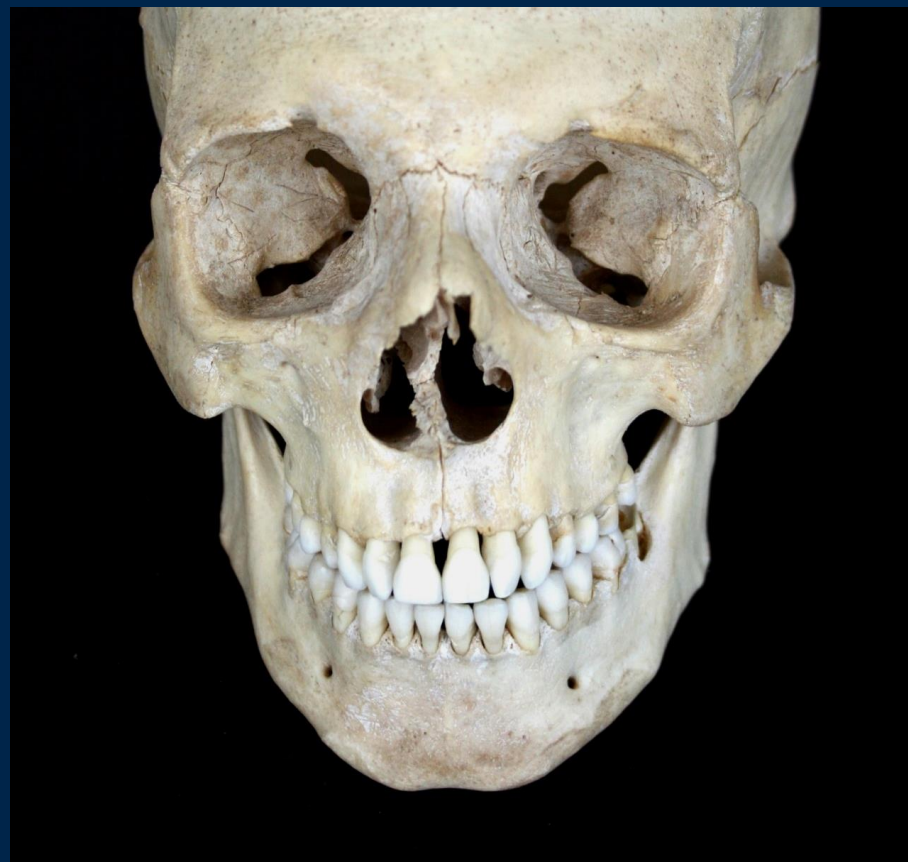- **Anatomy** (repetition), detailed description
- **Clinical notes**
- **Dentoalveolar topography**



Description



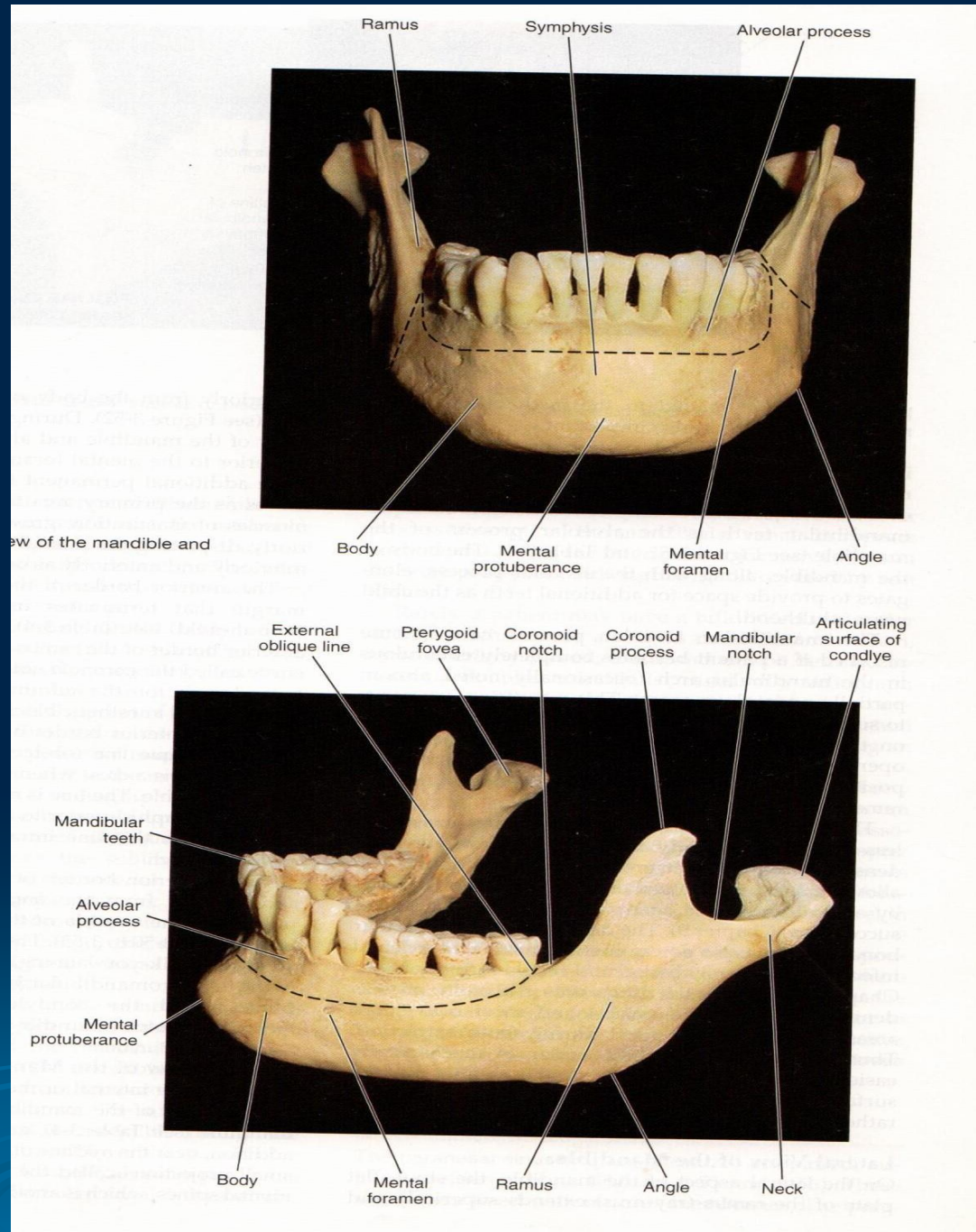
- An unpaired (single) facial bone
- Forms the osseous basis of the lower part of face
- The only skull bone connected with the remaining skull skeleton using articulation (ATM)
- The only **freely movable** bone of the skull
- The largest and strongest bone of the skull
- It also articulates with each of the maxillae by the way of lower and upper dentition



Corpus

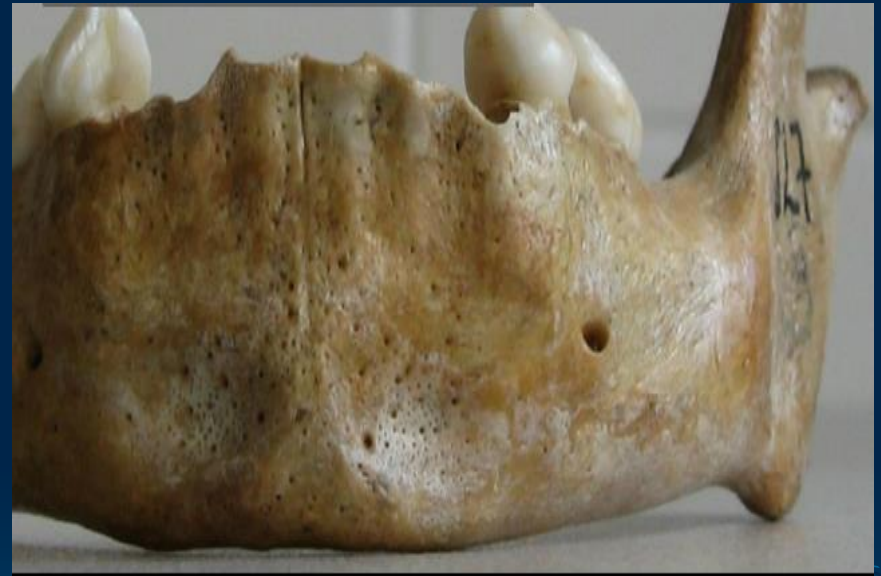Ramus

Angulus

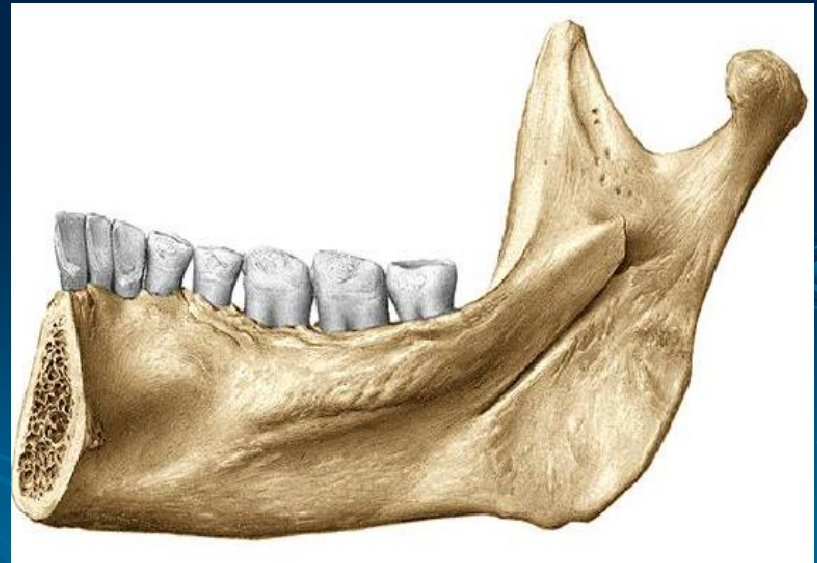
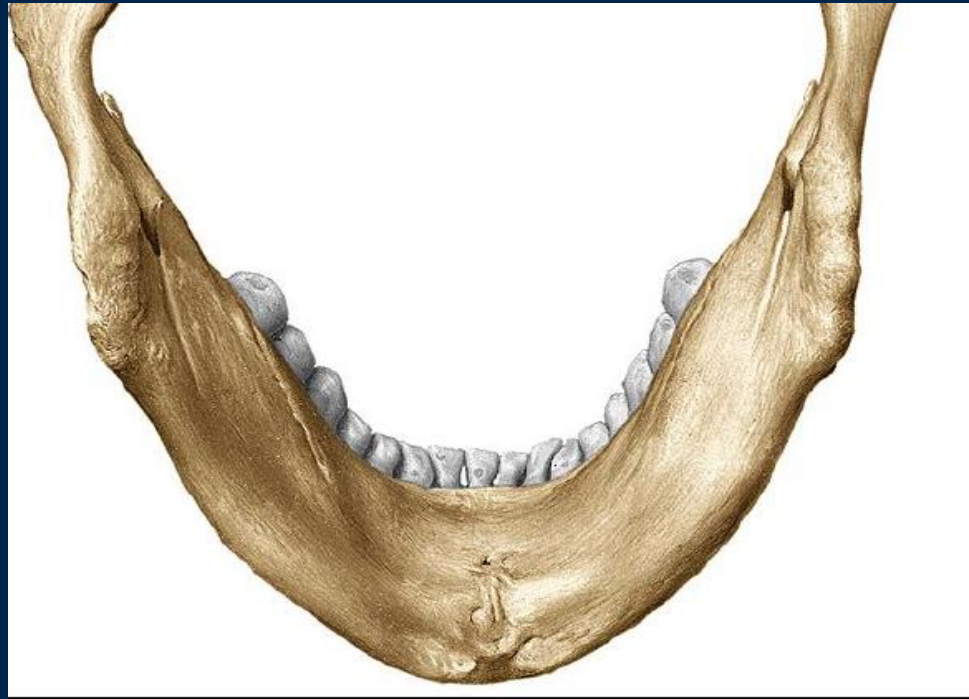
Corpus mandibulae

- Thickened along its whole lower margin and in the chin area – where it forms **trigonum mandibulae (protuberantia mentalis + tubercula mentalia)** – bony prominence of the chin
- Along cranial edge of mandibular body – **proc. alveolaris** with alveoli dentales with septa and juga alveolaria anteriorly
- **Mental foramen**



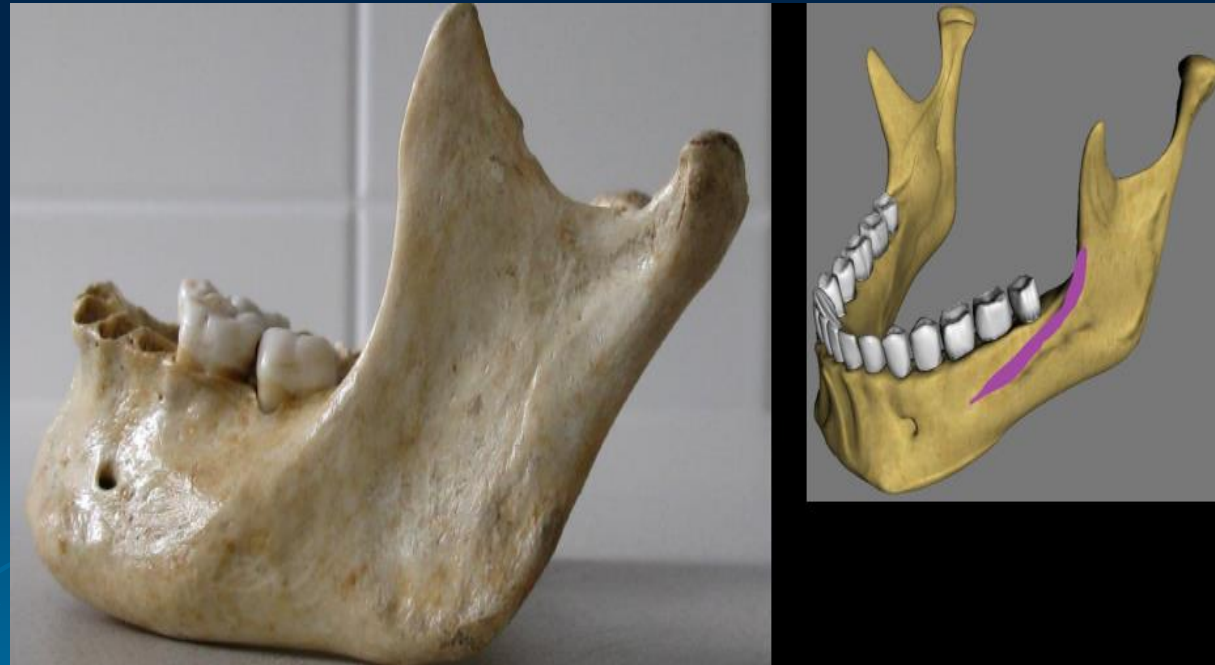- On the inner plane of the chin part – **spina mentalis** – origin of m. genioglossus and m. geniohyoideus
- Laterocaudally on each side – shallow pit **fossa digastrica**, to which venter ant. m. digastr. is attached
- An oblique margin **linea mylohyoidea** passes – for attachment of m. myloh.; above it a shallow pit **fovea sublingualis**, below **fovea submandibul.** – both cavities have equally named salivary glands



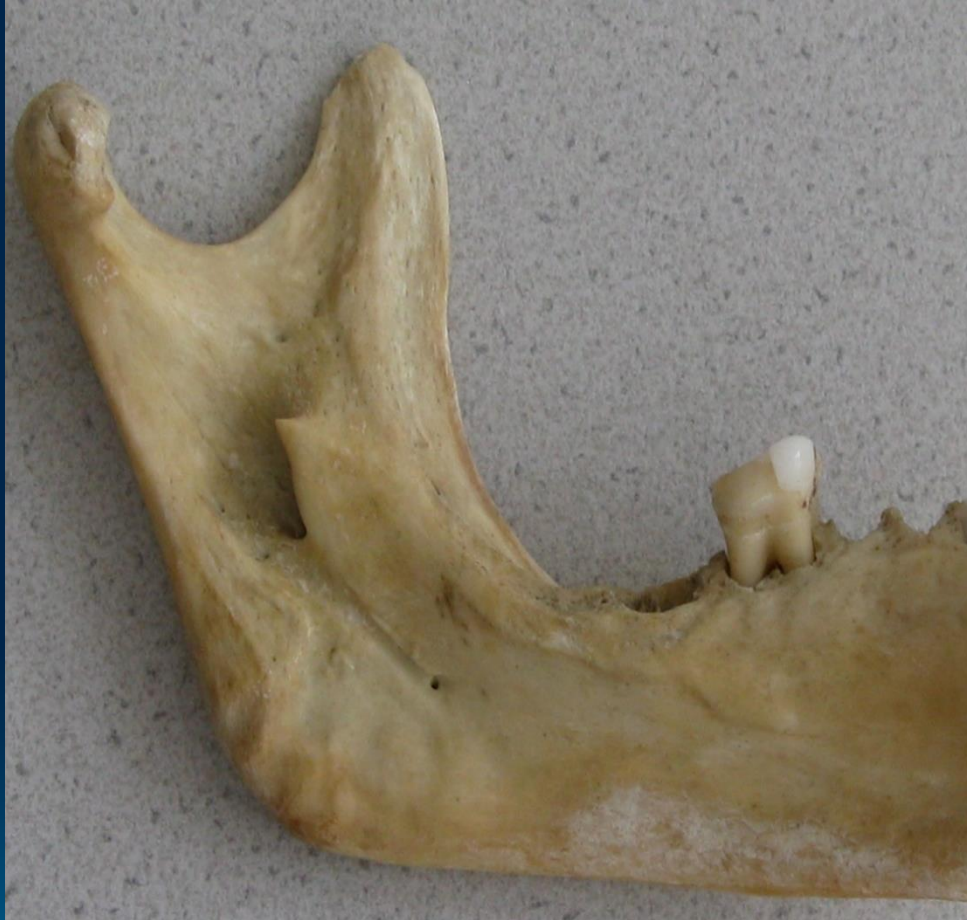Ramus mandibulae

- Is attached to corpus in mandibular left and right **angle**
- Protrudes ventrally into **processus coronoideus** (insertion of m. temporalis) and dorsally into **proc. condylaris** with cranial enlargement **caput m.**, below it a narrow neck – **collum m.** with central depression – **fovea pteryg.** (for attachment of mastic. muscle m. pteryg. later.)

- **Incisura mandibulae**
- On external surface **linea obliqua** protrudes caudally



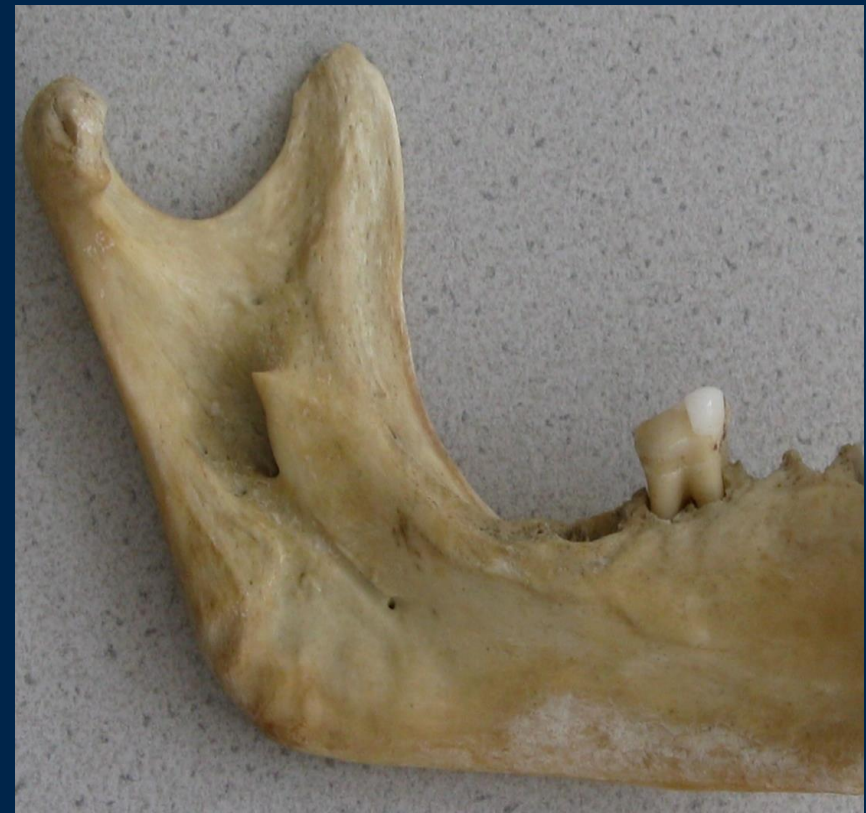Inner surface of ramus mandibulae



- Mandibular foramen
- the beginning of canalis mandibulae
- middleline between anterior and posterior edge of ramus
- 1 cm above M3
- 2 cm behind M3

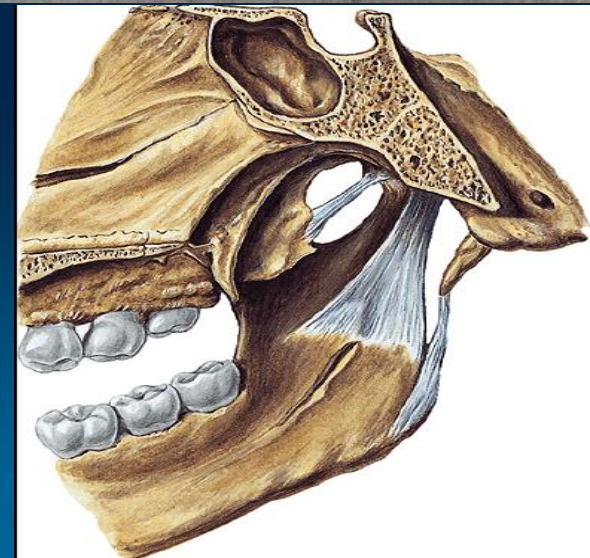
CAVE! Local anesthesia

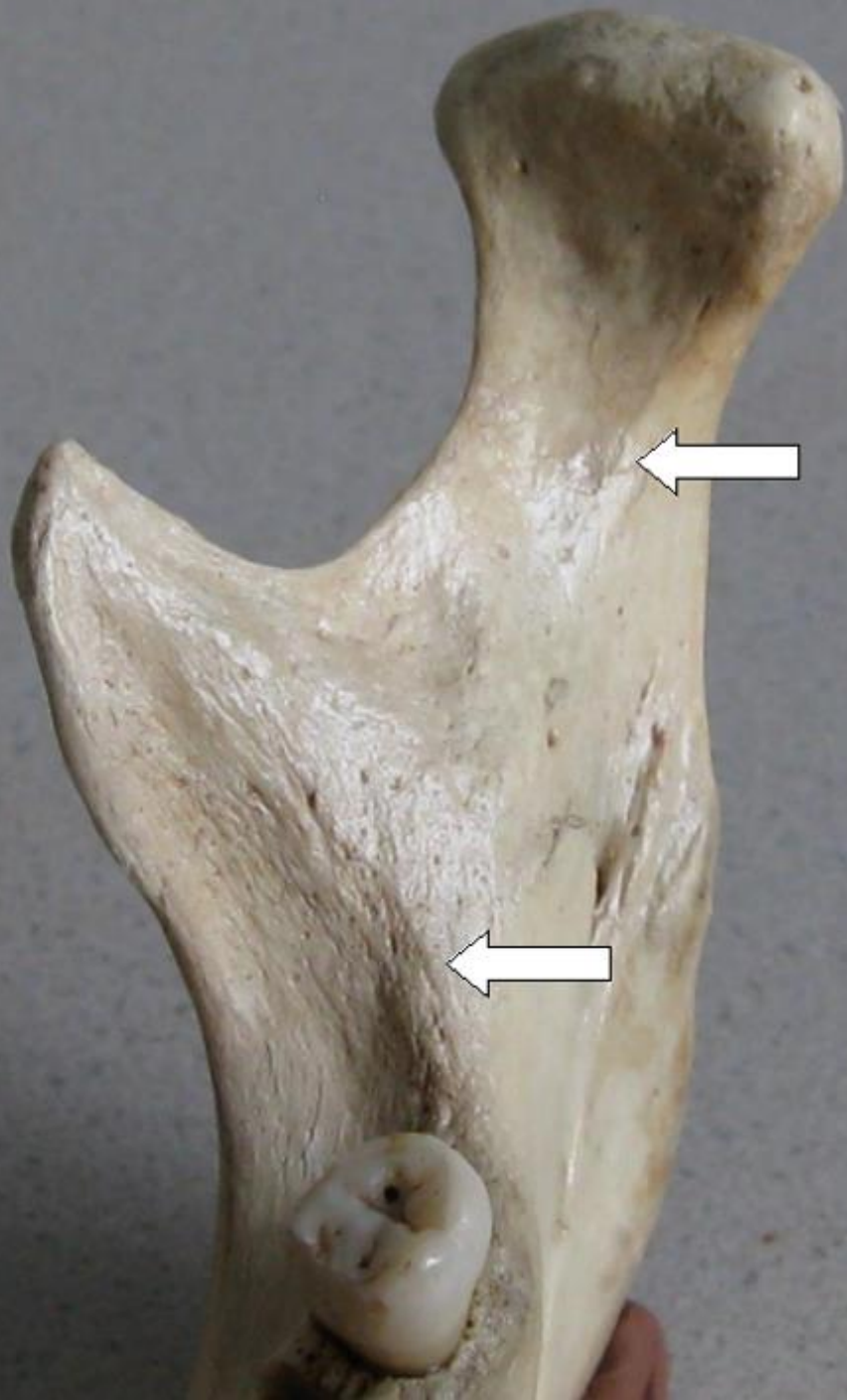- foramen m. - through which the neuro-vascular bundle passes into canalis m.; it is demarcated by thin osseous plate – **lingula m.** (attachement of lig. sphenomandibul.)



- **Sulcus mylohyoideus**

- On external and internal side of m. angle – **tuberositas** for attachment of masticatory muscles



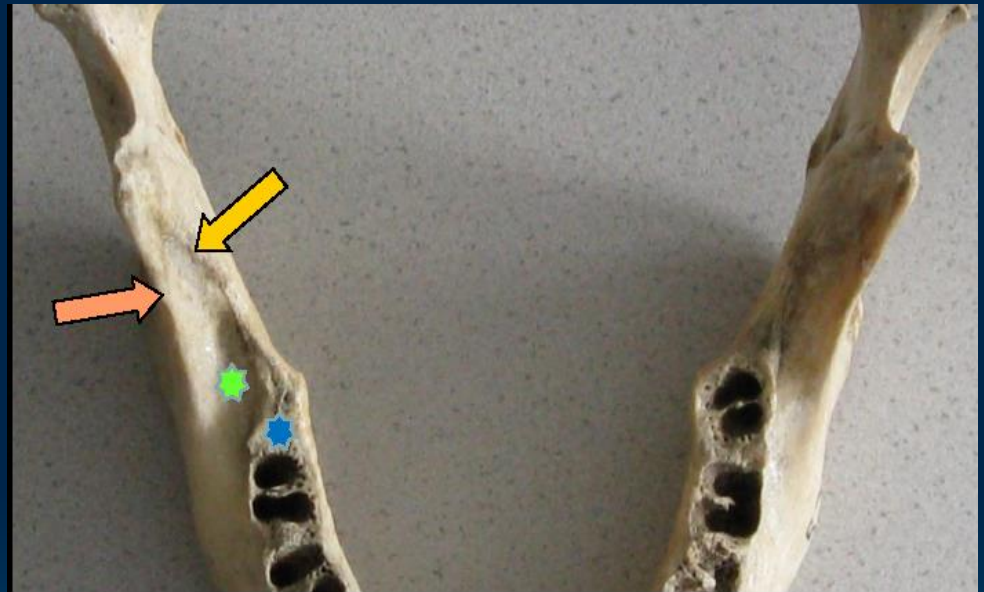


Crista colli mandibulae

Crista temporalis

➤ Trigonum retromolare

- there is very porous bone – CAVE during extraction of the last molar



Crista temp. < crus med. + lat. a vytvoří
ohraničení trig. retromolare

Anestezie

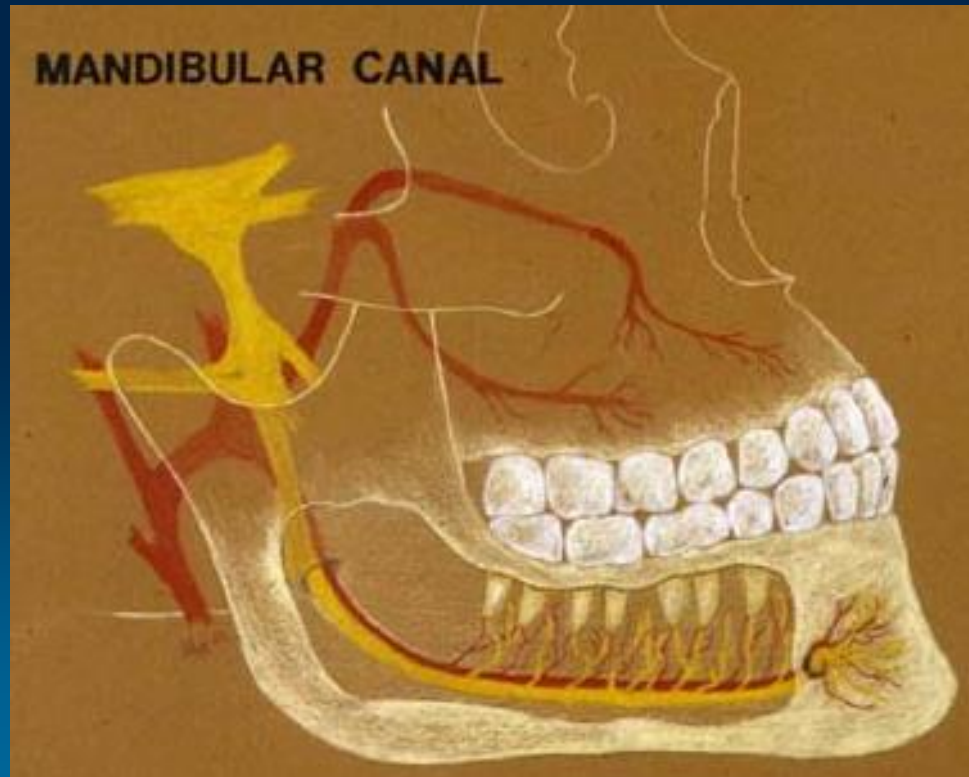
Fossa retromolaris

Výživa paci

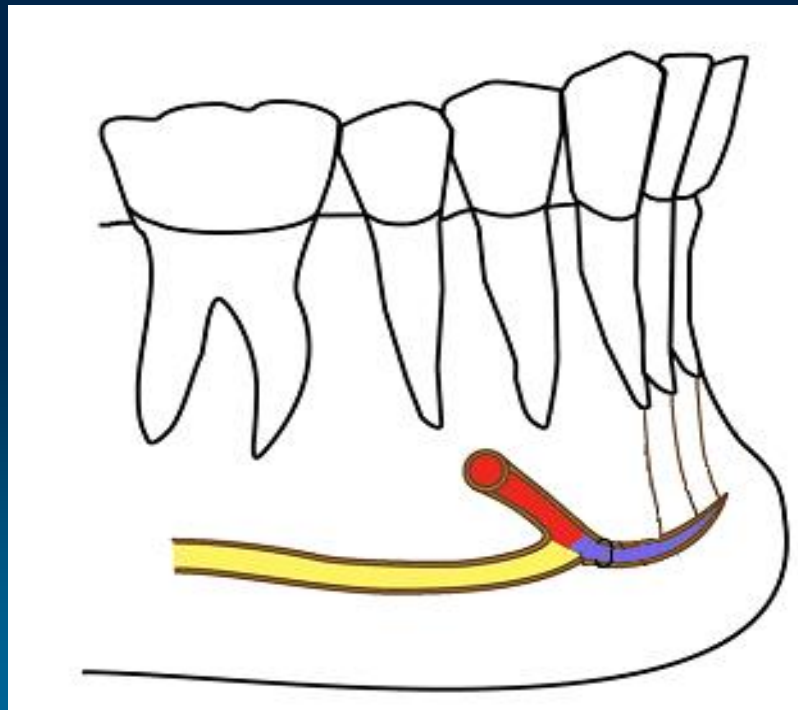
Ramus ant. → linea obliqua

Mandibular canal

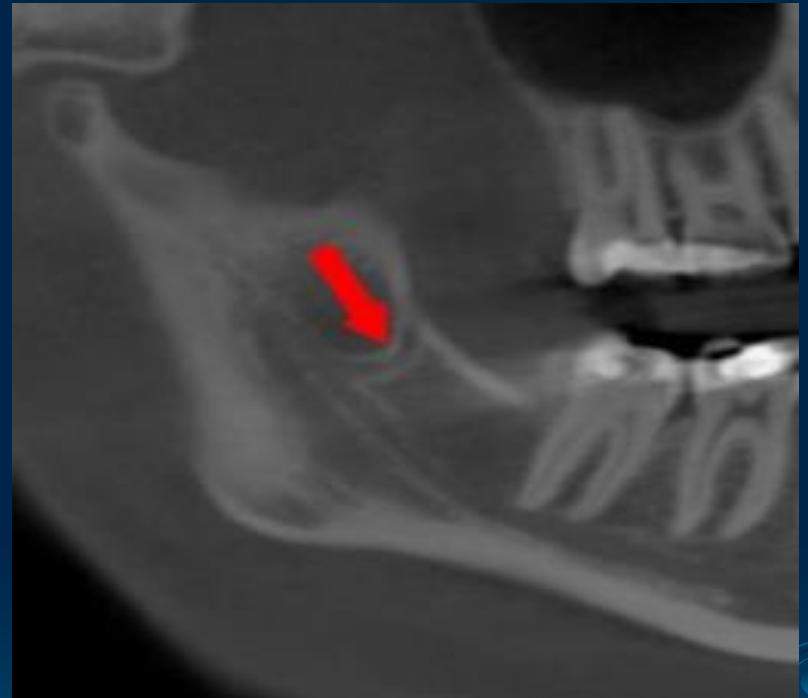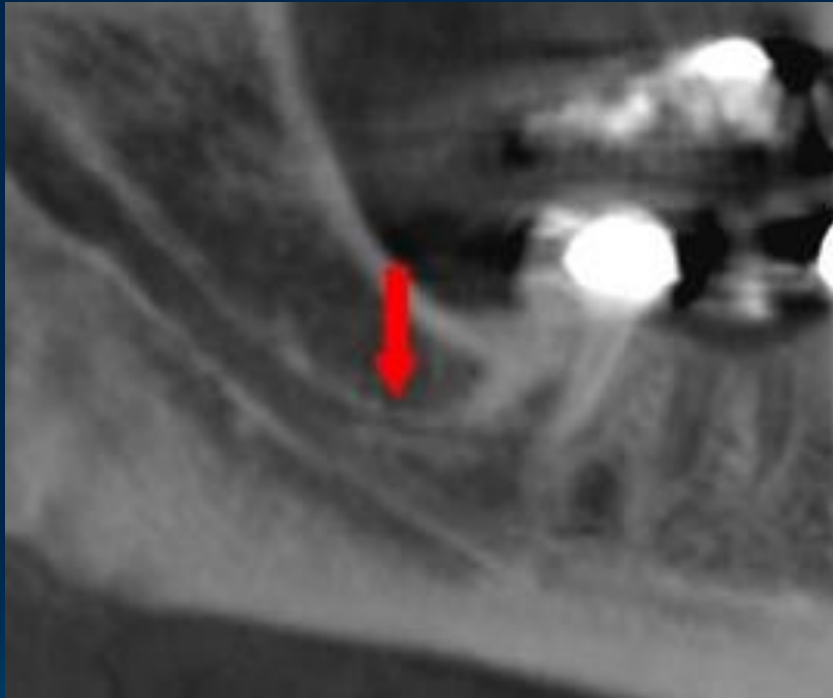
- Is placed under the alveoli and communicates with them by small openings
- Contains the **inferior alveolar nerve, artery, vein**



- Demarcated by the compact bone (noticeable to x-ray)
- On arriving at the incisor teeth, it turns back to communicate with the **mental foramen**, giving off a small canal known as the **mandibular incisive canal**



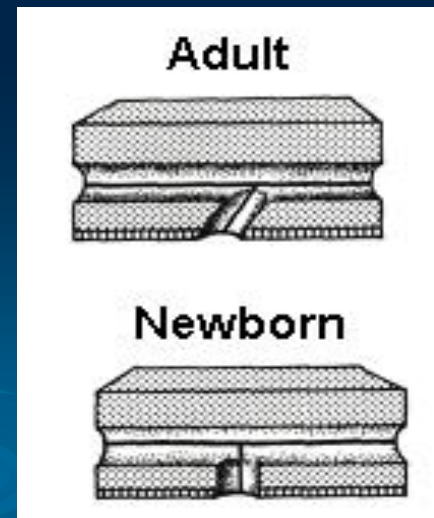
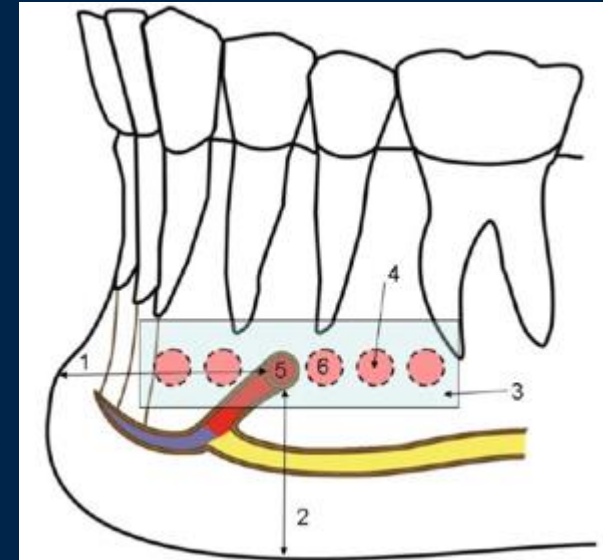
Canalis mandib. bifidus

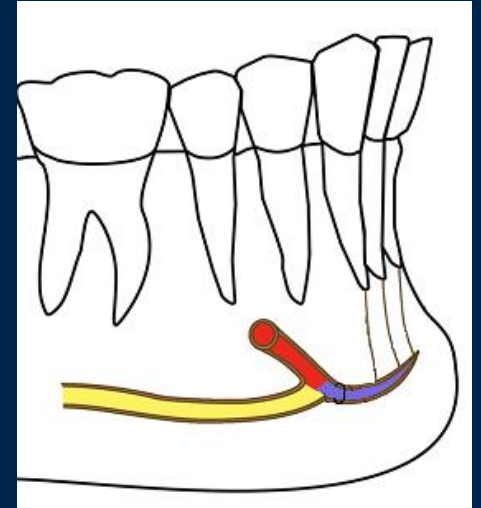
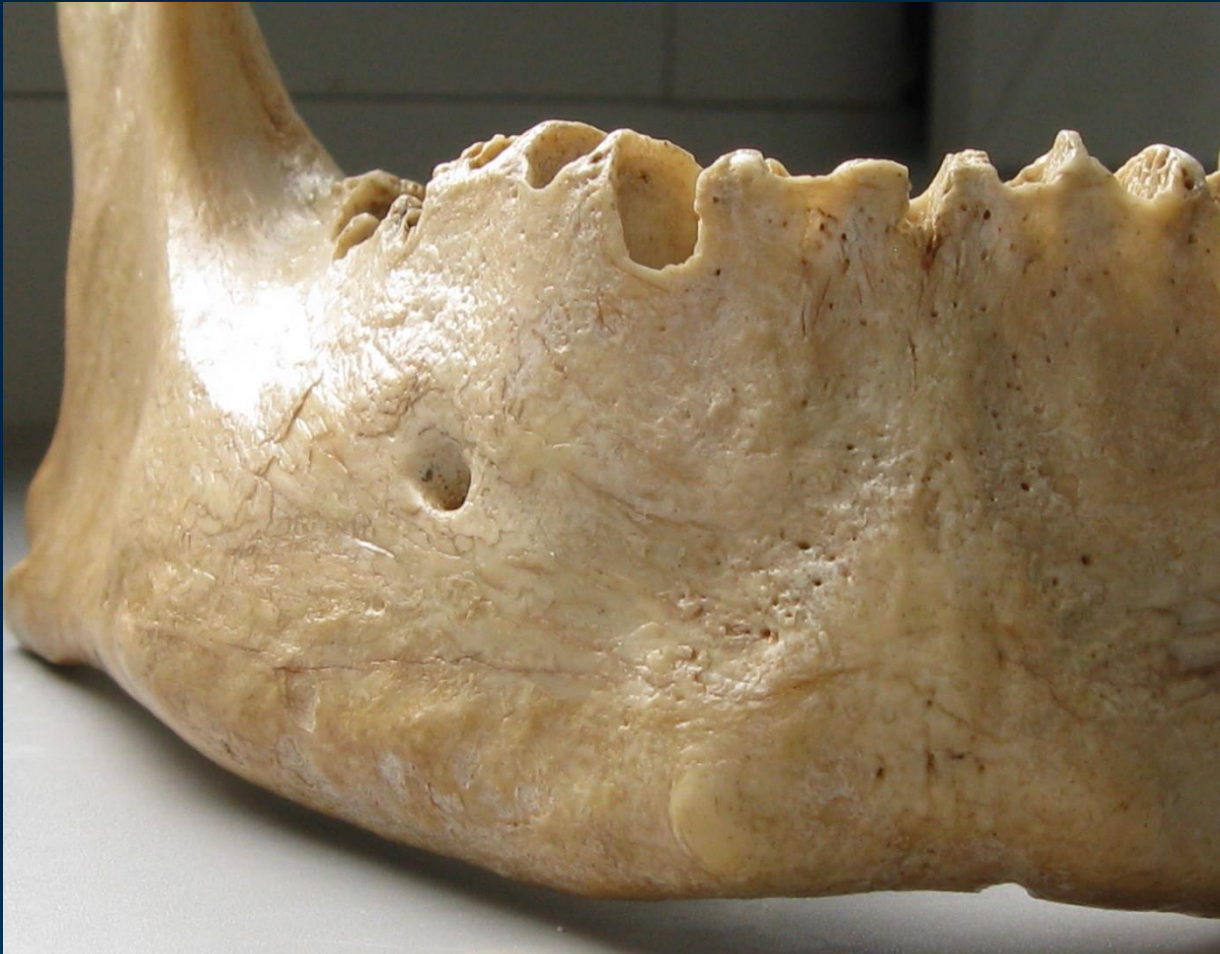

Over 99% simple

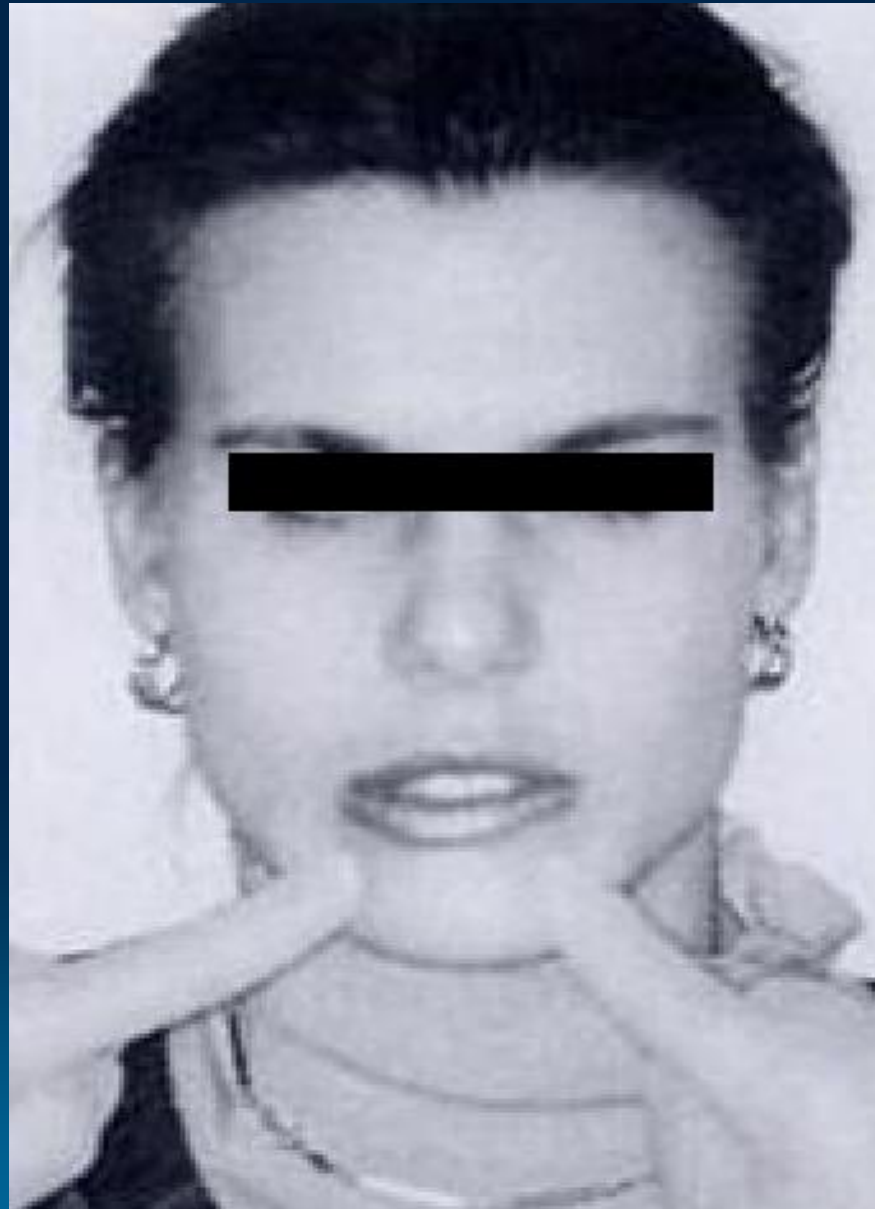Mental foramen

- The opening of mandibular canal
- on external side
- The position of this foramen is most frequently **near the apex of the mandibular second premolar** and rested between the premolars
- The foramen **open upward and slightly posteriorly** in adults
- The foramen open **straight upward** in newborns



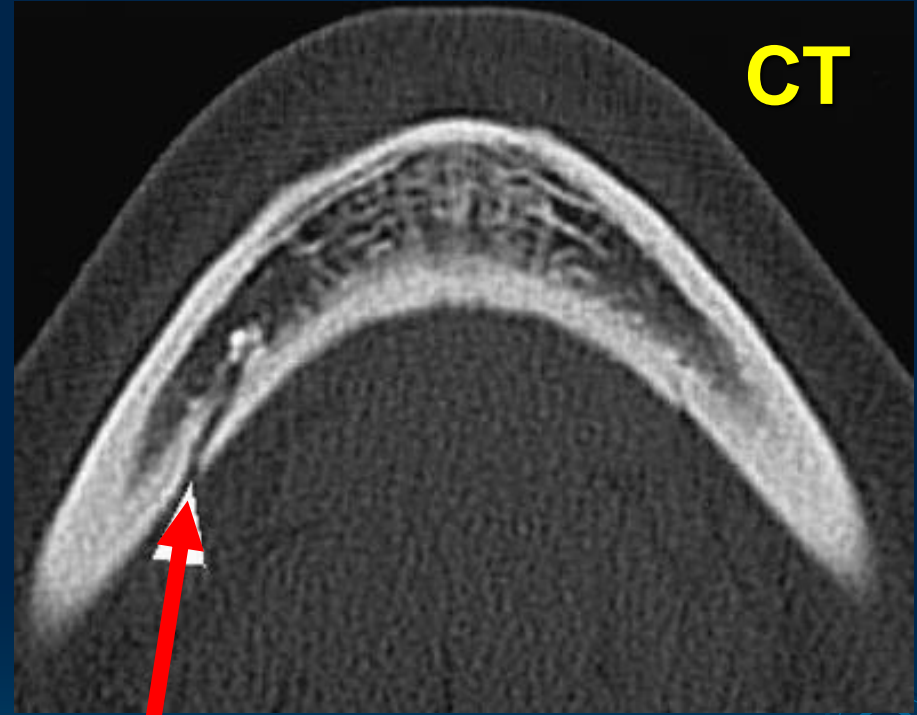

CAVE ! Local anesthesia



Lateral (accessory orifices)

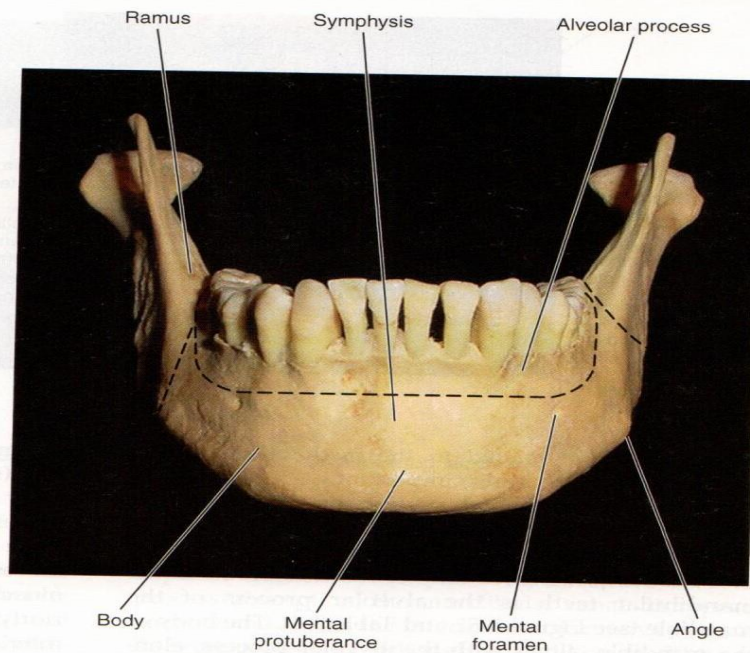
- Inner area of mentum sup. and inf. retromental for.
- Unilateral, bilateral or multiple
- In neighbourhood of mylohyoid line



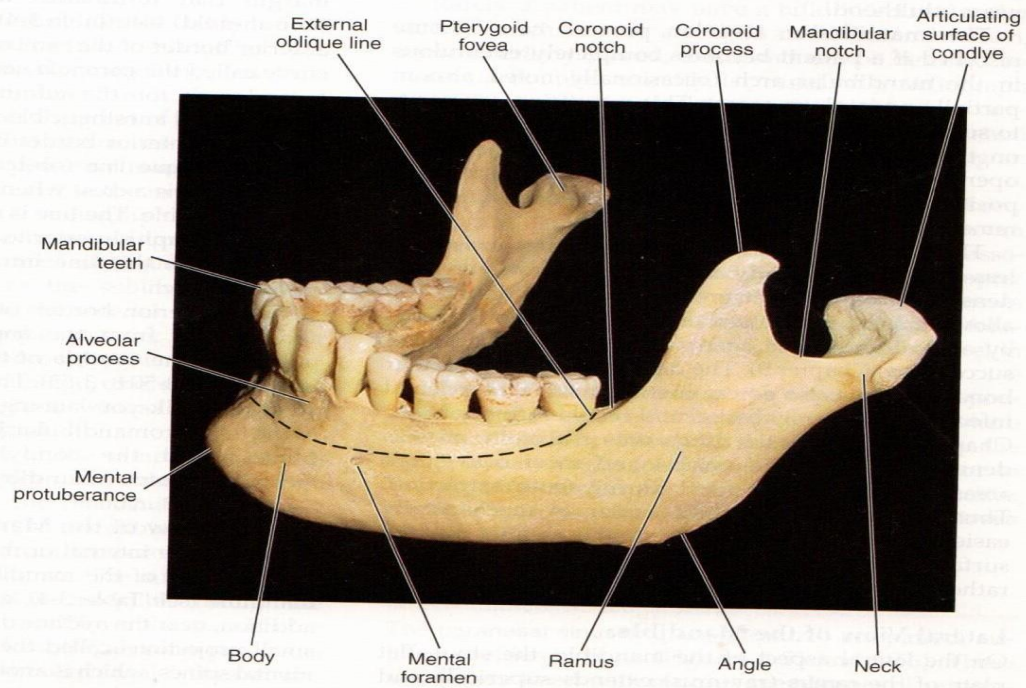
CAVE! Bleeding (implant placement)

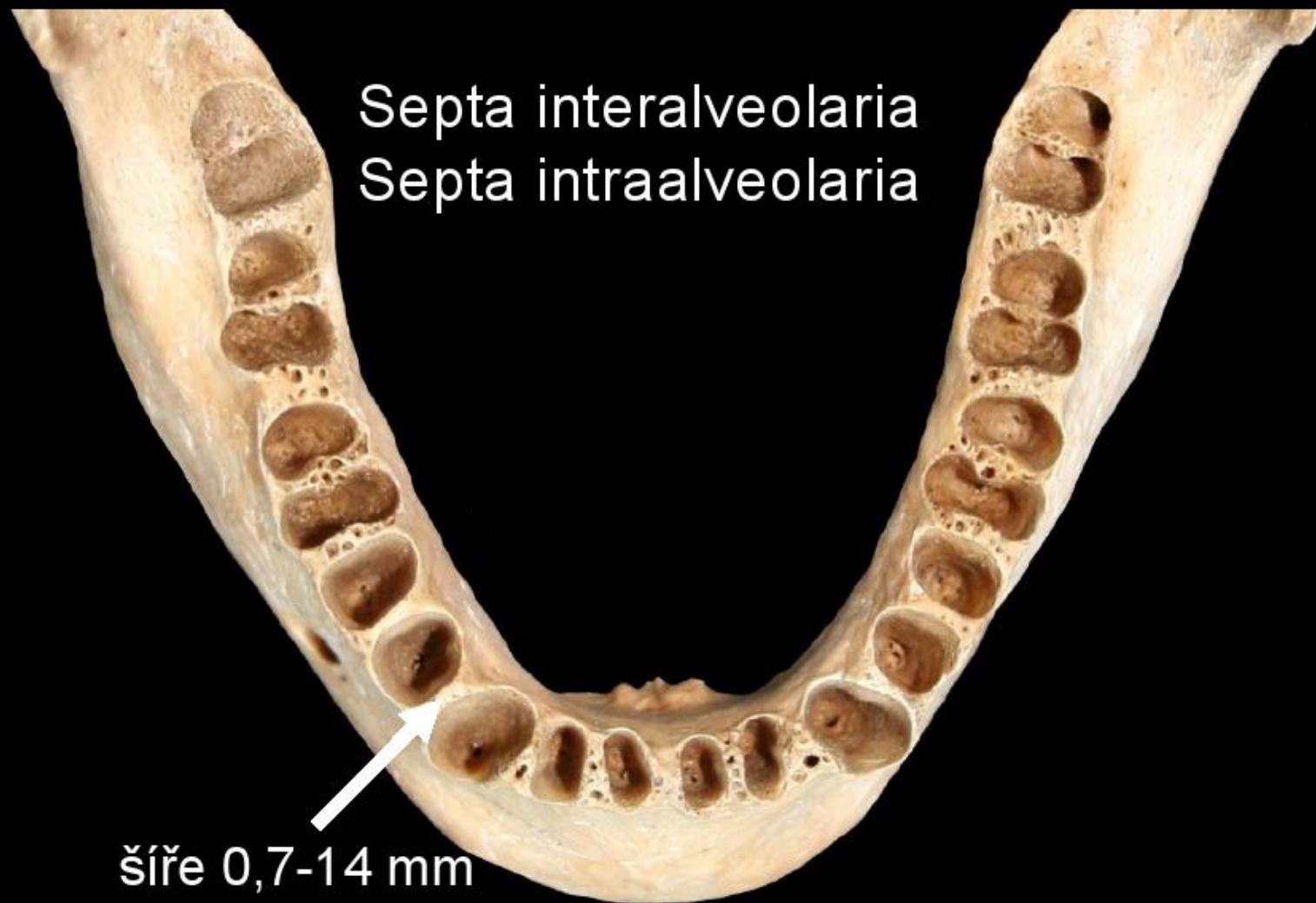Alveolar process

- The portion of the jaw bone that contains the roots of the mandibular teeth and the alveoli in which they are suspended
- The development is dependent on **tooth eruption** and its maintenance on **tooth retention**
- Is composed of **compact** bone (0.1-0.8 mm) that encloses the **spongiosa**



View of the mandible and

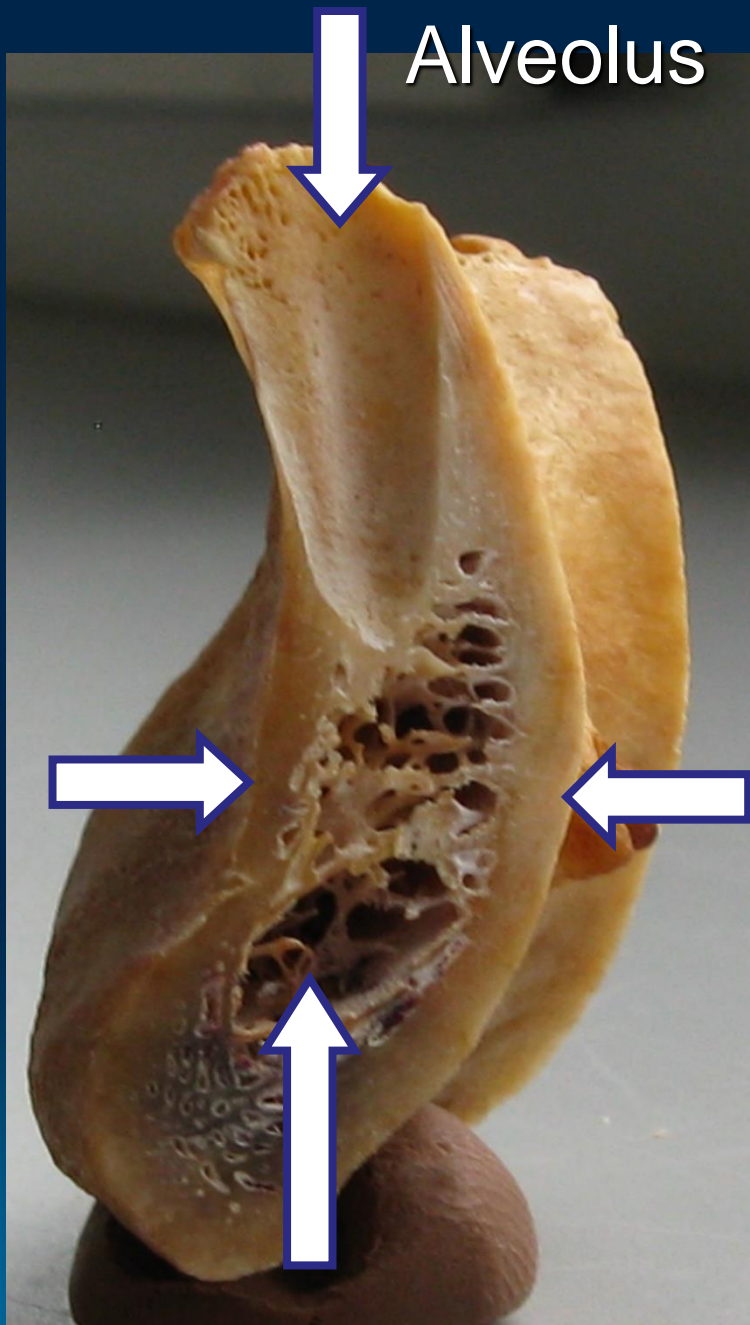




Septa interalveolaria
Septa intraalveolaria

šíře 0,7-14 mm

Jaw bone structure



Alveolus

Compact bone
(labial cortical
plate)

Compact bone
(lingual cortical
plate)

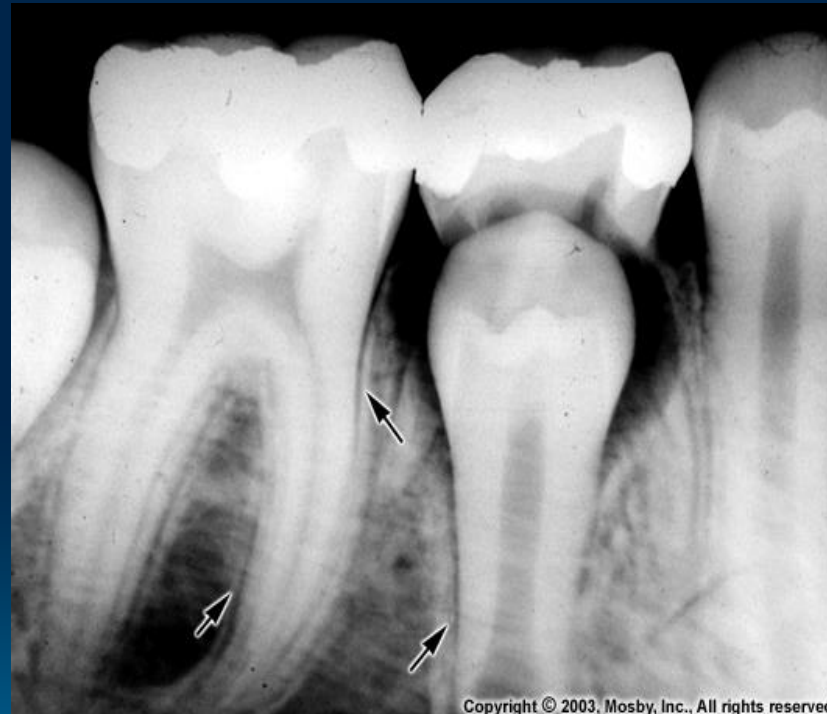Spongy bone

Alveolus

- Is composed of a thin plate of **cortical bone** with numerous perforations (or **cribriform plate**) that allow the passage of **blood vessels** between the bone marrow spaces and the periodontal ligament
- The coronal rim of the alveolar bone forms the **alveolar crest**, which generally parallels the cemento-enamel junction at a distance of 1-2 mm apical to it

Bundle bone

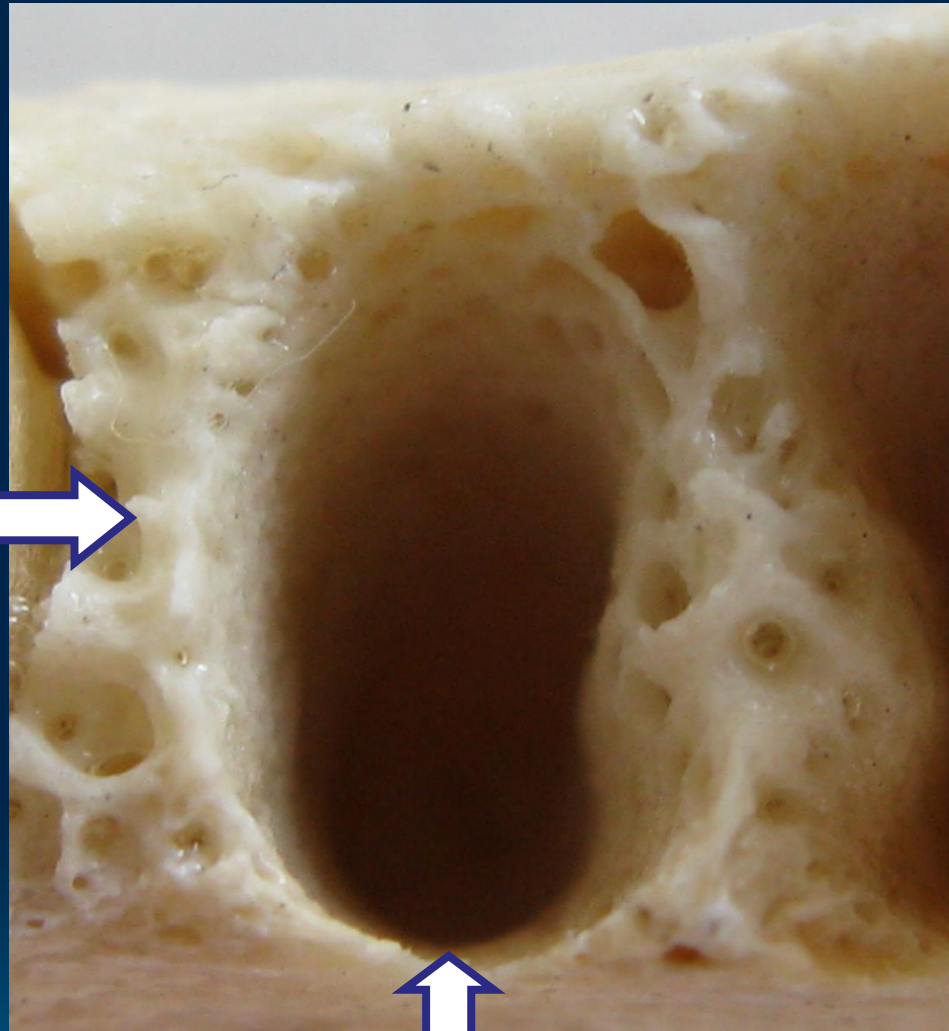
= the inner portion of the bone of the alveolus that surrounds teeth and into which the collagen fibers of the periodontal ligament are embedded



- Radiographically, the bundle bone is the **lamina dura**

Septum
interalveolare
(*spongy bone*)

0.7-14 mm

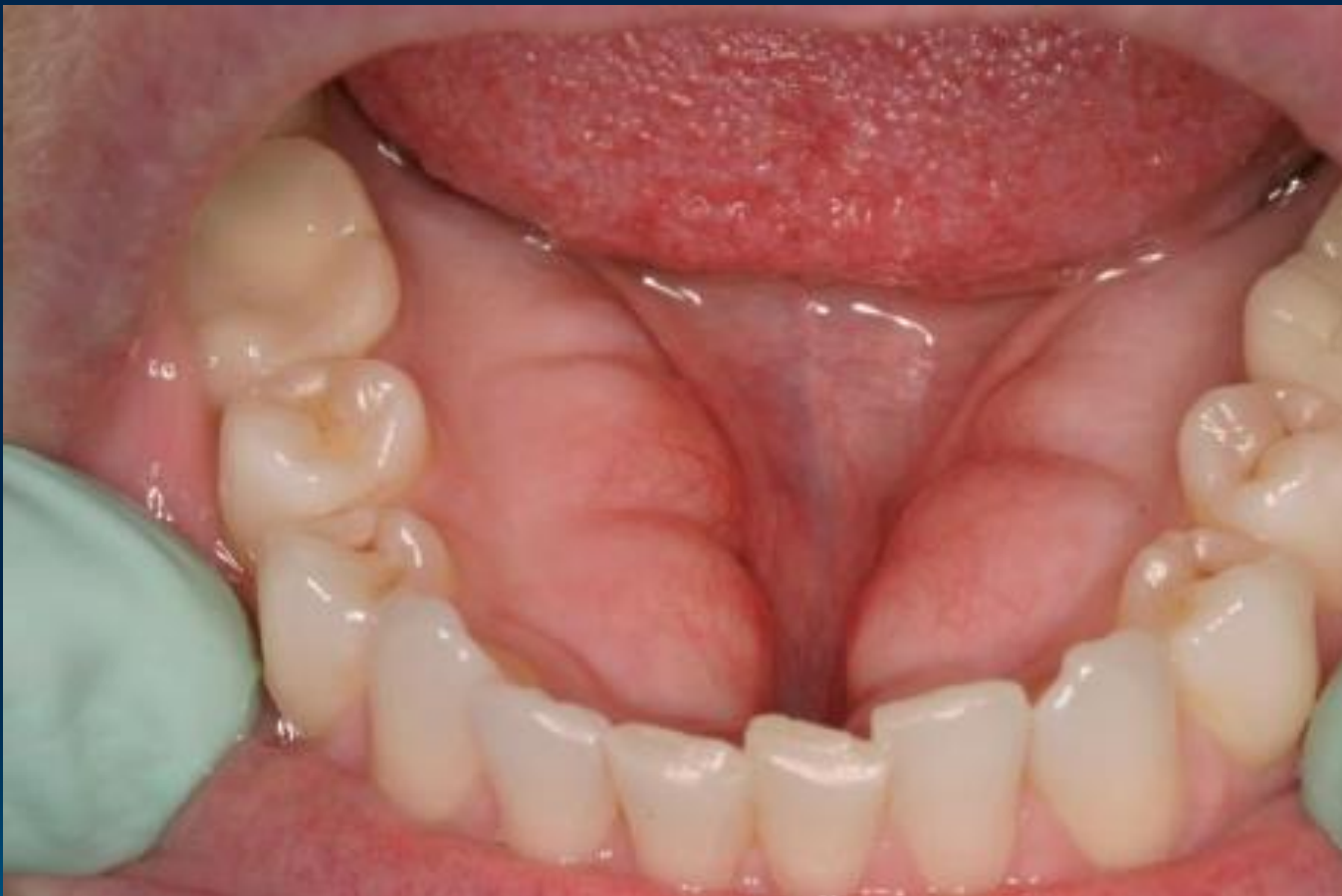

Alveolus
(*compact bone*)

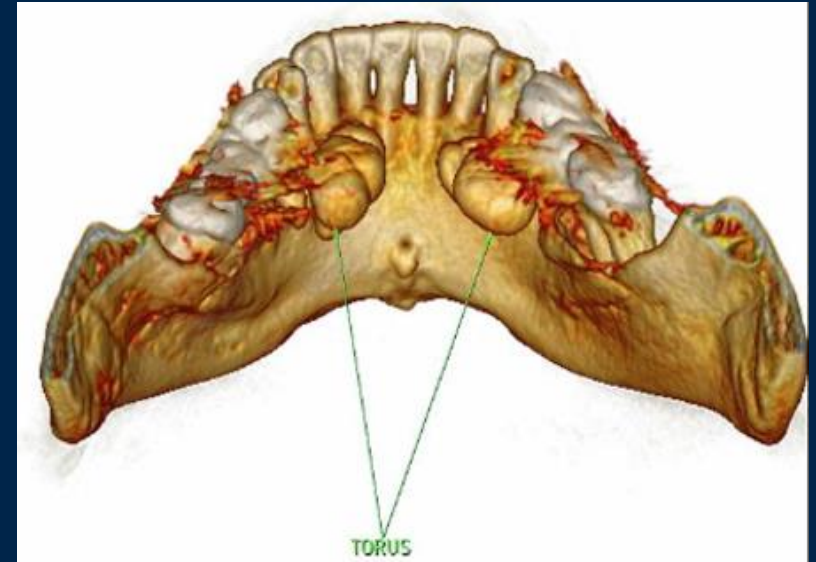
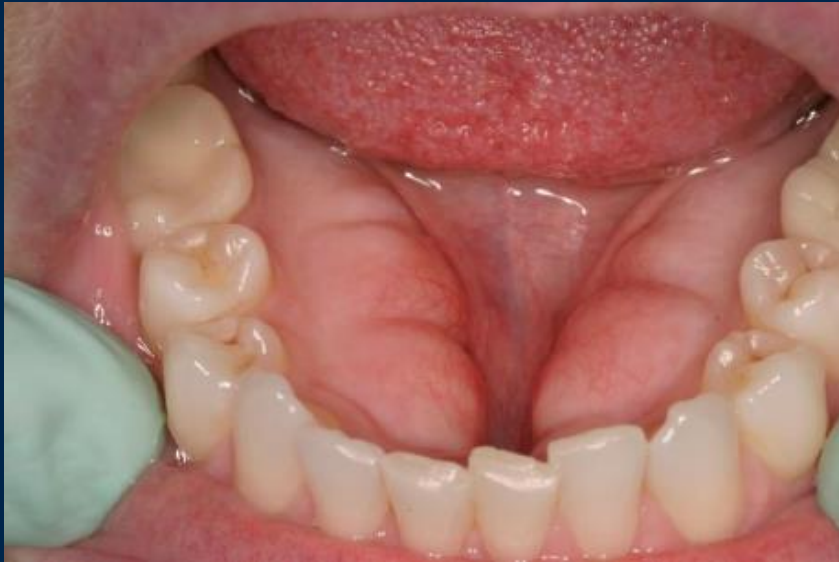Reconstruction of alveolar bone

- The whole life the bone keeps the potential to reconstruction
- Bone is resorbed on the **side of pressure** and opposed on the **site of tension** - regenerated
- Movement of a tooth by extrusion involves applying traction forces in all regions of the periodontal ligament to stimulate marginal apposition of crestal bone

?

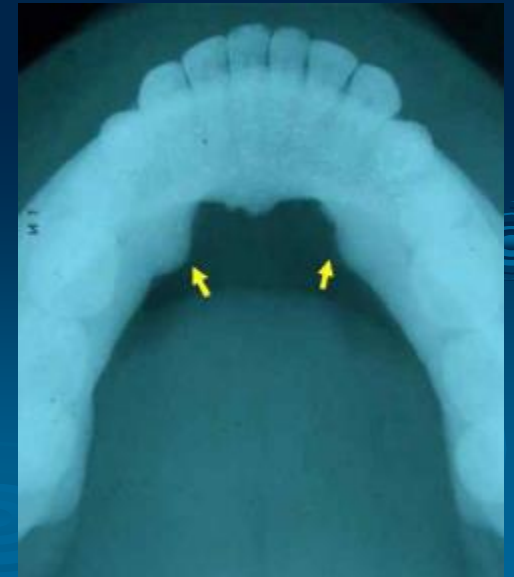

Torus mandibularis



Benign bony growth along the lingual aspect of the mandible

- unilateral or bilateral
- most often between the second and third decade of life
- unclear etiology

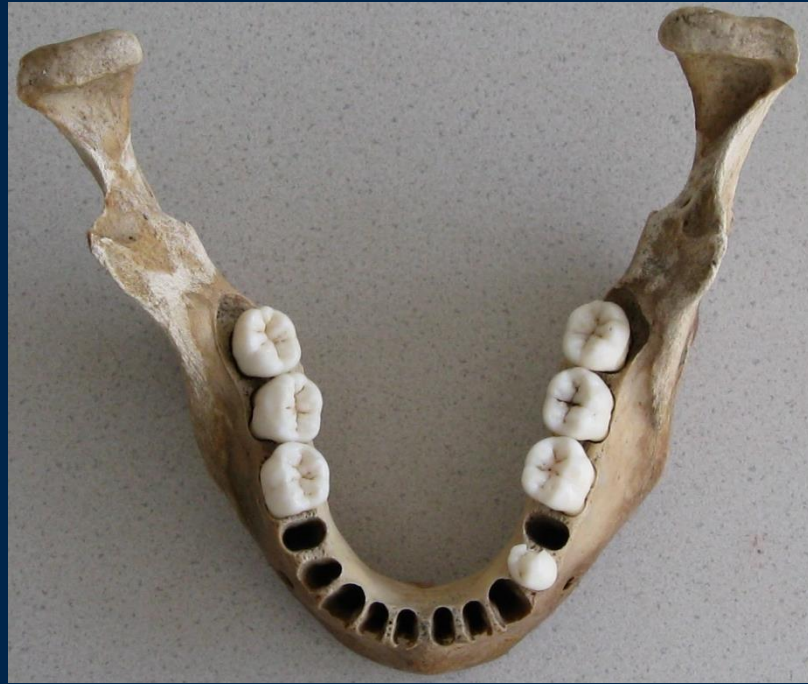

Dentoalveolar topography

Important for anesthesia, extraction, injury, implantology, endodontic treatment ...


1. The transverse asymmetry of alveolus
2. The rate of the spongy and the compact bone
3. The relationship of the roots of the lower jaw to neighbouring structures

1. The transverse asymmetry of alveolus

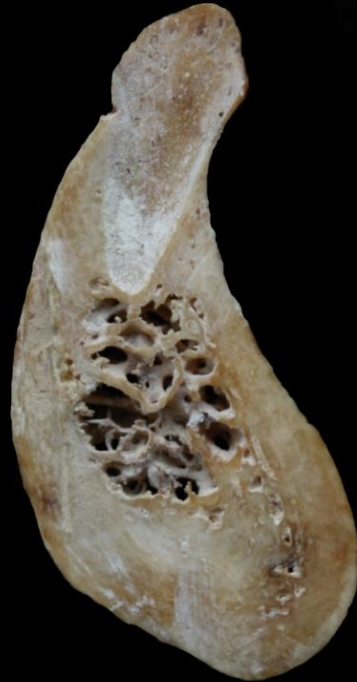

- The dental and skeletal arch are asymmetric !
- Roots of the teeth:
 - 1-5 eccentric in the vestibular direction
 - 6 in alveolar process axis
 - 7-8 eccentric into oral direction

2. The rate of the spongy and the compact bone

- The layer of **compact bone** is thicker than in the upper jaw
 - Roots of the incisivi and canini teeth are surrounded by the compact bone
 - Roots of the premolars and molars are surrounded by the **pre- and retroalveolar spongy bone** that is thin, fragibile
- 

Incisivi, Canini



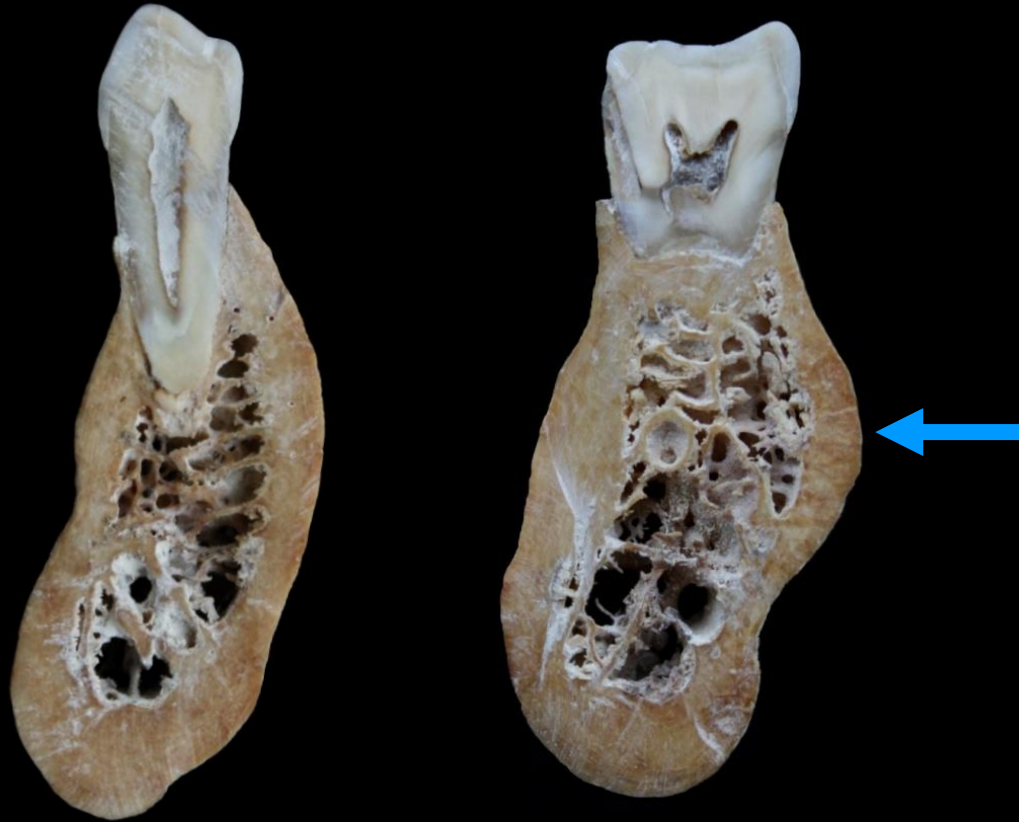
Compact bone only

CAVE!

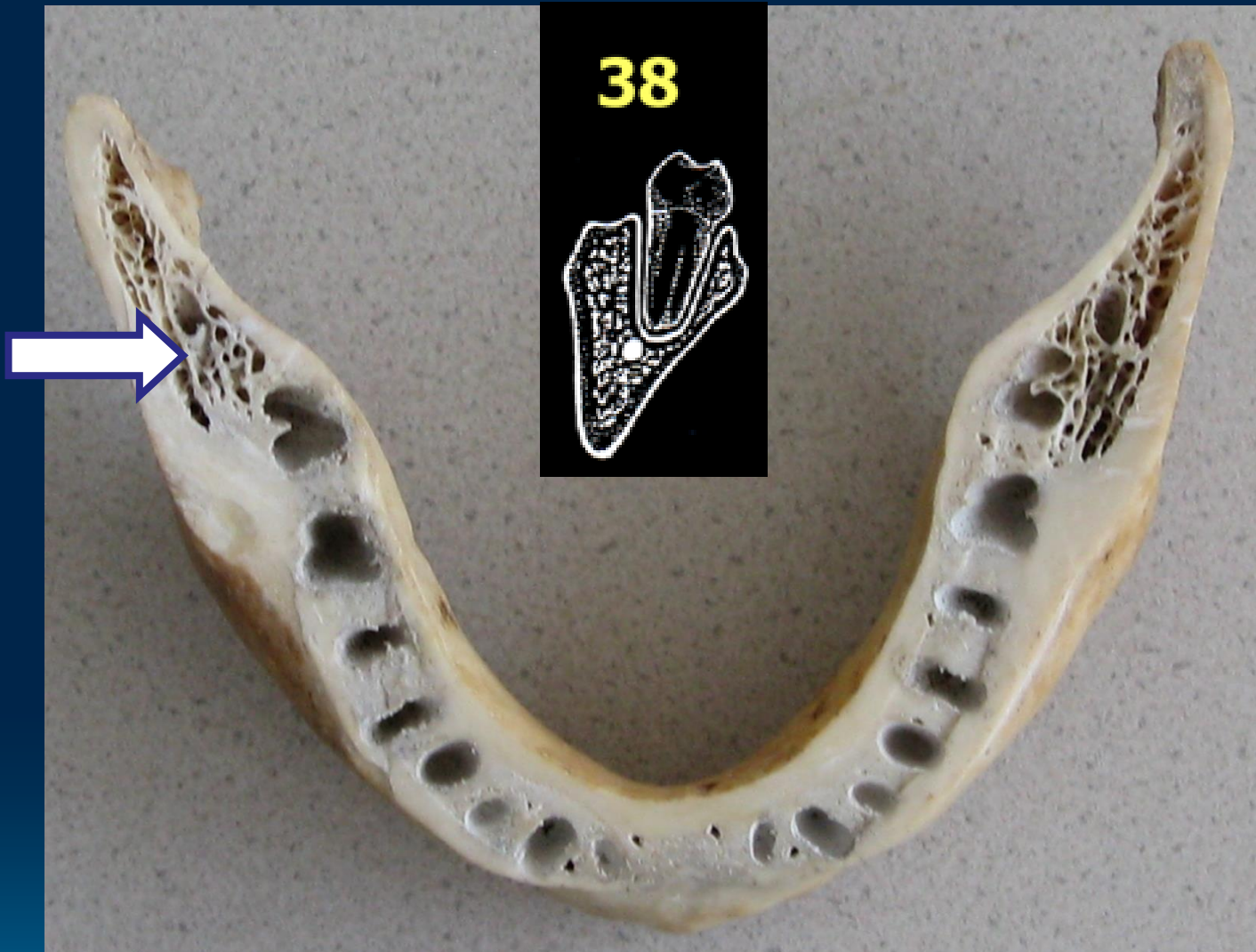
- Fractures by extraction !
- Root of the 3rd tooth – fracture of mandible !

Premolars

Molars



Compact bone and variable thickness of spongy bone buccally and lingually ([linea mylohyoidea](#))

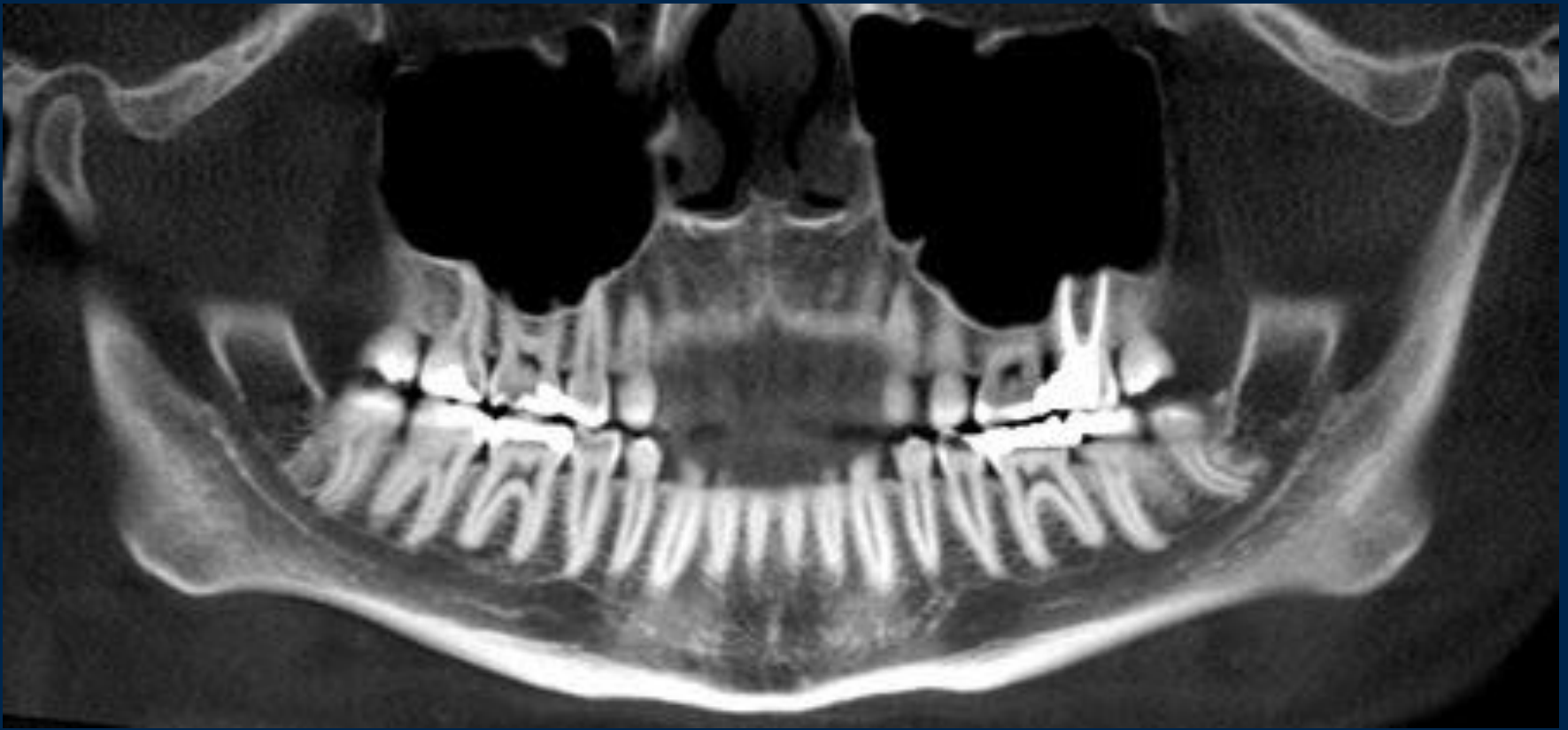

Spongy bone is distally to 8

3. The relationship of the roots of the lower jaw to neighbouring structures

Canalis mandibulae
(incisivus, mentalis)





Variable layer of **spongy bone** between canals and teeth's roots

CAVE!

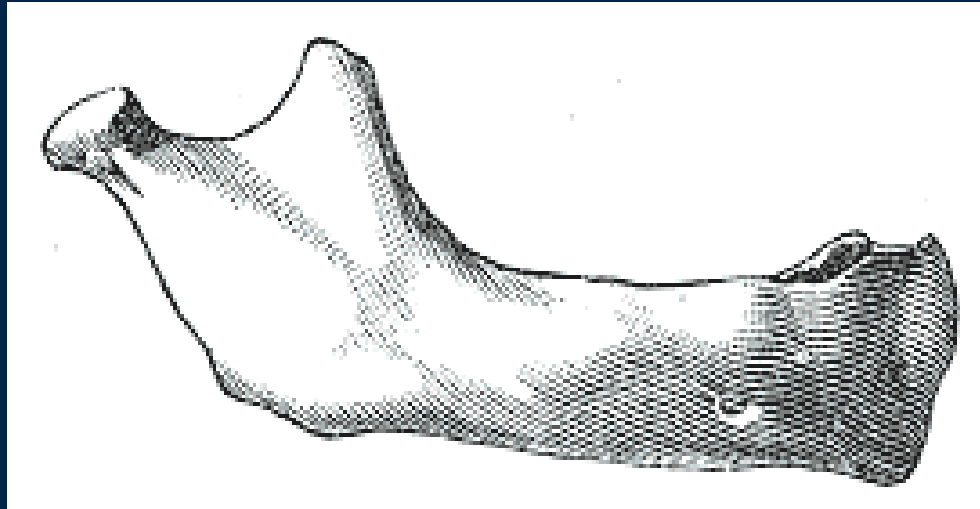
- Dehiscence of the canal and the alveolus
- Implants

Age changes

- newborn
- adult
- old

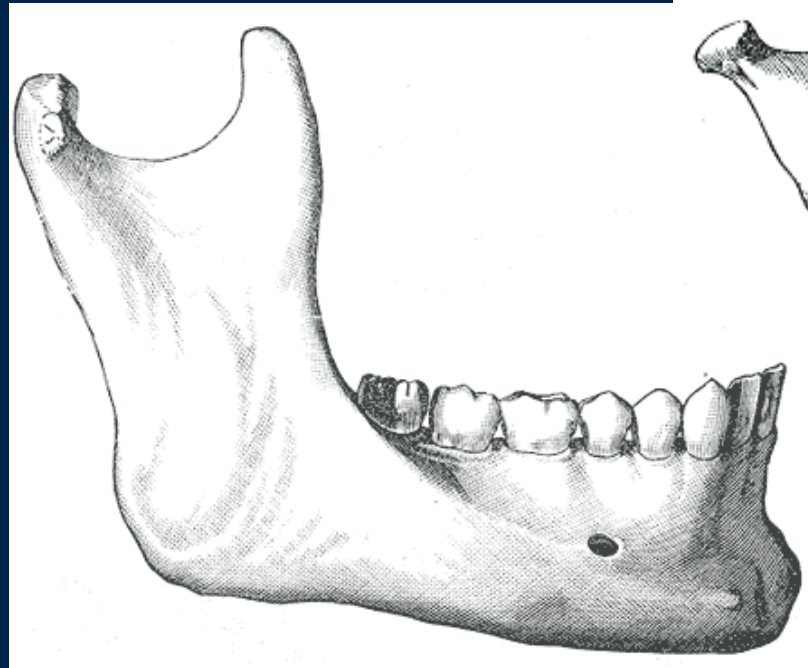


Newborn



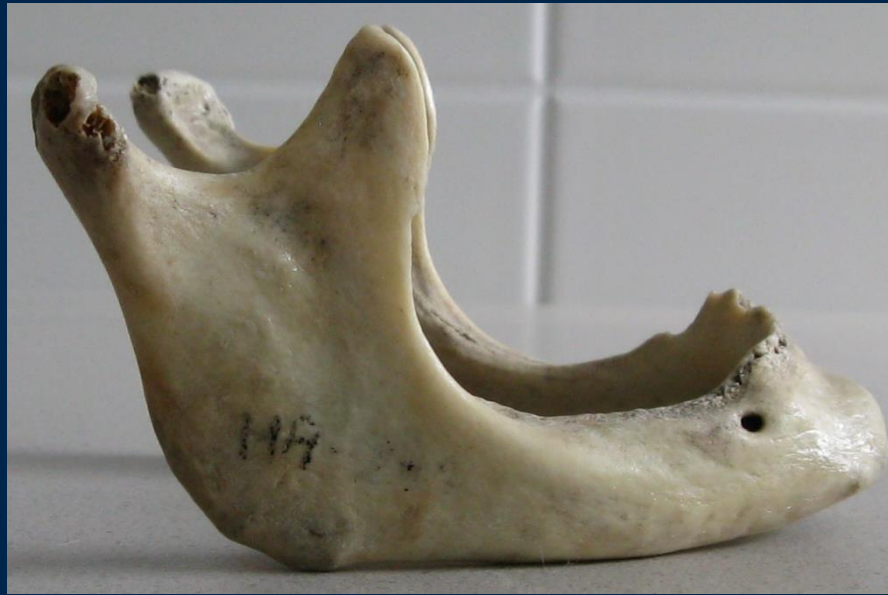- mandibular corpus is low
- the body contains the sockets of deciduous teeth (only with the development and eruption of teeth proc. alveol. appears)
- the angle between corpus and ramus is 150° (widely open)
- mental foramen lies on the lower edge of corpus
- mandibular body is still paired - it meets in so-called symphysis menti – it ossifies in first year of life

Adulthood

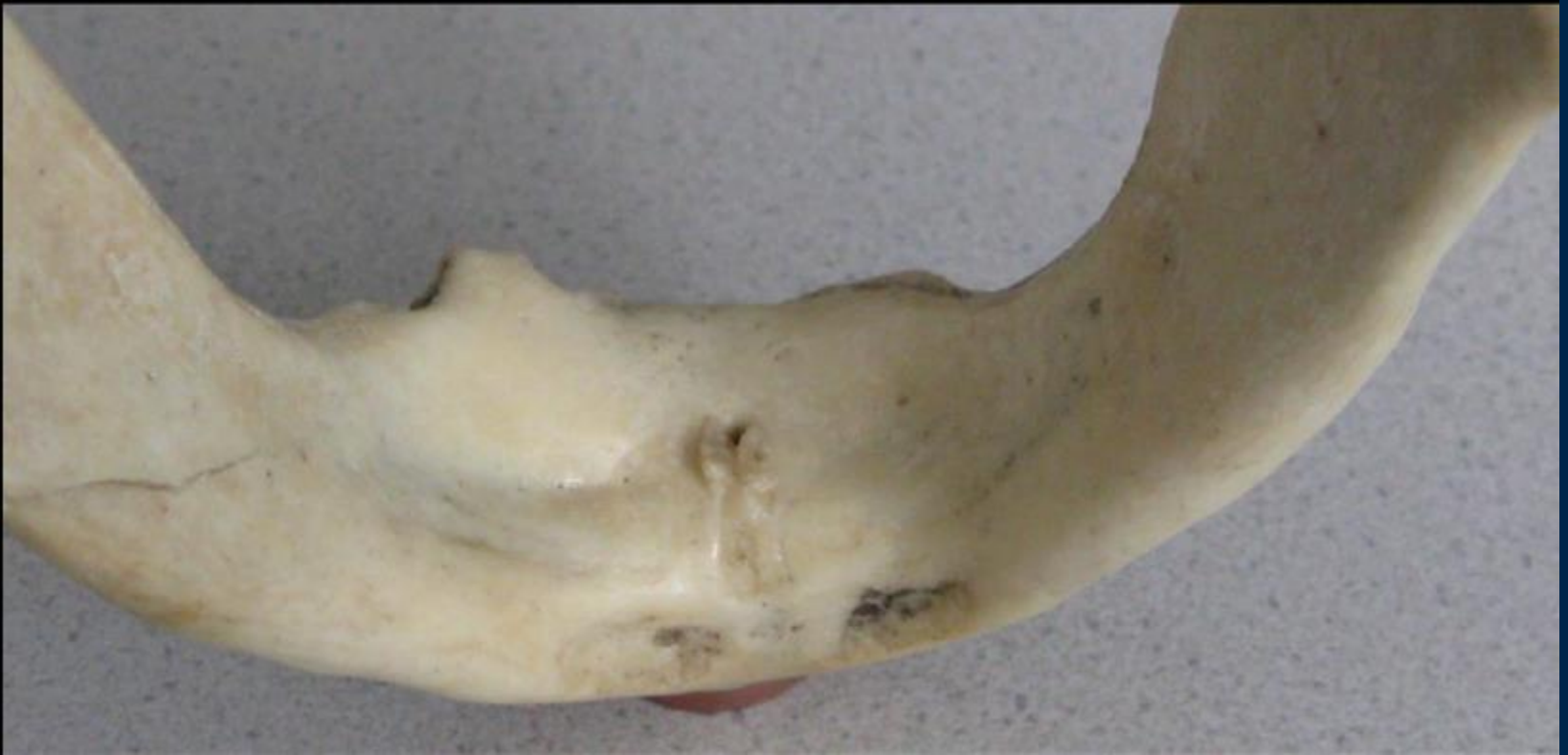

- the angle is much sharper – about 120°
- condylar process is higher than the coronoid process and the sigmoid notch becomes deeper
- Alveolar processus developed
- Mental foramen lies in the middle of the corpus and changes its direction

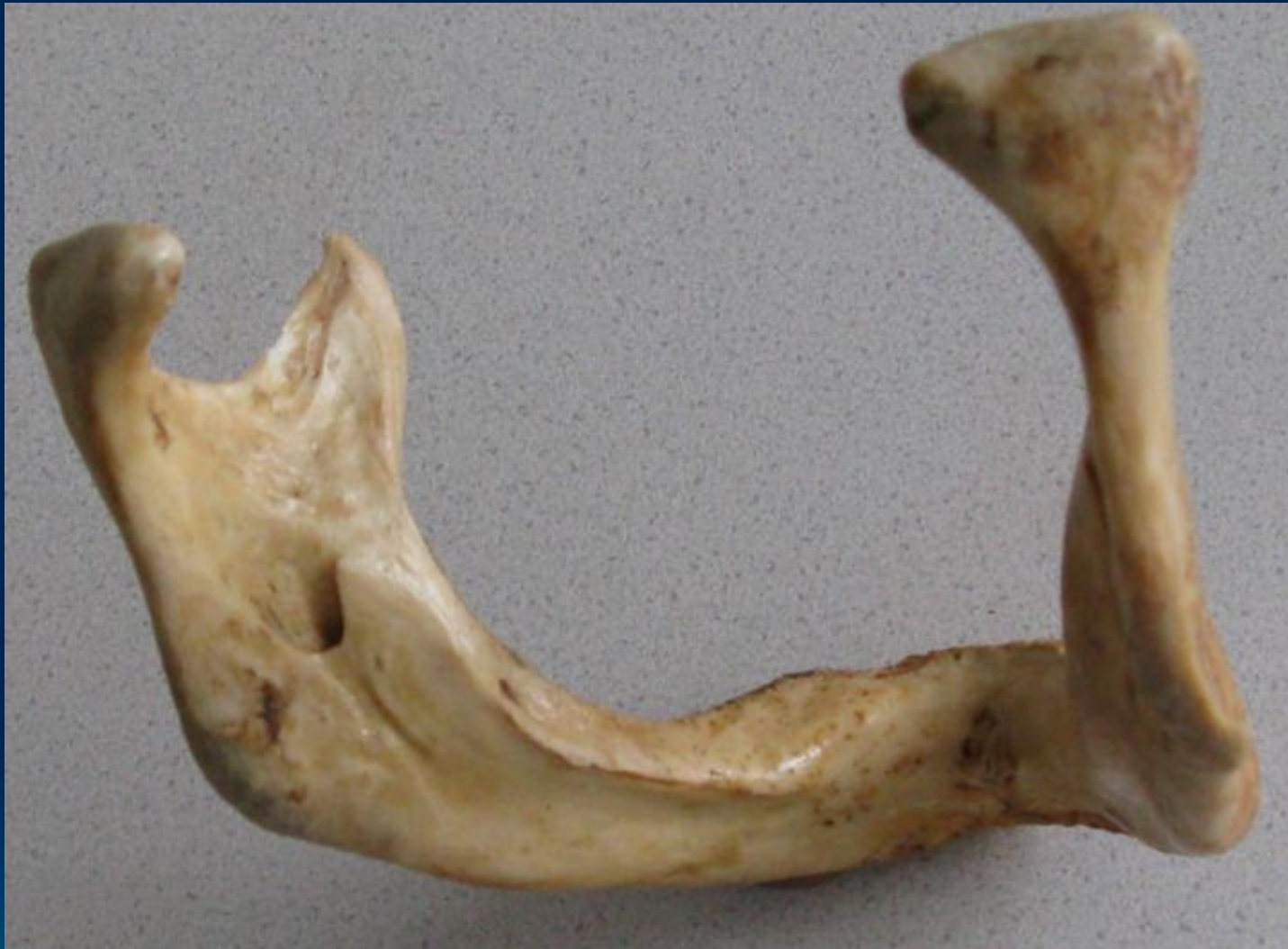Old age



- after the loss of teeth, the body is reduced + due to atrophy of the alveolar process → mandibular foramen is closer to the alveolar border
- enlargement of the angle to 140°
- deepen pterygoid fovea → neck is tapered
- sharp mylohyoid line, highlighted mental spinae



- enlarged mental spinae



- sharp mylohyoid linea

Resorption of alveolar bone

Decreased bone of alveolar process is noted when there is inactivity of tooth

