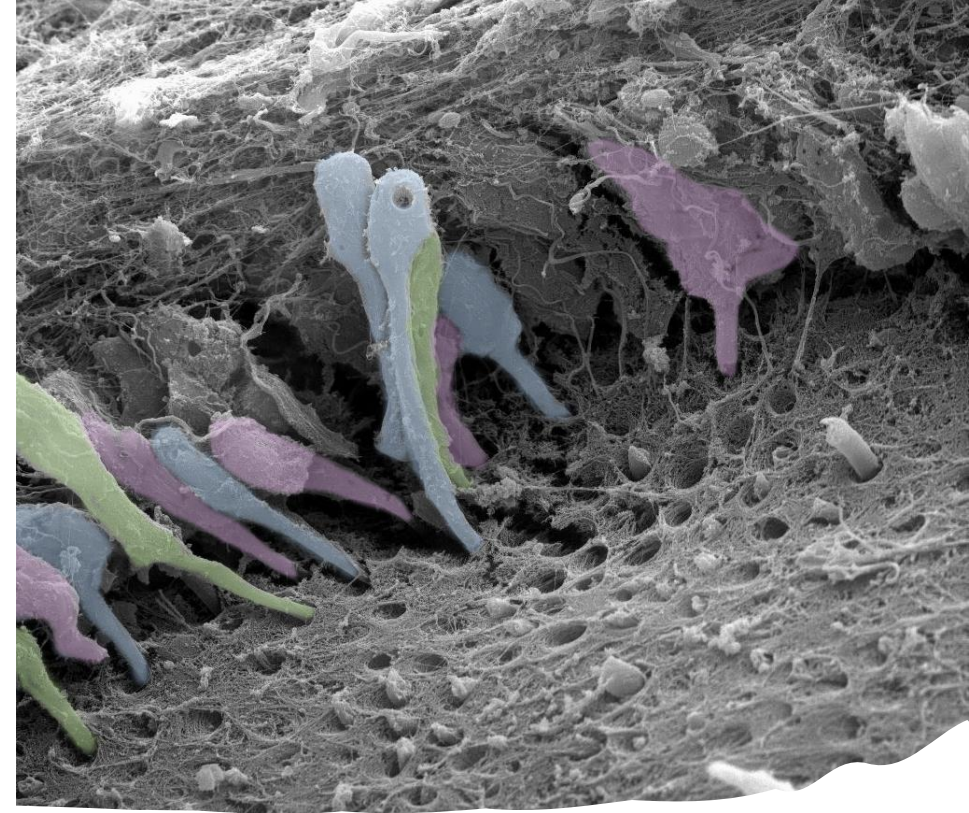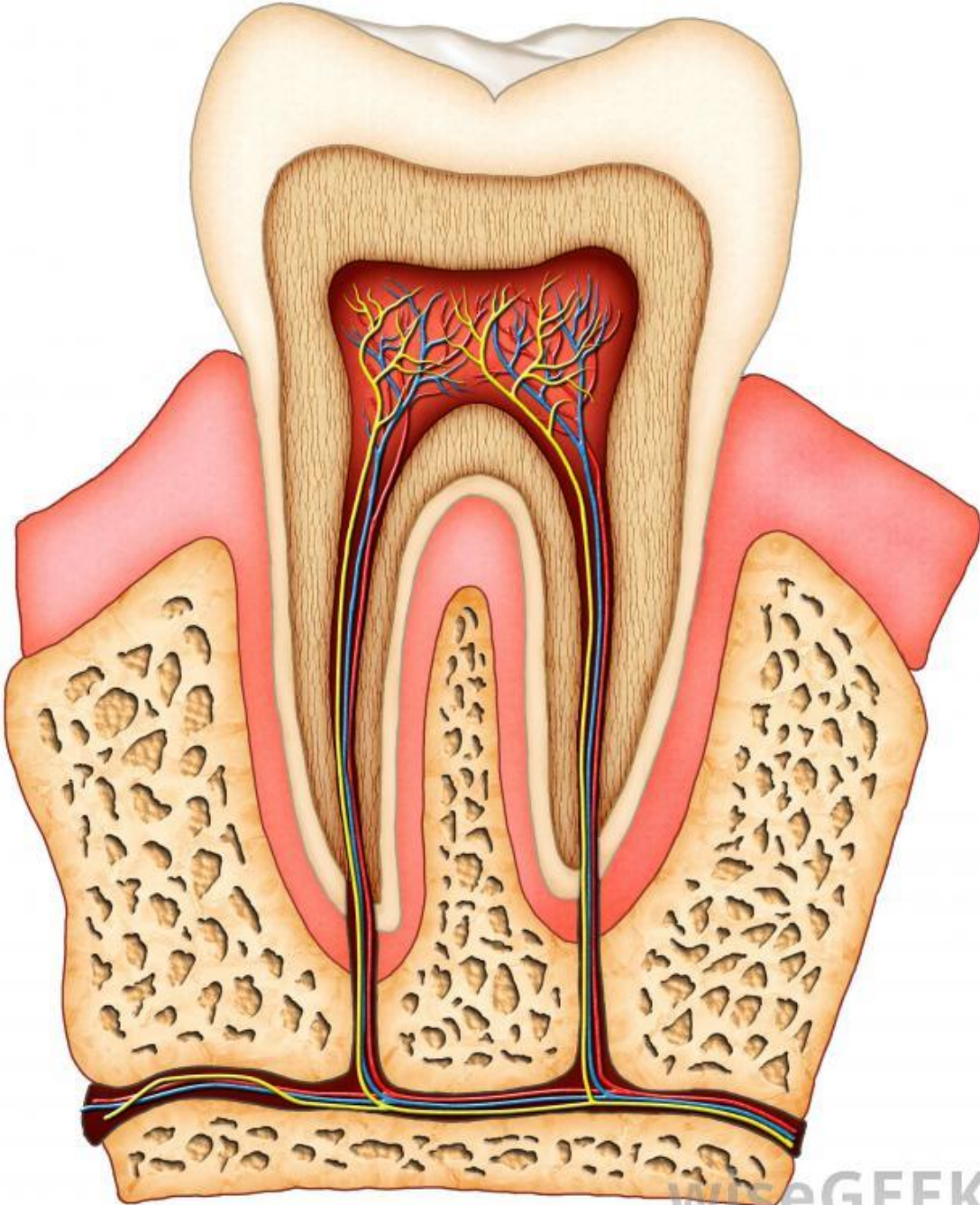
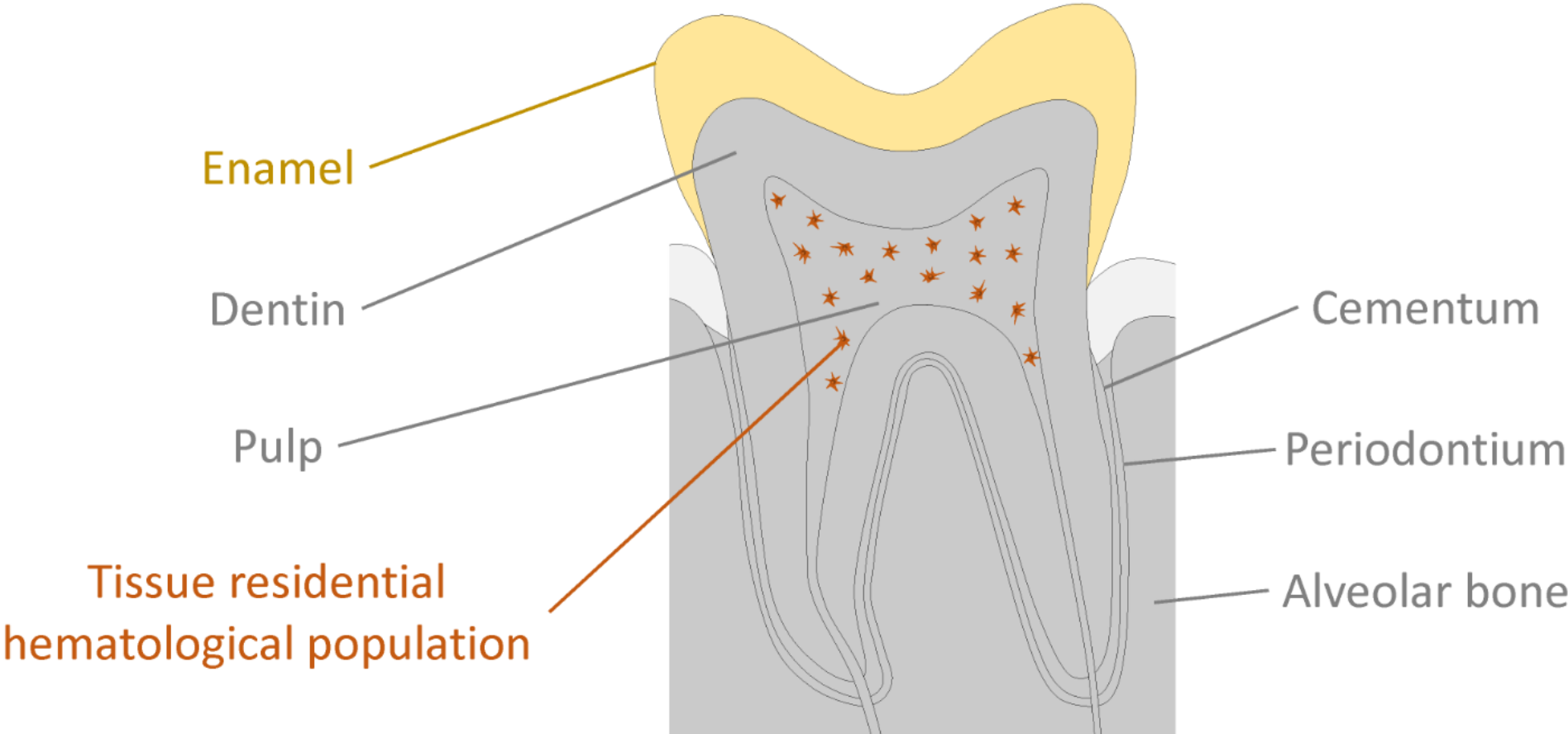


Dentin-pulp complex

Dental pulp + dentin

10. 4. 2024

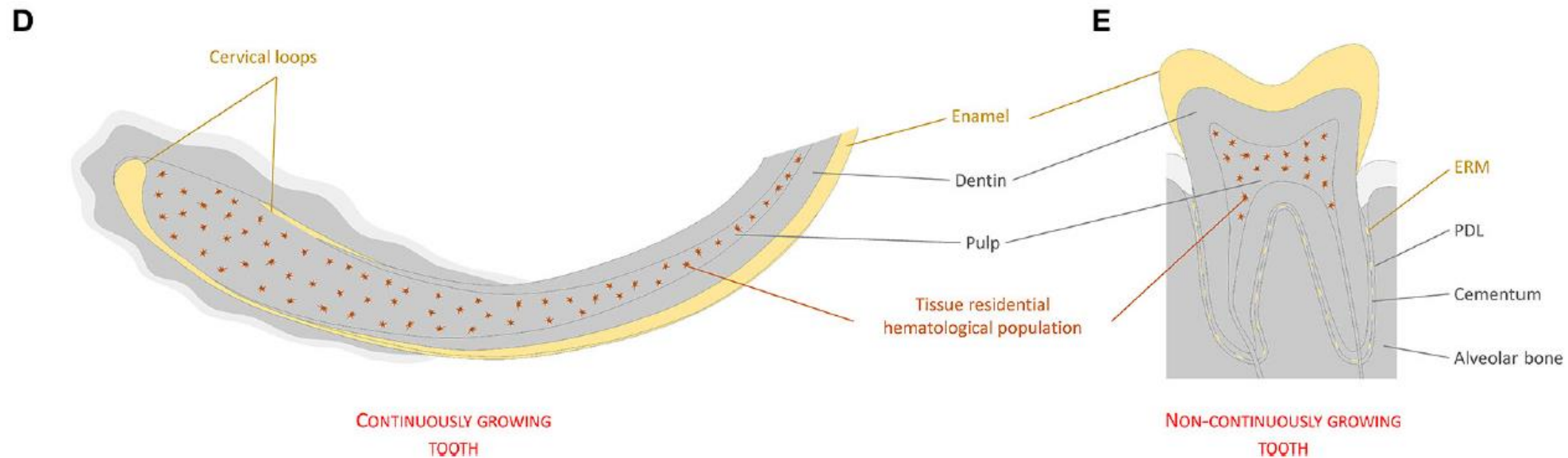
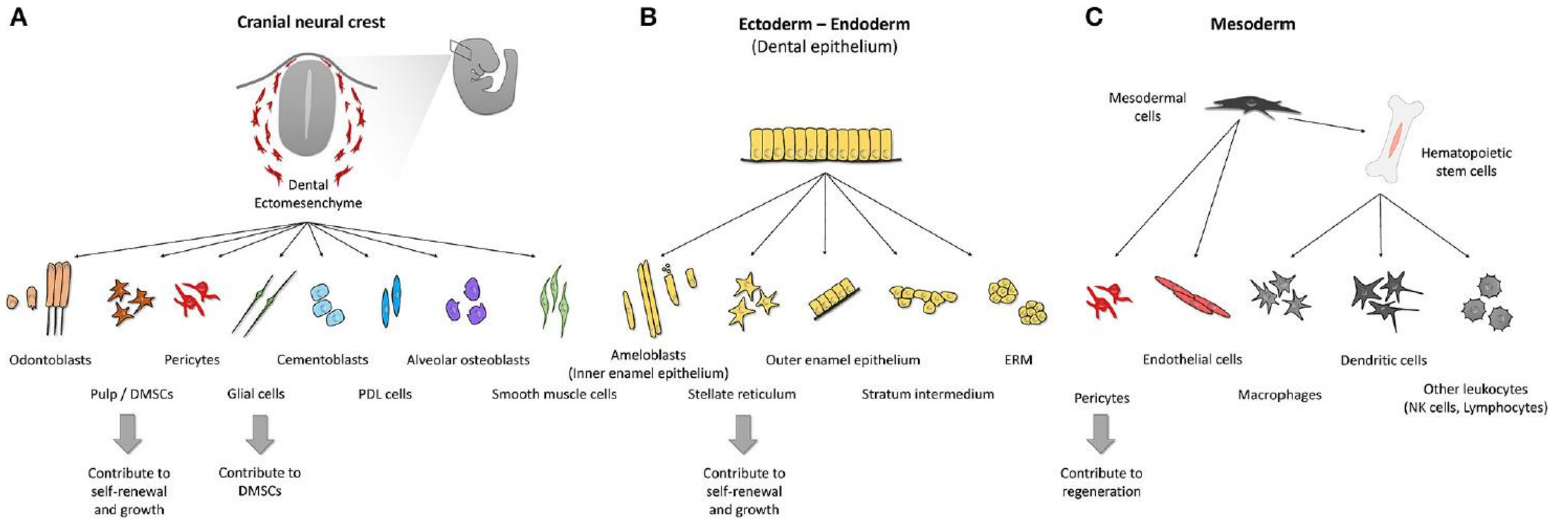


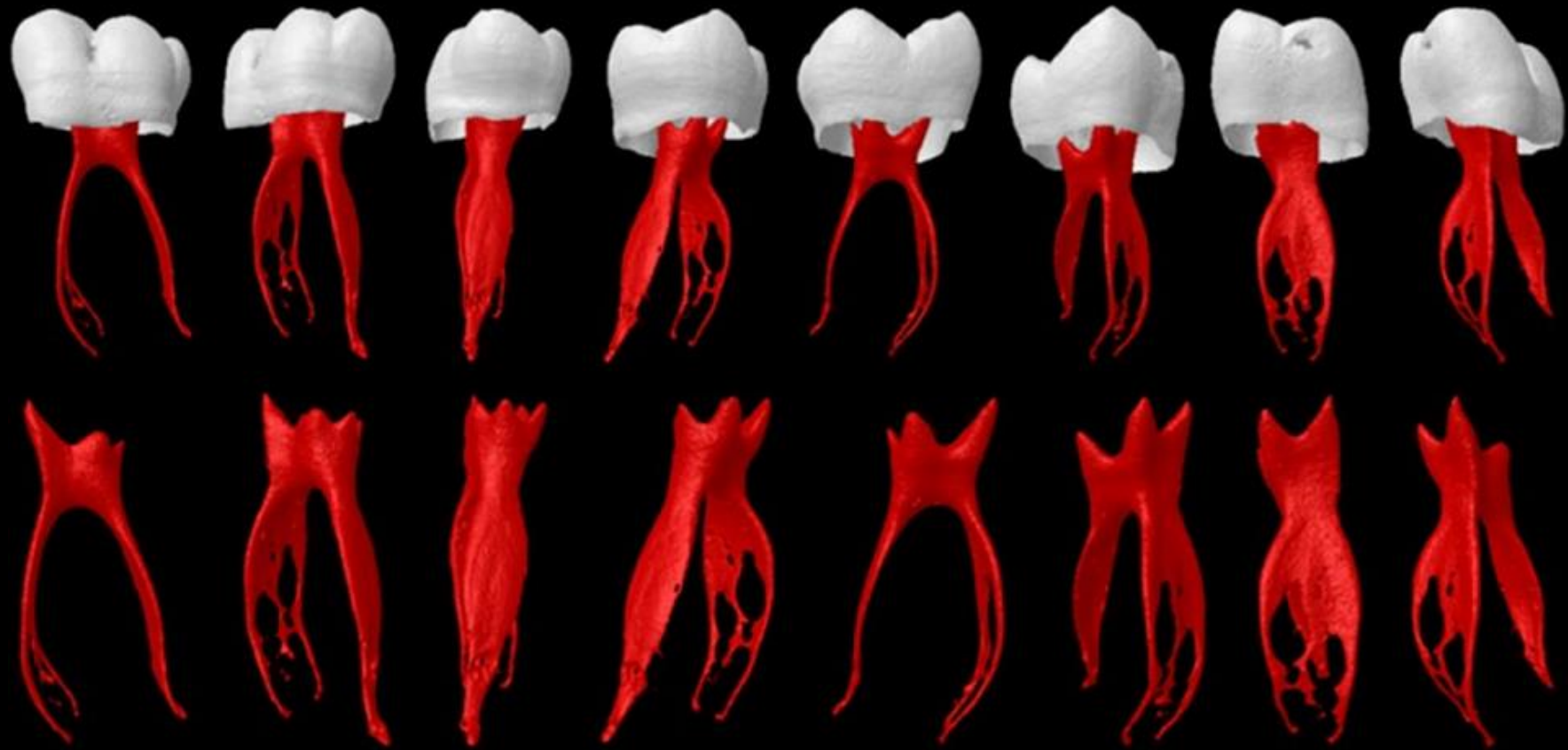


Neural crest - derived

Epithelial - derived

Mesodermal - derived





The fundamental importance of the pulp:

- a) **Tooth vitality** - nutrition and protection of odontoblasts against foreign and infectious agents
- b) **Reparative processes** - pool of undifferentiated cells for pulp fibroblasts and odontoblast-like cells

Dental pulp shape depends on:

- Tooth Type
- Age of the individual
- Pathological and repair changes

Dentin-pulp complex

Summary term used for dental pulp and dentin
Tight developmental, histological and functional connections
Common development history (ectomesenchymal origin)



Dental pulp Fibroblasts

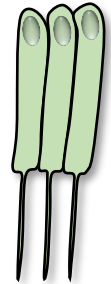
Stromal pulp tissue
Support for odontoblasts
Support for blood vessels and nerves
Immune reactions
Stem cell niche

Interactions



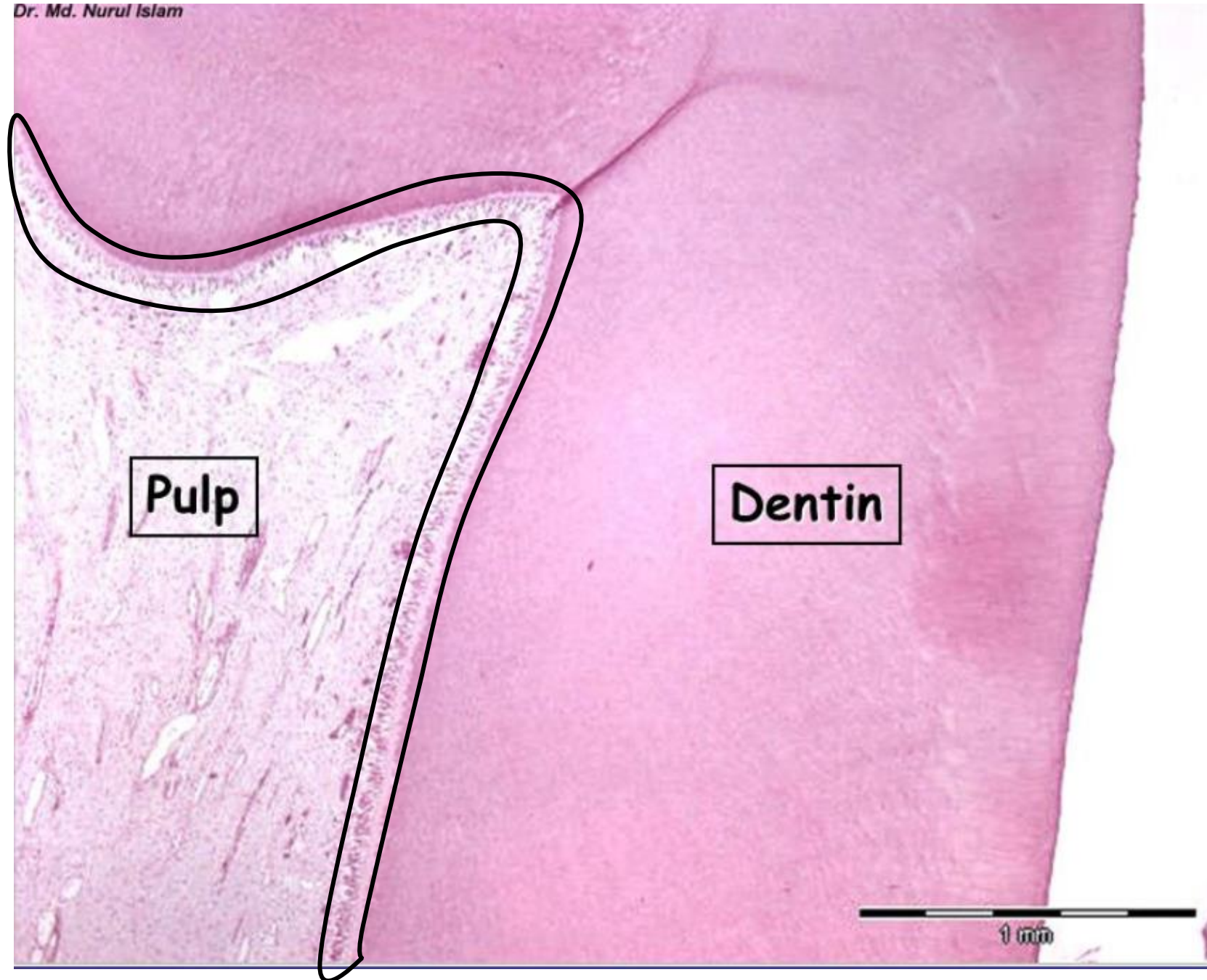
Odontoblasts

Dentin production
Living component of dentin
Reactions on tooth damage
(pain, immune response, reparative processes)



Dentin-pulp complex

Dr. Md. Nurul Islam




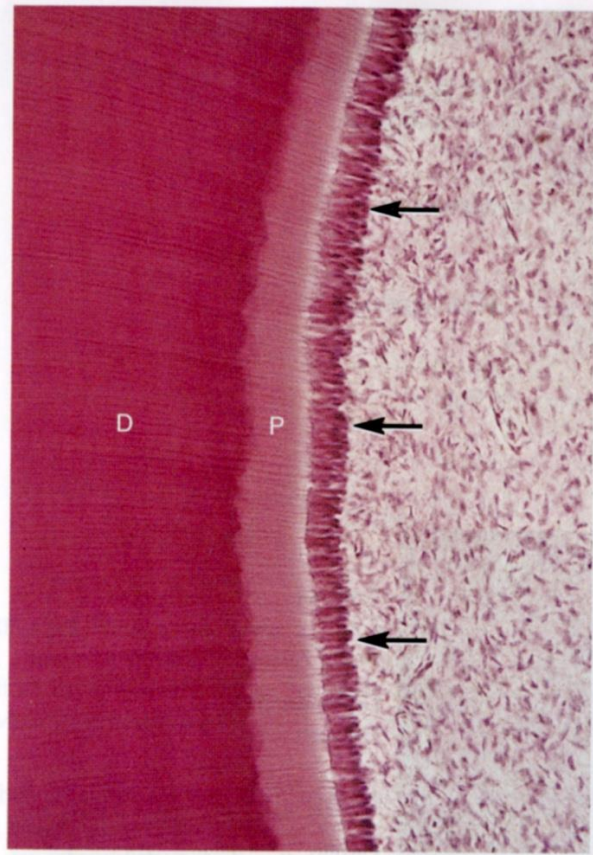
Odontoblasts

Interface of dentin and the pulp

Elongated shape, polarization (nucleus with organelles in basal third)

Single cell layer

Secretory vesicles on apical side



Odontoblasts function

- In healthy teeth, lifetime-active cells
- Odontoblasts' processes/fibres (Tomes Fibres) maintain dentin matrix formation, responsible for dentin viability
- Odontoblasts' processes involved in the pain perception
- Periodontoblastic space between the tubule wall and Tomes fibre, contains dentinal fluid and mucopolysaccharide material

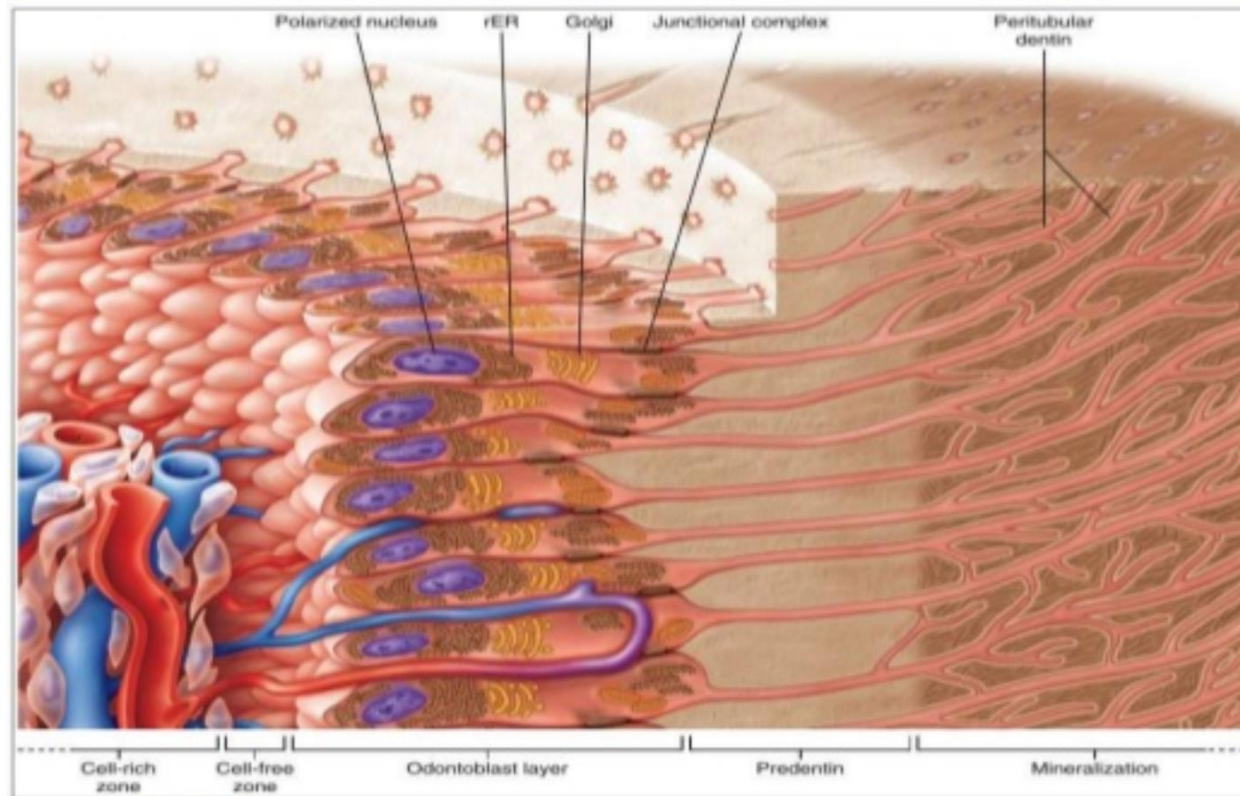
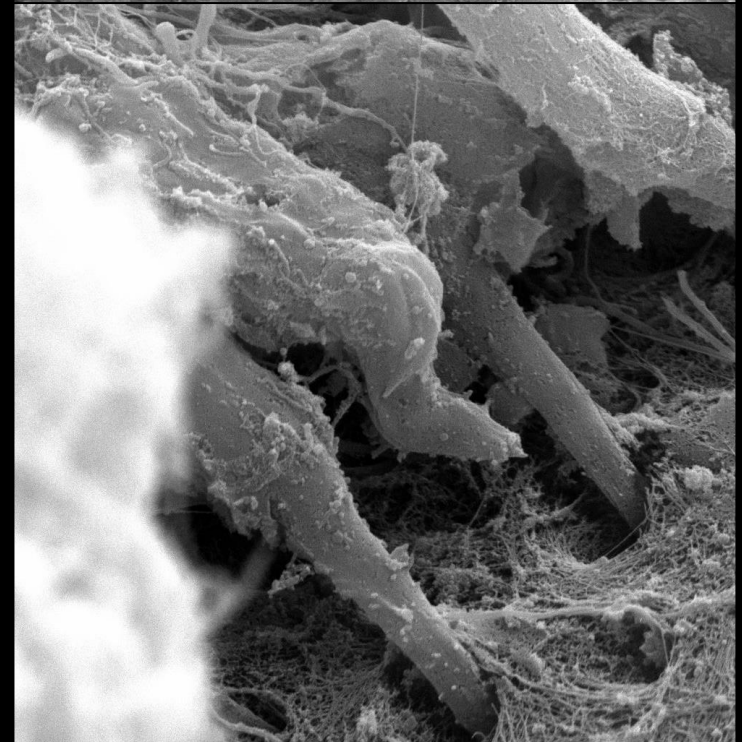
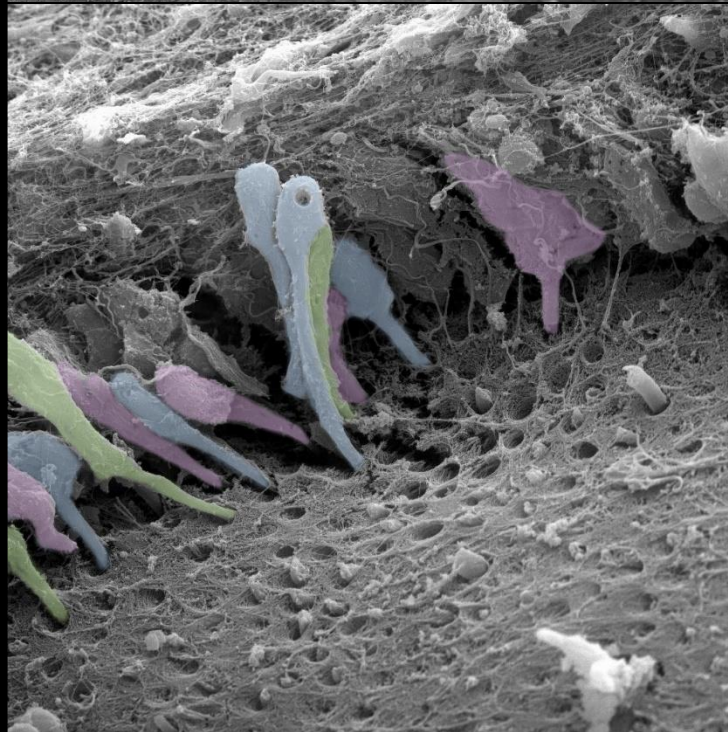
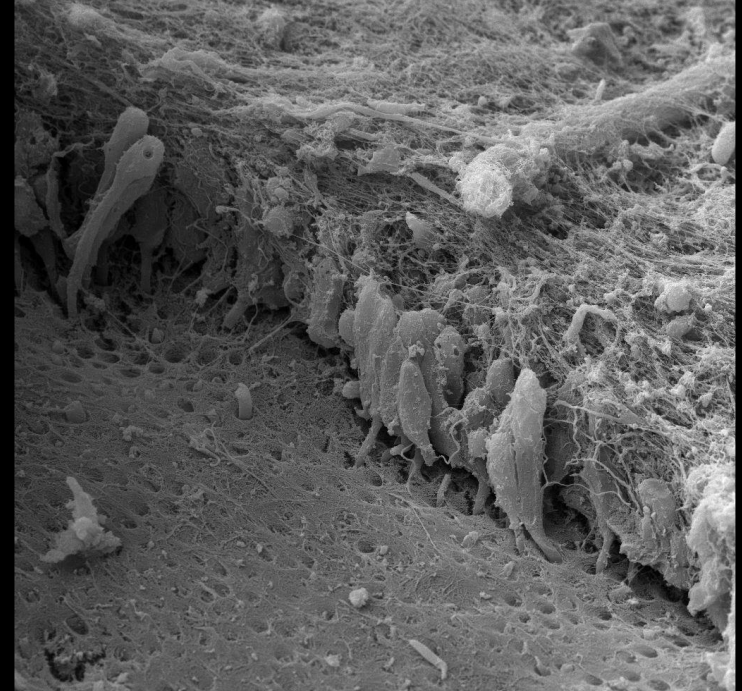
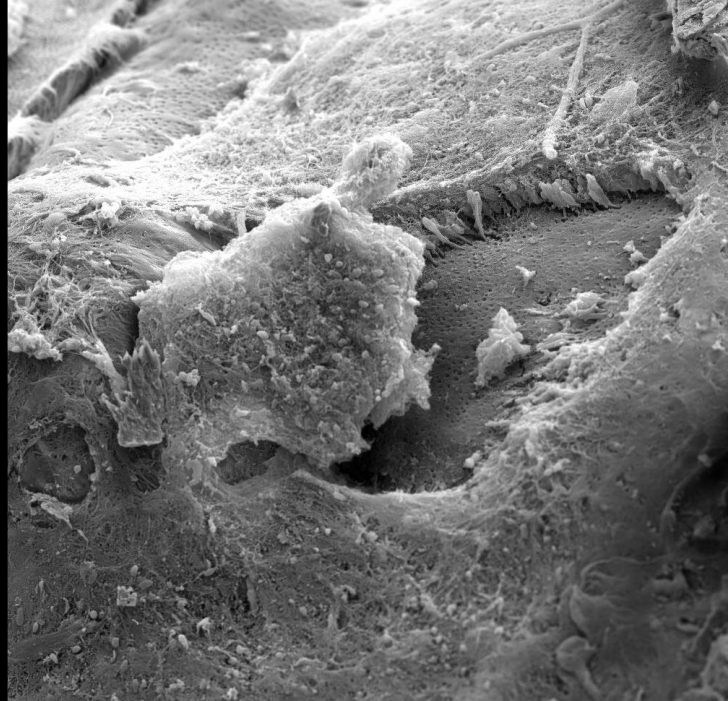
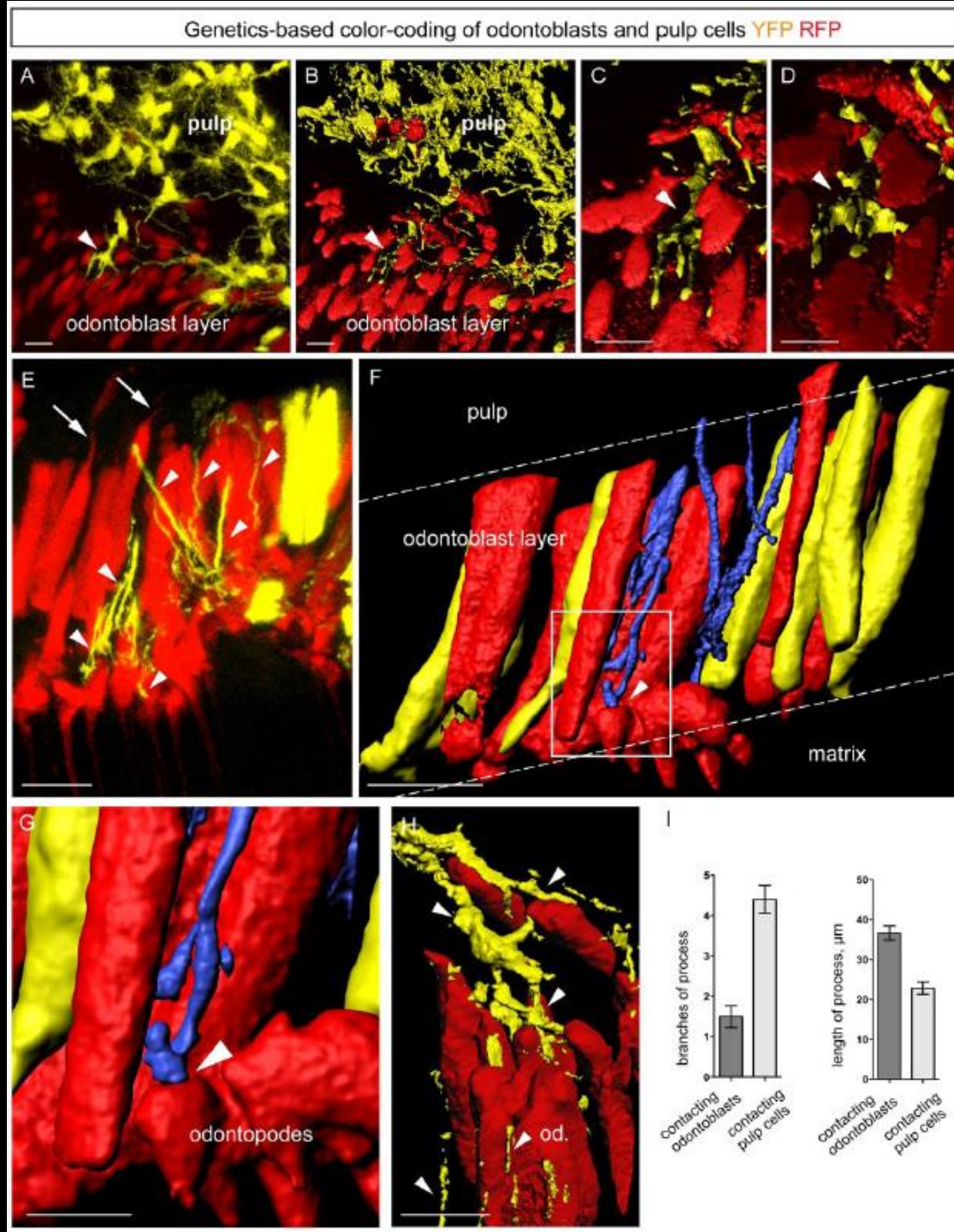


FIGURE 8-40 Schematic representation of the cells bordering pulp. rER, Rough endoplasmic reticulum.

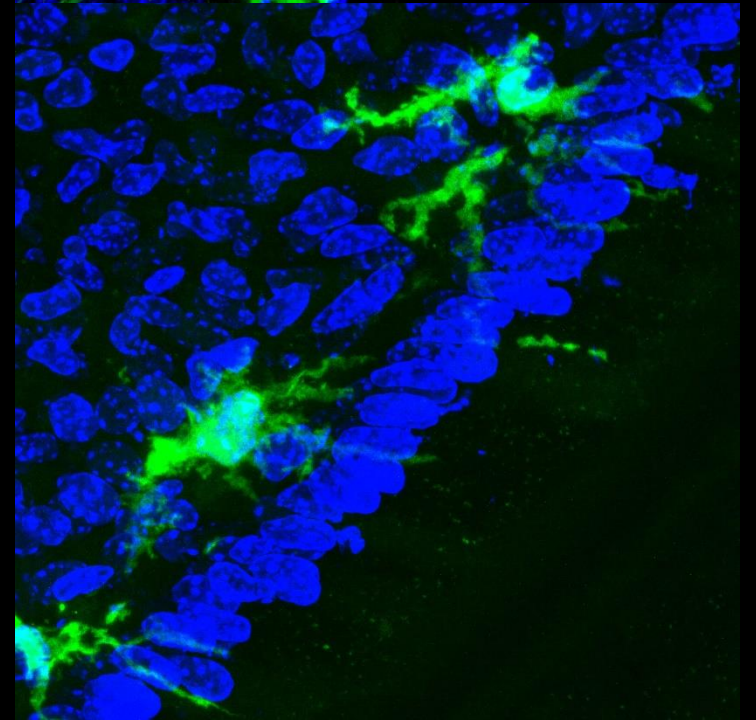
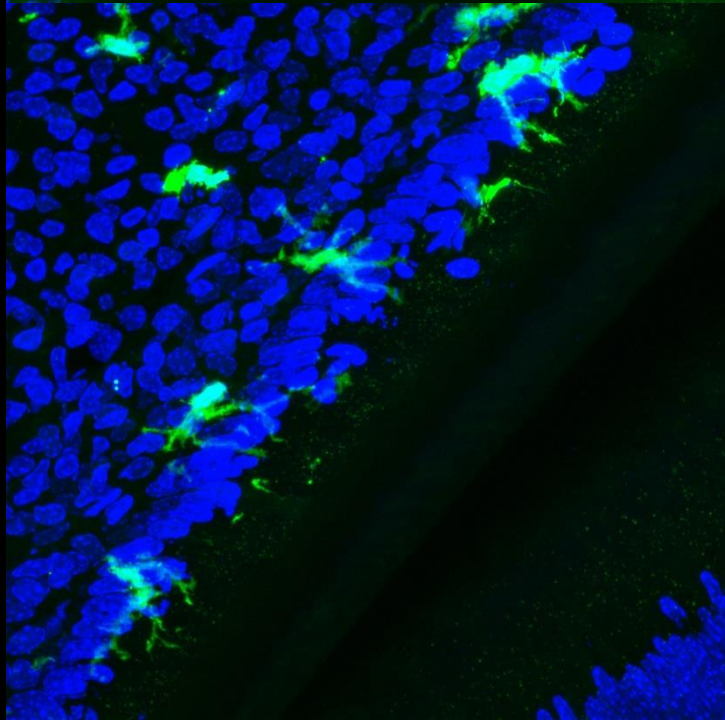
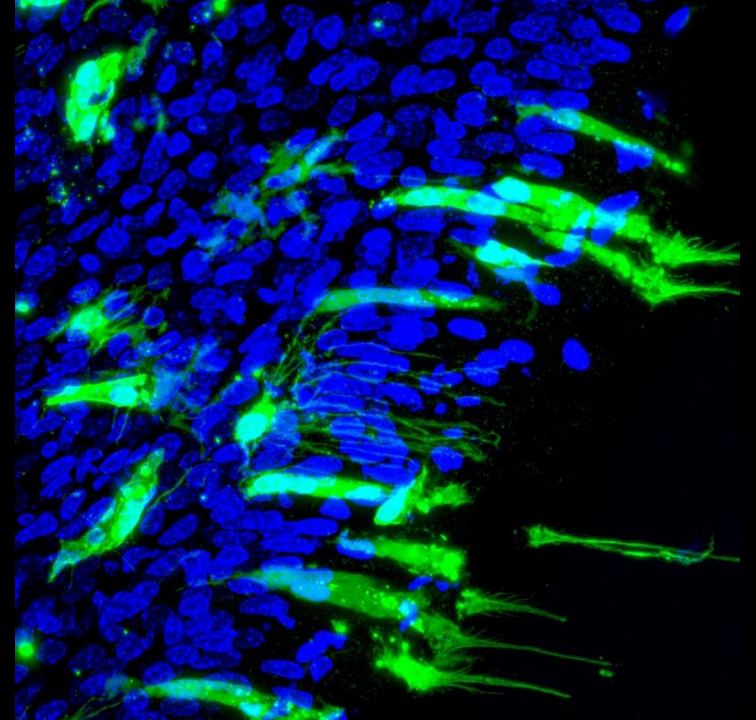
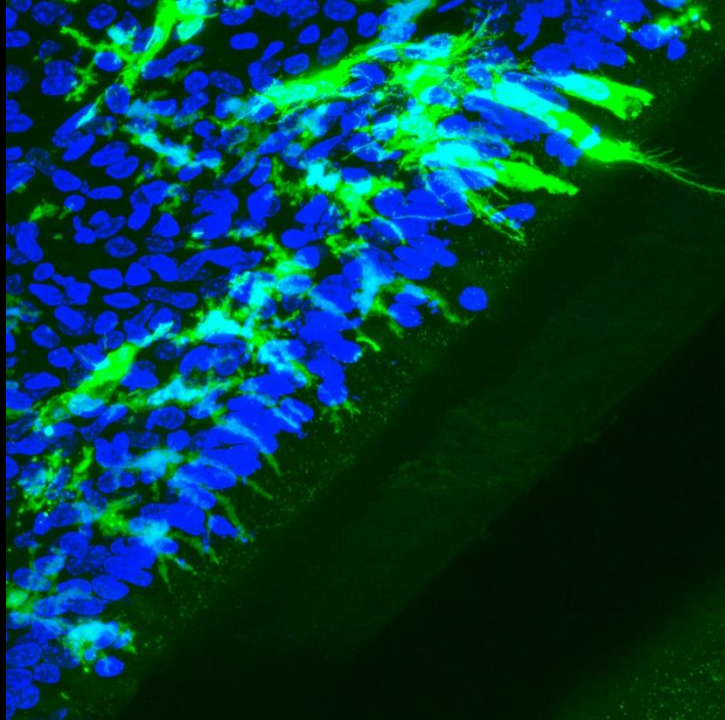
Odontoblasts



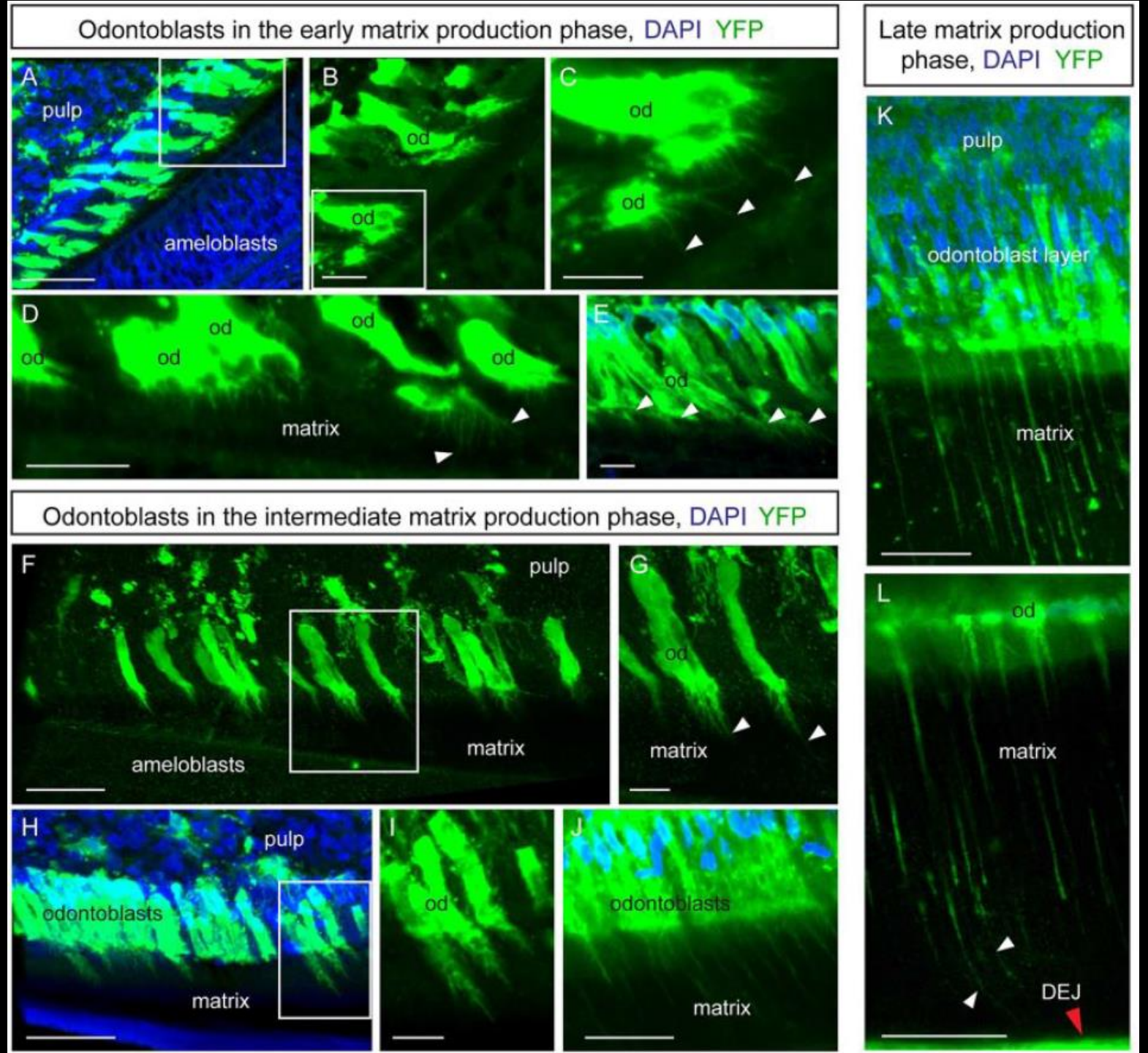
Odontoblasts



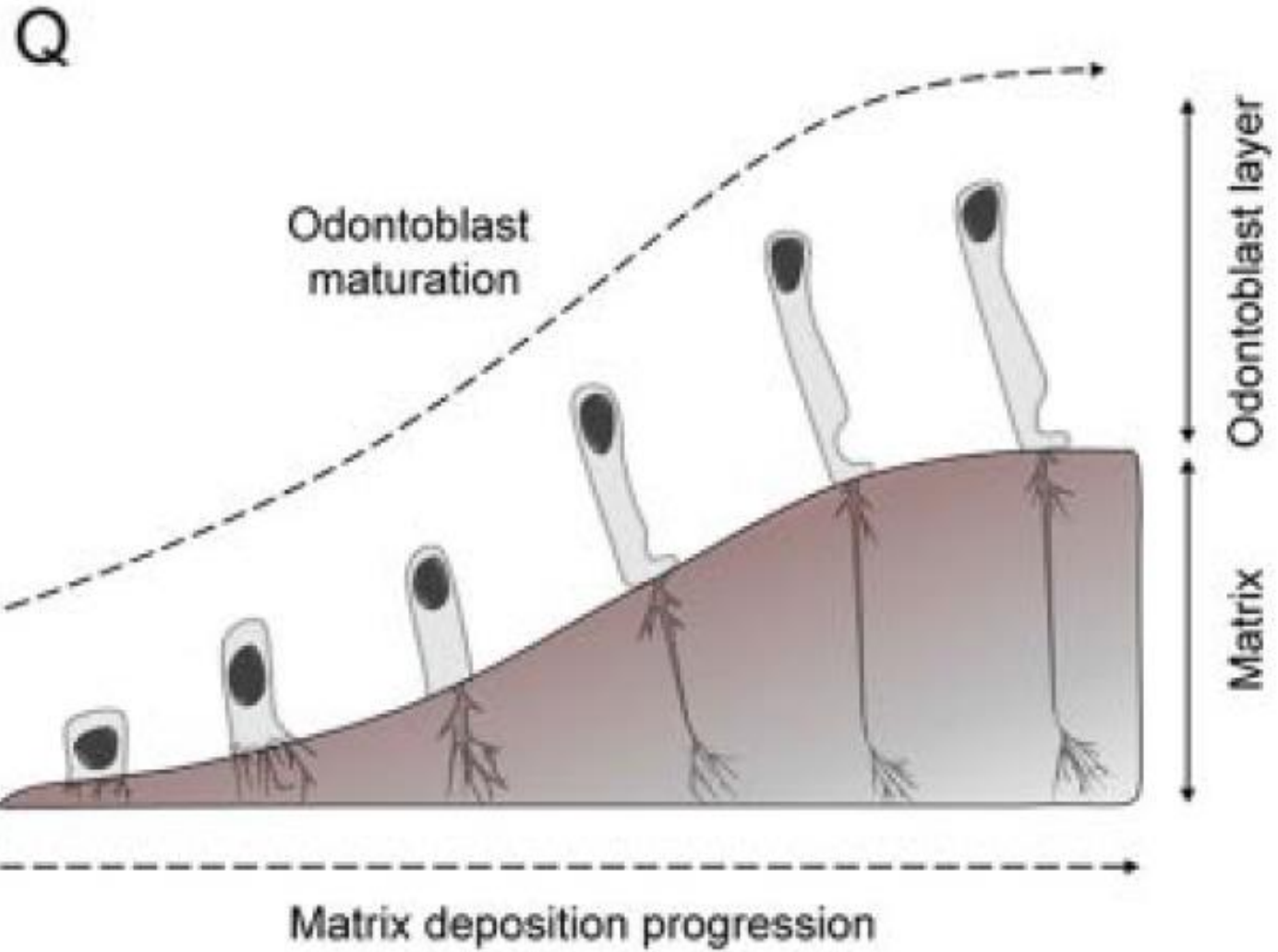
Odontoblasts /
Pulp cells



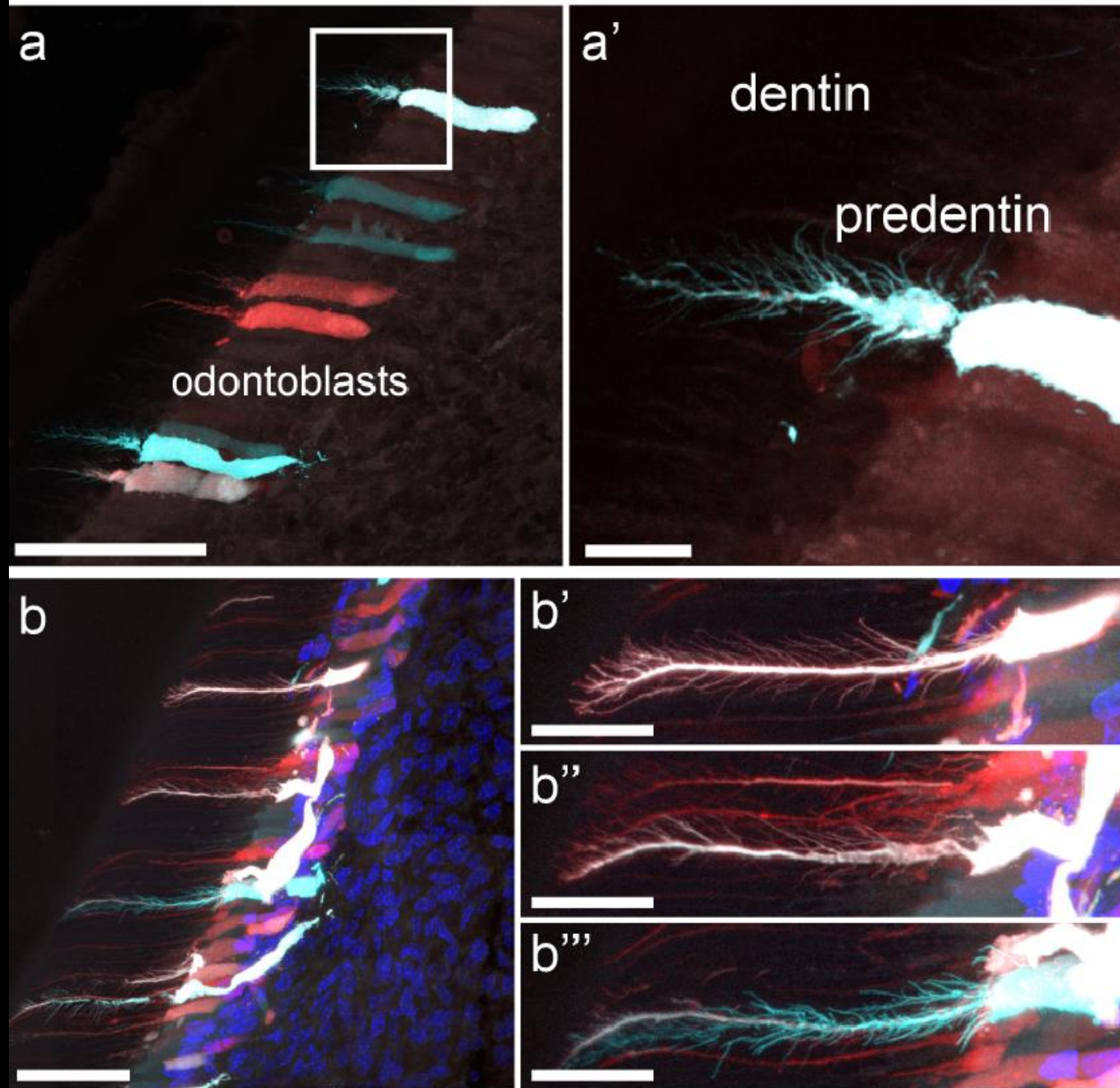
Development of odontoblasts



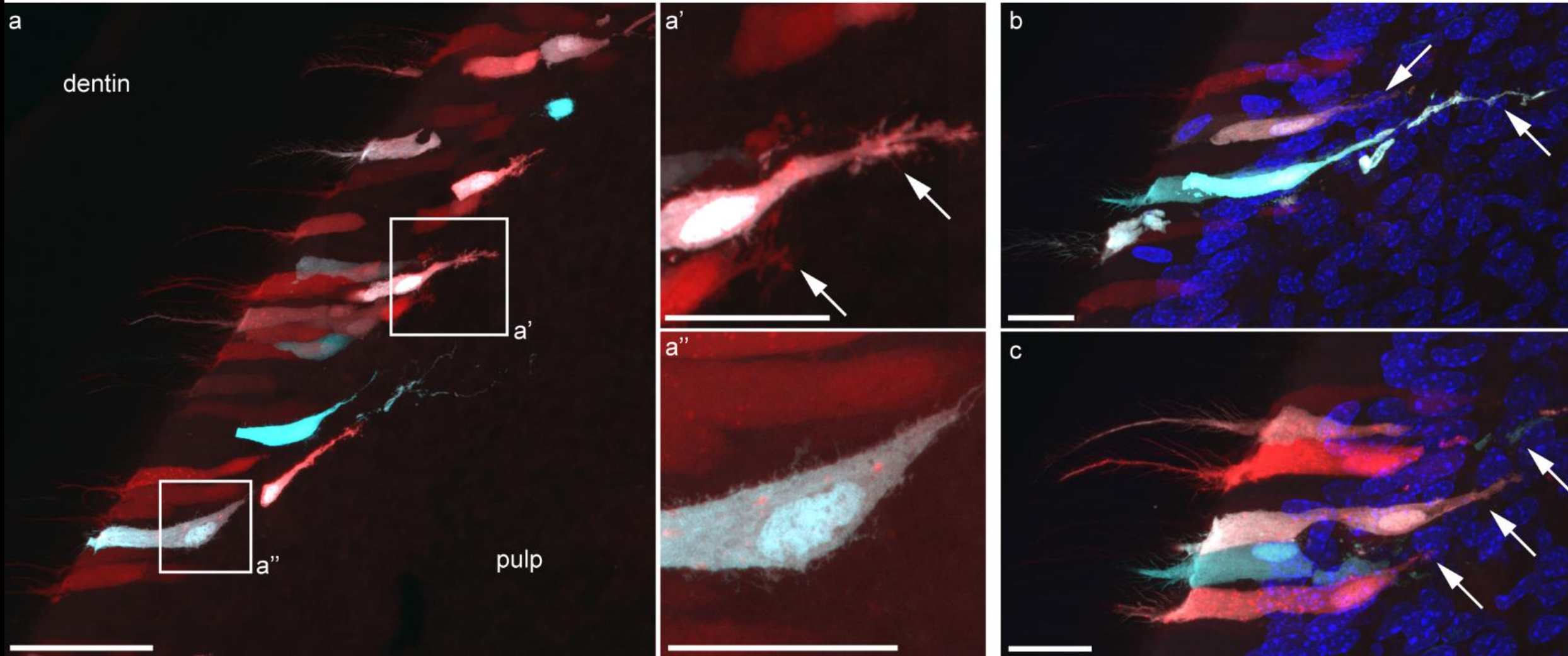
Development of odontoblasts



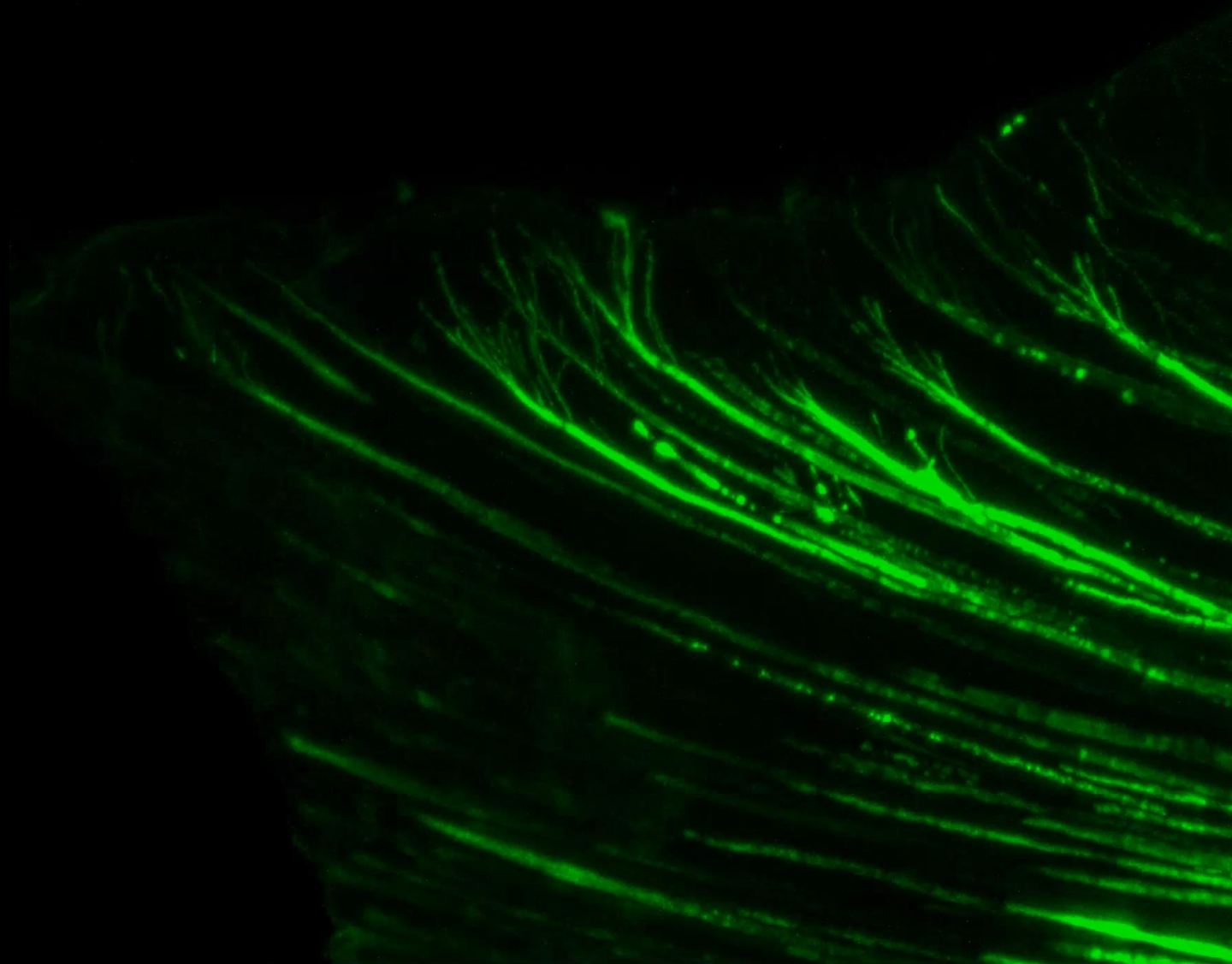
Odontoblasts dentinal processes analysis



Odontoblasts pulp-penetrating processes



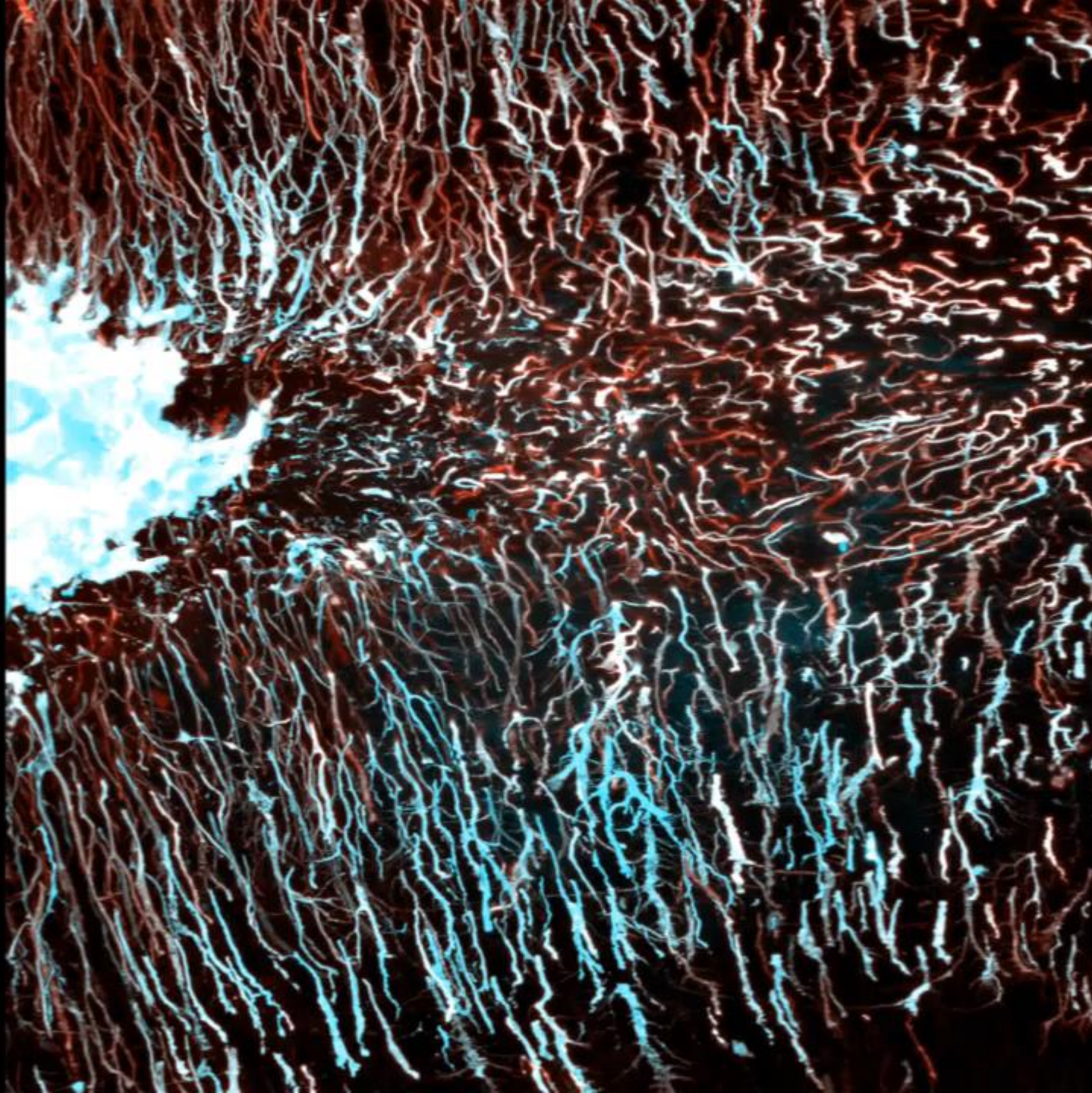
Enamel



Dentin



DENTIN



Microscopic structure of dental pulp, function and changes during aging

Ectomesenchymal origin

Located in *cavitas dentis*

Reticular structure

In primary dentition structure similar to jelly-like connective tissue

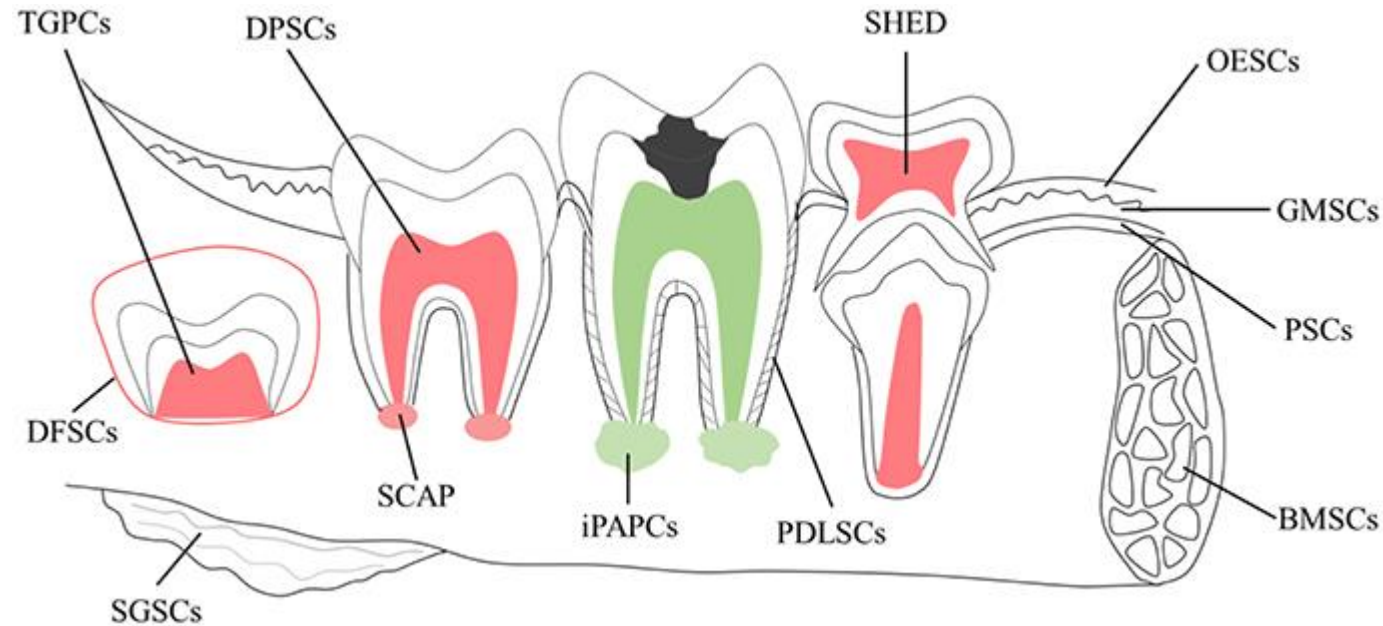
Extracellular matrix (ECM)

- **Fibres:**
 - Collagen
 - Reticular fibres
- **Amorphous matter:**
 - Glycosaminoglycans and glycoproteins

Cellular part

- Particularly fibroblasts,
- Immune system: macrophages, plasma cells, dendritic cells and tissue-residential blood cells (neutrophils or eosinophils, granulocytes, lymphocytes)
- Glial cells
- Endothelial cells, pericytes
- Dental mesenchymal cells

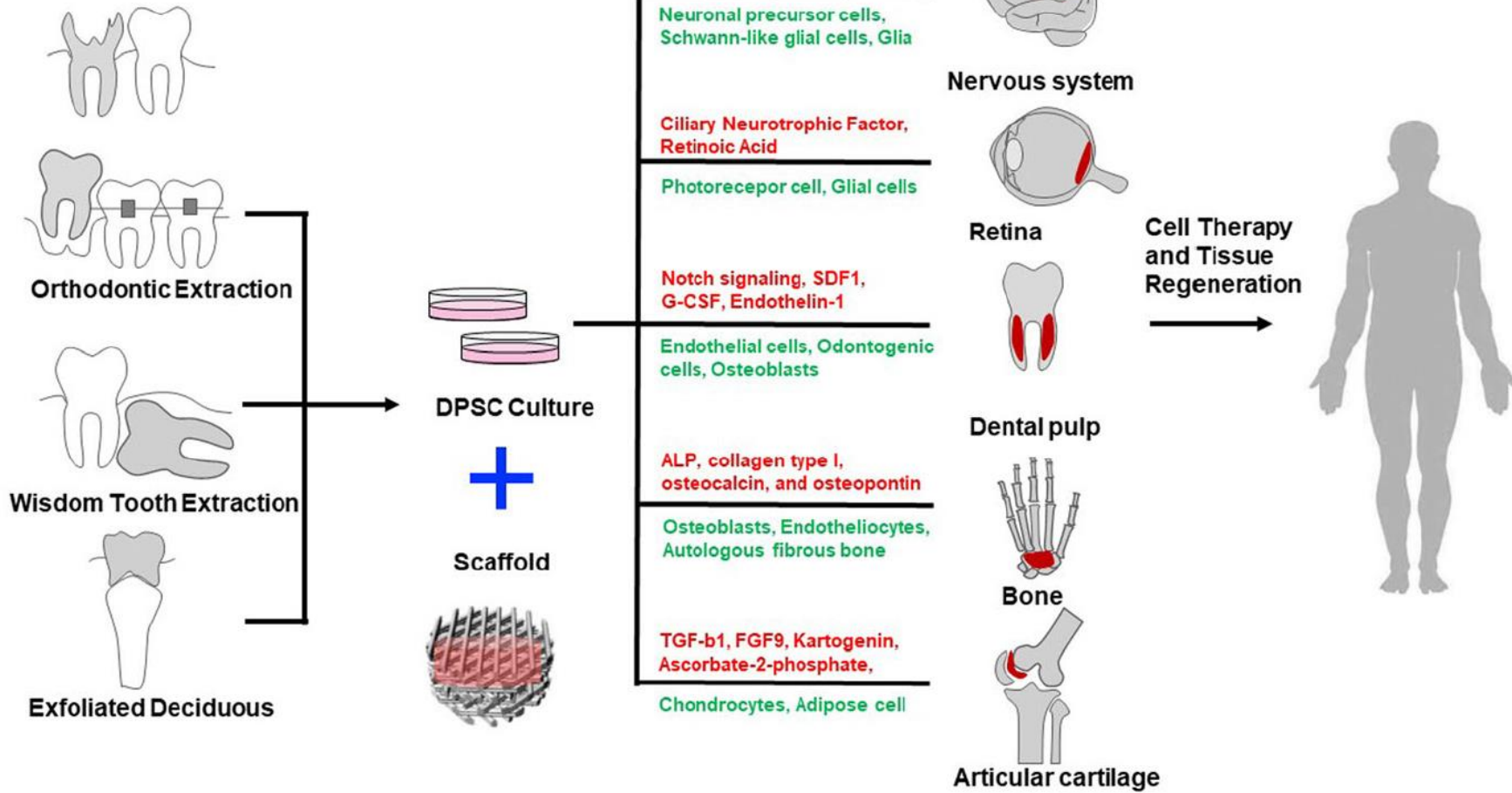
Stem Cells in (human) teeth

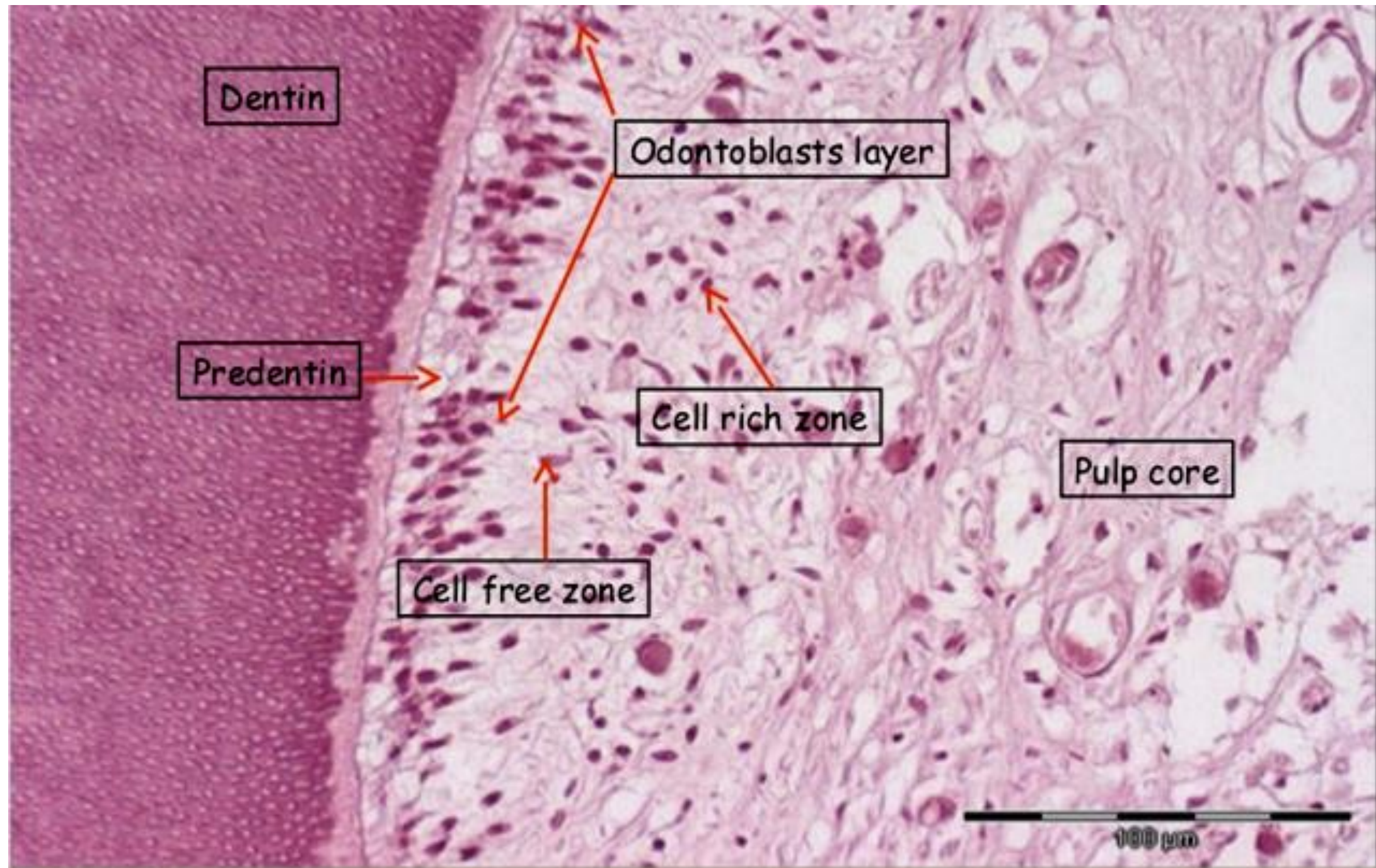


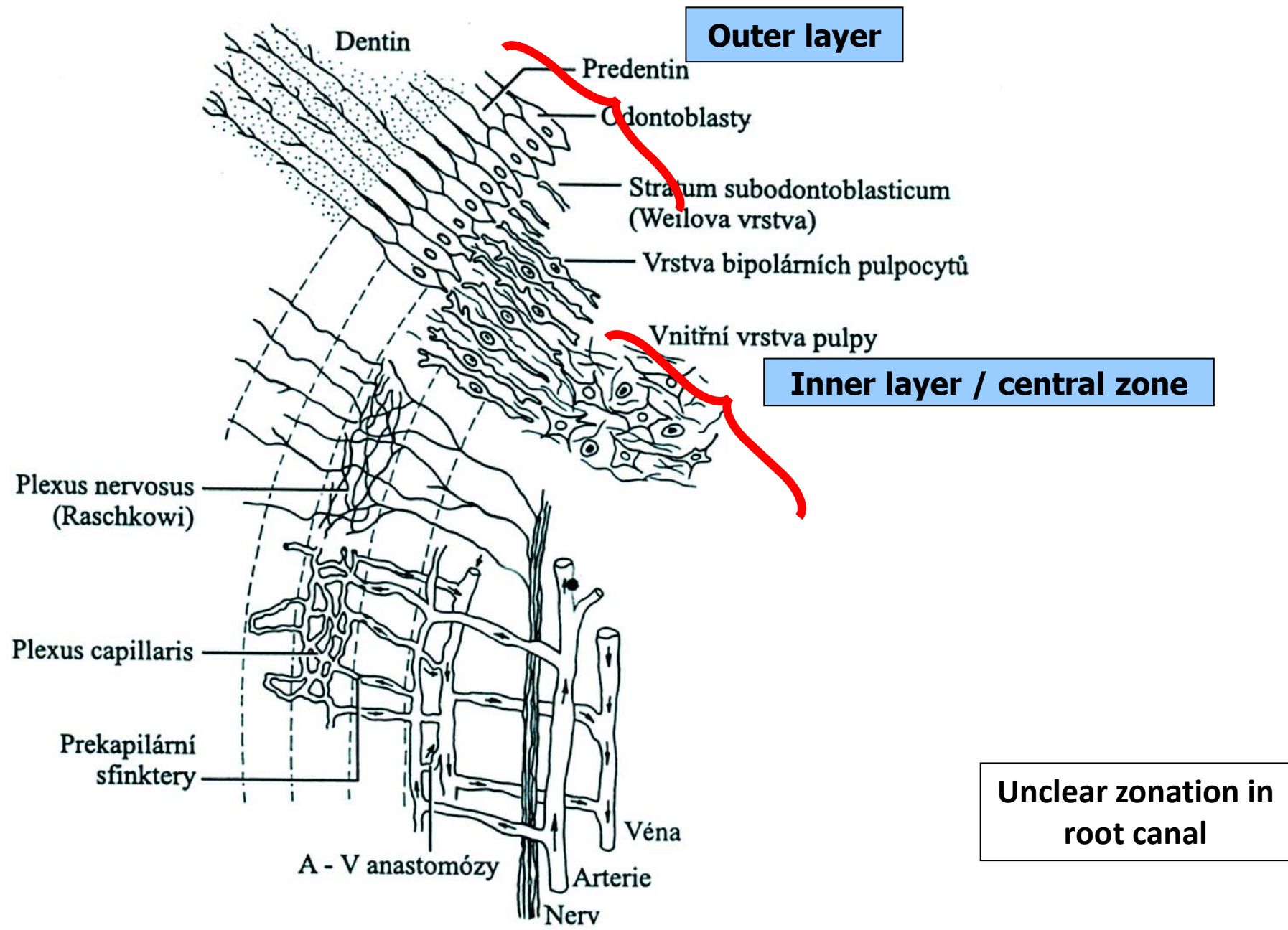
Schematic of potential sources of adult stem cells in the oral environment

TGPCs	tooth germ progenitor cells
DFSCs	dental follicle stem cells
SGSCs	salivary gland stem cells
SCAP	stem cells of the apical papilla
DPSCs	dental pulp stem cells
iPAPCs	inflamed periapical progenitor cells
SHED	stem cells from human exfoliated deciduous teeth
PDLSCs	periodontal ligament stem cells
BMSCs	bone marrow stem cells
OESCs	oral epithelial stem cells
GMSCs	gingival-derived mesenchymal stem cells
PSCs	periosteal stem cells

Dental Pulp stem cell sources and multilineage application capability







Obr. 15-6. Schematický náčrt mikroskopické stavby zubní pulpy, její inervace a cévního zásobení

Blood and lymph vessels

Very rich blood supply (especially at a young age)

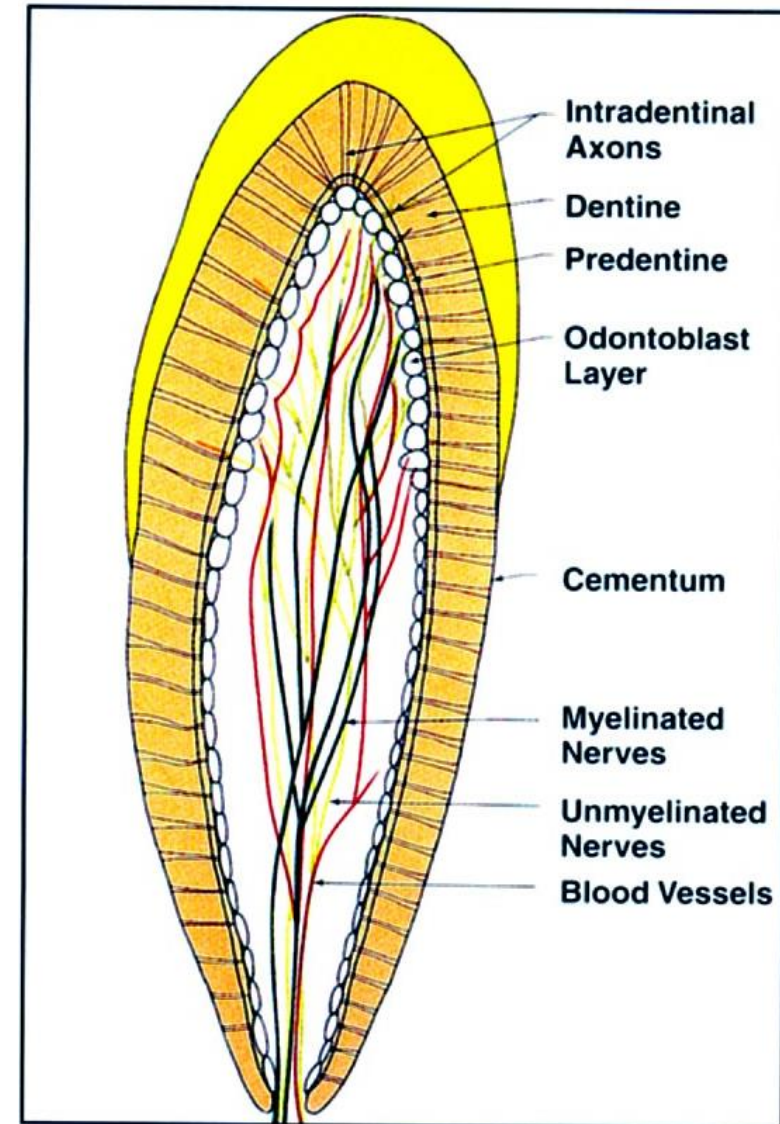
Arteries (2-10)

- Oriented longitudinally through the center of the pulp
- Numerous side branches
- They divide into terminal networks – odontoblasts supply

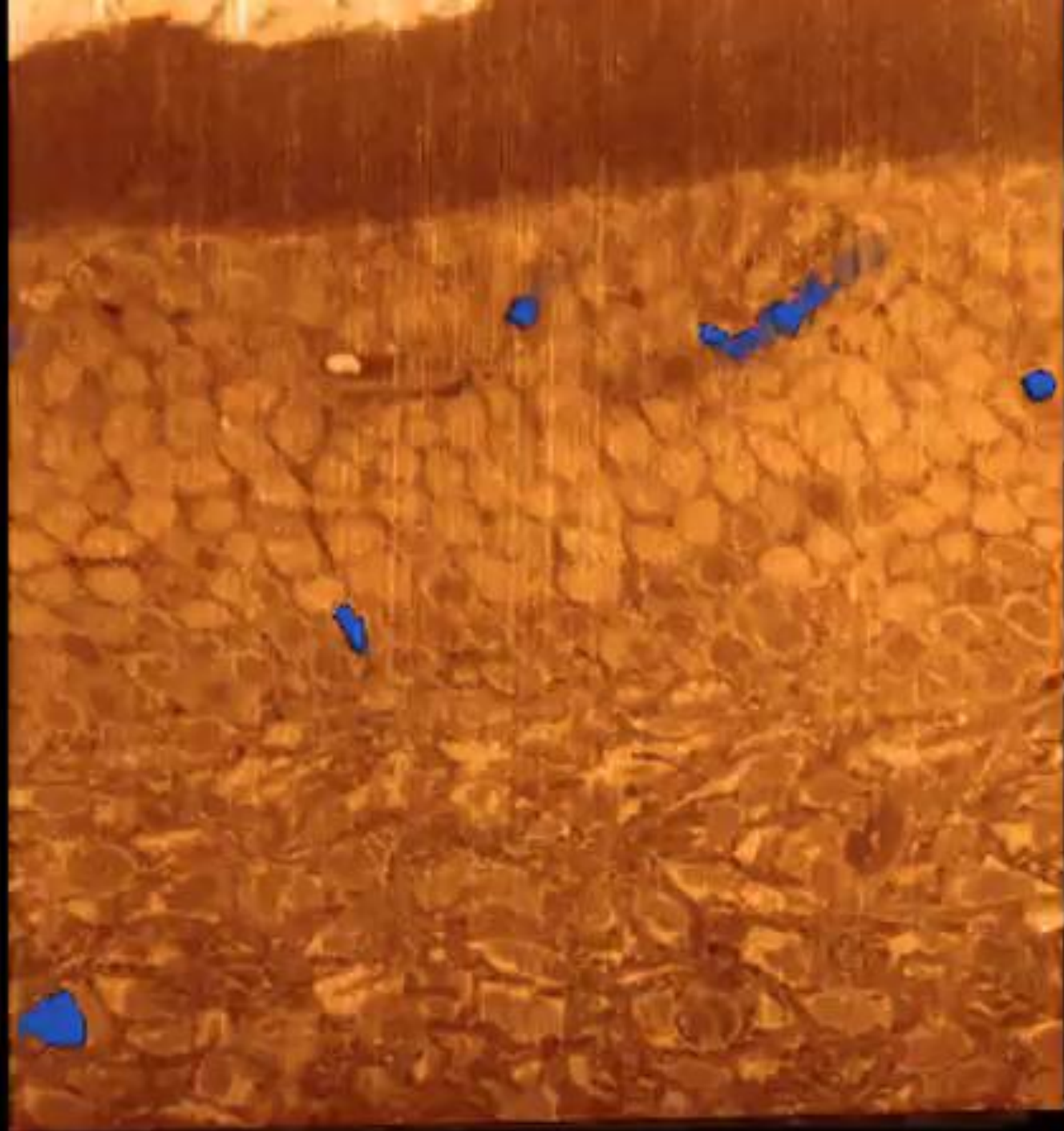
Subodontoblastic capillary network

- Arteries with narrow lumen, thick wall reinforced by several layers of smooth muscle cells
- Veins and venules wall very thin, which strikingly contrasts with their wide luminosity

Lymph circulation begins with the lymph capillaries that connect to small lymph vessels leaving the dental pulp together with the blood and nerve vessels through the foramen of the apicis radialis dentis



32 General distribution of myelinated nerves (dark green), unmyelinated nerves (light green) and blood vessels (red) in the



Pulp innervation

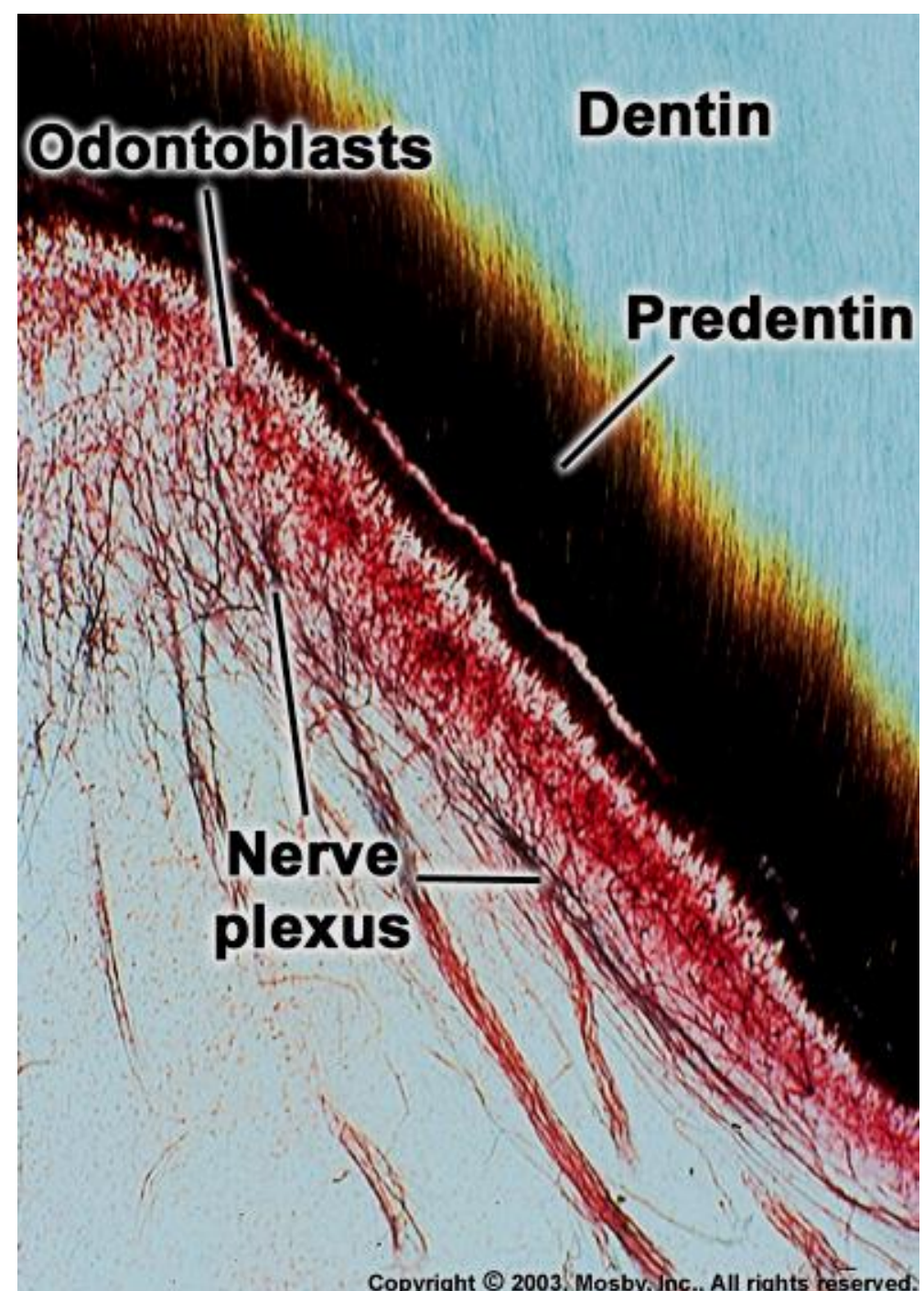
Both myelinated and non-myelinated

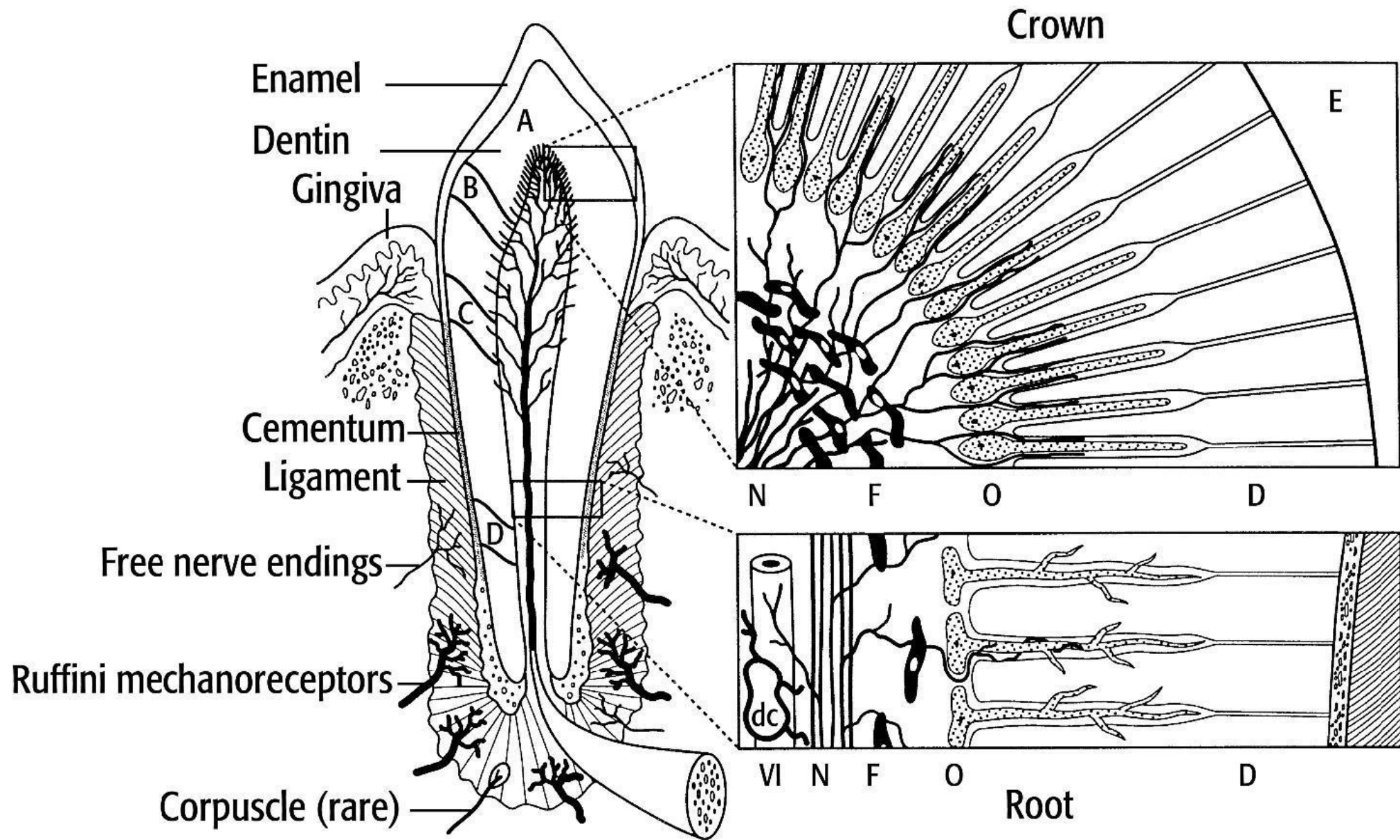
Myelinated nerve fibres in the dental pulp are rich in branches and reach up to the odontoblast bases under which they form a dense network:

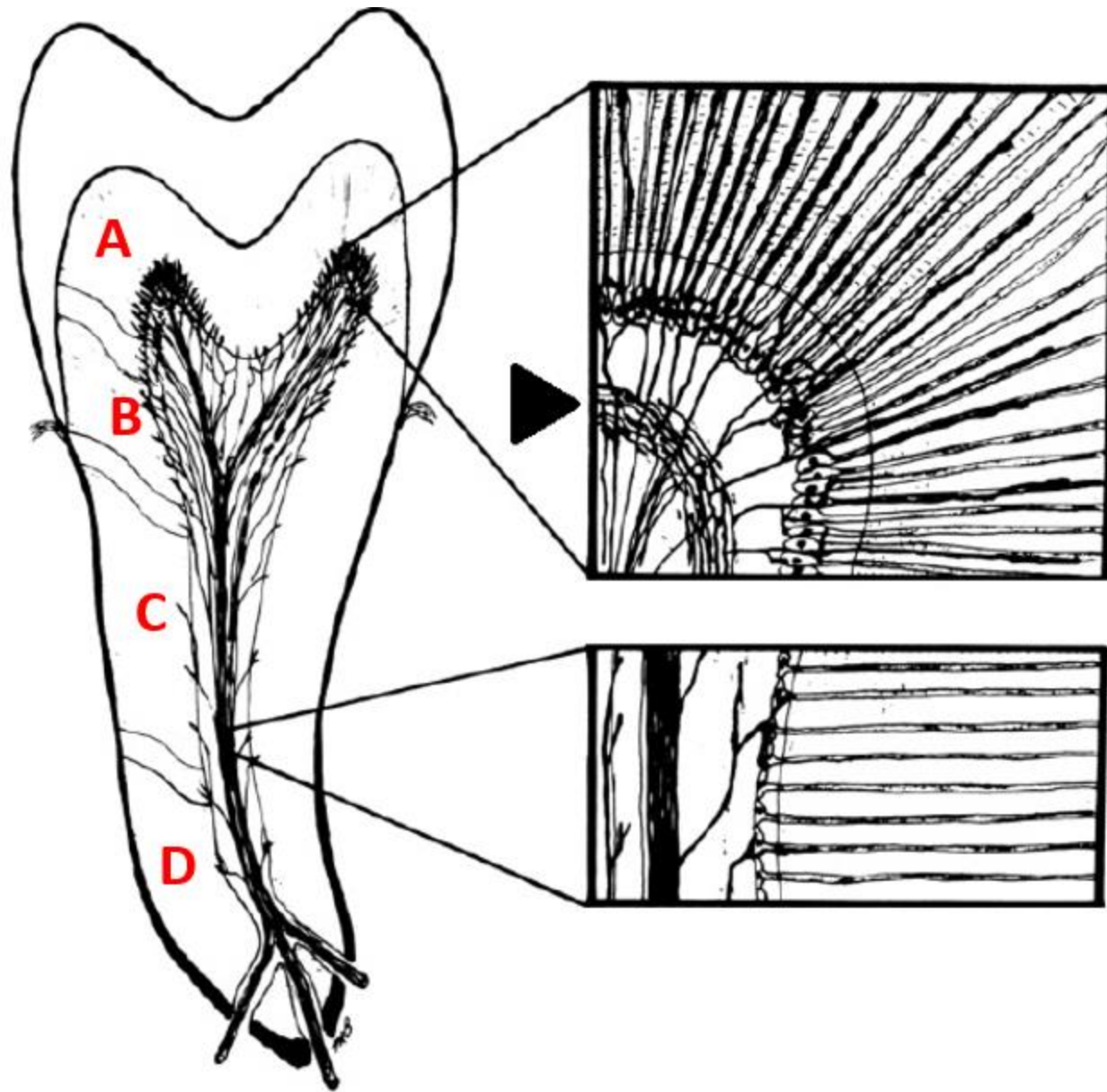
Plexus subodontoblasticus Raschkowi


the nerve fibres ends on the bodies of the odontoblasts, some enters the predentin and dentin channels

Non-myelinated nerve fibres innervate blood vessels in the dental pulp



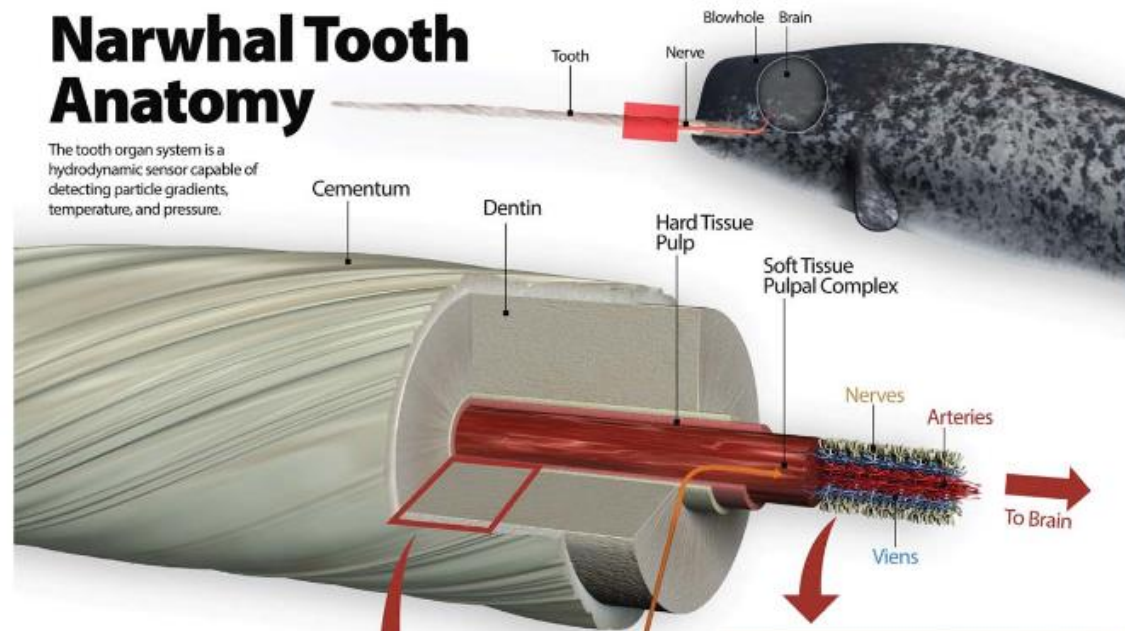




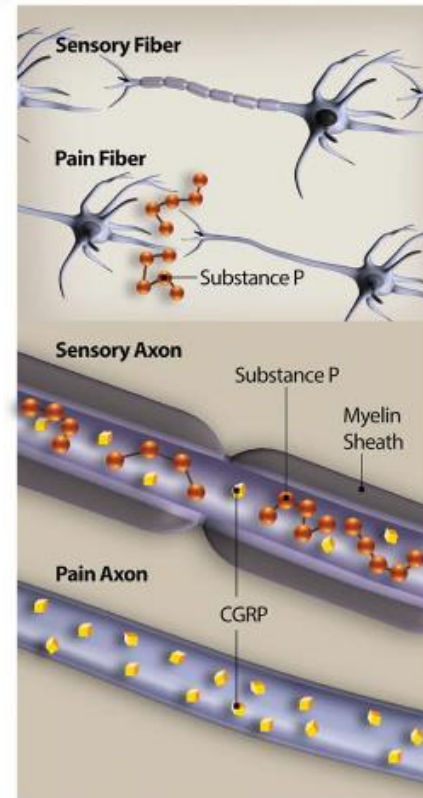
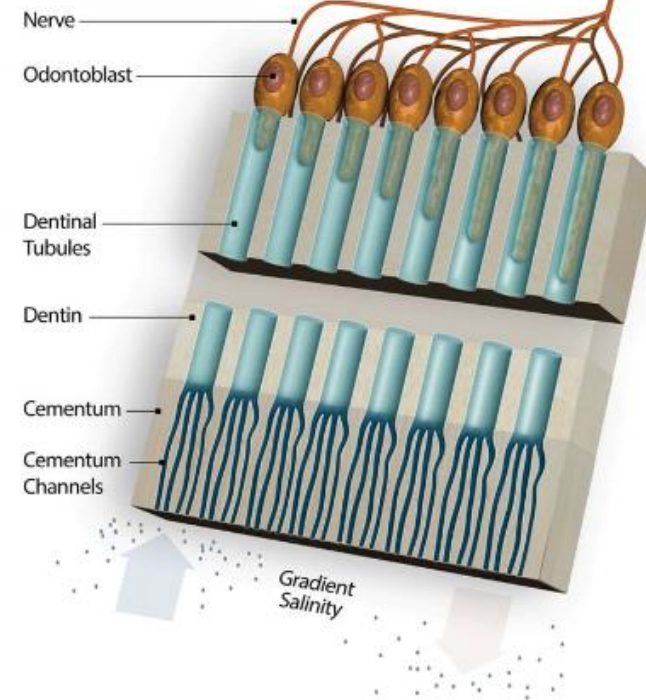


Narwhal Tooth Anatomy

The tooth organ system is a hydrodynamic sensor capable of detecting particle gradients, temperature, and pressure.



Hard Tissue



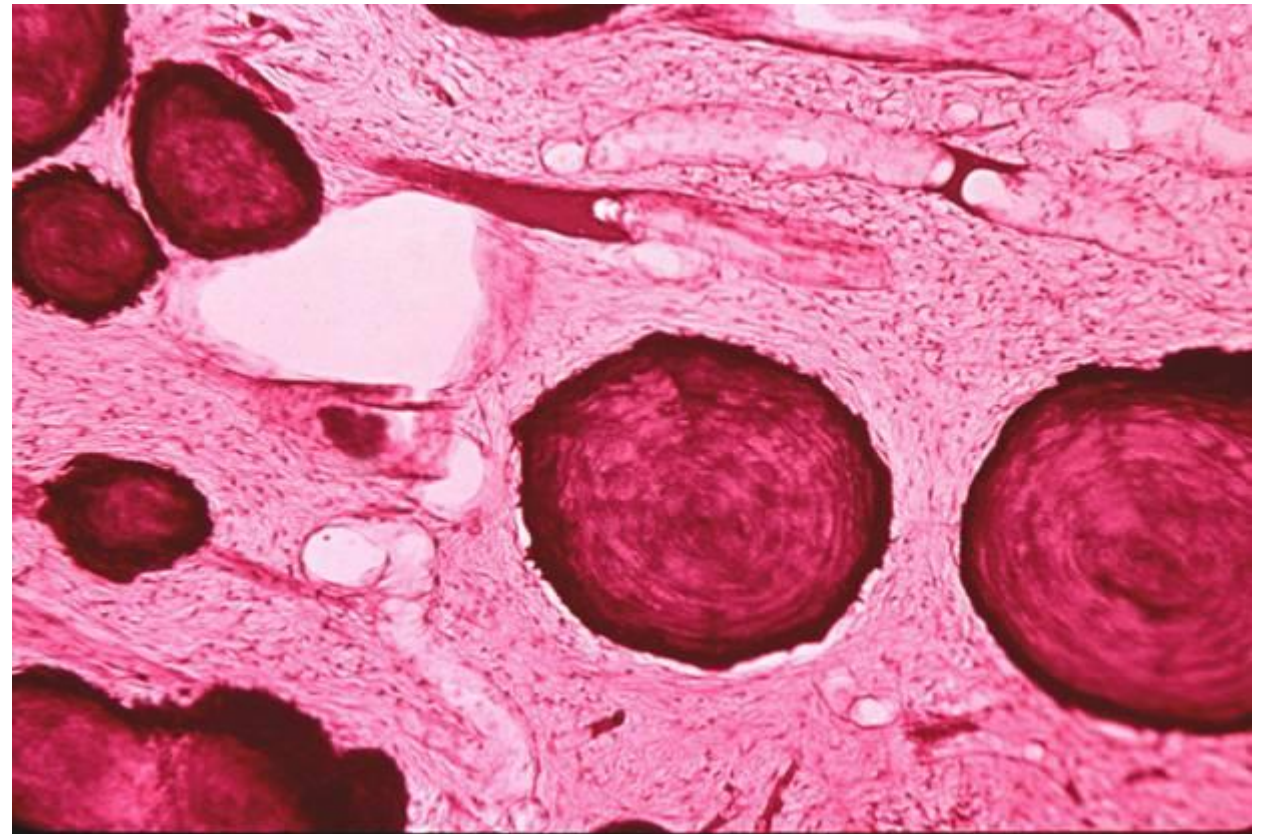
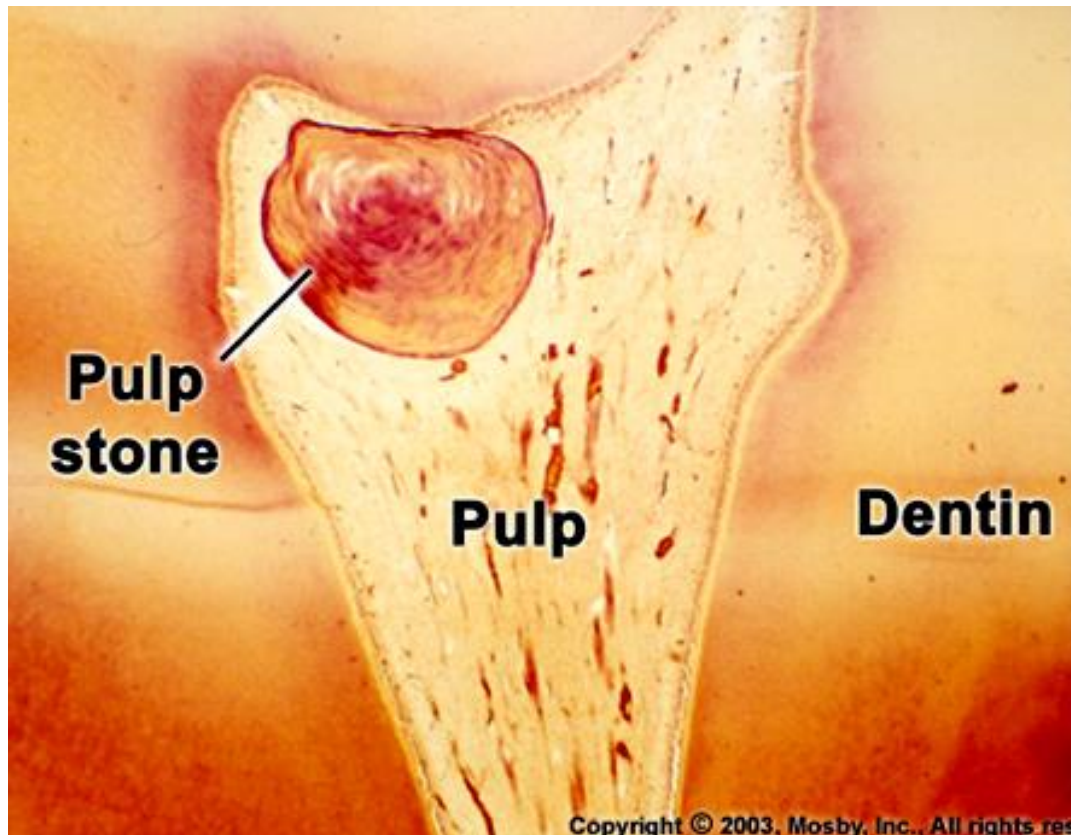
Pulp changes during aging

- Fastest development immediately after eruption
- Age-related changes: chemical composition, structure and volume

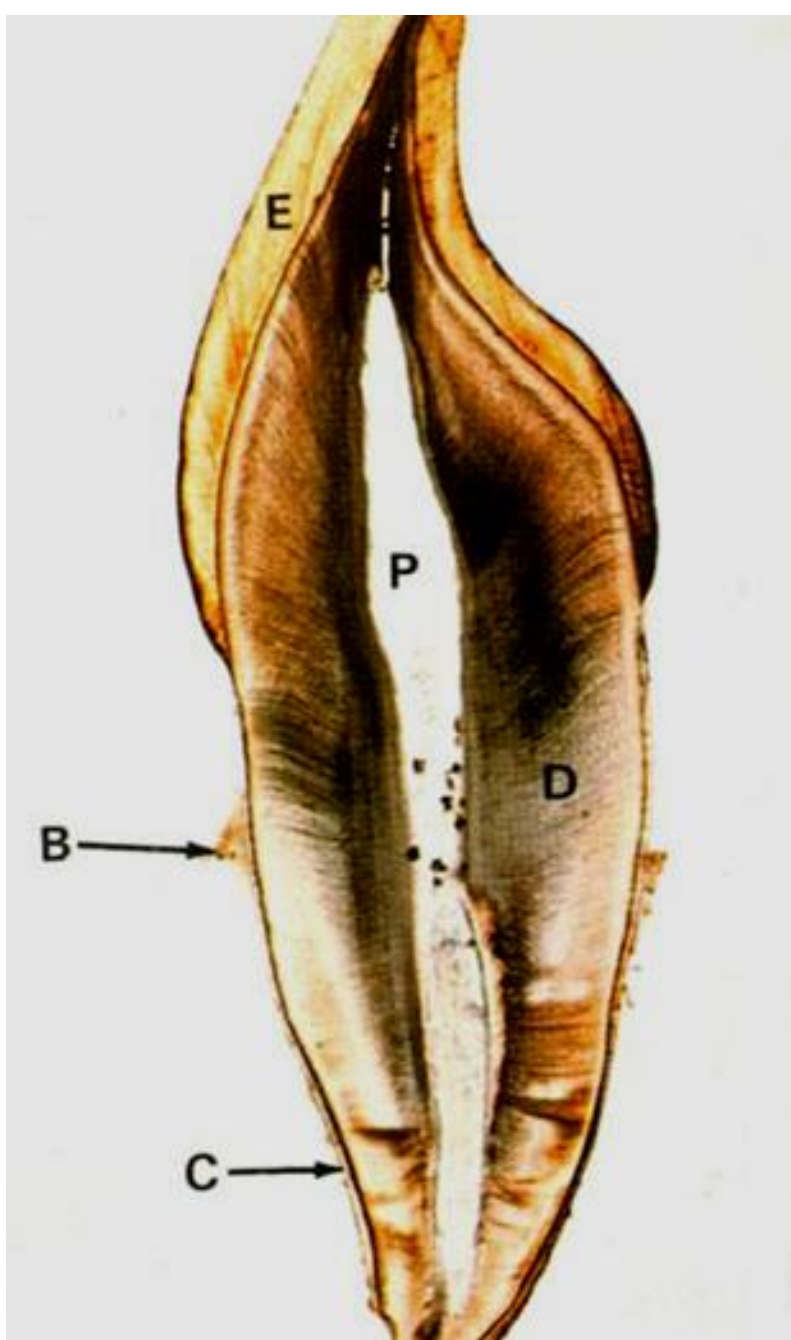
Chemical composition – amorphous matter loses its mucilaginous character

Structure – cell loss, increase of fibres - transformation into dense collagenous connective tissue

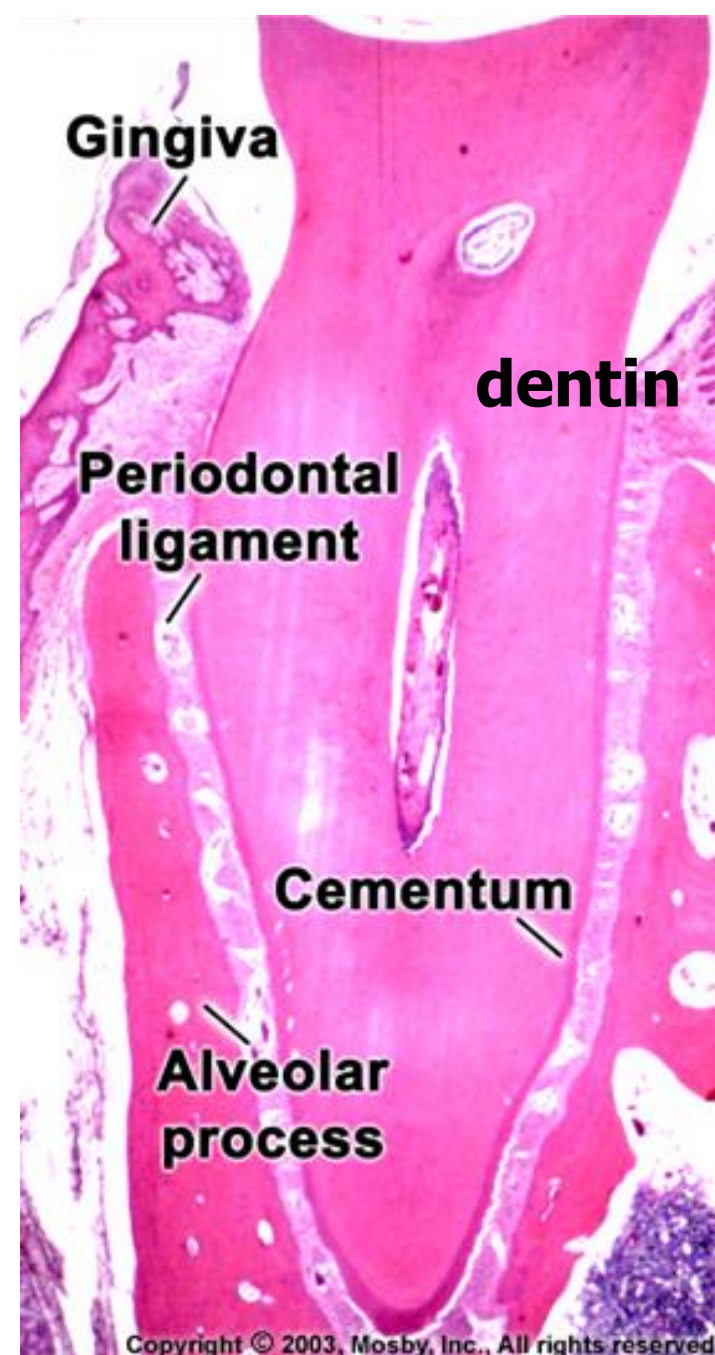
Volume – loss due to deposition of secondary and tertiary dentin and denticles formation



DENTIN

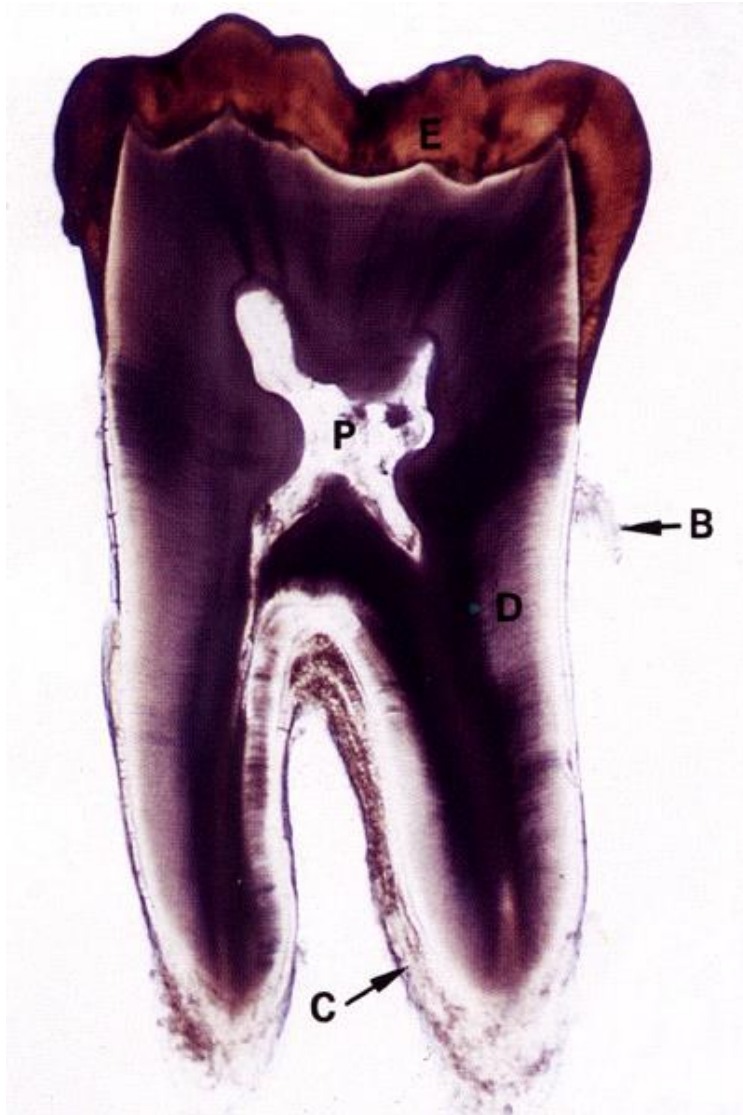


Podélný výbrus



Dekalcifikovaný řez

Microstructure of dentin, dentin types, clinical significance



The most abundant dental tissue
Living tissue - contains parts of living cells
No blood vessels nor bone-lamellar structure
Derives from ectomesenchyme

**Functional and developmental connection with the pulp
(dentin-pulp complex)**

Physical properties

Ivory color

Harder than bone or cementum, but softer than enamel

Refractive index 1.62 (same as enamel)

Specific weight 2.14 g/cm³ (lower than enamel)

Flexible and permeable (permeability decreases with age)

Thickness 2-4 mm (primary dentition half)

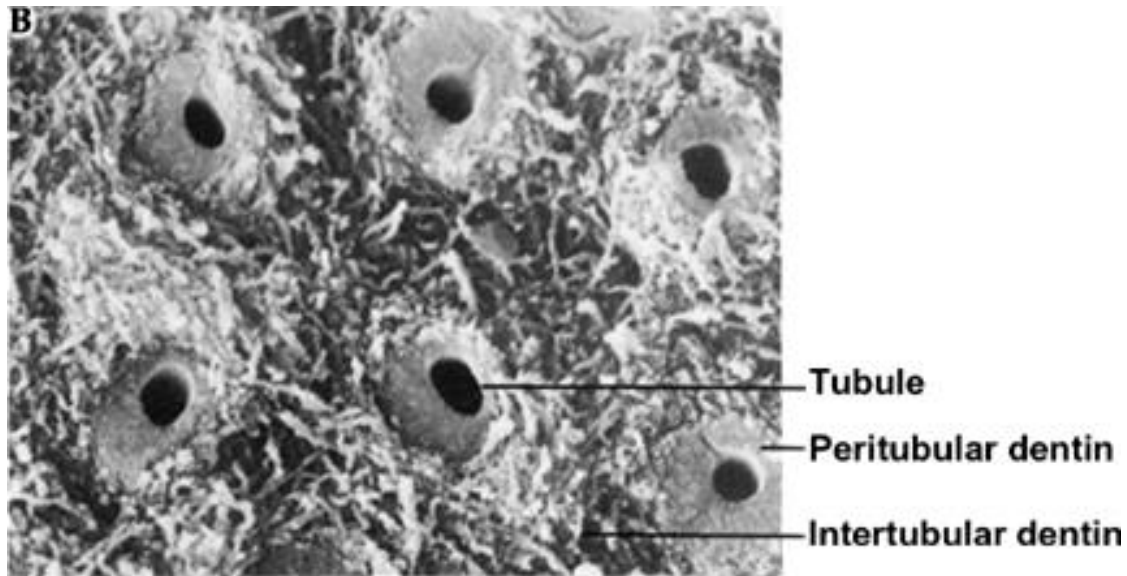
Dentin matrix

Consists of collagen fibrils (collagen type I) forming bundles

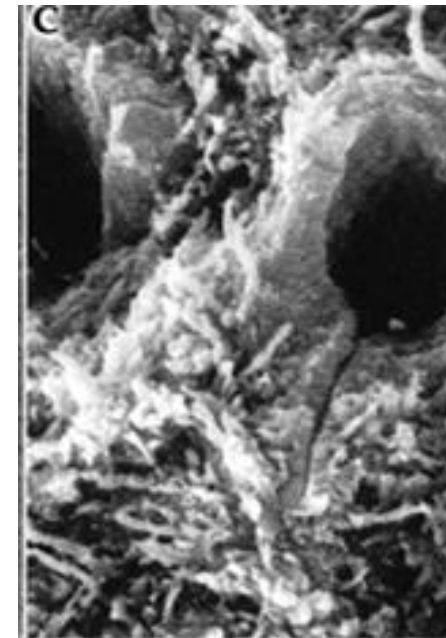
The fibres run parallel to the tooth surface from the root tip to the crown (perpendicular to the the dentin tubules)

Amorphous matrix - glycosaminoglycans, proteoglycans and lipids, impregnated with hydroxylapatite crystals

In the **tubular dentinal matrix, the collagen fibers are missing**, contain more hydroxylapatite crystals, compact appearance, about 15% harder than the matrix between the channels

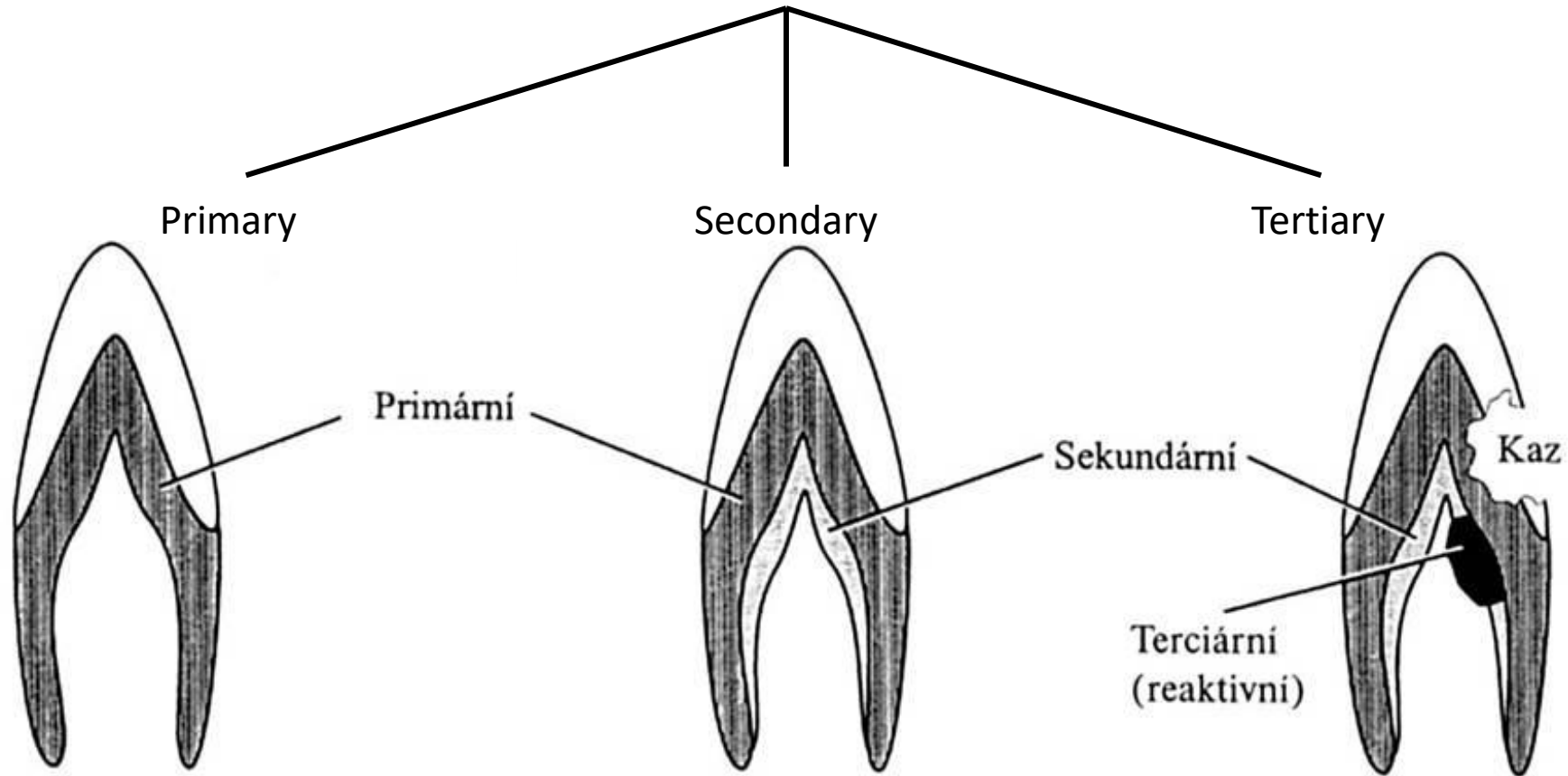


Copyright © 2003, Mosby, Inc., All rights reserved.



© 2003, Mosby, Inc., All rights reserved.

Types of dentin



Secondary dentin

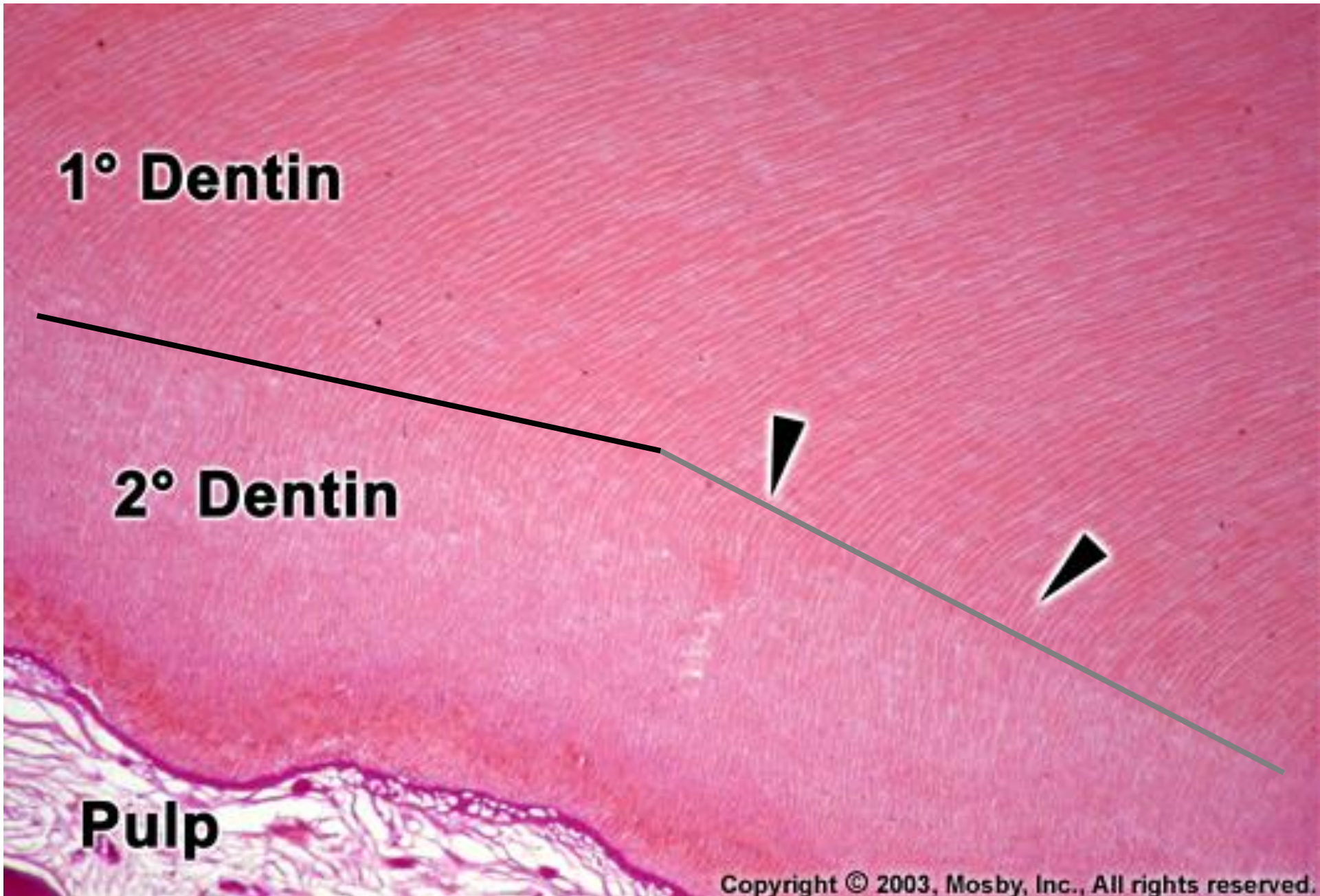
Laid down **after the root growth is finished**, when the crowns have reached the occlusal plane and the teeth are functionally loaded

Only for permanent dentition teeth

Stored slowly throughout the whole existence of a permanent tooth.

Can be separated from the primary dentin by a more pronounced incremental line

Secondary dentine deposition results in a reduction in the pulpal cavity

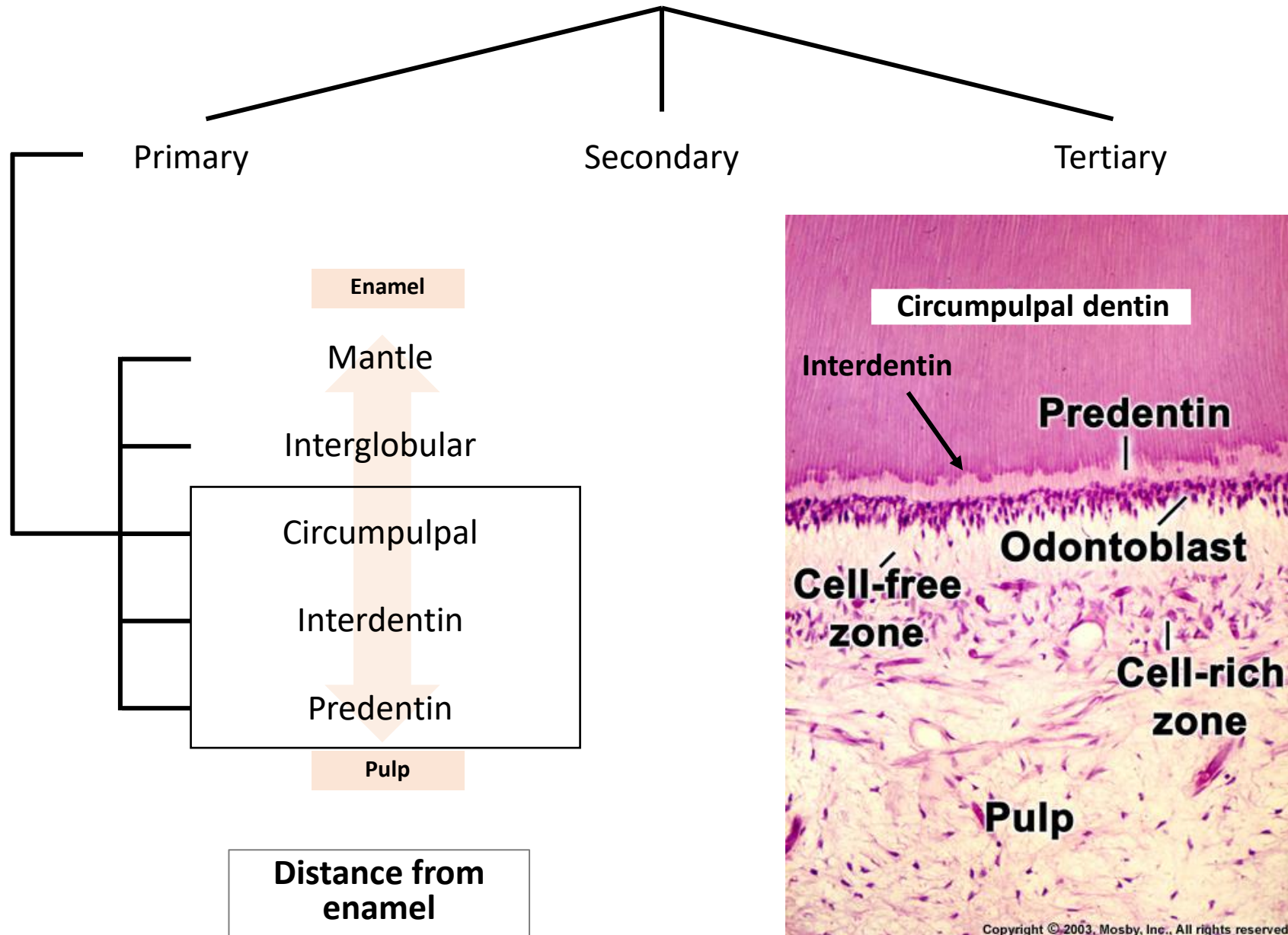


1° Dentin

2° Dentin

Pulp

Dentin types



Circumpulpal dentin

90 % of all dentin

Contains dentinal tubules

Interdentin

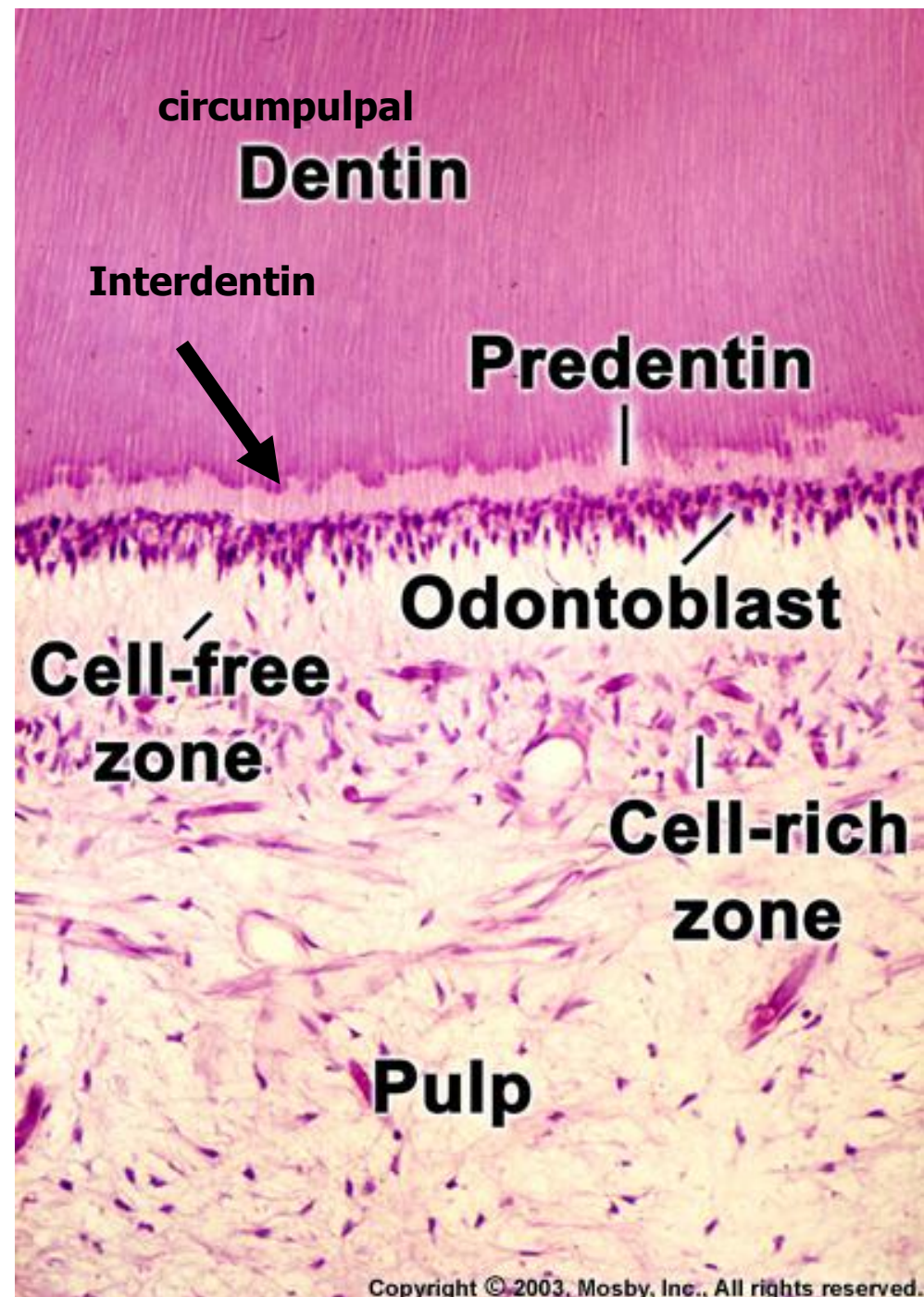
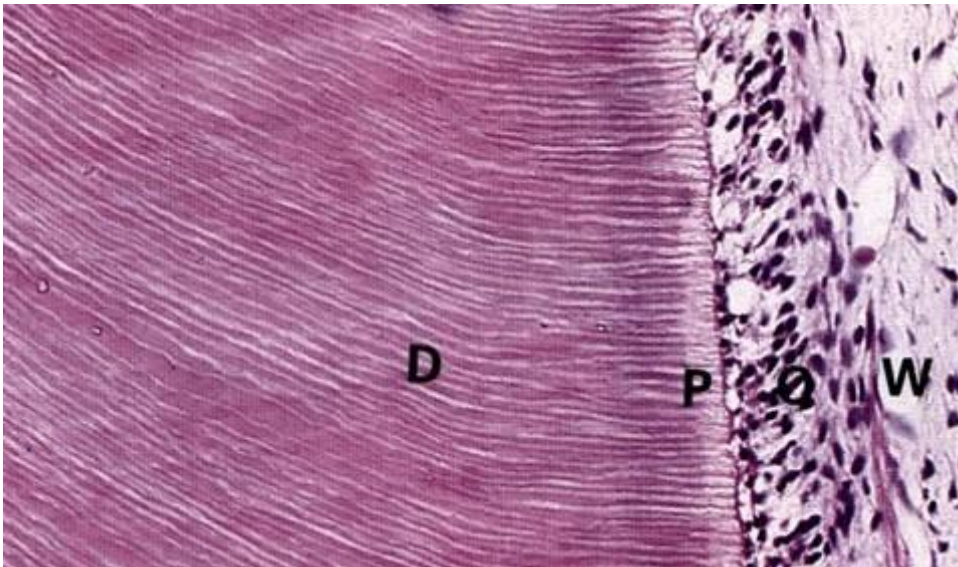
Thin layer between circumpulpal dentin and predentin where dentin mineralization starts

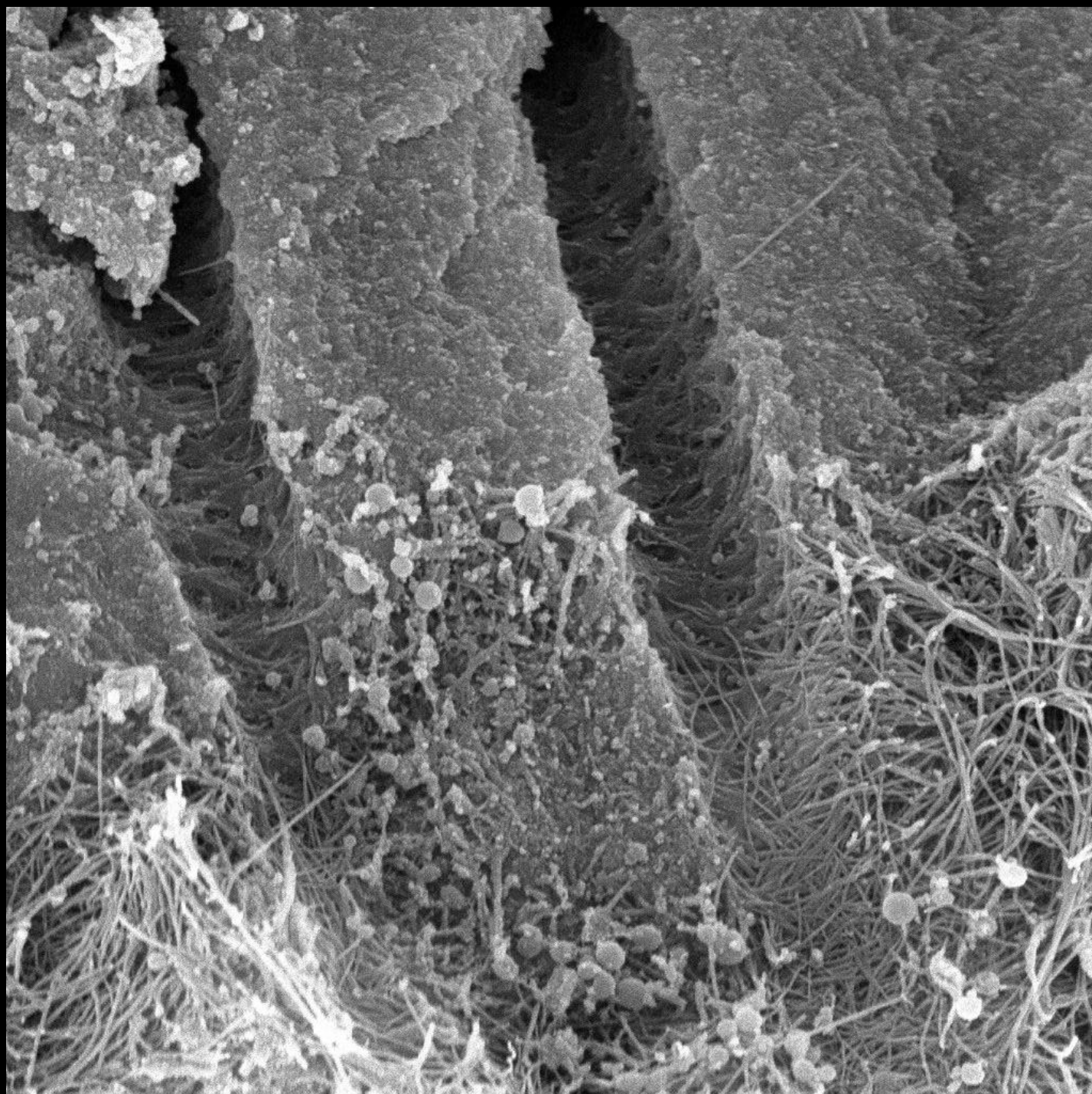
Predentin

Non-calcified layer near odontoblasts

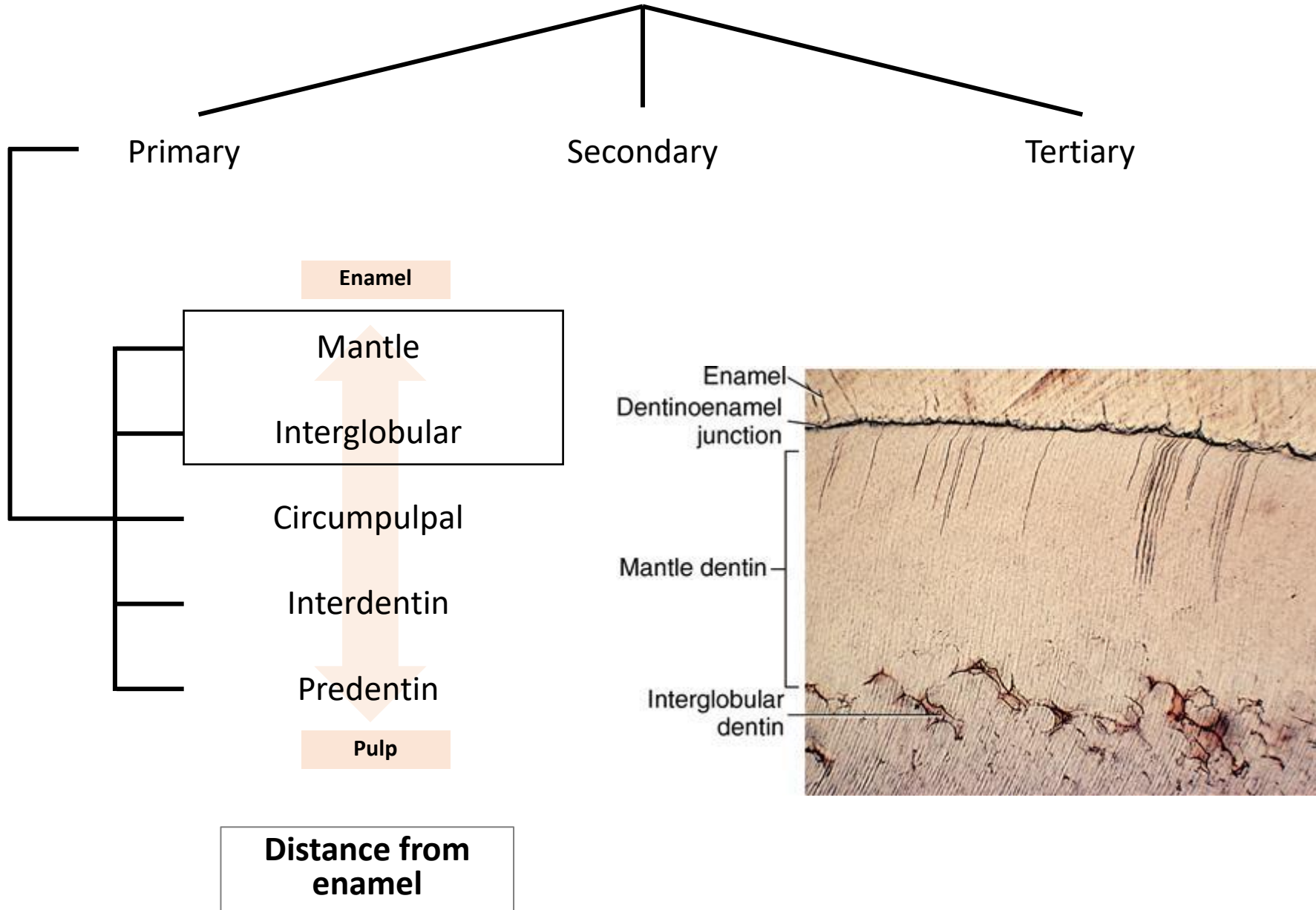
Forms a collagen skeleton for mineralization

In both temporary and permanent teeth





Dentin types



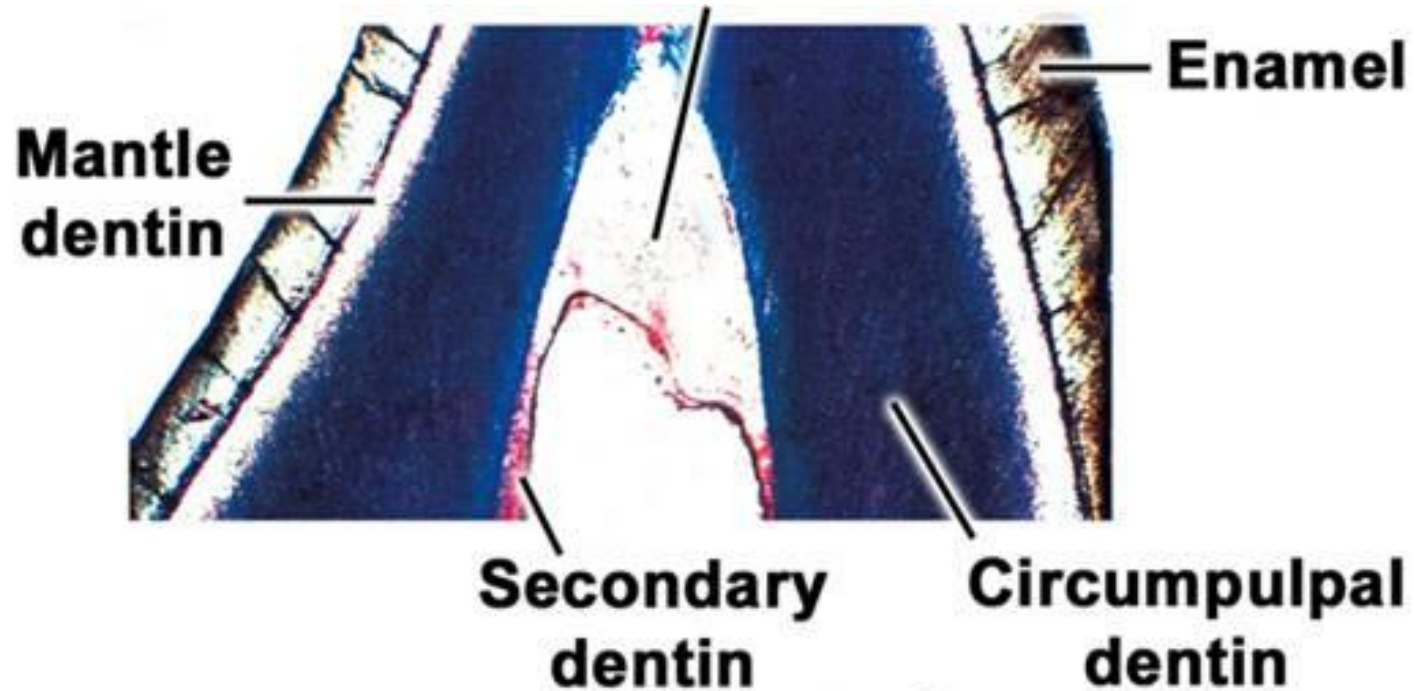
Mantle dentin

Firstly-formed dentin, **thickness** around **30 um**

Variable mineralization

Collagen fibres oriented perpendicular to the DEJ surface (Korff bundles)

Branched terminal parts of dentin tubules terminates here



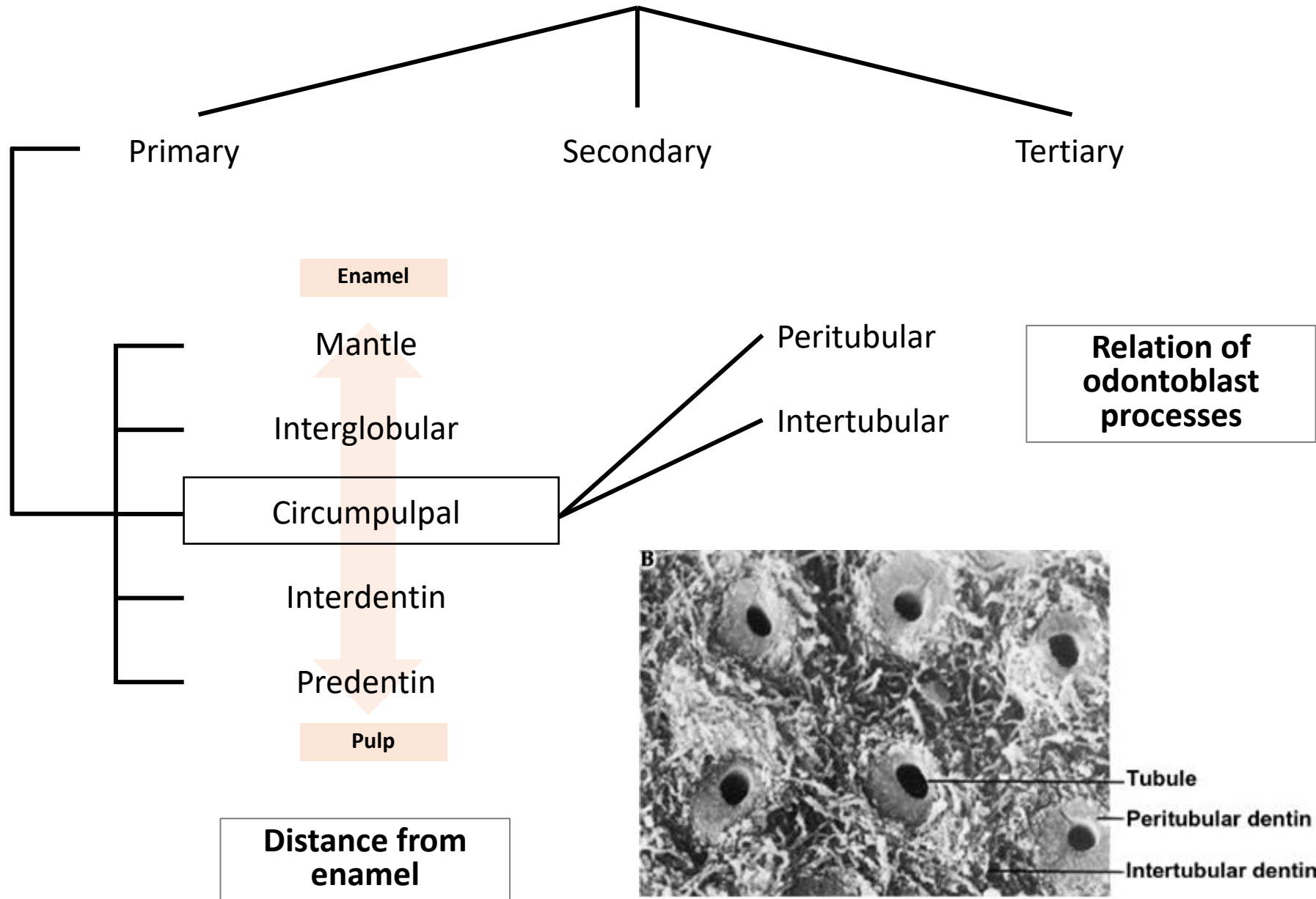
Copyright © 2003, Mosby, Inc., All rights reserved.

Interglobular dentin

Imperfectly calcified dentin at the interface of mantle and circumpulpal dentin

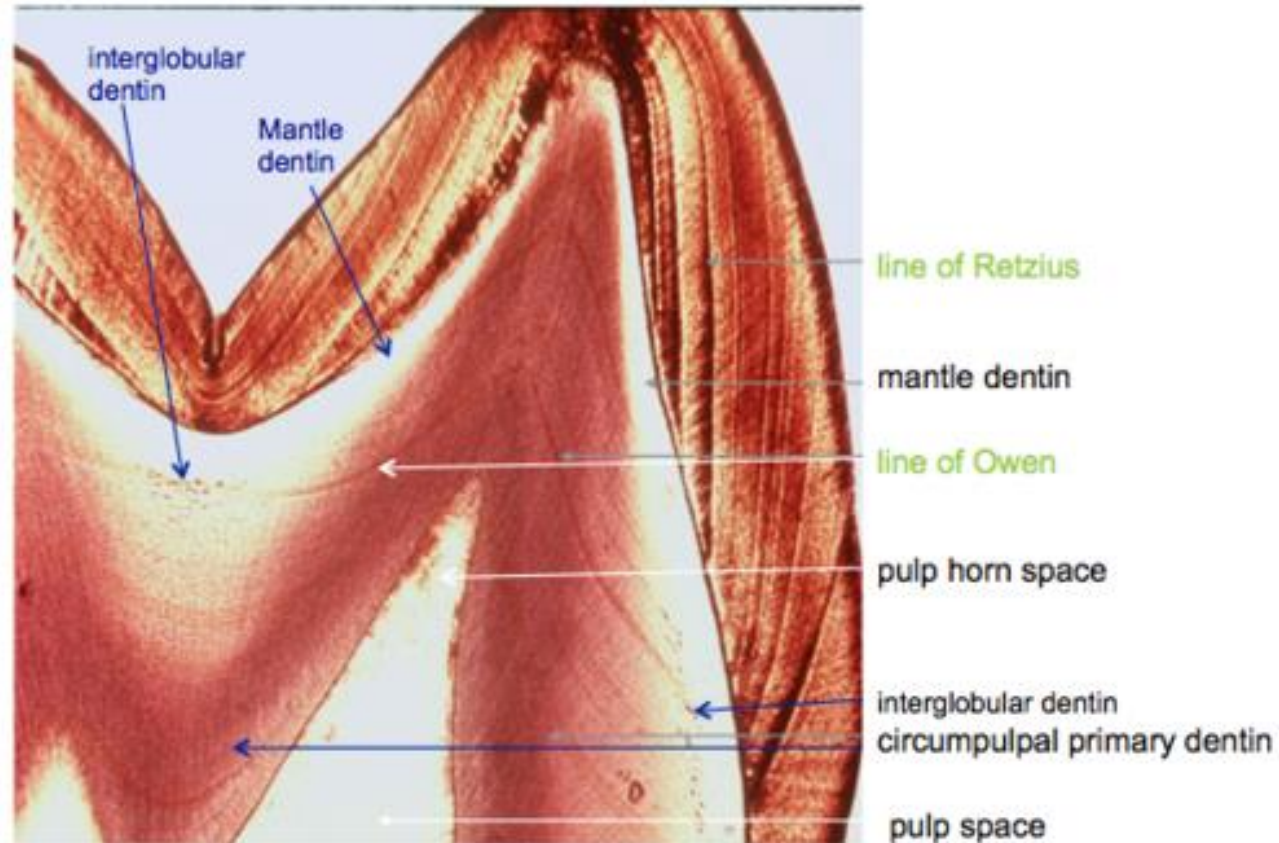
Fusion of dentin globules is impaired

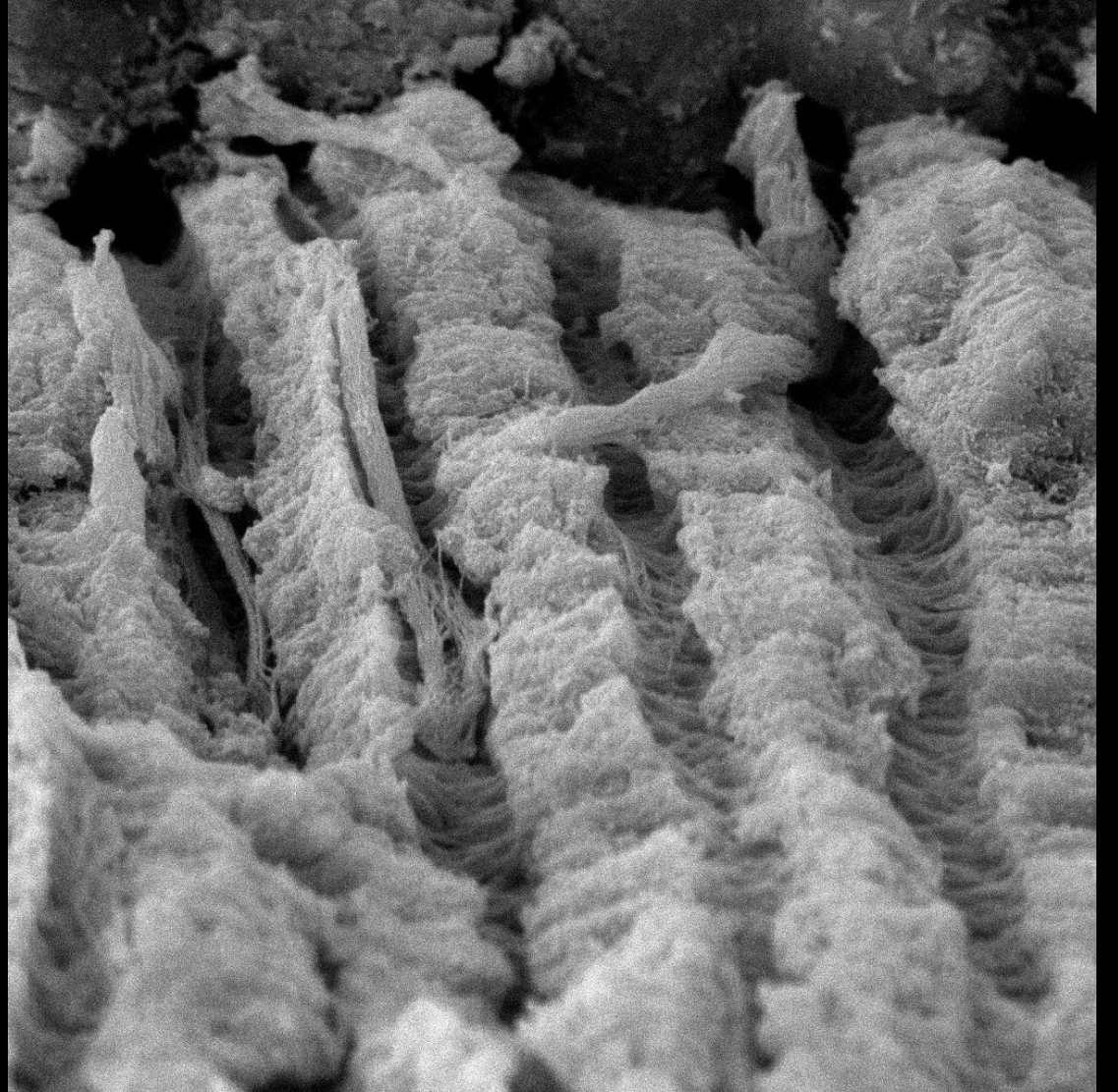
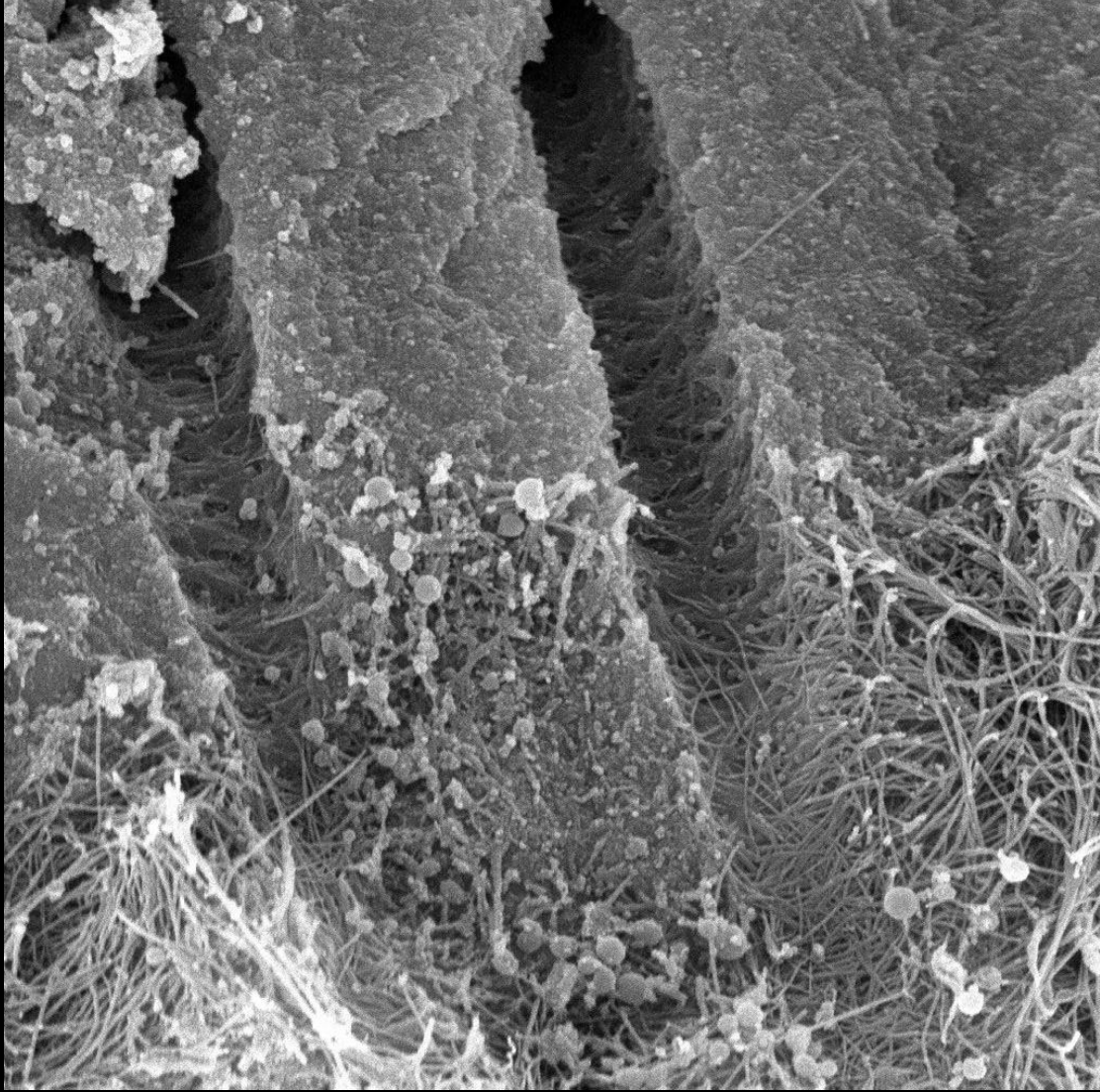
Dentin types

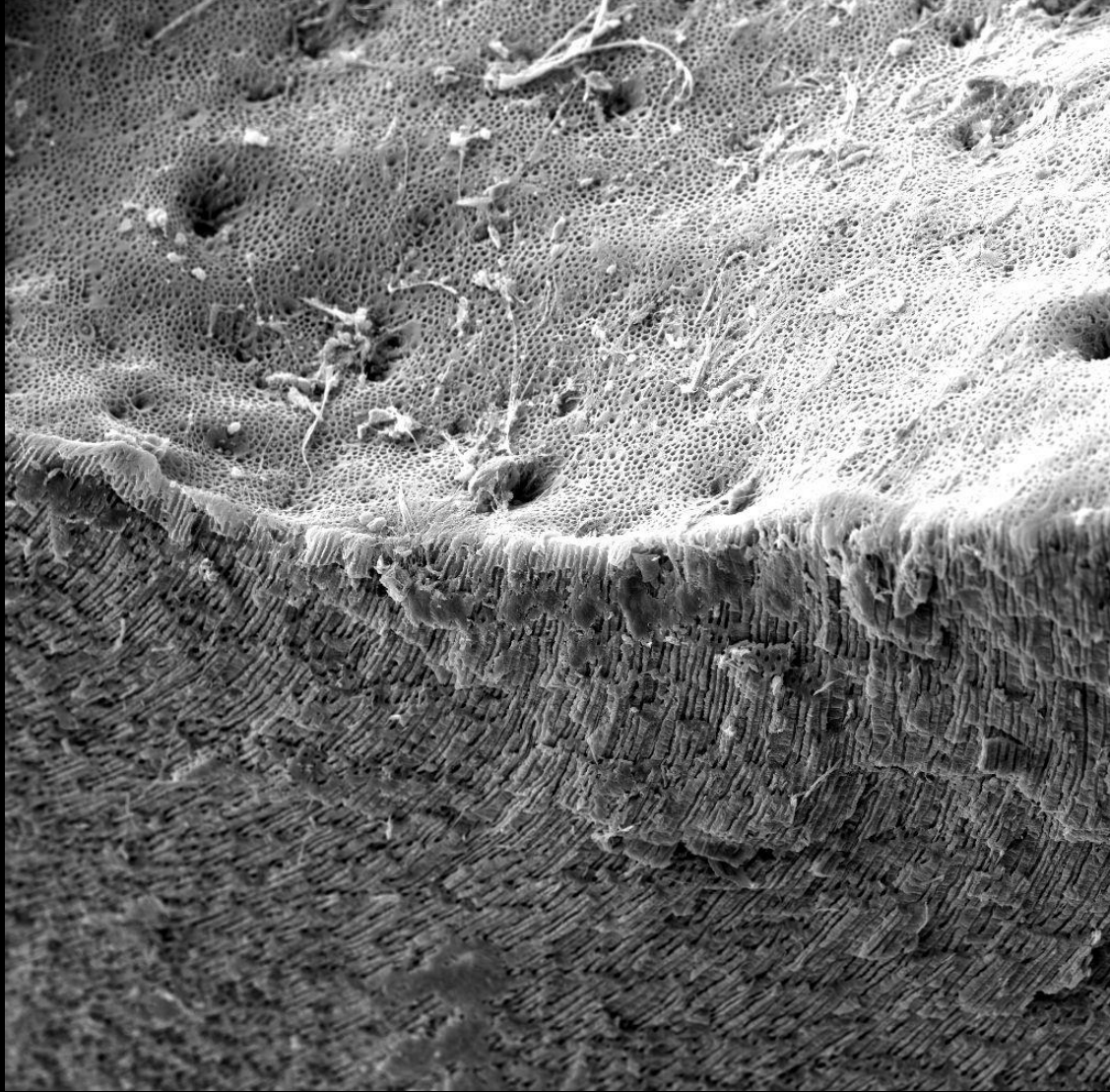
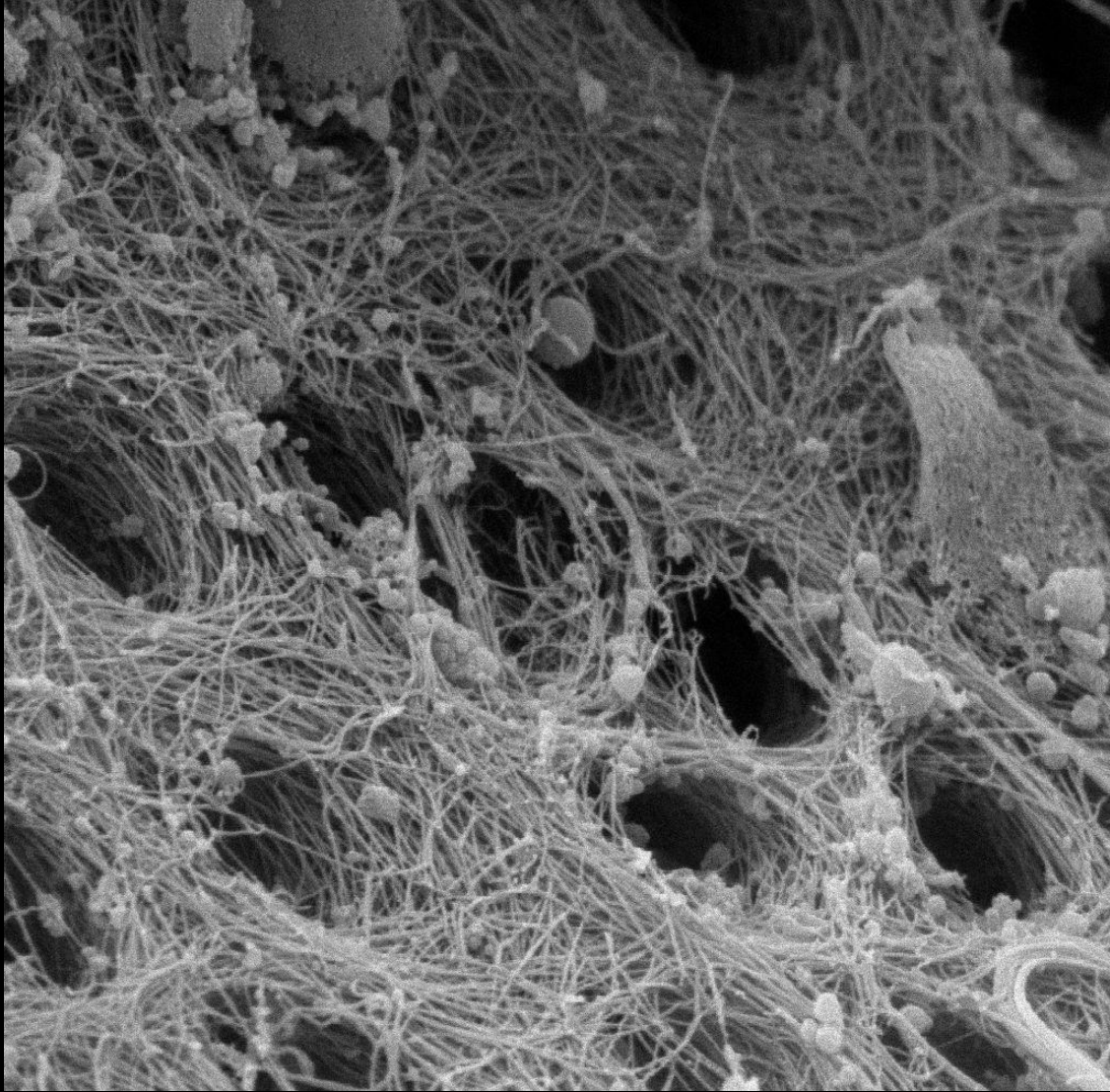


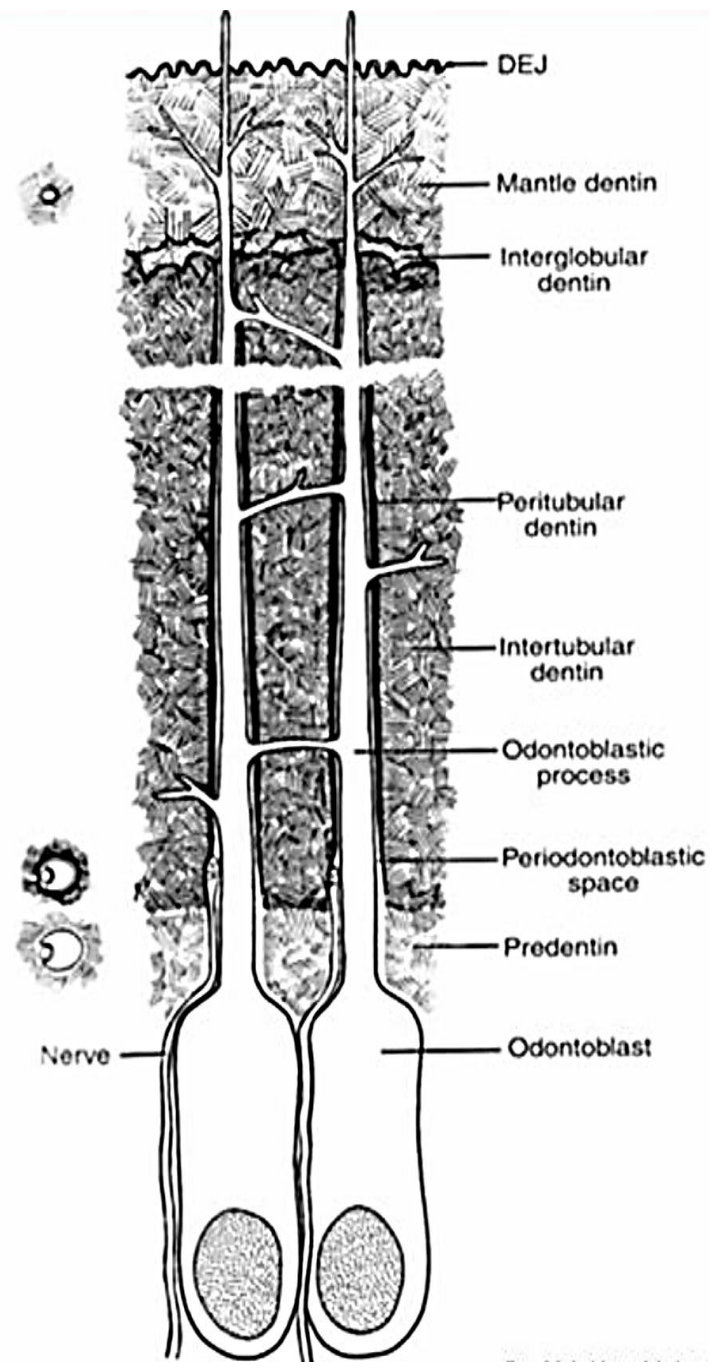
Circumpulpal dentin (*von Ebner*)

- Collagen fibres run obliquely to perpendicular to the course of tubules
- Mineralization is globular.
- Only minor branching of the dentinal tubules here.

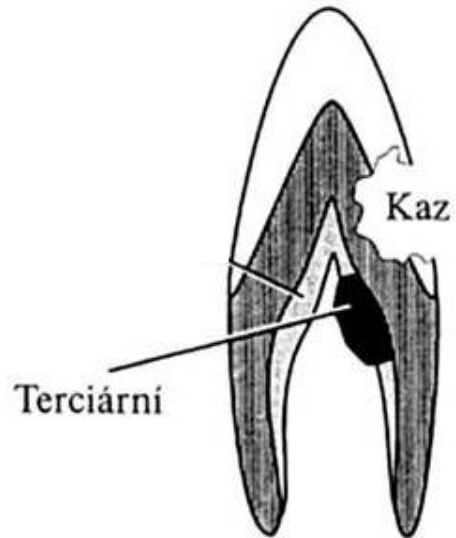
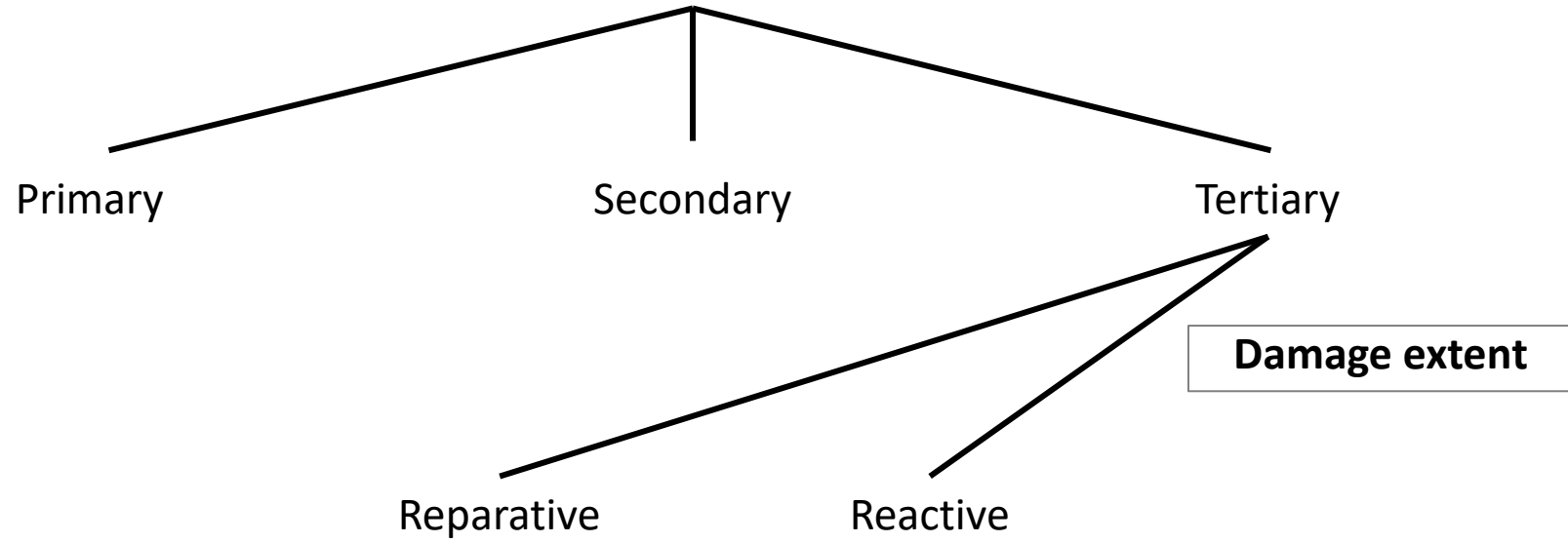




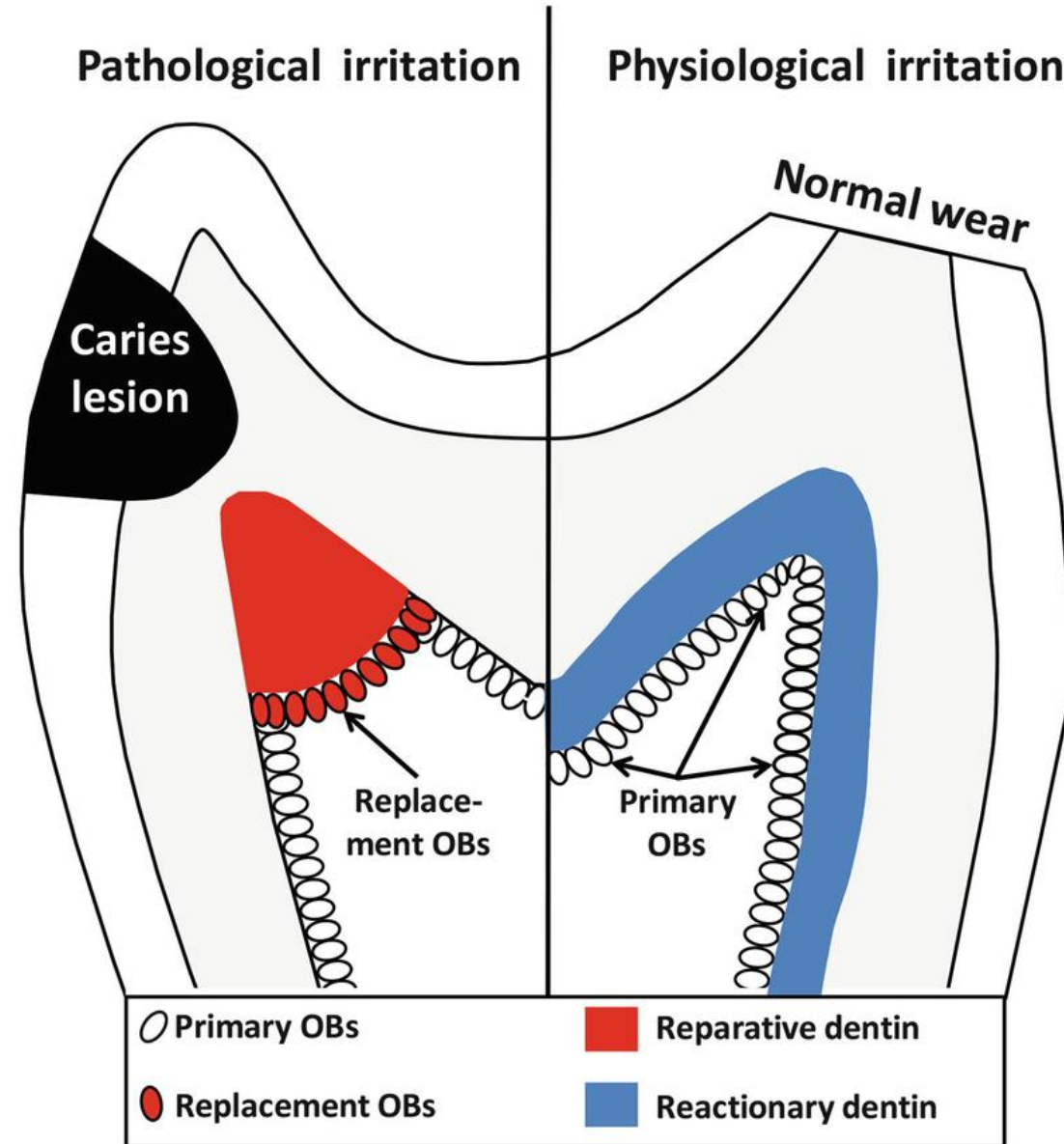




Dentin types

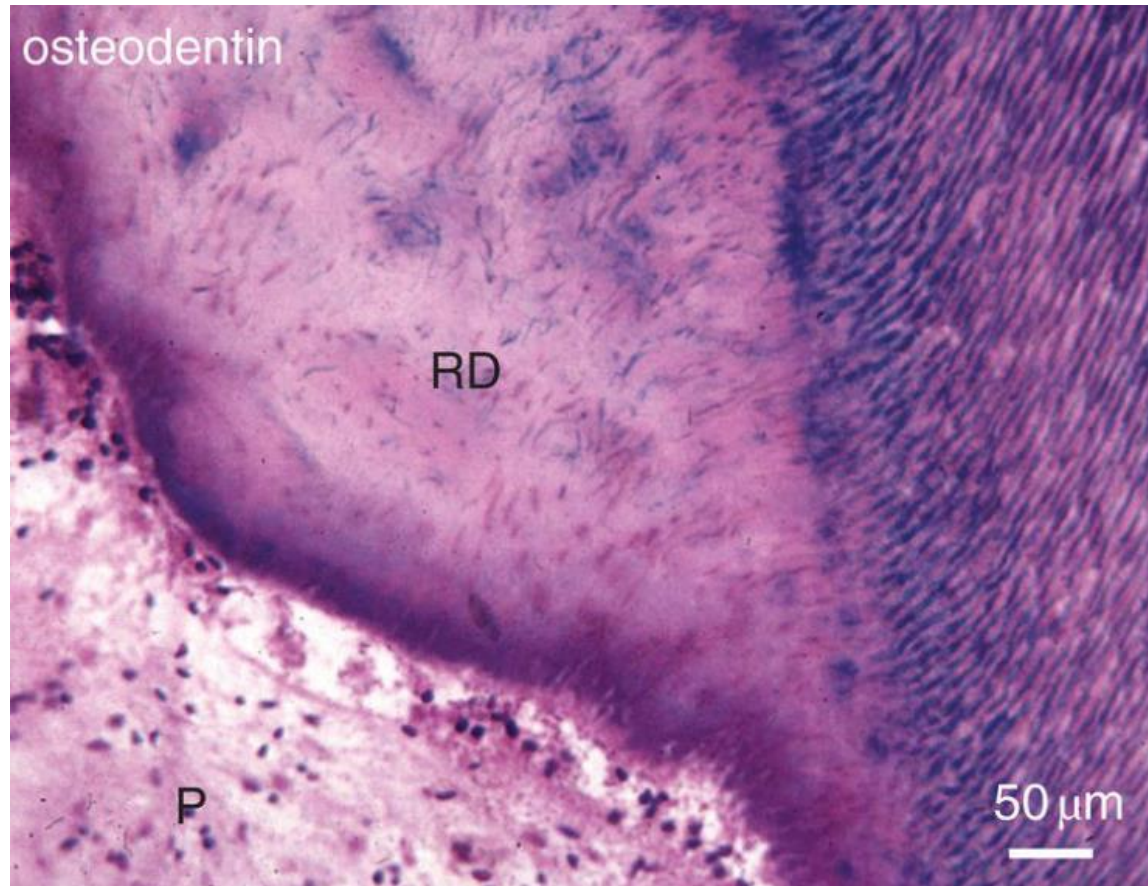


Tertiary dentinogenesis



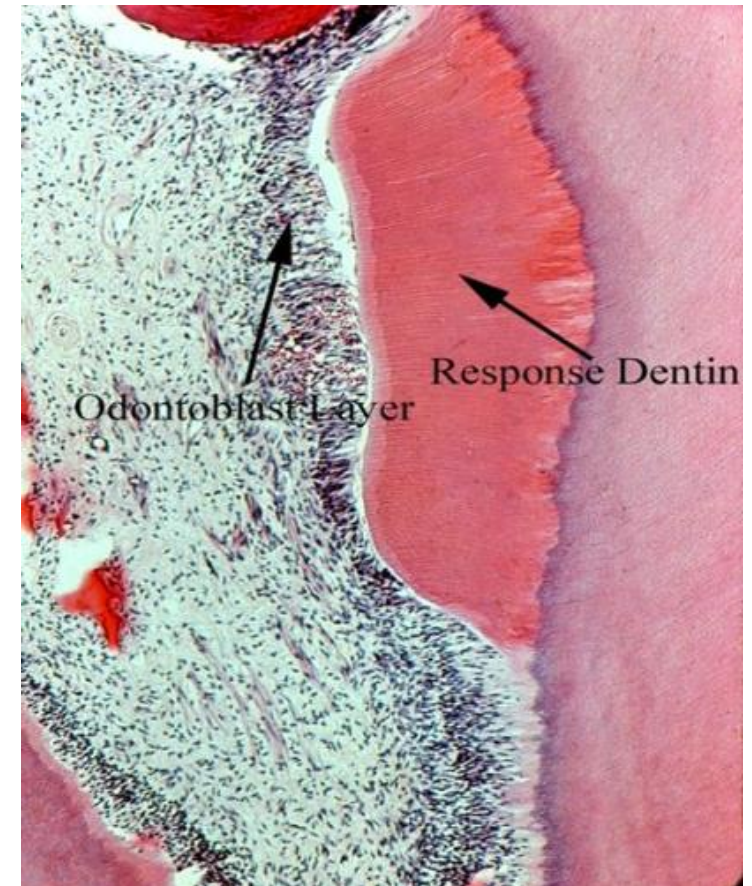
Tertiary dentinogenesis

Reparative[?] dentin



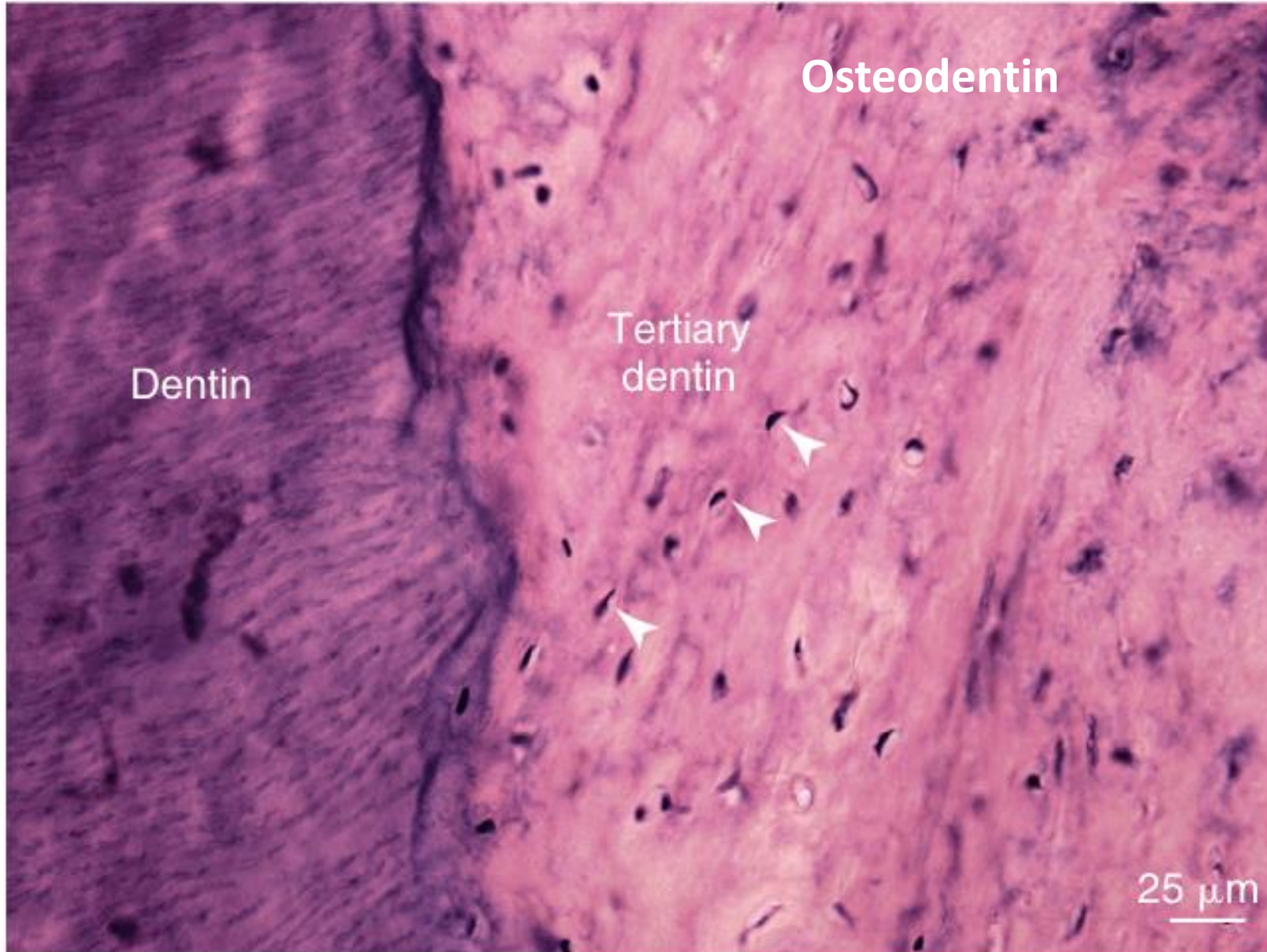- Cause of formation:** Reaction to larger dentin damage
- Structure:** Amorphous structure
- Dentinal tubules:** NO
- Dentin-forming cells:** Newly differentiated from pulp
- Cell bodies:** May be present (osteodentin)
- Main function:** Protection from infection

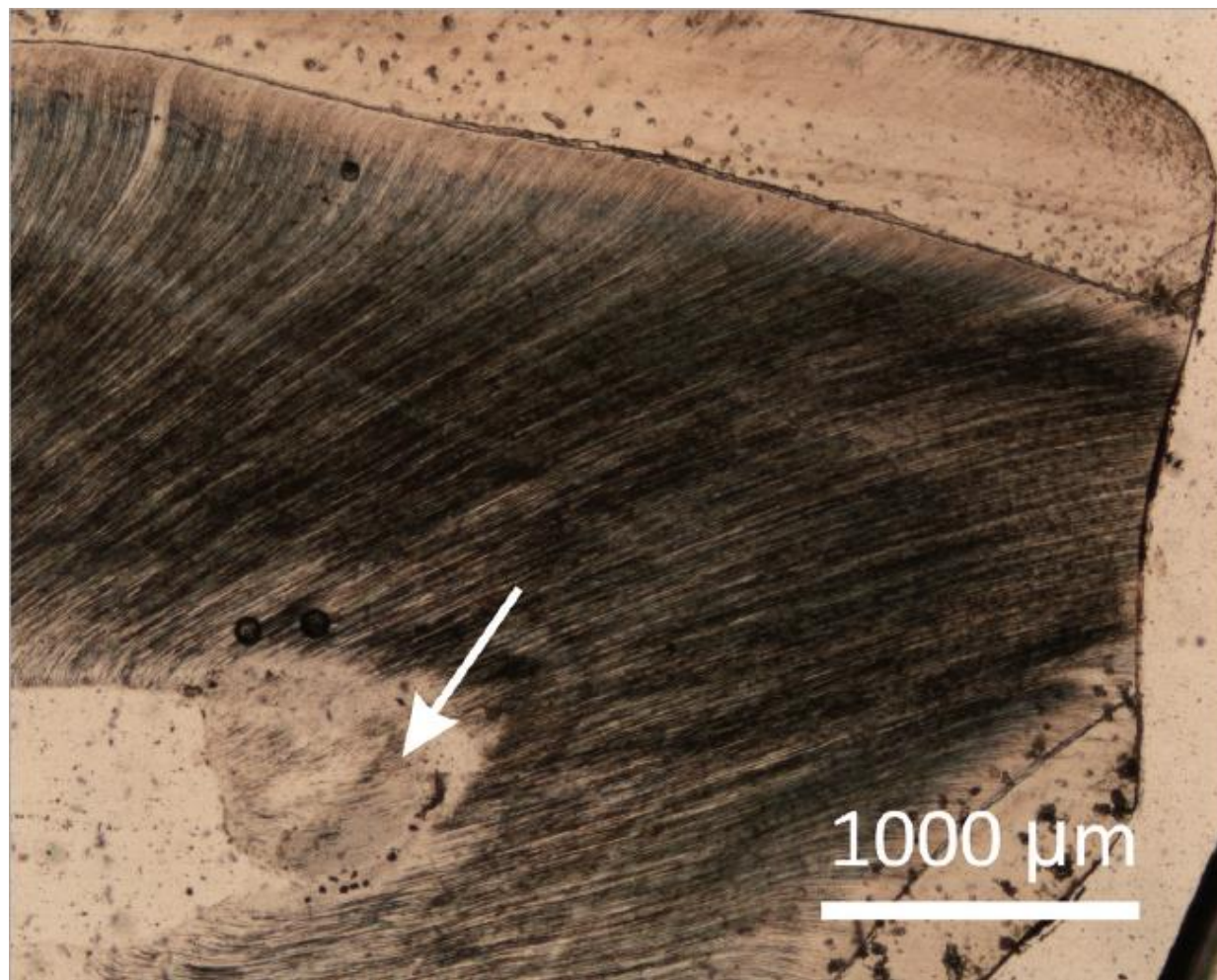
Reactionary[?] dentin



- Cause of formation:** Minor stimuli
- Structure:** Arranged
- Dentinal tubules:** YES
- Dentin-forming cells:** Odontoblasts
- Cell bodies:** NO
- Main function:** Increase of tooth wall

Tertiary dentinogenesis





Histologický výbrus vysoce abradovaného horního dočasného špičáku v oblasti korunky a vrcholu dřevové dutiny, kde se pod vlivem vnějších stimulů ukládá *terciární dentin*. Šipka ukazuje na **reakční dentin**, formu terciárního dentinu, která vzniká jako pomalá reakce zubu na poškození atricí/abrazí. Jako rychlá odpověď při poškození zubu kazem se vytváří *dentin reparační*. Foto: AH

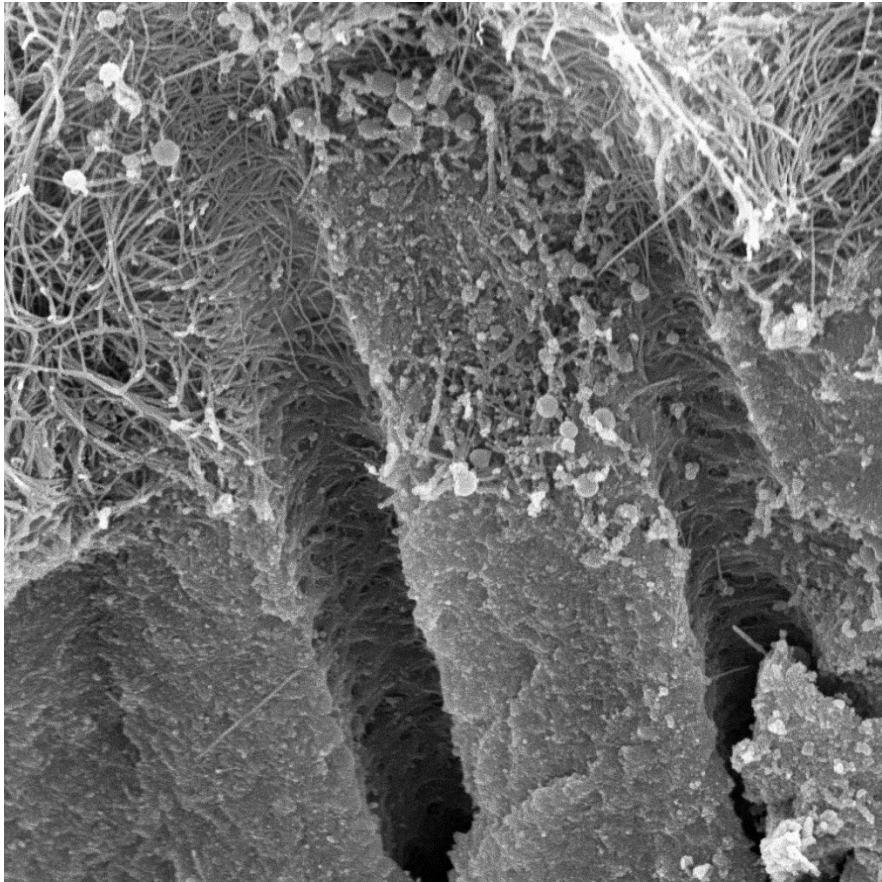
Chemical composition

Inorganic
70 %

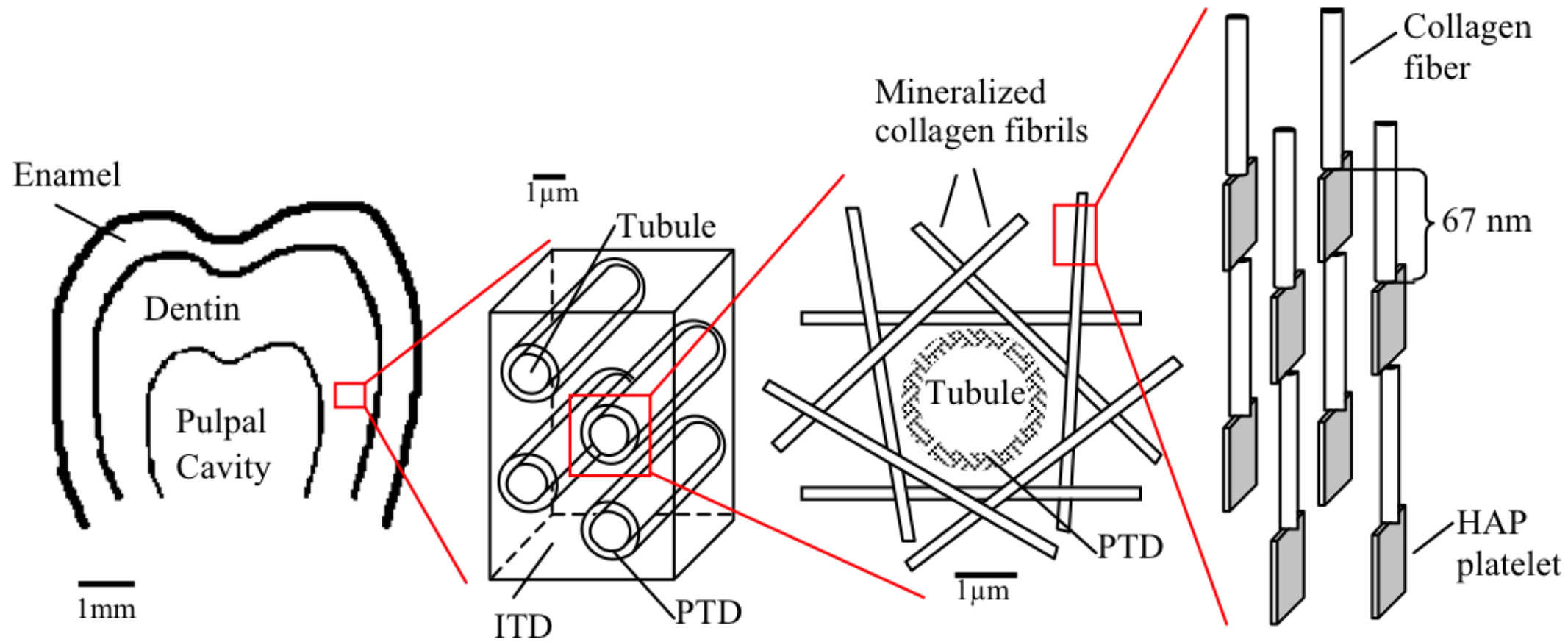
Water
10 %

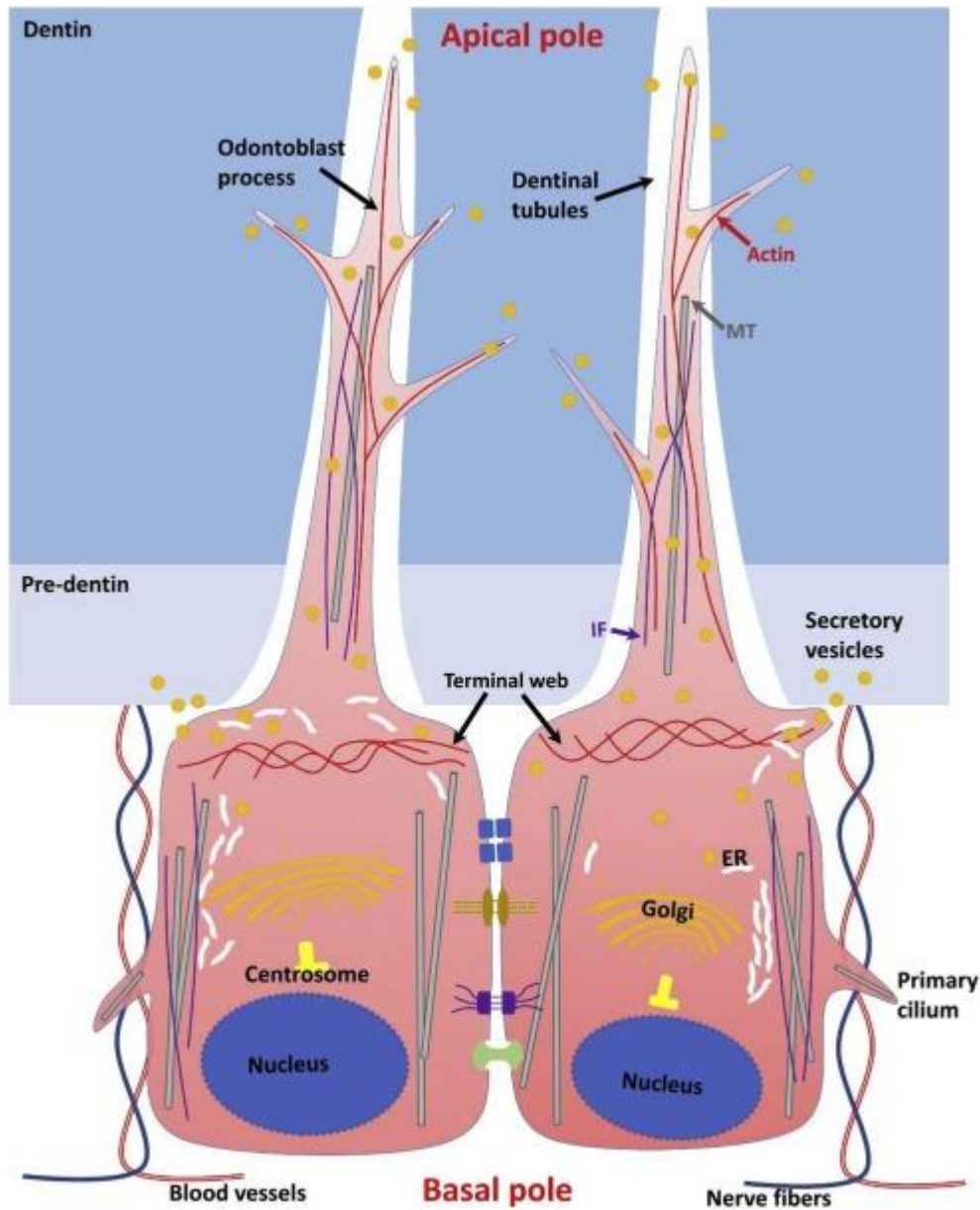
Organic
20 %

- Hydroxylapatite crystals
- Crystals smaller than than in enamel
- Crystals attached to fibres



- **Collagens** - collagen I (III a V) (90 %)
- **Non-Collagenous Proteins** (8%)
 - a) Phosphorins – Ca²⁺ and phosphate donors, crystal growth control
 - b) Gla-proteins (gamma-carboxyglutamate proteins, acidic character) + glycoproteins (osteonectin, osteopontin, sialoprotein I and II) - calcium carriers, crystal growth
 - c) Proteoglycans - control of crystal growth
- **Phospholipids** (2%)



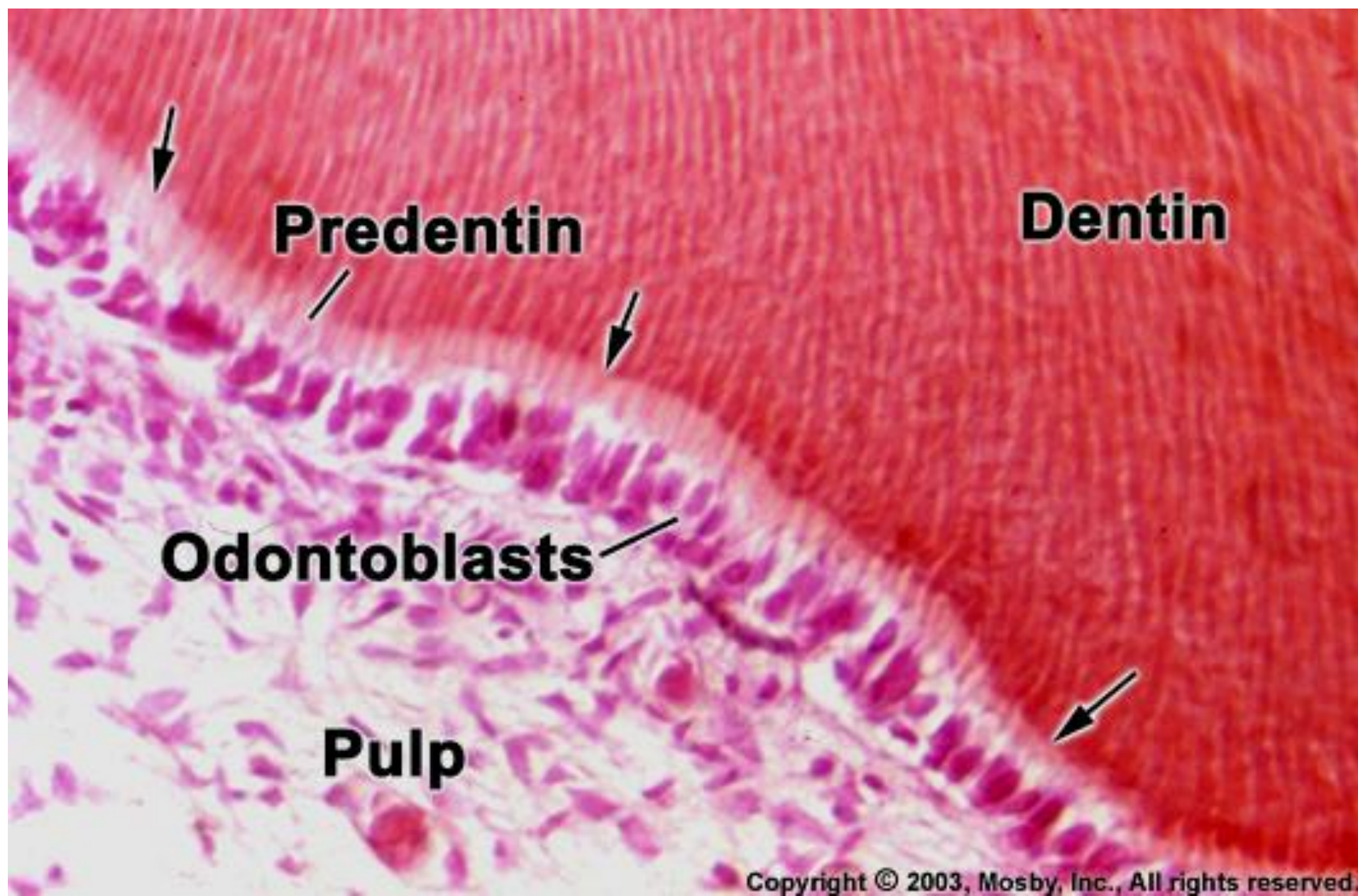


Junctional complex

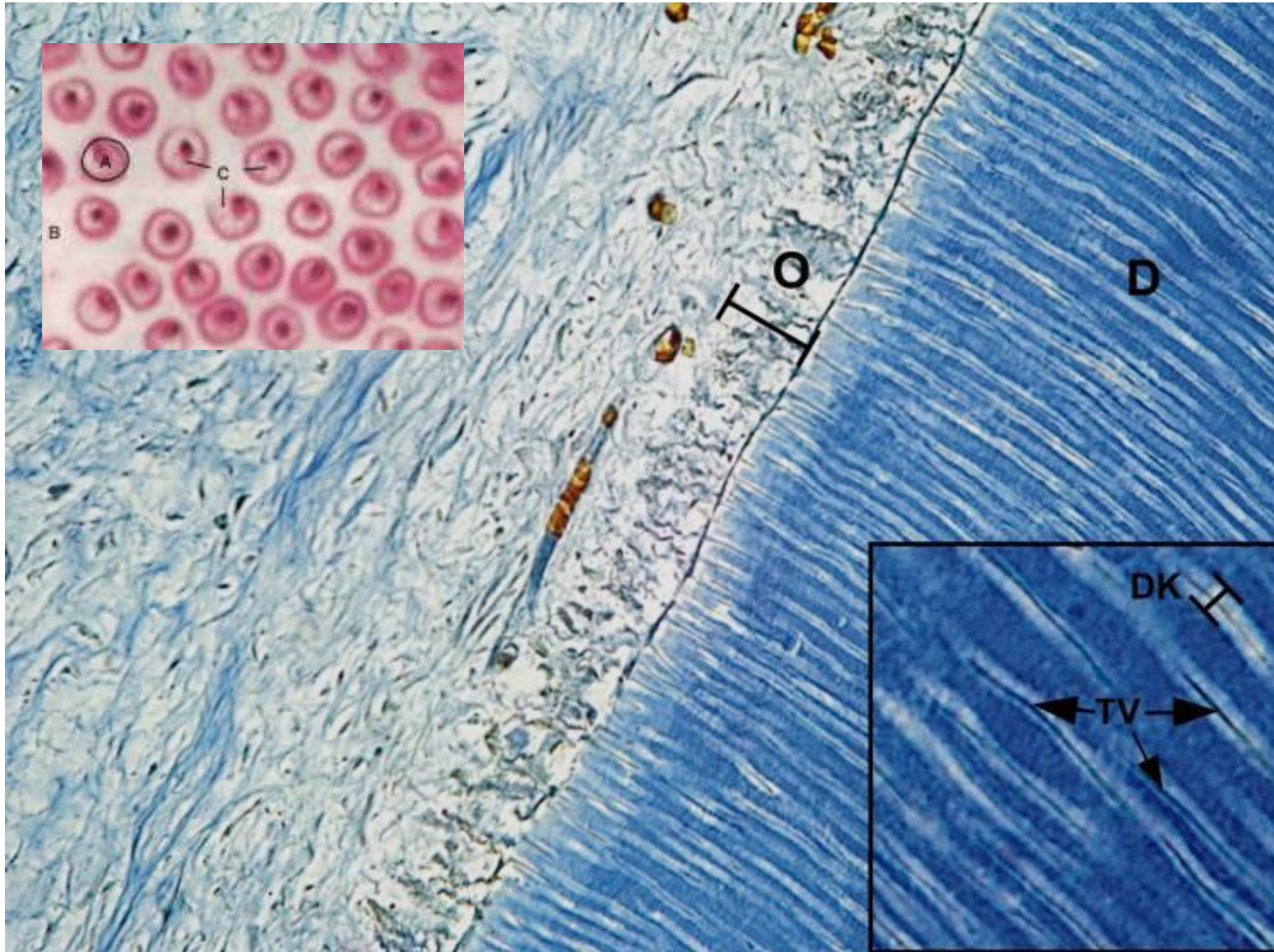
Numerous connecting complexes among the odontoblast apices:
tight junctions, gap junctions, desmosomes -
synchronization of odontoblasts

Above the connecting complexes, the apex slowly changes into a thin and long, short-sided branch -
Tomes fiber



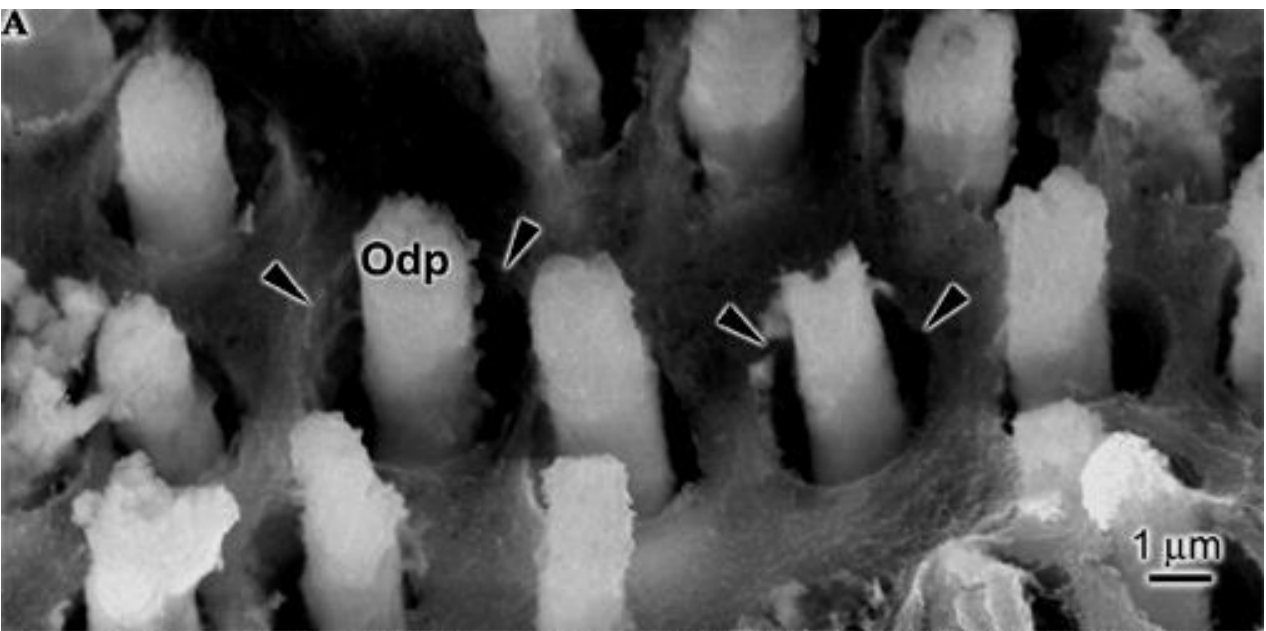
A basal process may be present



Each fiber is has its own canal - **Dentinal Canal** (tubulus)

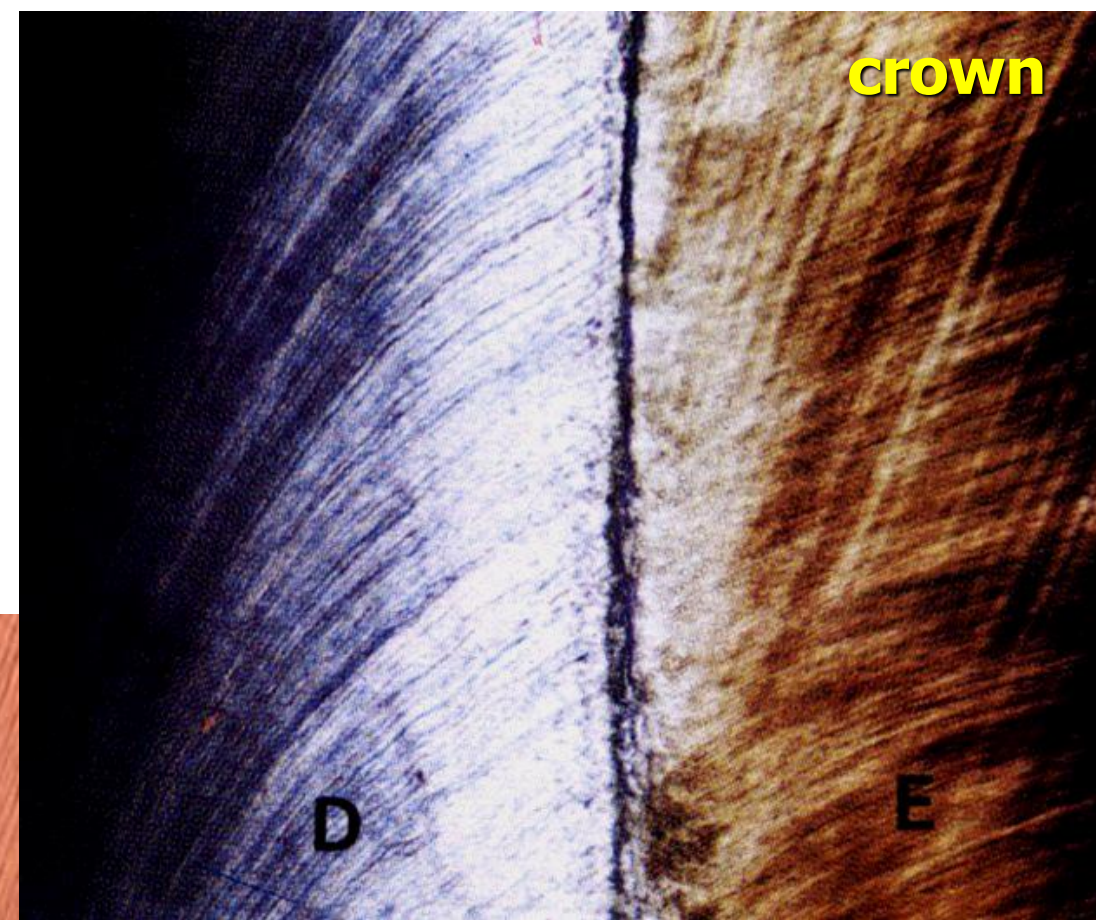



Tomes fibres



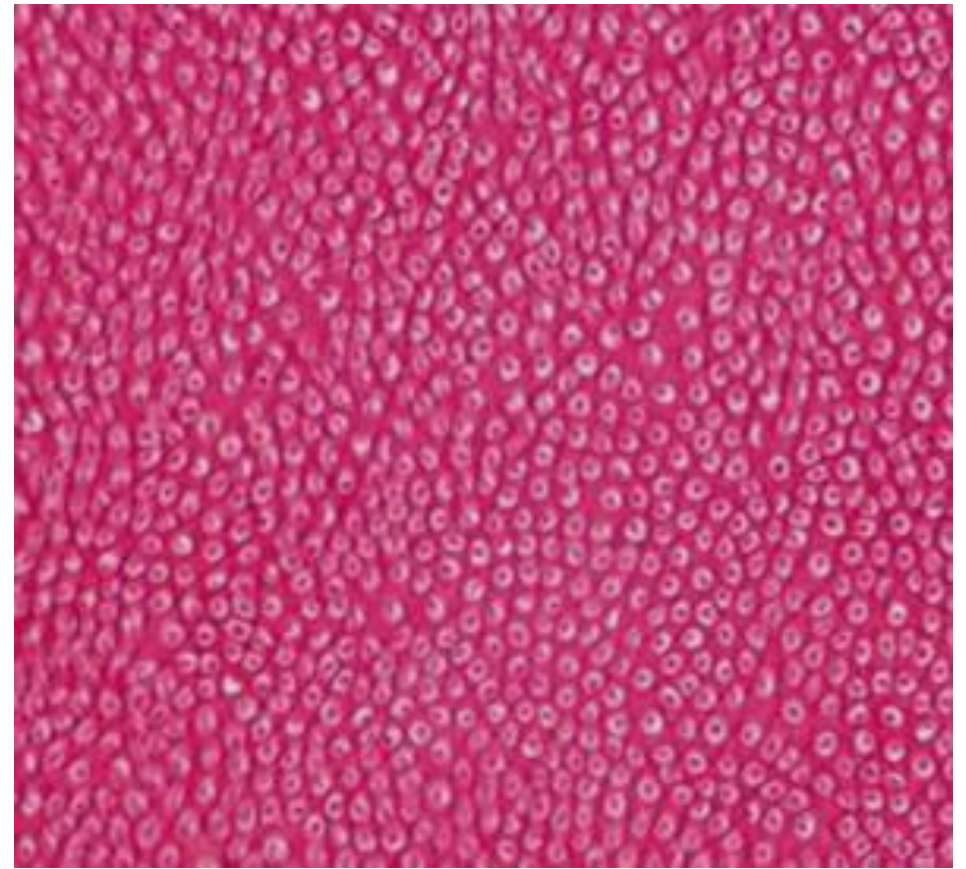
Channels with Tomes fibres penetrate the entire dentin and cause the dentinal stripes

visible on stained sections as well as ground sections





Dentinal tubules
(transversal section)



Dentinal tubules with Tomes fibres
(transversal section)


1 mm² surface can contain around 50 000 tubules

Dentinal tubules shape

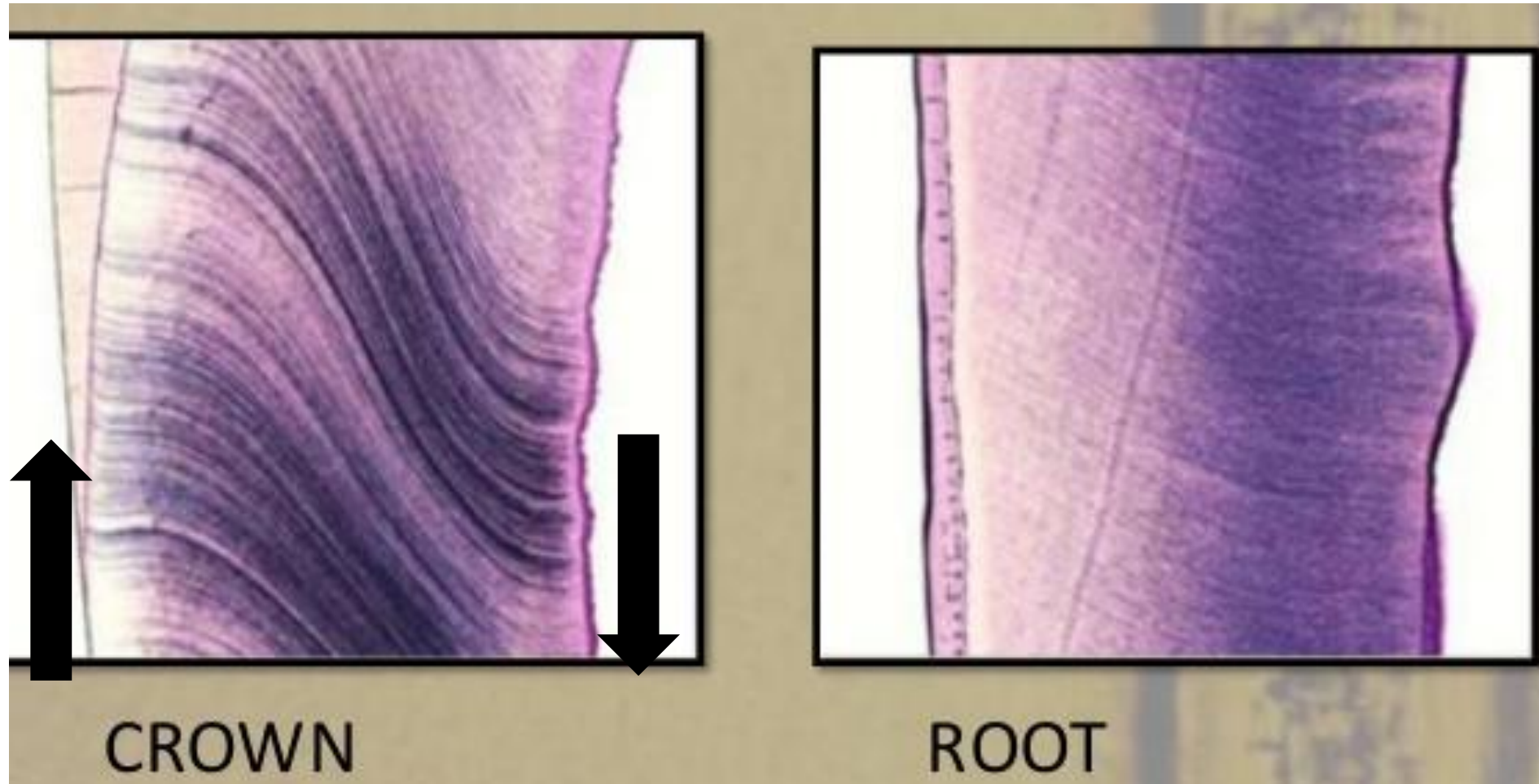
S-shaped (2 bends - primary bending) towards DEJ (or cemento-dentinal junction)



Schreger shapes
(Crown part of dentin)



Primary dential bending



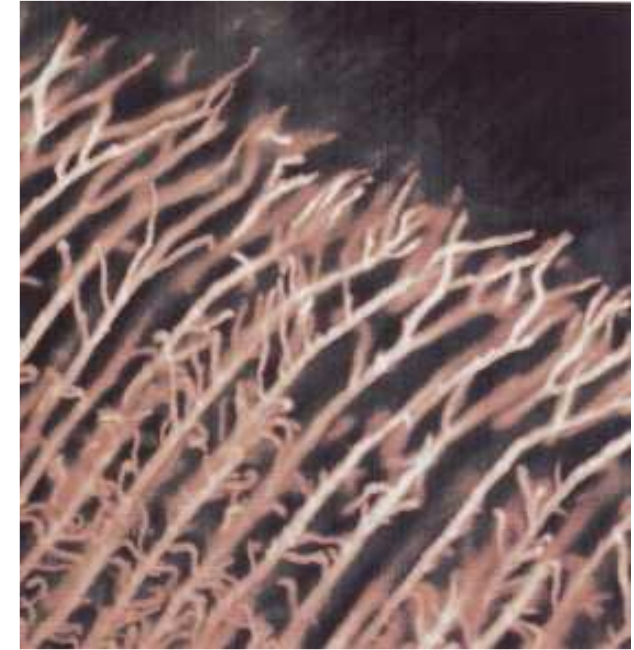

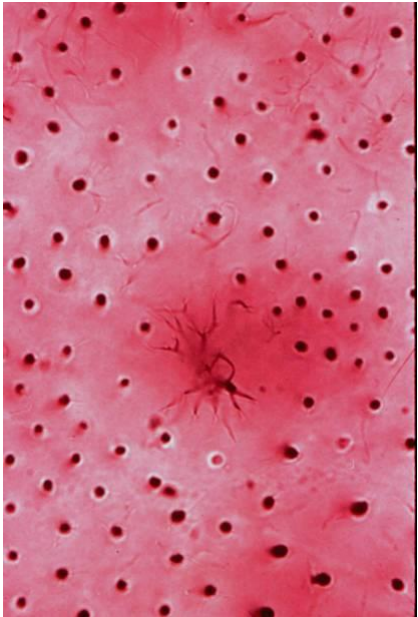
In addition to S-shape primary bending, up to another 200 secondary bends -

Primary and secondary tubular bending caused by migration movements of odontoblasts during dentinogenesis

Diameter of the dentin tubules is around **1–4 μm**

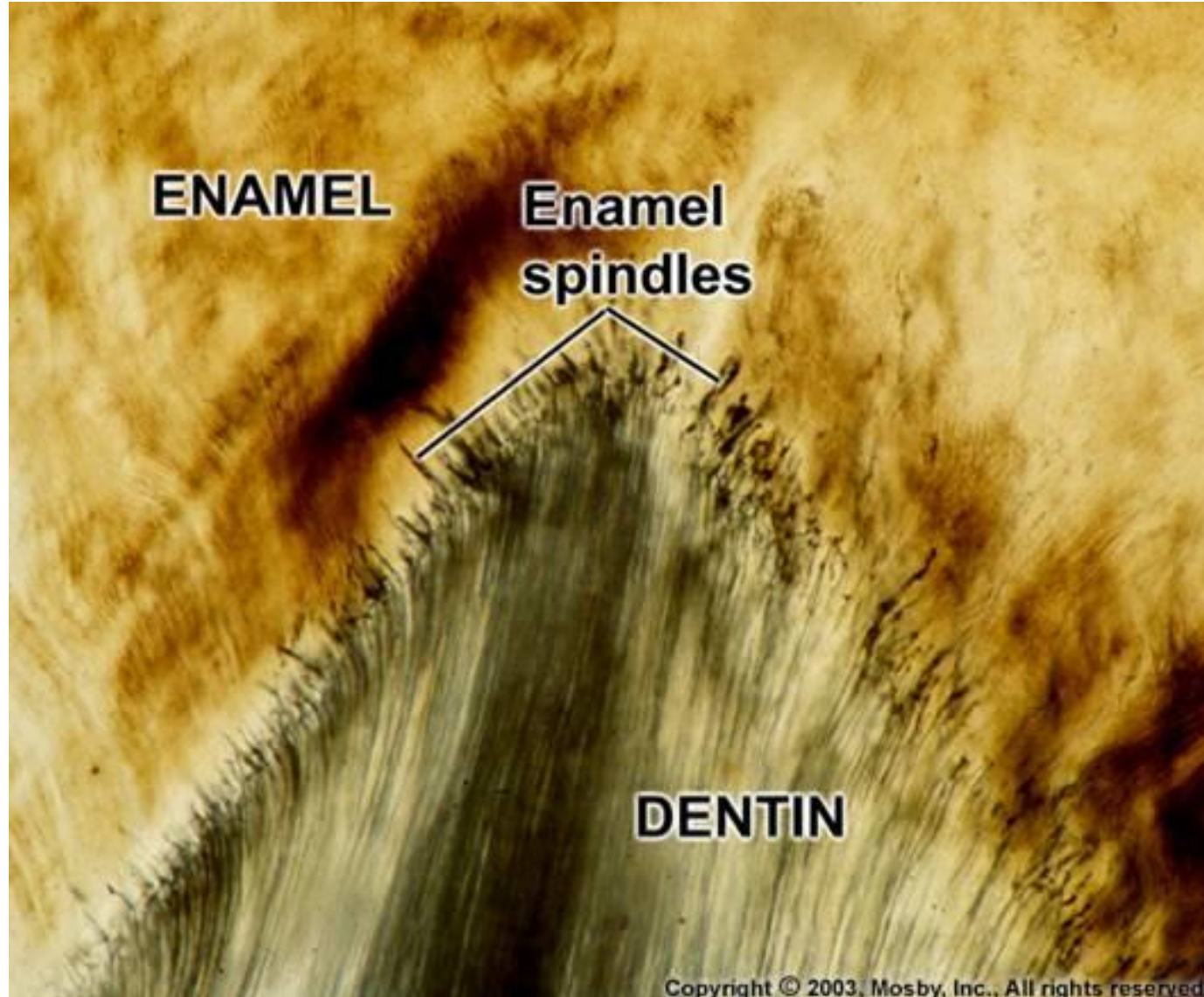
Decreasing towards DEJ (or cemento-dentinal junction)


Neighboring tubules can be interconnected by anastomoses (tubicles)




Enamel spindles (*fuscus enameli*)

Dentine tubules extension into enamel





Detail **dentino-cementového spojení** na longitudinálním výbrusu trvalého zubu, zobrazeno v procházejícím světle. Dentin je nahoře; cement dole, je patrné jeho vrstevnaté přirůstání (vodorovné linie). Foto: AH

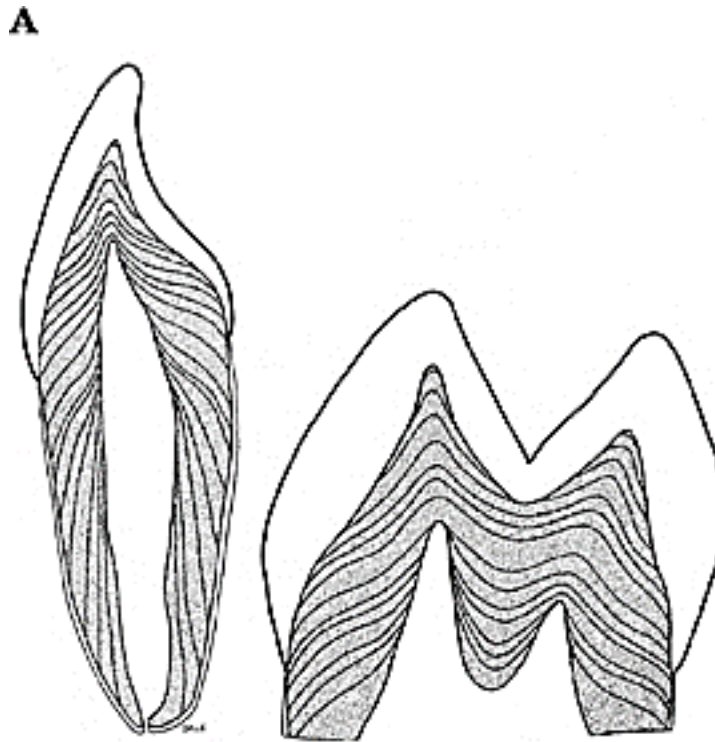


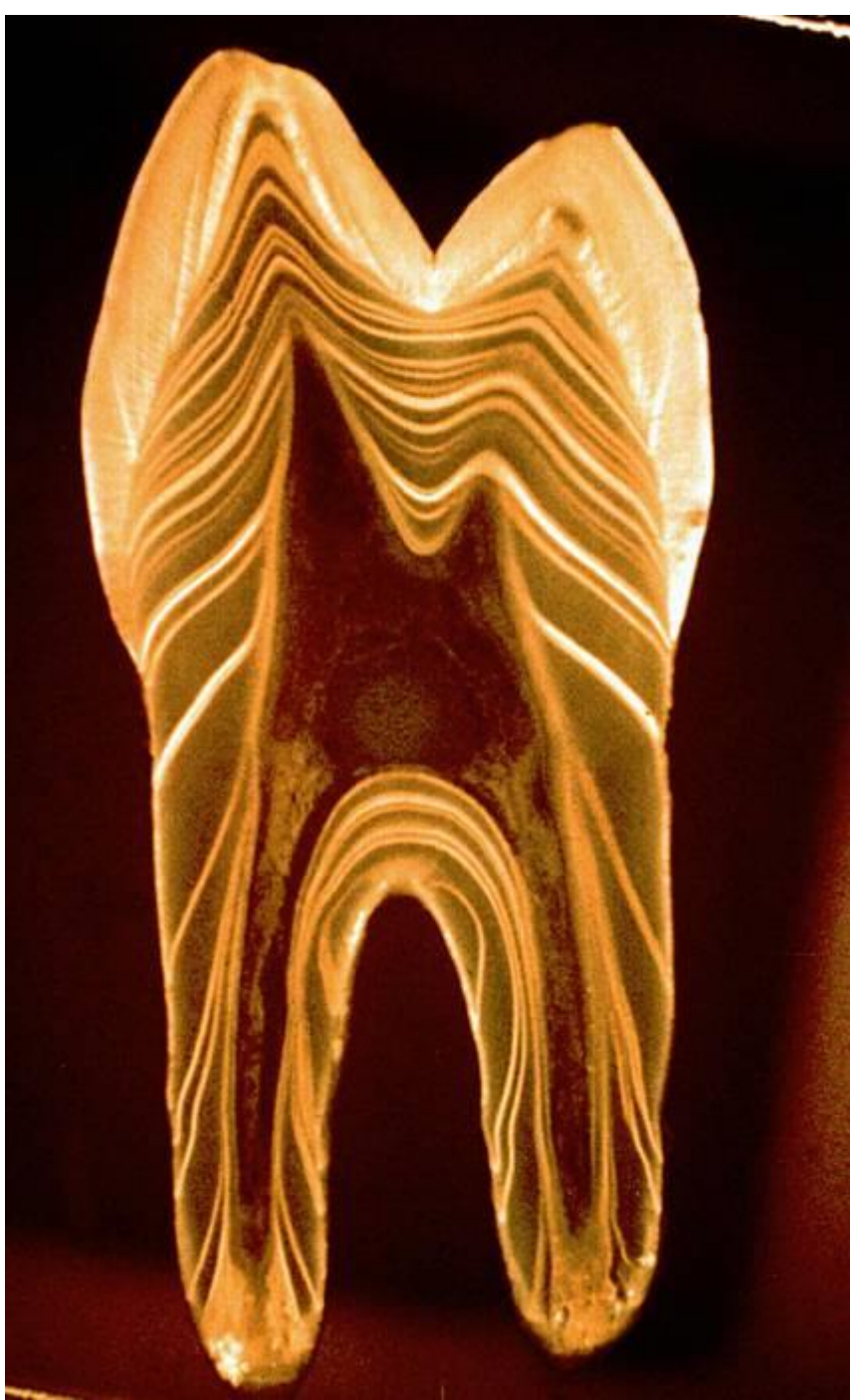Dentino-sklovinné spojení na transverzálním výbrusu trvalého zubu, zobrazeno v procházejícím světle. Dentin je dole, sklovina nahoře. Ve vnitřní třetině skloviny jsou patrné *sklovinné trsy (enamel tufts)*, podobné trsům trávy a prasklinky probíhající celou její tloušťkou, tzv. *sklovinné lamely (enamel lamellae)*. Foto: AH

Dentin incremental lines

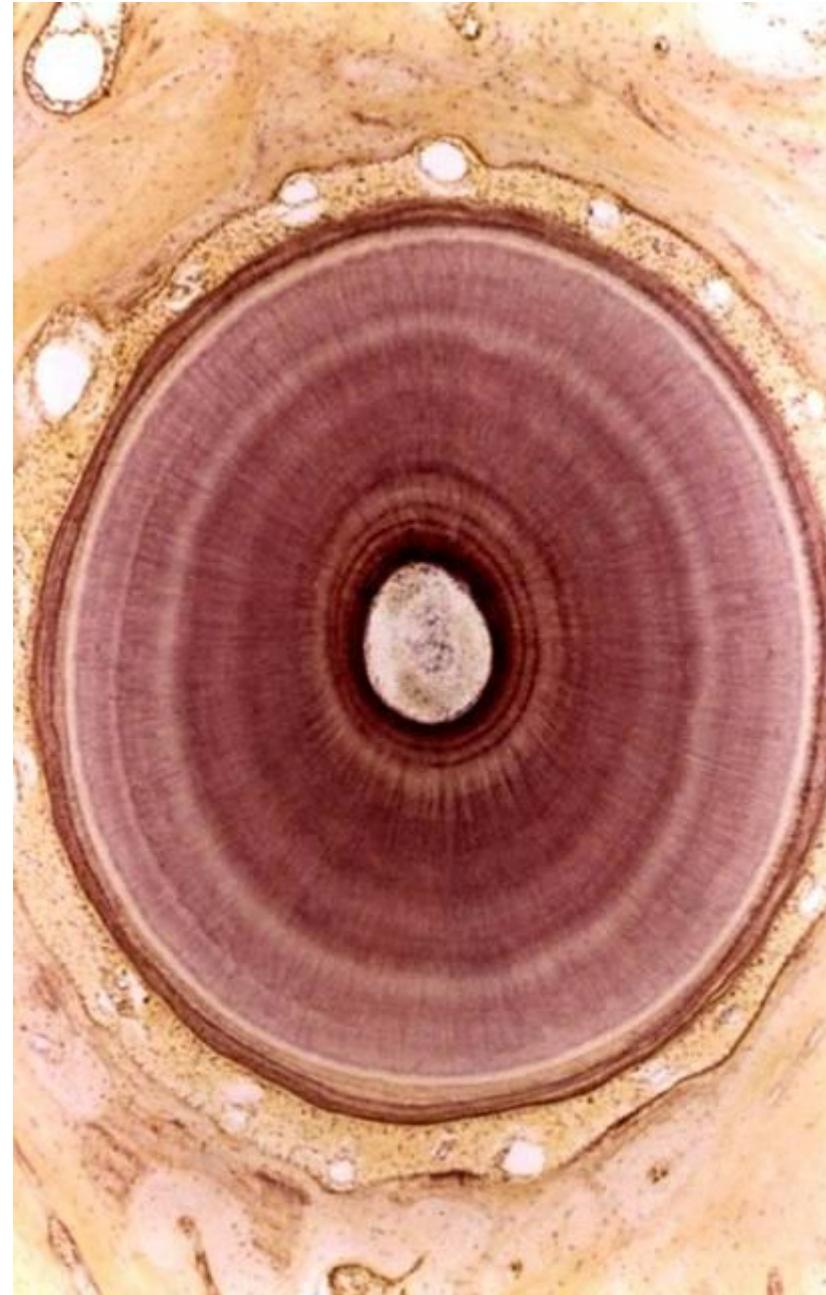
Caused by gradual deposition and mineralization of dentin

- **von Ebner lines** - **4-8 μm** distance - daily increments
- **Owen's lines** - **15-30 μm** distance - joint calcification of 4-5 day increments
- **Neonatal line** - Owen line in temporary teeth - separates fetal and postnatal dentine





Circular pattern on cross section



Sclerotic dentin

"**Dead Dentin**", more resistant to dental caries, color of amber

Origin of **dentin tubule closure** by the thickening of peritubular dentin until complete tubules termination

Formed in the crown part and increases with age - a sign of aging

According to its amount, the age of the individual is determined (forensic)

