

Urinary tract diseases

Male genital system

V. Žampachová
I. ÚP

Congenital anomalies

- **Extrophy of the bladder** – non-closure of anterior wall (bladder +/- abdominal, symphysis pubis; infections incl. pyelonephritis; ↑ risk of ca)
- **Congenital stenosis** – ureteropelvic junction, double/bifid ureter → hydronephrosis
- **vesicoureteral / ureteropelvic** reflux

Urinary tract obstruction

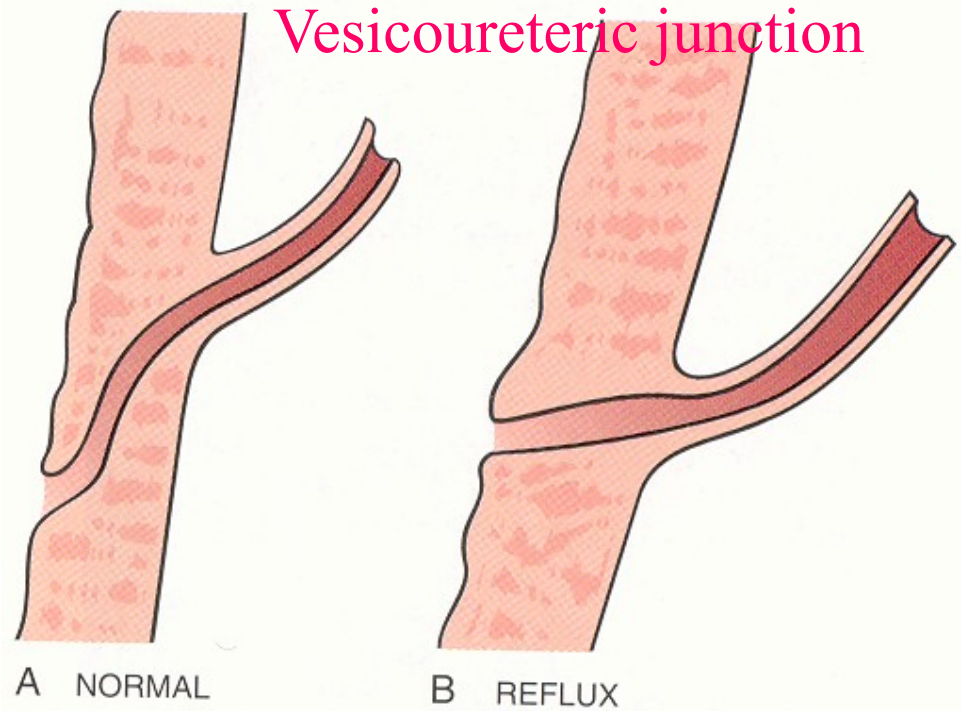
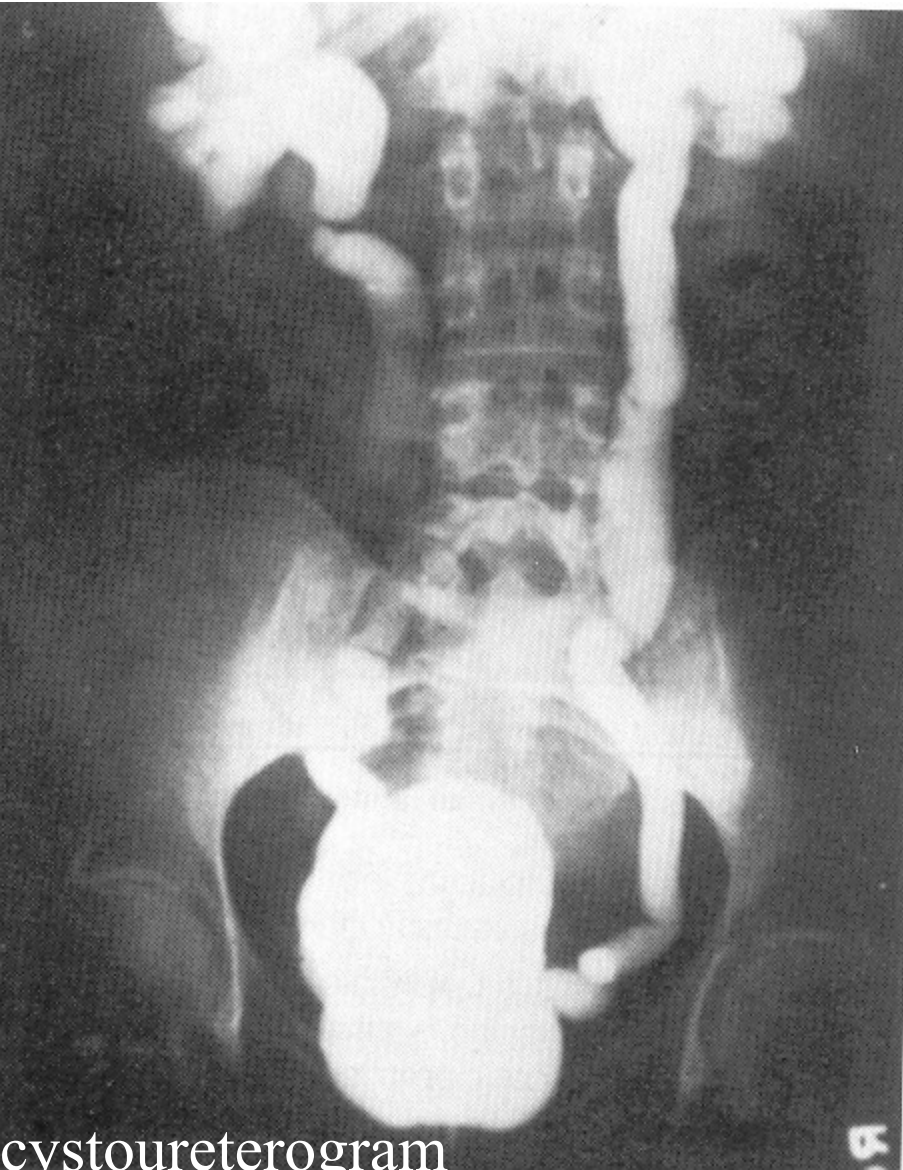
- increased susceptibility to urolithiasis
- increased susceptibility to infection
- risk of hydronephrosis

- Combination of inborn + acquired risk factors

Vesico-ureteric reflux

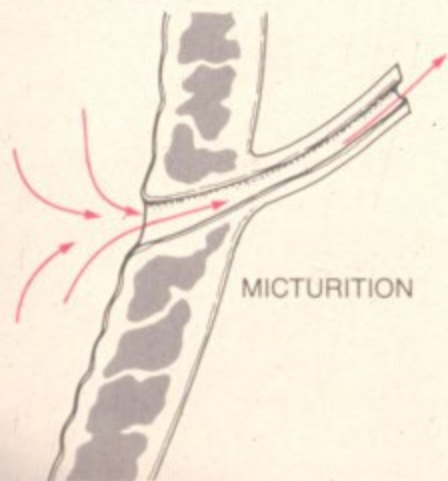
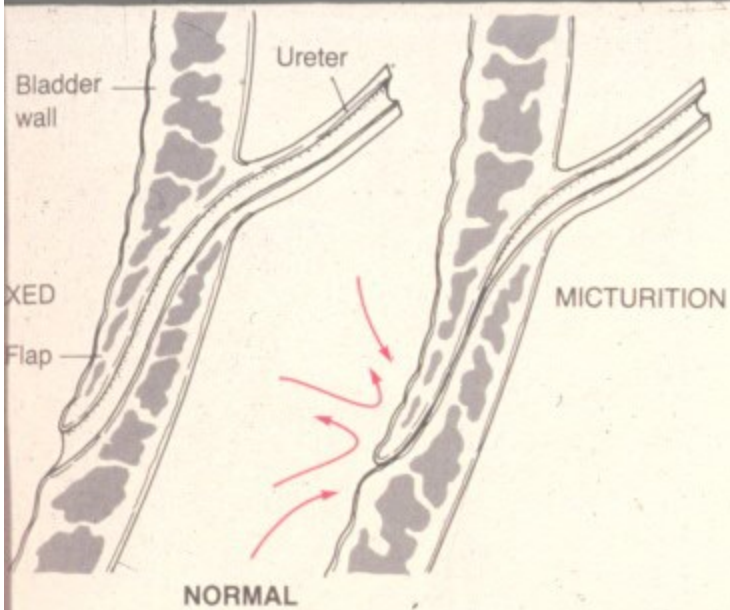
- Incompetence of the vesico-ureteral valve
- Combination of congenital defect (short intravesical part of ureter, 1-2% of children)
- ↓ ureteral contractility in infection
- acquired in bladder atonia (spinal cord injury)

Vesico-ureteric reflux

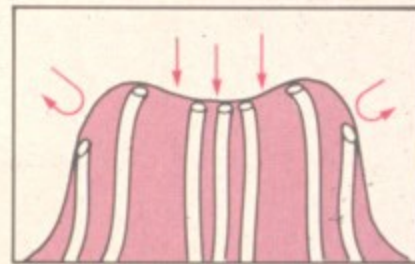
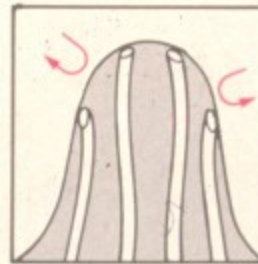
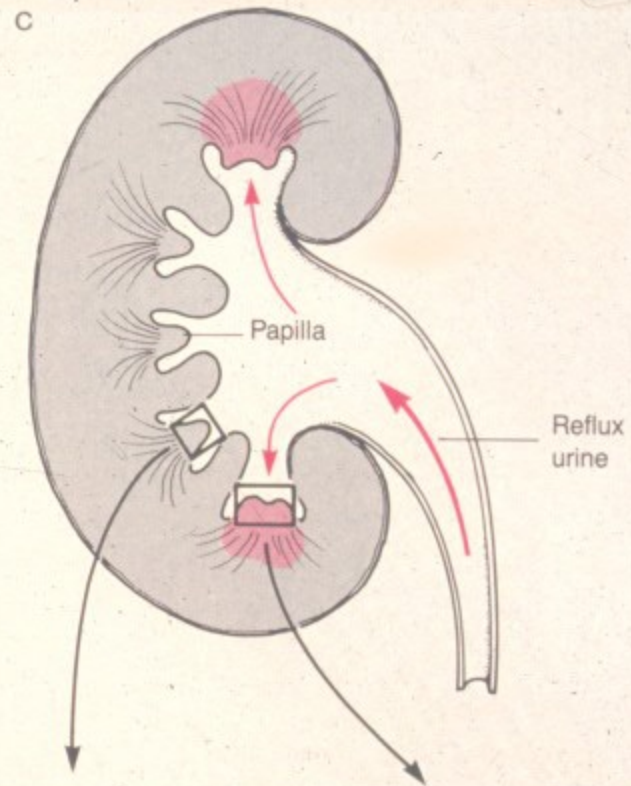


Intrarenal reflux

- Upper and/or lower renal papillae
- Progression of infection into the kidney tissue
- No reflux – usually no ascending infection



SHORT INTRAVESICAL URETER

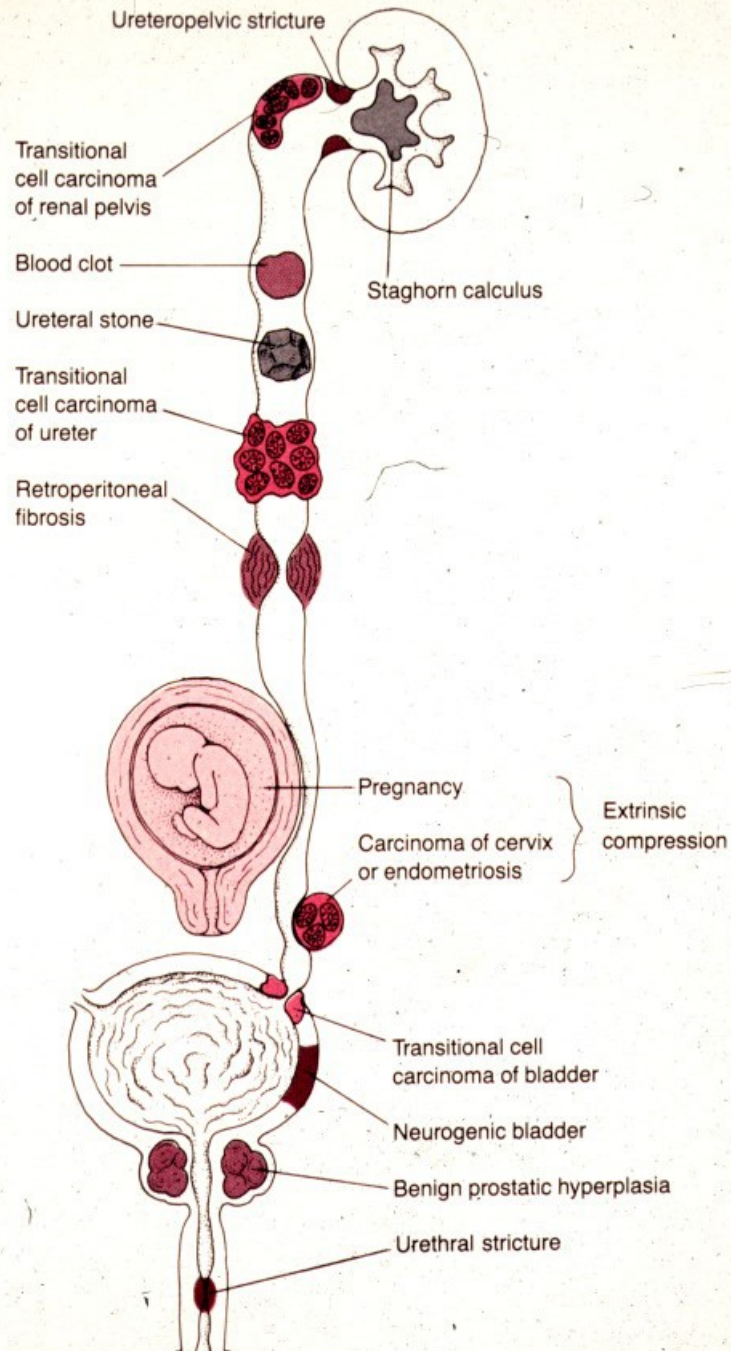


Obstruction causes

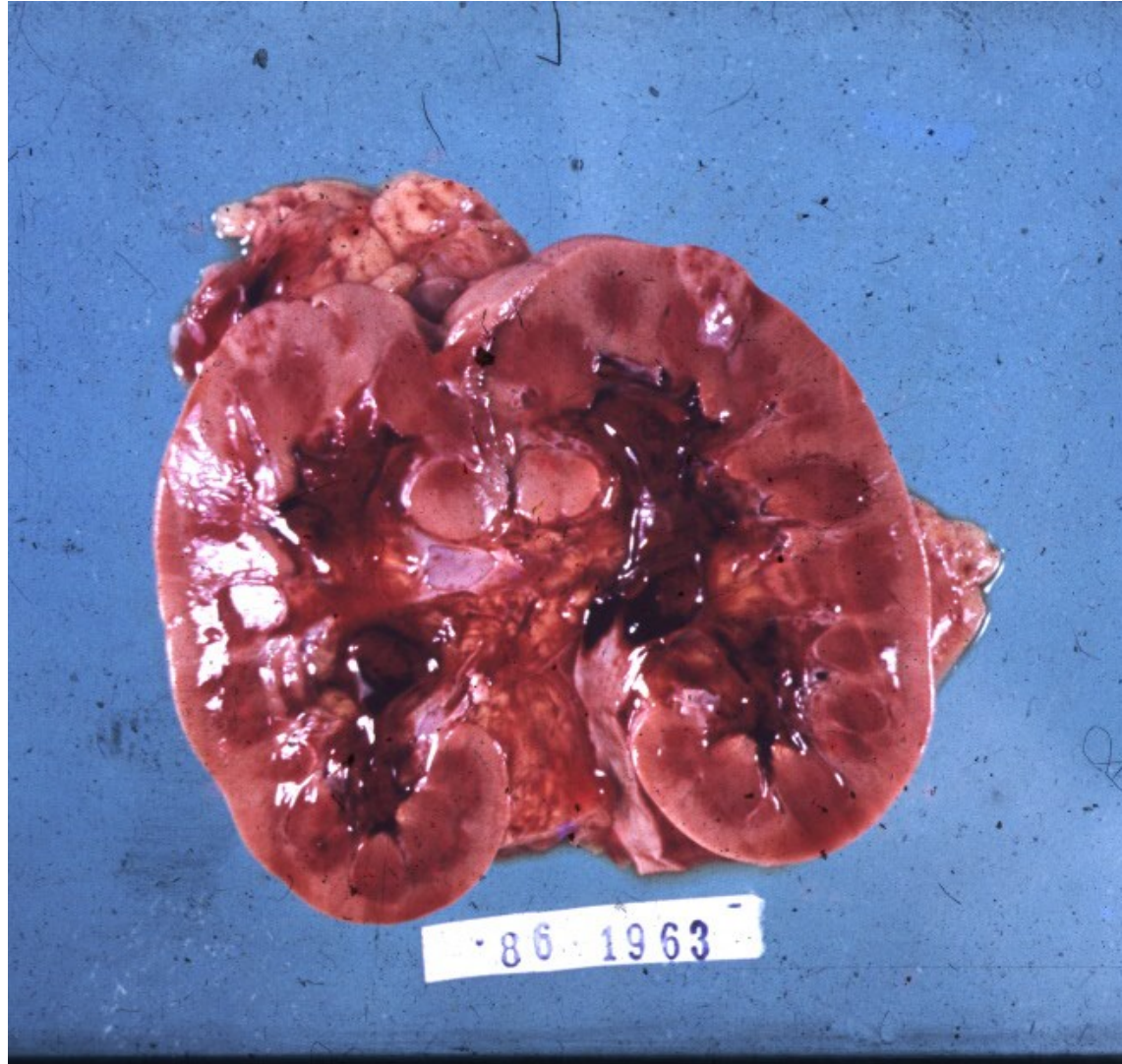
- **Intrinsic** – luminal obstruction (stone, blood clot, necrotic papilla, tumor or its part)
- **Wall stenosis or dysfunction** (inborn, inflammation, postinflammatory, tumor, ...)
- **Extrinsic** – external compression, some causes common for both sexes, some different

Obstruction causes

- **In males:** prostatic hyperplasia, prostatic ca, urethral stenosis, phimosis + complications
- **In females:** pregnancy, cervical ca (+ therapy), uterine myoma, ovarian tumor, uterine prolapse
- **in both:** chronic inflammation/fibrosis (retroperitoneal fibrosis), tumor (colorectal ca, LN,...), aortic aneurysm



Massive hematuria from renal calculi,
tumors, or papillary necrosis



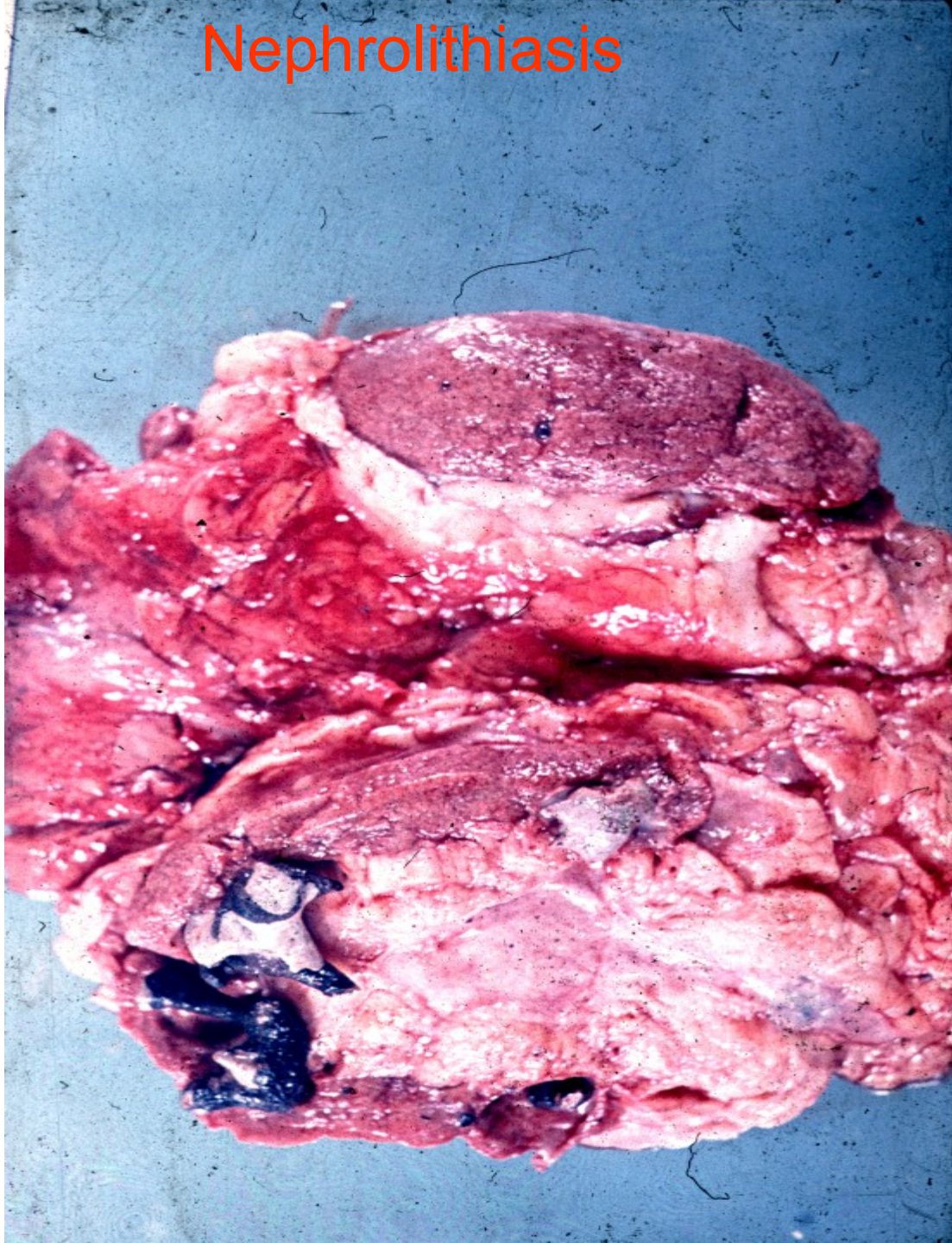
Urinary calculi

- Usually of renal origin
- Stones > 5 mm cannot pass into ureter
- Renal colic – pain + spasms during the passage of a stone along the ureter
- Chronic dull pain lumbal – lower pelvic region
- \uparrow risk of obstruction
- Repeated infection
- Epithelial transformation: squamous metaplasia

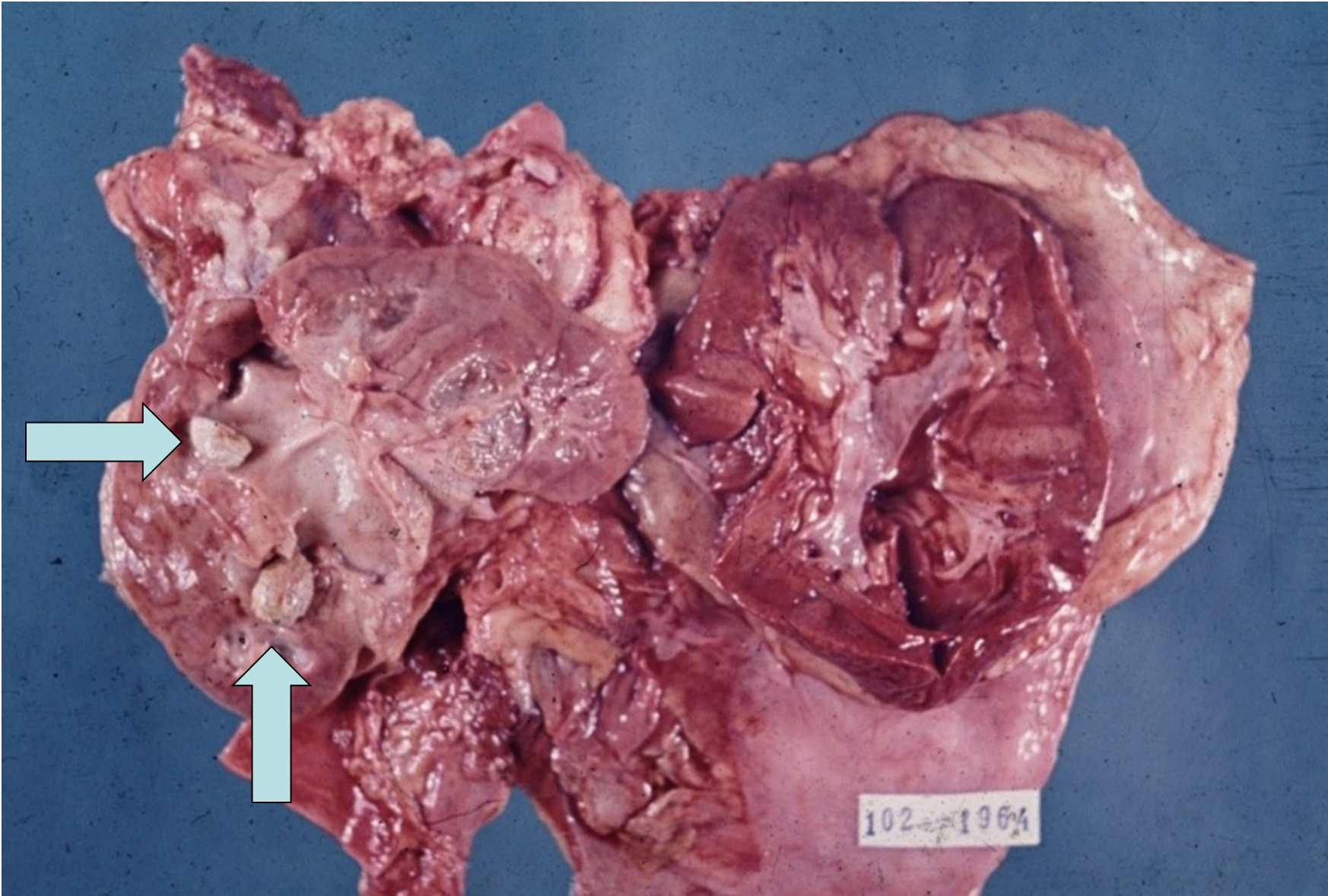
Urinary calculi

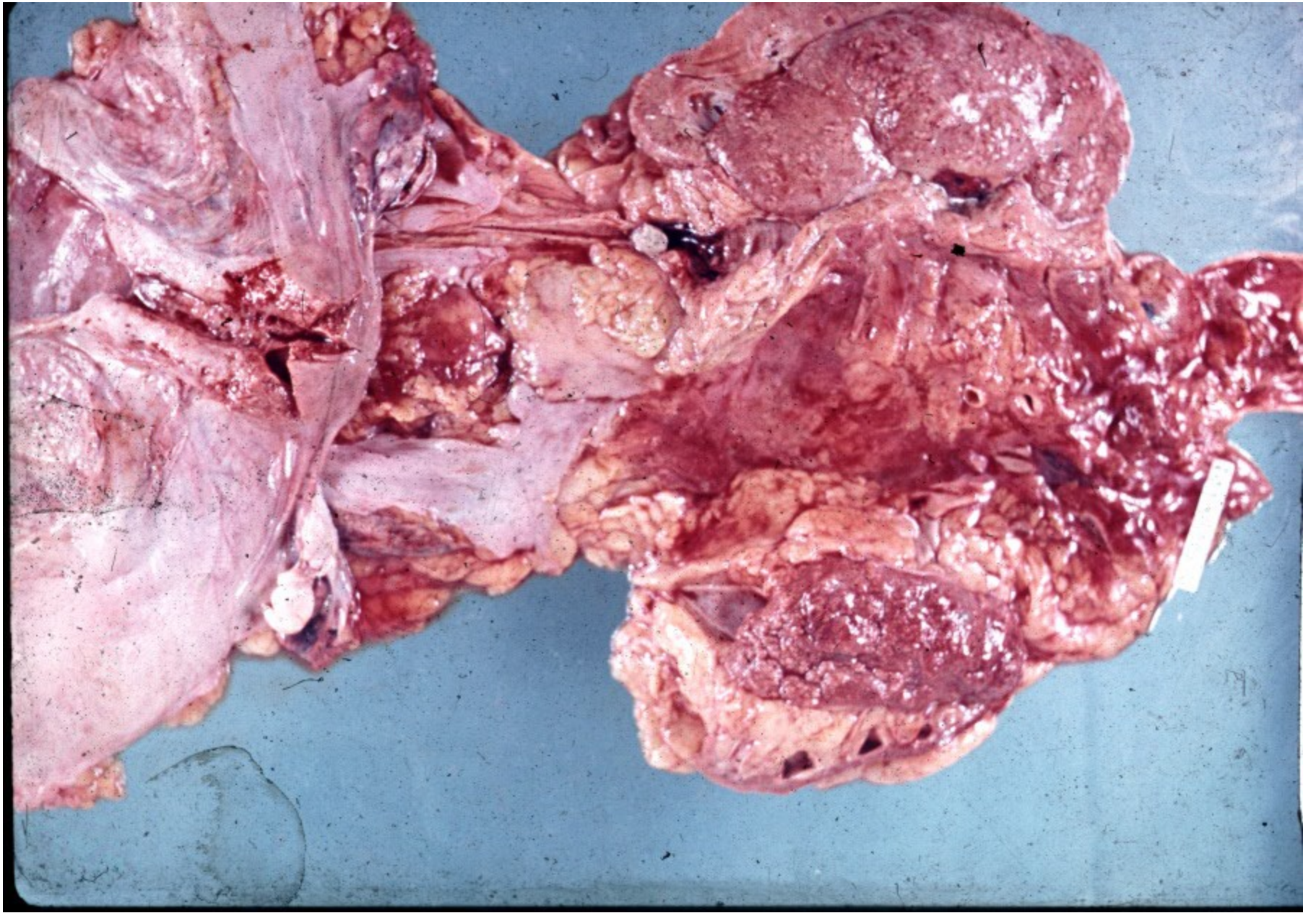
- **Calcium** containing stones: commonest, laid down in an acid urine.
- **Complex triple phosphate** stones: often associated with urinary infection, in an alkaline urine.
- **Mixture of uric acid and urate-uric acid** stones, 20% of patients with gout, in an acid urine. Pure uric acid stones radiolucent.
- **Cystine** stones: in primary cystinuria, important in childhood.

Nephrolithiasis

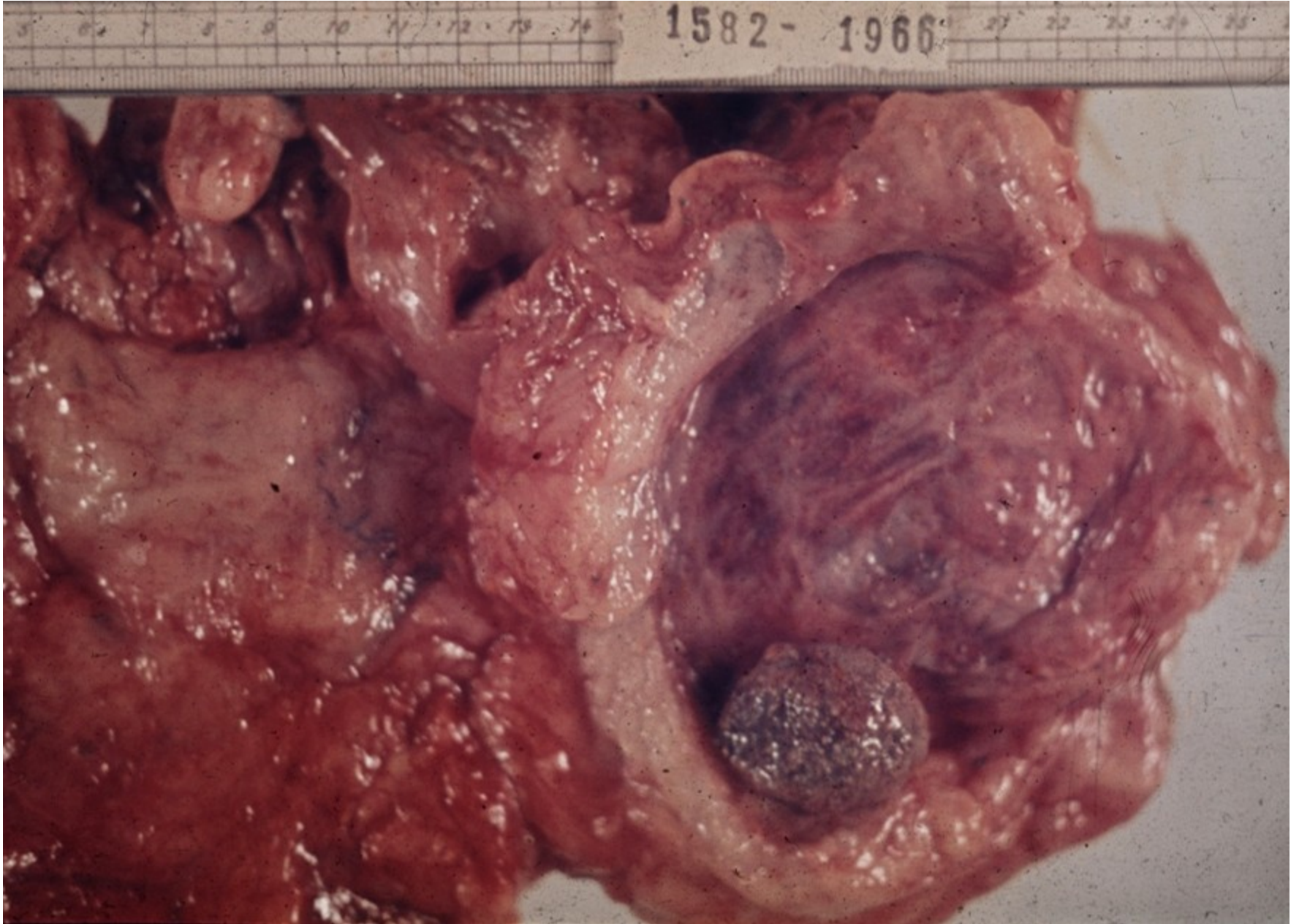

Pyelolithiasis in situ





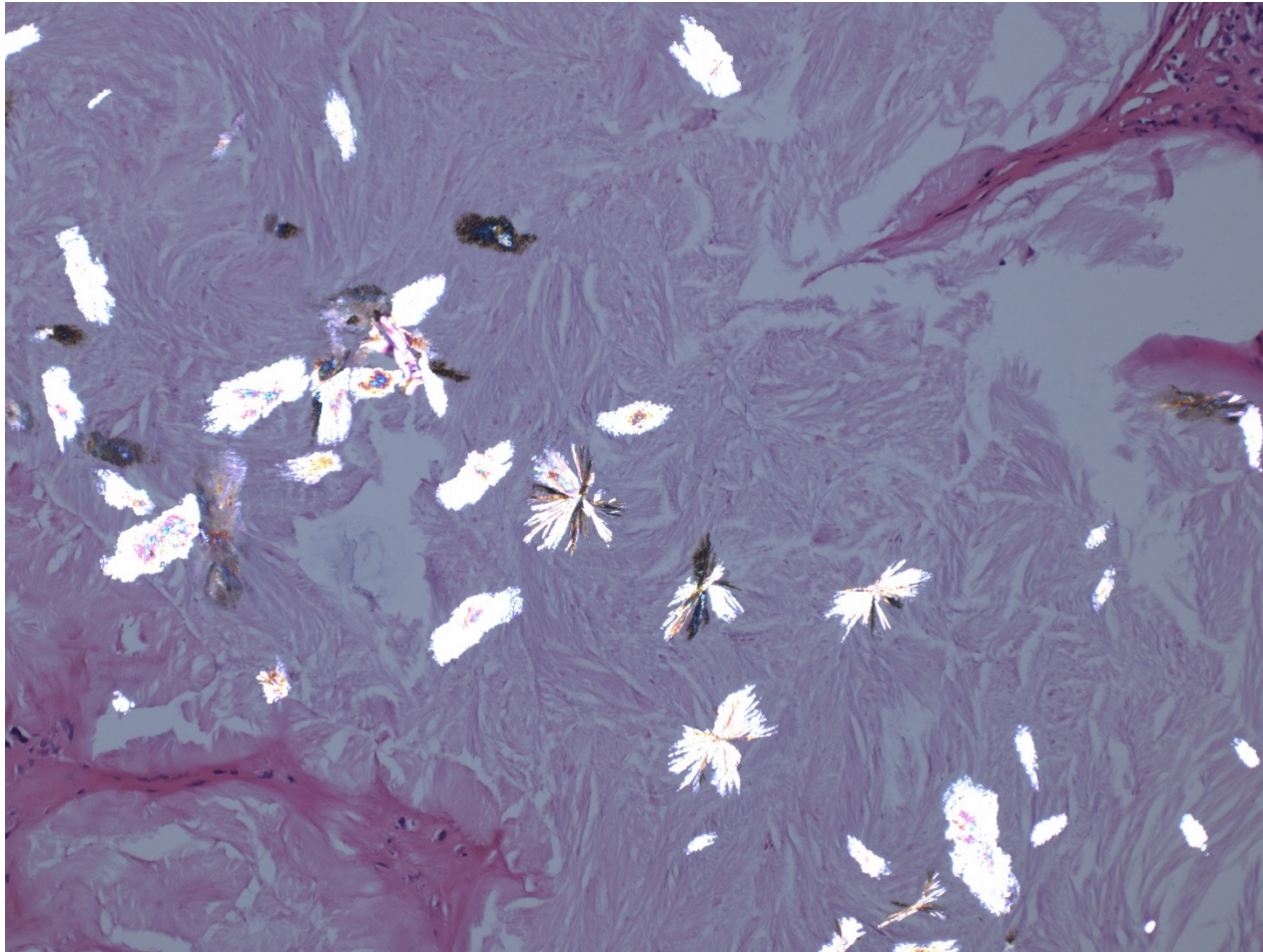
Urocytolithiasis




Urate nephropathy

- Hyperuricemic disorders (urate crystals formation) may lead to 3 forms of injury:
- **Acute urate nephropathy** in patients with haematologic malignancies, commonly during chemotherapy (extensive cell breakdown – release of nucleic acids – urate crystals in tubules – acute renal failure
- **Chronic urate nephropathy** – in gout. Urate crystals surrounded by foreign body giant cells, tubulo-interstitial nephritis
- **Urate stones**

Urate crystals



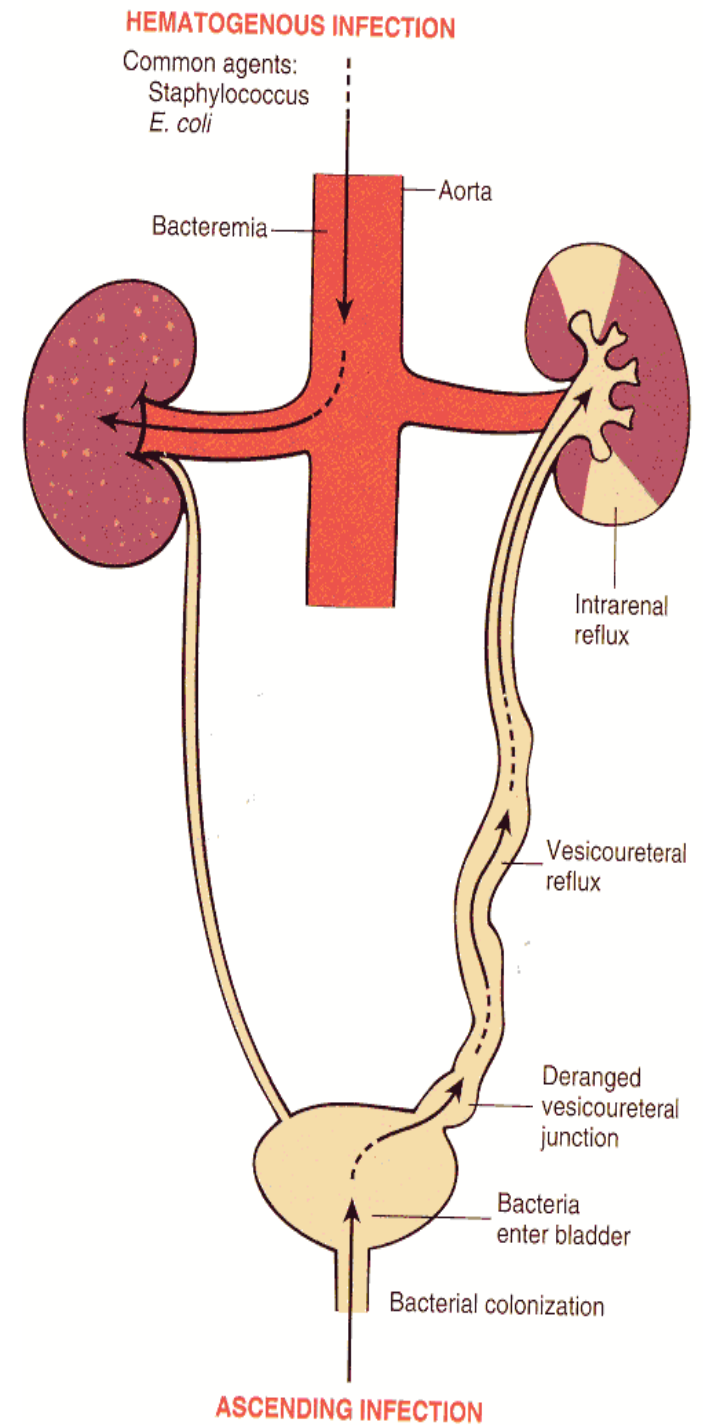
Urate crystals - polarization



Acute pyelonephritis

- Common purulent renal inflammation, bacterial infection by *Escherichia coli*, *Proteus*, *Klebsiella*, *Enterobacter*
- **Ascending** infection by urine reflux in urinary tract inflammation
- **Descending (haematogenous)** infection in septicaemia, rare, bilateral

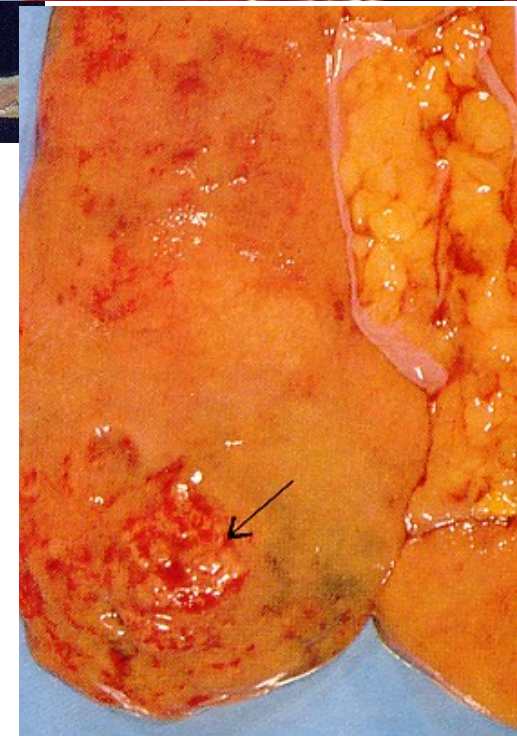
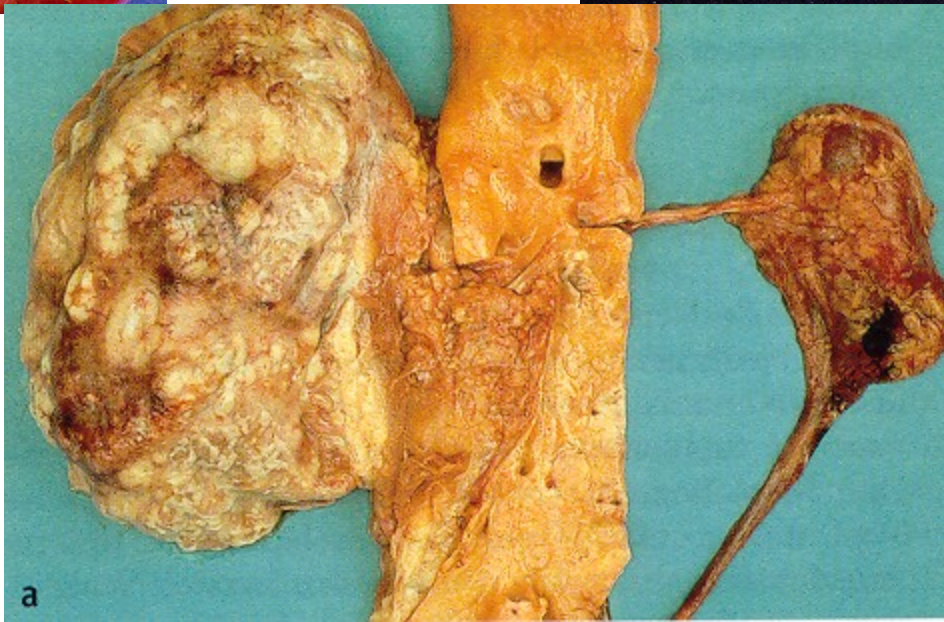
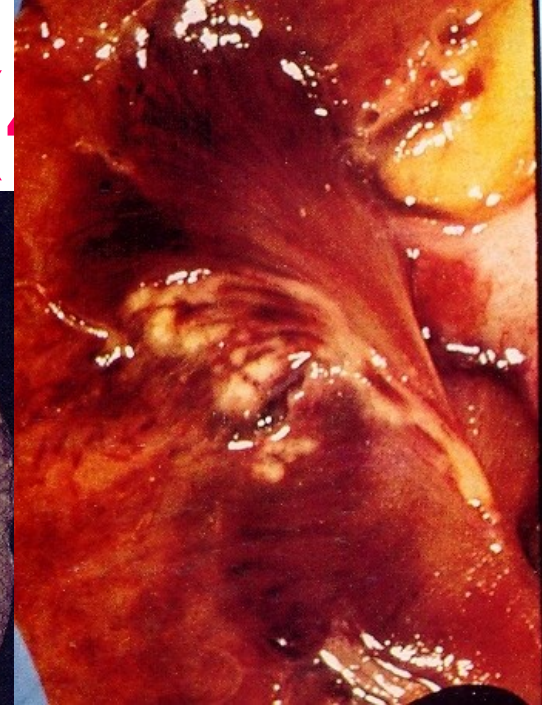
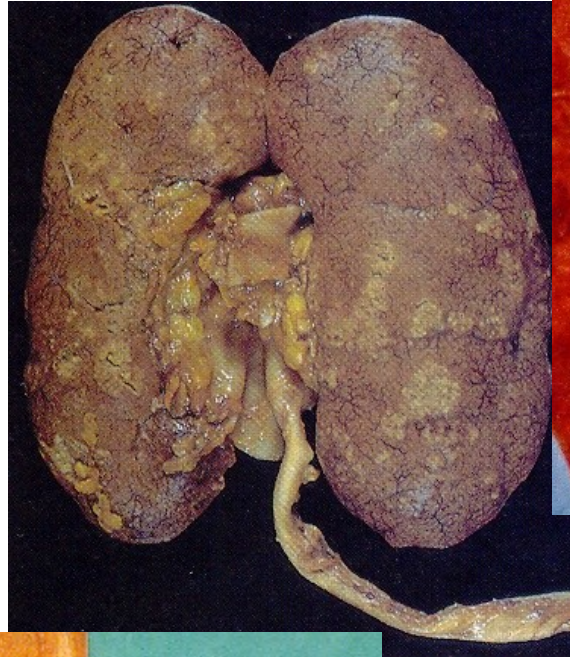
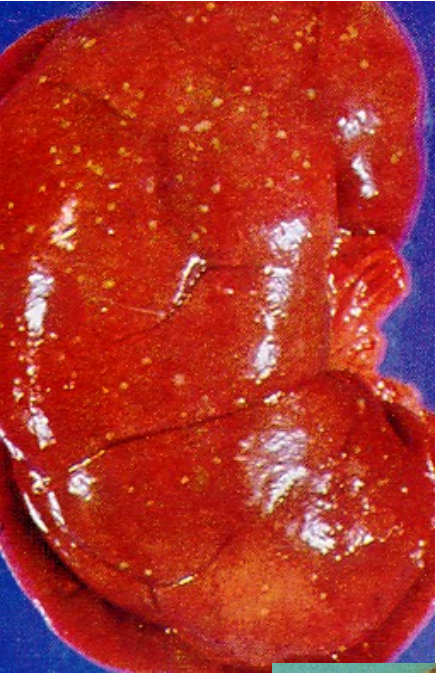Acute pyelonephritis



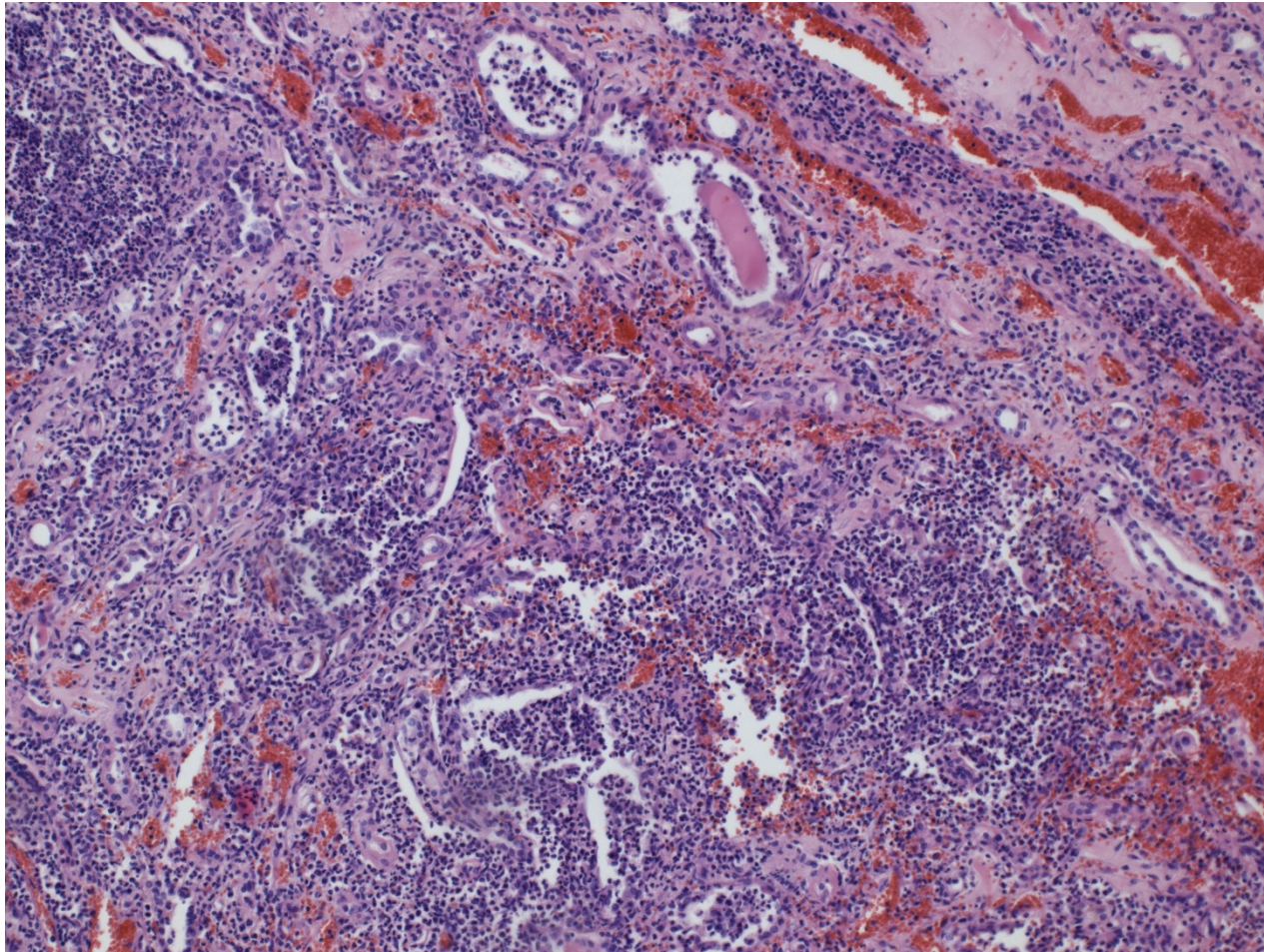
Acute pyelonephritis

- Facilitated by DM, gout, all causes of obstructive uropathy (e.g. nephrolithiasis, tumors, urinary tract anomalies incl. vesicoureteric and intrarenal reflux)
- Instrumental interventions (cathetrization, cystoscopy)
- GROSS: enlarged kidney, cortical and medullary abscesses
- MICRO: purulent neutrophilic exudate in tubules and interstitium, oedema, abscess formation, usually pus in renal pelvis

Acute pyelonephritis (A)



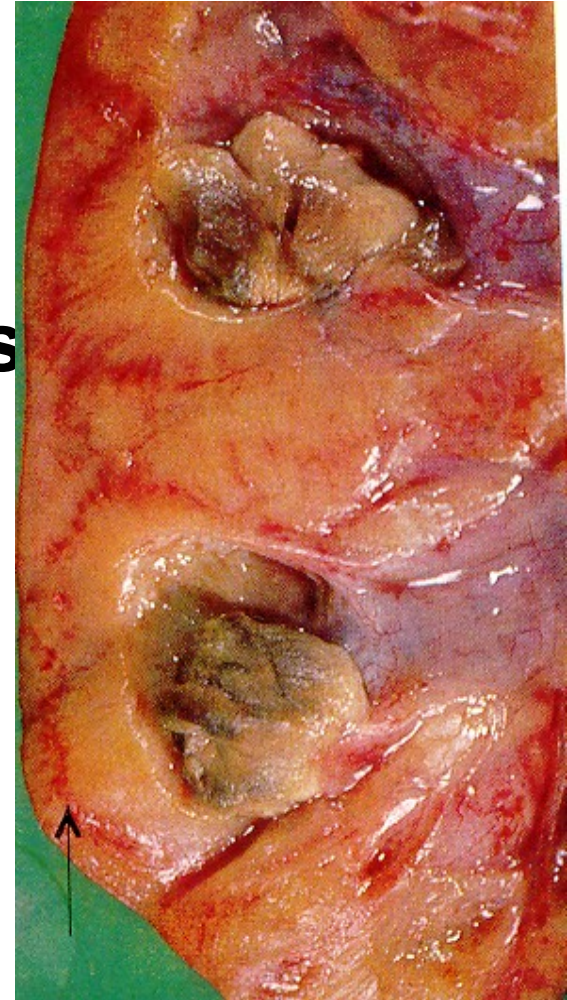
Acute pyelonephritis



Acute pyelonephritis - complications

- **Pyonephros**
- **Papillary necrosis** in diabetics
- **Peri- and paranephritic abscess**
- **Sepsis**

**Papillary
necrosis**



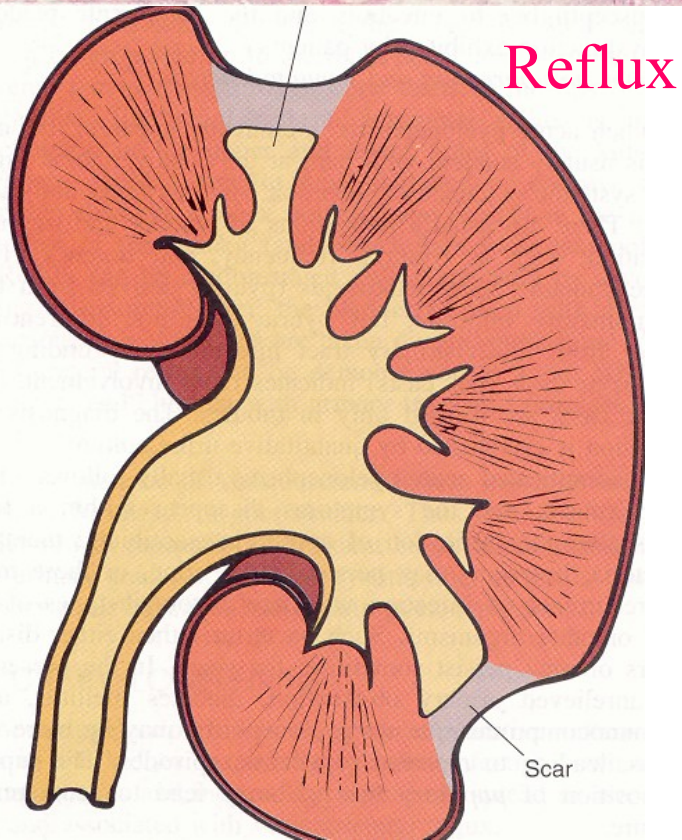
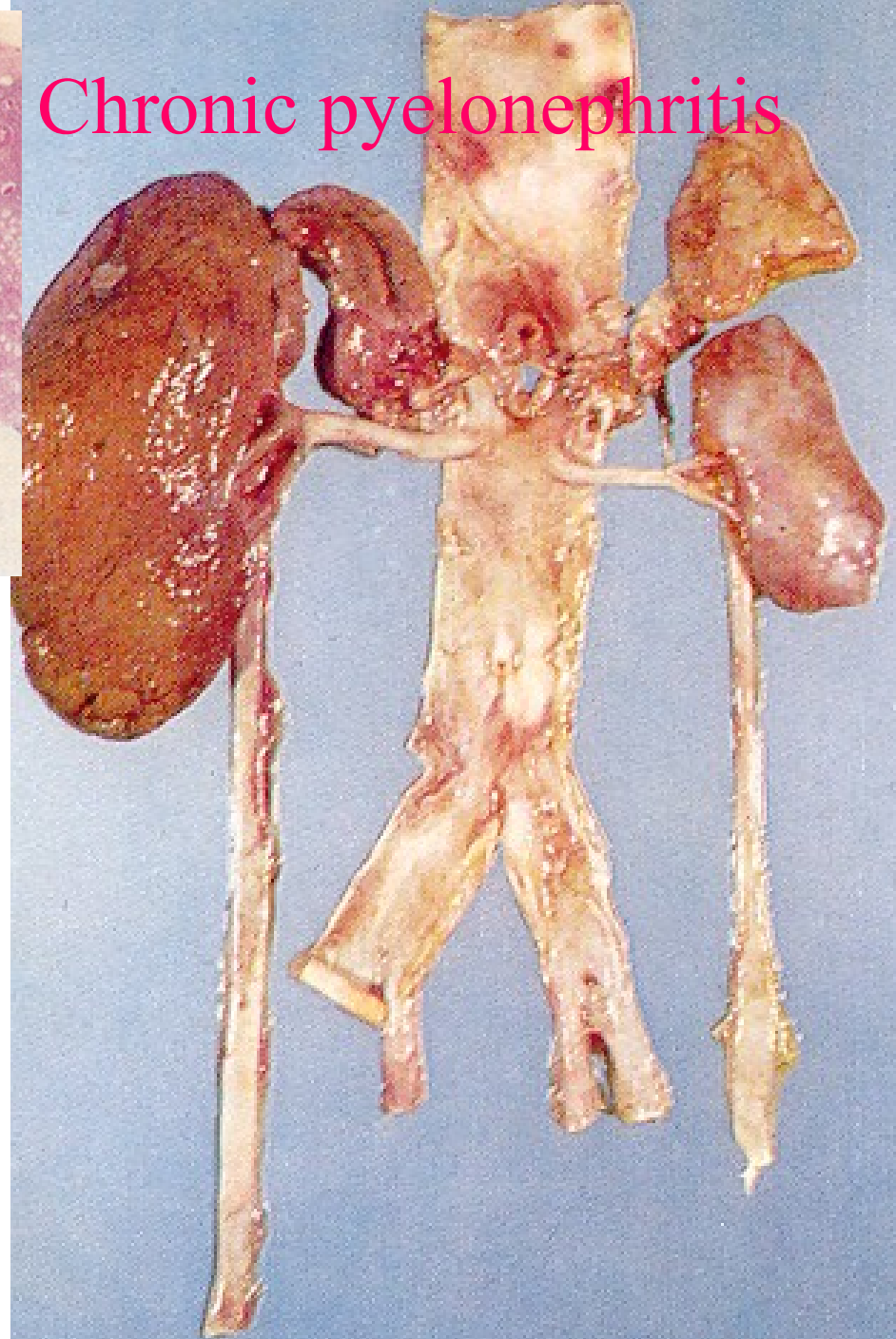
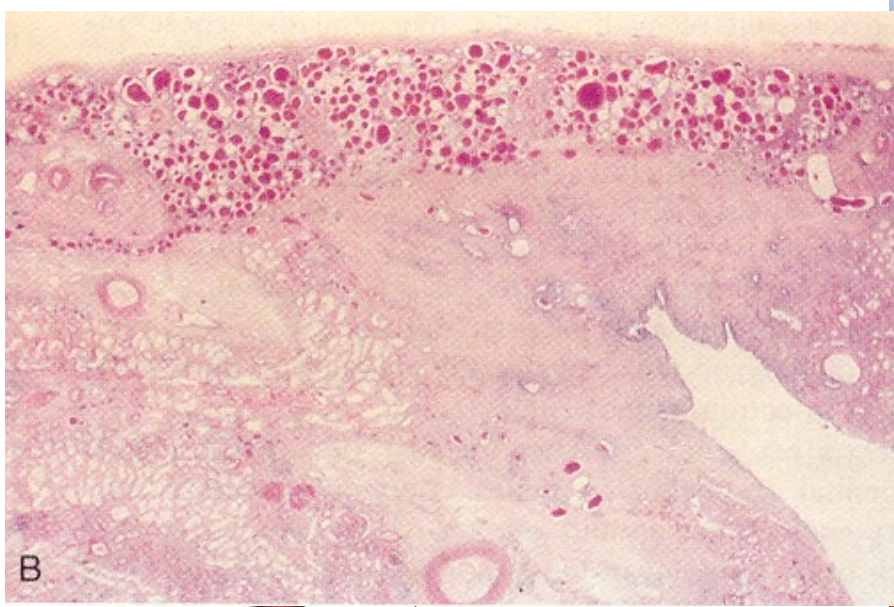
Chronic pyelonephritis

- Uni- or bilateral chron. tubulo-interstitial renal inflammation with scarring
- 10-20% end-stage kidney
- **Obstructive PN** - repeated infections
- **Reflux nephropathy –vesicoureteric** and/or **pelveorenal reflux** (from lower and upper pole calyces into renal parenchyme)

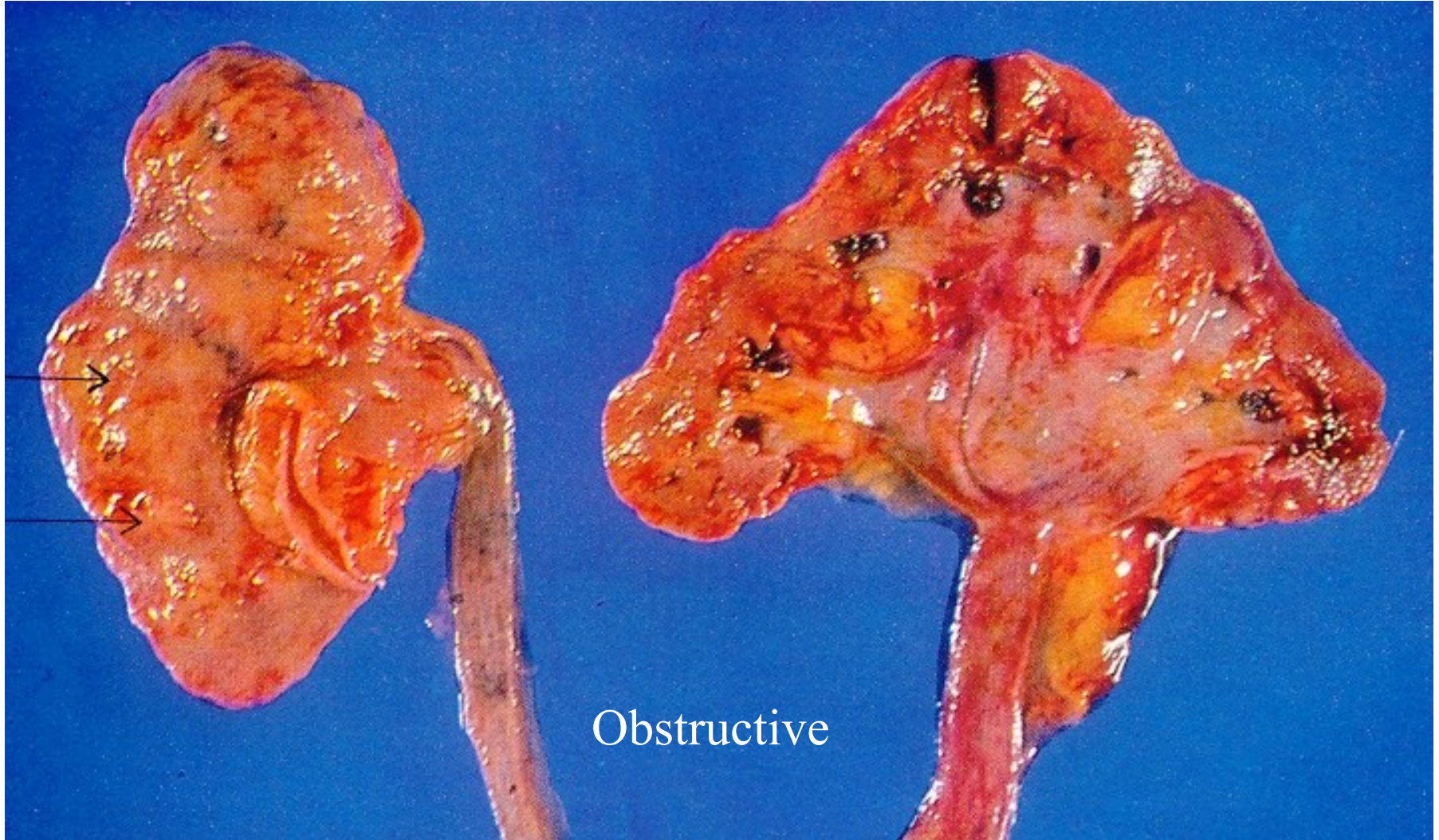Chronic pyelonephritis

- Thin cortex /medulla, superficial flat scars, granulation
- Dilated renal pelvis, greyish mucosa
- Loss of microscopic architecture
 - glomerular hyalinisation→ tubular atrophy + dilatation („thyroidisation“)
 - interstitial fibrosis
 - inflammatory infiltrate

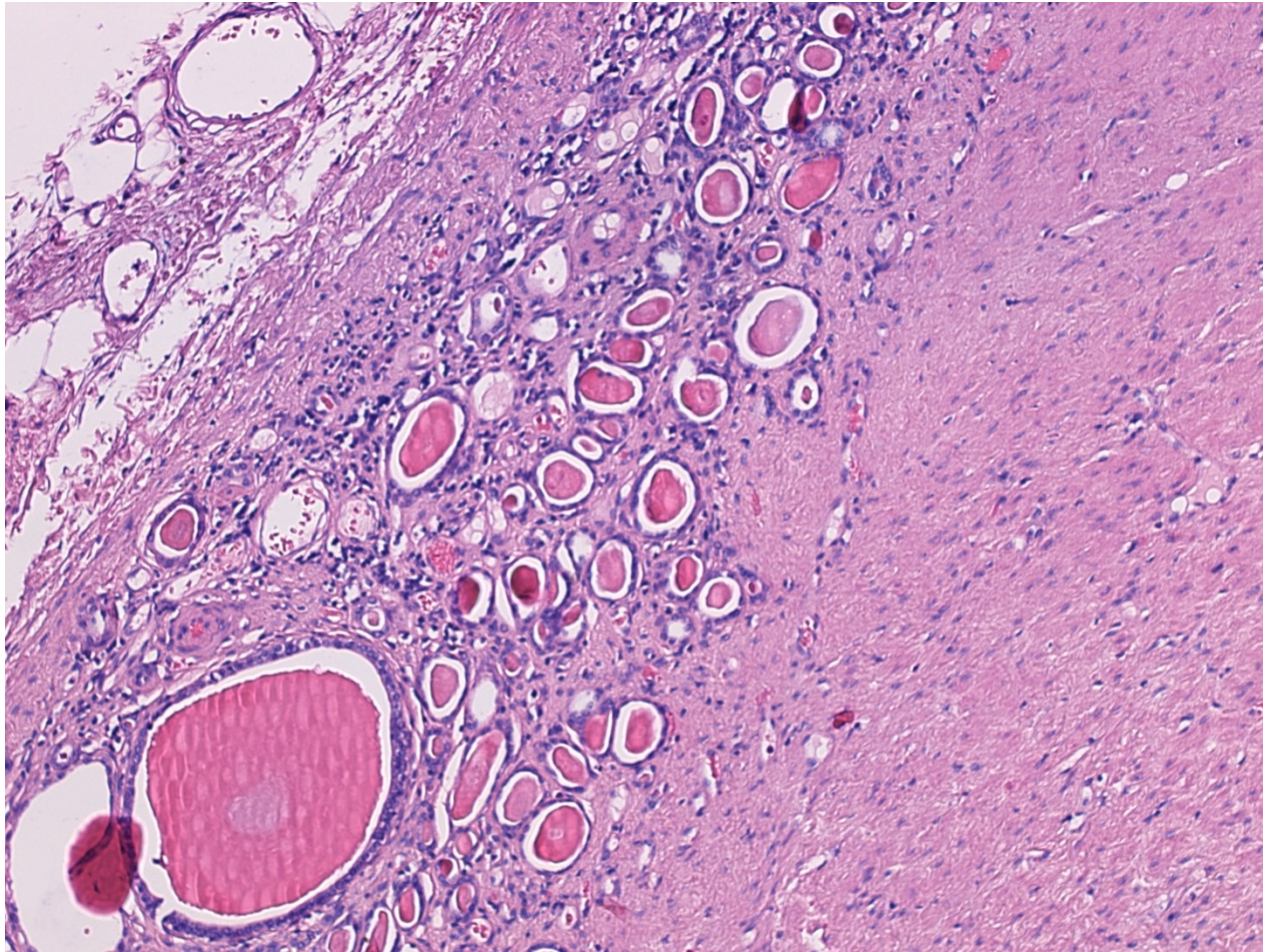
Chronic pyelonephritis



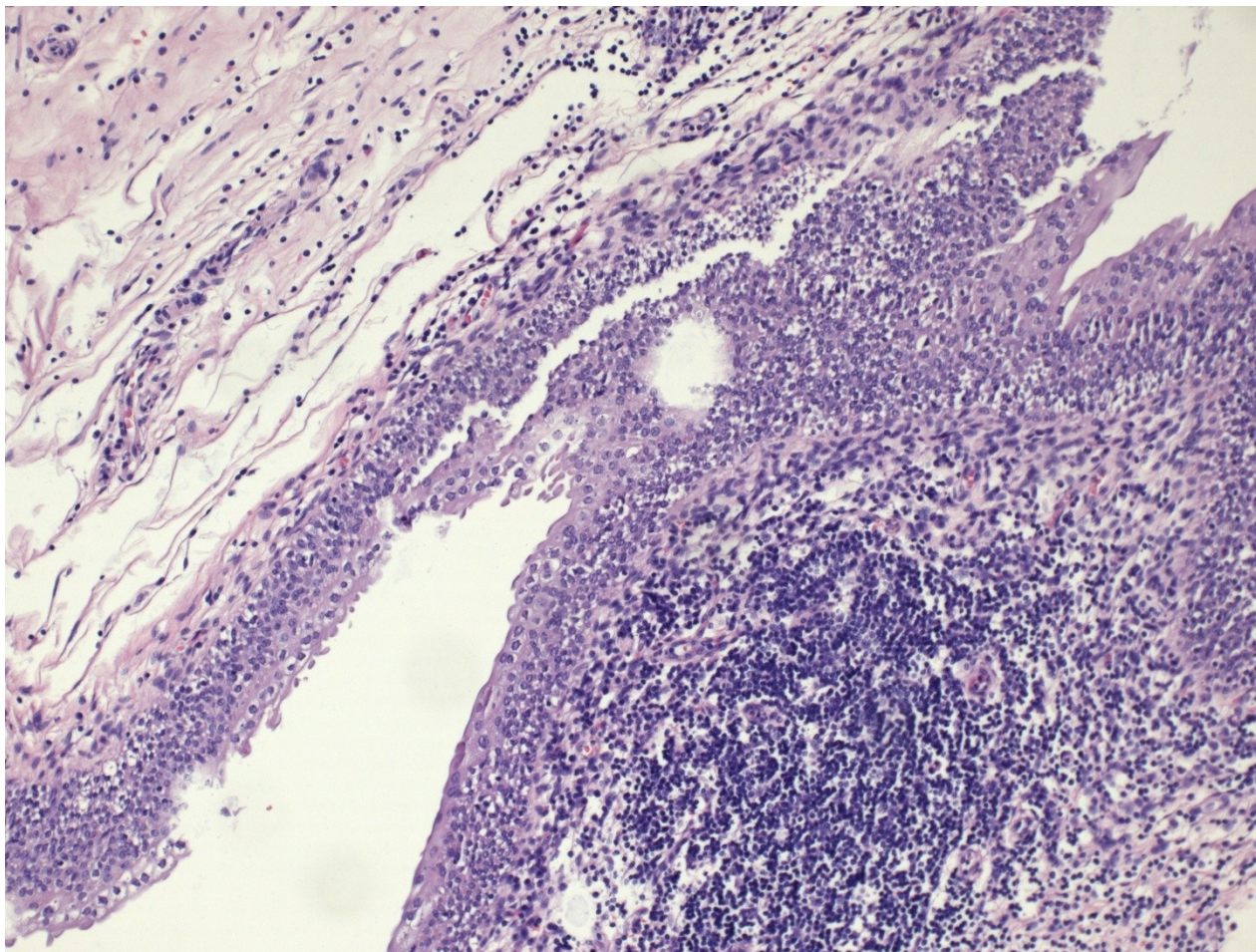
Chronic pyelonephritis



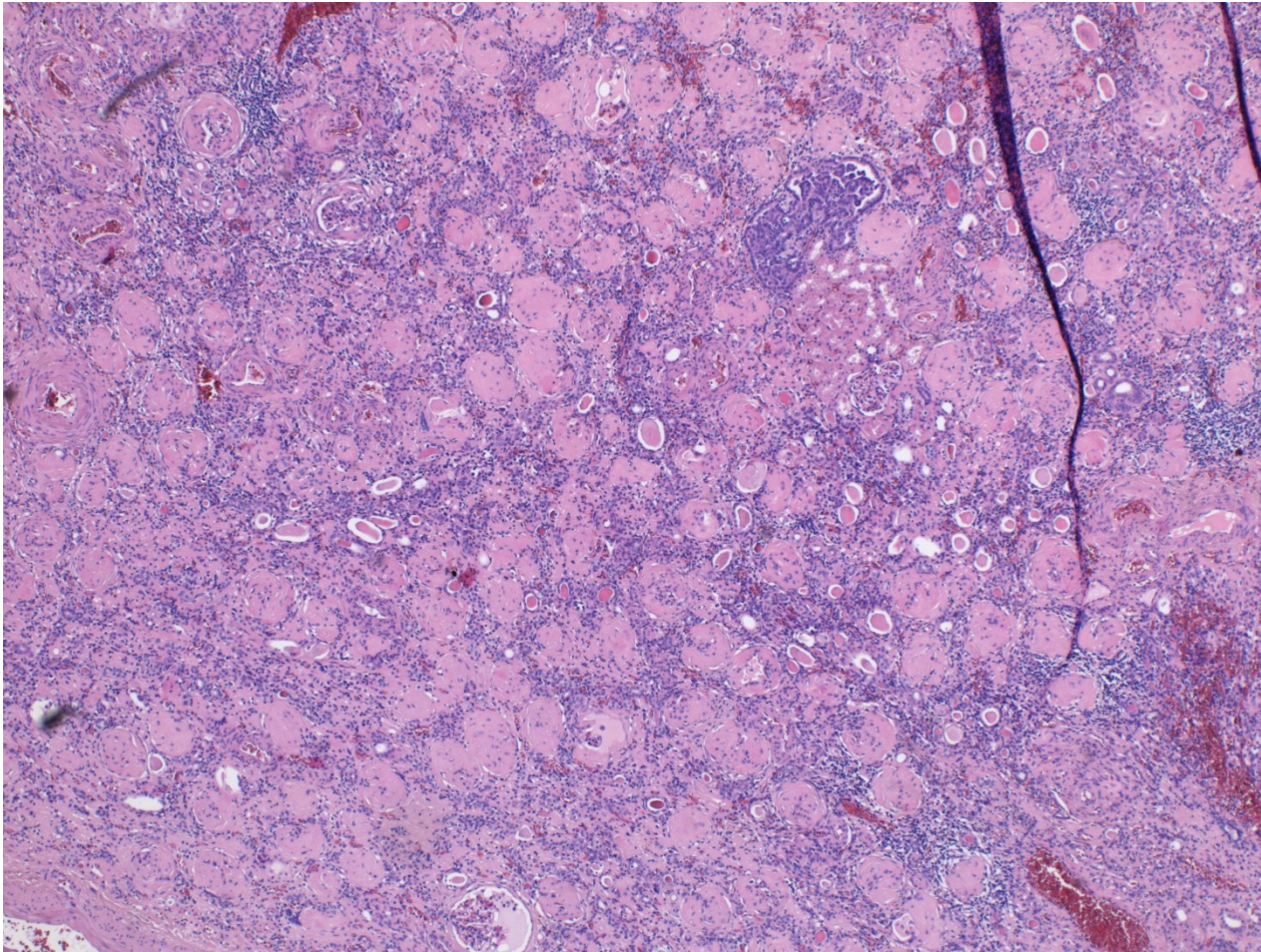
Chronic pyelonephritis



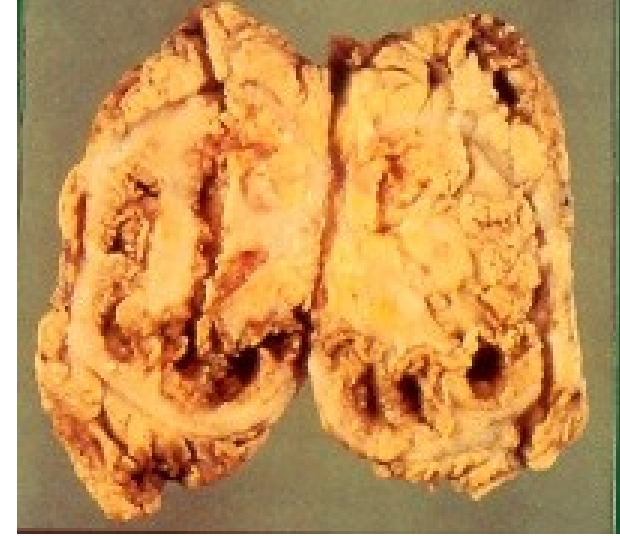Chronic pyelitis



Kidney – end-stage



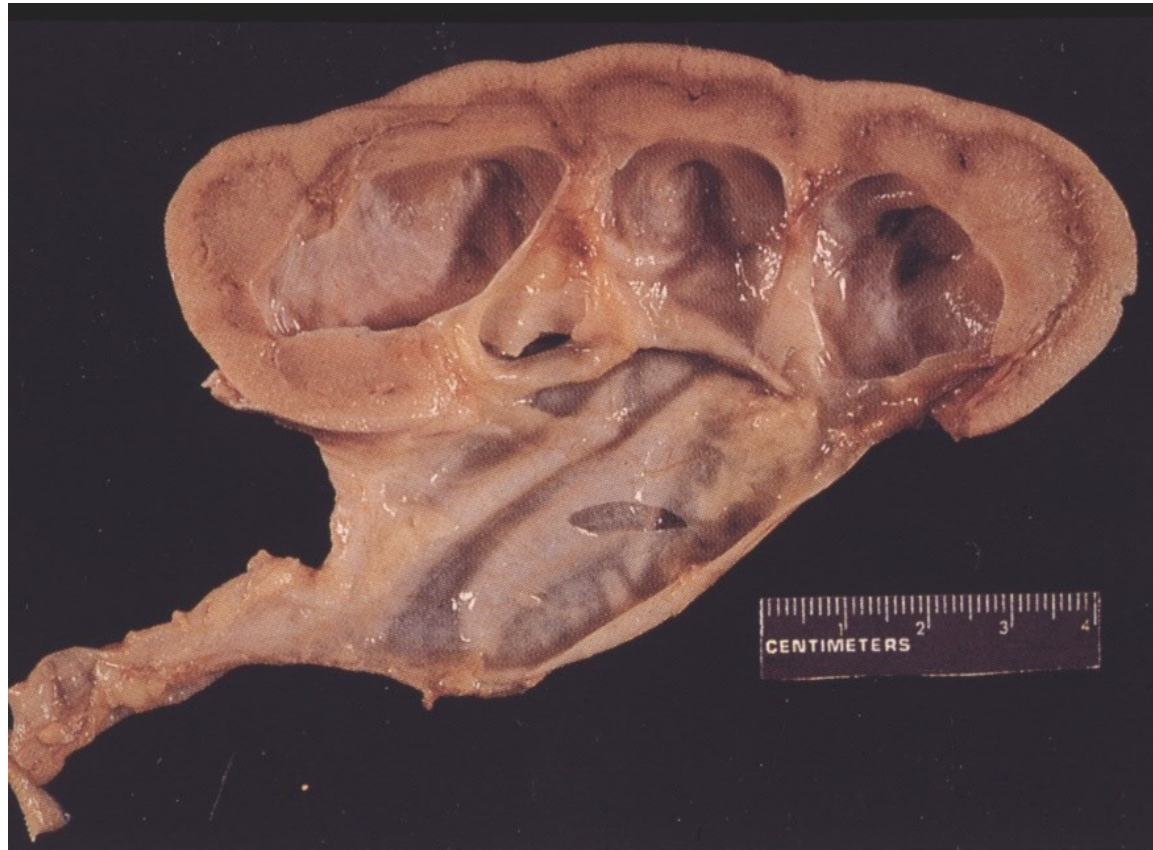Xanthogranulomatous pyelonephritis



- Uncommon form of chronic pyelonephritis with accumulation of foamy macrophages in interstitium
- Yellowish focal lesions in macroscopy, diff. dg. x renal carcinoma, renal TB

Hydronephrosis, hydroureter

Renal tissue atrophy, renal insufficiency



Tumors of the renal pelvis

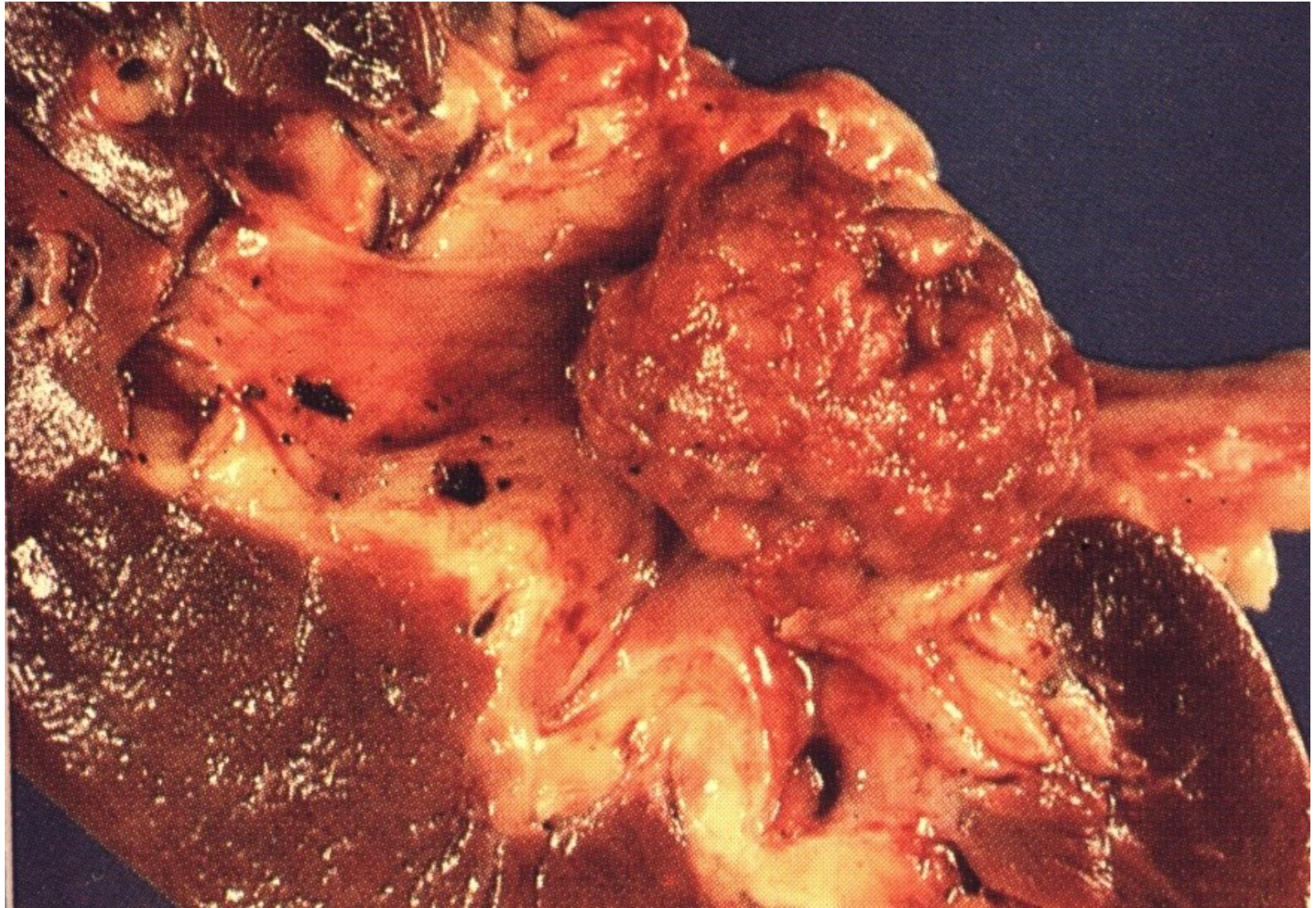
Primary: transitional cell neoplasia, mostly papillary transitional cell carcinoma (invasive, non-invasive)
Rarely other types of carcinoma (squamous cell, neuroendocrine, adenocarcinoma)
Other types (mesenchymal, melanoma, ...)

Secondary: local progression from the kidney
metastasis

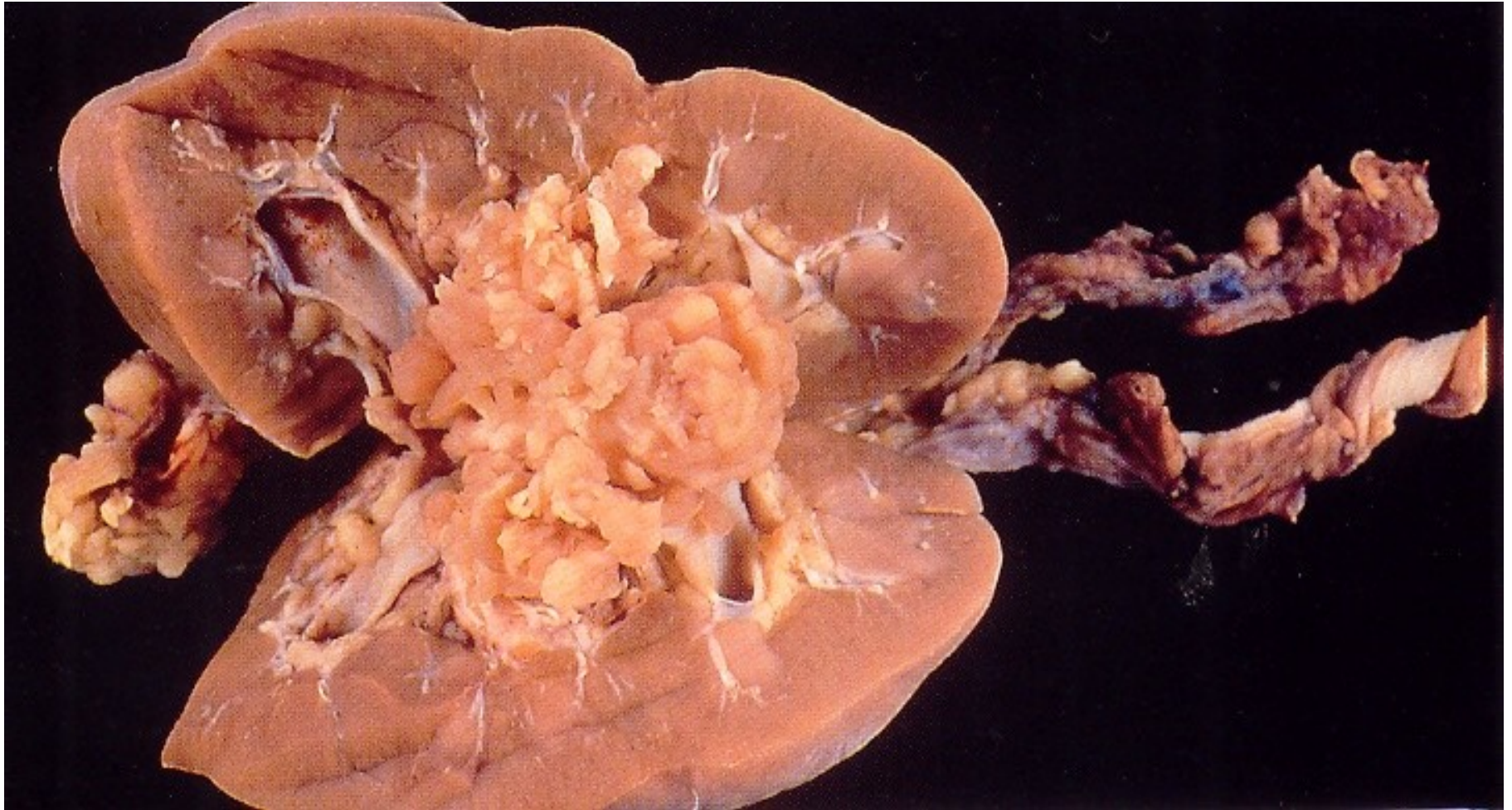
Transitional cell ca

- in pelvis or ureter less common than bladder
- possible multiple dysplastic foci
- histopathology similar to bladder ca
- possible perigenous seeding
- invasion into kidney and surrounding tissues
- diff. dg. x renal cell ca

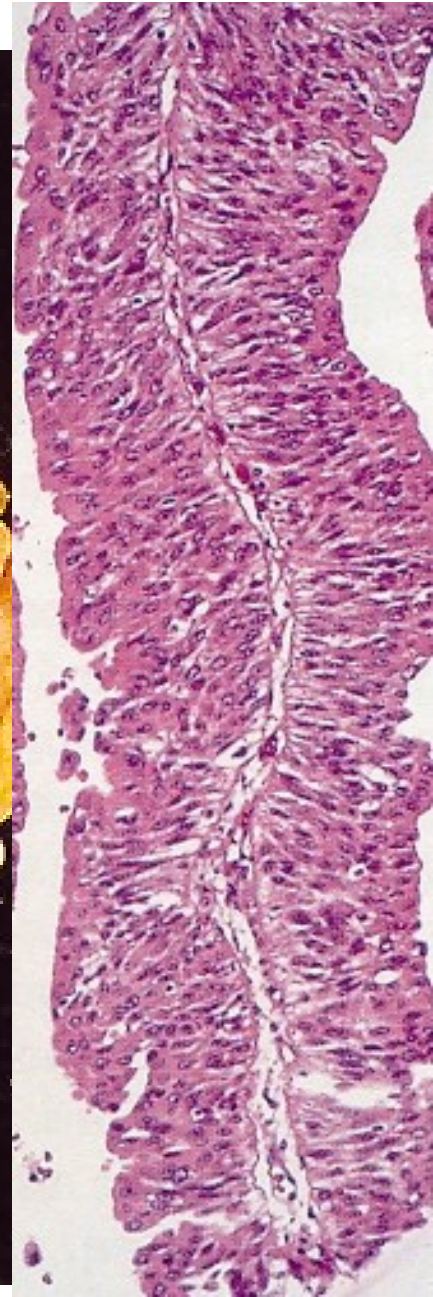
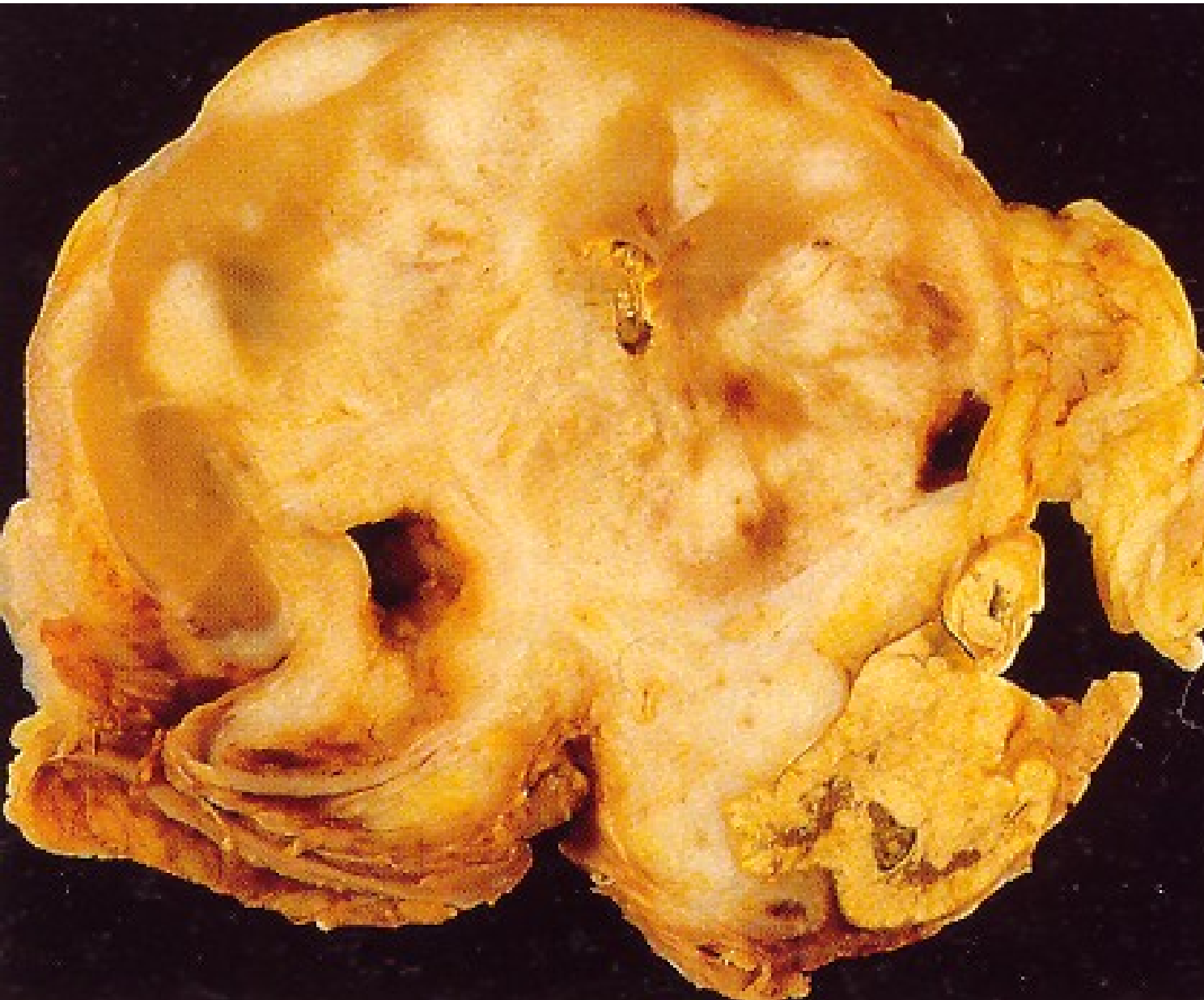Invasive urothelial carcinoma – renal pelvis



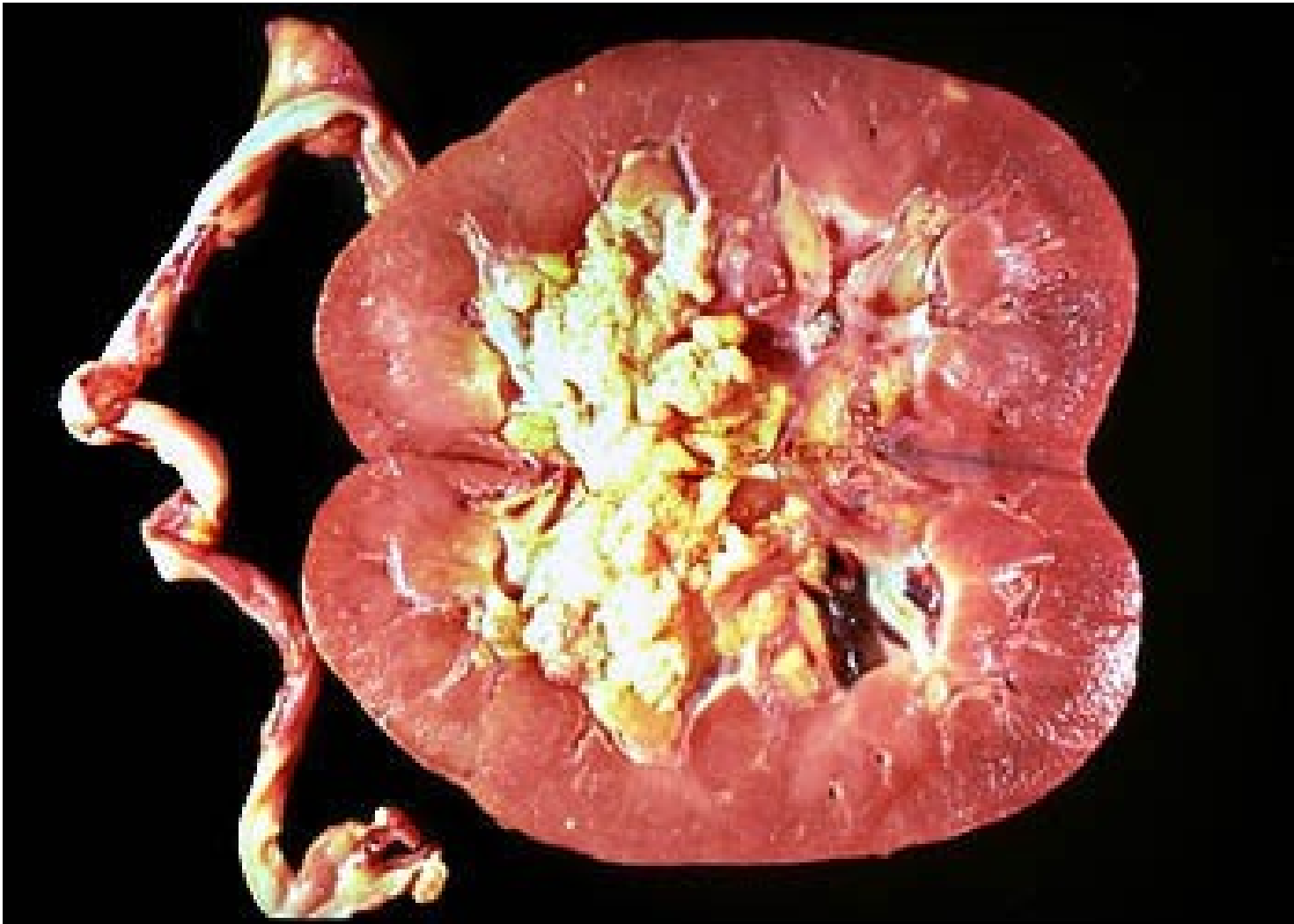Transitional cell ca of the renal pelvis



Transitional cell ca of the renal pelvis



Concurrent urothelial ca of pelvis + bladder possible



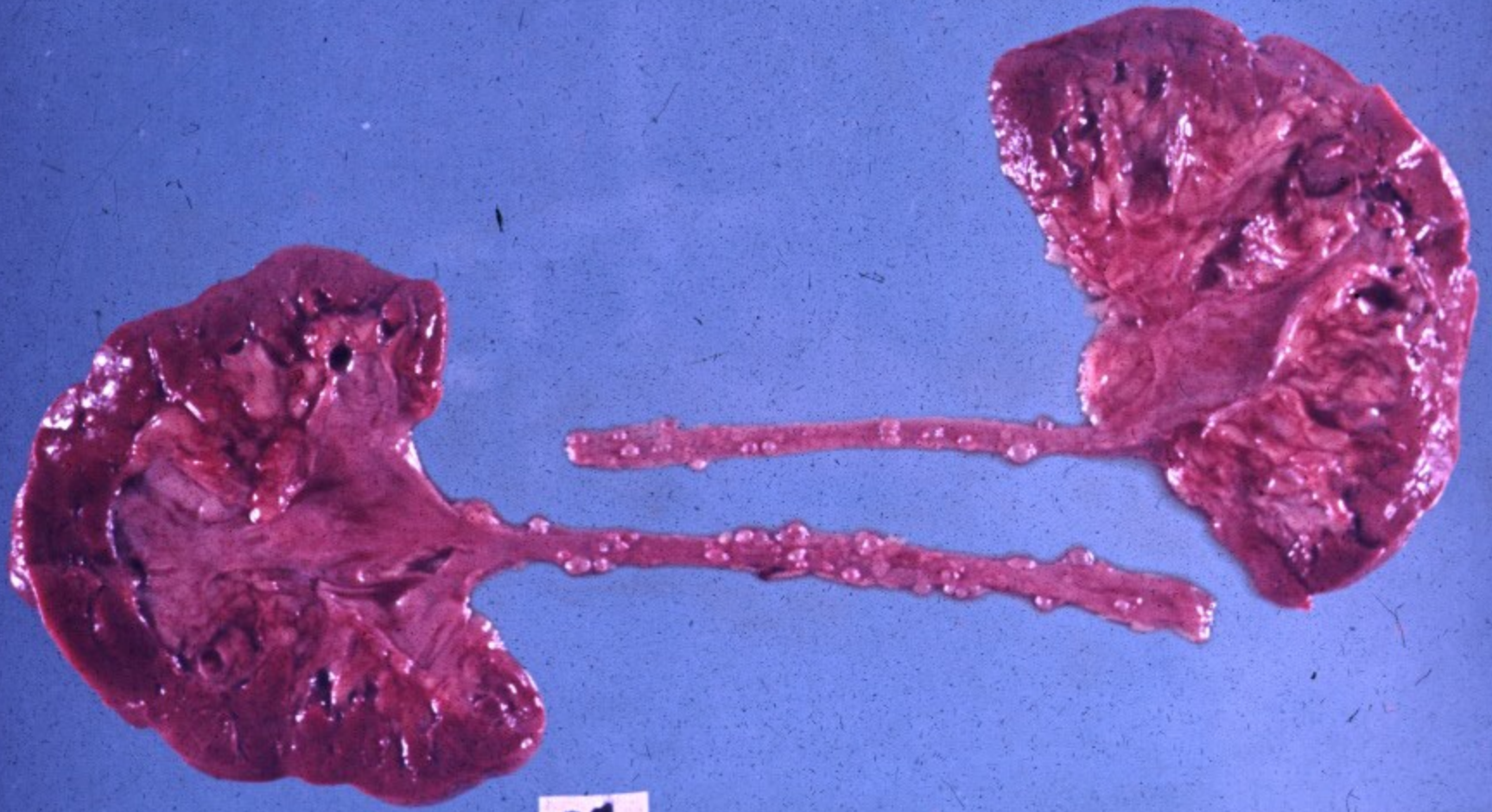
Ureter

- **congenital anomalies** (double/bifid ureter, obstruction of the ureteropelvic junction, lesion of the vesicoureteric junction, diverticula)
- **obstruction**
- **inflammation** (acute, chronic incl. ureteritis cystica - preneoplastic)
- **neoplasia and pseudotumorous lesions** (transitional cell tu, squamous cell ca, fibroepithelial polyp, etc.)

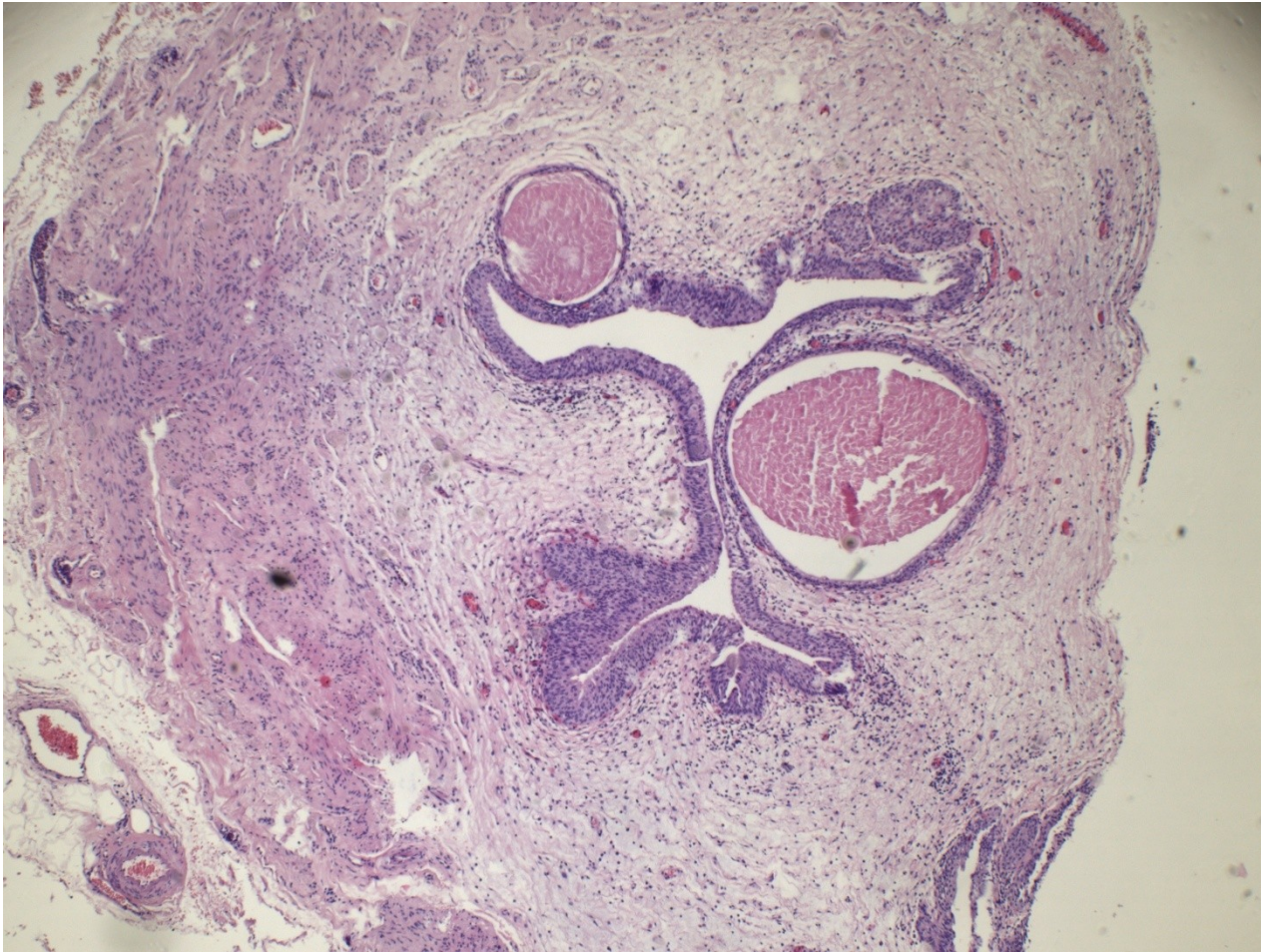Ureteritis cystica

- Special form of chronic ureteritis
- Numerous cysts in the ureteral mucosa, solid or cystic nests of transitional or metaplastic glandular epithelium.
- Terminal stage of chronic inflammations
- ↑ risk of ca

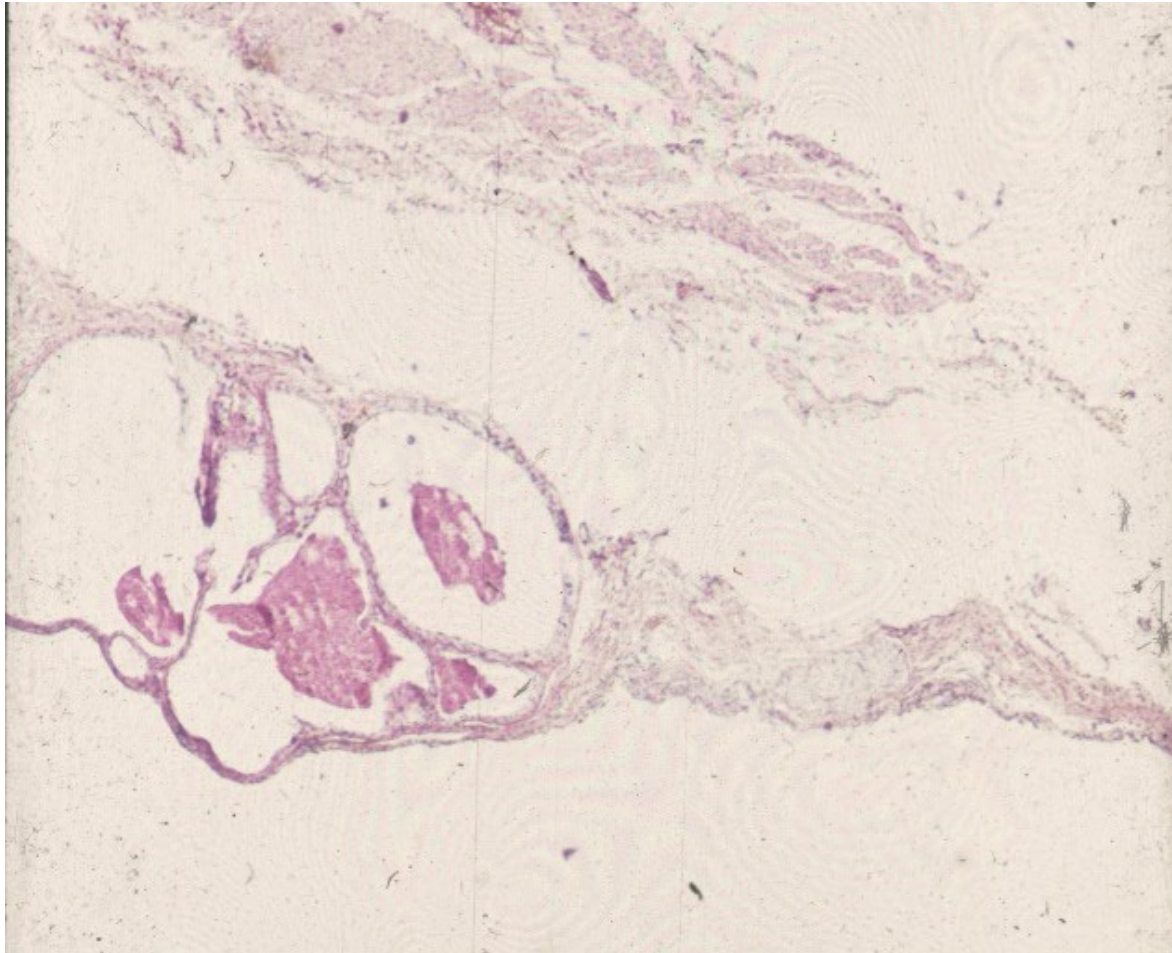
Chronic ureteritis cystica



Cystic ureteritis



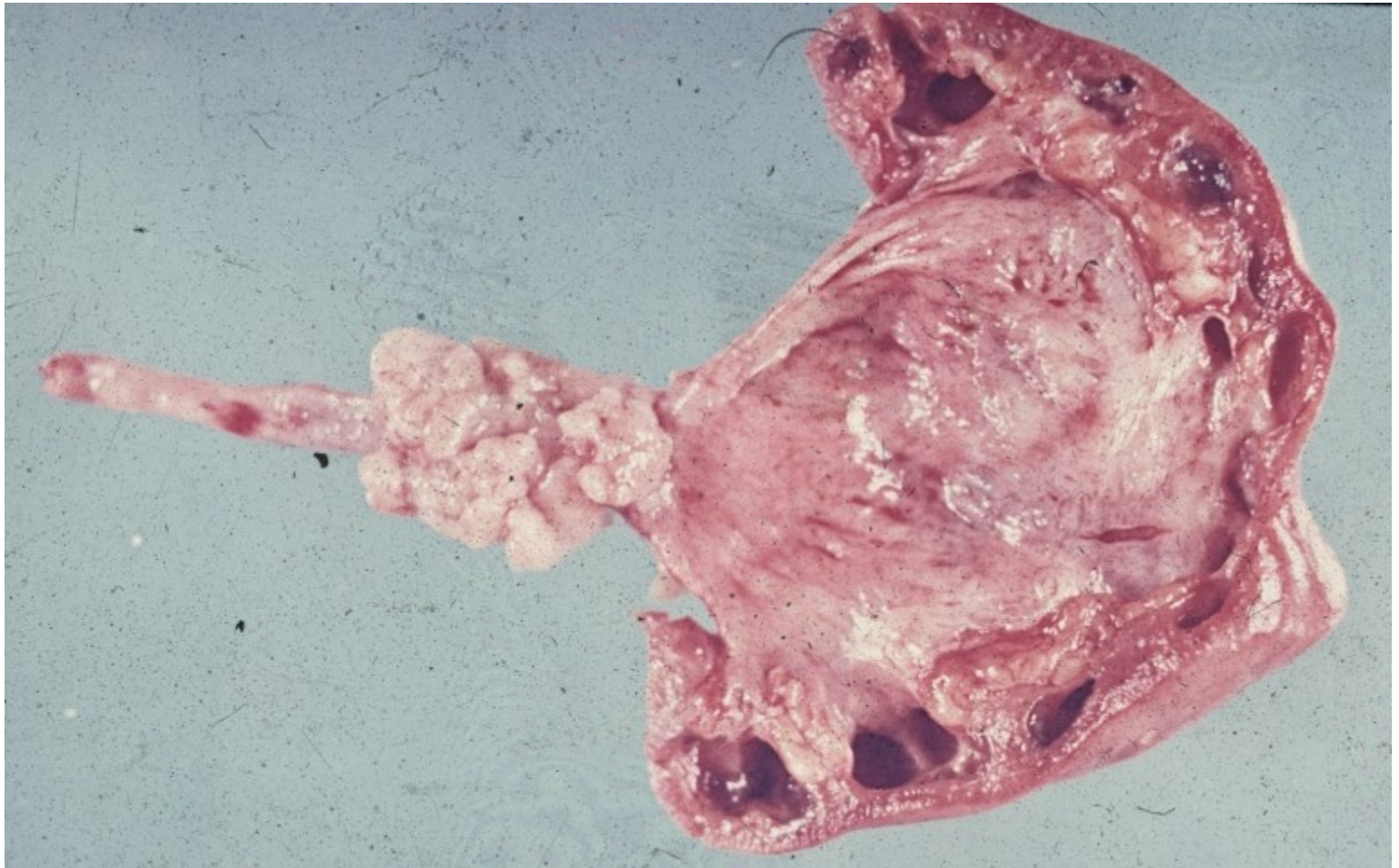
Cystic ureteritis



Tumors, tumor-like lesions

- **Fibroepithelial polyp**: small, loose stroma + epithelium
- **Benign**: rare, mesenchymal tumors
- **Malignant**: transitionall cell carcinoma
progression of malignancy from surrounding tissues

Transitional cell carcinoma of the ureter



Urinary bladder

- **congenital anomalies** (exstrophy, diverticula, persistent urachus)
- **cystitis** (acute, chronic, special forms – malakoplakia, tbc, schistosomiasis, etc.)
- **metaplasia** – usually in cystitis (c. cystica, c. glandularis), squamous m.- leukoplakia
- **tumors and pseudotumorous lesions**
- **miscellaneous** (calculi, fistulae, prolapse)

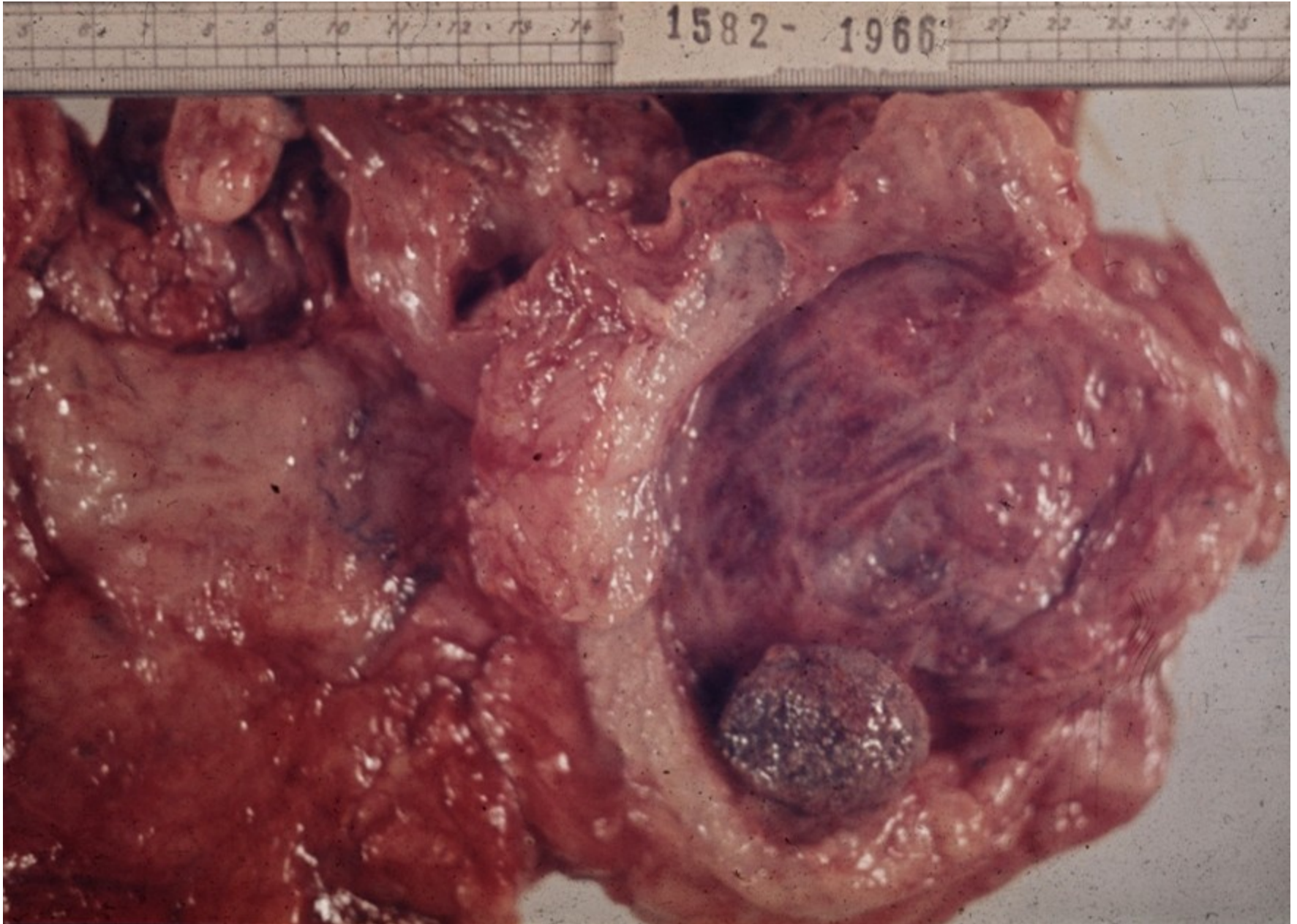Exstrophy

- nonclosure of anterior bladder + abdominal wall incl. missing layers
- bladder may be opened to the outside
- ascending renal infection
- epithelial metaplasia, ↑ risk of ca
- commonly in combination with other congenital anomalies

Diverticula

- **Congenital**: uncommon, solitary. Wall defect; intrauterine urinary obstruction
- **Acquired**: multiple. Most common in prostatic hyperplasia, concurrent with cystitis
- ↑ risk of infection, stones, perforation

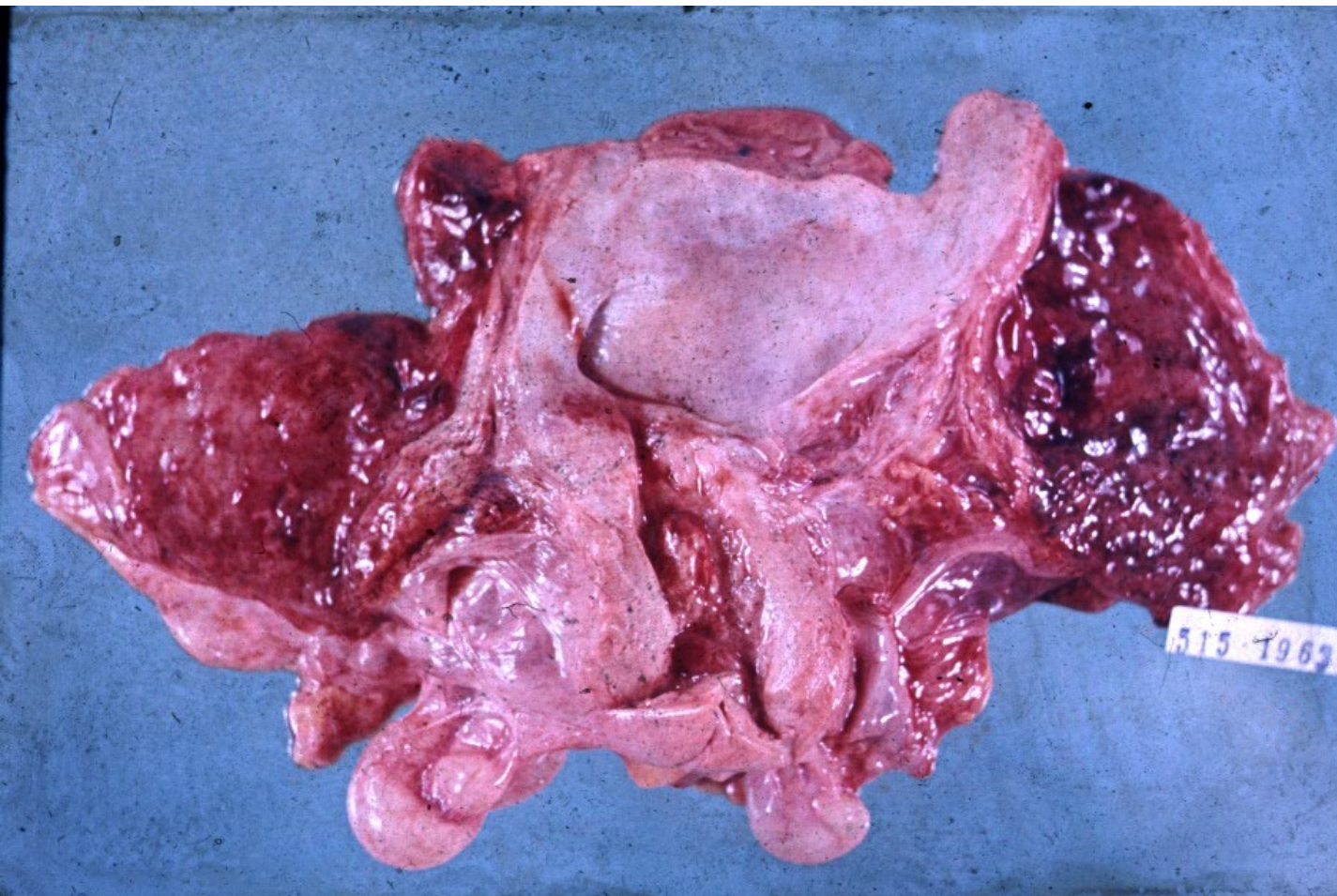
Urocystolithiasis + chronic cystitis + diverticula



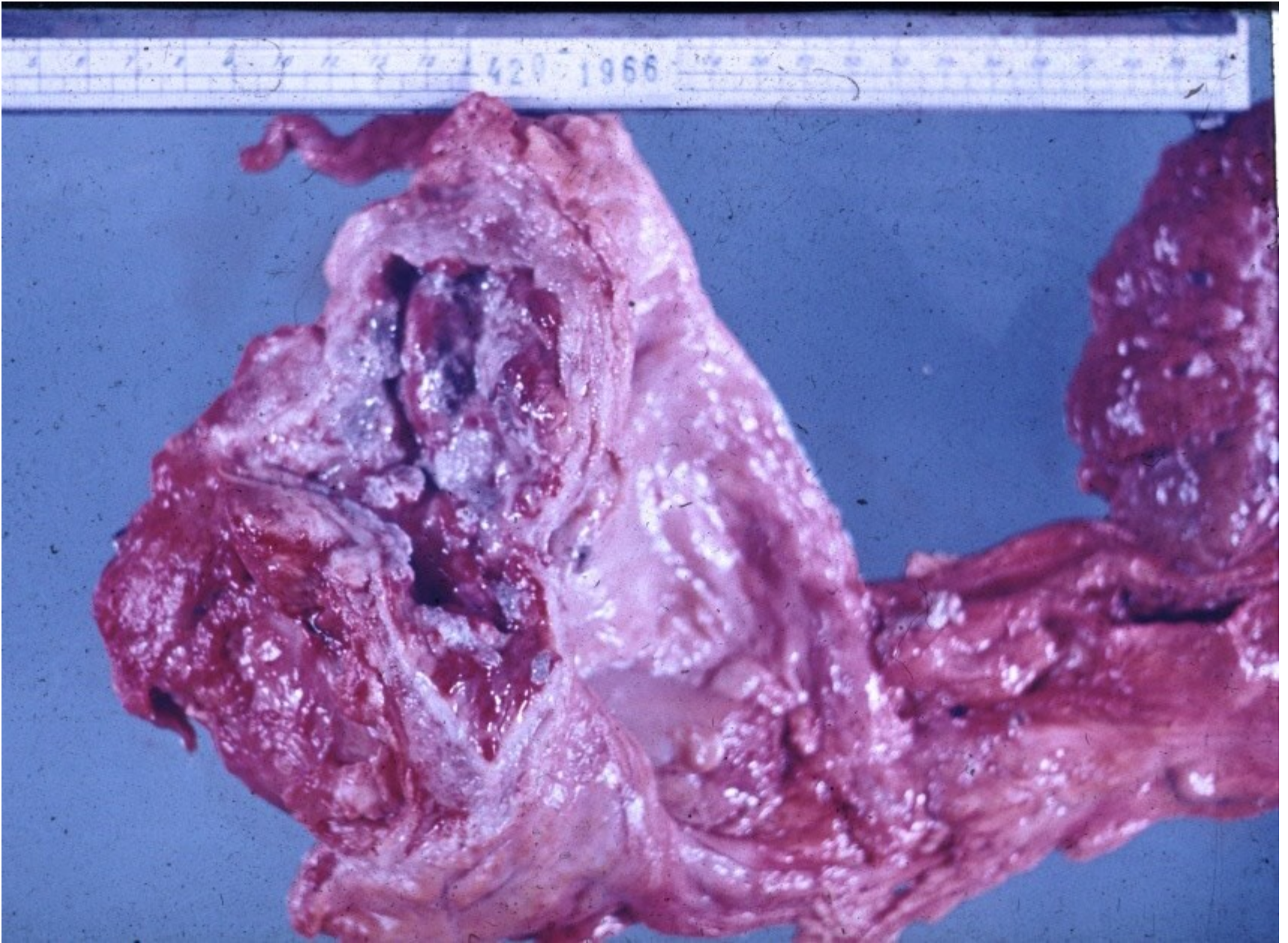
Acute cystitis

- highly common in females (short urethra, perineal connection with anus)
- mostly fecal bacteria, mixed flora
- risk factors – urine pH, hormonal status, iatrogenic
- usually purulent (leucocytes, blood in urine), urging, pain; may have systemic signs
- complications – ureteral spread, ulcers, rare phlegmona, pseudomembranous infl.

Haemorrhagic cystitis



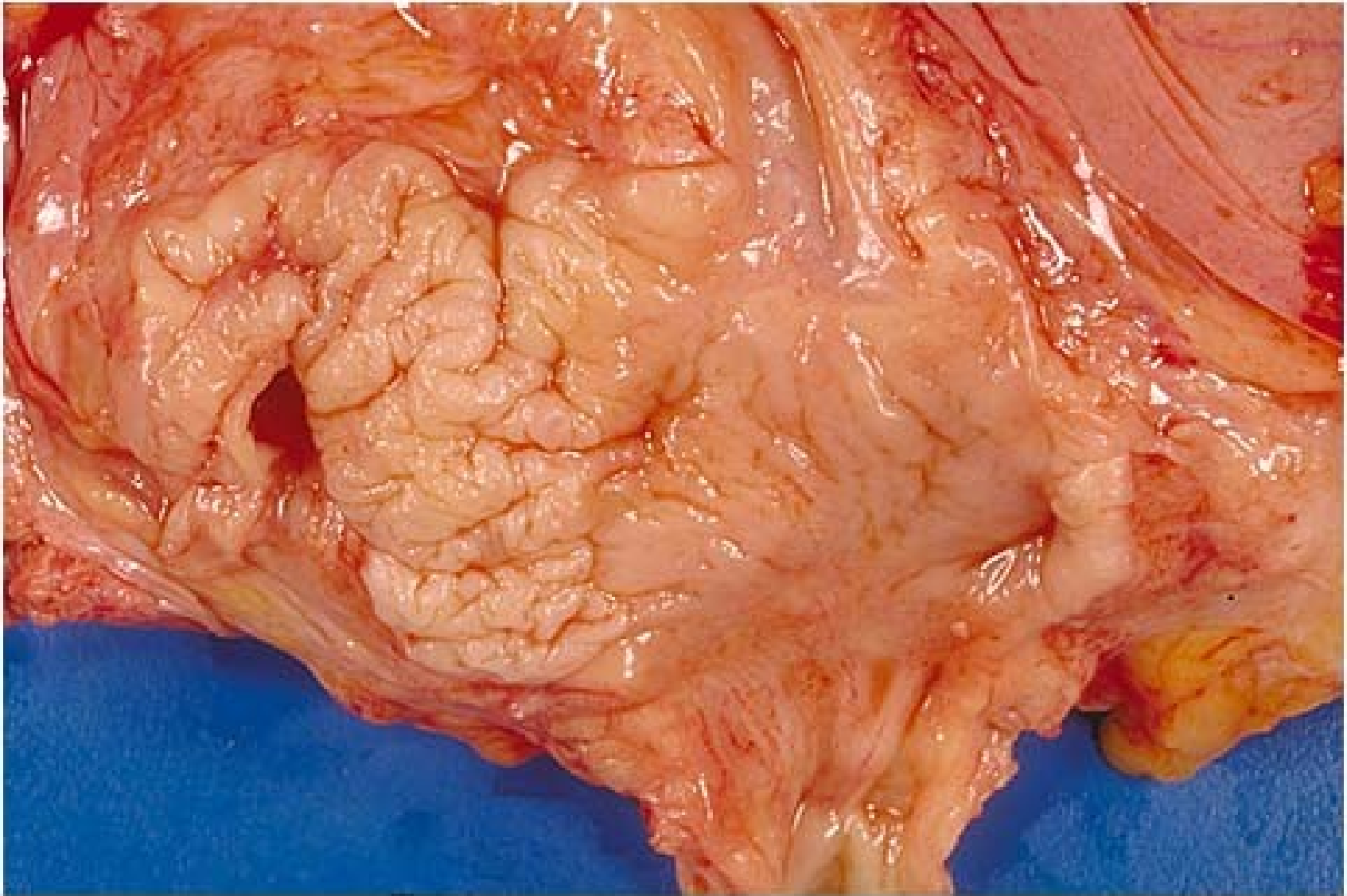
Ulcerative cystitis



Chronic cystitis

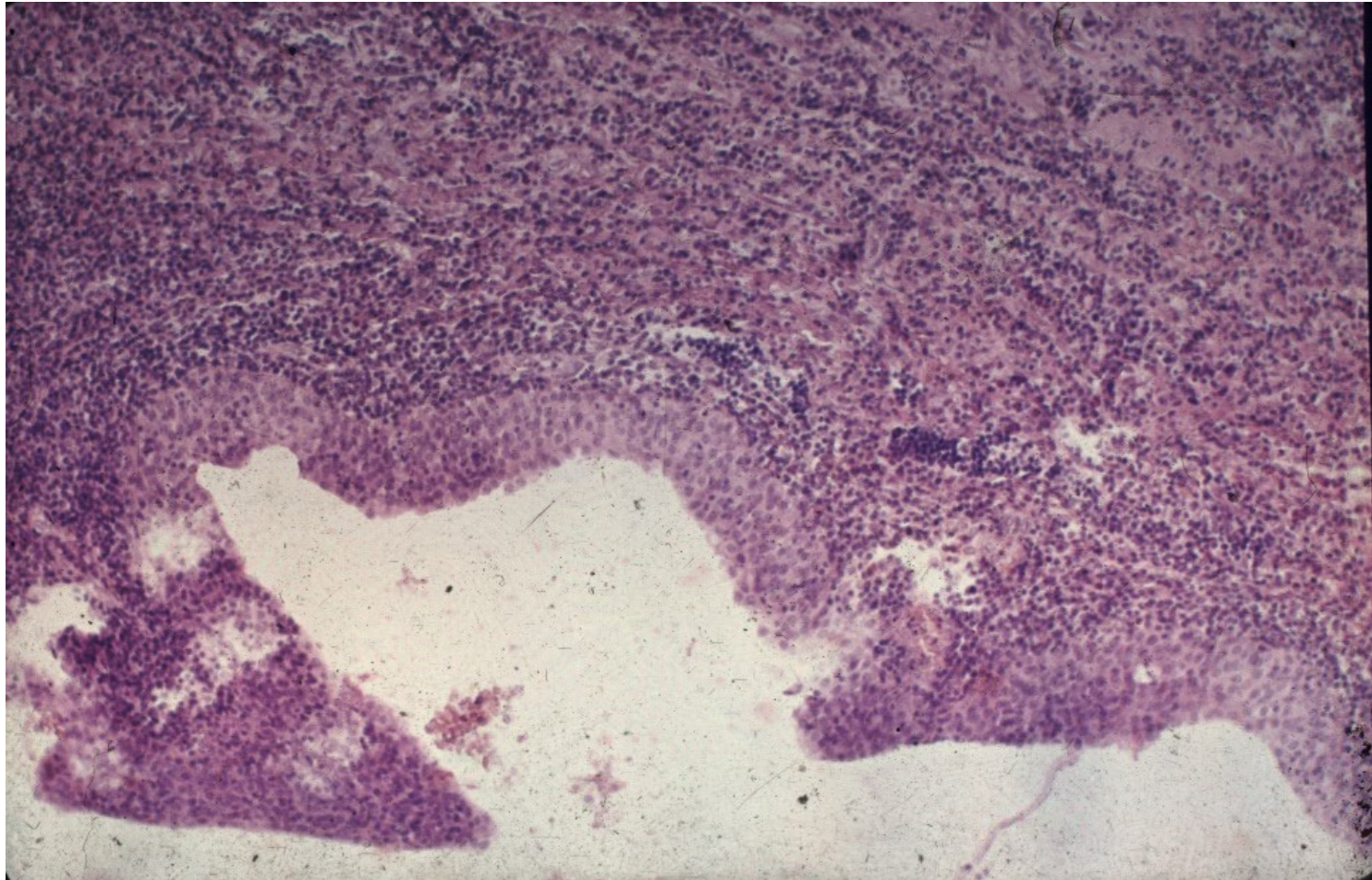
- epithelial transformations – polyps, epithelial hyperplasia (Brunn's nests, reactive atypia – x neoplastic), metaplasia (squamous - leukoplakia, glandular)
- neoformation of lymphatic follicles in stroma
- in obstruction + muscular hyperplasia, diverticuli
- acute exacerbations, stone formation
- may be risk factor for neoplasia
- diff. dg. x neoplasia

Leukoplakia

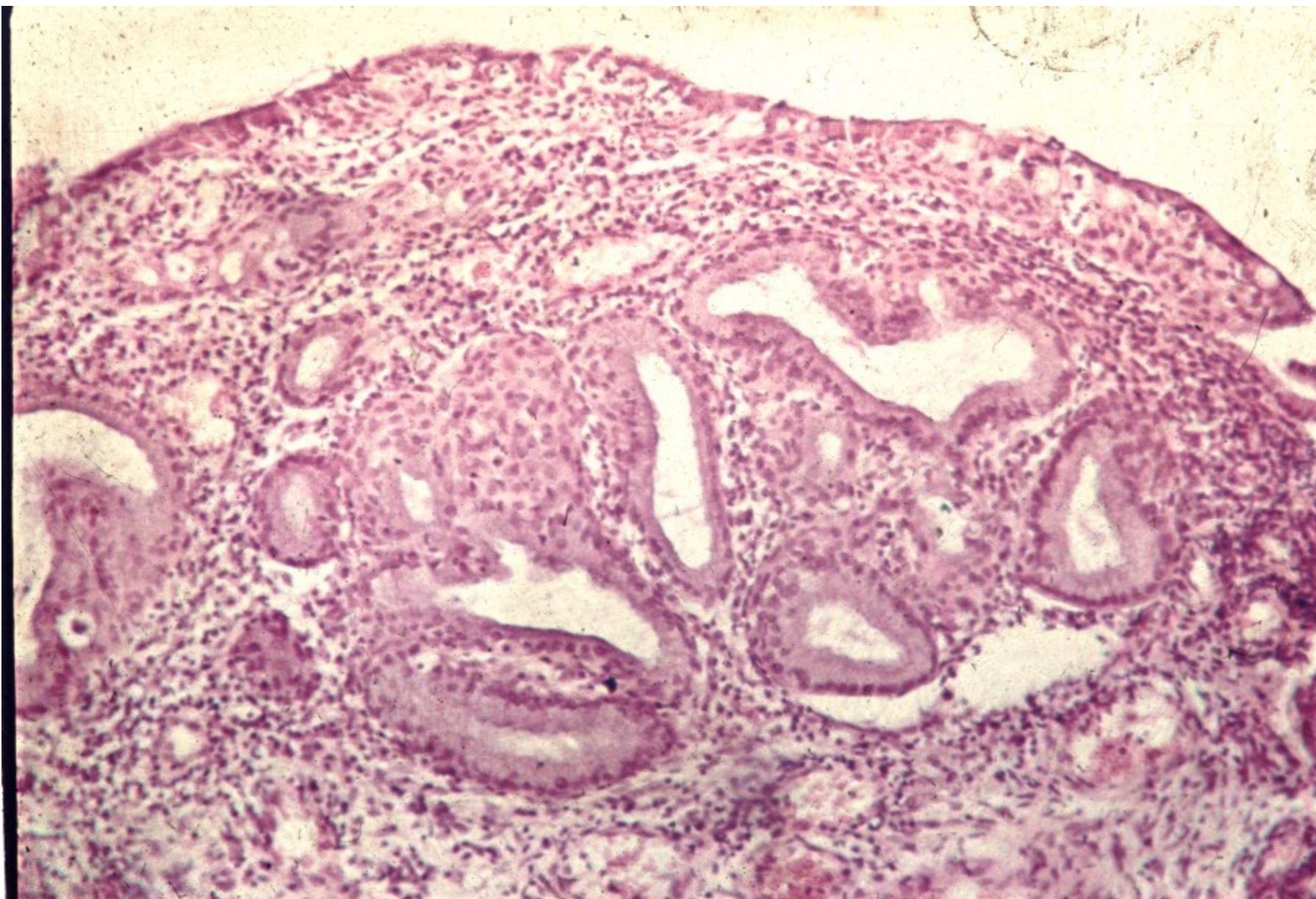


Copyright © 2002, Elsevier Science (USA). All rights reserved.

Chronic cystitis with squamous metaplasia



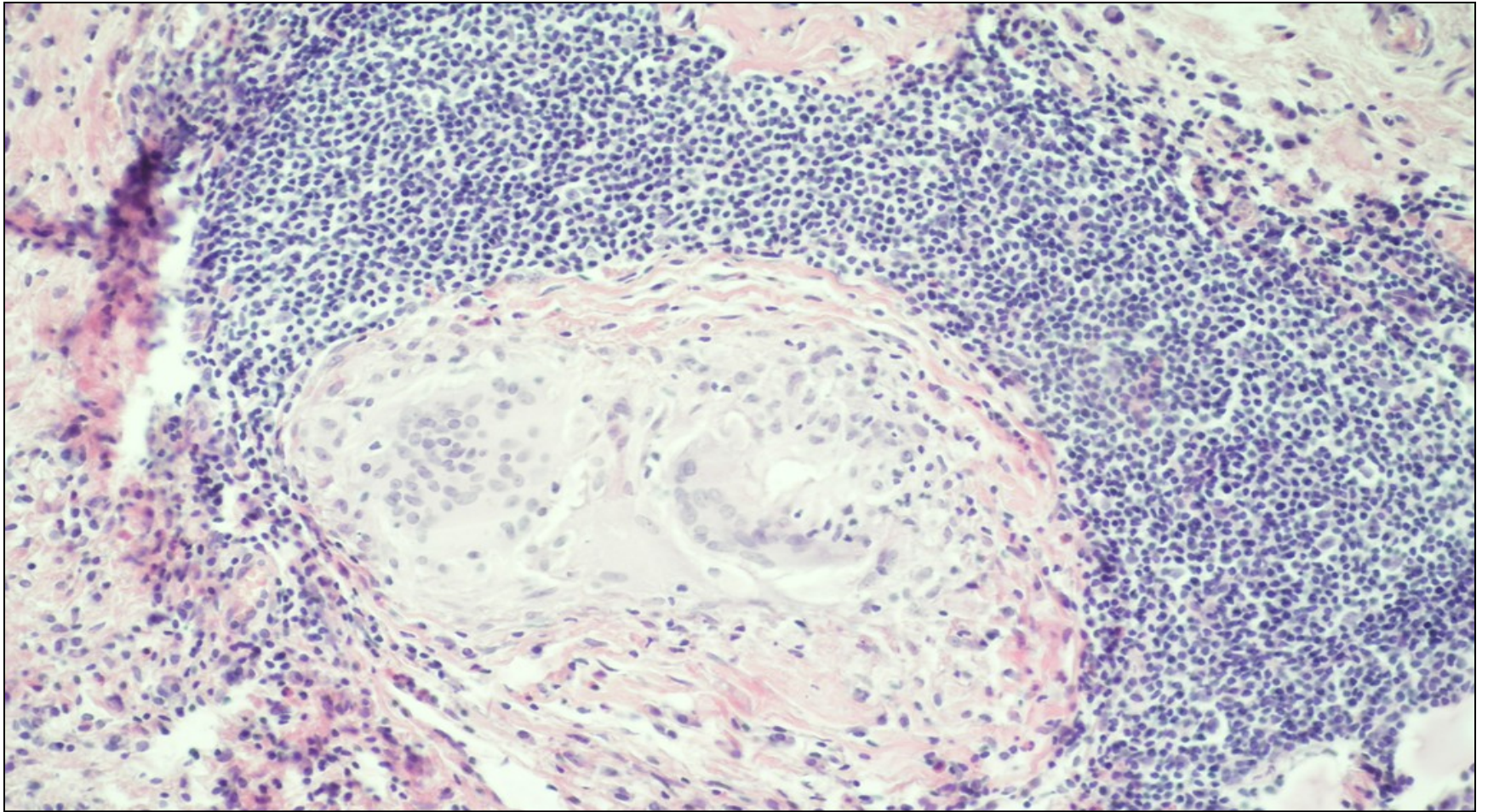
Glandular cystitis



Granulomatous cystitis

- **specific**
 - parasites
 - TB, incl. BCG vaccine as treatment for bladder ca
 - other
- **nonspecific**
 - foreign body reaction, incl. post-treatment (endoresection)

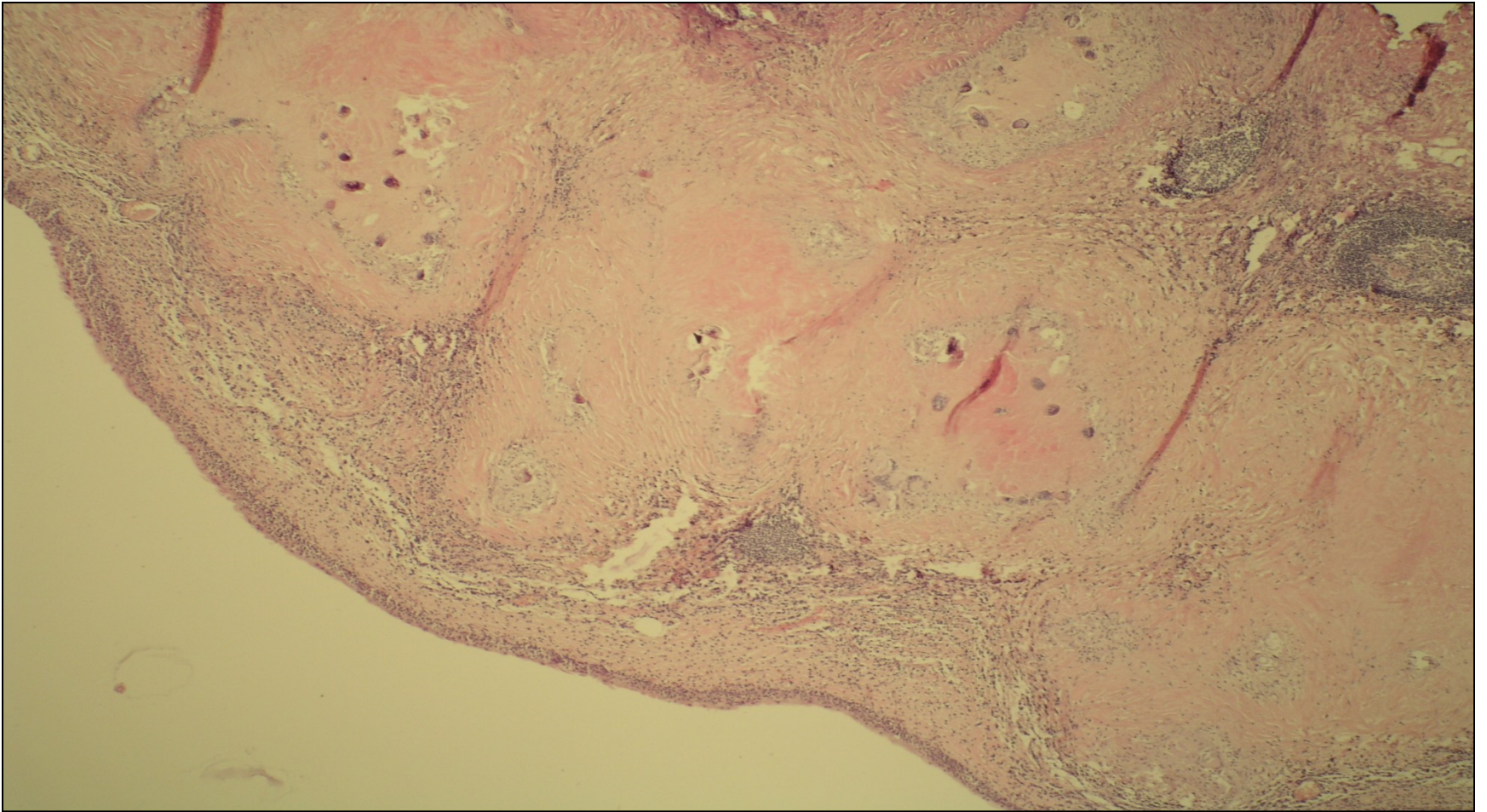
Granulomatous cystitis



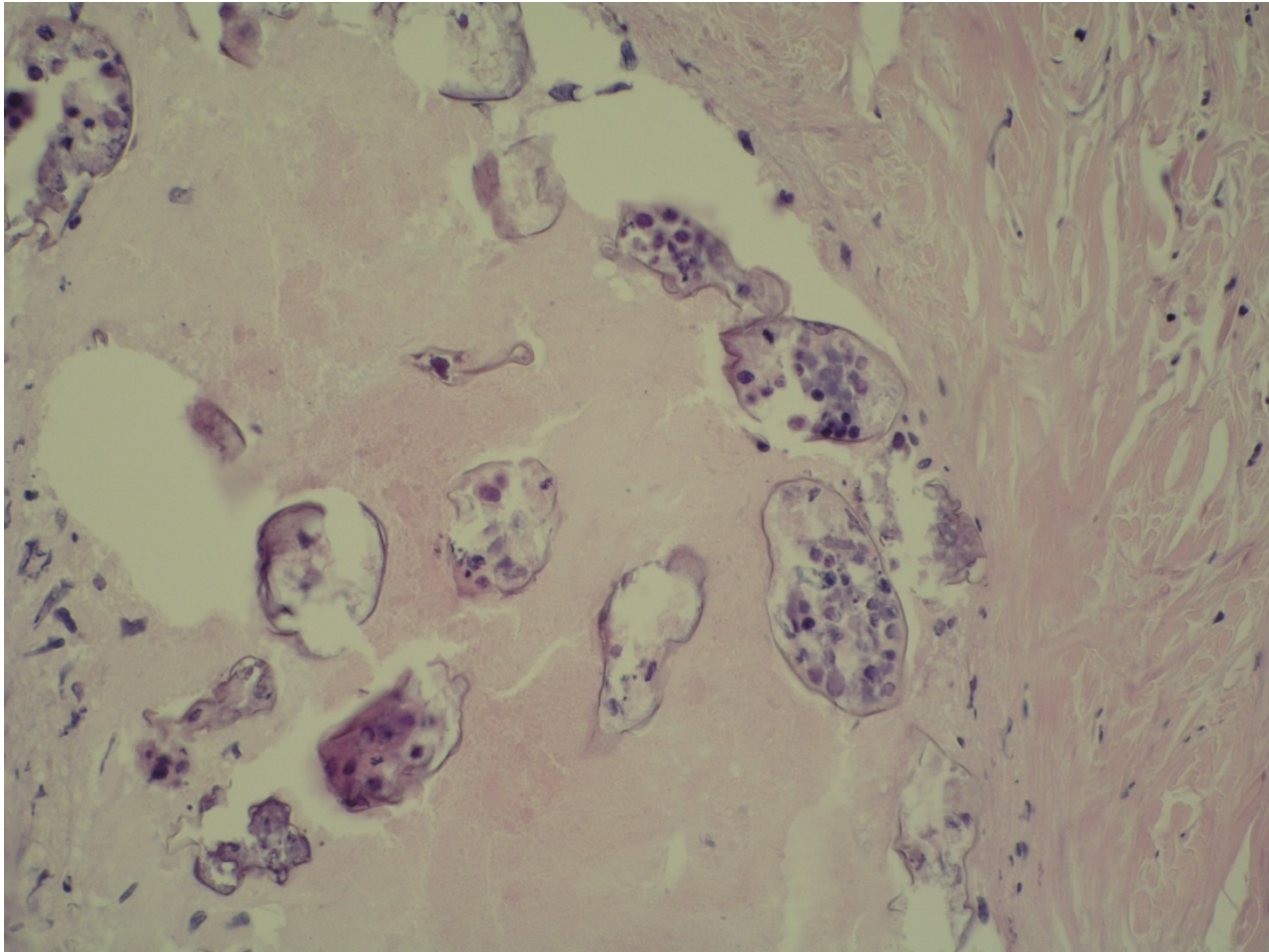
Schistosomiasis

- chronic parasitic inflammation
- endemic in Africa, Middle East
- possible traveller infection, worm lives for up to 20 years
- granulomatous reaction to eggs + fibrosis
- strictures, squamous metaplasia
- ↑ ↑ risk of squamous ca

Schistosomiasis



Schistosomiasis



Transitional cell (urothelial) tumors

exophytic:

- papilloma (benign), inverted papilloma
- papillary urothelial neoplasm of low malignant potential (PUNLMP)
- non-invasive papillary urothelial carcinoma – low grade, high grade
- invasive urothelial carcinoma – low grade, high grade

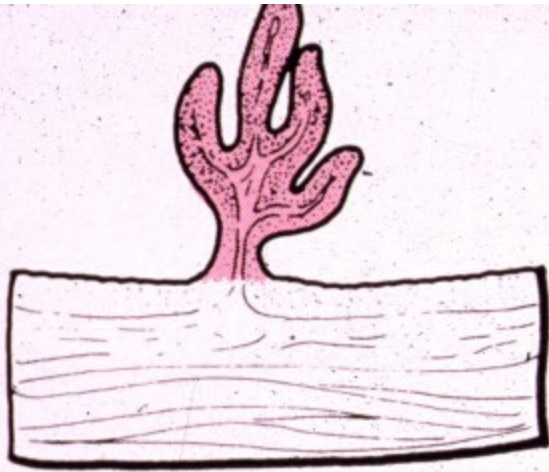
Transitional cell (urothelial) tumors

- **Flat lesions**

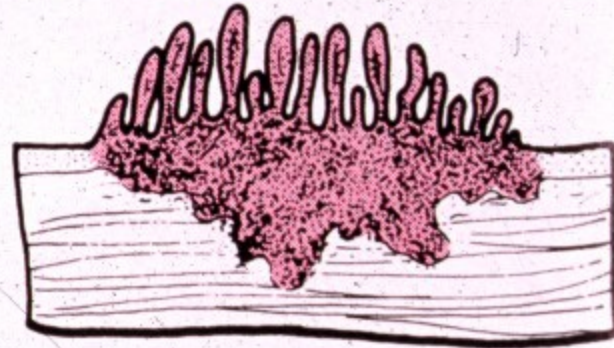
Intraepithelial neoplasia

- dysplasia
- carcinoma in situ (CIS)

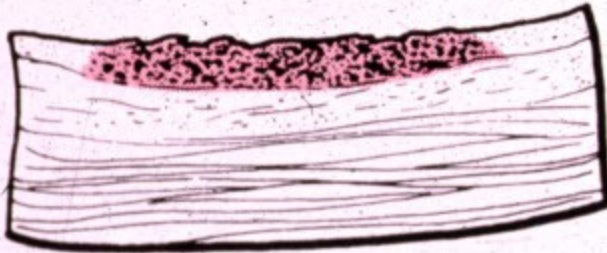
Invasive carcinoma



Papilloma-
papillary carcinoma



Invasive papillary
carcinoma



Flat noninvasive
carcinoma

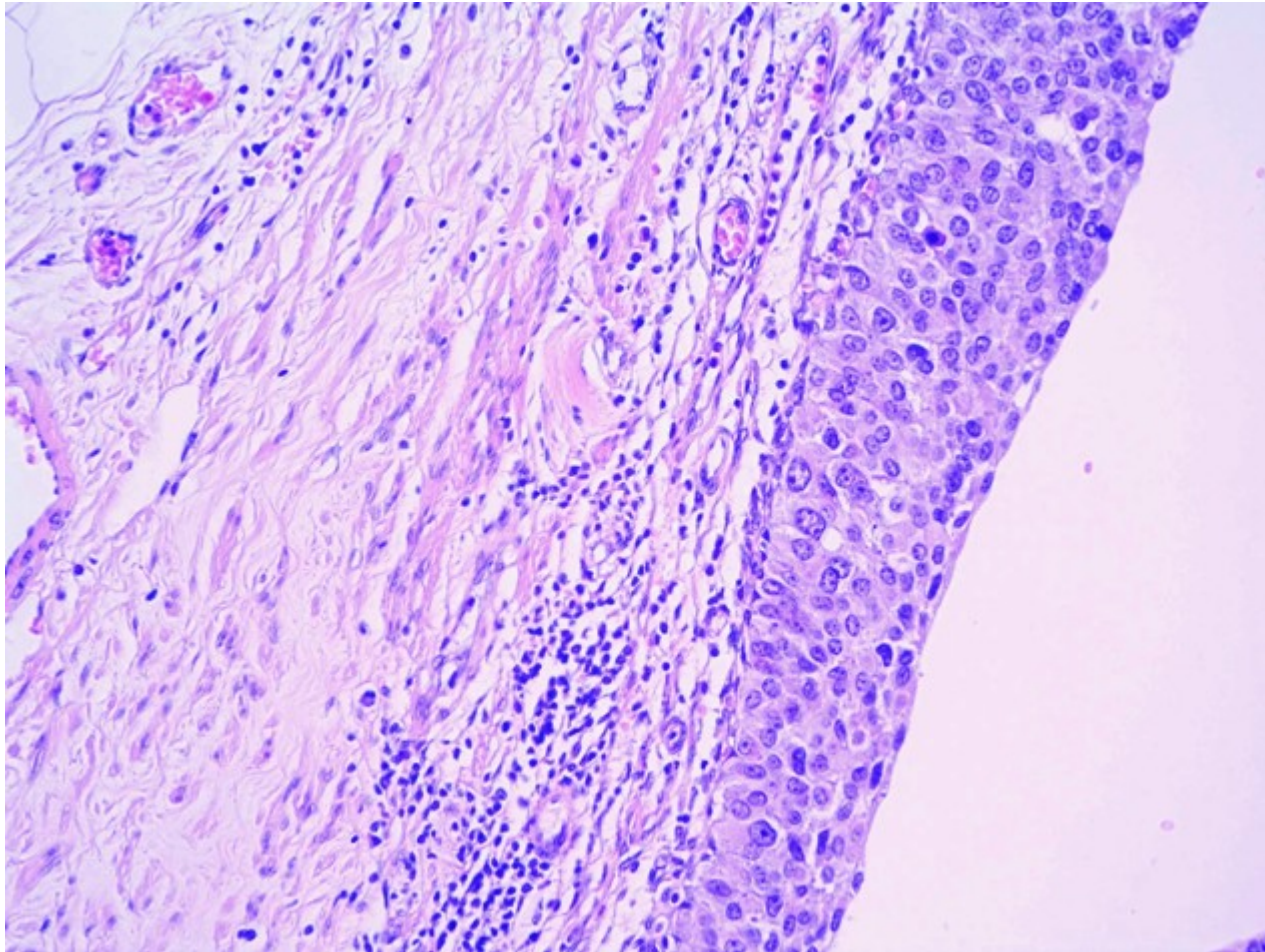


Flat invasive
carcinoma

Figure 21-9. Four morphologic patterns of bladder tumors.

from Robbins' Pathology of Diseases

Urothelial ca in situ



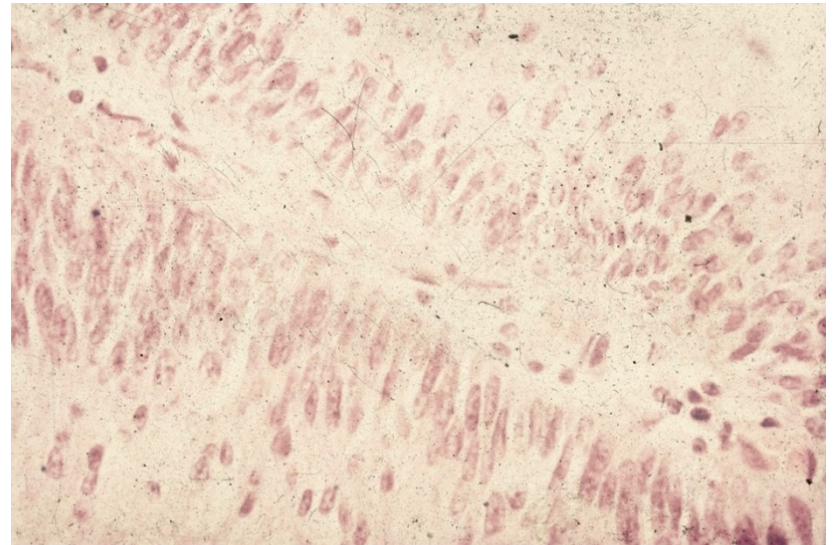
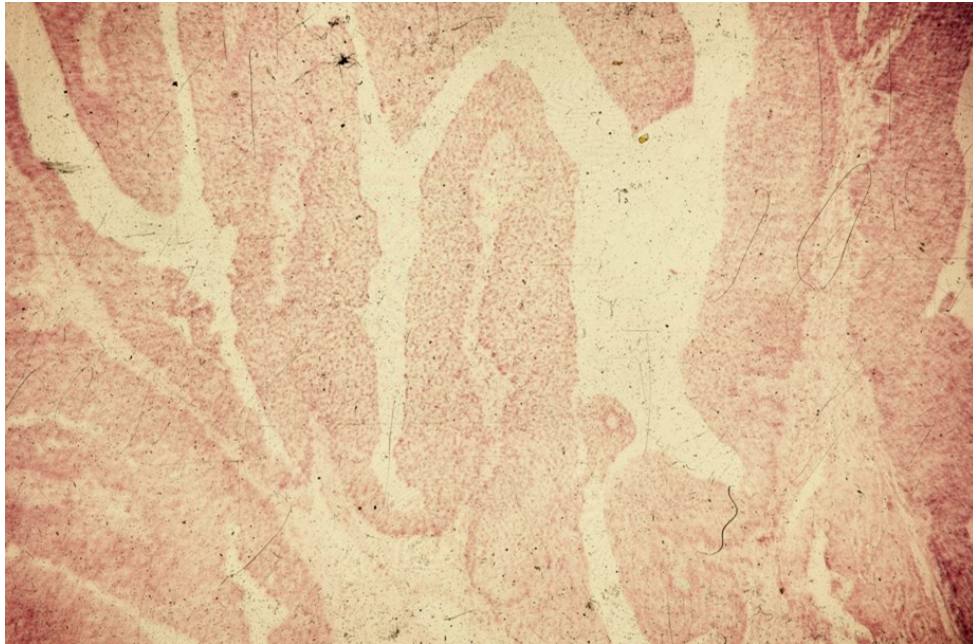
Urothelial papilloma

- Rare
- Solitary
- Exophytic / endophytic (inverted)
- Normal urothelium – no atypia, usual number of layers, superficial differentiation of umbrella cells

Papillary urothelial neoplasm of low malignant potential

- Slight increase in the number of cell layers, normal stratification, minimal increase in nuclear size and density
- Basal sporadic mitotic activity
- Risk of recurrence, possible progression into ca

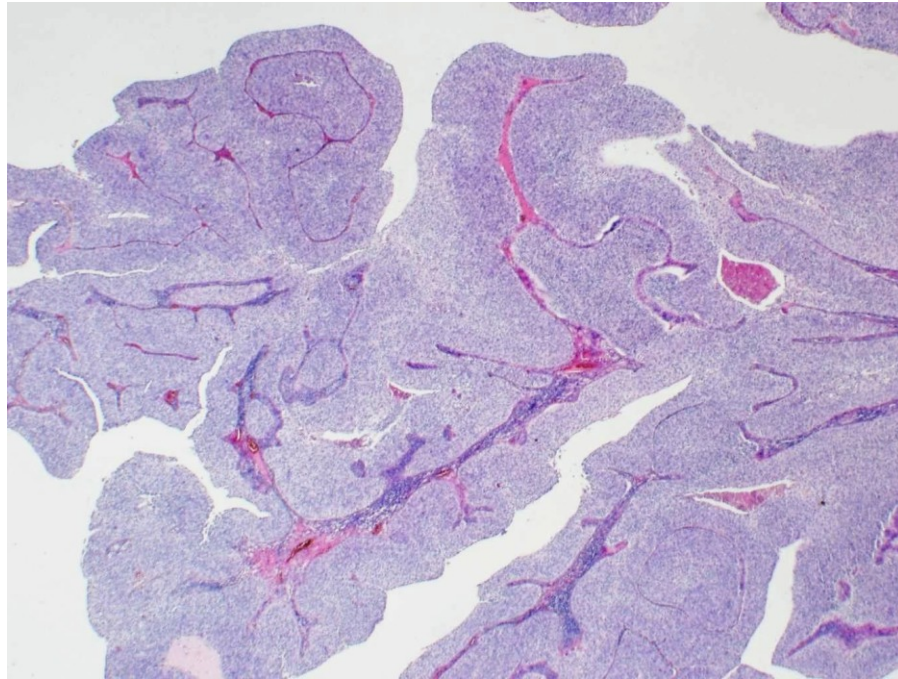
Papillary urothelial neoplasm of low malignant potential



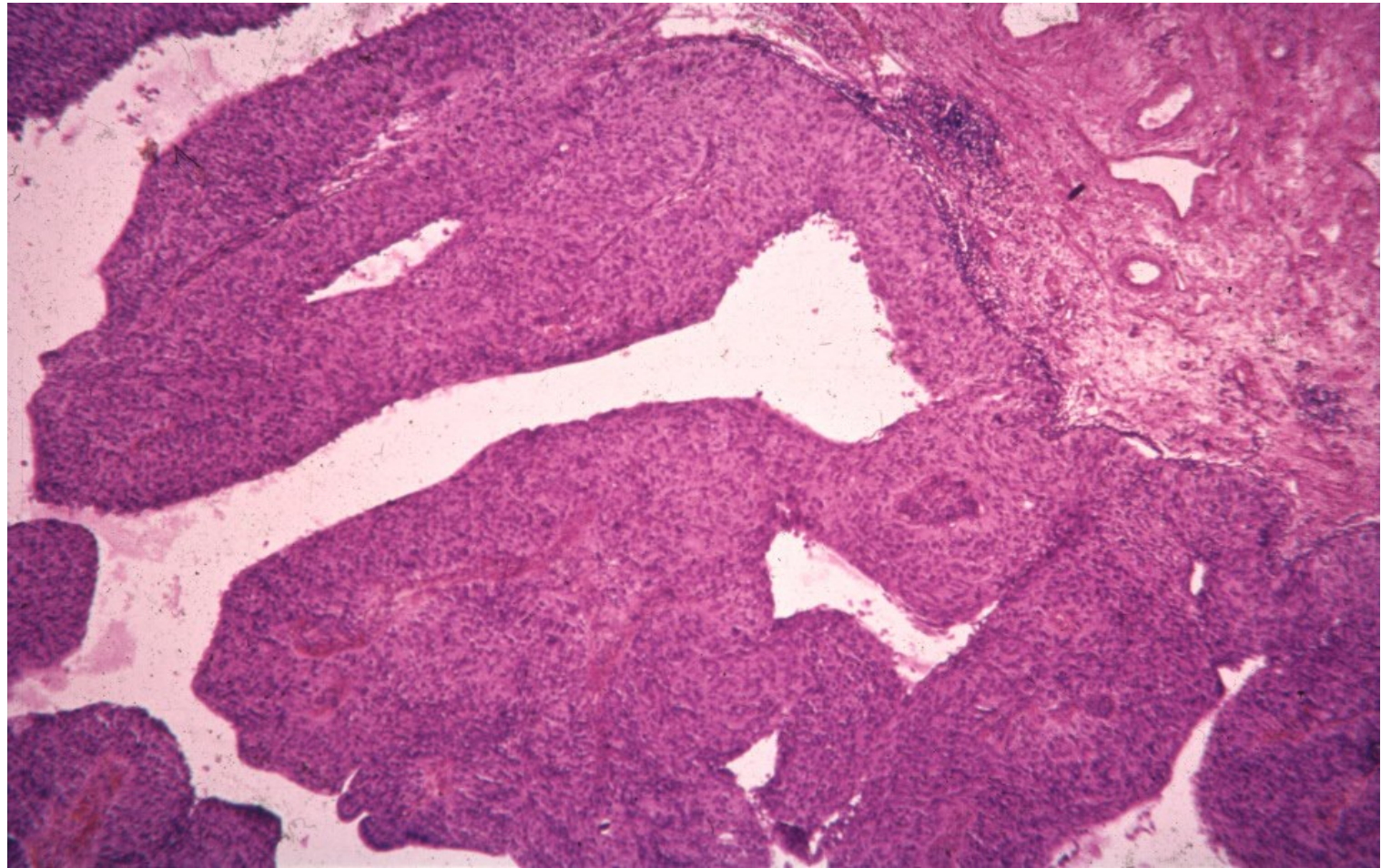
Non-invasive papillary urothelial carcinoma

- low grade
- high grade
- cytonuclear atypias of a carcinoma
- no stromal invasion
- histological code of a ca in situ (8130/2)

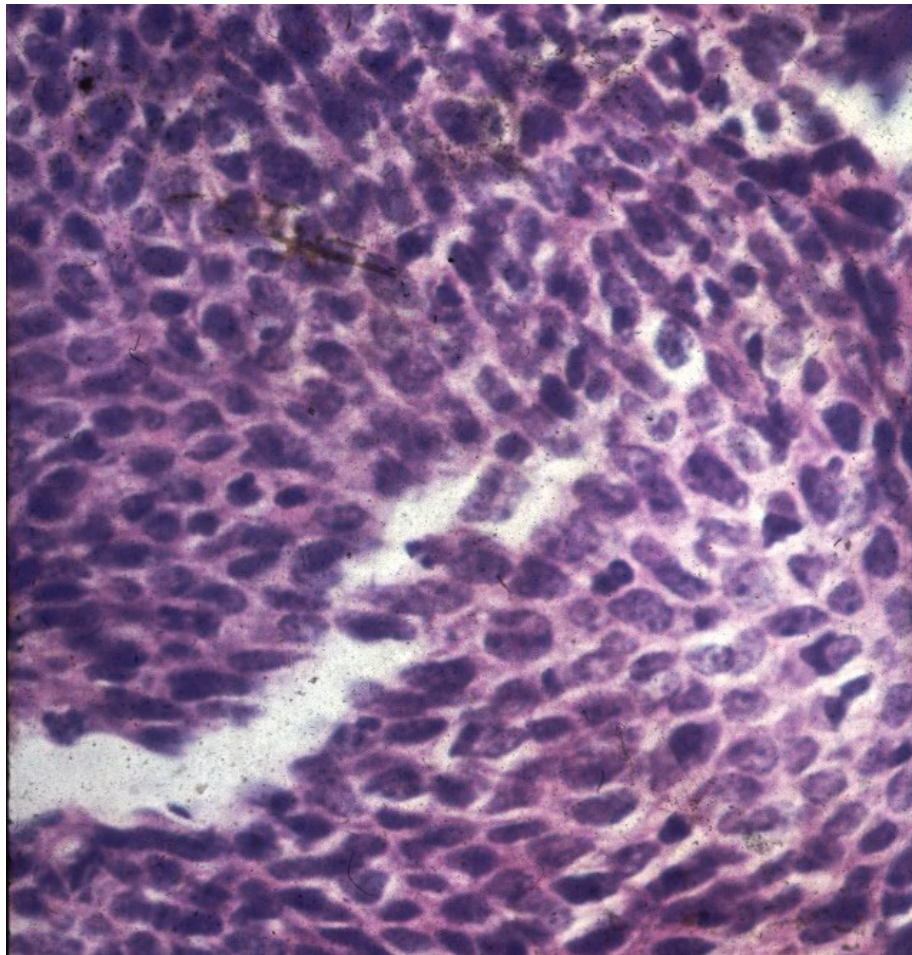
Non-invasive papillary urothelial carcinoma, low grade



Non-invasive papillary urothelial carcinoma, high grade



Non-invasive papillary urothelial carcinoma, high grade



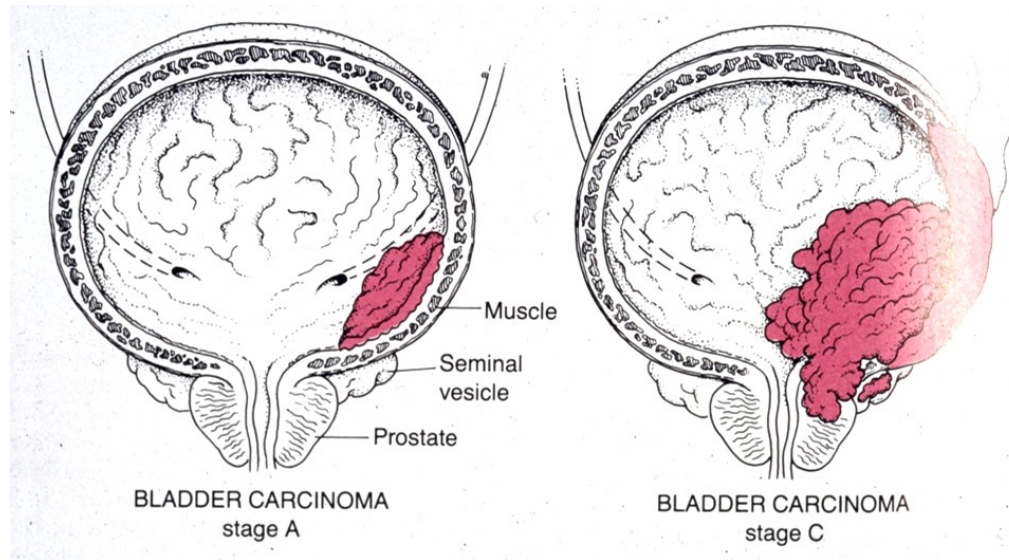
Invasive urothelial carcinoma

- ex flat urothelial ca in situ
- ex non-invasive papillary urothelial ca (papillary component commonly present)
- variable grade
- invasion into deep bladder structures (muscle layer), adjacent tissues/organs (fat, ureters, prostate gland, ...)

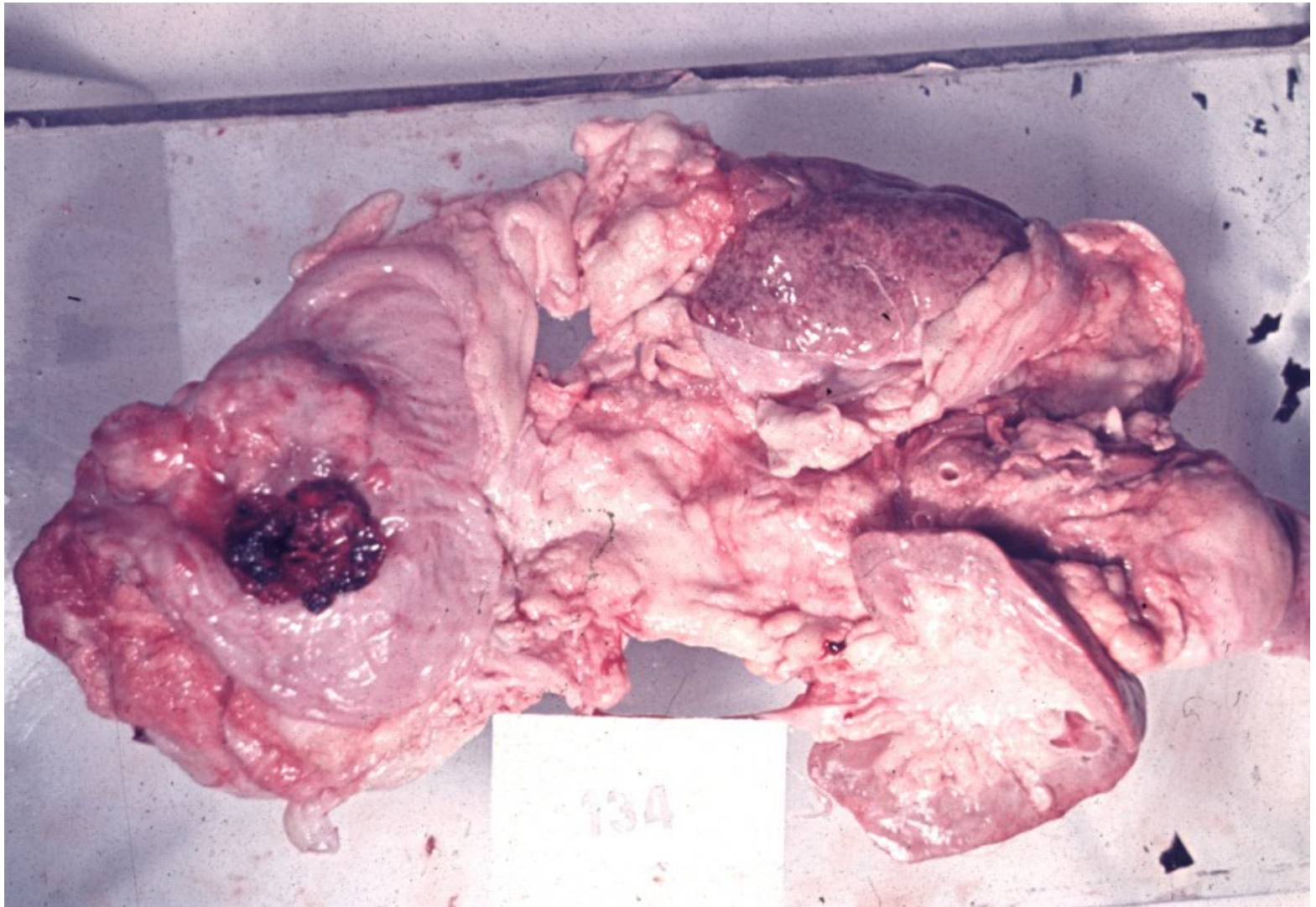
Invasive urothelial carcinoma

- 90% ca in the bladder (rare squamous cell ca or adenocarcinomas), mostly in 50 – 80 yrs old
- etiology: smokers, professional (anilin dyes, plastics industry), analgesic abuse, irradiation. Sq. cell ca in chronic inflammation (schistosomiasis)
- Differentiation grade G1 – G3
- asymptomatic, possible haematuria

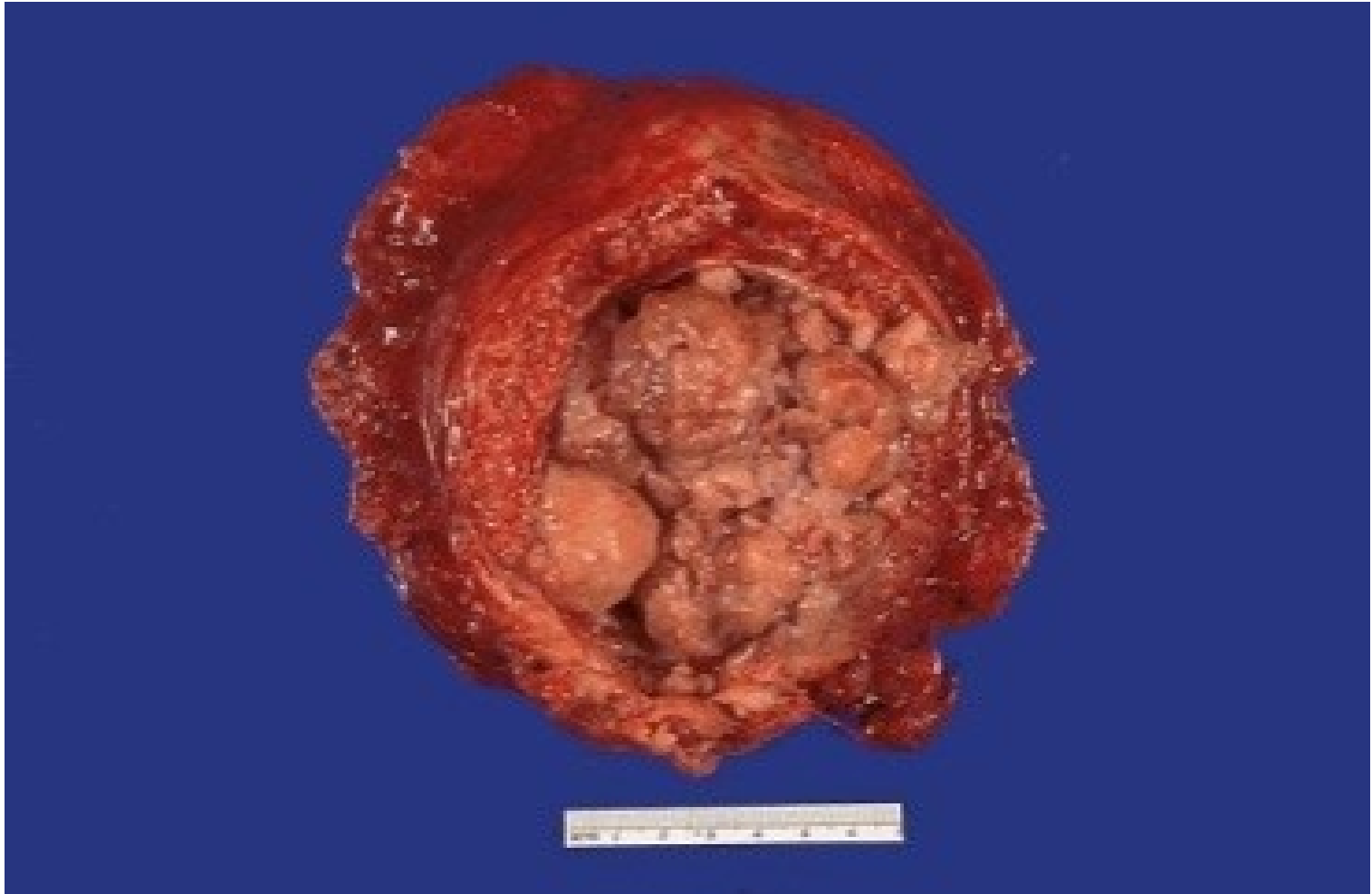Invasive urothelial carcinoma - staging



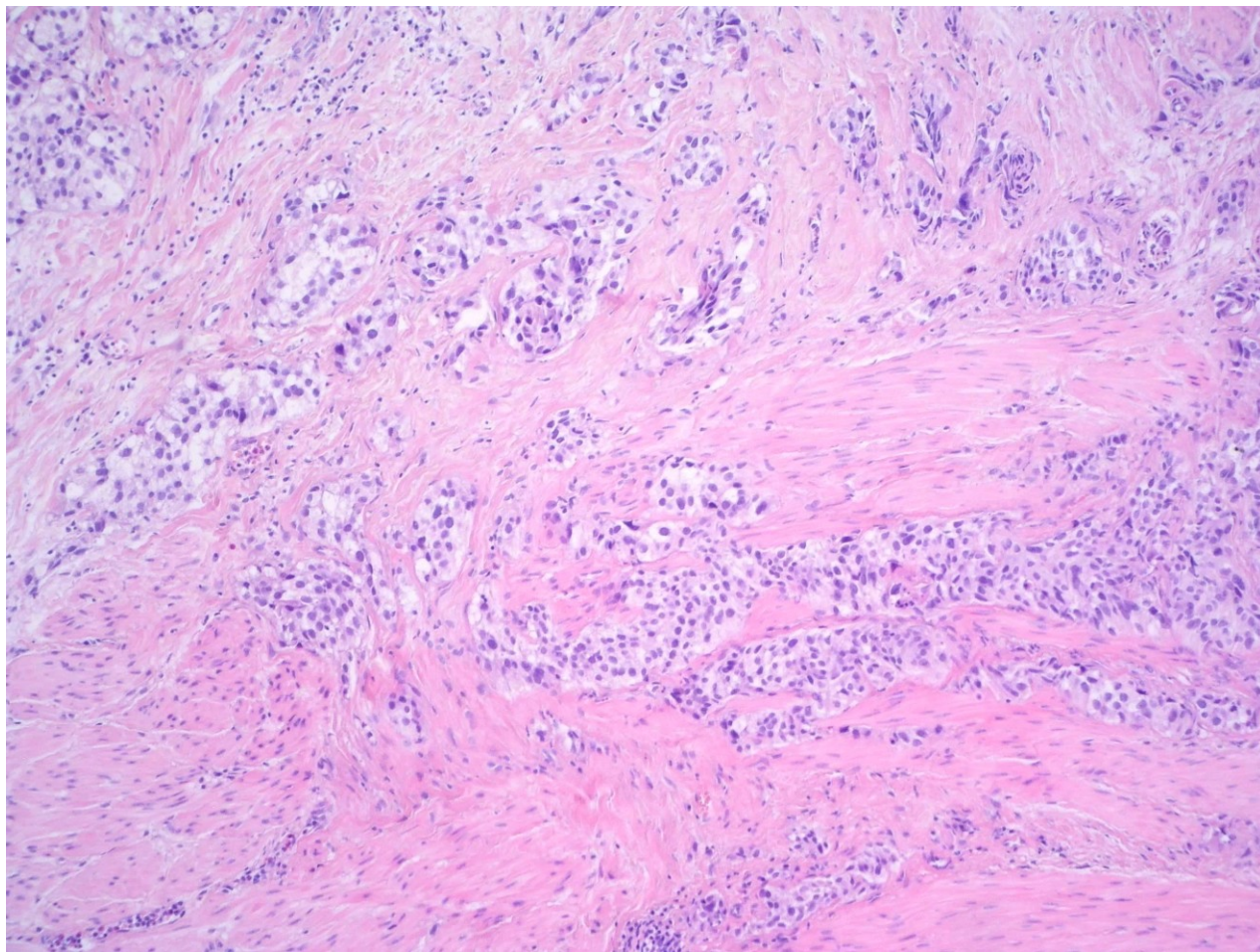
Bladder carcinoma



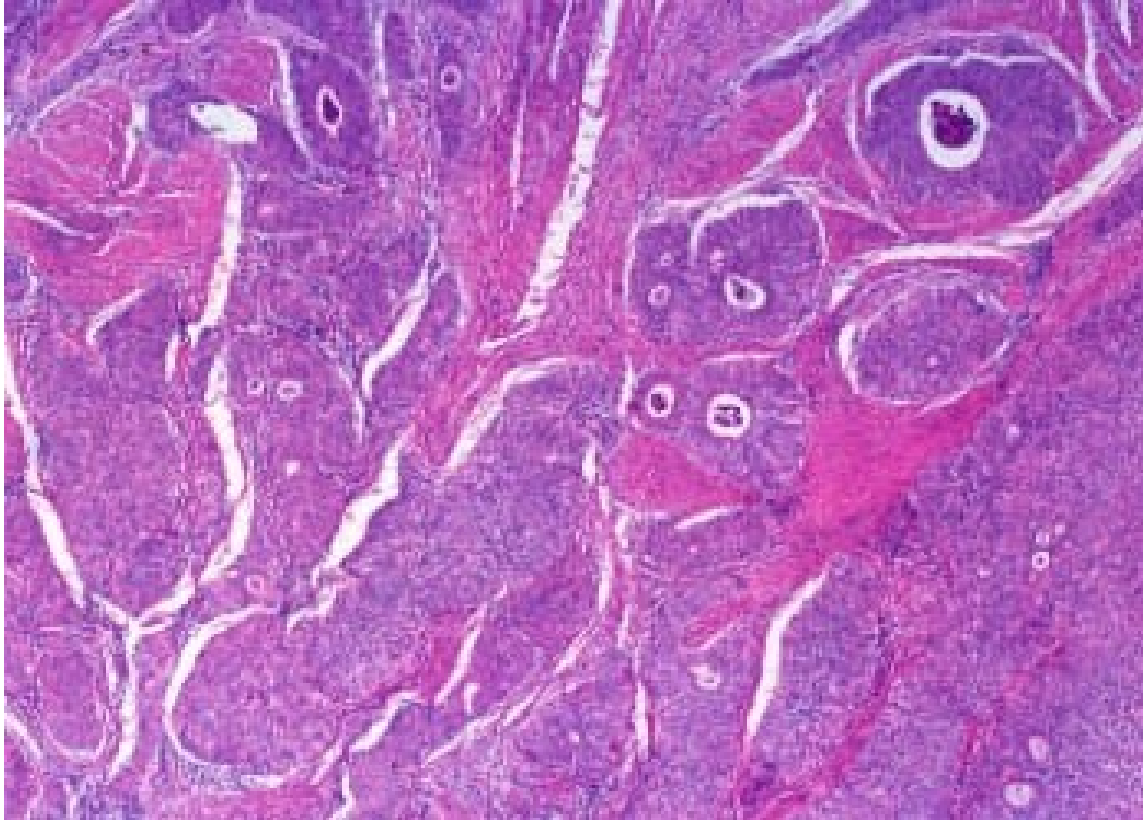
Bladder carcinoma



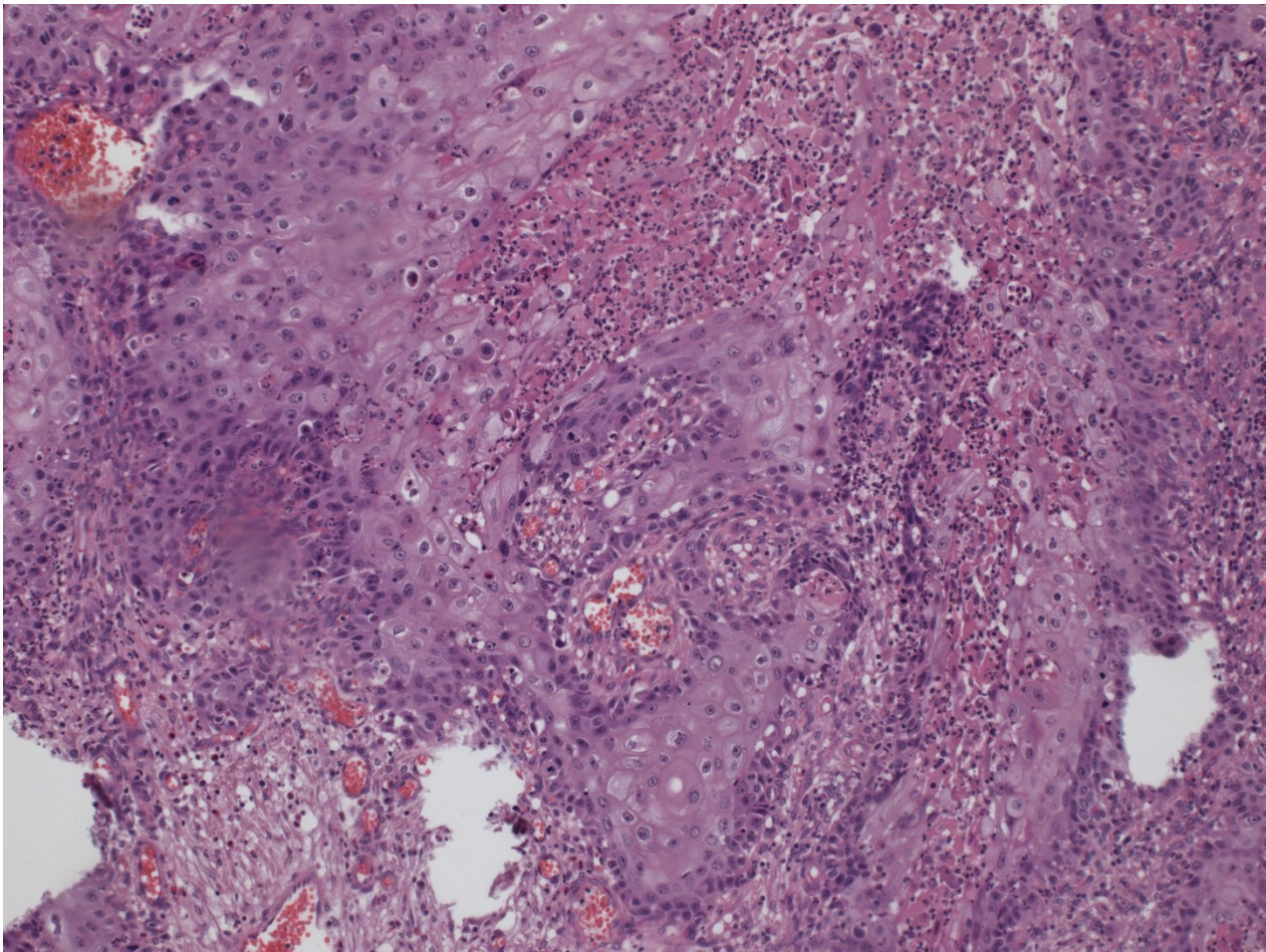
Invasive urothelial carcinoma



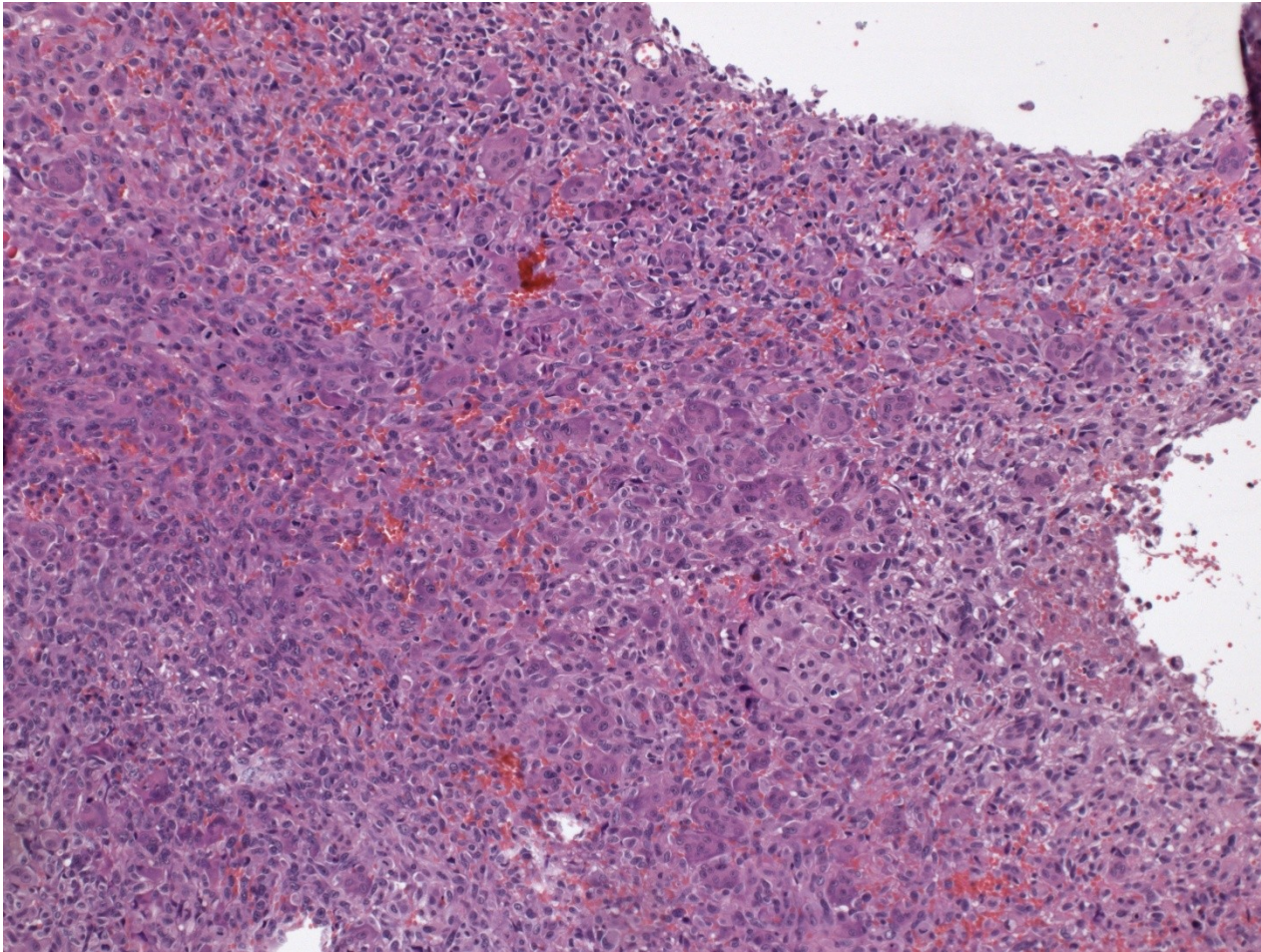
Carcinoma with glandular transformation



HG ca w. squamous transformation



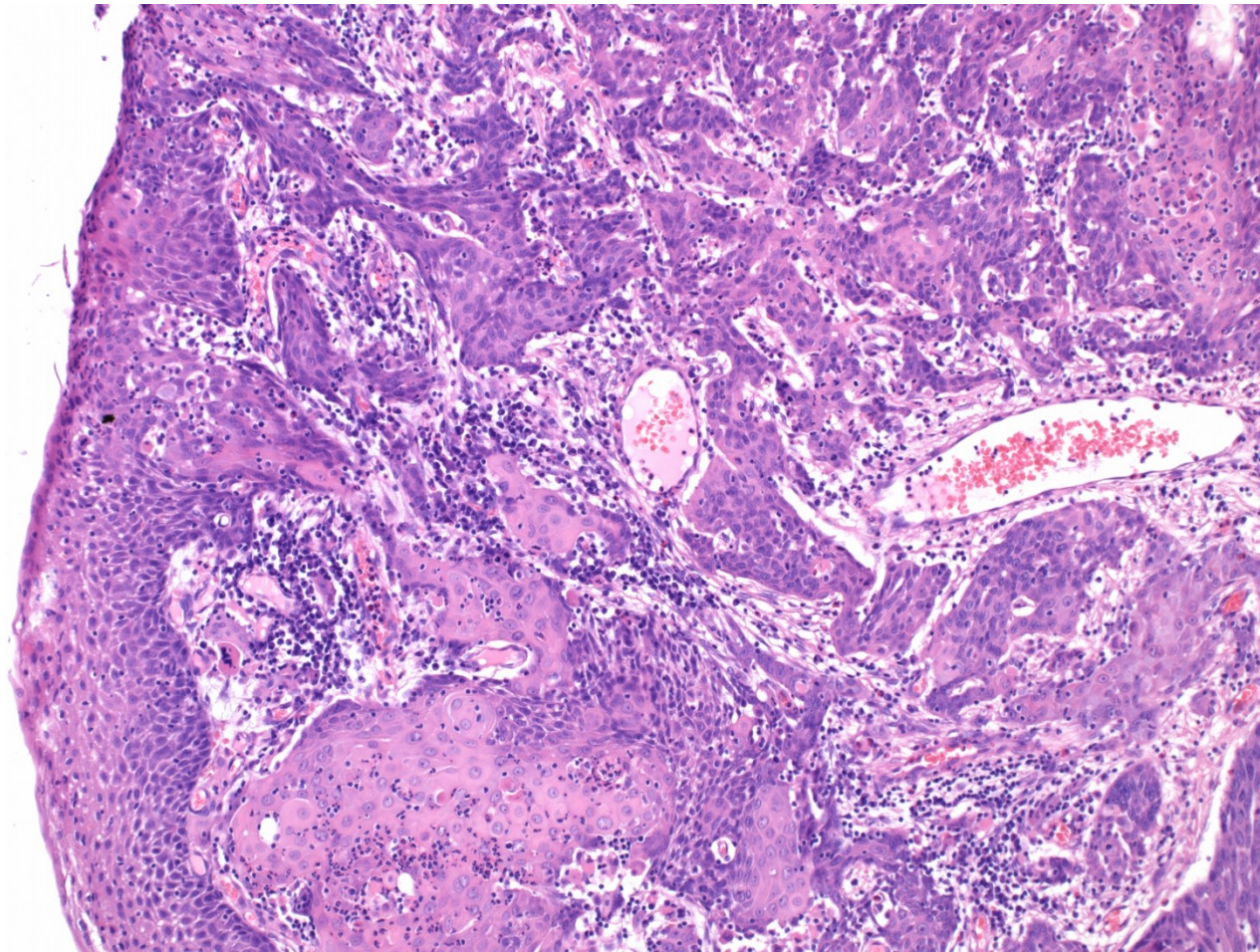
HG sarcomatoid ca



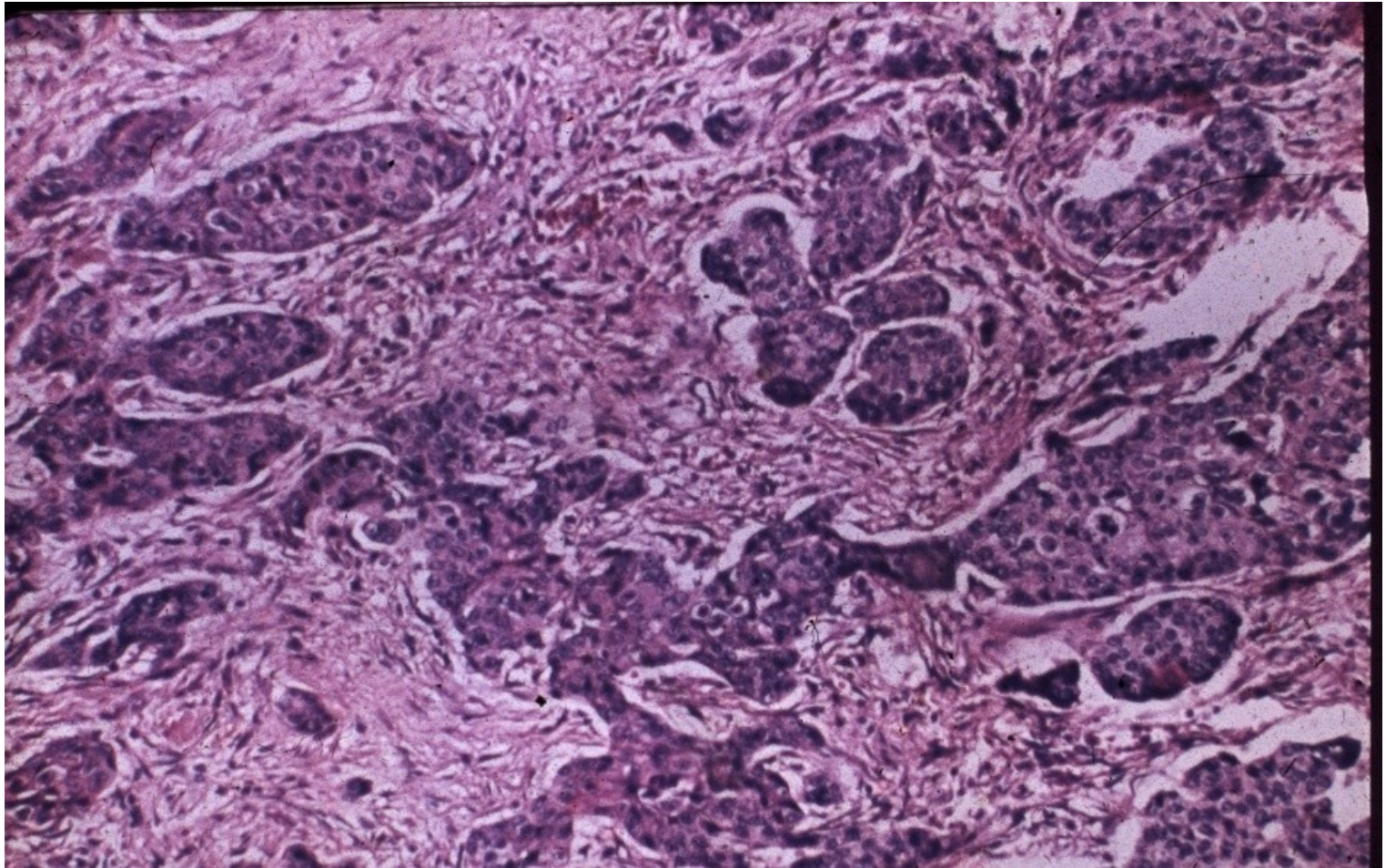
Bladder epithelial tumors - other

- squamous cell carcinoma
- adenocarcinoma
- small cell carcinoma (neuroendocrine ca)
- mixed ca
- secondary tumors – prostatic ca, cervical ca, rectal ca

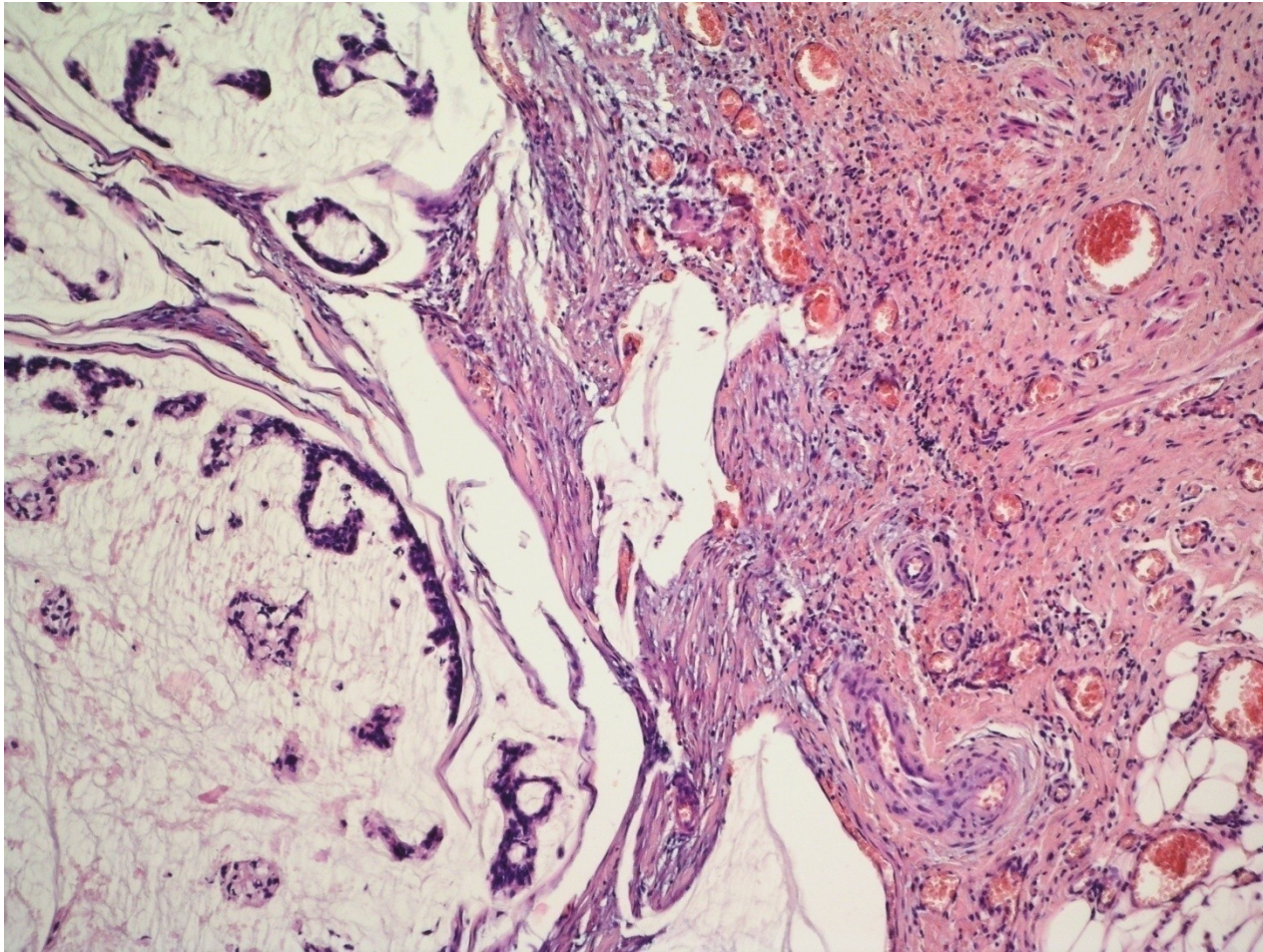
Sq. cell metaplasia + ca



Squamous cell carcinoma



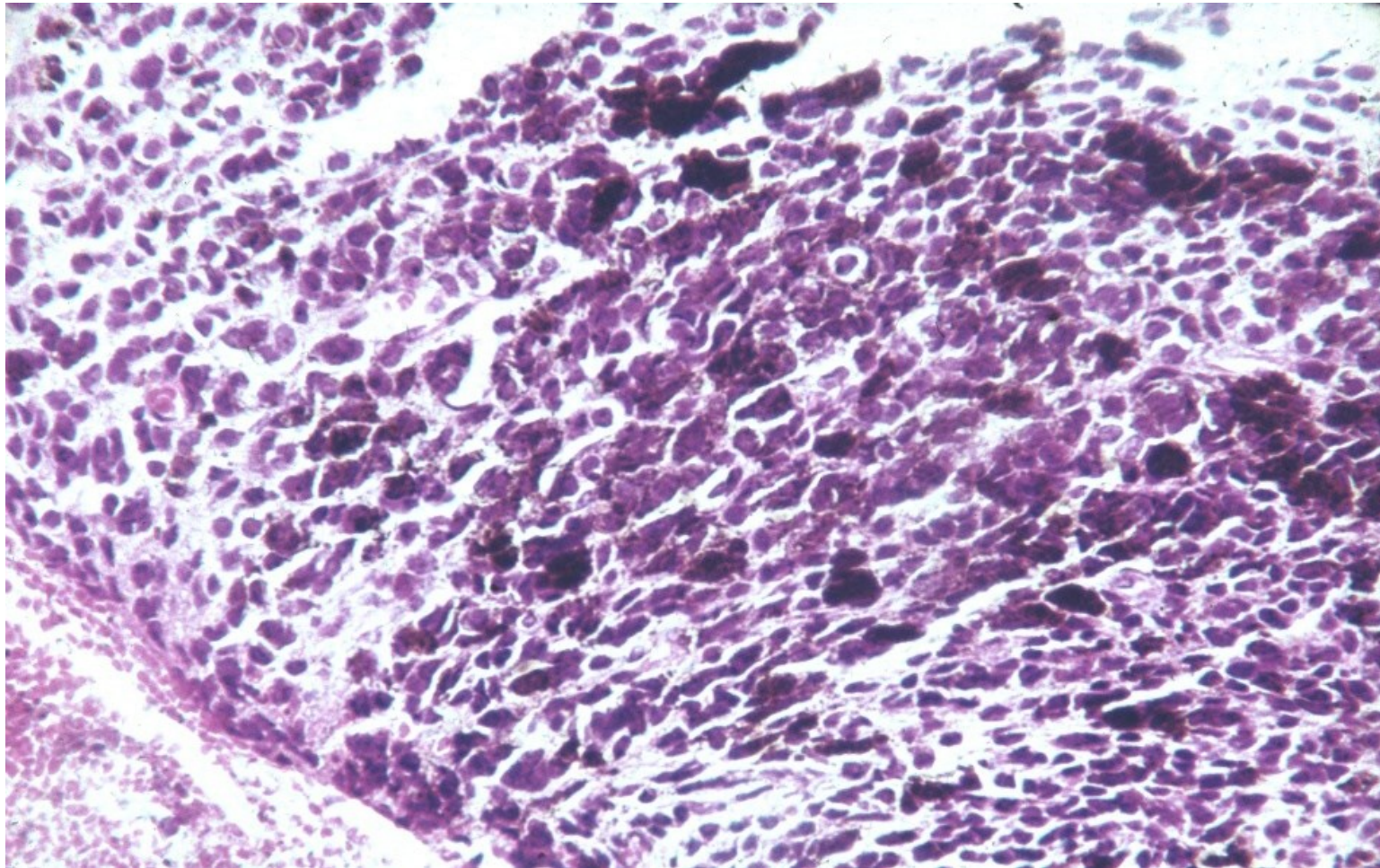
Mucinous adenocarcinoma



Bladder non-epithelial tumors

- Melanocytic
- Mesenchymal (benign, malignant sarcomas)
- Other

Malignant melanoma in the bladder



MALE GENITAL SYSTEM

Penis, scrotum

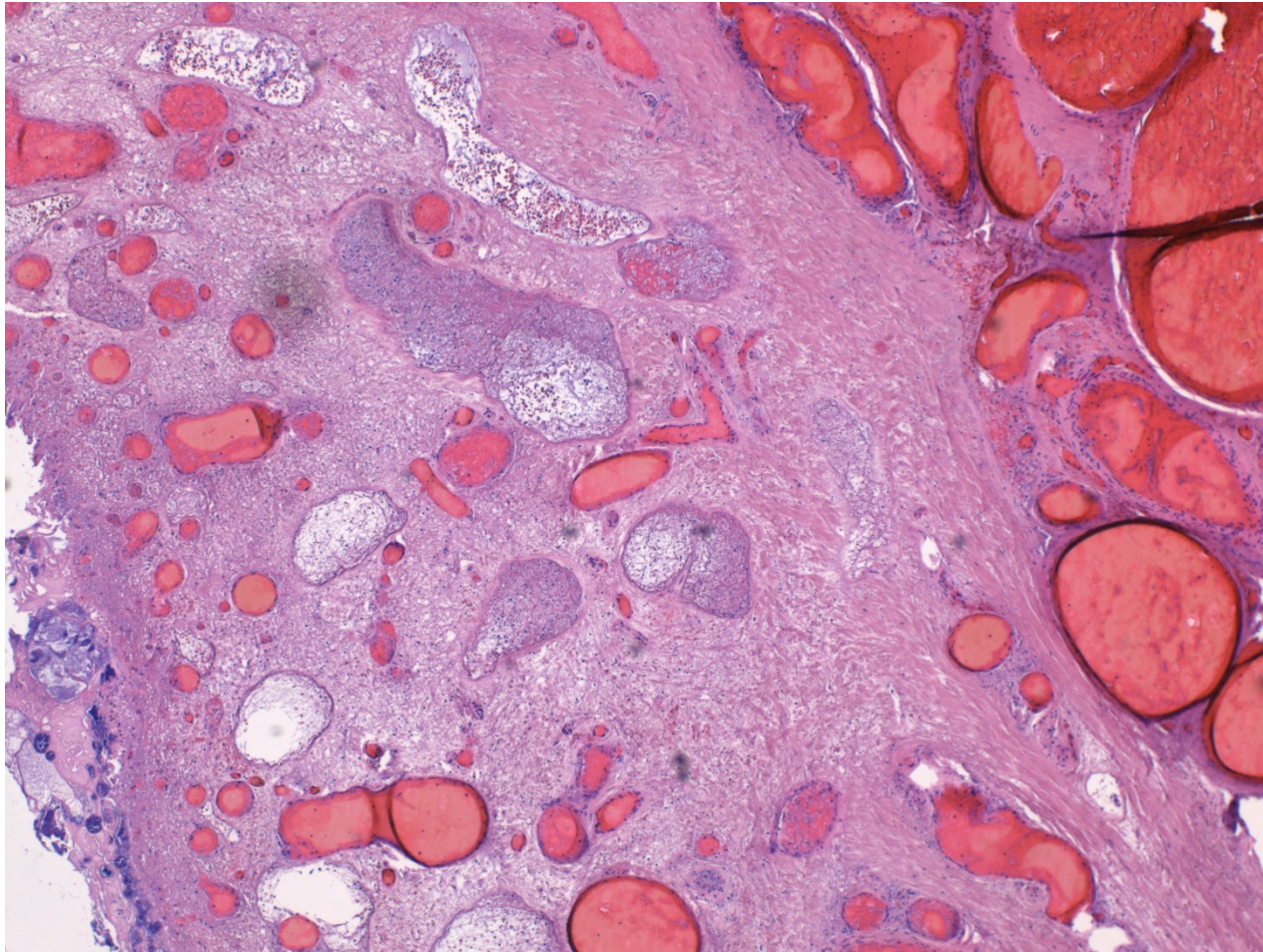
Congenital lesions

- **Epispadia**: less common, incomplete fusion of urethra, dorsal opening, may be a part of bladder exstrophy
- **Hypospadia**: more common, opening on inferior part of penis (glans, shaft, perineum)
- **Phimosis**: diminished size of prepuce opening, rare inborn, more common acquired – inflammation, scarring, ! ca

Circulatory disorders

- **Edema**
- **corpora cavernosa thrombosis,**
- **gangrene (uncommon)**

Penis – haemorrhagic gangrene



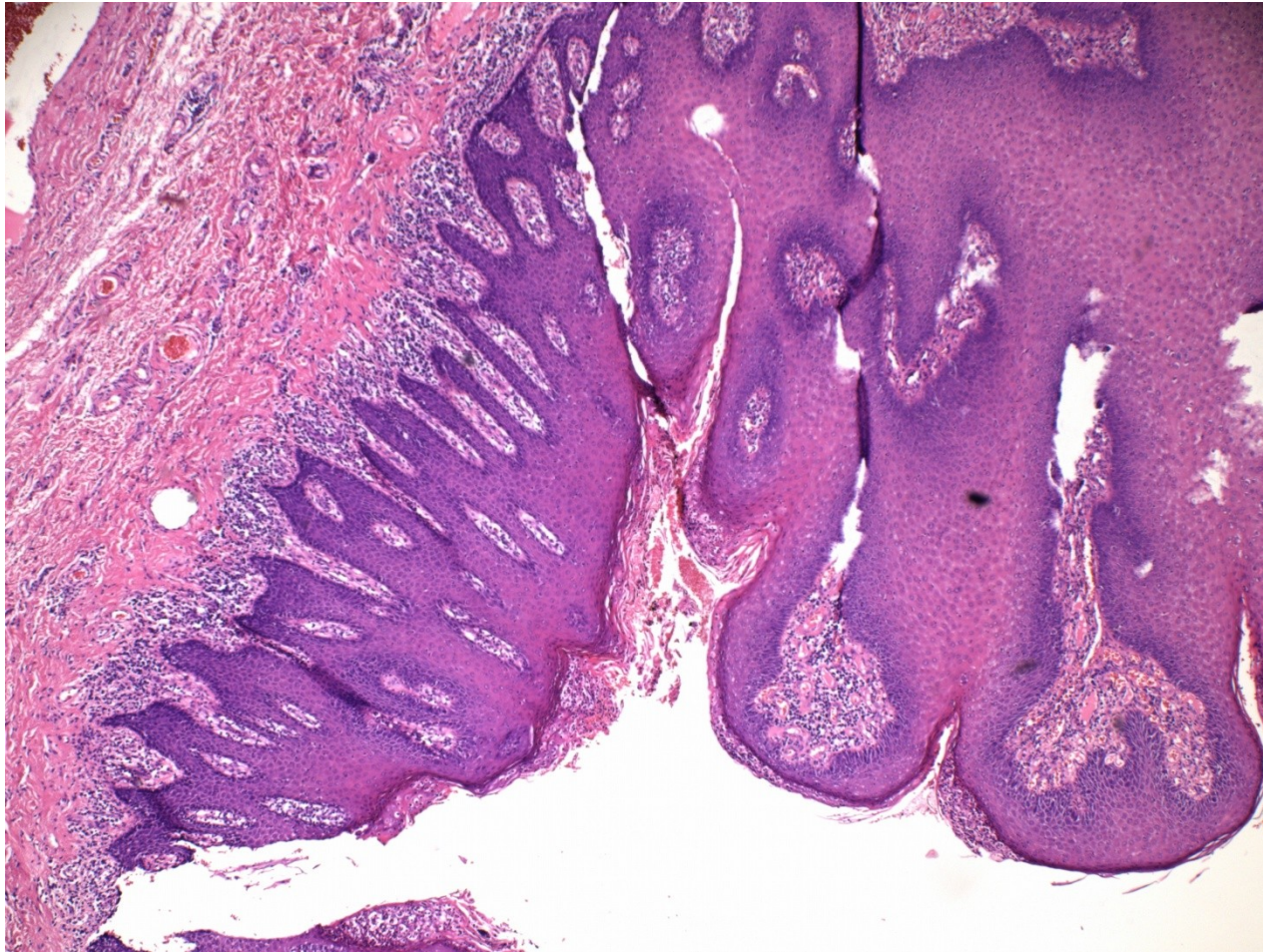
Balanoposthitis

- Glans + prepuce
- Sexually transmitted diseases – STD: syphilis, gonorrhoea, chancroid, herpes
- Non-specific infection: candida, pyogenic bacteria, anaerobic bacteria
- Poor hygiene – repeated infection
- Phimosis, chronic irritation

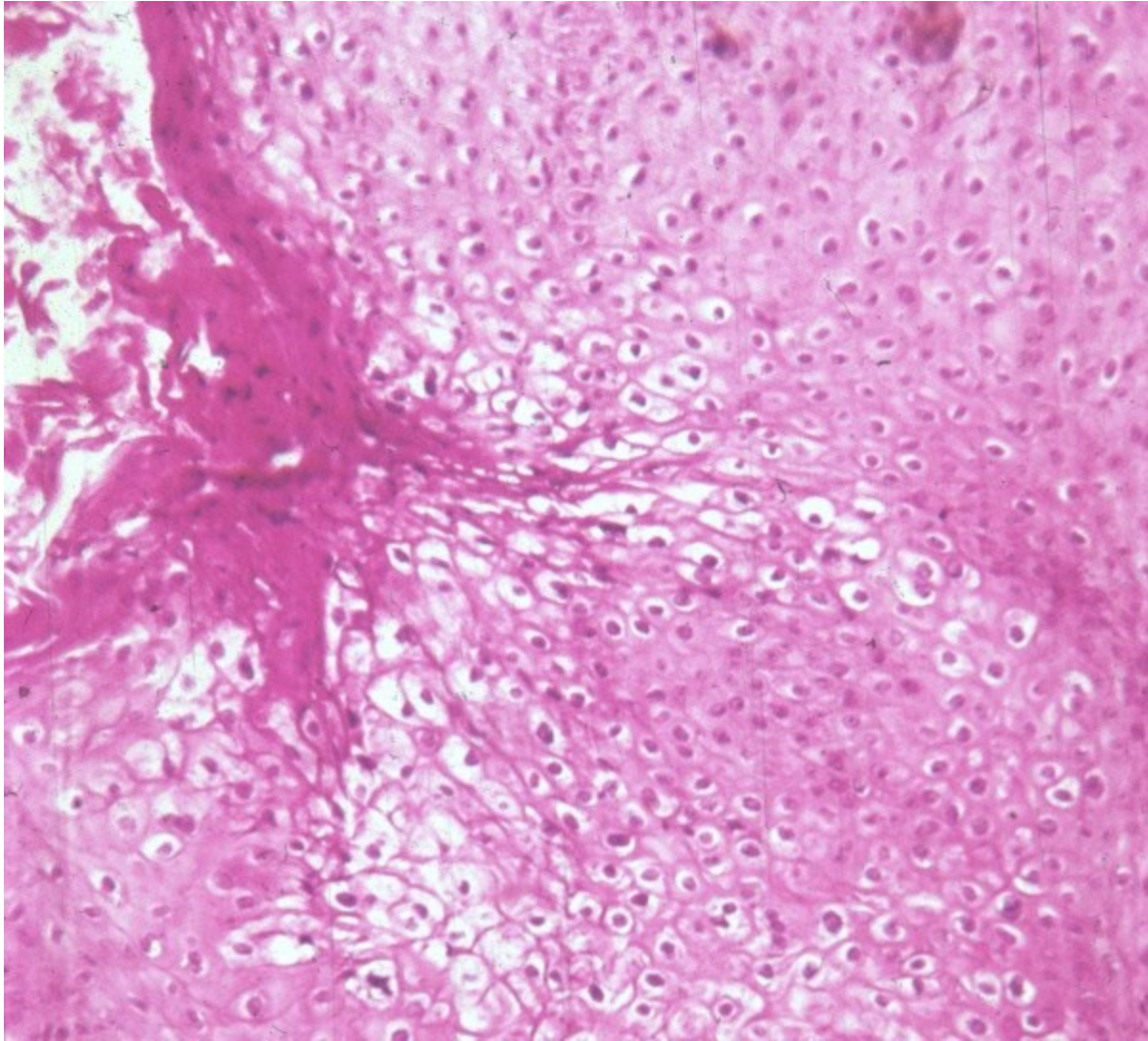
Viral infections

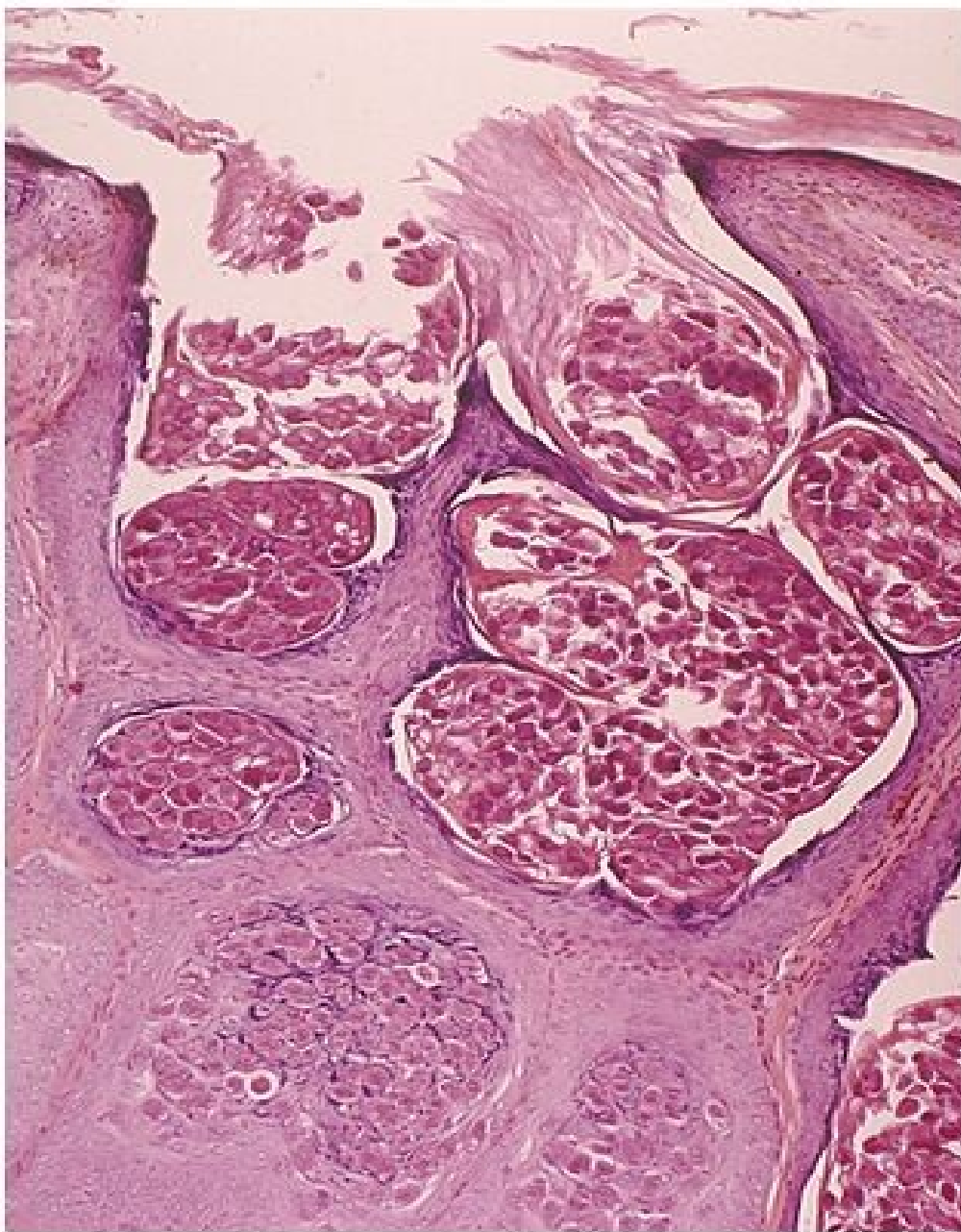
- inflammation +/- pseudotumorous lesion (molluscum contagiosum)
- benign tumors: **condyloma accuminatum** – HPV 6, 11) squamous cell papilloma
- preneoplastic lesion/intraepithelial neoplasia incl. carcinoma in situ
- HPV risk factor – HPV-associated neoplasia

Penile condyloma + psoriasis



condyloma accuminatum - HPV



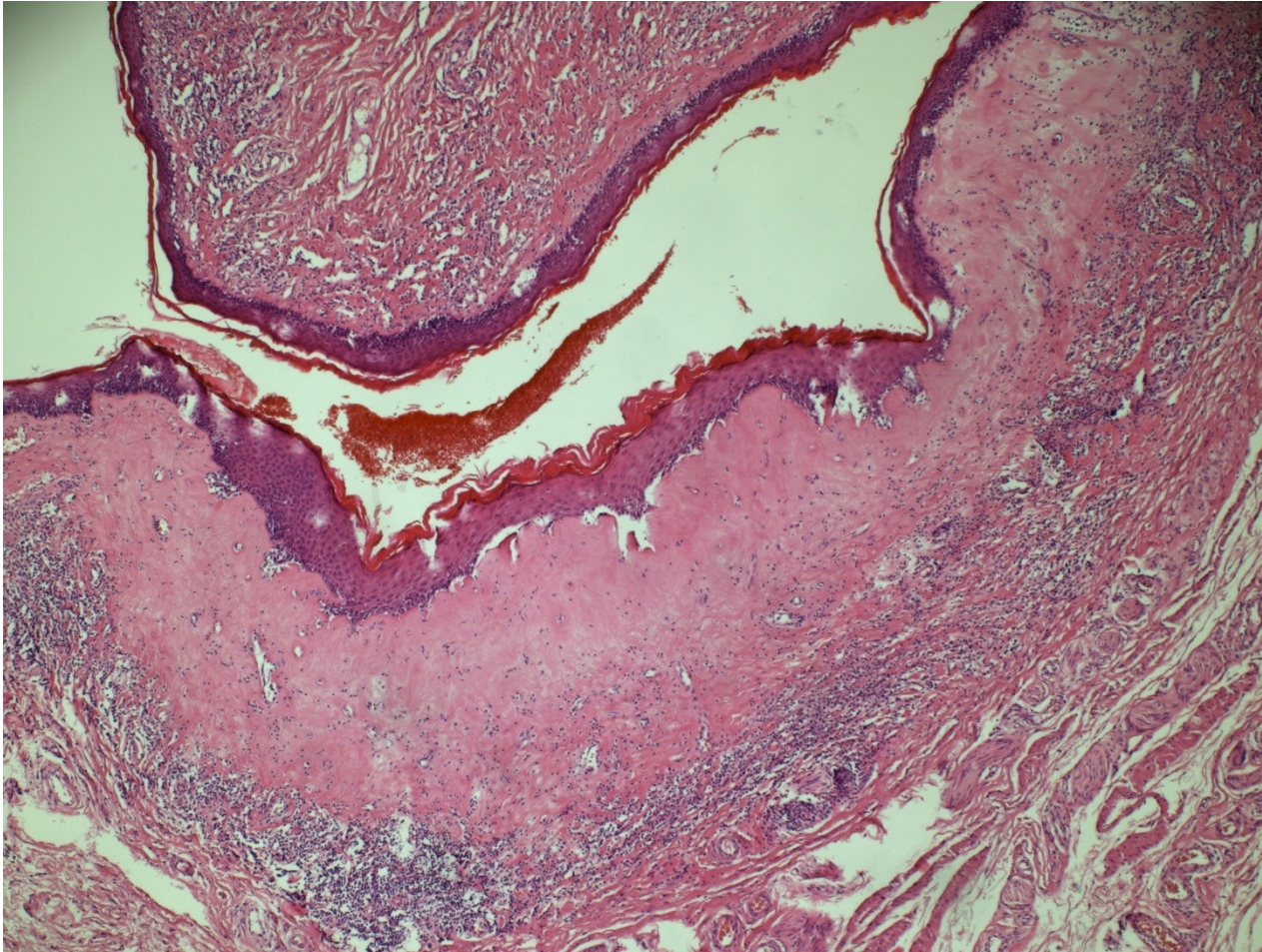


Molluscum contagiosum

Balanitis xerotica obliterans - lichen sclerosus

- chronic inflammatory disorder
- epithelial hyperkeratosis, atrophy, inflammatory infiltrate
- risky terrain for ca

Lichen sclerosus



Tumorous lesions

- Fibromatosis (Peyronie's disease) – deformation possible
- Pseudotumor - fibroepithelial polyp
- Benign tumors – HPV papilloma, adenoma

Malignant tumors

- Skin tumors (squamous cell carcinoma, melanoma)
- Mucosa tumors (various types of squamous cell carcinoma incl. exophytic verrucous ca)
- Urethral tumors
- Other primary tumors
- Secondary tumors

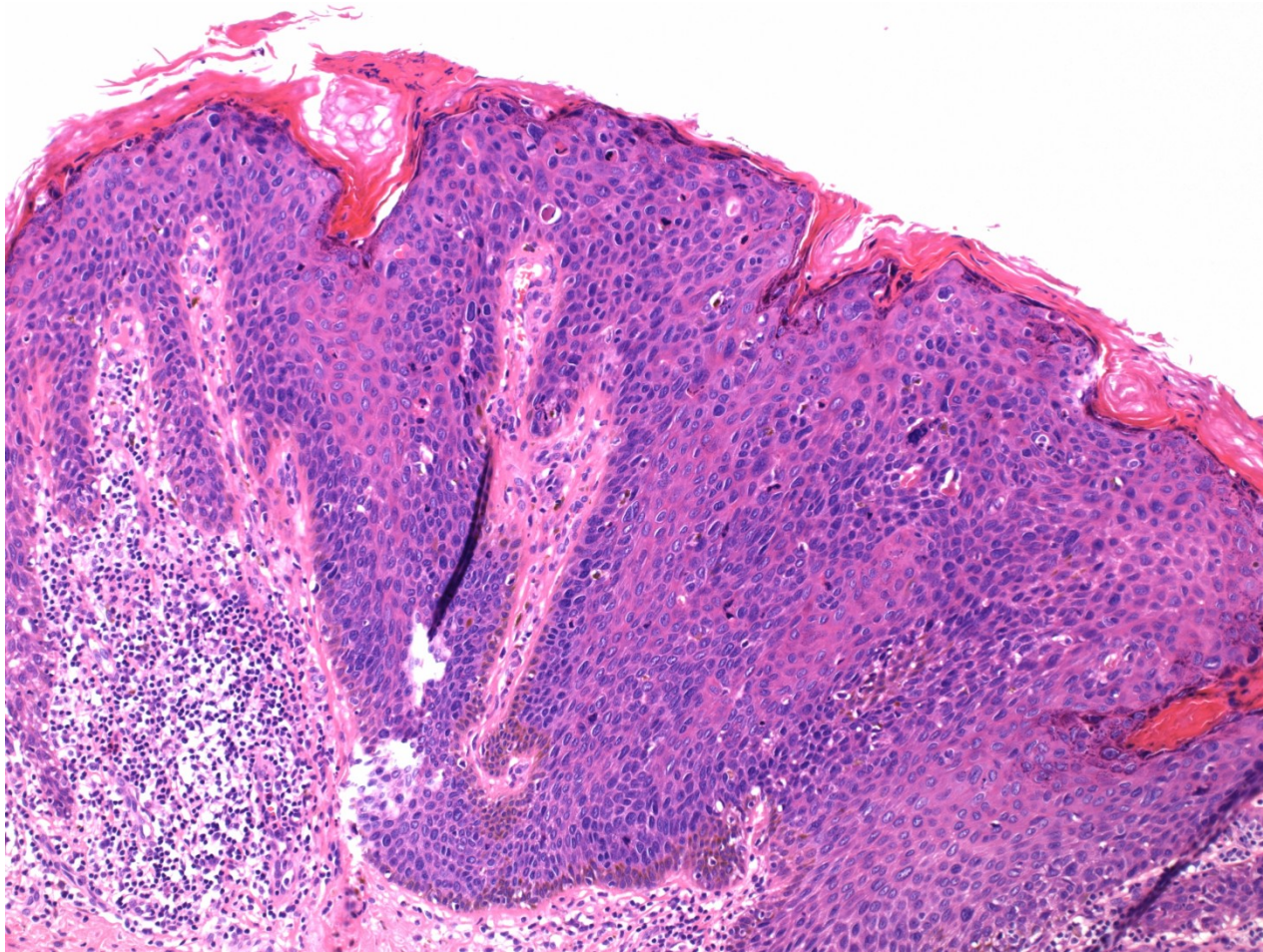
Penile intraepithelial neoplasia

- penile intraepithelial neoplasia
 - HPV-associated
 - high grade PeIN
 - differentiated PeIN, HPV independent
 - associated w. chronic inflammation – lichen sclerosus, smoking, trauma
 - always high grade

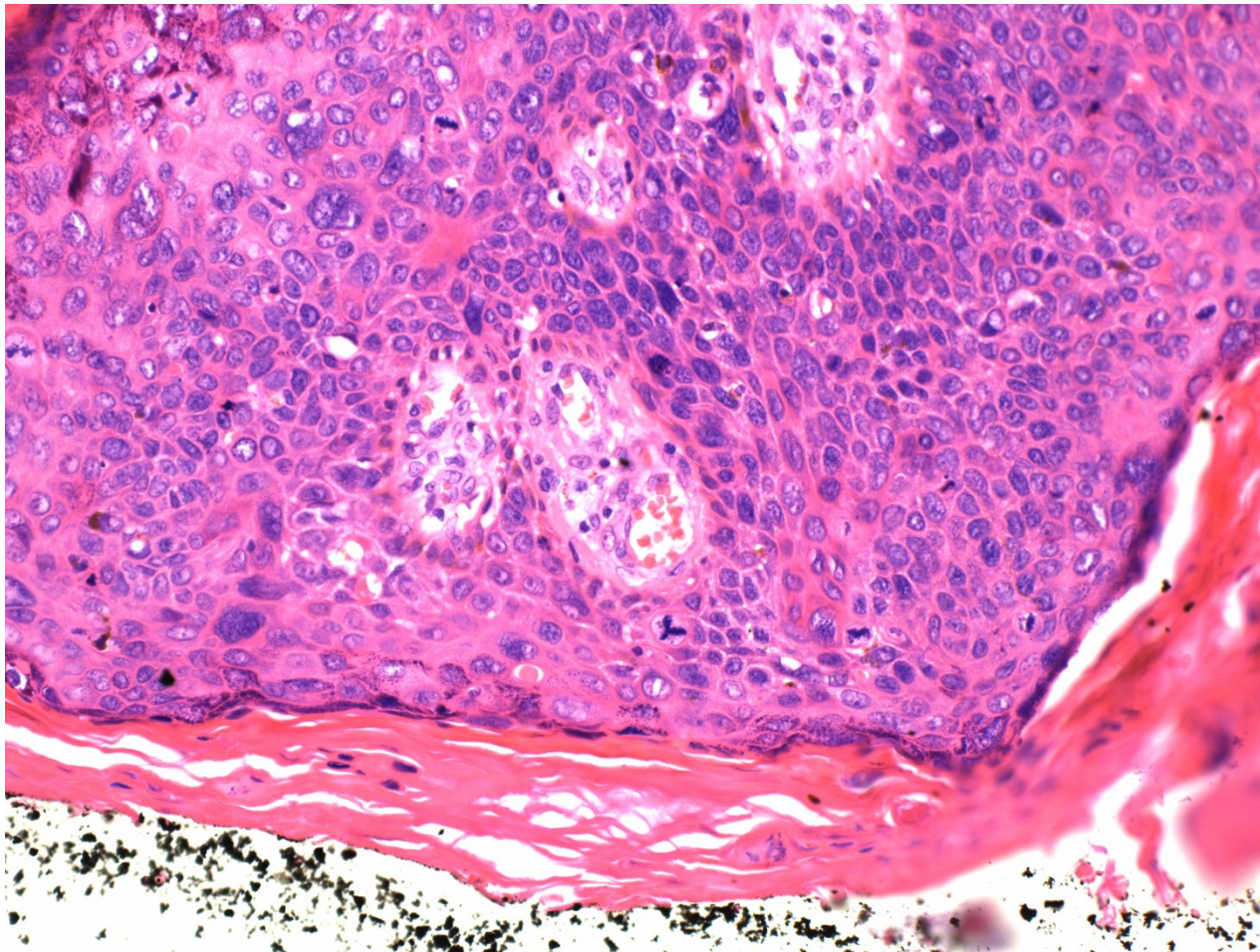
HPV-associated PeIN

- 80 % of PeIN
- Bowen's disease – clinical term for PeIN on the shaft (skin)
- erythroplasia of Queyrat - clinical term for PeIN on on the glans/foreskin - red focus on the mucosa

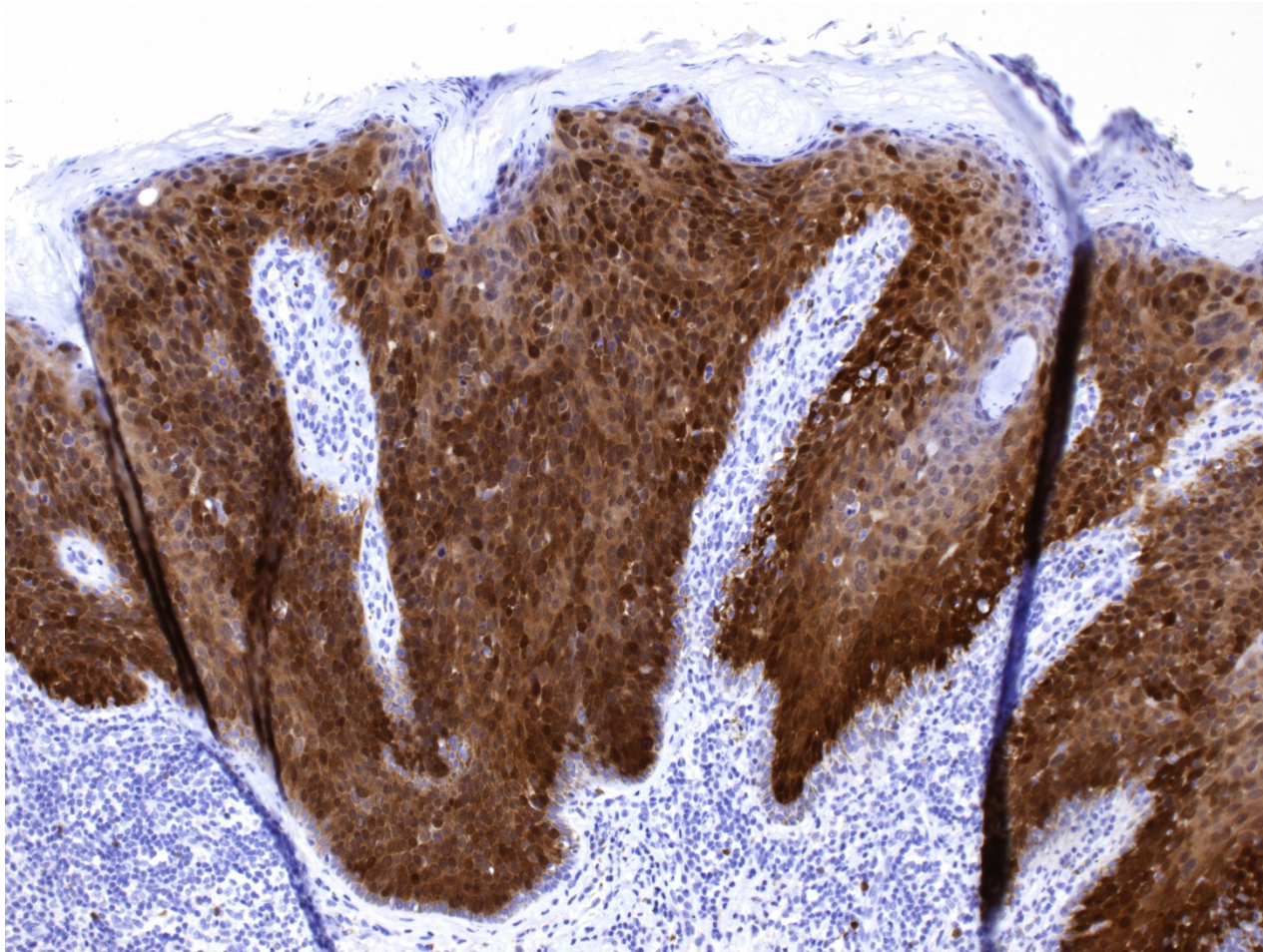
PeIN, HPV associated



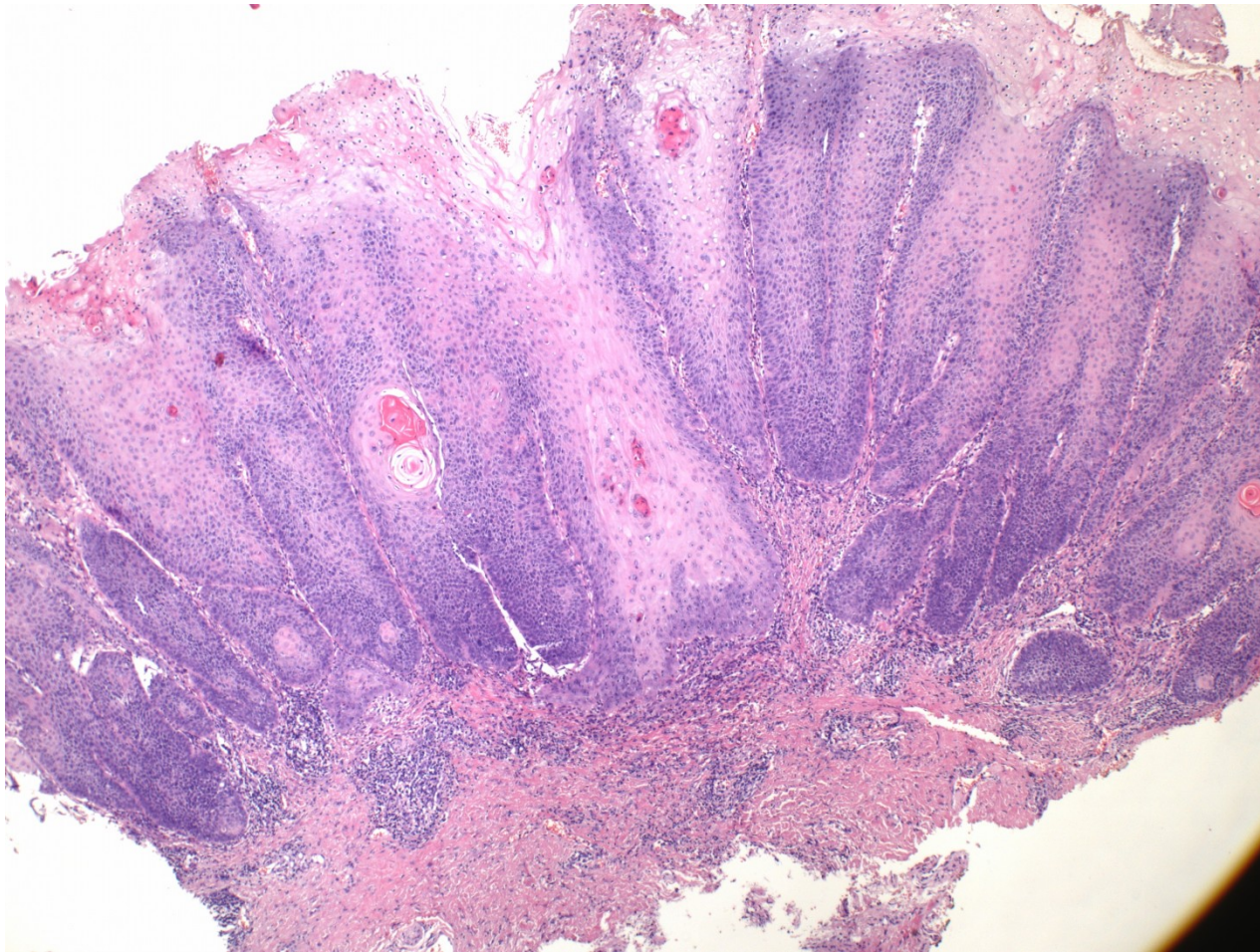
PeIN, HPV associated



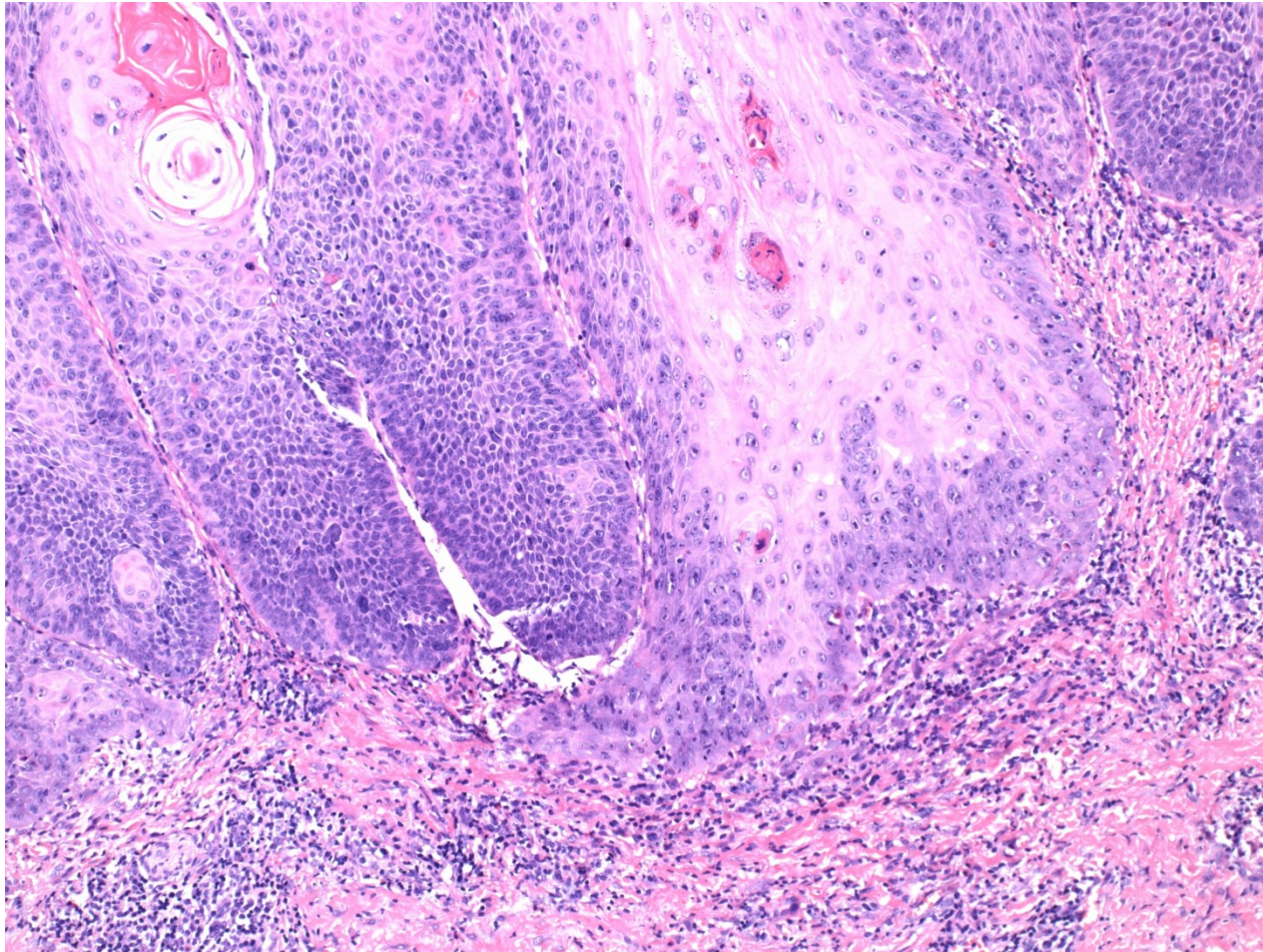
PeIN, HPV associated, IHC p16



Penile intraepithelial neoplasia - SCC

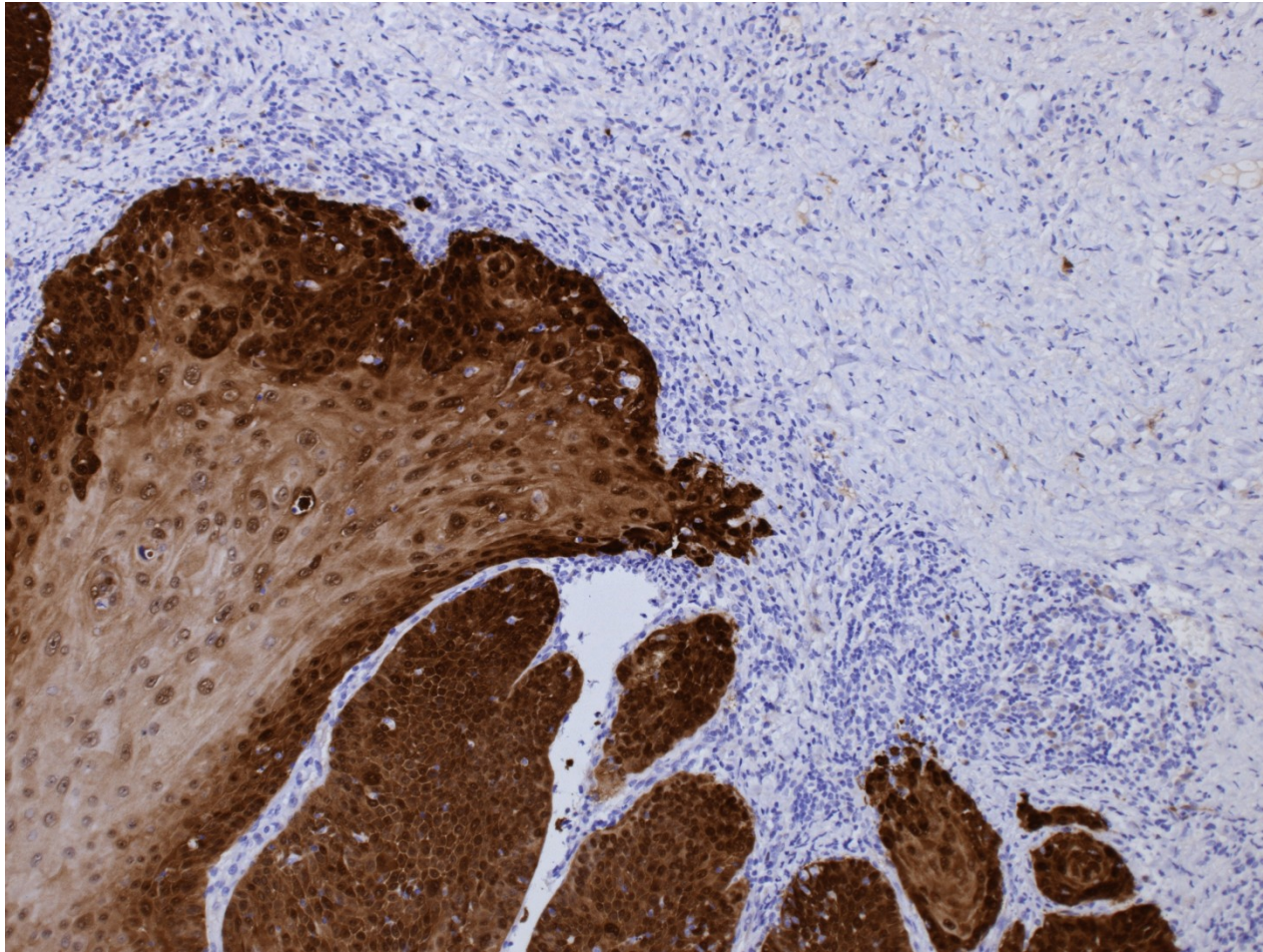


Penile intraepithelial neoplasia - SCC



Penile intraepithelial neoplasia – SCC

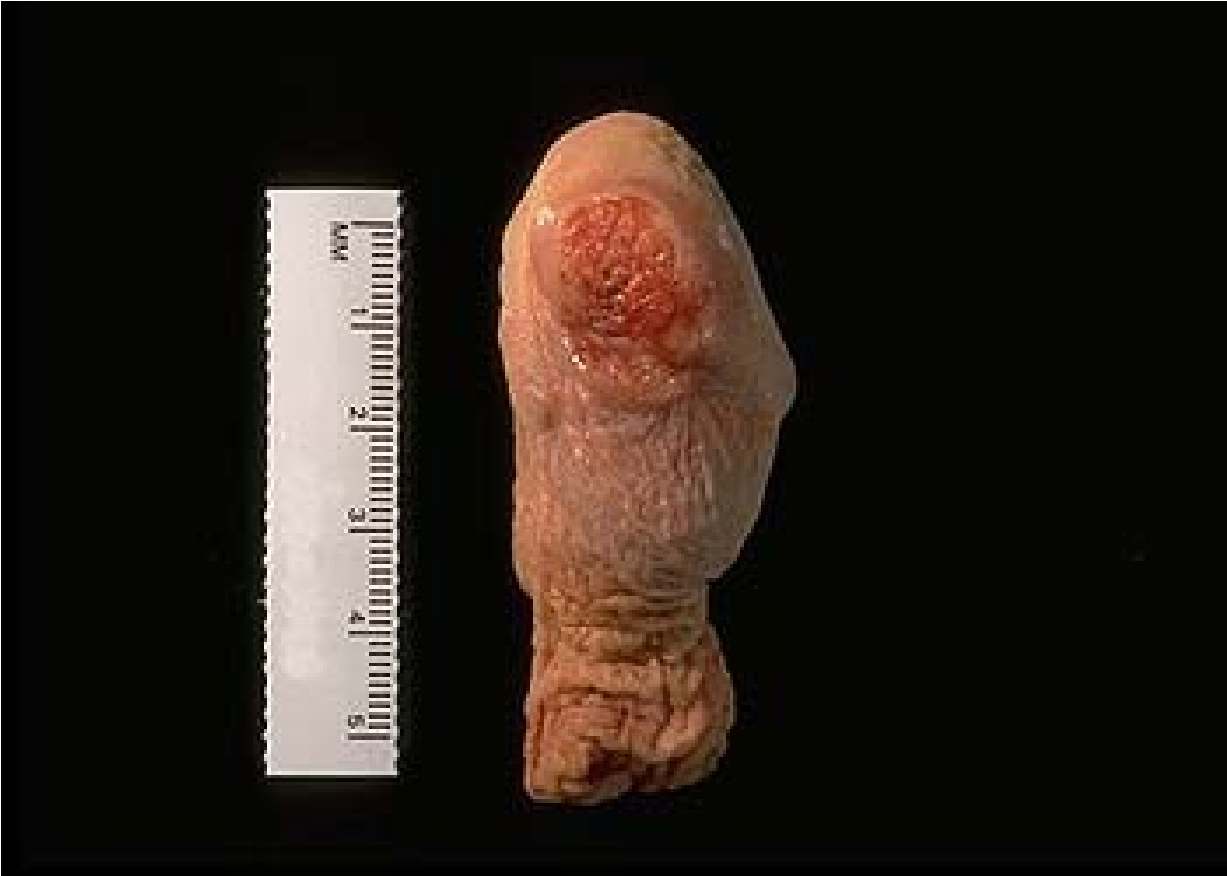IHC p16



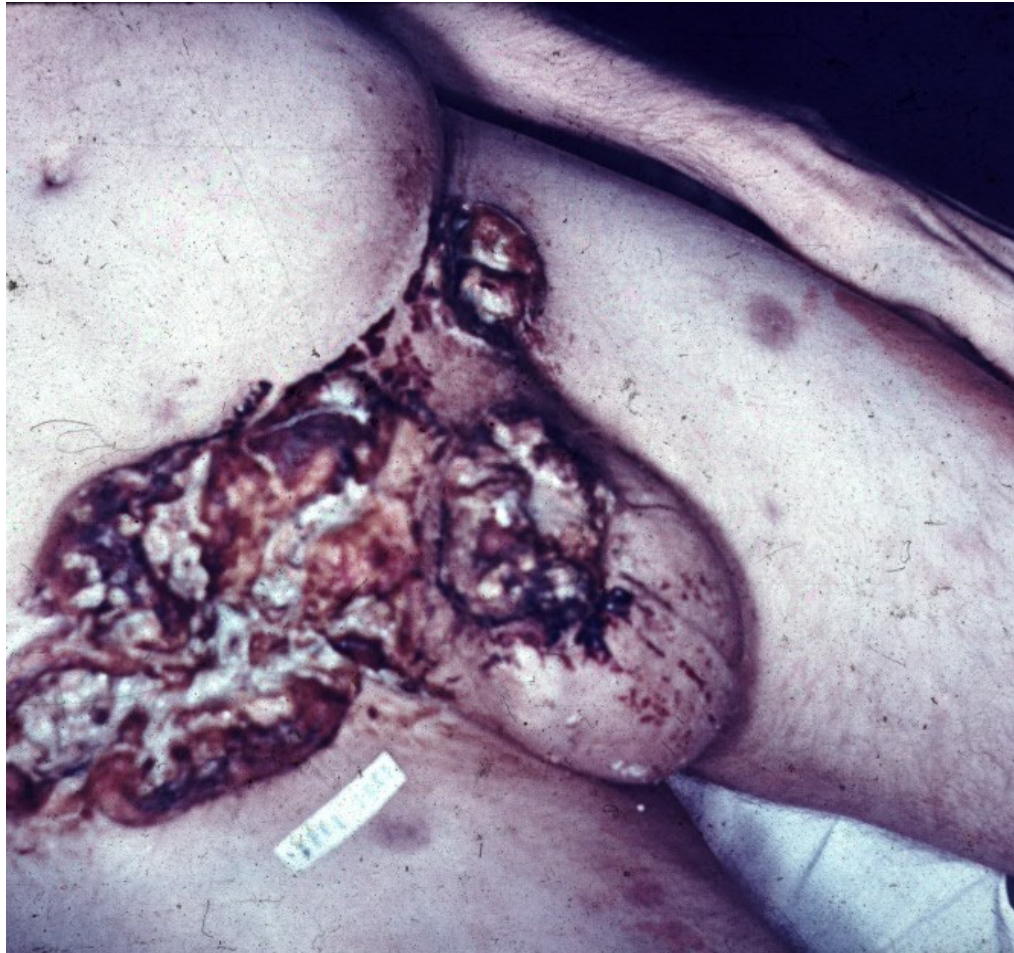
Invasive squamous cell ca

- geography (Latin America, East Asia)
- circumcision - protective factor (↓HPV, carcinogenes in smegma)
- risk factors – smoking, occupational (mineral oil, tar)
- gross – ulcer, non-healing lesion
- micro – sq. ca of variable type/grade
- HPV-associated
- HPV-independent

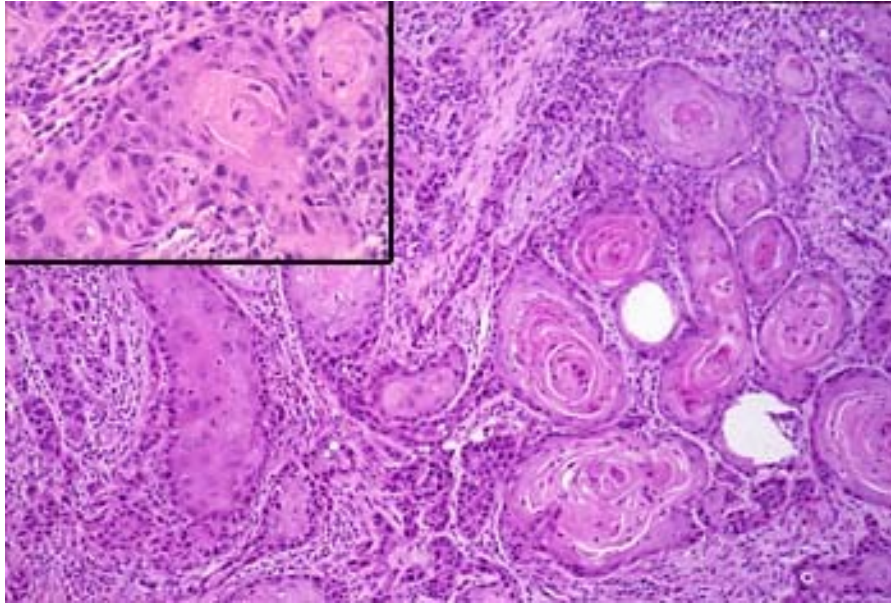
Carcinoma of the penis



Carcinoma of the penis



Squamous cell carcinoma of the penis



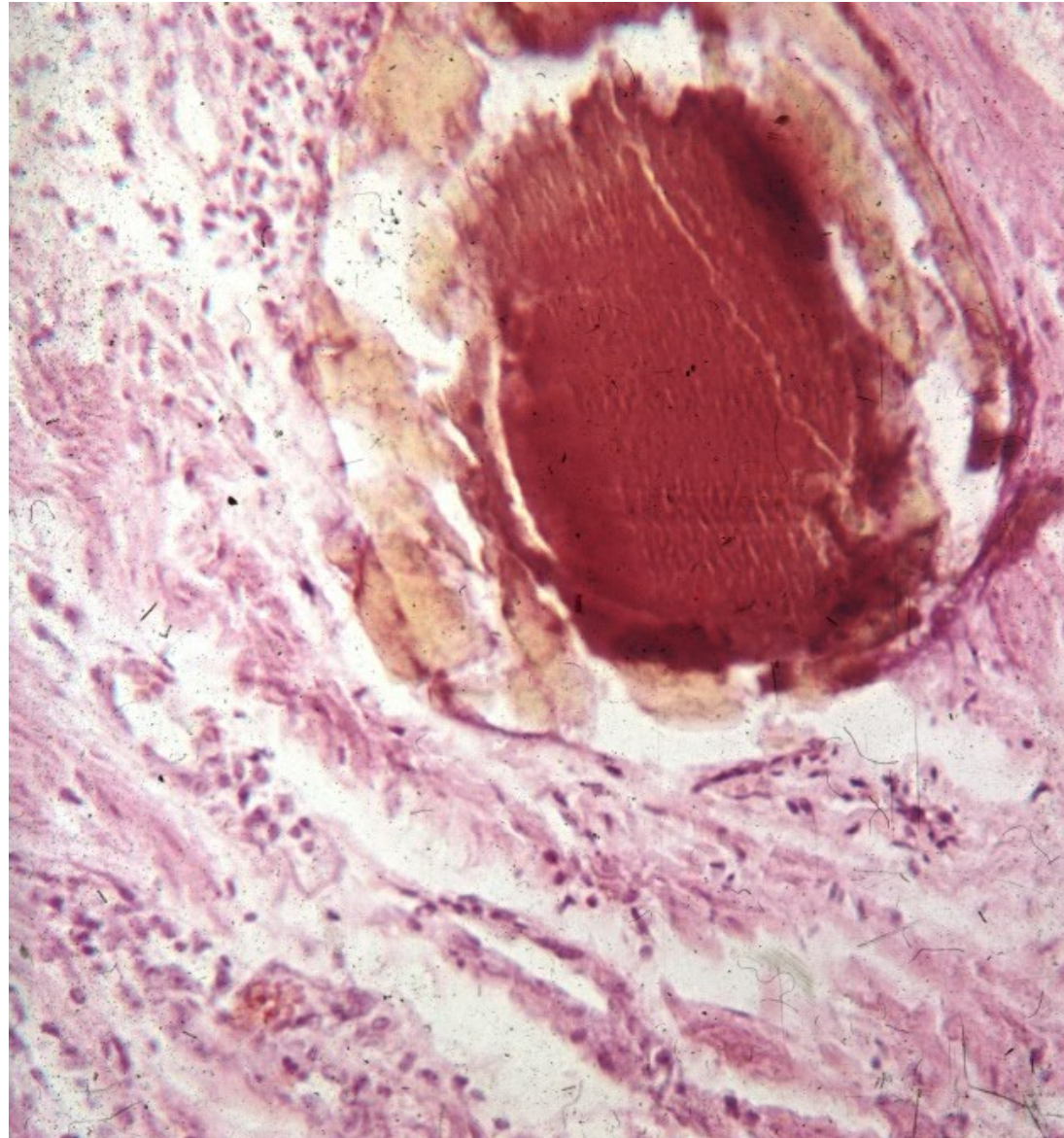
Prostate gland

- **infarction** (usually in hyperplastic prostate, repair with sq. cell metaplasia may mimic ca)
- **inflammation** (acute/chronic, a/bacterial, granulomatous)
- **benign nodular hyperplasia (adenomyomatous)** + related lesions
- **precancerous lesions, tumors** (PIN, adenocarcinoma, other)

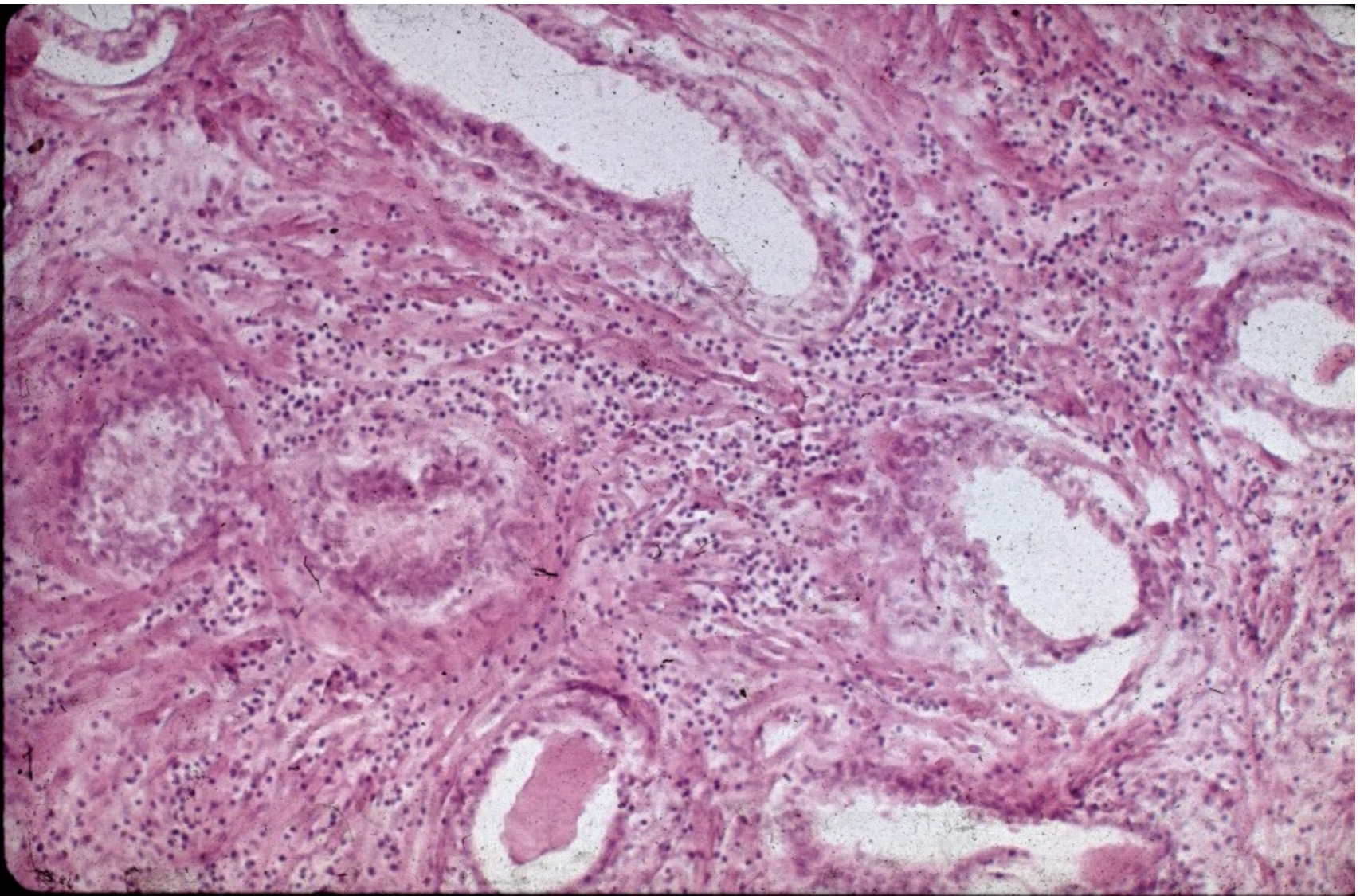
Inflammation

- **Acute bacterial**: ~ UTI, intraprostatic reflux of urine, iatrogenic – catheterization, cystoscopy, surgery. Pain, dysuria, fever.
- **Chronic bacterial**: repeated UTI, non-specific symptoms. Difficult to treat.
- **Chronic abacterial**: most common, no UTI, negative bacterial culture, reactive (+ prostatolithiasis), Chlamydia, ureaplasma
- **Granulomatous**: specific: Tb, BCG used for bladder ca; reactive

Prostatolithiasis



Chronic prostatitis

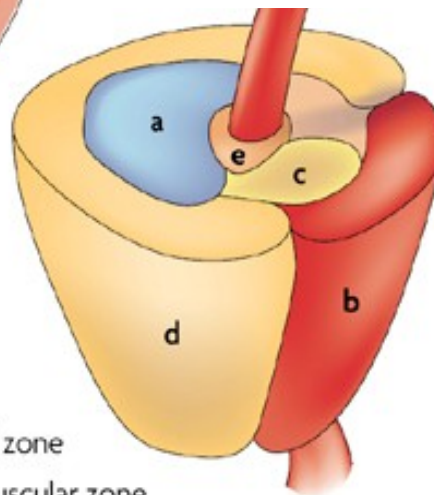
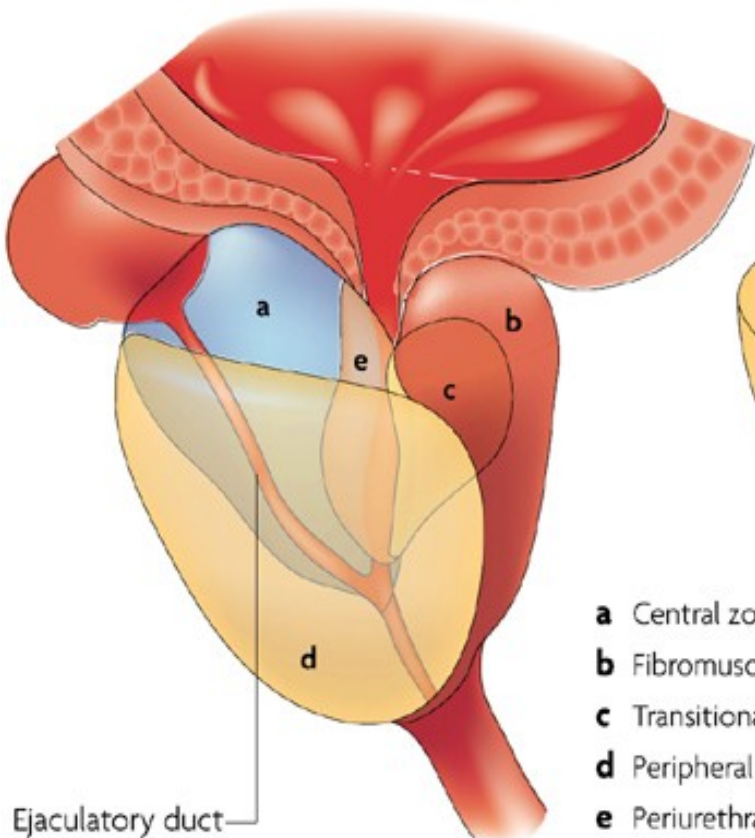


Zonal predisposition of prostate diseases

	Prostate zone		
	Peripheral	Transition	Central
Focal atrophy	Medium-high prevalence	Medium-high prevalence	Low prevalence
Acute inflammation	Low prevalence	Low prevalence	None
Chronic inflammation	Medium-high prevalence	Medium-high prevalence	Low prevalence
Benign prostatic hyperplasia	None	High prevalence	Low prevalence
High-grade PIN	Medium-high prevalence	Low prevalence	Low prevalence
Carcinoma	Medium-high prevalence	Low prevalence	None

	High prevalence		Low prevalence
	Medium-high prevalence		None

Prostate zones



- a** Central zone
- b** Fibromuscular zone
- c** Transitional zone
- d** Peripheral zone
- e** Periurethral gland region

Ejaculatory duct

Benign prostatic hyperplasia

- Common in older men, high incidence > 60 yrs
- Adenomyomatous hyperplasia – stromal (smooth muscle, fibrotic tissue) + glandular, alternating with atrophy, cystic and regressive changes. Two cellular layers – outer myoepithelial, inner secretory
- Gross: enlarged, nodular, firmer.
- Main changes in central (periurethral) region

Benign prostatic hyperplasia

- **Outcome:** partial → complete urethra obstruction, urinary residuum, risk of infection (+ ascending – pyelonephritis), bladder trabecular hypertrophy, hydronephrosis.
- Benign, but setting for possible preneoplastic changes
- Th: surgery, drugs

Benign prostatic hyperplasia

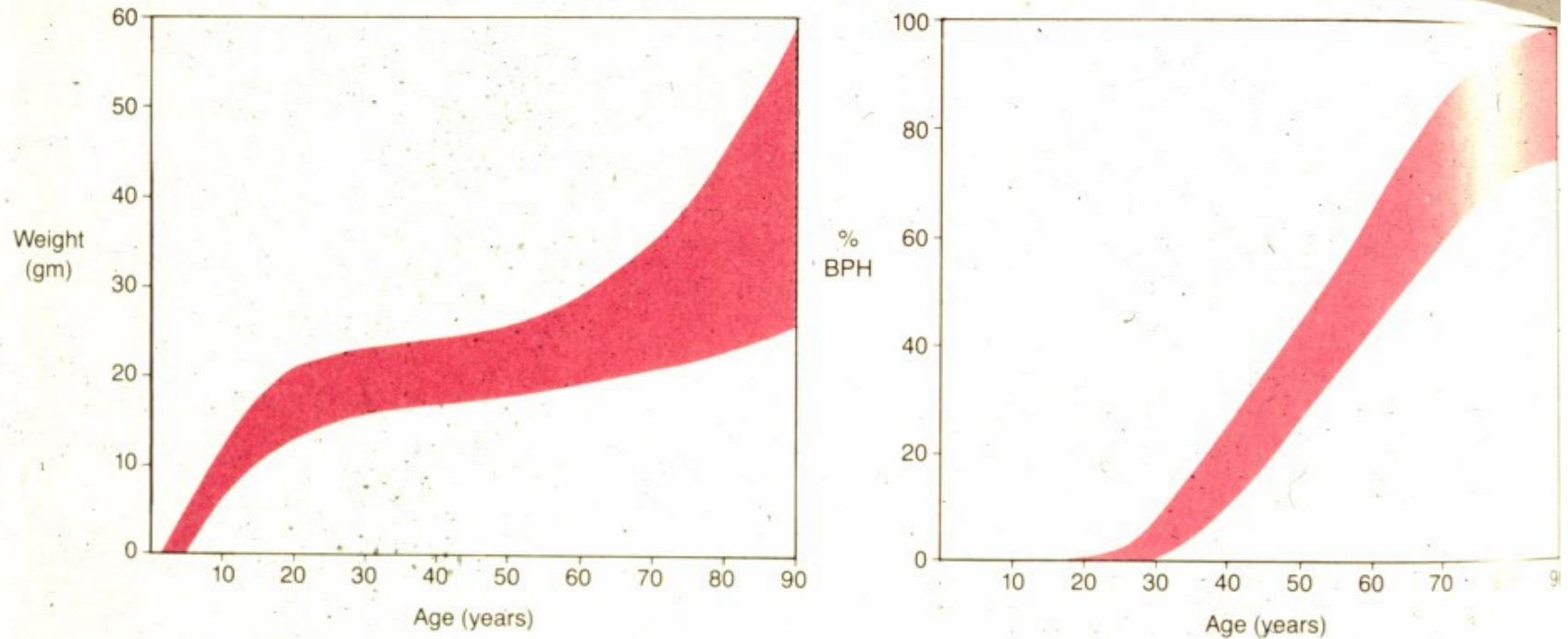
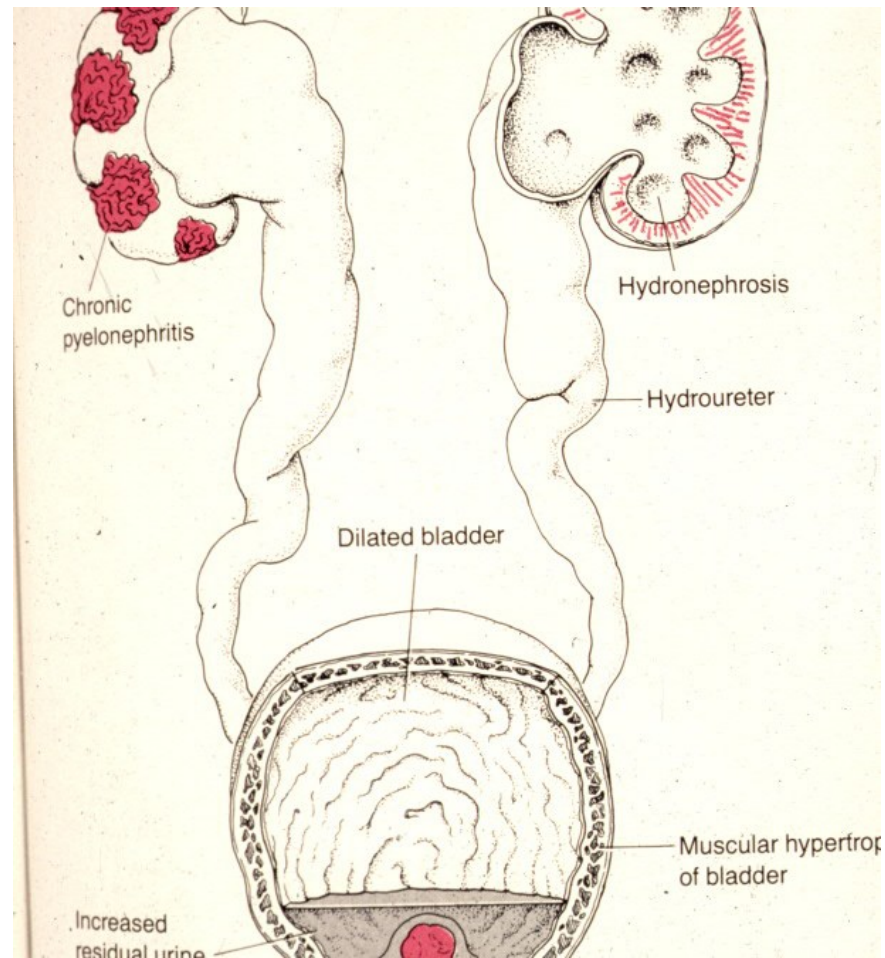


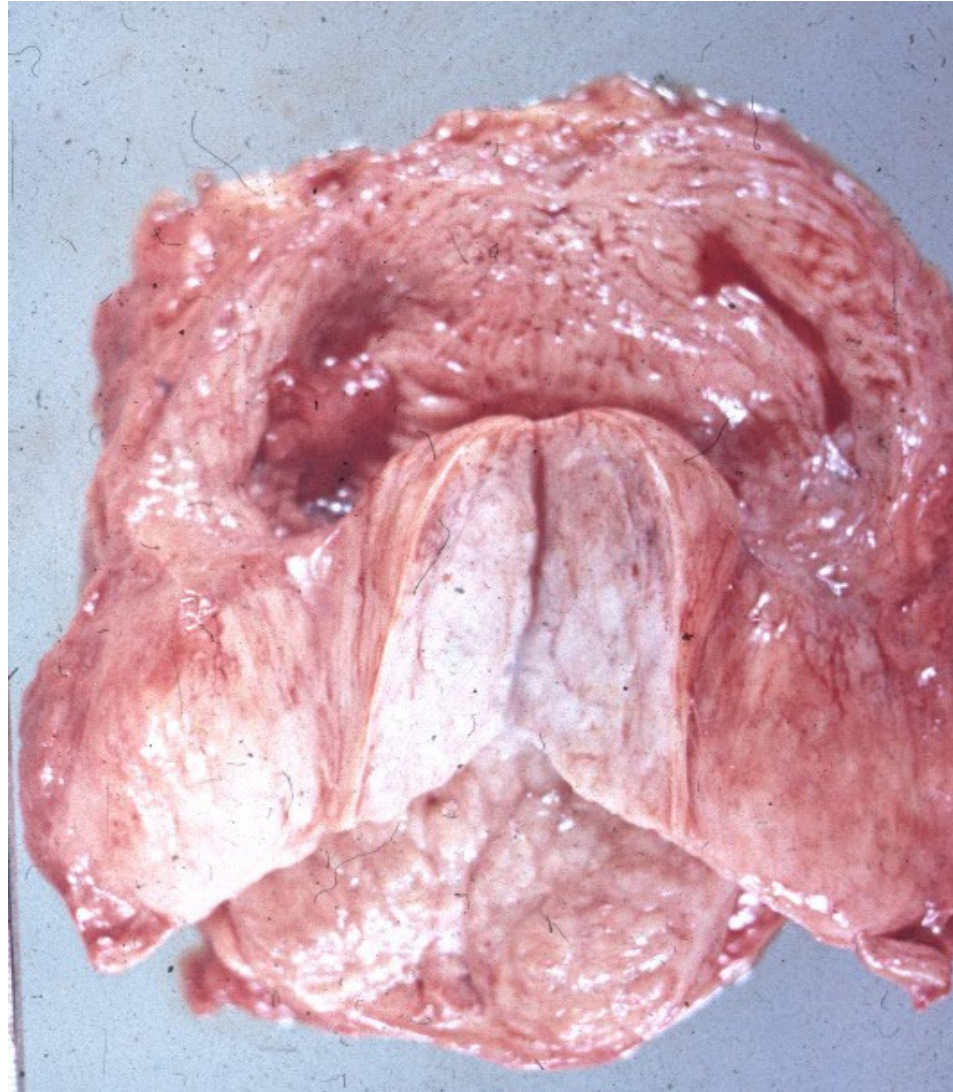
FIGURE 17-34

Growth of the prostate (*left*) and frequency of nodular hyperplasia (*right*). By 80 years of age, most men have benign prostatic hyperplasia.

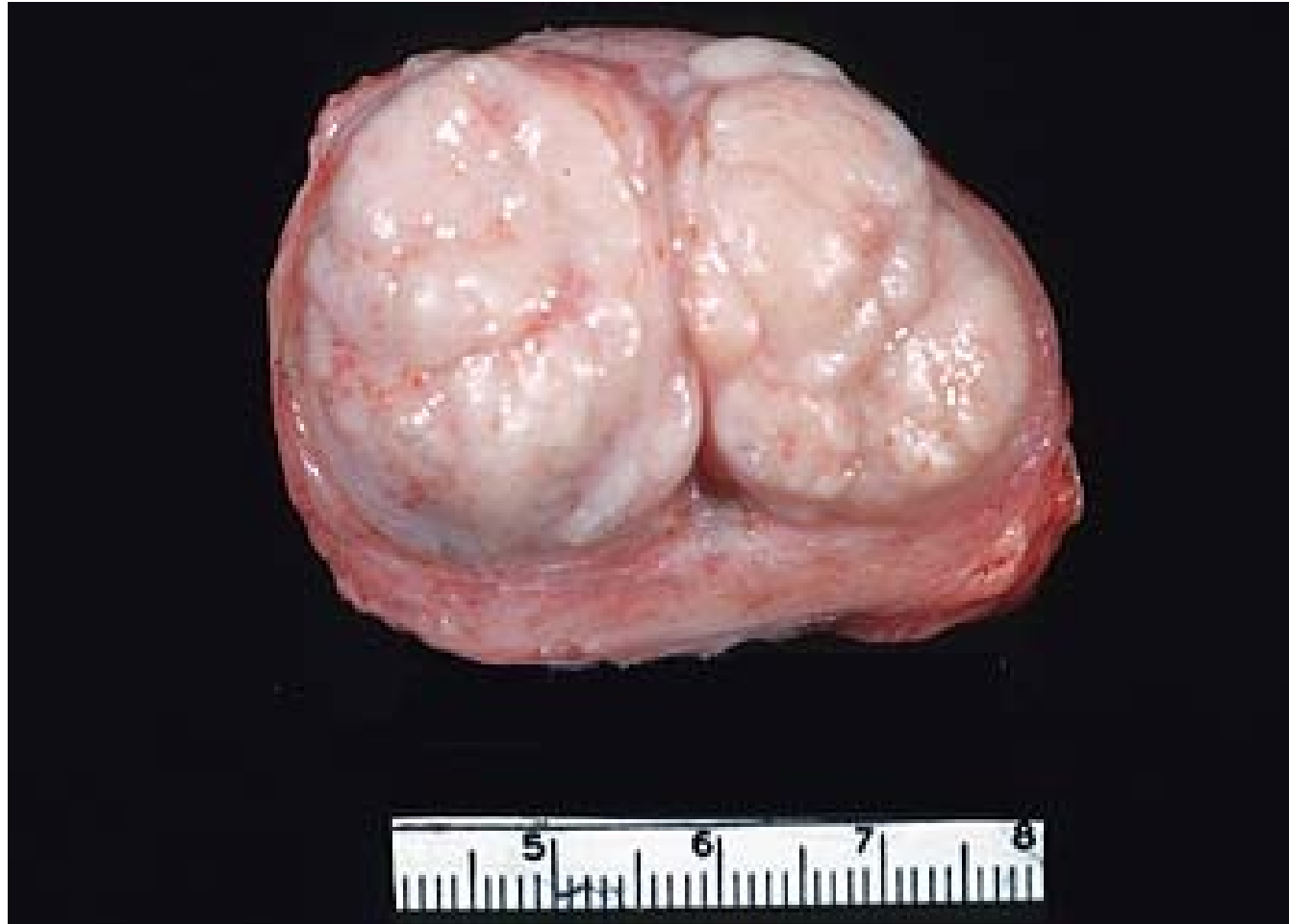Benign prostatic hyperplasia - complications



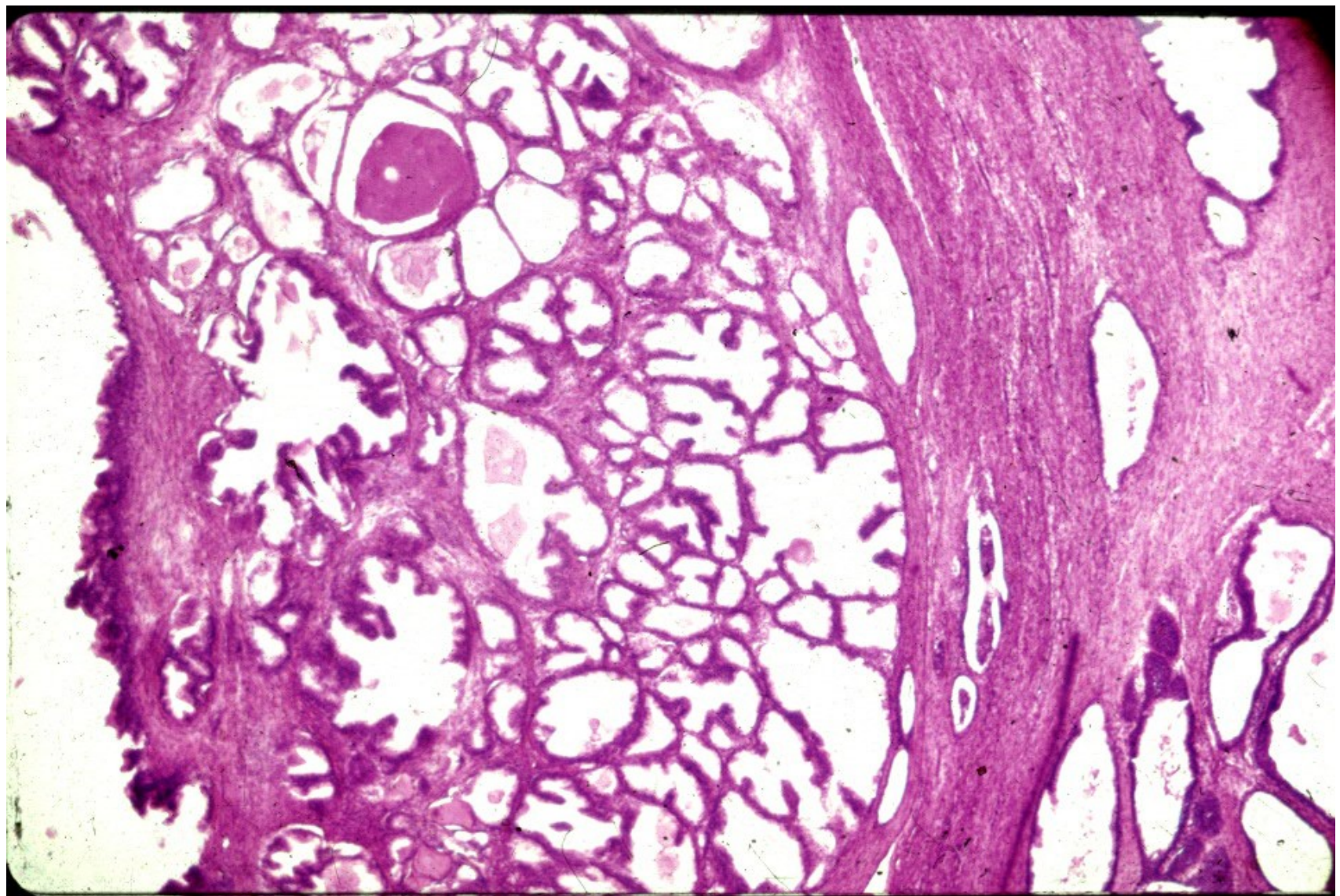
Benign prostatic hyperplasia



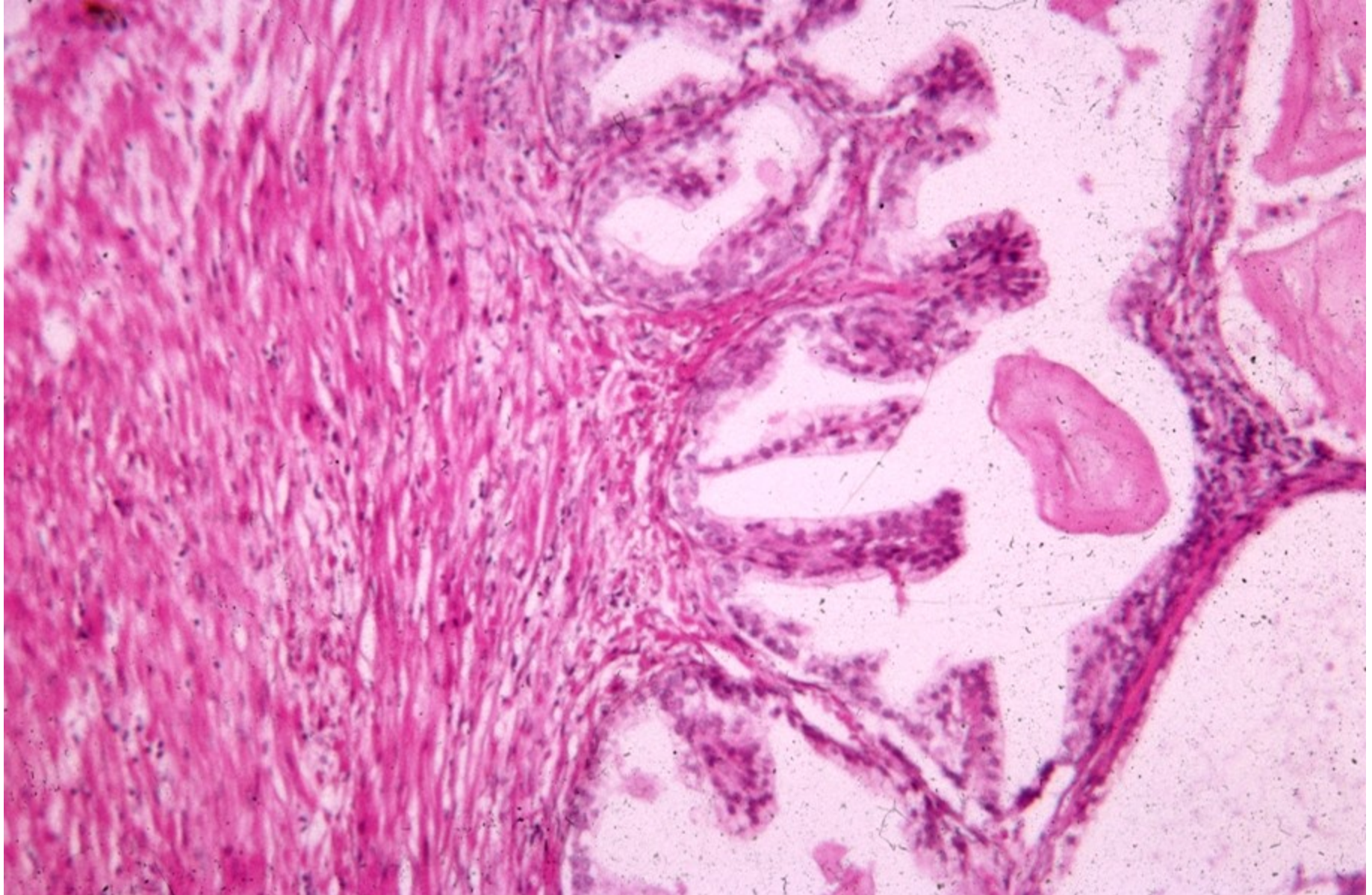Benign prostatic hyperplasia



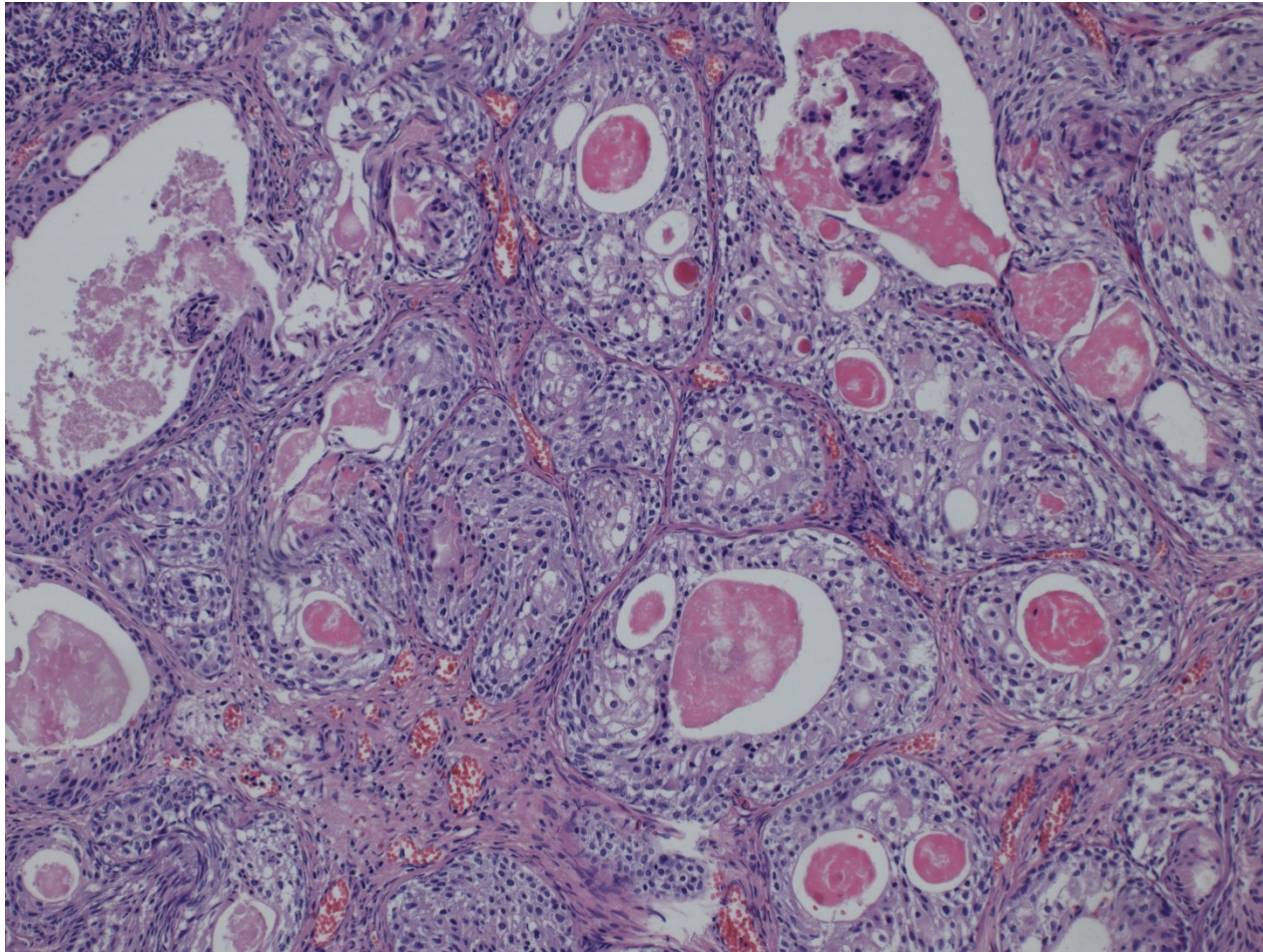
Benign prostatic hyperplasia



Benign prostatic hyperplasia



Prostate – squamous cell metaplasia



Pseudotumors, tumors:

- Benign prostatic hyperplasia
- Carcinoma
 - **Acinar**
 - Ductal
 - Squamous cell
 - Adenosquamous
 - Transitional cell
 - Neuroendocrine
- Secondary tumors
 - local ca infiltration from adjacent organs (bladder, rectum)
 - haematogenous metastases (lung ca, malignant melanoma, ..)

Prostatic carcinoma

- Adenocarcinoma: usually acinar, less common other types – ductal
- most common male ca (~1:6)
- late middle age – older males
- Highly variable course from clinically latent to extremely aggressive
- Screening (PSA) questions – possible overtreatment x late diagnosis

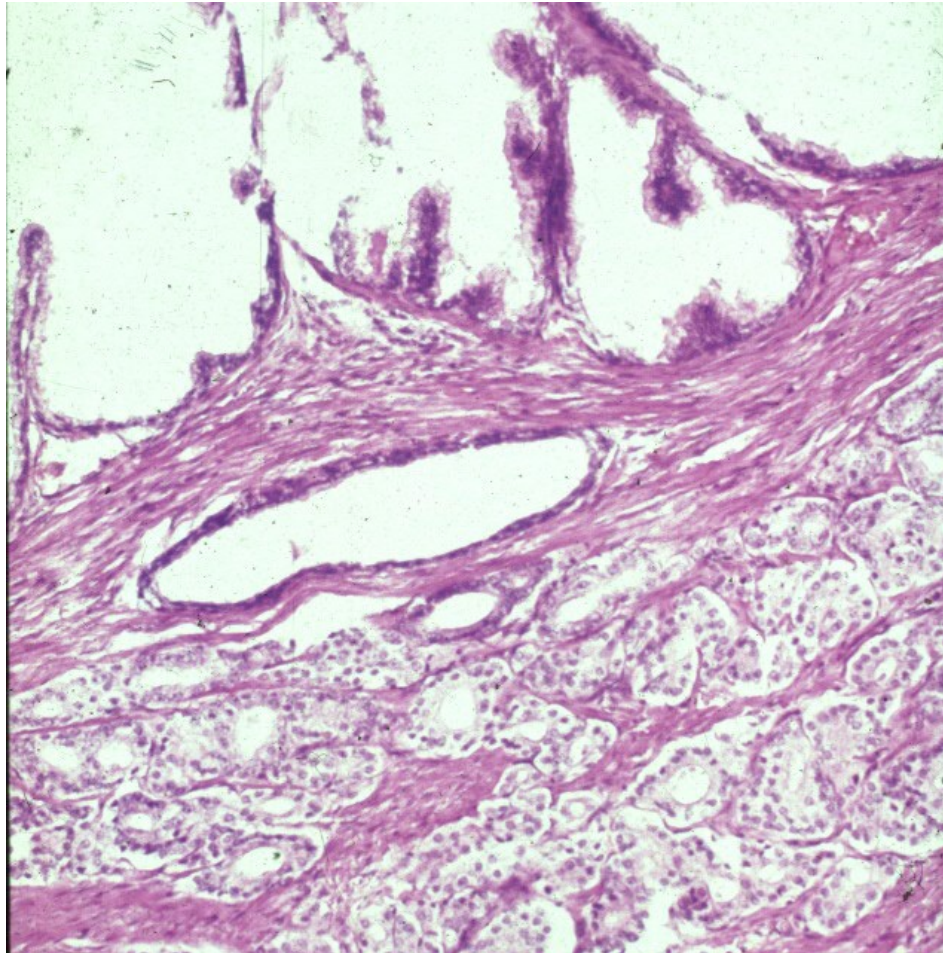
Prostatic carcinoma

- Important factors: race, family history, age, hormone level (androgenes), environment
- Peripheral part (dorsal) – per rectum
- PIN: prostatic intraepithelial neoplasia – precursor lesion. High grade PIN important + included into pathological report
- Distinctive nucleoli, architectural changes, in PIN myoepithelial layer still present

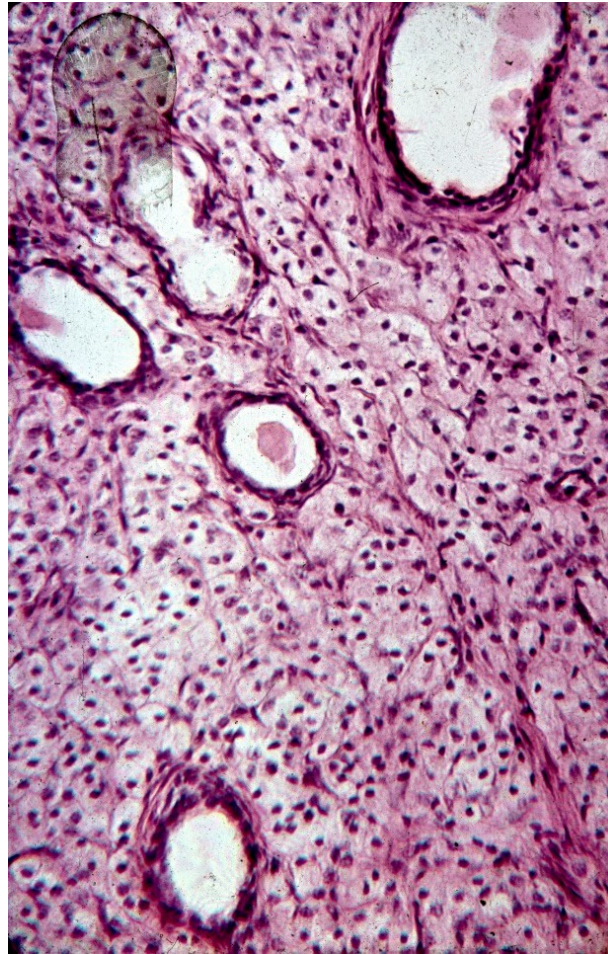
Prostatic carcinoma + hyperplasia



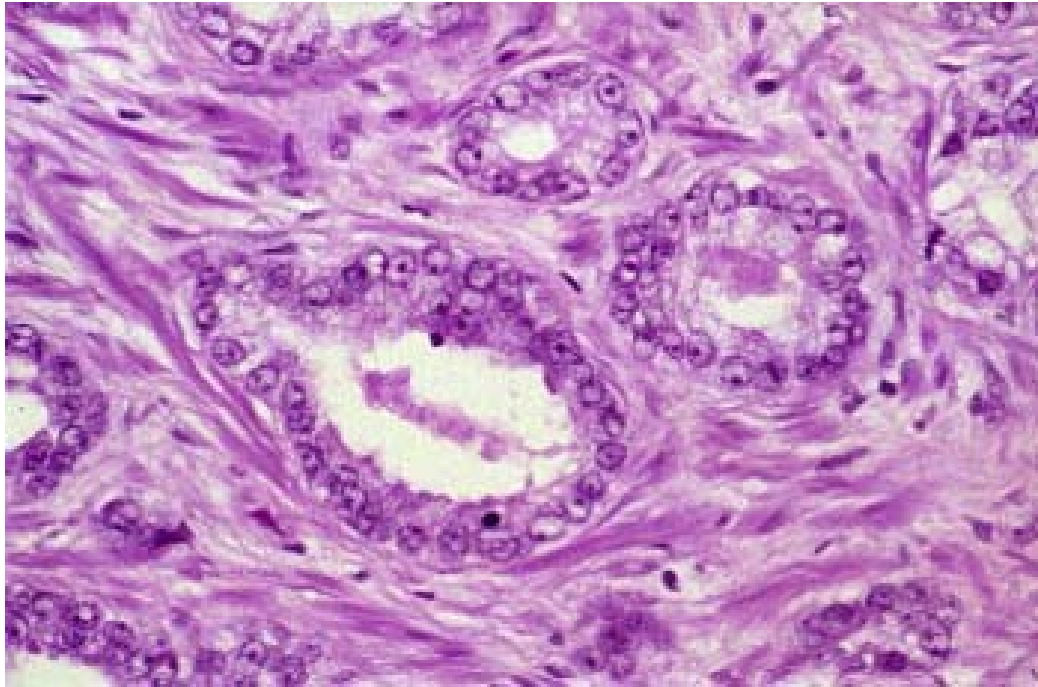
Prostatic carcinoma



Prostatic carcinoma



Prostatic carcinoma



Acinar prostatic adenocarcinoma

- **Gleason histologic grading (WHO modification):**

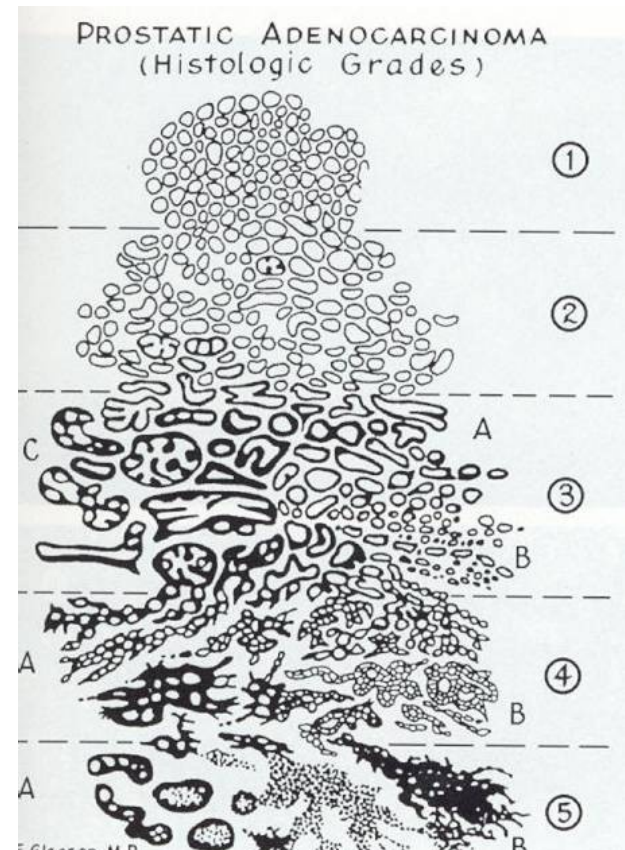
- **grade of glandular differentiation, growth pattern**

- **combined score - dominant + secondary pattern in 5-grade system**

- grade 1 similar to normal prostatic tissue (uncommon in ca)

- grade 5 with solid, dissociated pattern

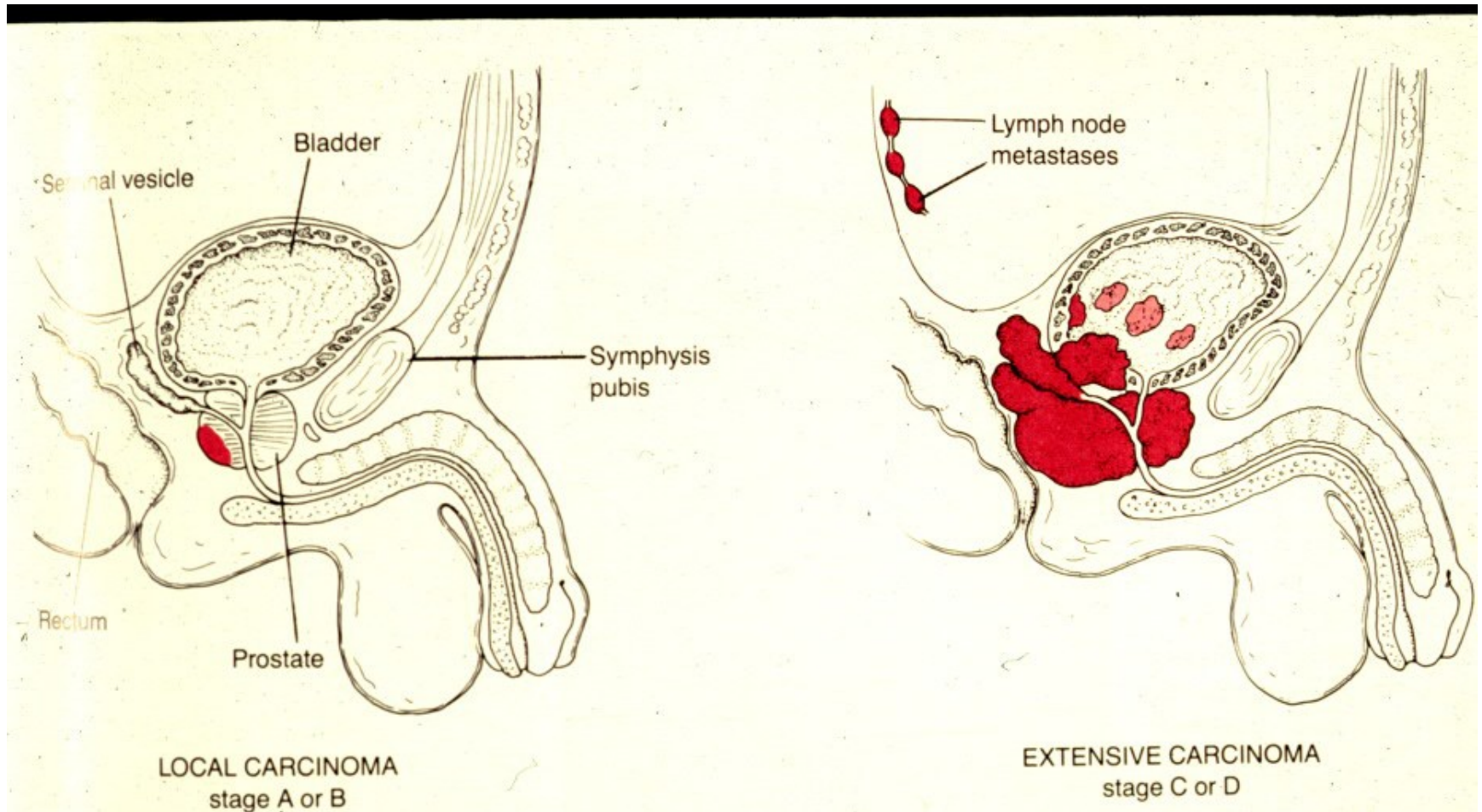
- final combined score, commonly Gleason score 7 (4+3)



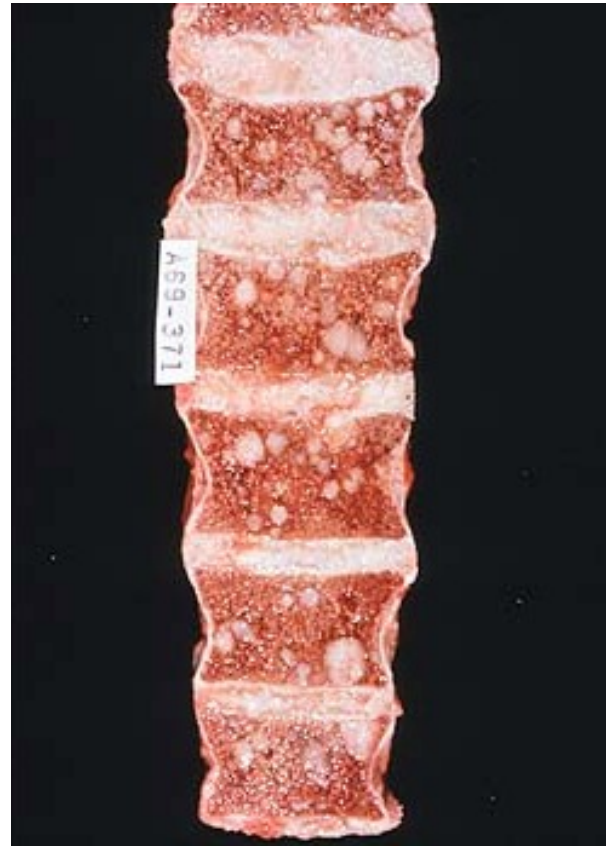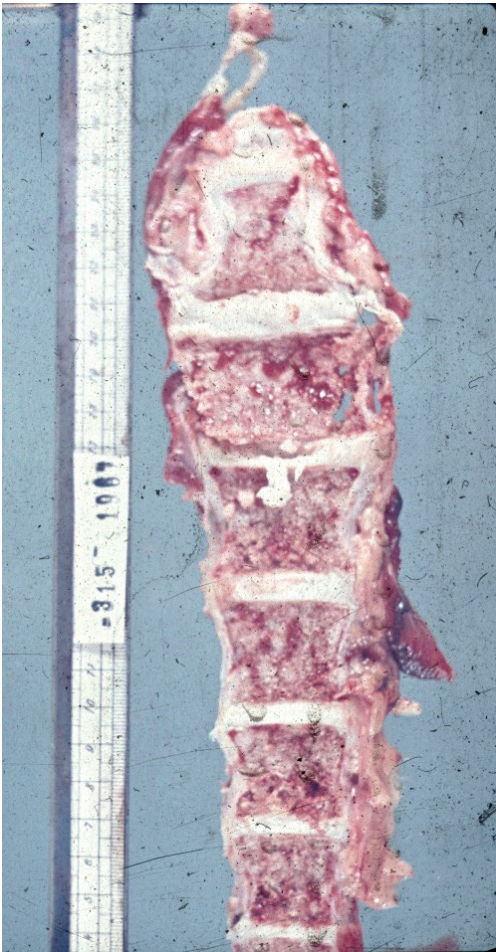Prostatic carcinoma

- Local spread – into urinary bladder; diff. dg x high grade transitional cell ca, may be concurrent
- Metastatic spread: regional lymph nodes, hematogenous typical into bones – osteoplastic meta
- Symptoms – urinary commonly late, more due to prostatic hyperplasia; local spread; meta

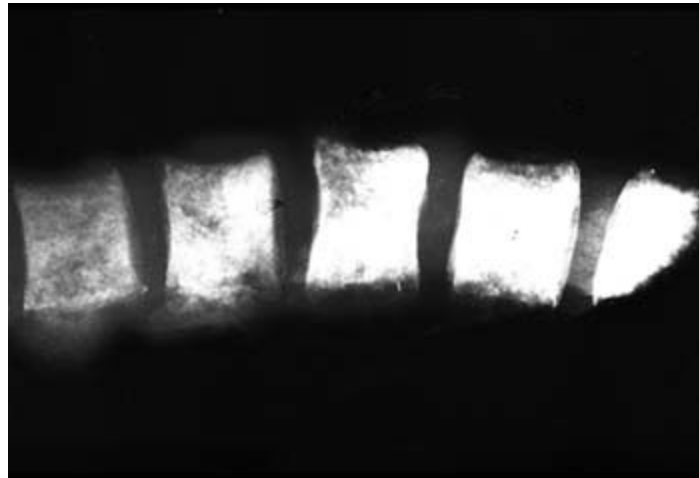
Prostatic carcinoma



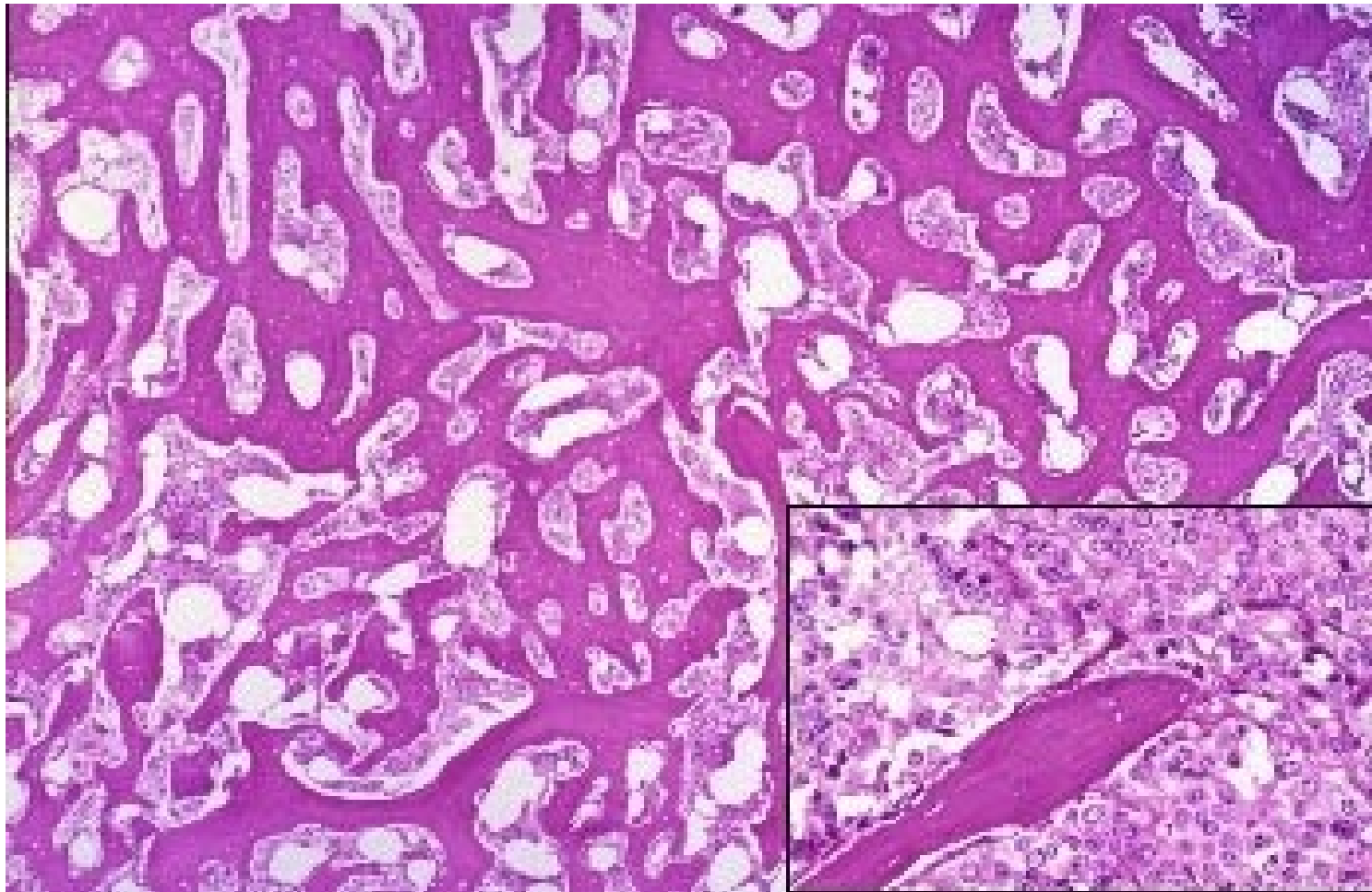
Prostatic carcinoma - spine metastases



Prostatic carcinoma - spine metastases, X-ray



Prostatic ca metastasis in bone



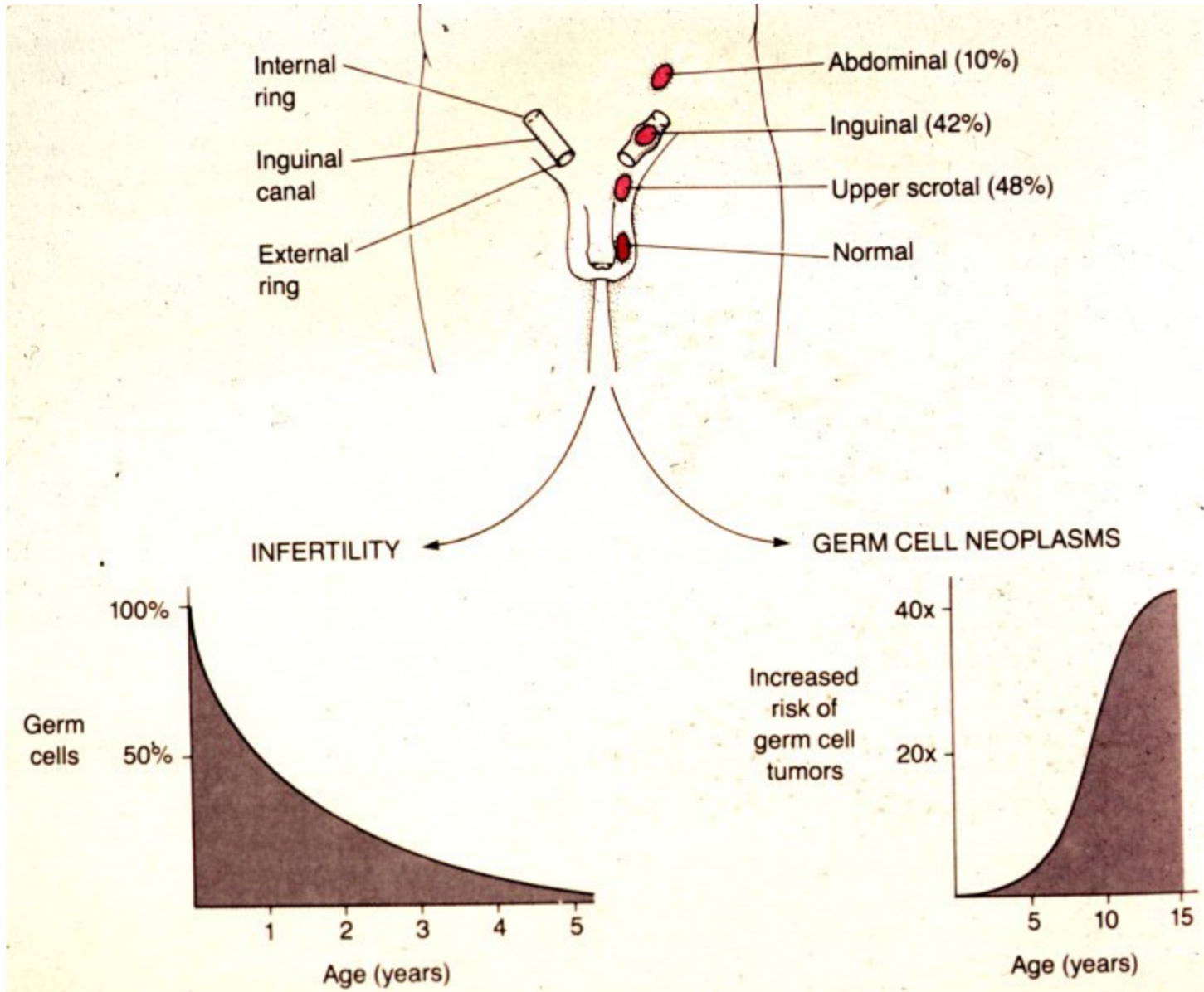
Testis, epididymis, cord

- **congenital** (cryptorchidism – atrophy, risk of neoplasia)
- **regressive changes** (atrophy, torsion)
- **inflammation** (orchitis – nonspecific acute/chronic, STD (gonorrhoea, syphilis, chlamydia), mumps, tbc, idiopathic granulomatous)
- **tumors**

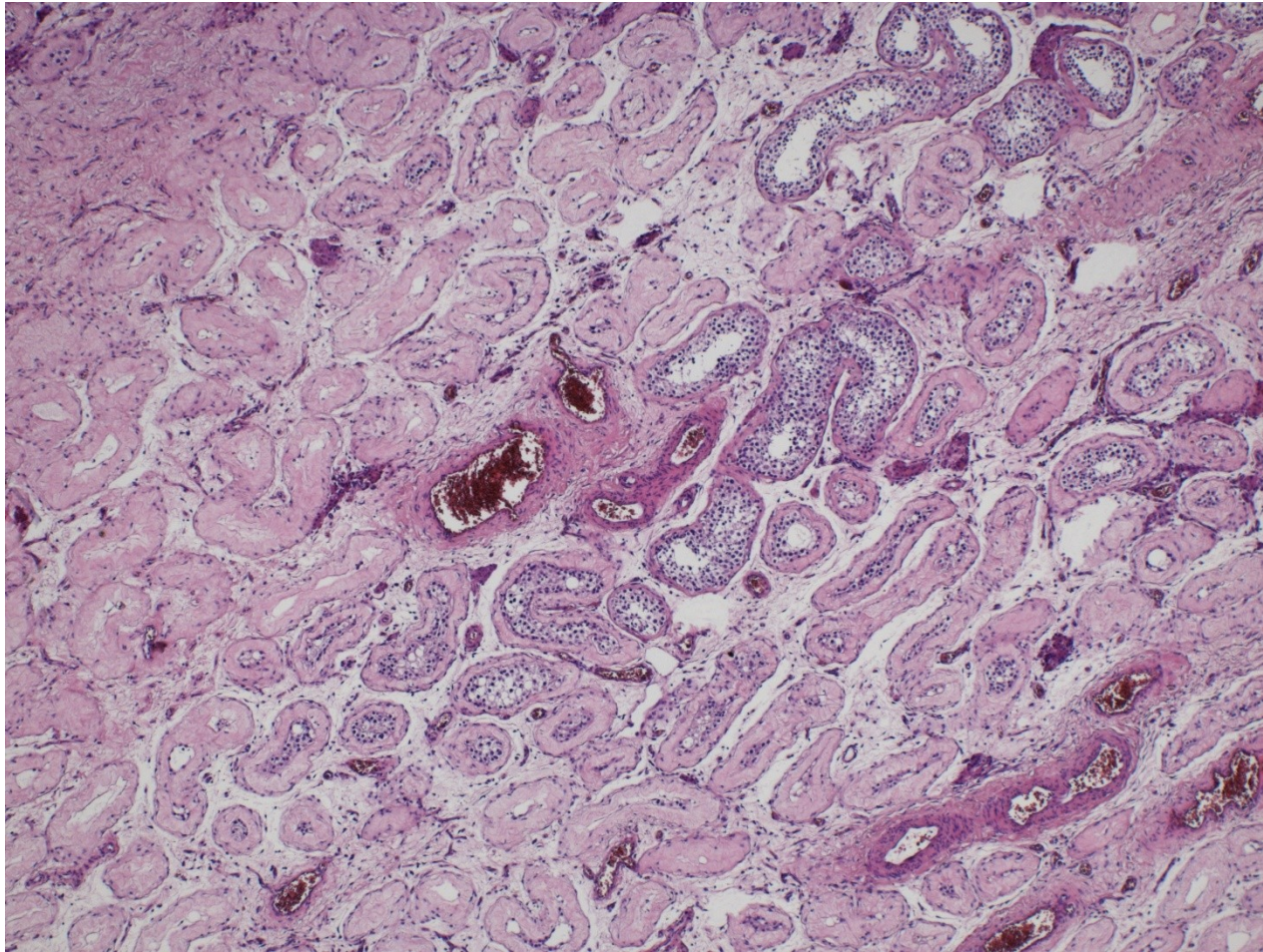
Cryptorchidism

- Undescended testis
- 1 in 10 newborn males, usually descends during 1st year of life
- remains in inguinal canal or abdominal cavity – surgery necessary before puberty
- atrophy – infertility, germ-cell tumors

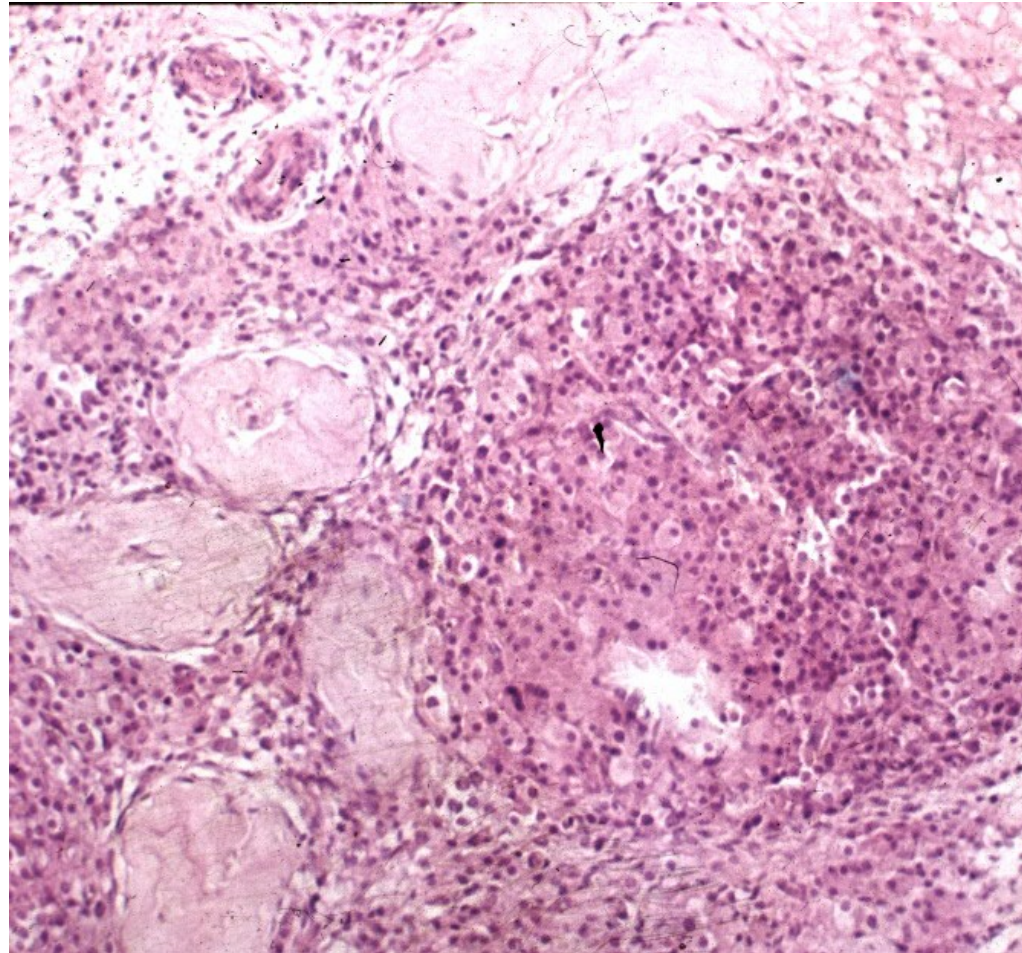
Cryptorchidism



Partial testicular atrophy



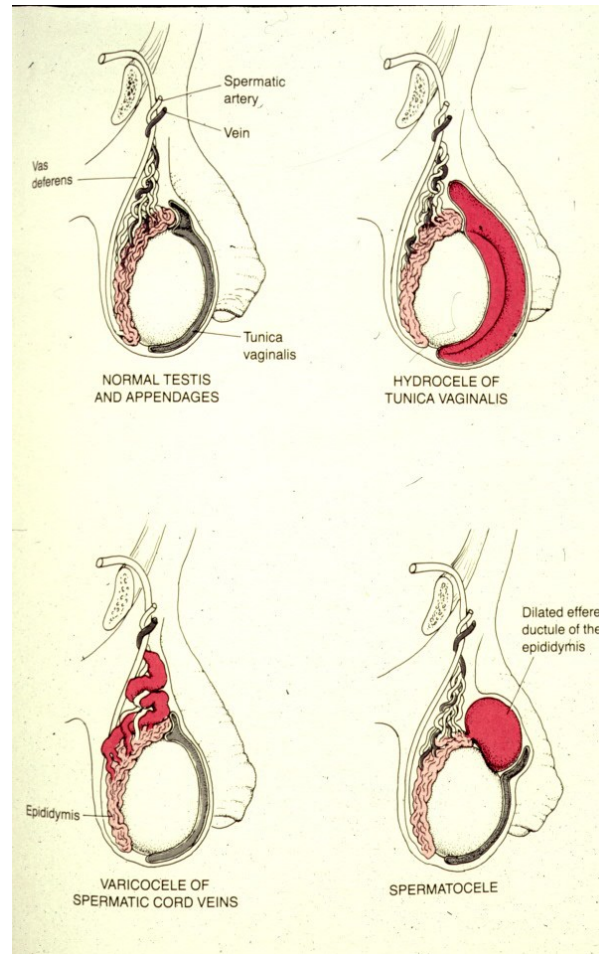
Testicular atrophy + Leydig cell hypertrophy



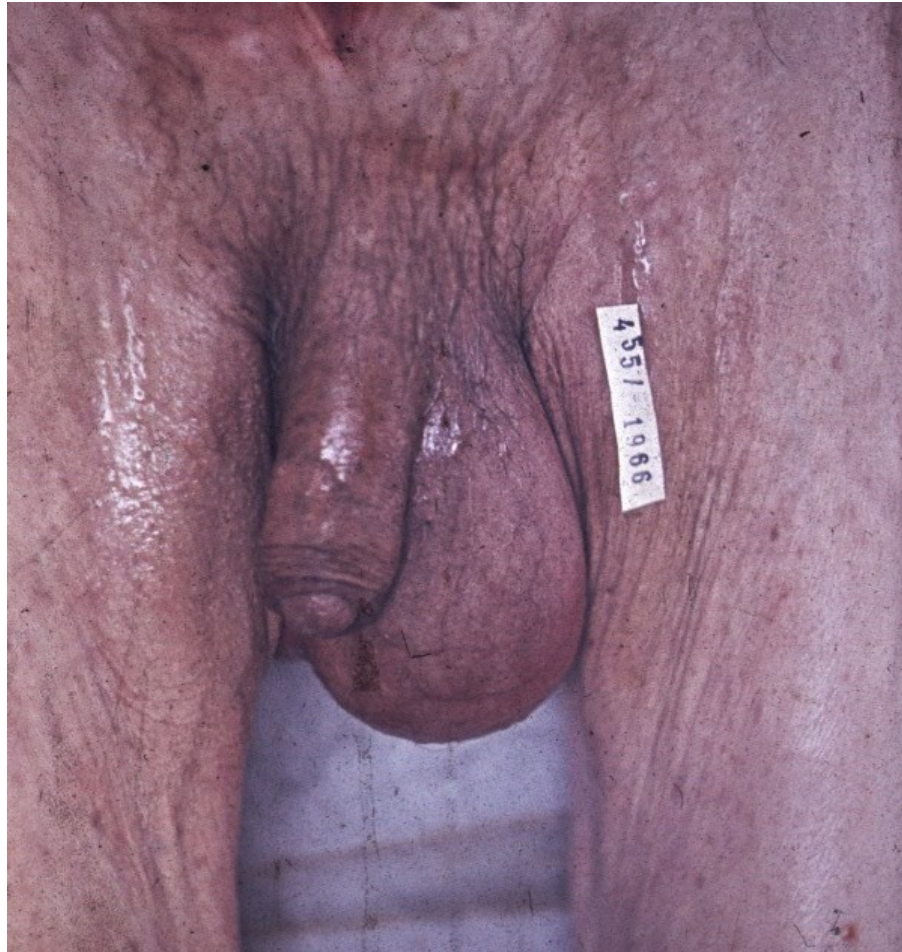Intrascrotal swelling

- Commonly pathology of epididymis, tunica vaginalis
- Hydrocele – serous fluid in tunica vaginalis
- Haematocele – haemorrhage into tunica vaginalis
- Varicocele – dilated veins
- Spermatocele – epididymitis + cystic dilatation of ducts

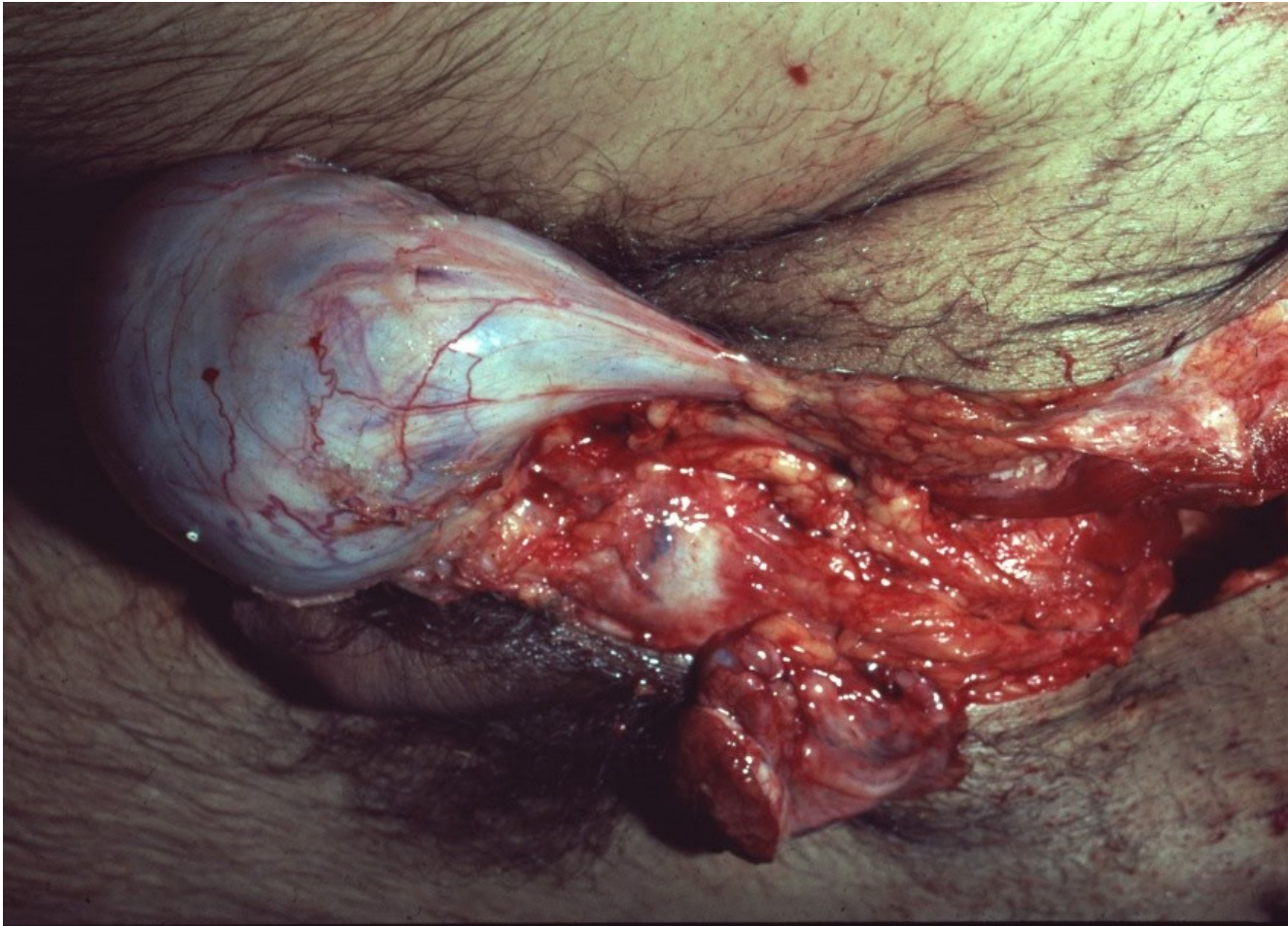
Intrascrotal swelling



Intrascrotal swelling - hydrocele



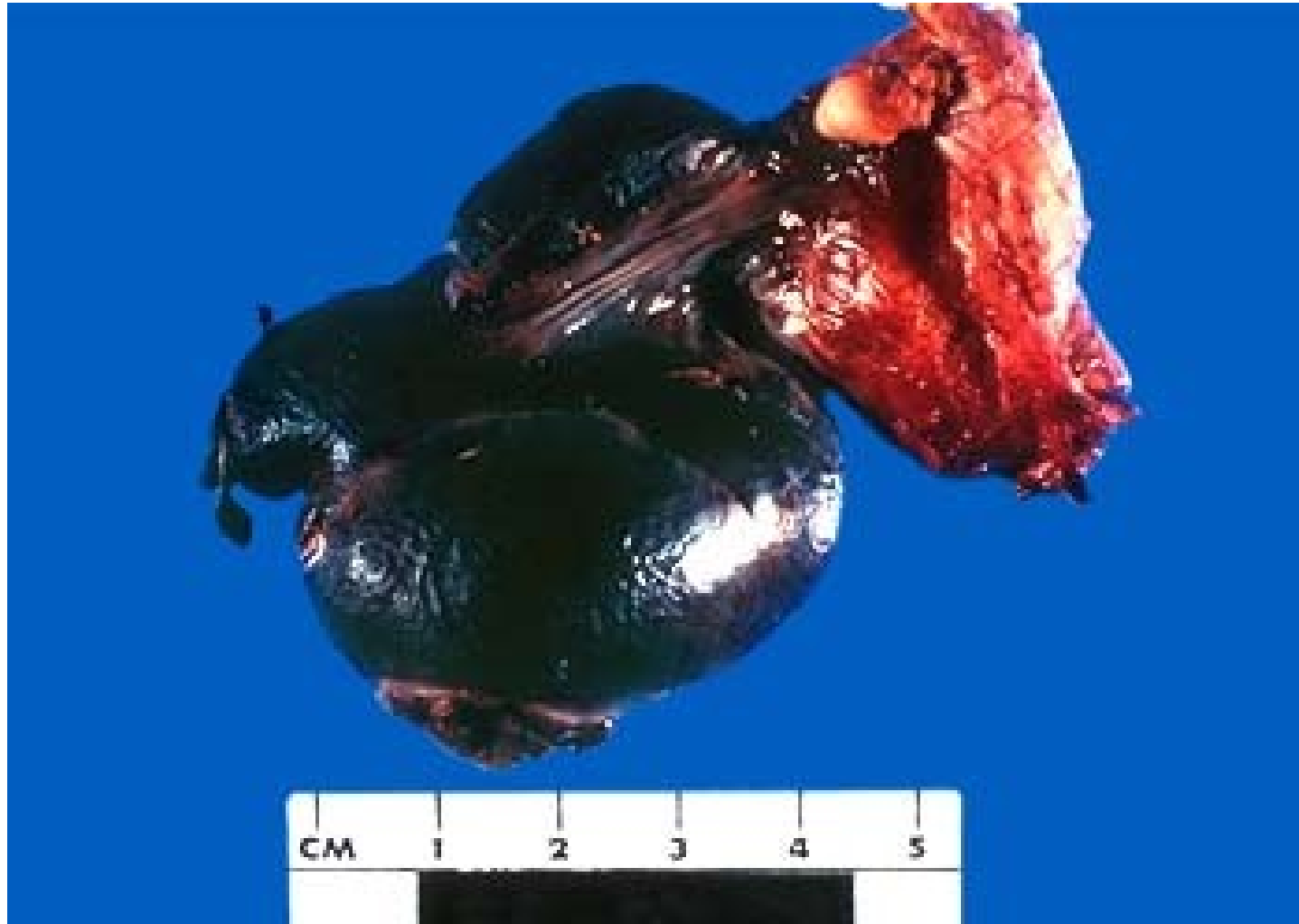Intrascrotal swelling - varicocele



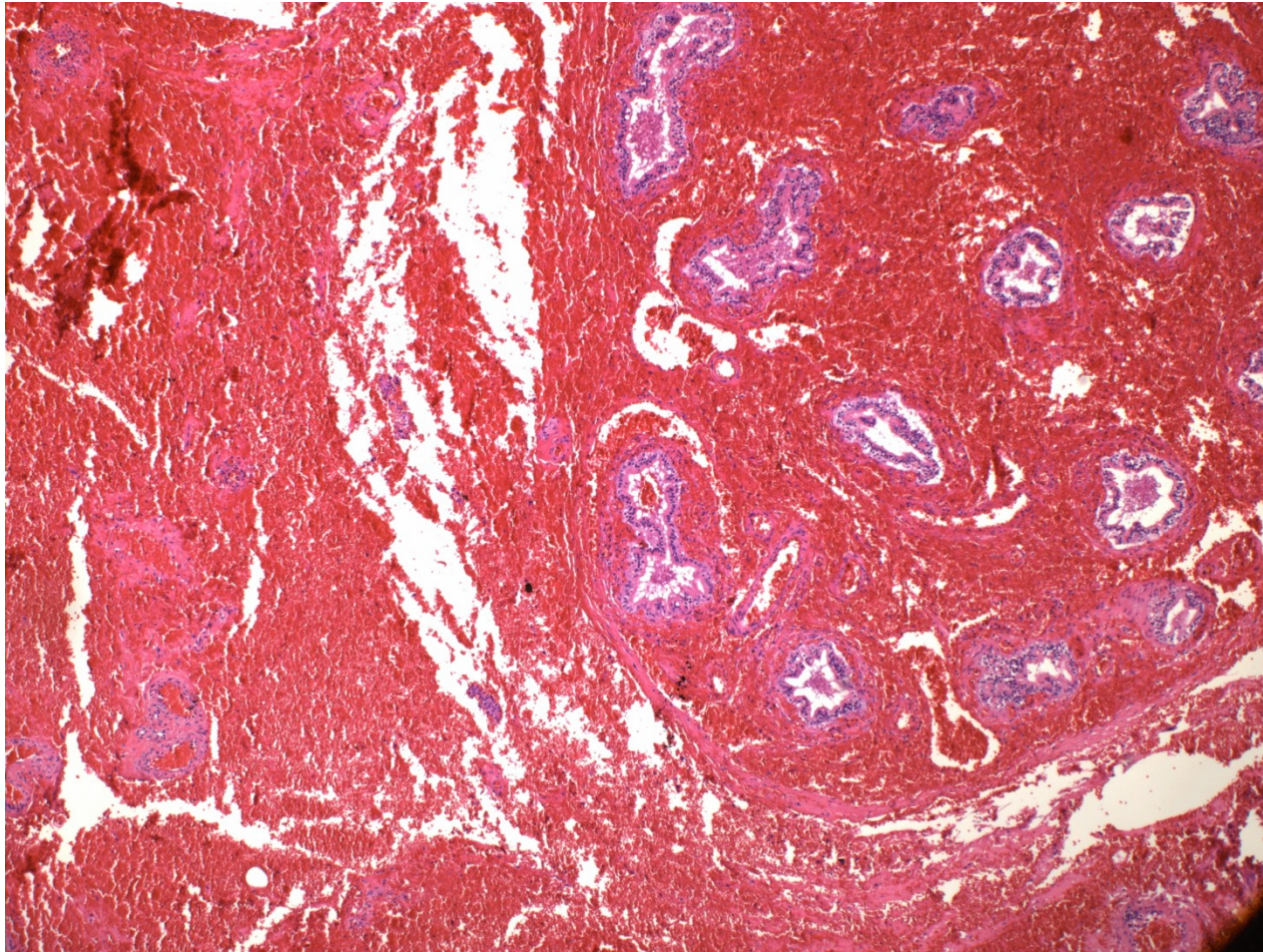
Testicular torsion

- Spermatic cord turns around its own axis
- Haemorrhagic necrosis
- Acute pain, swelling
- More common in young
- Immediate surgery necessary

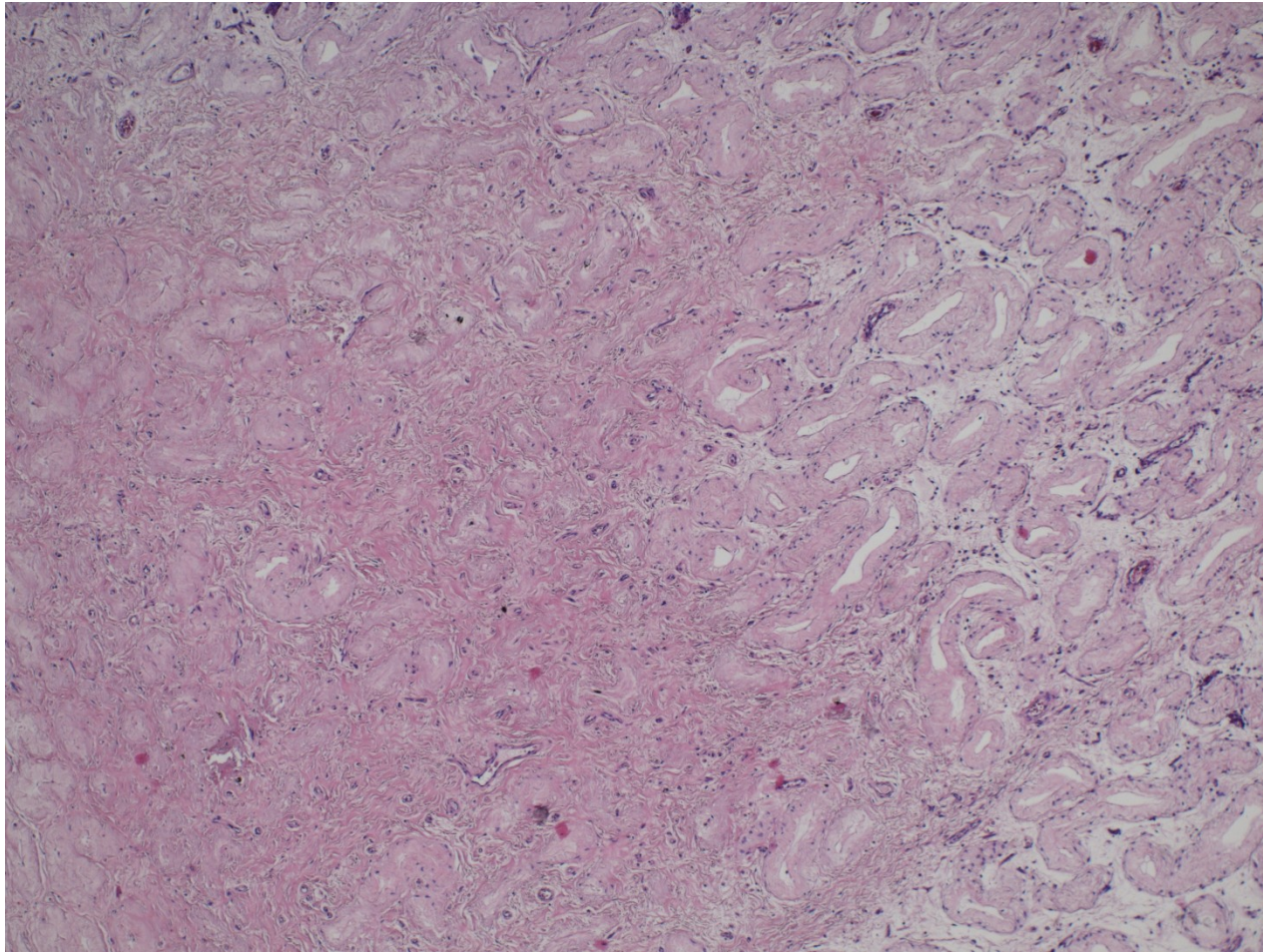
Torsion



Testicular torsion



Testicular infarction



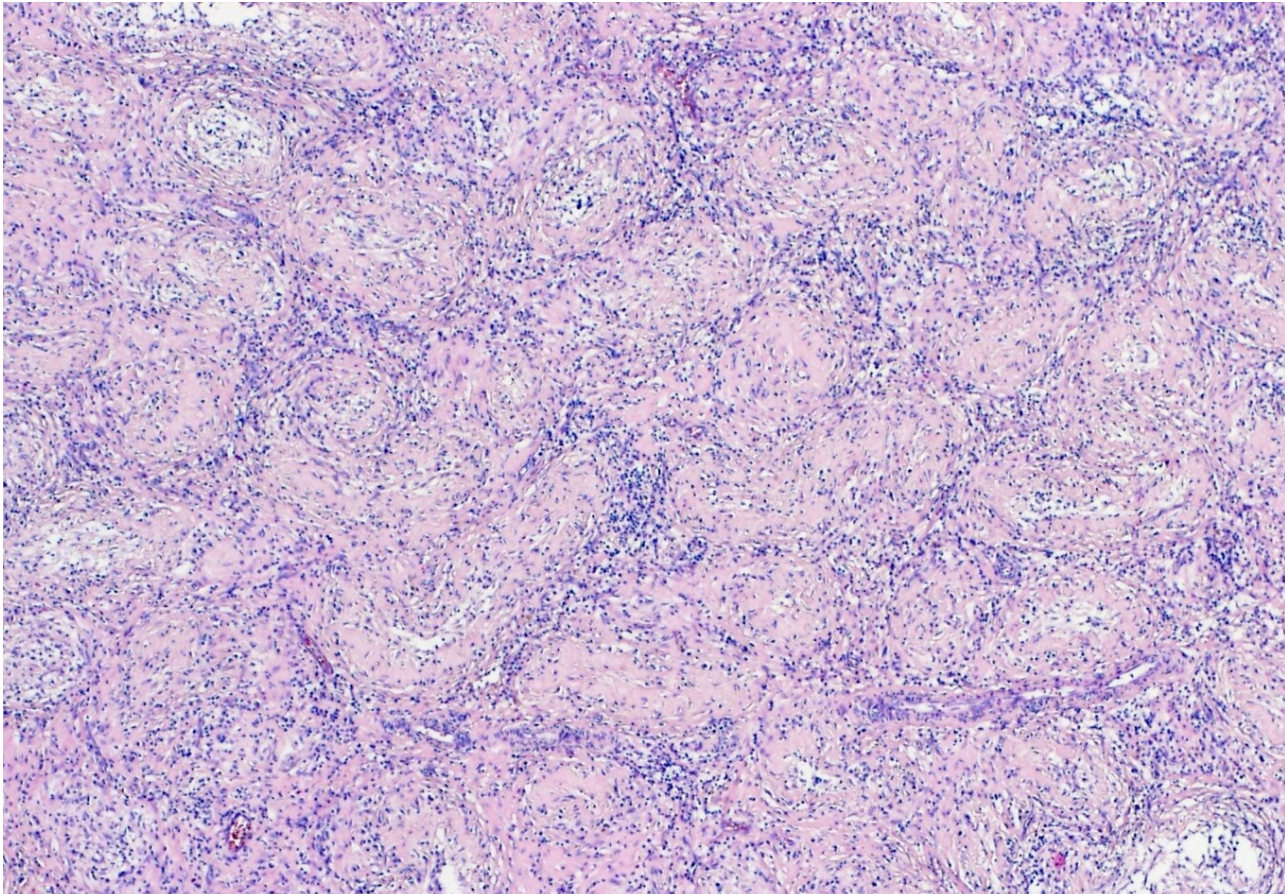
Testis, epididymis inflammations

- epididymis >>> testis
- usually ascending from urinary tract and/or prostate
- caused by
 - gramnegative bacteria (children)
 - chlamydias, gonococcus (STI, adults)
 - E. coli (older adults)

Testis, epididymis inflammations

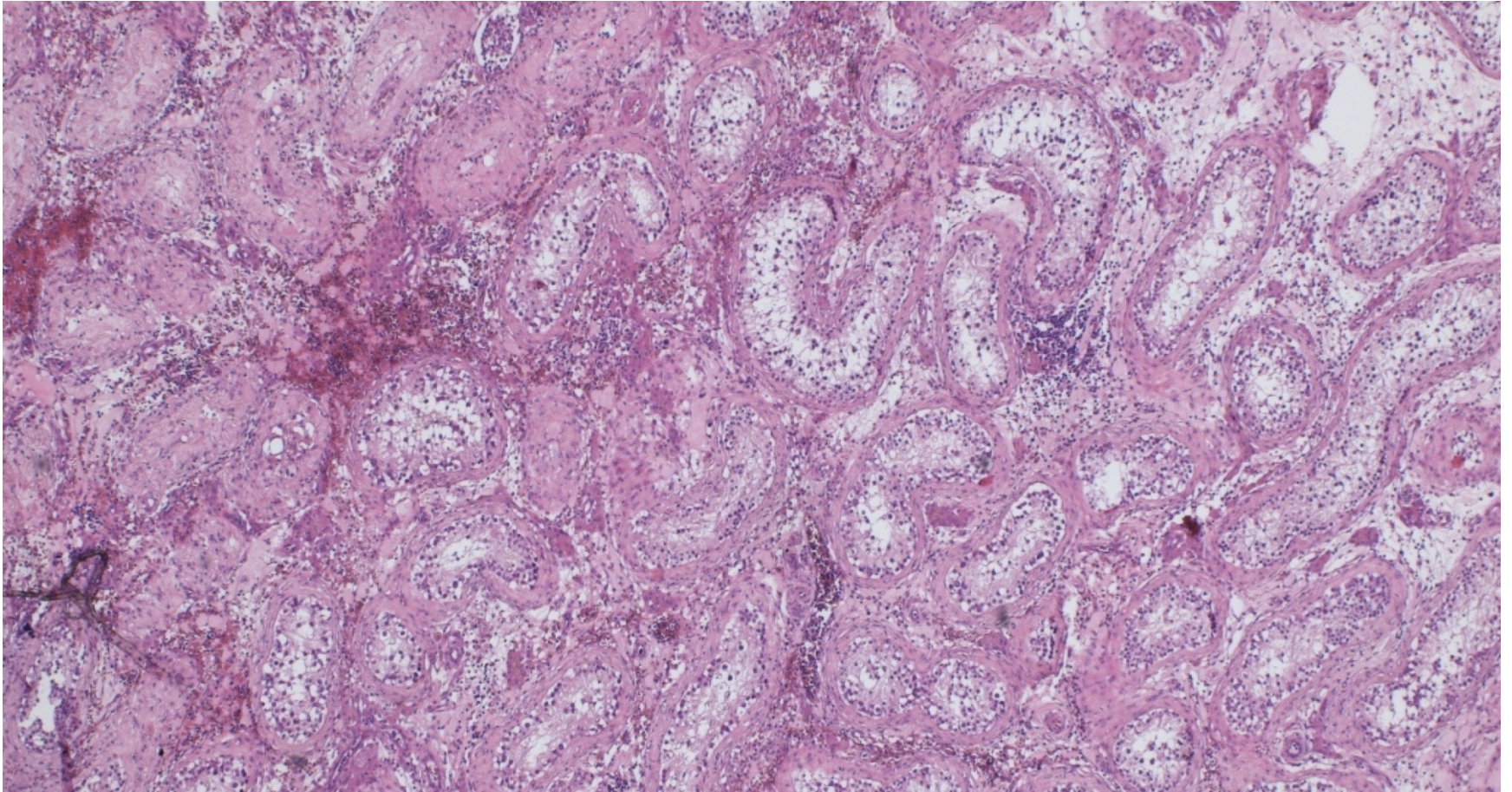
- **Bacterial**
 - purulent → abscess, non-specific orchitis/epididymitis
- **Interstitial non-purulent orchitis**
 - mumps in adults
 - interstitial oedema + lymphocytes, plasma cells, macrophages
- **Granulomatous orchitis**
 - may be posttraumatic, v.s. autoimmune inflammation
 - non-caseating tuberculoid granulomas centered on tubules
 - firmer testicular mass (diff. dg. x tumor)
- **Spermatocytic granuloma**
 - in the head of epididymis due to rupture of tubules
 - reactive tuberculoid granulomas around spermatozoa

Granulomatous orchitis

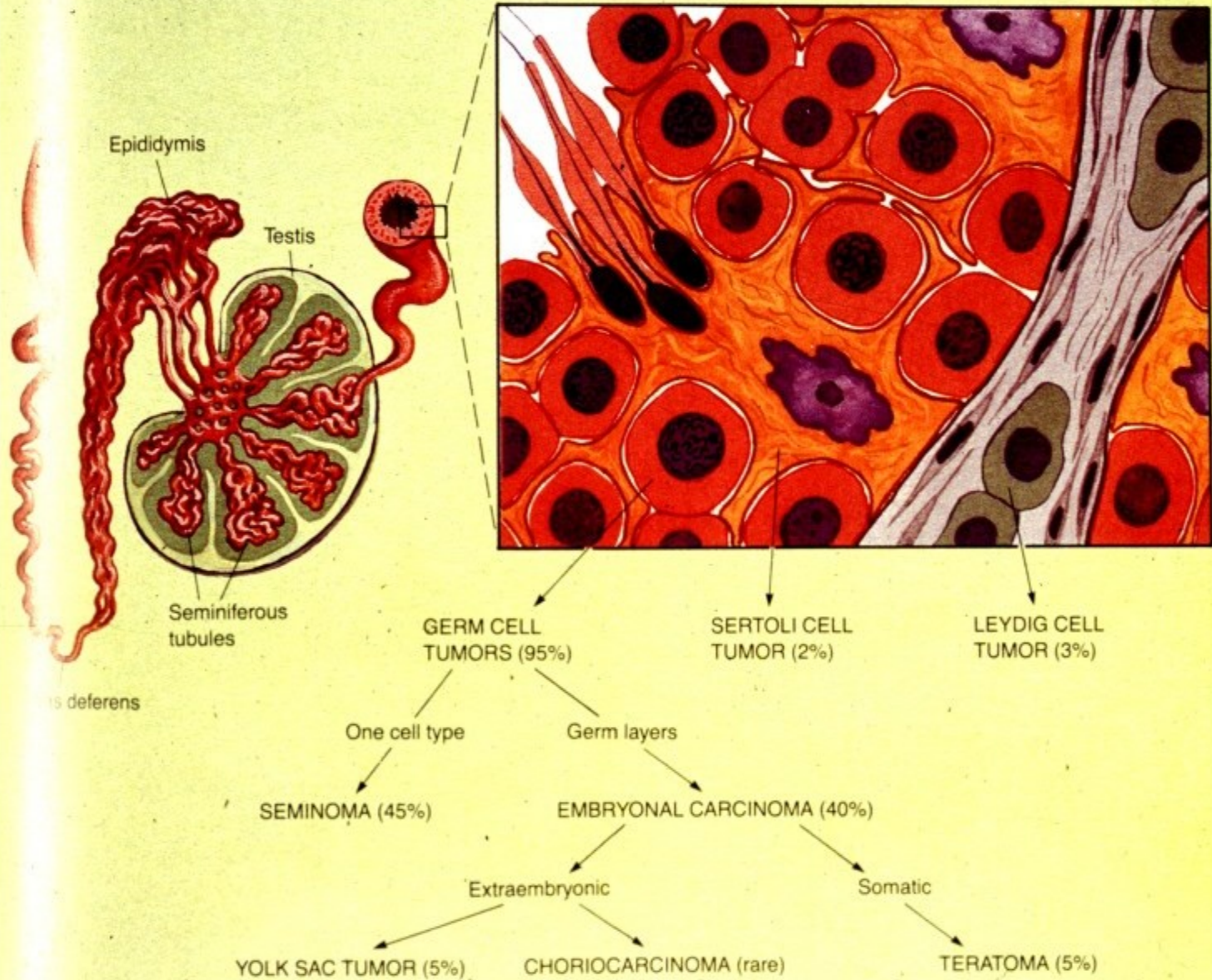


Tuberculoid granulomas.

Orchitis + atrophy



Testicular tumors



WHO pathologic classification of testicular tumors

GERM CELL TUMORS

Derived from germ cell neoplasia in situ

Tumors of one histologic pattern

- Seminoma (germinoma family of tumors)
- Non-seminomatous germ cell tumors
 - Embryonal carcinoma
 - Yolk sac tumor (postpubertal type)
 - Choriocarcinoma
 - Teratoma (postpubertal type)
 - Teratoma with somatic malignancy

GERM CELL TUMORS

(cont.)

Tumors showing more than one histologic pattern – Mixed germ cell tumors

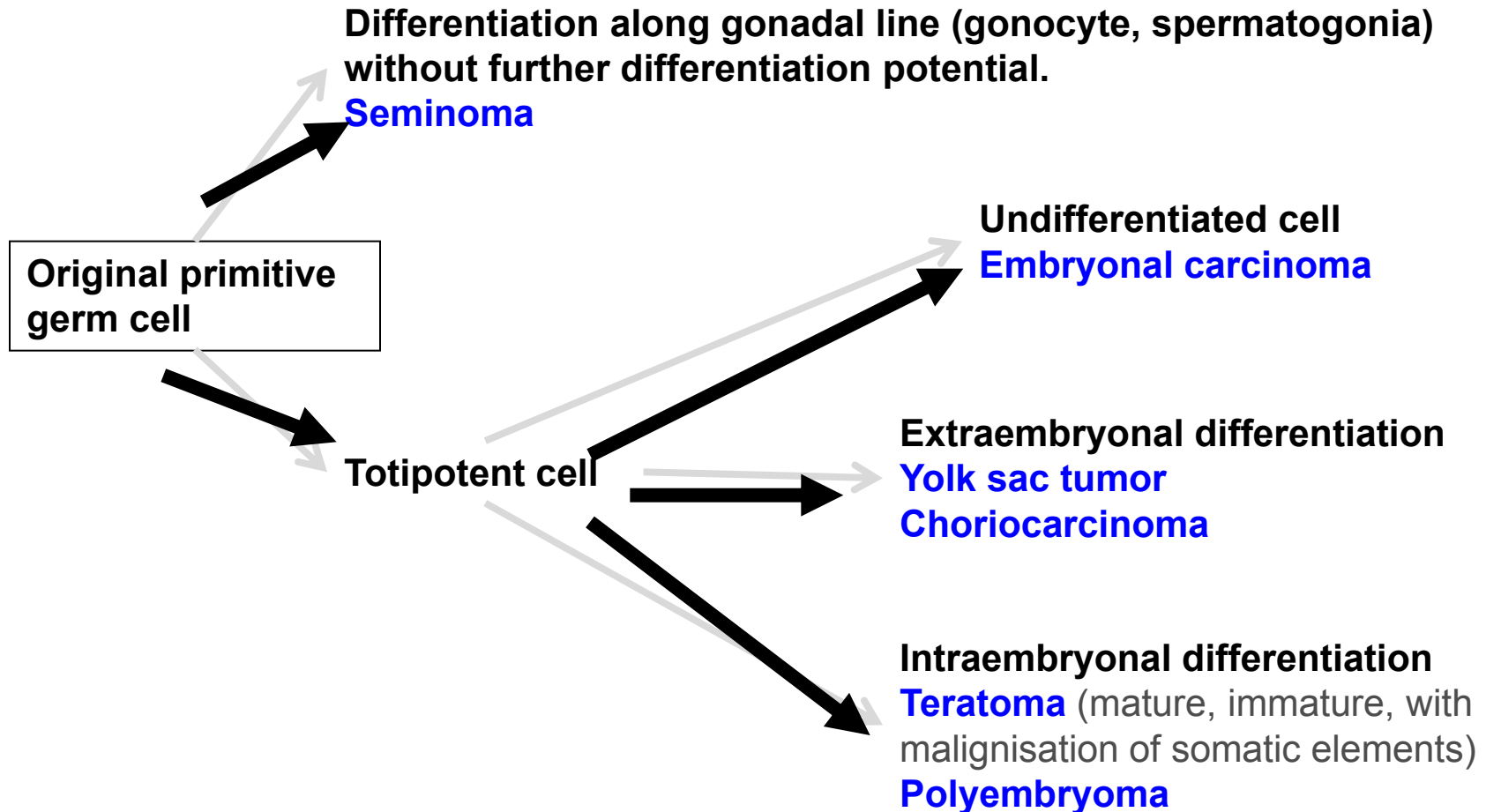
- Embryonal carcinoma + teratoma (teratocarcinoma)
- Choriocarcinoma + any other types
- Other combinations

Germ cell tumors

Unrelated to germ cell neoplasia in situ

- Spermatocytic tumor (formerly spermatocytic seminoma)
- Teratoma, prepubertal type
- Yolk sac tumor, prepubertal type

Germ cell tumors histogenesis



SEX CORD-STROMAL TUMORS

- **Well-differentiated forms**
- **Mixed forms**
- Leydig cell tumor
- Sertoli cell tumor
- Granulosa cell tumor
- **Incompletely differentiated forms**

Testicular tumors

- Other types

Neuroendocrine tumors

Haematopoietic neoplasms (DLBCL)

Tumors of collecting ducts and rete testis
(adenoma, carcinoma)

Tumors of paratesticular structures
(mesothelial tumors, tumors of the
epididymis, ...)

Testicular tumors

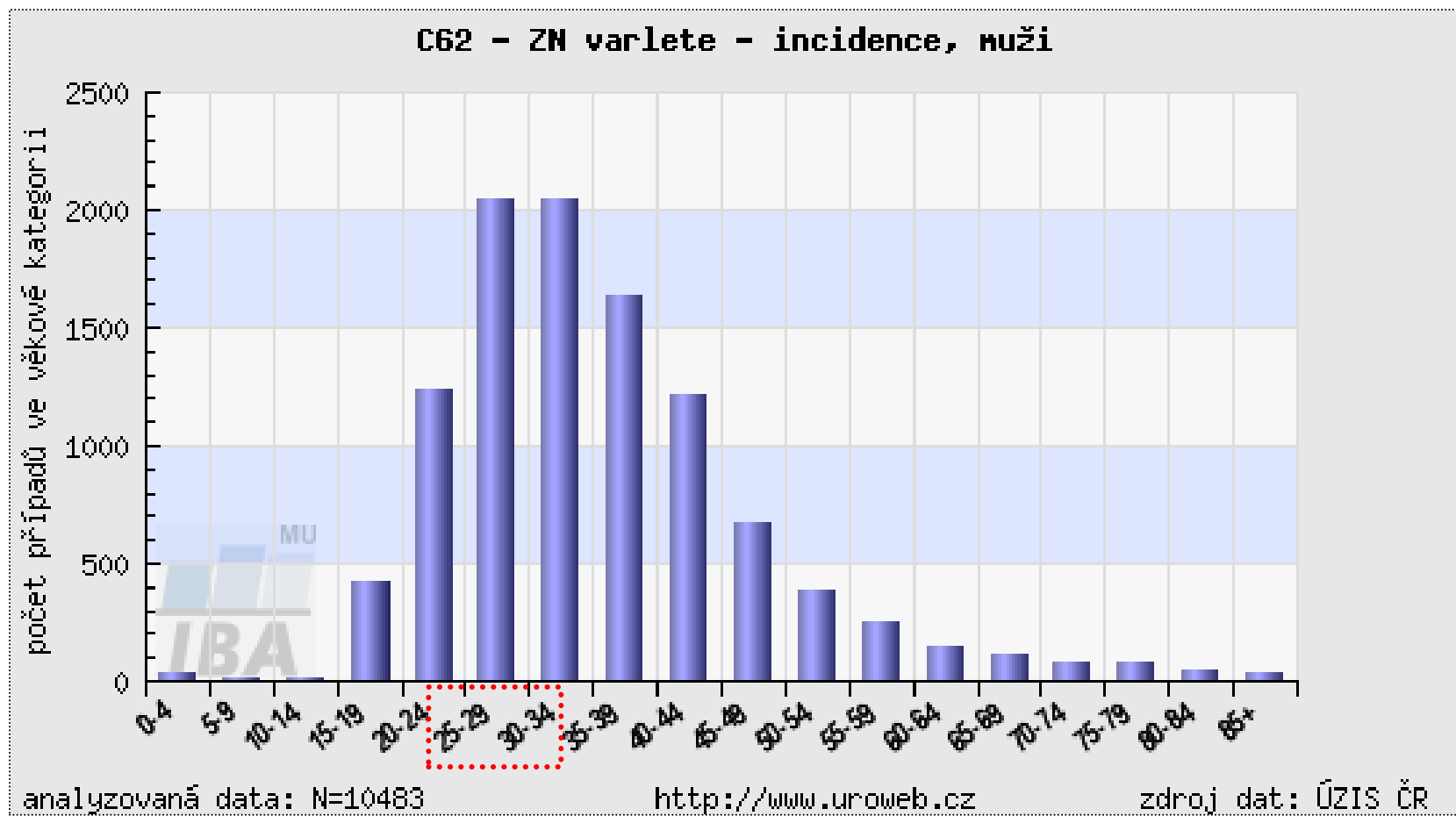
Clinical features

- painless unilateral enlargement of testis
- secondary hydrocele
- symptoms from metastases
- retroperitoneal mass
- gynaecomastia

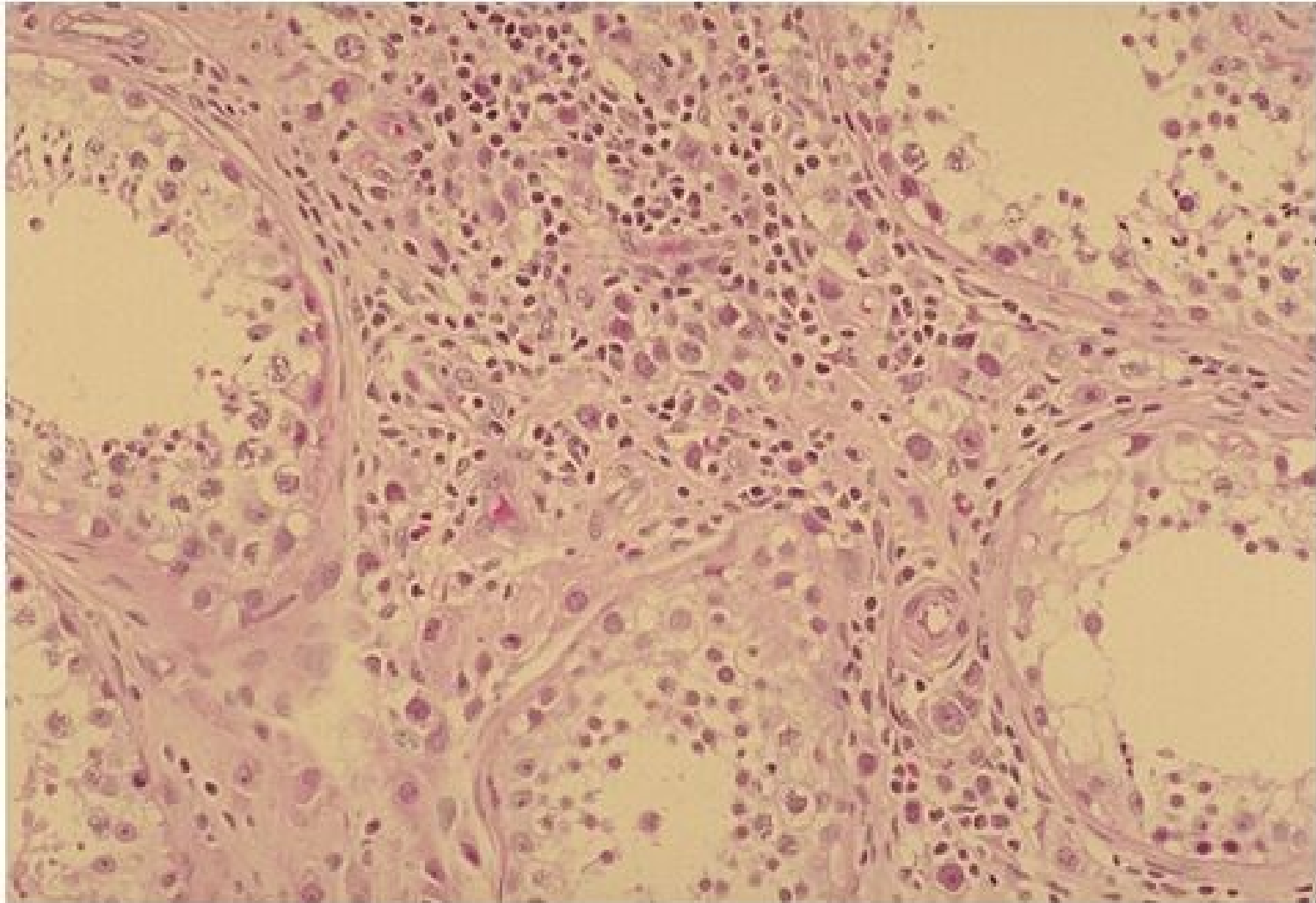
Testicular tumors : histopathological report

- gross picture (incl. size)
- histological type
- presence of vascular / lymphatic propagation
- tumor staging (TNM classification)
- presence of intratubular germ cell neoplasia (ITGCN - in situ germ cell lesion)

Age structure of testicular tumors patients

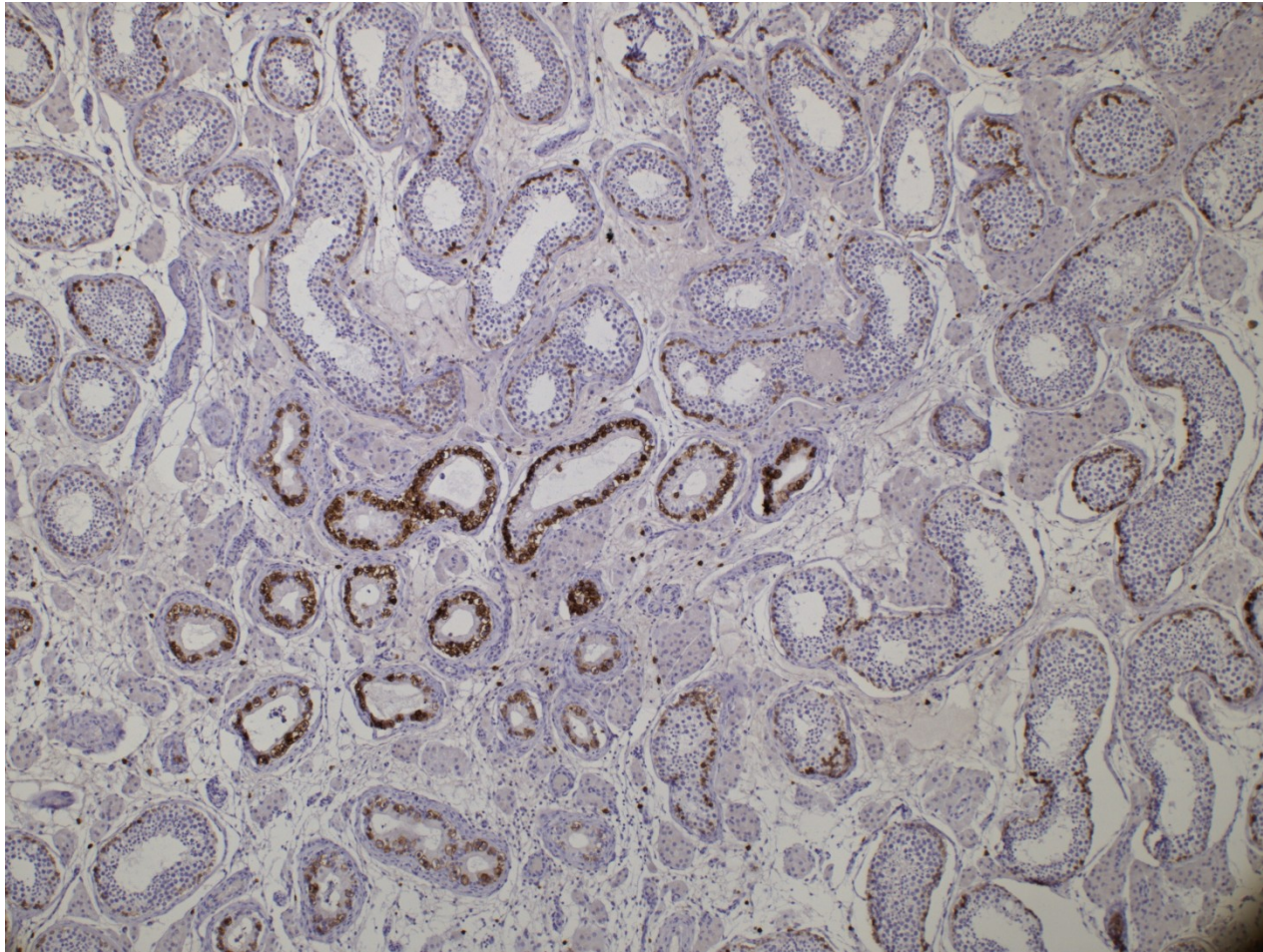


Germ cell neoplasia in situ



Copyright © 2002, Elsevier Science (USA). All rights reserved.

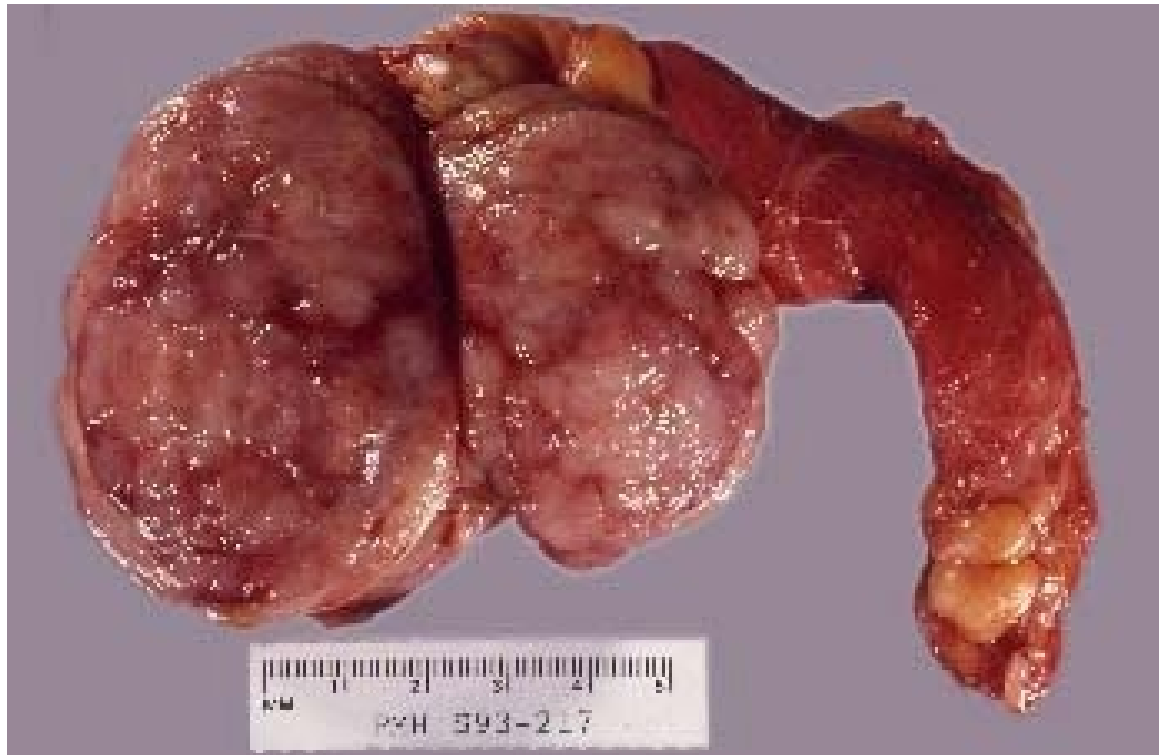Germ cell neoplasia in situ - IHC



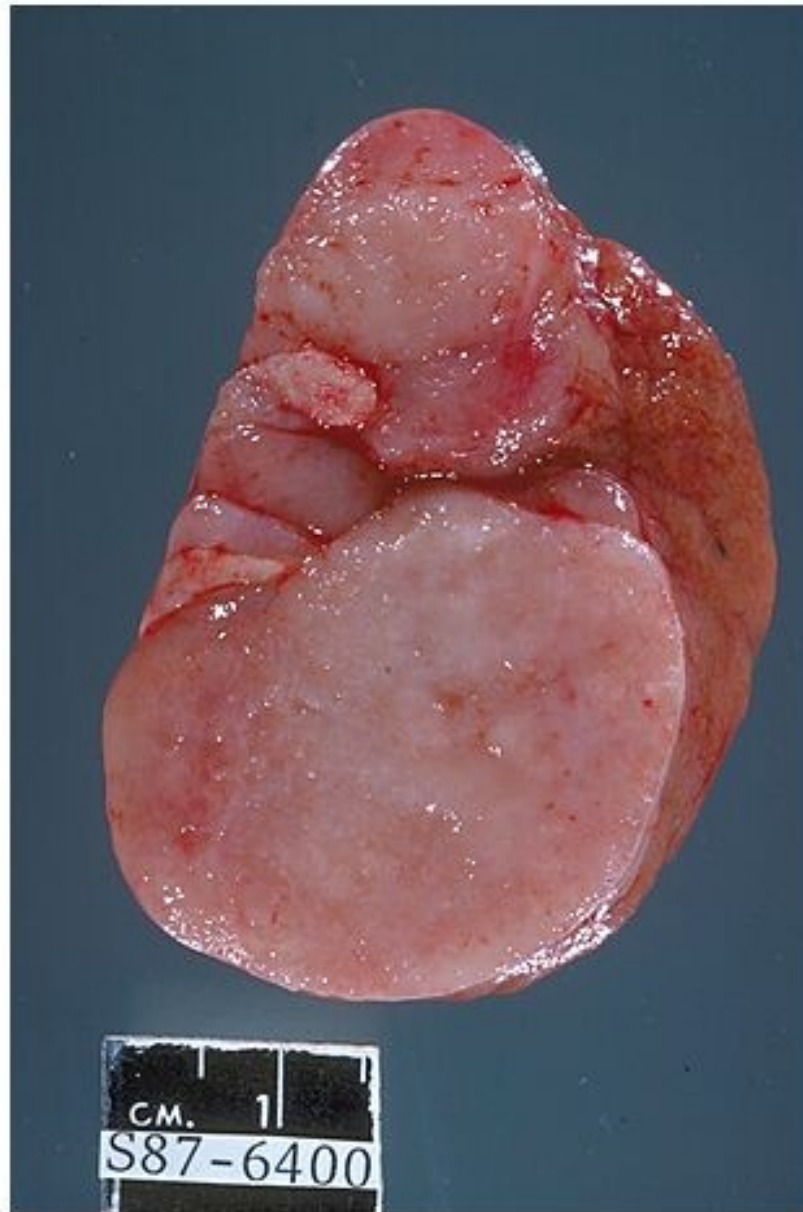
Seminoma

- most common
- peak in 4th decade, not in infants
- gross: homogenous, greyish
- micro: large cells, clear cytoplasm, hyperchromatic nucleus
- stroma with lymphocytic reaction, granulomas possible
- good prognosis usual

Seminoma

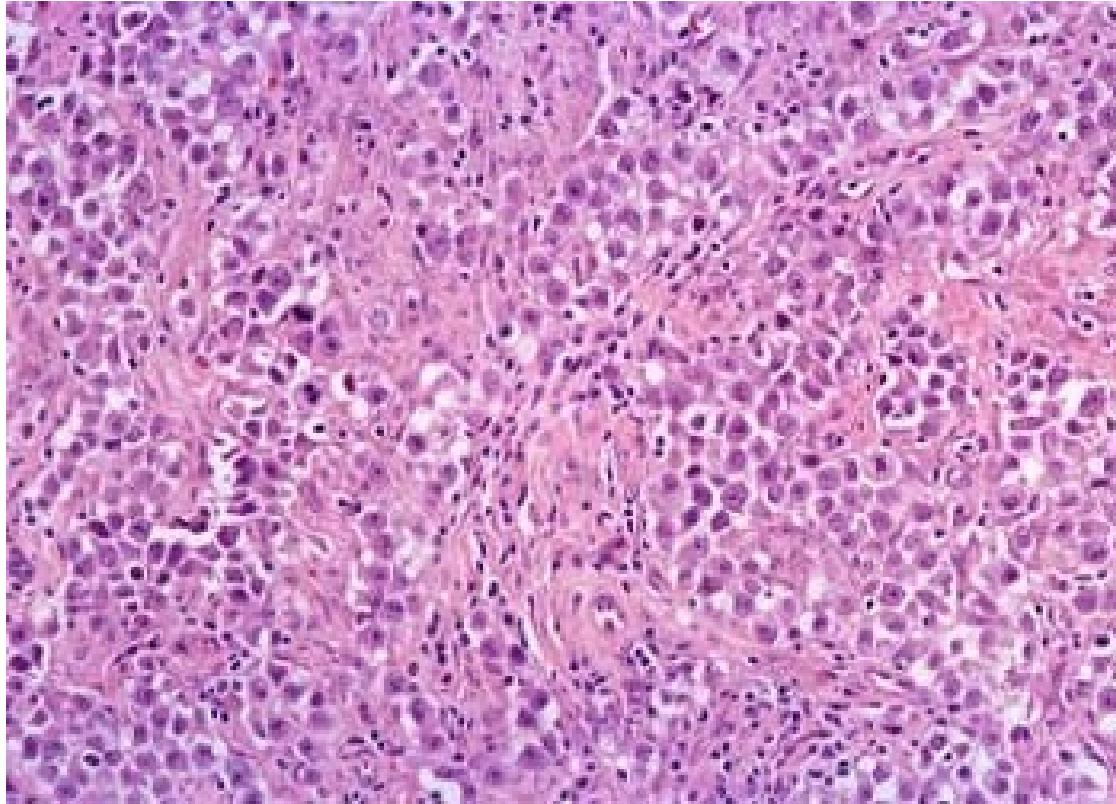


Seminoma

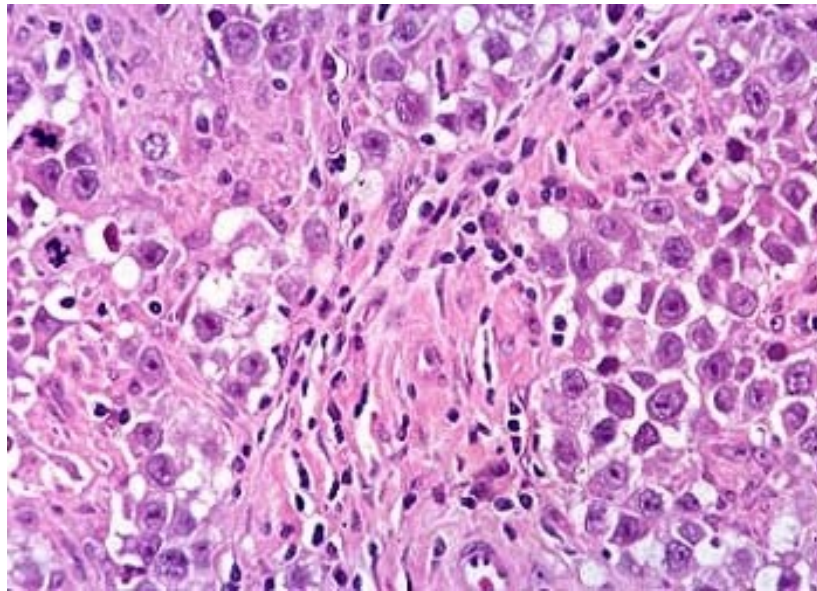


Copyright © 2002, Elsevier Science (USA). All rights reserved.

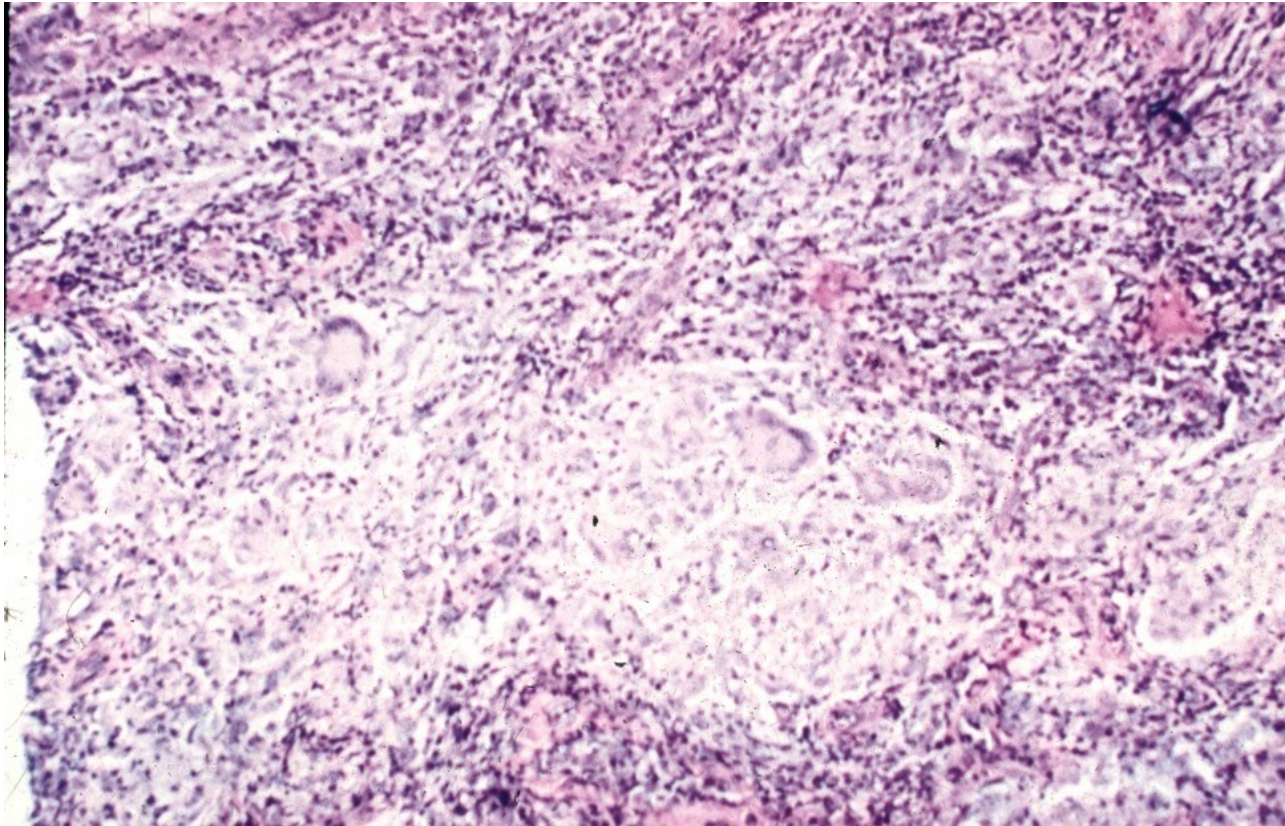
Seminoma



Seminoma



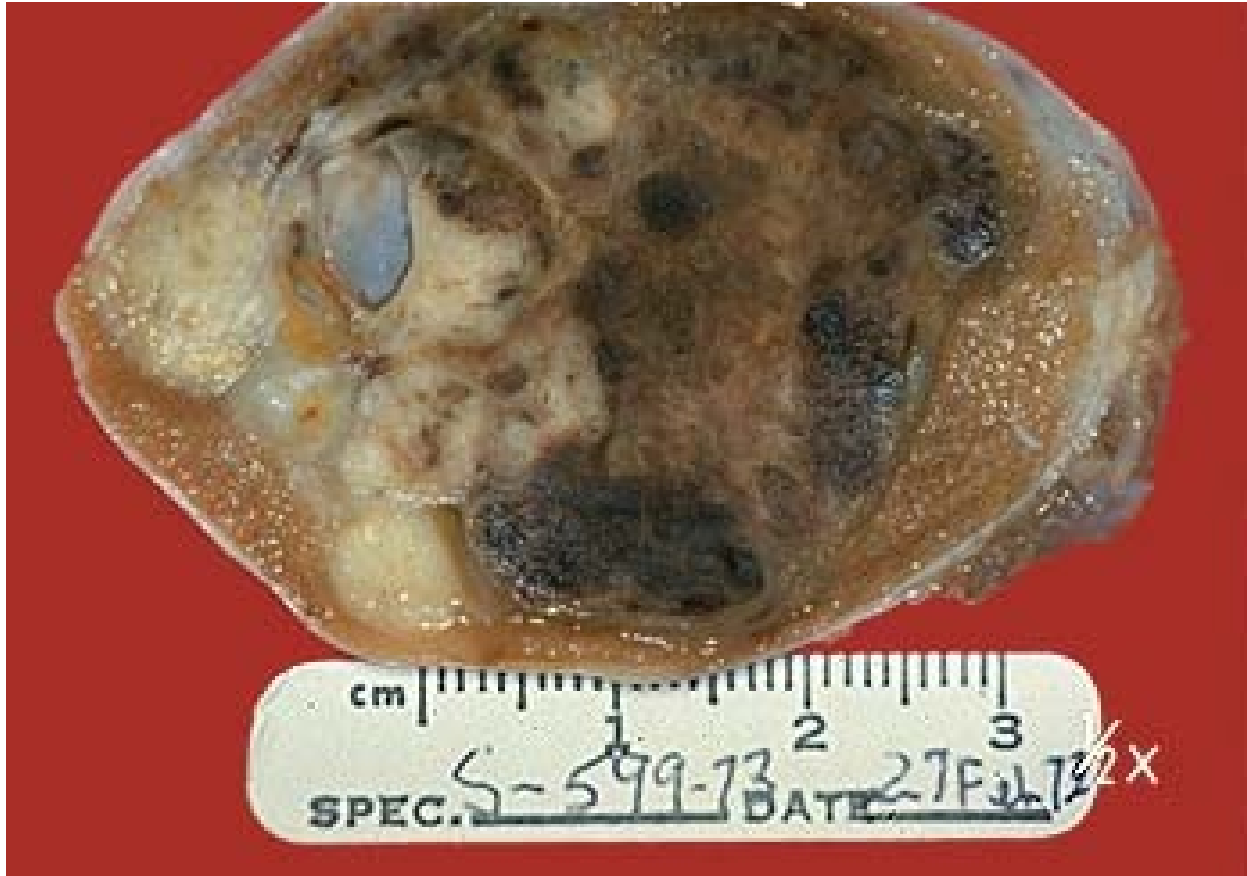Seminoma



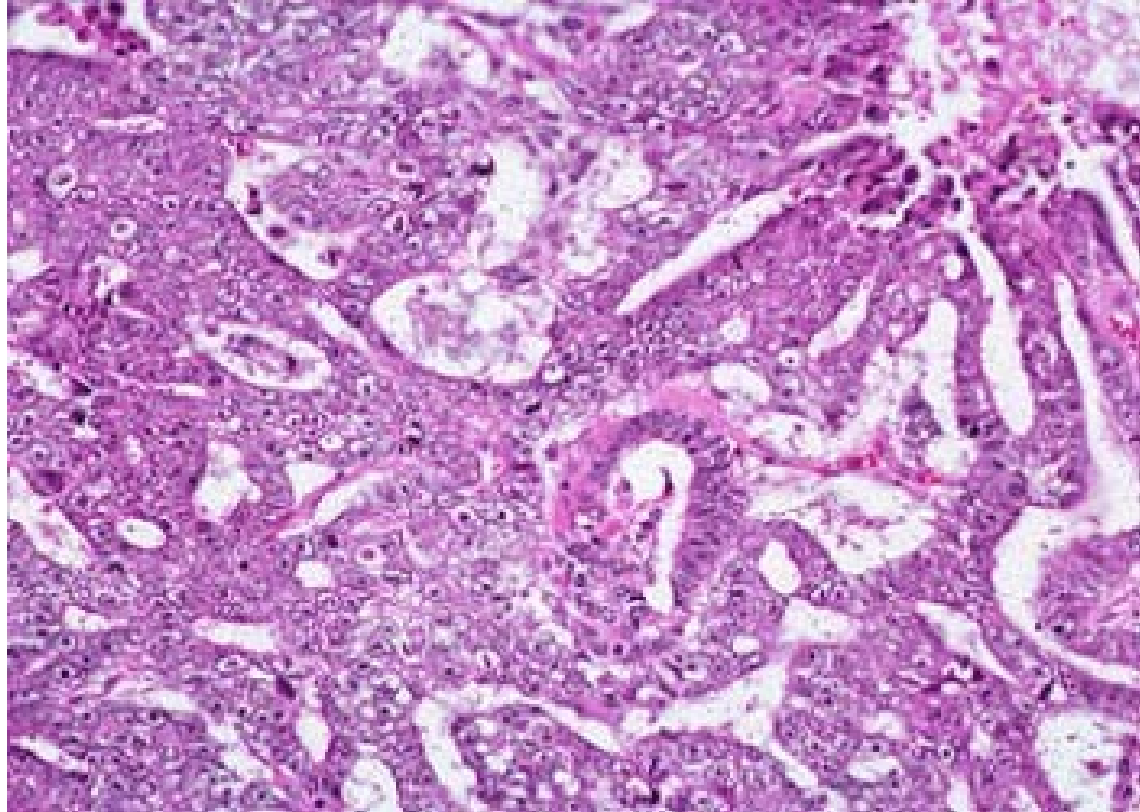
Embryonal carcinoma

- mostly 20-30 yrs
- gross: variable, haemorrhage, necrosis
- micro: organoid glandular, trabecular formations
- large anaplastic cells

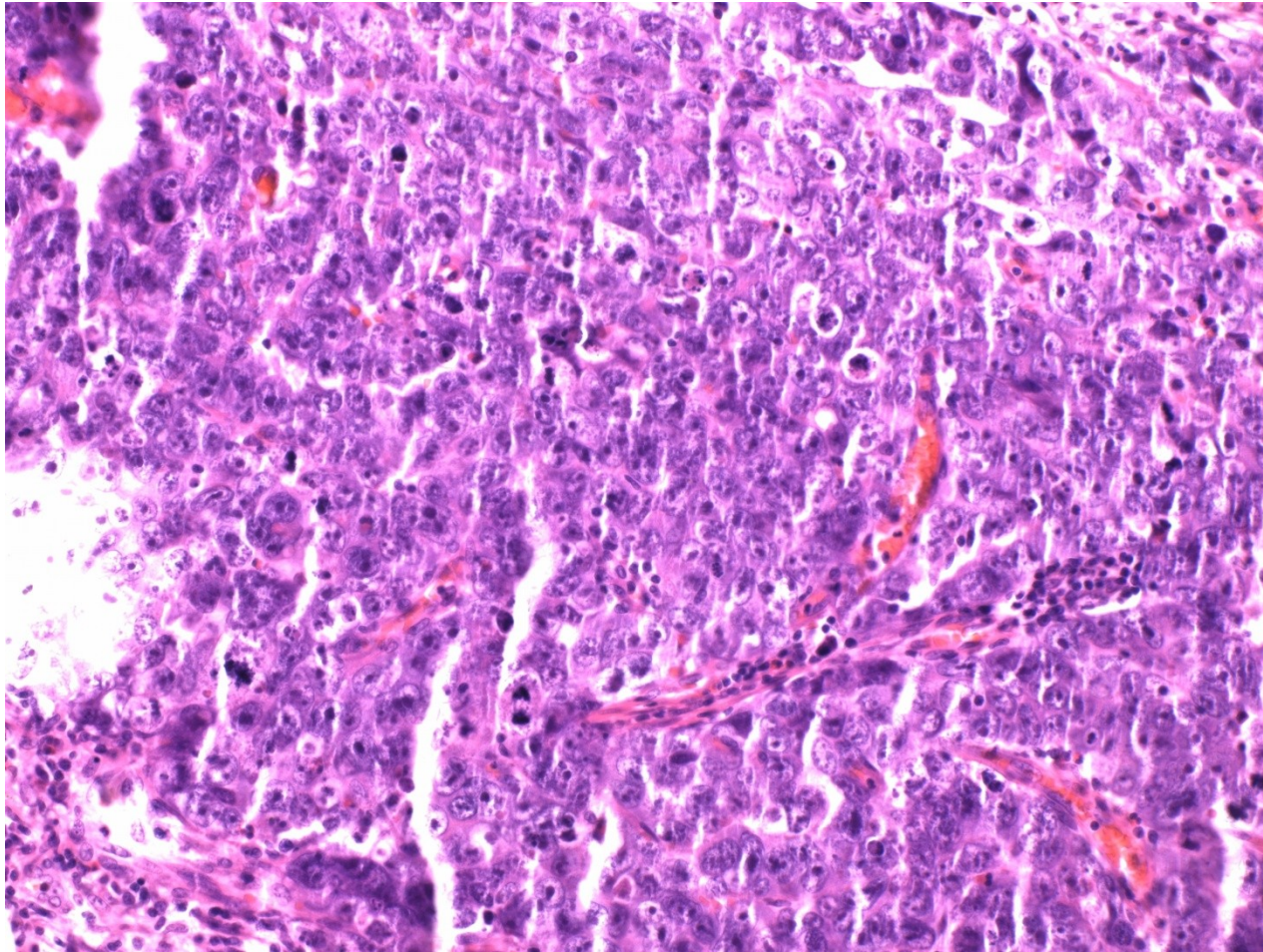
Embryonal carcinoma



Embryonal carcinoma



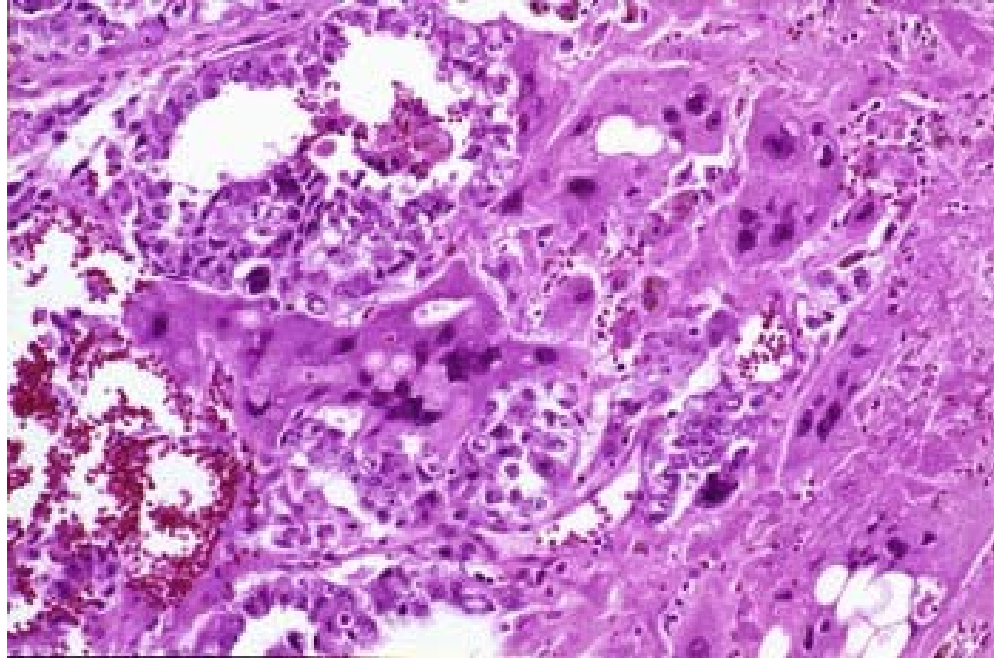
Embryonal carcinoma



Choriocarcinoma

- similar to gestational chca
- pure very rare, common admixture
- HCG production (! disperse trofoblastic cells possible in seminoma)
- extensive haemorrhage
- cyto- + syncytiotrophoblast

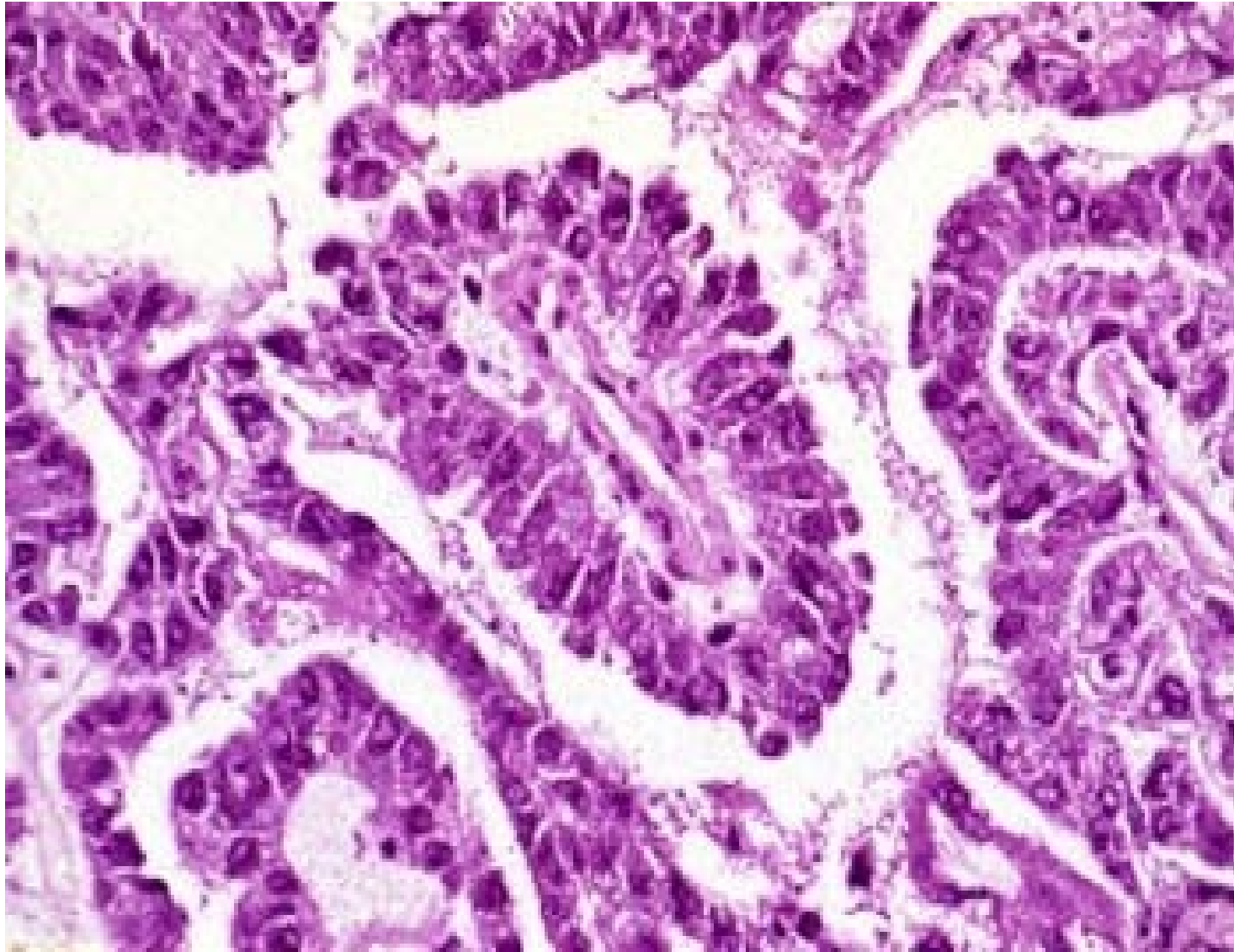
Choriocarcinoma



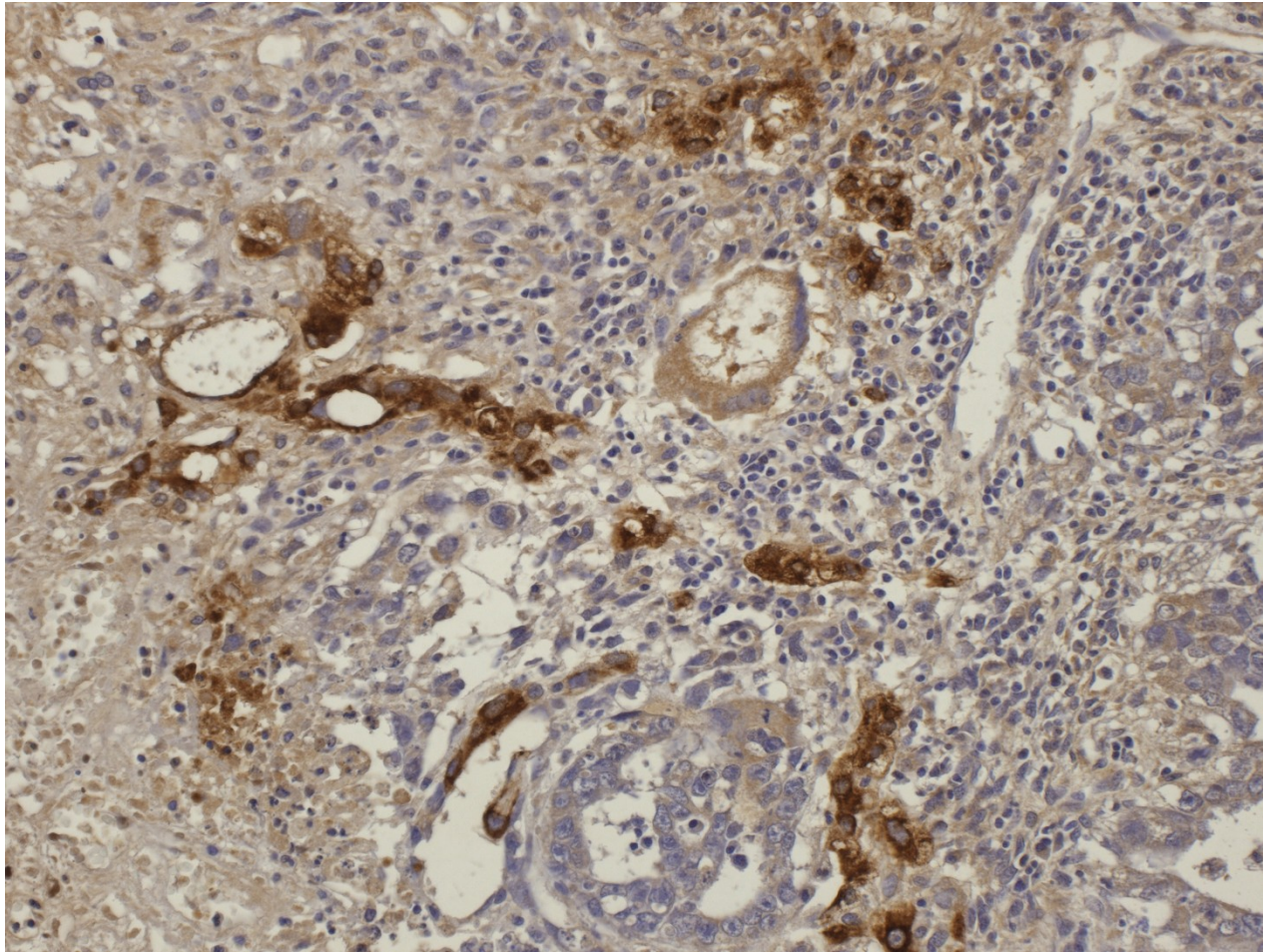
Yolk sac tumor

- Pure: most common testicular tu in children < 3 yrs
- Common part of mixed germ cell tumors
- AFP production
- variable histology – microcystic, reticular, papillary formation, variable patterns
 - glomeruloid structures (Schiller-Duval bodies)
 - stalk with capillary lined on the surface by layer of tumor cells

Yolk sac tumor



Yolk sac tumor – AFP IHC



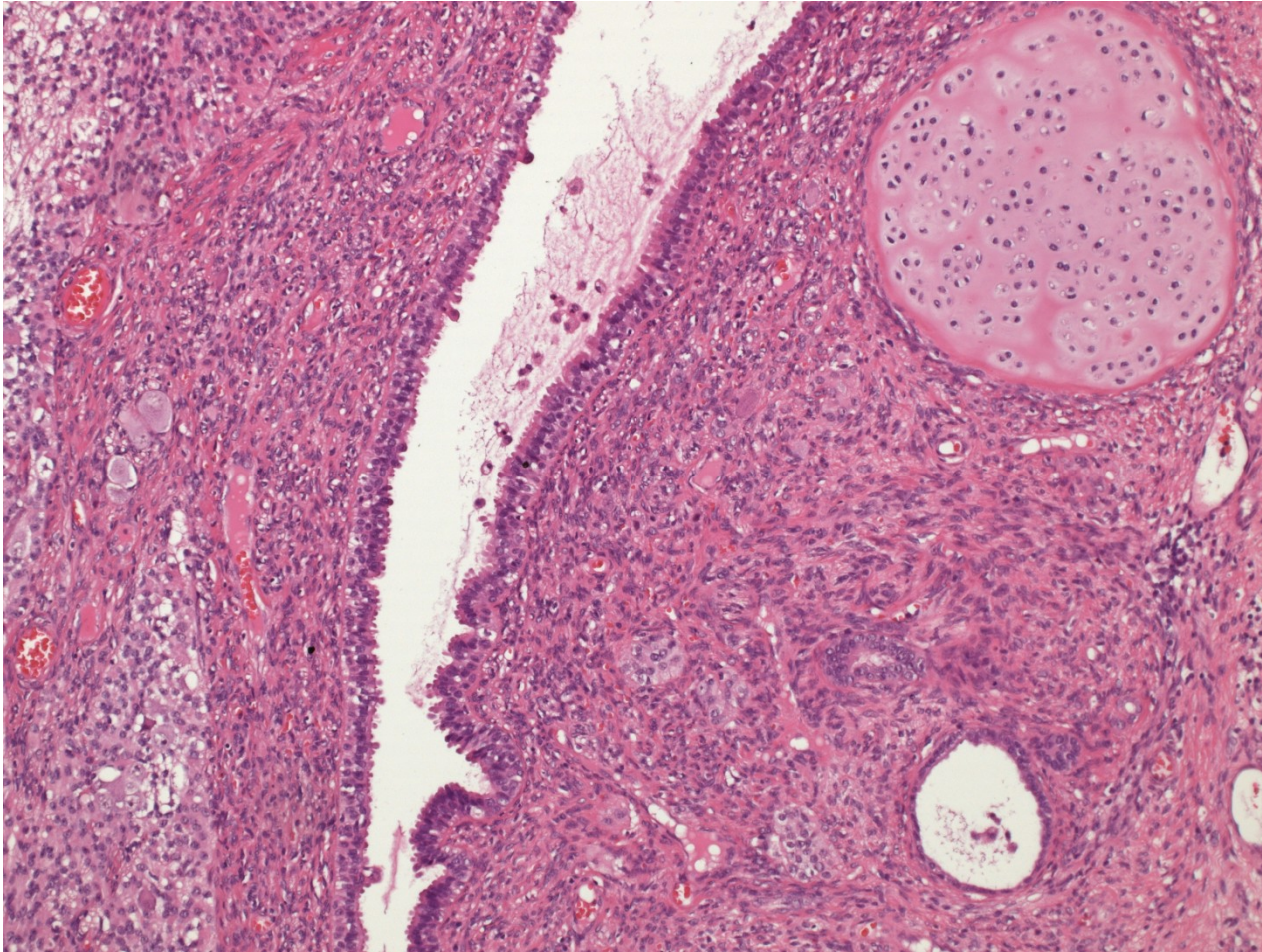
Teratoma

- variable components: ecto-, meso-
endoderm (intraembryonal)
- commonly glandular + squamous
epithelium
- mesenchymal tissues incl. cartilage
- in males usually immature, component of
mixed germinal tu (x females)

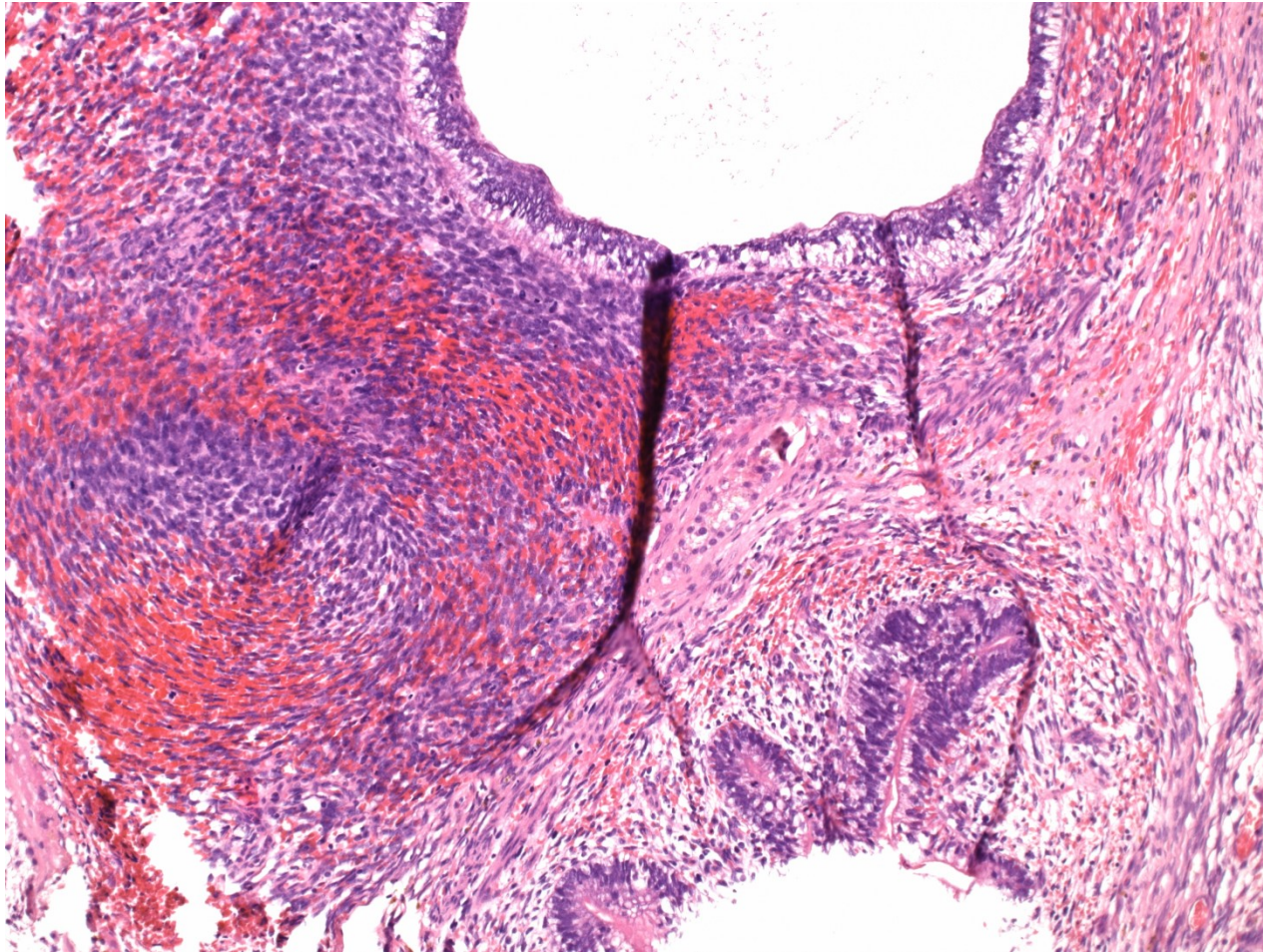
Teratoma

- histologic classification
 - differentiated mature t.
 - completely matured tissues with organoid structure
 - commonly cystic, containing serous fluid, mucus, keratin
 - differentiated immature t.
 - immature tissues of embryonal/fetal appearance (neuroectoderm, mesenchyme)
 - t. with somatic type malignancy
 - sarcoma, carcinoma, PNET, neuroblastoma

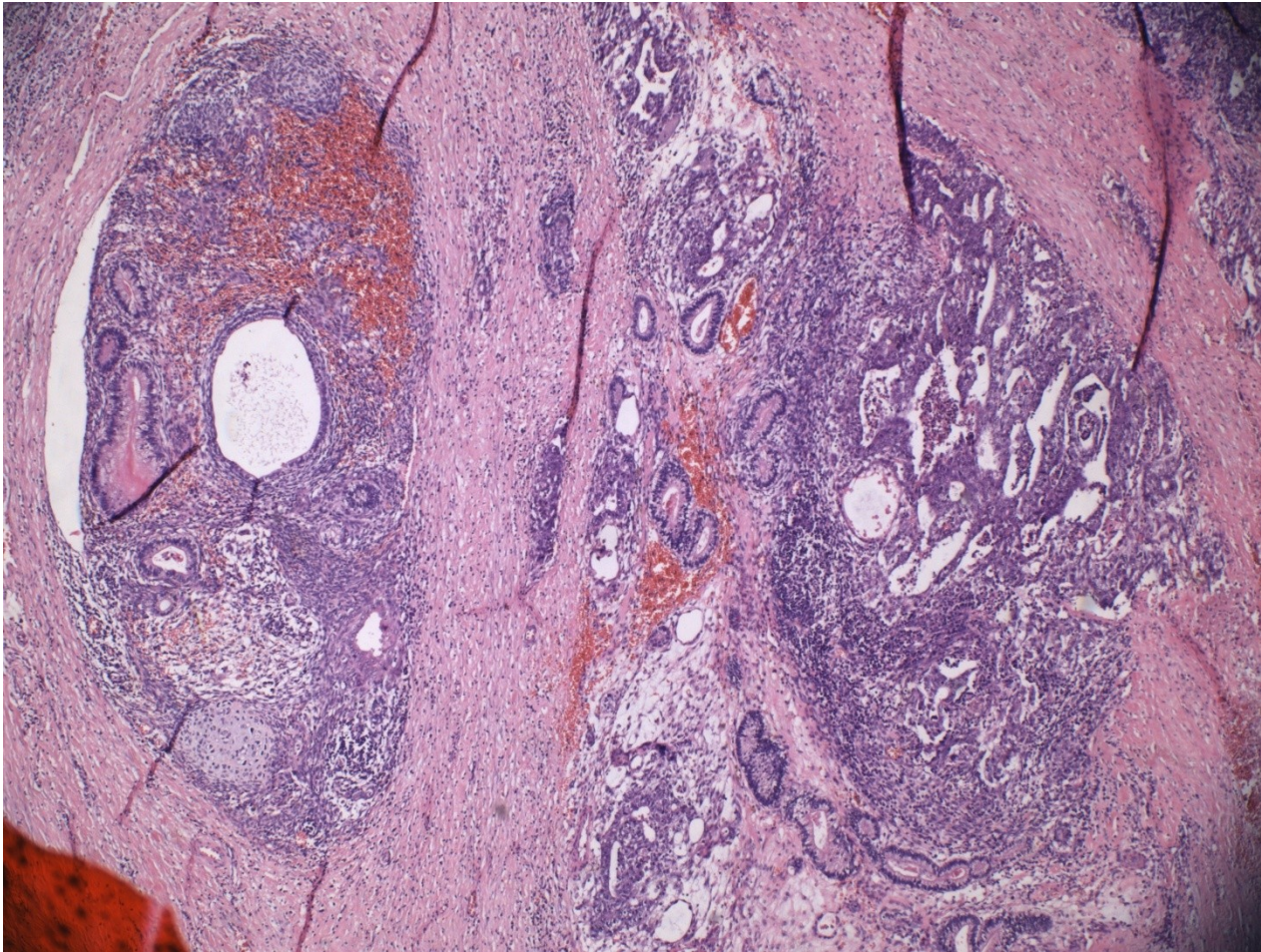
Teratoma



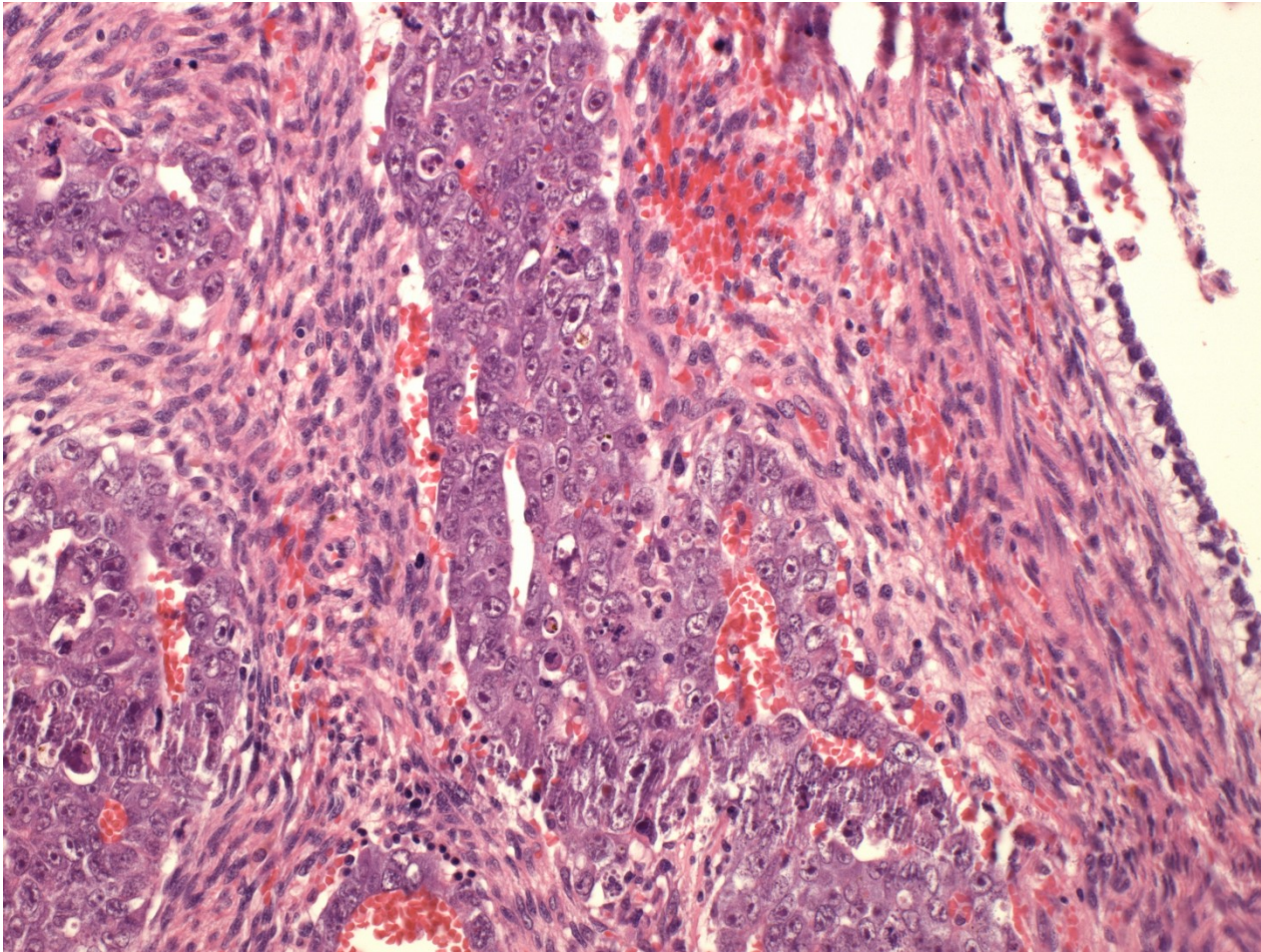
Teratoma



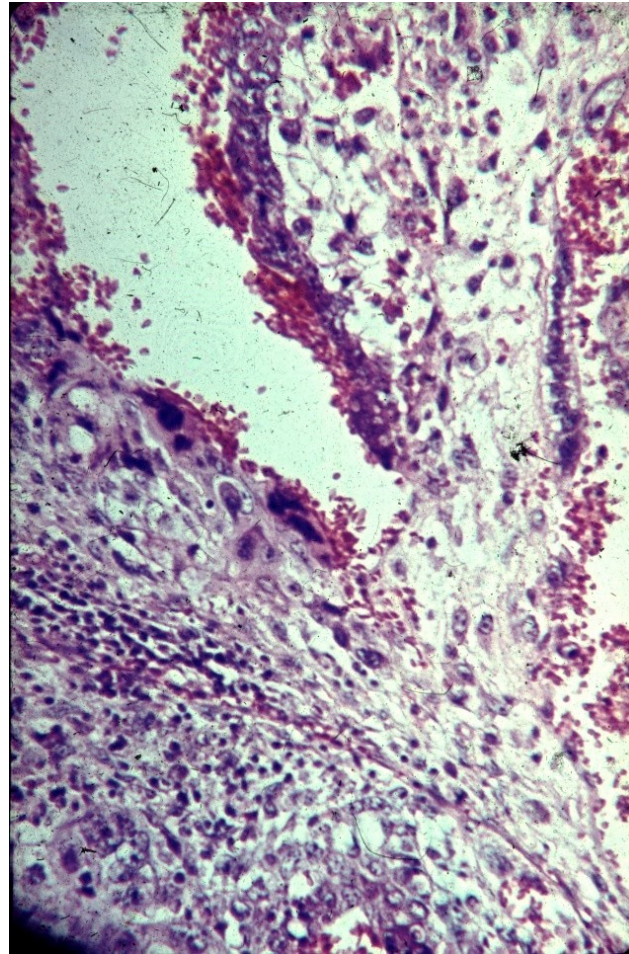
Teratoma + embryonal ca



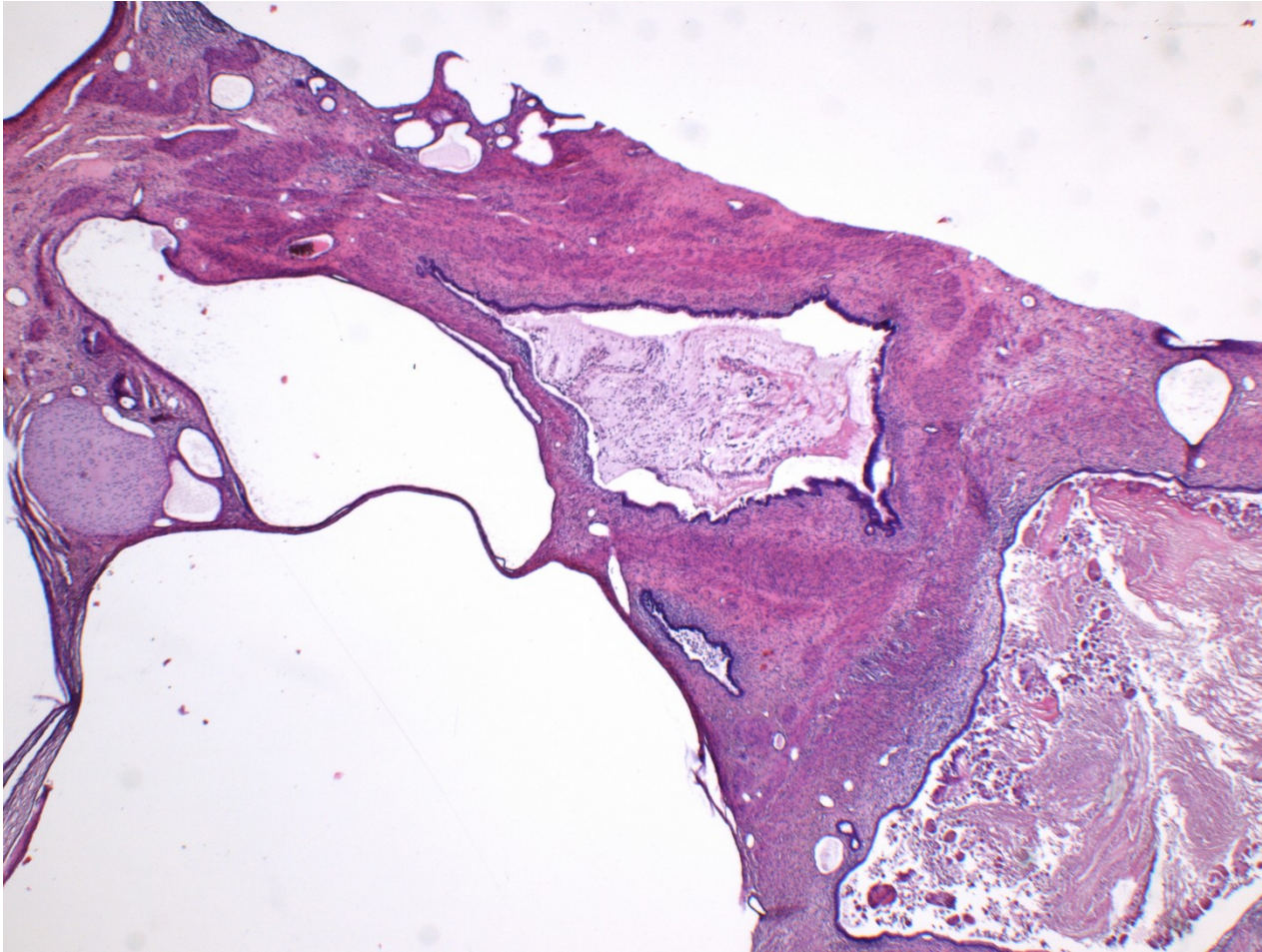
Teratoma + embryonal ca



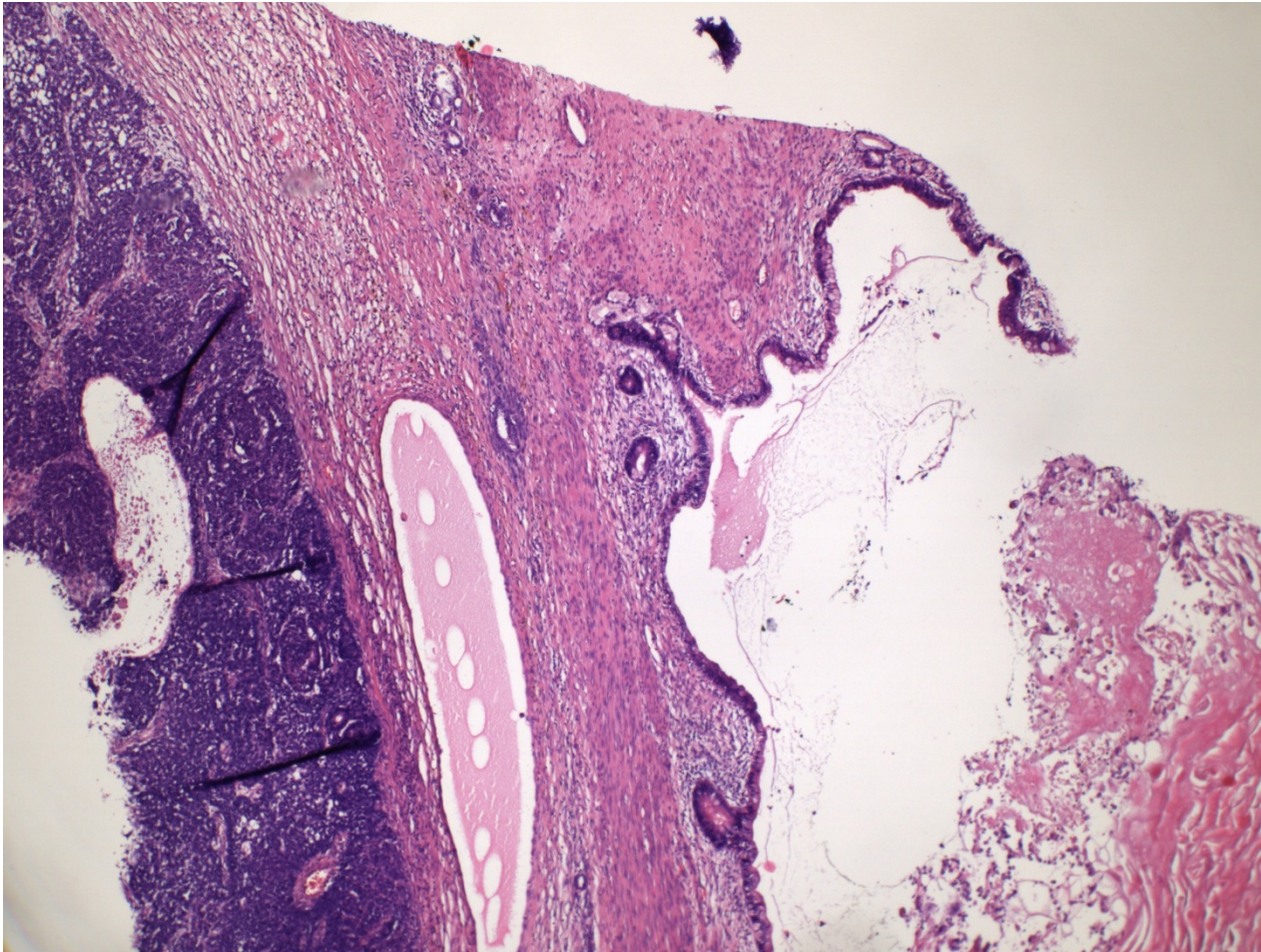
Teratoma + choriocarcinoma



Teratoma – meta in lungs

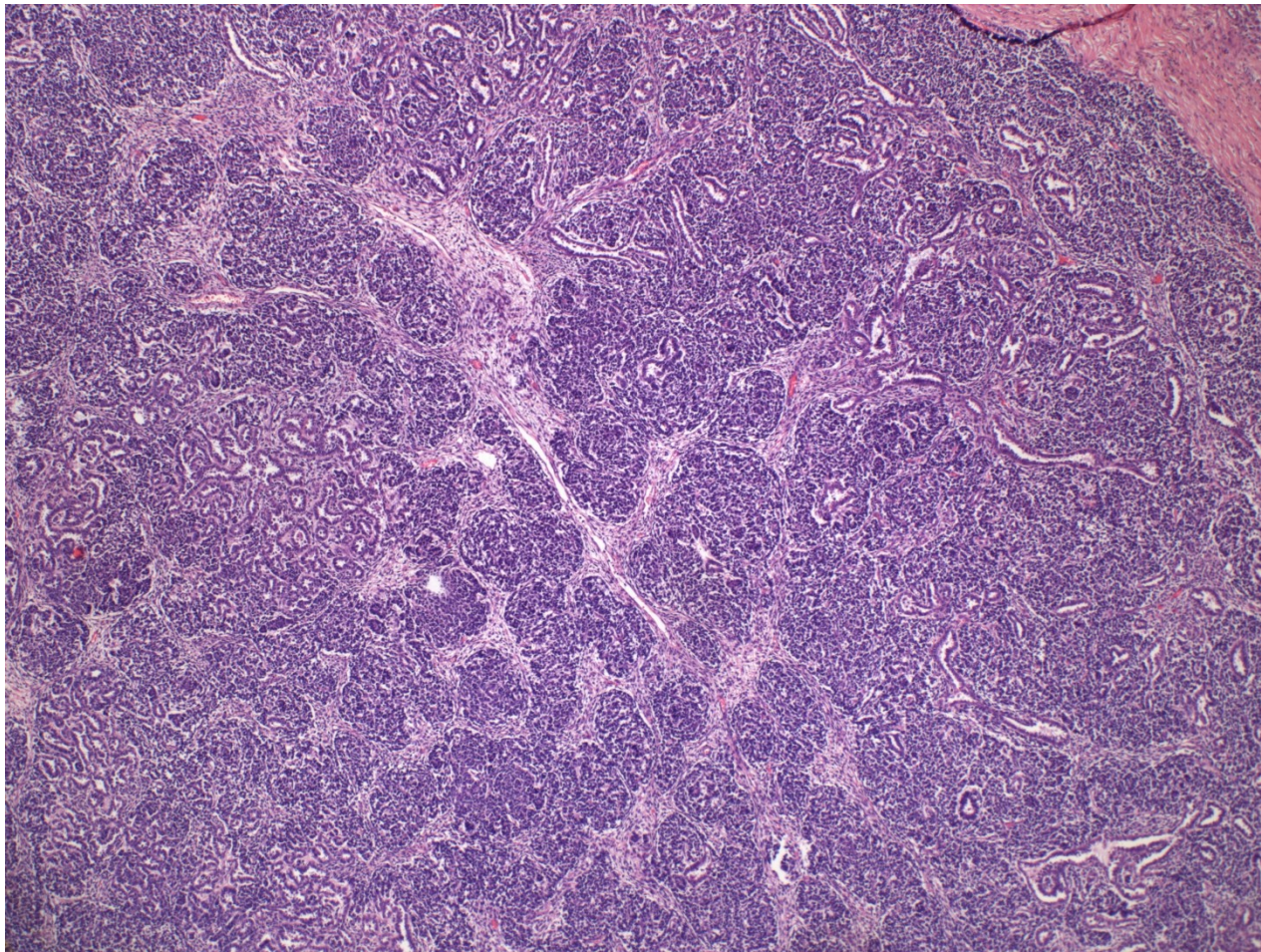


Teratoma – meta in lungs



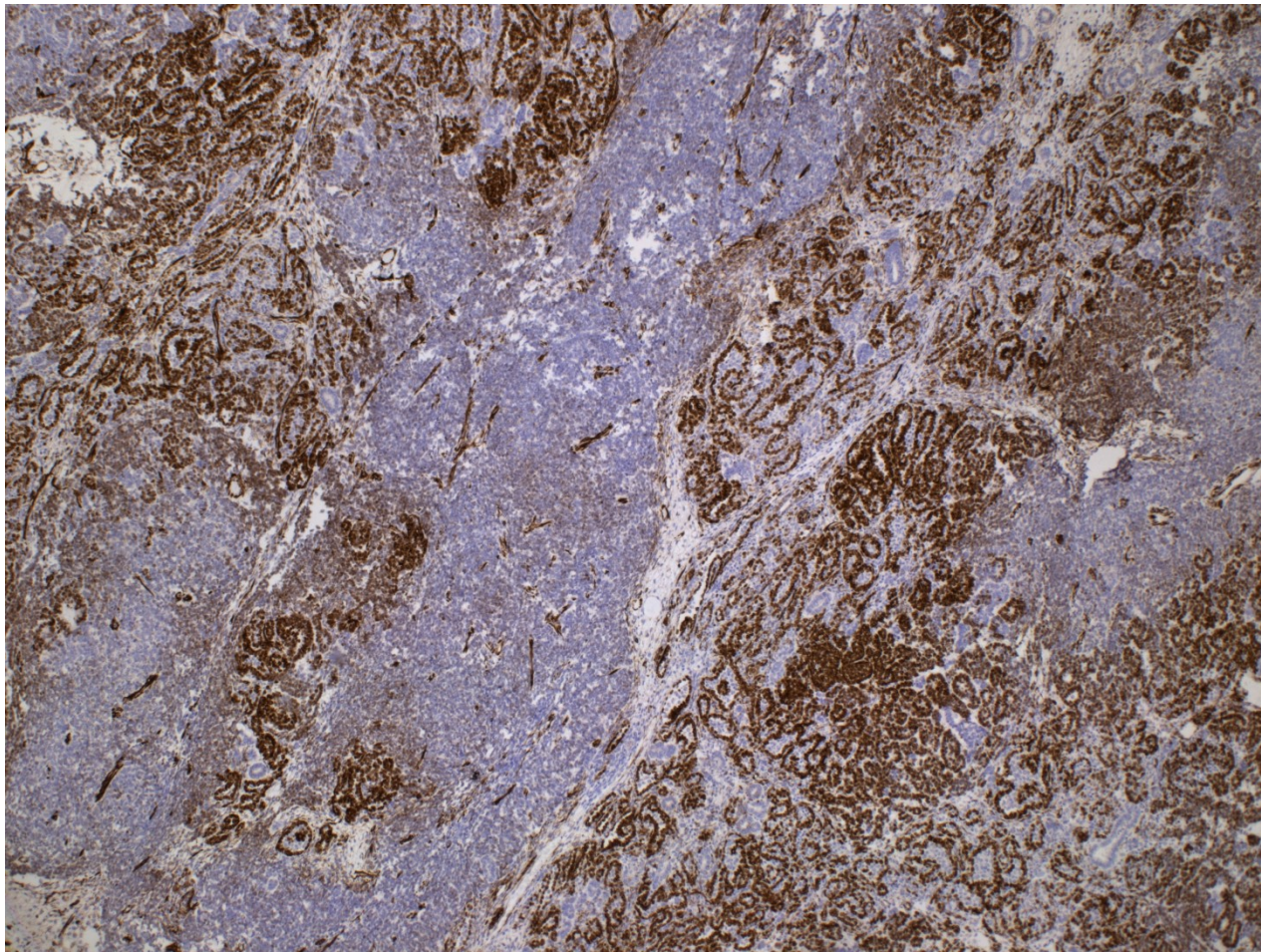
Teratoma w. somatic malignancy

nephroblastoma



Teratoma w. somatic malignancy

nephroblastoma



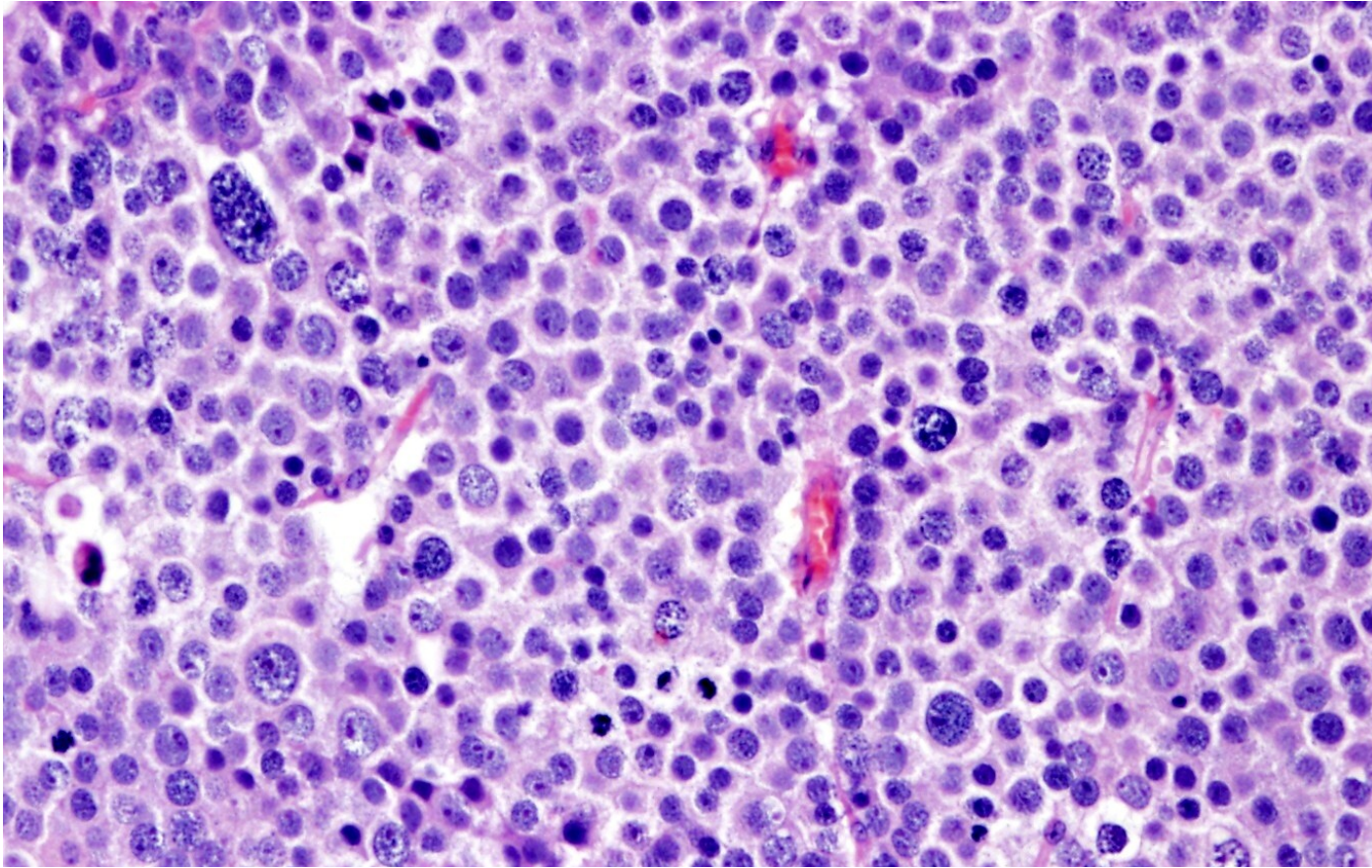
Germ cell tumors

- lymphatic spread common (paraaortic LN)
- hematogenous possible, esp. in non-seminomatous (lungs, bones, liver, brain)
- different histology in metastasis possible
- scarring of the primary tumor possible (burn-out tumor) – diff. dg. x other primary localization

Spermatocytic tumor

- unrelated to germ cell neoplasia in situ
- usual age > 65 yrs
- slow growth, rare metastasis
- more pleiomorphic cells – variable stages of differentiation
- no stromal reaction

Spermatocytic tumor

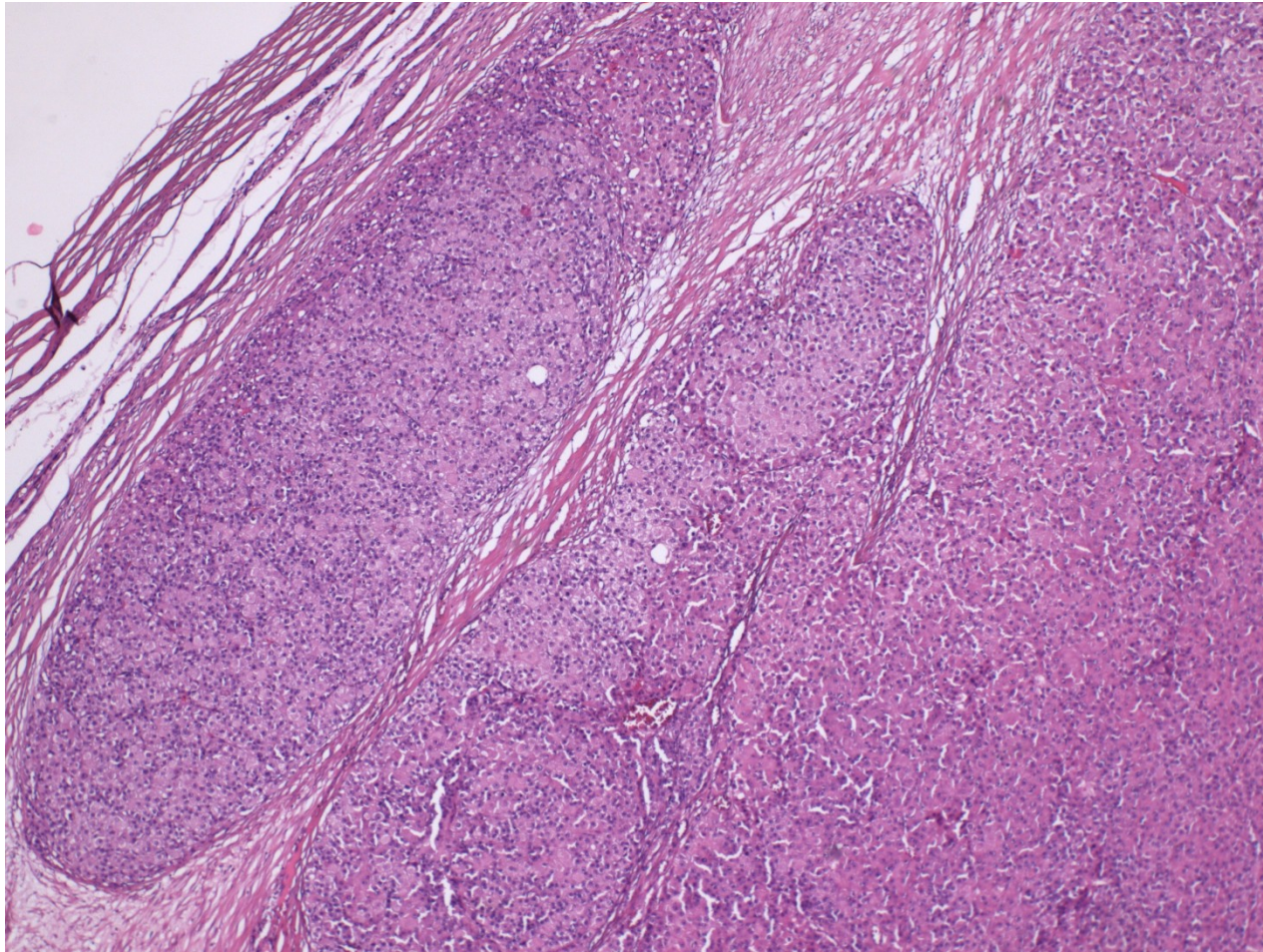


Mixture of polymorphic tumor cells (~ early stages of spermatogenesis): large cells with lacy chromatin, middle-sized cells with round nuclei, small lymphocyte-like cells.
Fibrotic septa without lymphocytic infiltrate

Sex cord-stromal tumors

- less common than germ cell tu
- Leydig cell tumor
 - any age, peak middle age
 - androgen secreting cells – clinical signs incl. precocious puberty
 - benign or malignant, similar histology
- Sertoli cell tumors
 - very uncommon, mostly benign

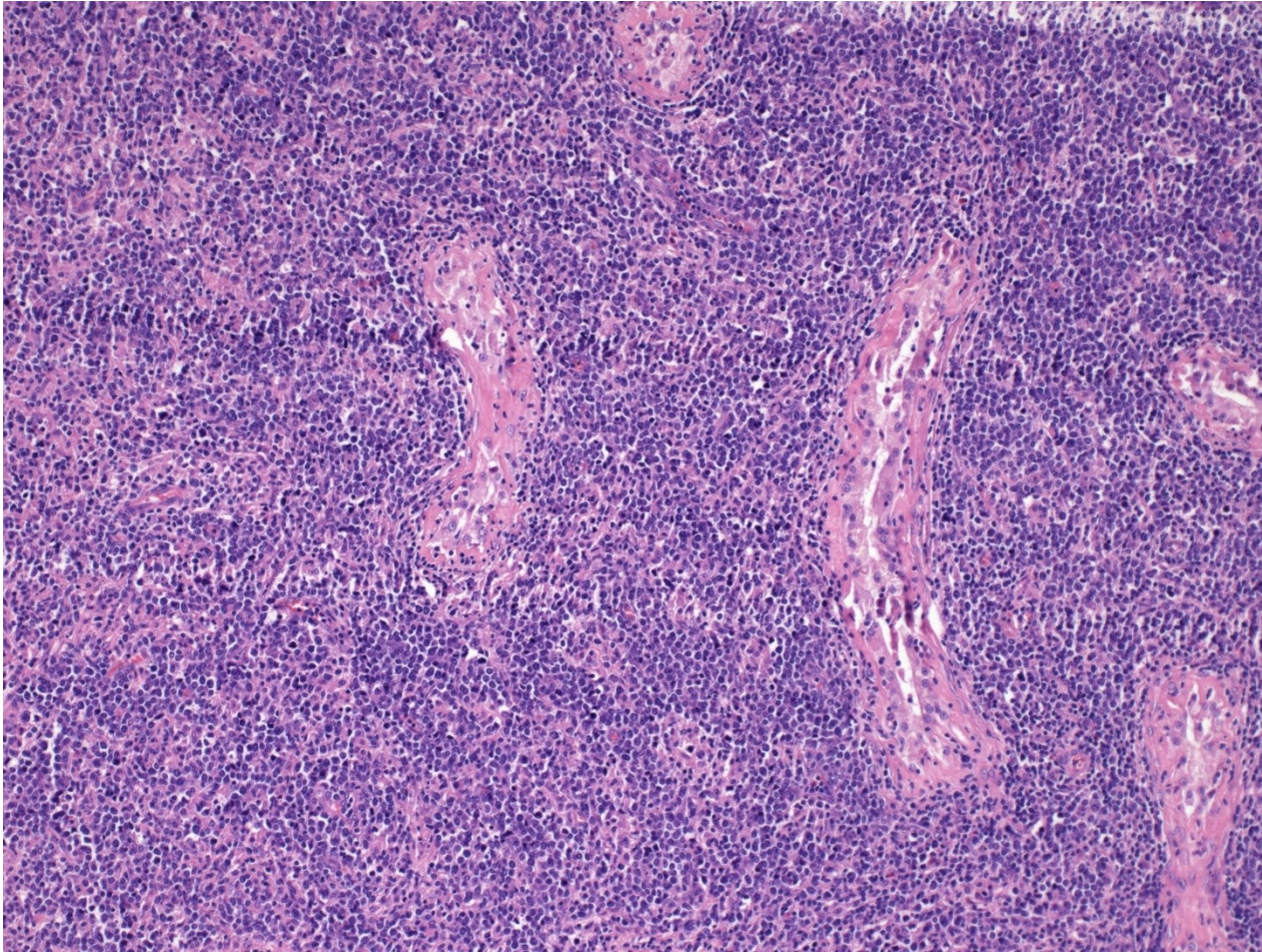
Malignant Leydig cell tumor



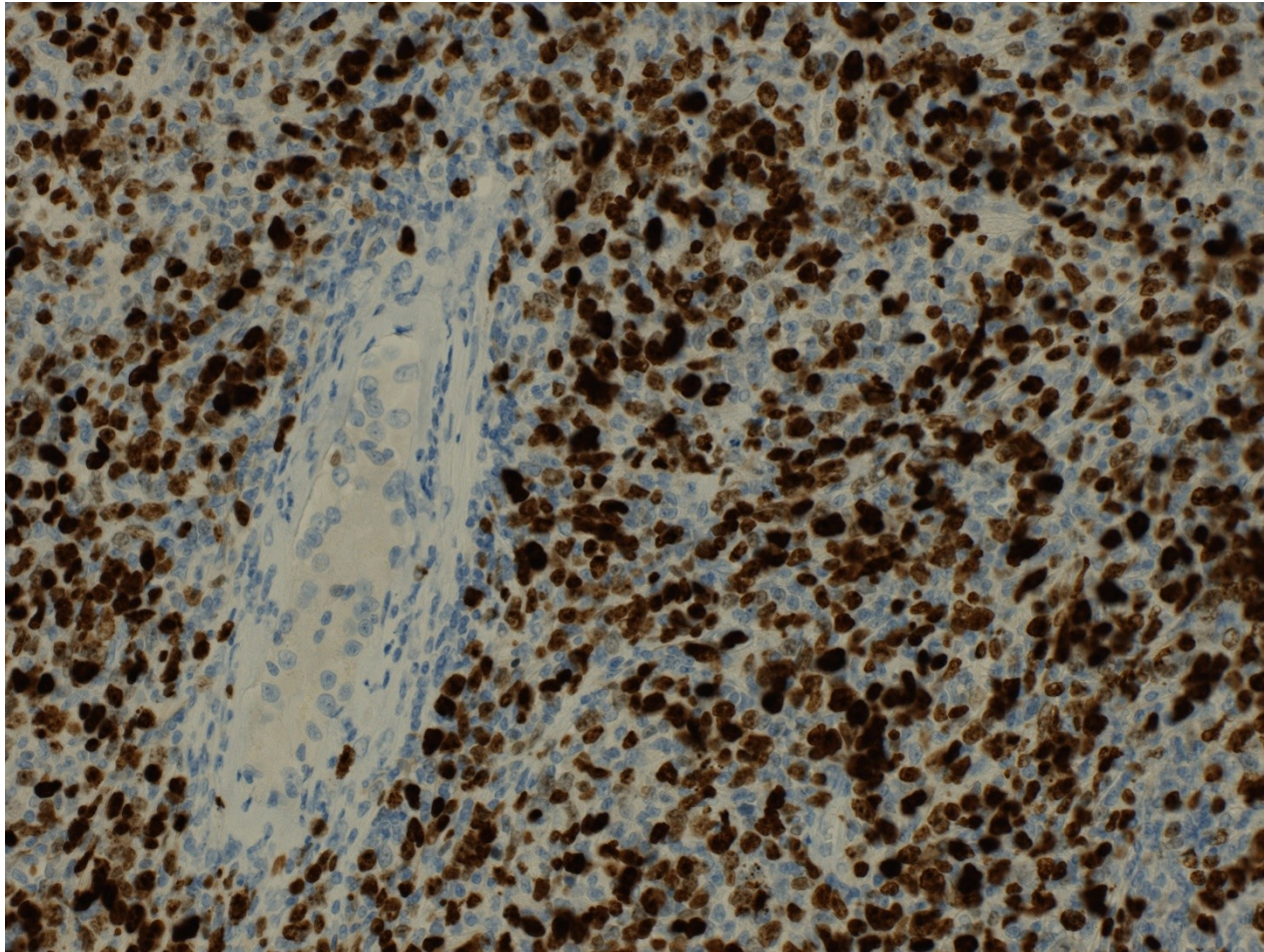
Other testicular tumors

- primary malignant lymphoma
 - older males, in this age ML more common than germ cell tu
 - commonly DLBCL
 - may be already systemic

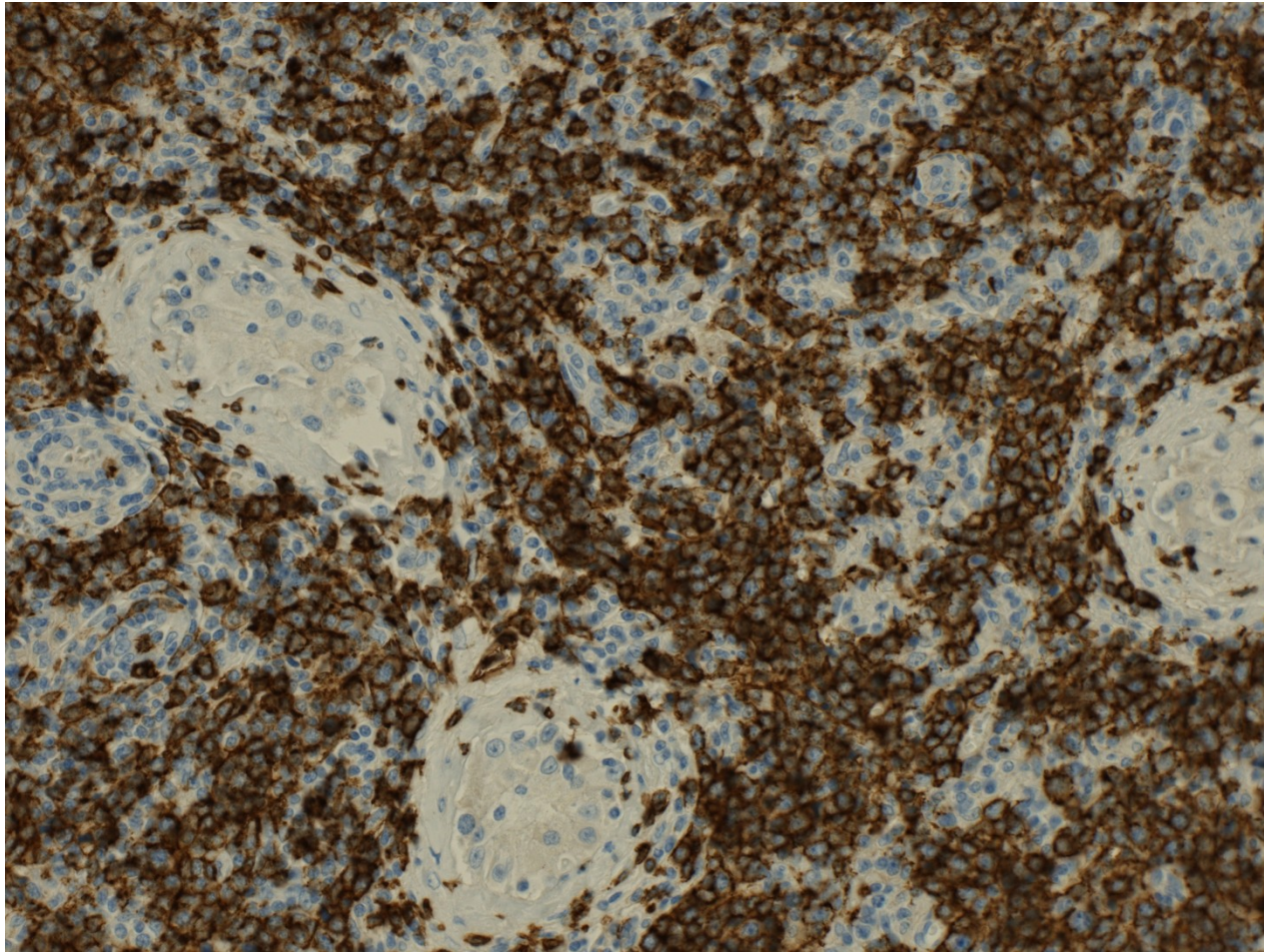
Testicular DLBCL



Testicular DLBCL – Ki-67 proliferation rate



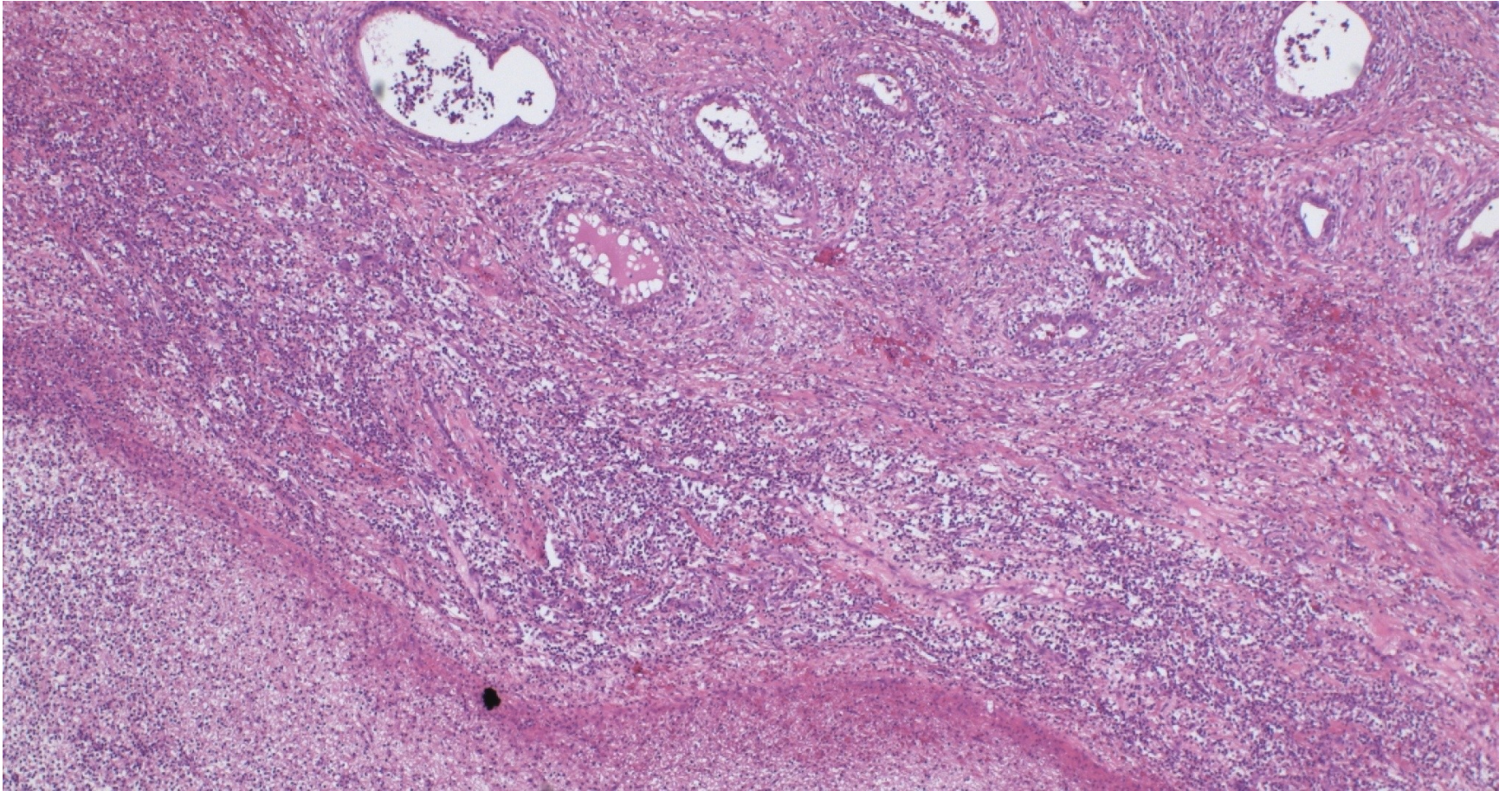
Testicular DLBCL – CD20+ B-cell type



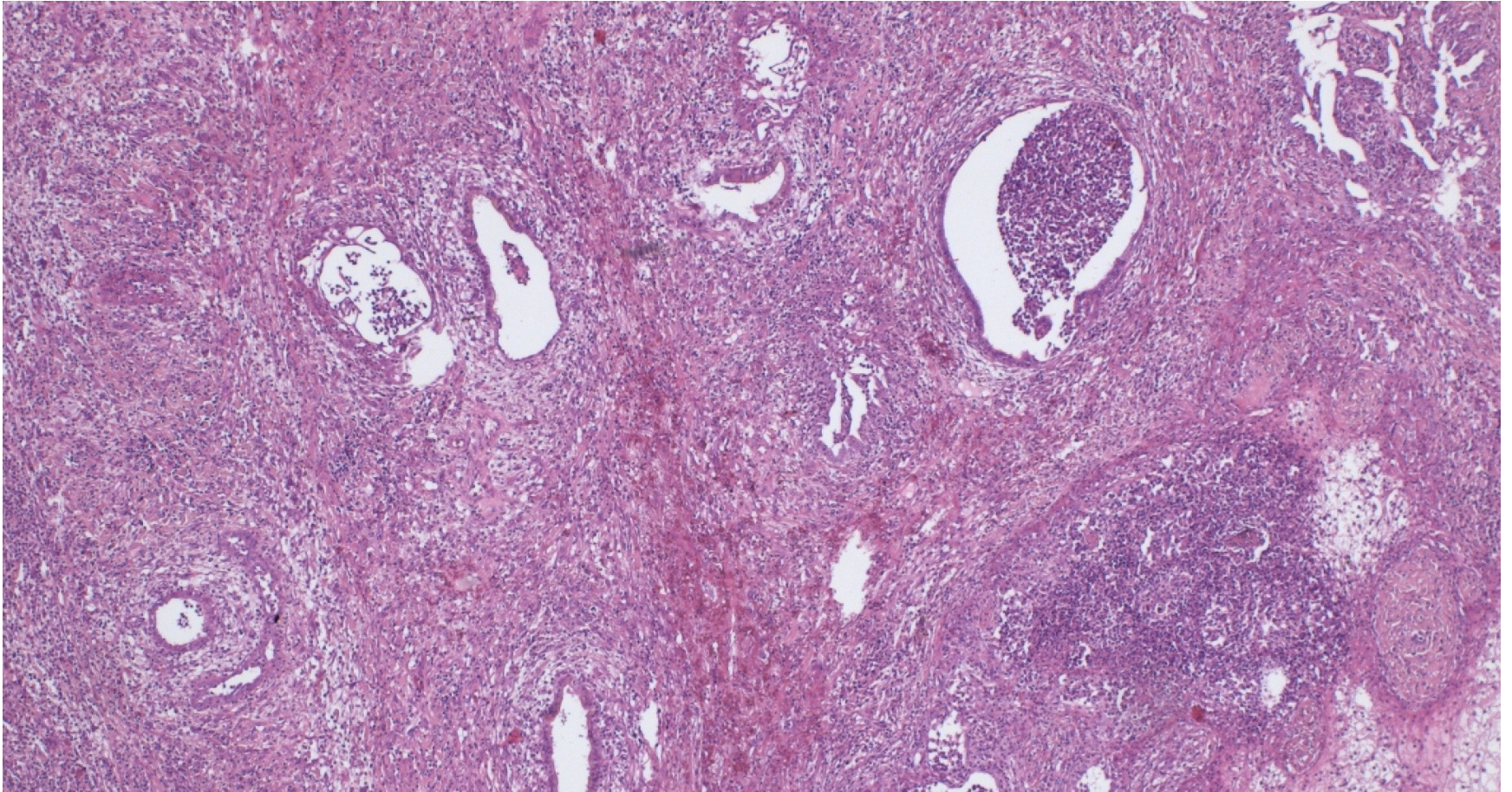
Epididymitis

- nonspecific epididymitis most common
- usually connected to UTI, bacterial
- purulent, abscess formation, necrosis
- progression to orchitis
- healing by repair, fibrosis + cysts possible
- diff. dg. x tumors

Epididymitis w. abscess



Epididymitis w. abscess



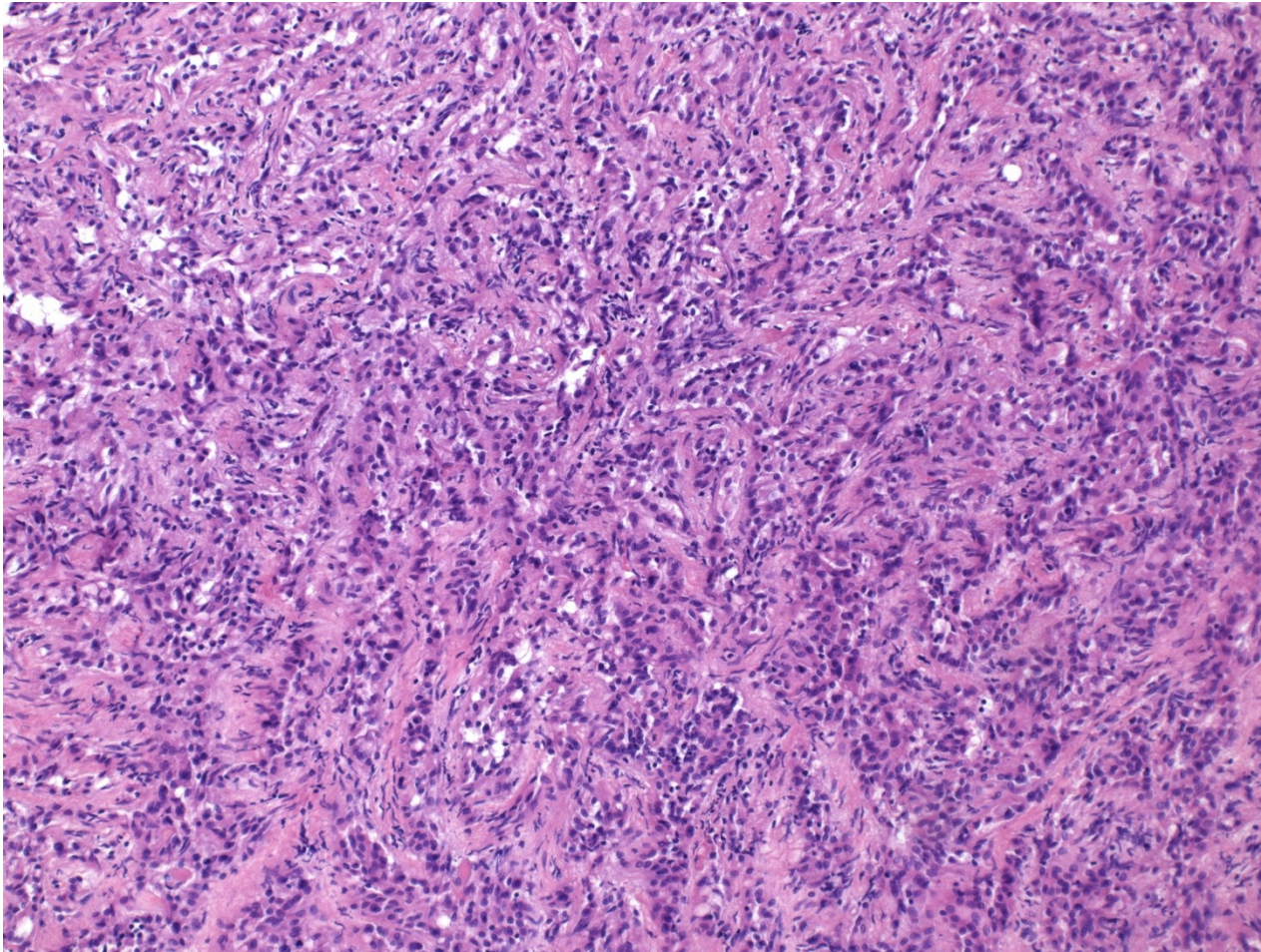
Sperm granuloma

- pathological situation of sperm in direct contact with stroma
- chronic granulomatous inflammation
- diff. dg.
 - macro x tumor
 - micro x other causes of granuloma incl. TB

Tumors

- most commonly extension from testicular tumors
- primary tumors rare
 - adenomatoid tumor: benign, phenotype mesothelial, possibly from remnants of Müllerian tract

Adenomatoid tumor



Adenomatoid tumor

