

Female genital tract

V. Žampachová
I. ÚP LF MU

Inborn defects

- Complicated embryogenesis, different original tissues (mesoderm → gonads;
paramesonephros → müllerian ducts → ovarian tubes, uterus, upper part of vagina
urogenital sinus → lower part of vagina, vestibulum
mesothelium → ovarian surface, tubal epithelium, endometrium

FLORA of the REPRODUCTIVE SYSTEM

- *Lactobacillus, Streptococcus, Corynebacterium, Mycobacterium.*
- *Candida albicans*
- The flora occupies the external genitalia. Internal reproductive structures normally remain sterile.

Genital tract infections

- Genital tract – open to the outside, barriers necessary
- **Barrier function** - vaginal flora, endocervical mucus
- **Predisposing factors** – nonexistent barrier (age), barrier defect (loss of protective vaginal flora, menstruation, abortion, delivery + residua, instrumentation and other mucosal microtraumata, systemic diseases, drugs,...)

Genital tract infections

- **Ascending infection** most usual (STD, G- fecal bacteria – E. coli, Proteus,...)
- Lower genital tract (**STD** – HSV, molluscum contagiosum, HPV, trichomonas, chancroid, granuloma inguinale; **endogenous** – candida)
- Entire genital tract (**STD** – gonorrhea, chlamydia, mycoplasma, syphilis; **endogenous** – enteric bacteria), may end in PID

The Female Reproductive System

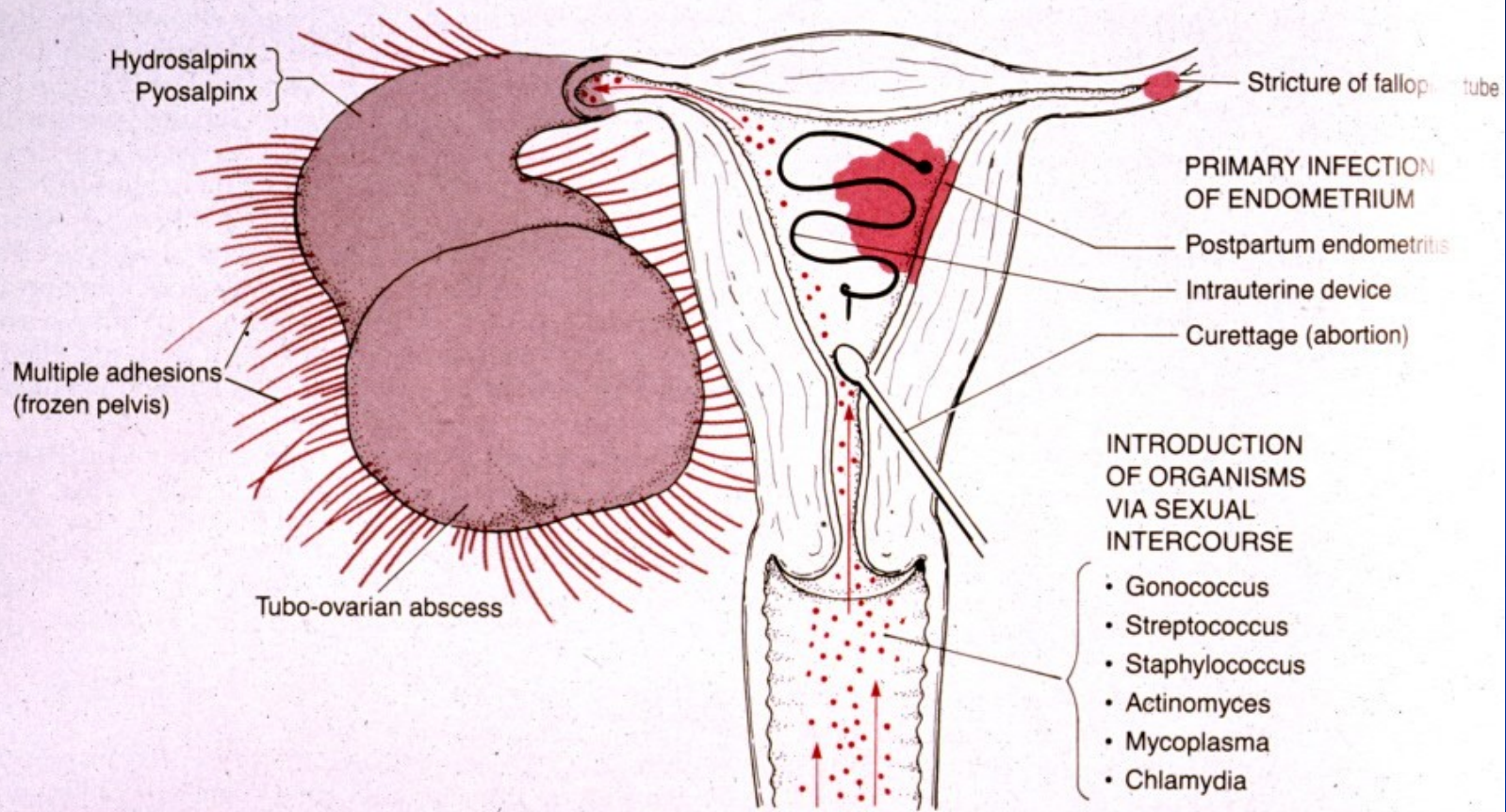
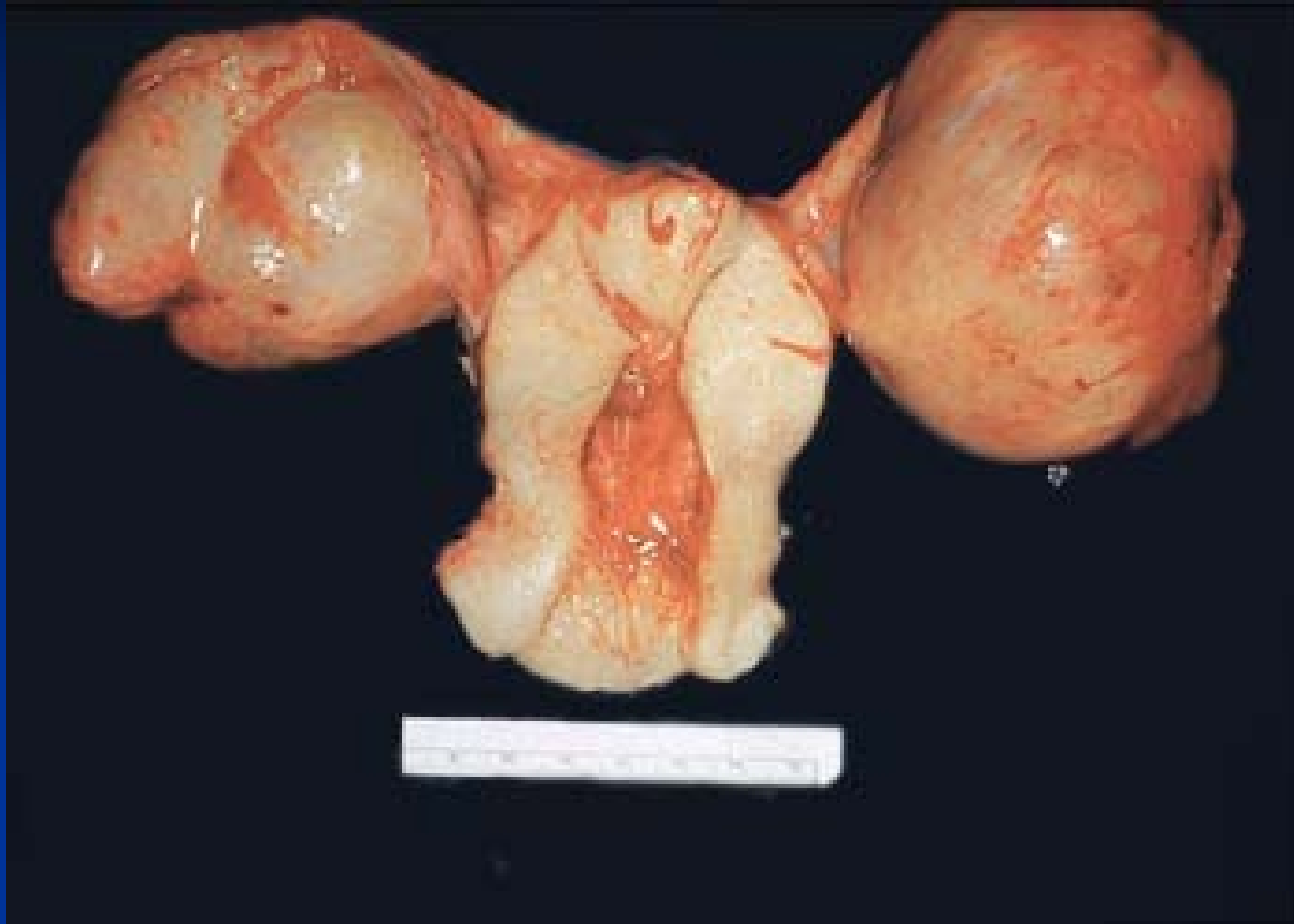

FIGURE 18-2
Pelvic inflammatory disease.

Robbin's Pathologic Basis of Disease

Acute endometritis and salpingoophoritis



Sexually Transmitted Infections

- Sexually Transmitted Disease – **STD/STI**
- Infection transmitted through vaginal, anal or oral sex
- Every sexually active individual is at risk
- Women acquire infections from men more than men from women
- 2/3 of STD occur in people under 25 yrs of age
- Infection by multiple agents common (↑ risk)
- Fetus or infants – vertical transplacental or perinatal transmission of STD → abortus, inborn defects, neonatal infection. Diagnosis + treatment!!

STI

ascending inf.: endometritis, salpingitis, PID



■ sexual partner → horizontal transmission → STI



vertical transmission: placenta (fetus, neonate)

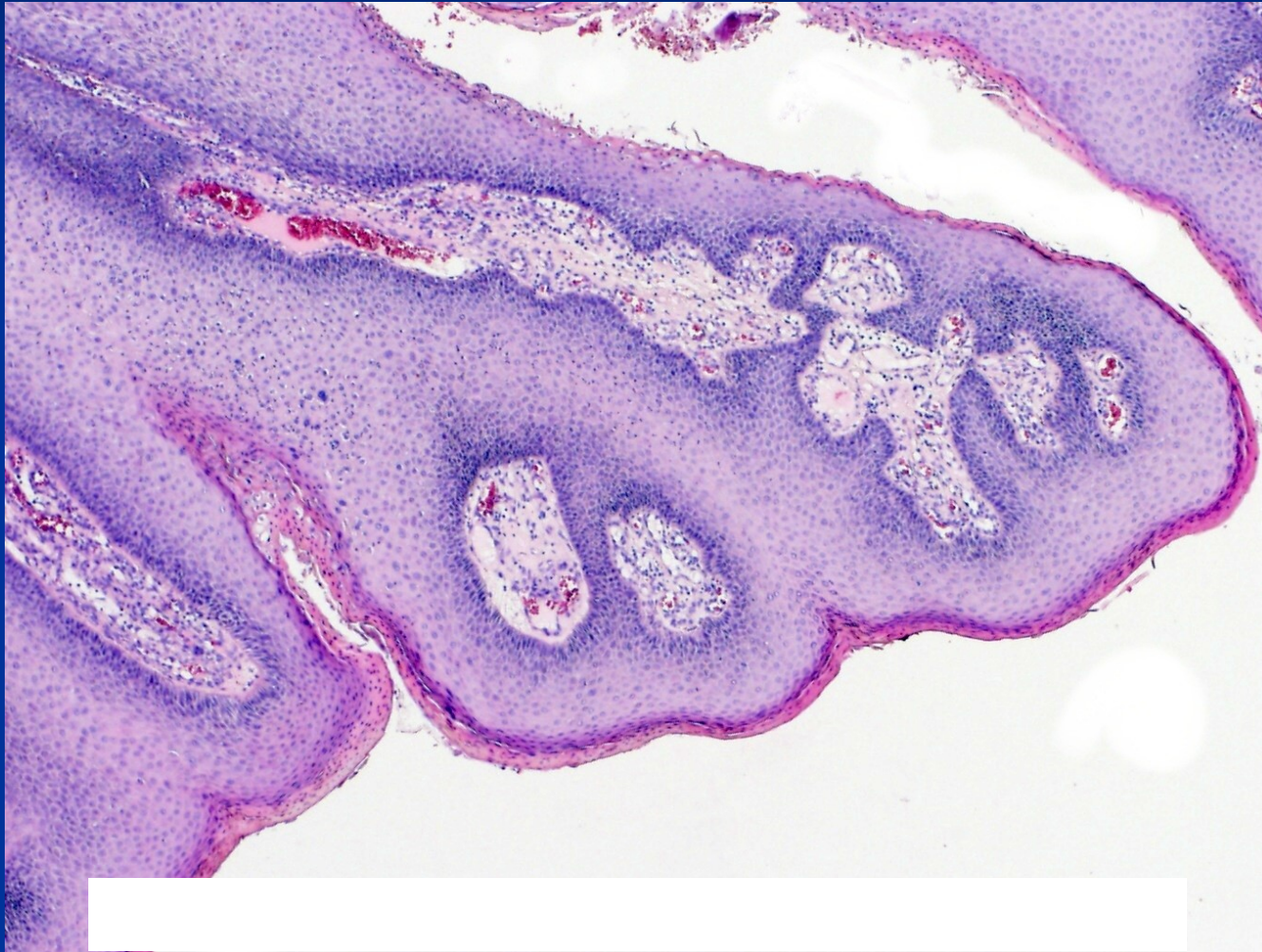
STD

- **Viruses:** HSV, HPV, HIV, hepatitis B, C
- **Chlamydiae:** Ch. trachomatis
- **Mycoplasmas:** M. urealyticum (urethritis)
- **Bacteria:** Neisseria gonorrhoeae, Treponema pallidum, Haemophilus ducreyi (chancroid), Klebsiella granulomatis (granuloma inguinale)
- **Protozoa:** Trichomonas vaginalis (urethritis, balanitis, vaginitis)

Genital warts

- Condyloma accuminatum - HPV
- Most HPV infections asymptomatic or unrecognized
- Mostly found in young, sexually active; associated with early onset of sexual activity, multiple sexual partners
- Transmitted by all types of sexual contact
- Usually cleared from host's organism
- Vaccination (already ↓ in low risk types manifestations – LSIL)

Condyloma accuminatum



Genital warts: complications

- Possible urethral obstruction or destruction of normal tissue
- Can be transferred to fetus during pregnancy or delivery
- Large warts may obstruct the birth canal; cesarean section may be necessary
- Infants infected may develop a chronic respiratory condition – laryngeal papillomatosis

Chlamydia: manifestations

- In females often asymptomatic until uterus and tubes infected; may present with dysuria, urinary frequency, vaginal discharge
- (1/3 of males may be asymptomatic; dysuria, urethral discharge, testicular pain)
- Patient infectious even if asymptomatic

Chlamydia: complications

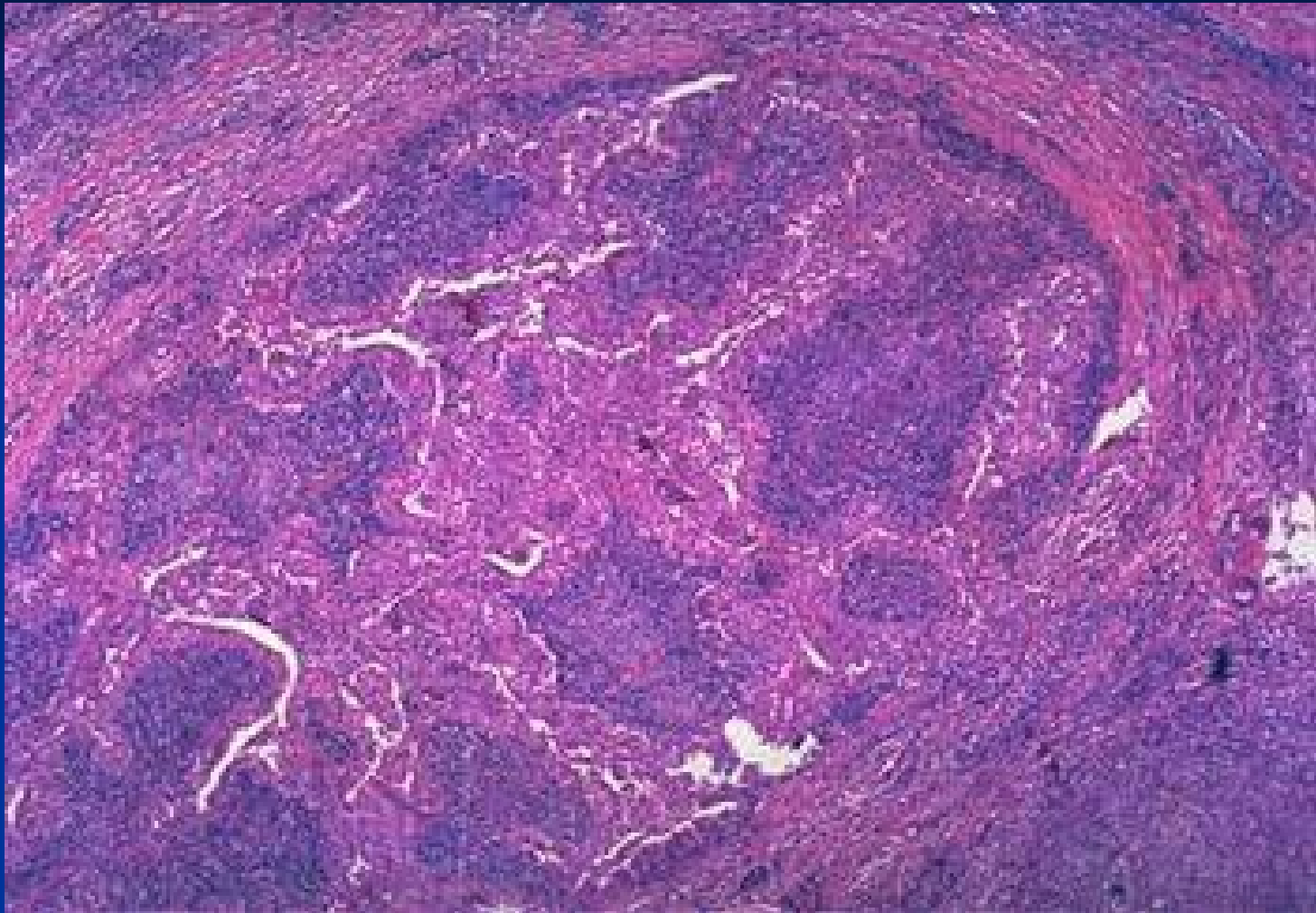
- May result in PID (pelvic inflammatory disease)
- Major cause of infertility, ectopic pregnancy in women; may cause stillbirth or spontaneous abortion (miscarriage)
- (In males may result in epididymitis, prostatitis, sterility, Reiter's syndrome)
- In neonates may cause blindness, pneumonia

Gonorrhoea

- ‘clap’; one of the most common STDs (second only to Chlamydia)
- Caused by *Neisseria gonorrhoeae*; incubation period is 2-8 days
- Transmitted by sexual contact, during passage through the birth canal
- Usually targets the cervix, (male urethra)

Gonorrhoea

- Female: mostly asymptomatic until advanced disease; dysuria, urinary frequency or abnormal vaginal discharge
- (Male: dysuria, serous, milky or purulent urethral discharge; regional lymphadenopathy)
- Complications: (prostatitis, epididymitis, sterility); PID, endometritis, salpingitis, peritonitis; in neonates gonorrhoea can infect the eyes, nose or anorectal region



Purulent salpingitis - gonorrhoea

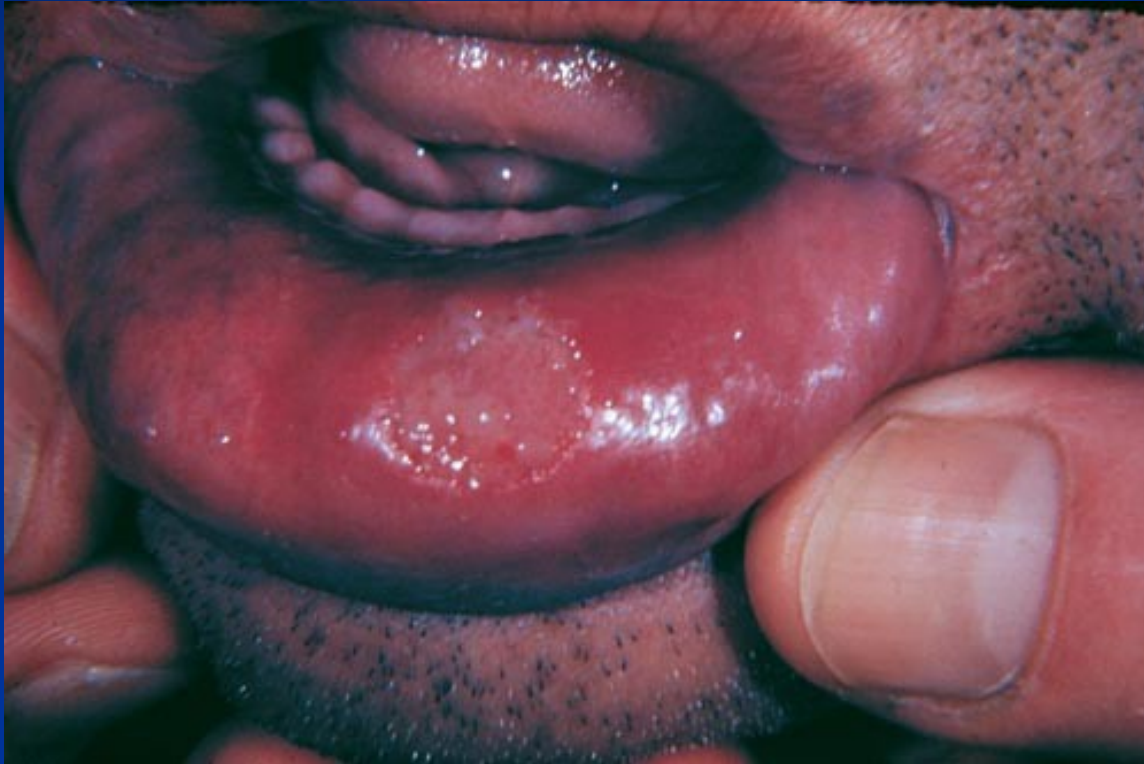Syphilis

- Spirochete *Treponema pallidum*
- Transmitted from open lesions during sexual contact
- Organism can survive days in fluids
- May also be transmitted by infected blood, body fluids, including saliva
- Average incubation is 20-30 days
- Spreads through blood, lymphatic system
- Congenital syphilis - transplacental

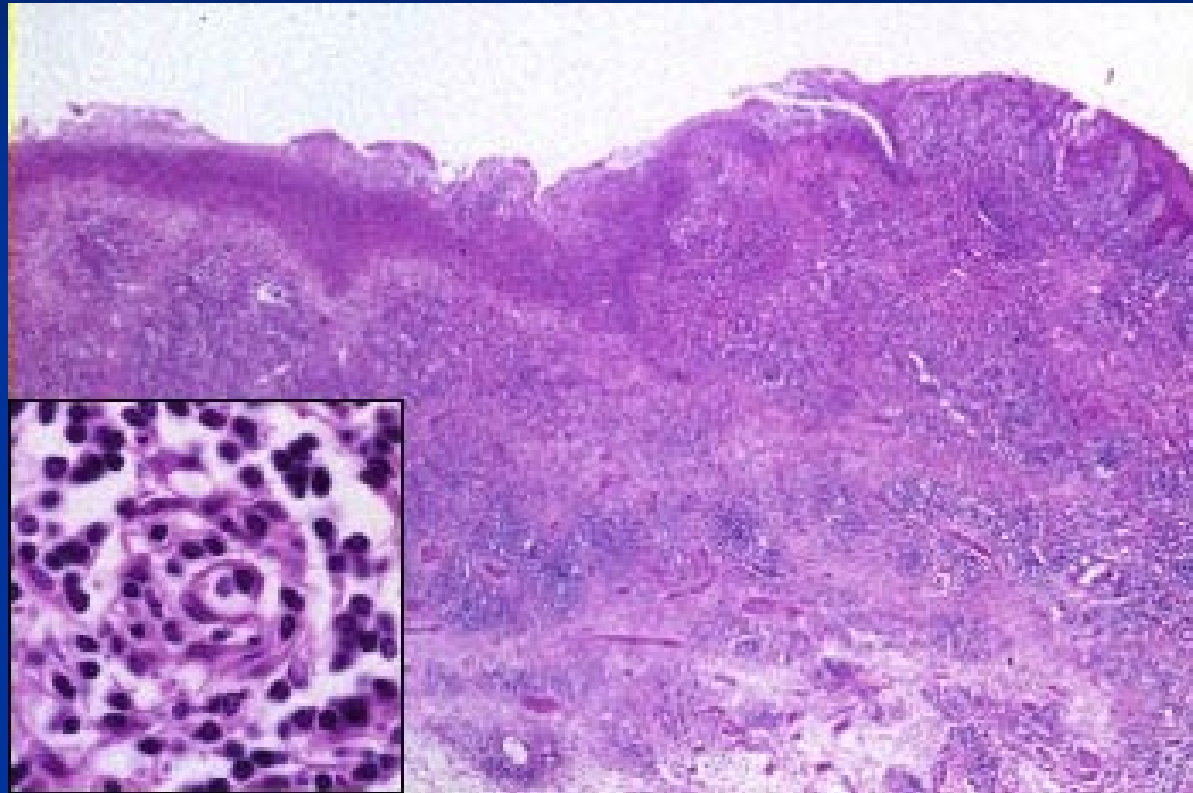
Syphilis: primary stage

- **Chancre:** painless ulcer in the site of inoculation; regional lymphadenopathy
- chancre appears 3-4 weeks after infectious contact, disappears within 4-6 weeks
- Chancre may go unnoticed in women
- Highly infectious during primary stage even if no symptoms are present
- Micro: nonspecific, high amount of plasma cells in inflammatory infiltrate

Syphilis – primary



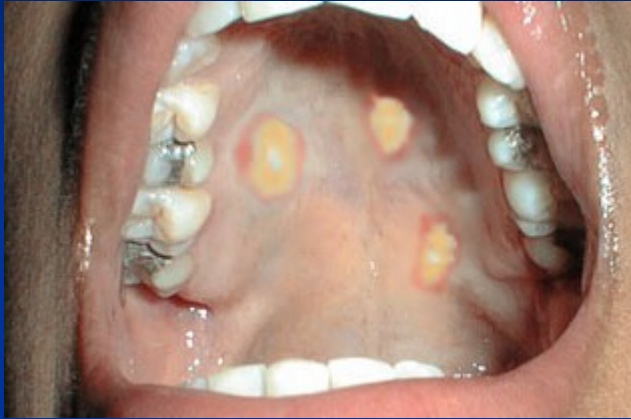Syphilitic chancre – plasma cells in infiltrate



Syphilis: secondary stage

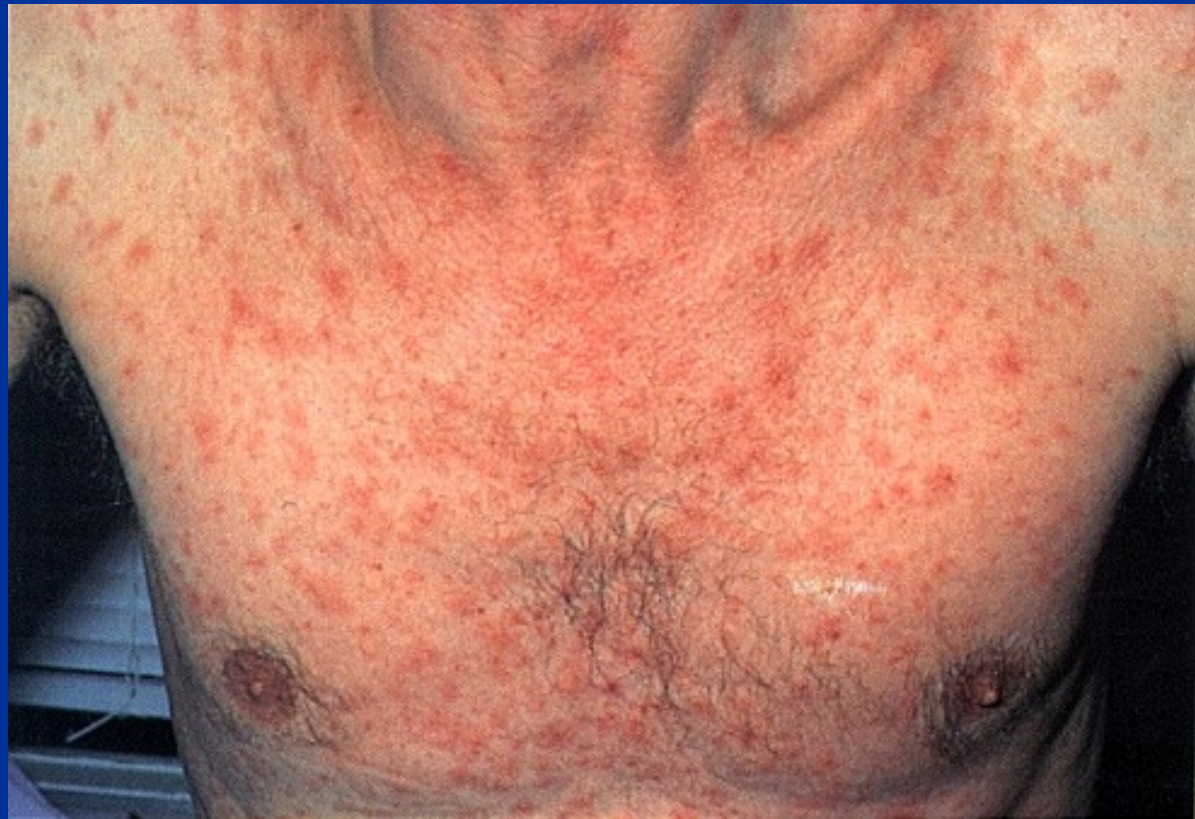- Symptoms of secondary syphilis appear any time from 2 weeks to 6 months after initial chancre disappears, in 75% of untreated people
- **Primary generalisation**, flu-like symptoms, sore throat; generalized lymphadenopathy
- **Skin rash** (especially on palms of hands and soles of feet) maculopapular, pustular;
- **condylomata lata** - mucus patches + erosions in oral cavity; flat, broad-based wart-like papules on labia, anus or corner of mouth, **highly infectious**; secondary alopecia
- Disappears within 2-6 weeks

Syphilis - secondary



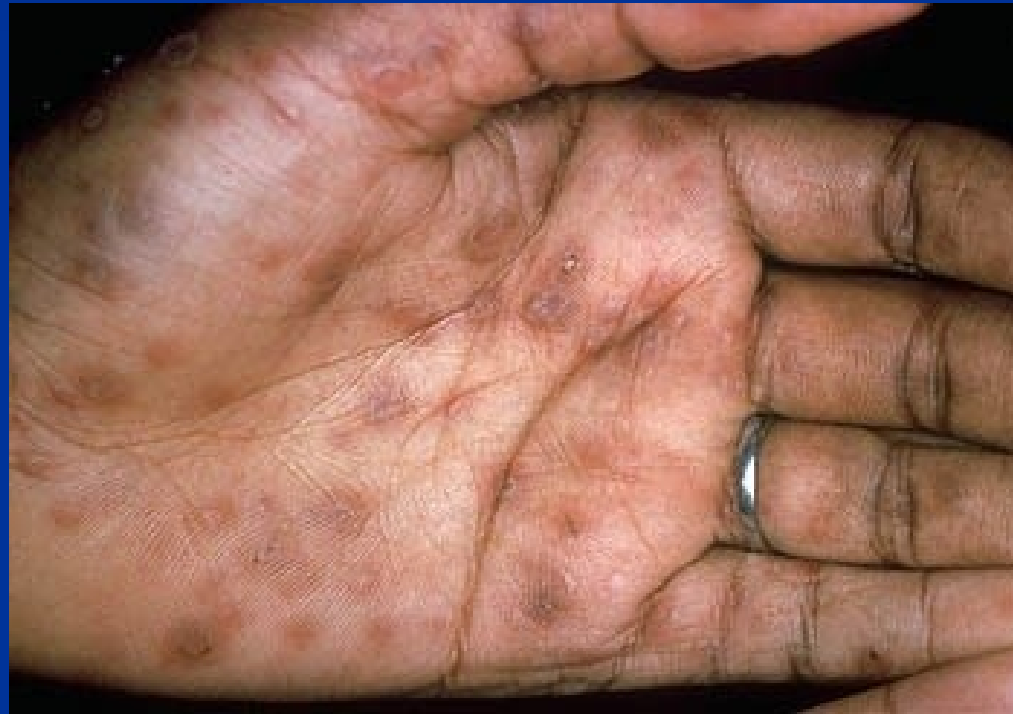Condylomata lata

Syphilitic rash

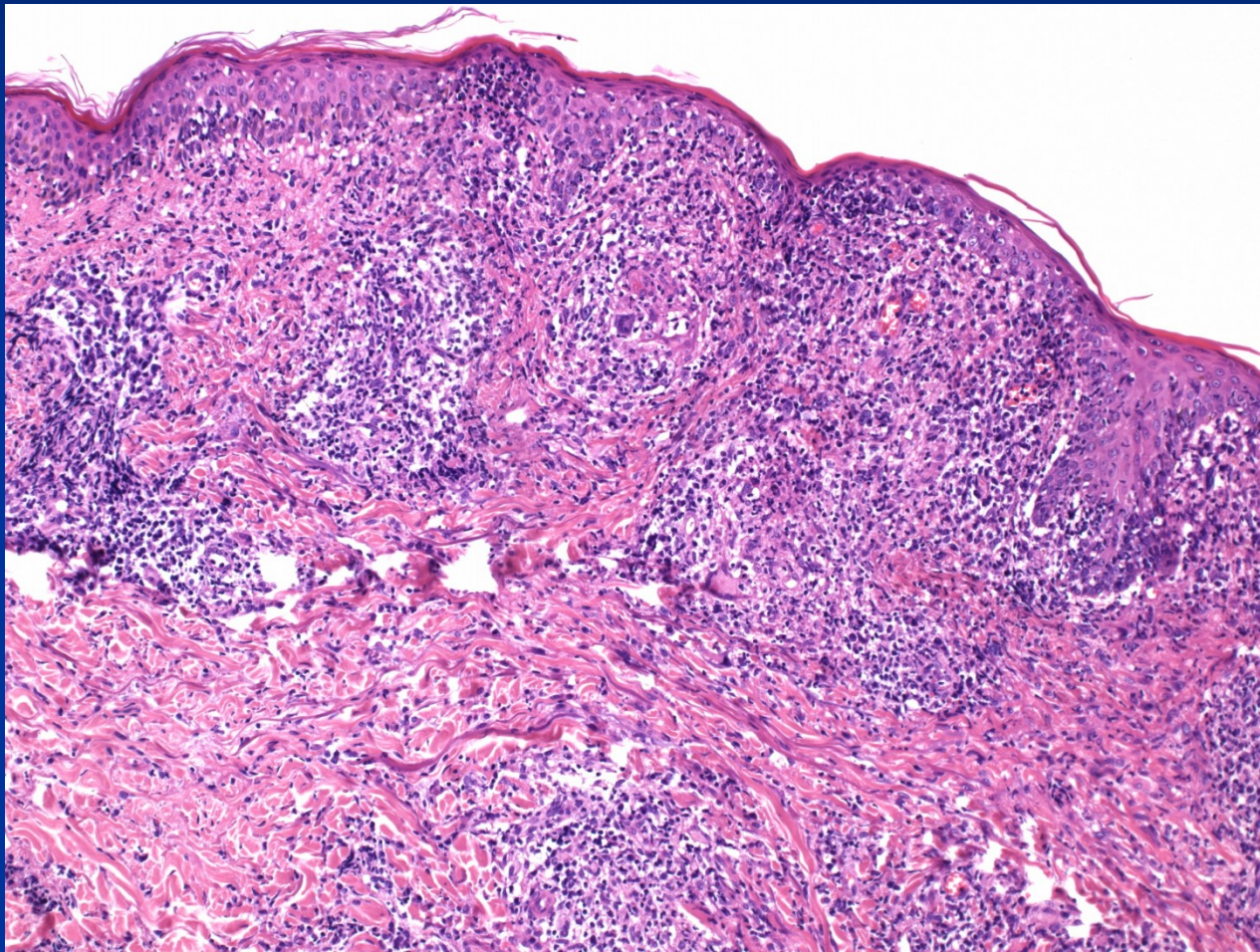


Syphilis

- secondary stage – early generalisation



Syphilis: secondary stage in HIV+



Chancroid (Soft chancre)

- *Hemophilus ducreyi*
- Mostly tropical and subtropical areas
- HIV co-transmission
- Four to seven days after infection: tender, erythematous papule → irregular ulcer
 - More painful in males; not indurated; multiple; on external genitalia
 - Inguinal lymph nodes are enlarged and tender (buboes)
- Micro: nonspecific ulcer, superficial zone of neutrophilic debris and fibrin, underlying zone of granulation tissue, lymphoplasmacytic infiltrate

Granuloma inguinale (Donovanosis)

Klebsiella granulomatis (*Calymmatobacterium donovani*)

tropical and subtropical areas

Gross: papular lesion (on genitalia) → ulcer

Ulcer : protuberant, soft, painless mass; borders raised and indurated; abundant granulation tissue; mimicking carcinoma
(**pseudoepitheliomatous hyperplasia**)

Micro: silver stains (e.g., the Warthin-Starry stain): encapsulated coccobacilli (Donovan bodies) in macrophages

lymph nodes typically spared (unlike chancroid)

Complications: extensive scarring + lymphatic obstruction, possible lymphedema (elephantiasis)

Scars in untreated cases → urethral, vulvar, or anal strictures

Pathology of ovaries

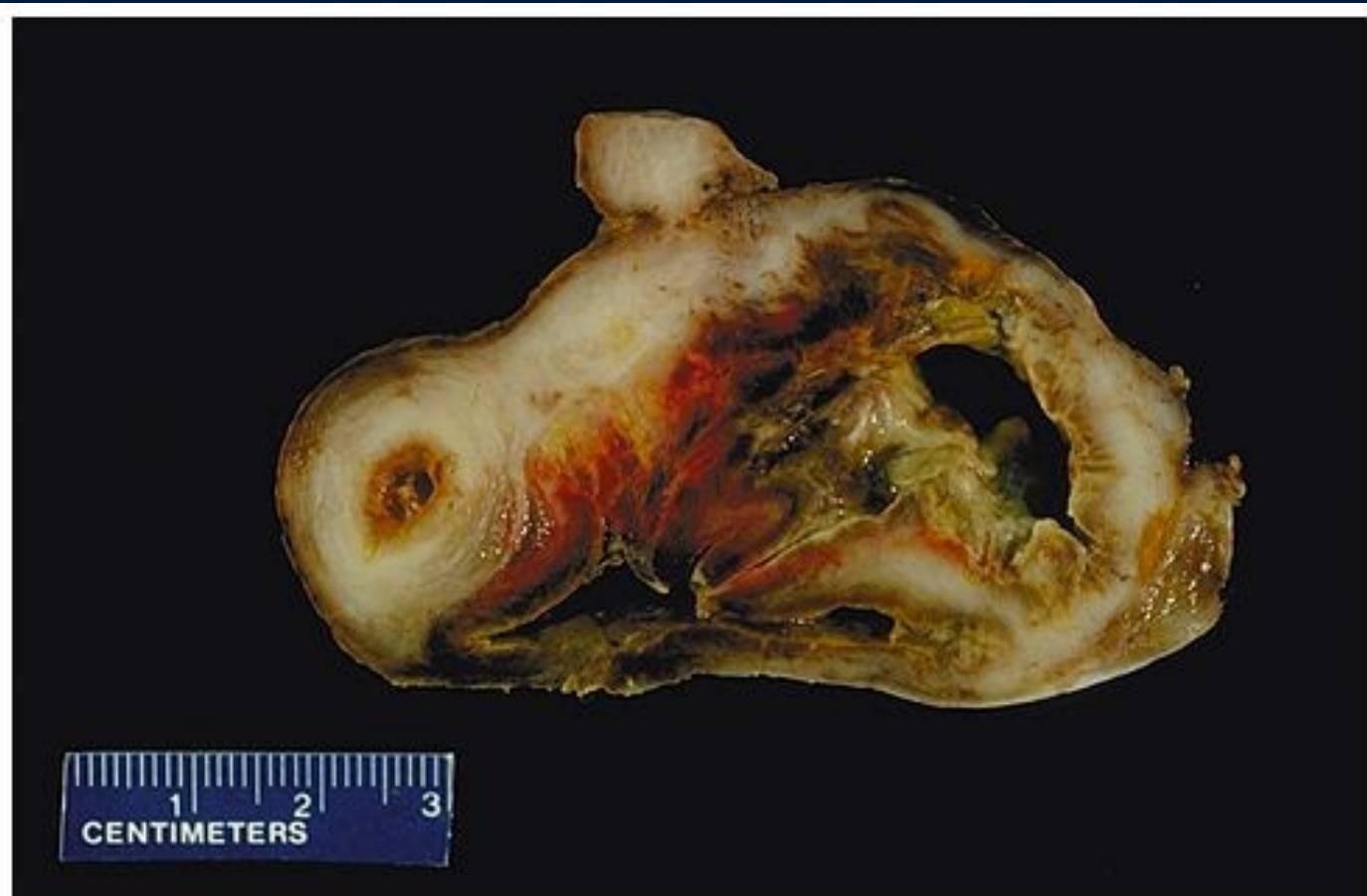- Pathological lesions: morphological, functional, commonly both
- Signs: commonly late, nonspecific (menstruation cycle and/or fertility disturbances, pelvic pain, abdominal distention) → late diagnosis

Pathology of ovaries

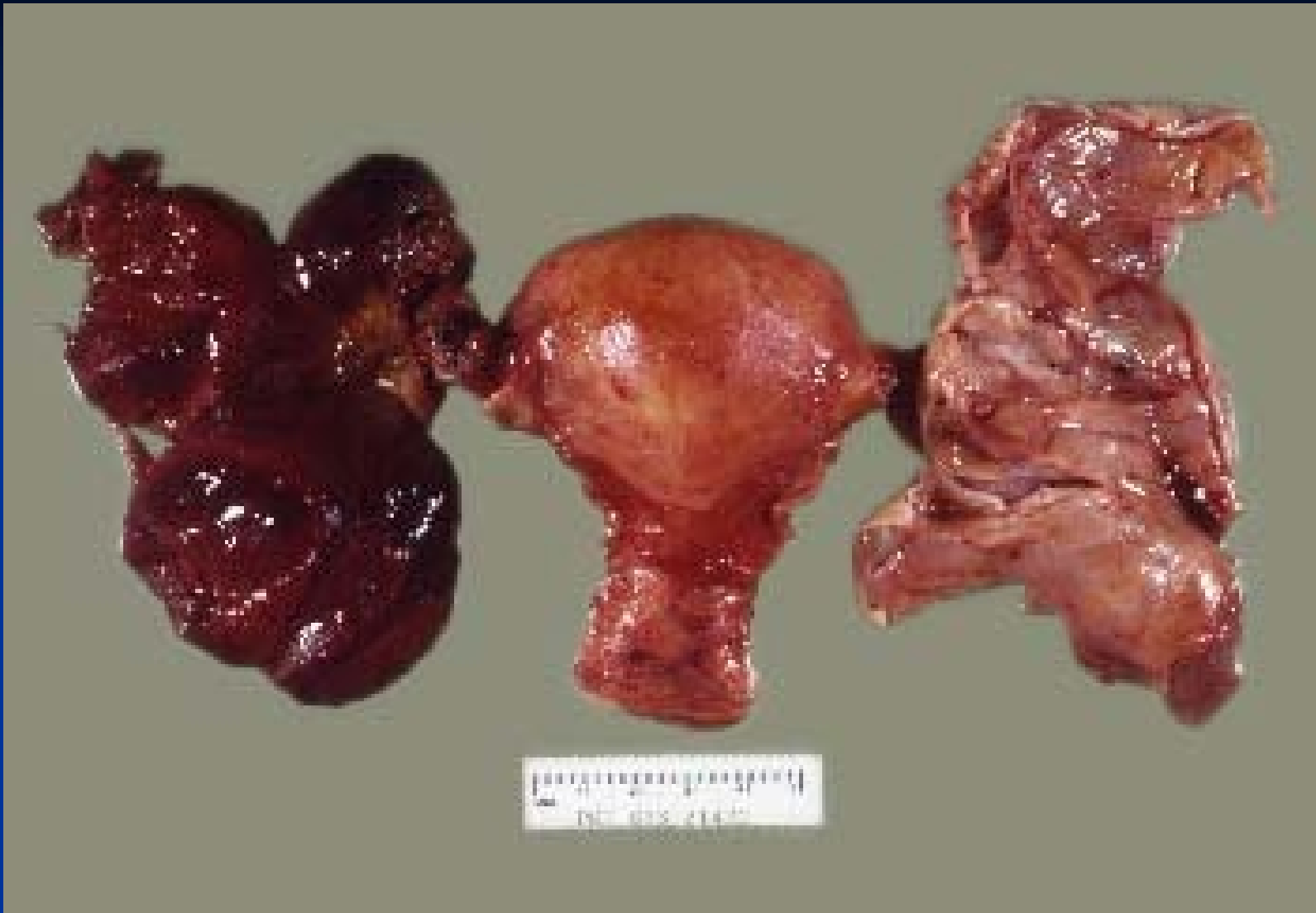- **Inborn defects:** commonly a part of complex chromosomal disturbances (X0 Turner syndrome, gonadal dysgenesis), intrauterine infections, ...
- **Inflammation:** usually chronic, part of nonspecific pelvic inflammatory disease
- **Cysts:** common, variable causes
- **Tumors:** variable origin, commonly cystic form

Chronic inflammation

- „tuboovarian abscess“ – mixture of chronic abscesses, proliferation of granulation and fibrotic tissue, multiple adhesions, stenoses
- Fecal bacteria, str., staph., actinomycetes
- Pelvic pain, fever in acute exacerbation, may → peritonitis, sepsis
- Risk of infertility, GEU

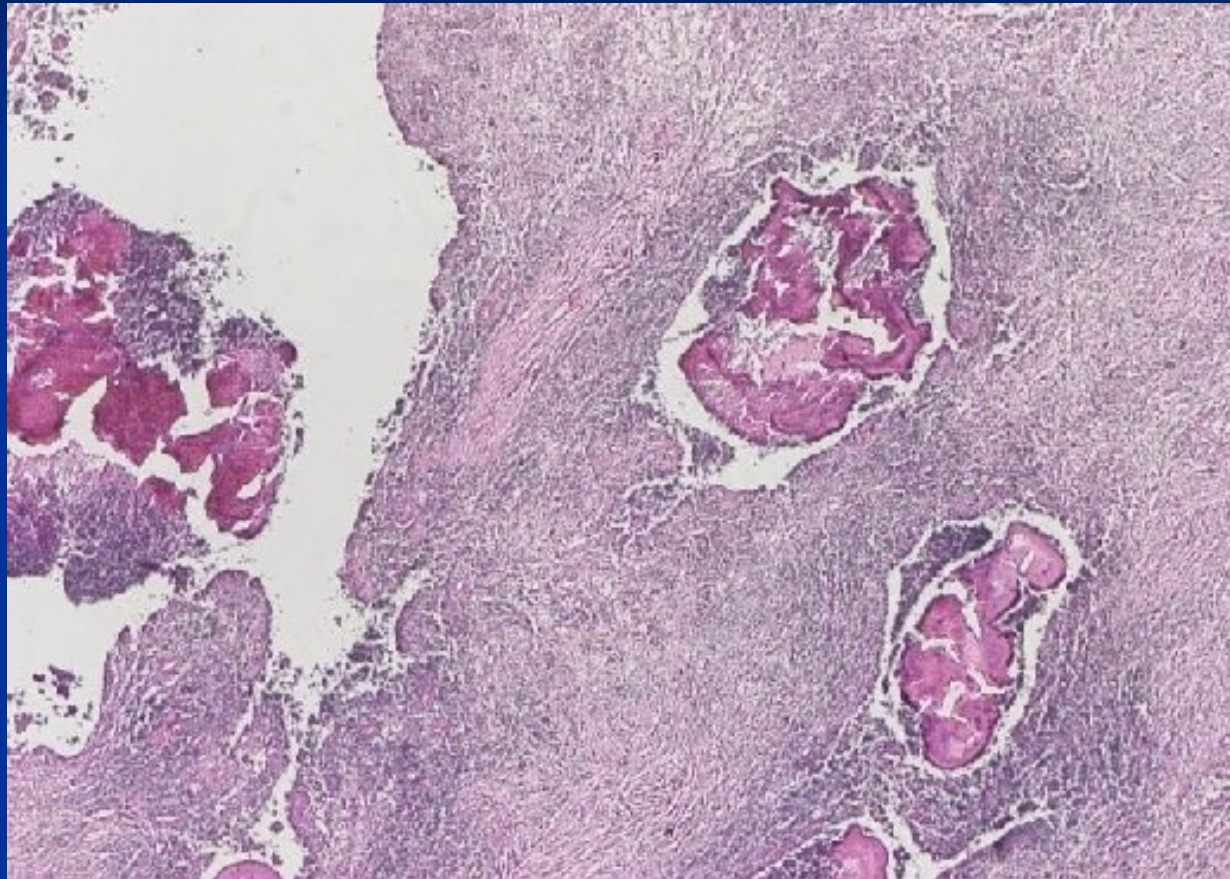


Copyright © 2002, Elsevier Science (USA). All rights reserved.



PID - torsion

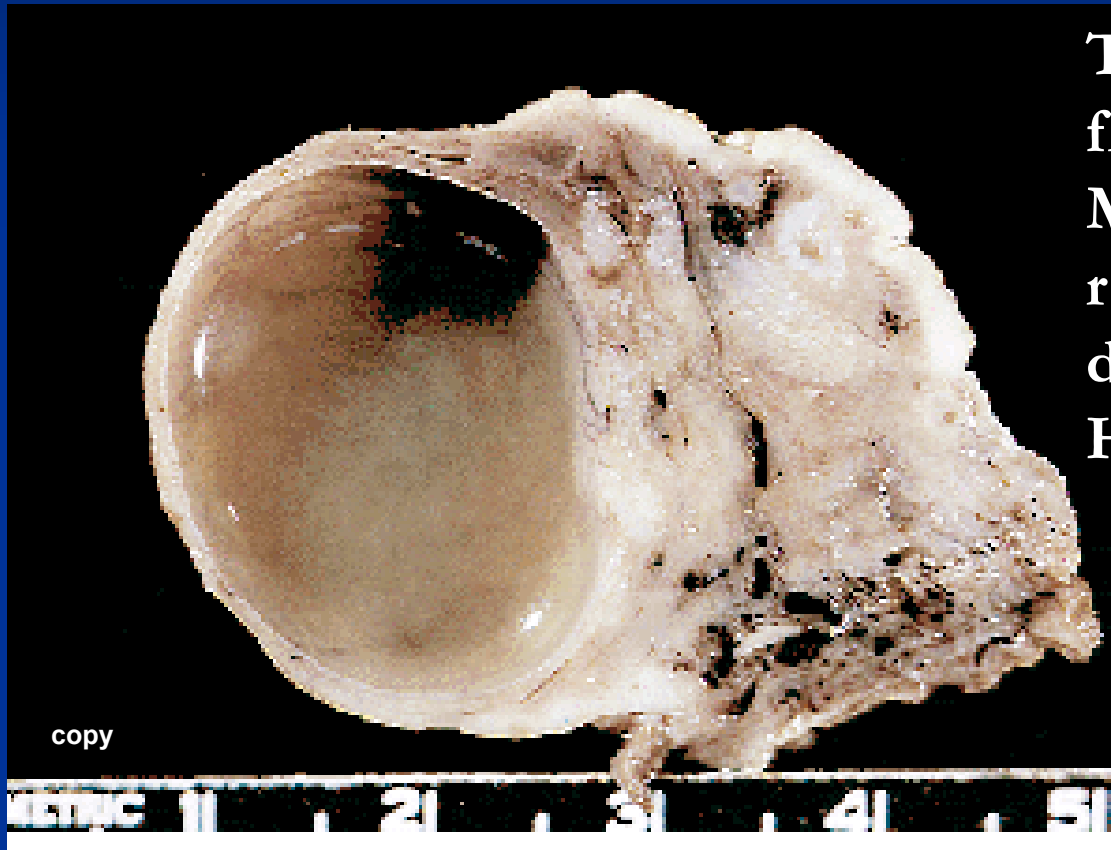
Actinomyces – sulphur granules



Ovarian cysts

- **non-neoplastic** — *inclusion c.* (mesothelial, epithelial)
functional c. (follicular, luteal, polycystic ovary syndrome, ovarian hyperstimulation syndrome)
endometriosis
- **neoplastic** (*epithelial tumors, germ cell tu, sex-cord stromal tu, metastatic tu, etc.*)

Follicle cyst

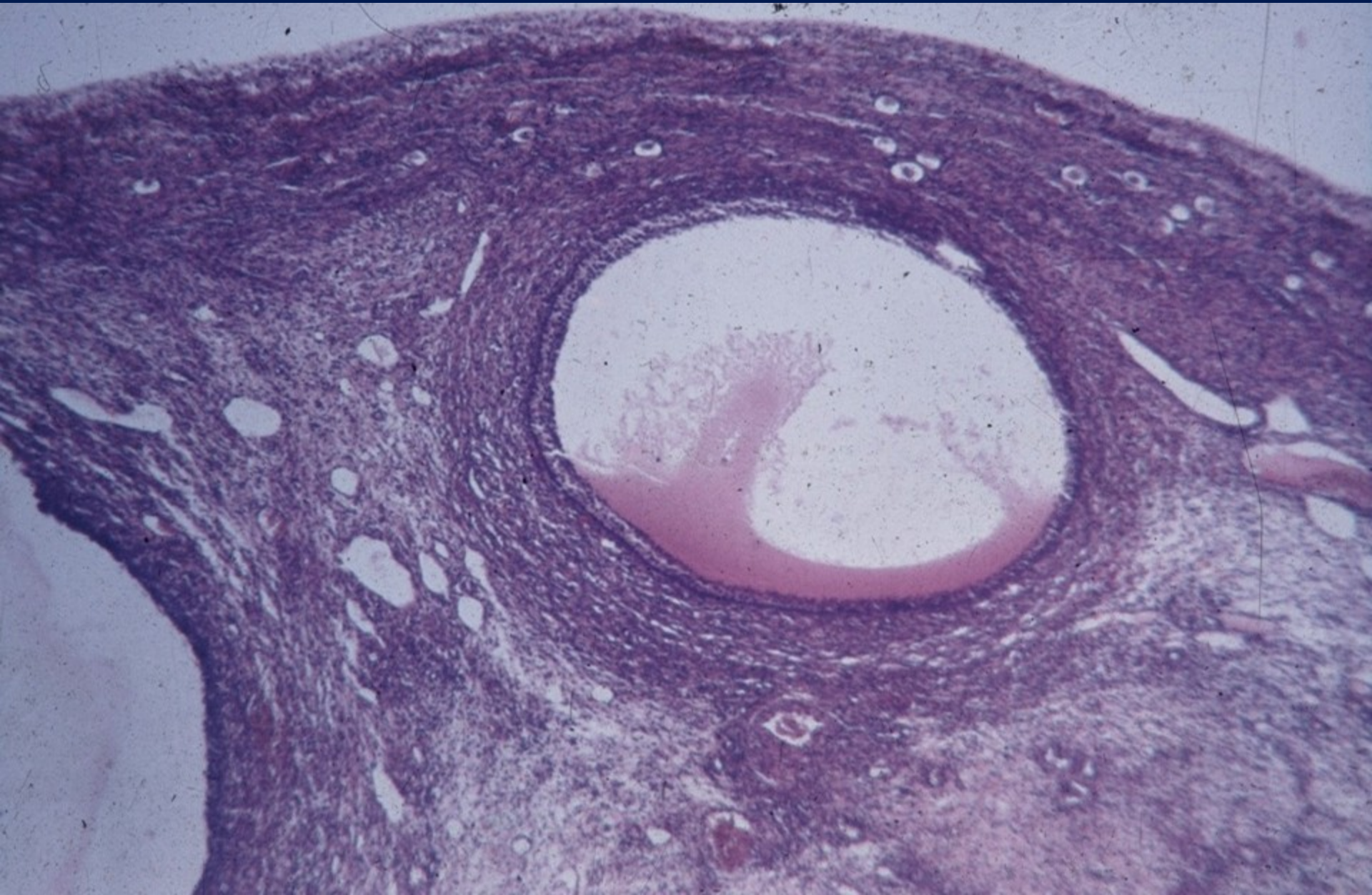


Thin walled, contains clear fluid, diameter ≥ 2 cm

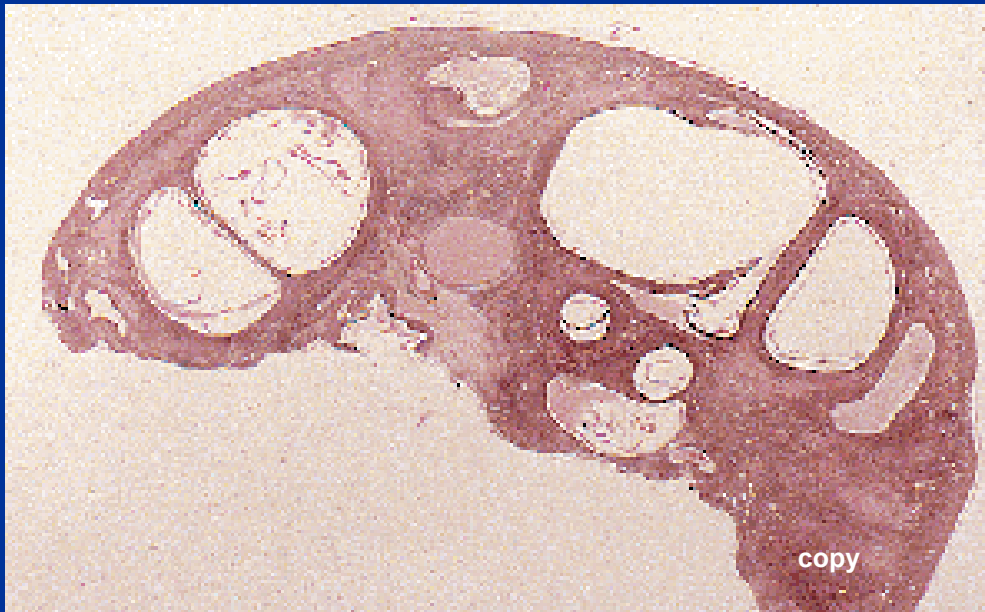
Micro: enlarged non-ruptured follicle, longer duration

Hyperestrinism possible

Ovarian follicle < 20 mm



Polycystic ovarian disease



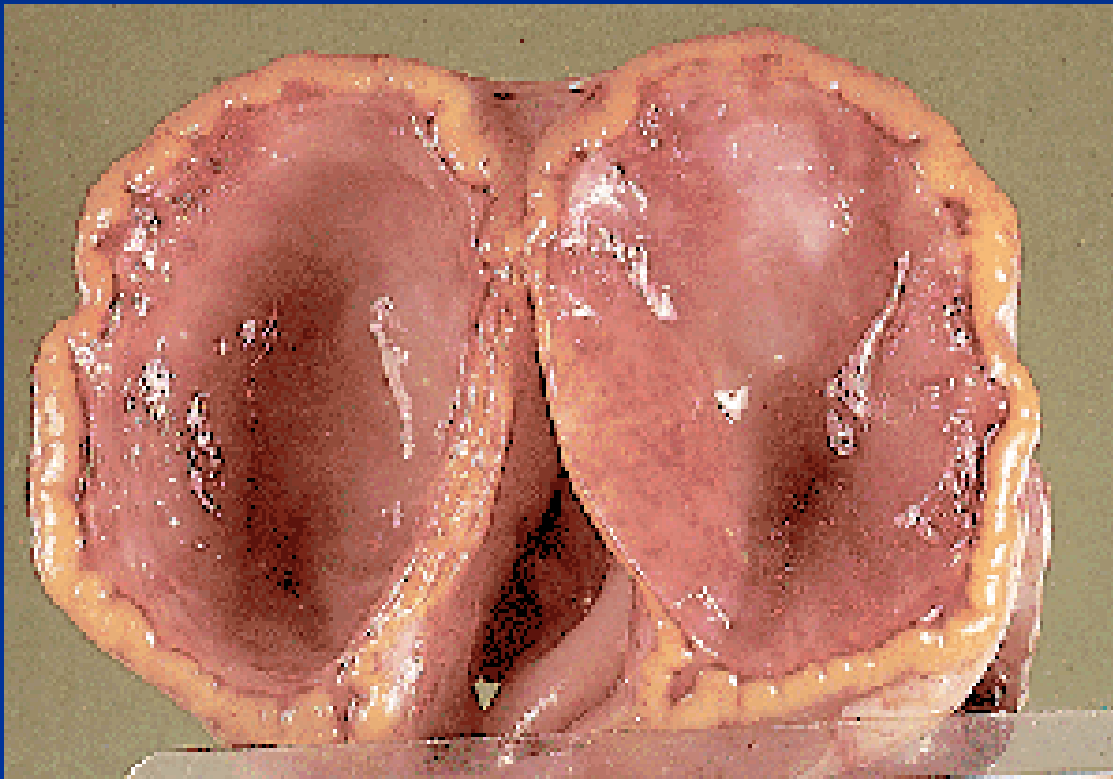
Complex etiology, stopped normal follicular maturation, enlarged ovaries with smooth surface, multiple thin-walled cysts

Profound hormonal + metabolic

(insulin)disturbances

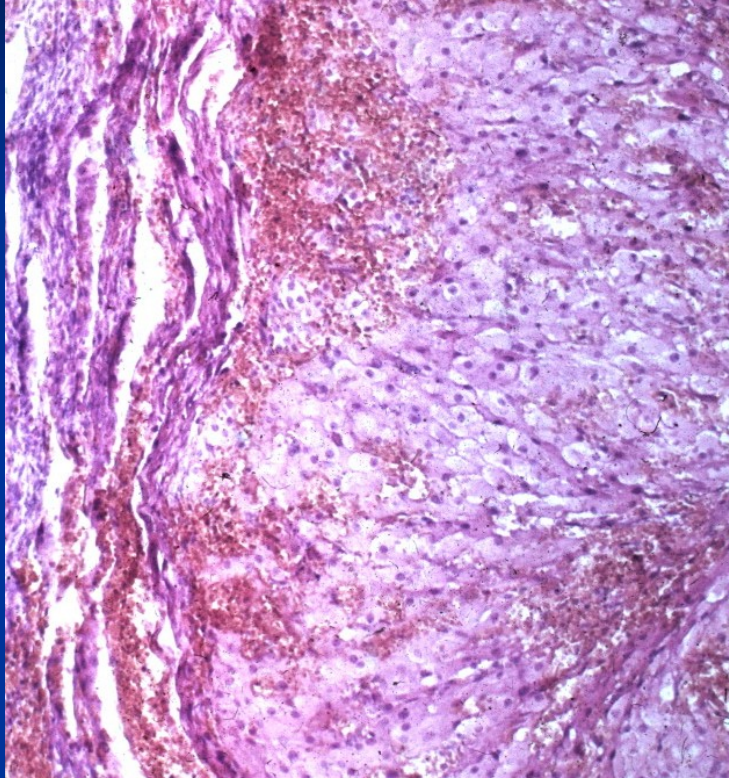
Infertility (amenorrhea), obesity, hirsutism

Corpus luteum cyst



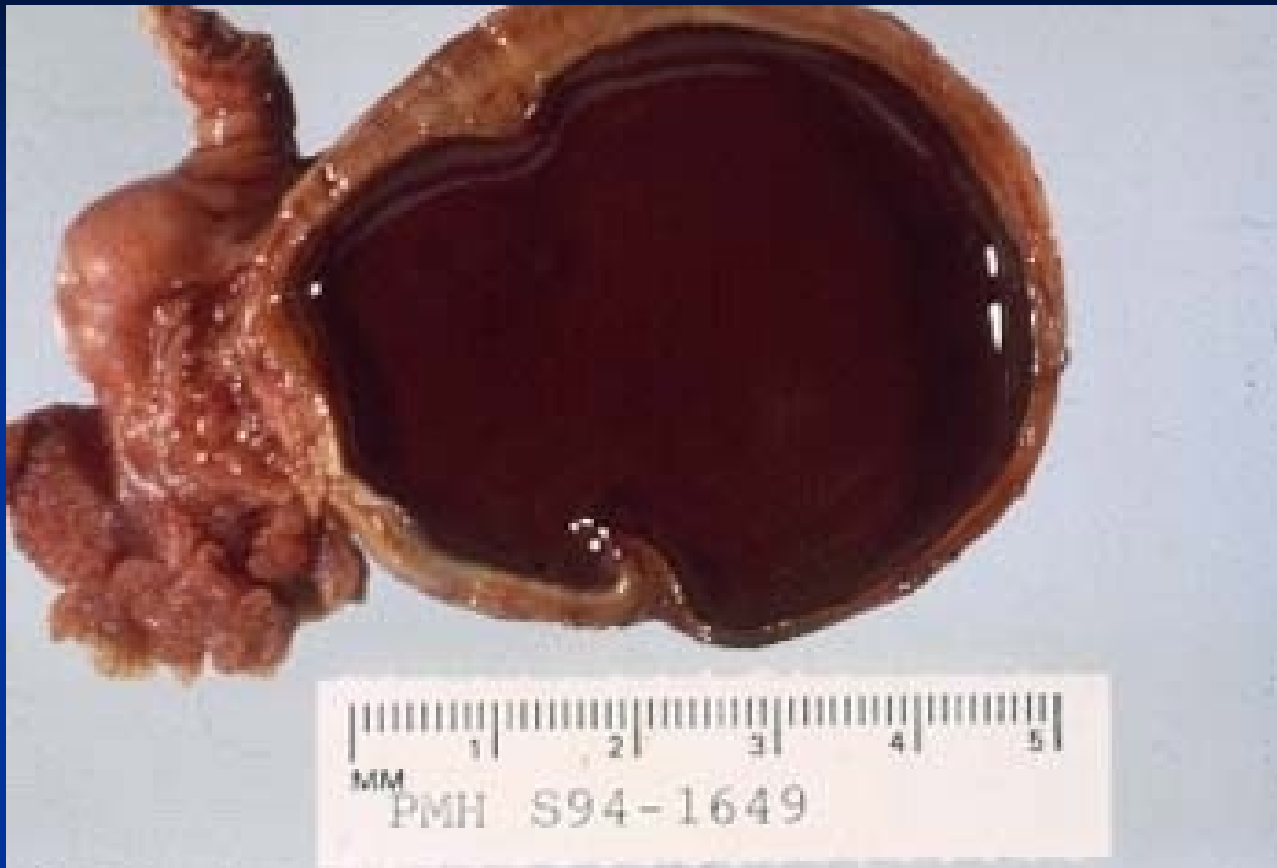Yellow convoluted wall,
smooth lining, may
contain bloody fluid
Not regressed corpus
luteum, typical cells
with foamy cytoplasm

Corpus luteum cyst

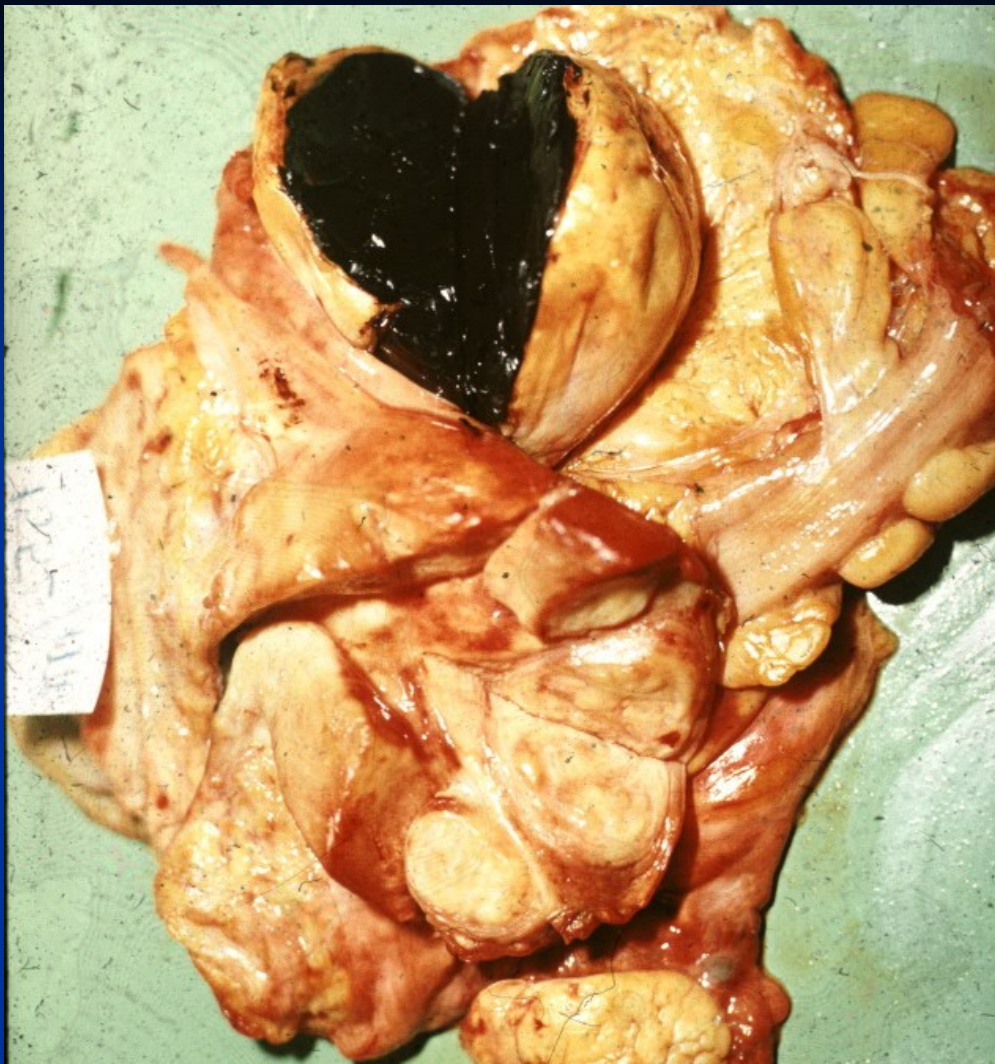

Endometriosis

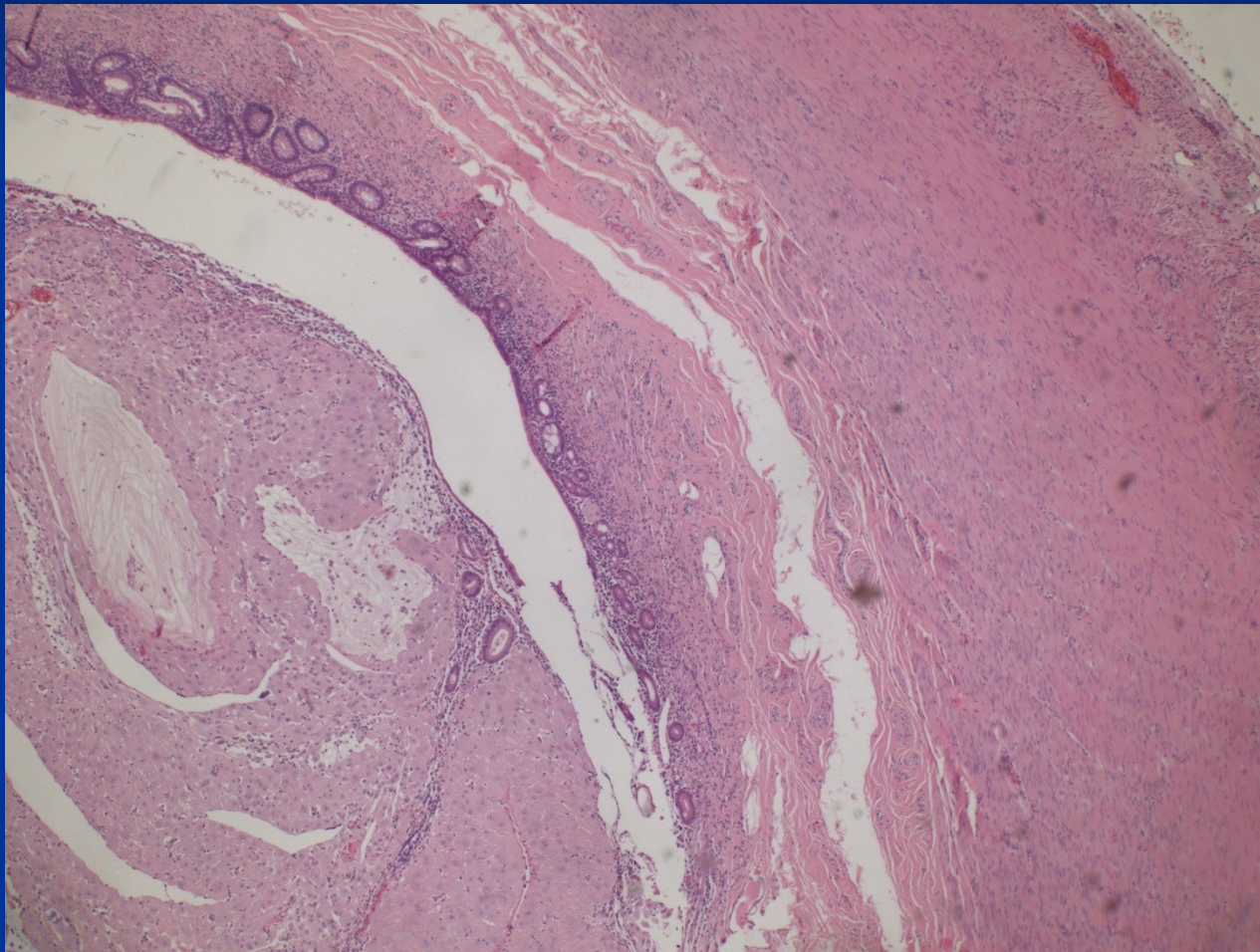
- foci of functional endometrium (glands + stroma) in an ectopic localisation
 - ovaria, cavum Douglasi, fallopian tubes, peritoneum, bladder, umbilical skin, ... lung, bones ...)
 - cyclical changes during MC
 - haemorrhagic (chocolate) cysts, hemosiderin pigmentation
 - pain, pelvic inflammatory disease + adhesions, infertility
 - possible source of endometrioid adenocarcinoma
 - 10 % of women of reproductive age
- adenomyosis:
 - endometrial diverticula (outpouching of basalis into myometrium, mostly no functional hormonal changes)



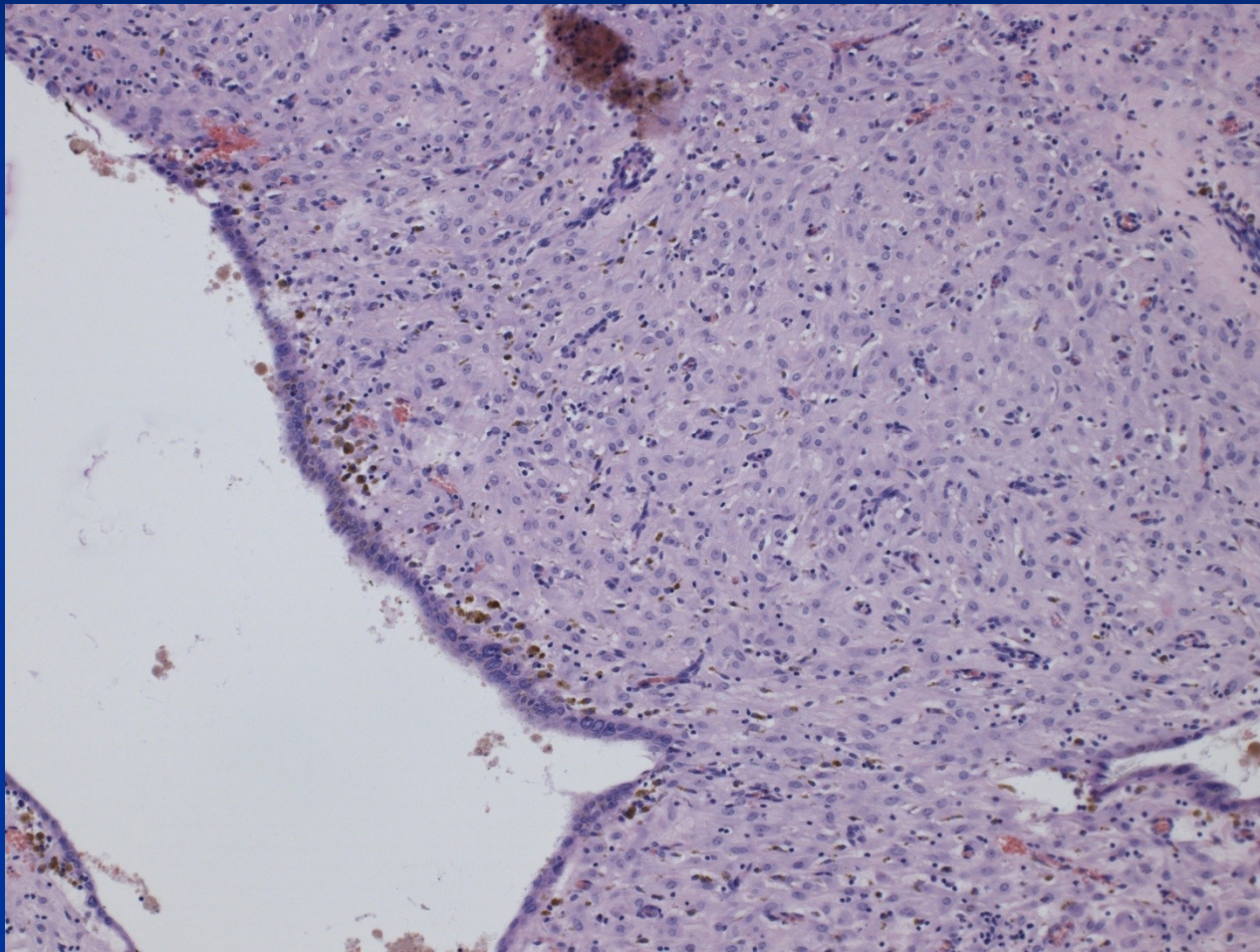
Endometriosis – „chocolate cyst“



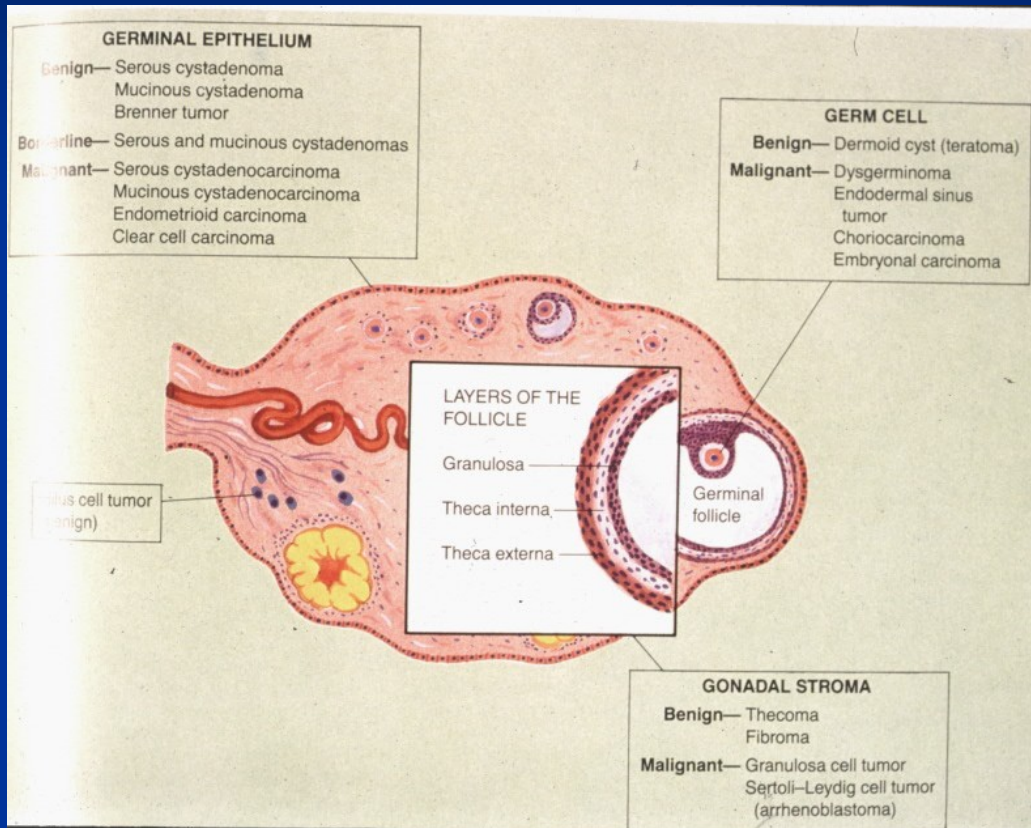
Endometriosis in appendix



Endometriosis – decidual change



Ovarian tumors



Ovarian tumors

- Epithelial tumors
 - most common, 70 %
 - adults
- Germ cell tumors
 - 15-20 %
 - children, adults
- Sex cord-stromal tumors
 - 5-10 %, any age
- Metastasis
 - 5 %, variable

Classification/nomenclature

1. Epithelial tumors

Epithelial type

- Serous
- Mucinous, endocervical-like and intestinal type
- Seromucinous
- Endometrioid
- Clear cell tumors
- Brenner tumors
- Others

Classification/nomenclature

■ Epithelial tumors

Biologic potential

- **Benign** (commonly in form of cystadenoma)
- **Borderline** (Low malignant potential) – moderate atypias, mitotic activity, architectonic changes (multilayering, irregular papillary budding), non-invasive peritoneal implants possible
- **Malignant**

Epithelial tumors

Form of growth

- Cystic
- Papillary incl. inverted
- Solid
- Increased amount of stroma, (adenofibroma)

Classification/nomenclature

■ Epithelial tumors

Names: combination, i. e.:

Mucinous cystadenoma

Borderline serous papillary tumor

Clear cell carcinoma of ovary

Classification

- 2. Sex cord-stromal tumors

- *Pure stromal tumors*

Tumors of the thecoma-fibroma group

Steroid (lipid) cell tumors

- *Pure sex-cord tumors*

Granulosa cell tumors

- *Mixed sex cord-stromal tumors,*

Classification

■ 3. Germ cell tumors

■ Teratoma

■ Immature t.

■ Mature (adult) t.: solid; cystic - dermoid cyst; monodermal - struma ovarii, carcinoid

■ Dysgerminoma

■ Yolk sac tumor

■ Embryonal carcinoma

■ Choriocarcinoma (non-gestational)

■ Mixed germ cell tumor

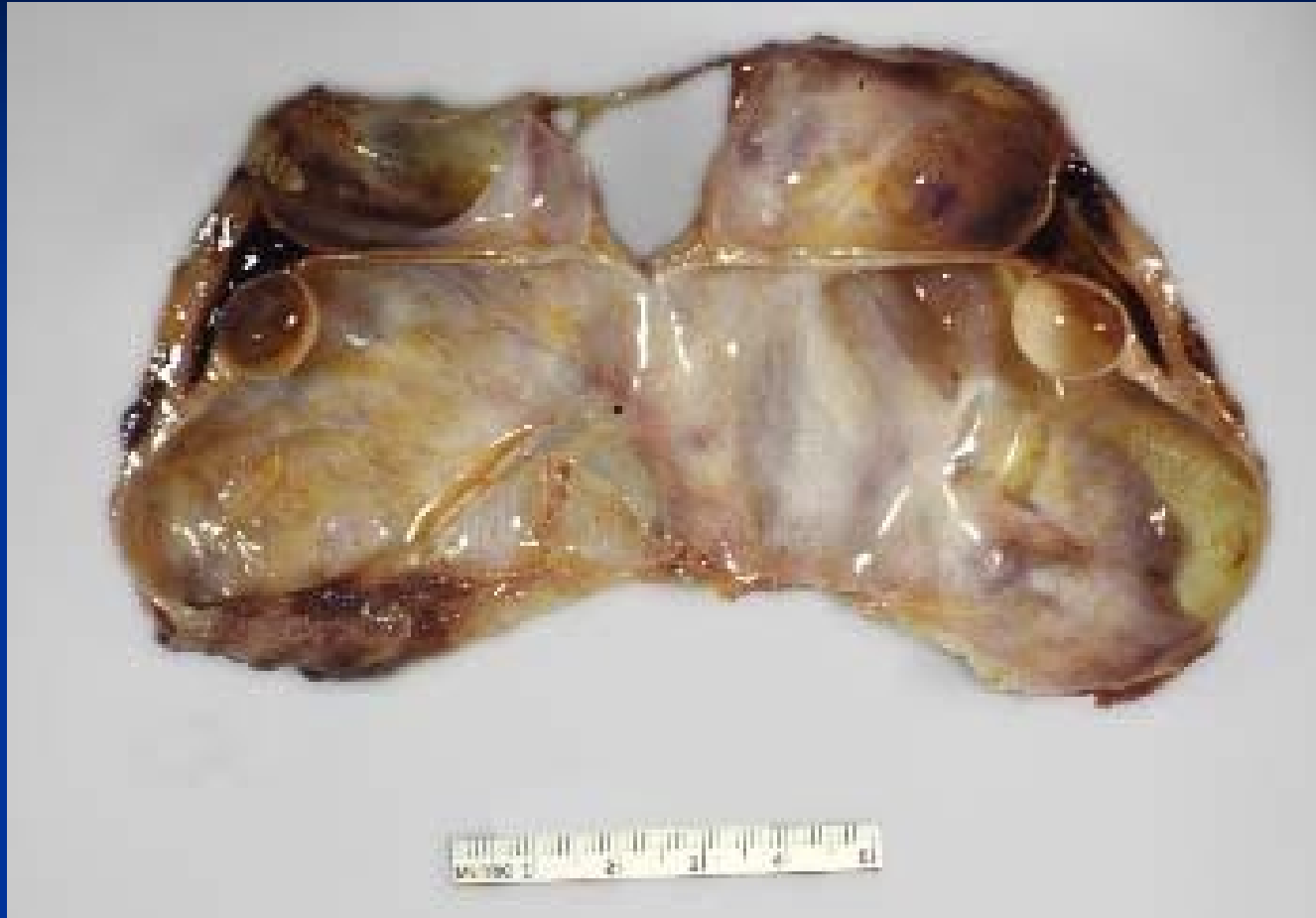■ 4. Other types (incl. mesenchymal, mesothelial, etc.)

■ 5. Metastatic tumors

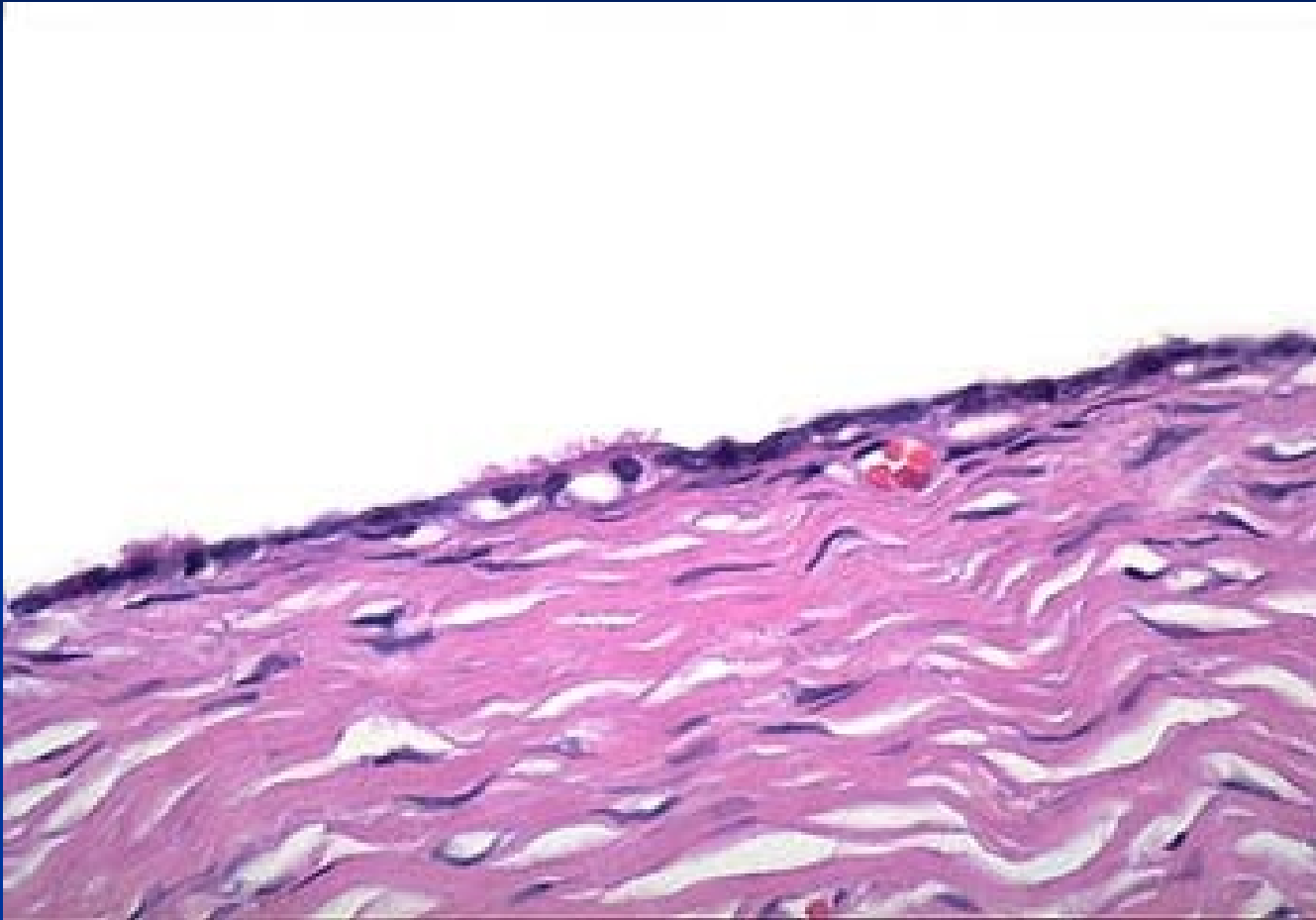
Serous cystadenoma

- Thin-walled multilocular cyst, variable size
- Clear fluid
- Lining smooth or papillary, micro ~ tubal epithelium, may be ciliated
- Possible non-cystic superficial papillary form on ovary
- Borderline tumor may be precursor of low-grade serous carcinoma

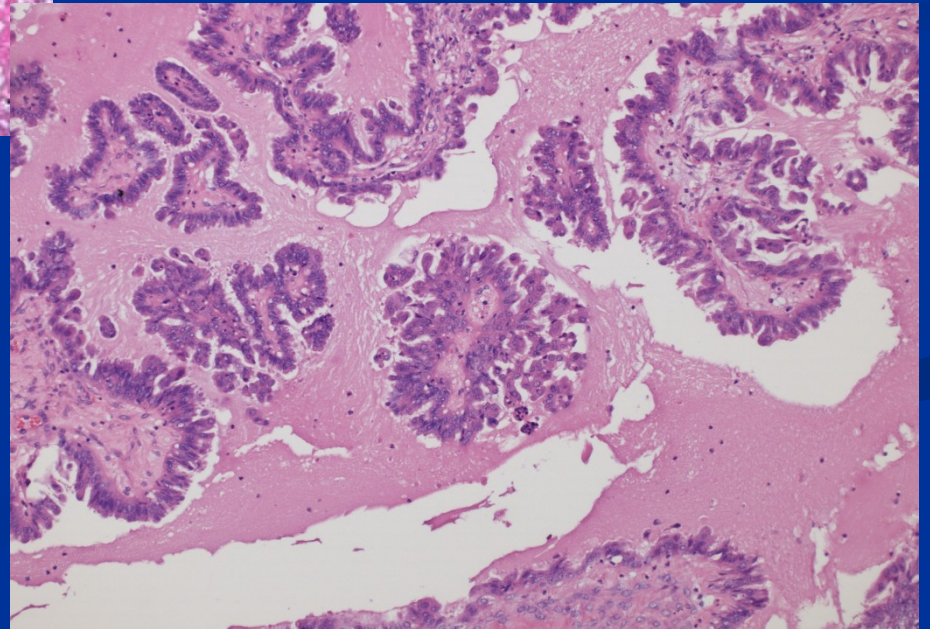
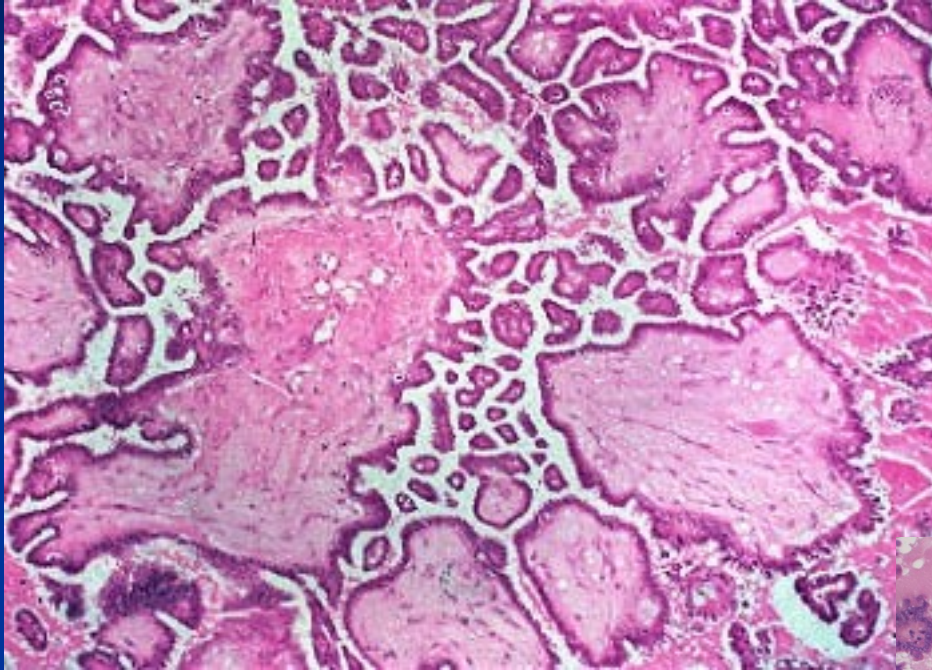
Serous cystadenoma



Serous cystadenoma

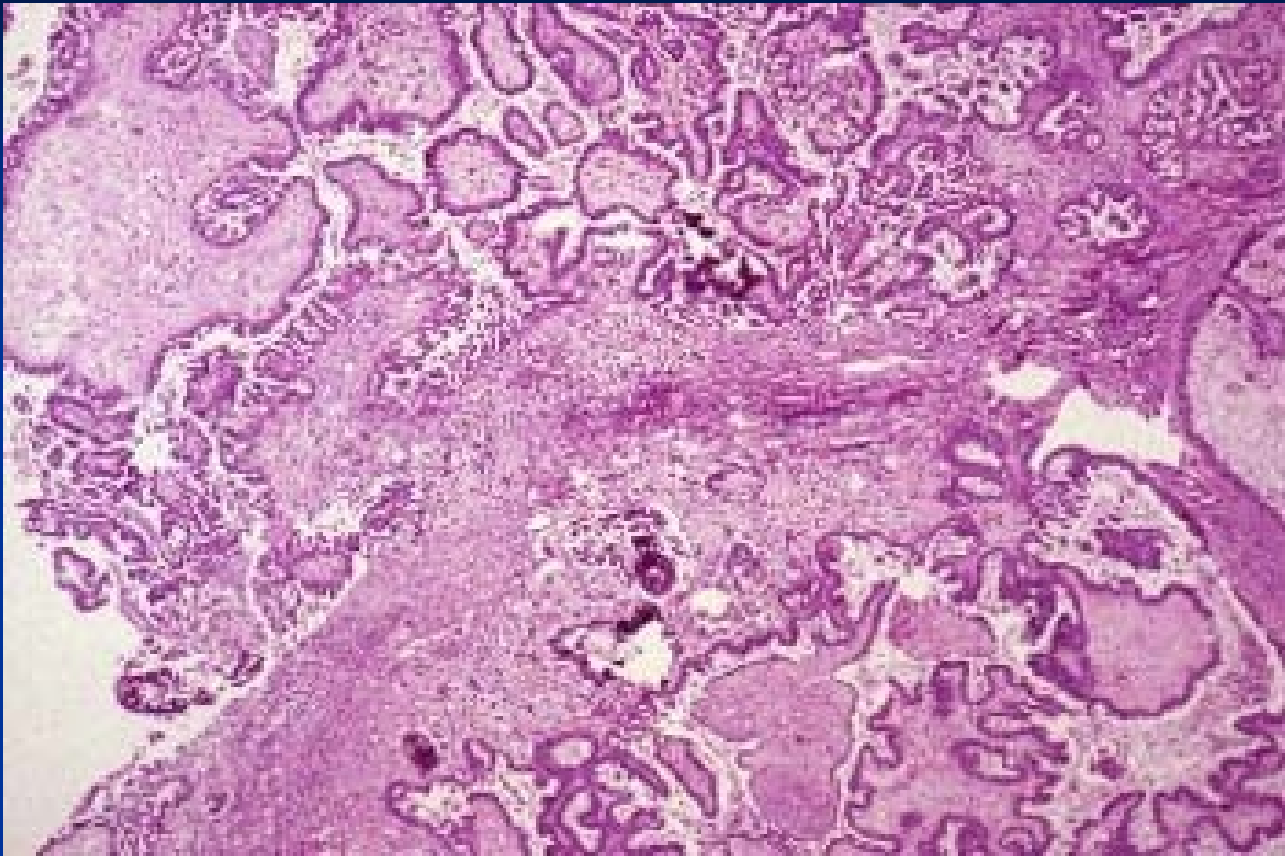


Serous borderline tumor

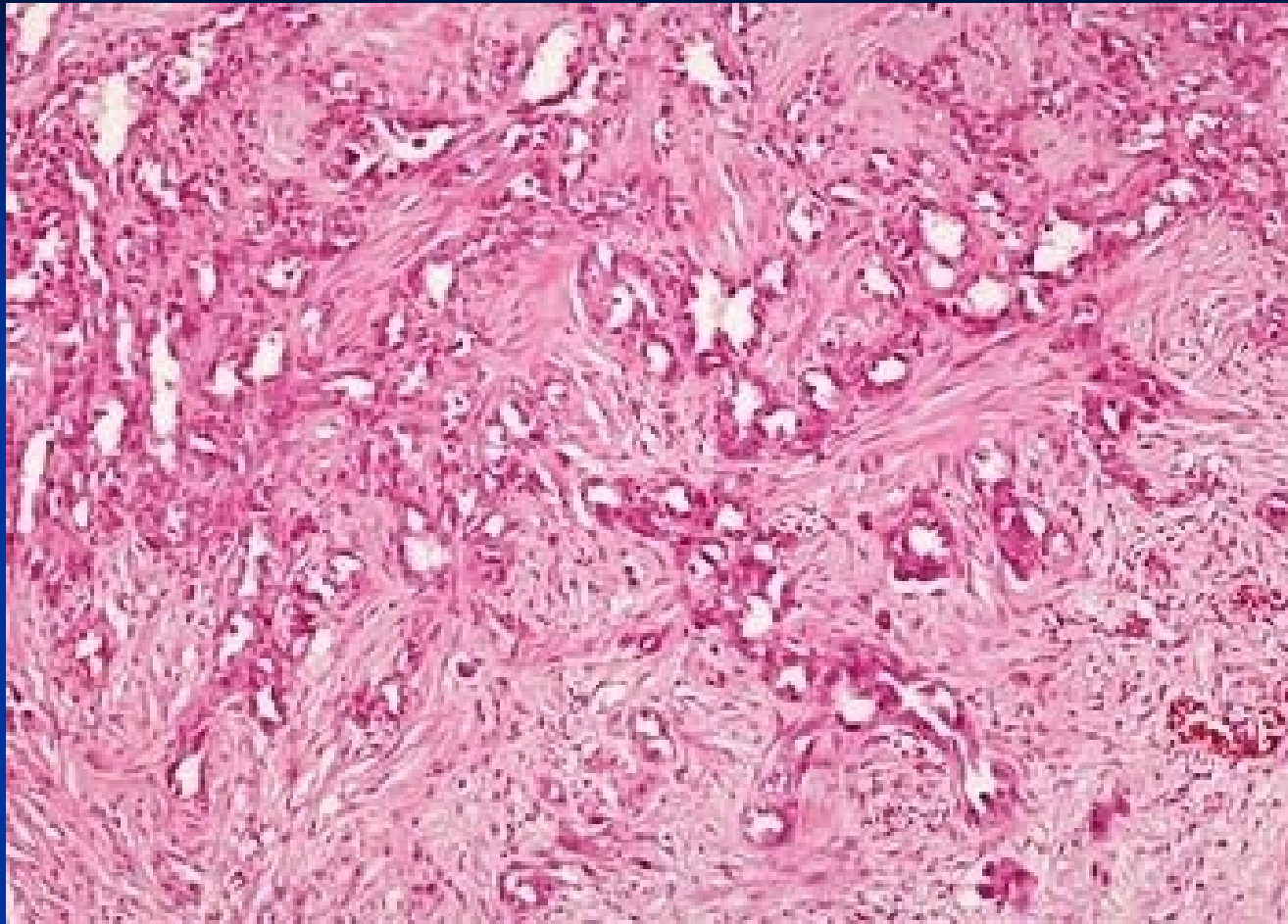


Serous carcinoma

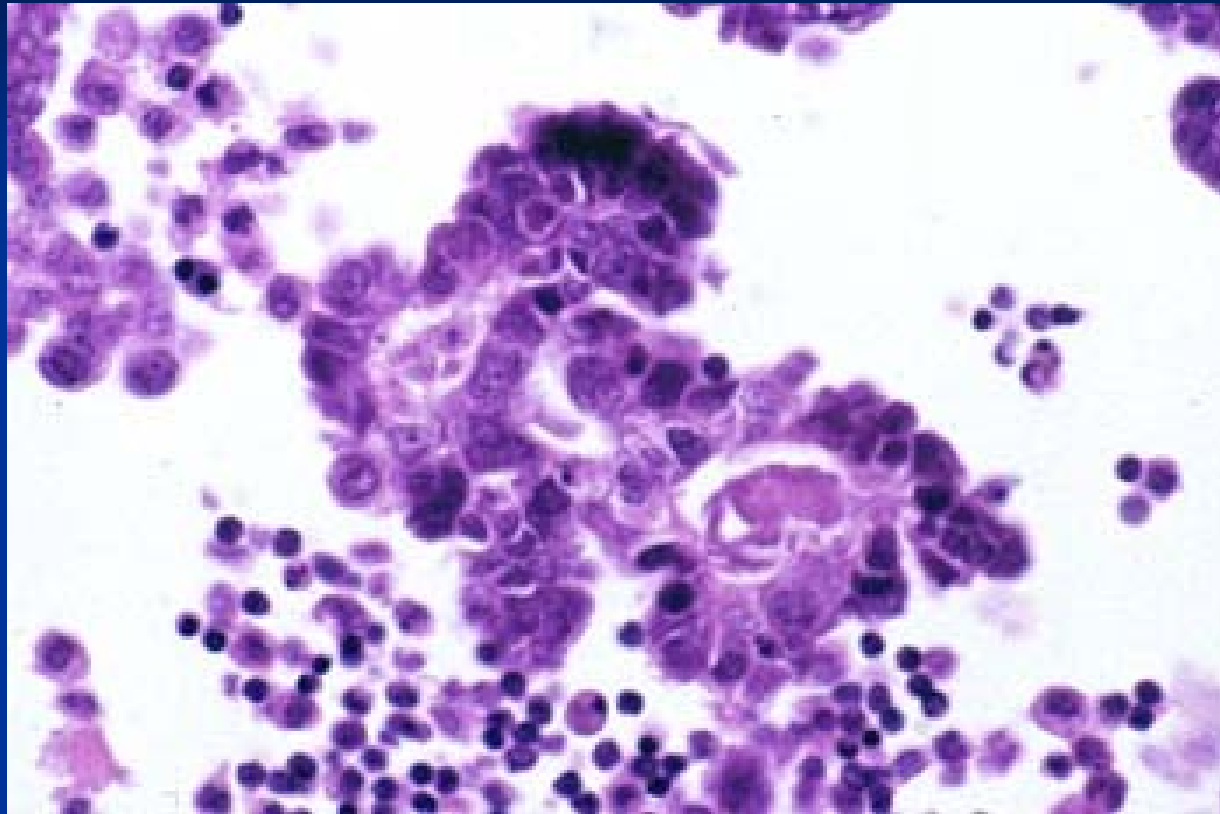
- Stromal invasion
- 2 different types – genetics, histology, prognosis
 - low-grade serous carcinoma (ovarian origin)
 - high grade serous carcinoma (from serous tubal intraepithelial carcinoma)
- Confluent wide papillae
- Possible microcalcifications (psammomata)
- Commonly partially solid in HG ca
- Growth into surrounding tissues
- Metastatic spread in abdominal cavity
- Oral contraception has protective effect
- Risk factors: smoking, obesity, genetics (BRCA)



serous carcinoma



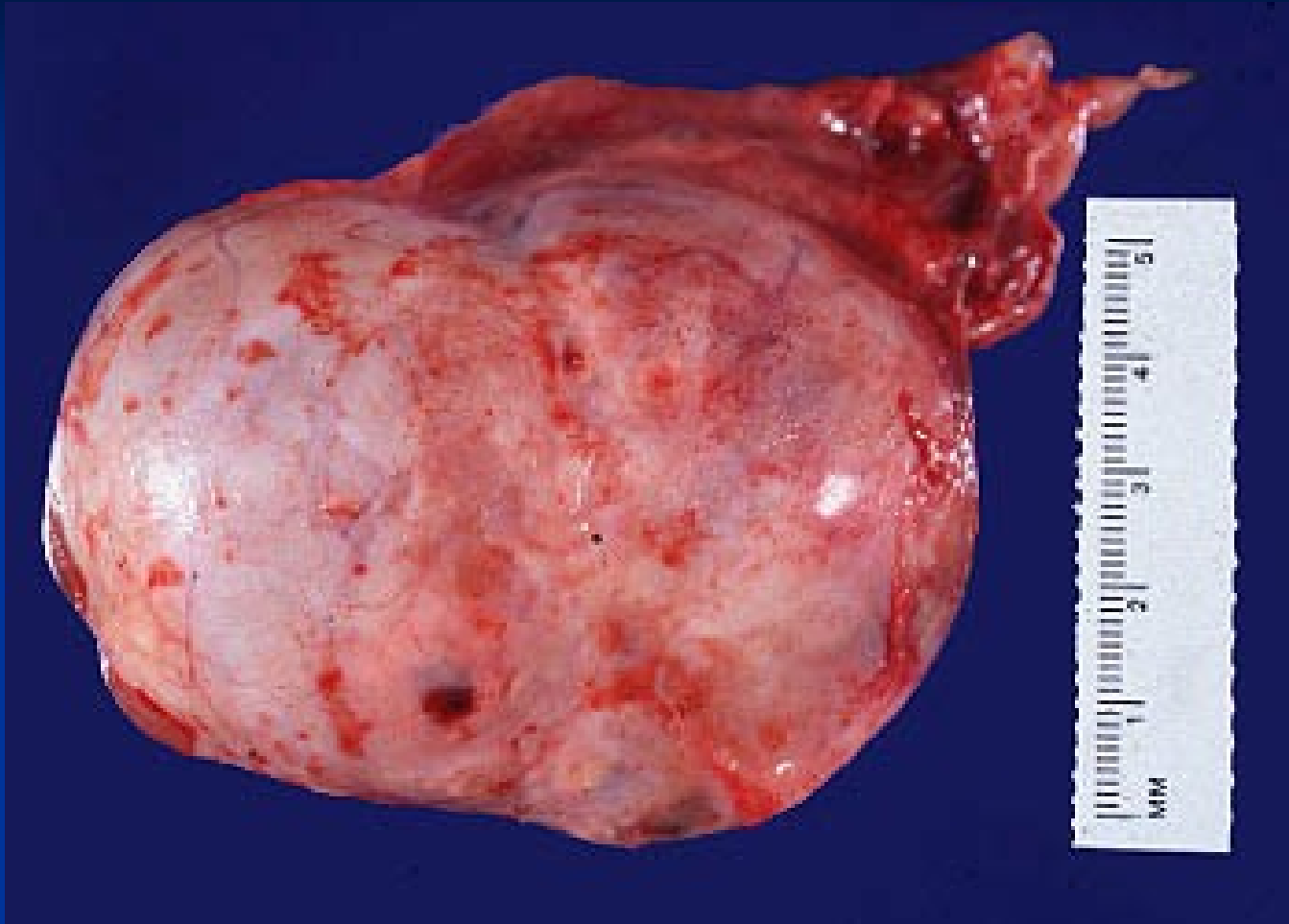
Serous carcinoma – stromal invasion



Malignant cell clusters in ascites

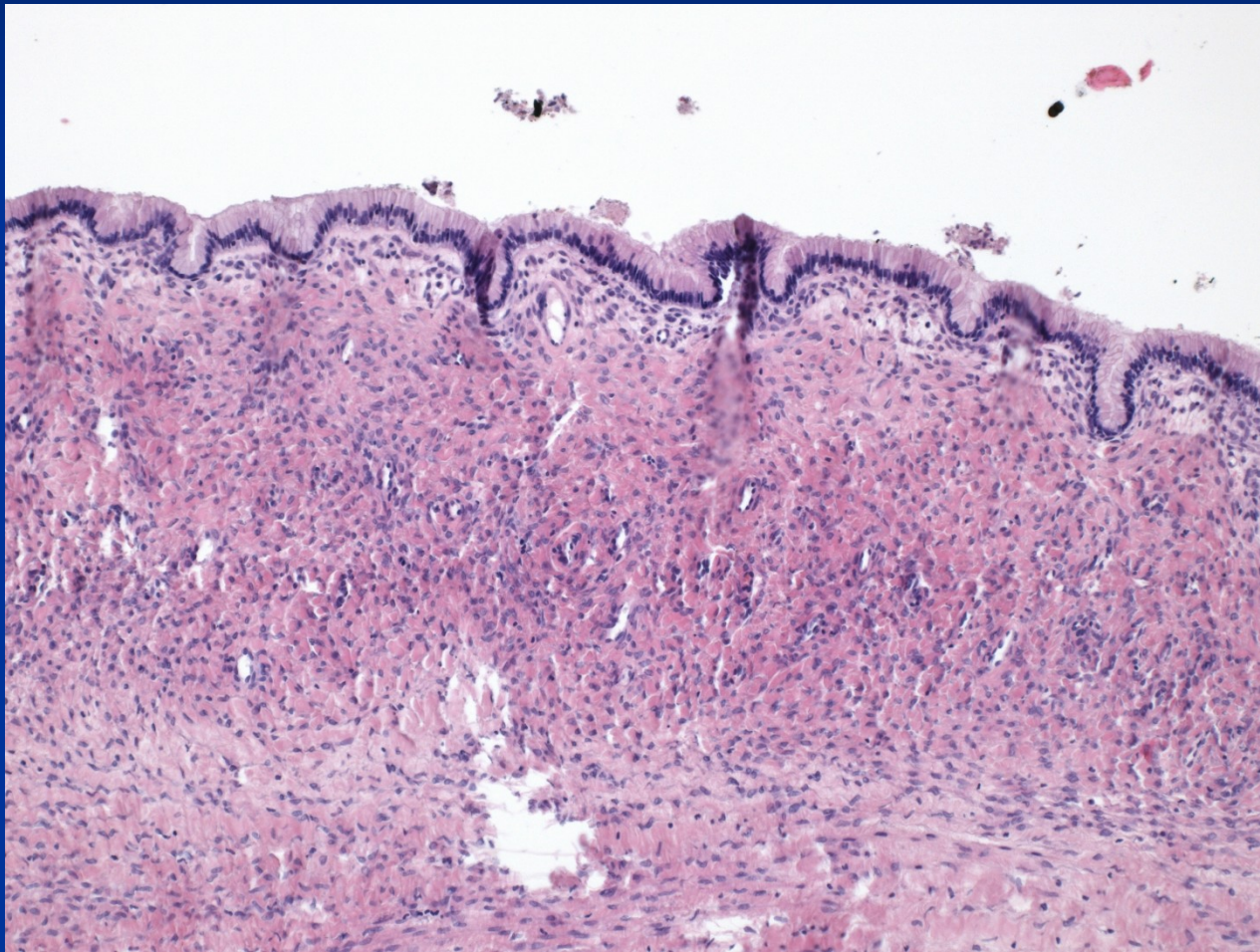
Mucinous cystadenoma

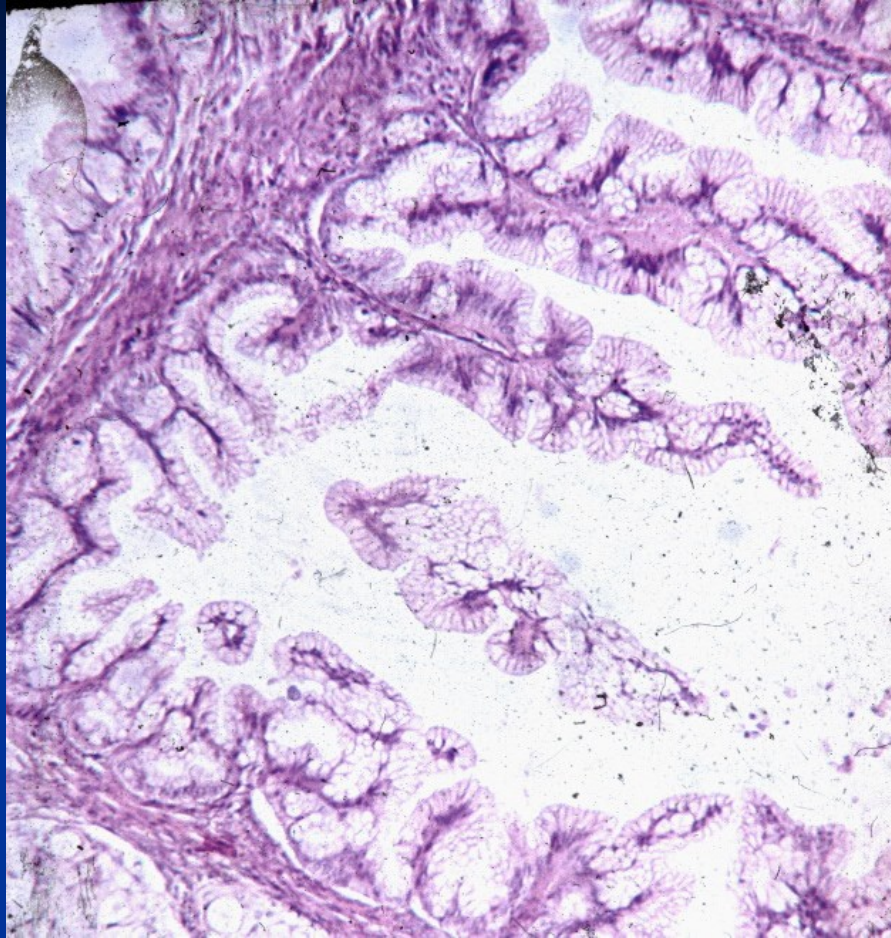
- large cysts with a smooth outer surface
- usually multilocular
- contain clear mucous material
- Micro: tall mucin-secreting columnar cells, mostly endocervical type, may be intestinal type
- Complications: huge size, abdominal distention, possible torsion, cyst rupture.



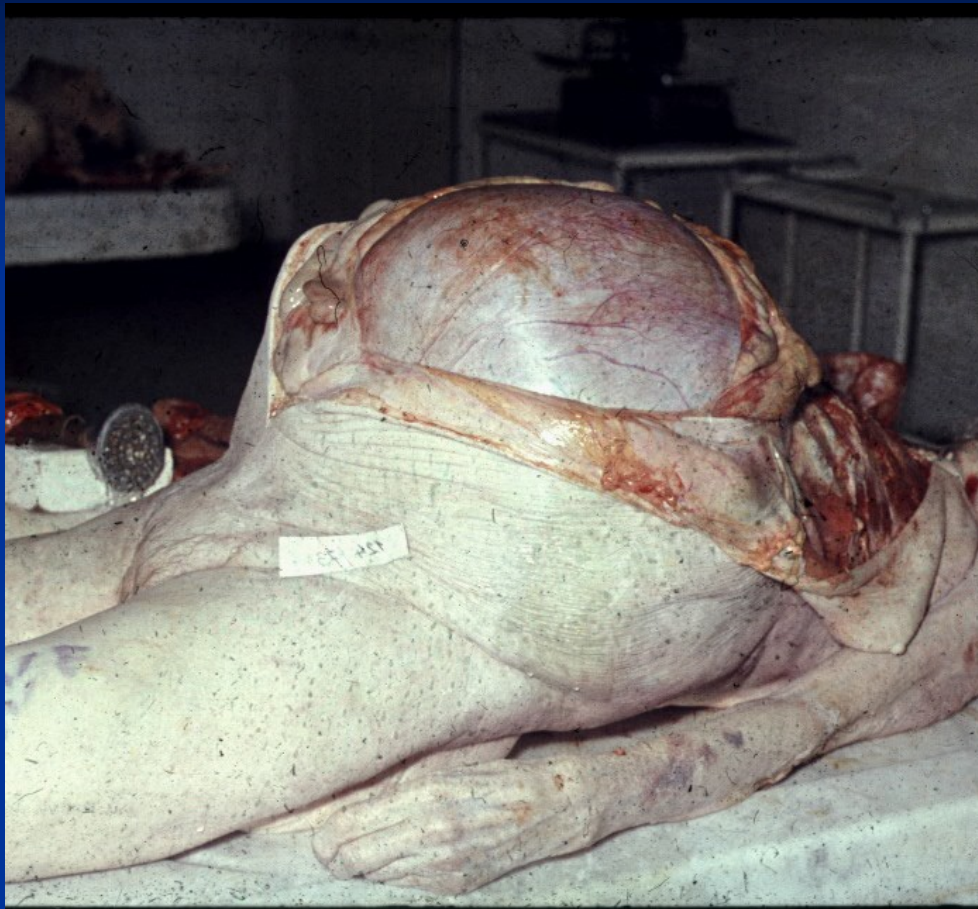Mucinous cystadenoma

Mucinous cystadenoma





Mucinous borderline tumor



Mucinous cystic borderline tumor

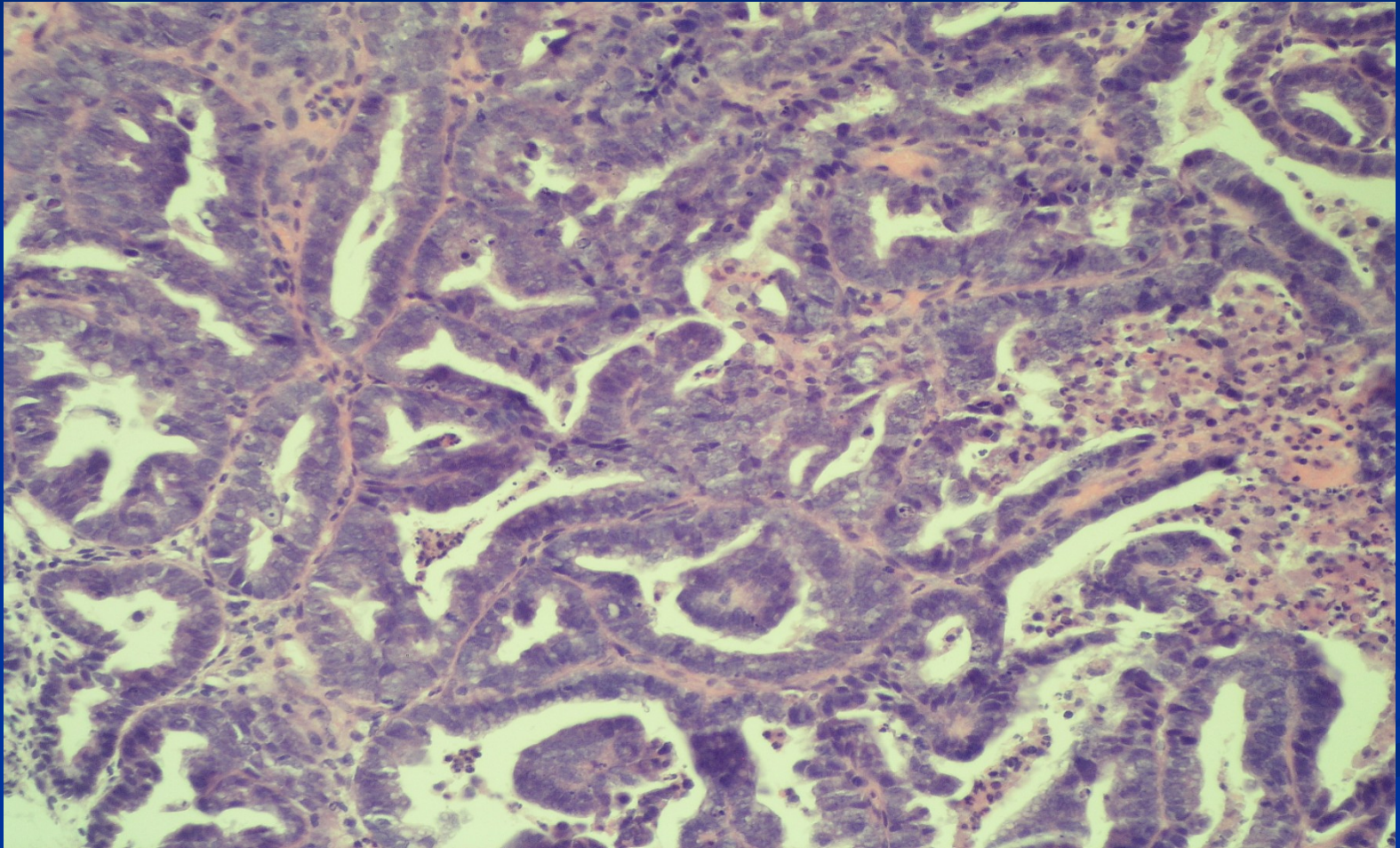
Mucinous carcinoma

- Commonly partially solid
- Metastatic spread into abdominal cavity possible
 - diff. dg. x „pseudomyxoma peritonei“, organisation of mucinous material → adhesions, fibrosis, stenosis, tumor origin usually in appendix
- Diff. dg. x other mucinous carcinomas (GIT)

Endometrioid tumors

- commonly malignant
- histologically mostly identical with endometrial adenocarcinomas (!diff. dg. primary x metastatic, in 1/4 may be concurrent primary ca in endometrium and ovary)
- mostly arises from foci of pre-existing ovarian endometriosis

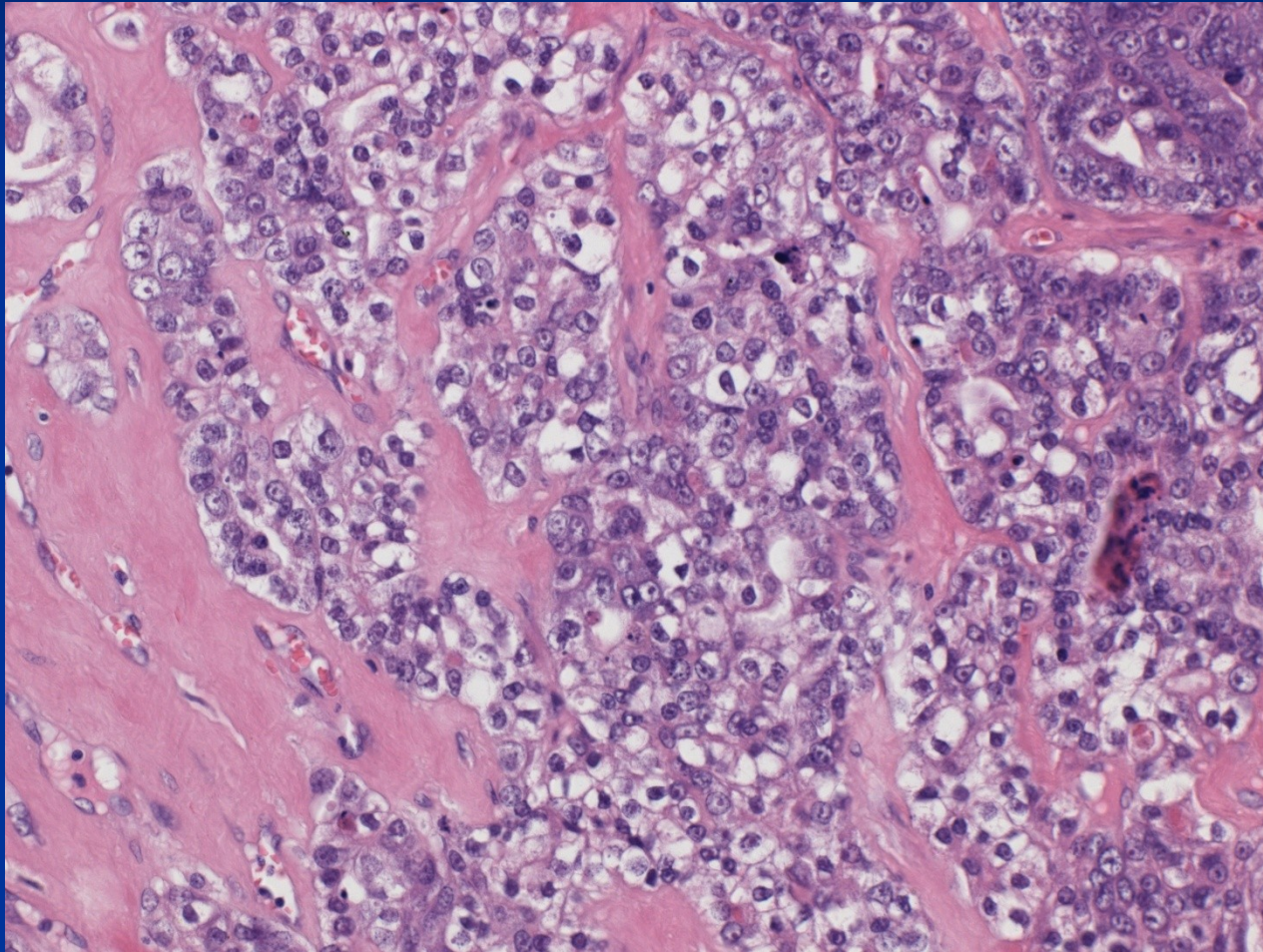
Endometrioid carcinoma



Clear cell tumors

- Almost always malignant
- Complex papillary and tubular pattern intermingled with sheets of highly atypical clear cells
- diff. dg. x other clear cell tumors (renal, vaginal)

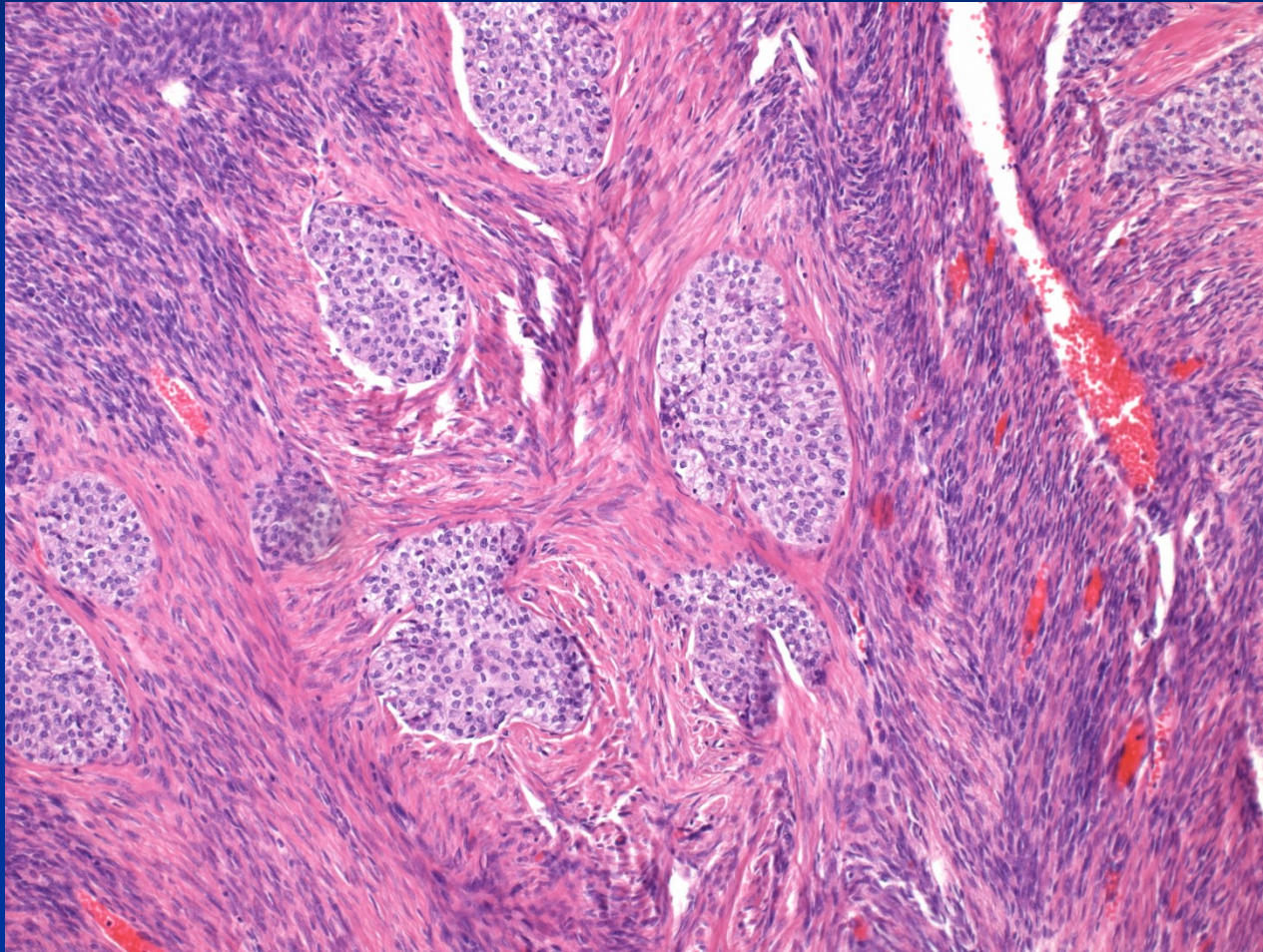
Clear cell carcinoma



Brenner tumors

- usually small, solid and benign
- Micro: rounded islands of transitional-type epithelium embedded in a dense fibrous stroma.
- Malignant forms rare.

Brenner tumor



Germ cell tumors

■ dysgerminoma

- ovarian counterpart of seminoma, rare, girls + young f.

■ embryonal carcinoma

- similar to testis, rare, younger age

■ yolk sac tumor

- similar to testis, younger age, 20 % of germ cell tu

■ choriocarcinoma

- similar to testis, nongestational, very uncommon

■ teratoma most common,

- usually mature – benign: dermoid cyst,
- immature – malignant
- malignisation in a mature teratoma

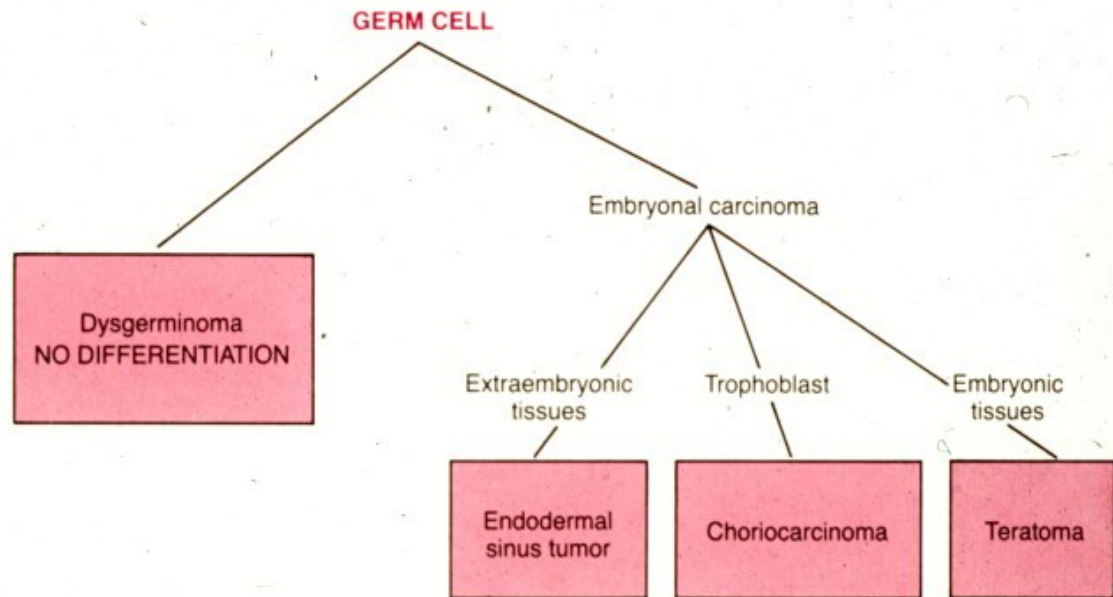
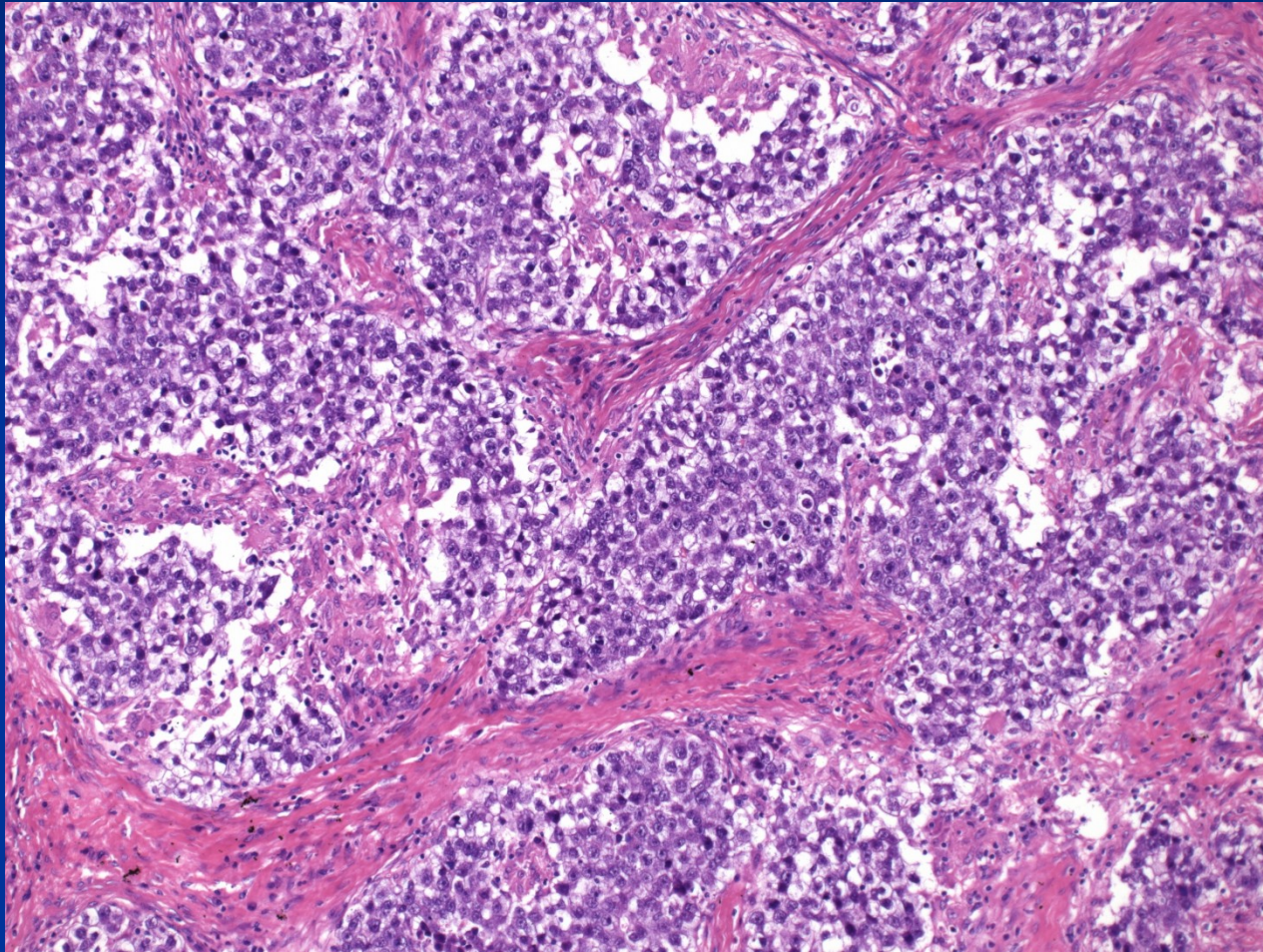
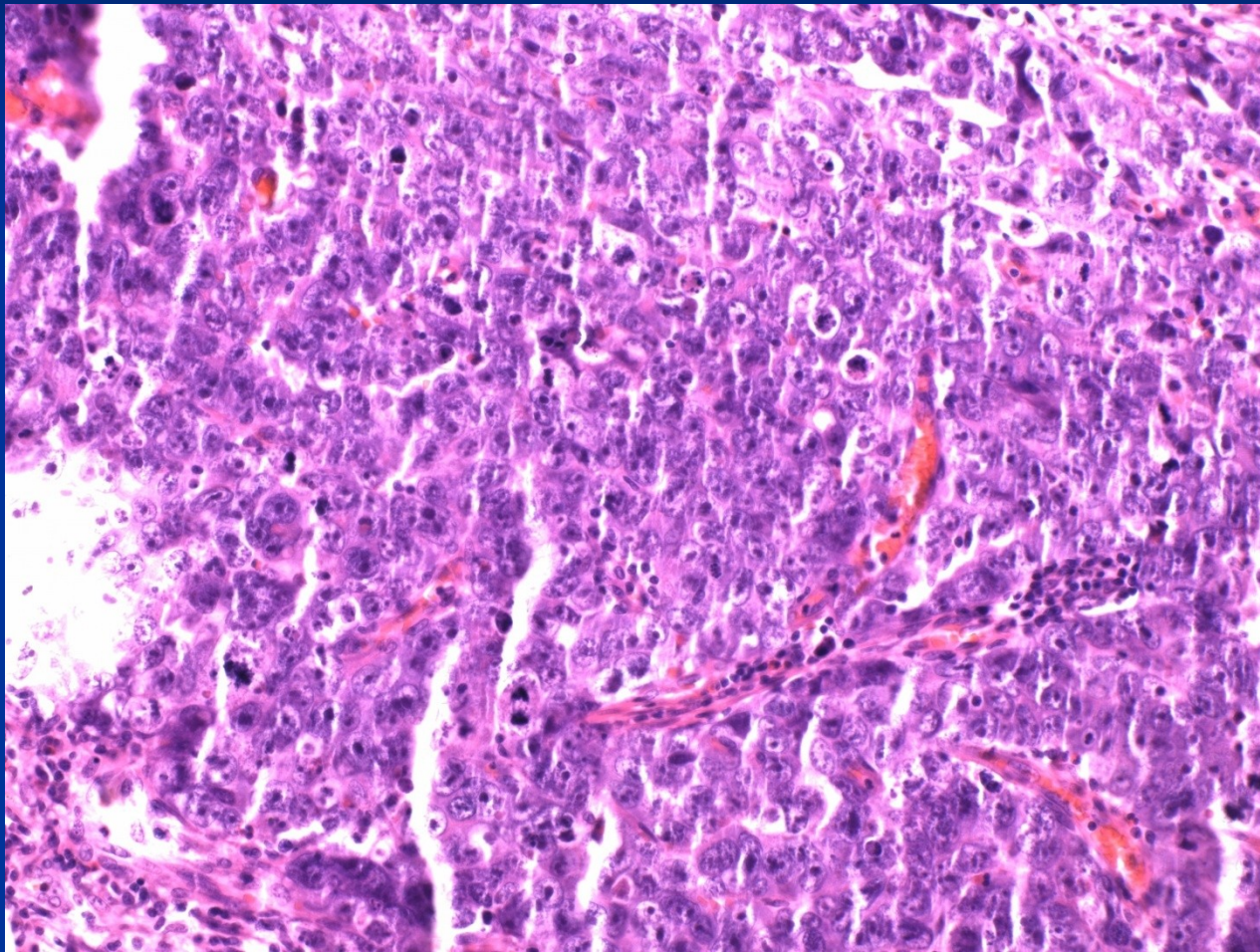


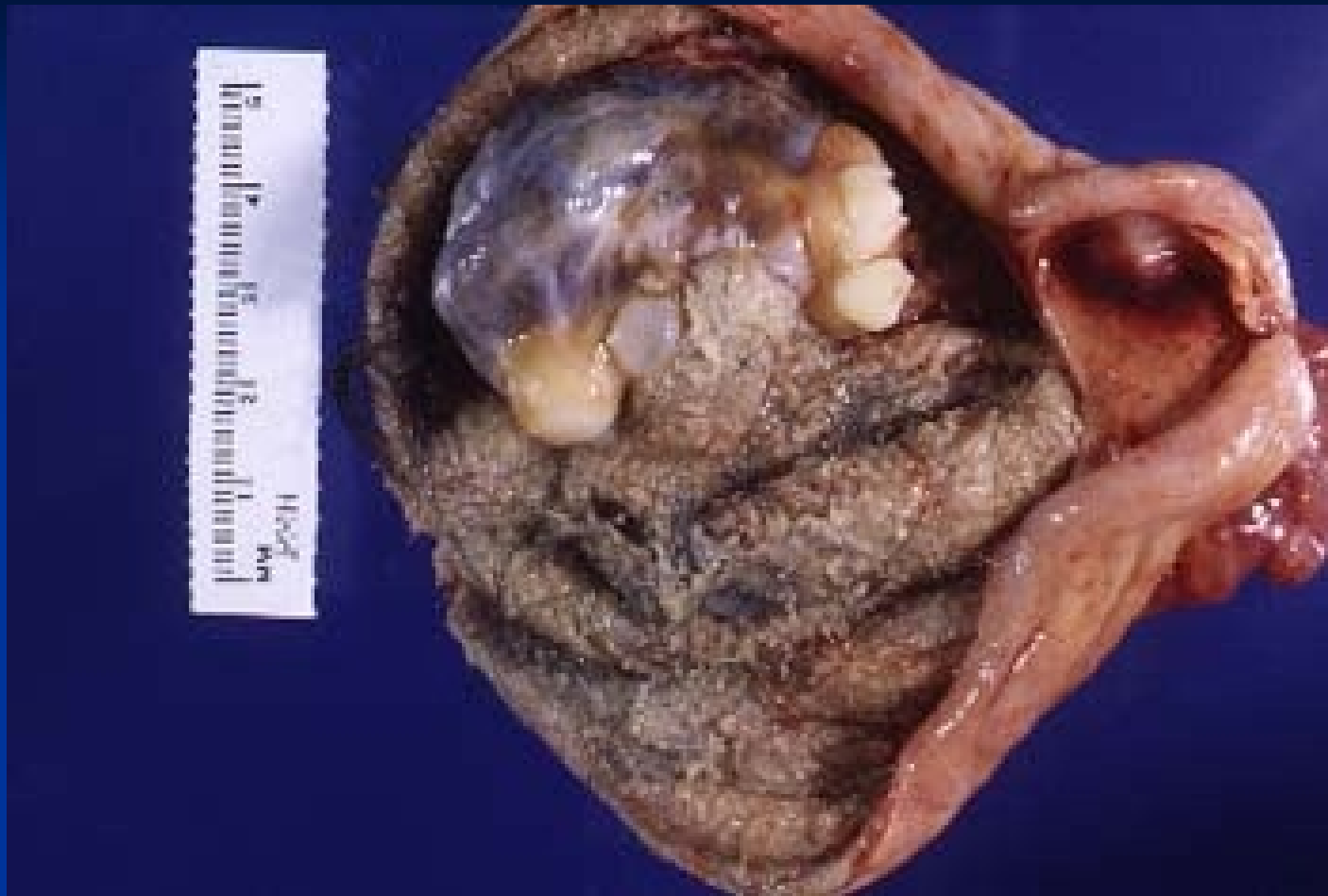Figure 23-48. Histogenesis and interrelationships of tumors of germ cell origin.

Dysgerminoma

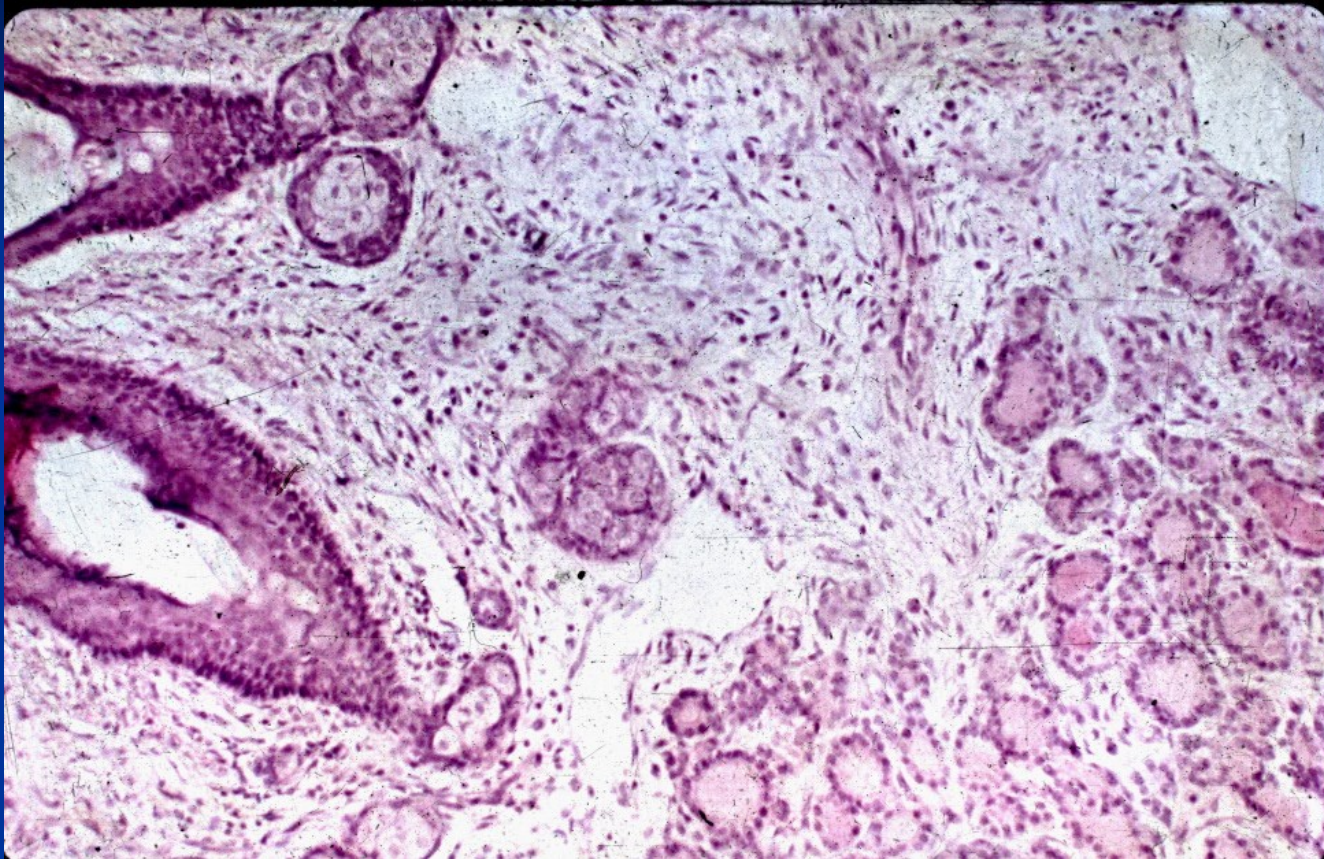


Embryonal carcinoma



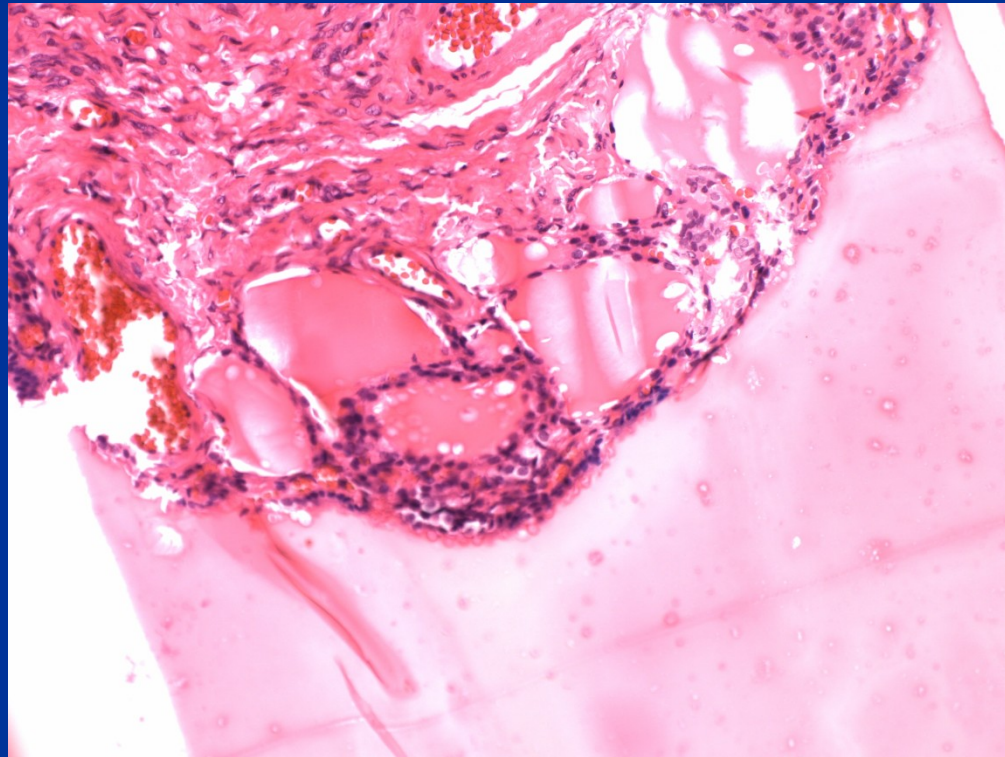


Dermoid cyst – mature cystic teratoma



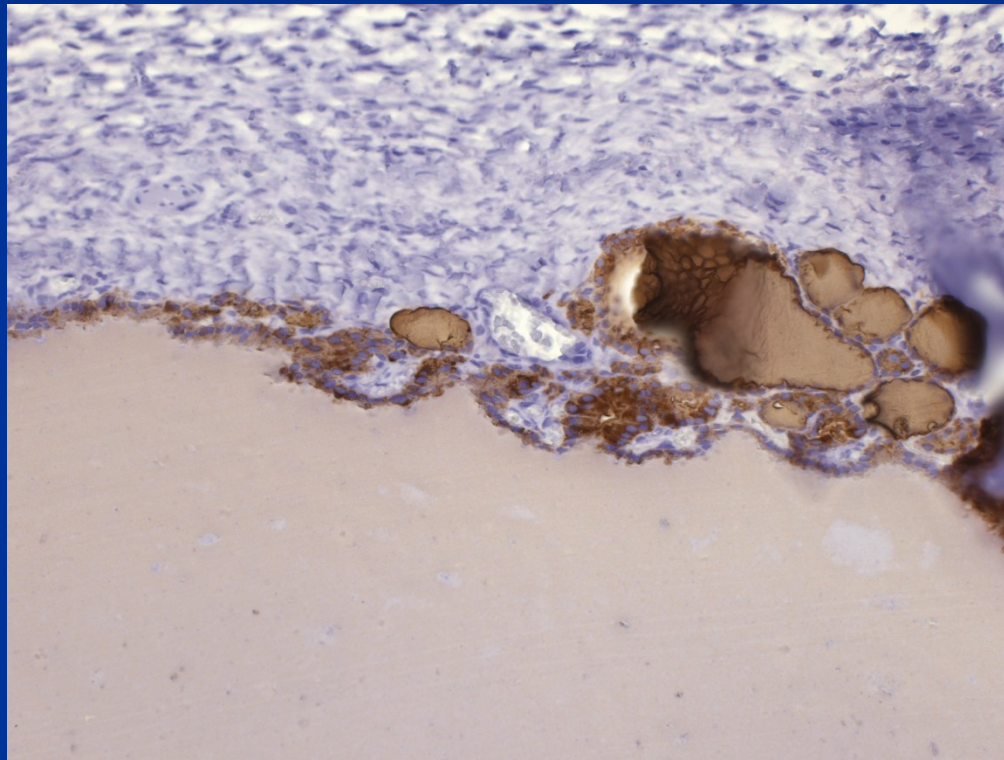
Dermoid cyst – mature cystic teratoma

Struma ovarii



Struma ovarii

- IHC thyreoglobulin



Sex cord-stromal tumors

■ Granulosa cell tumors

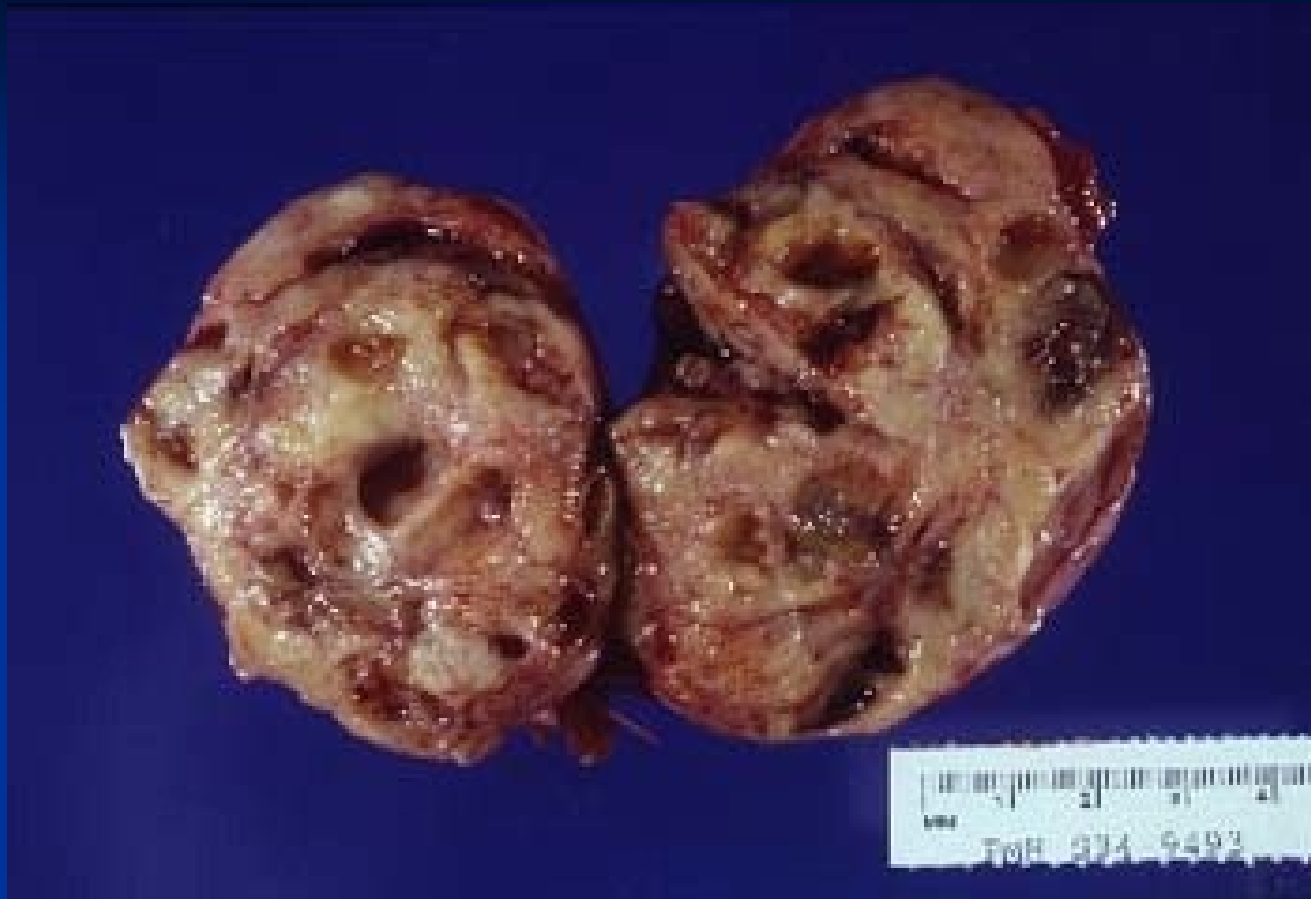- in adults potentially malignant, possible estrogen production – precocious puberty, risk of abnormal uterine bleeding, endometrial hyperplasia or ca

■ Thecoma-fibroma

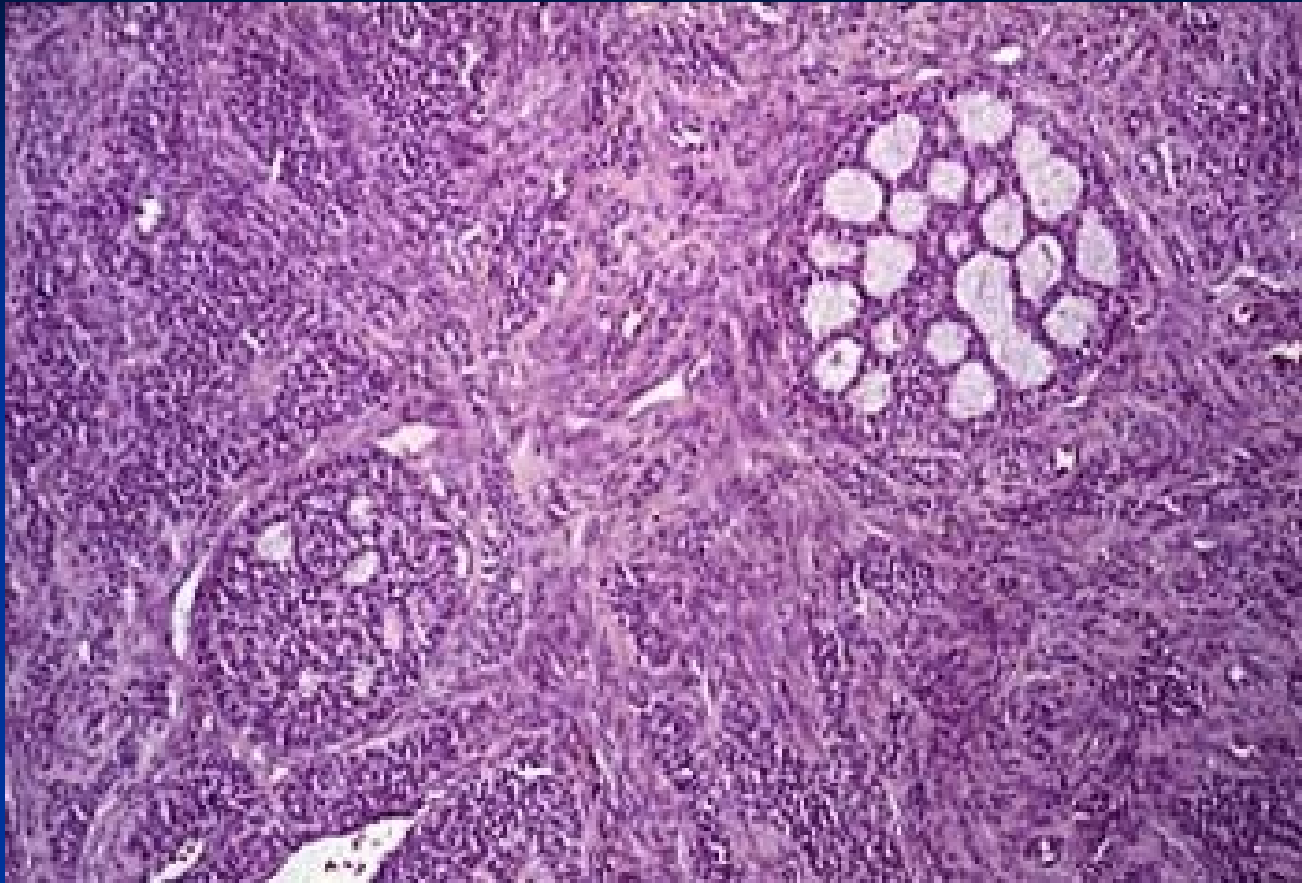
- most common, usually benign, possible association with ascites, rarely estrogen production

■ Sertoli-Leydig cell tumors

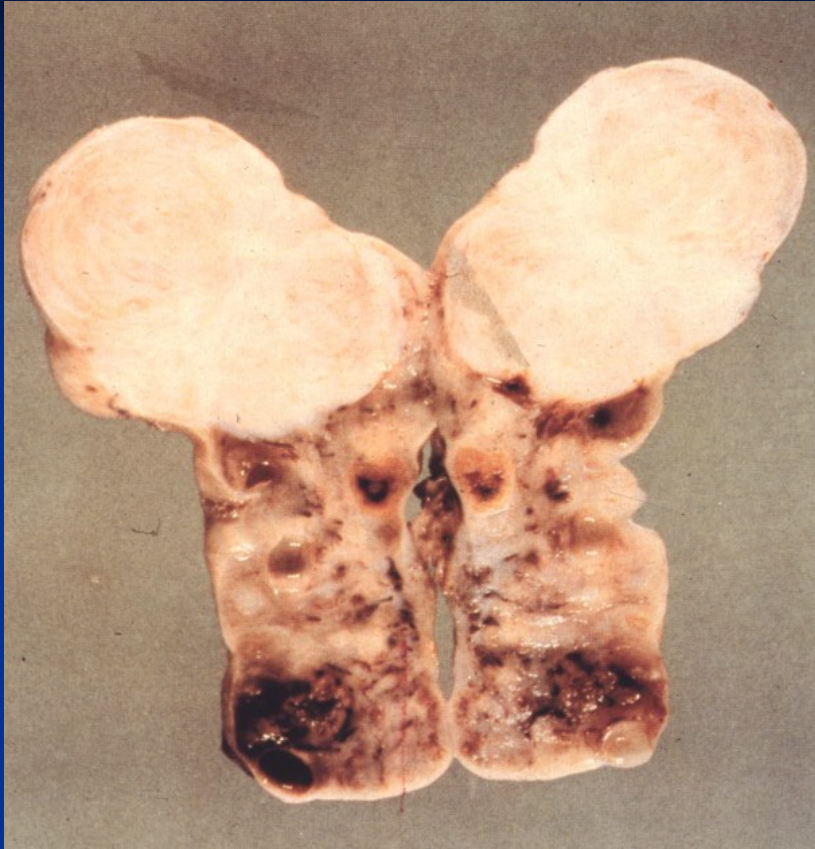
- possible masculinisation



Granulosa cell tumor

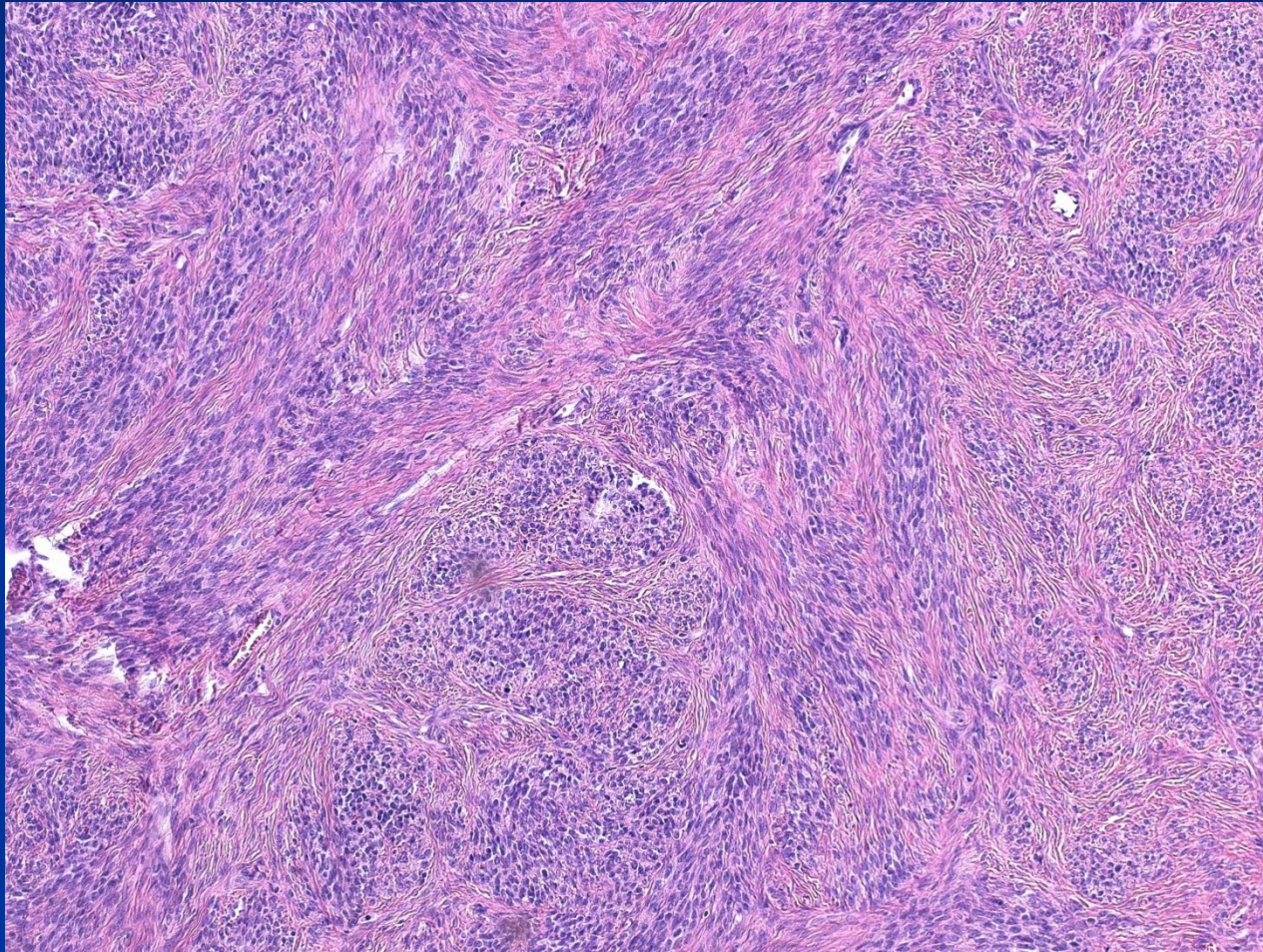


Granulosa cell tumor

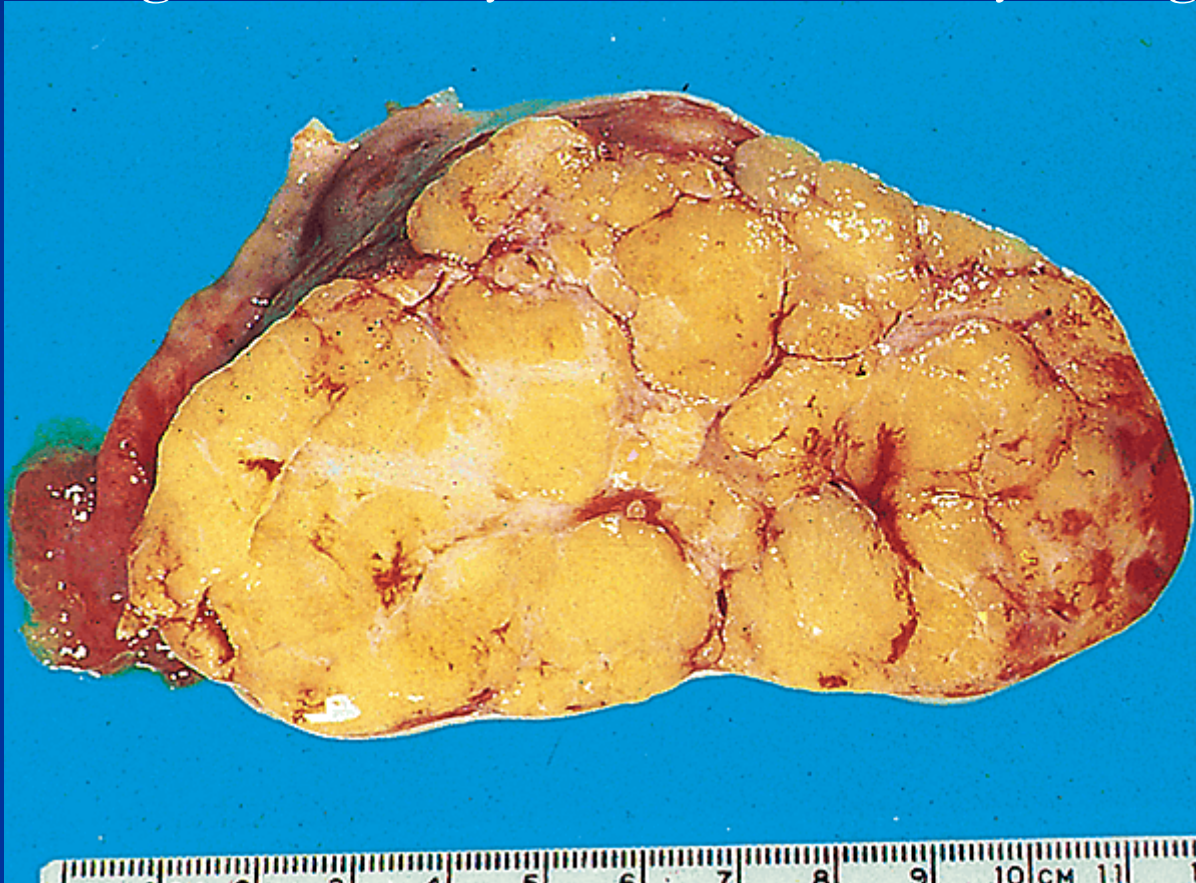


Ovarian fibroma – white-yellowish, solid, firm

Ovarian fibroma

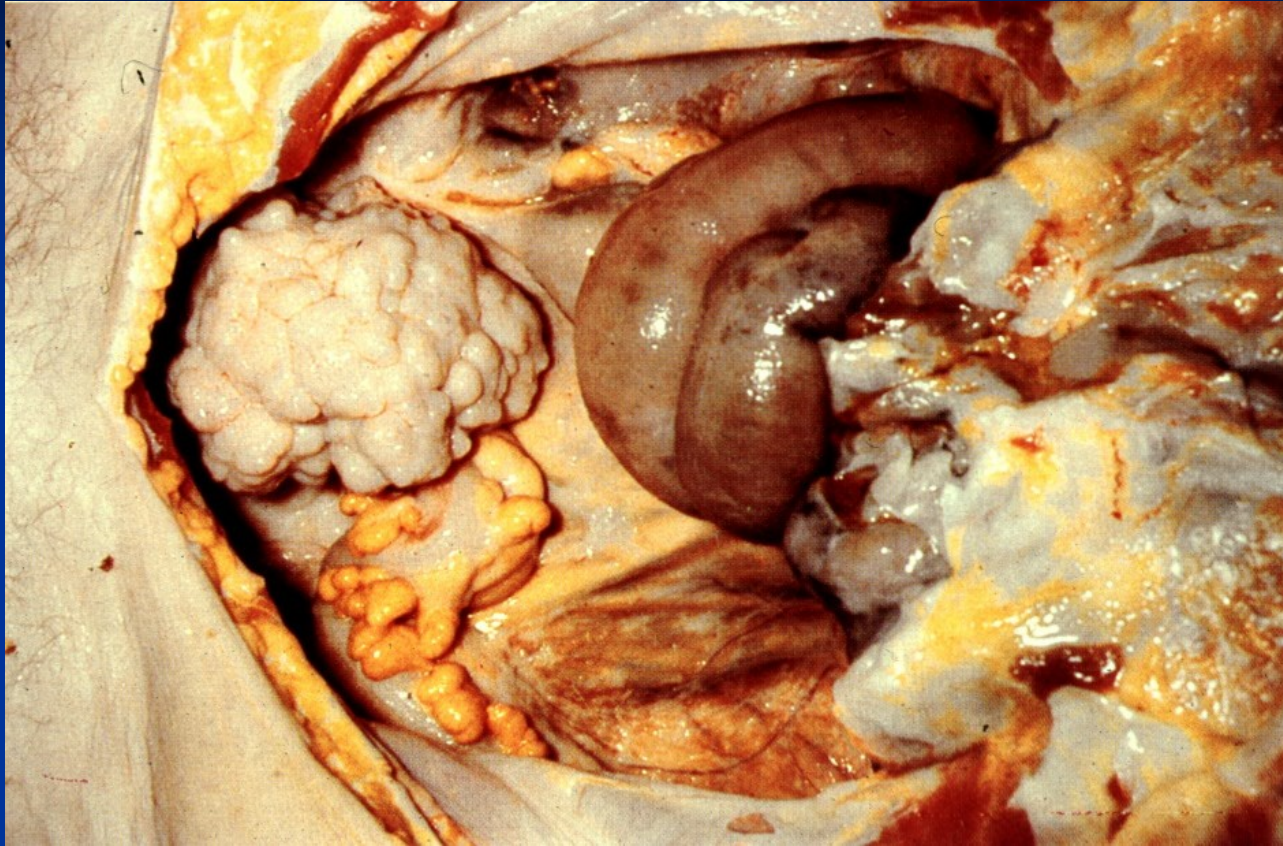


Thecoma - solid, lobulated, yellow (lipid containing cells), estrogenic activity common; usually benign

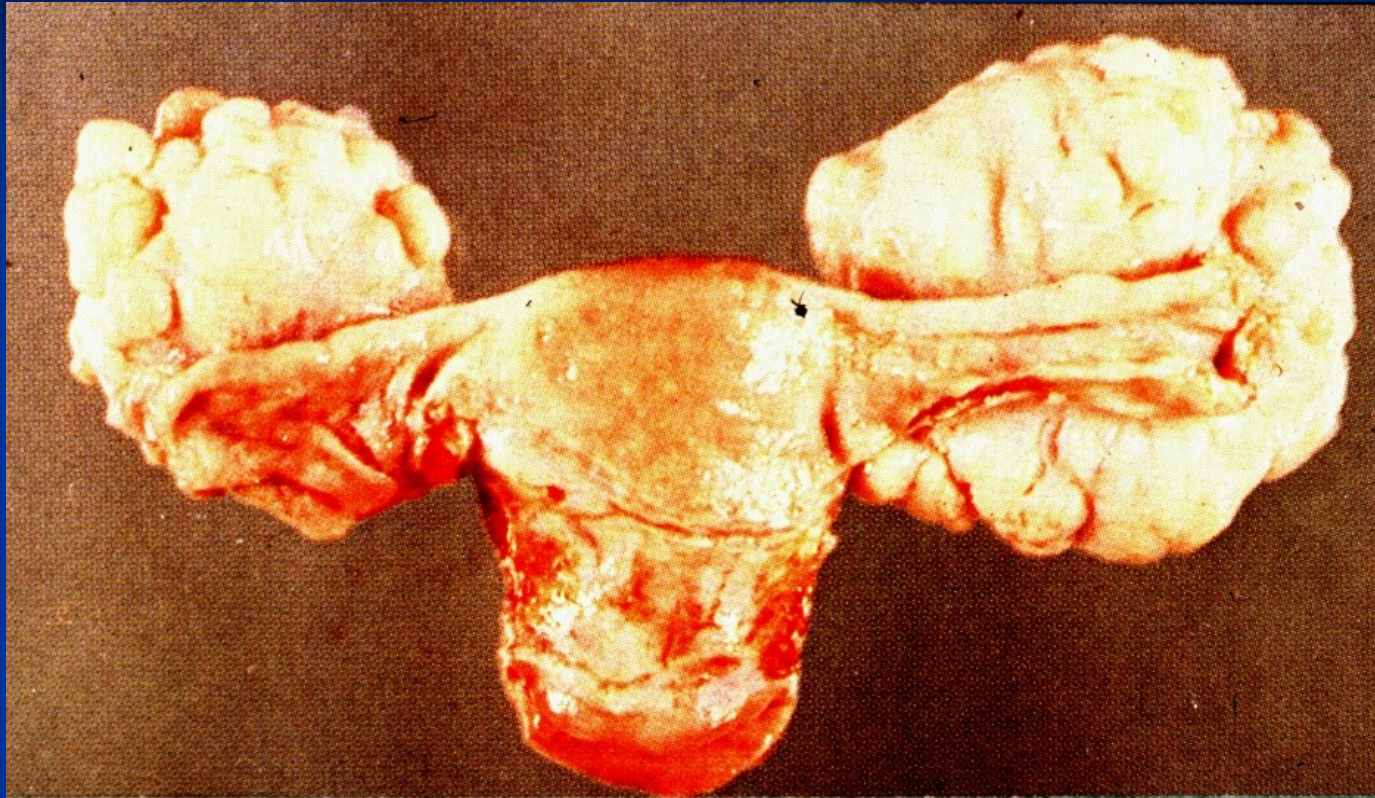


Metastatic tumors

- **GIT** (stomach, colorectal, commonly mucinous adenocarcinoma)
- **breast**
- **! synchronous primary endometrial ca + primary endometroid ovarian ca**



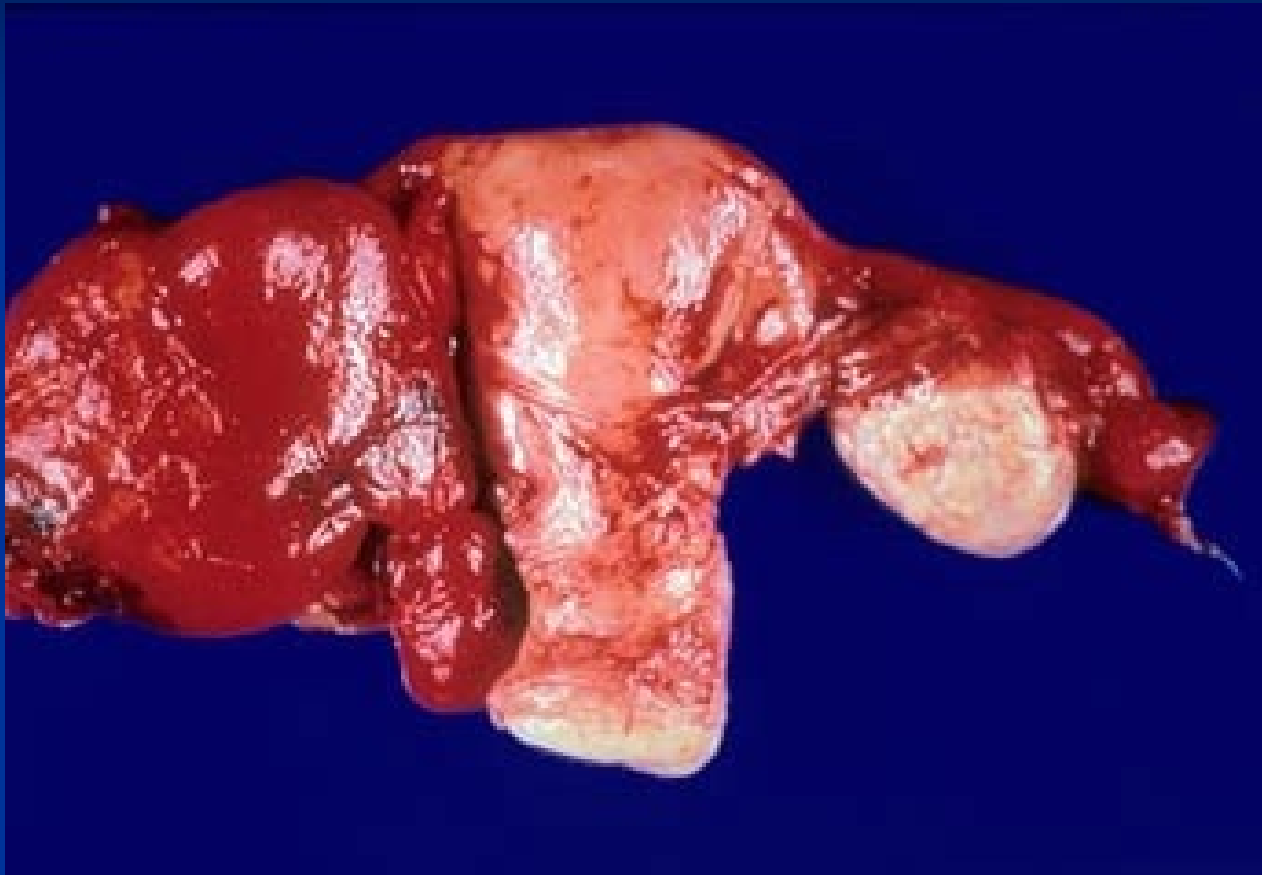
Krukenberg tumor, bilateral ovarian metastasis of GIT mucinous adenocarcinoma



Krukenberg tumor

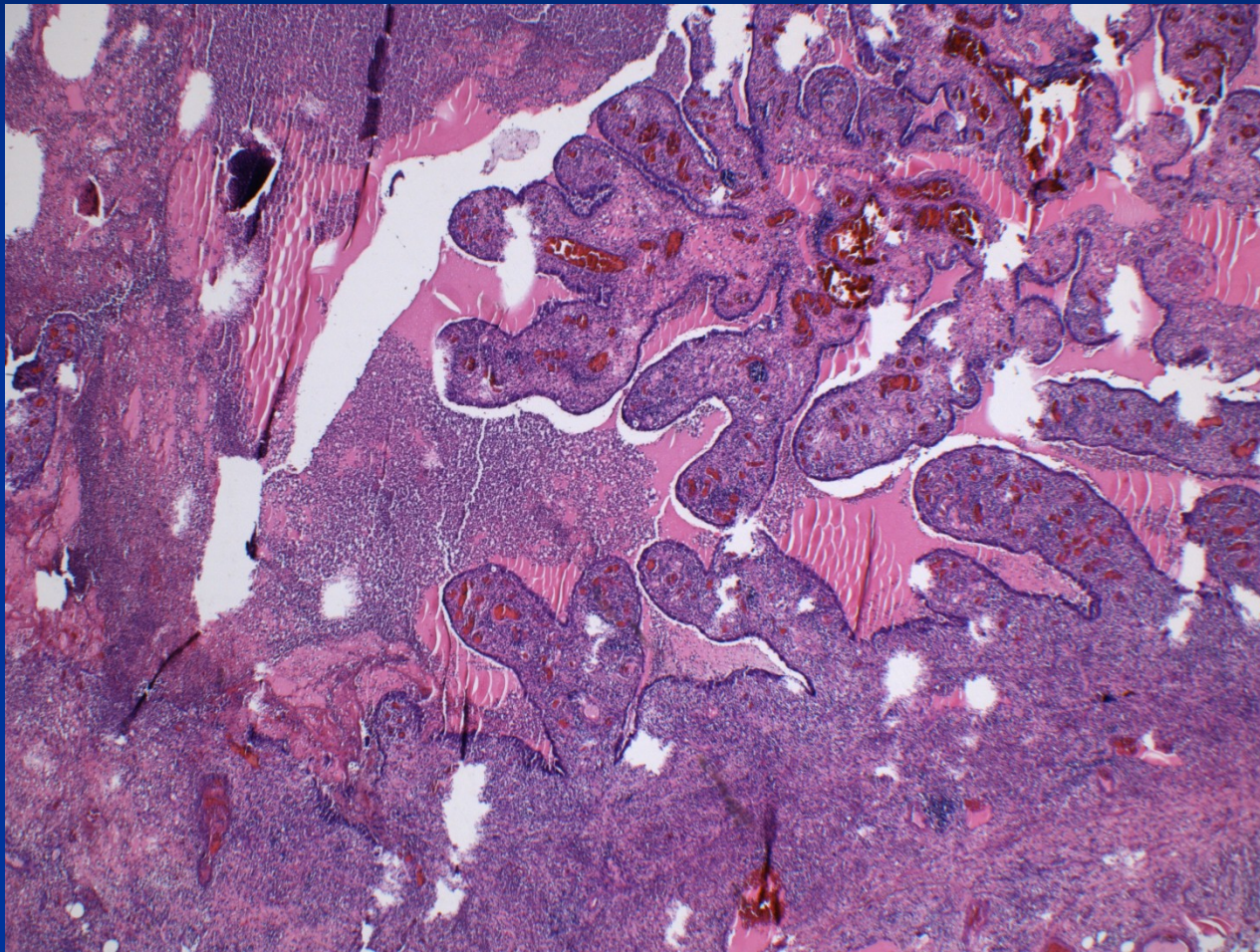
Fallopian tubes diseases

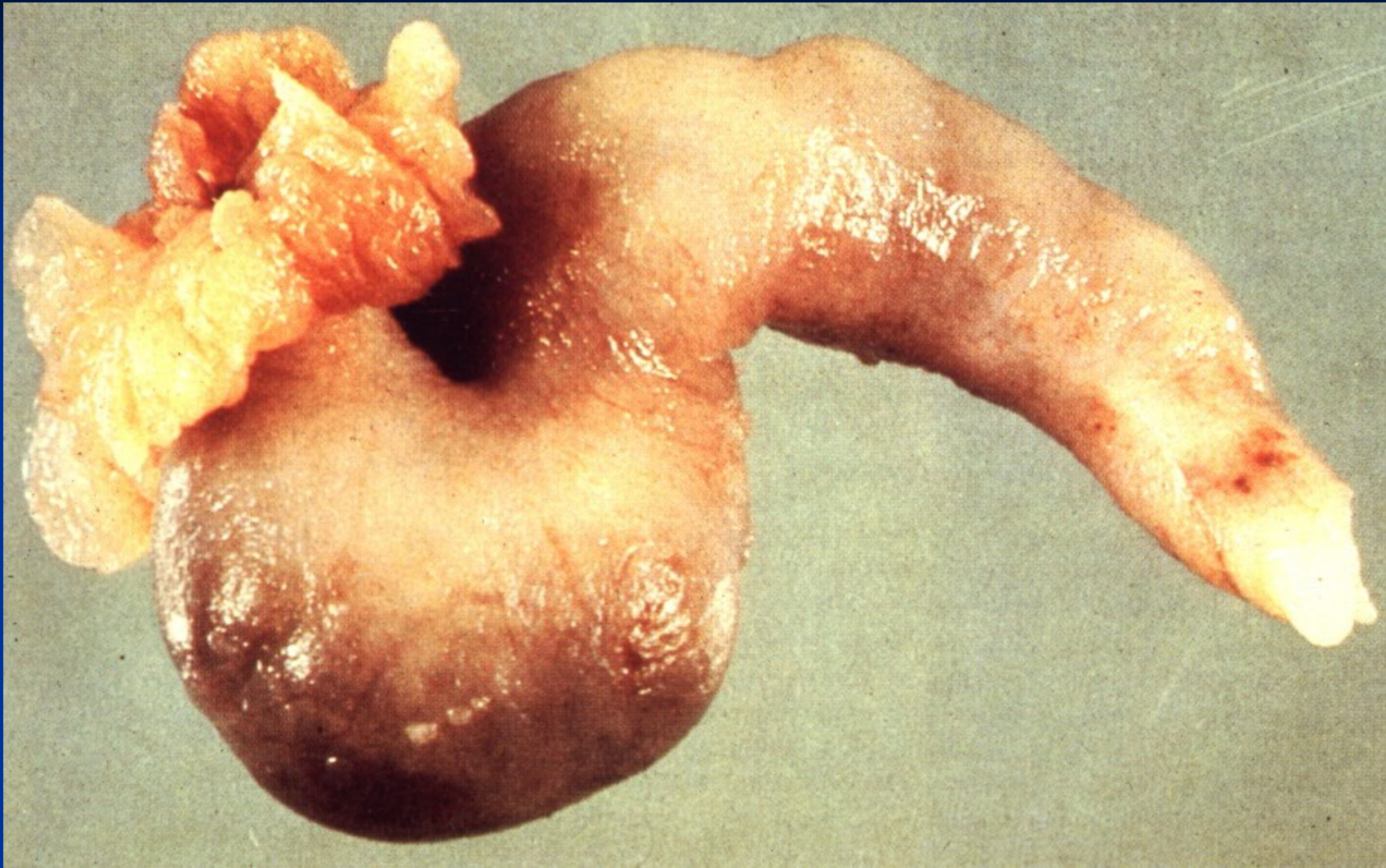
- Inflammation (risk of infertility or GEU)
- Cysts (paratubal)
- Tumors
 - serous adenofibroma, papilloma – benign
 - serous tubal intraepithelial carcinoma (STIC)
 - 1 % of normal population
 - 5-10 % in high risk (BRCA carriers), prophylactic surgery
 - source of high grade serous ovarian ca
- GEU (ectopic pregnancy)



Acute salpingitis + tuboovarian abscess

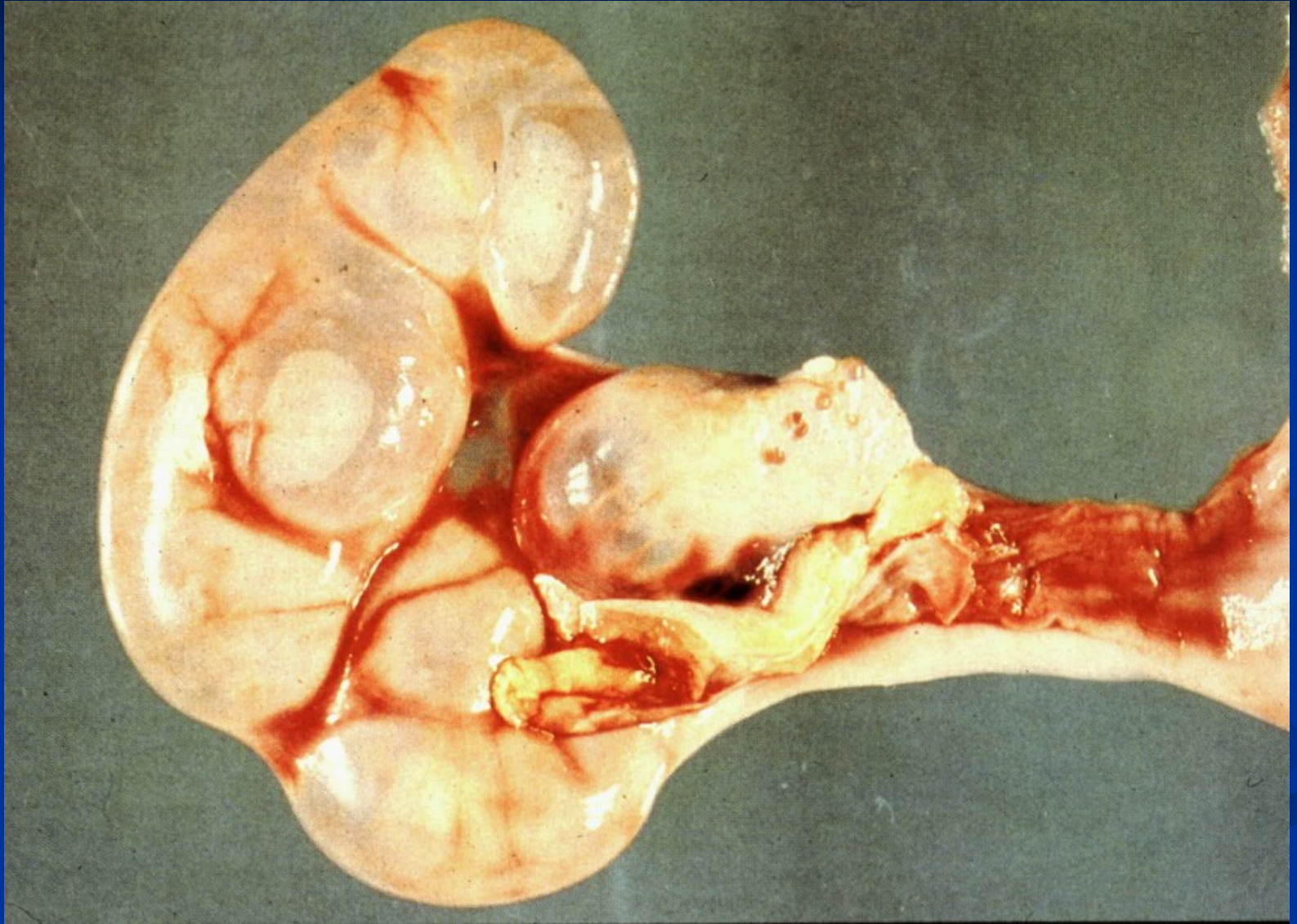
Acute salpingitis



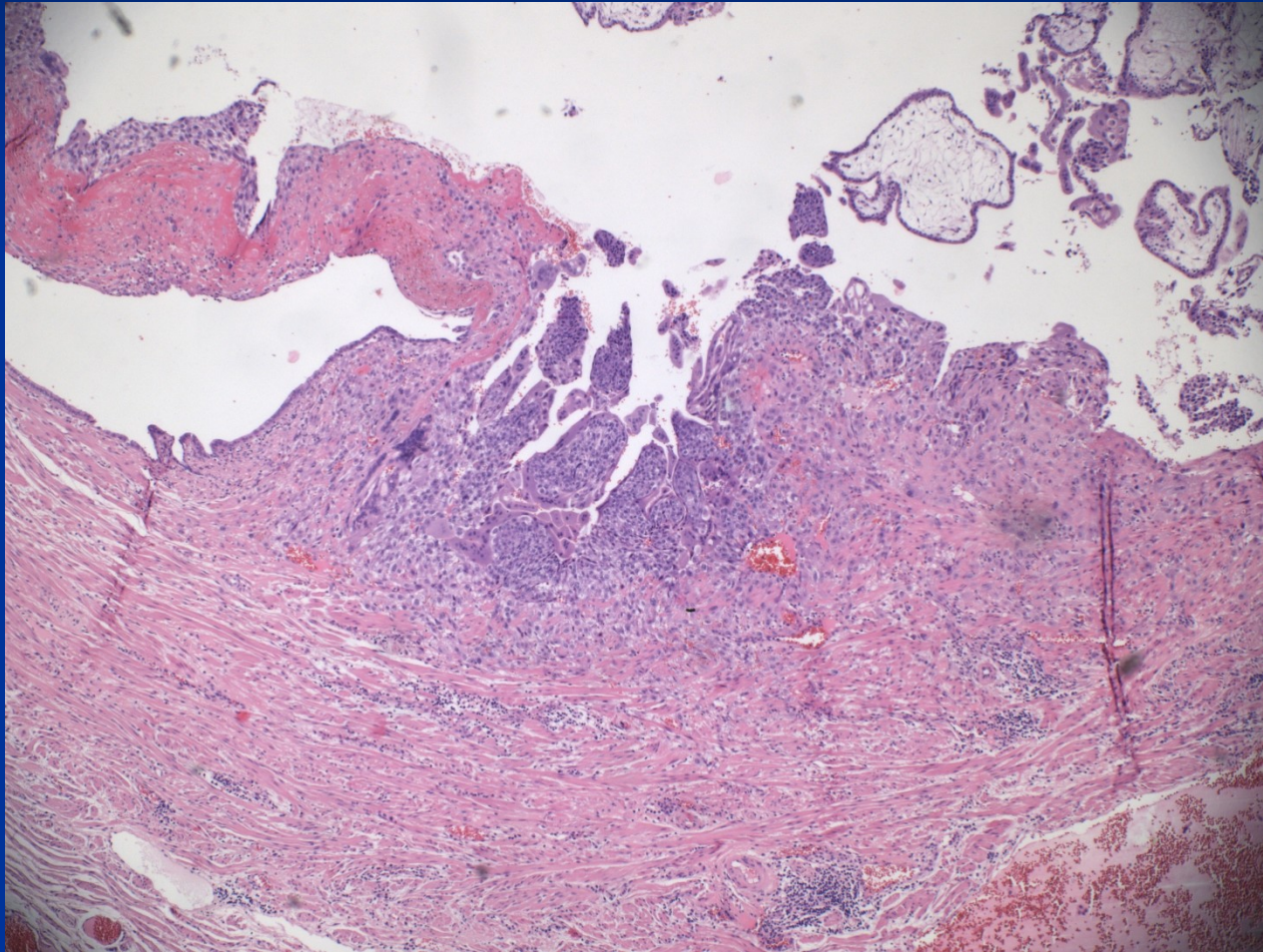


Chronic salpingitis

Hydrosalpinx



Tubal GEU – chorionic villi



Pathology of uterine corpus

- congenital anomalies
- inflammation
- functional endometrial disorders
- polyps (endometrial etc.)
- adenomyosis
- endometrial hyperplasia
- tumors

Clinical signs

- **Disordered puberty** (praecox, tarda)
- **Sterility, infertility** (incl. repeated abortions)
- **Climacteric disorders**

- **Abnormal bleeding**
- **Pain** (localization, type)
- **Abdominal distention**
- **Systemic signs**

Clinical signs

Abnormal bleeding:

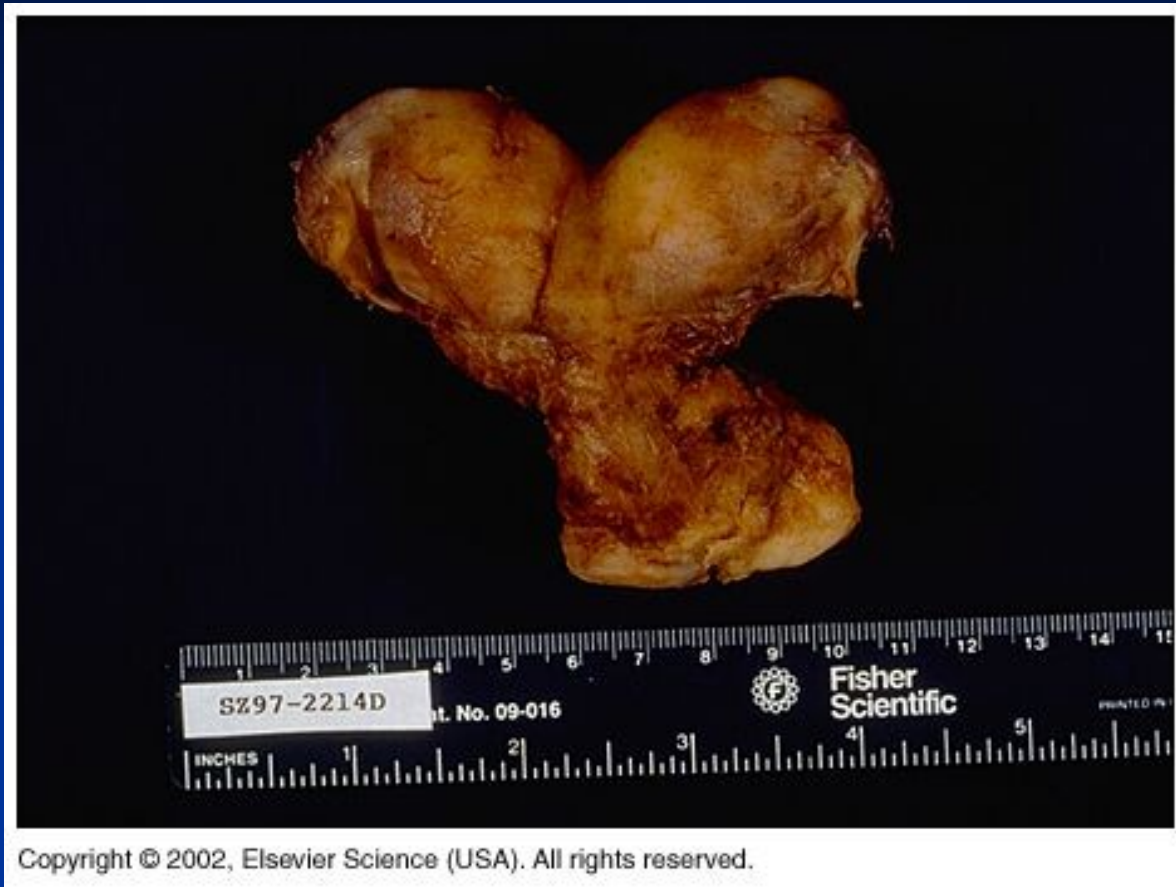- **Amenorrhea:** no bleeding
- **Oligomenorrhea:** cycle > 35 d.
- **Polymenorrhea:** cycle < 21 d.
- **Hypomenorrhea:** regular cycle , \downarrow bleeding
- **Menorrhagia:** regular cycle, \uparrow bleeding
- **Metrorrhagia:** irregular bleeding outside of the cycle, incl. prepuberty and postmenopause
- **Menometrorrhagia**

Abnormal bleeding

- Newborn: maternal estrogen
- Childhood: trauma!!, infection, tumor
- Adolescence: hormonal imbalance, incl. anovulatory cycle, psychogenic/nutritional problems
- Fertile age: anovulatory cycle, pathologic pregnancy, hormonal imbalance/response, inflammation, polyp, neoplasia
- Post/menopause: hyperplasia, polyp, neoplasia; atrophy

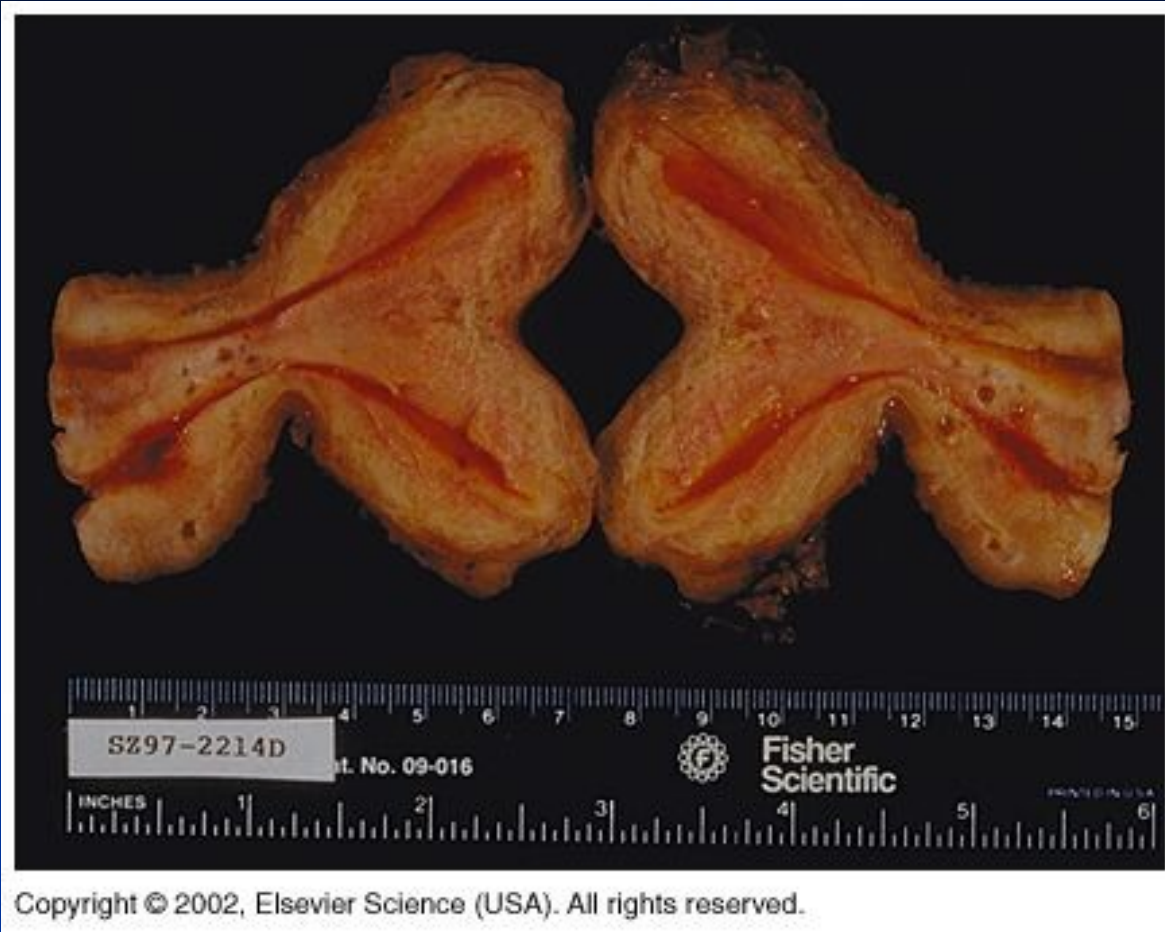Inborn defects

- Temporary uterine septum → if persistent, uterus didelphys, uterus bicornis.
- Müllerian ducts atresia → complete aplasia of uterus etc.

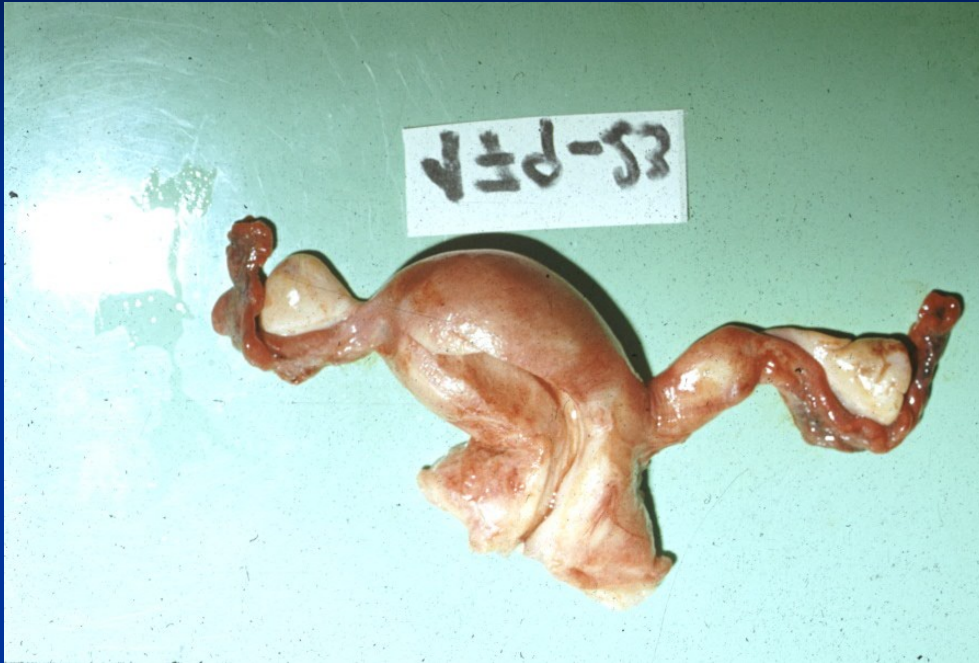

Copyright © 2002, Elsevier Science (USA). All rights reserved.

Uterus bicornis – persistence of temporary embryonal septum



Uterus didelphys



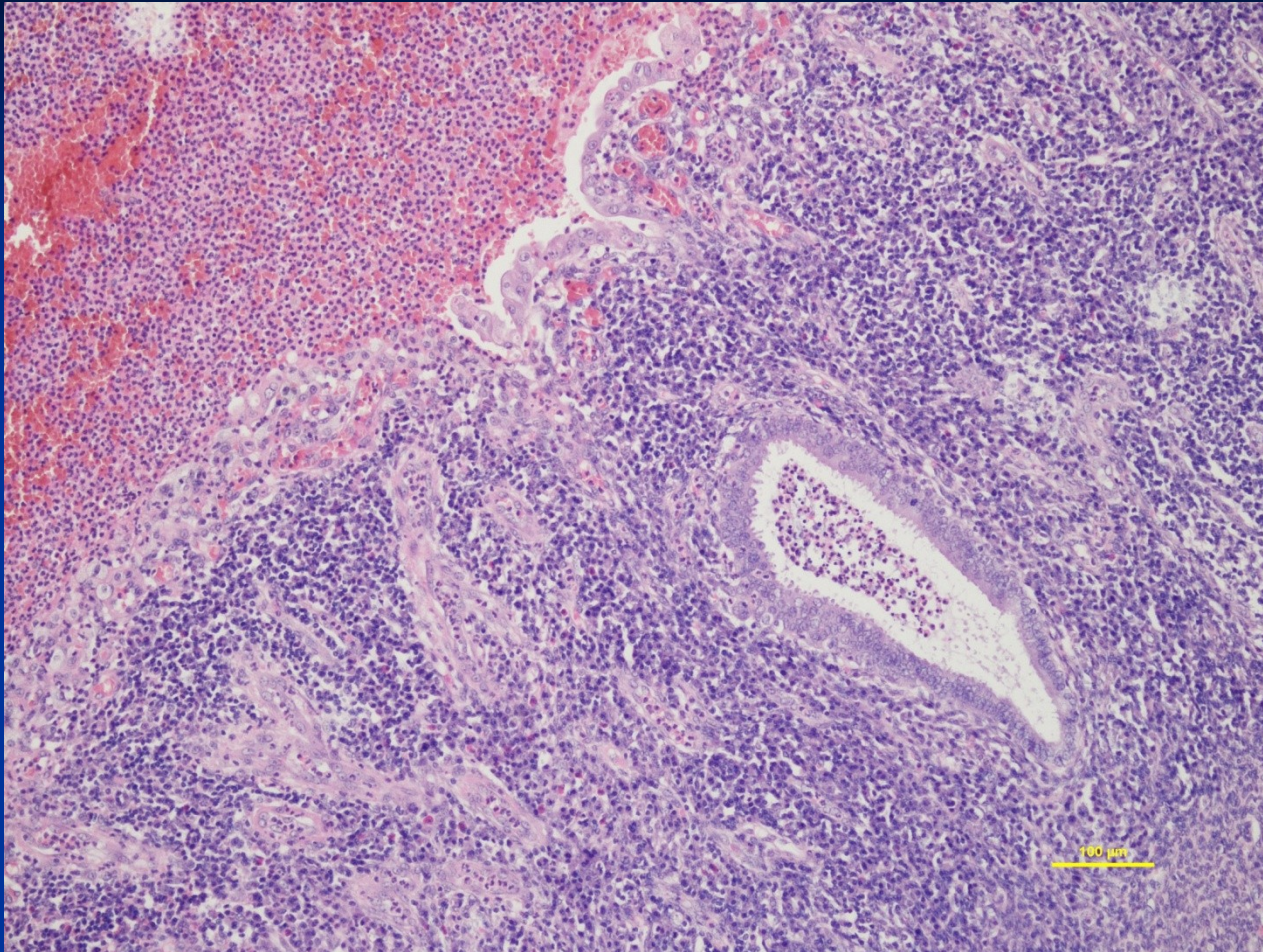
Uterus unicornis with rudimentary horn

Acute nonspecif. endometritis

- mixed pyogenic flora (endogenous) Clostridium welchii; STD – Neisseria gonorrhoeae, Chlamydia trachomatis, mycoplasma – commonly into chronicity
- **signs** - fluor, metrorrhagia, local pain, systemic signs, sepsis possible (puerperal)
- **gross** – hyperemia, petechiae, endometrial ulcerations; gangrena
- **micro** – mixed inflammatory infiltrate in intersticium and glands, abscess, necrosis, thrombosis, haemorrhagia

Acute nonspecific endometritis

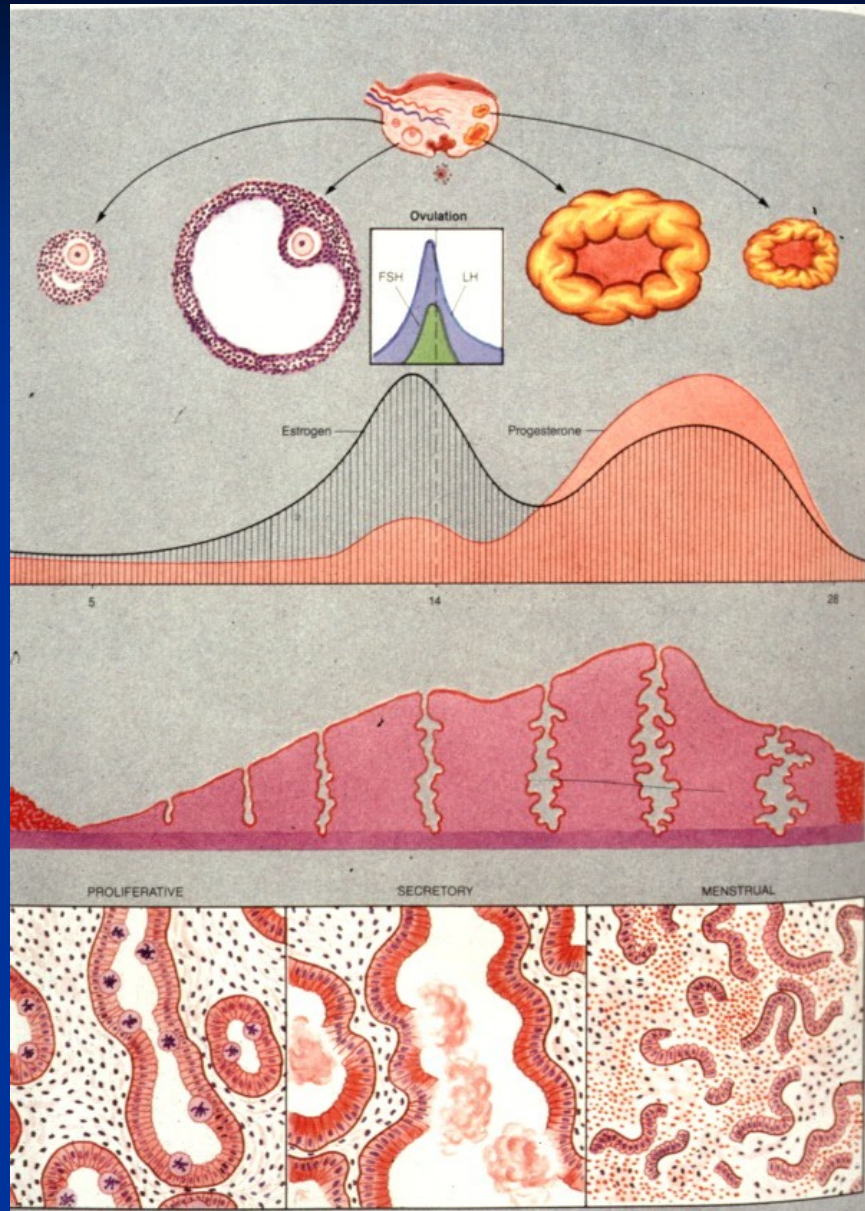
- **ac. complications:** ac. myometritis, parametritis (→ pelvic veins thrombosis), salpingitis (→ peritonitis), sepsis
- **chron. complications:** chron. endometritis (→ irregular bleeding, infertility; plasma cells in infiltrate, stromal changes, irreg. glands)
tubal stenosis, adhesions (→ infertility, GEU);
pelvic inflammatory disease (local + systemic symptoms)



Acute endometritis, intraglandular neutrophils

Disorders of menstruation cycle

- Psychogenic – sec. amenorrhea, psychogenic sterility
- Hypothalamic
- Pituitary – idiopathic, sec. (infl., tumors,...)
- Gonadal
- Uterine
- Metabolic – endocrine (thyr., adrenals), hepatic
- Nutritional



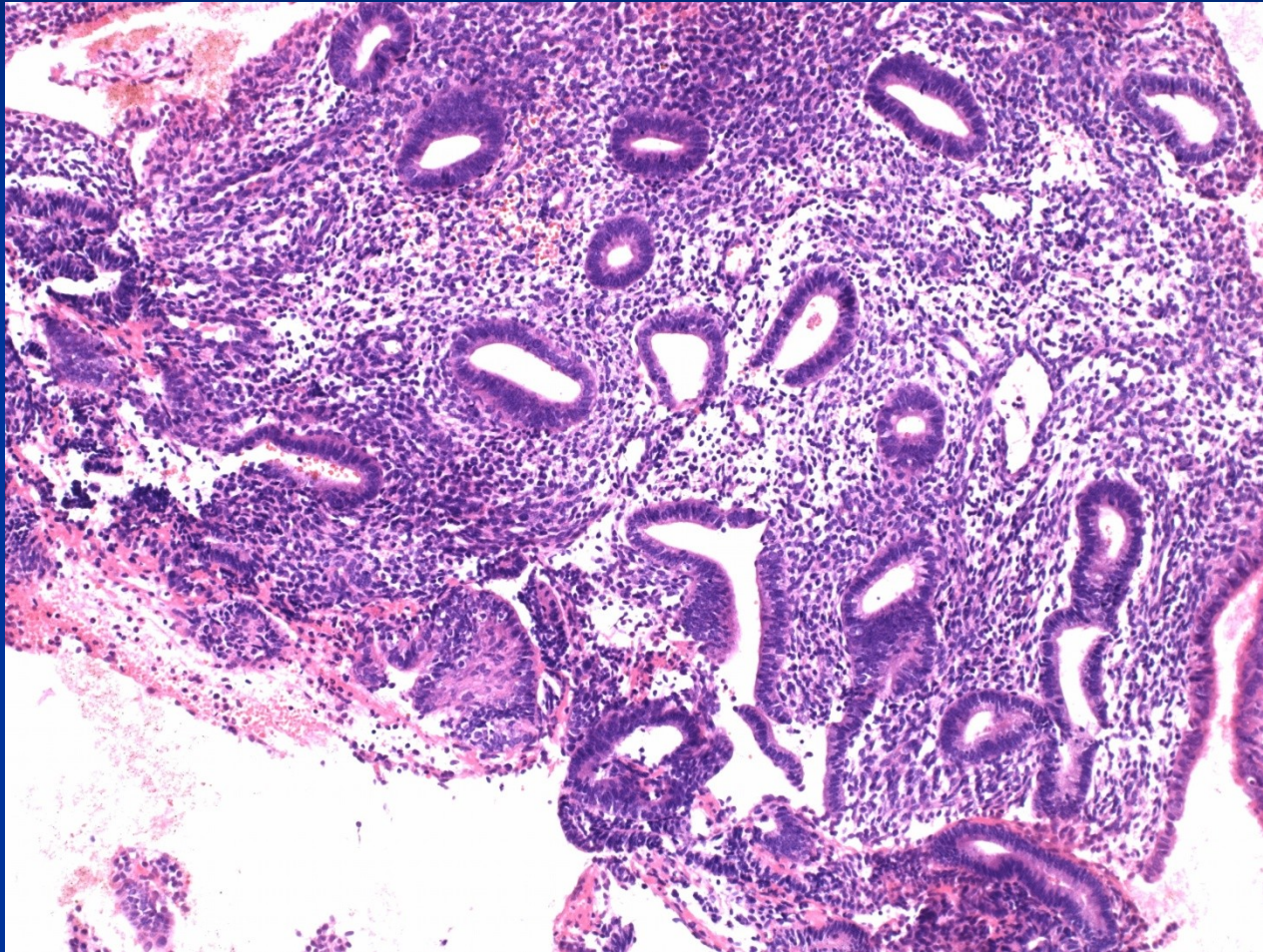
Functional endometrial changes

- **Dysfunctional bleeding** – no organic lesions (inflammation, polyp, hyperplasia, tumor); no exogenous hormones
- appearance of endometrium doesn't correspond to the cycle day (clinical data!)
- commonly focal stromal and glandular breakdown

Estrogen-associated

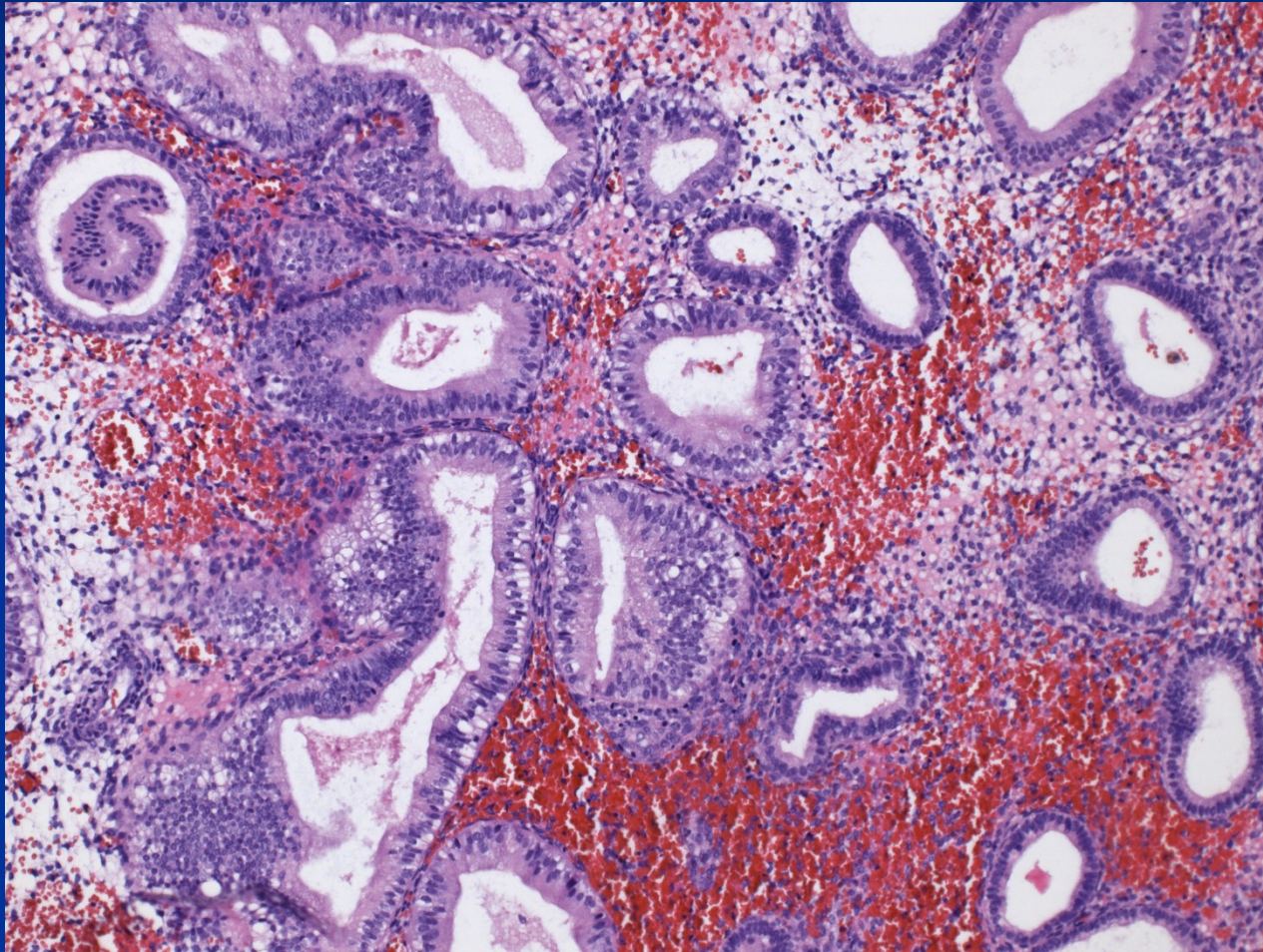
- irregular proliferation
- anovulatory cycle – estrogenic stimulation (proliferation) without progestins, may progress to hyperplasia
- ovulation bleeding – hormonal drop, edema, stromal breakdown

Irregular proliferation



Ovulation endometrium

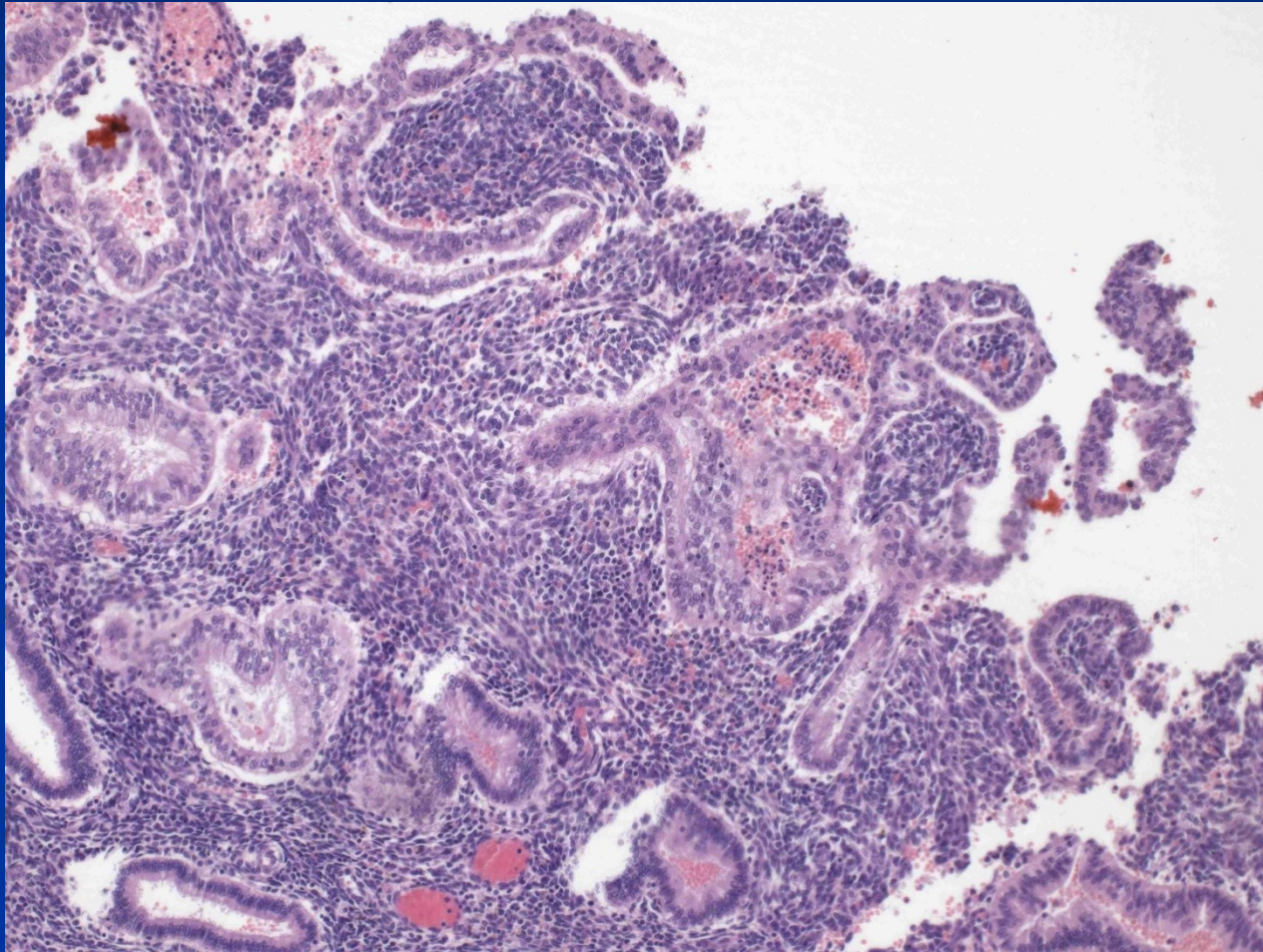
subnuclear vacuoles, stromal edema + bleeding



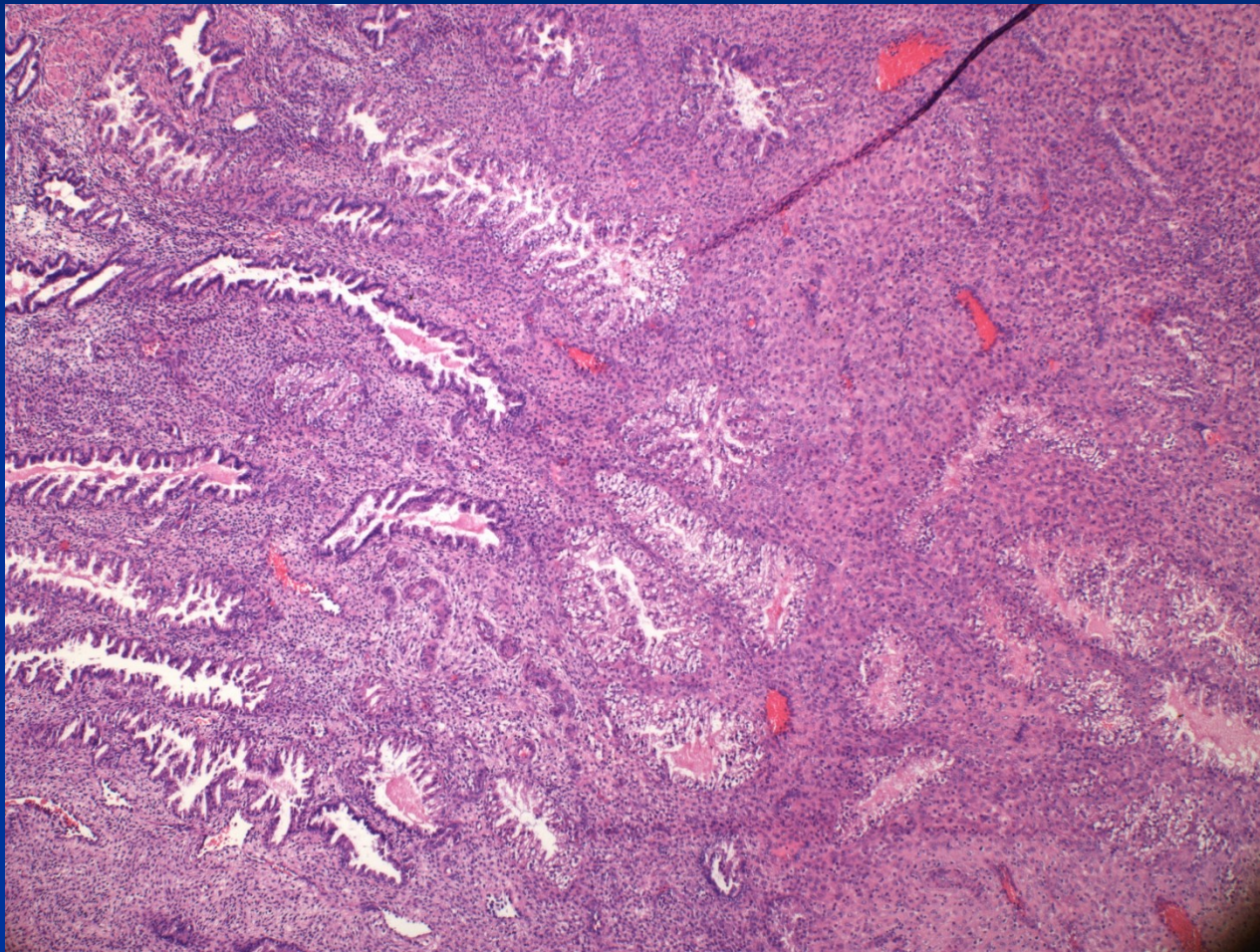
Progestin-associated

- luteal insufficiency – insufficient secretory transformation
- irregular shedding – irreg. response on hormone level drop
- hypersecretion, Arias-Stella phenomenon – ↑ progestins + stimulation; clear cells, reactive atypias

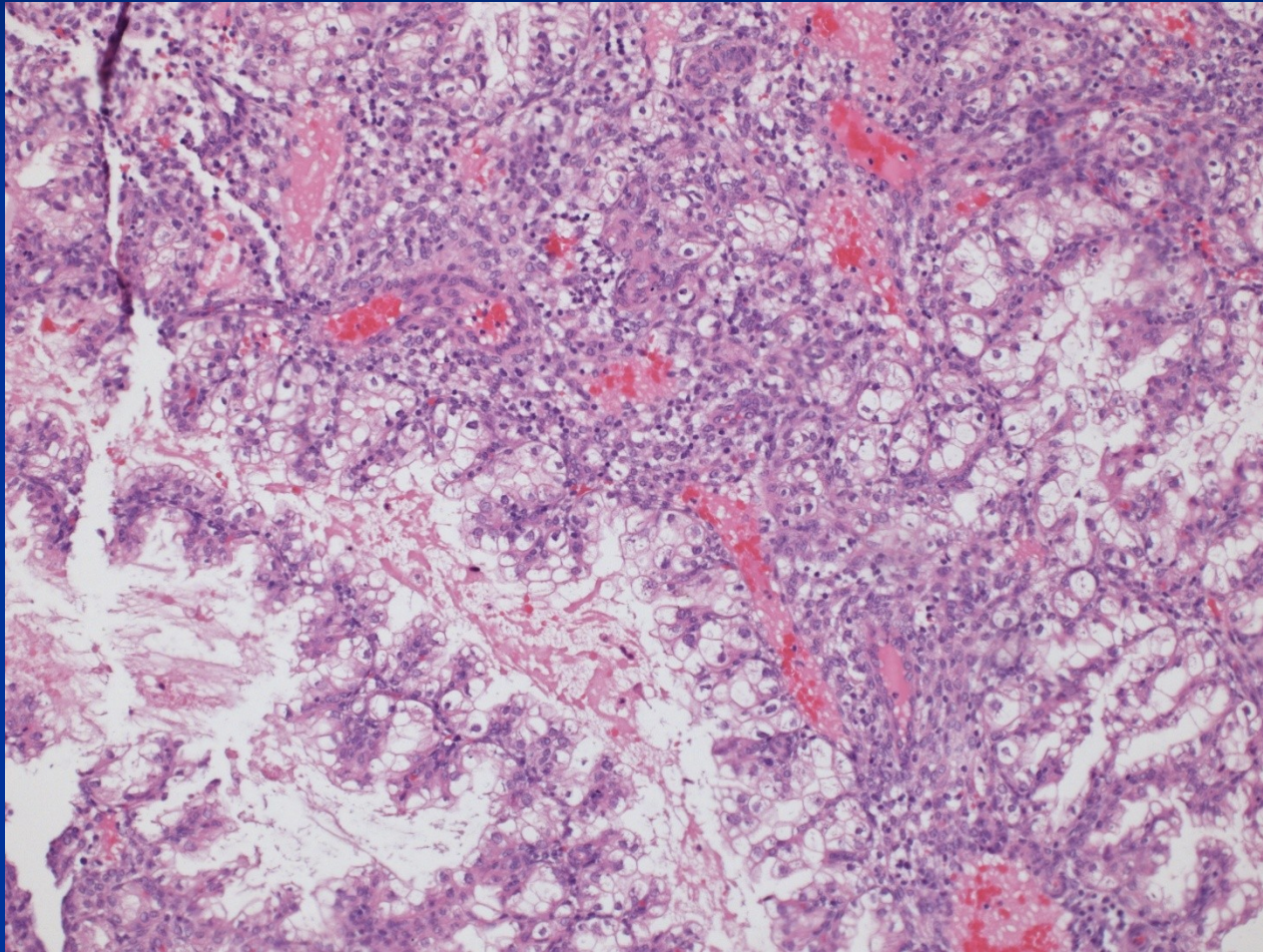
Disordered early secretion - ovulation



Irregular secretory endometrium



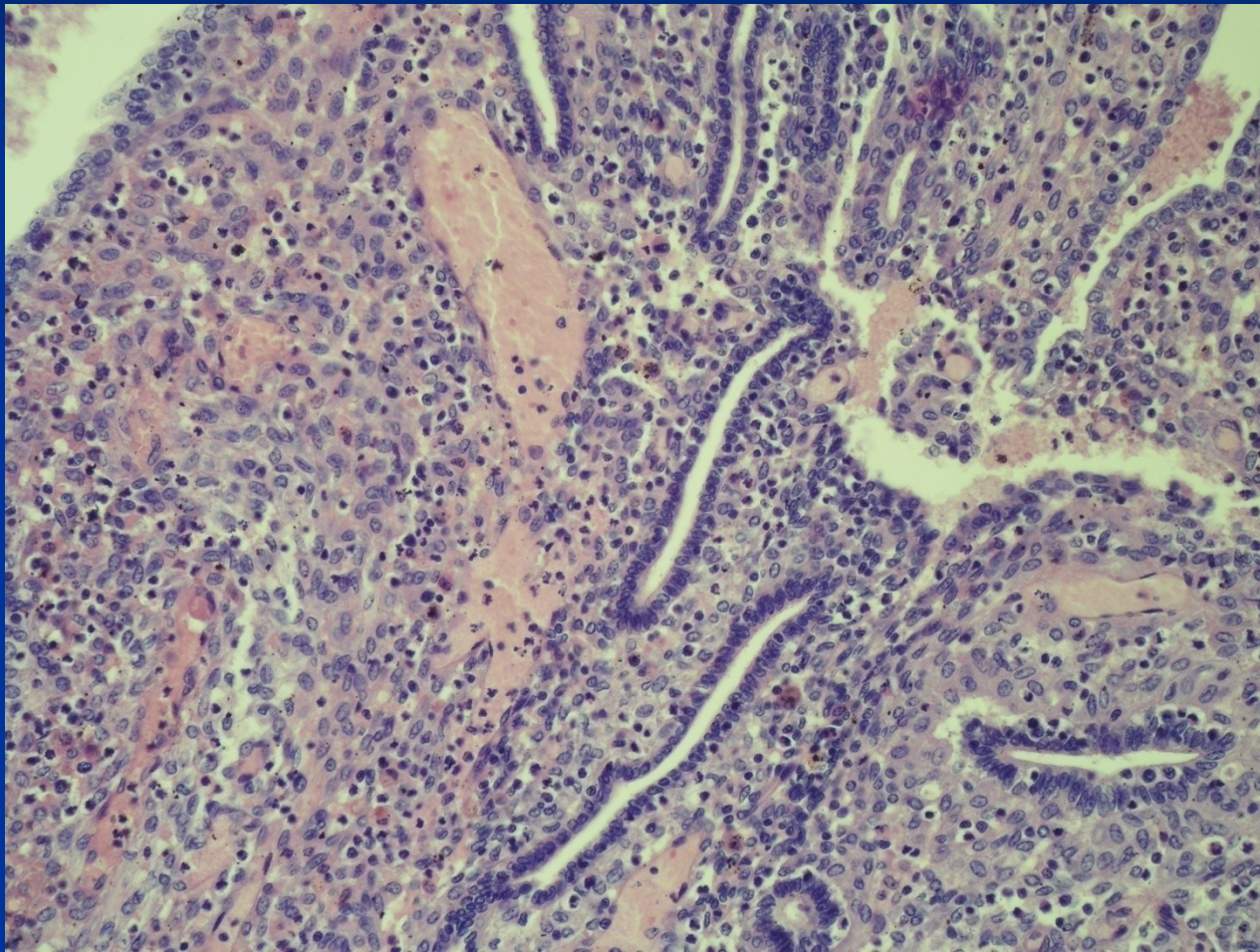
Hypersecretion



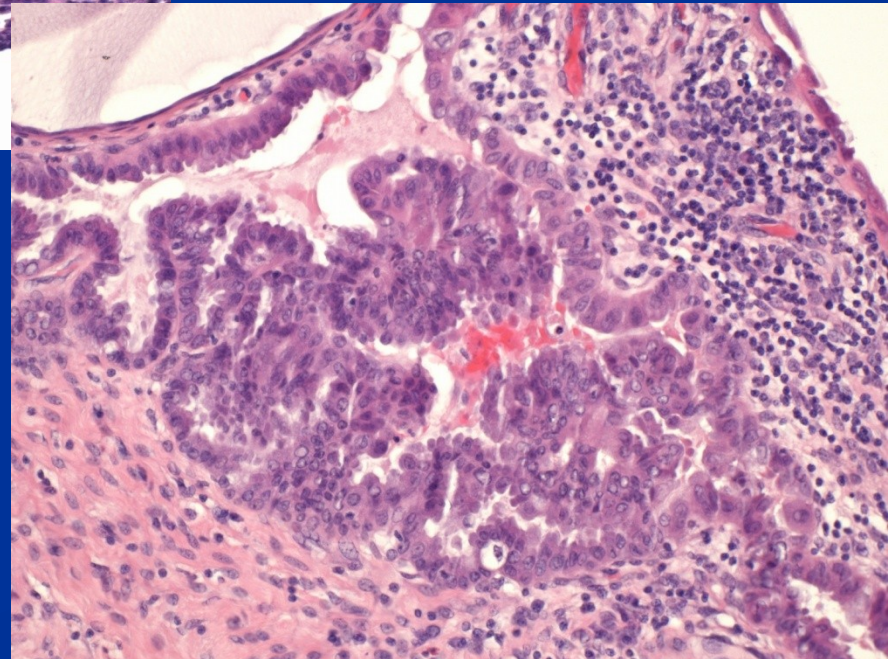
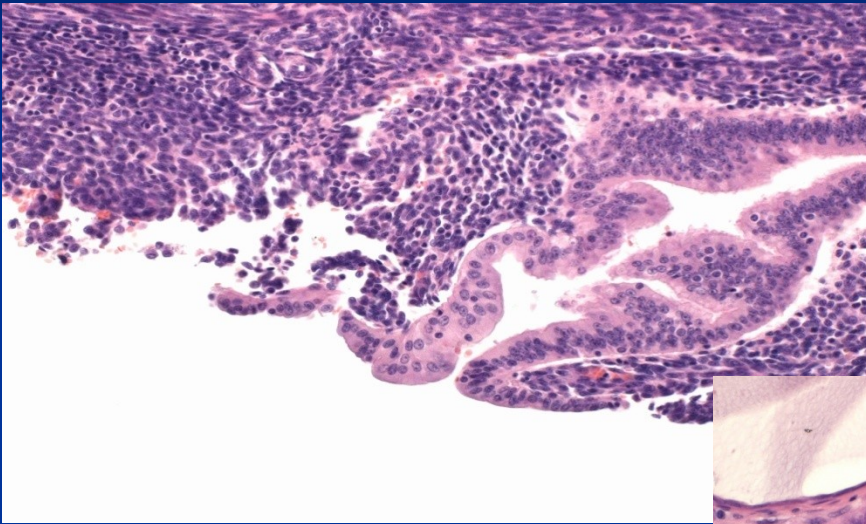
Iatrogenic endometrial changes

- **exogenous hormones – contraception:** variable appearance, combination → inactive to atrophic endometrium, progestins → stromogland. dissociation etc.
- **hormonal substitution therapy:** without HYE, combination prep. (risk of hyperplasia, ca)
- **IUD long-standing:** inflammation(focal. ac., chron. – actinomyces), ulceration, irreg. endometrium, metaplasia, thrombosis
- **tamoxifen:** endom. polyps, hyperplasia, ca
- **surgery, radiotherapy**

Stromoglandular dissociation



Epithelial changes - eosinophilic



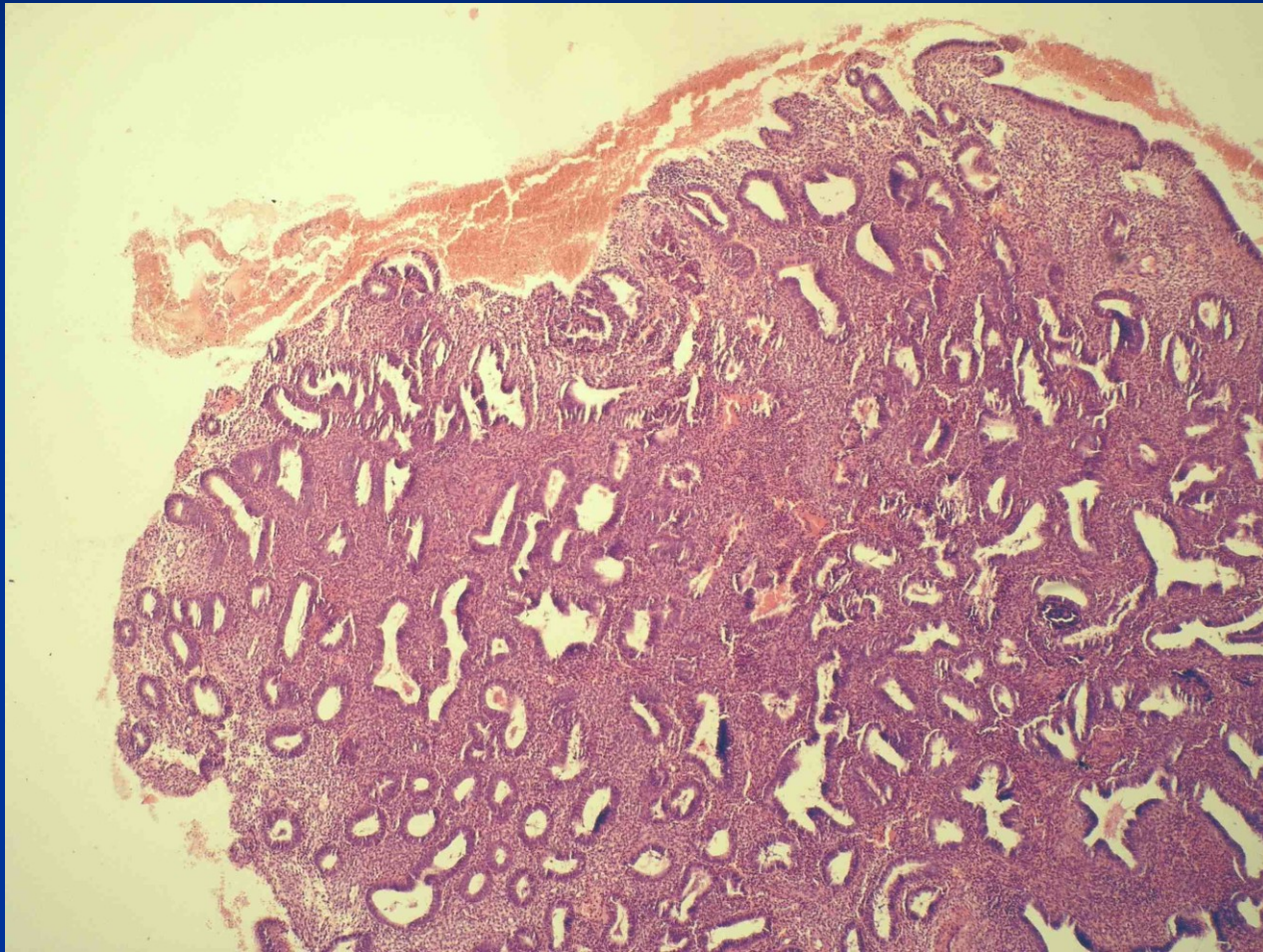
Polyps

- Endometrial polyp
- Polypoid hyperplasia
- Hyperplasia and polyps in tamoxifenem ther.
- Polypoid tumors – adenomyoma, carcinoma, submucosal leiomyoma, stromal tumors, etc.
- Pathological pregnancy (trofoblastic lesions, decidua etc.)
- Pseudotumors – pathol. material accumulation etc.

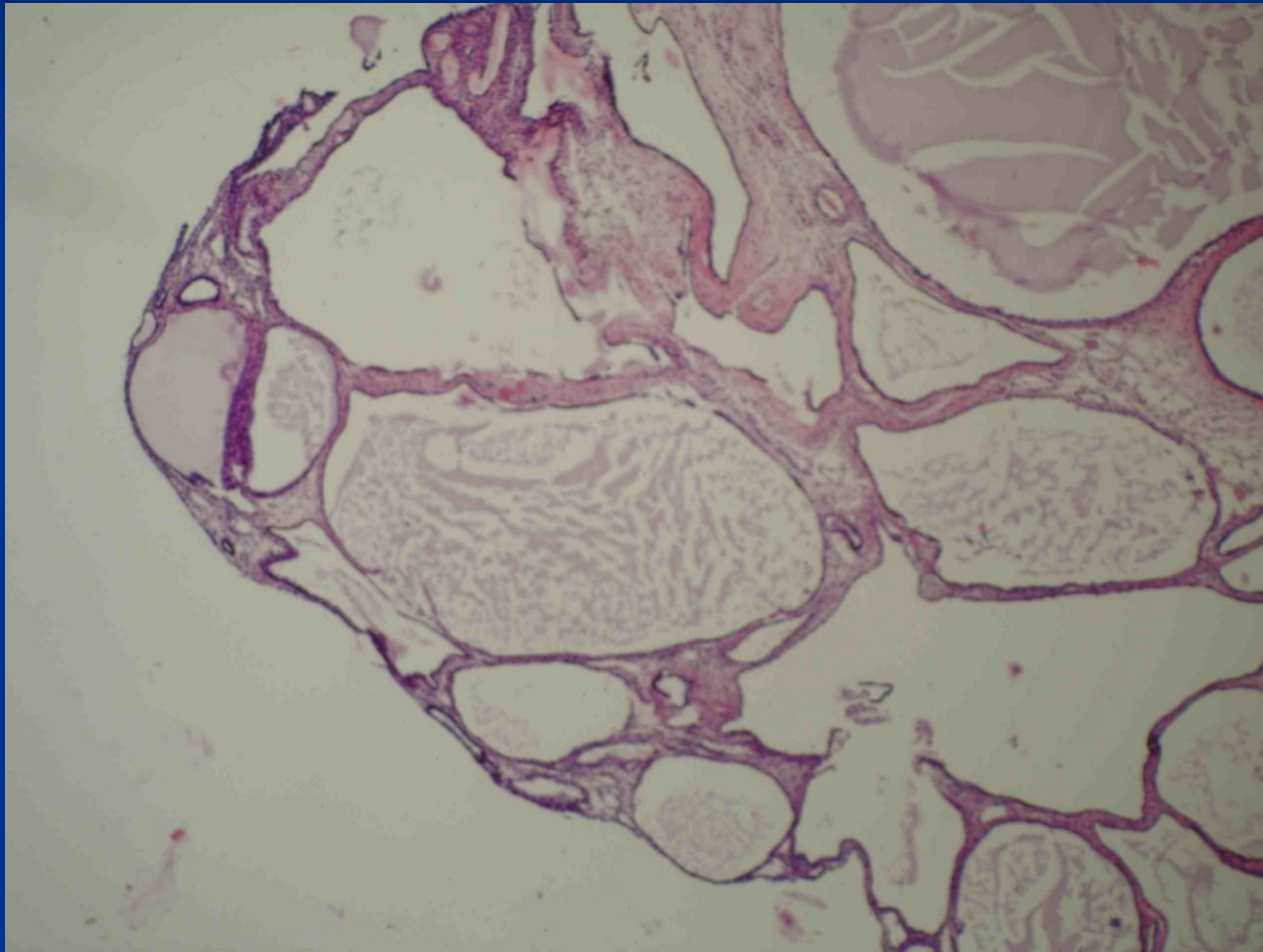
Endometrial polyp

- Possible iatrogenic origin (tamoxiphen)
- up to $\frac{1}{4}$ women during fertile life
- common in climacterium
- dysfunctional bleeding
- possible cause of infertility
- possible start/localisation of endometrial ca

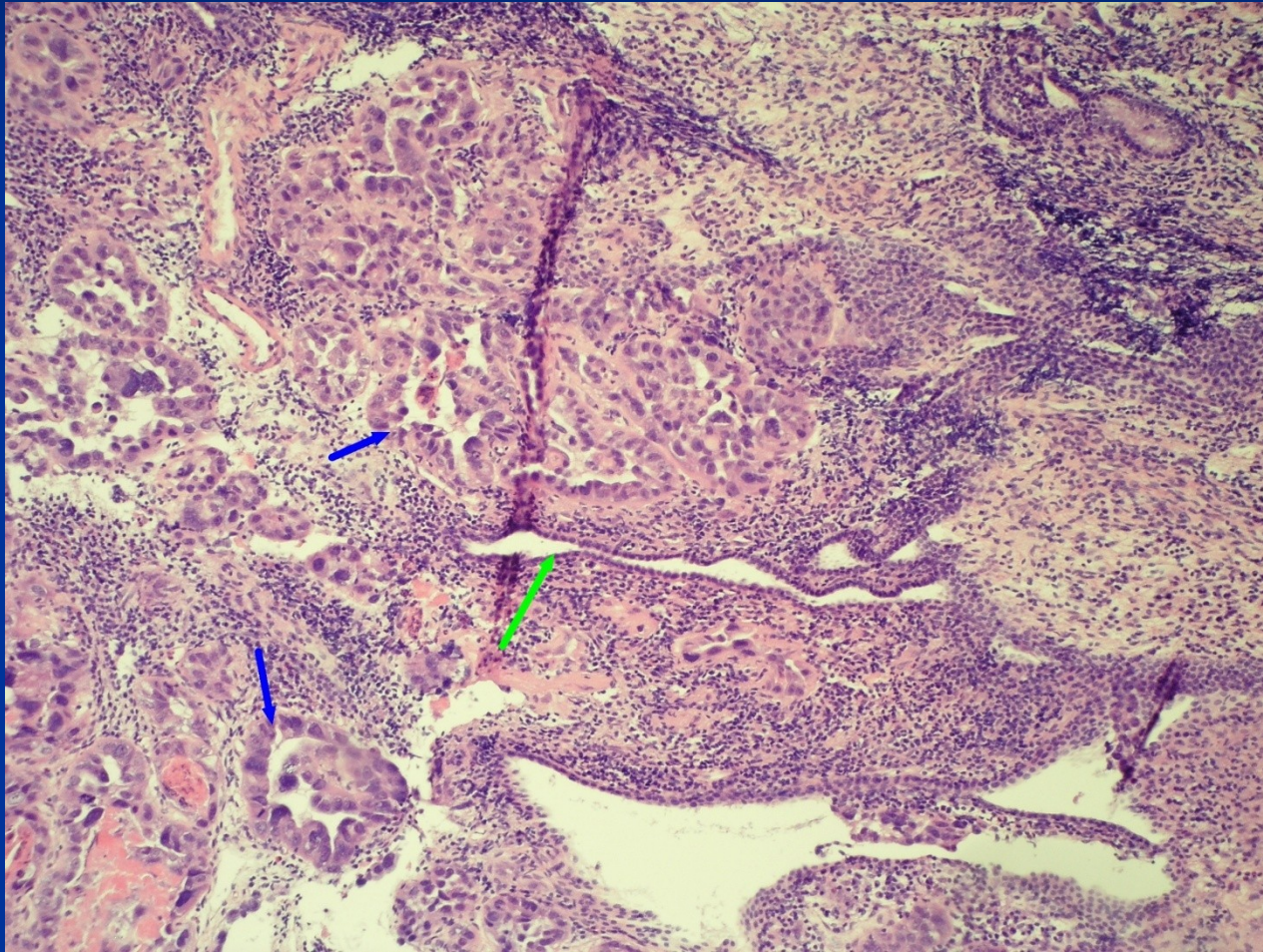
Endometrial polyp



Endometrial polyp

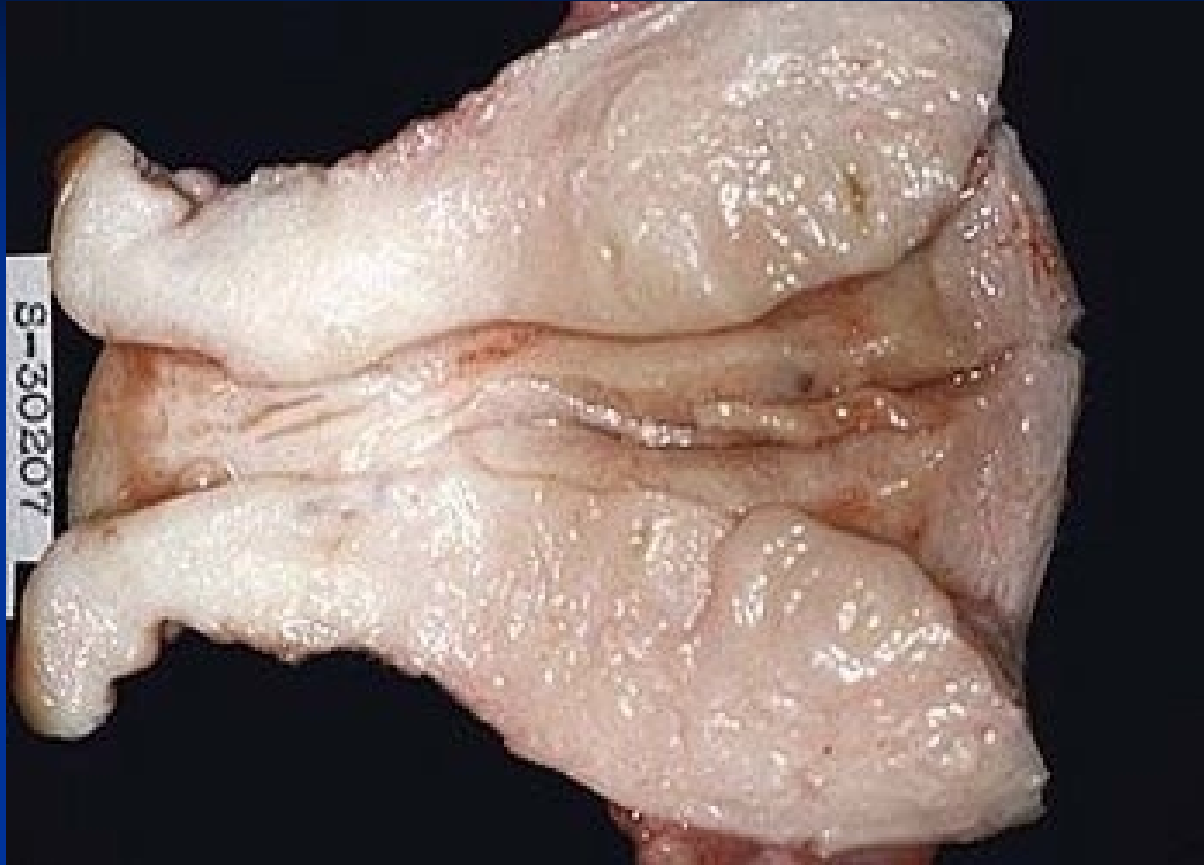


Endometrial ca in a polyp



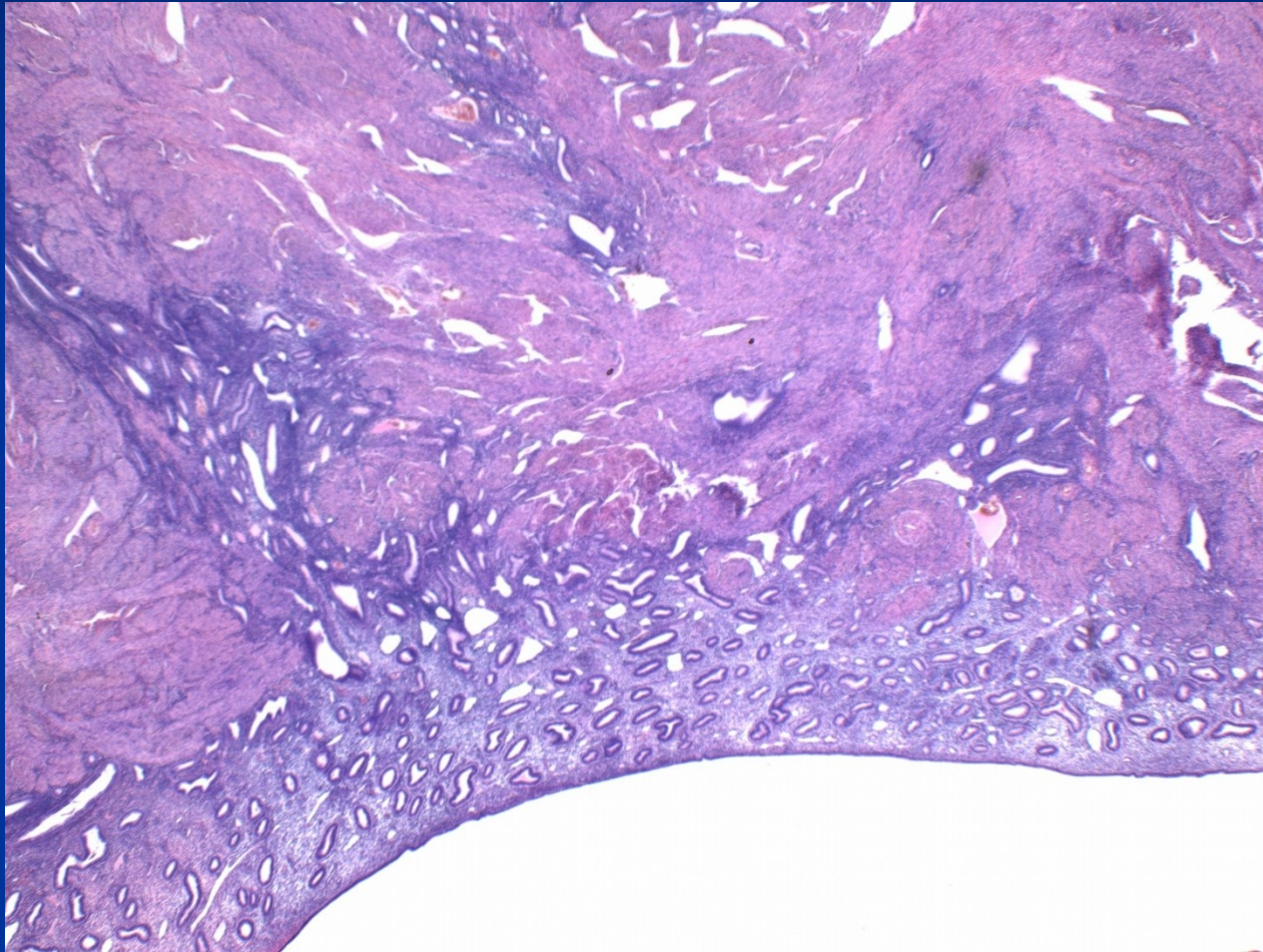
Adenomyosis

- irregular bleeding, dysmenorrhea, pelvicgia
- more common in perimenopause after repeated births („diverticulosis“)
- may predispose to uterine prolaps into vagina
- myometrial reaction incl. hyperplasia
- possible origo of endometrial tu in myometrium (! x ca invasion into myometrium)

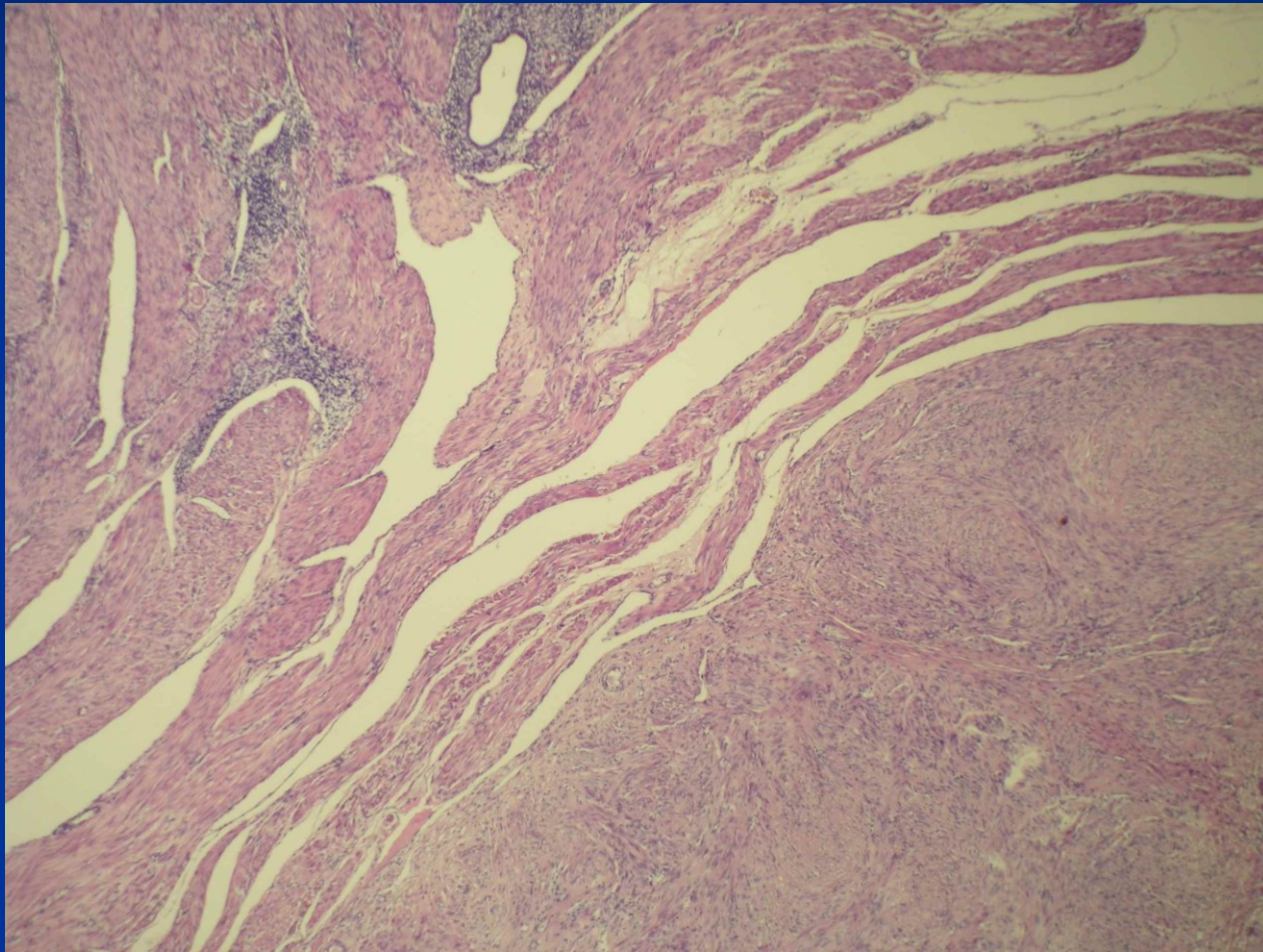


Adenomyosis

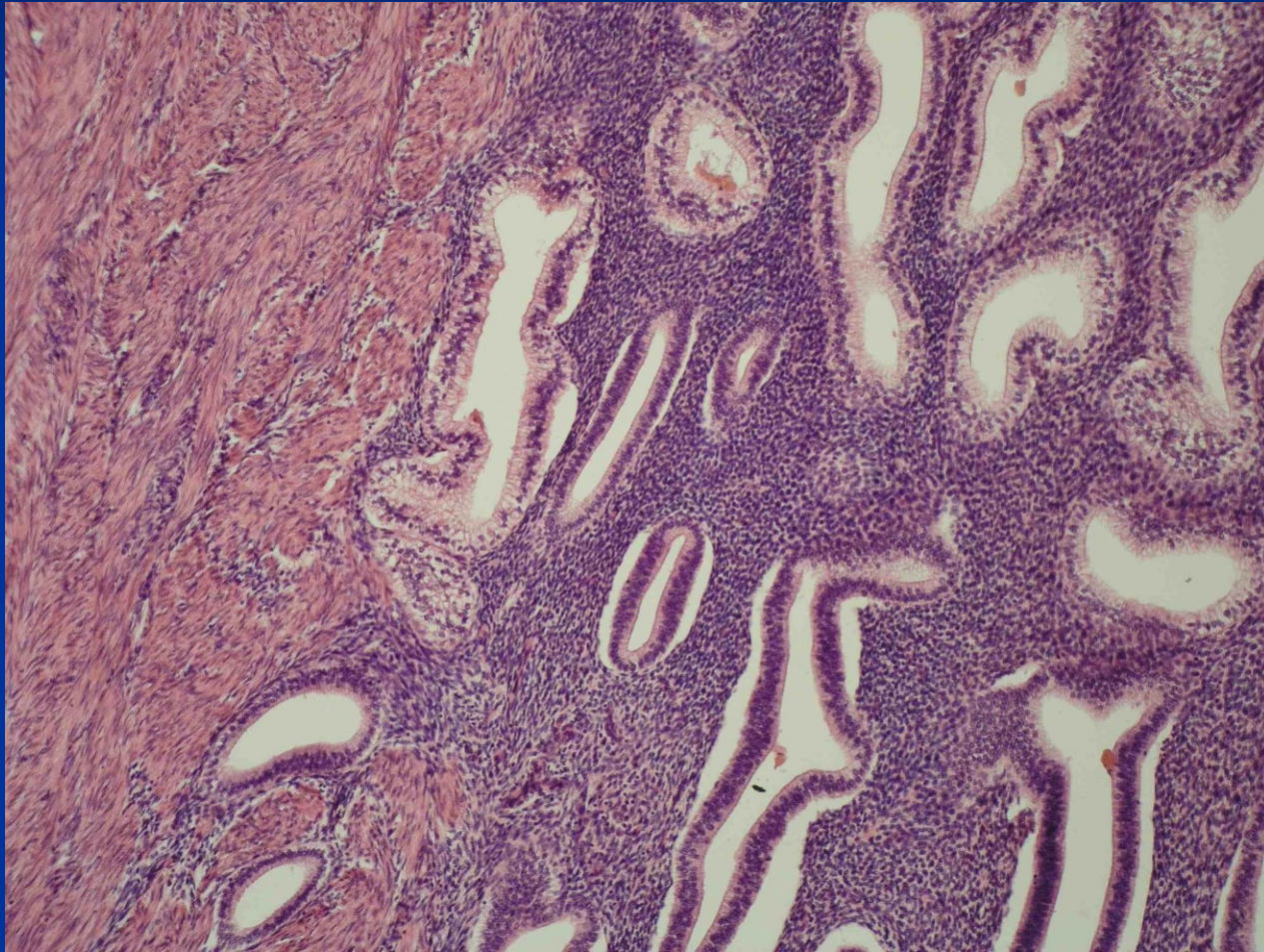
Adenomyosis



Adenomyosis + leiomyoma



Adenomyosis



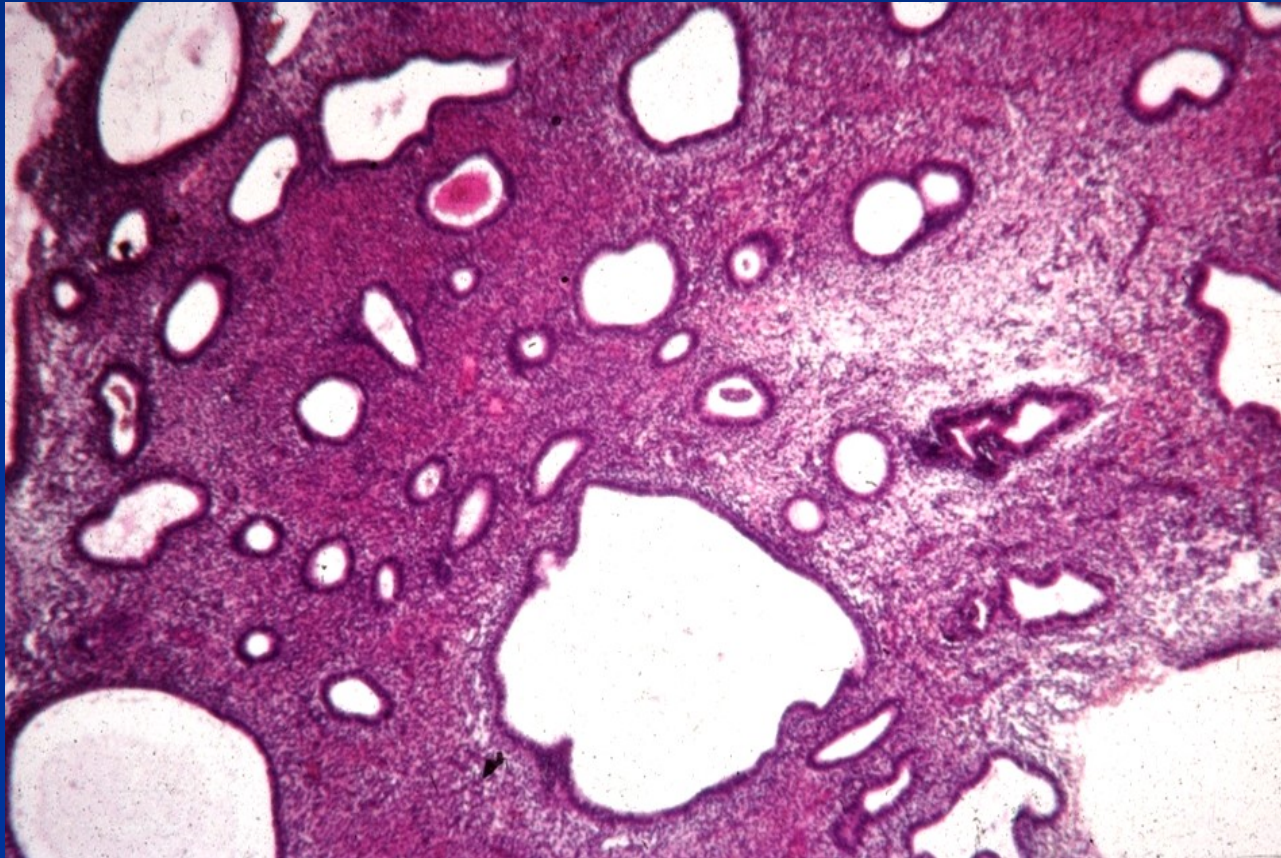
Hyperplasia, intraepithelial neoplasia

- Non-physiological non-invasive proliferation of endometrium, benign lesion (reactive) → premalignant condition (monoclonal)
- **Hormone dysbalance** - persistent estrog. stimulation without secretory transformation, incl. relative (progesterin insuff.). ~ endometr. ca type 1.
- **endogenous**: path. ovarian regulation, polycystic ovaries, hormon. active processes (tu), obesity with hyperestrinism etc.
- **exogenous**: hormon. therapy (pure estrogens)

Hyperplasia, intraepithelial neoplasia

- non-atypical - reactive
- presence of atypia - most important pathological sign – monoclonal – endometrioid **intraepithelial neoplasia**

Non-atypical hyperplasia

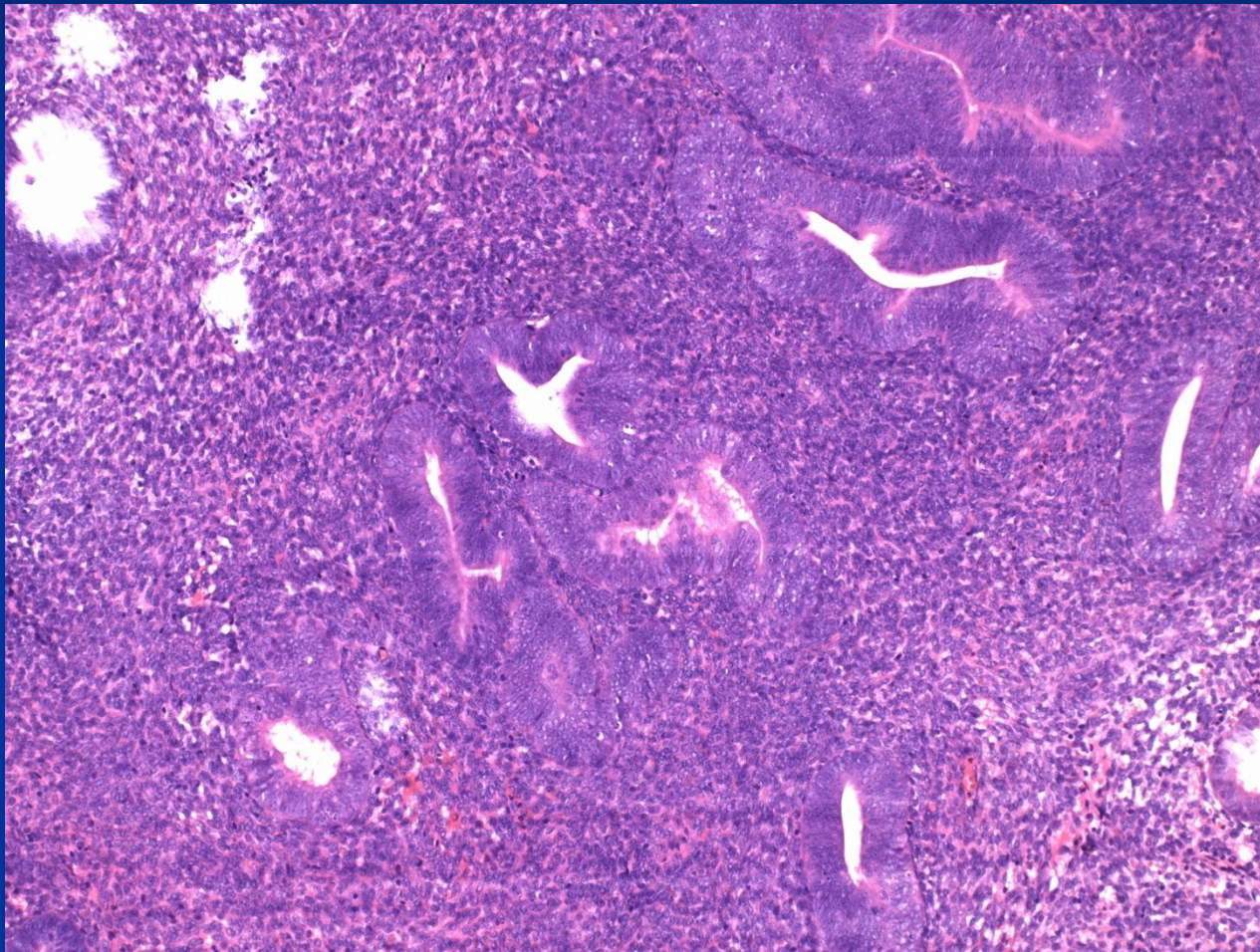


Endometrial intraepithelial neoplasia

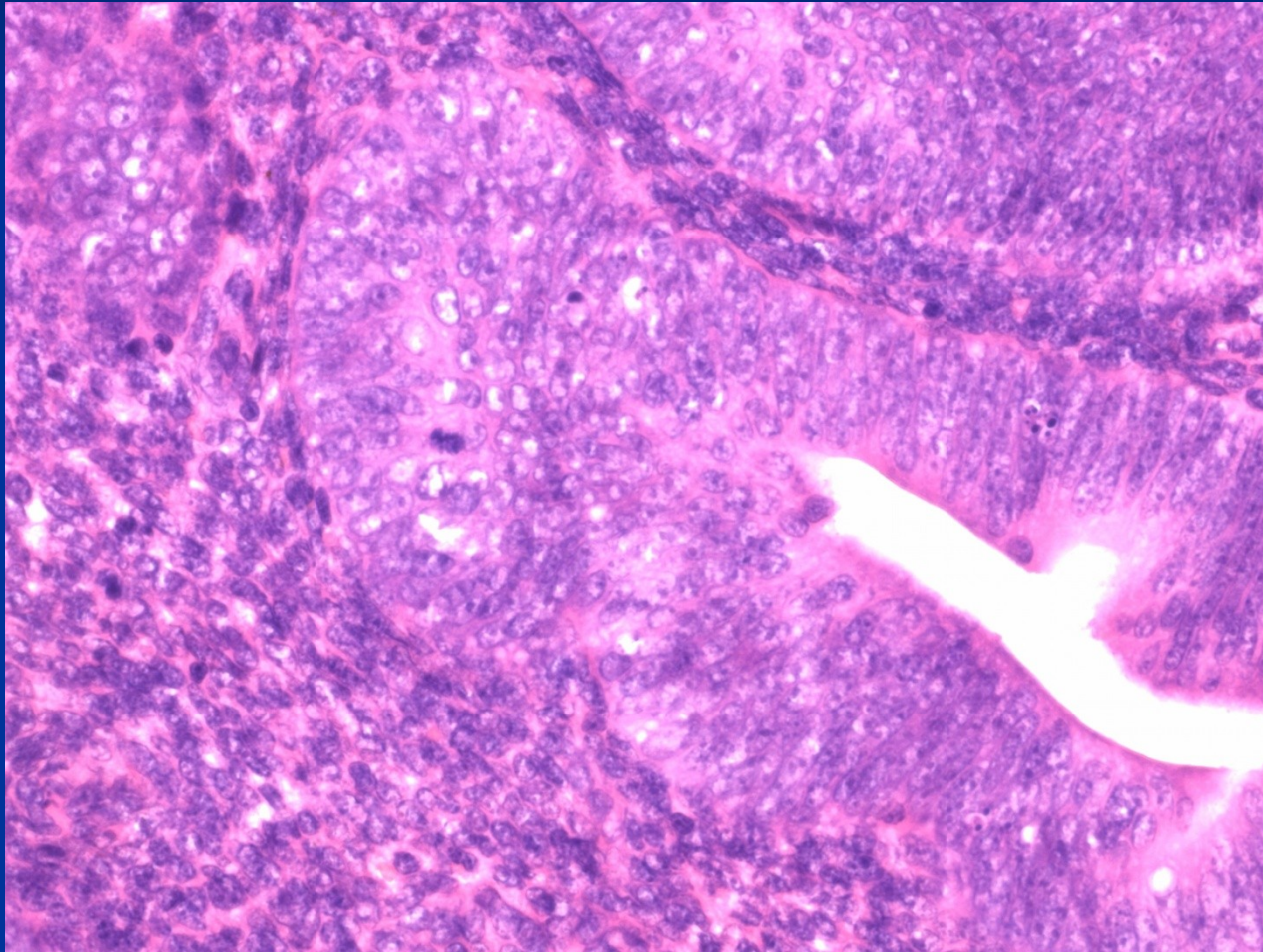
- **(EIN)** atypical hyperplasia > 1 mm, different from surrounding tissue
- $\frac{1}{4}$ - one third with EIN in biopsy have cancer in hysterectomy (immediately – 1 year)

intraglandular or superficial

Atypical hyperplasia/EIN



Atypical hyperplasia/EIN



Uterine corpus tumors – WHO

■ Epithelial tu and related lesions:

Endometrial carcinoma

- endometrioid incl. mucinous,
- serous,
- clear cell,
- other endometrial carcinoma, incl. squamous cell,
- metaplastic (carcinosarcoma = malignant mixed müllerian tumor
- others

Endometrioid carcinoma

- New classification (WHO 2020) – different genetic characteristics
 - 4 groups with different prognosis
 - problematic implementation into do praxis
 - in ideal case integration of microscopic picture and molecular characteristics (typical mutations, microsatellite instability, etc.)
 - *POLE*-ultramutated endometrioid ca, excellent prognosis
 - mismatch repair-deficient, intermediate risk
 - p53 mutated, bad prognosis
 - no specific molecular profile, intermediate risk

Precursor lesions, pseudotumors

Endometrial hyperplasia

- without hyperplasia
- Endometrial atypical hyperplasia / endometrial intraepithelial neoplasia

Endometrial polyps

Tamoxifen related lesions

Uterine corpus tumors – WHO

■ Mesenchymal tumors:

endometrial stromal lesions:

endom. stromal nodule (benign), low grade endom. stromal sarcoma, undifferentiated endom. stromal sarcoma

smooth muscle tumors: leiomyoma (+ variants), tu of uncertain malignant potential, leiomyosarcoma (+ variants)

tumors from perivascular epitheloid cells (PECom)

other mesenchymal tumors

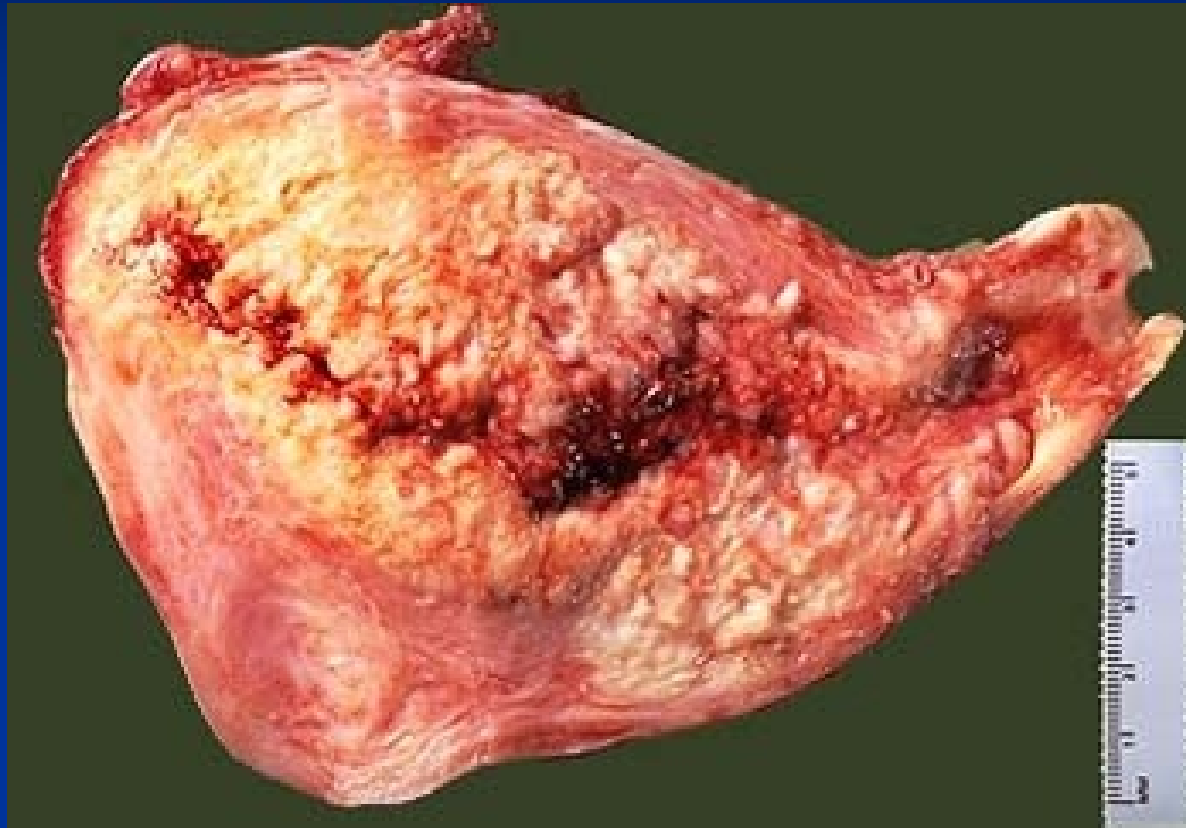
Uterine corpus tumors – WHO

- **Mixed epithelial and mesenchymal tumors:**
adenomyoma, adenosarcoma etc.
- **Gestational trophoblastic disease**
- **Other tumors: adenomatoid tumor (mesothelial), ...**
- **Secondary tumors**

Endometrial carcinoma

- **Signs:** abnormal bleeding – menometroragia in pre- and perimenopause, metrorrhagia in postmenopause;
uncommonly accidental finding
rarely - generalisation
- **Gross:** exophytic, ulcerated, whitish

Endometrial carcinoma

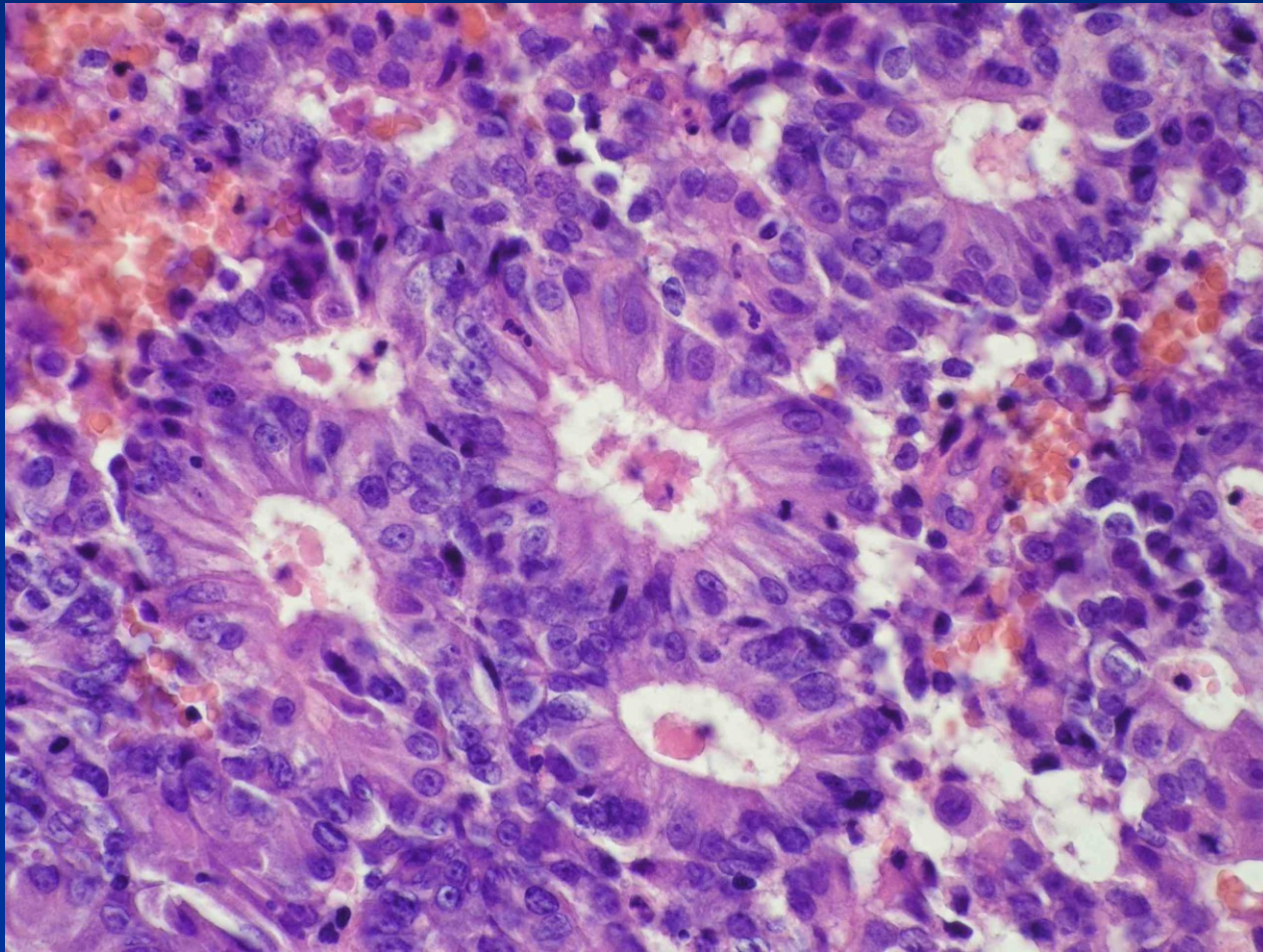


Endometrial carcinoma

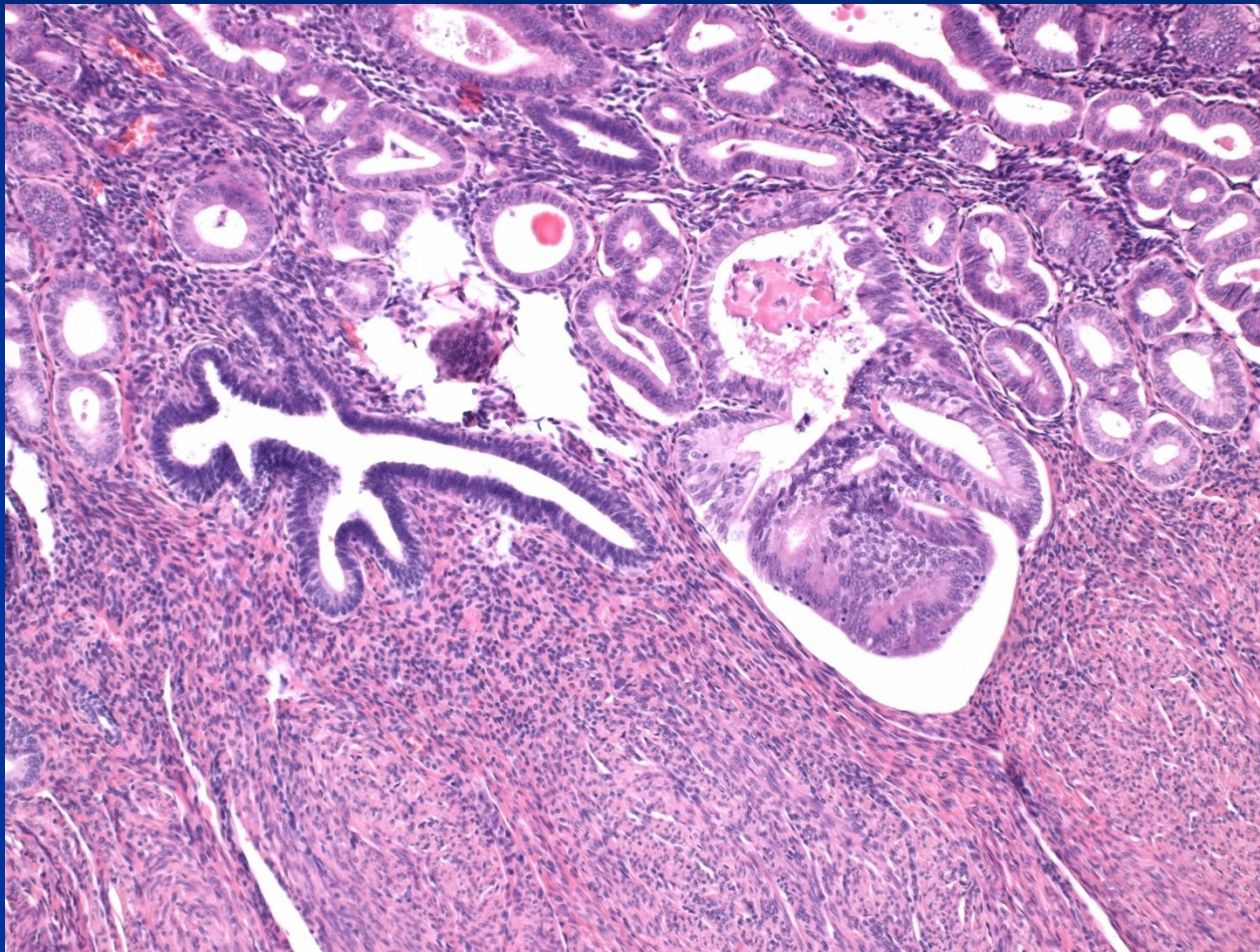
- **type 1** – cca 80%, estrogen-dependent, commonly in complex atyp. hyperplasia, **endometrioid type**, low grade, 55-65 yrs, better prognosis

risk factors – ↑ **estrogenous stimulation** (obesity, diabetes, hypertension, infertility incl. nulliparity, long fertile age, horm. active tu, horm. substitution)

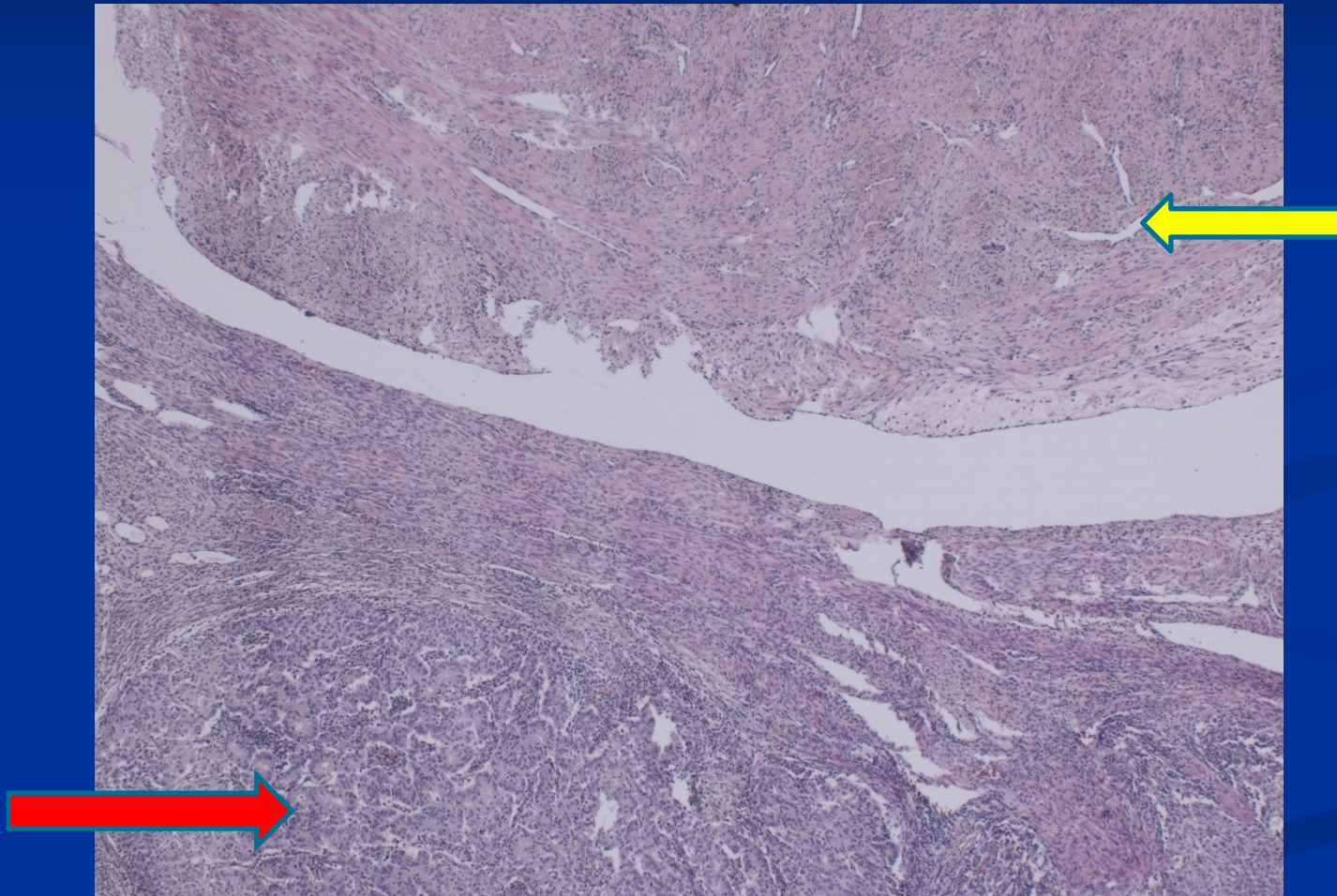
Endometrial endometrioid carcinoma



Endometrioid ca in adenomyosis



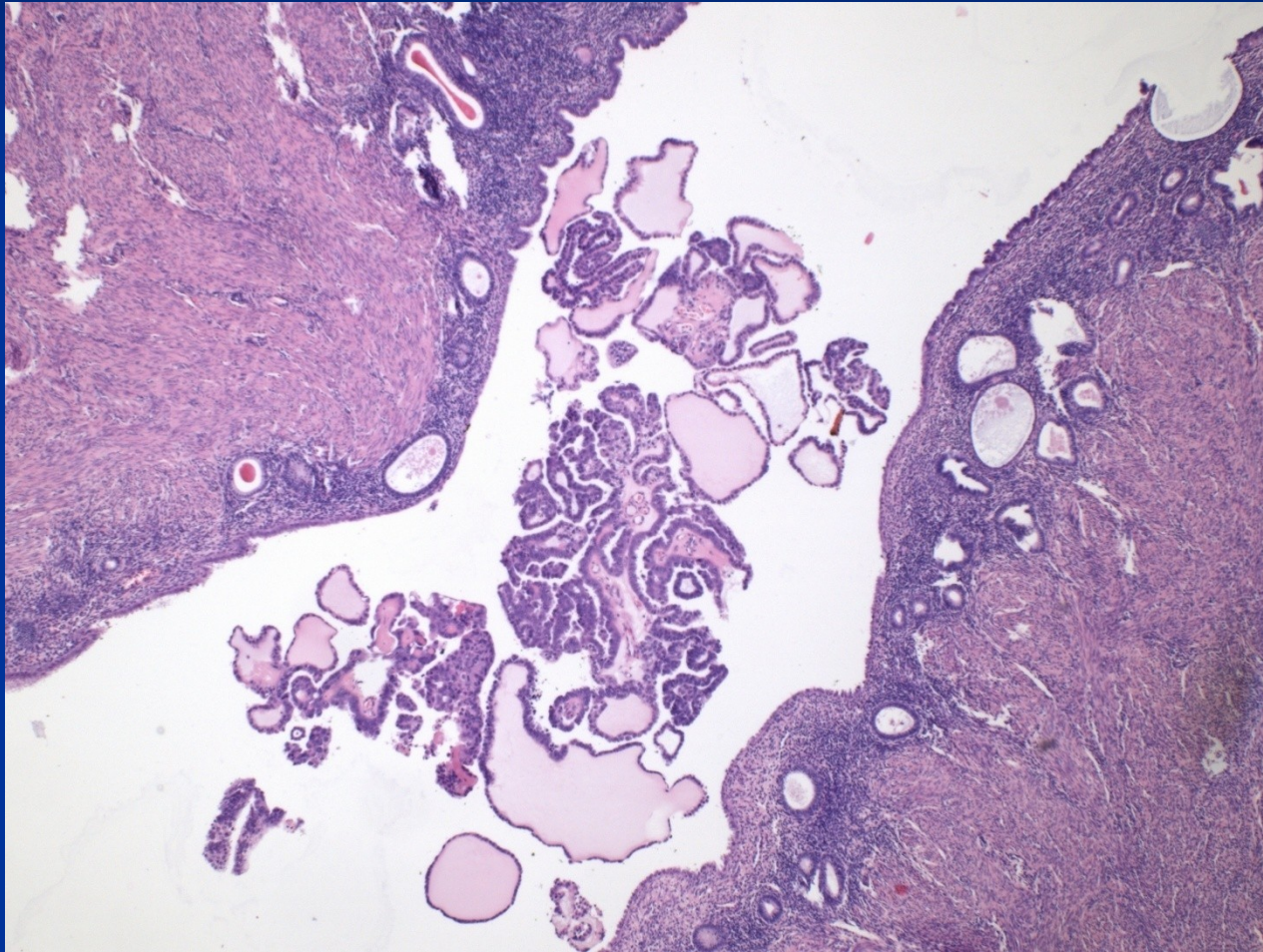
Endometrioid ca + leiomyoma



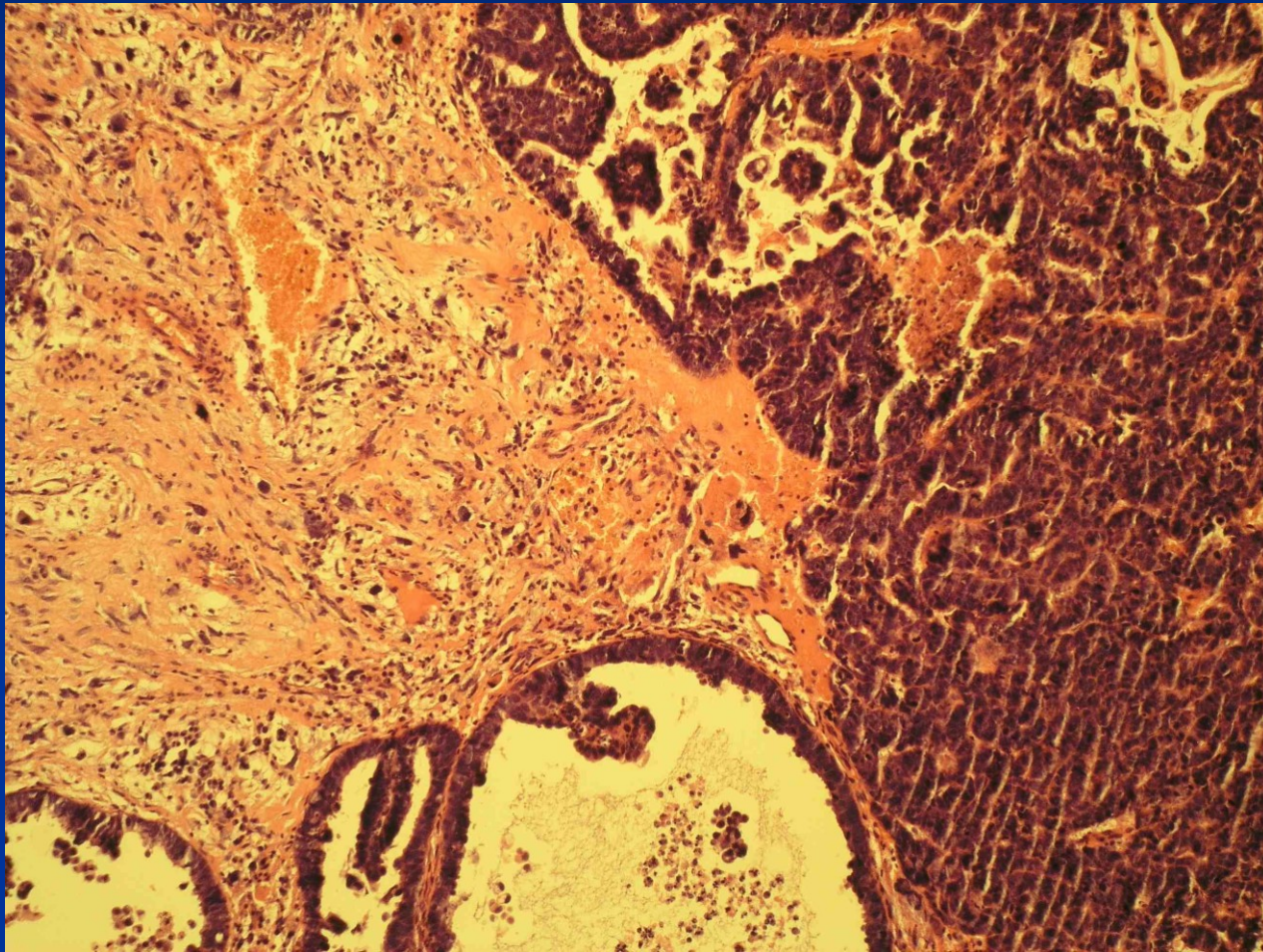
Endometrial carcinoma

- **type 2** – cca 15-20%, not directly connected with permanent oestrogenous stimulation, in later postmenopause, precursor: serous intraepithelial carcinoma, **serous and clear-cell types**, high grade, p53 mutation, aggressive, worse prognosis
- **Staging general** – according invasion into the uterine wall, cervix, surrounding structures

Serous adenocarcinoma



Metaplastic carcinoma



Mesenchymal tumors

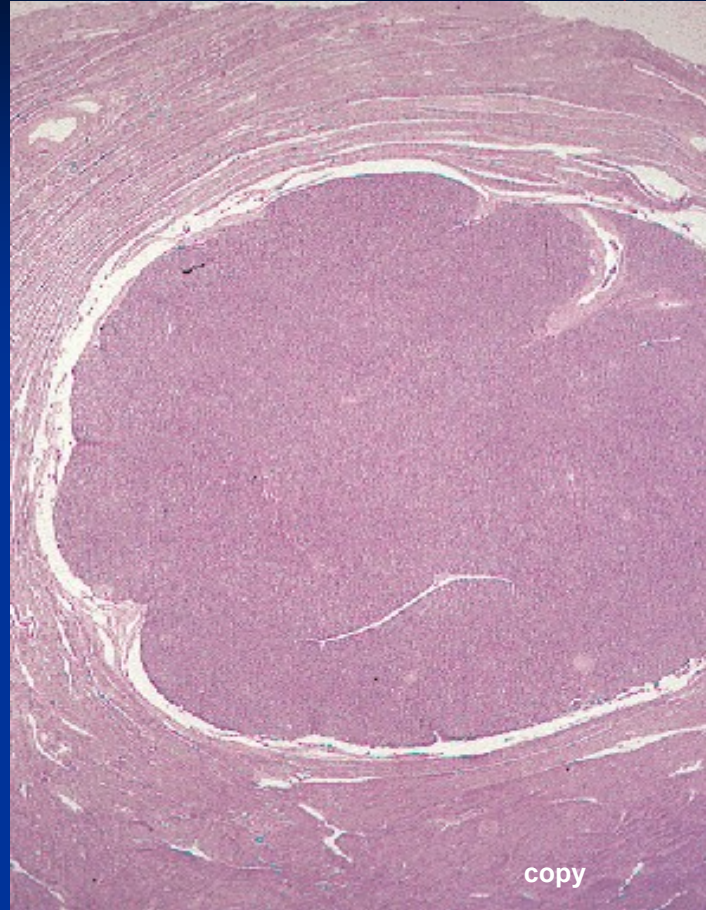
endometrial stromal lesions: cells similar to stroma in prolif. endometrium

endom. stromal nodule: demarcated, benign

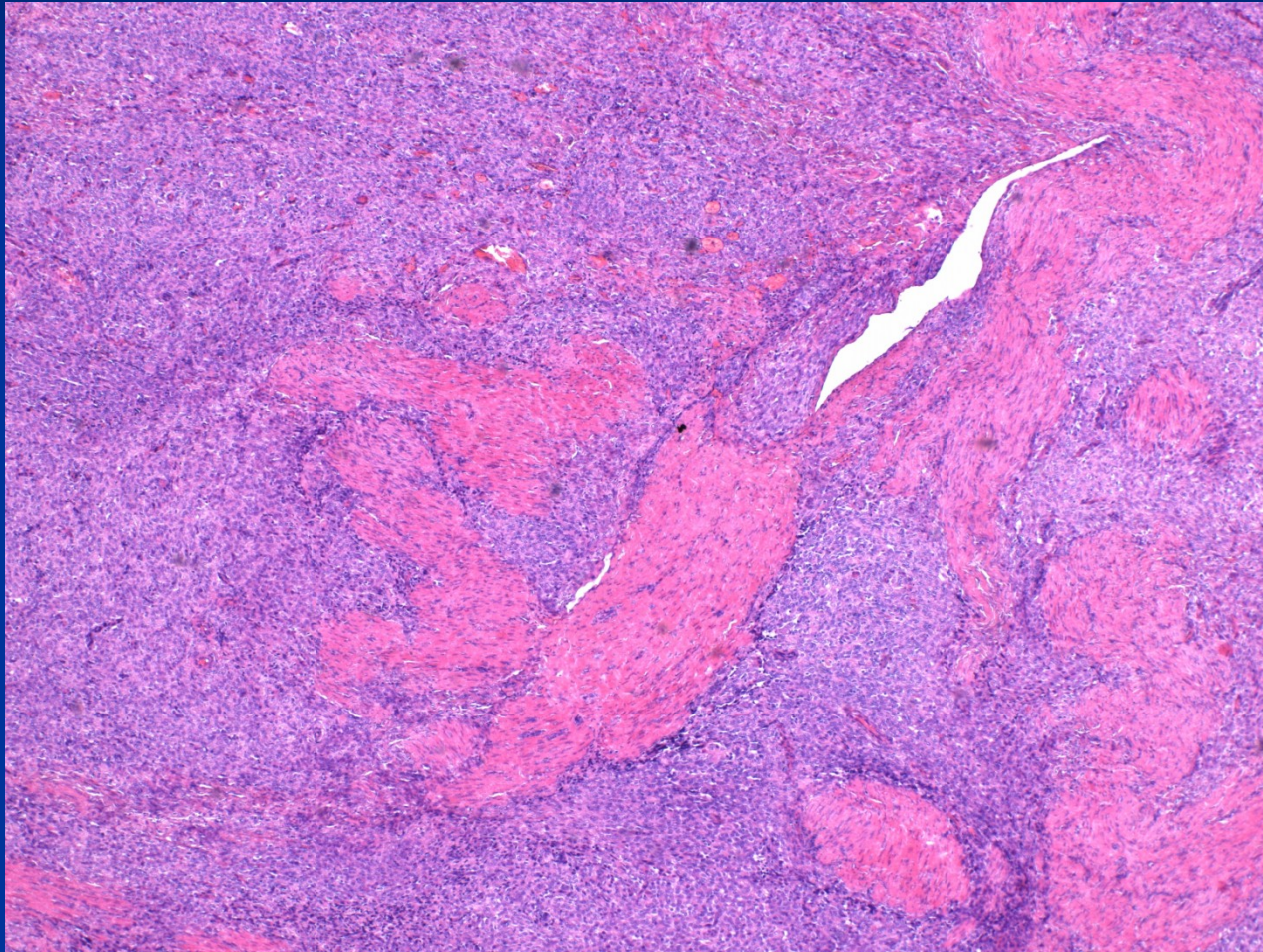
low grade endom. stromal sarcoma (LG ESS): well differ., invasion into surrounding myometrium and vessels, slow growth, usually good prognosis

undifferentiated endom. stromal sarcoma (HG ESS): aggressive with dissemination, highly atypical cells, high MI

Stromal nodule



LG ESS



Leiomyoma

- enlarging focus in pelvic region
- pain, irregular bleeding
- possible infertility
- pressure on surrounding organs (ureters, bladder)
- in pregnancy ↑ risk of abortion, possible barrier of normal delivery

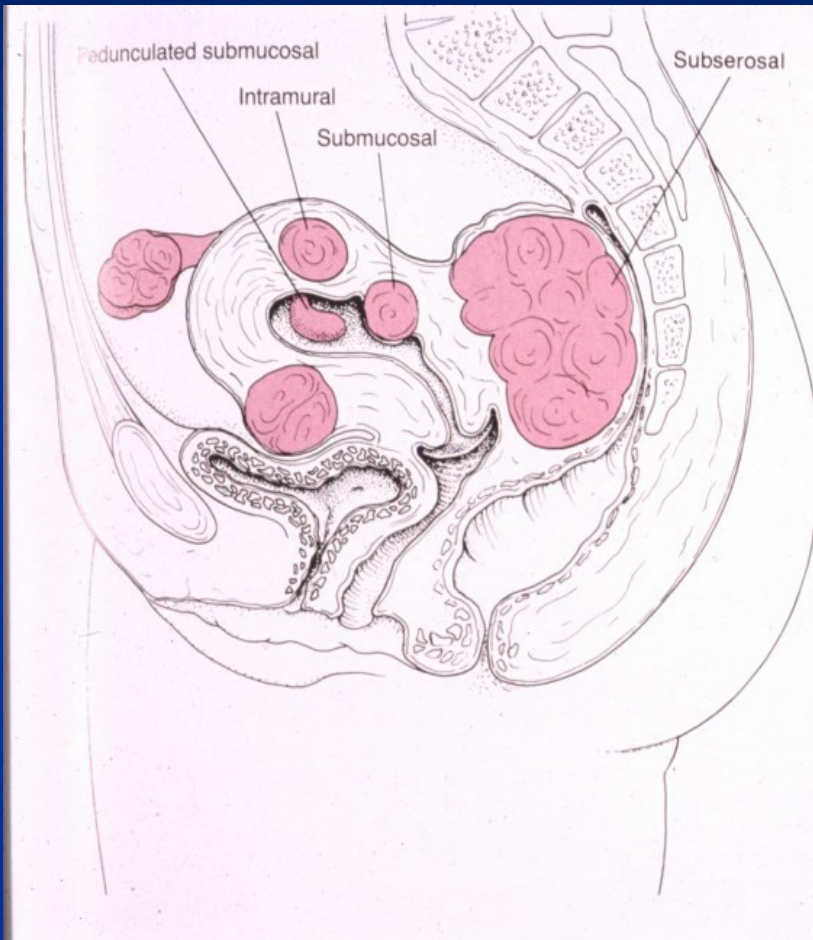
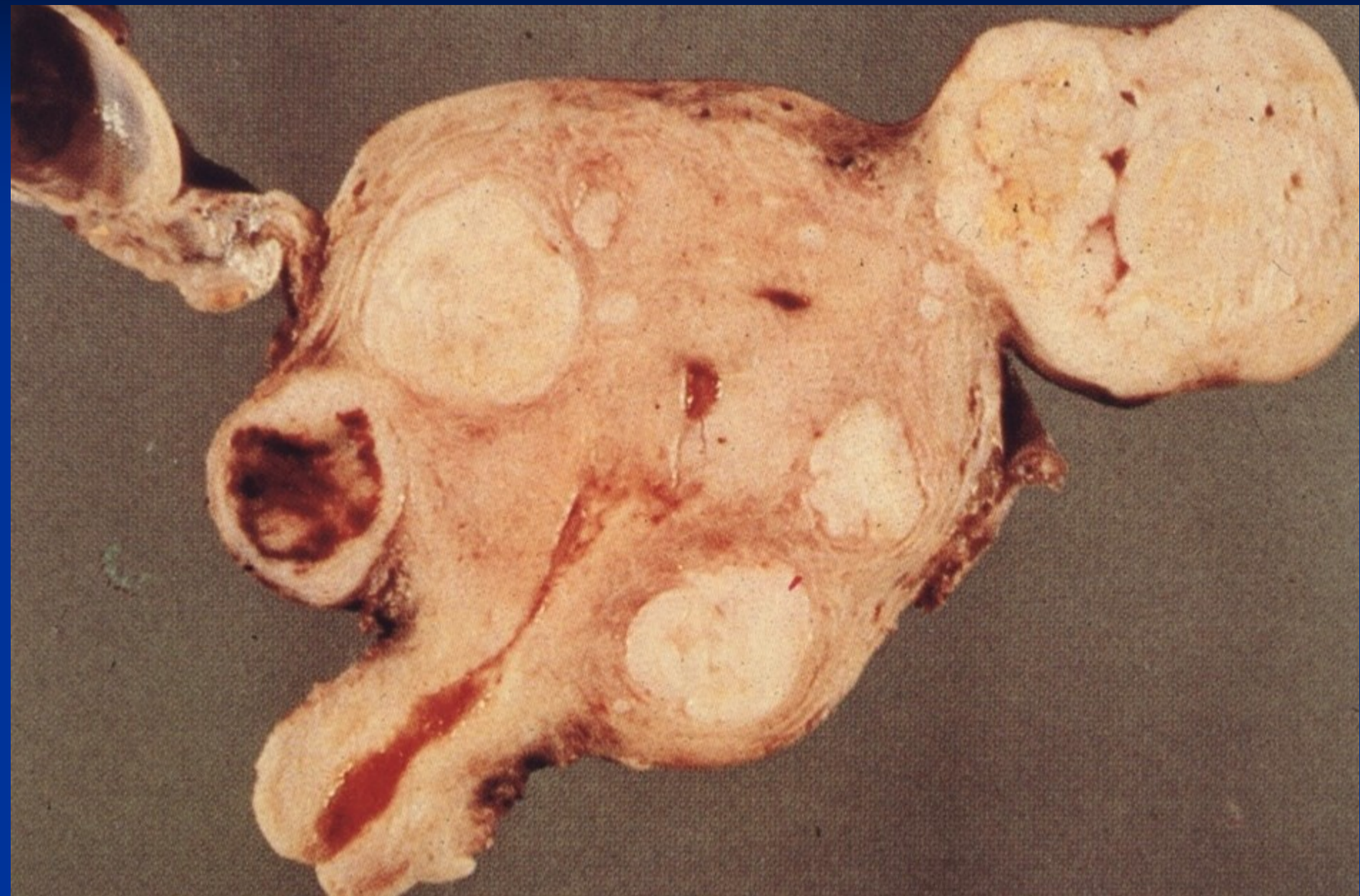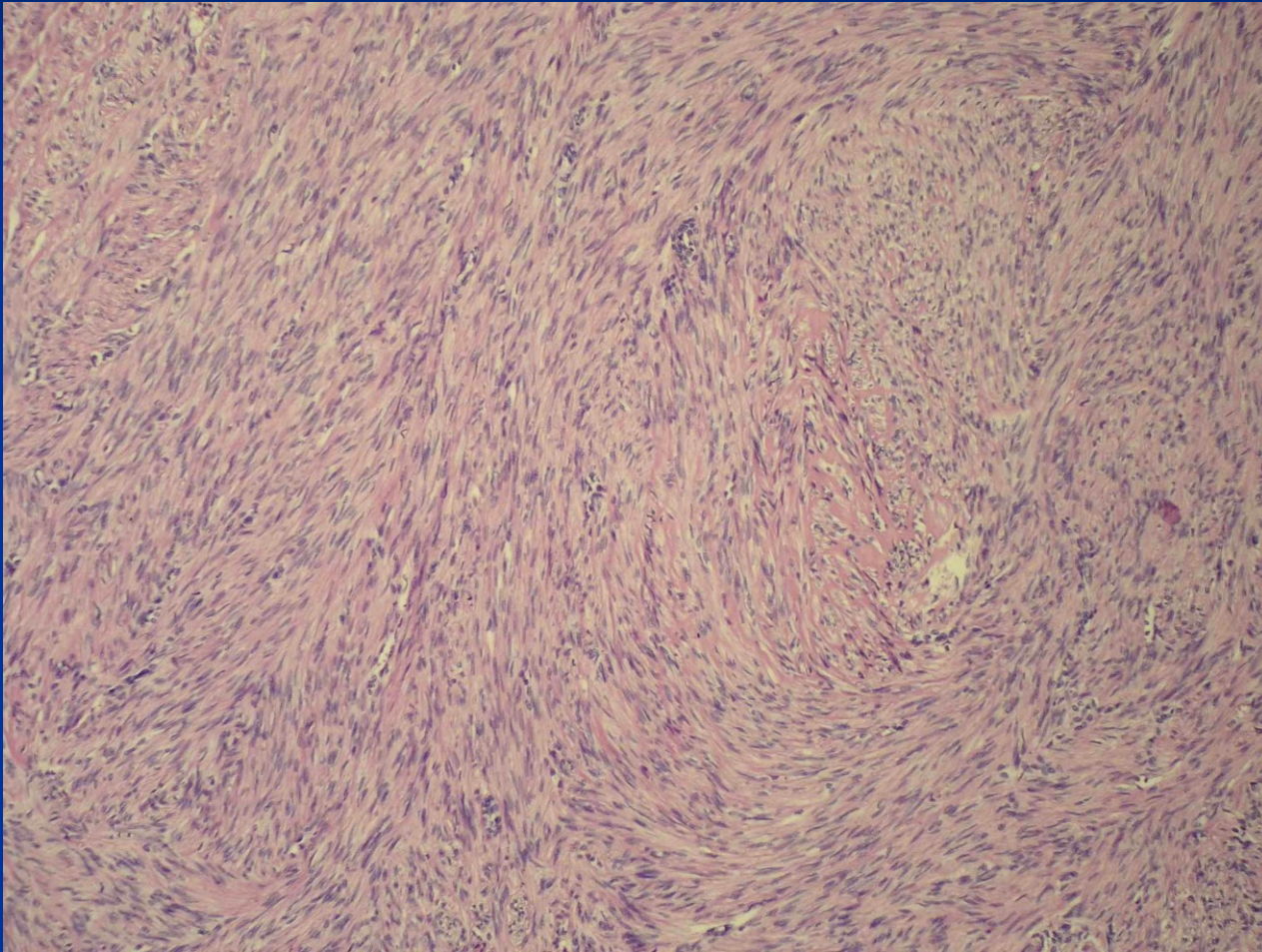


FIGURE 18-36
Leiomyomas of the uterus. The leiomyomas are intramural; submucosal, with a pedunculated one appearing in the form of an endometrial polyp; subserosal, with one compressing the bladder and the other the rectum.

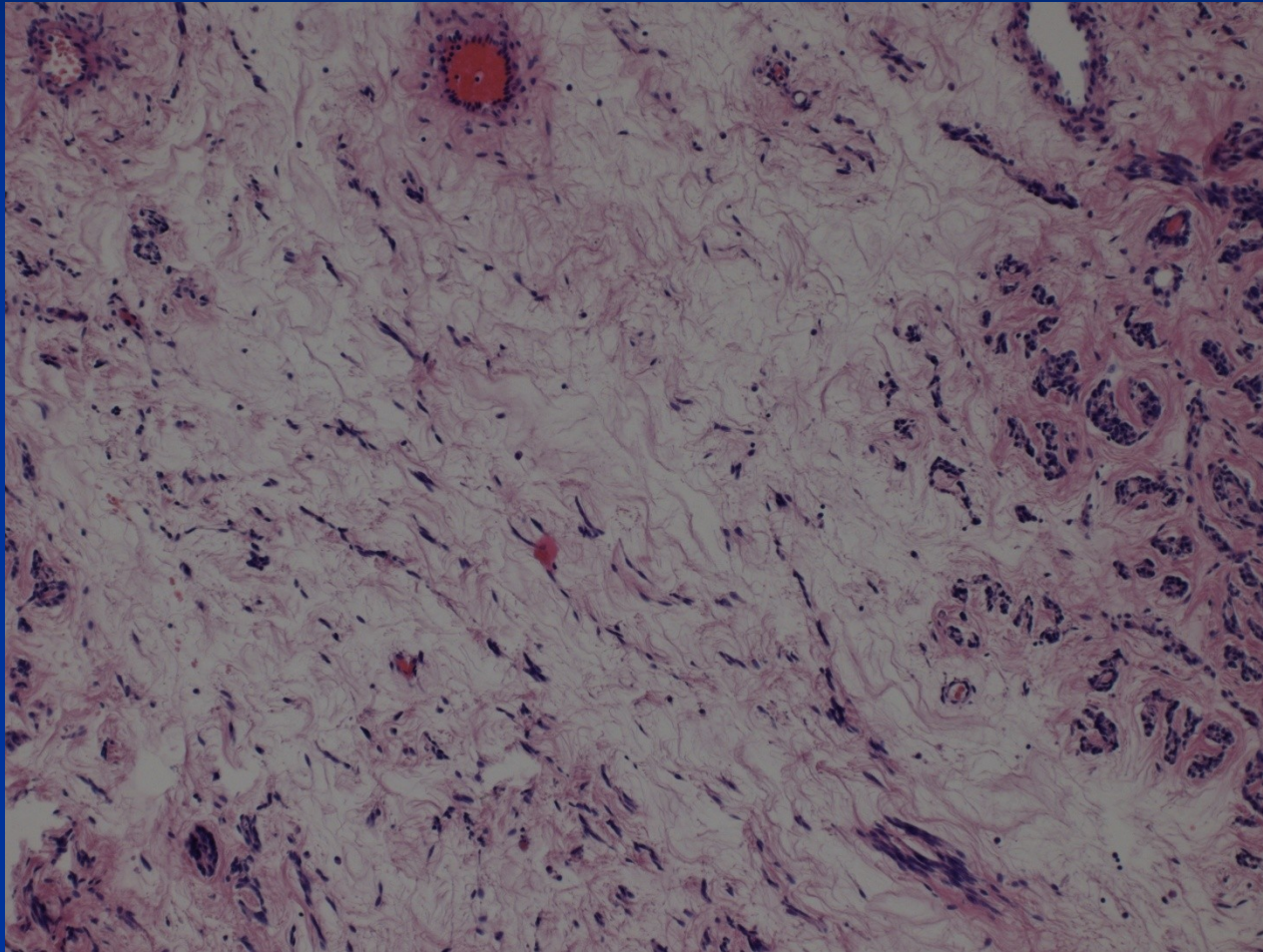
Leiomyomas



Leiomyoma

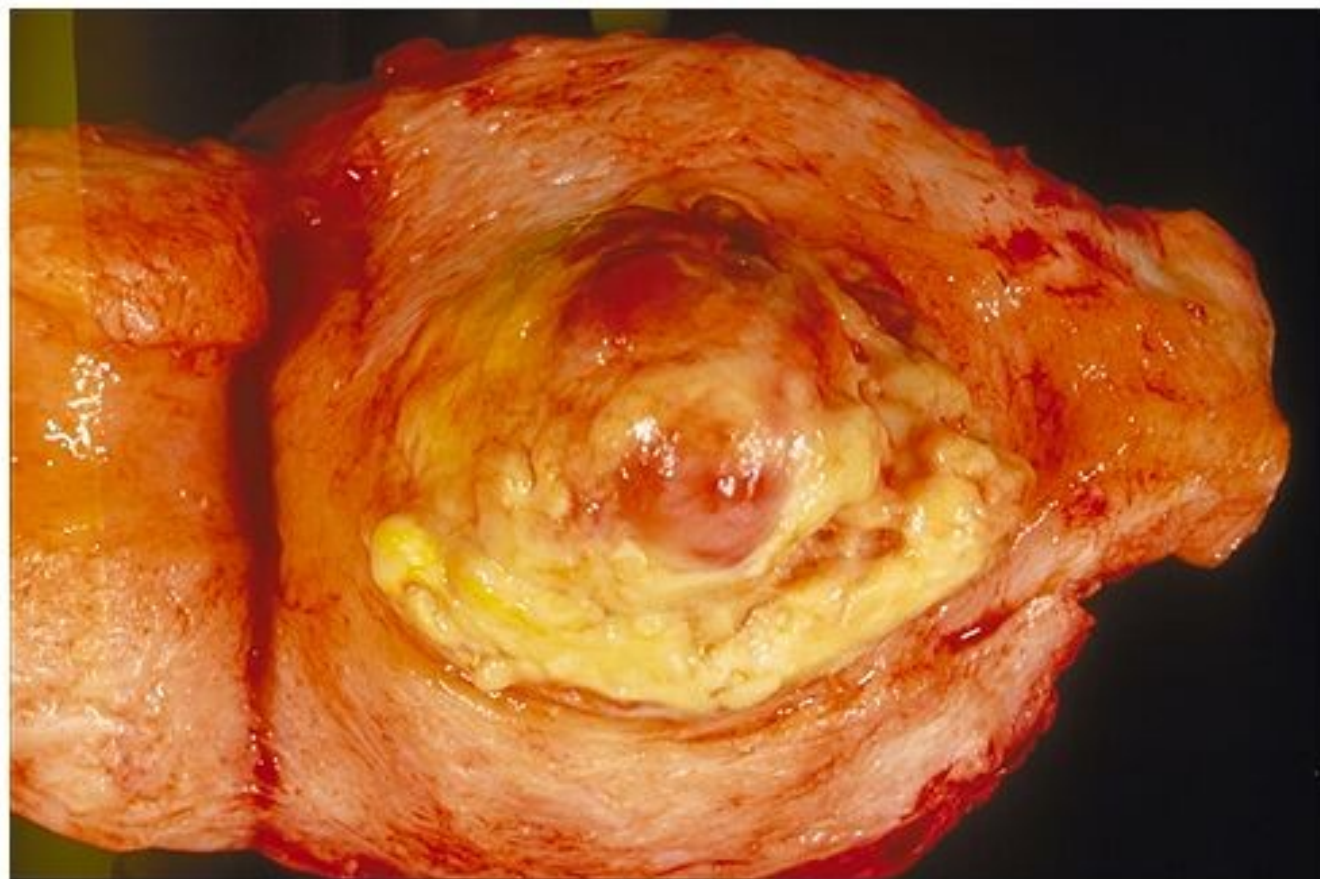


Leiomyoma – regressive changes



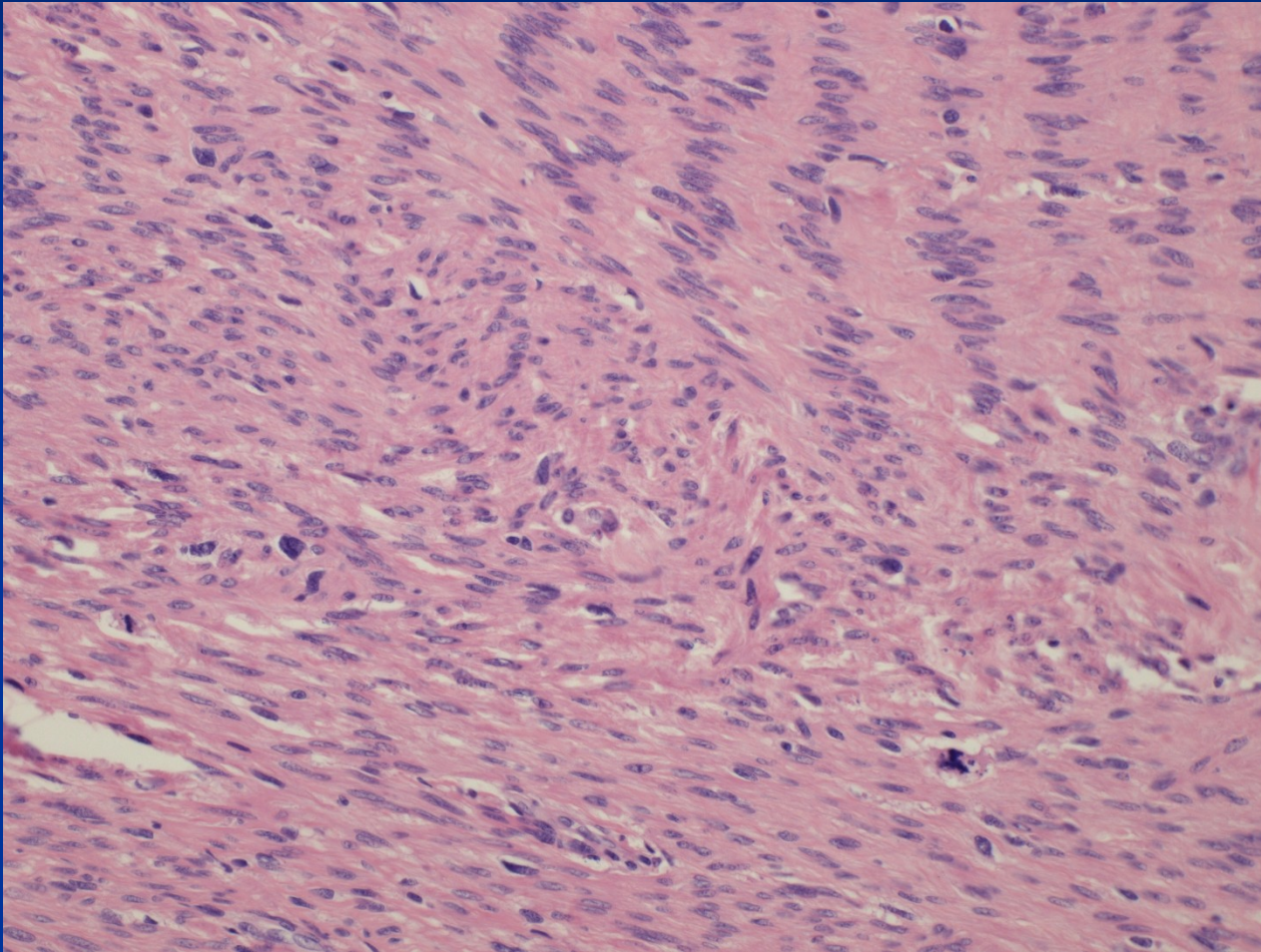
Leiomyosarcoma

- rare, de novo from myometrium
- mostly in age of 40-60
- recurrence common, haematogenous meta (lungs, bones, brain), abdominal dissemination
- solitary, rose-grey, soft, haemorrhagia, necrosis
- micro – variable differentiation

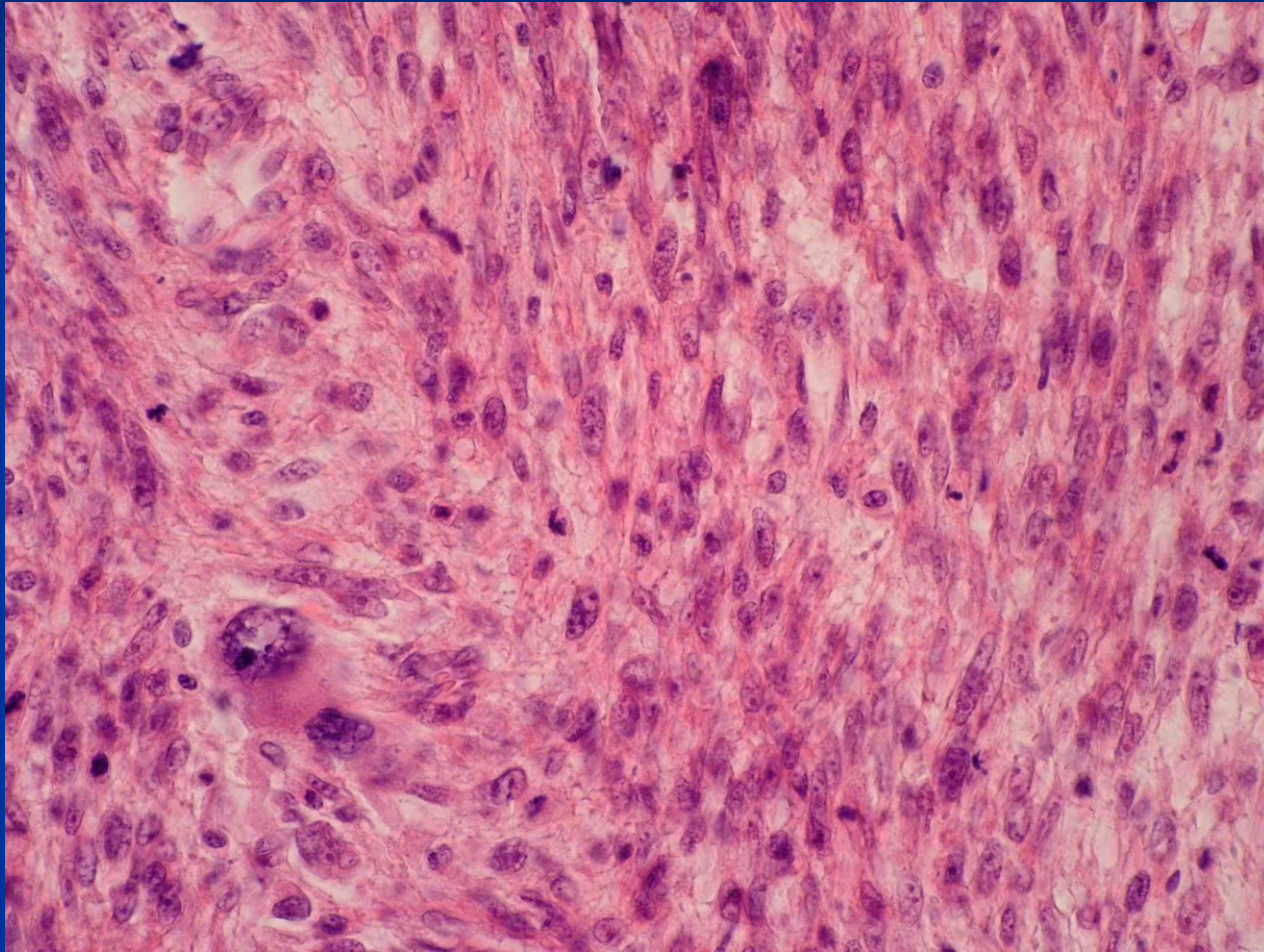


Copyright © 2002, Elsevier Science (USA). All rights reserved.

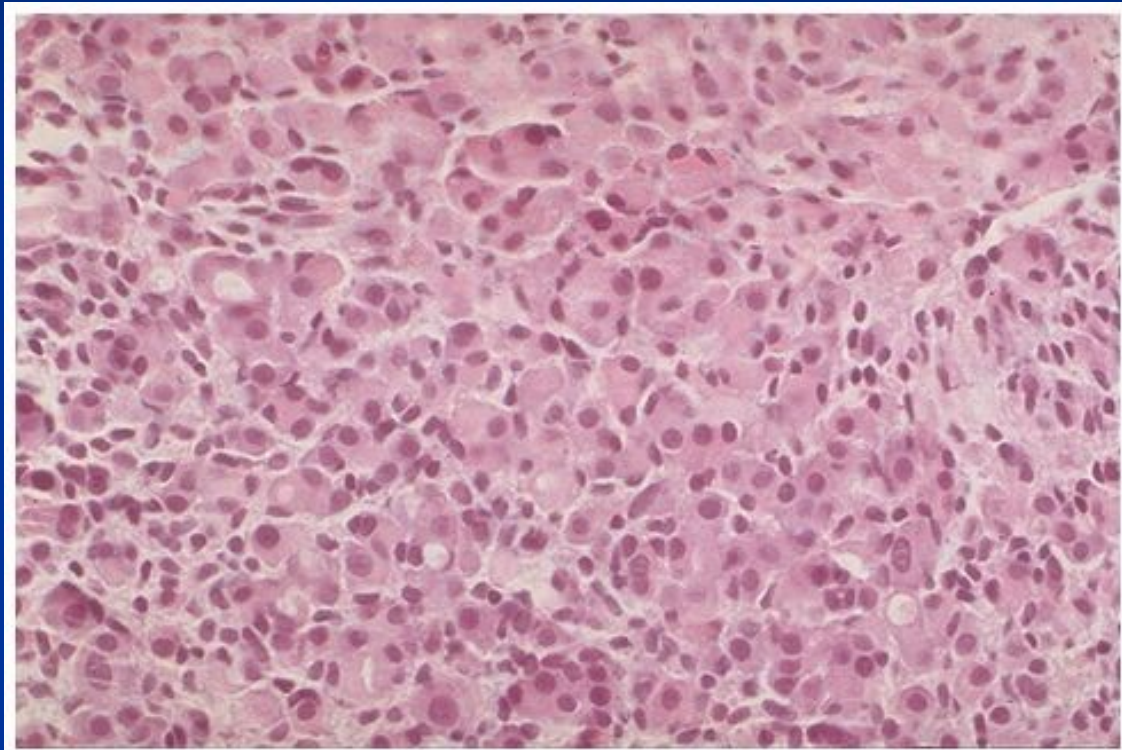
Leiomyosarcoma



Leiomyosarcoma



Breast ca metastasis

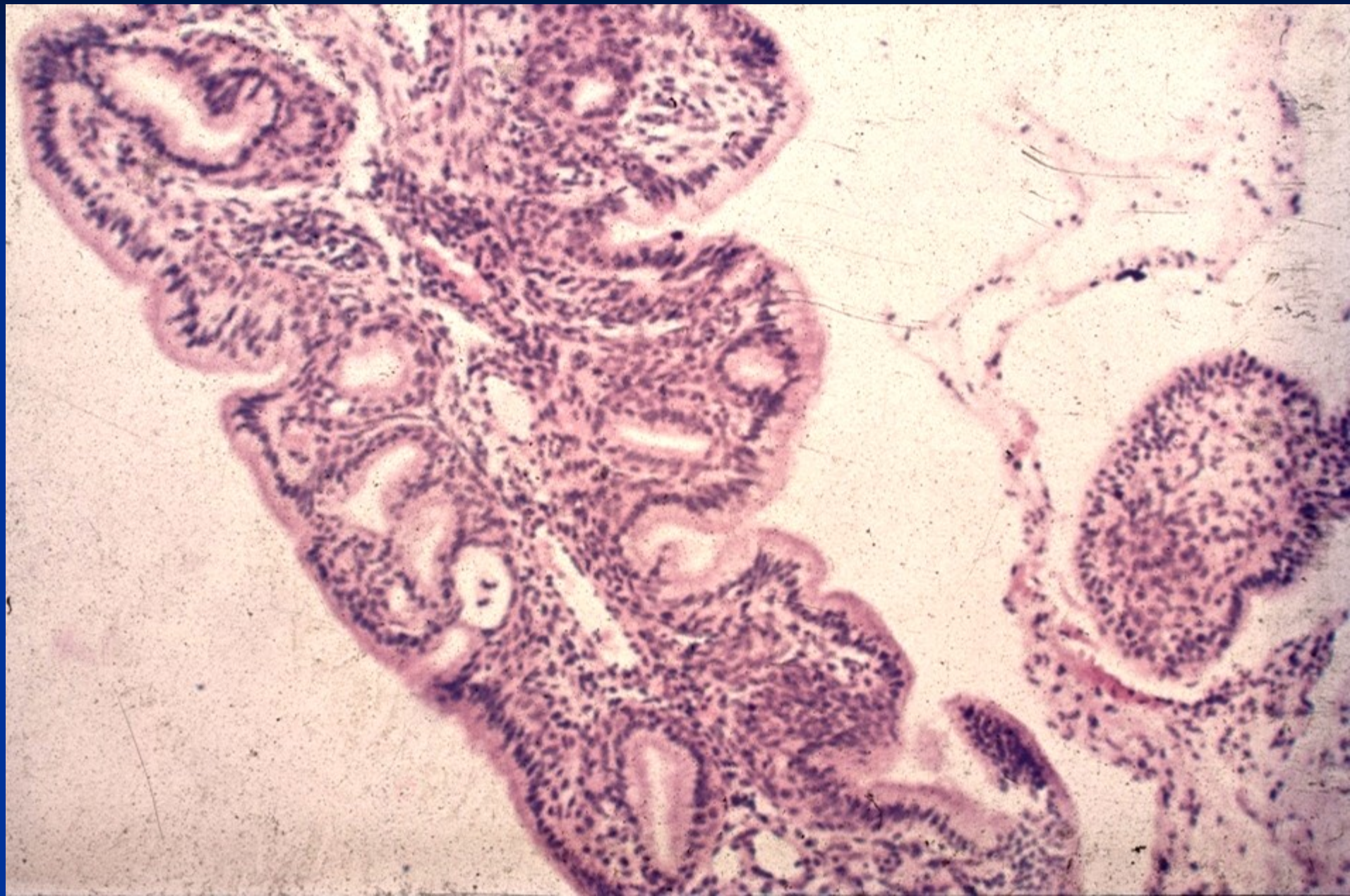


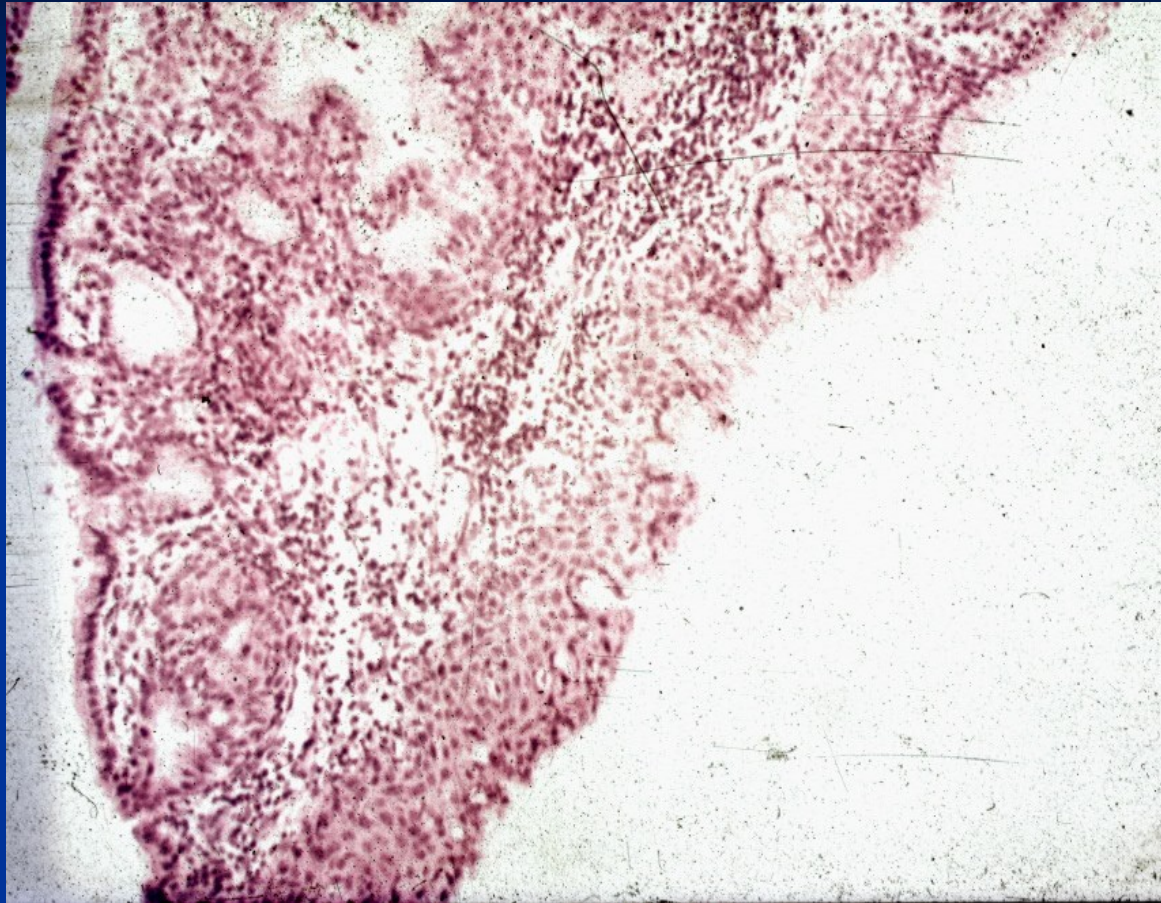
Copyright © 2002, Elsevier Science (USA). All rights reserved.

Pathology of the cervix

- cervicitis
- polyps
- physiological epithelial changes – metaplasia,
- precursor lesions:
 - squamous intraepithelial lesion (low grade, high grade – LSIL, HSIL = dysplasia /cervical intraepithelial neoplasia(CIN)
 - HPV-associated
 - HPV-independent
 - glandular: adenocarcinoma in situ
- carcinoma (invasive epithelial tumor)
- other tumors

Endocervical polyp





Endocervical polyp with squamous metaplasia

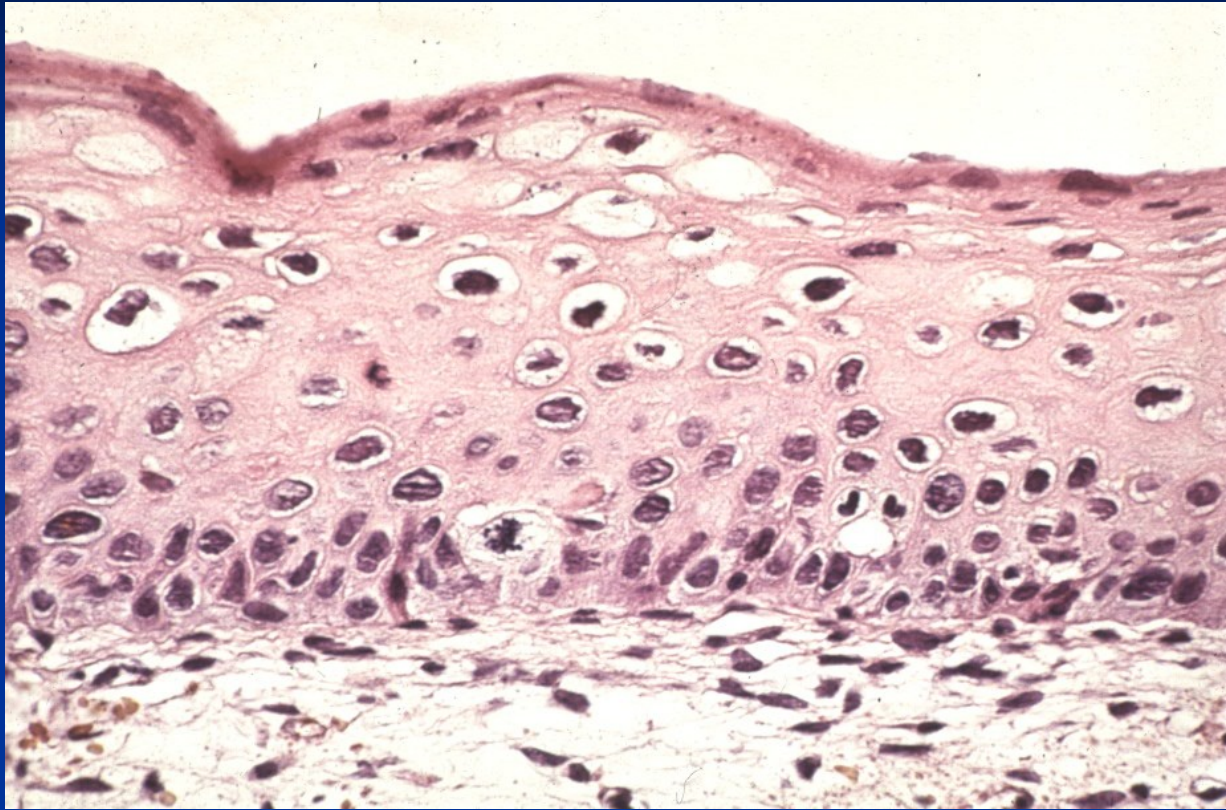
Cervical intraepithelial neoplasia

- flat HPV condyloma (without dysplasia)
- mild dysplasia (CIN I)
- moderate dysplasia (CIN II)
- severe dysplasia (CIN IIIa)
- carcinoma in situ (CIS, CIN IIIb)

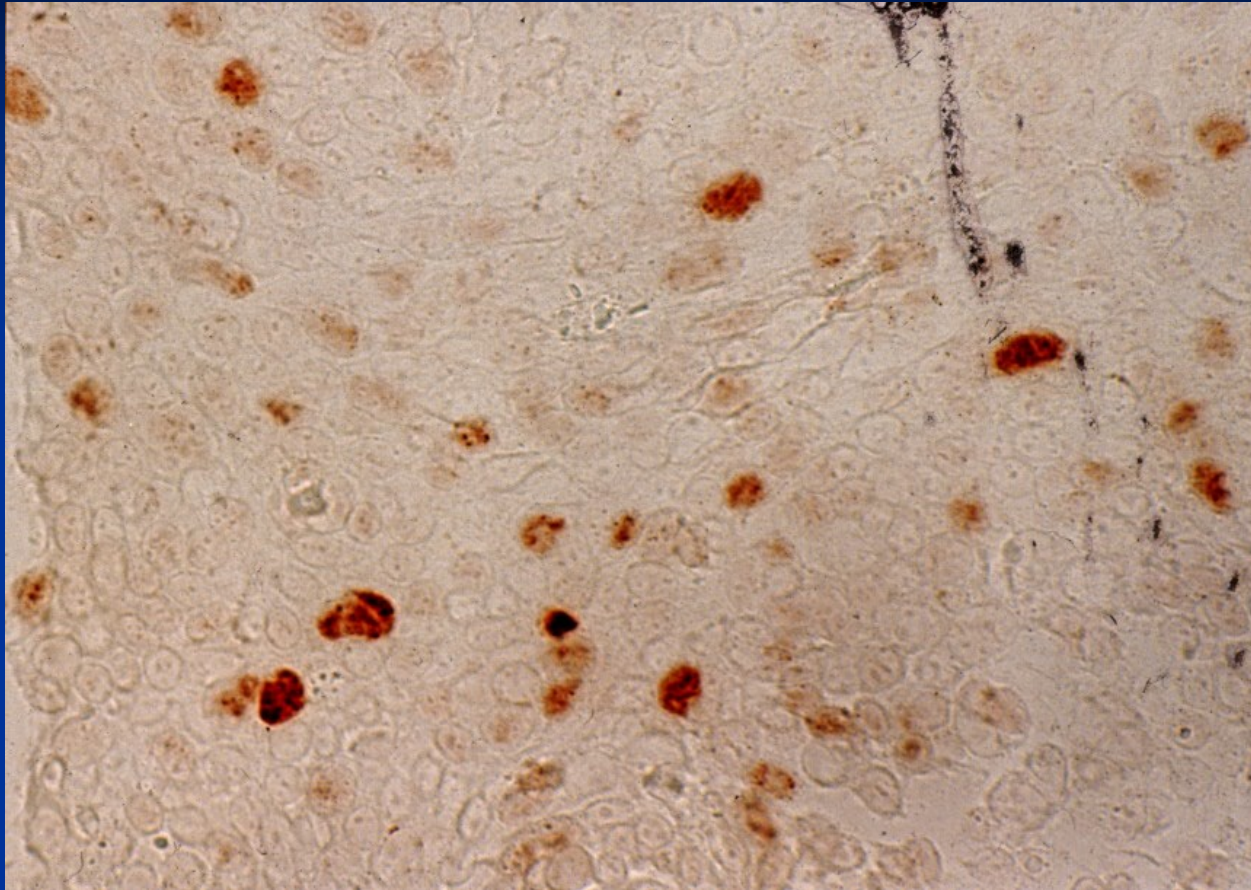
New classification:

Low grade squamous intraepithelial lesion (LSIL):
condyloma + CIN I

High grade SIL (HSIL): CIN II + CIN III

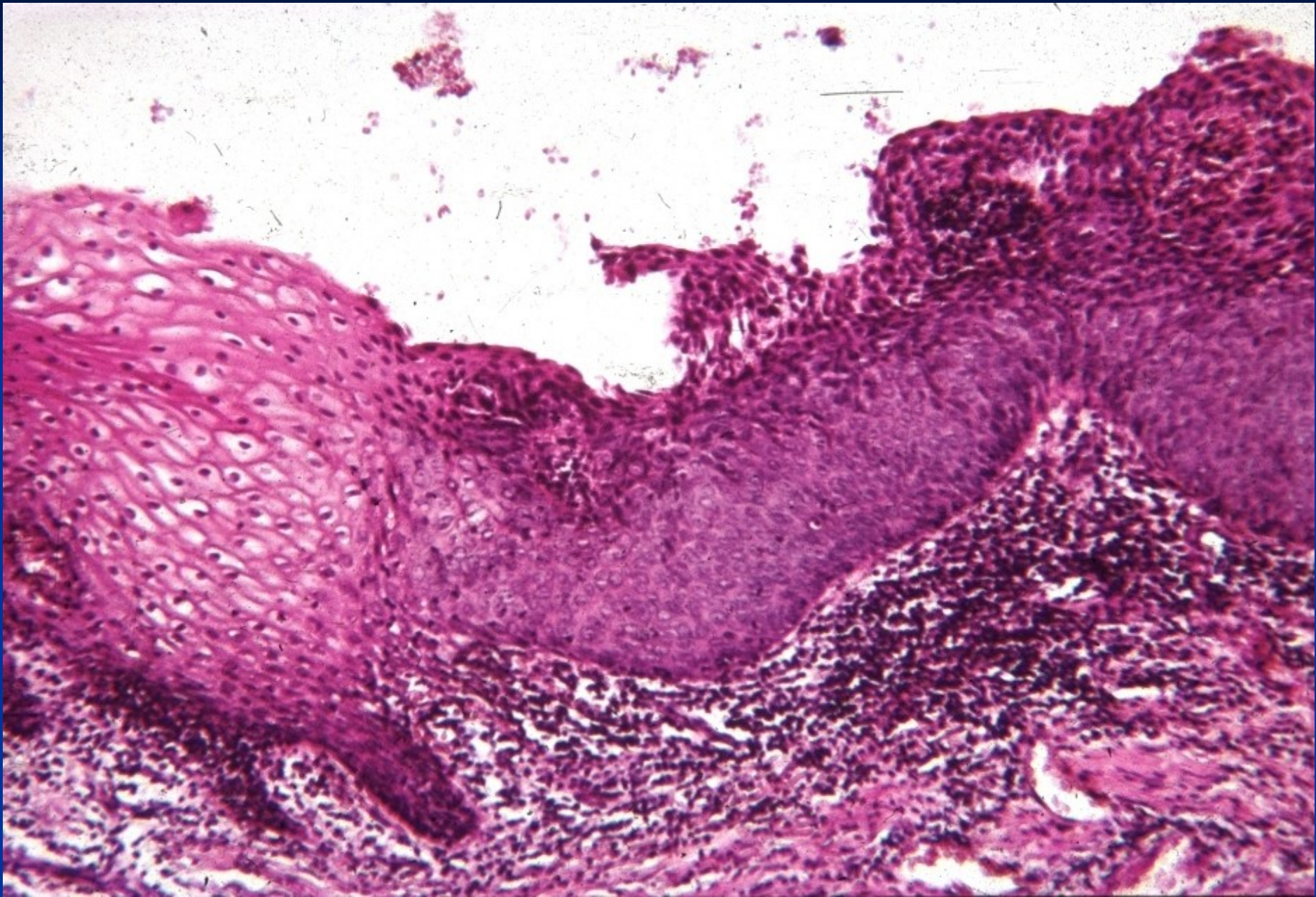


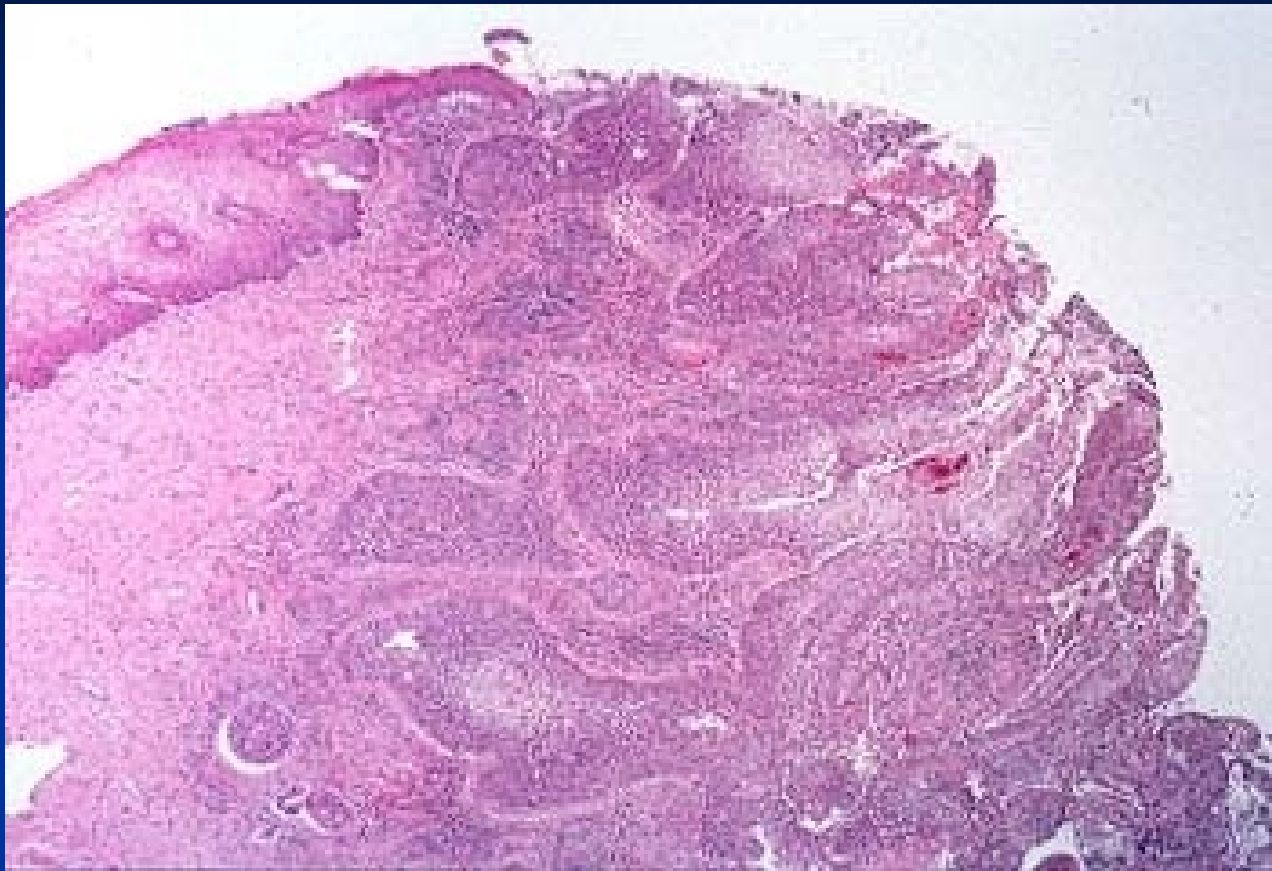
HPV – koilocytosis - LSIL



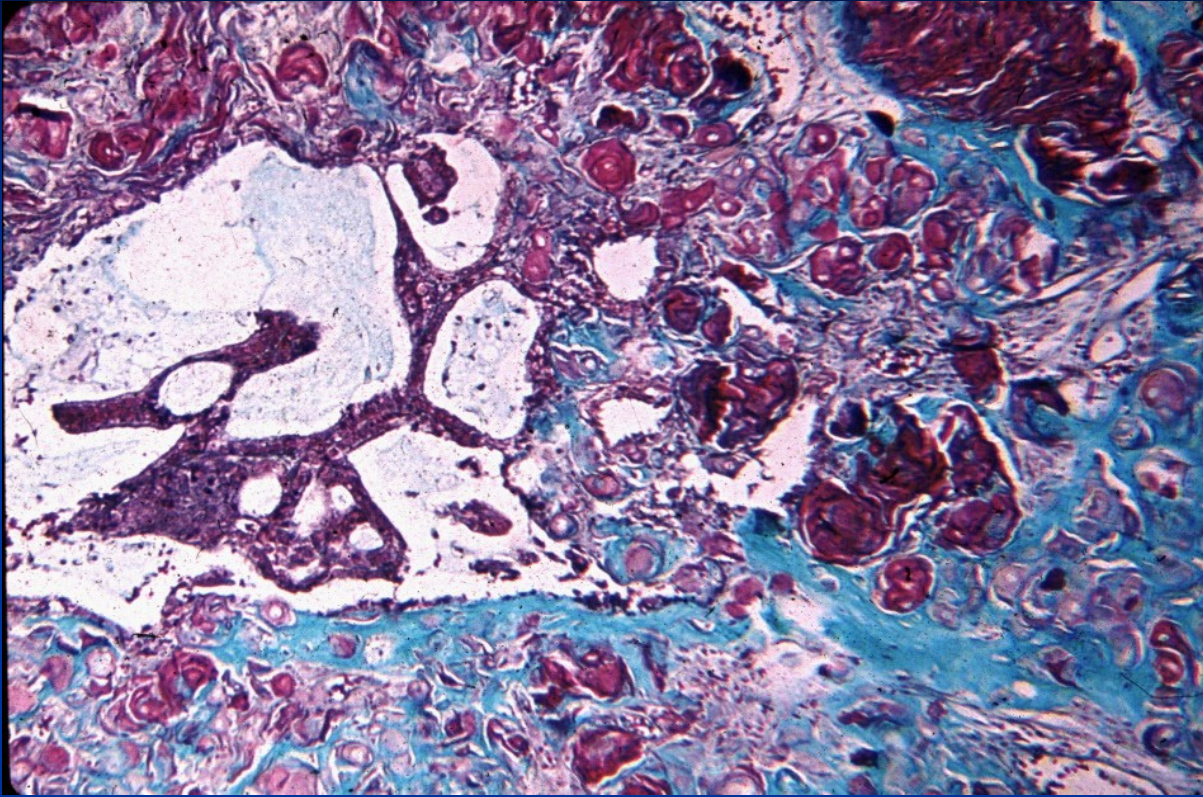
HPV – p16 immunohistochemistry

HSIL

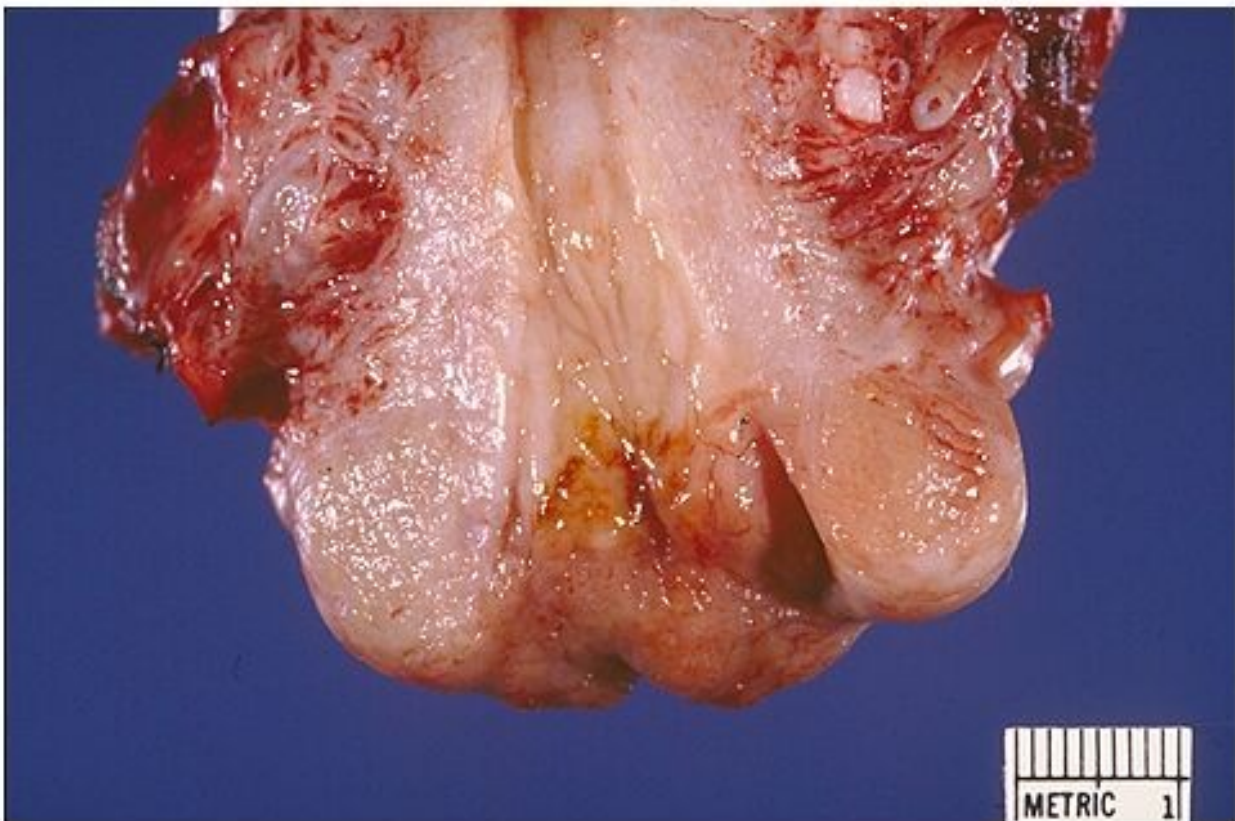




Invasive squamous cell carcinoma

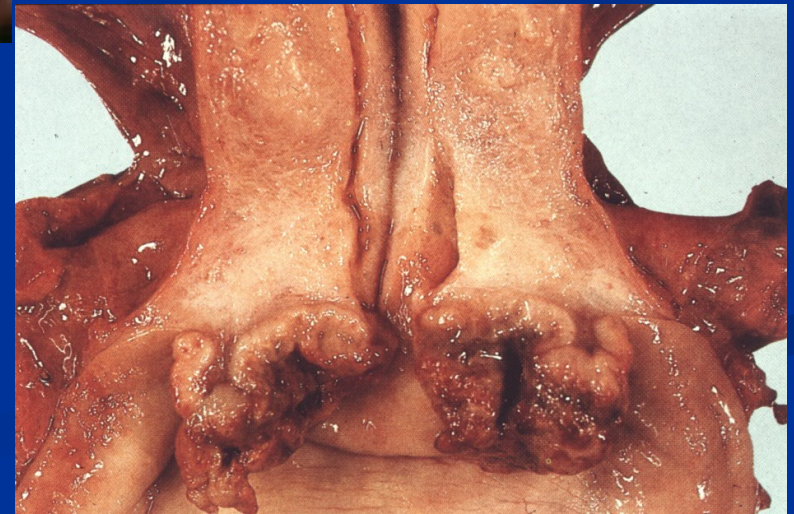
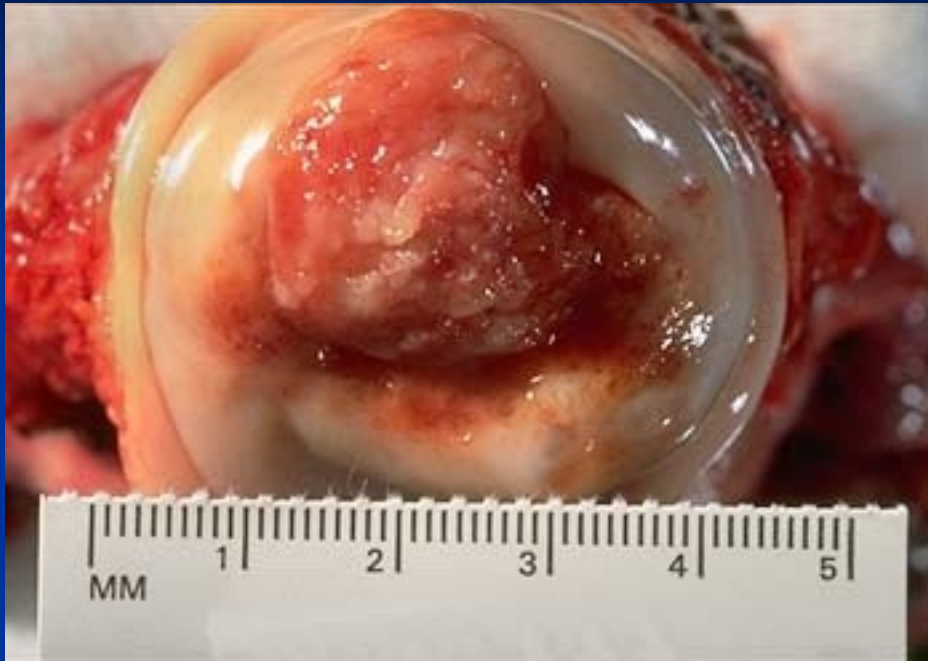
Adenosquamous carcinoma – alcian blue staining

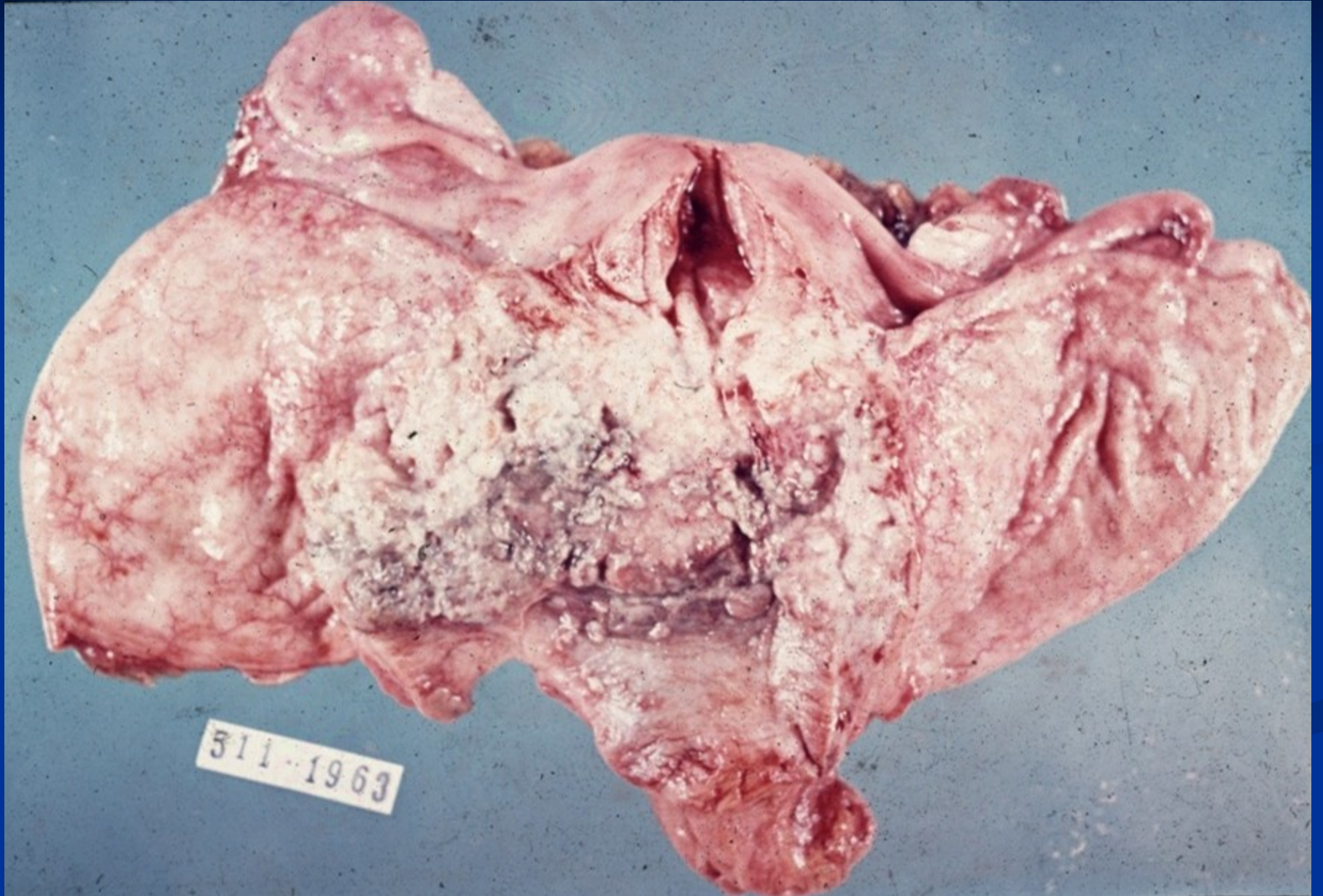


Copyright © 2002, Elsevier Science (USA). All rights reserved.

Cervical squamous cell carcinoma



Cervical squamous cell carcinoma



Vaginal pathology

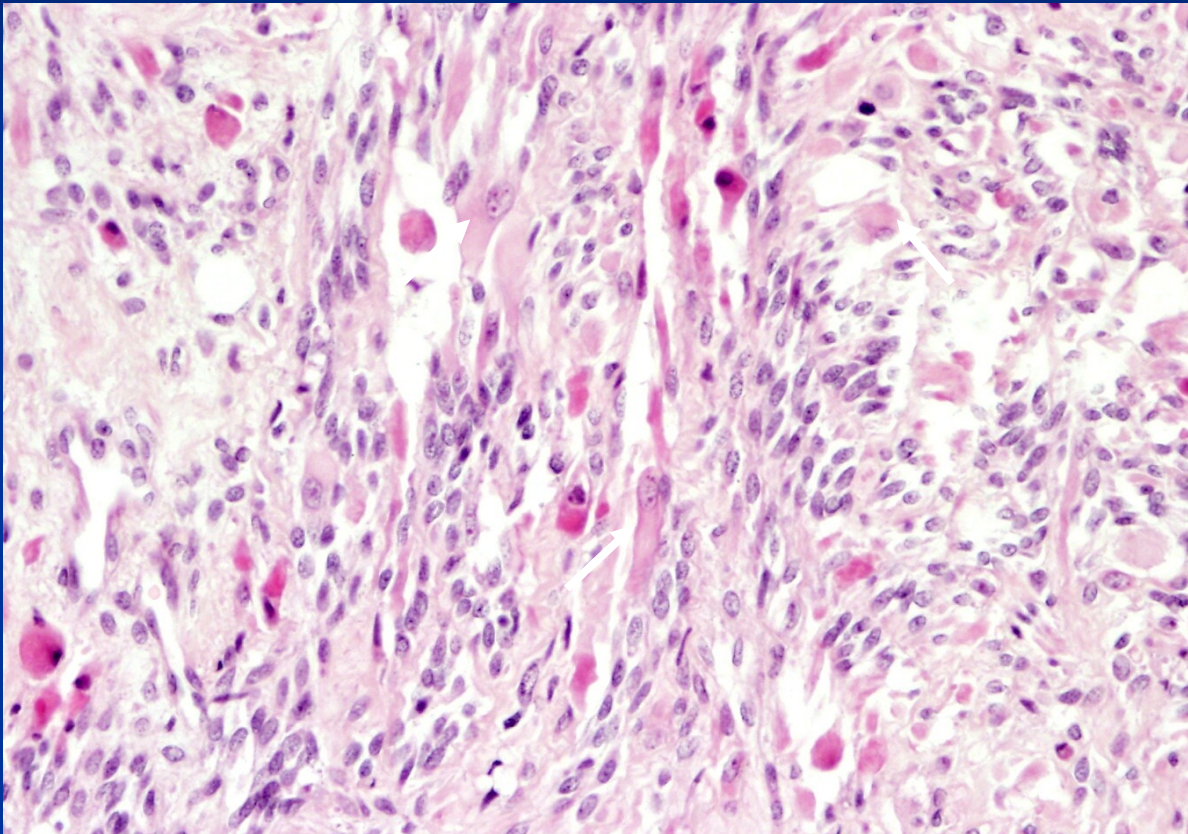
- inflammation
- polyps, cysts
- vaginal squamous intraepithelial neoplasia (VaIN)
- vaginal adenosis (glands)
- tumors

Vaginal tumors and pseudotumors

- fibroepithelial polyps, glandular cysts
- HPV lesions concurrent with cervical/vulvar
 - condyloma accuminatum, vaginal intraepithelial neoplasia (VaIN I-III) → squamous carcinoma
- HPV independent squamous cell carcinoma
- glandular tumors

- embryonal rhabdomyosarcoma (sarcoma botryoides)
 - gross – soft polypoid tumor protruding into vaginal lumen
 - girls <5 years

Embryonal rhabdomyosarcoma



Rhabdomyoblasts
(arrows)

Vulvar pathology

- inflammatory disorders (infectious, noninfectious)
- cysts
- vulvar intraepithelial neoplasia (VIN)
 - HPV-independent
- squamous intraepithelial lesion
 - HPV-associated
 - LSIL, HSIL
- tumors

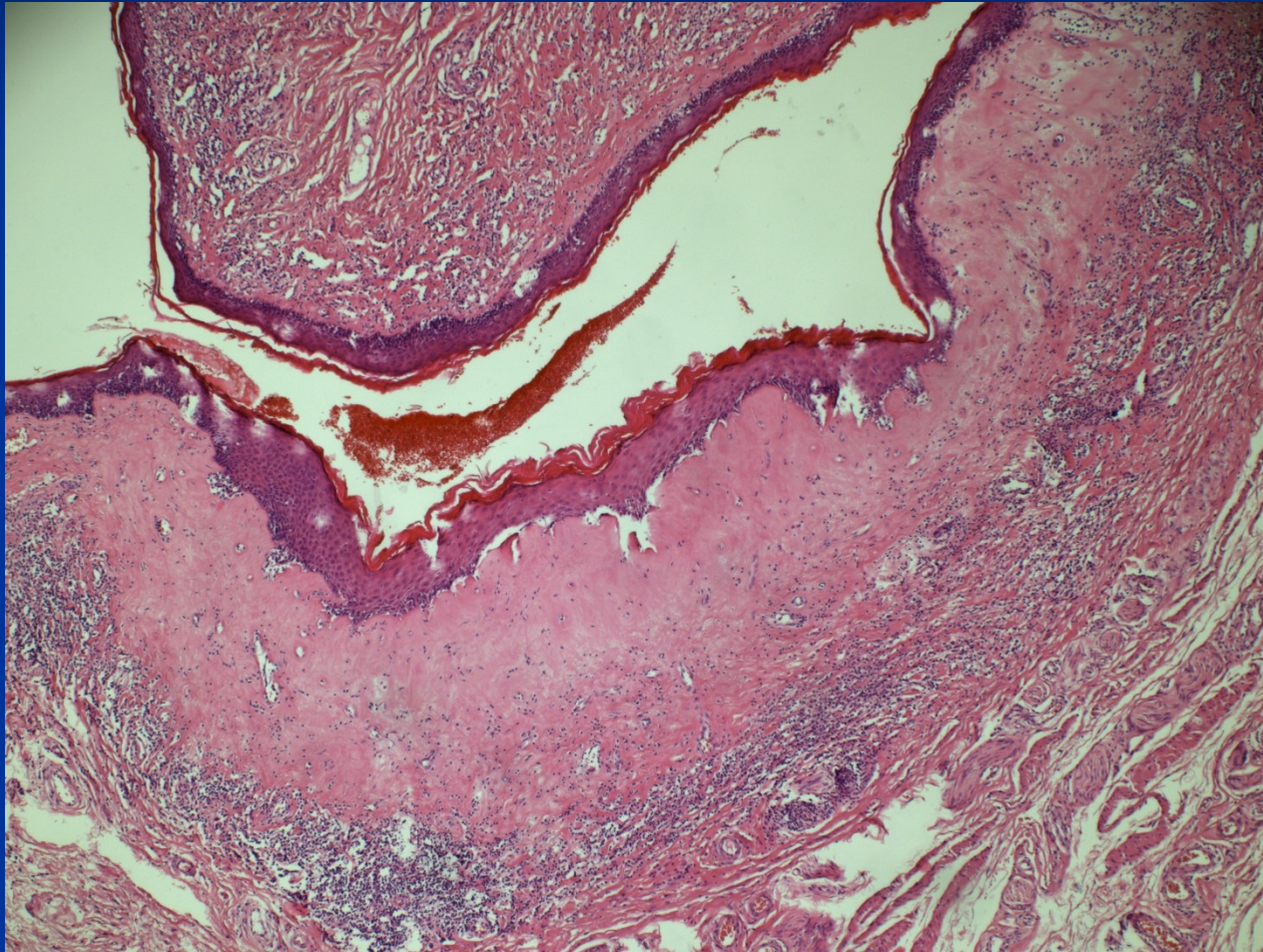
Non-neoplastic epithelial disorders

- gross appearance of leukoplakia – white plaque
- mostly in peri-, postmenopausal women
- inflammatory dermatoses (psoriasis, chronic dermatitis), pre- malignant lesions (VIN, ca), disorders of unknown etiology

- Lichen sclerosis
 - epithelial atrophy + hyperkeratosis
 - superficial dermis – band of oedema + hyalinisation
 - perivascular mononuclear inflammatory cell infiltrate
 - → → stenosis of vaginal orifice (craurosis vulvae)

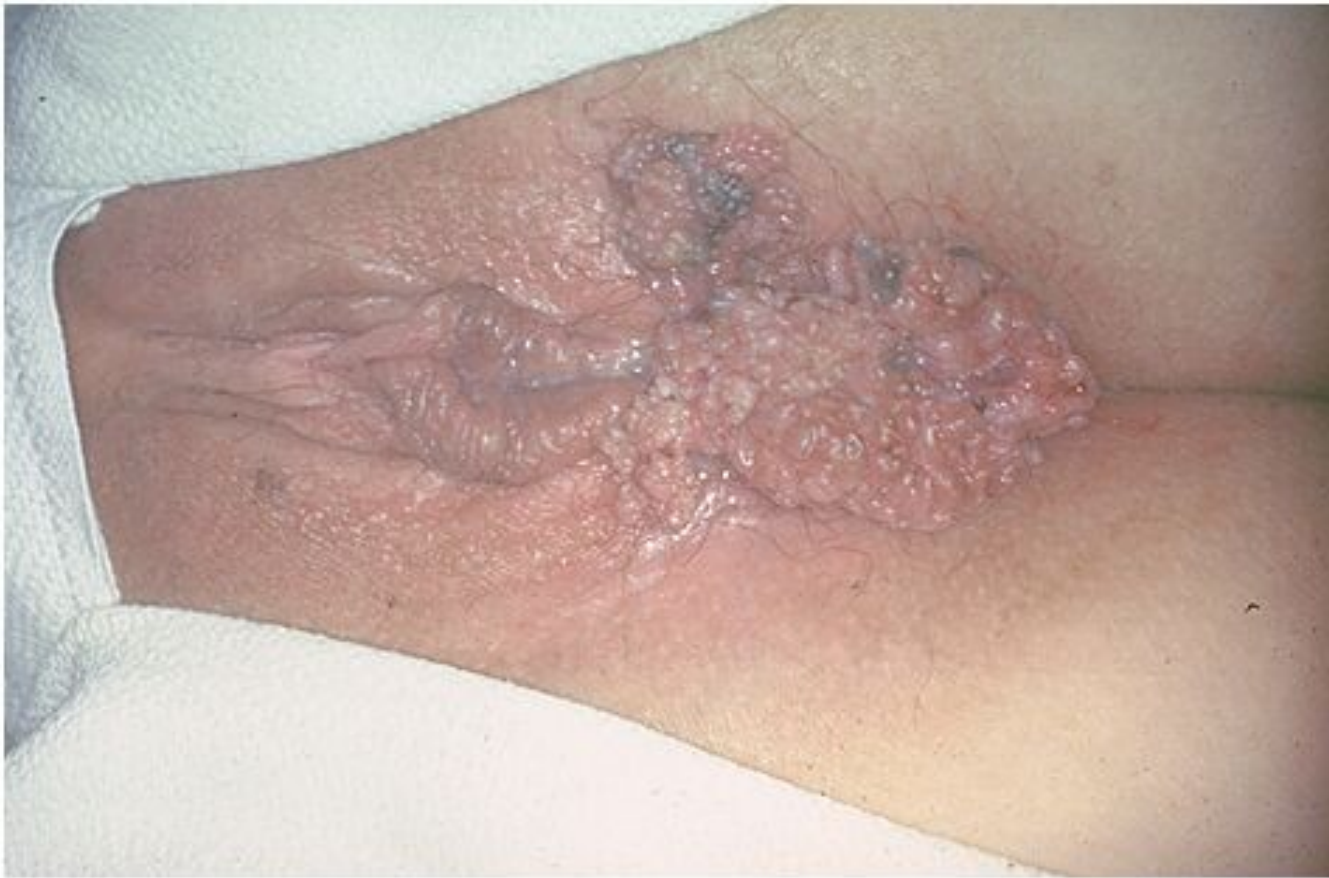- Lichen simplex chronicus – squamous cell hyperplasia
 - epithelial hyperplasia + marked hyperkeratosis
 - not a precancerosis

Lichen sclerosus



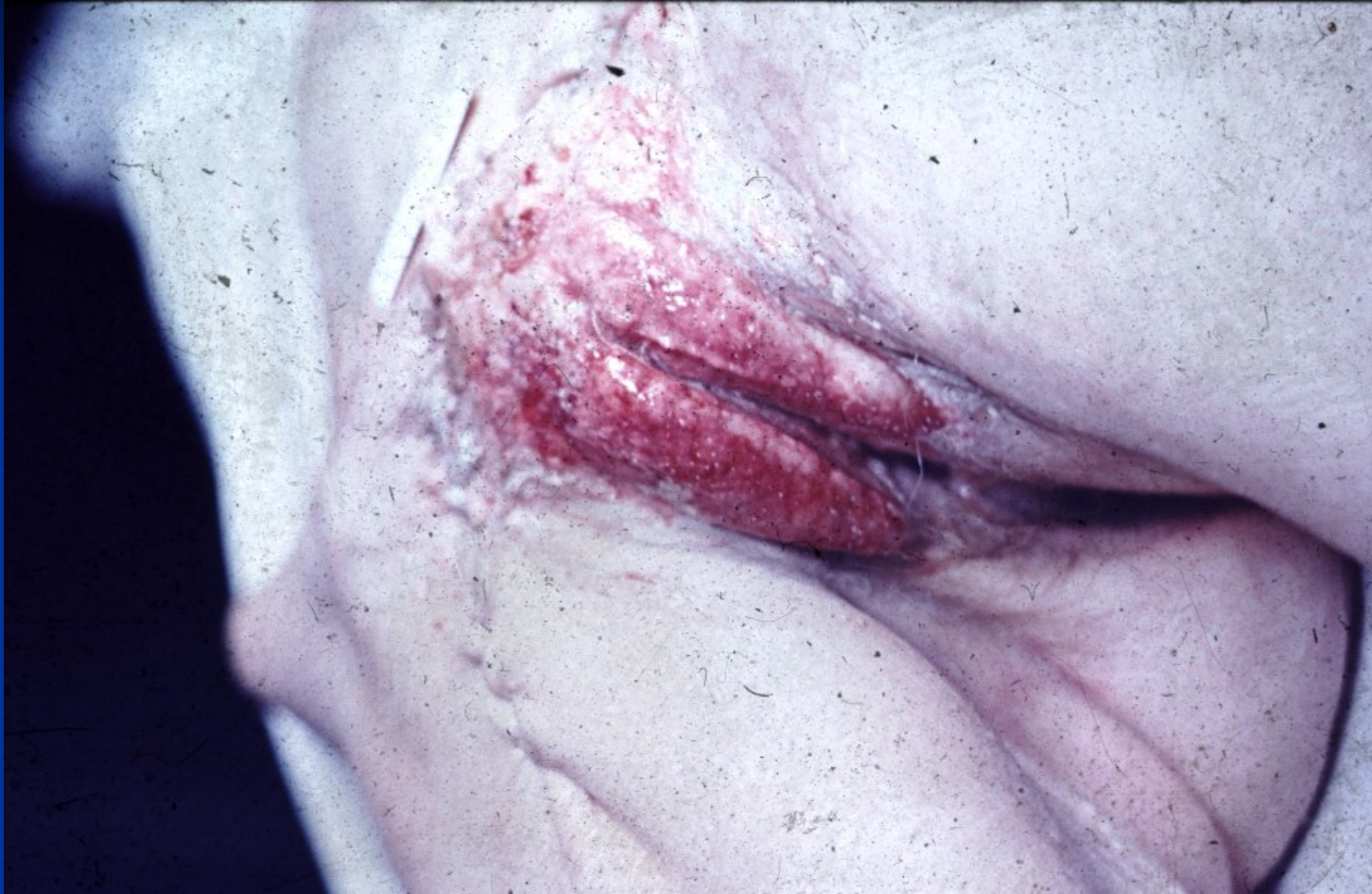Vulvar neoplasia

- **condyloma accuminatum**
 - low-risk HPV (6, 11)
 - squamous cell papilloma with koilocytar epithelial transformation
- **vulvar intraepithelial neoplasia – VIN; LSIL/HSIL**
- **carcinoma**
 - squamous ca (90 %) HPV-associated, HPV-independent
 - adenocarcinoma, basal cell carcinoma
- **malignant melanoma**



Copyright © 2002, Elsevier Science (USA). All rights reserved.

Extensive HPV condylomatosis



Vulvar squamous carcinoma

