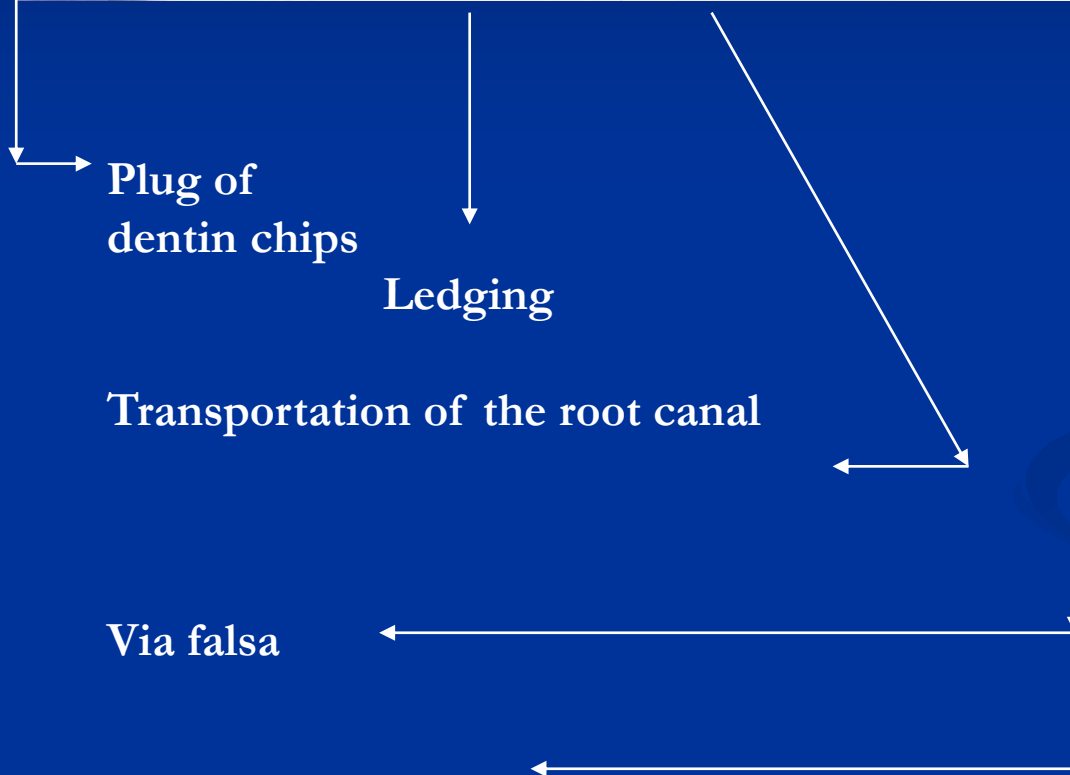
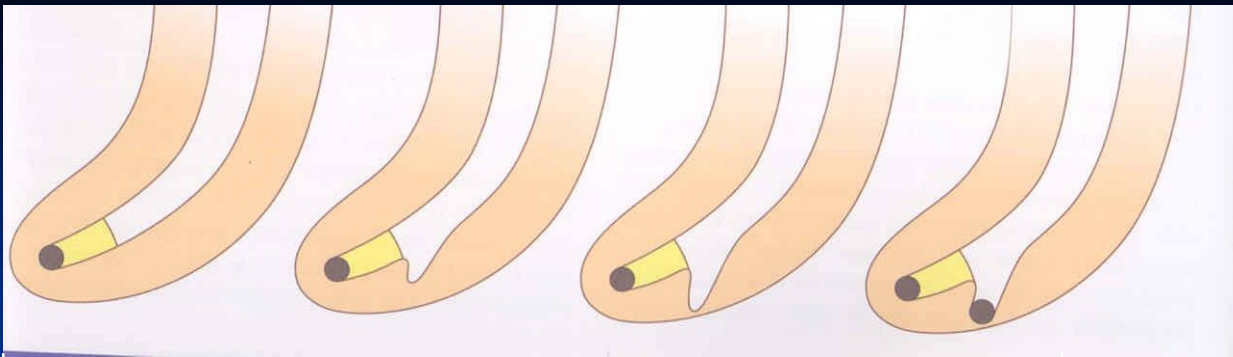

# Complications of endodontic treatment

**Local**

**Regional**

**Systemic**



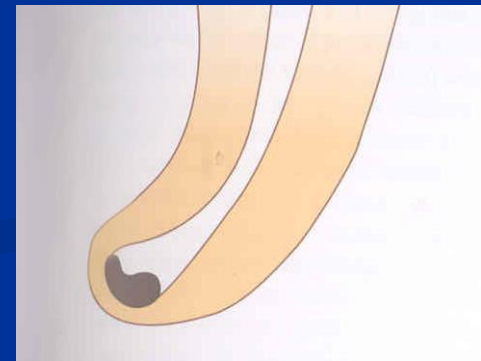
Plug of dentin chips

Ledging

Transportation of the root canal

Via falsa

Zippering a elbow



# Local complications

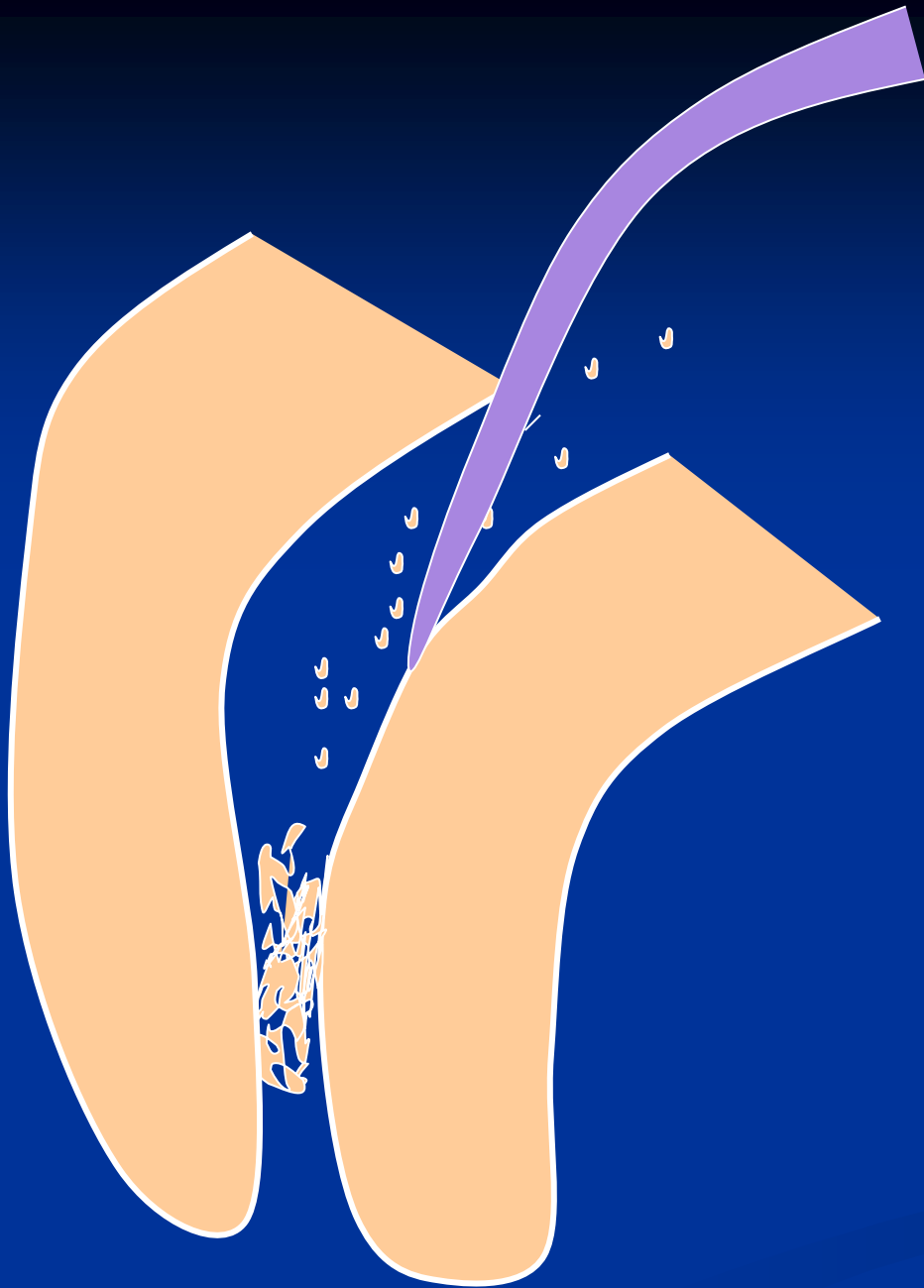
# Plug



## Reasons

**Insufficient irrigation and  
recapitulation**

*Loss of the working length*



## Solution

Repeated careful  
instrumentation  
with a thin  
instrument

*Irrigation is not  
effective in this  
case!!!*

# Ledging




## Reasons

The instrument is not bended in advance!

No control of the WL

=

No recapitulation Loss of the WL



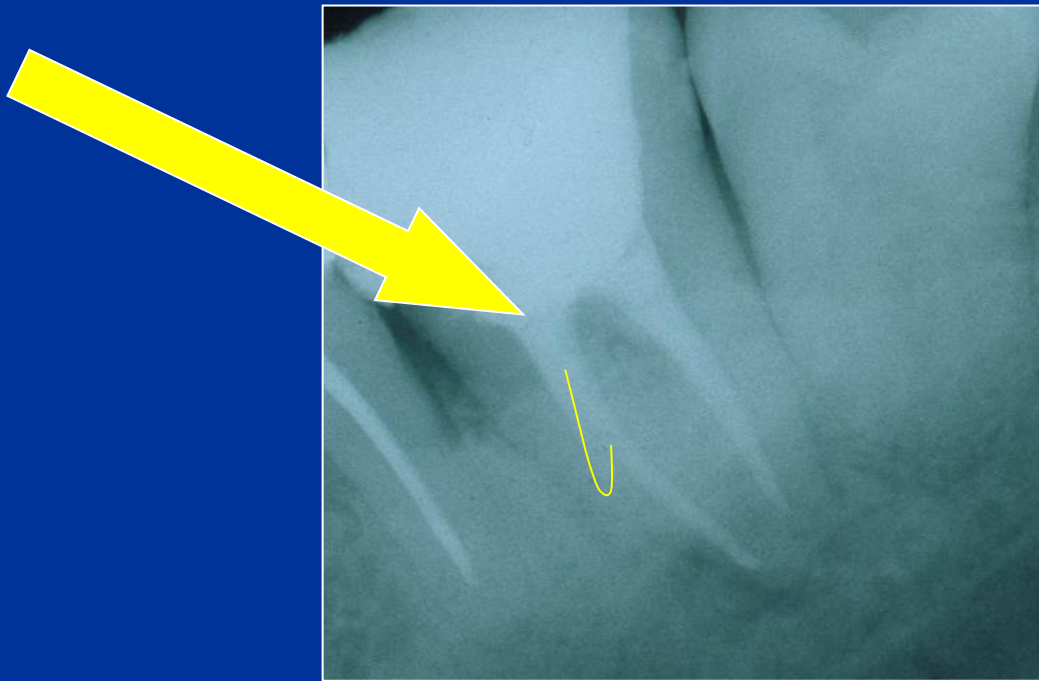
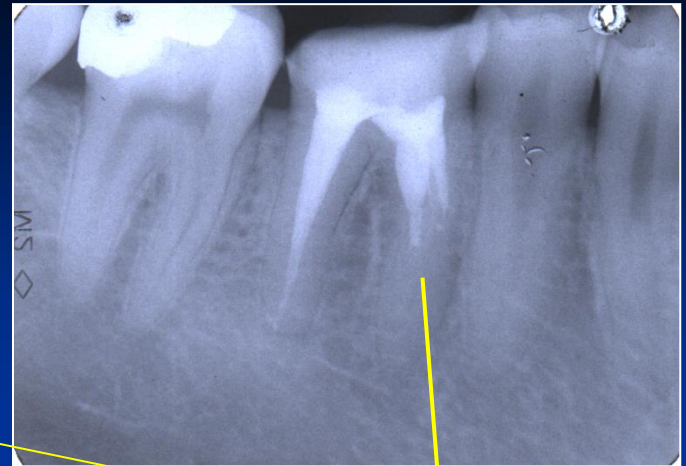
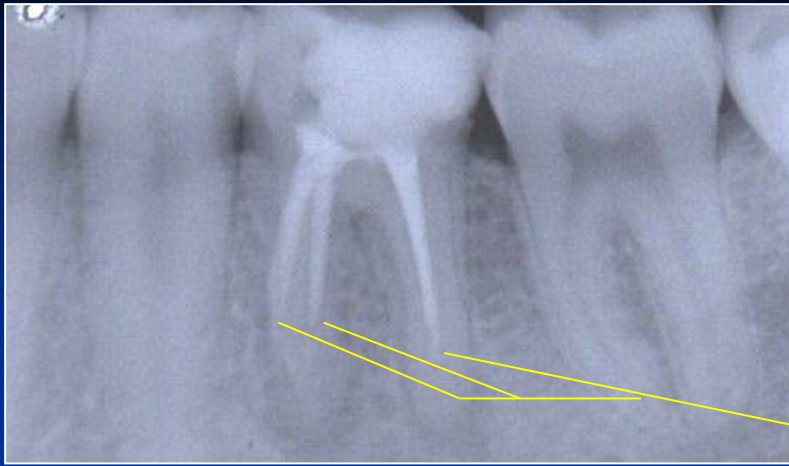
### Solution

The instrument must be  
bended in advance

Careful but complete rotation

Finishing with the fine filing

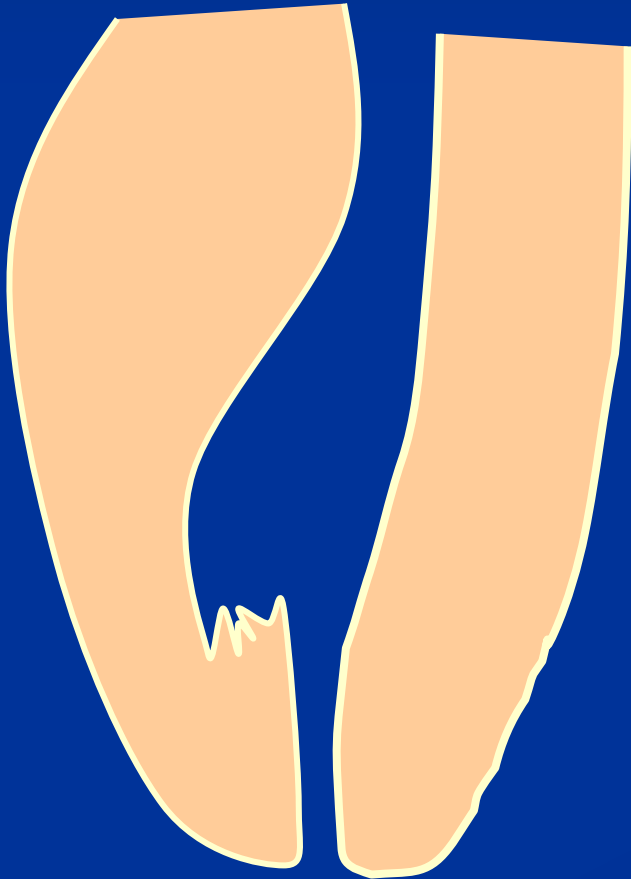*No NiTi!!!*



Ledging

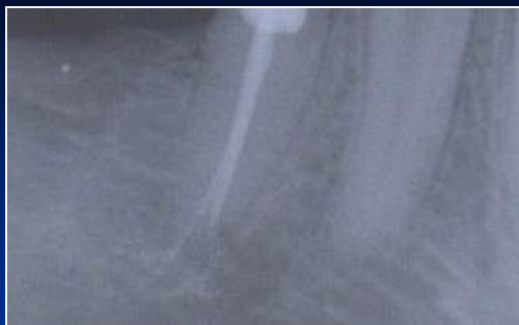



# Zippering a Elbow



The instrument is not bended in advance!

Rotation in curved canals



# Stripping

## Reasons

Bad orientation in morphology – no diagnostic x-  
Instruments are not bended  
Rotary NiTi with a big taper


## *Dangerous zones*

*Mandibular molars – mesial roots*

*Premolars, esp. maxillar*

*Mandibular incisors*

*Oblast isthmu*




# Stripping

**Důkladný přehled!**

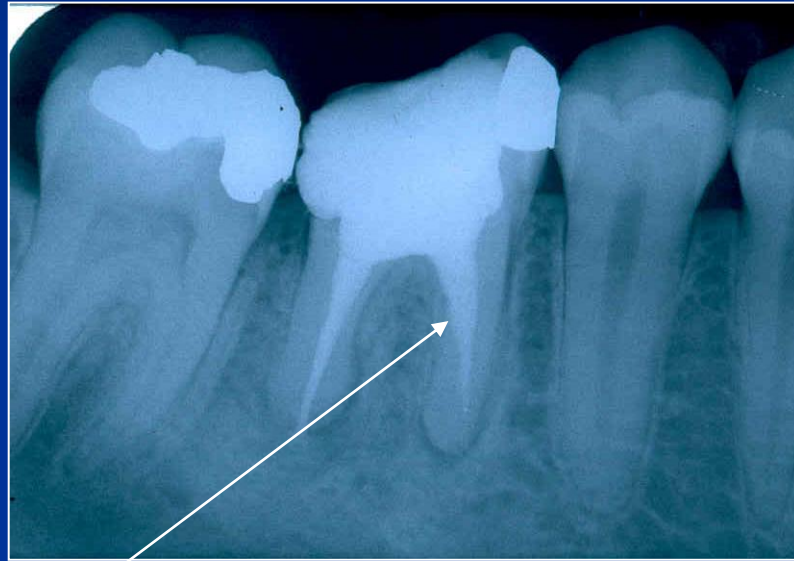
**Šetřit oblast isthmu!**

**Ruční preparace!**

**Menší kónus NiTi !**



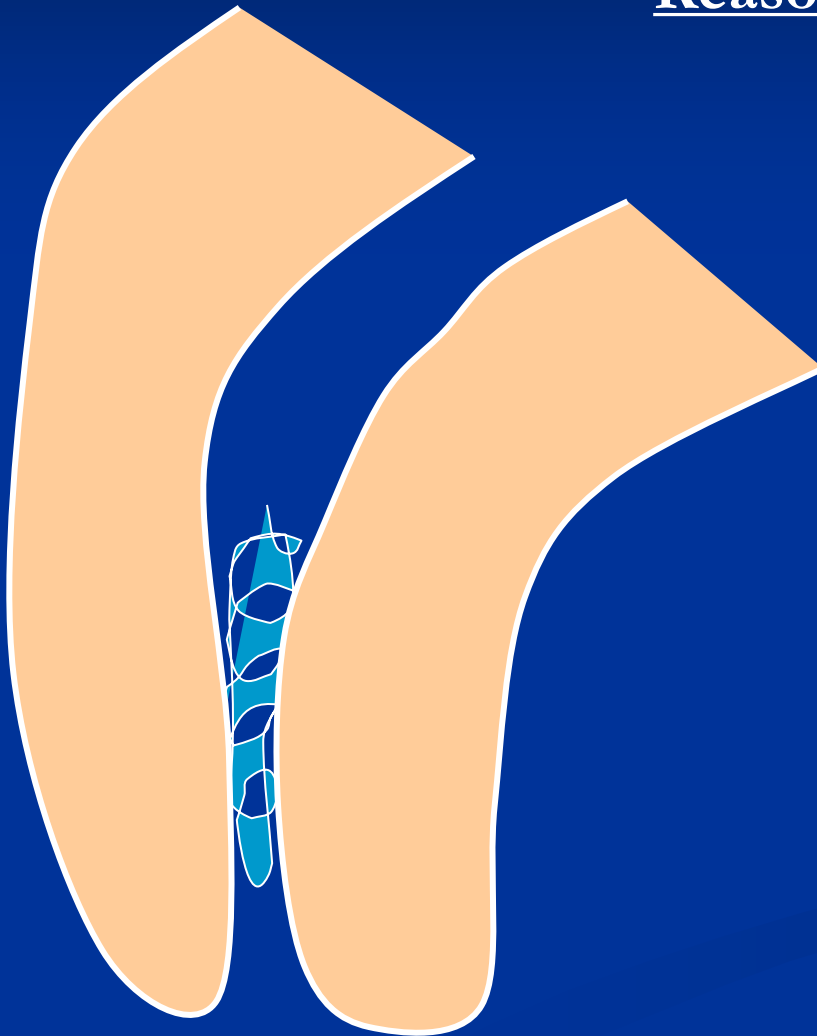
# Stripping



**Bend the instrument and eventually blunt it !**

# Fracture of the root canal instrument

## Reasons



**Insufficient  
coronal flaring**

**Old root canal  
instrument**

**Aggressive force**

**Incorrect  
movement of the  
root canal  
instrument**

## Solution

Enlargement of the  
root canal till the  
instrument

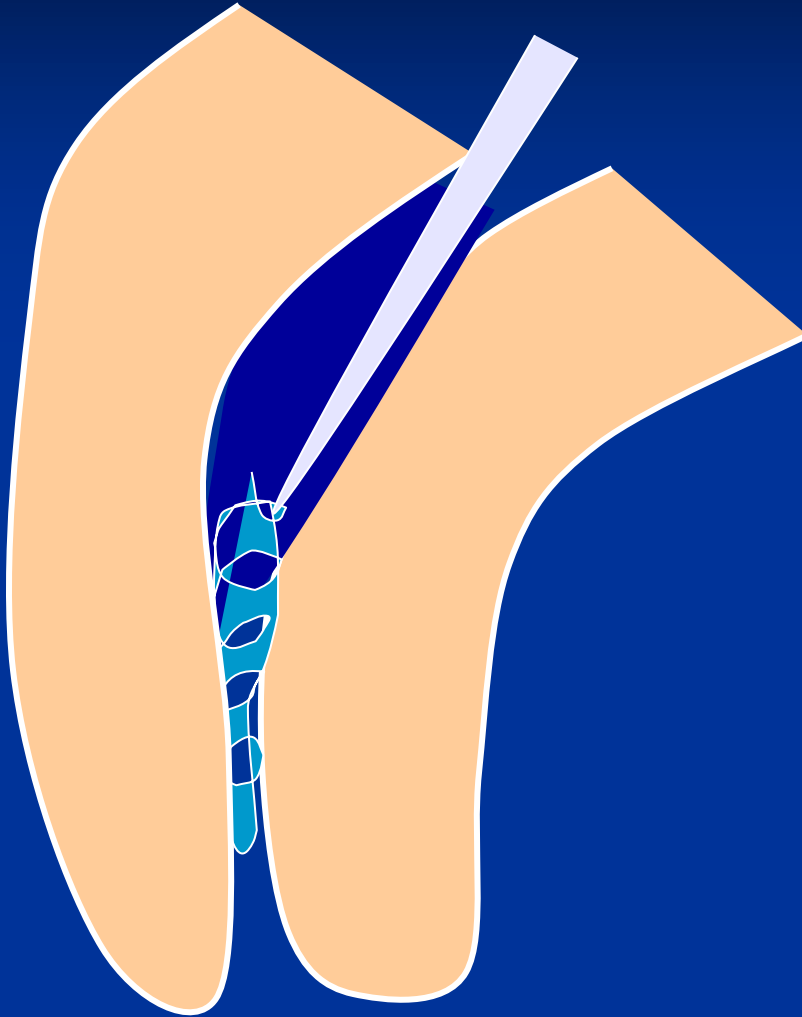
Ultrasound tips

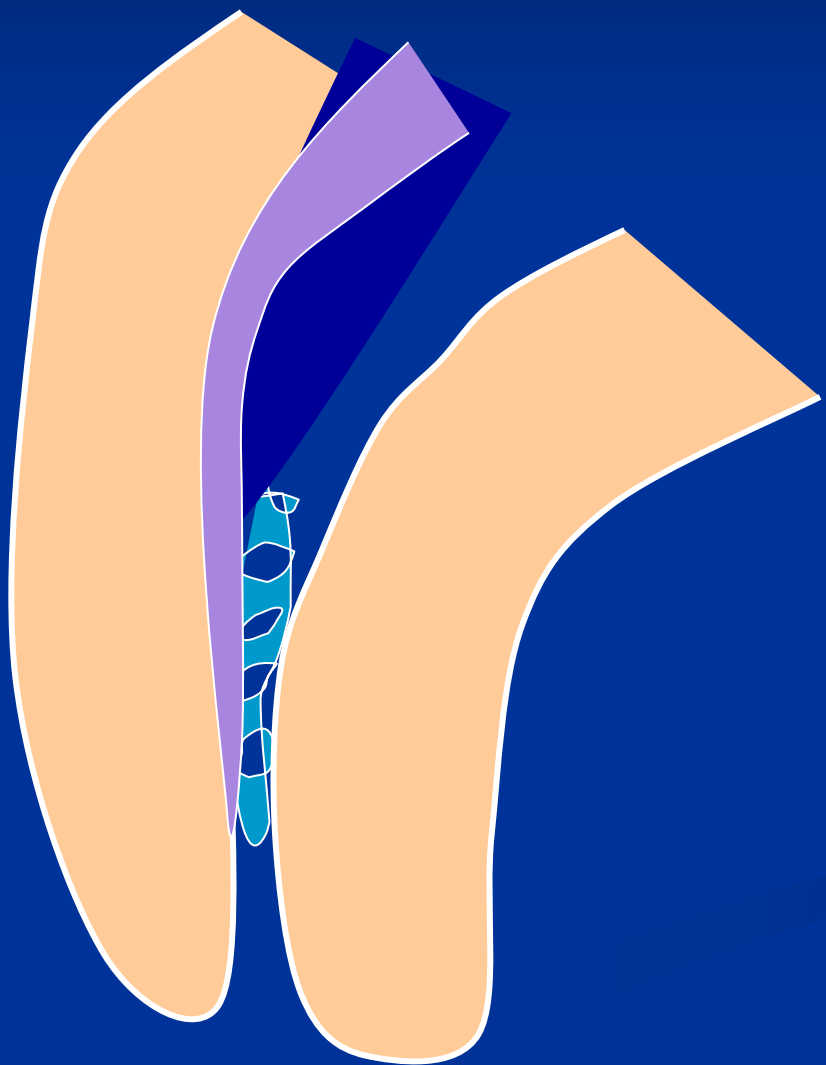
Rotating root canal  
instrument – caution!

Bypass

Leaving in

Surgical treatment

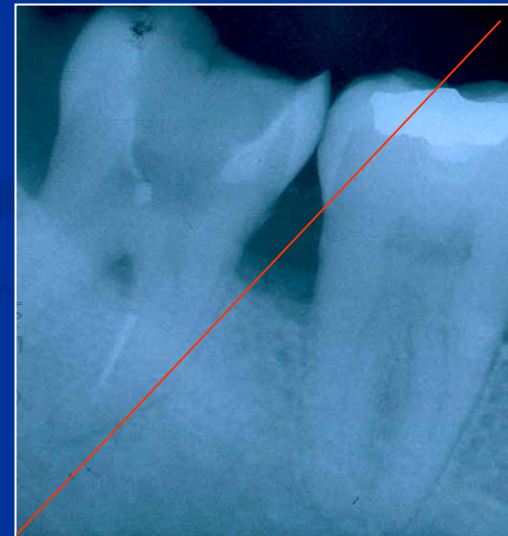
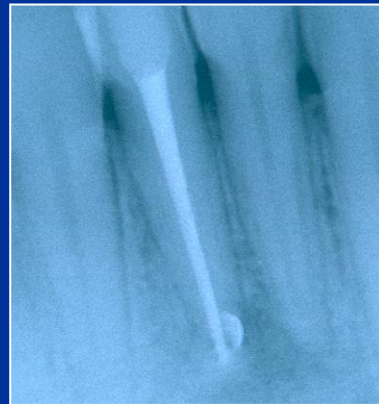
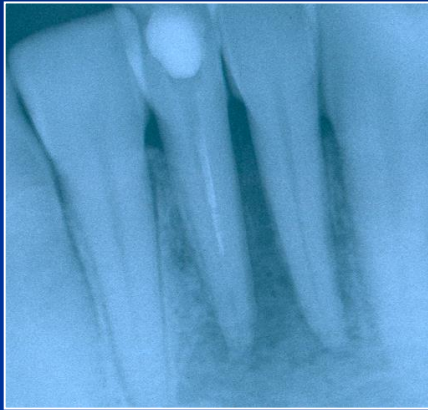


Bypass



# Fractured instrument



# Via falsa - Perforation

- Perforation of the bottom of the pulp chamber or the coronal part of the root canal
- Perforation in the middle part of the root canal
- Apical perforation

LOT 000724 EXP 0507

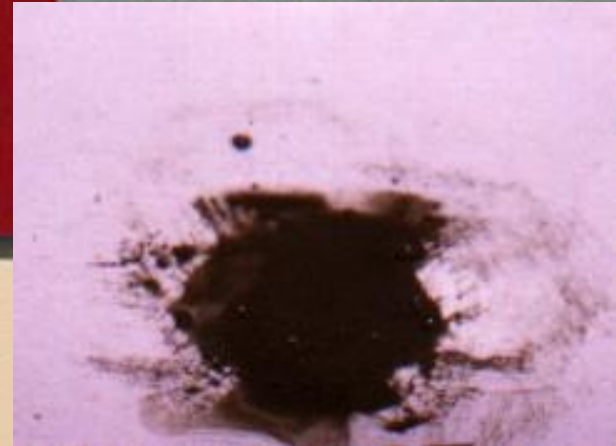
DENTSPLY

# PRO ROOT™

*MTA (Mineral Trioxide Aggregate)  
Root Canal Repair Material*

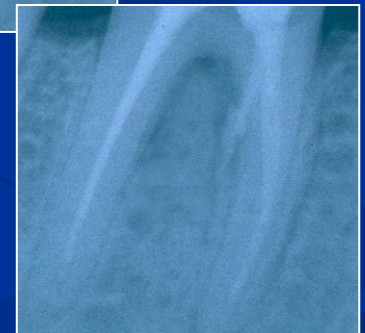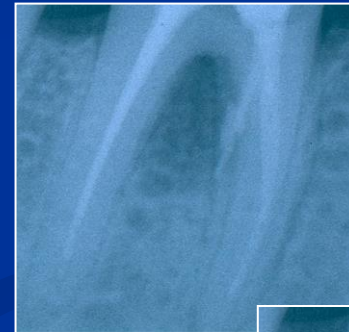Contents: 1 gram (1 treatment)

CE  
0120



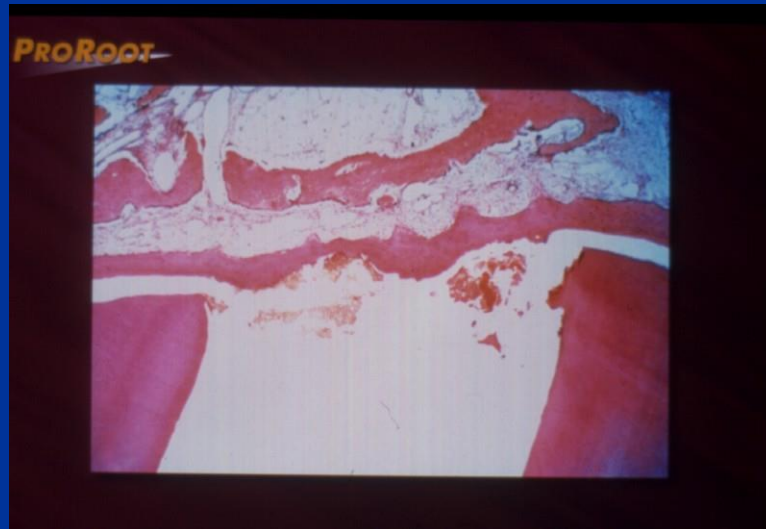# MTA composition

- Dicalcium silicate
  - Trikalcium silicate
  - Trikalcium aluminate
  - Tetrakalcium aluminate
  - Cuprum sulphate
  - Bismuthum trioxide
- = Portland cement



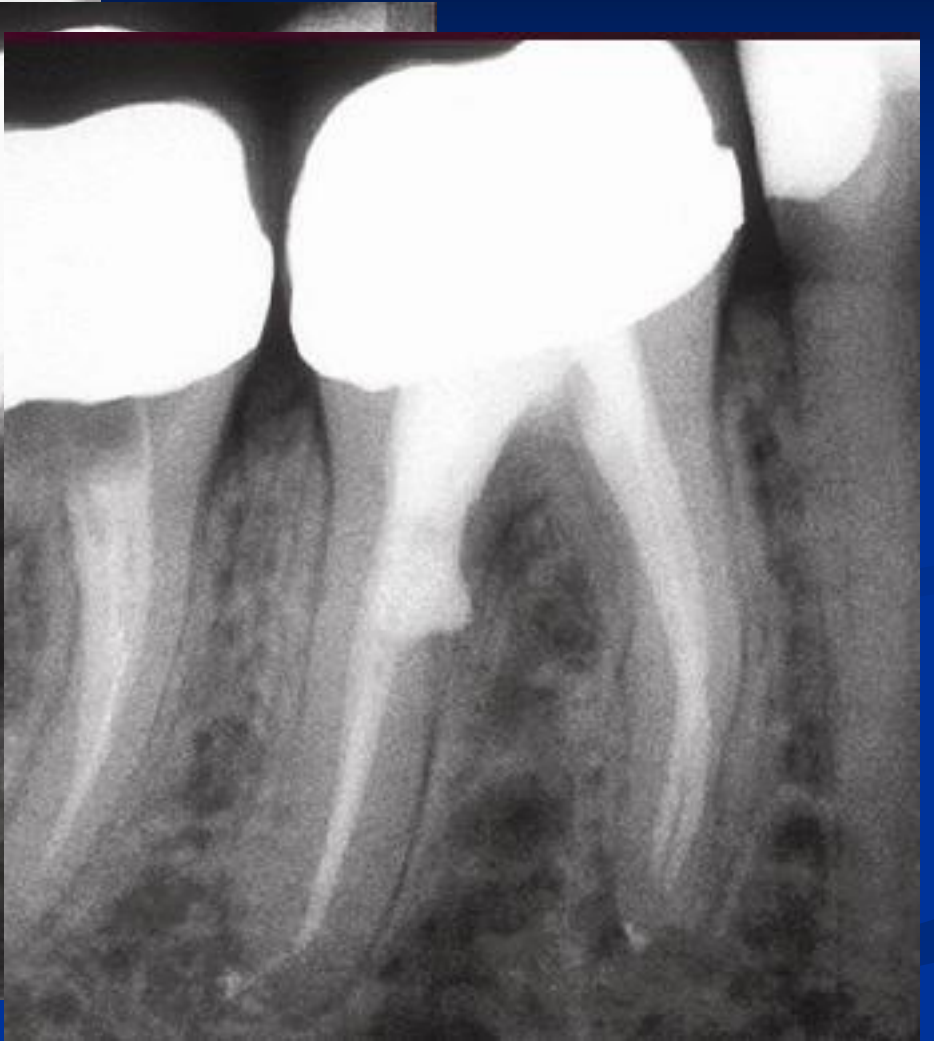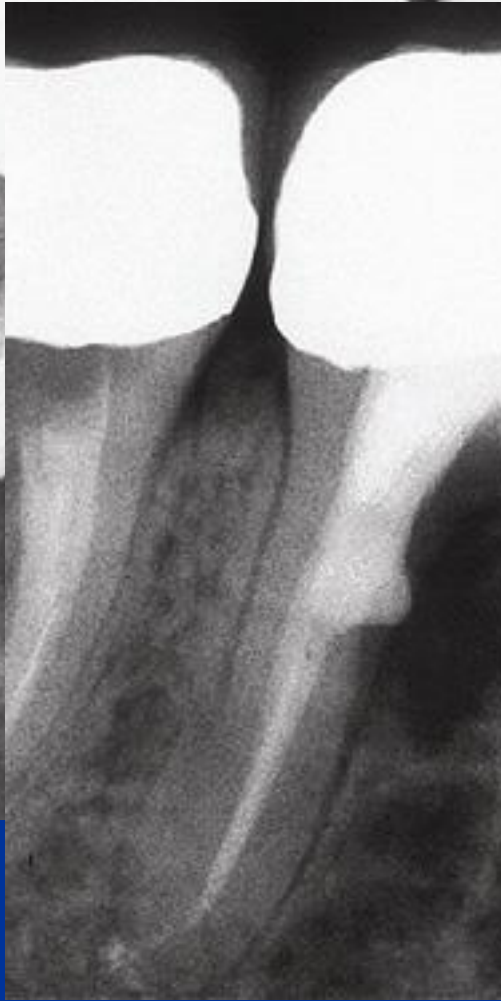
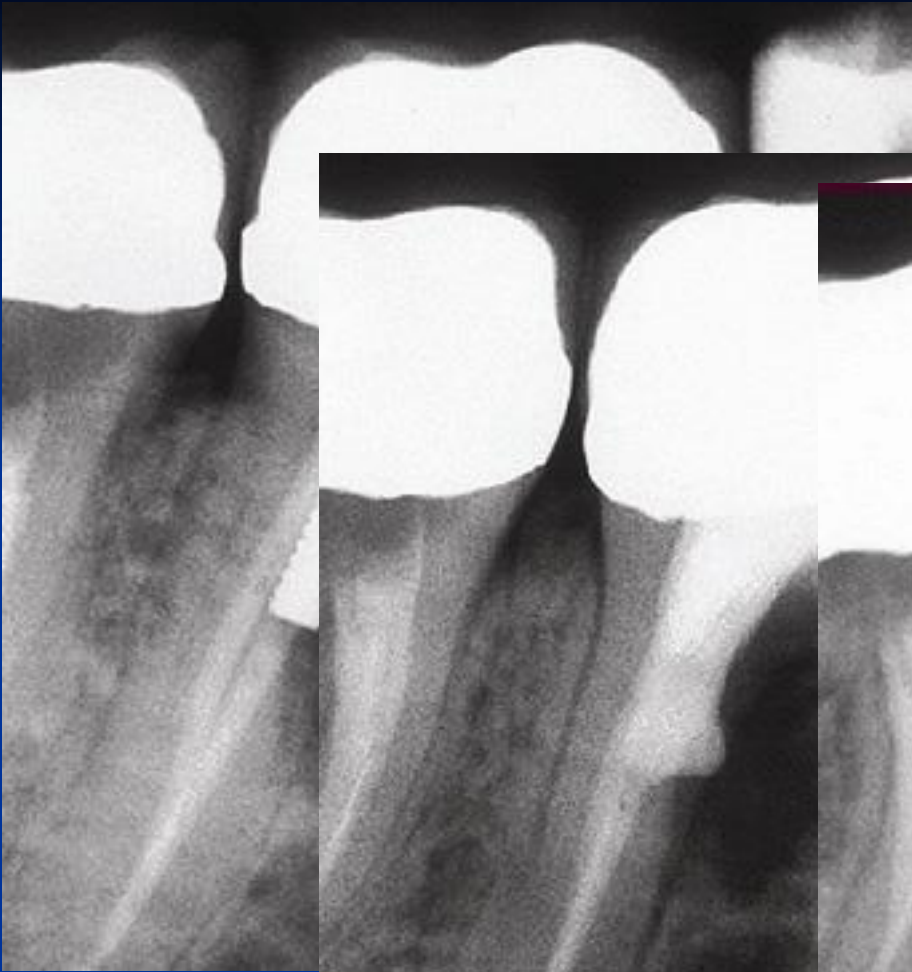# MTA

- Good sealing ability
- Promotion of healing



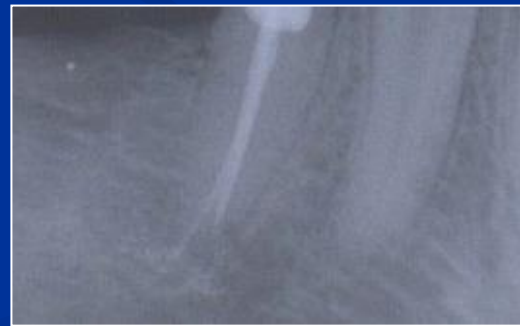




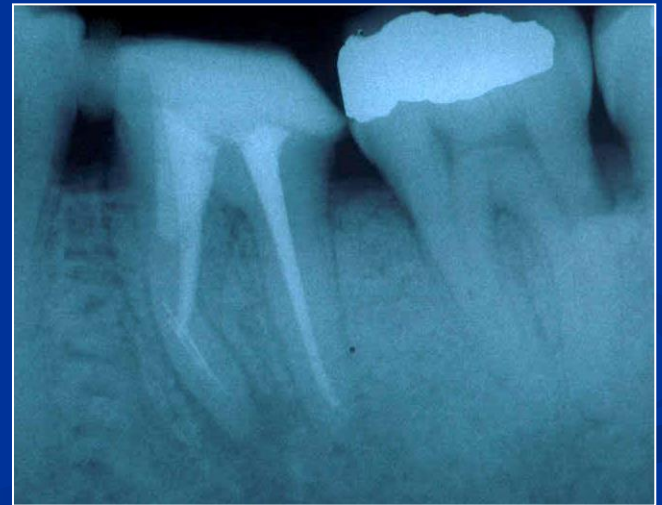
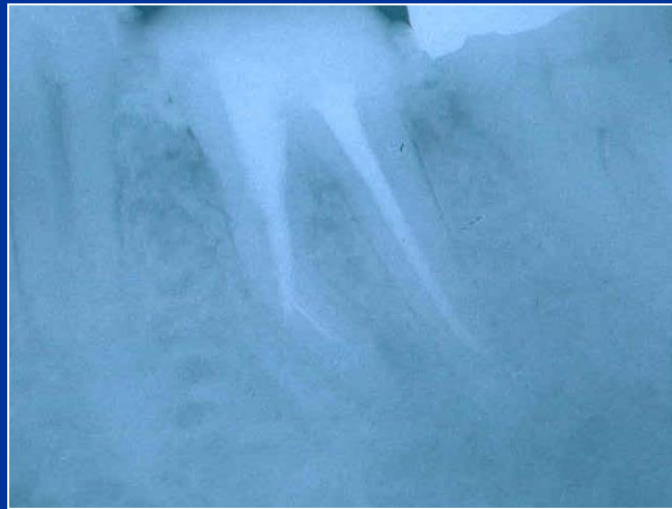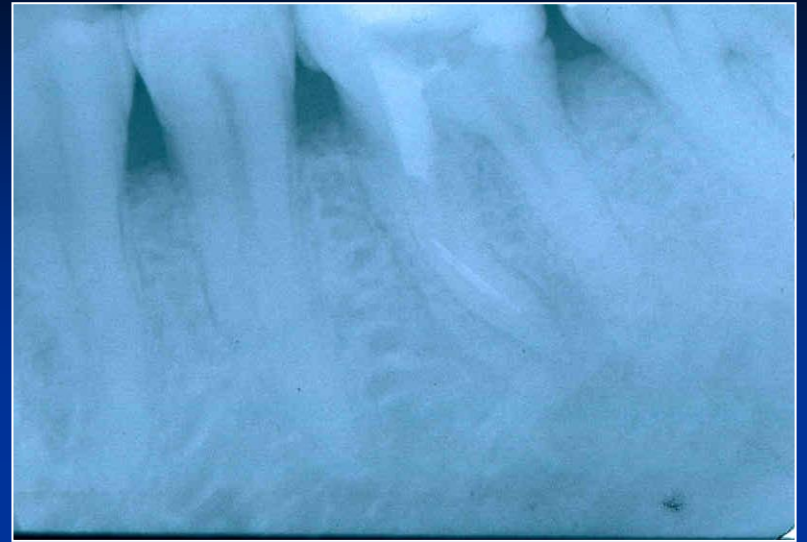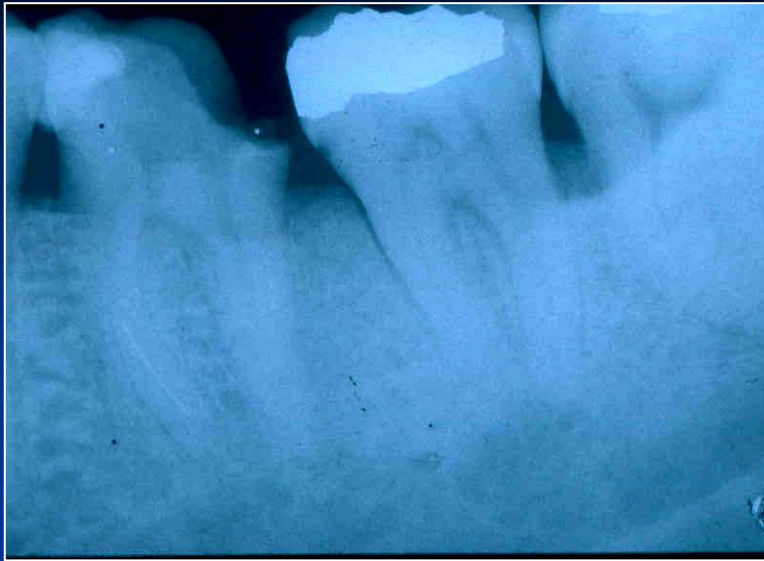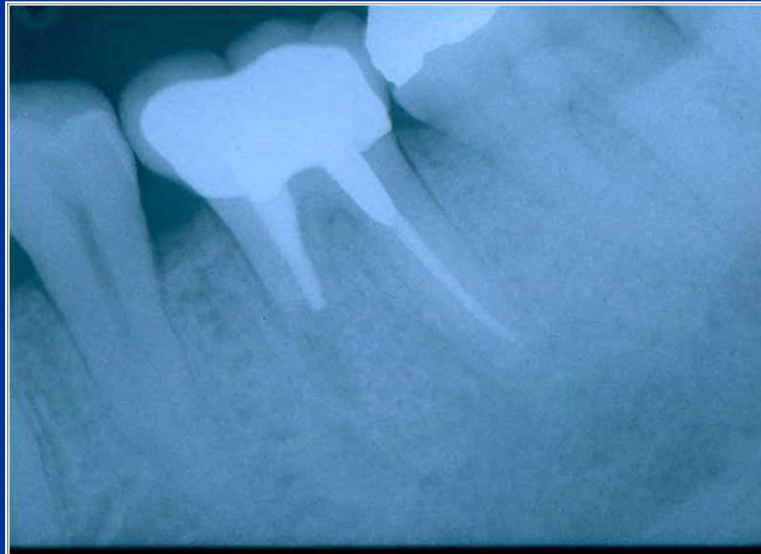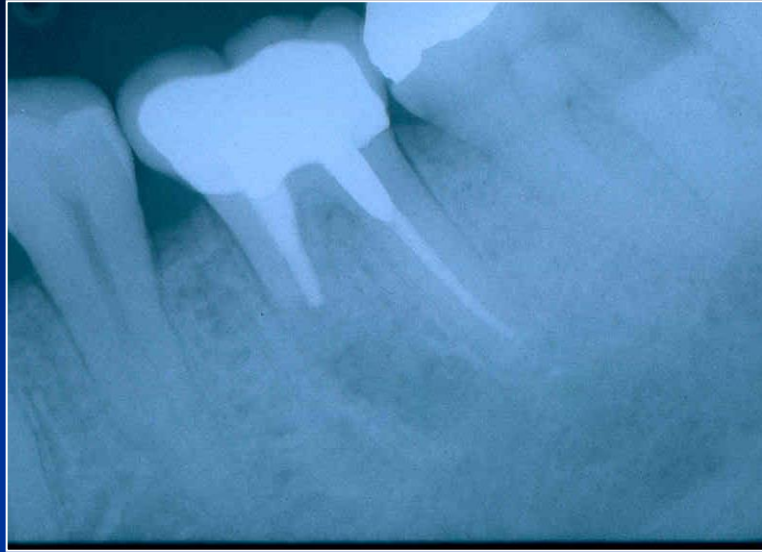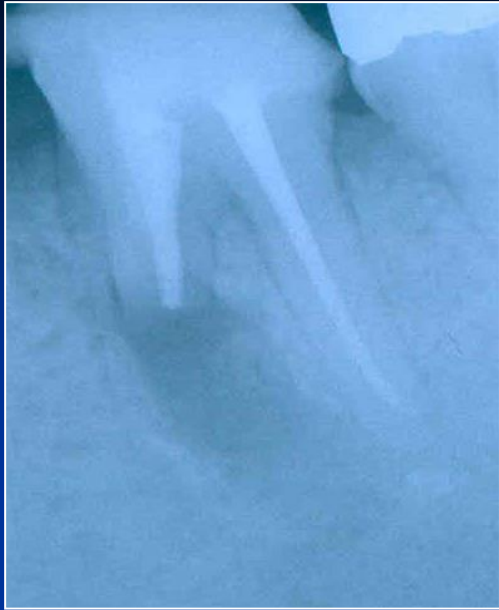# Via falsa - treatment

- No bleeding
- Desinfection
- MTA – moisture (wet cotton pellet)
- Filling



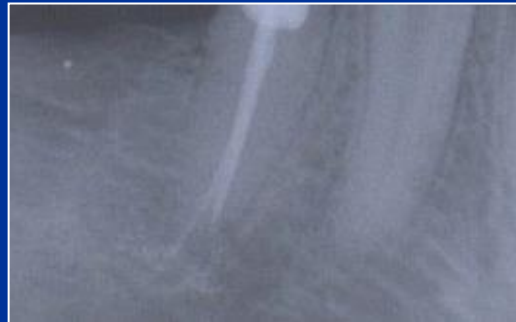





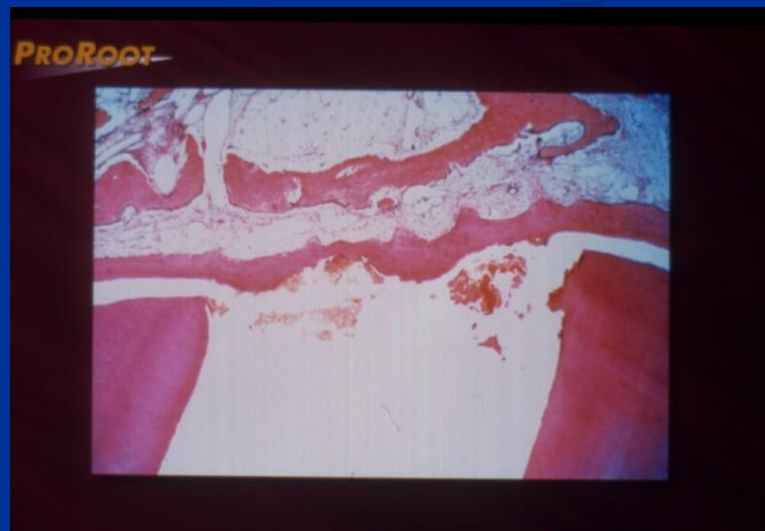# Via falsa

- Apical perforation
- Plug of MTA, root canal filing



# MTA

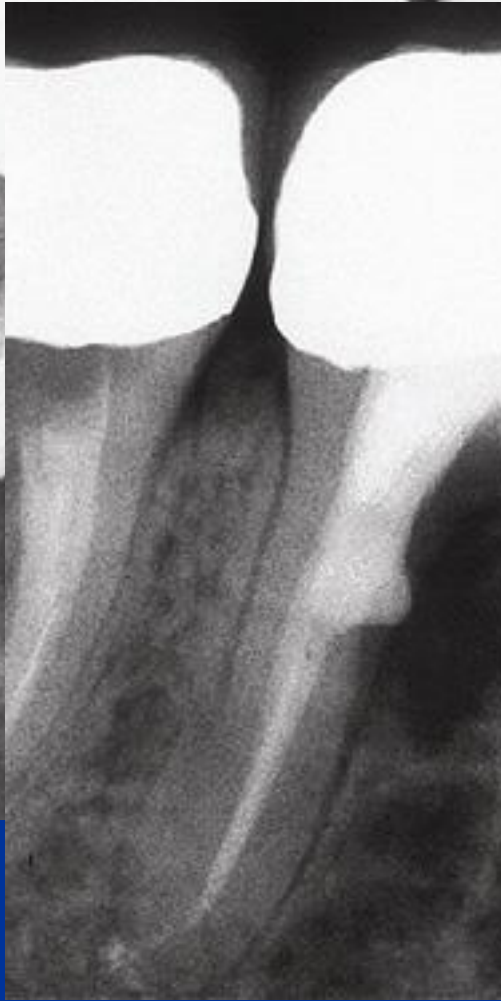
- Umožňuje hojení – dobrý okrajový uzávěr !  
Zabraňuje přístupu mikroorganismům,  
umožňuje hojení dřeně a periodoncia tvrdou  
tkání.

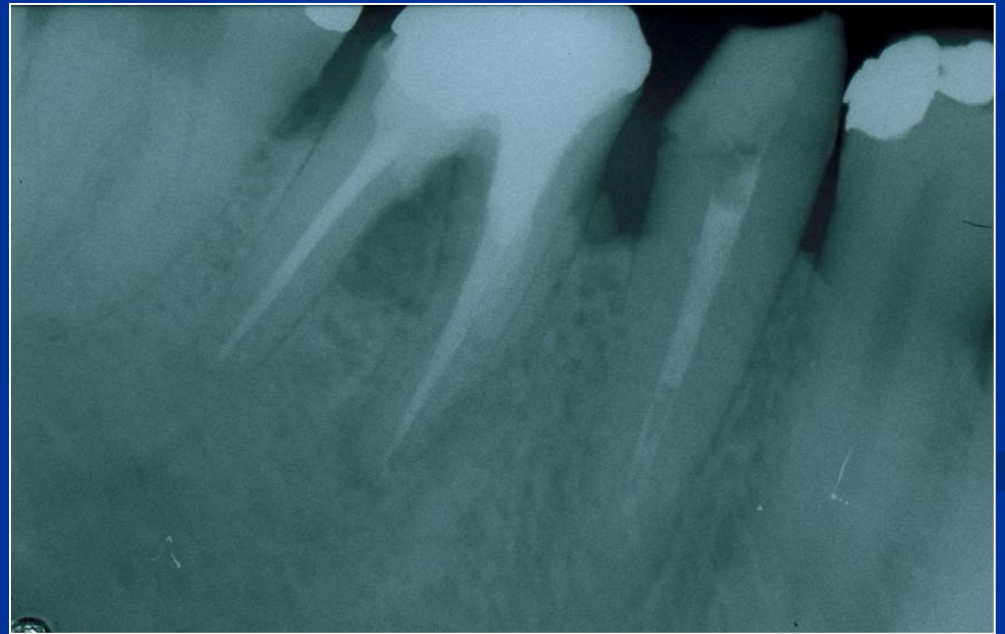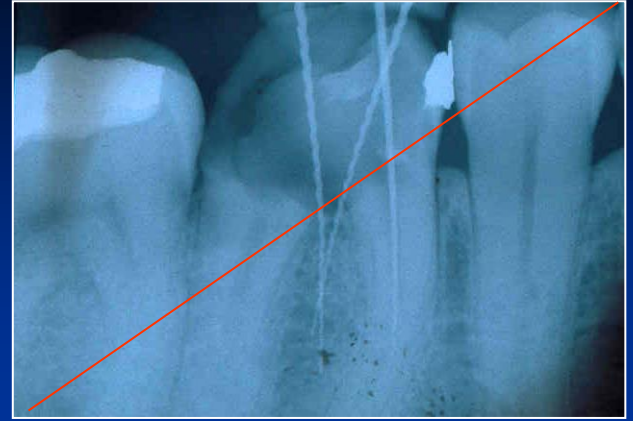

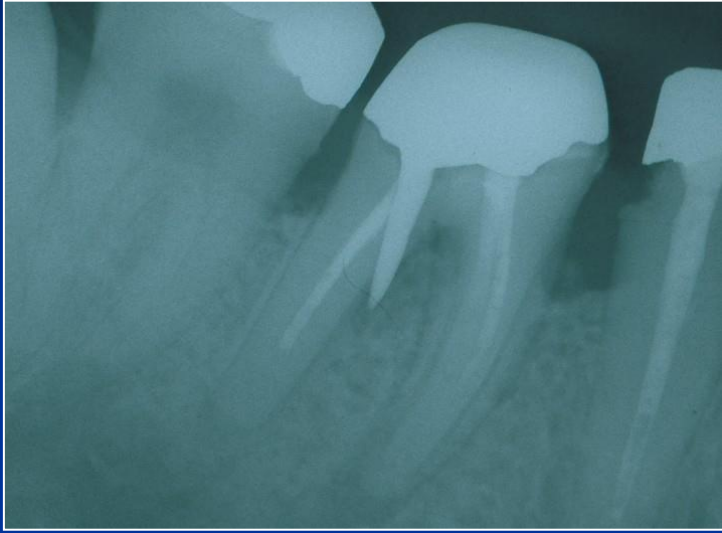


*Zdroj: Manuál firmy Maillefer*

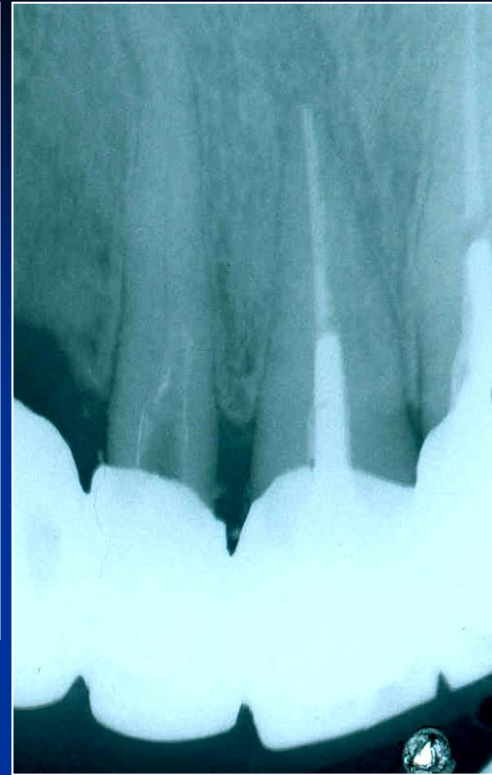
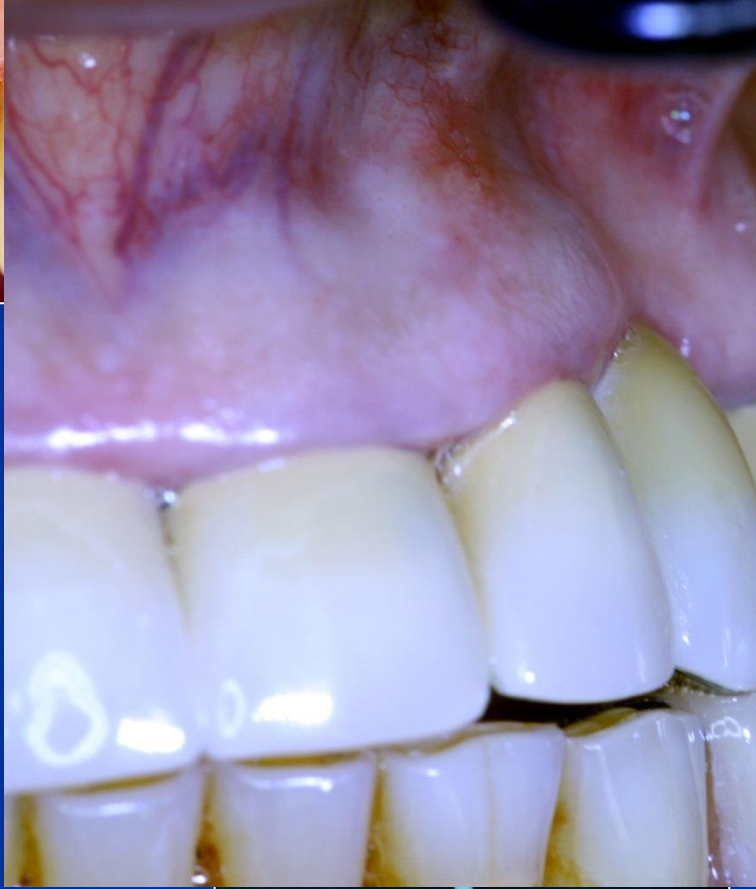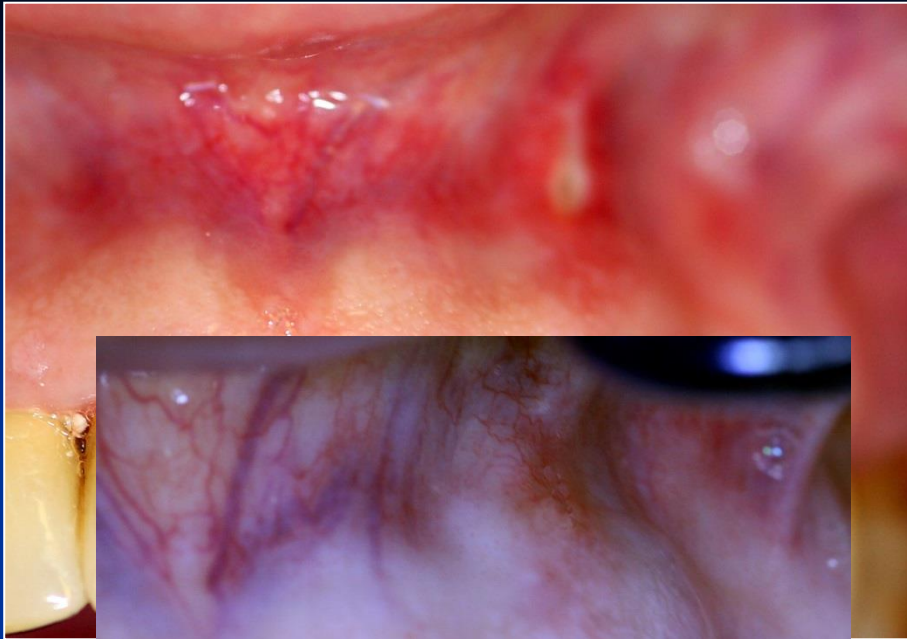


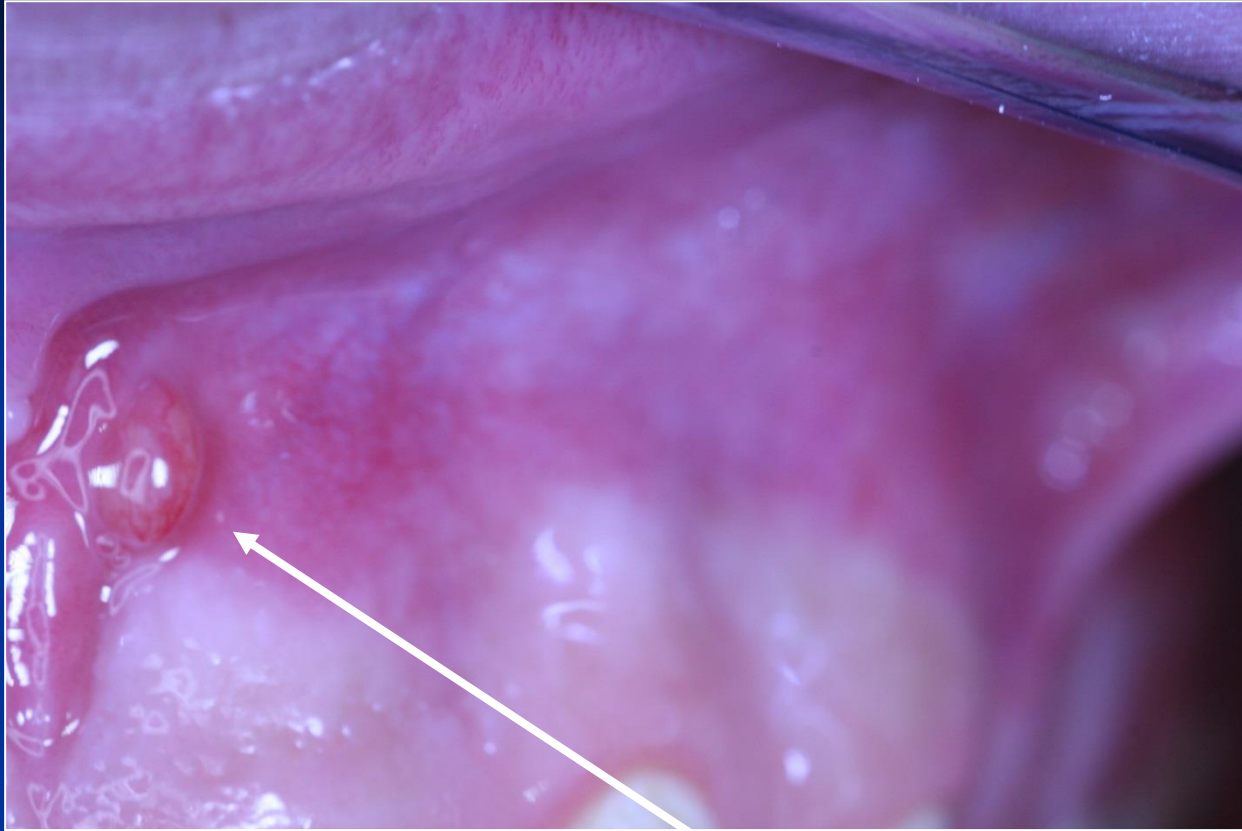




# Regional complications







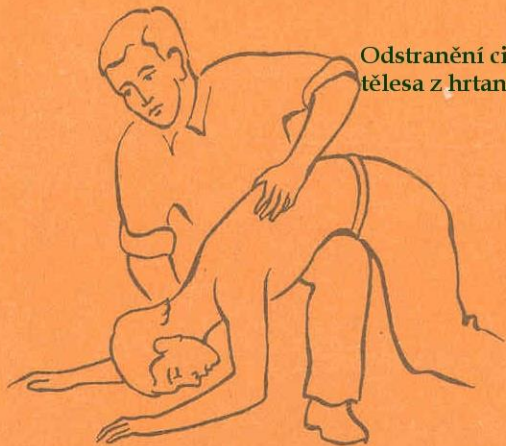
**Fistula**

# Systemic complications

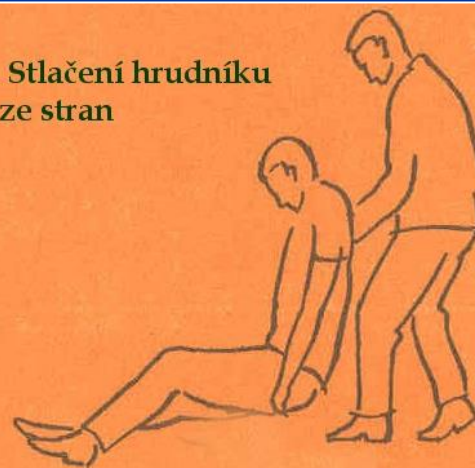# Systemic complications

- Periostitis
- Inflammation of soft tissues (face, neck)
- Gulp of the instrument (X ray, remnant diet, information)
- Aspiration of the instrument - cough

**Odstranění cizího  
tělesa z hrtanu**



**Stlačení hrudníku  
ze stran**



# Caution!

*Always find the lost instrument !!!!!*

# Safety in endodontics

- Rubber dam
- Glasses
- Careful instrumentation, irrigation, filling (WL, recapitulation)