

Radiography

Radiography

- Roentgen tube – x- ray tube:

Cathode – anode – tension

Cathode (heated) - electrons –against anode
– brake - x ray radiation originates



Radiography

- Imaging method completing clinical examination of patients

Radiography

Principle:

X- rays going through various materials
(tissues) are absorbed – image on the film
(a special suspension AgBr – silver bromide)
or digital receptors



Rigid CCD Digital Sensor
Sirona Dental Systems,
LLC

Digital Phosphor Plate
Air Technique, Inc.


F-Speed Dental Film
Kodak Dental Systems

Roentgen tube X ray tube

Cathode
wolfram
(tungsten) filament inside
(heated – brought to white heat)

Focus – made of wolfram

Anode



Extraoral and intraoral radiography

- Extraoral:

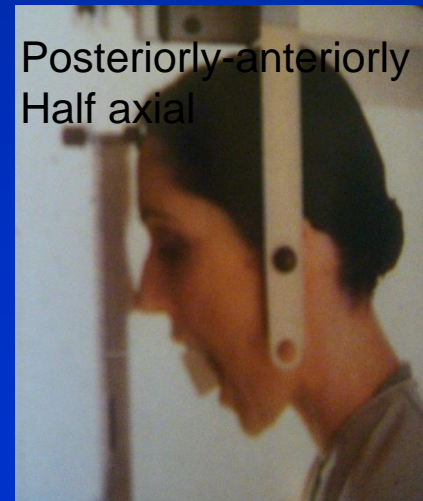
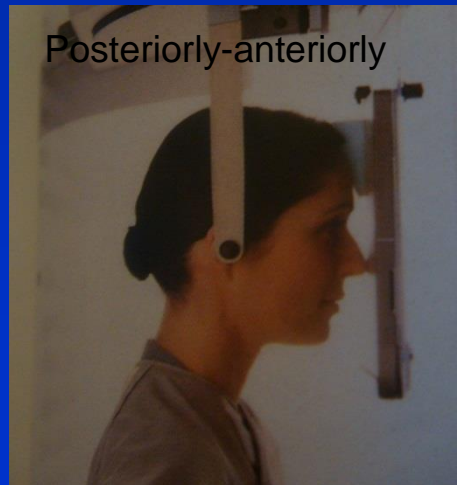
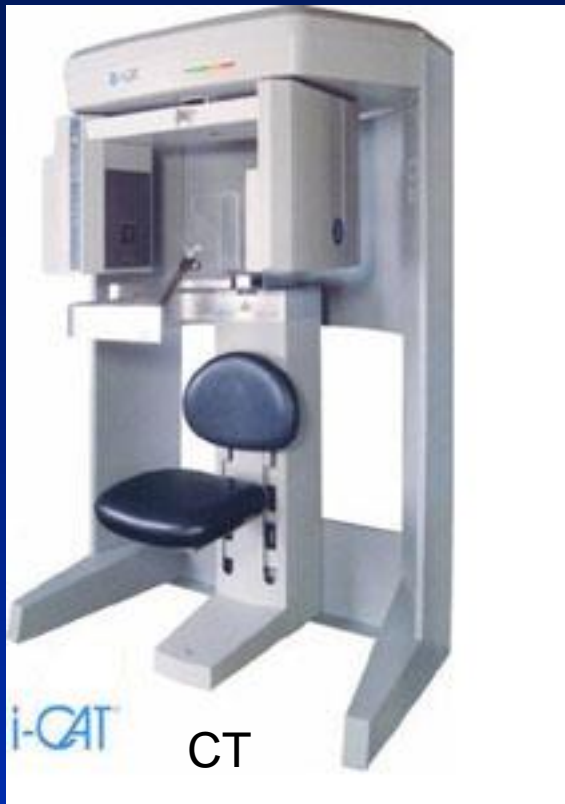

The film is placed outside of oral cavity

- OPG (orthopantomography)
- Teleradiography
- Special projections of a skull (posteriorly – anteriorly)
- Half axial
- Side projection (TMJ, mandible)
- CT

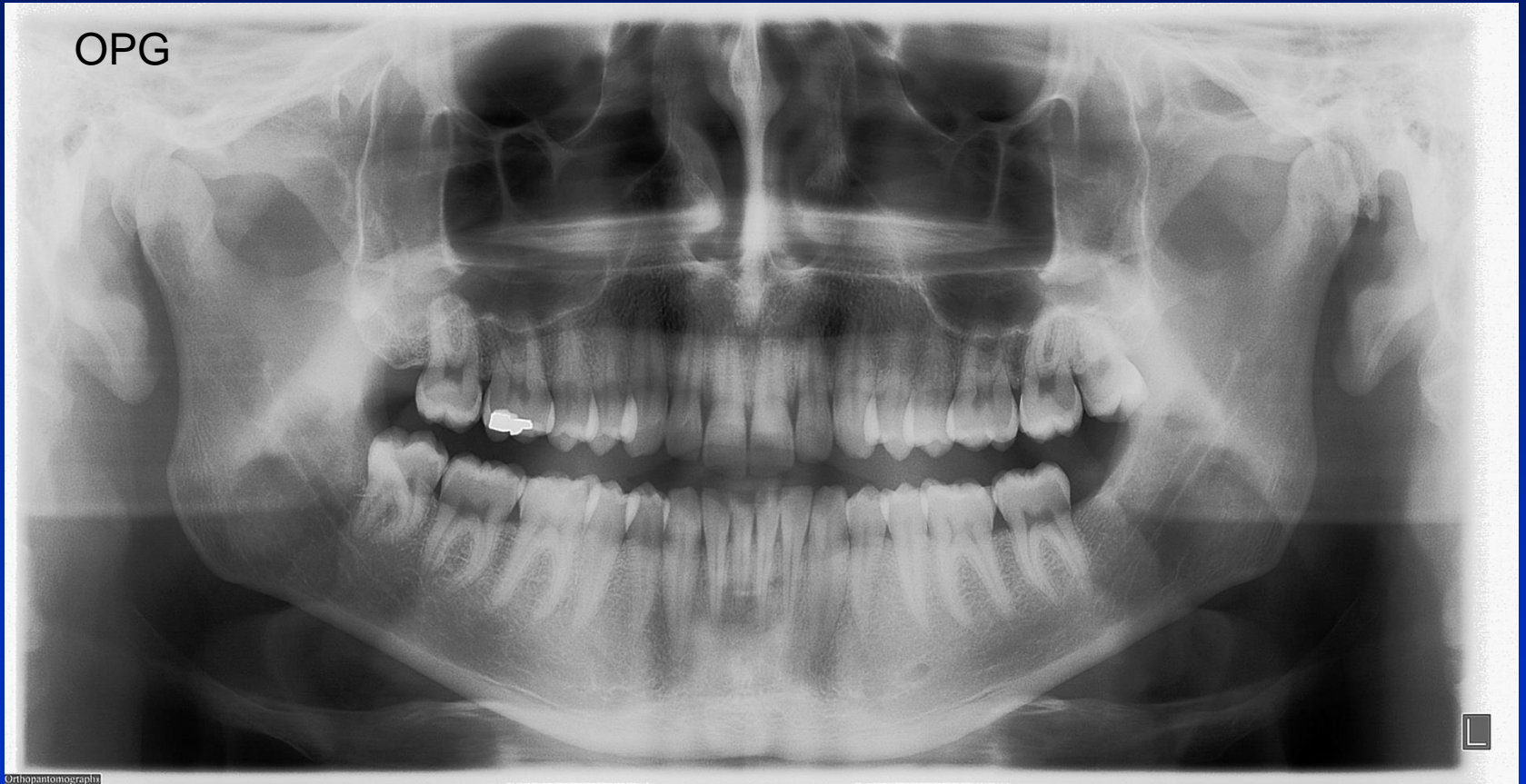Extraoral and intraoral radiography

Intraoral – the film is placed in the oral cavity – a special x-ray apparatus.

- Teeth
- Alveolar bone
- Periodontal space
- Fillings
- Caries
- Level of endodontic treatment



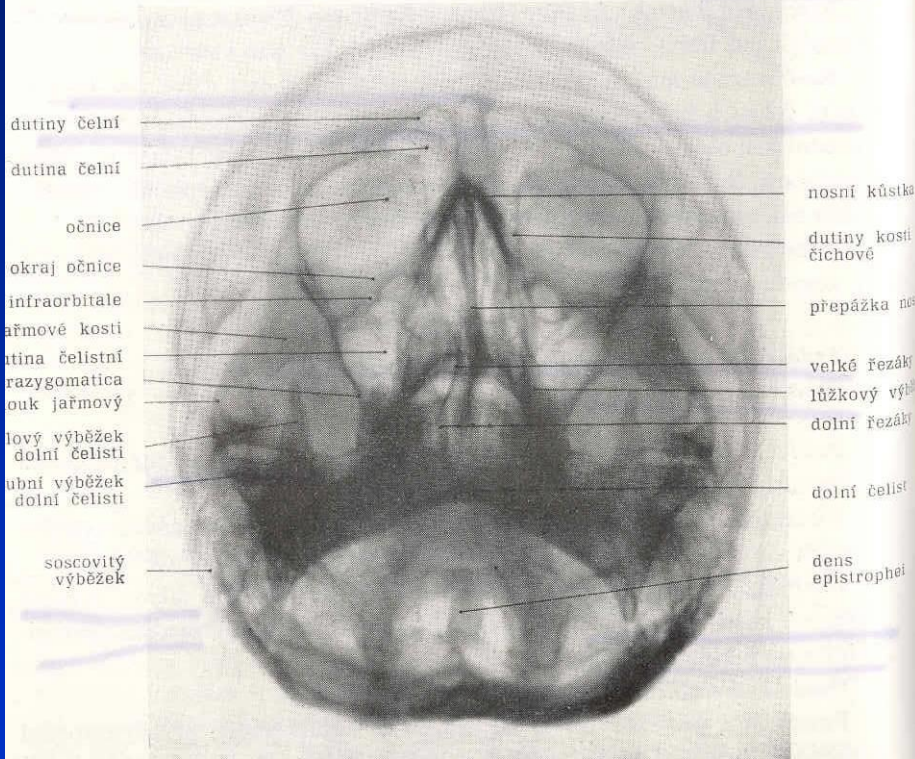
OPG



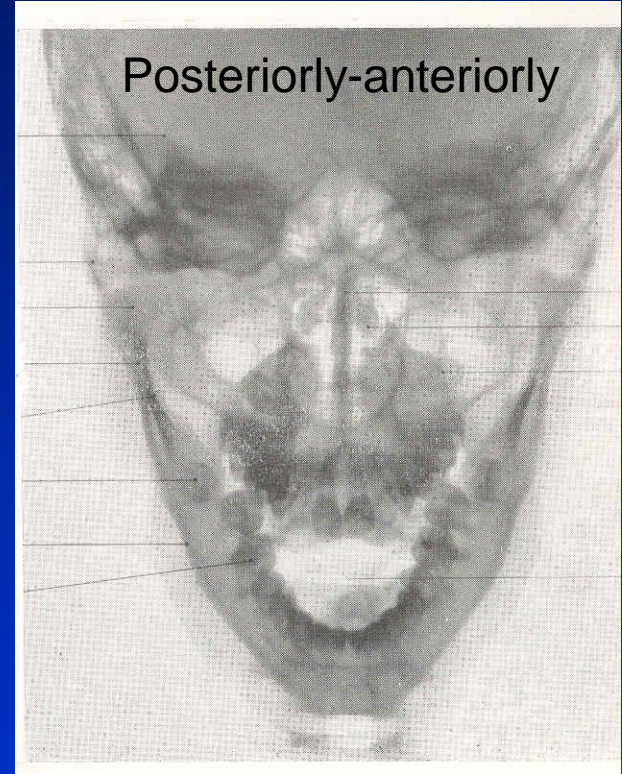
pohled zpredu

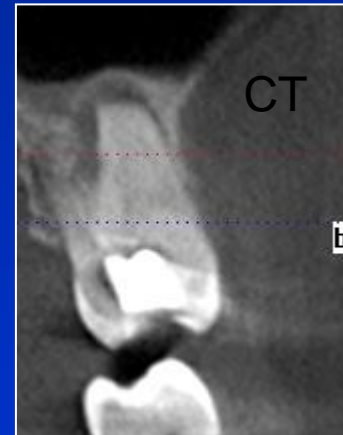
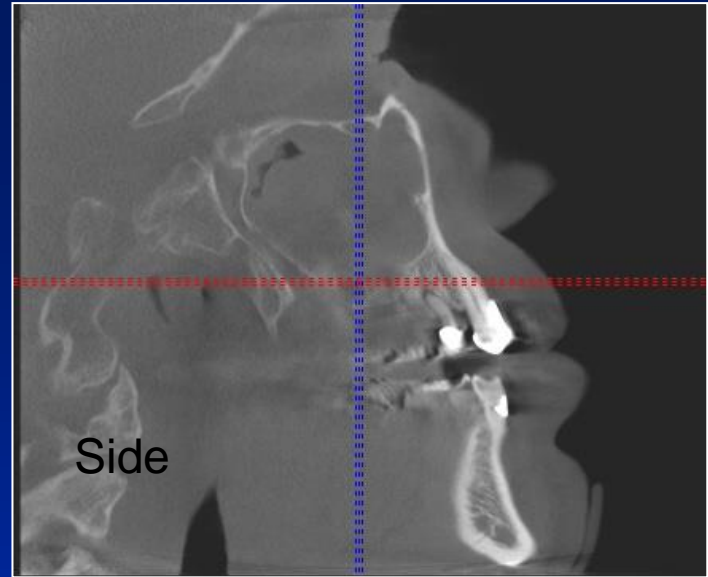
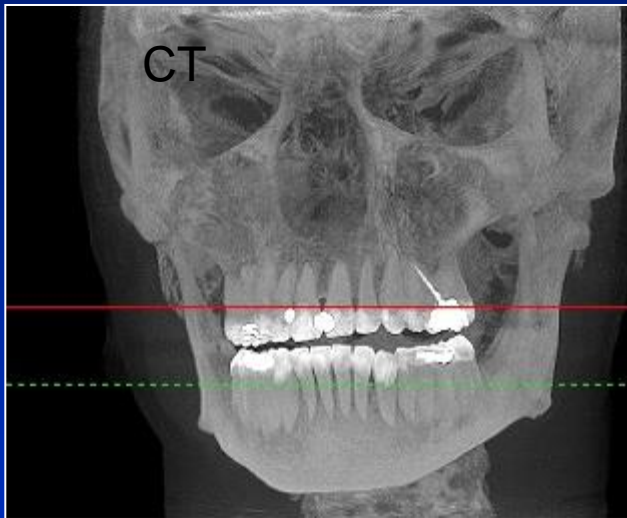
pohled z boku

Half axial



Posteriorly-anteriorly





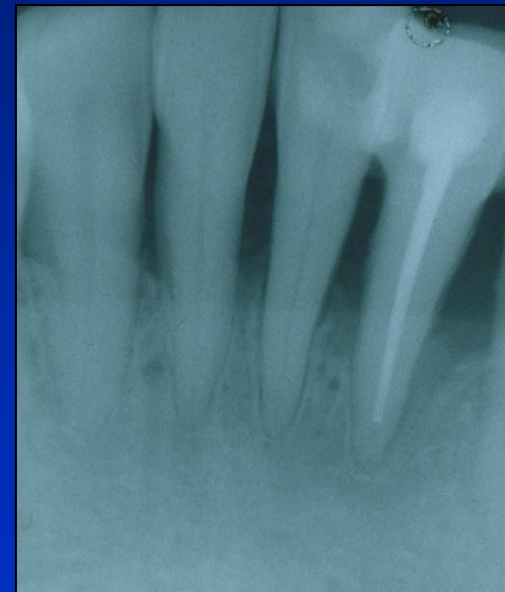
CT, 3D possibility

Intraoral radiography

Film or receptor placed in oral cavity

Special apparatus

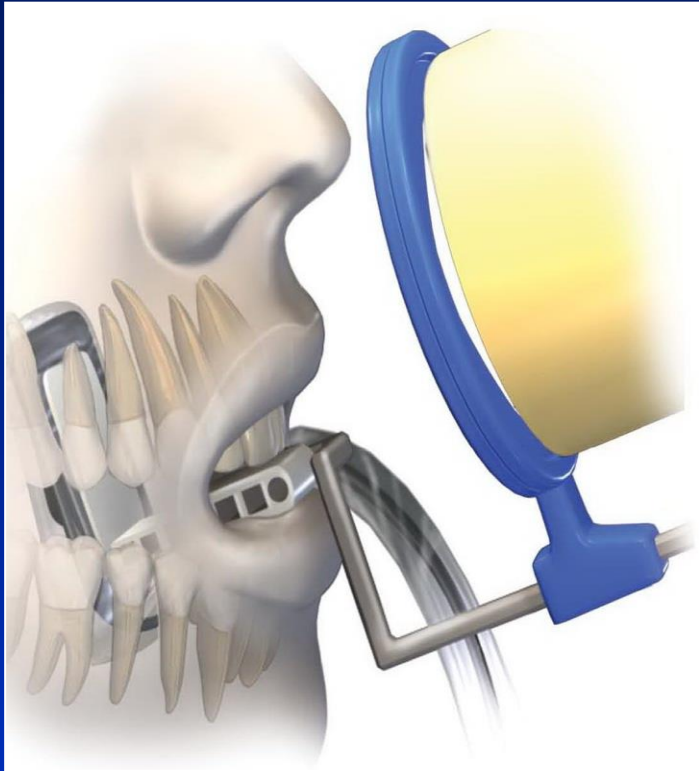
- Teeth
- Alveolar bone
- Periodontal space
- Fillings
- Caries
- Impacted teeth
- Level of endodontic treatment



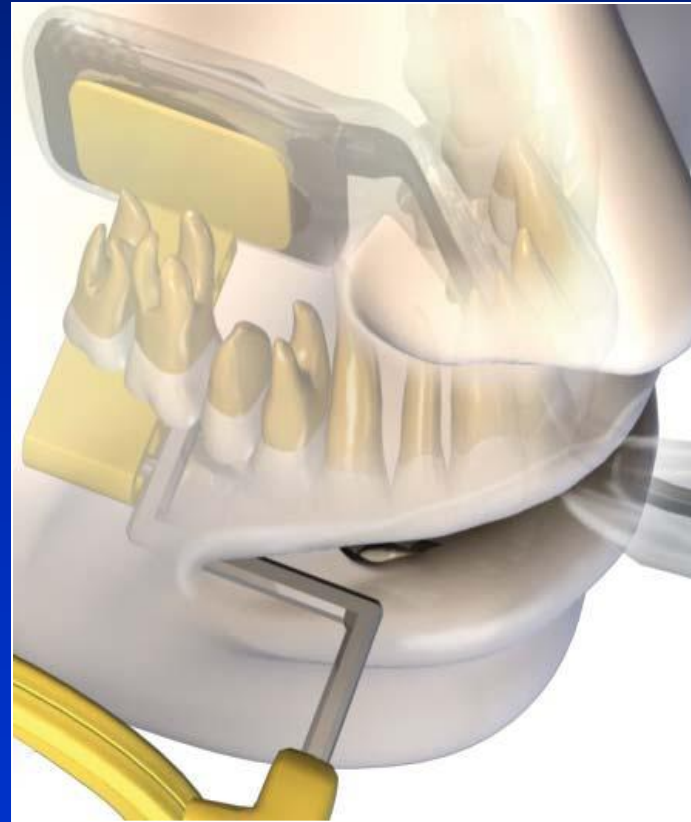
Position of the tubus

- In vertical plane
- In horizontal plane

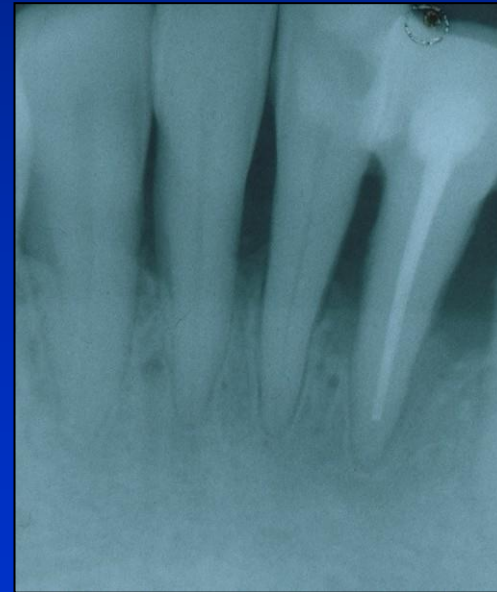
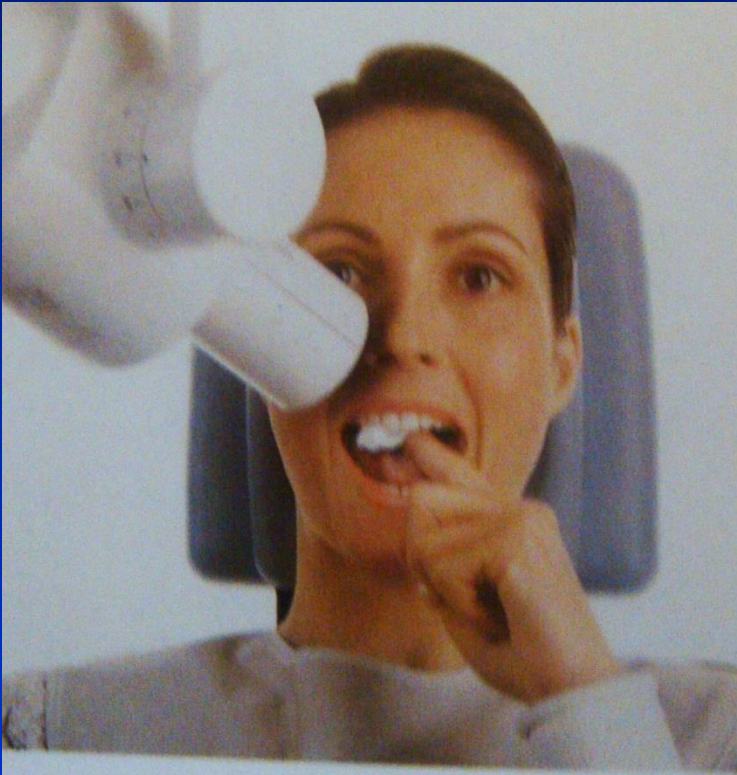
In vertical plane



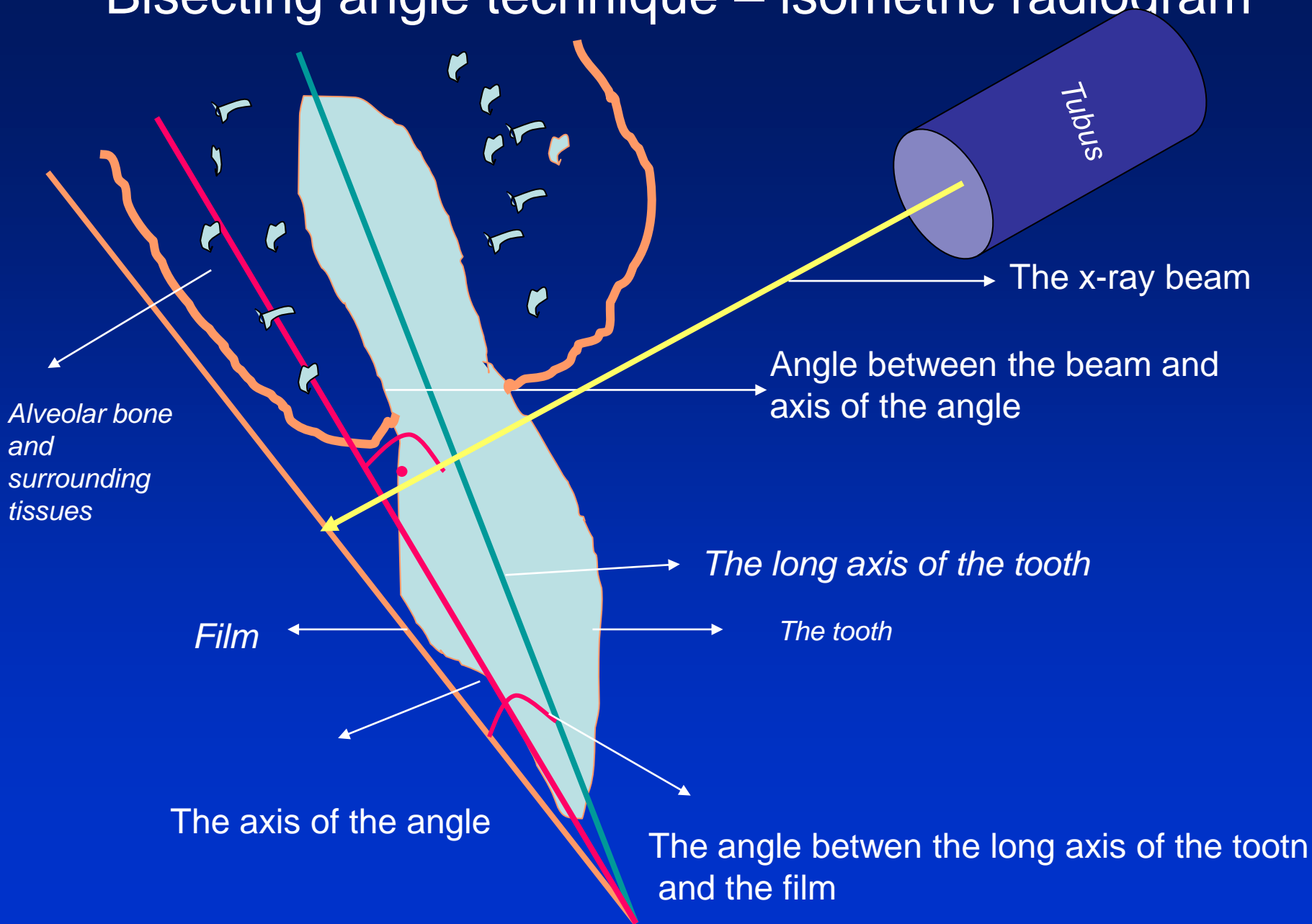
Paralleling technique
Film or receptor in a special holder
Parallel to long axis of teeth



If paralleling technique is not possible use the bisecting angle technique



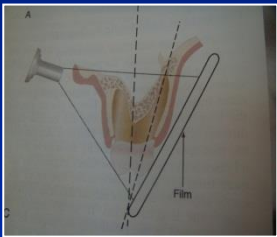
Bisecting angle technique – isometric radiogram



Hypometric and hypermetric picture

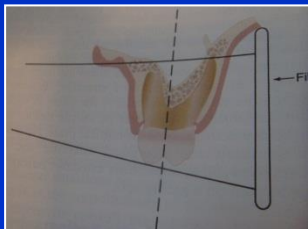
Hypometric – the picture is smaller

Central beam goes perpendicular on the tooth



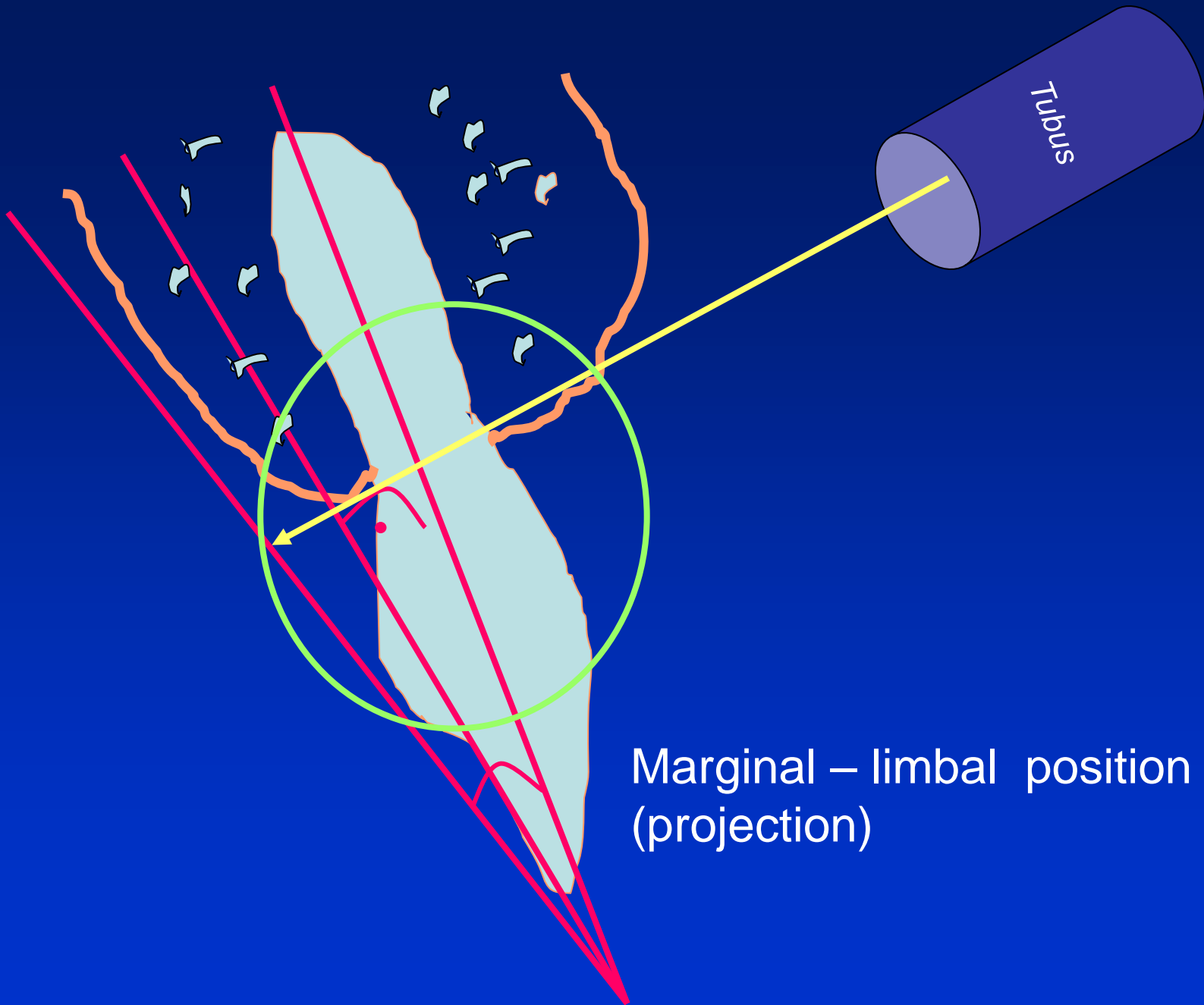
Hypermetric picture – the picture is bigger

– central beam goes perpendicular to the film paprsek goes perpendicular to the film.

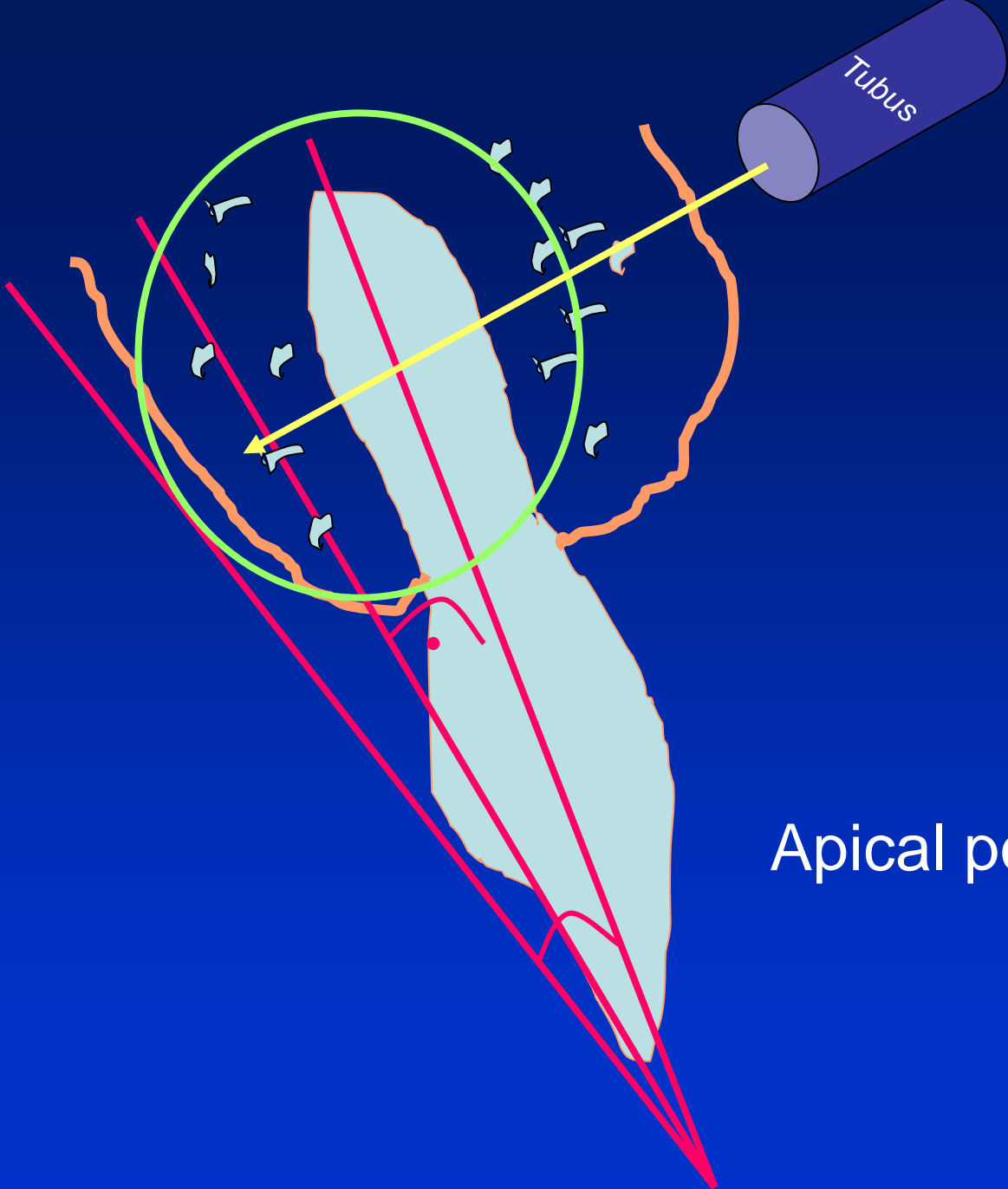


The tubus can have various position

- Apical projection: the central beam goes through the apex area
- Periodontal projection: the central beam goes through the uper third of the root
- Coronal projection: the central beam goes through the crown.



Marginal – limbal position
(projection)

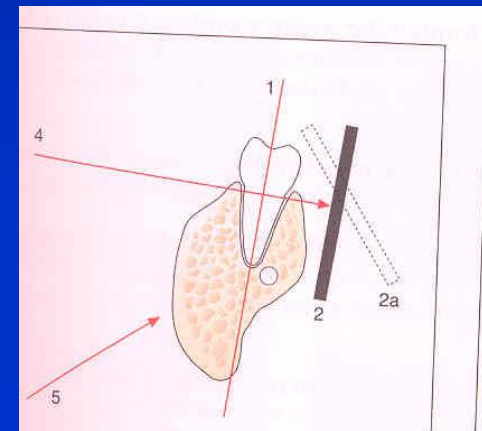
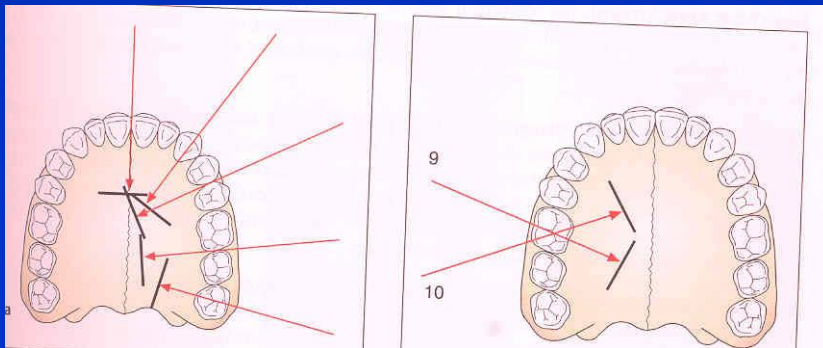


Apical position - projection

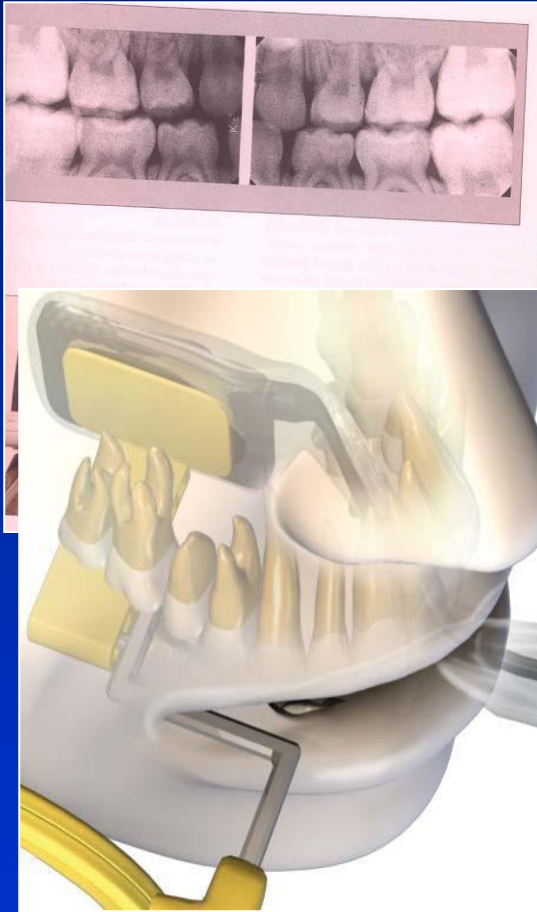In horizontal plane

Orthoradial and excentric projection

- Orthoradial – the central beam goes parallel to interdental septa
- Excentric— the central beam goes from distal or mesial side. (Useful for endodontics or impacted teeth esp. canine)



Bitewing



Film or receptor is placed in a special holder, patient bites into

The central beam goes parallel to interdental septa

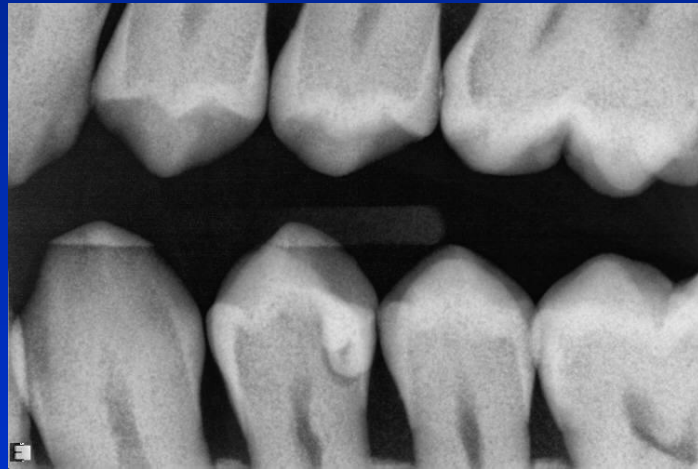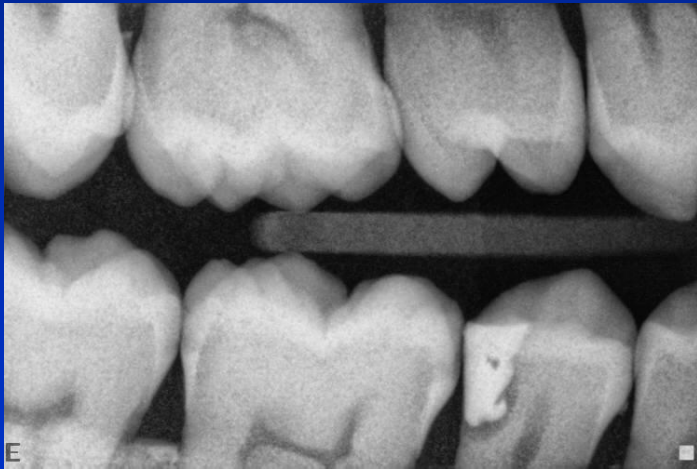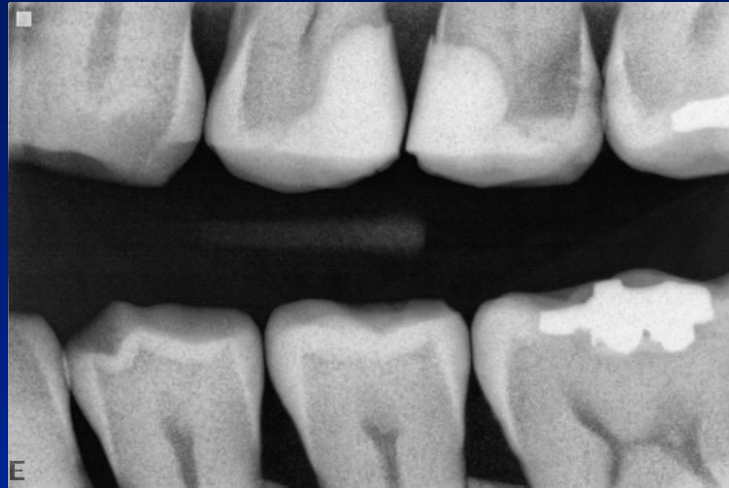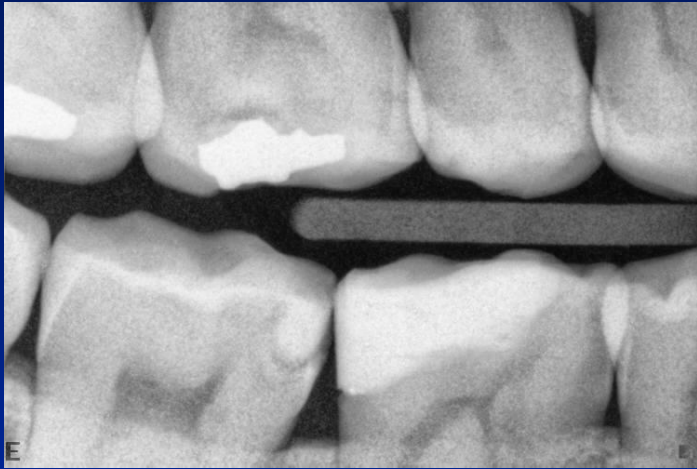Crowns of teeth are well seen
– good for early diagnosis of dental caries in posterior area

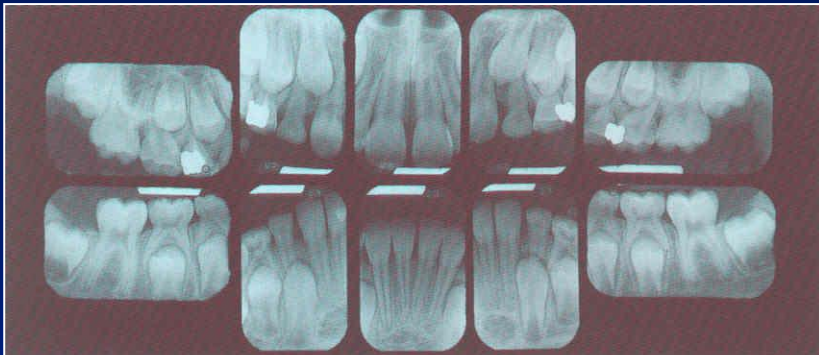
Principle of imaging

- Irradiation is absorbed in various materials esp. in hard tissues. Accc to amount of absorbed irradiation radioopacity or radiolucency can be seen.

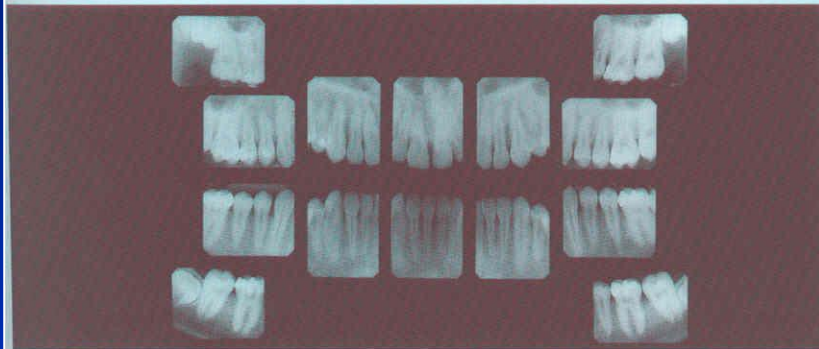
Radiolucency – dark

Radioopacity - white

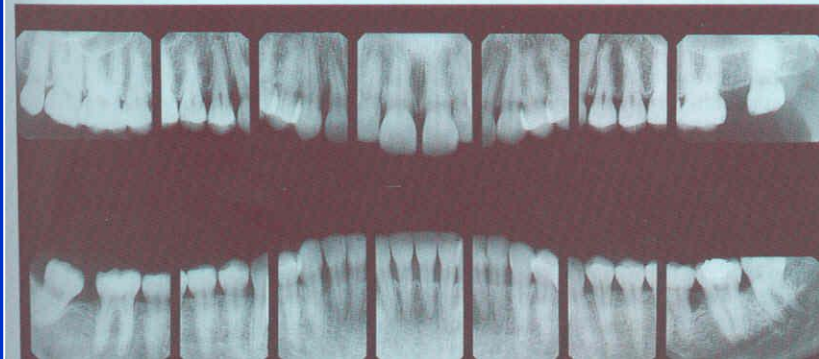




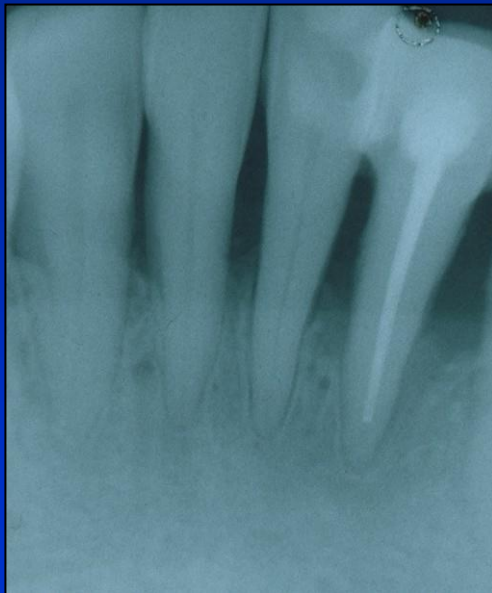
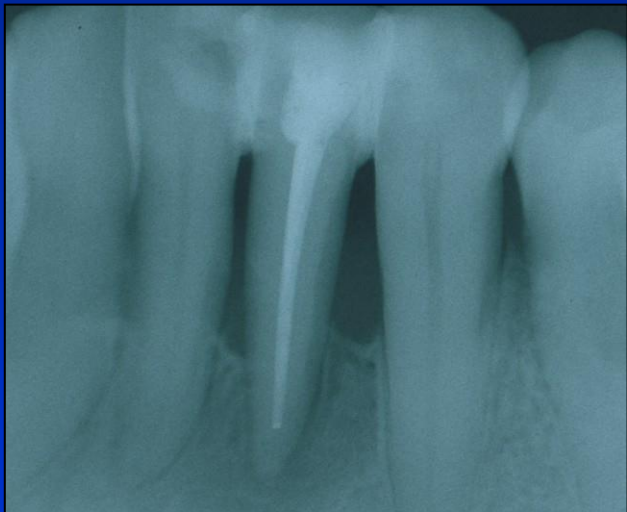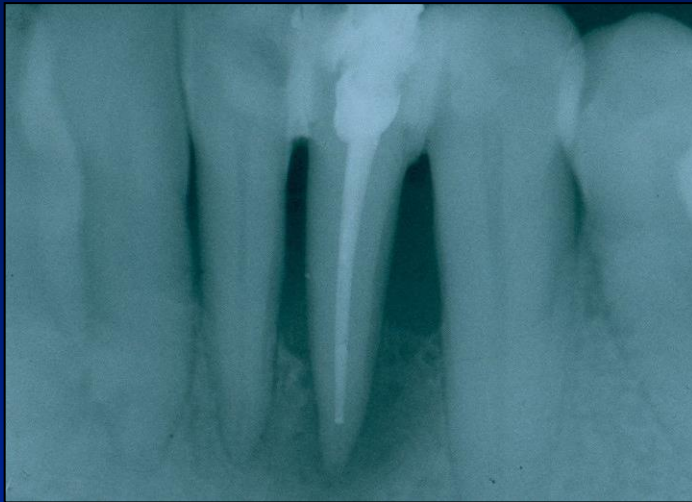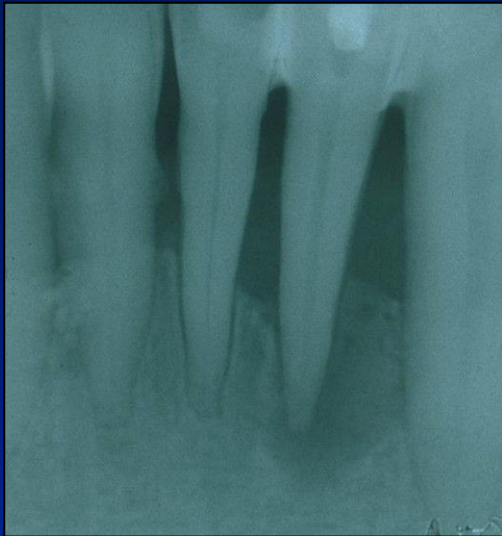58



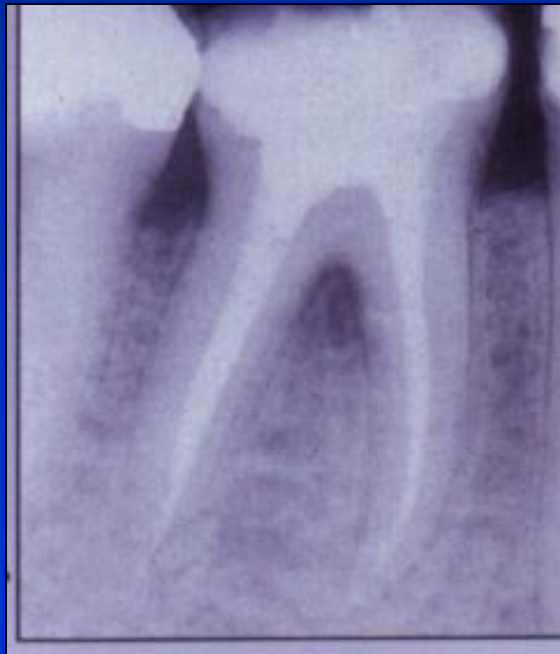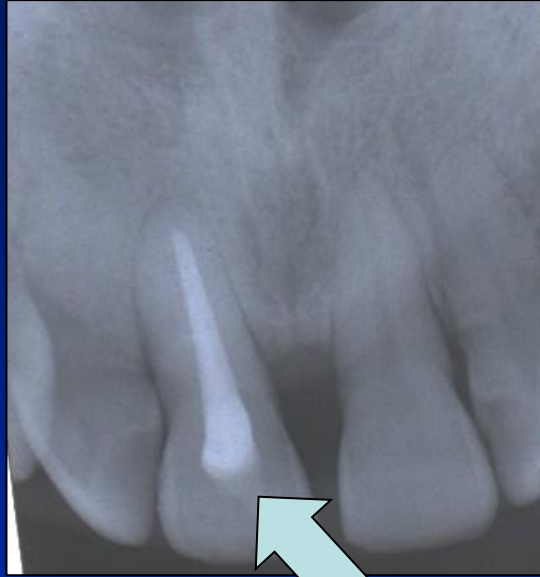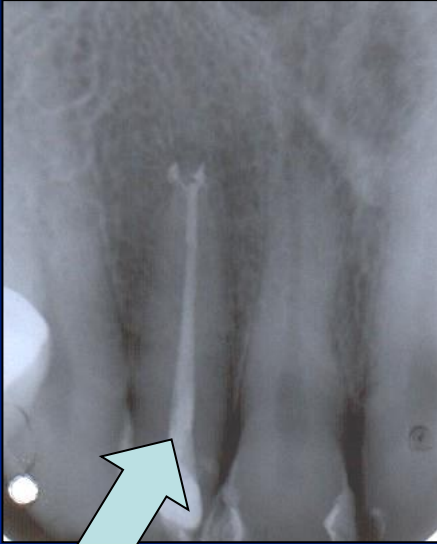
59

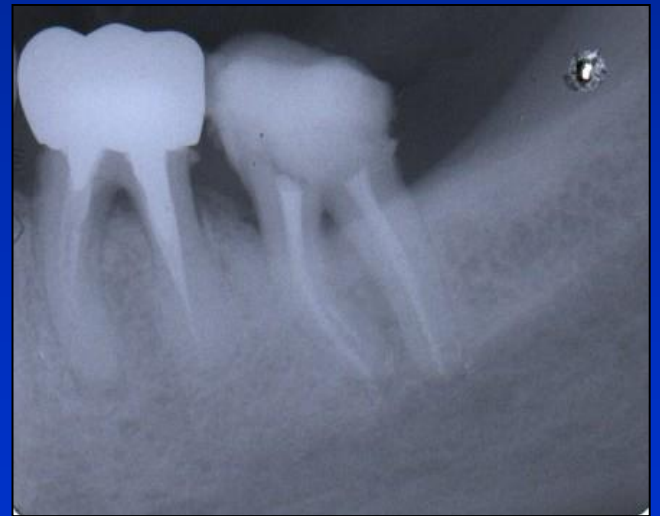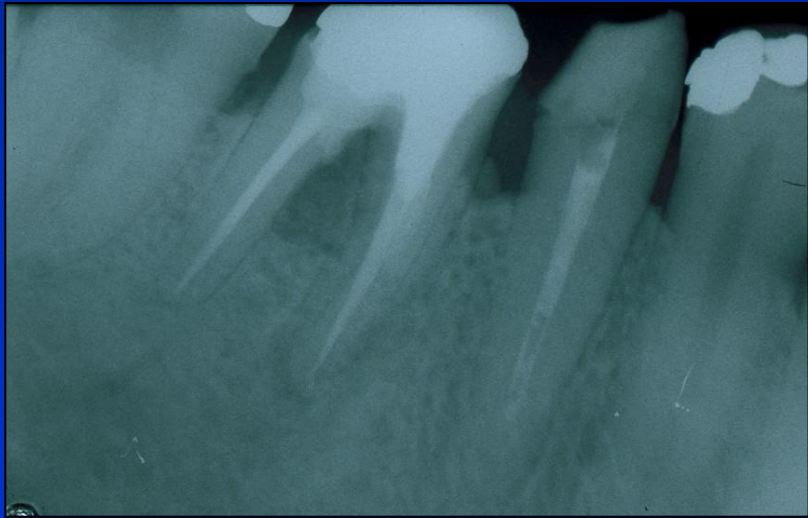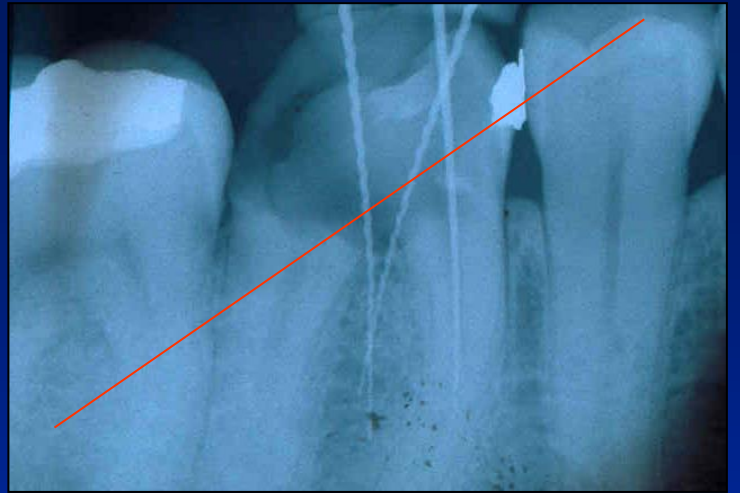


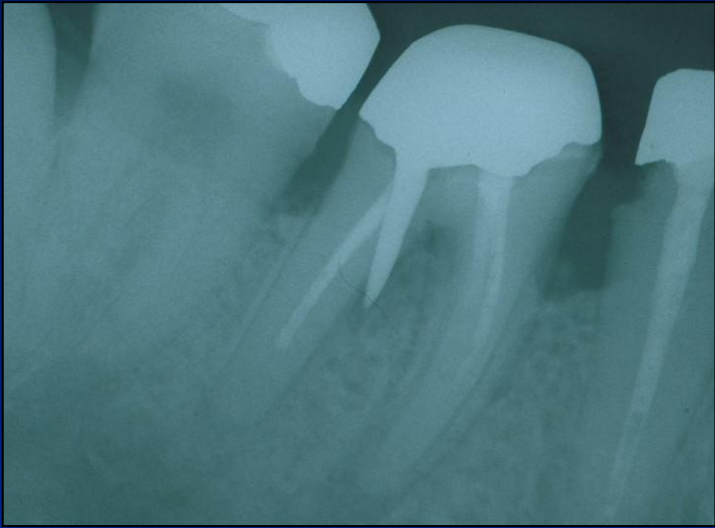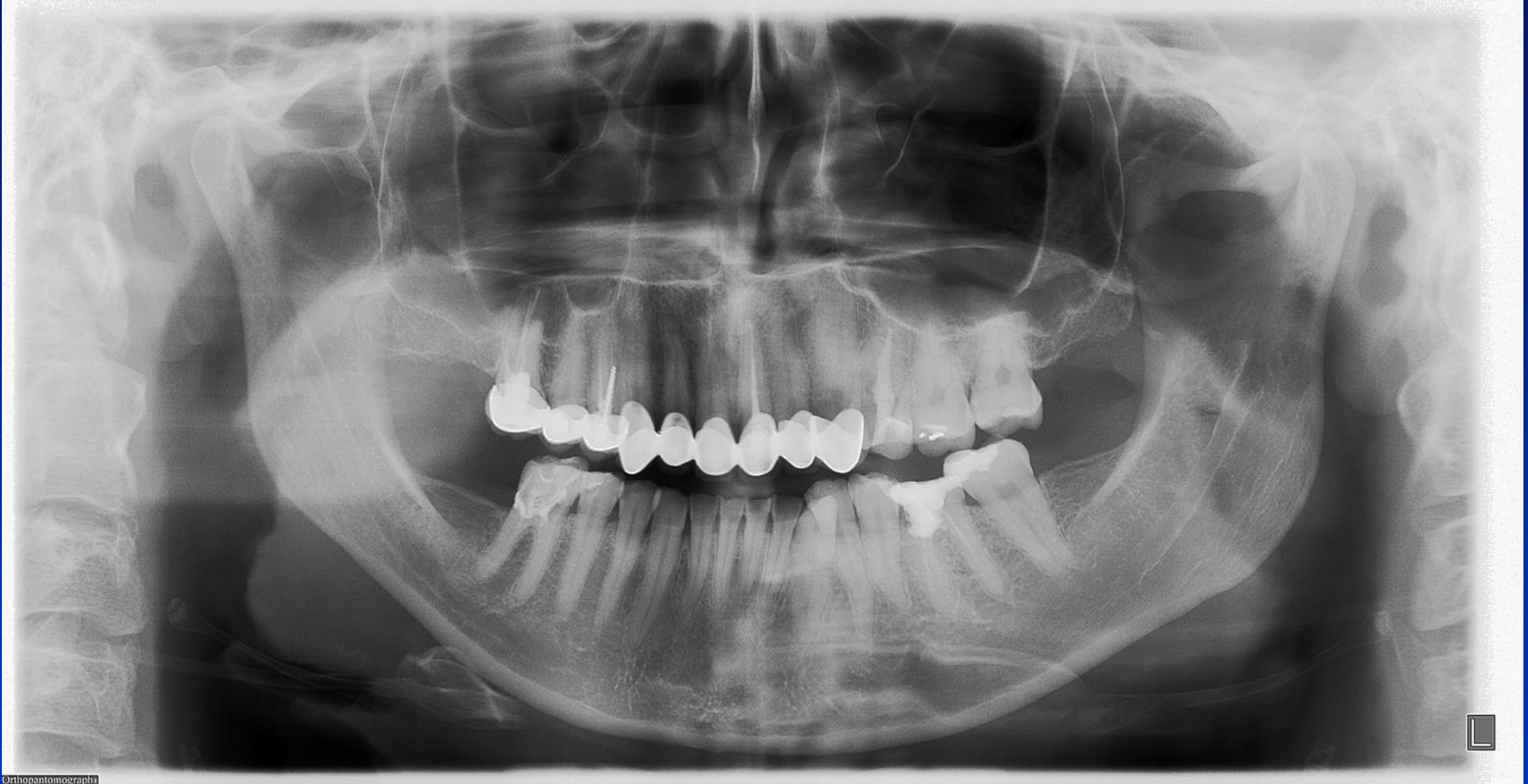- Rtg status



i.o.

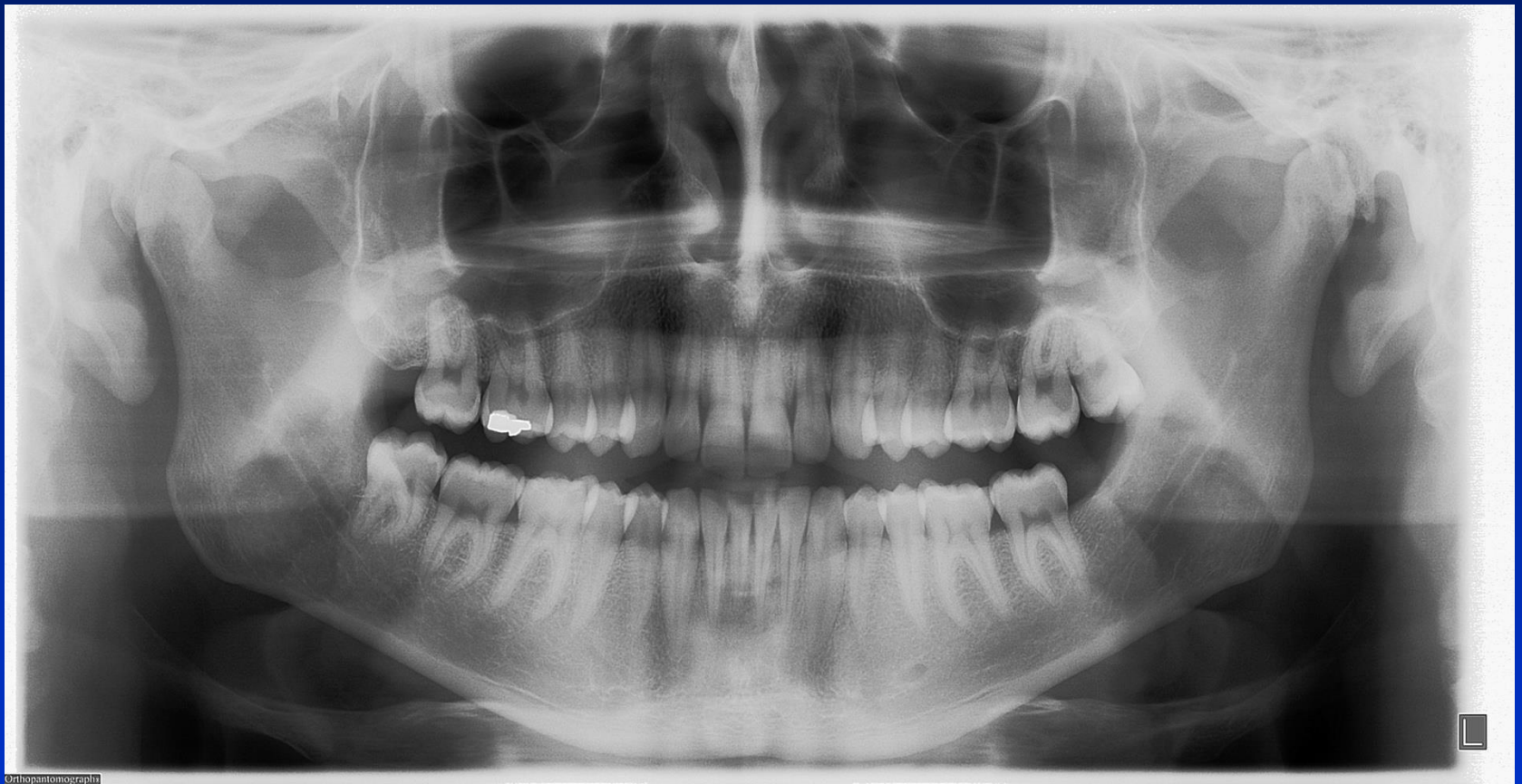





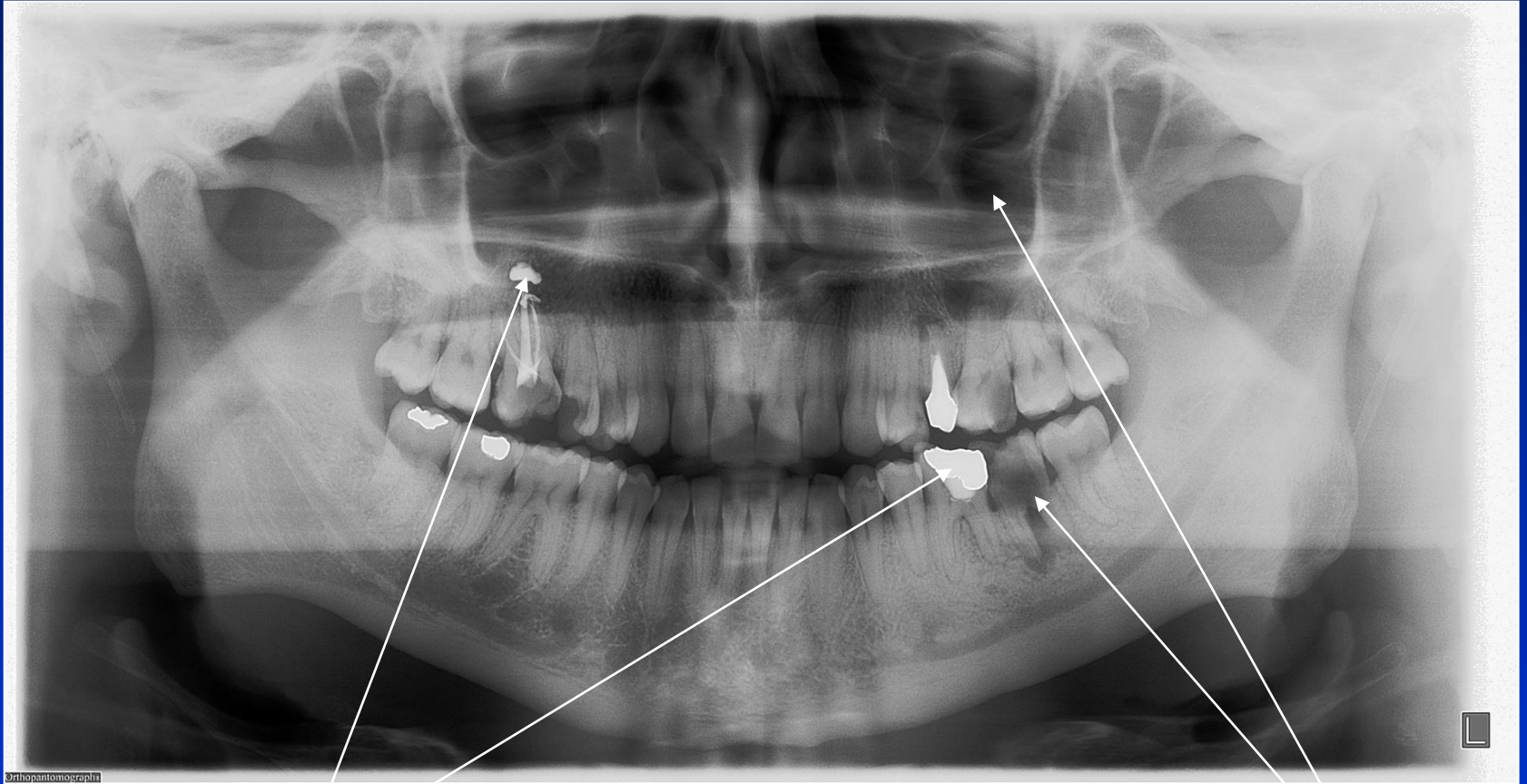
Orthopantomograph

OPG



Orthopantomograph



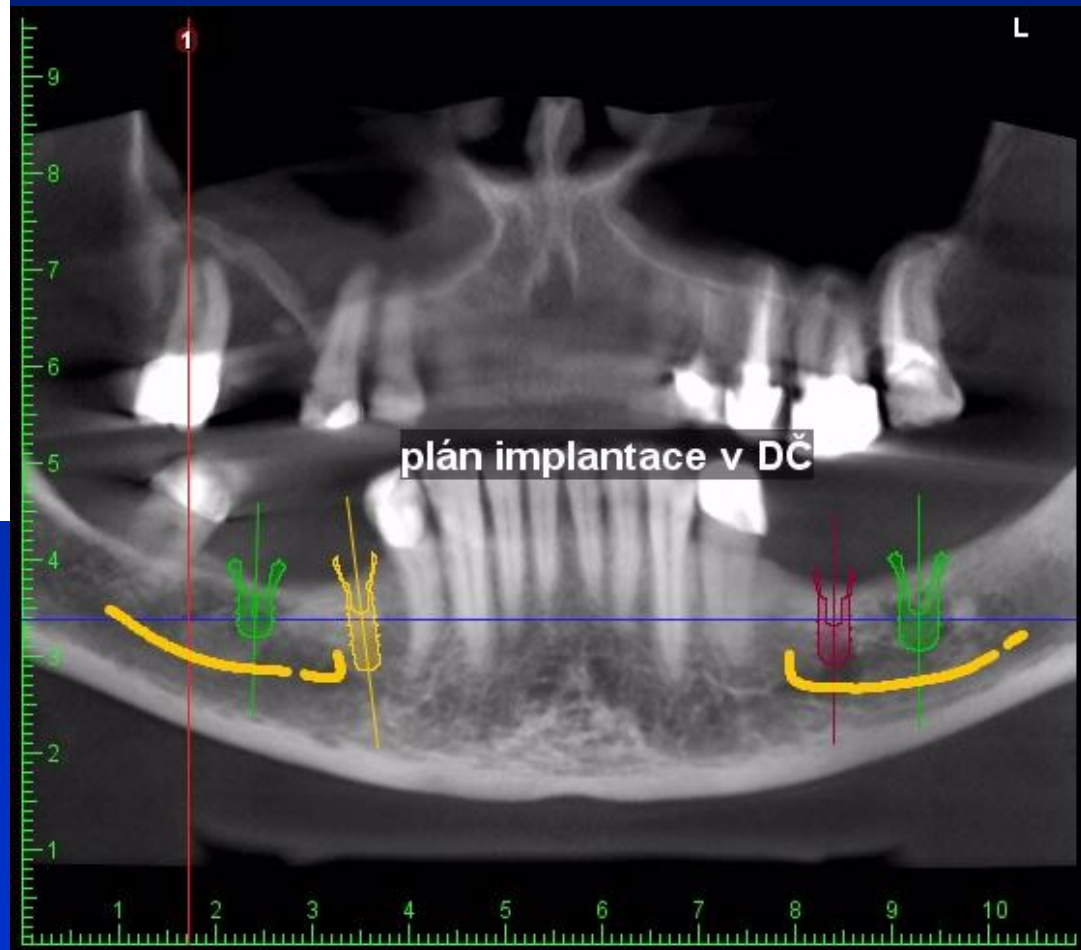
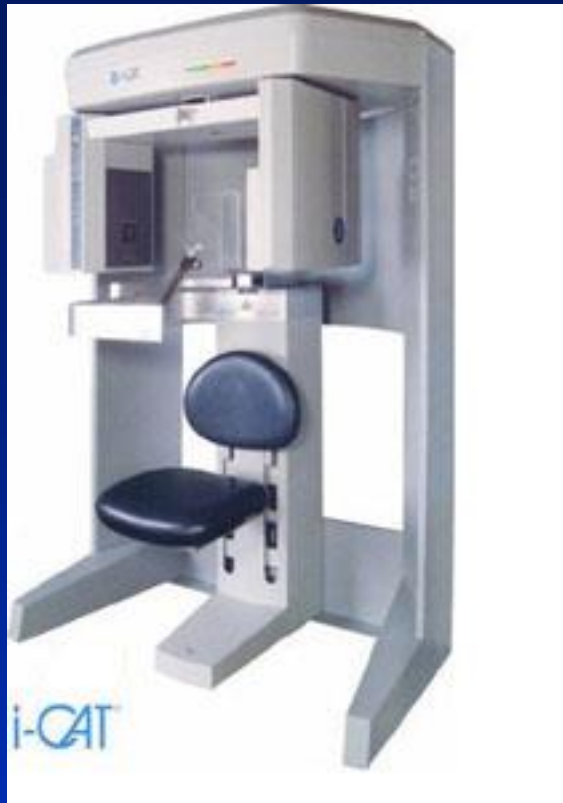

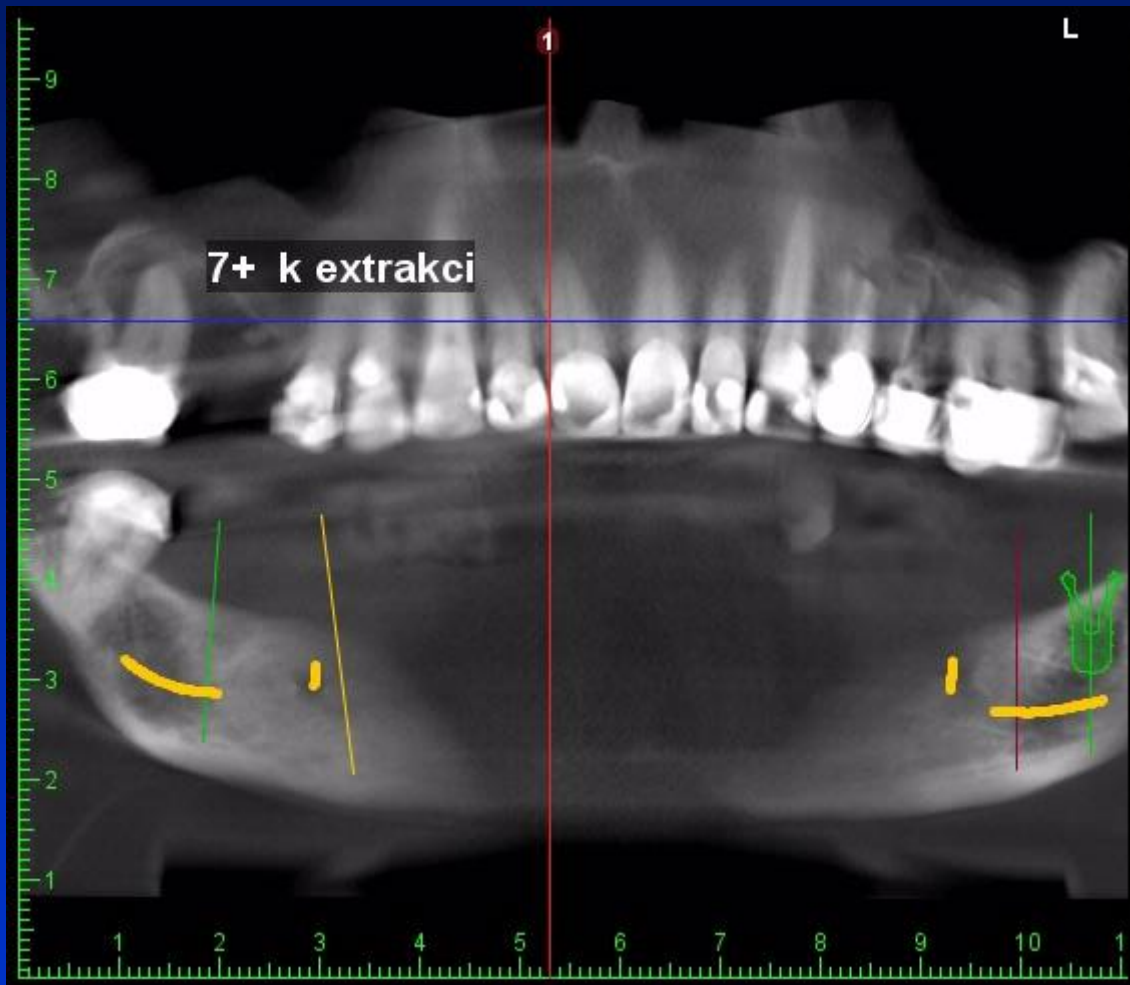Orthopantomograph

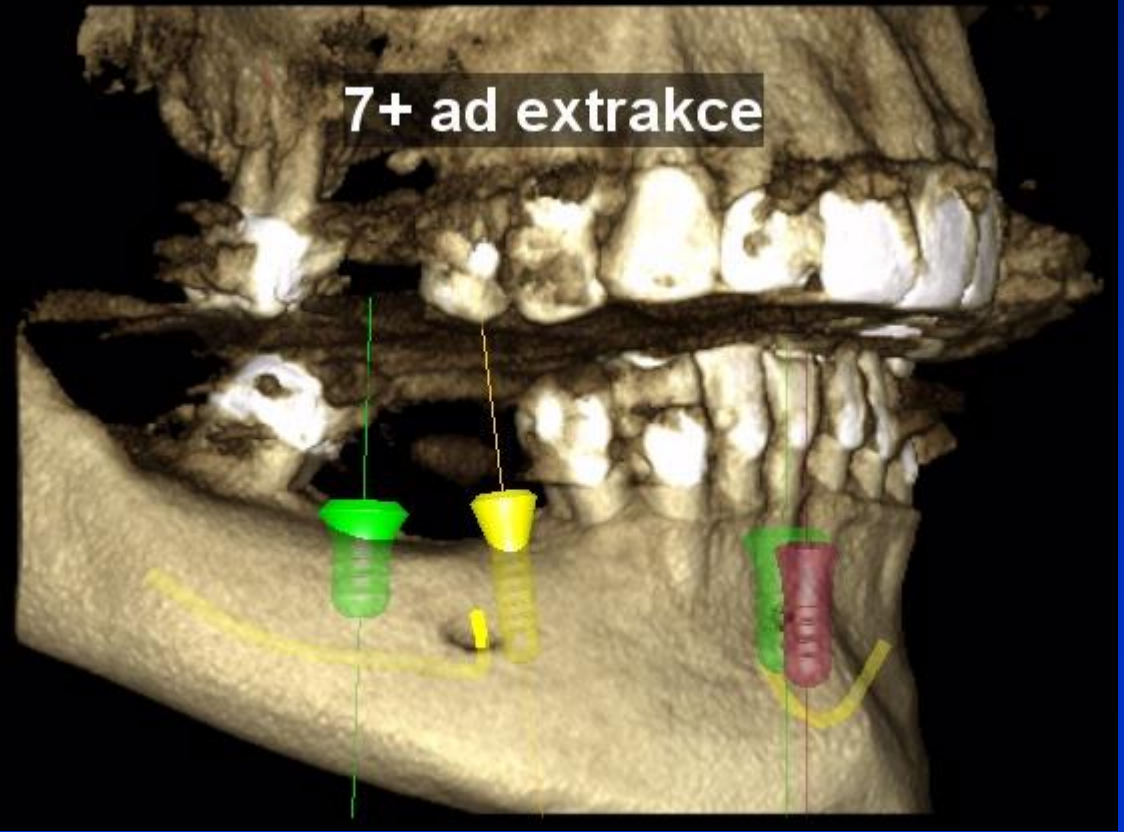
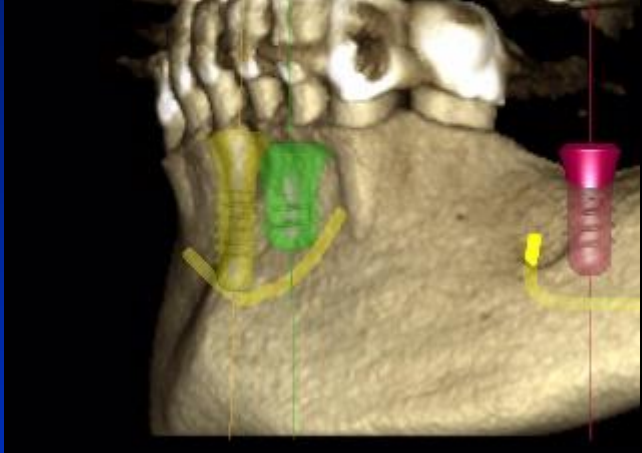
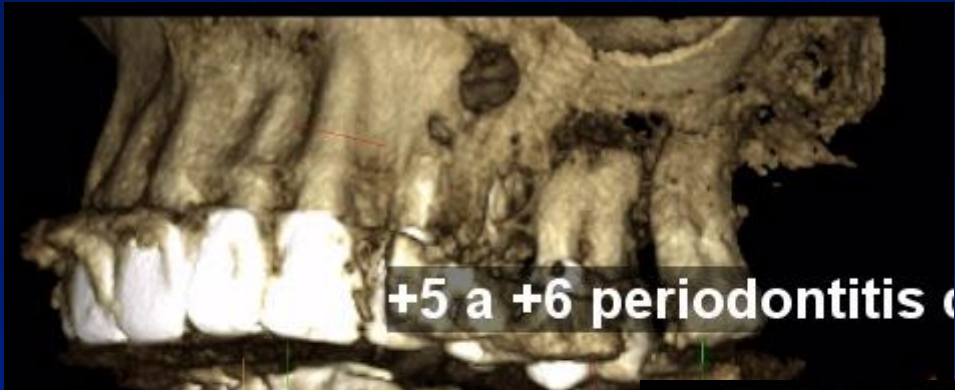radioopacity

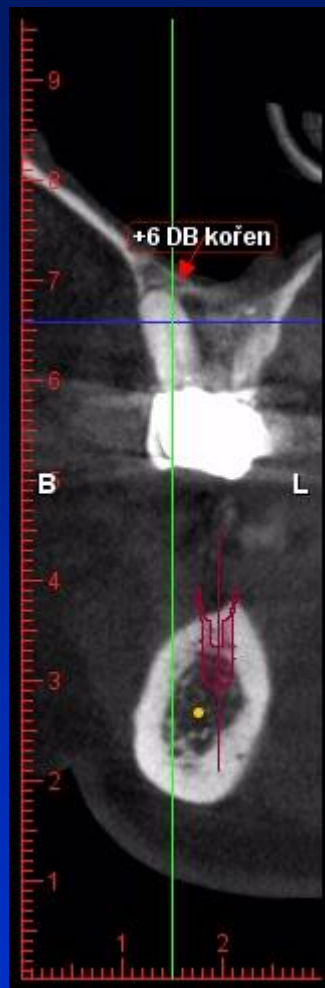
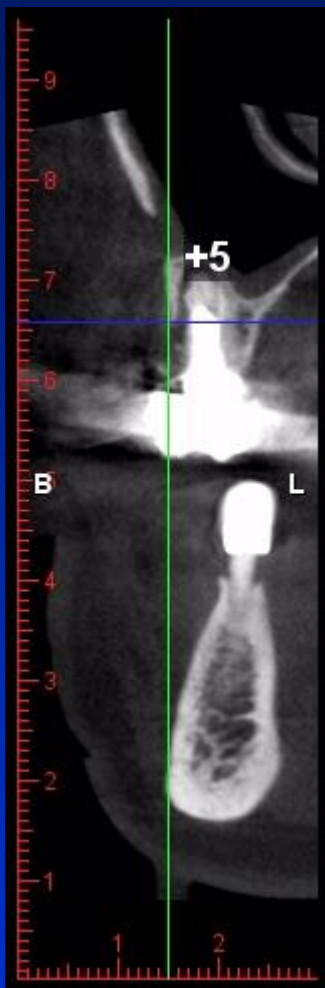radiolucency

CBCT



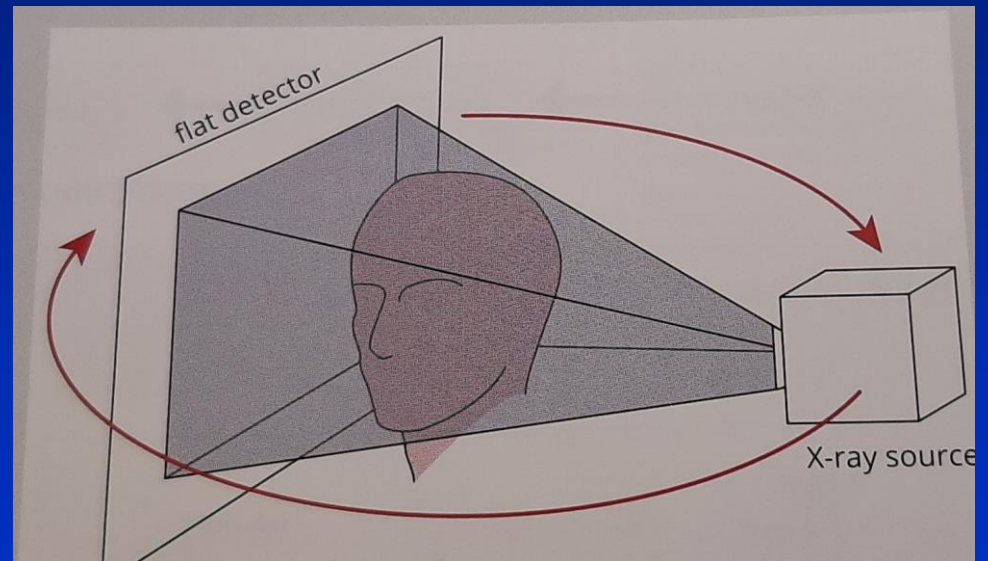






CBCT – cone beam computer tomography

CBCT
Source and detector rotate

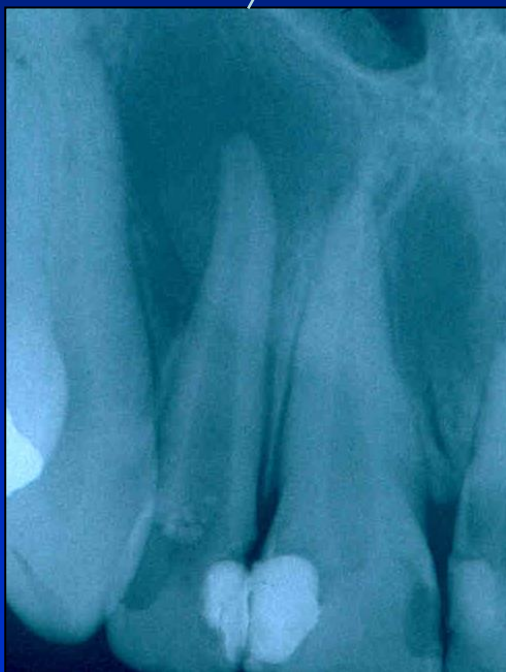

CBCT – cone beam computer tomography

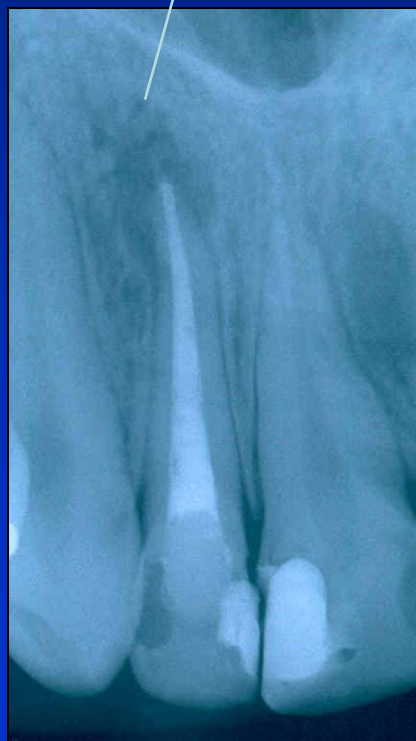- High diagnostic effect
- Endodontics
- Omplantology
- Surgery
- Traumatology



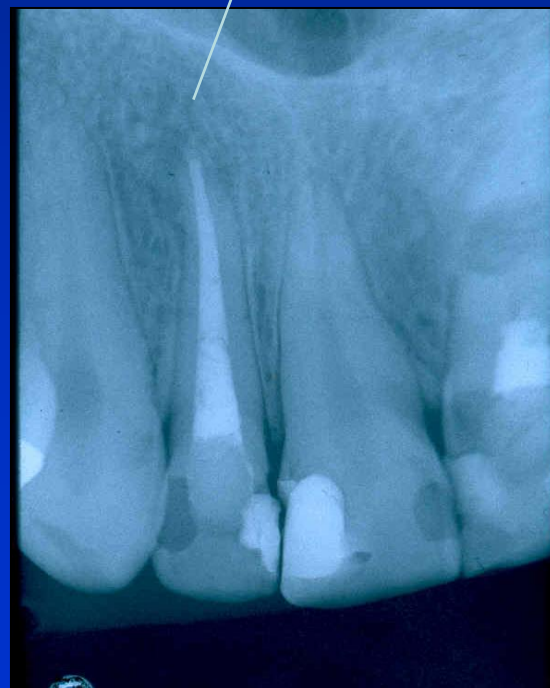Radiogram before the treatment





Radiogram after the treatment



Radiogram 6 month post.op.





Radiogram with inserted root canal instrument