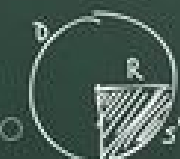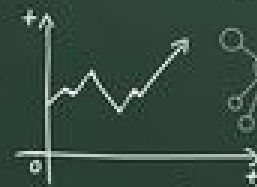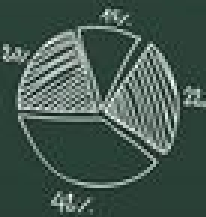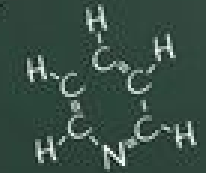




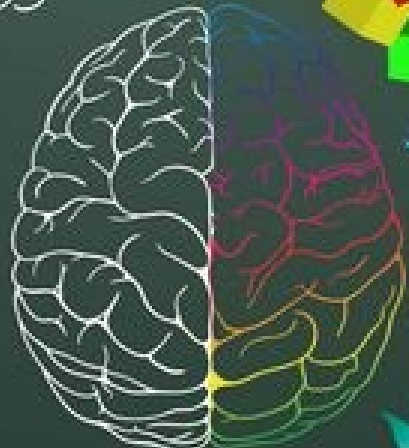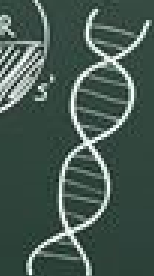PROJECT



$$x=y^{\frac{b}{3a}}$$
$$E=mc^2$$

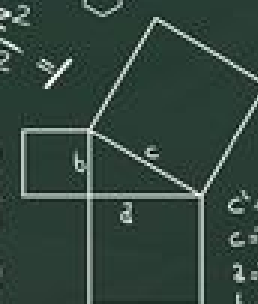
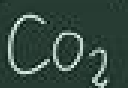

$$x^2=y^2$$




$$\frac{x^2+y^2}{a^2} + \frac{z^2}{b^2} = 1$$

UP
DOWN



$$c^2 = b^2 + d^2$$
$$c = \sqrt{b^2 + d^2}$$
$$a = \sqrt{c^2 - b^2}$$
$$b = \sqrt{c^2 - a^2}$$

BIOSCIENCE

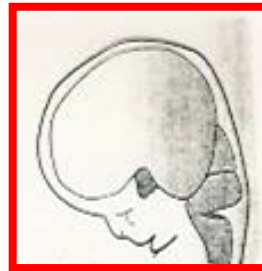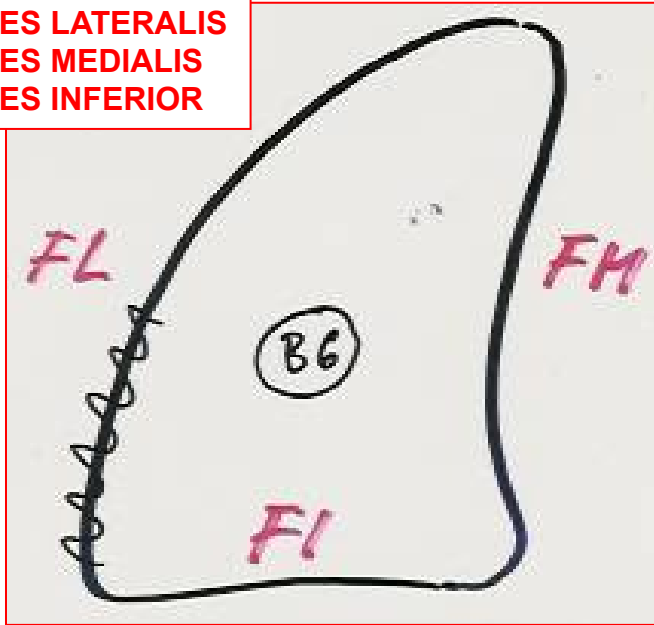


LOVE



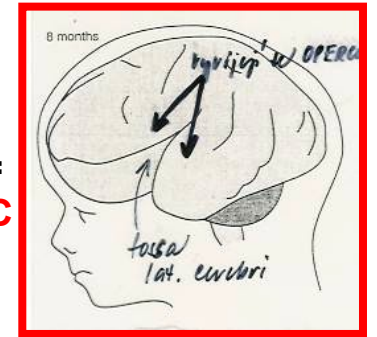
TELENCEPHALON – CEREBRUM

3 surfaces
 FACIES LATERALIS
 FACIES MEDIALIS
 FACIES INFERIOR

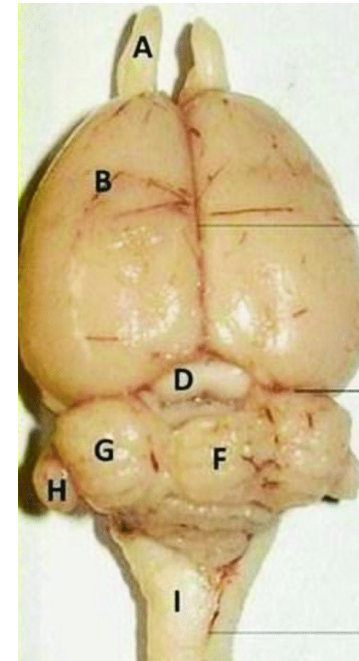
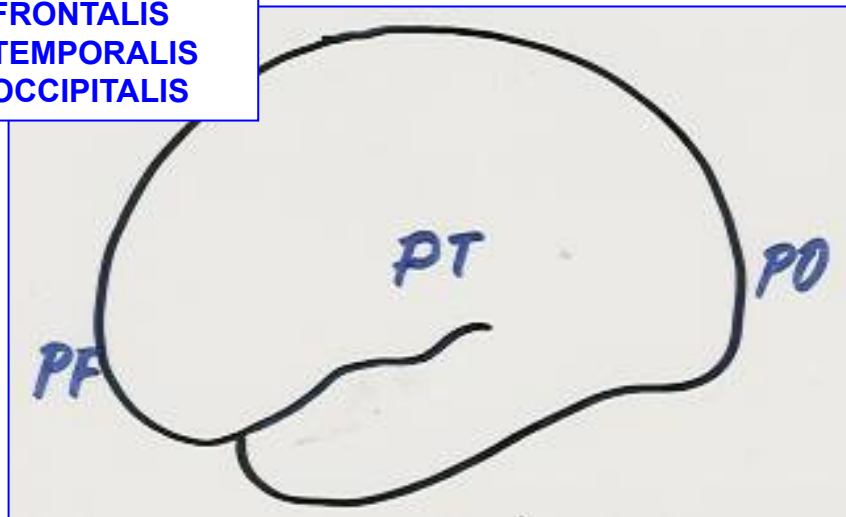


Before 4 month of
 IU development=
**LISSENCEPHALIC
 BRAIN**

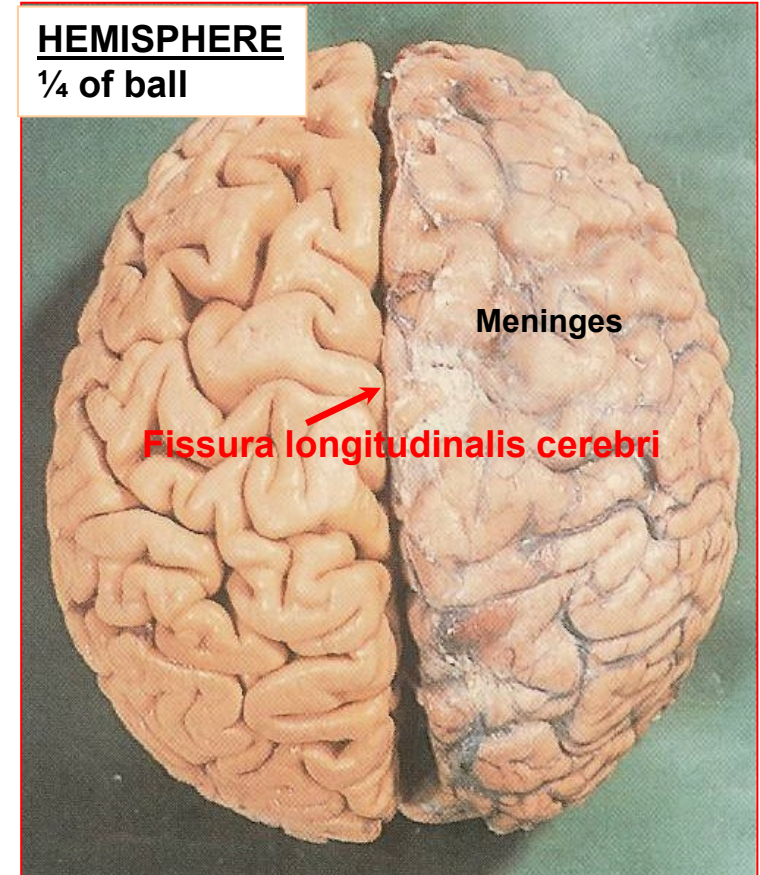
From 4 month
 start gyriification=
**GYRENCEPHALIC
 BRAIN**



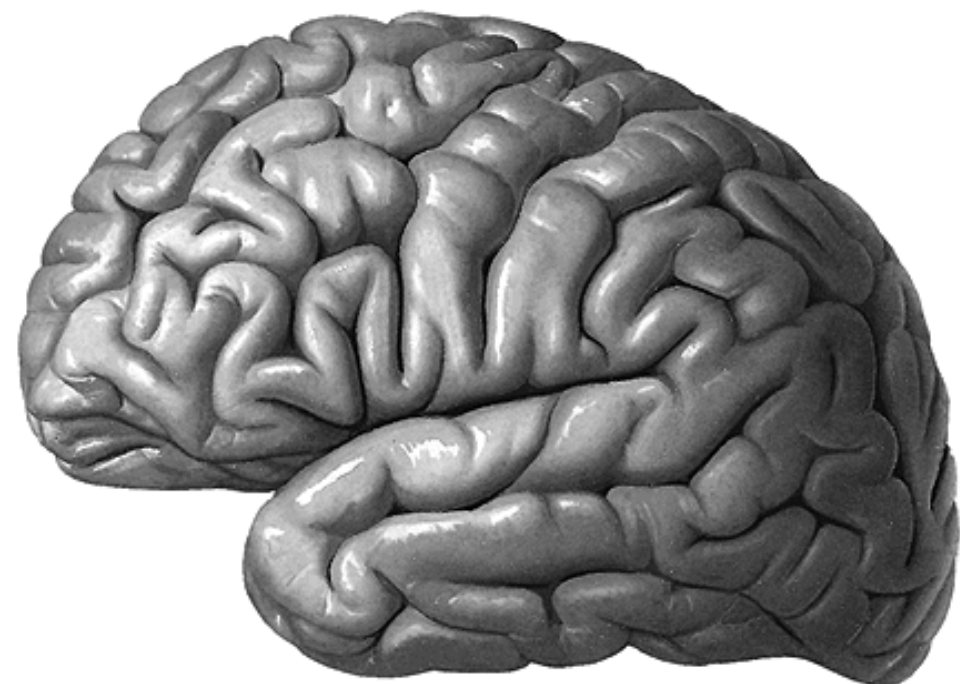
3 poles
 POLUS FRONTALIS
 POLUS TEMPORALIS
 POLUS OCCIPITALIS



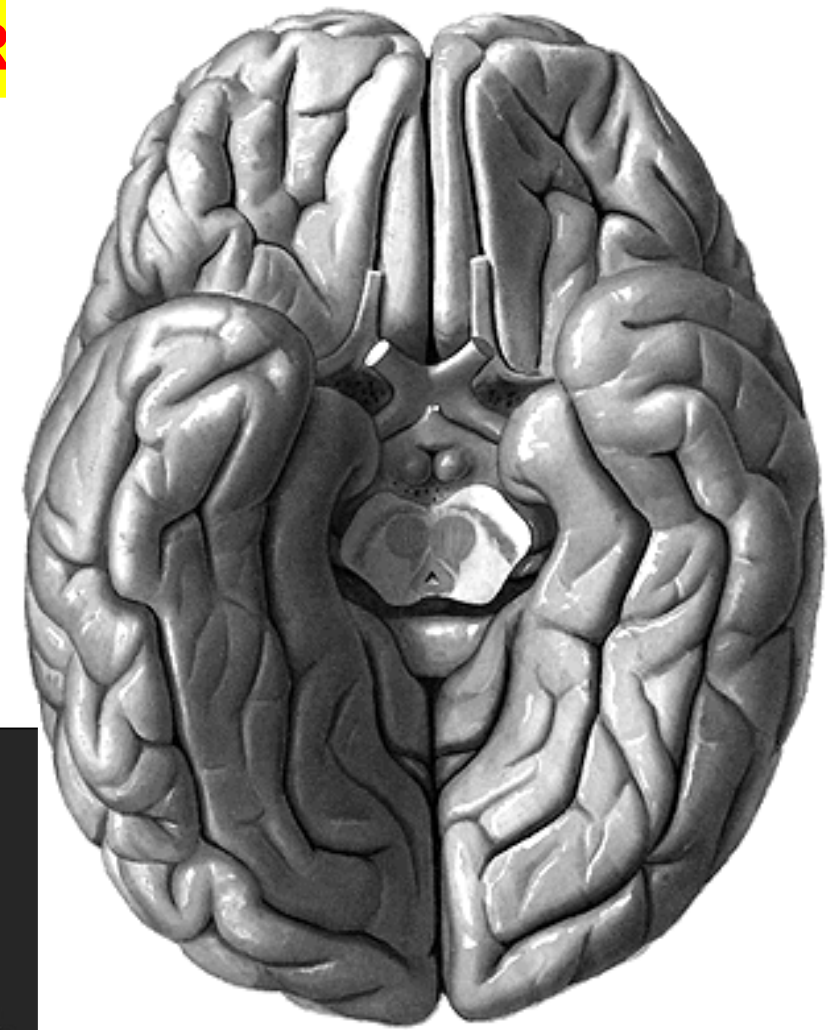
HEMISPHERE
 1/4 of ball



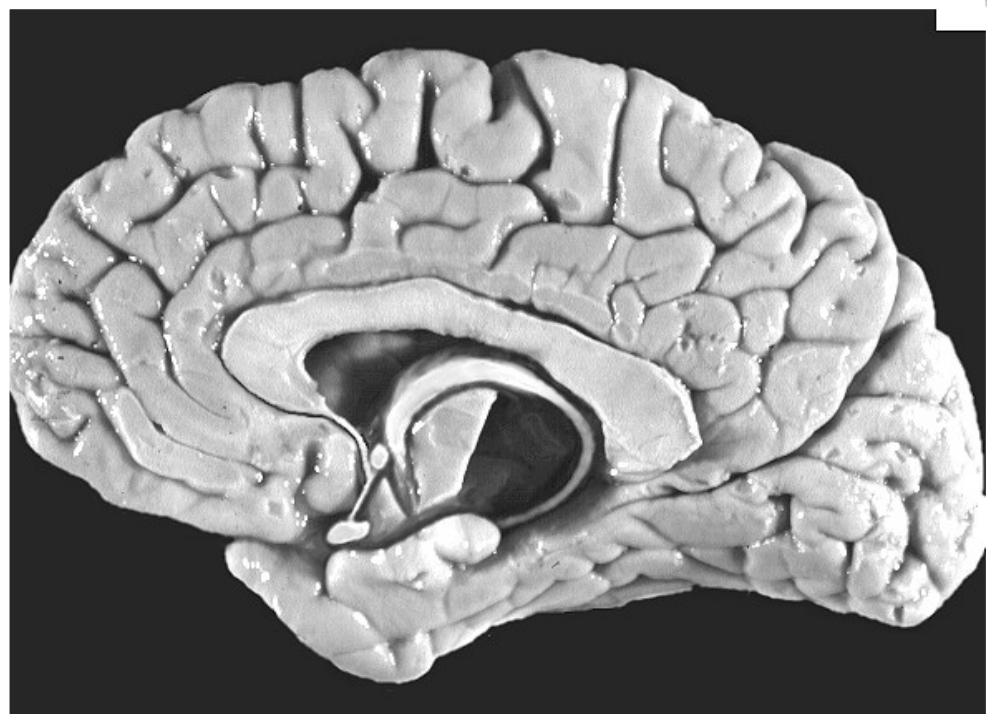
HEMISPHERIA CEREBRI



facies superolateralis (convexa)

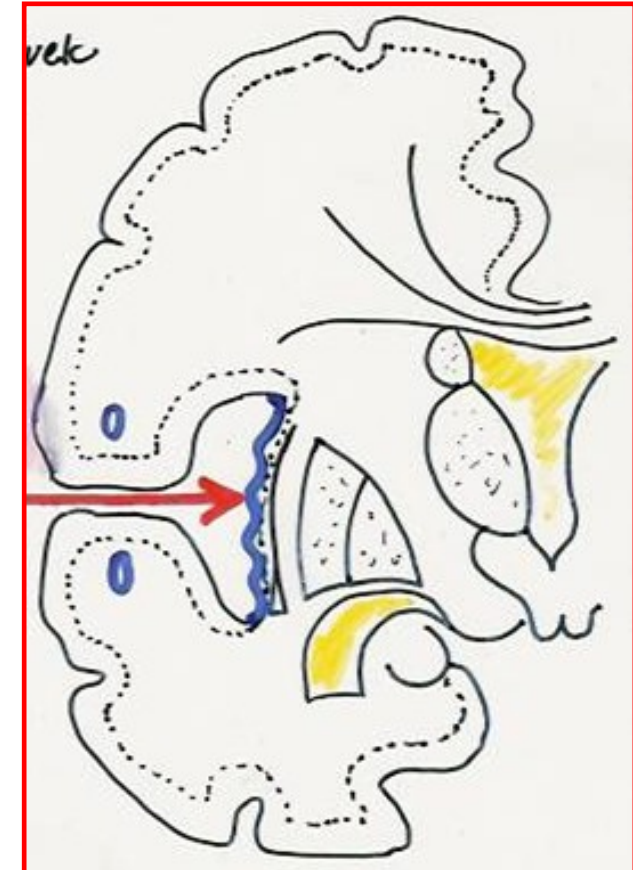
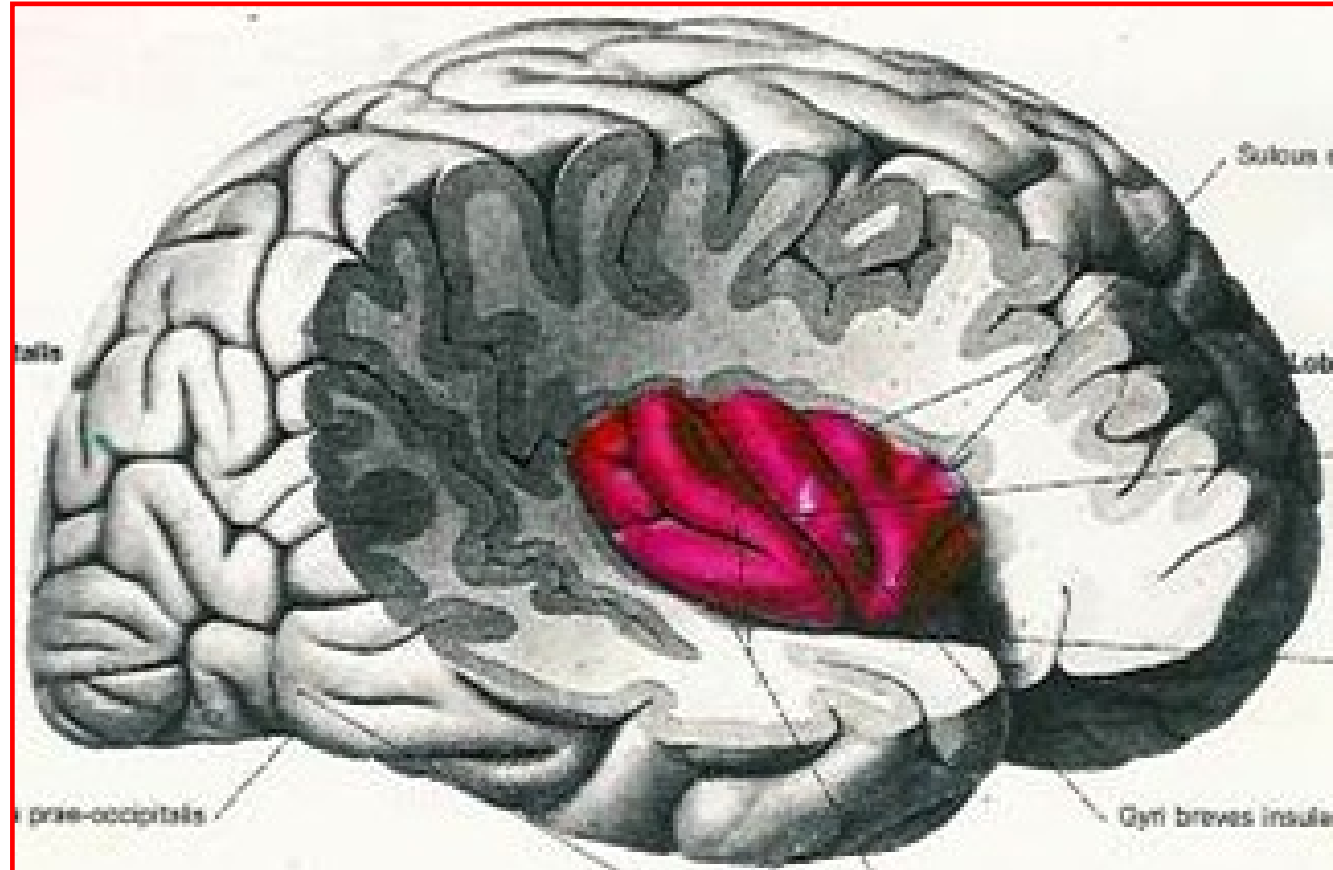


facies inferior

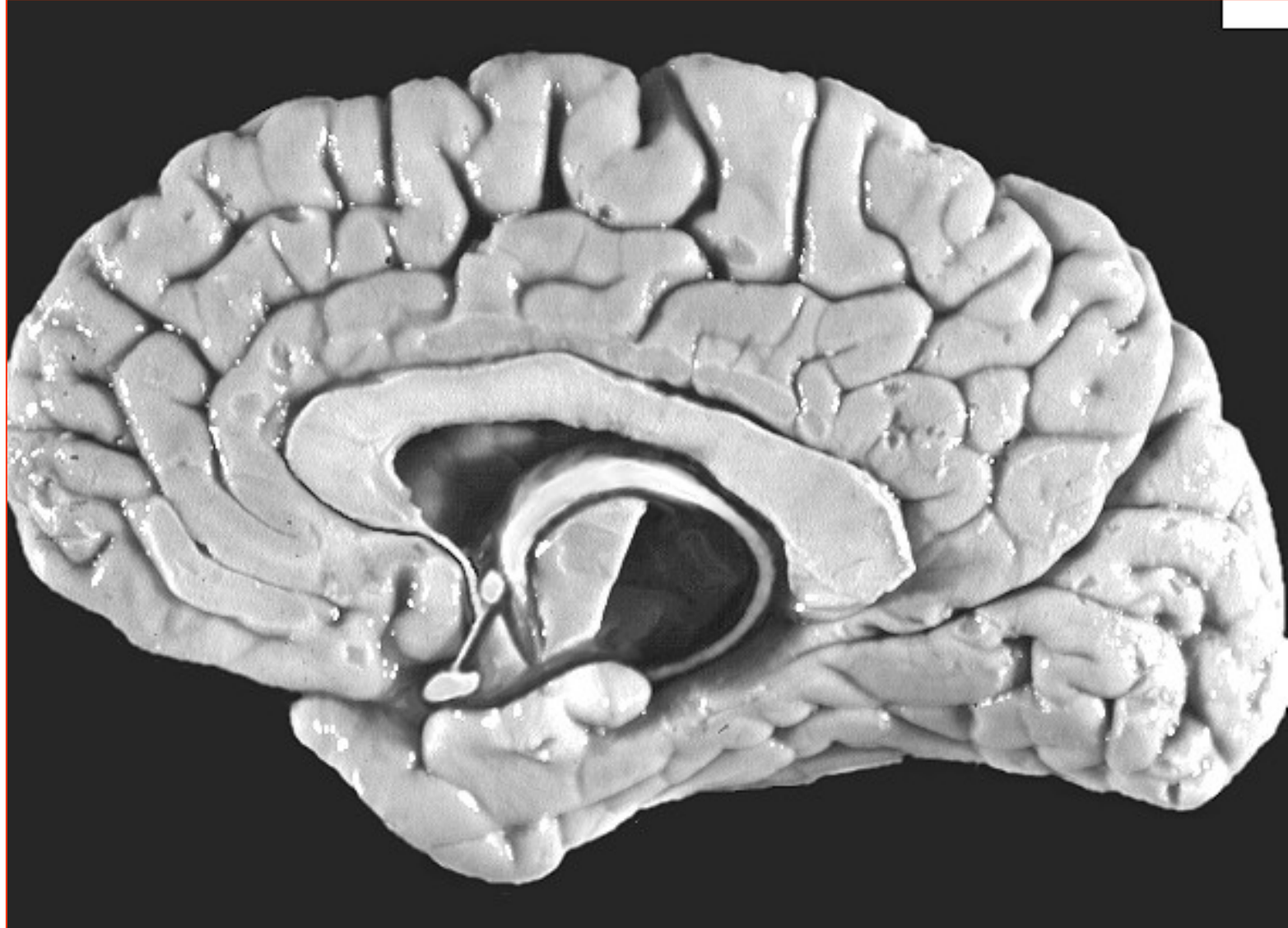
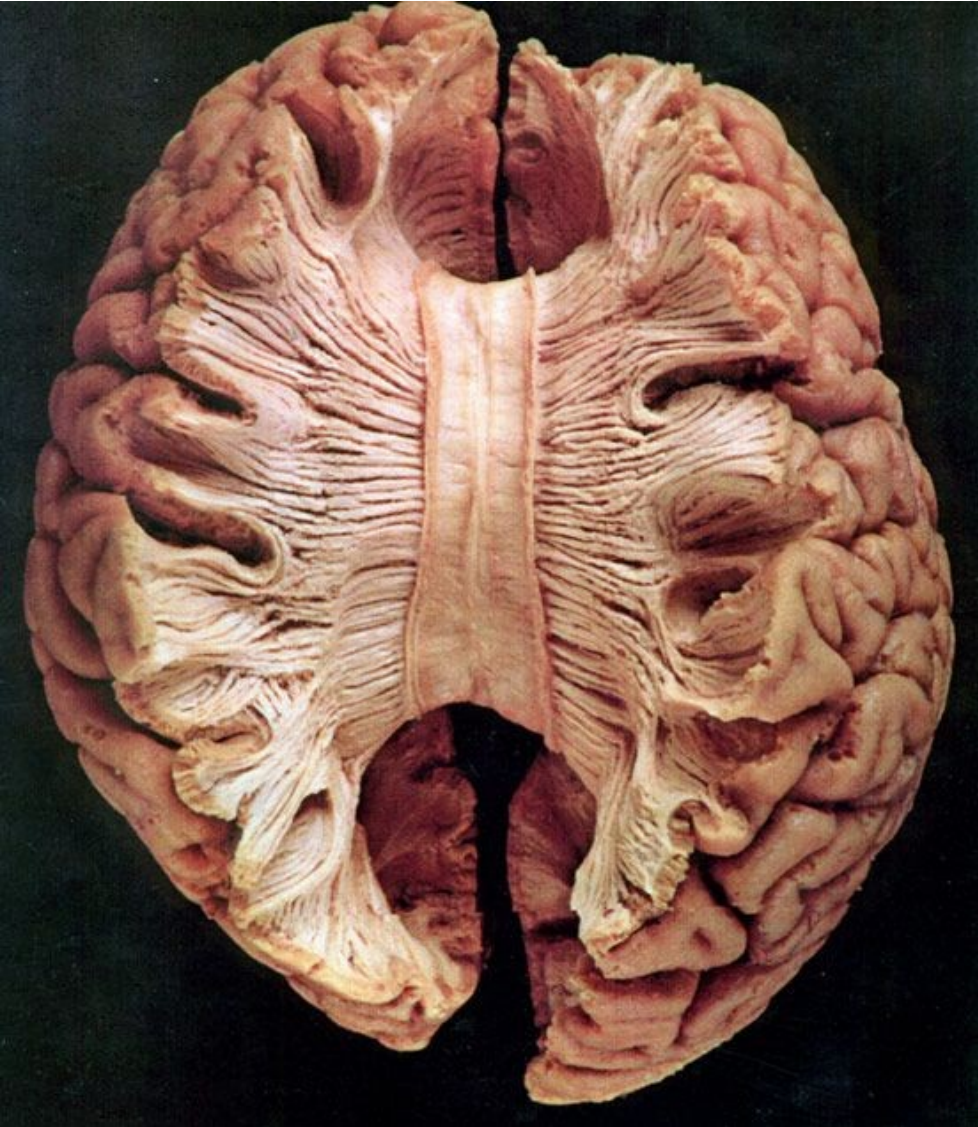


facies medialis

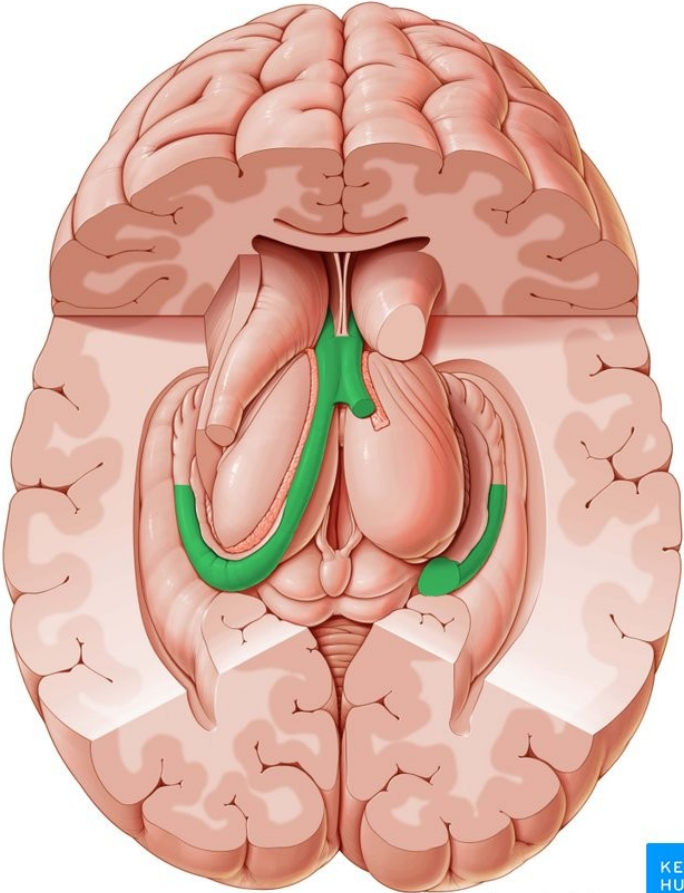
FISSURA LATERALIS CEREBRI (Sylvii) - FOSSA LATERALIS CEREBRI INSULA – GYRI INSULAE



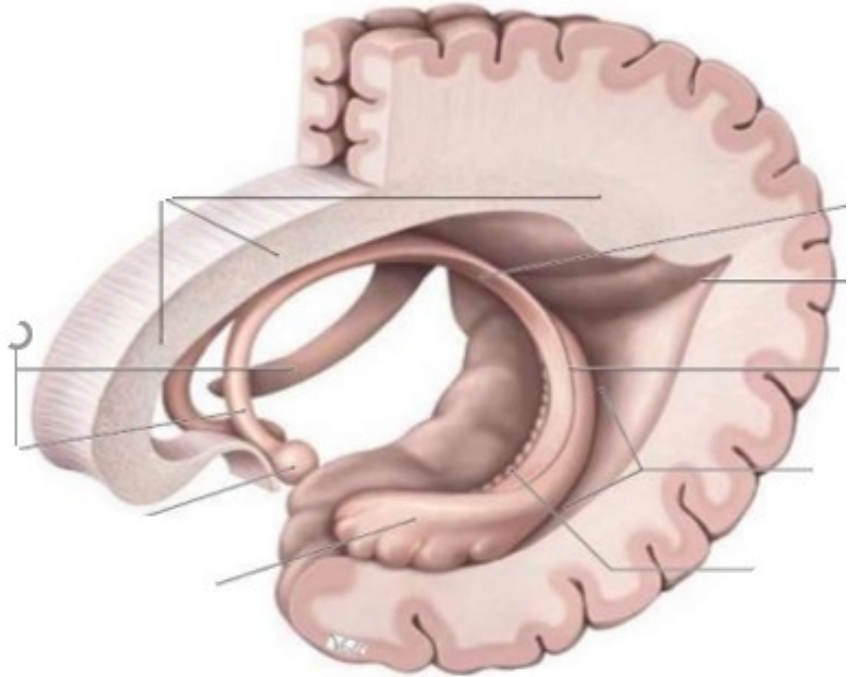
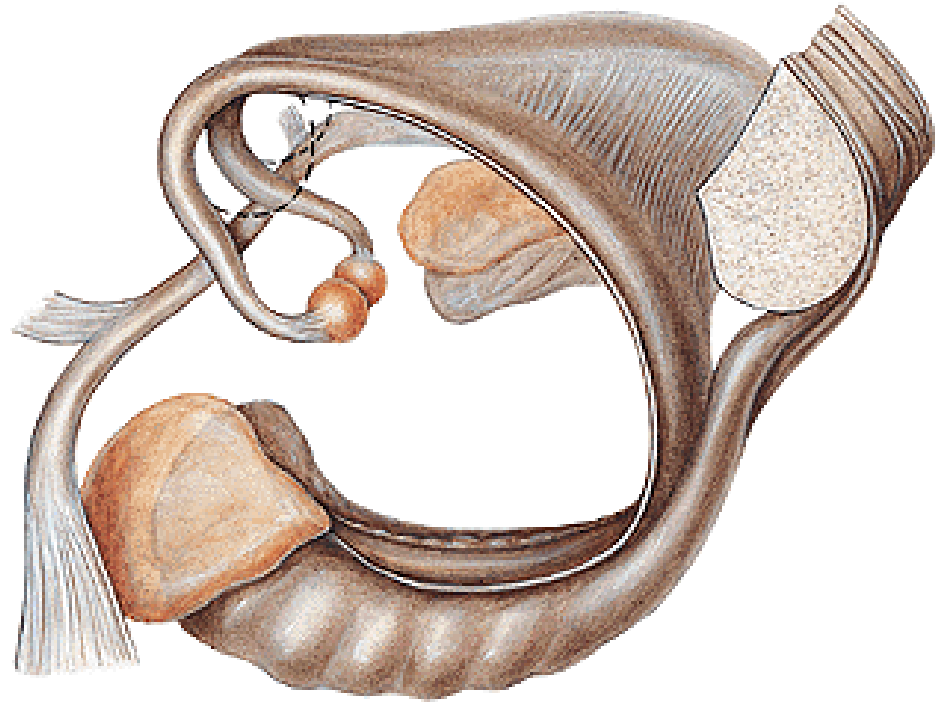
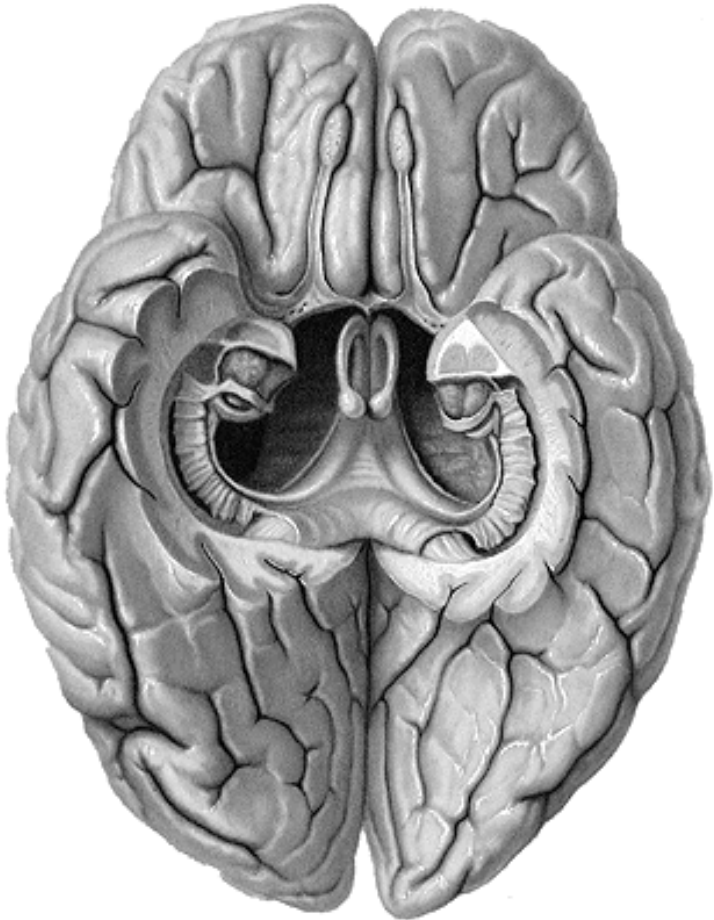
CORPUS CALLOSUM



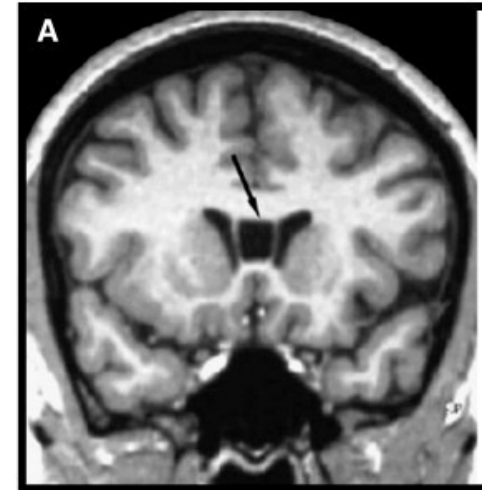
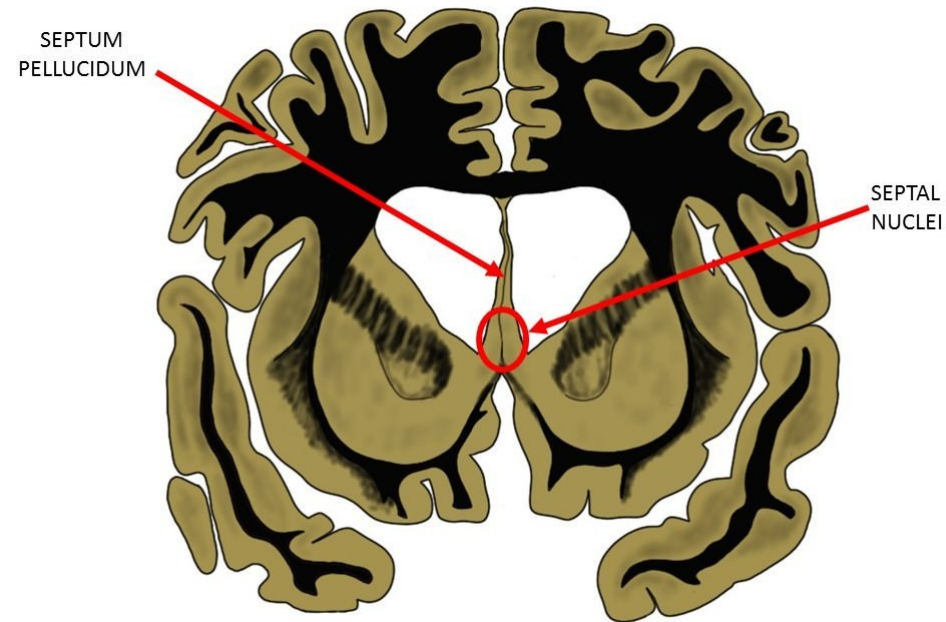
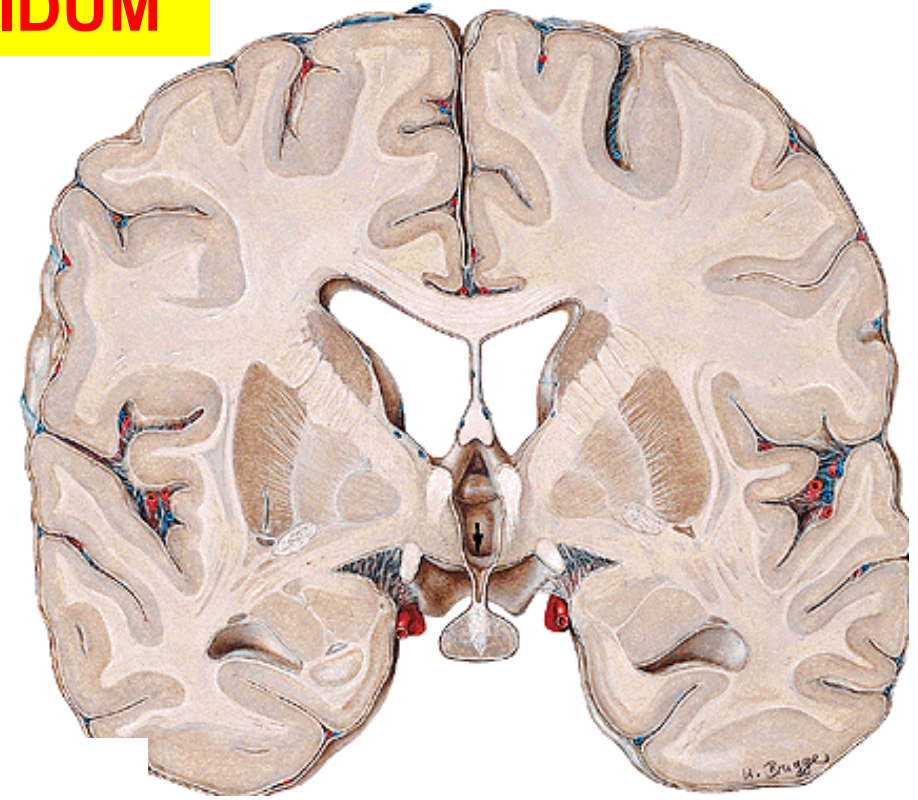
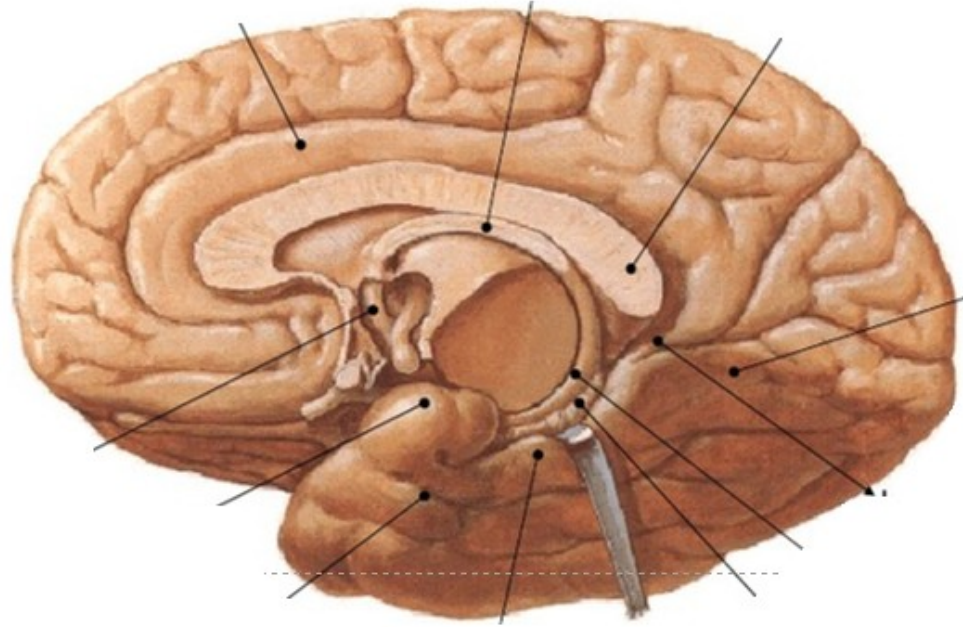
FORNIX



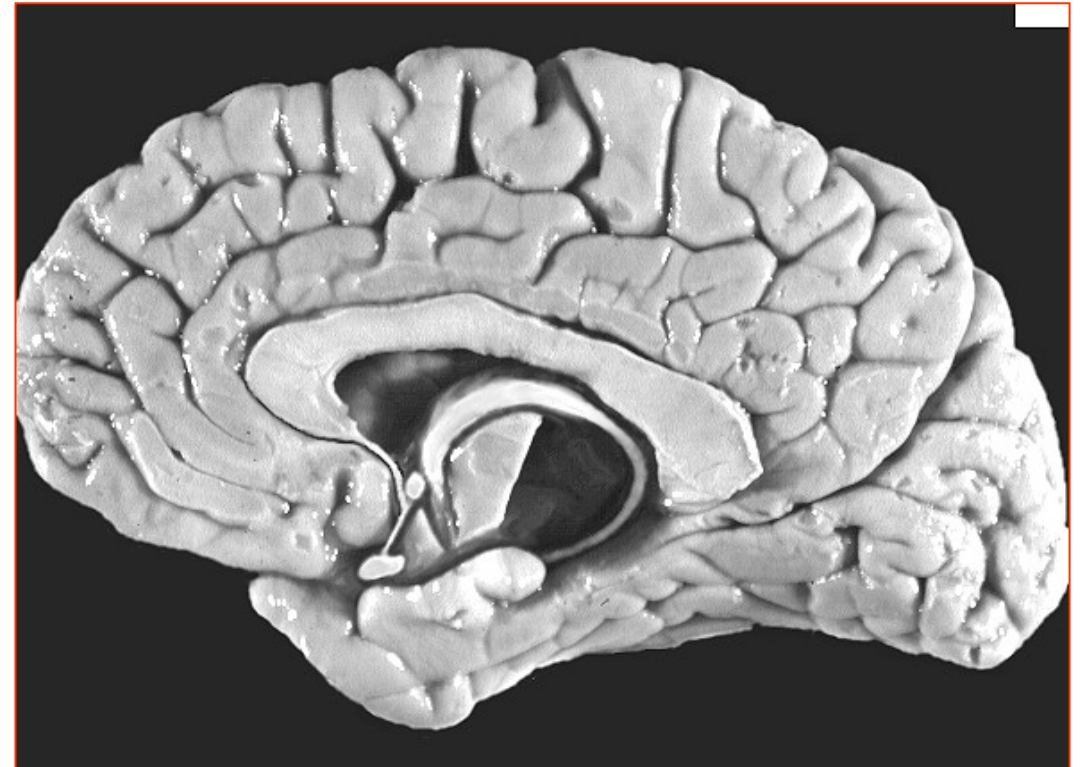
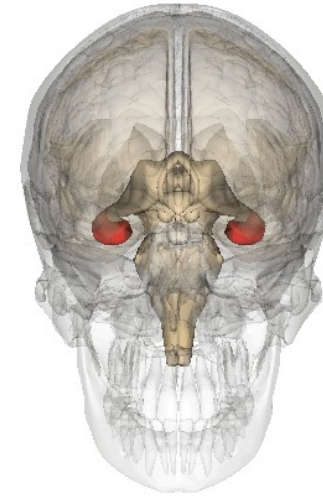

© www.kenhub.com **KEN HUB**



SEPTUM PELLUCIDUM



HIPPOCAMPUS

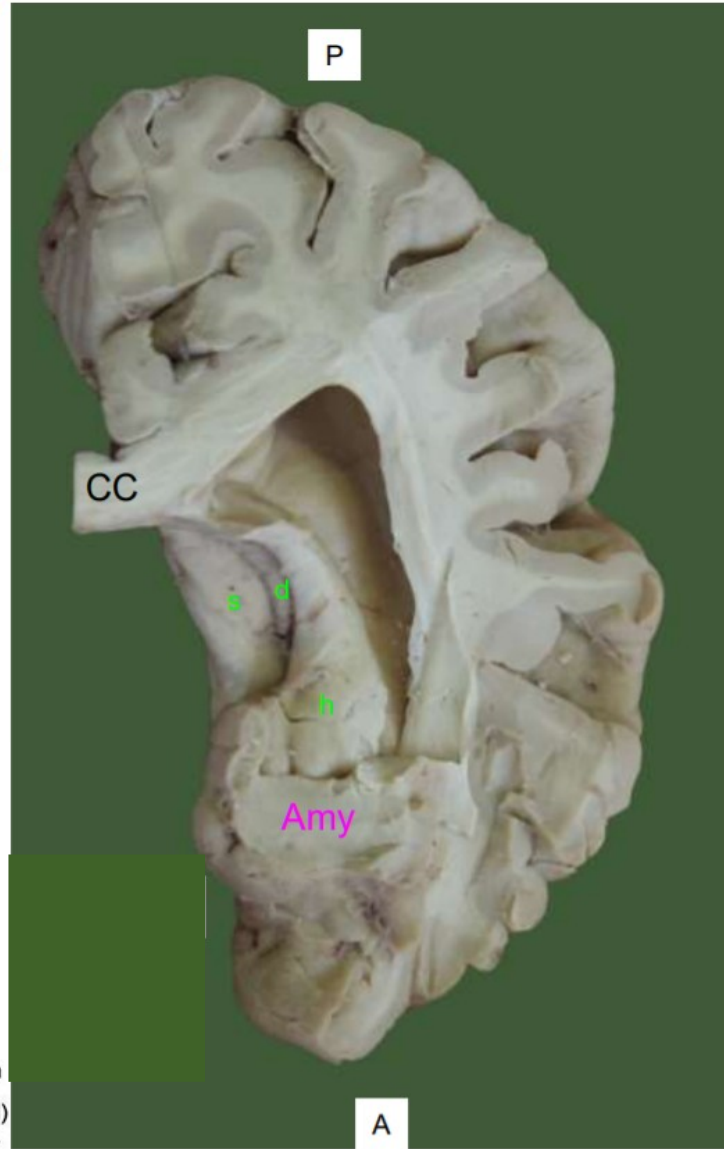
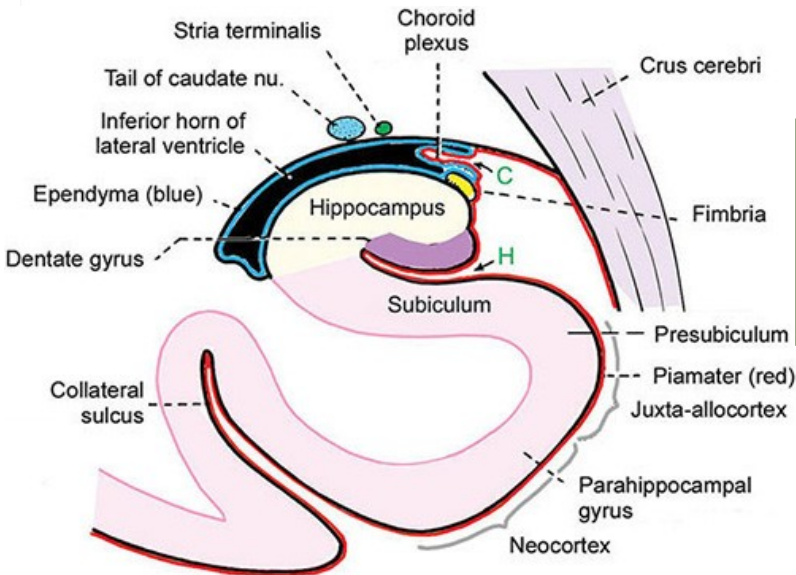


HIPPOKAMPÁLNÍ FORMACE

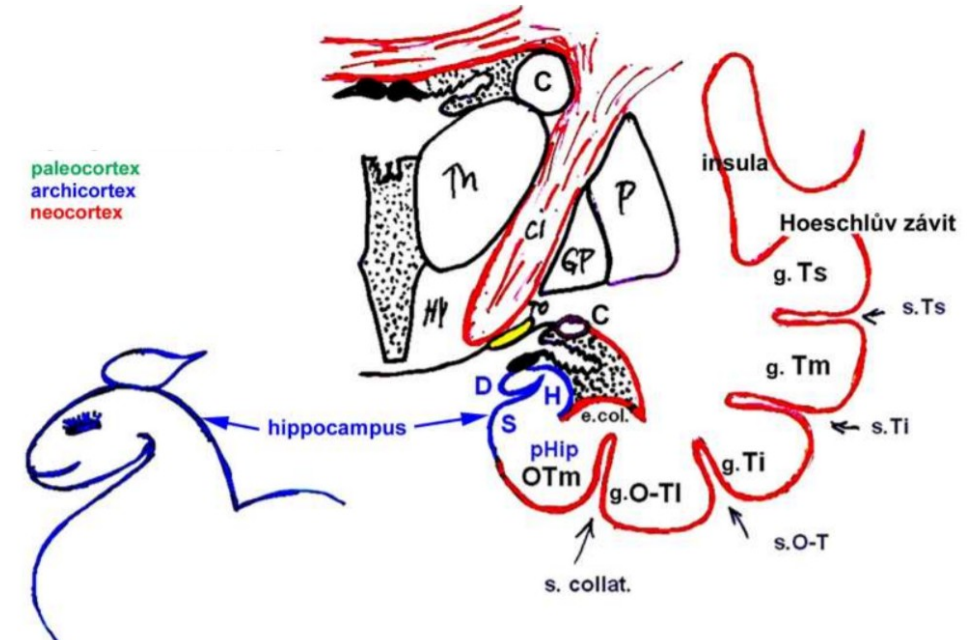
= archicortex

= Cornu Ammonis + subiculum + g. dentatus

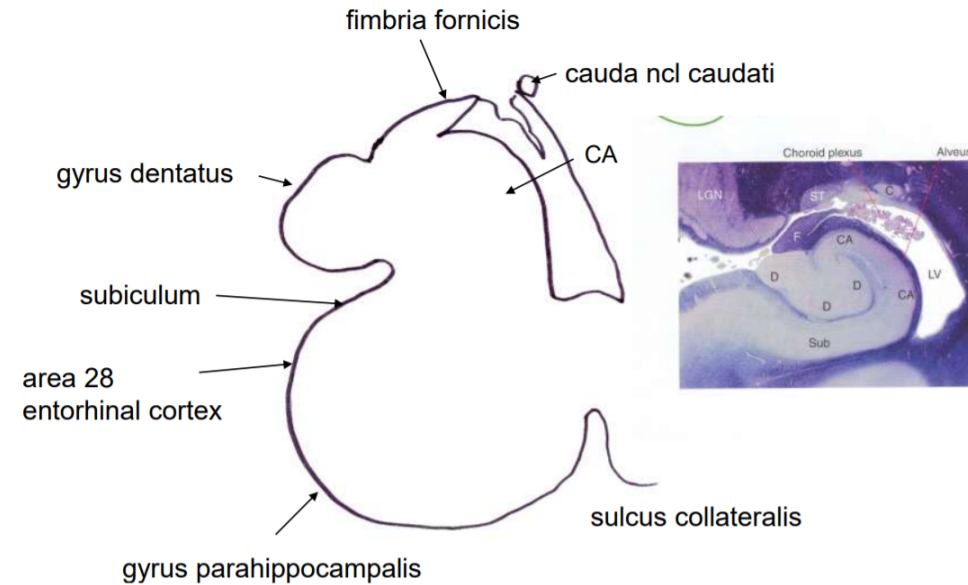
Inferior horn of lateral ventricle is open



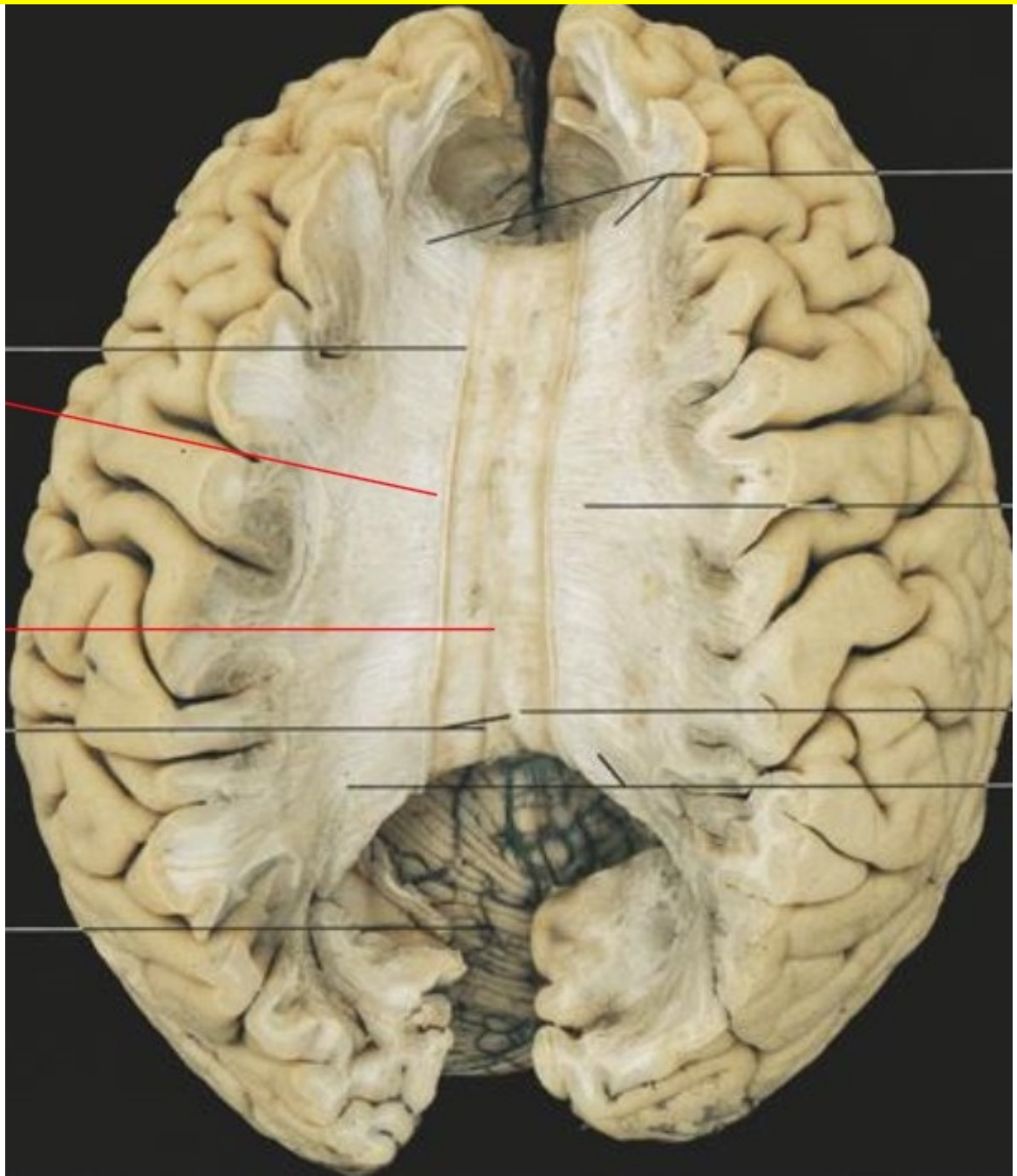
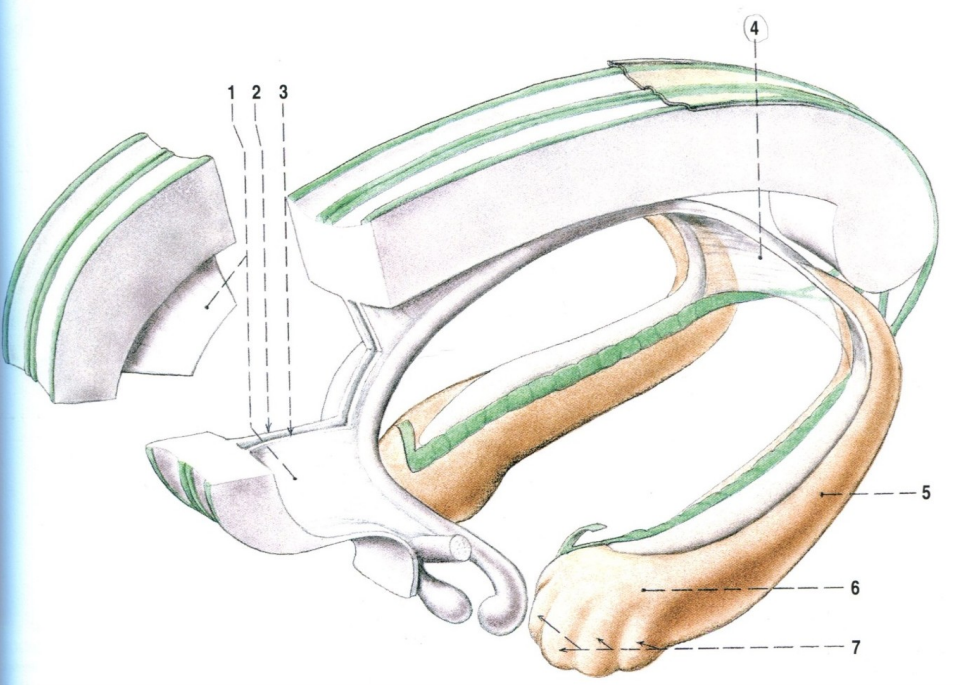
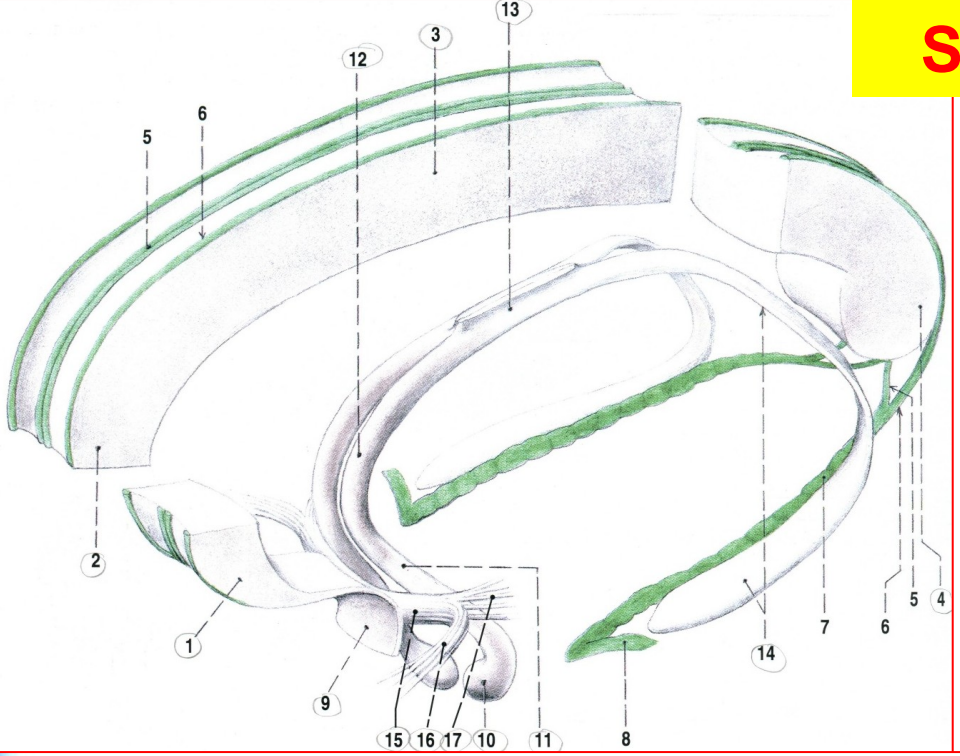
Frontal section of the hippocampus



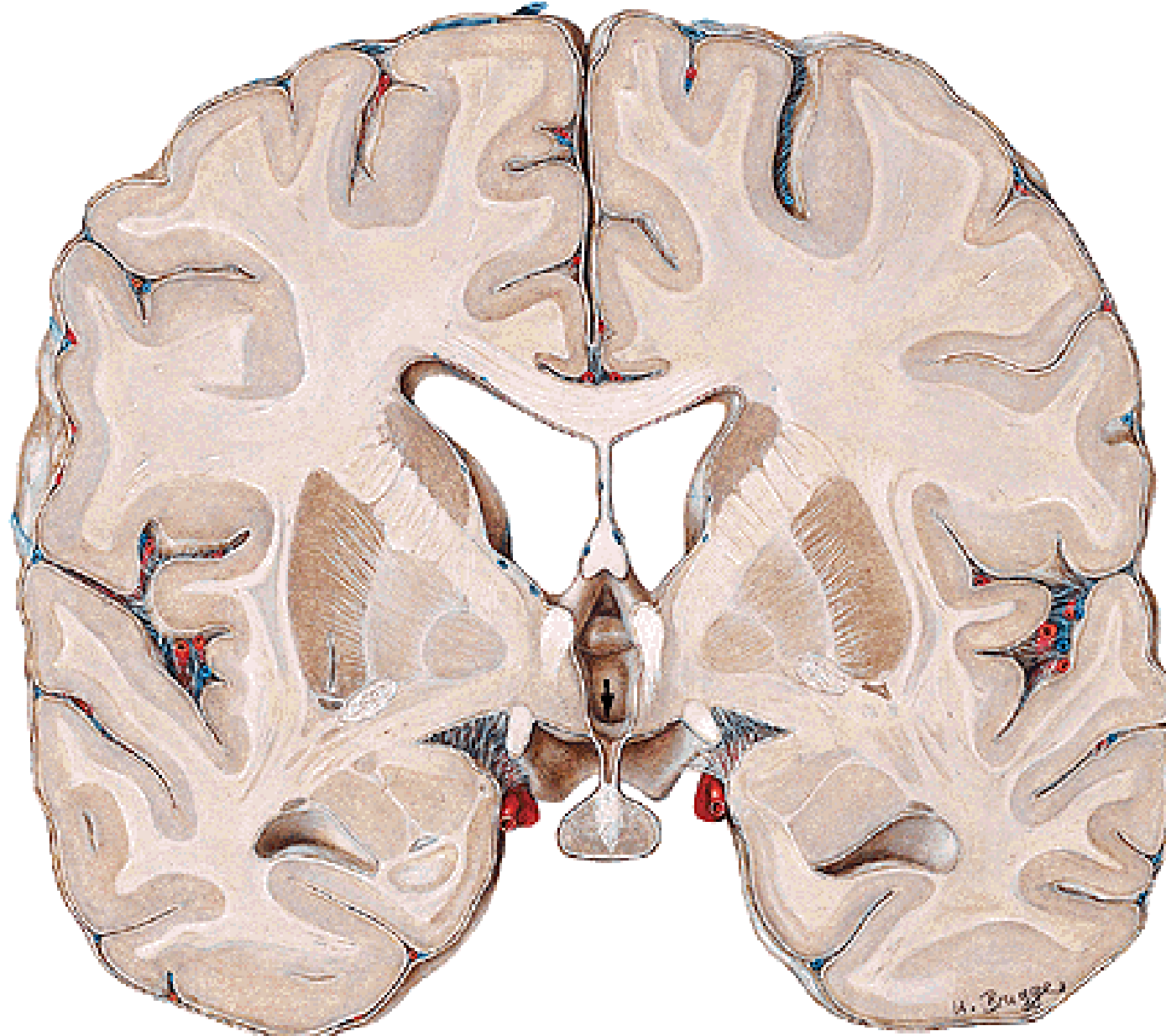Frontal section of the hippocampus



STRIAE LONGITUDINALES ET INDUSIUM GRISEUM



STRUKTURA TELENCEPHALA



CORTEX CEREBRI

vývojově starší ALLOCORTEX

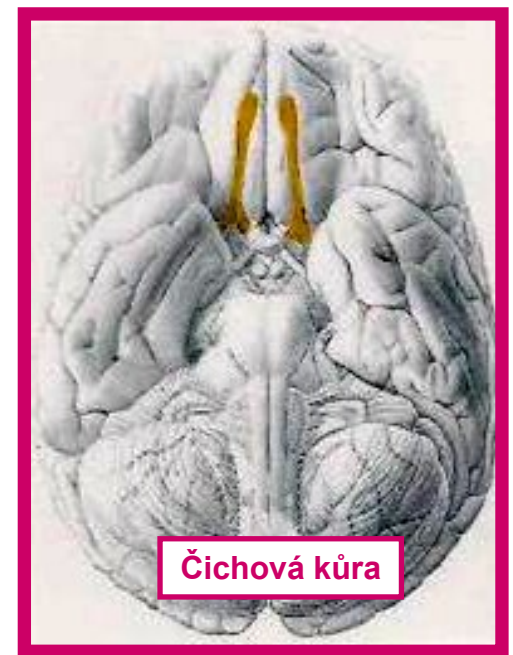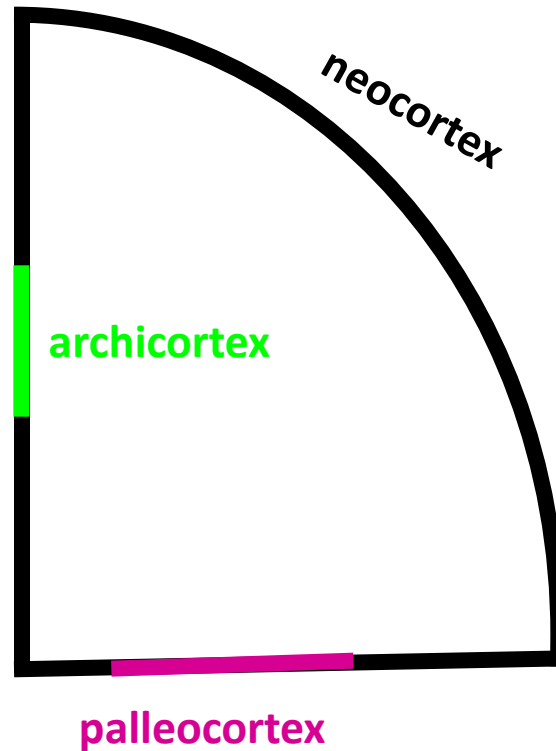
3-4 vrstvy buněk

a) paleocortex (čichový mozek)

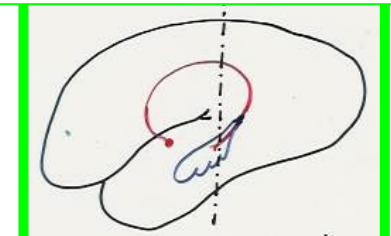
b) archicortex

■ **vývojově mladší NEOCORTEX**

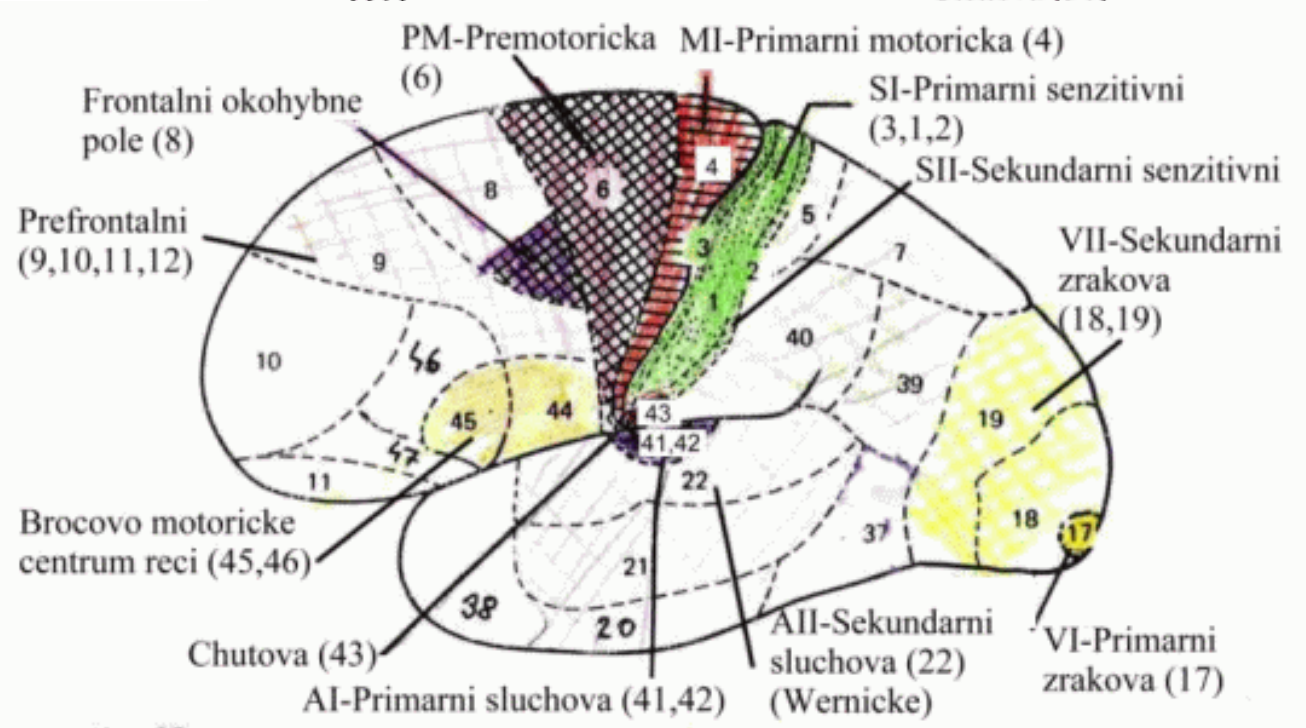
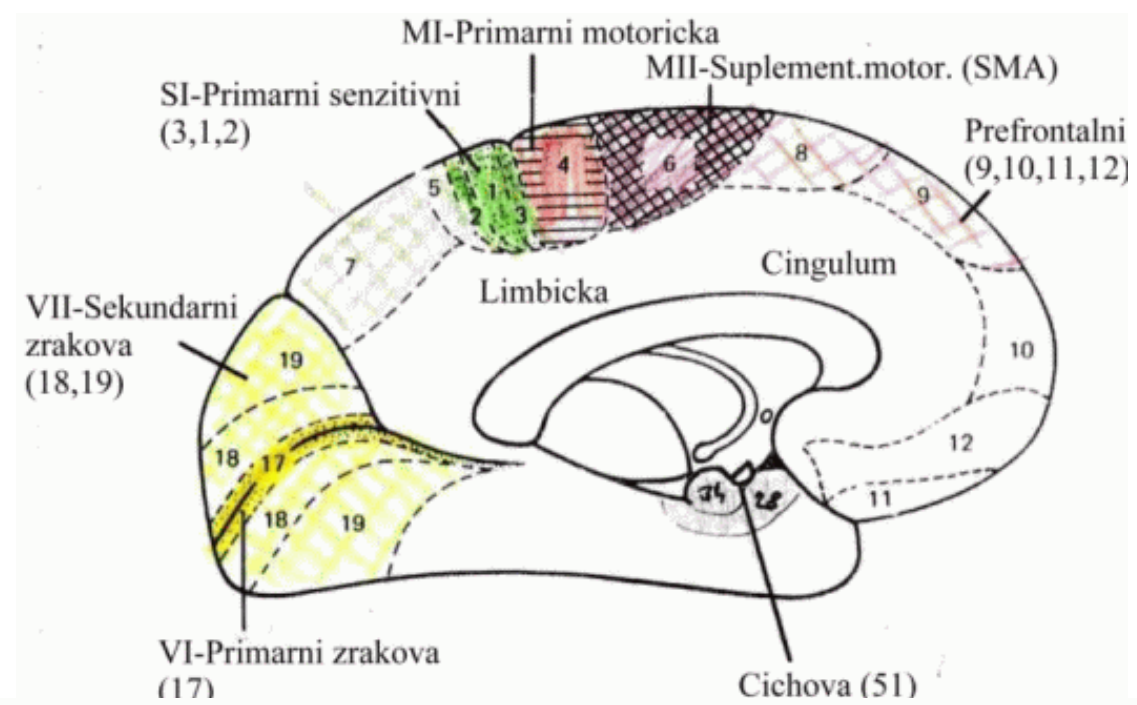
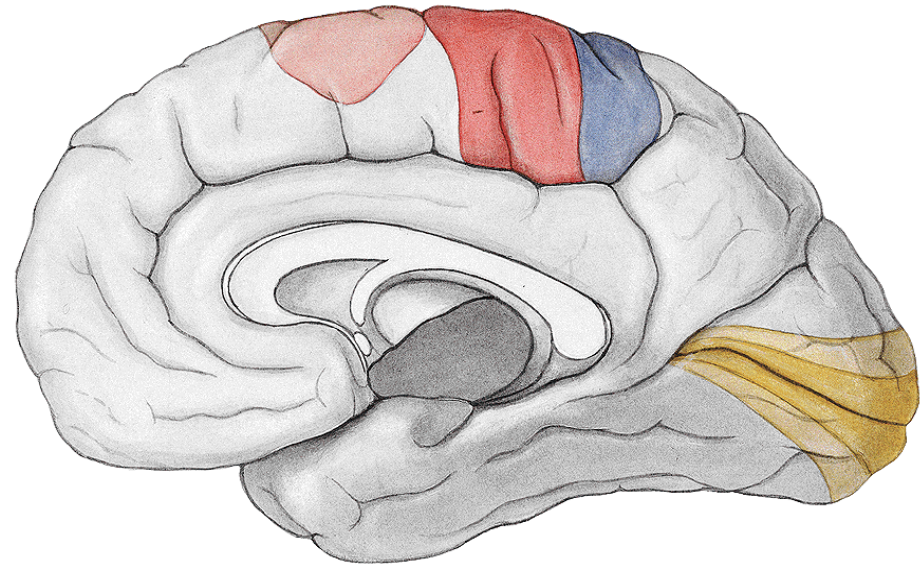
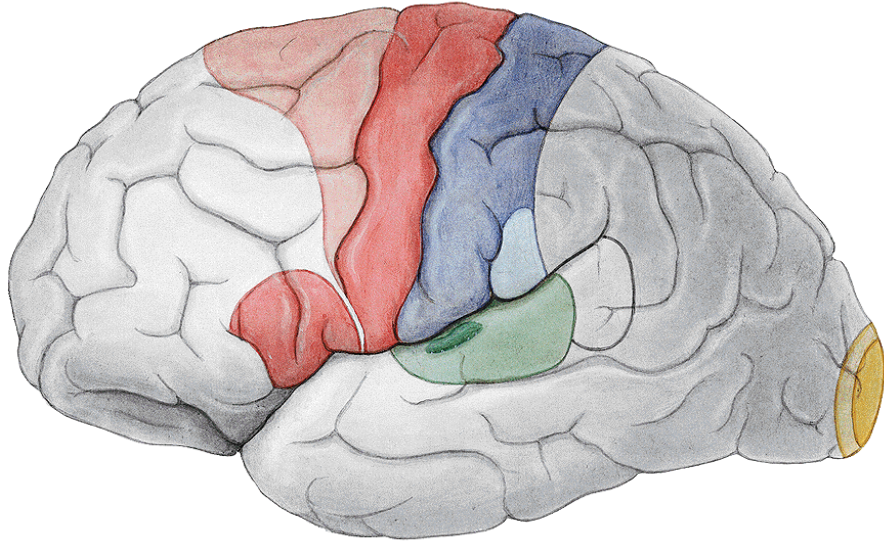
6 vrstev buněk



Limbická kůra
Hipokampální formace -
hippocampus



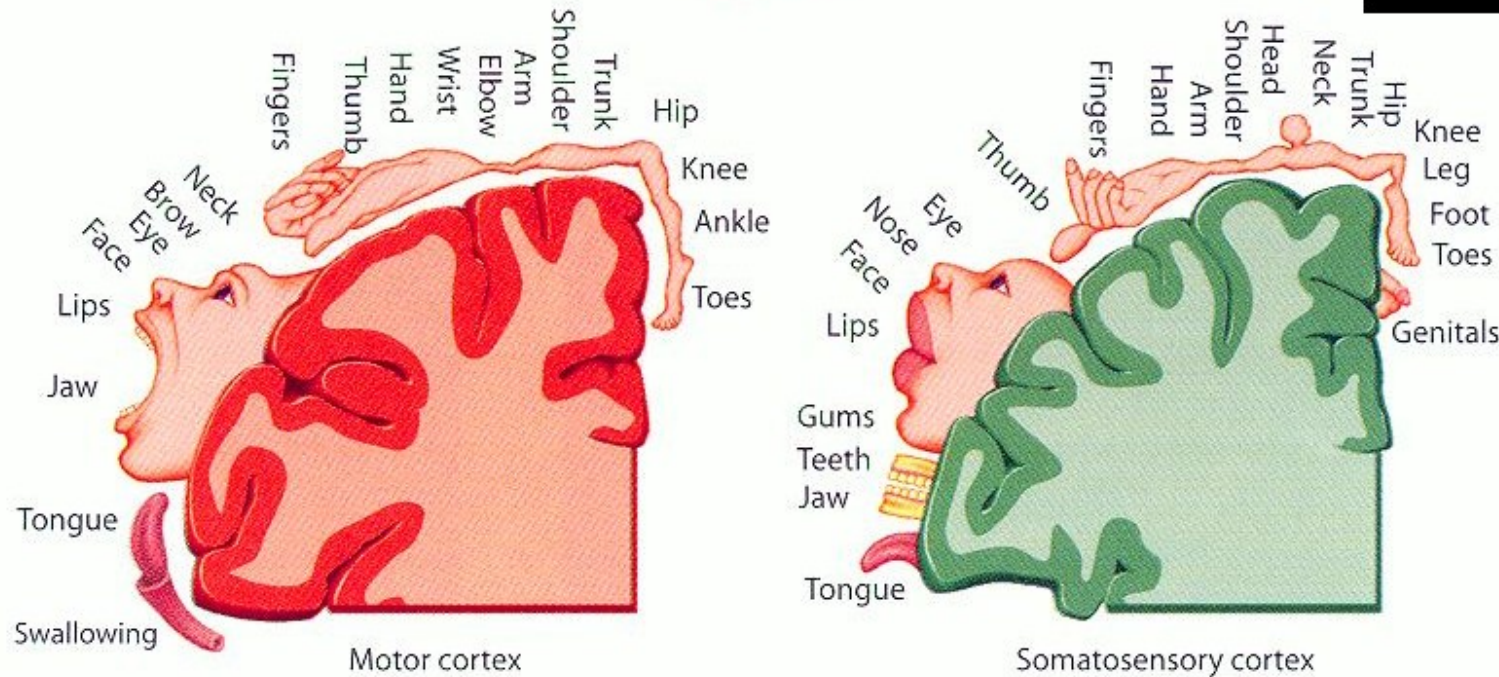
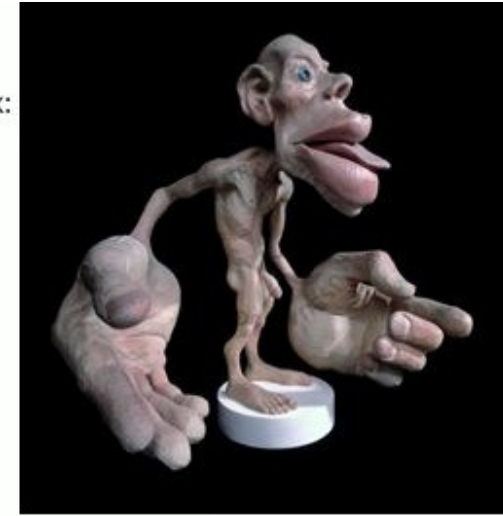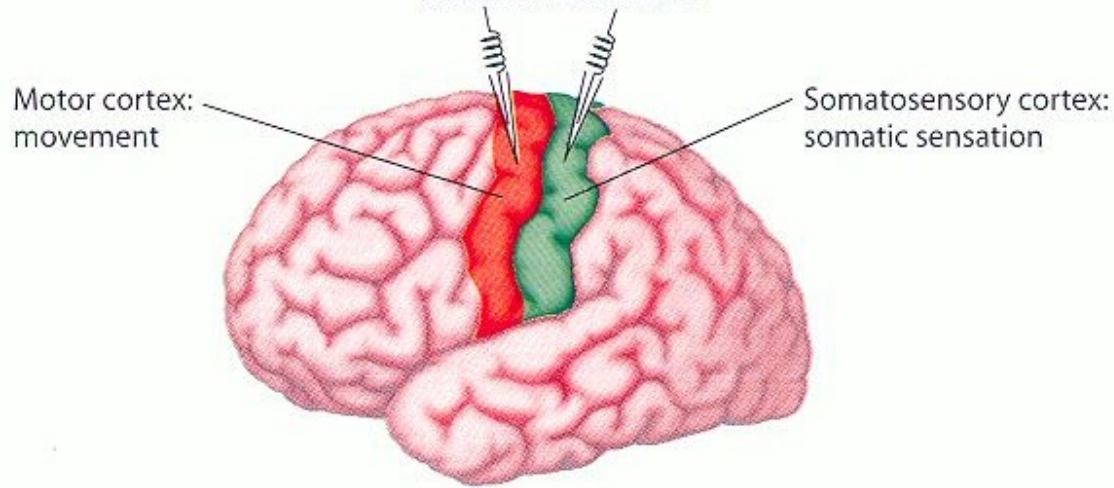
NEOCORTEX – VRSTVY, CYTOARCHITEKTONIKA



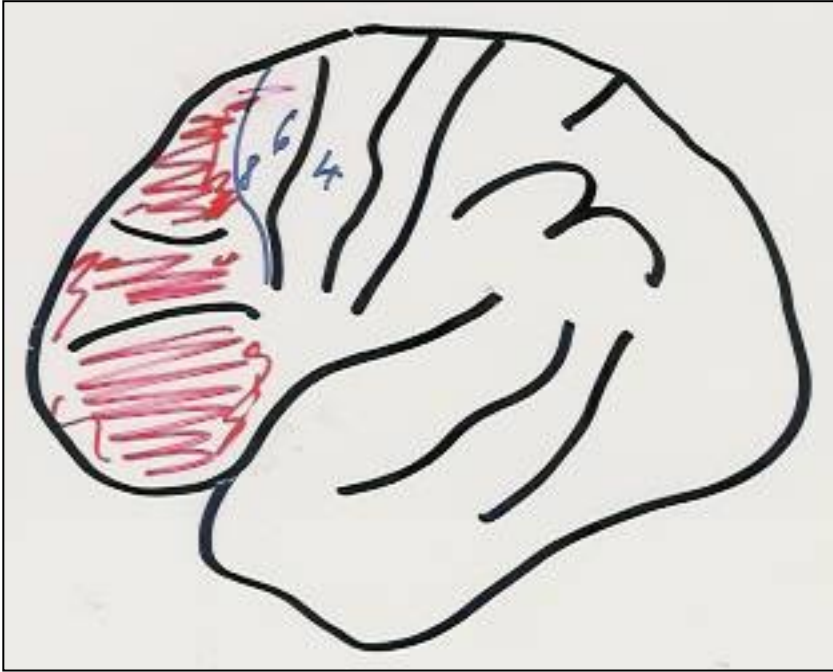
SOMATOTOPIKA PRIMÁRNÍ MOTORICKÉ + SOMATOSENZORICKÉ KŮRY PENFIELDŮV MOTORICKÝ + SENZORICKÝ HOMUNKULUS

Gyrus praecentralis, BA 4

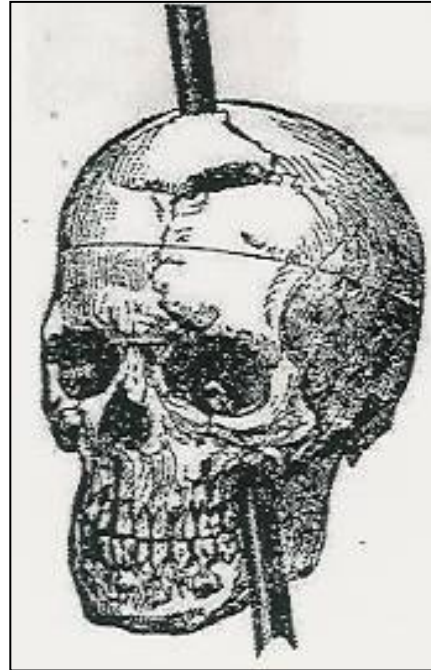Gyrus postcentralis, BA 3,1,2



PREFRONTÁLNÍ ASOCIAČNÍ KOROVÁ OBLAST



BA 9,11,11,12,44,45,46,47
33% celkové plochy kůry



PREFRONTÁLNÍ SYNDROM

Rozsah asociační kůry ve fylogeneze

Potkan



Člověk



DOMINANCE HEMISFÉR

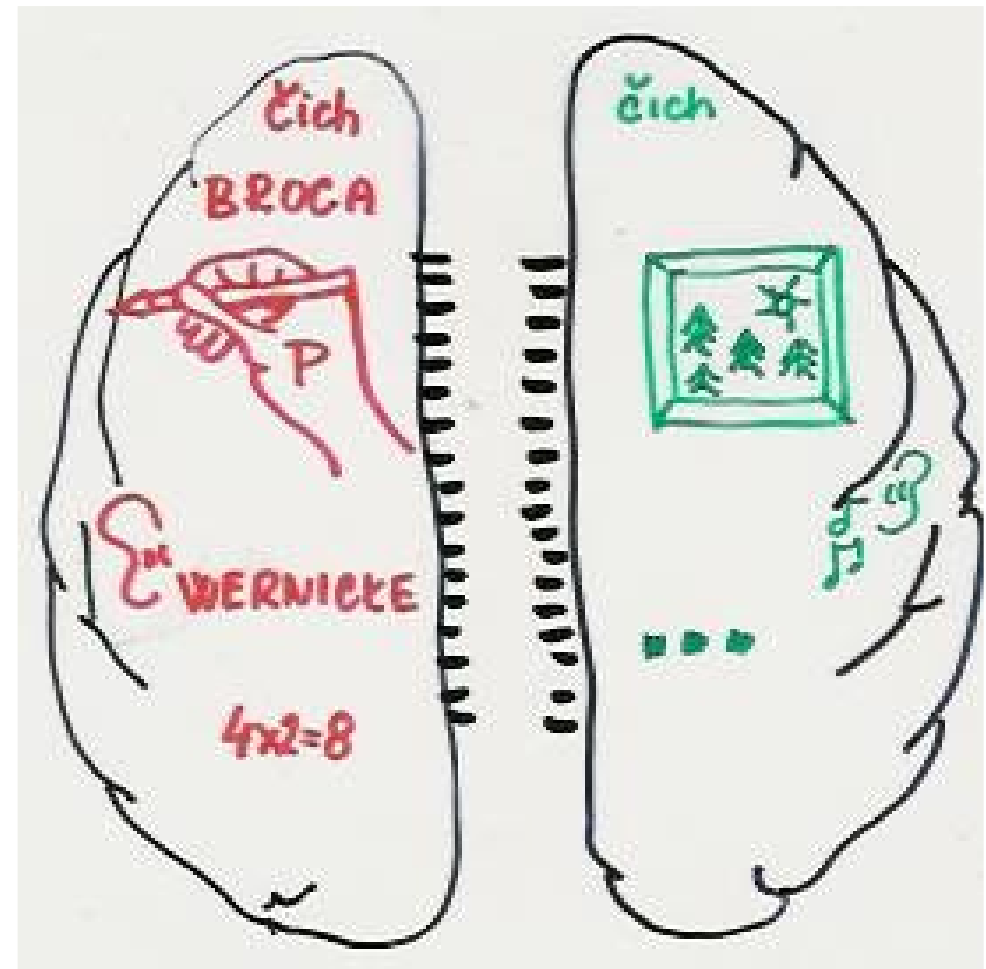
NORMÁLNÍ /STANDARTNÍ/ DOMINACE - 70% populace

Levá (dominantní) hemisféra: v ní lokalizovány funkce řečové – verbální = „mluvící hemisféra“, **praváctví** = vrozená větší obratnost pravé ruky

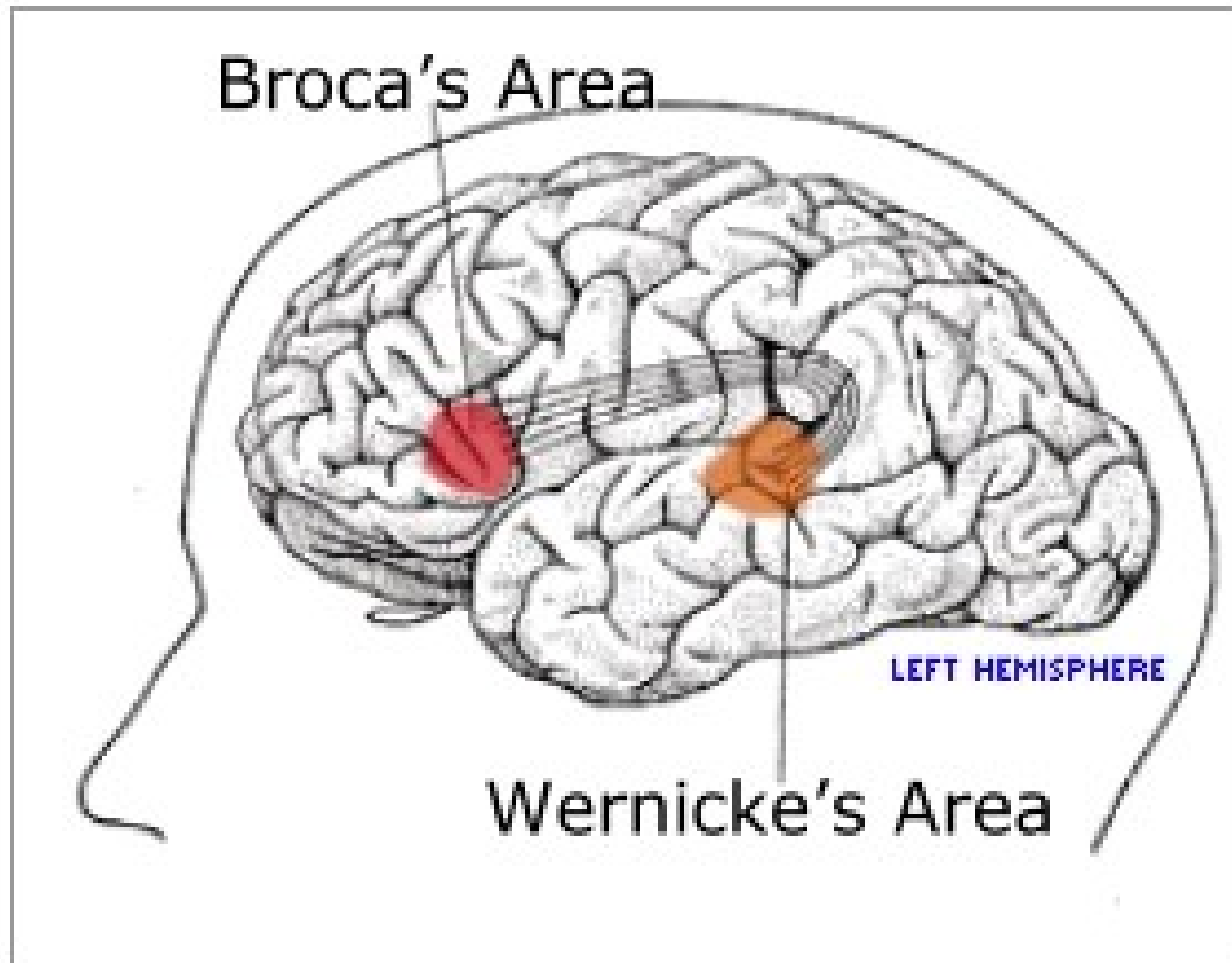
Pravá (recesivní) hemisféra: funkce **múžické**, **časoprostorové**

ABNORMÁLNÍ DOMINANCE – 30% populace

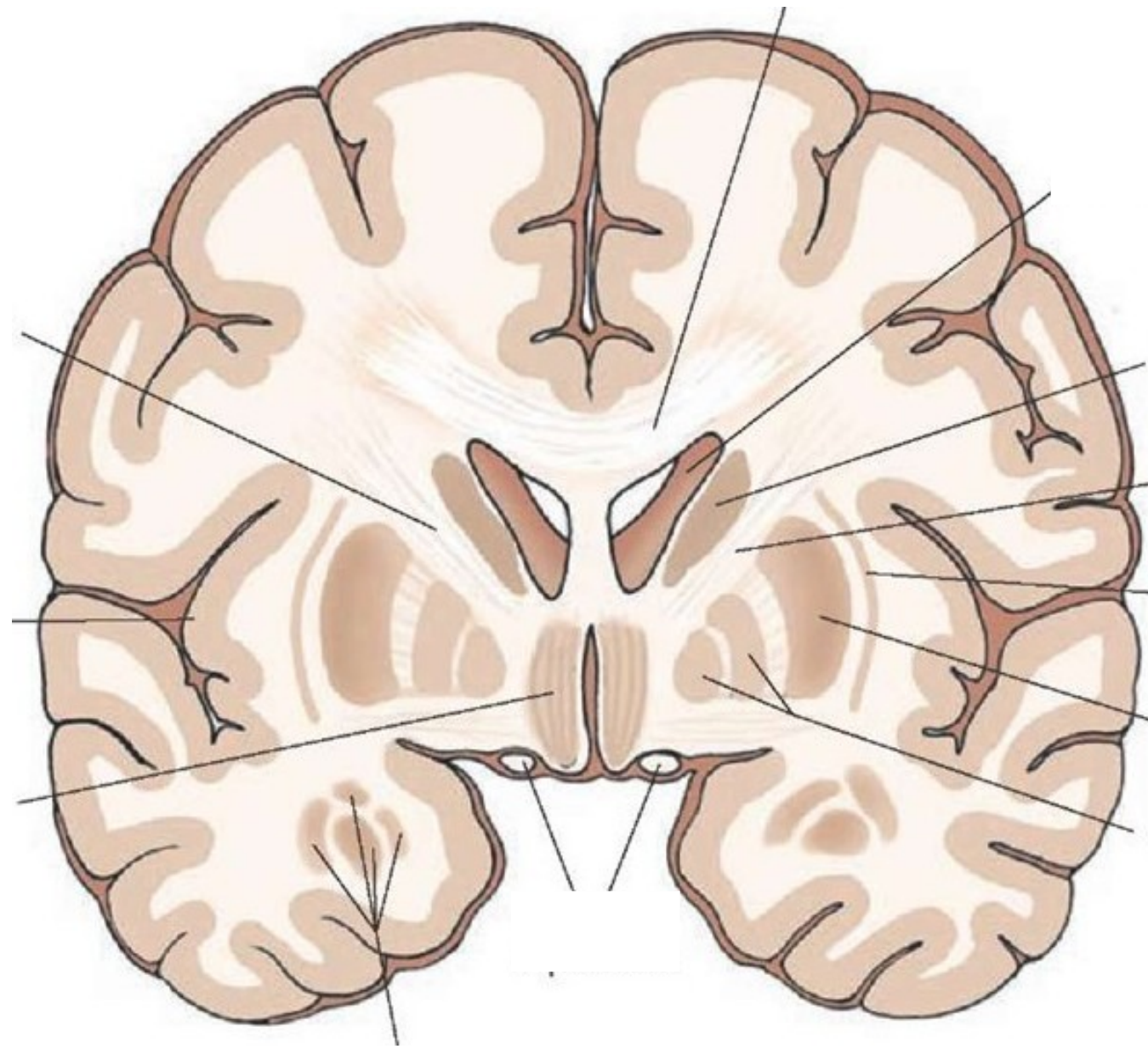
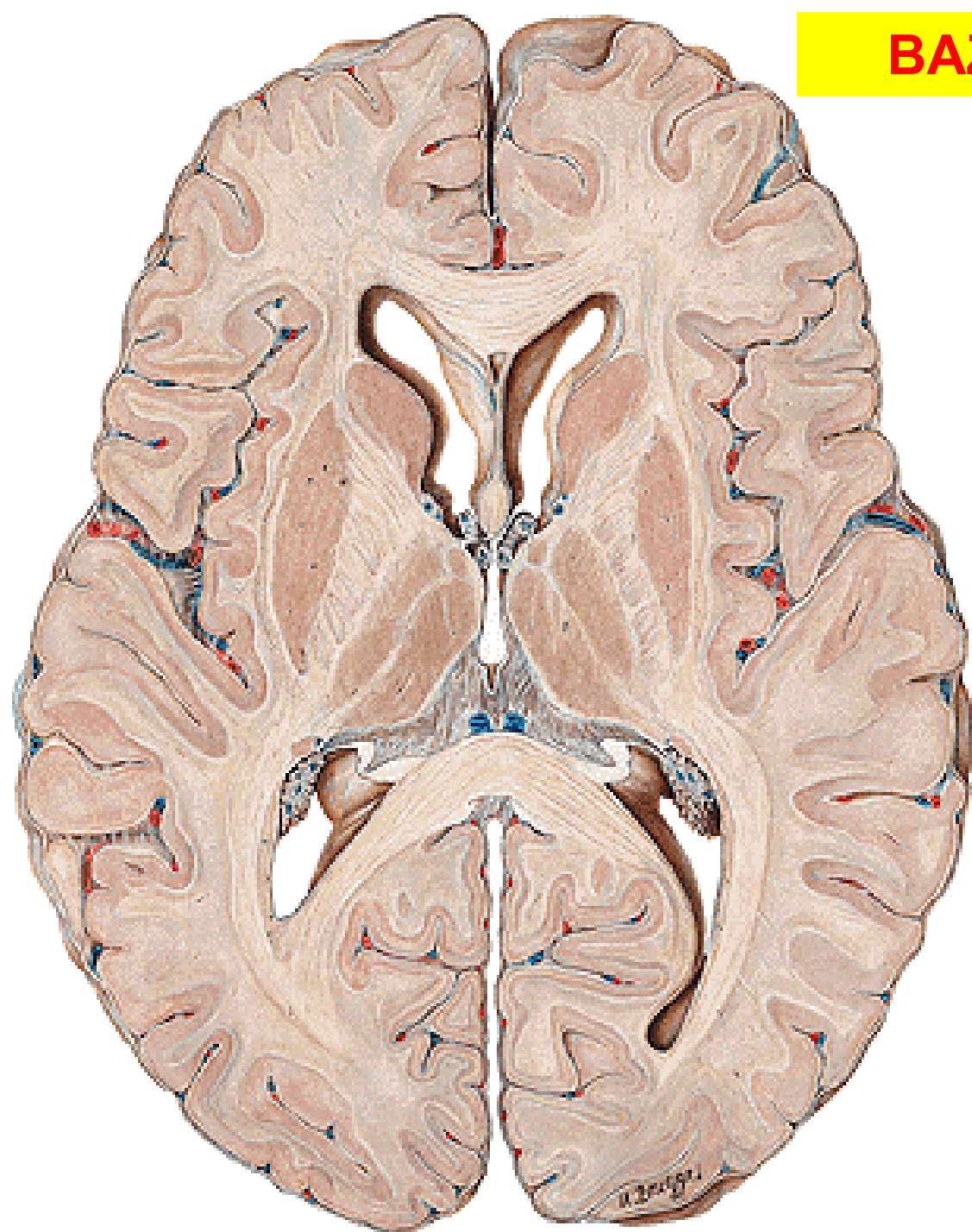
Odchylka od standartní dominance – klinicky se projevuje leváctvím či ambidextrií



ŘEČOVÁ CENTRA, FATICKÉ FUNKCE



BAZÁLNÍ GANGLIA



BAZÁLNÍ PŘEDNÍ MOZEK

DORSÁLNÍ STRIATUM

- NCL.CAUDATUS, PUTAMEN

VENTRÁLNÍ STRIATUM

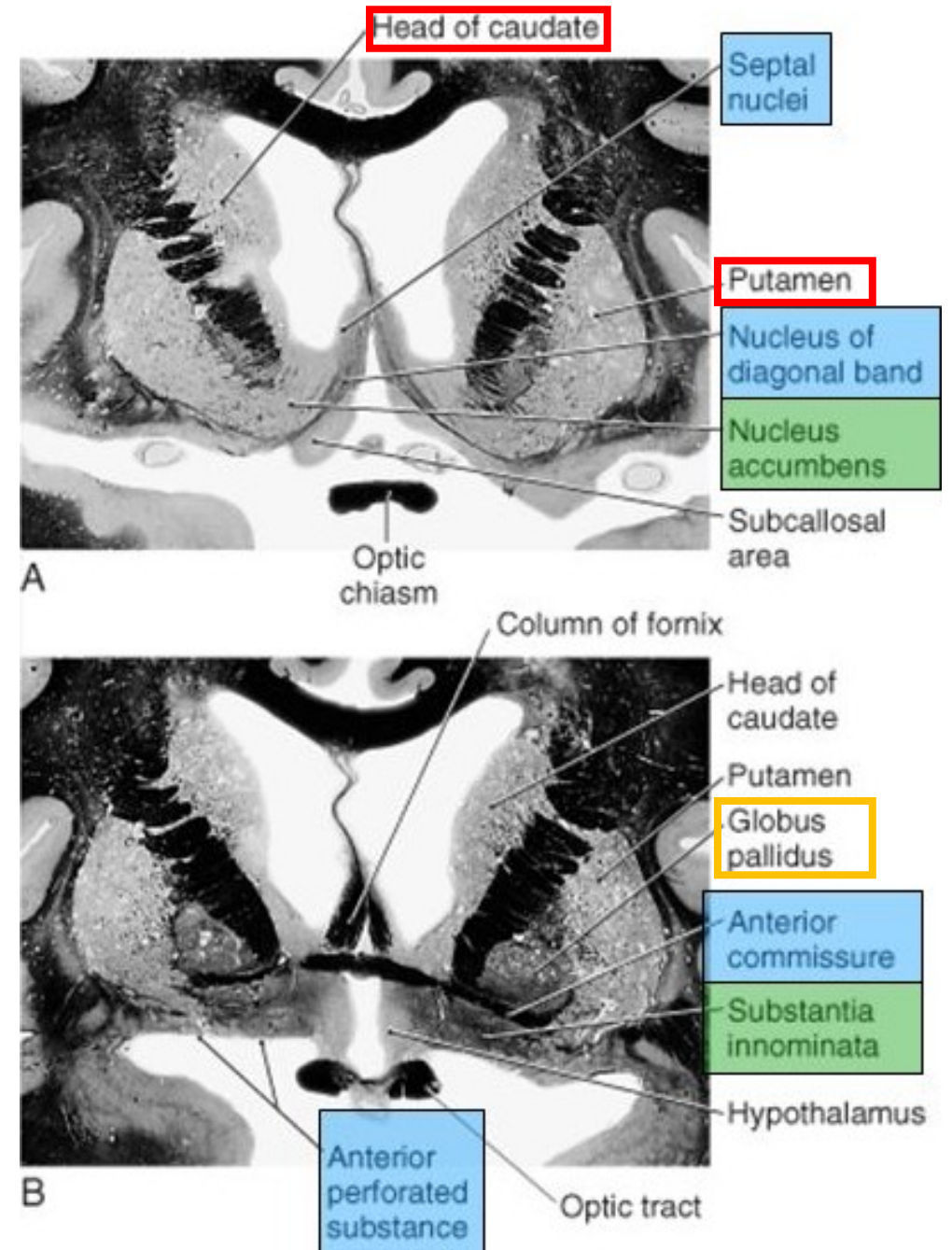
- NCL.ACCUMBENS

DORSÁLNÍ PALLIDUM

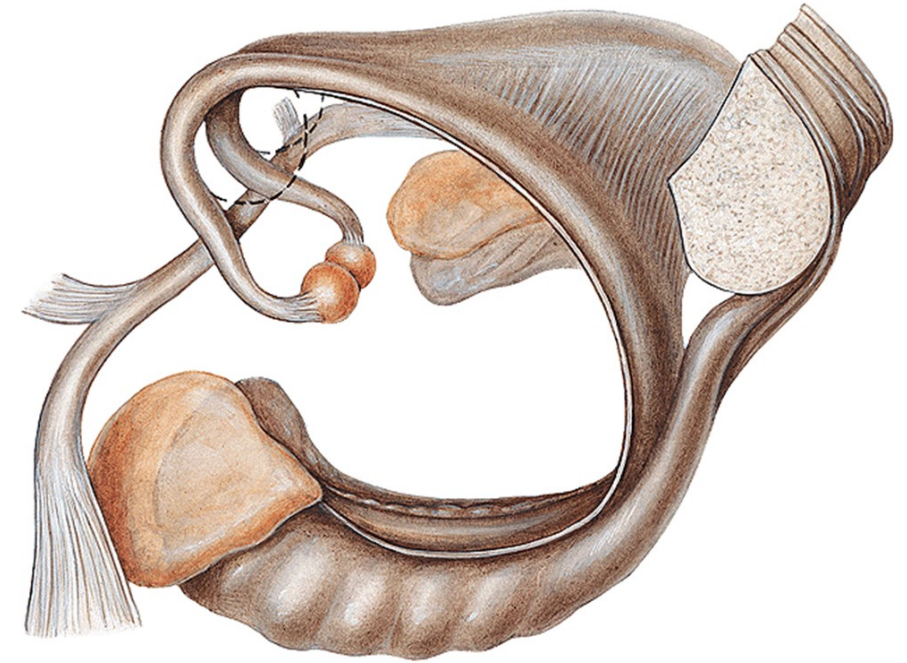
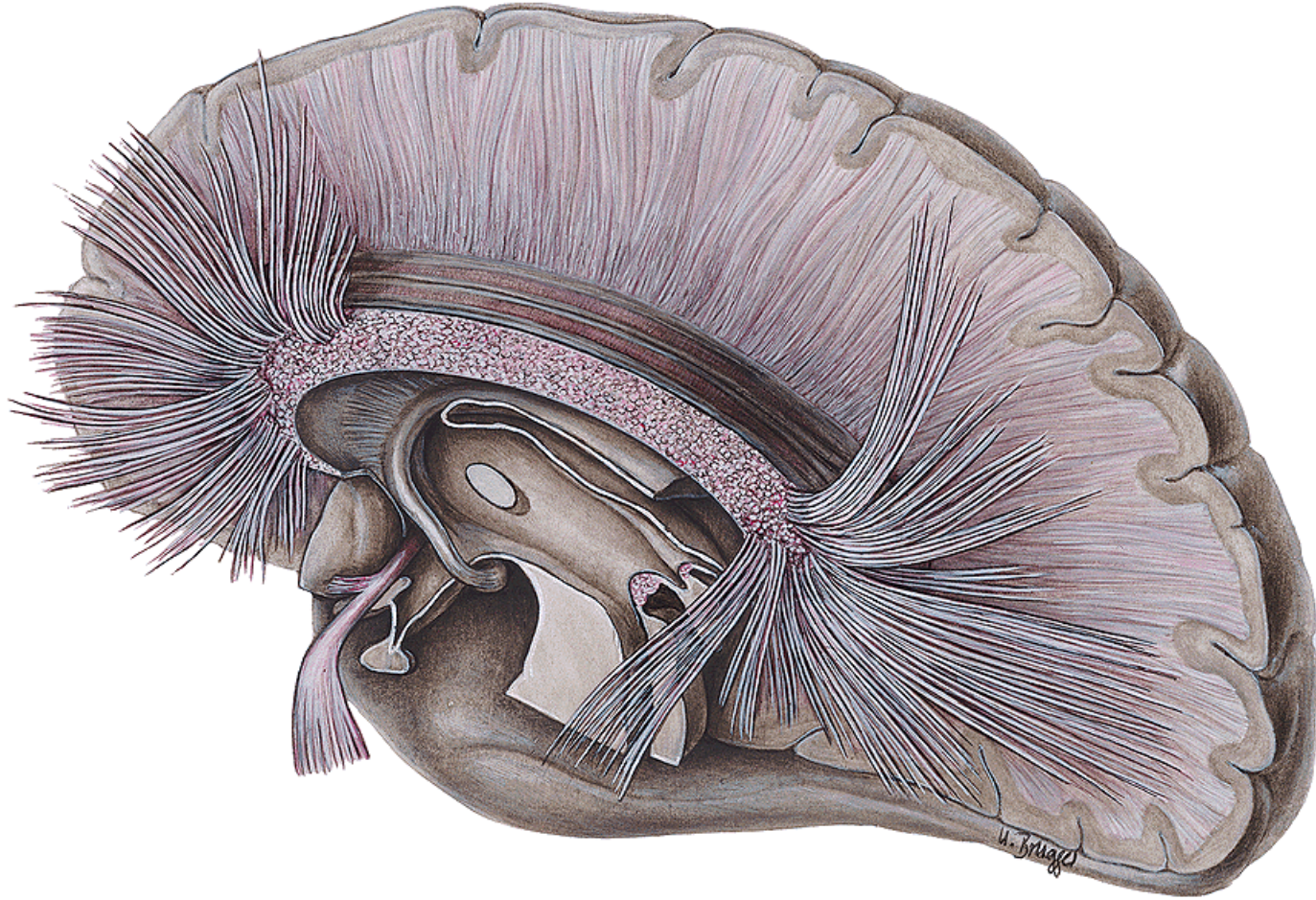
- GLOBUS PALLIDUS

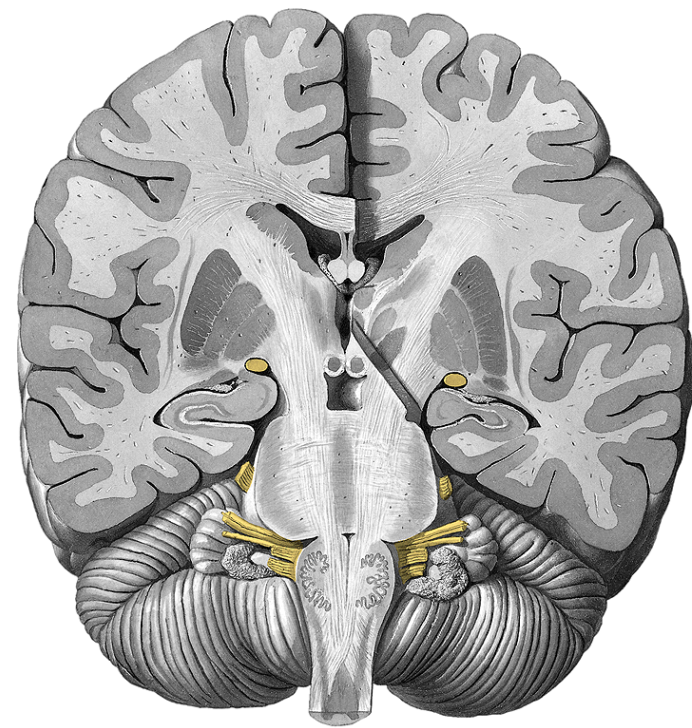
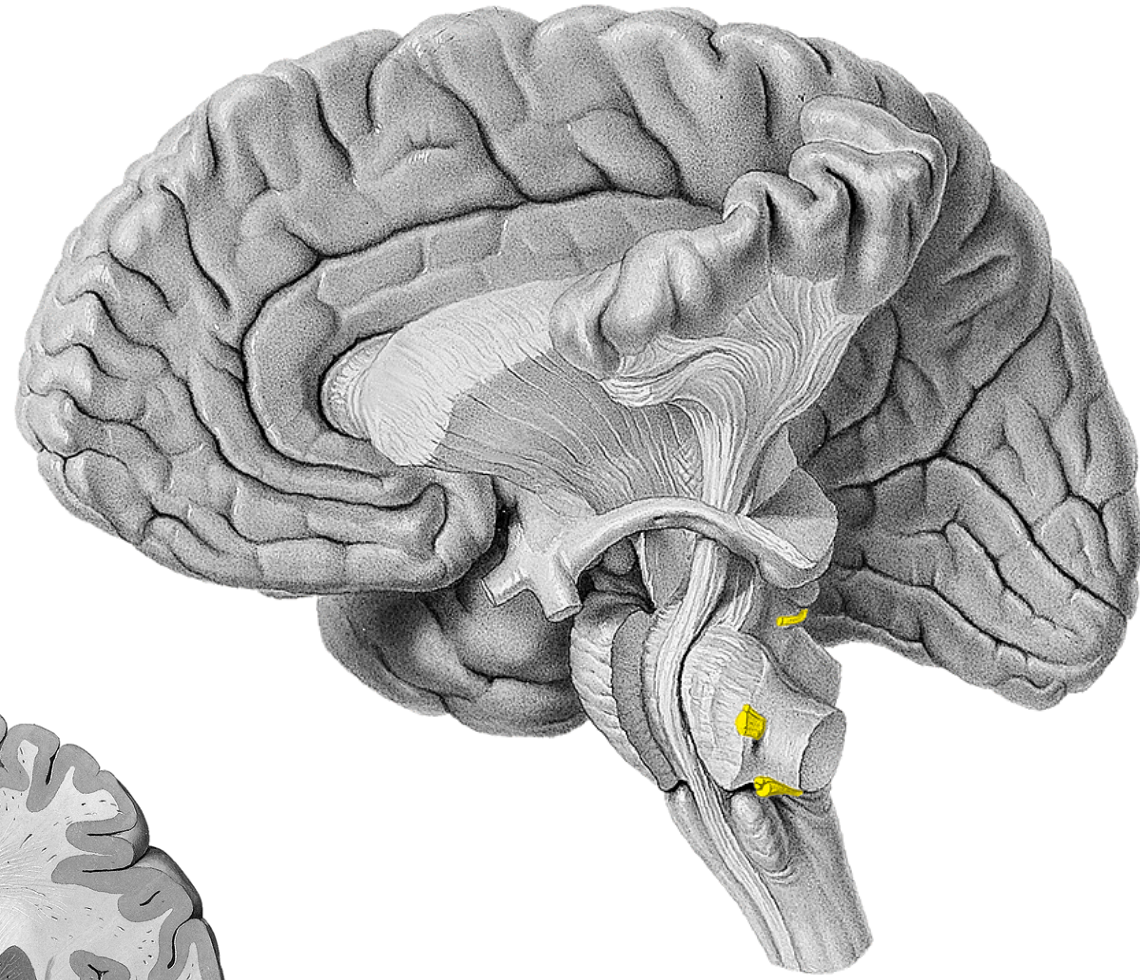
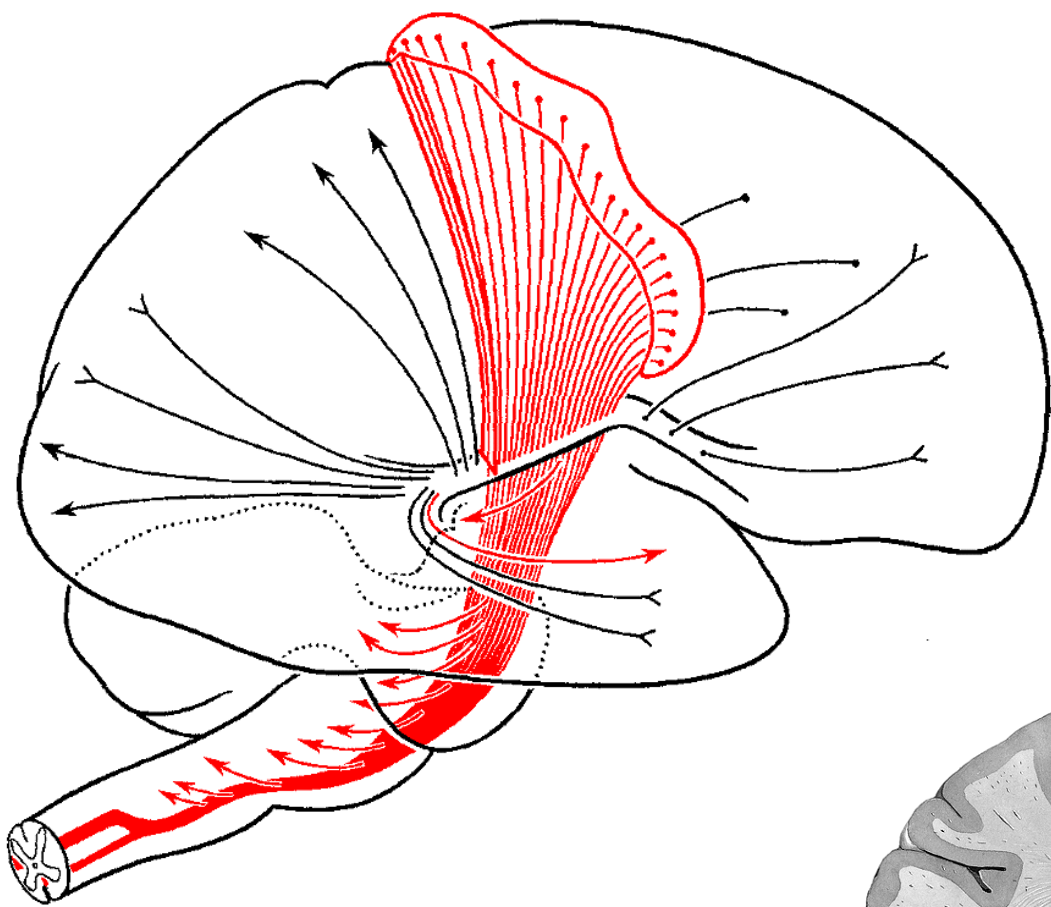
VENTRÁLNÍ PALLIDUM

- SUBSTANTIA INNOMINATA, NCL.BASALIS

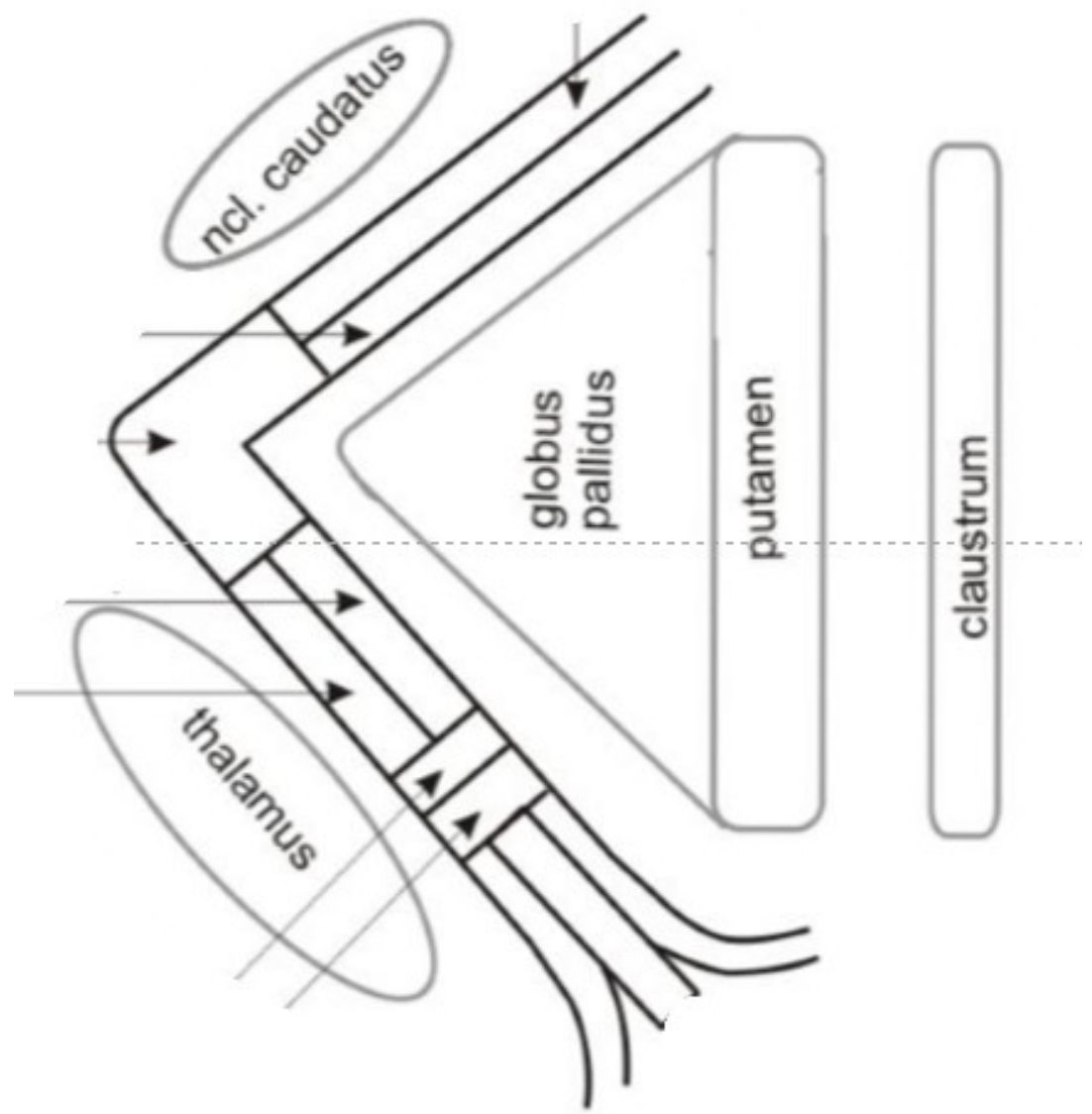
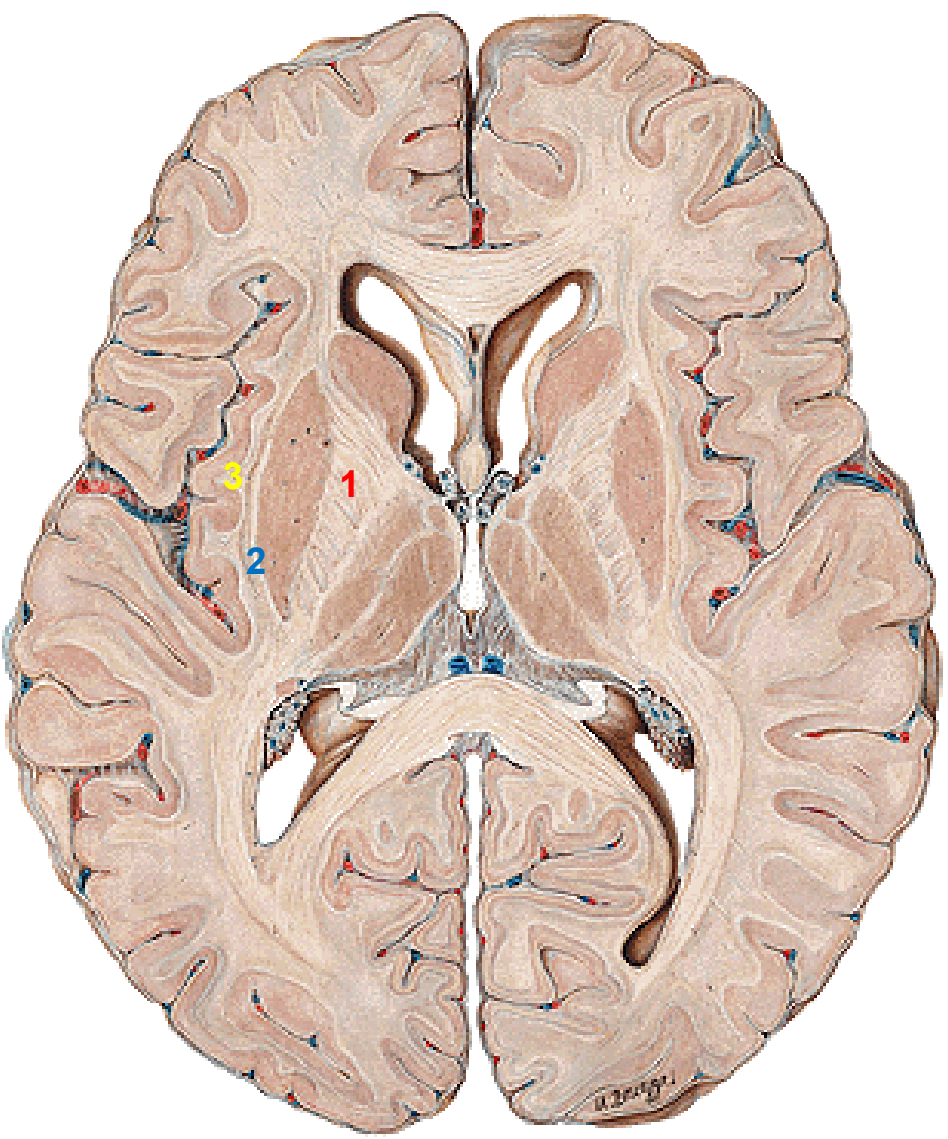


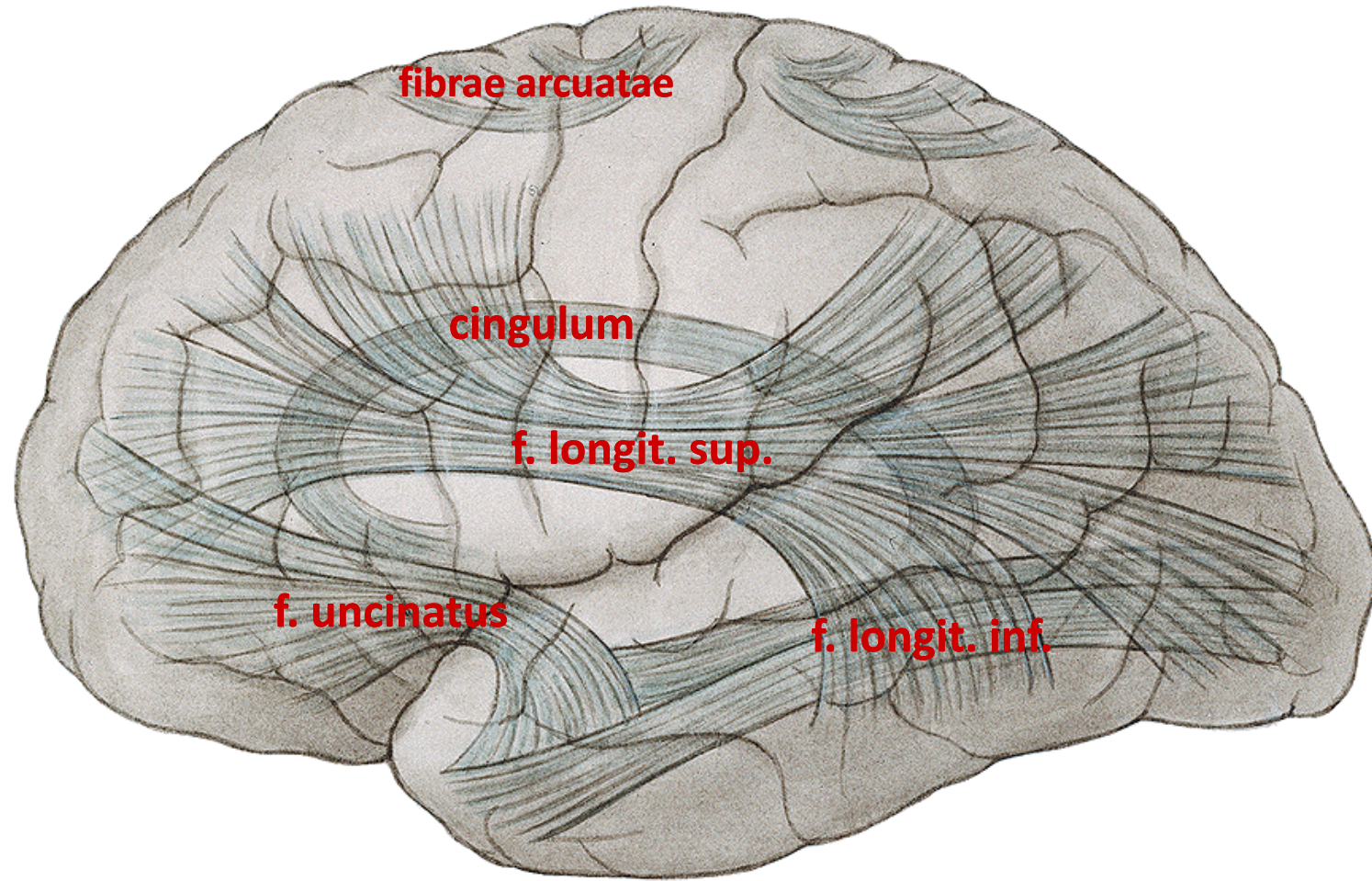
BÍLÁ HMOTA TELENCEPHALA – CORPUS MEDULLARE





**capsula
interna**





fibrae arcuatae

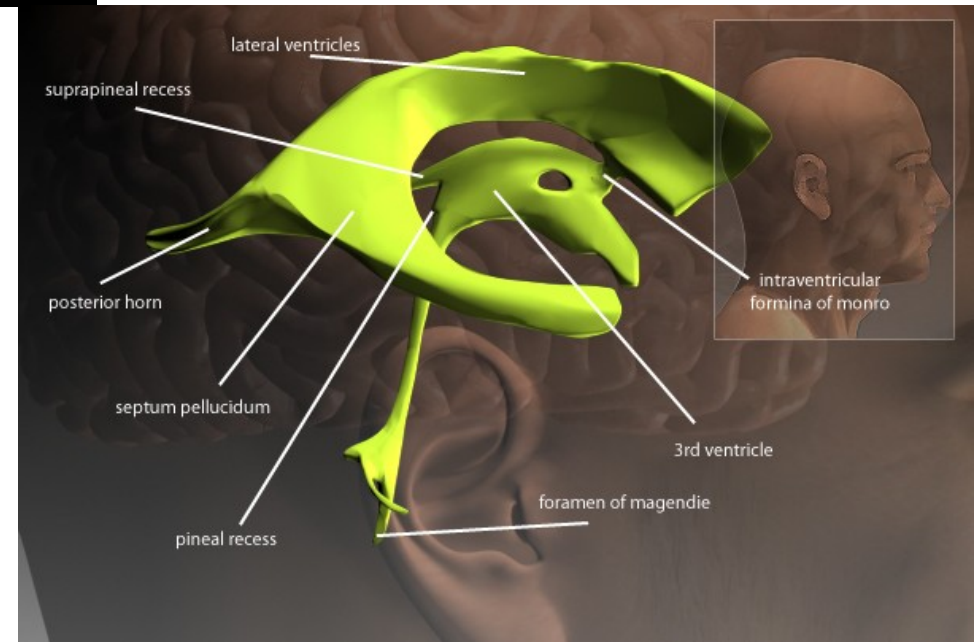
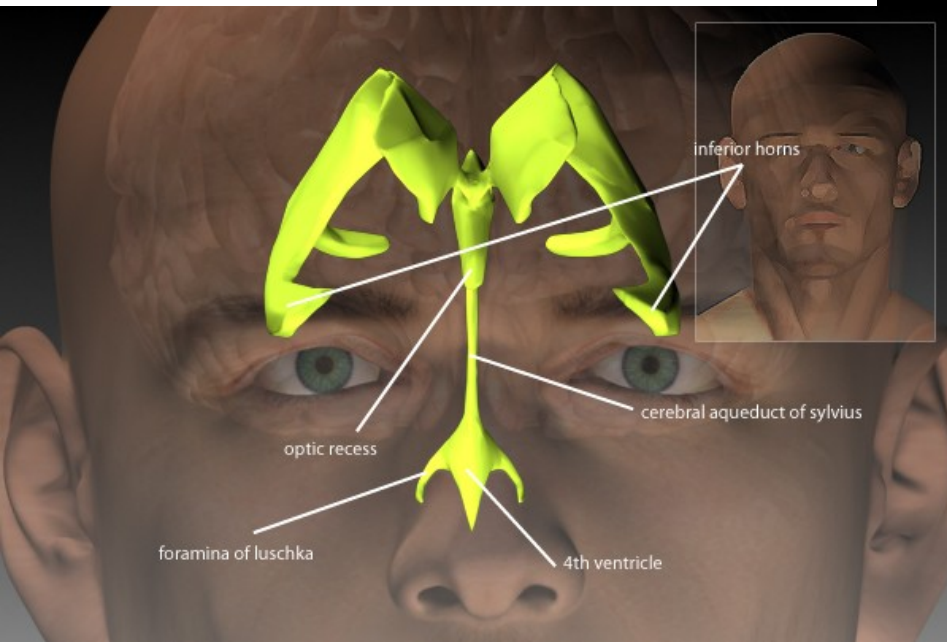
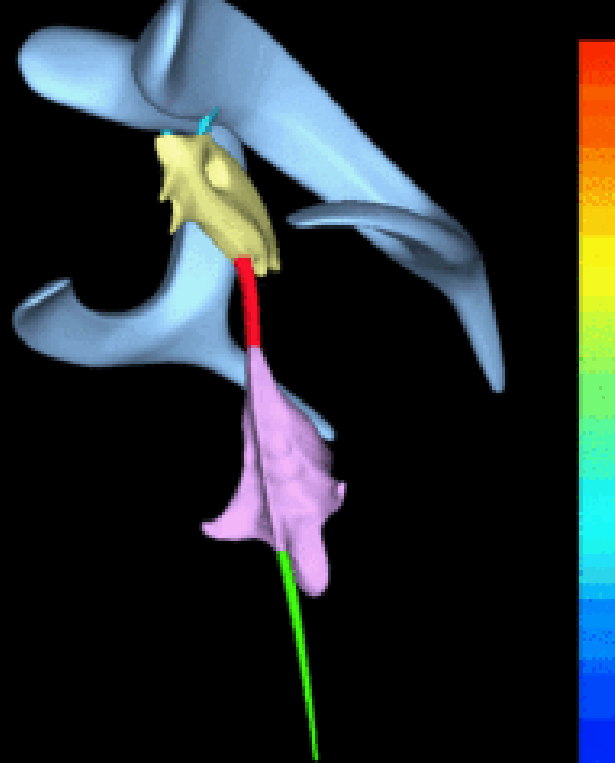cingulum

f. longit. sup.

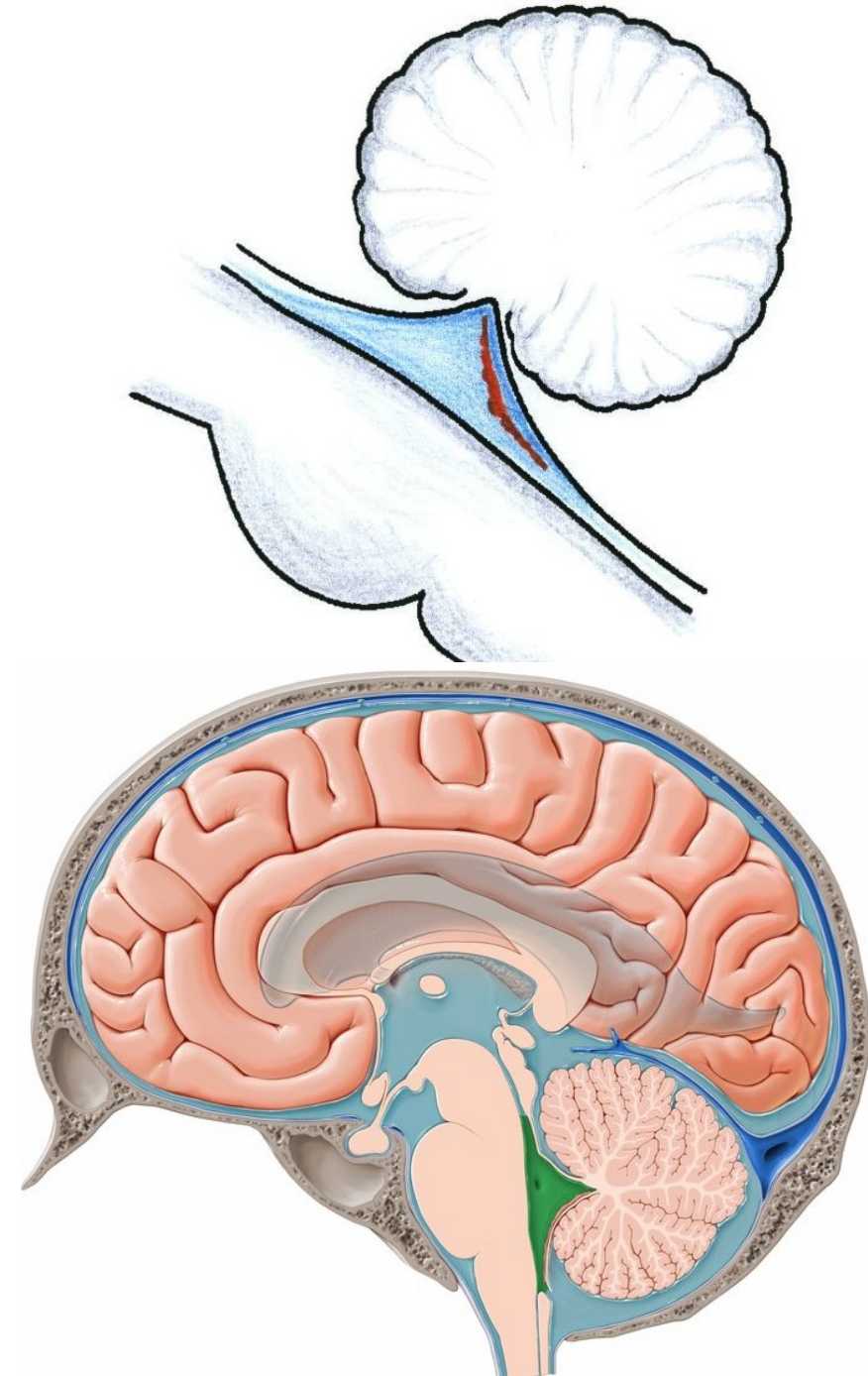
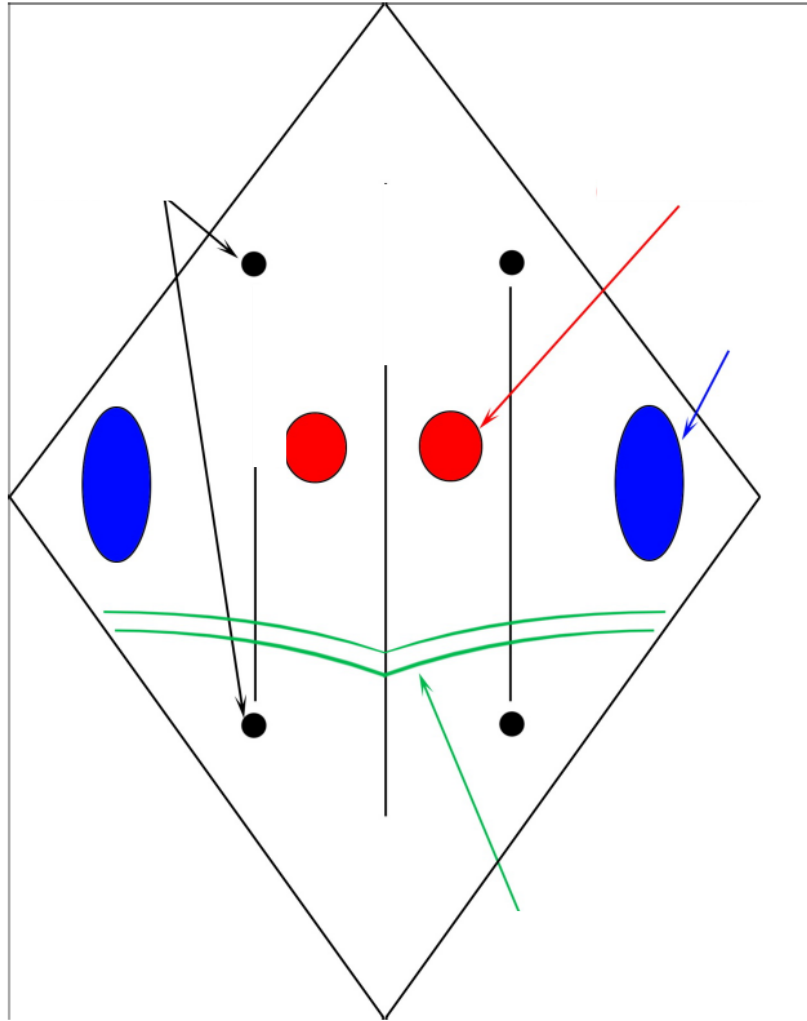
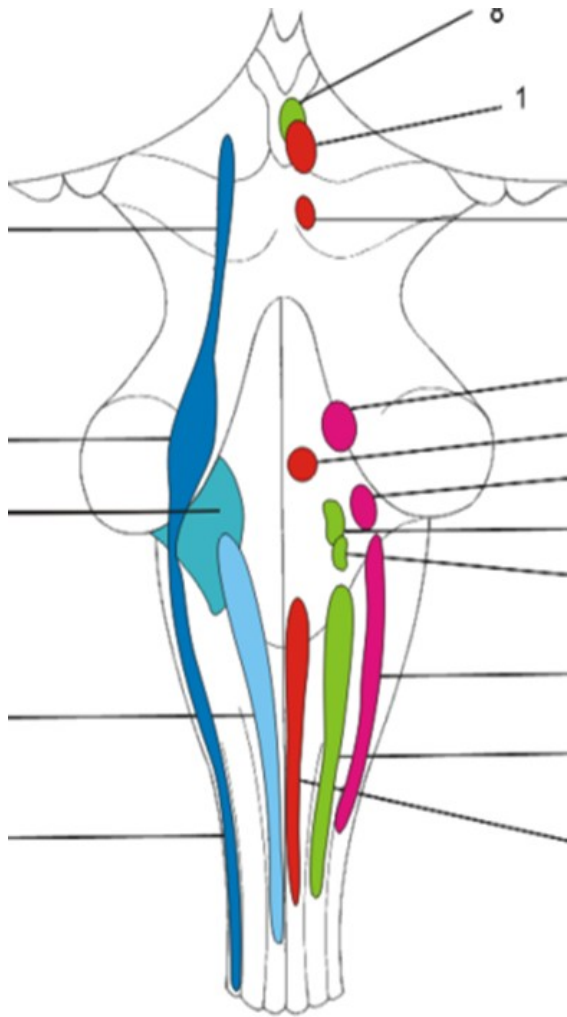
f. uncinatus

f. longit. inf.

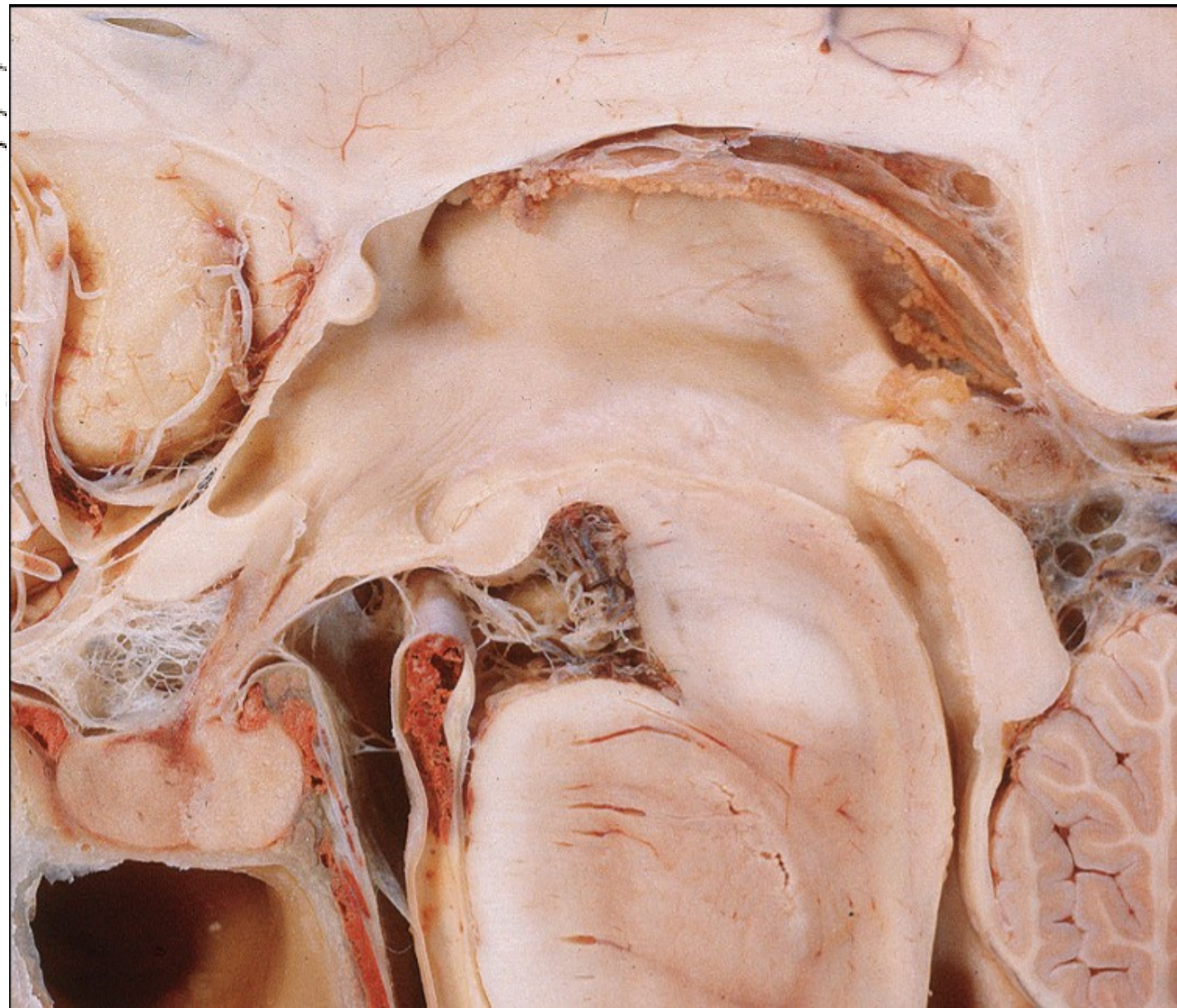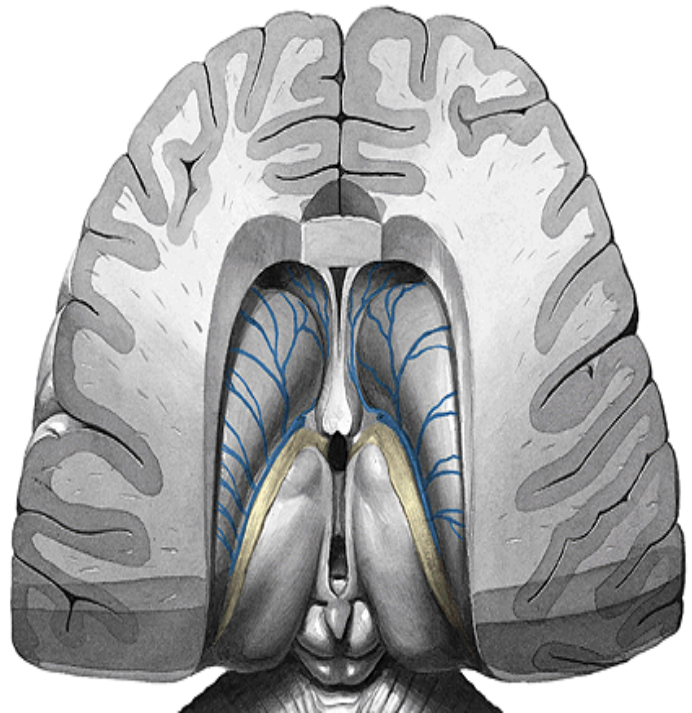
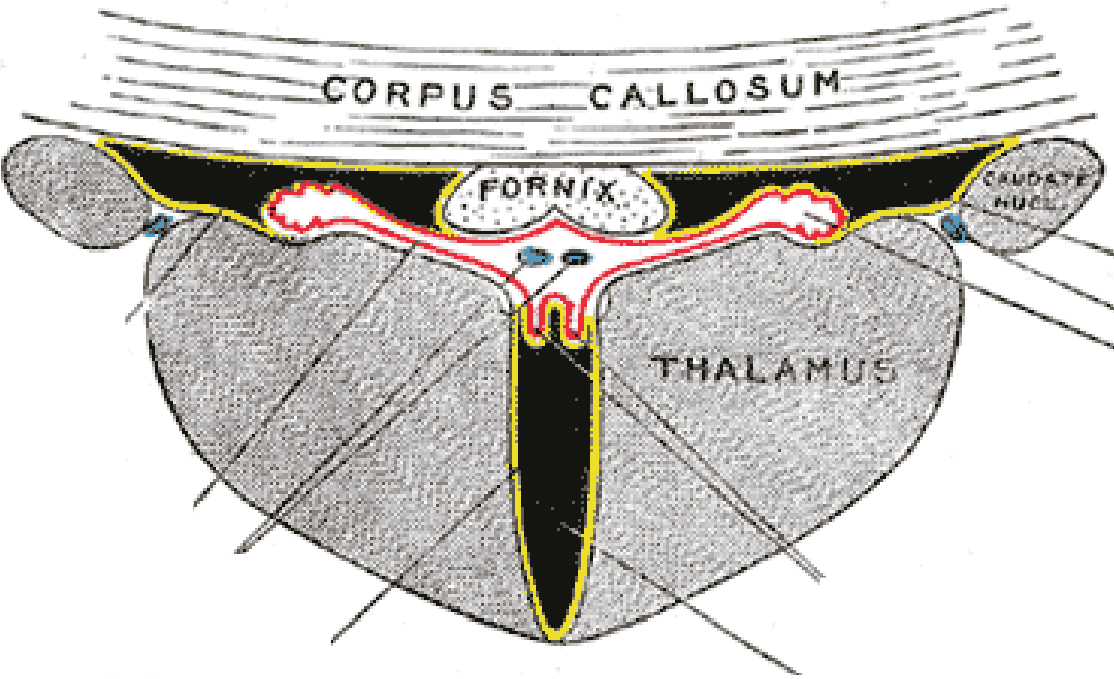
VENTRICULI CRANIALES



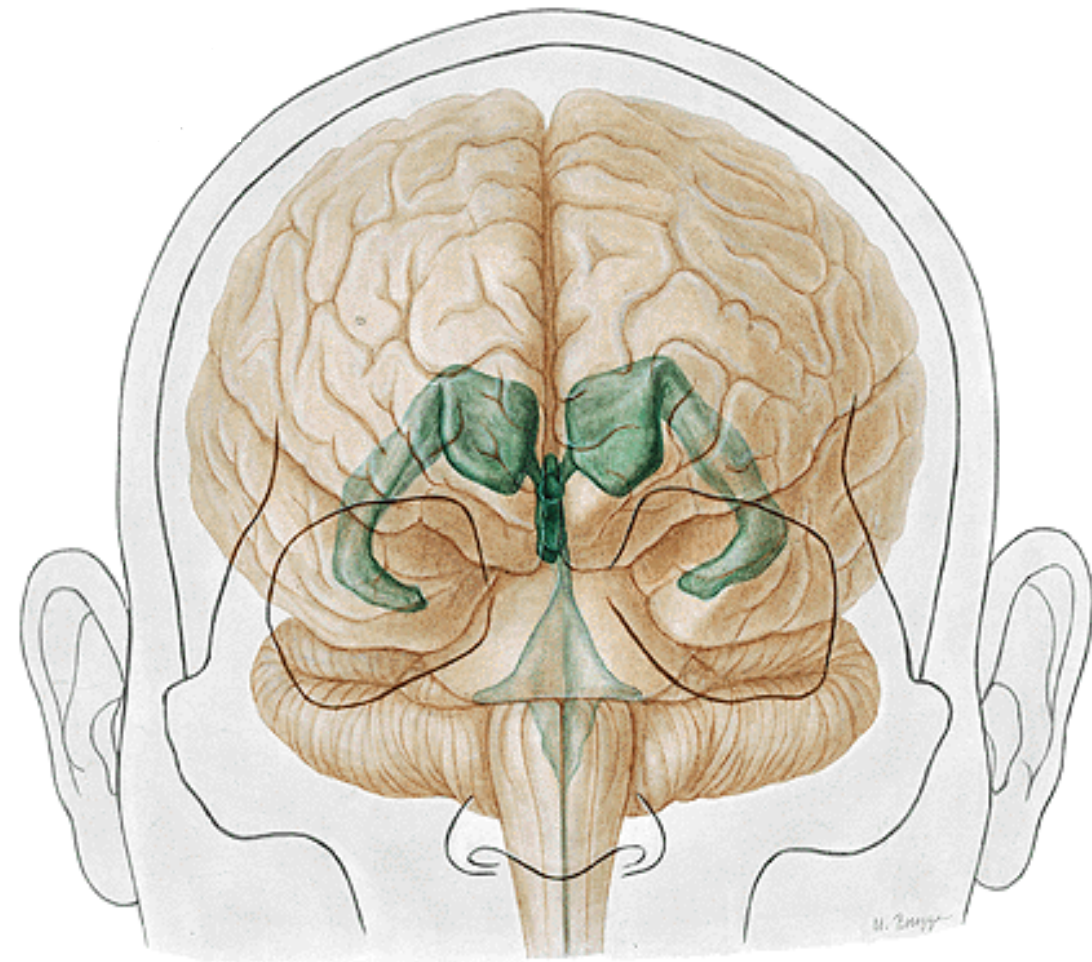
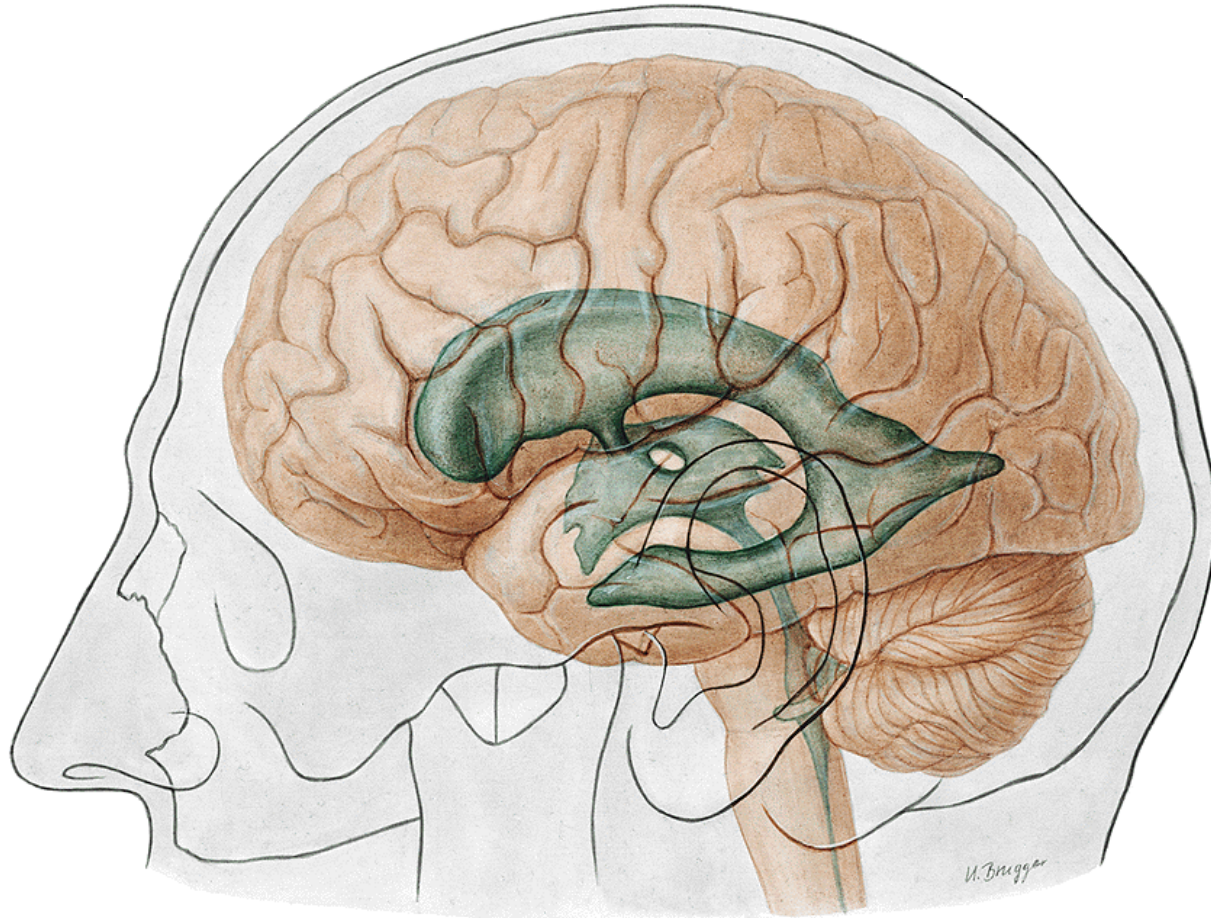
VENTRICULUS QUARTUS

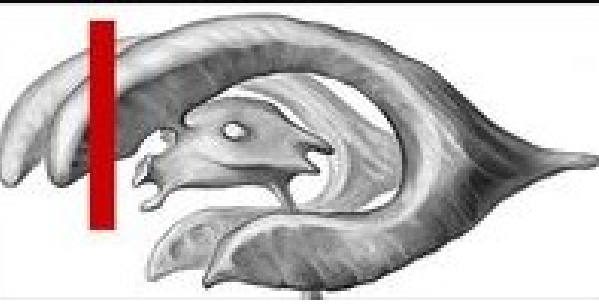


VENTRICULUS TERTIUS

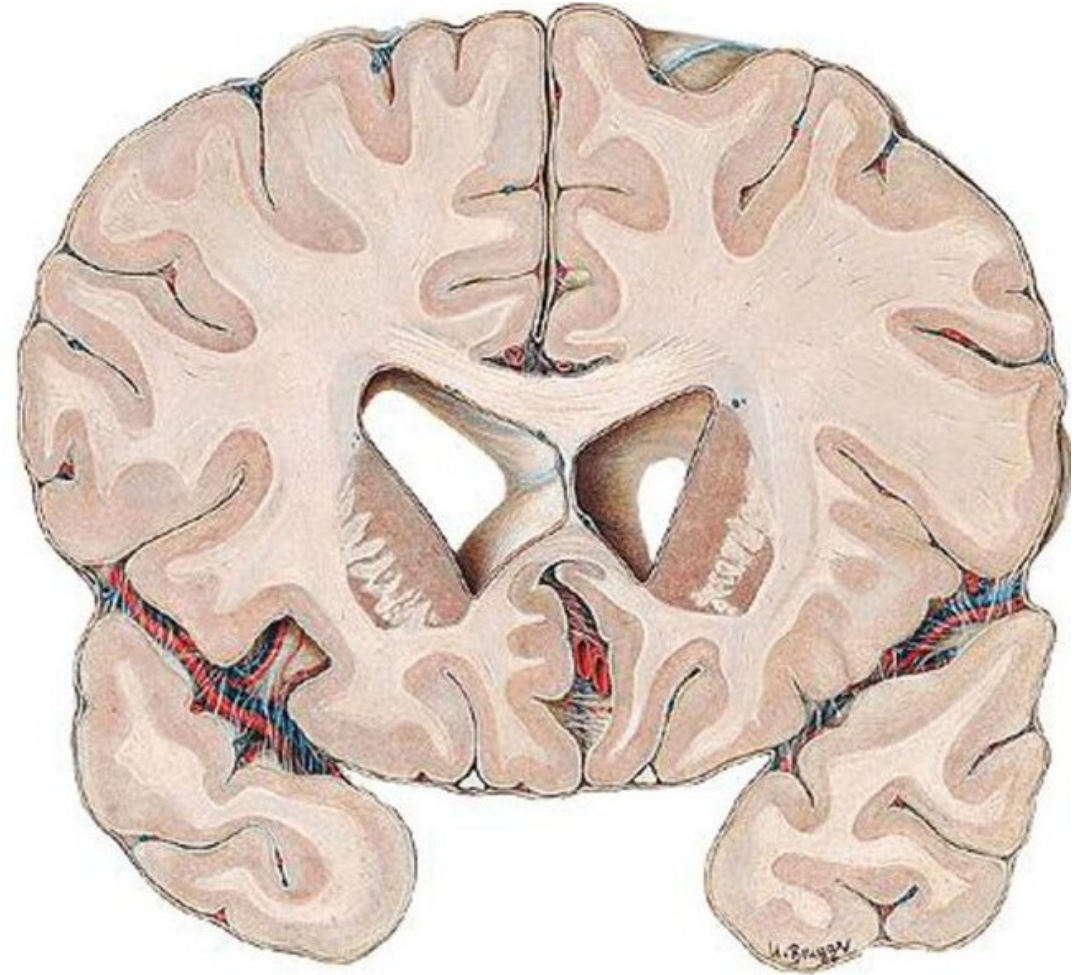
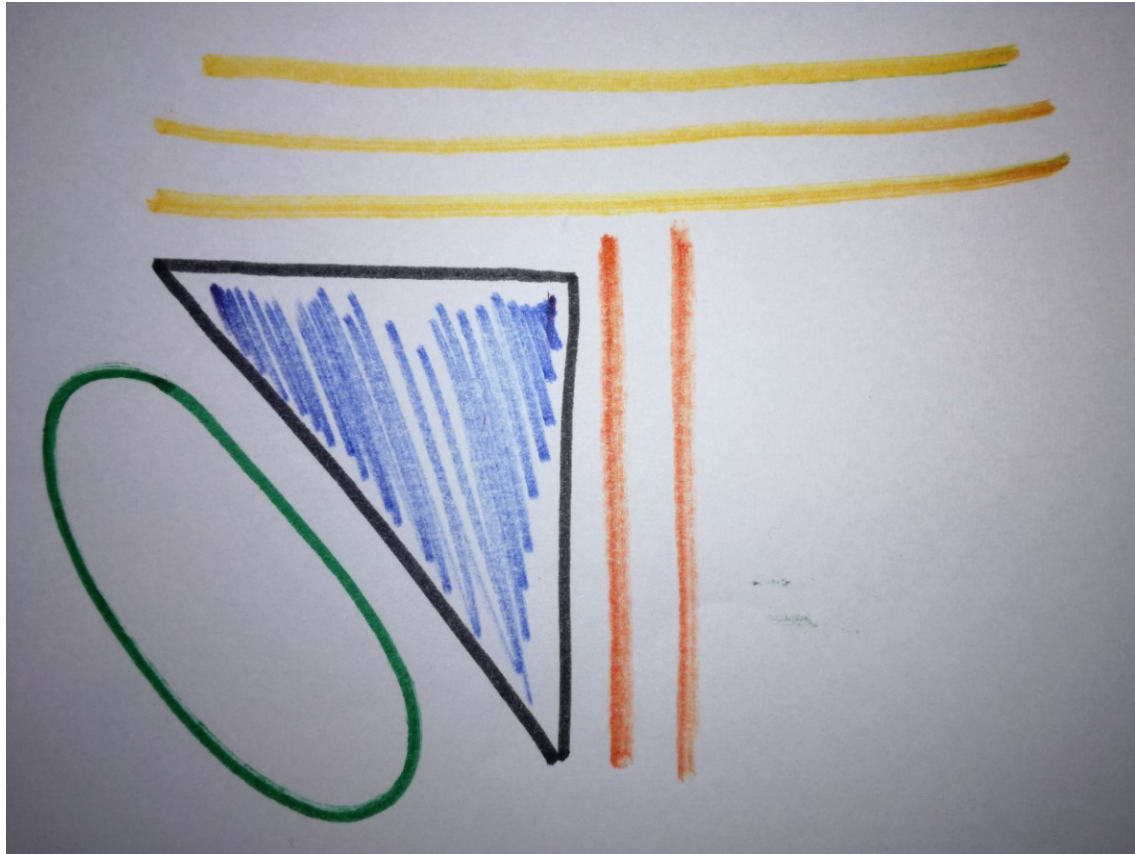


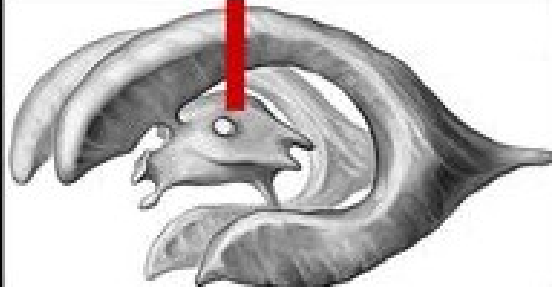
**VENTRICULI
LATERALES**



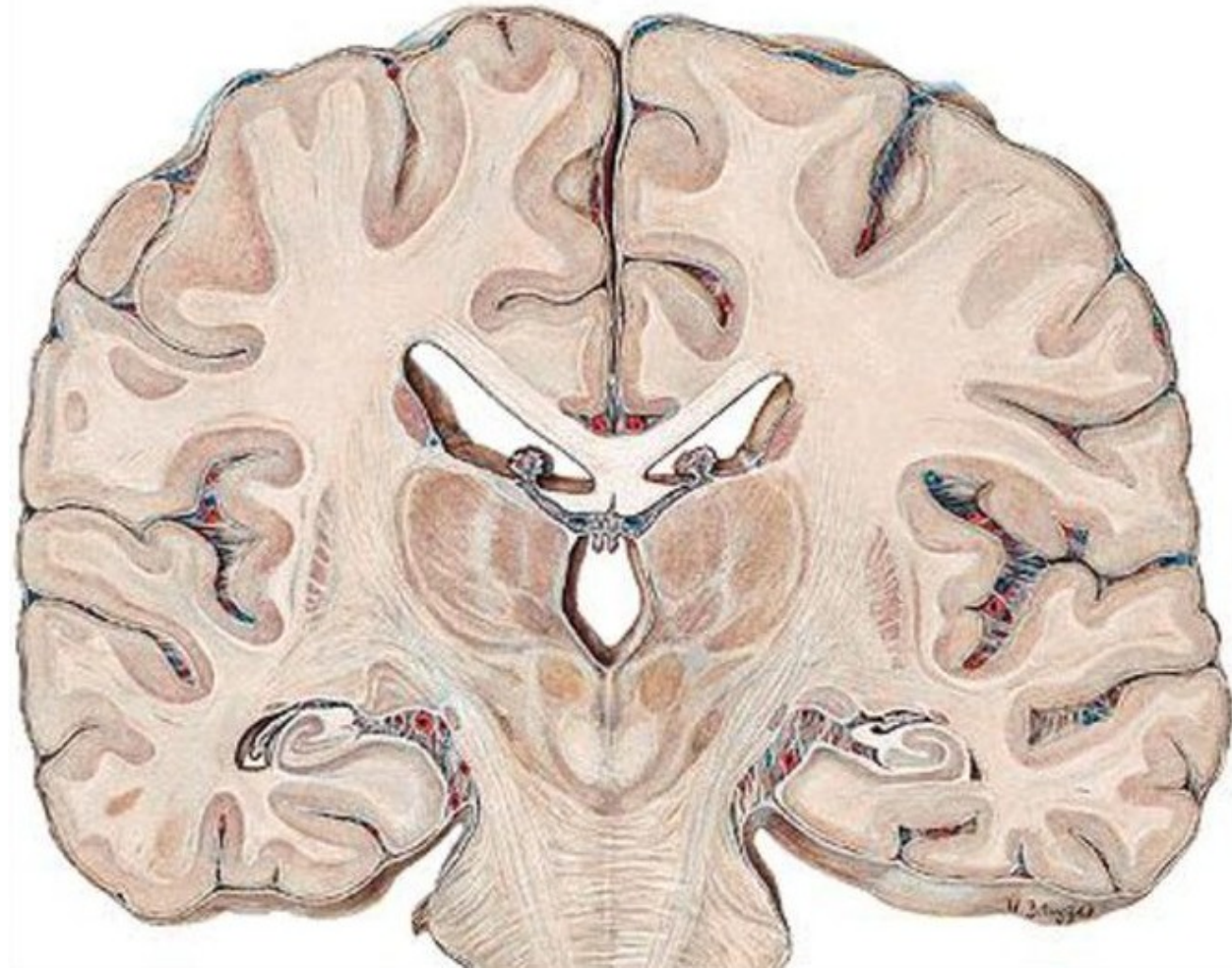
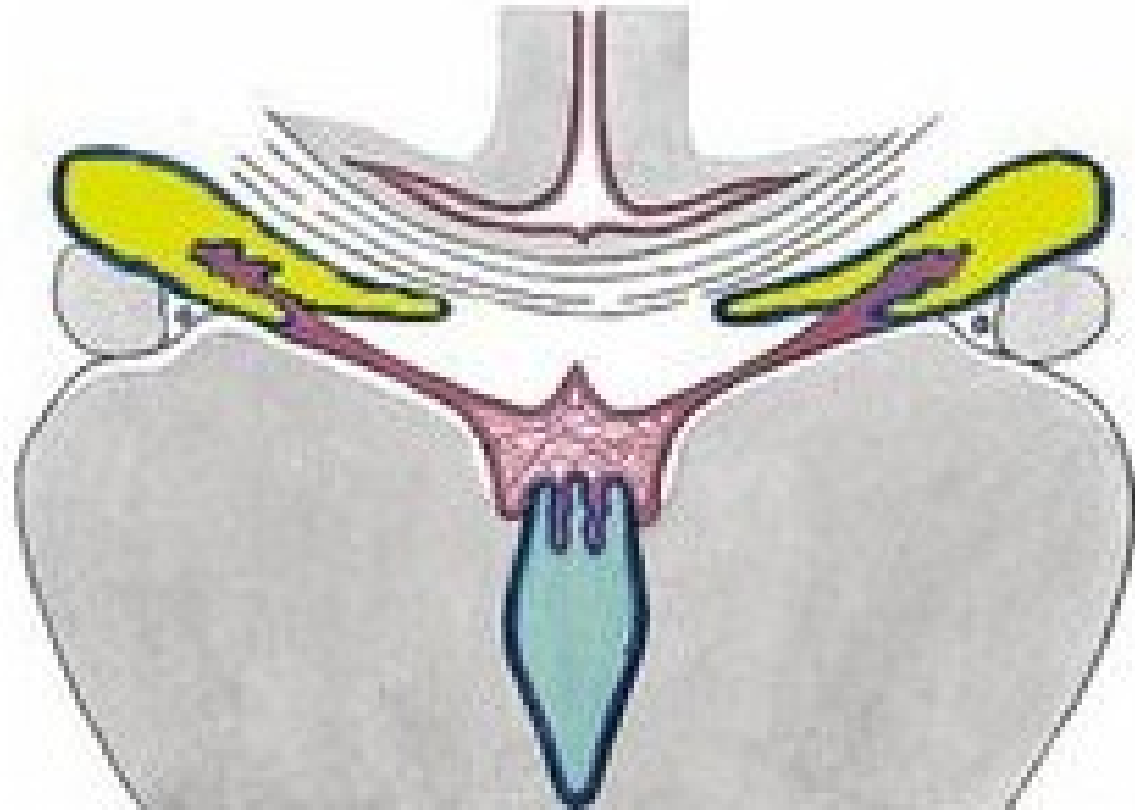


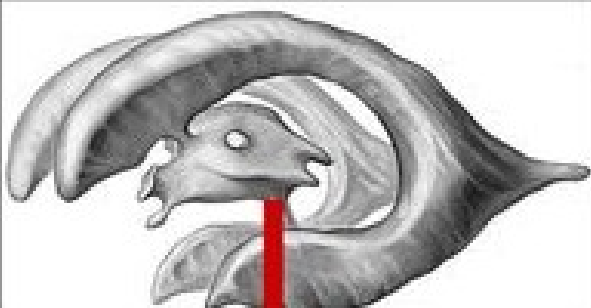**CORNU
ANTERIUS**



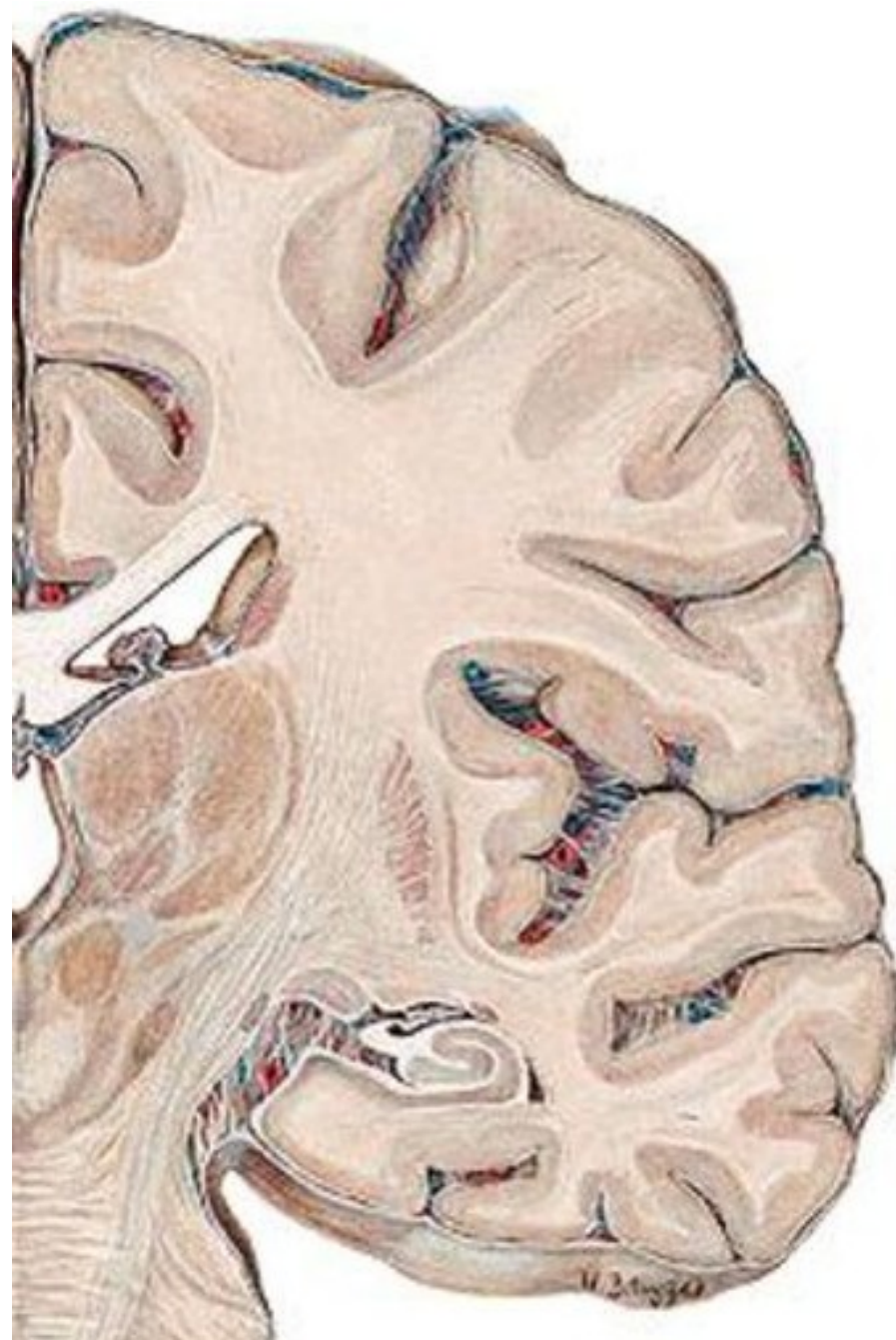
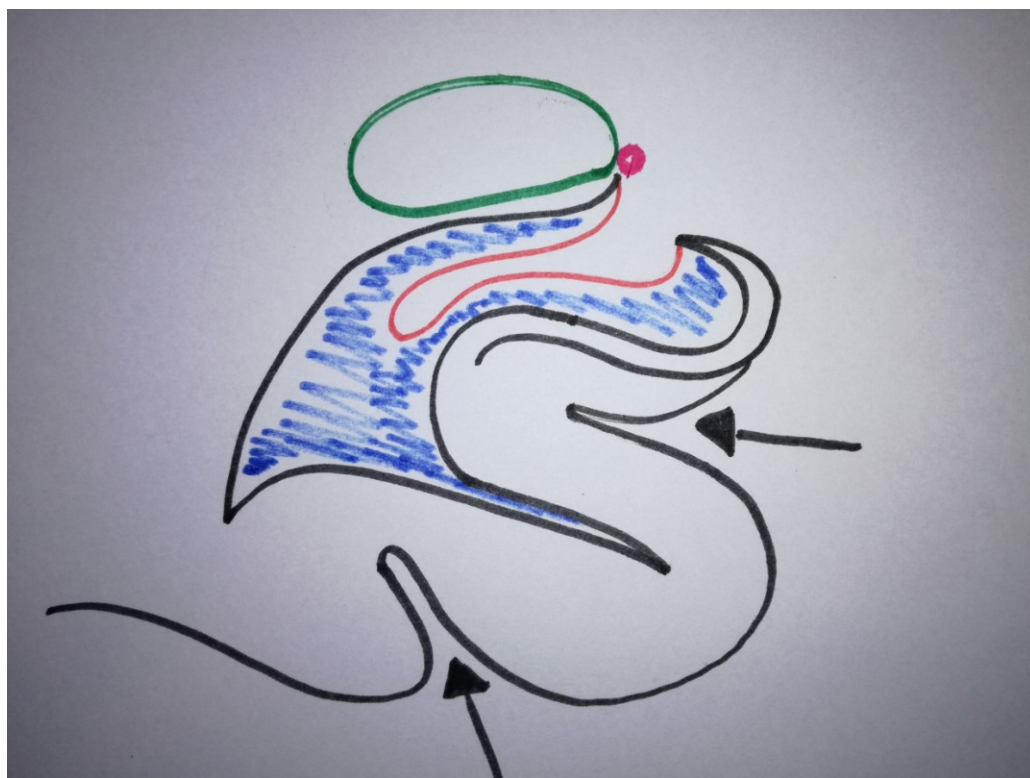


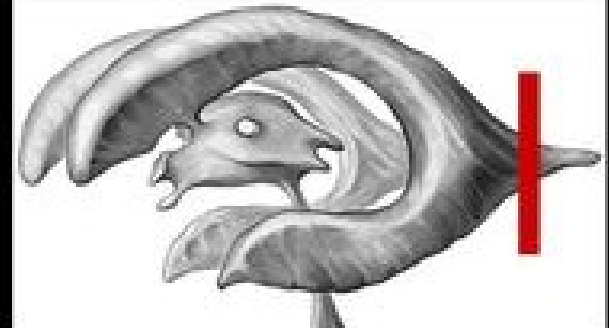
**PARS
CENTRALIS**



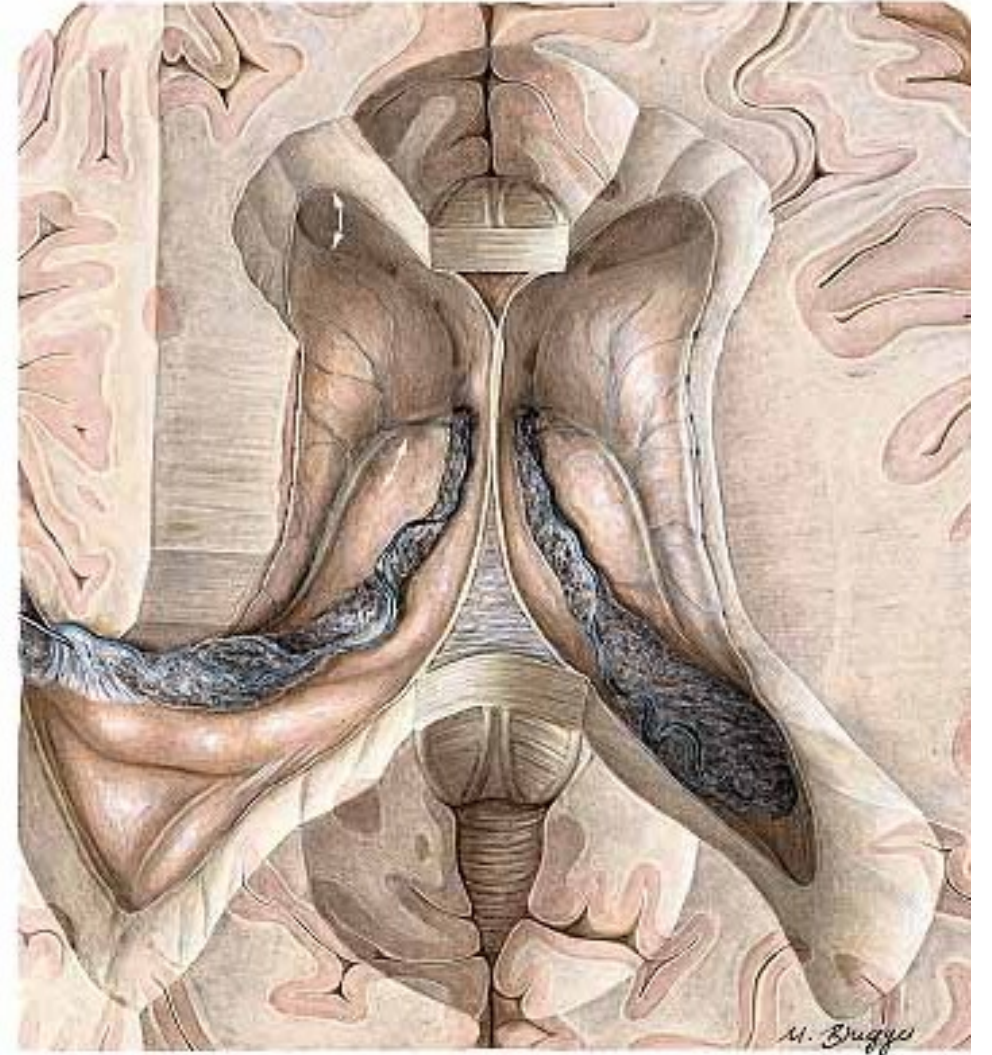
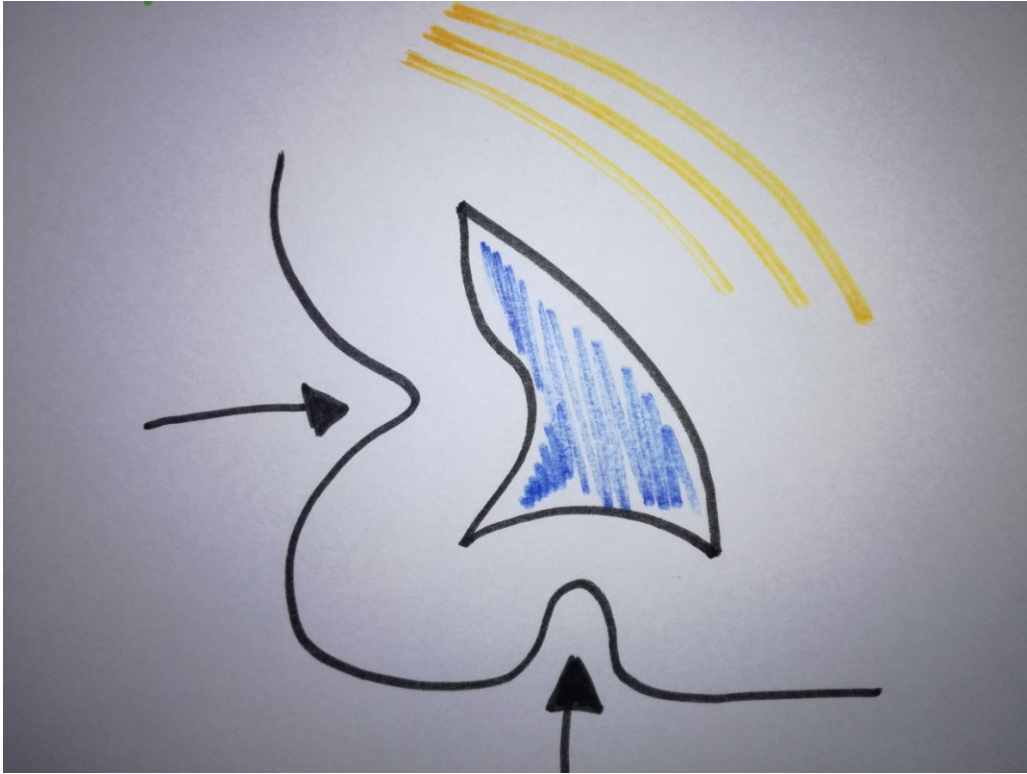


**CORNU
INFERIUS**

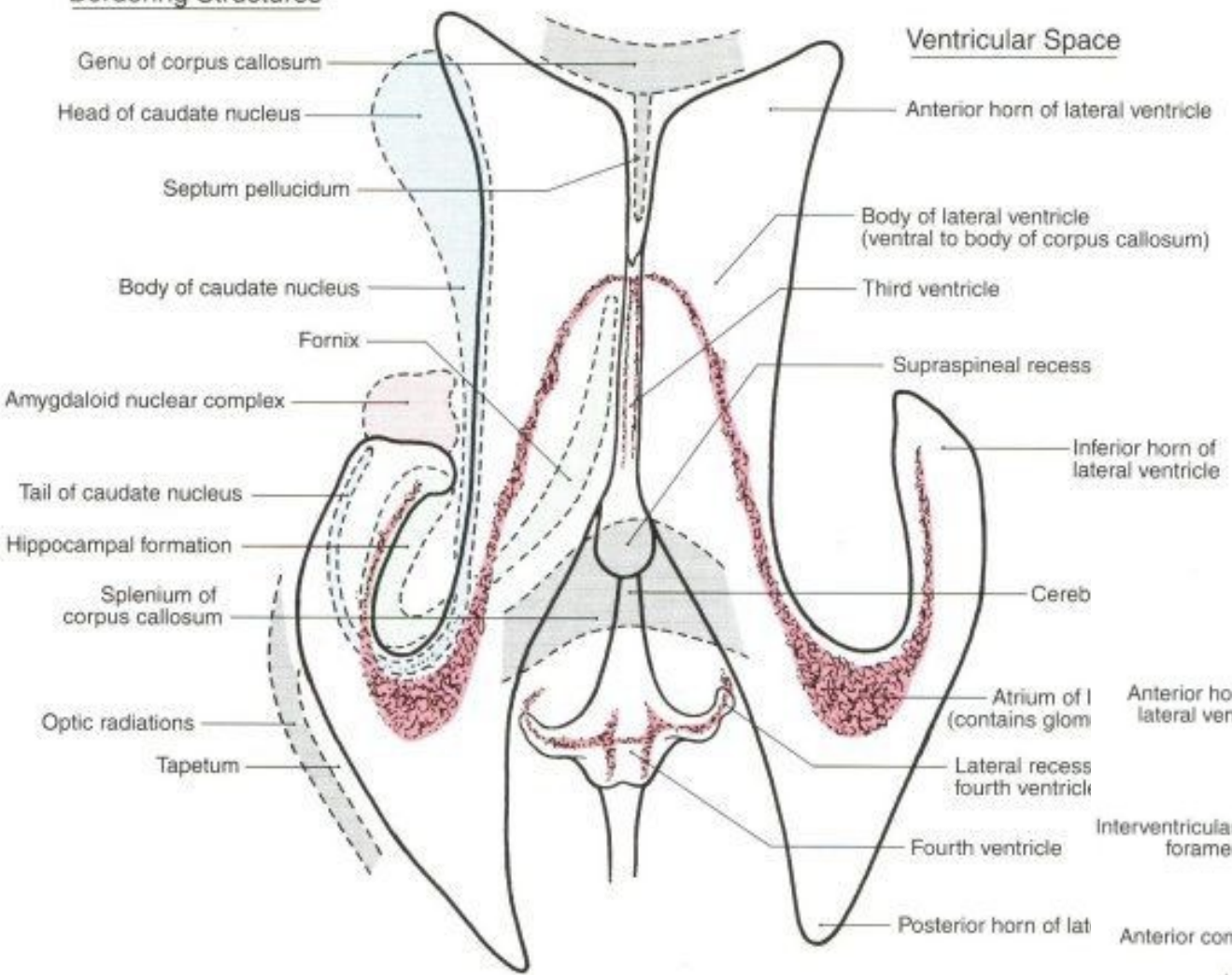




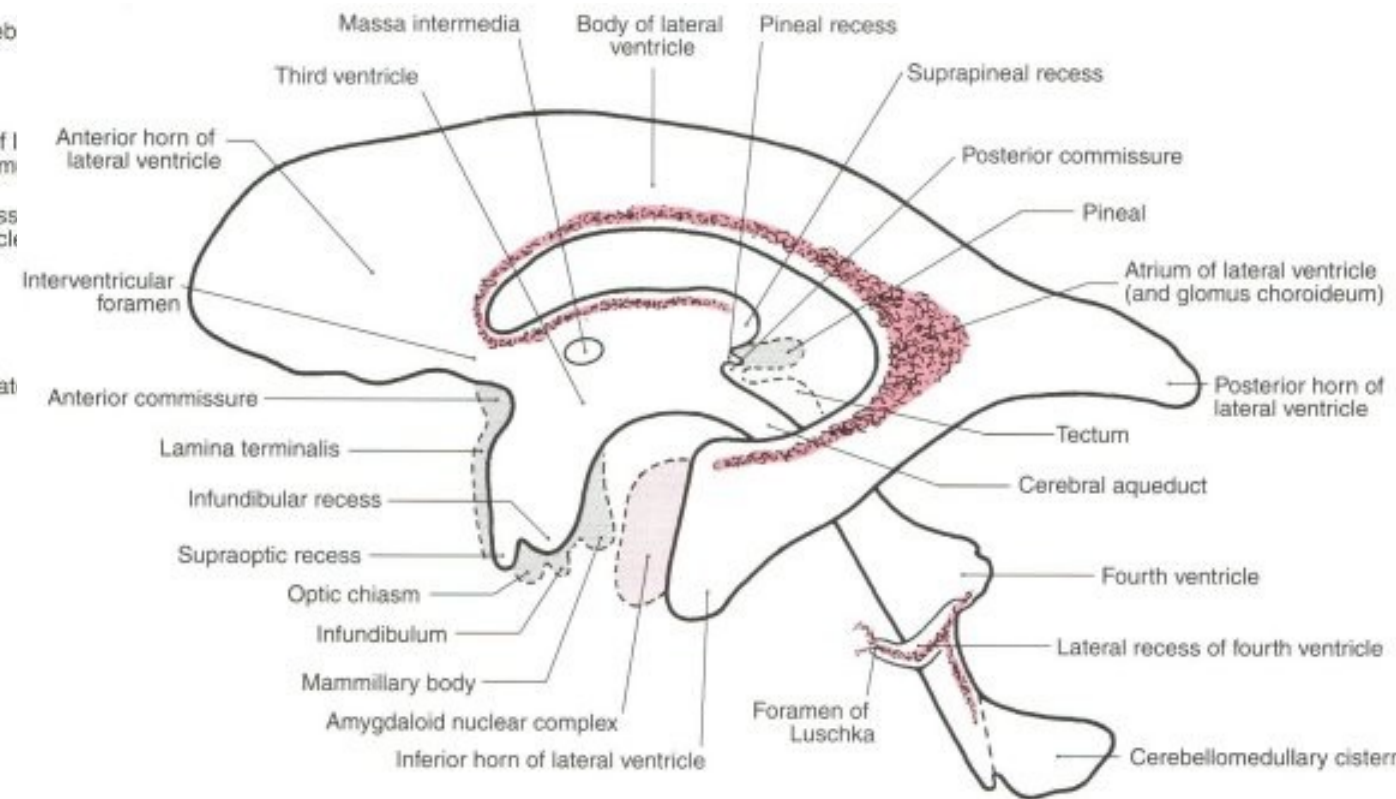
CORNU POSTERIUS



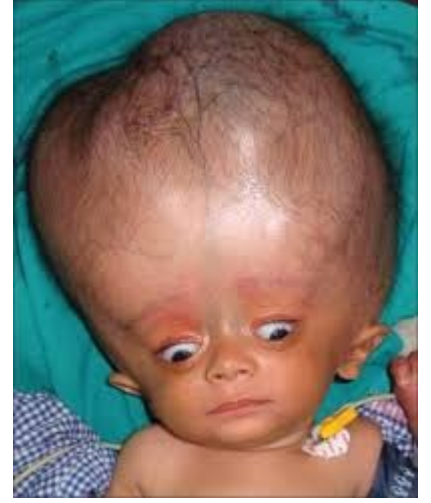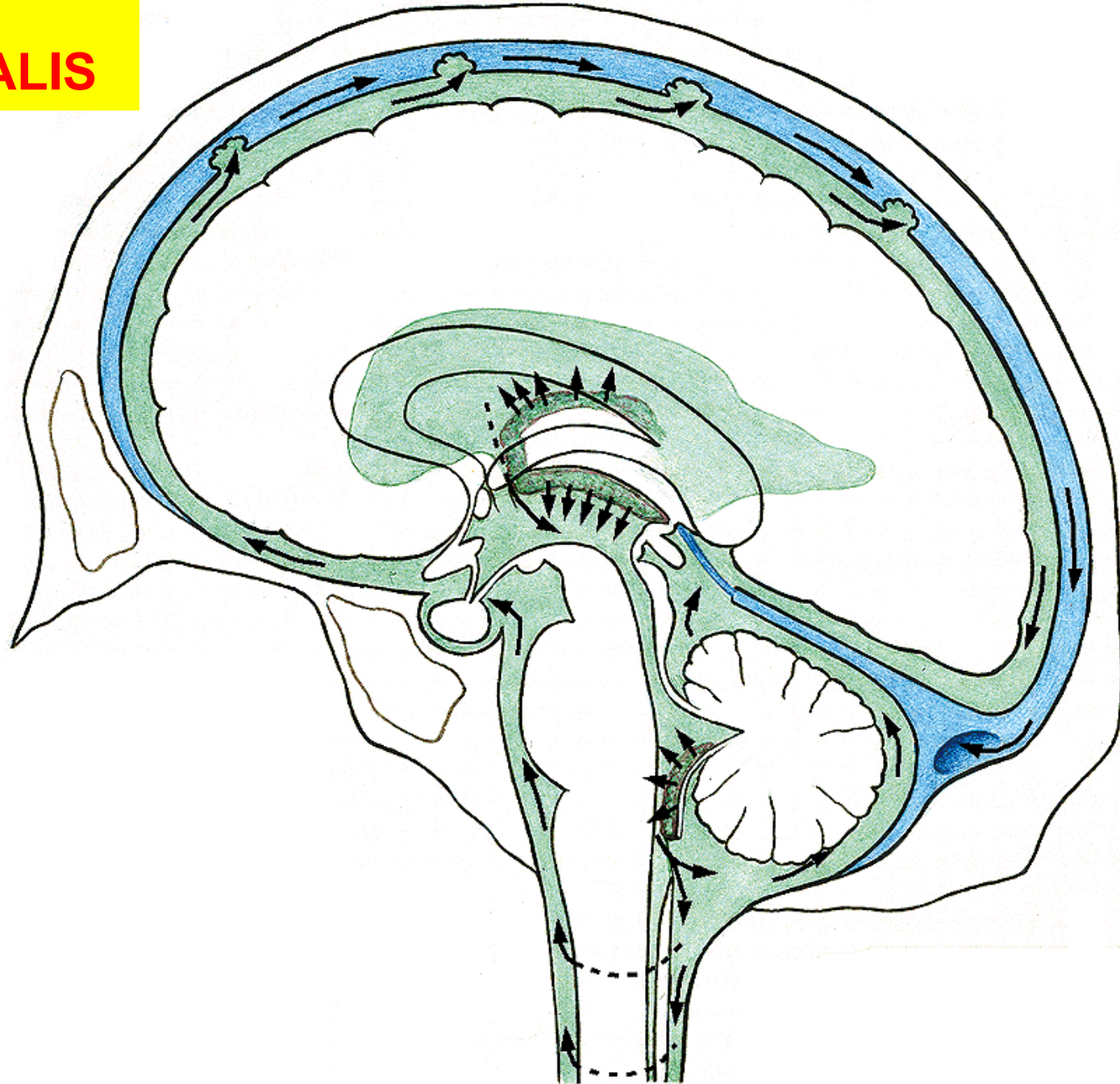
Bordering Structures



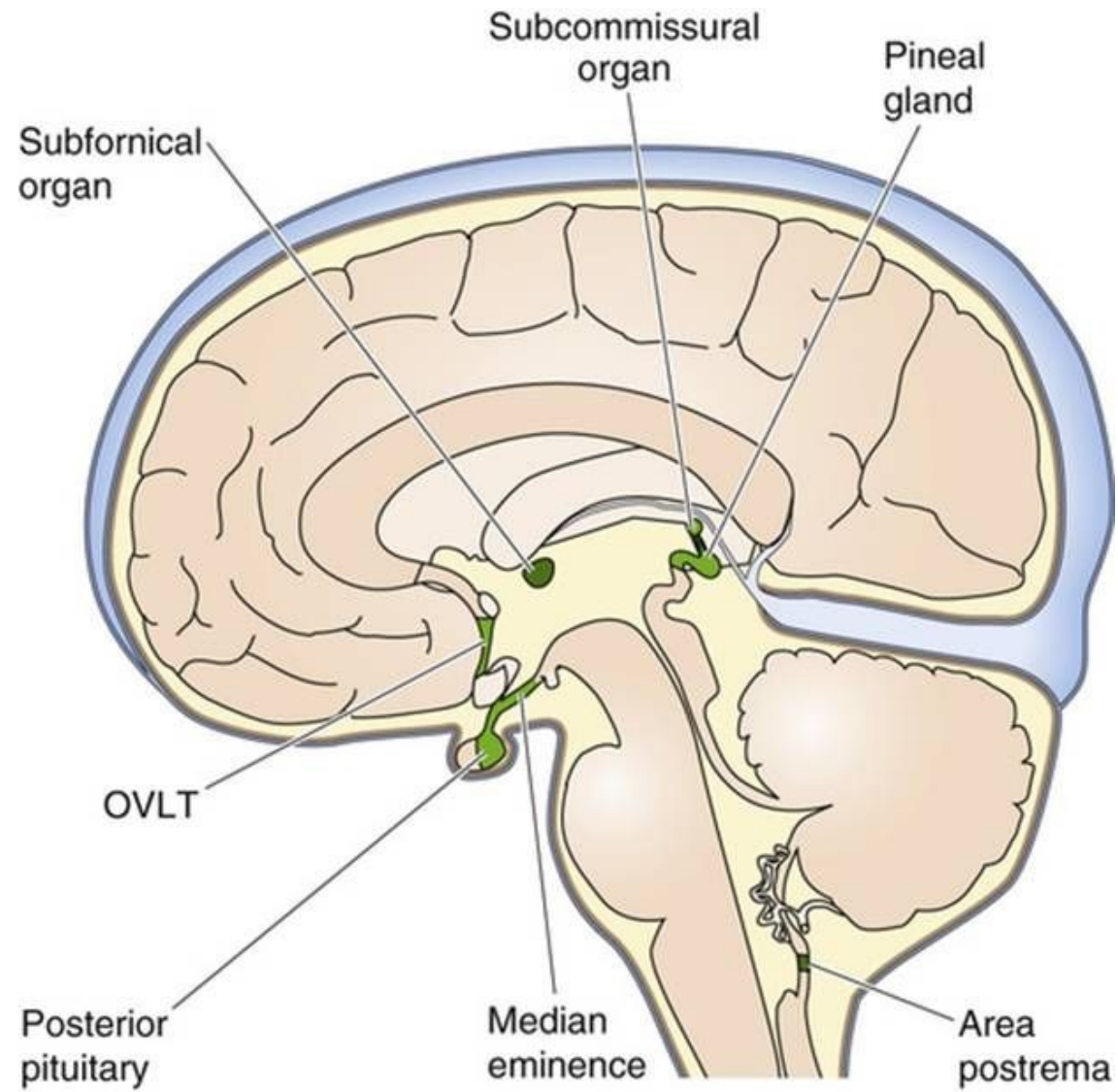
Ventricular Space



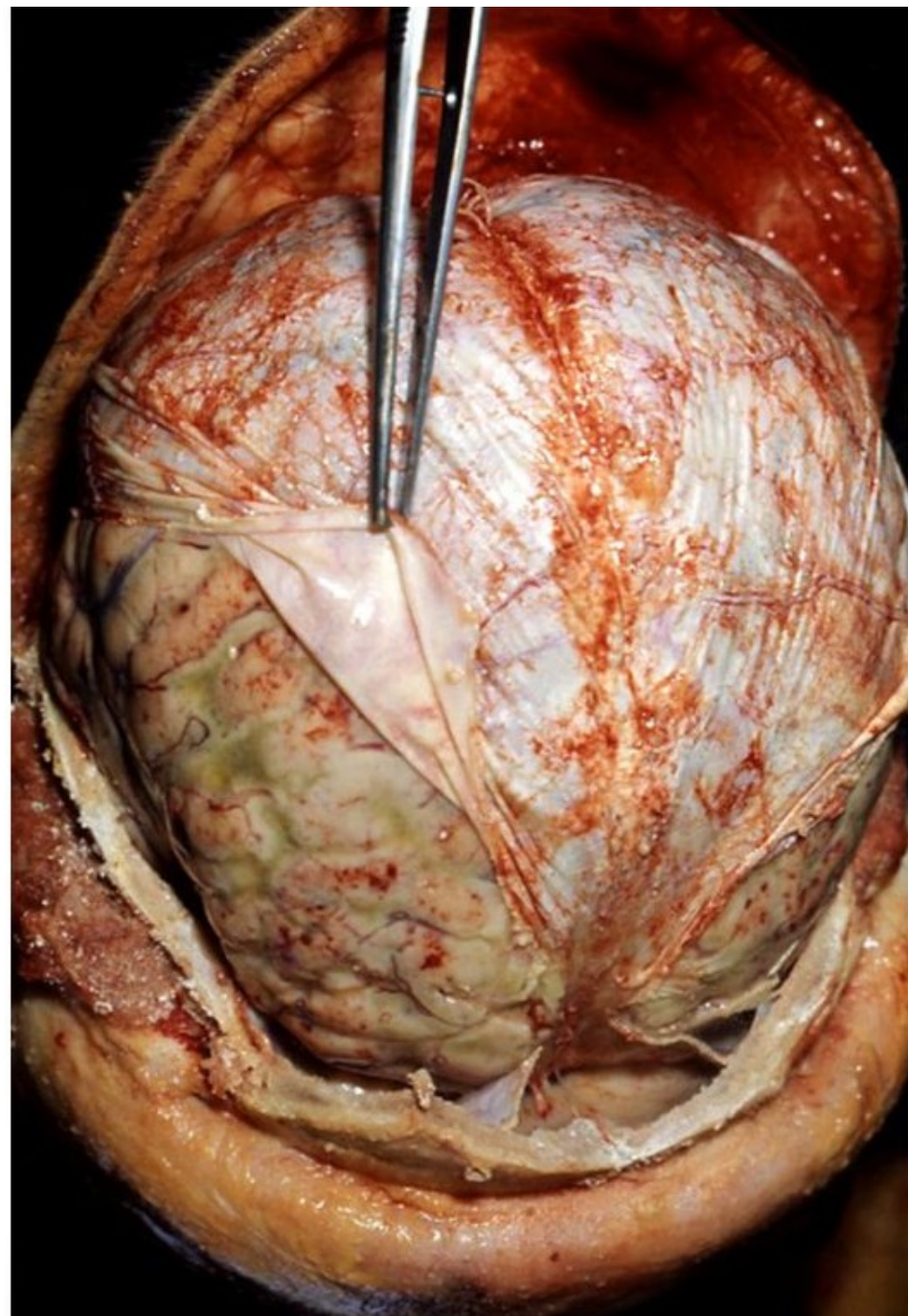
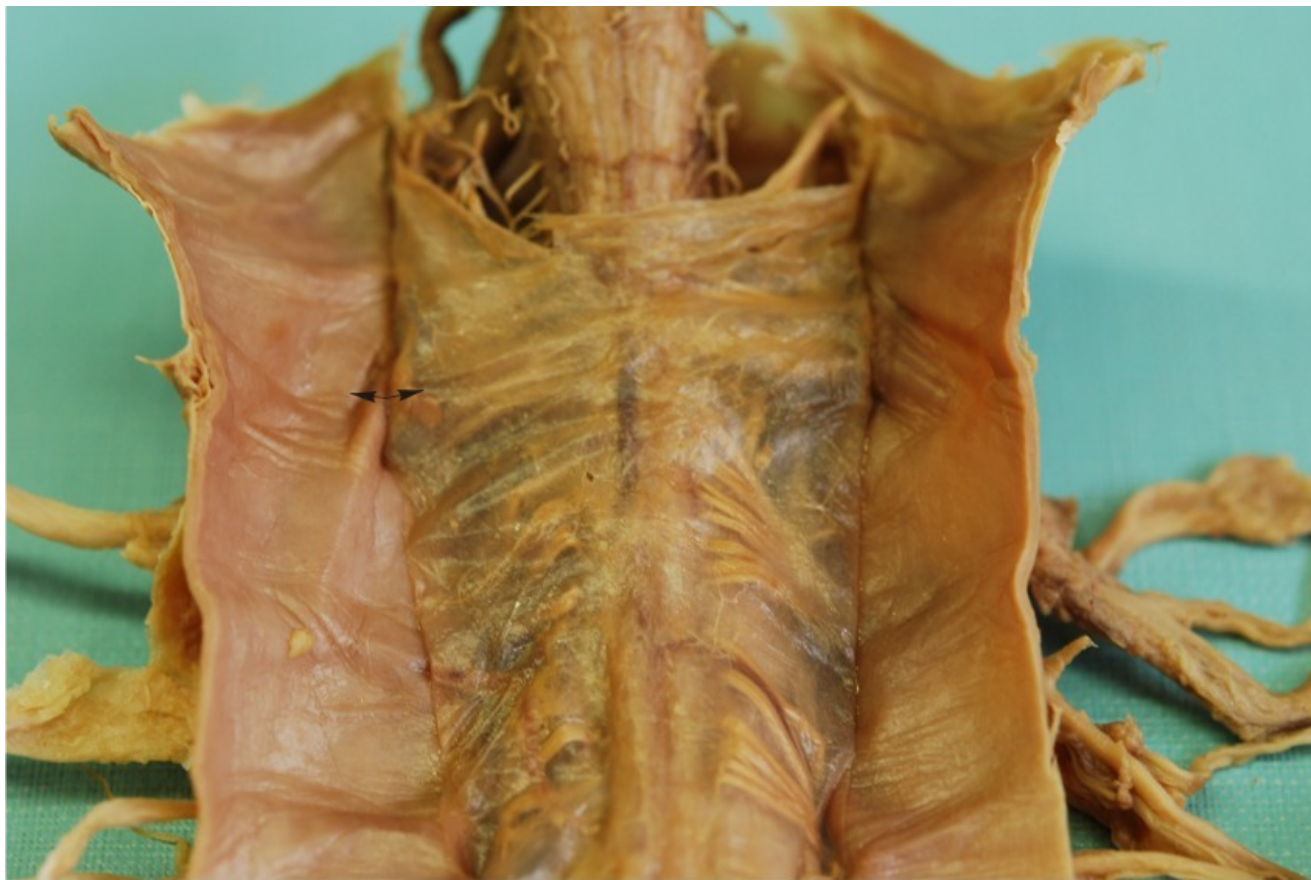LIQUOR CEREBROSPINALIS



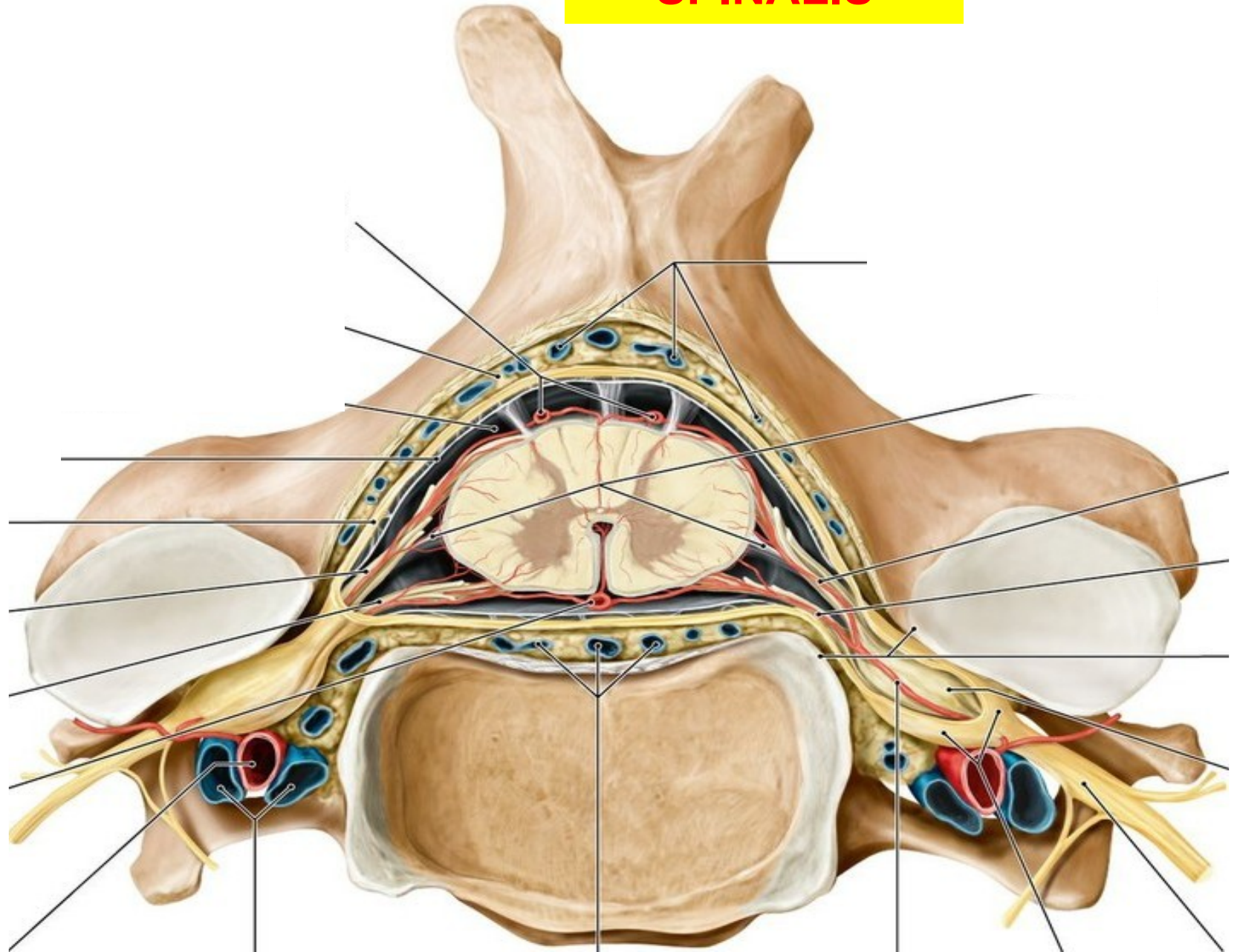
CIRCUMVENTRIKULÁRNÍ ORGÁNY



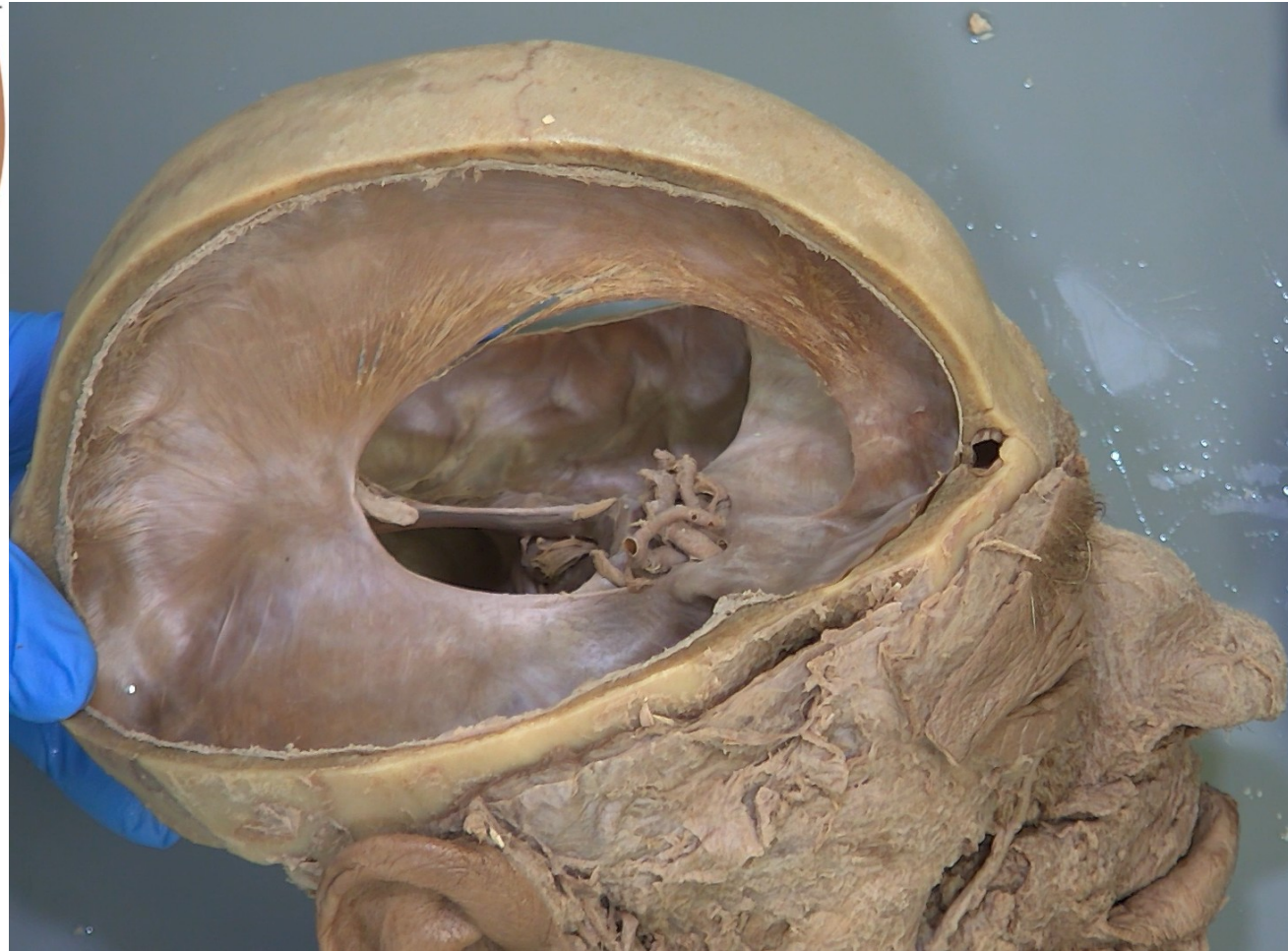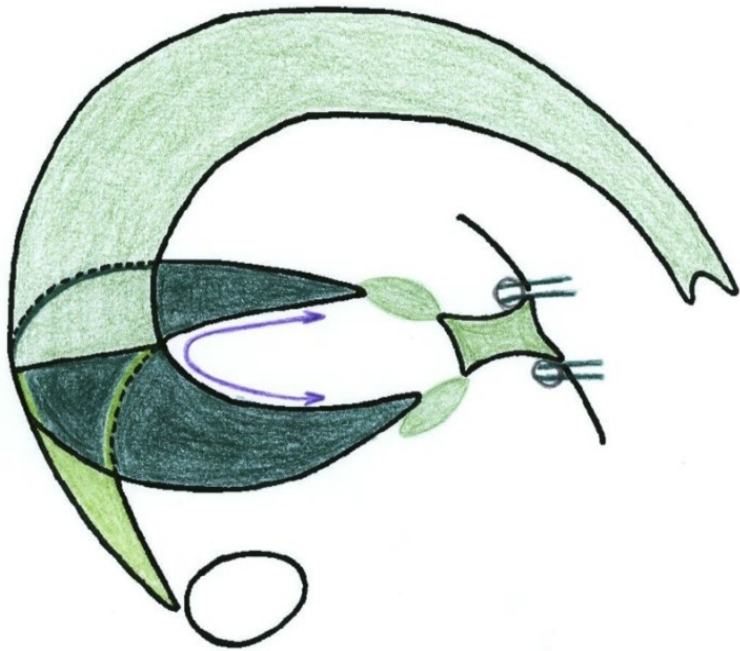
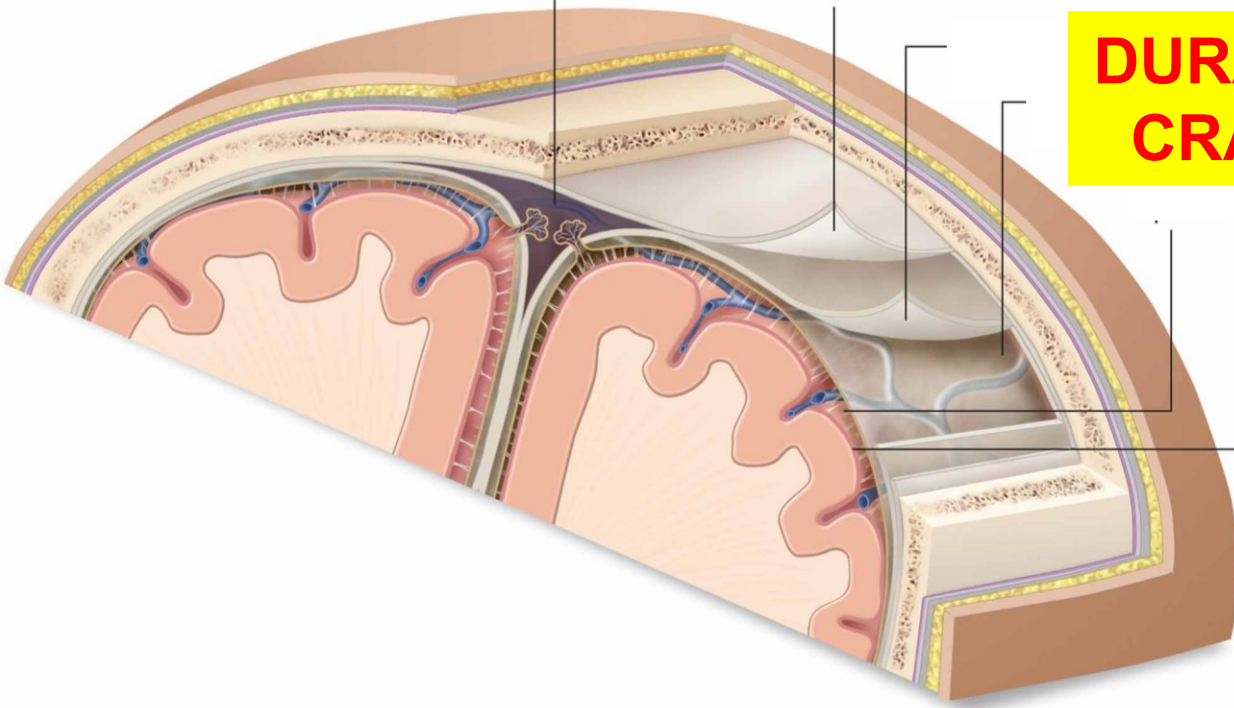
OBALY MOZKOMÍŠNÍ - MENINGY



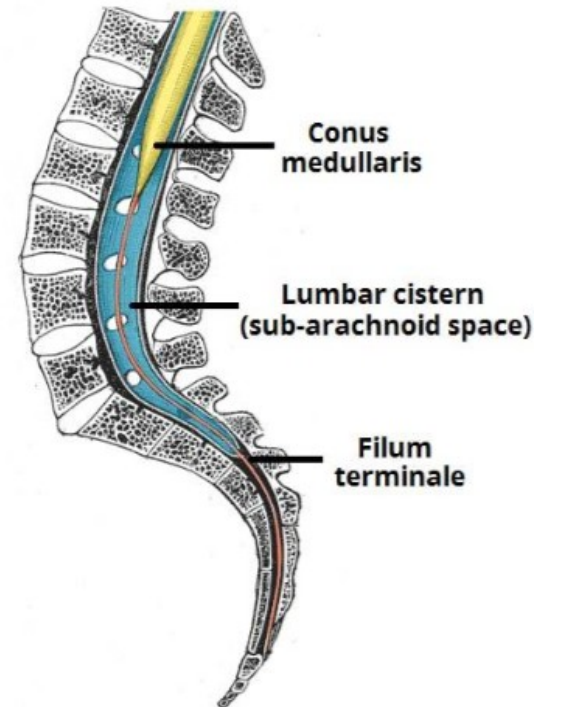
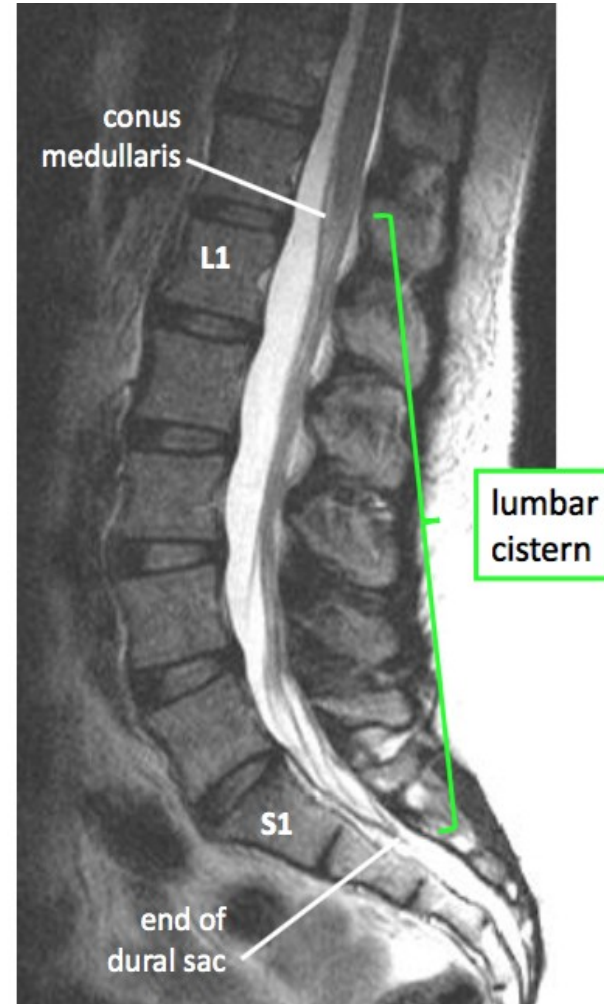
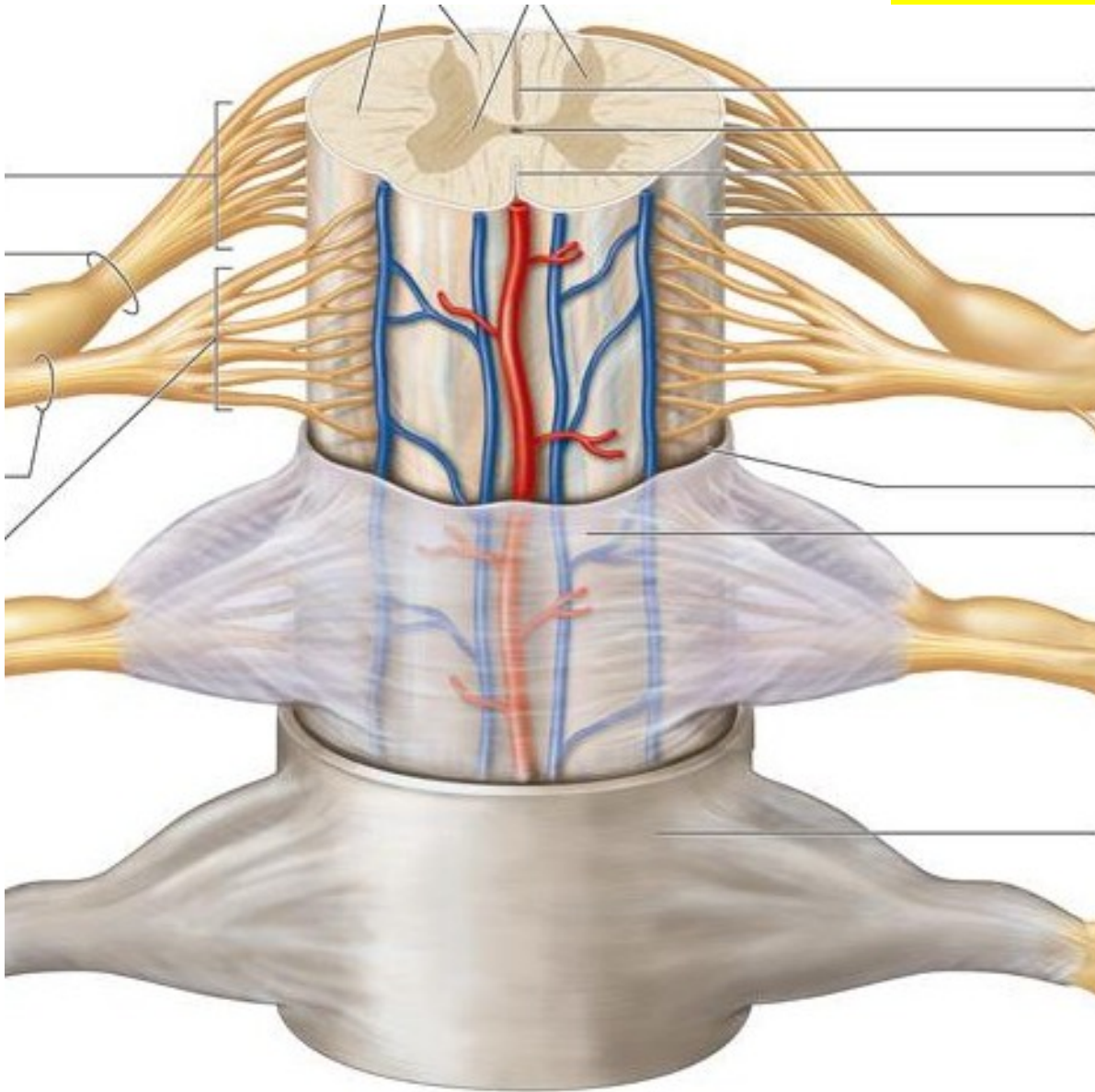
DURA MATER SPINALIS



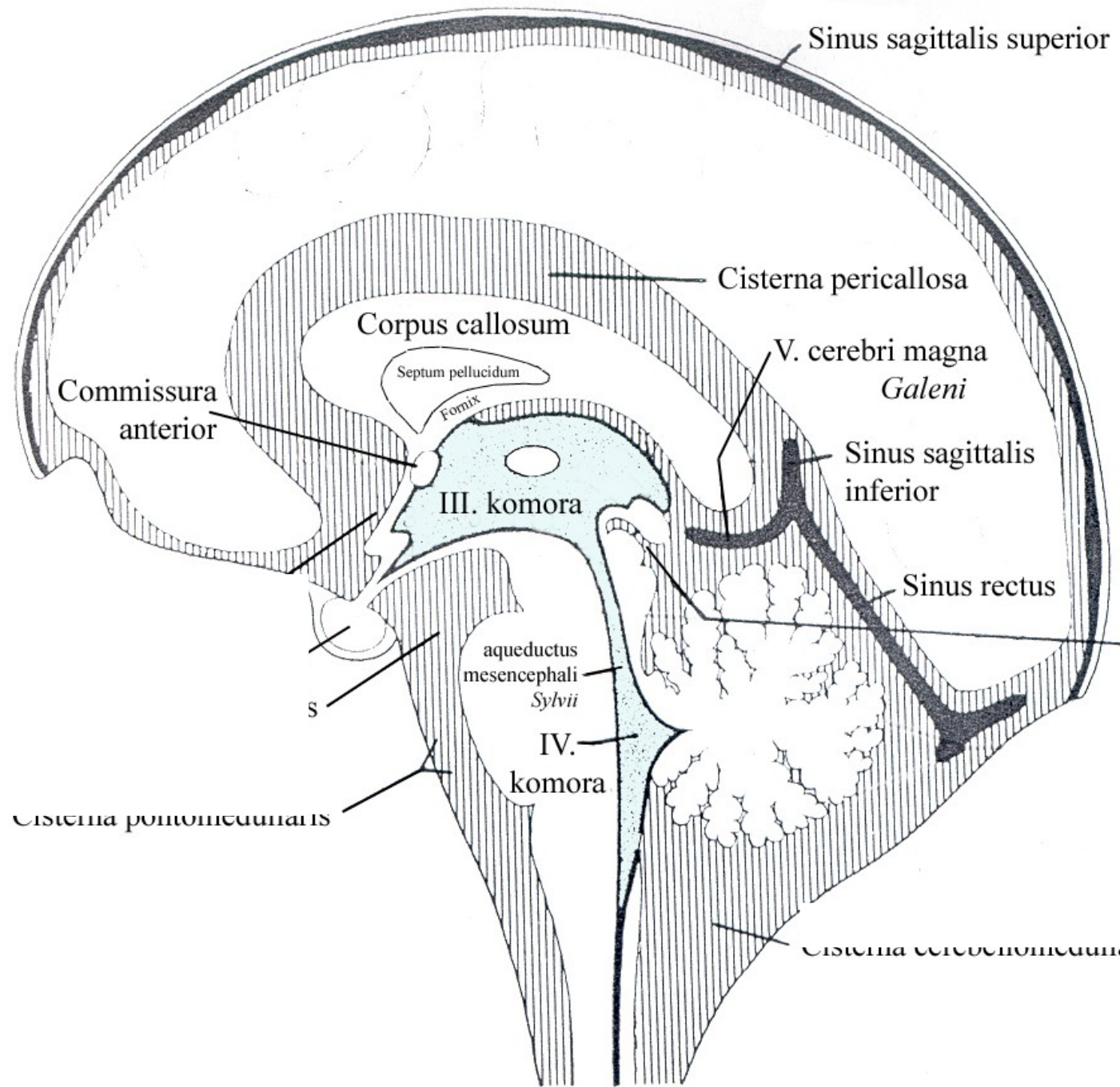
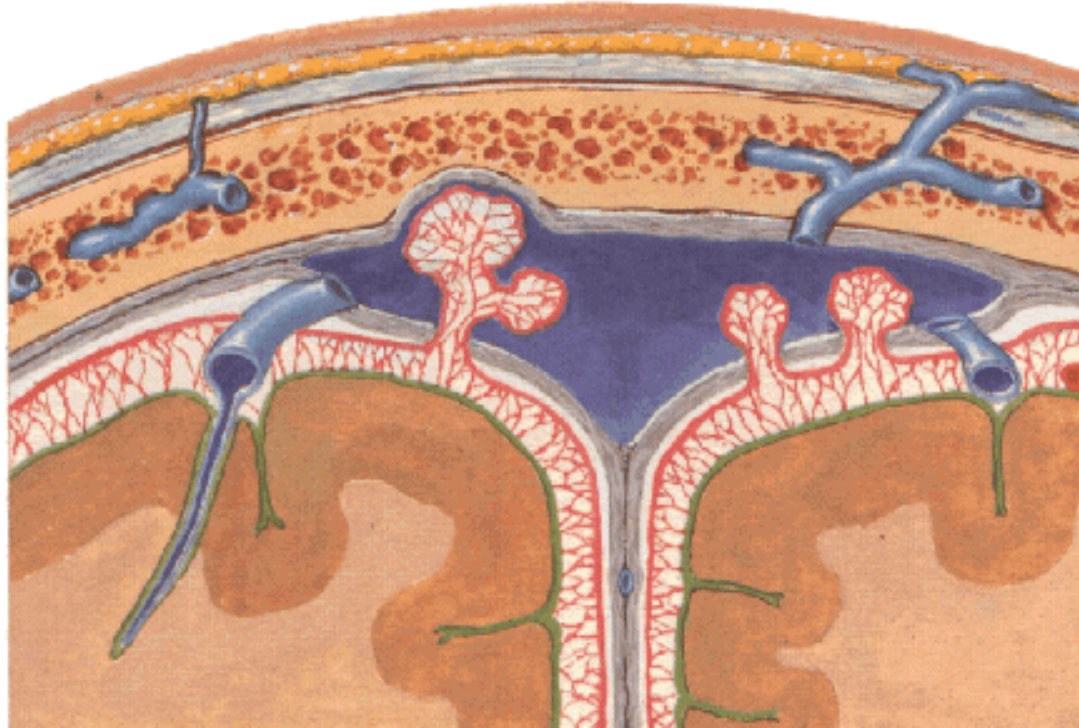
**DURA MATER
CRANIALIS**



ARACHNOIDEA SPINALIS

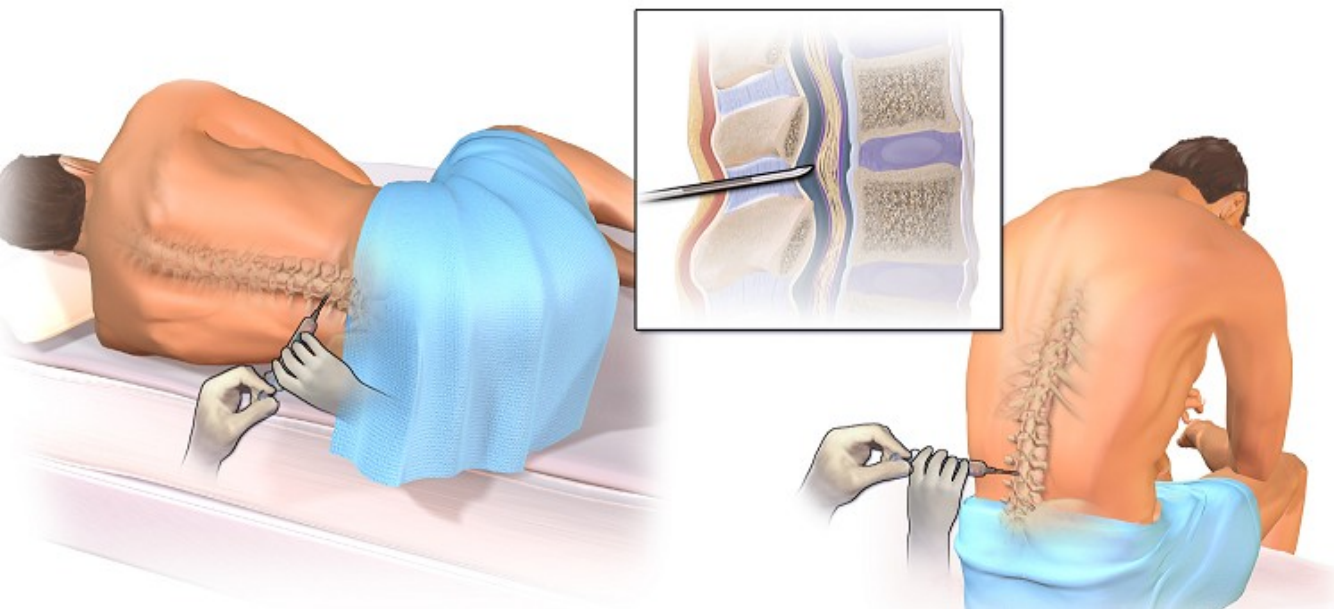


ARACHNOIDEA CRANIALIS

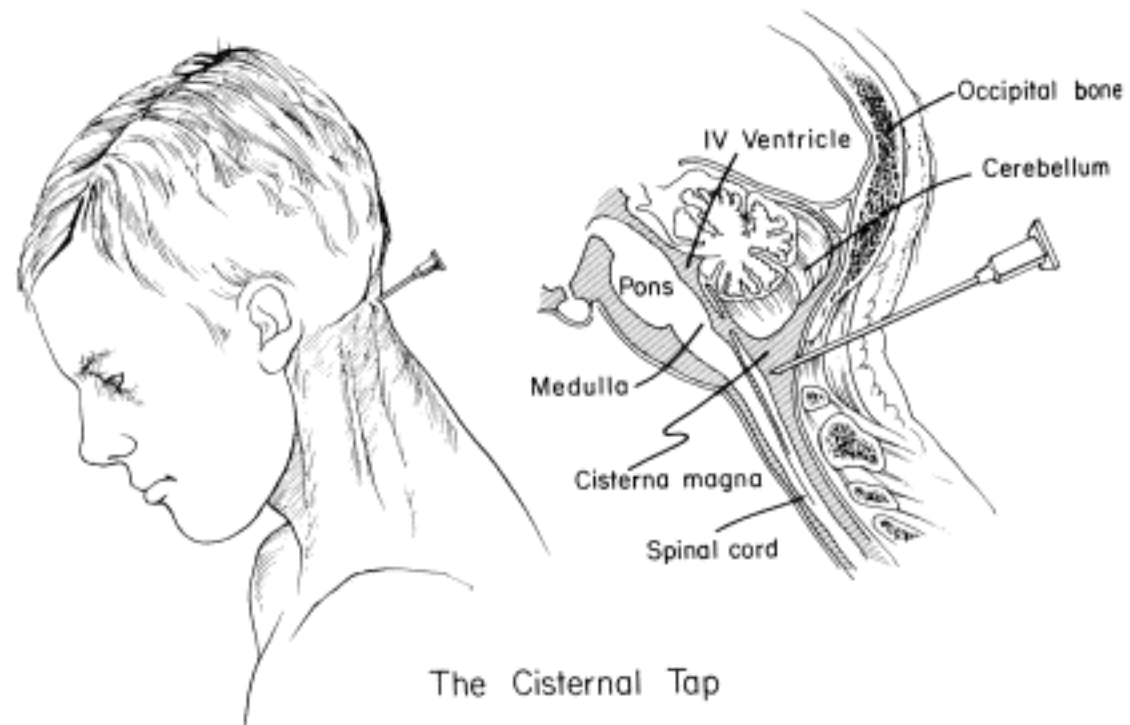


ODBĚR LIKVORU

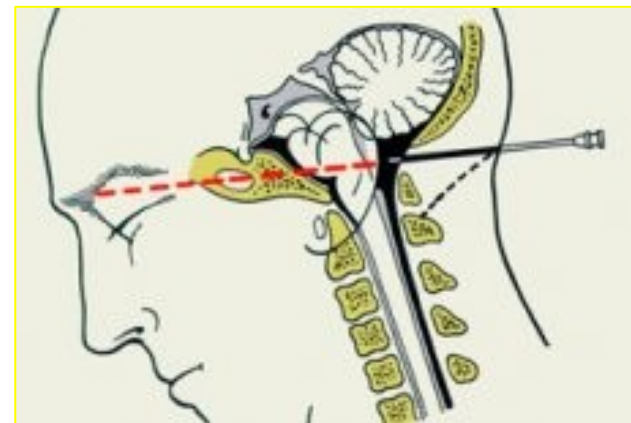
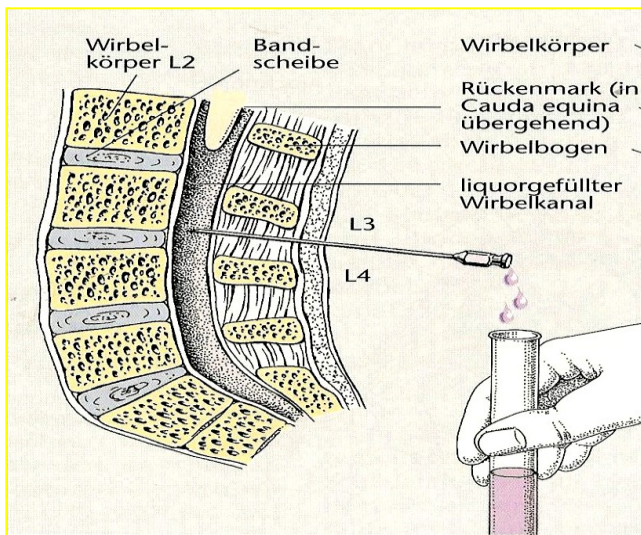
LUMBÁLNÍ PUNKCE



SUBOKCIPITÁLNÍ PUNKCE

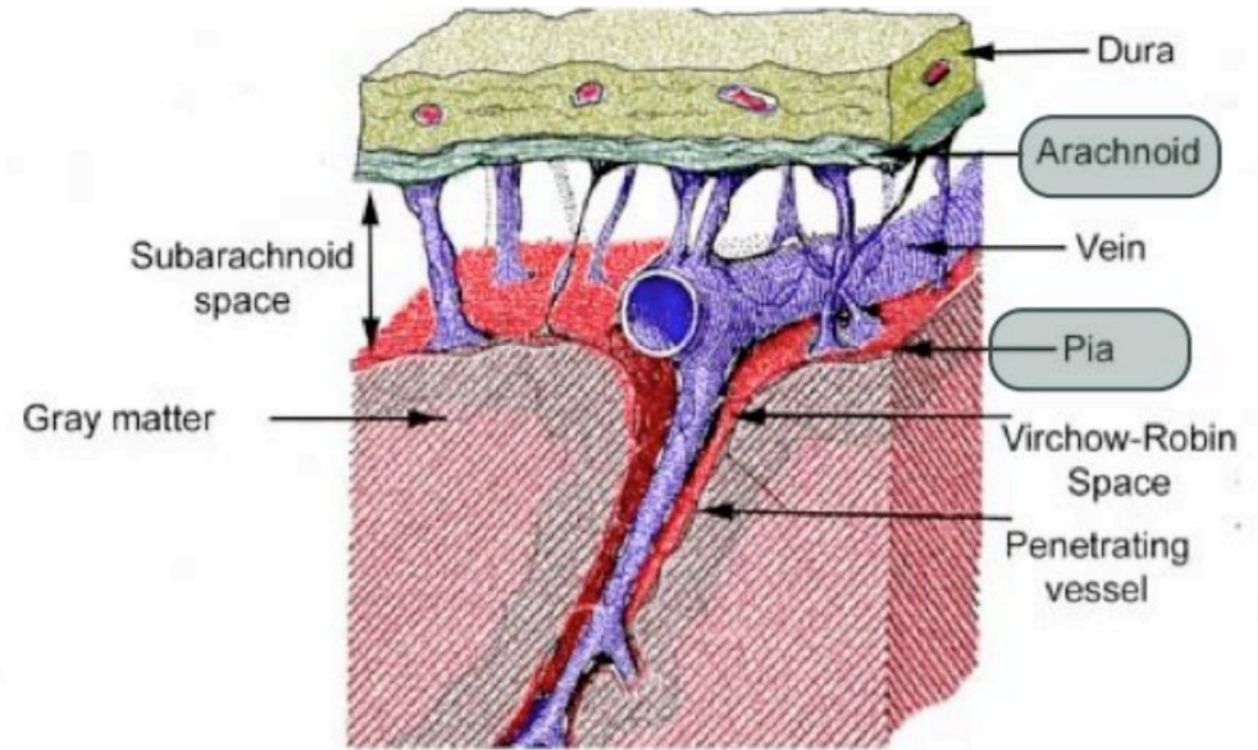
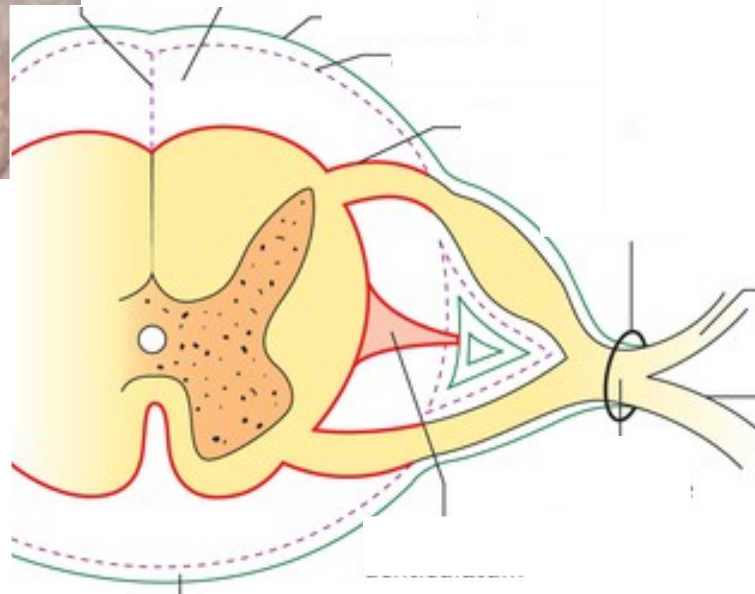
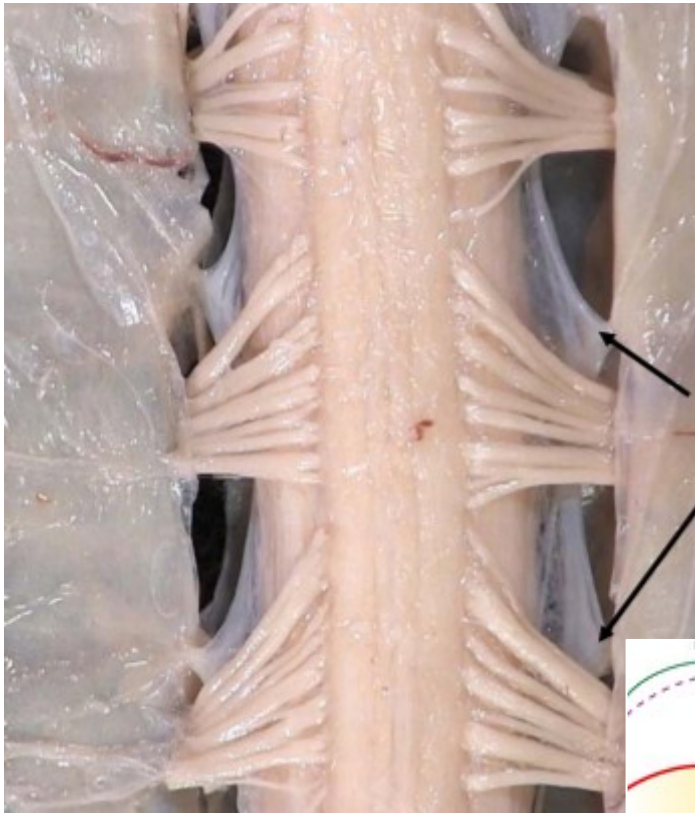


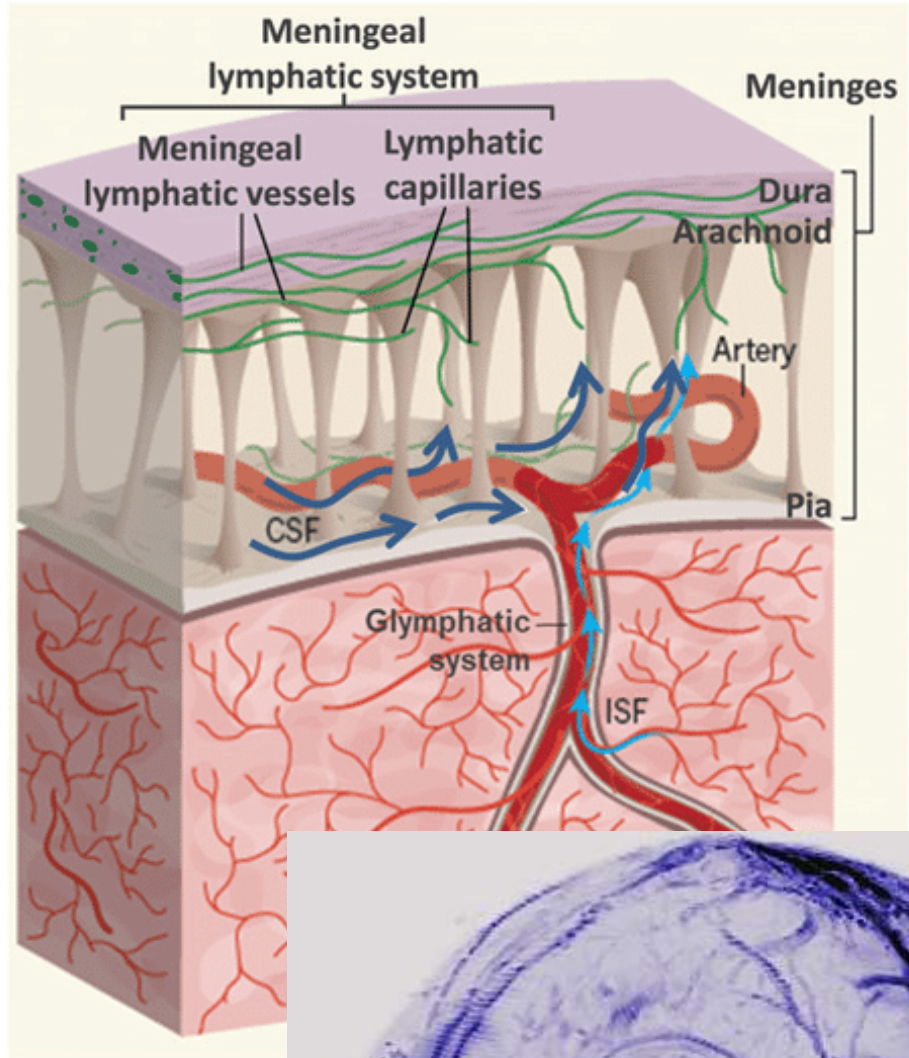
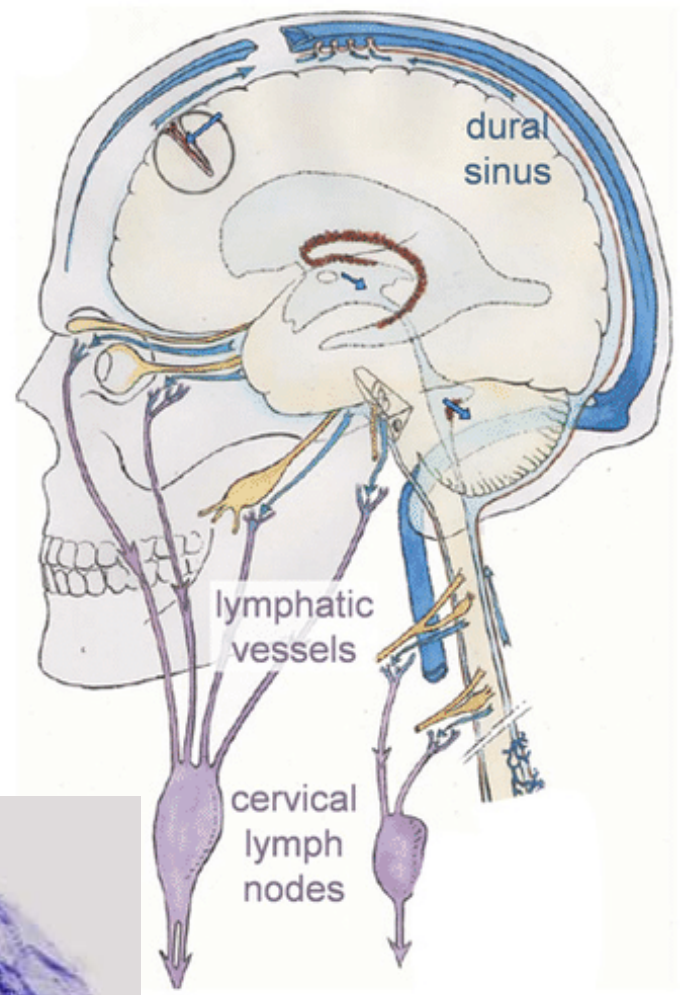
The Cisternal Tap



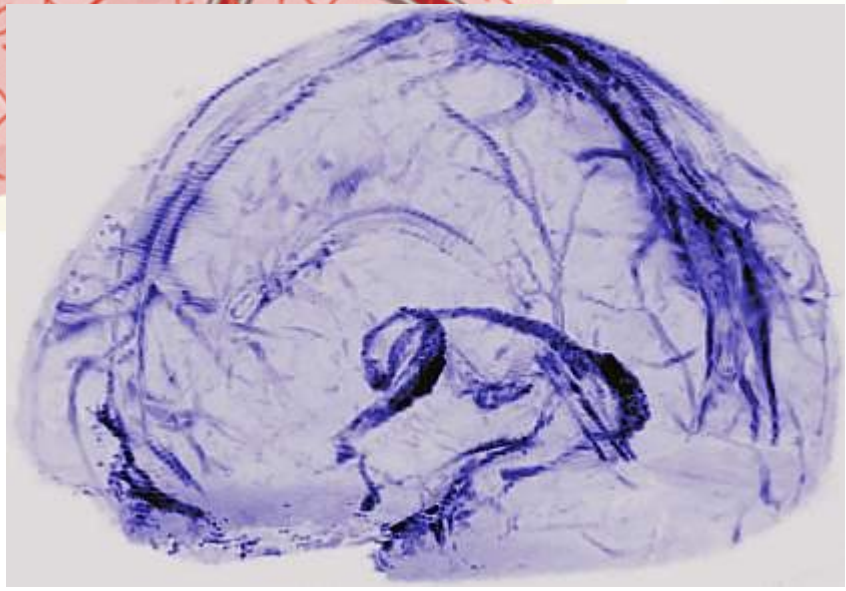
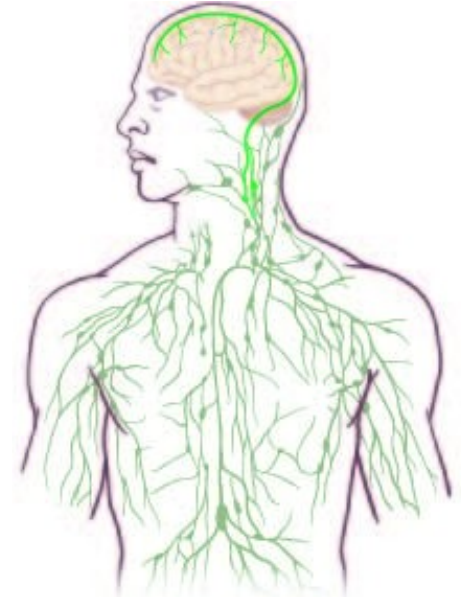
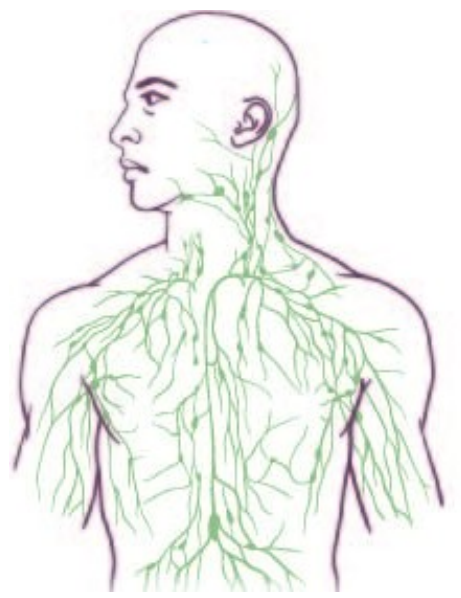
PIA MATER SPINALIS

PIA MATER CRANIALIS

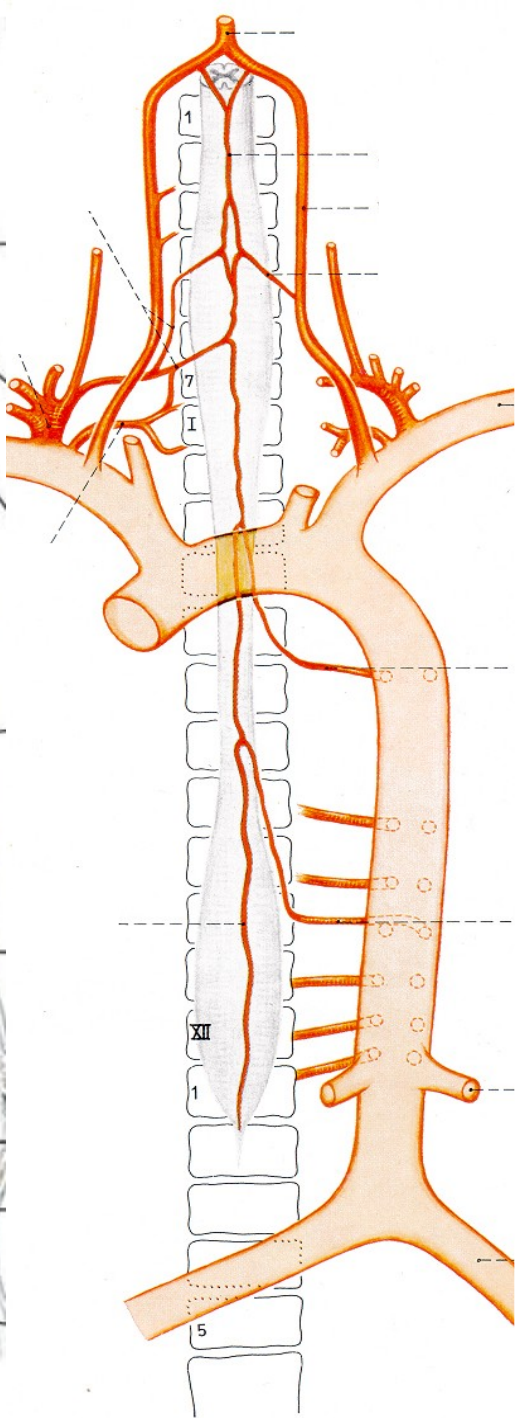
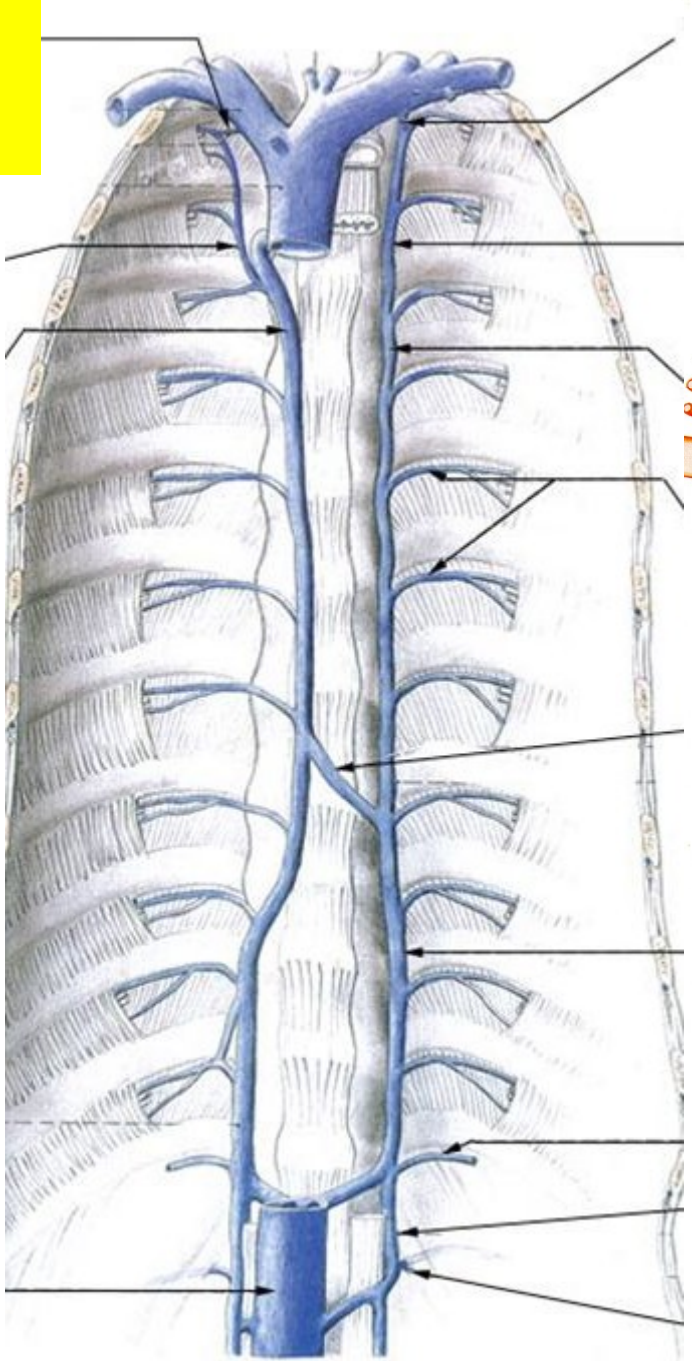
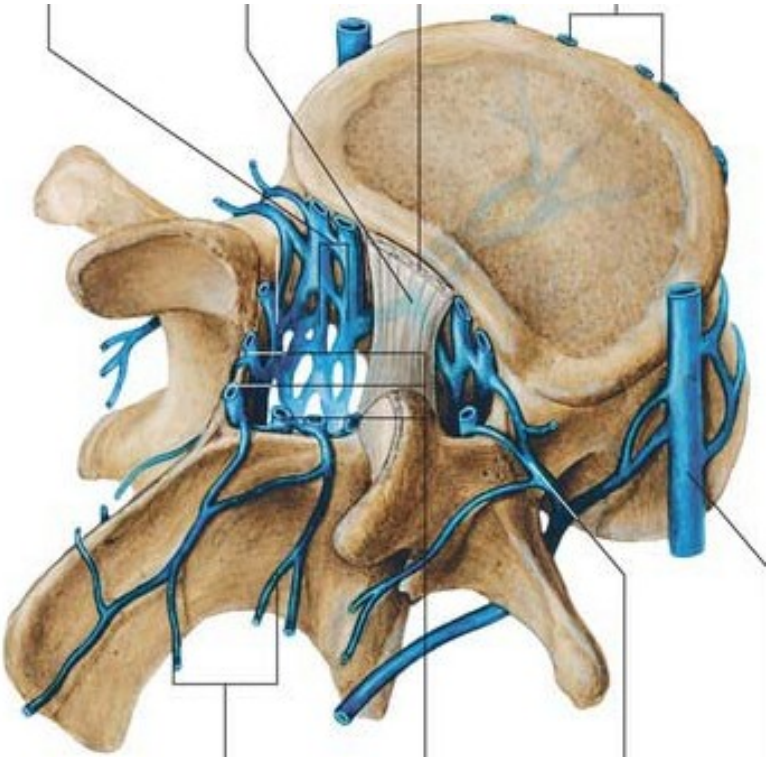
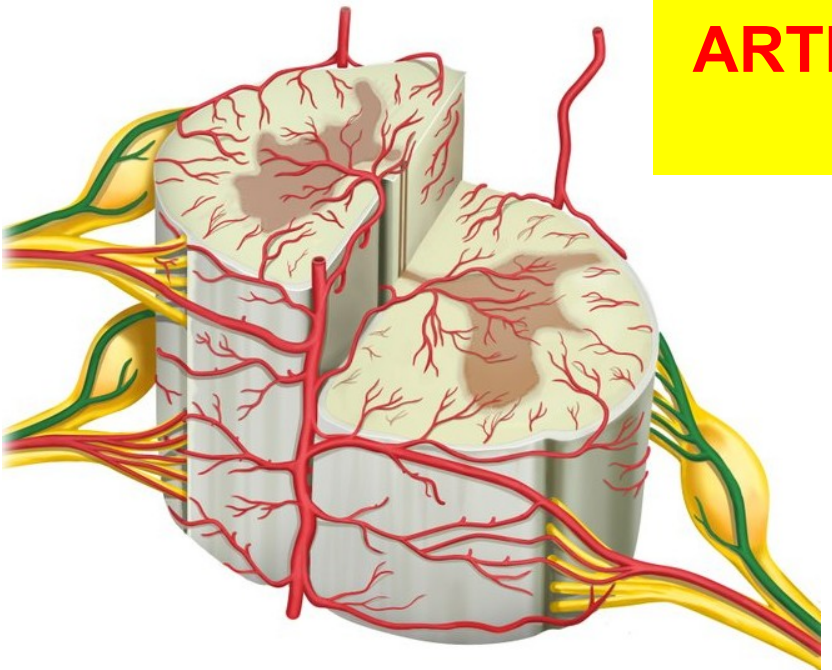


A**B**

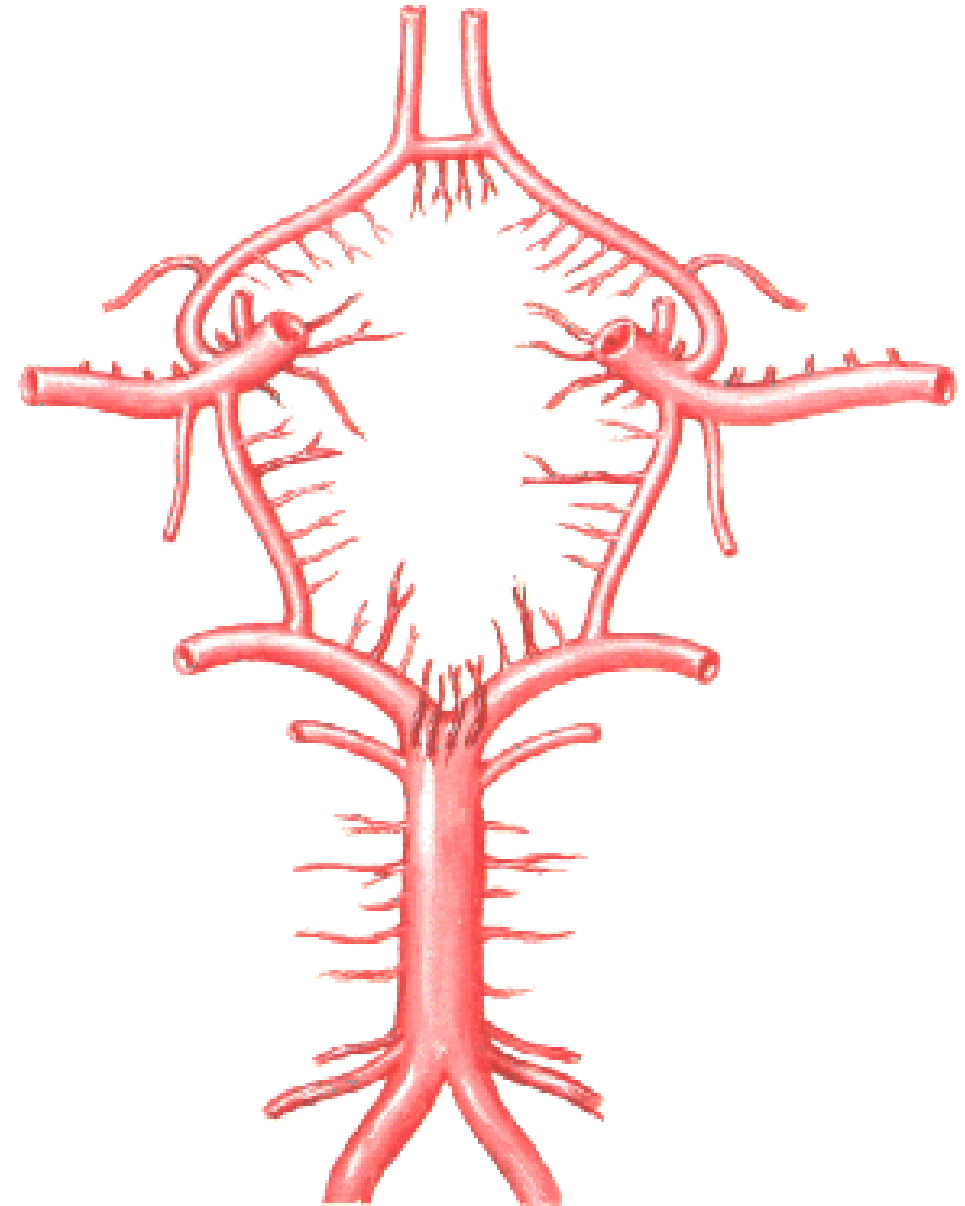
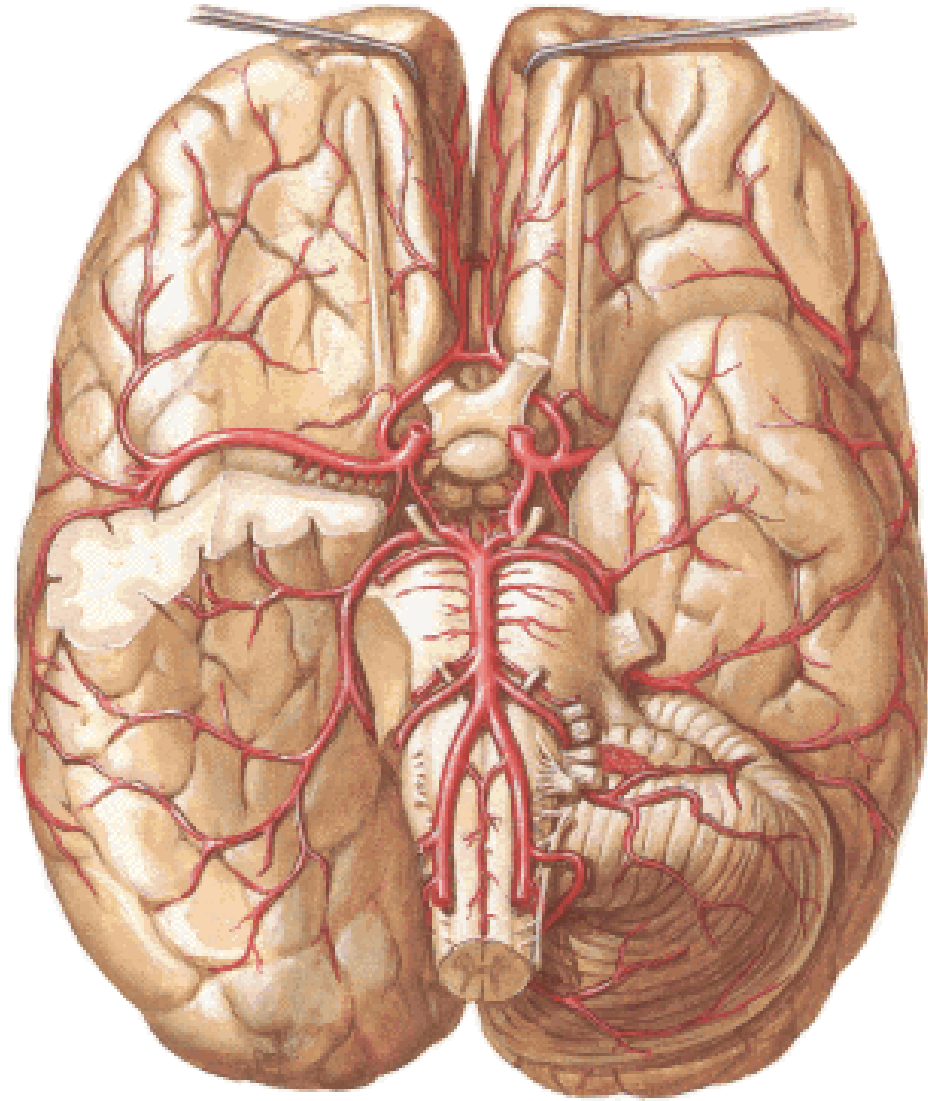
MÍZNÍ CÉVY

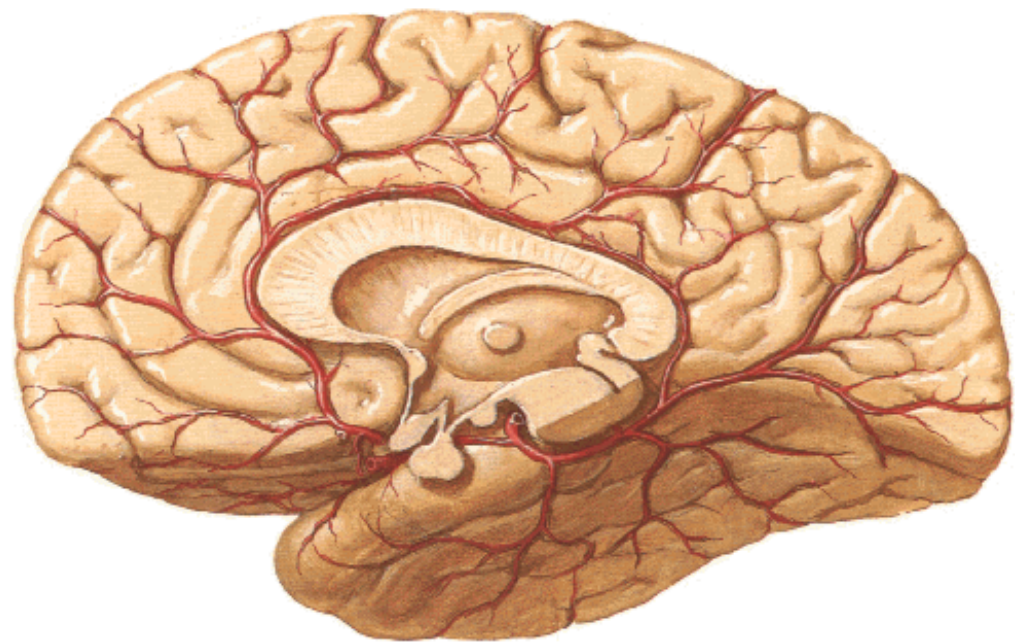
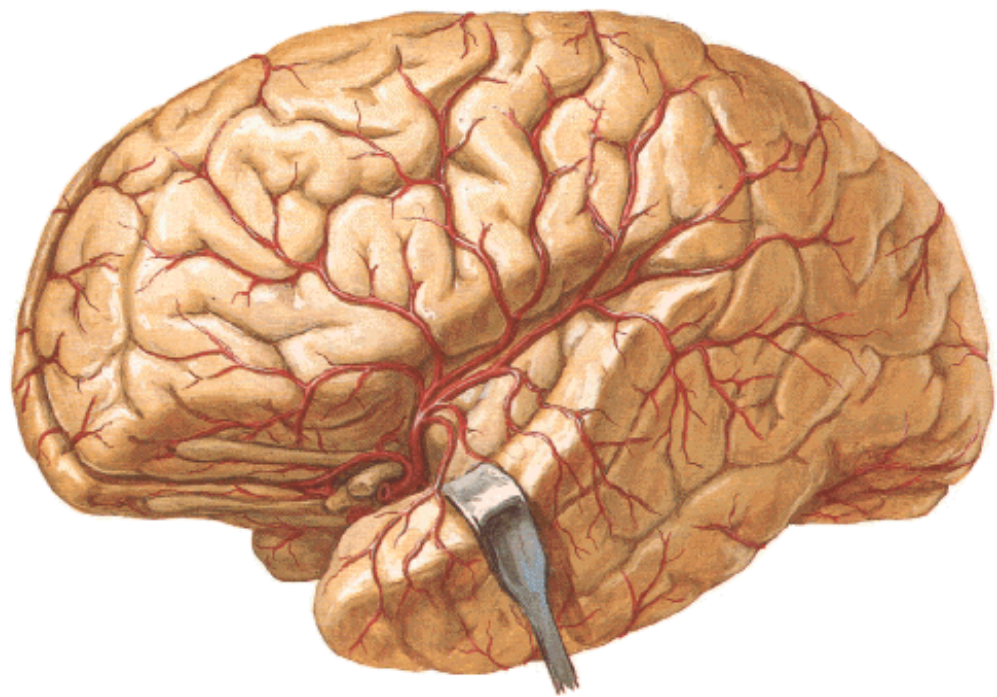
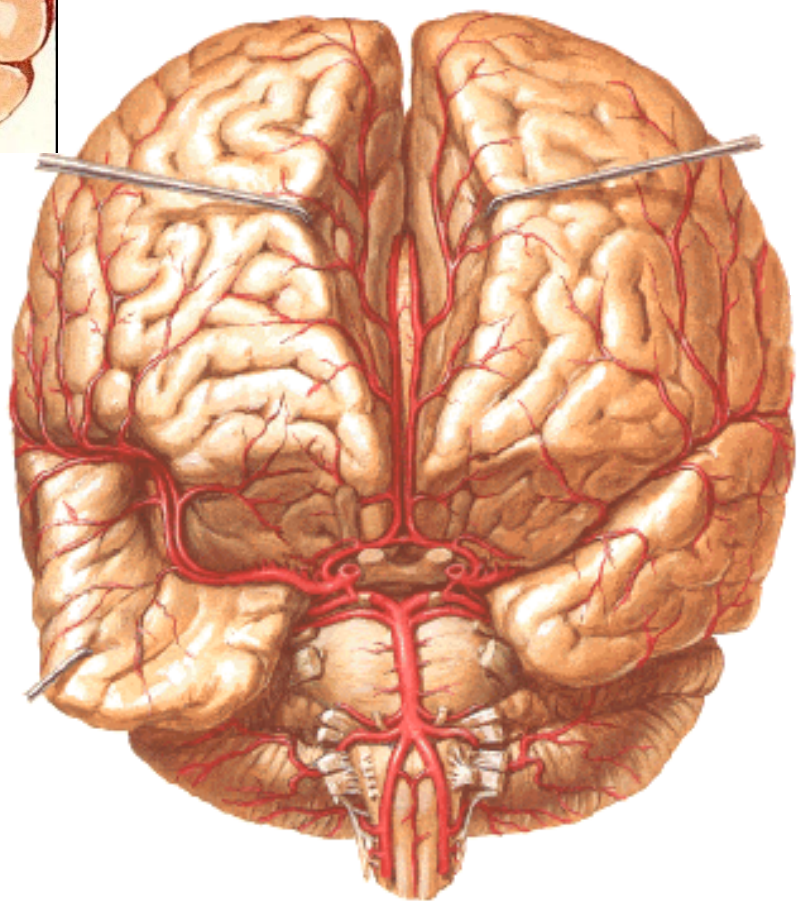
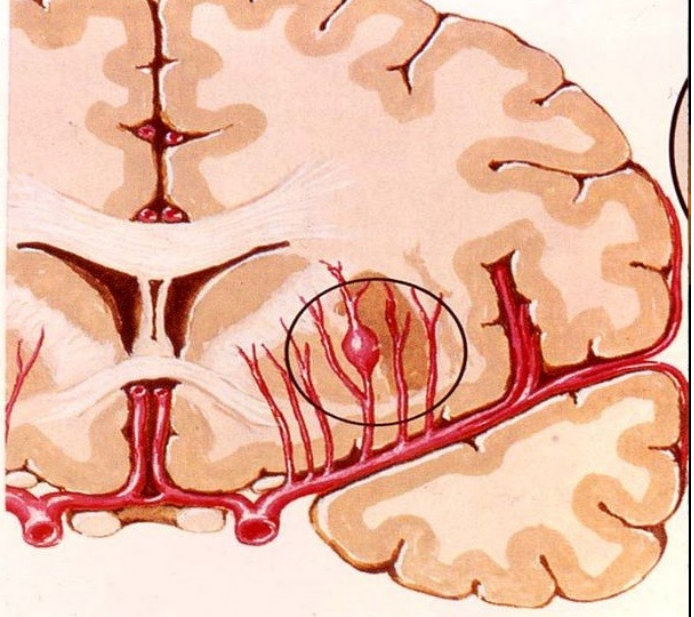


ARTERIAE ET VENAE SPINALES

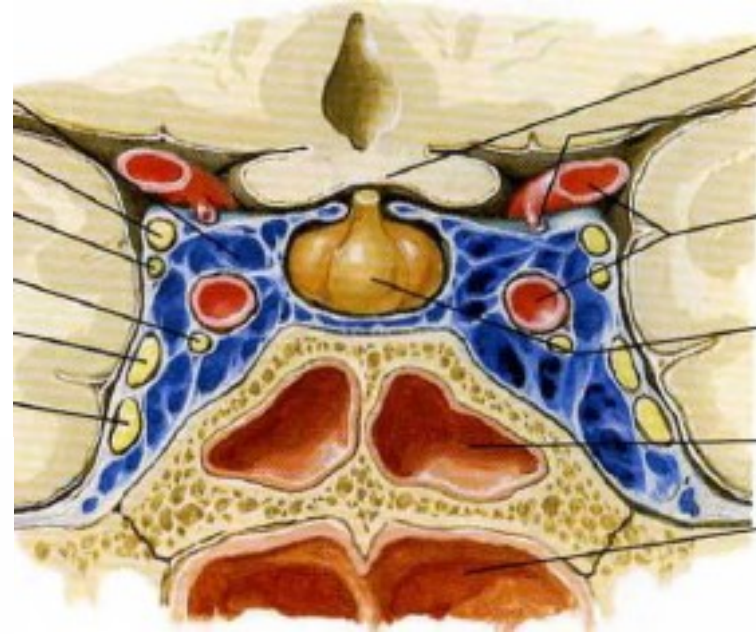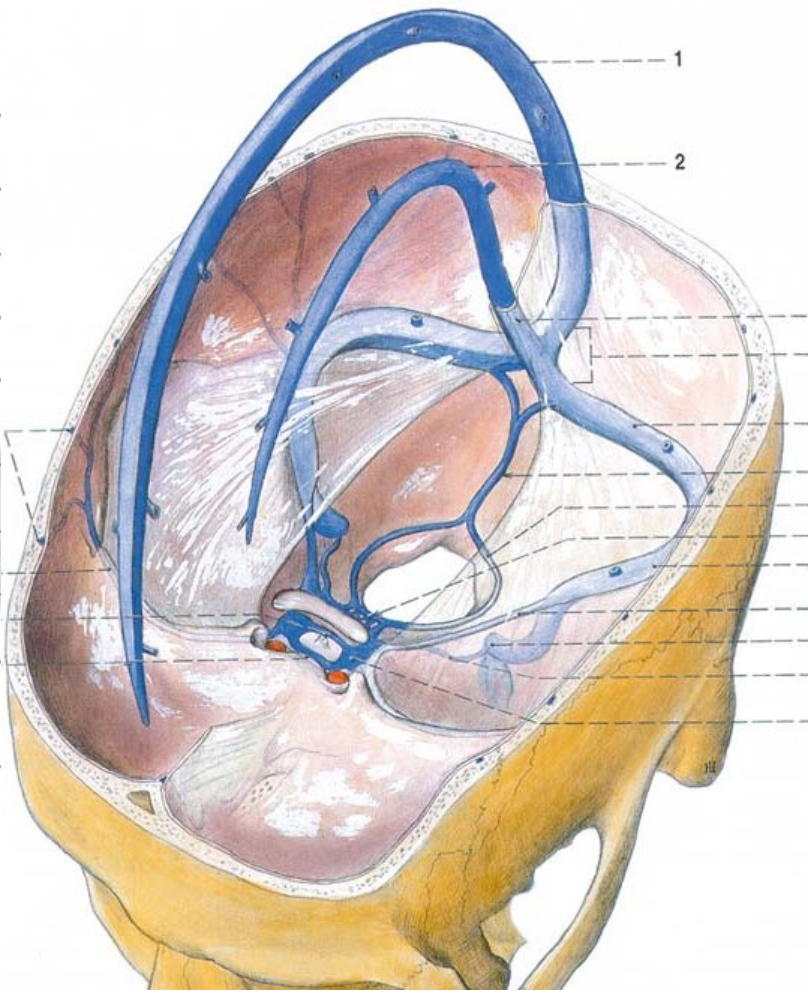
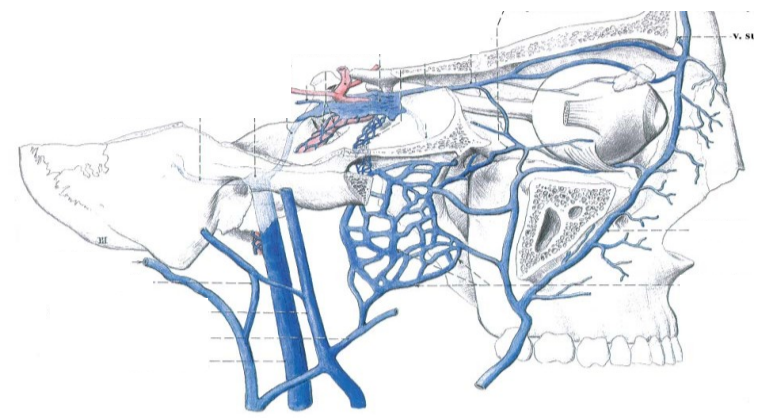
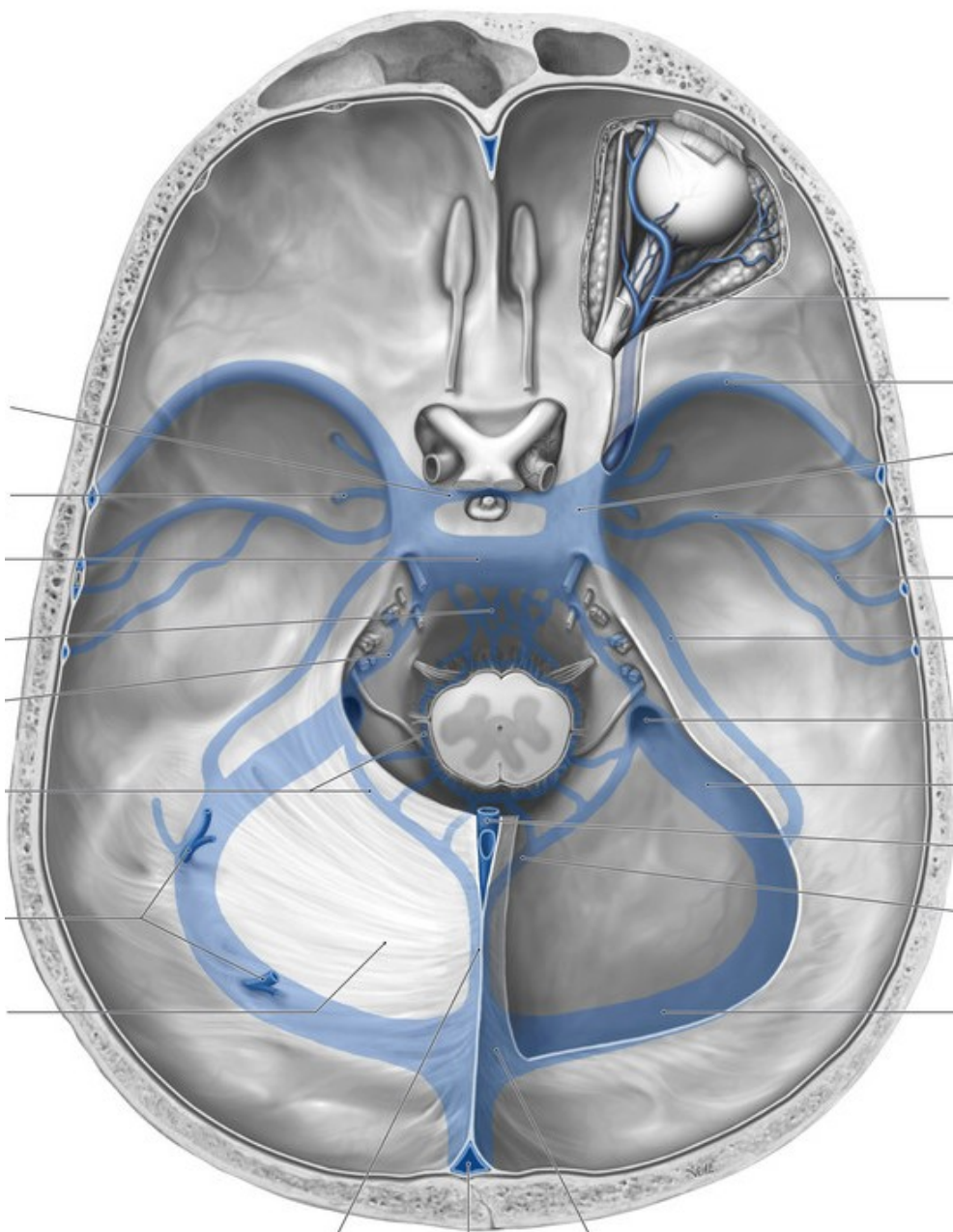


CIRCULUS ARTERIOSUS CEREBRI

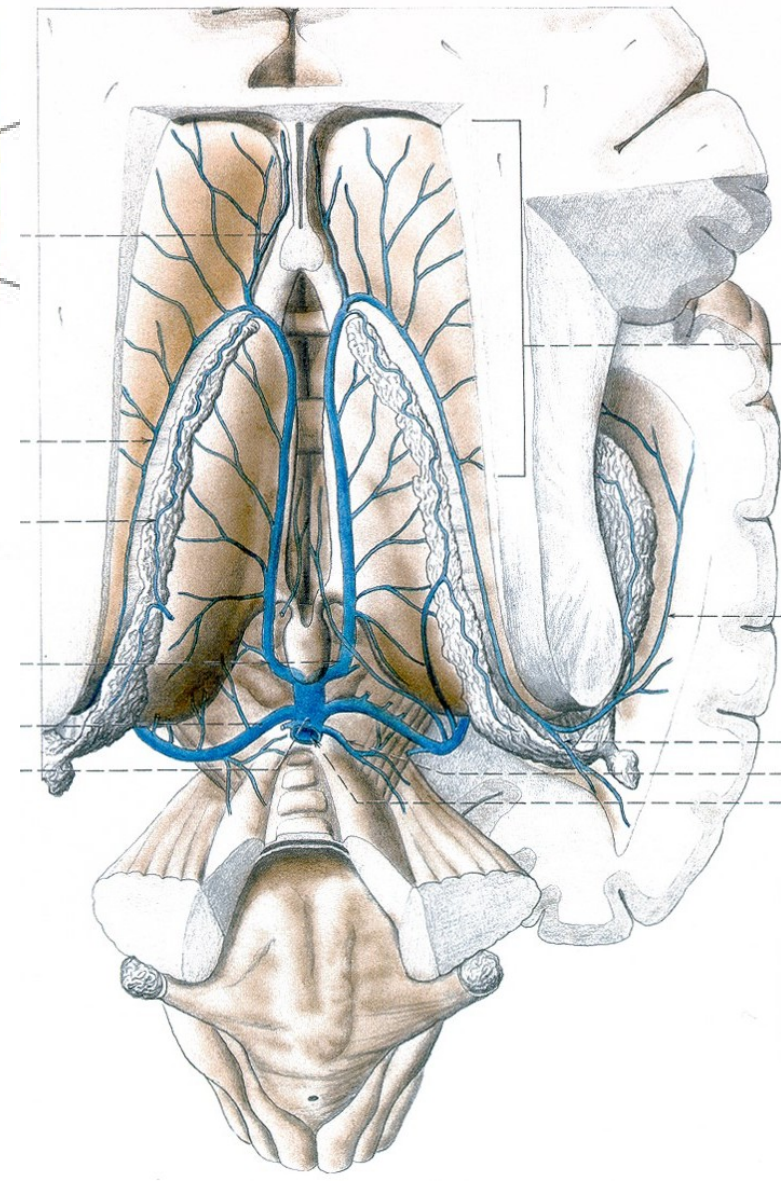
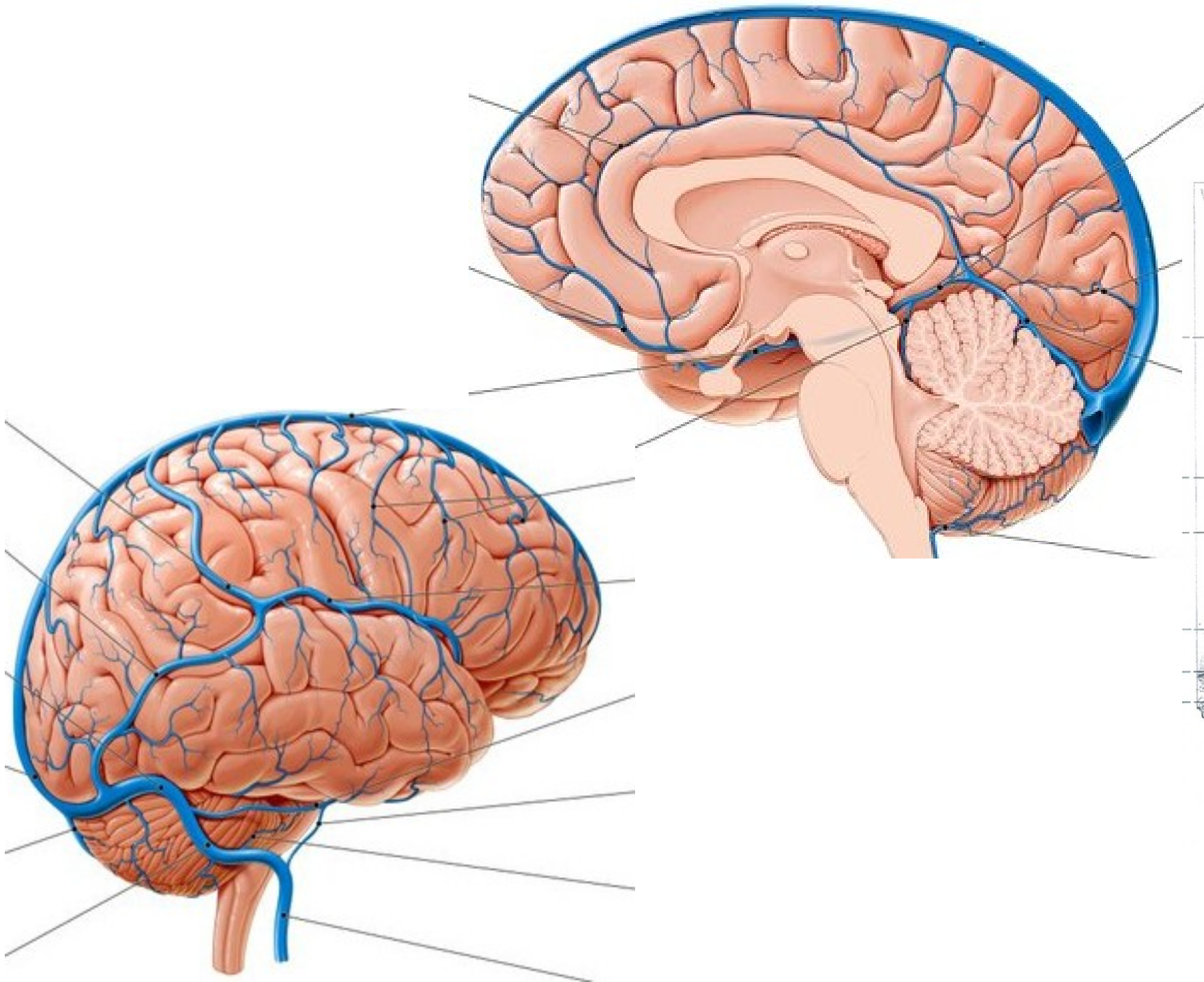




SINUS DURAE MATRIS

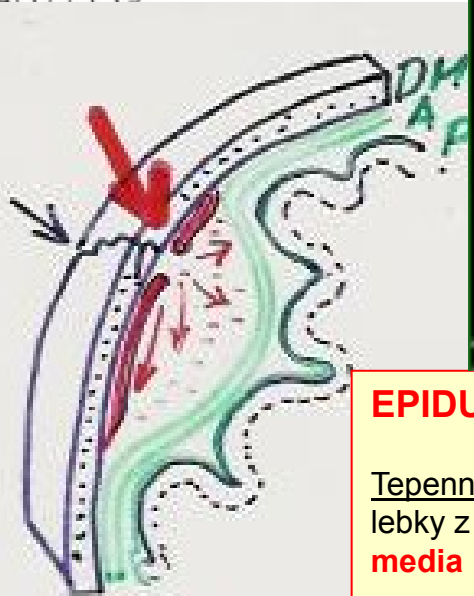
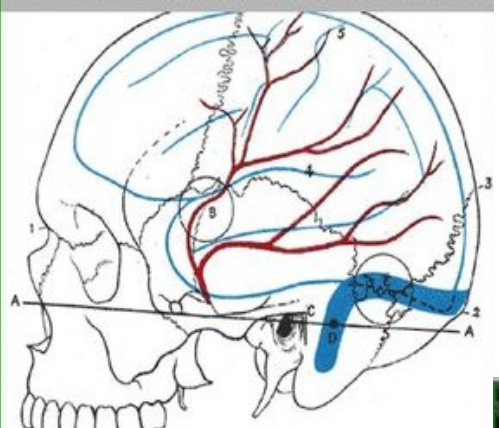


**VENAE
CEREBRI**

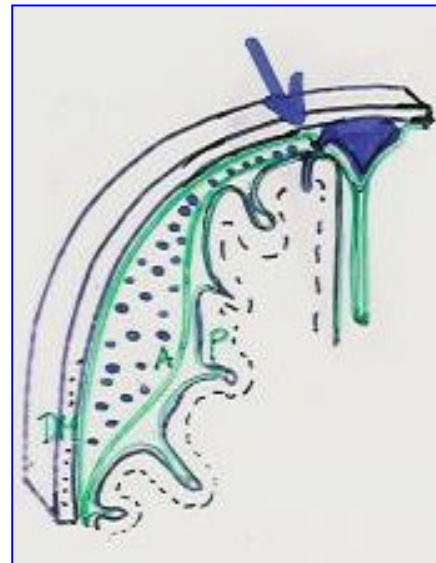


INTRAKRANIÁLNÍ KRVÁCENÍ

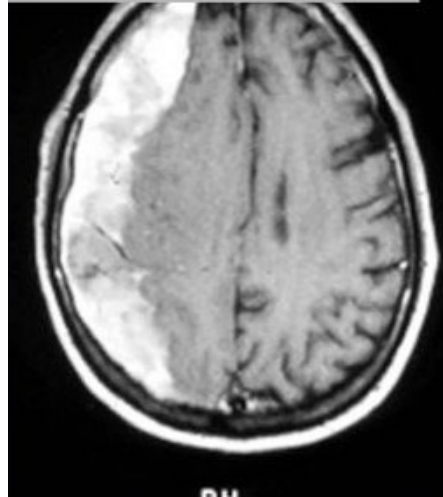
EPIDURÁLNÍ HEMATOM



EPIDURÁLNÍ KRVÁCENÍ
Tepenné krvácení při frakturách lebky z přetržení **a. meningea media**

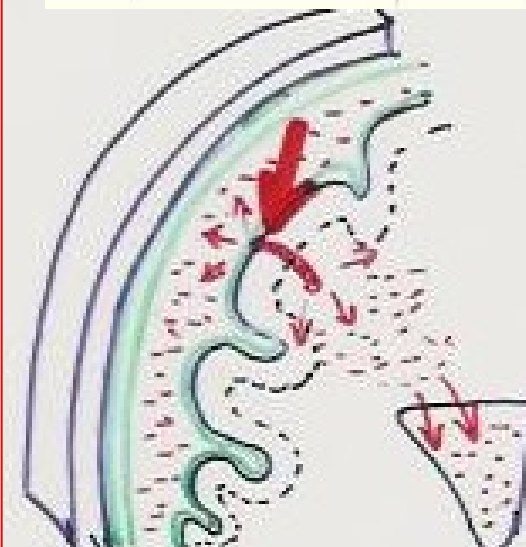
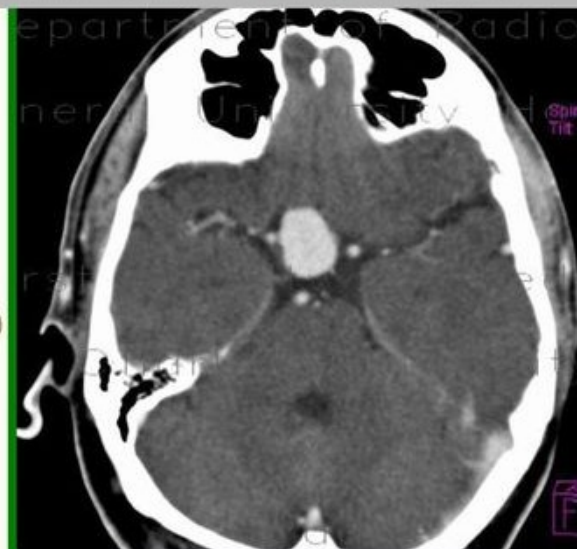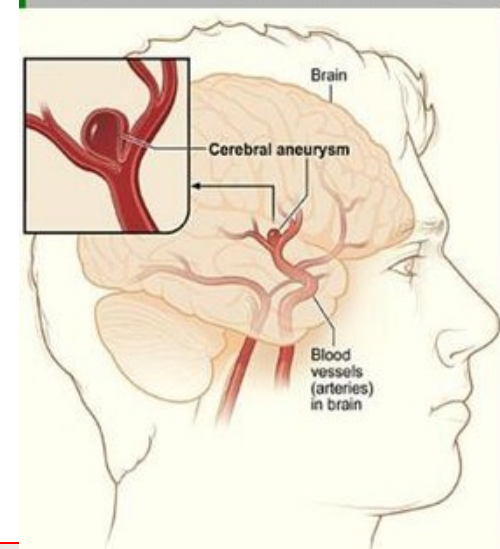


SUBDURÁLNÍ HEMATOM



SUBDURÁLNÍ HEMATOM
Žilní krvácení do **subdurálního prostoru** z přetržené **přemostující žíly** při tupých traumatech lebky

SUBARACHNOIDÁLNÍ KRVÁCENÍ-ANEURYSMA



SUBARACHNOIDÁLNÍ KRVÁCENÍ (A) do subarachnoidálního prostoru – krvavý likvor
INTRAPARENCHYMOVÉ KRVÁCENÍ (B) může se chovat expanzivně a provalit se do komor
Tepenné krvácení při ruptuře stěny **mozkové tepny** při patologiích cév: aneurysmata, tepenné malformace, hypertenze

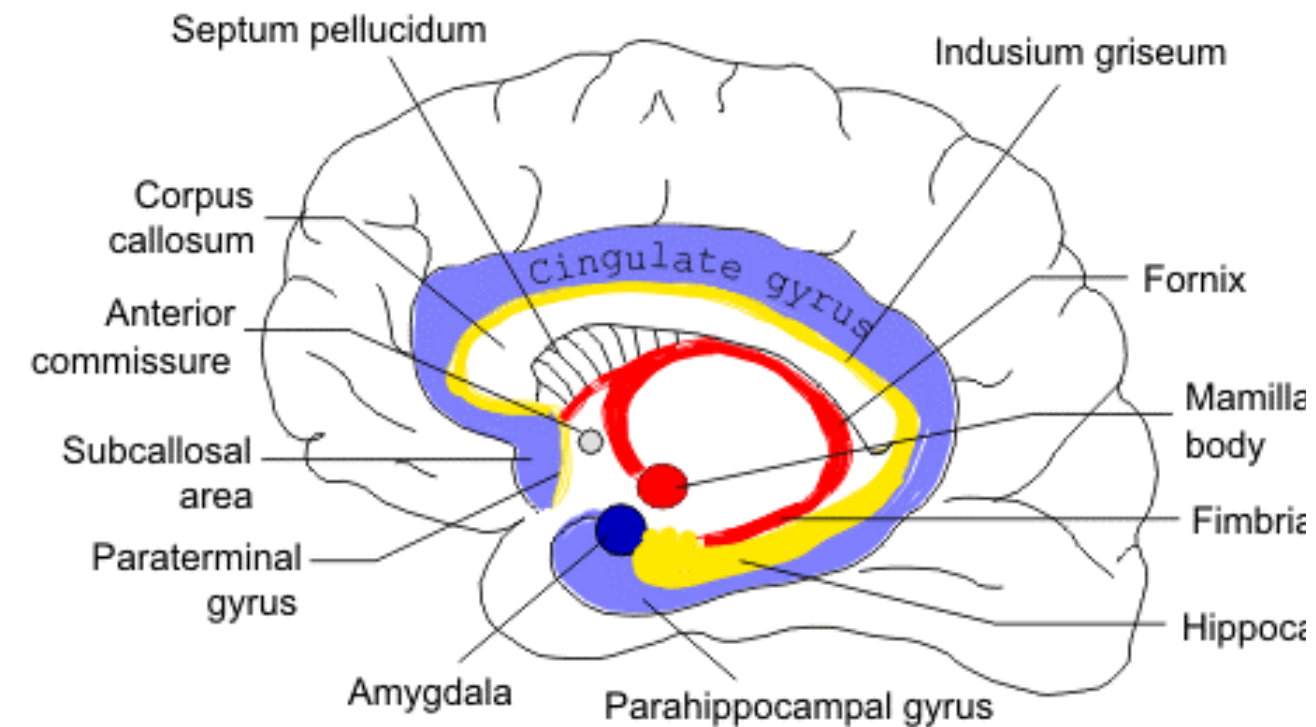
LIMBICKÝ SYSTÉM

Vnější část: area subcallosa – gyrus cinguli – istmus gyri cinguli – gyrus parahippocampalis

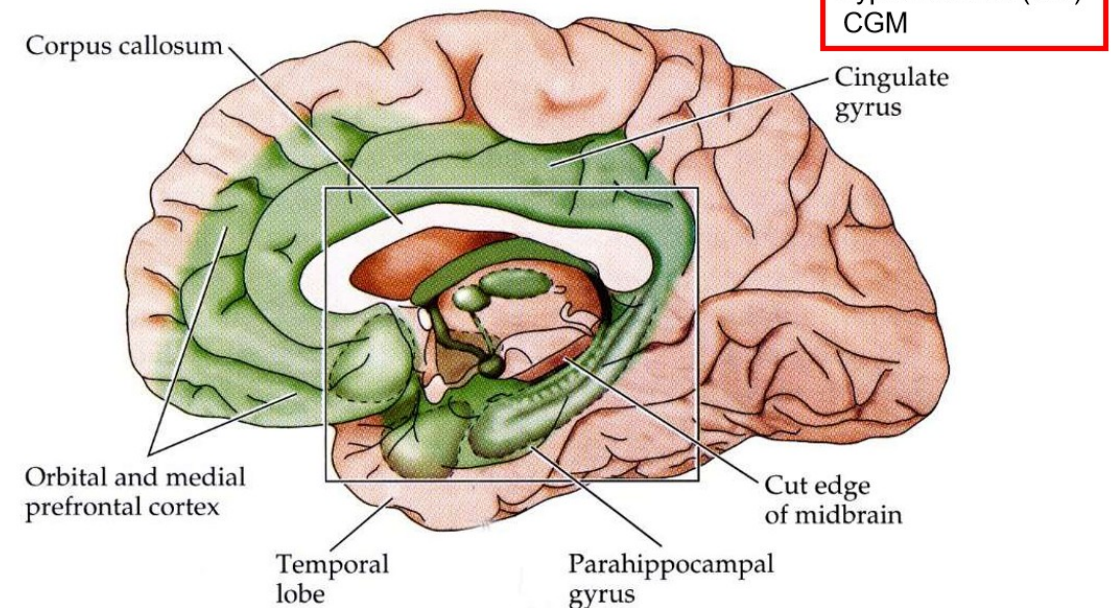
Vnitřní část: gyrus paraterminalis – striae longitudinales et indusium griseum – gyrus fasciolaris – gyrus dentatus – hippocampus

Fornix + fornikální okruh – propojení hippocampu s corpora mammilaria a jádry septum verum

Neokortikální paralimbická kůra = insula + pól temporálního laloku + prefrontální kůra – kortikální centrum emocí, abstraktního myšlení, osobnosti, prožívání, vyšší nervové činnosti



New aspect of limbic system



STRUKTURY LIMBICKÉHO PŘEDNÍHO MOZKU:

1) Korové oblasti

- Gyrus cinguli, parahippocampalis (hippocampus) = archicortex
 - Čichový kortex=paleocortex
 - Paralimbická kůra = neocortex
- insula, temporální pól, prefrontální kůra (asociační kůra, centra emocí a vyšší nervové činnosti člověka)

2) Podkorové struktury (kmenové)

Thalamická jádra – ncl. anteriores thalami

Hypothalamus a corpus mamillare

Amygdalární jádra v temporálním laloku

Ncl. accumbens septi (patří k BG a je nazýváno jádrem „závislostí a touhy“),

Septum verum (tzv. „pravé septum“, leží pod septum pellucidum = pouze gliová

ploténka bez neuronů)= **ncl.septi**

Habenulární jádra v epithalamu

Ncl. interpeduncularis mezencephala

Jádra retikulární formace

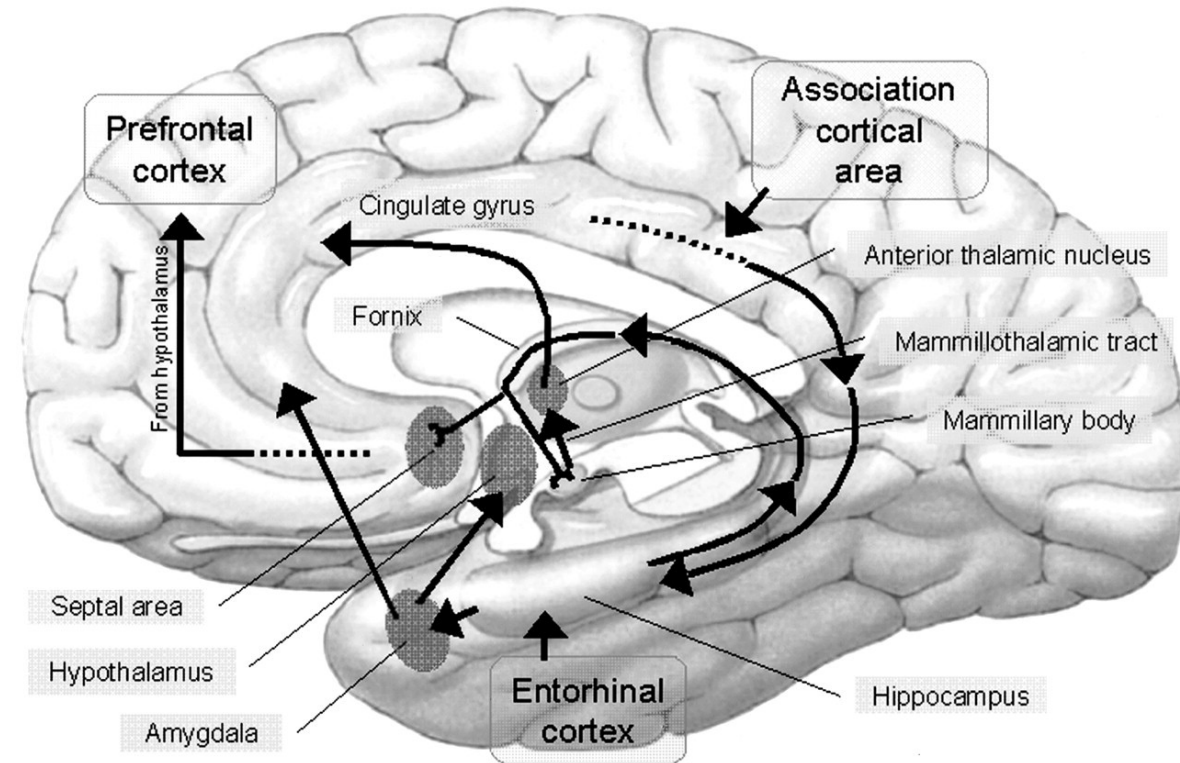
Jejich spoje:

Stria terminalis

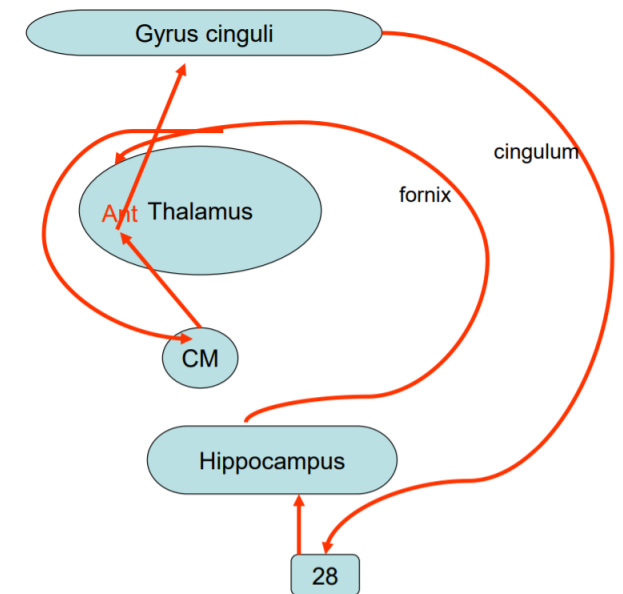
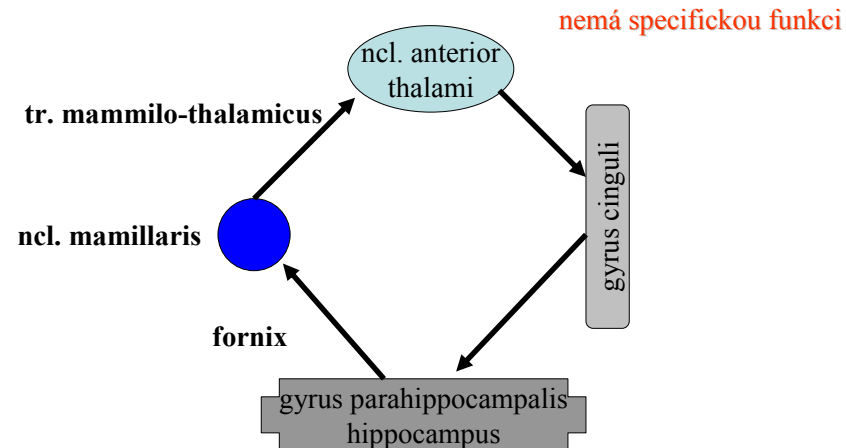
Fornix

Cingulum

Ventrální amygdalofugální svazek



Papezův okruh (James Papez 1939)



KLASICKÉ SCHÉMA REFLEXU:

PODNĚT

- Různá místa neocortexu
- Čichový vjem- cesty přes stria olfactoria-med.- g.paraterminalis, septum verum intermedia- substantia perforata ant.-hypothalamus lat- amygdala, area entorhinalis (28), uncus

CENTRUM

- Amygdalární komplex – limbická korová oblast

EFEKTOR

- Napojení na thalamus a hypothalamus PAPÉZOVÝM OKRUHEM
- HLAVNÍ VÝSTUPY:
 1. Fornix – hippocampus + corpora mammilaria
 2. Corpora mammilaria – tr.mamillothalamicus – ncll.anteriores thalami – tr.thalamocorticalis – gyrus cinguli, preforntální cortex
 3. Stria terminalis thalami – amygdala + hypothalamus
 4. Stria medullaris thalami – hypothalamus + ncll.habenulares
 5. Striae longitudinalis corporis callosi
 6. FLD
 7. Amygdalární komplex