

**MUNI  
MED**

**STUDENT'S GUIDE  
TO STATE EXAMINATION  
QUESTIONS  
FROM THE SURGERY**

**TOMÁŠ LEDVINA  
JAN LEDVINA  
PETR KRŠIČKA  
PETRA KUREČKOVÁ  
TEODOR HORVÁTH  
AND TEAM OF AUTHORS**

**MASARYKOVA  
UNIVERZITA**

Dear Readers,

You now hold the result of the dedicated work of numerous physicians from a wide range of medical, not only surgical, departments. Each author is deeply committed to facilitating your orientation within surgical topics and fostering a comprehensive understanding to guide you effectively toward accurate surgical reasoning and action.

The aim of this work extends beyond merely reflecting the dynamic evolution of the field of surgery. Above all, it seeks to impart key insights rooted in the rich surgical tradition of Brno – to authentically highlight the historical significance of what we consider the "crown jewel" of surgery at the Faculty of Medicine, Masaryk University.

These materials are by no means a substitute for the mandatory and recommended literature; rather, they serve as an overview and supplement, designed primarily as a guide to assist you in preparing for questions on the state examinations in surgery (*the number of the official state exam question can be found in brackets after the chapter title*).

Finally, we kindly request your feedback – an evaluation of each chapter in terms of both scope and content. Your input is invaluable and will greatly contribute to the improvement of this resource. We welcome any suggestions for revisions, proposals for additions or improvements, whether by condensing or expanding particular sections. Beyond constructive criticism, we are, of course, equally appreciative of any questions or positive feedback.

Your feedback will be invaluable in guiding this text's further development and refinement. Please send your thoughts to our email address: **chirmuni@group.muni.cz**, and we will respond to each message.

We wish you joy in achieving grown understanding and the creative inspiration it brings as you use this resource to enhance your surgical knowledge and skills.

The Editors,

Tomáš Ledvina, Jan Ledvina, Petr Krsička, Petra Kurečková and Teodor Horváth

VERSION UPDATED TO 7.1.2025

RECOMMENDED LITERATURE:

PAFKO, Pavel. *Základy speciální chirurgie*. 1. vyd. Praha: Galén, 2008, 385 s.

ISBN 9788072624027.

ŠNAJDAUF, Jiří a Richard ŠKÁBA. *Dětská chirurgie*. 1. vyd. Praha: Galén, 2005, 395 s.

ISBN 807262329X.

HOCH, Jiří a Jan LEFFLER. *Speciální chirurgie: učebnice pro lékařské fakulty*. 2. vyd. Praha:

Maxdorf, 2003, 224 s. ISBN 8085912066.

MARKO, Ľubomír a Peter KOTHAJ. *Atlas miniinvazívnej chirurgie a chirurgickej endoskopie*. 1.

vyd. Banská Bystrica: Marko, 1998, 156 s. ISBN 8096807609.

KABELKA, Miroslav. *Dětská chirurgie: učebnice pro lékařské fakulty*. 1. vyd. Praha: Karolinum,

1992, 320 s. ISBN 8070665610.

## TEAM OF AUTHORS

### University Hospital Brno - Bohunice:

- **Surgical Clinic:** MUDr. Cabanová Lucia; MUDr. Csölle Jakub; MUDr. Farkašová Martina; MUDr. Gregora Jakub; MUDr. Grolich Tomáš, Ph.D.; MUDr. Hlavsa Jan, Ph.D.; doc. MUDr. Horváth Teodor, CSc.; MUDr. Ivanecká Dominika; MUDr. Jaborník Martin; MUDr. Konečná Drahomíra; MUDr. Kurečková Petra; MUDr. Mgr. Kysela Petr, Ph.D.; MUDr. Linhartová Marcela, Ph.D.; MUDr. Marek David; MUDr. Marek Filip, Ph.D.; MUDr. Mitáš Ladislav, Ph.D.; MUDr. Moravčík Petr; MUDr. Petříková Laura; MUDr. Poláchová Veronika; MUDr. Pospíšil Jan; MUDr. PharmDr. Potrusil Martin; doc. MUDr. Procházka Vladimír, Ph.D.; MUDr. Svatoň Roman; MUDr. Svoboda Martin; MUDr. Španková Markéta; MUDr. Štefela Horváthová Erika; MUDr. Trenz Aleš; MUDr. Vaverka Vítězslav; MUDr. Vysloužil Pavel; MUDr. Vytešnicková Martina; MUDr. Zatloukal Martin
- **Clinic of Radiology and Nuclear Medicine:** MUDr. Andrašina Tomáš, Ph.D.; MUDr. Bárta Radek; MUDr. Hanzlová Barbora; MUDr. Matkulčík Peter; MUDr. Rohan Tomáš
- **Department of Gastroenterology and Internal Medicine:** doc. MUDr. Dastych Milan, CSc., MBA; doc. MUDr. Kroupa Radek, Ph.D.; MUDr. Skutil Tomáš
- **Urology Clinic:** doc. MUDr. Fedorko Michal, Ph.D., FEBU; MUDr. Kašík Marek; MUDr. Moravčíková Mária; MUDr. Trinh Tuan; MUDr. Varga Gabriel, Ph.D., FEBU; MUDr. Wasserbauer Roman
- **Clinic of accident surgery:** MUDr. Dobiášek Miroslav; doc. MUDr. Krtička Milan, Ph.D.; MUDr. Rak Václav, Ph.D.; MUDr. Staňa Martin; MUDr. Študent Petr; MUDr. Tručka Robert
- **Clinic of burns and reconstructive surgery:** MUDr. Dubovská Nikola; MUDr. Ferkodičová Iveta; MUDr. Hokynková Alica, Ph.D.; MUDr. Holoubek Jakub; MUDr. Mager Radomír, Ph.D.; MUDr. Matysková Dominika; doc. MUDr. Streit Libor Ph.D.; doc. MUDr. Šín Petr, Ph.D., MBA; MUDr. Topolčaniová Lenka; MUDr. Váňa Vladimír
- **Clinic of Neurosurgery:** doc. MUDr. Fadrus Pavel, Ph.D.; prof. MUDr. Smrčka Martin, Ph.D., MBA
- **Orthopedic clinic:** doc. MUDr. Chaloupka Richard, CSc.; MUDr. Parížek Dominik; MUDr. Ryba Luděk, Ph.D.
- **Institute of Laboratory Medicine - Bacteriology Section:** MUDr. Horváthová Beáta
- **Hospital Pharmacy - Clinical Pharmacy Section:** PharmDr. Musilová Karolína

### **University Hospital Brno - Children's Hospital:**

- **Clinic of paediatric surgery, orthopedics and traumatology:** MUDr. Bibrová Štěpánka, Ph.D.; MUDr. Doušek Robert; MUDr. Husár Matej; MUDr. Ledvina Jan; MUDr. Mareček Lukáš; MUDr. Marek Ondřej, Ph.D.; prof. MUDr. Plánka Ladislav, Ph.D.; MUDr. Starý David, Ph.D., MUDr. Tůma Jiří, CSc.; MUDr. Turek Jakub, Ph.D.; MUDr. Urbášek Karel, Ph.D.; MUDr. Václav Ondřej
- **Clinic of paediatric anesthesiology and resuscitation:** MUDr. Klabusayová Eva, DESAIC; MUDr. Kořínková Bianka; MUDr. Šoltysová Jana; prof. MUDr. Štourač Petr, Ph.D., MBA, FESAIC

### **St. Anne's University Hospital Brno:**

- **1st Dept. of Surgery:** MUDr. Berková Alena, Ph.D.; MUDr. Glombová Katarína; MUDr. Hasara Roman; MUDr. Hemmelová Beáta, Ph.D.; MUDr. Chovanec Zdeněk, Ph.D.; MUDr. Kašpar Michal; MUDr. Konečný Jan, Ph.D.; MUDr. Křenek Adam; MUDr. Musil Tomáš; doc. MUDr. Penka Igor, CSc.; MUDr. Peštál Adam, Ph.D.; MUDr. Prudius Vadim, Ph.D., MUDr. Reška Michal, Ph.D.; MUDr. Urbánek Libor; doc. MUDr. Veverková Lenka, Ph.D.; MUDr. Vlček Petr, Ph.D.; MUDr. Vojtaník Pavol; MUDr. Vystrčilová Tamara; MUDr. Žák Jan, Ph.D.
- **2nd Dept. of Surgery:** MUDr. Novotný Tomáš, Ph.D.
- **Dept. of Neurosurgery:** MUDr. Barák Martin; prof. MUDr. Brichtová Eva, Ph.D.
- **1st Dept. of Orthopedic:** MUDr. Jindra Jakub; MUDr. Kubíček Marian; MUDr. Liskay Jakub; MUDr. Mahdal Michal, Ph.D.; MUDr. Martinek Lukáš; MUDr. Nachtnebl Luboš, Ph.D.; MUDr. Pazourek Lukáš, Ph.D.; doc. MUDr. Tomáš Tomáš, Ph.D.
- **Dept. of Plastic and Aesthetic Surgery:** MUDr. Bayezid Can Kadir; MUDr. Berkeš Andrej; doc. MUDr. Dvořák Zdeněk, Ph.D.; MUDr. Janeček Pavel; MUDr. Klabusay Filip, Kubát Martin; MUDr. Menoušek Jan; MUDr. Streit Libor, Ph.D.

**Center for Cardiovascular and Transplant Surgery:** MUDr. Fila Petr, Ph.D.; doc. MUDr. Němec Petr, CSc., MBA

### **Masaryk Memorial Cancer Institute:**

- **Department of Surgical Oncology:** doc. MUDr. Coufal Oldřich, Ph.D.; doc. MUDr. Fait Vuk, CSc; MUDr. Gabrielová Lucie; MUDr. Hrabec Roman, FEBU; MUDr. Krésová Pavlína, Ph.D.; MUDr. Krsička Petr; MUDr. Rothová Veronika; doc. MUDr. Staník Michal, Ph.D.; MUDr. Šimůnek Radim; MUDr. Zapletal Ondřej; prof. MUDr. Žaloudík Jan, CSc

### **Trauma Hospital in Brno:**

- **Dept. of Traumatology:** MUDr. Kelbl Martin, Ph.D.; MUDr. Pavlacký Tomáš; prof. MUDr. Veselý Radek, Ph.D.; prof. MUDr. Wendsche Peter, CSc.; MUDr. Zukal Radek

### **Ivančice Hospital:**

- **Dept. of Surgery:** MUDr. Koloděj Daniel; MUDr. Ledvina Tomáš; MUDr. Majerčák Lukáš; MUDr. Musilová Zuzana, Ph.D.

### **University Hospital Ostrava:**

- **Dept. of Imaging Methods:** MUDr. Zavadil Jan

### **Tábor Hospital, Inc.:**

- **Dept. of Surgery:** MUDr. Laššáková Zuzana

### **Academician Ladislav Dérer Hospital:**

- **Surgical Clinic of SZU and UNB:** MUDr. Kučera Adam

### **External Contributors:** MUDr. Melichar Jindřich, CSc.

# CONTENT

<b>GENERAL SURGERY</b> .....	<b>9</b>
<i>Acute gastrointestinal bleeding (25)</i> .....	10
<i>Acute appendicitis (26)</i> .....	14
<i>Presentation, diagnostic process and management of appendicitis in paediatric, pregnant and elderly patients (38)</i> .....	18
<i>Acute (a)calculous cholecystitis, common bile duct stones, jaundice (4)</i> .....	22
<i>Diverticular disease (36)</i> .....	25
<i>Intestinal ischemia (28)</i> .....	28
<i>Peritonitis (27)</i> .....	33
<i>Ileus (29)</i> .....	37
<i>Hernias of the anterior abdominal wall, diaphragmatic hernias (11)</i> .....	40
<i>Small bowel and large bowel neoplasms (37)</i> .....	44
<i>Inflammatory diseases of small bowel and their surgical management (34)</i> .....	48
<i>Inflammatory diseases of large bowel and their surgical management (35)</i> .....	52
<i>Hemorrhoids, anal fissure (2)</i> .....	56
<i>Anorectal fistula and abscess, pilonidal sinus disease (1)</i> .....	60
<i>Esophageal surgery, anatomy, approaches, types of operations (20)</i> .....	65
<i>Surgery for benign gastric diseases (31)</i> .....	68
<i>Gastroduodenal ulcer diseases (32)</i> .....	71
<i>Gastric tumours (33)</i> .....	74
<i>Liver surgery – anatomy, approaches, types of operations (3)</i> .....	78
<i>Neoplasms of the liver (5)</i> .....	83
<i>Spleen surgery – anatomy, approaches, types of operations (6)</i> .....	87
<i>Acute and chronic pancreatitis (7)</i> .....	90
<i>Pancreatic neoplasms (9)</i> .....	94
<i>Obstructive jaundice (30)</i> .....	97
<i>Retroperitoneal tumours (10)</i> .....	102
<i>Adrenalectomy - anatomy, approaches, types of operations (8)</i> .....	106
<i>Diagnostic methods in urology . examination, laboratory tests, endoscopic and imaging methods (39)</i> .....	108
<i>Arterial aneurysms (12)</i> .....	113
<i>Peripheral arterial disease of lower extremities (13)</i> .....	117
<i>Acute limb ischemia (14)</i> .....	122
<i>Treatment of varicose veins (15)</i> .....	126
<i>Goitre, surgery of thyroid gland (17)</i> .....	128
<i>Gynecomastia, inflammatory disorders of the breasts (16)</i> .....	132
<i>Breast tumors (24)</i> .....	136

<i>Thoracic outlet syndrom, nerve compression syndromes of arm and forearm (21)</i> .....	141
<i>Acute mediastinitis (18)</i> .....	145
<i>Mediastinal tumors, superior vena cava syndrom (19)</i> .....	148
<i>Pulmonary abscess, empyema (22)</i> .....	151
<i>Lung cancer and mesothelioma (23)</i> .....	155



# GENERAL SURGERY

## ACUTE GASTROINTESTINAL BLEEDING (25)

Majerčák Lukáš, Kysela Petr

Acute gastrointestinal bleeding is part of the acute abdomen group. Gastrointestinal bleeding can be classified into upper, middle and lower GI bleeding due to the different diagnostic and therapeutic approaches. Acute bleeding has a sudden onset, often accompanied by **haemodynamic instability** (e.g., blood pressure drops and increased heart rate).

### **Acute Upper GI Bleeding:**

The boundary is the **Treitz ligament**. The most common cause of upper GI bleeding is **peptic ulcer disease** of the gastroduodenum. Other sources may include **oesophageal varices**, **Mallory-Weiss syndrome**, or **tumours** (most commonly adenocarcinoma, typically GIST, less frequently lymphoma).

The presentation includes **haematemesis**—vomiting blood, either fresh or digested (resembling **coffee grounds**), and **melaena**, which is stool containing digested blood, typically tarry black, sticky, and with a characteristic odour. Similar stool discolouration can also occur after consuming beetroot, blueberries, activated charcoal, or iron supplements, although the stool is usually formed in these cases. In some cases of massive bleeding with rapid passage, upper GI bleeding can present as **enterorrhagia**—the evacuation of red, undigested blood. Depending on the severity of the bleeding, the patient may develop anaemic symptoms (weakness, pallor, palpitations, dyspnoea), haemorrhagic shock (centralised circulation, cold sweat, cold extremities), or altered consciousness (collapse, syncope, often during defecation).

History-taking should include asking about the use of **NSAIDs or corticosteroids**, which can cause gastroduodenal ulcers, as well as any coagulopathies or anticoagulant/antiplatelet medication. Ask about **alcohol abuse** and signs of **liver cirrhosis**, which is the most common cause of portal hypertension and oesophageal varices. The physical examination assesses the patient's overall condition (consciousness, BP, HR, SpO<sub>2</sub>) and confirms melaena or enterorrhagia on rectal examination. Abdominal pain rarely accompanies upper GI bleeding. Blood tests initially show **leukocytosis**, followed by anaemia and a drop in haematocrit. In massive bleeding, a drop in haemoglobin may only appear later, so clinical status should guide management. The definitive diagnosis and source of bleeding are confirmed by **gastroscopy** (only if the patient is stabilised). In peptic ulcer disease, the **Forrest classification** assesses bleeding severity (I. active bleeding, II. signs of recent bleeding, III. no signs of bleeding).

The main treatment involves monitoring the patient's vital signs in an ICU, stabilising circulation with fluid replacement, followed by blood transfusion if necessary, discontinuing anticoagulants, and correcting coagulation (with fresh frozen plasma, clotting factors, etc.). For peptic ulcer bleeding, **proton pump inhibitors (PPIs)** are administered. In variceal bleeding, **vasoactive agents** (terlipressin, somatostatin) are used. **Gastroscopy** is key in diagnosing and treating acute upper GI bleeding. It offers the possibility of controlling the bleeding through local injection (e.g., diluted adrenaline or ethanol injected around the lesion, then into its centre), **thermocoagulation**, or **mechanically** (applying clips or ligating varices with rubber bands). If endoscopic treatment of arterial bleeding fails or is impossible, **angiography** is indicated to selectively embolise the source (transarterial embolisation - TAE). In cases of endoscopically unmanageable variceal bleeding, one option is a **portosystemic shunt (TIPS)**, or a **Sengstaken-Blakemore tube** may be temporarily used to tamponade the gastric cardia and oesophagus. However, this method is temporary due to the risk of pressure ulcers. Surgical treatment of upper GI bleeding is rarely needed due to advances in endoscopy and minimally invasive techniques and is reserved for cases of uncontrollable bleeding. Surgery includes **suturing or excising the ulcer** via **duodenotomy** or **gastrotomy** (incising the duodenum or stomach) or, in most cases, resectional surgery (Bilroth I, Bilroth II, or in extreme cases, total gastrectomy). Every rebleed with circulatory instability after less invasive methods should be managed surgically.

### **Acute Middle GI Bleeding:**

Bleeding from the **small intestine** is a diagnostic and therapeutic challenge. The most common cause in older patients is **angiodysplasia**. However, other causes can include ulcers due to ectopic gastric mucosa (typically in a Meckel's diverticulum), bleeding due to portal hypertension after endoscopic treatment of gastric varices, or GIST, and rarely other malignancies. It's also important to consider **aorto-enteric fistula**, particularly in patients with a history of severe retroperitoneal inflammation (e.g., pancreatitis) or vascular reconstruction on the aorta.

Upper and lower endoscopies are usually performed in a stable patient, which does not reveal the source. **Push-type endoscopy** can evaluate up to 160 cm of the jejunum orally and up to 120 cm of the terminal ileum anally. In cases of recurrent minor bleeding, **intestinal ultrasound**, **enteroclysis**, or CT can be performed. Suspicion of small bowel pathology without detection on CT, US, or enteroclysis is a typical indication for **capsule endoscopy**. To exclude ectopic gastric mucosa or neuroendocrine neoplasia, **octreotide scanning** from nuclear medicine can be used. Significant bleeding warrants immediate **contrast-enhanced CT**. Therapeutically, intervention is usually either **surgical** or through **endovascular embolisation**, with the risk of ischaemia. Surgical resection is

usually simple, but localising the bleeding source is difficult, and **intraoperative enteroscopy** may be required. In case of the aorta-enteric fistula neither endoscopy nor contrast-enhanced CT usually confirms the diagnosis. After typical repeated unexplained bleeding, it often manifests with massive exsanguinating enterorrhagia. In suspected aorto-enteric fistula, urgent surgical revision is indicated.

### **Acute Lower GI Bleeding:**

Lower GI bleeding occurs less frequently than upper GI bleeding. The most common cause is **colonic diverticulosis**, followed by anorectal conditions (bleeding haemorrhoids), bowel inflammation of ischaemic or infectious origin (including Clostridium enterocolitis), and **IBD** or malignancies. A specific group includes bleeding after **colonoscopy polypectomy** or recent bowel surgery.

Clinically, lower GI bleeding presents as **rectal bleeding** (rectorrhagia/enterorrhagia). It is important to determine whether the blood is fresh, clotted, on or within the stool. The fresher the blood on the stool's surface, the more distal the bleeding source. As with upper GI bleeding, depending on the severity, the patient's condition may progress to shock and altered consciousness.

History-taking should include asking about **family history** of malignancies, diagnosed diverticulosis, IBD, recent colonoscopy or bowel surgery, use of broad-spectrum **antibiotics**, and again **coagulopathies** or anticoagulant medication. The clinical examination focuses on assessing circulatory stability, abdominal examination, and rectal examination—starting with inspection for external haemorrhoids, fistulas, fissures, palpation for thrombosed haemorrhoids or tumours, and then evaluating the stool consistency on the glove. Laboratory tests should focus on blood count (to assess bleeding severity) and coagulation parameters (normalising coagulation is crucial for stabilising the patient). Early diagnosis requires **anoscopy/proctoscopy**, which identifies the source of bleeding from the rectum or anus, or it may reveal blood coming from higher up.

Again, the cornerstone of treatment is stabilising the patient in an ICU (monitoring vital signs, fluid therapy, blood transfusion, normalising coagulation parameters etc.). In cases of uncertainty about the bleeding source and suspected varices/haemorrhoids, **somatostatin analogues** are also administered. **PPIs** do not have a direct therapeutic effect but are given prophylactically as acute bleeding increases the risk of stress ulcers. In most cases (about 80 %) of acute lower GI bleeding, **spontaneous haemostasis** occurs without requiring radiological, endoscopic, or surgical intervention. **Colonoscopy** in acute undiagnosed bleeding and an unstable patient is not indicated. Verifying the bleeding source and possibly its treatment via colonoscopy is possible in a stable patient after proper orthograde bowel preparation (cleansing with laxatives). In an unstable patient with enterorrhagia, the source should also be considered in the upper GI tract (see above), and

**gastroscopy (GFS)** should be performed. If haemodynamic instability persists despite initial treatment, **CT angiography** is indicated to identify the bleeding source. If found, bleeding can be stopped **radiologically by selective embolisation**, with the risk of ischaemia. If radiological intervention fails and the patient's haemodynamic instability persists, **resection surgery** is indicated—either right or left hemicolectomy, depending on the bleeding site, or in extreme cases, **total colectomy**.

## ACUTE APPENDICITIS (26)

Křenek Adam

### **Introduction:**

Acute appendicitis is the most common abdominal emergency requiring surgery. Establishing the correct diagnosis is a key prerequisite for successful treatment. Acute appendicitis may be the biggest liar in the field of surgery, because the symptoms described in textbooks are given for typical forms and for the typical course of acute inflammation of the appendix. Depending on the position of the appendix, the duration of the inflammation and the age of the patient, inflammation of the appendix can manifest itself in a wide range of symptoms in each affected individual. When examining the abdomen, every surgeon must think about this disease.

Academician Arnold Jirásek already stated in 1949: "It is an insidious, insidious and dangerous disease that causes diagnostic difficulties due to its unpredictable onset and course. We can definitely say that this statement is still valid today.

### **Patogenesis:**

Although acute appendicitis is the most common acute abdominal emergency, its etiopathogenesis is still not fully understood.

Obstruction of the lumen of the appendix probably plays the most important role in the pathogenesis of appendicitis.

According to various authors, obstruction is found in up to 2/3 of cases of acute appendicitis, especially obstruction of the proximal part of the lumen - fibrous bands from the cecum, lymphatic hyperplasia, fecoliths, stones, rarely parasites. In the remaining third of cases, no obstruction is found. In these cases the triggers may include pressure on the appendix from the outside, its length or a disturbance of the microbial flora caused by frequent use of antibiotics.

Intraluminal pressure causes arterial obstruction and ischemia in the intestinal wall. Intestinal microorganisms penetrate the damaged mucosa causing intramural inflammation. Depending on the stage of the inflammation, we distinguish between catarrhal, ulcerative, phlegmonous and the most severe stage – gangrene. Gangrene is the cause of perforation of the appendix with the development of circumscribed (bounded) or diffuse peritonitis.

If our organism reacts to a perforation or an acutely inflamed appendix by limiting the entire process, it surrounds the inflamed organ with omentum, small and large intestine, adjacent mesentery - a periappendicular infiltrate is formed. The infiltrate consists of our tissues, organs, exudate and fibrin. Macroscopically, the organs are closely adhered to each other, their preparation is difficult, with a risk of their injury and bleeding. The rule is that the infiltrate is not treated surgically (of

course, only in case the patient's condition is stable), but is treated conservatively - hospitalization, bed rest, ATB, infusion therapy, analgesic therapy. A periappendicular abscess may develop from the infiltrate.

Abscess treatment is today the domain of interventional radiology, when a puncture is performed under CT or US.

### **Clinical picture:**

Typically, the disease begins with pain, periumbilical with subsequent transfer to the right hypogastrium. The pain is limited, worse when coughing, walking, and moving. Patients usually describe it as a dull constant pain. If vomiting is present, it develops early after the onset of abdominal pain. Vomiting before the development of pain rather casts doubt on the diagnosis of appendicitis.

The clinical picture of appendicitis can be influenced by the atypical position of the appendix or the patient's altered reaction due to age, pregnancy or the use of drugs - antibiotics, immunosuppressants, steroids.

**Laterocaecal appendicitis** - pain in the lateral right hypogastrium and muscle contraction can affect the lumbar region.

**With a long appendix** that reaches the subhepatic landscape, it can mimic inflammation of the gallbladder.

**Retrocaecal appendicitis** leads to pain and muscle contraction, similar to laterocaecal appendicitis, with painful extension of the leg in the hip when examining the patient on the left side.

**The inflammation located close to the ureter** can mimic the picture of renal colic.

**Pelvic appendicitis** may not cause muscle spasms. The pain is usually close to the symphysis and the inguinal ligament, internal rotation in the hip is painful. Dysuric problems or diarrhea also occur. In women, it mimics gynecological disease.

**Mesoceliac appendicitis** (the appendix lies medially between the loops of the small intestine on the mesentery) is manifested by poor clinical findings on the abdomen with pain around the navel.

**Left-sided appendicitis** (a long appendix extends into the left hypogastrium or a normal-length appendix is located to the left due to situs viscerum inversus) leads to pain and muscle contraction in the left hypogastrium. Clinically, it can mimic diverticulitis. The situation will often be clarified only during surgical revision of the abdomen

### **Appendicitis in children**

a) Up to 2 years of age - rare, the appendix opens into the caecum widely, there is no congestion of the contents in the appendix. Danger due to reduced ability to limit inflammation (low immune resistance of the organism, poor ability of the peritoneum to form adhesions, short omentum).

Manifestations: drowsiness, irritability, tearfulness, loss of appetite. Vomiting, high temperature and pain occur when the disease progresses

b) Above 2 years of age, the clinical picture practically does not differ from that of adults

### **Senile appendicitis**

Difficult to diagnose, the body's ability to respond to inflammation is reduced, classic symptoms may not be present, pain is low, muscle contractions are usually absent. The course of the disease itself is more serious, purulent complications and perforation are frequent

### **Appendicitis in pregnancy**

Symptoms depend on the stage of pregnancy. In the 1st trimester, the clinical picture is not different from non-pregnant women. During the 2nd and 3rd trimester, the clinical finding is changed by the dislocation of the cecum with the appendix cranially. The uterus overlaps the area of the hypogastrium, making the clinical examination difficult and reducing the ability of the omentum to localize the infection, therefore there is an increased risk of developing diffuse peritonitis in case the appendix perforates. The mother can thus be at risk of severe intra-abdominal infection and the fetus from premature birth to death. Therefore, when appendicitis is suspected, it is better not to hesitate with appendectomy.

### **Abdominal examination:**

**Inspection** - restriction of the breath wave in the right hypogastrium during inflammatory irritation of the peritoneum in this place may be present. **Auscultation** - is of no greater importance for establishing the diagnosis, in case of diffuse peritonitis we do not hear peristalsis for paralytic ileus.

**Percussion** - soreness and defensive contraction of the abdominal wall - Pléniés sign. **Palpation** - pain in the right hypogastrium, Blumberg's sign - pain during decompression of the right hypogastrium, Rovsing - pain in the right hypogastrium during decompression of the left hypogastrium **Per rectum:** bulging of Douglas space, painful indagation.

**Laboratory tests:** in the tests we look for elevation of inflammatory parameters - Leukocytes, CRP.

### **Paraclinical examination:**

a) **Ultrasound examination** - can exclude or confirm the diagnosis.

b) **X-ray:** not contributive in the diagnosis of acute appendicitis, in some cases we can observe the air fluid levels in the right half of the abdomen.

Given that, as already mentioned in the first paragraph of the chapter, that acute appendicitis can be manifested by a whole range of symptoms, we always combine and evaluate clinical examination and paraclinical methods as a whole and in the context of the patient's overall condition. If, despite all the available examinations, we have diagnostic dilemma, a CT examination of the abdomen or a diagnostic laparoscopy is performed.



### **Differential diagnosis**

Acute mesenteric lymphadenitis, inflammation of Meckel's diverticulum, Crohn's disease, gallbladder disease (cholecystitis, biliary colic), perforated gastroduodenal ulcer, acute gastroenteritis, renal colic, ureterocele, ureteral stricture and systemic diseases, e.g. porphyria, diabetes mellitus.

In women, we always consider gynecological diseases – right-sided adnexitis, ovarian cyst perforation, ovarian cyst torsion, ruptured ectopic pregnancy

### **Therapy:**

The treatment of appendicitis is primary surgical - appendectomy. Appendectomy can be performed laparoscopically or from a laparotomy. In the case of appendectomy from laparotomy, we choose gridiron (McBurney) incision, pararectal or lower median laparotomy. Periappendicular infiltrate is treated conservatively. In extreme cases, when adequate surgical care is not available, acute appendicitis can be treated conservatively - ATB, infusion therapy.

### **Complications of acute appendicitis:**

**Perforation** - perforation can result in:

- a) **Periappendicular infiltrate** - treatment: conservative (hospitalization, bed rest, ATB, infusion therapy, analgesic therapy)
- b) **Abscess** - treatment: puncture under CT or ultrasound
- c) **Peritonitis** - treatment: surgery

**Post-inflammatory adhesions** in the postoperative period can be the cause of mechanical ileus.

**Pylephlebitis** - rarely occurring purulent thrombophlebitis of the portal venous system. Patients tend to have chills, high temperature, subicterus, and later liver abscesses. This is a rare but serious and potentially fatal complication

### **Conclusion:**

Appendicitis is a common disease that requires an acute surgical solution. In most cases, the disease follows a typical course, but we must always think of a different course and different symptoms.

**PRESENTATION, DIAGNOSTIC PROCESS AND MANAGEMENT OF APPENDICITIS IN PAEDIATRIC,  
PREGNANT AND ELDERLY PATIENTS (38)**

Poláchová Veronika, Konečná Drahomíra

Acute appendicitis (hereinafter referred to as „AA“) is the most common cause of sudden abdominal stroke, which can affect the entire population. Issue of AA has been elaborated in detail in a separate chapter. In this chapter, we will focus on AA in childhood, pregnancy and old age, which are characterized by elements so specific that they require their own commentary.

In developed countries, AA affects 7% of the population with incidence peaking in the 2<sup>nd</sup> - 3<sup>rd</sup> decade of life.

### **I. CHILDHOOD**

AA in childhood, especially up to the age of two, tends to be a rarity. Considerable experience and patience on the part of the physician is required due to very limited cooperation from the young patient. In the early stages, the clinic may manifest itself with tearfulness, irritability and inappetence. This symptomatology may initially be mistaken for dyspepsia or enterocolitis. Later vomiting, temperature and pain may follow. As a consequence of this delay, a definitive diagnosis of AA is more often not made until the later stages, when it is often already complicated by perforation of appendix with peritonitis.

In youth and in adolescence the clinic already resembles more AA of an adult, with problems such as migratory pain passing within a few hours from the umbilicus to the right lower quadrant, signs of peritoneal irritation, tachycardia, subfebrile, vomiting may begin to appear. Children tend to take an antalgic posture with the lower limbs flexed. However, in making the diagnosis we must beware of possible dissimulation on the side of boys and tendency to exaggeration on the side of girls.

The diagnosis includes: taking a targeted anamnesis, clinical findings, ultrasound of abdomen, and in case of complications it is possible to perform a CT scan, blood count (leukocytosis), CRP and urine analysis.

In the differential diagnosis it is necessary to exclude urological causes of difficulties, ovarian or testicular torsion, mesenteric lymphadenitis, intestinal invagination and ileus.

Children are treated surgically. It consists in appendectomy, which can be performed either classically from laparotomy or laparoscopically, which is preferred treatment for children older than 8 years or it depends on the habit of the body.

### **II. PREGNANCY**

The incidence of AA is the same for pregnant women as for non-pregnant woman. It can occur in all trimesters of gestation, at birth or in the puerperium, however most often in the second and third trimesters of pregnancy. Diagnosis of this disease is usually difficult. There may be a more rapid progression of inflammation, which is associated with additional risks for both the expectant mother and the fetus. Quickness of diagnosis and interdisciplinary cooperation are therefore very important. Physiological changes and anatomical distribution of organs caused by a gradually growing uterus significantly affect the clinical picture. Initial symptoms such as nausea, vomiting, lack of appetite or unclear laboratory (leukocytosis) are initially attributed to the current pregnancy.

Symptoms and physical examination in the 1<sup>st</sup> trimester do not differ significantly from non-pregnant women. Right lower abdominal tenderness can be a reliable sign of AA.

Diagnostic difficulties occur in the 2<sup>nd</sup> and 3<sup>rd</sup> trimesters due to atypical localization of pain caused by relocation of the appendix and cecum to the right subcostal region. Thus, as the pregnancy progresses we can expect the appendix to lodge more cranially. It is important to differentiate the pain caused by AA, which is constant and localized in the right subcostal region, from possible uterine contractions, which occur at regular intervals. Other symptoms may include diarrhoea or conversely cessation of gas and faeces.

During the clinical examination the patient is examined in the classic position on the back. Especially when it comes to pregnant women we can apply the examination with rolling the patient to the left side with constant pressure in the painful area, if the pain persists, it may be appendicitis. The same examination in reverse with rolling over to the right side with pain ileoceccally may also clarify the diagnosis of AA.

Diagnosis is also difficult during labour because of persistence of pain even in between contractions or in the puerperium of labour because of abdominal wall weakness and thus obscuration of symptoms.

Laboratory testing of blood and urine is not conclusive as a result of leukocytosis caused by pregnancy, and therefore it is possible to monitor the dynamics of inflammatory parameters during possible developing inflammation.

Among imaging methods, ultrasound is the first choice, during which the fetal vitality is of course also determined. We try to avoid CT scans because of the radiation load, MRI is more expensive however it is compensated by zero radiation.

In differential diagnosis, the most important thing is to exclude gynaecological causes of problems, such as ectopic pregnancy, ovarian cyst, ovarian torsion, miscarriage, adnexitis, and right-sided hydronephrosis or pyelonephritis.

When AA is suspected, even if paraclinticity is not proven, we usually proceed to surgery. This is due to the lower risk of anaesthesia for mother and child compared to appendicitis without surgery. At first in the early stage of pregnancy laparoscopic revision is considered, only at a more later stage of pregnancy, approximately after the third trimester, laparotomy from an alternate incision is resorted to.

### **III. OLD AGE**

10% of patients with acute appendicitis are over 60 years of age. In the old age, due to age, comorbidities or possible dementia, diagnosis is more difficult. They often underestimate their symptoms and seek medical attention at more advanced stages of the problem than would be appropriate. Therefore morbidity and mortality rates are increasing when it comes to patients over 70 in comparison to younger patient.

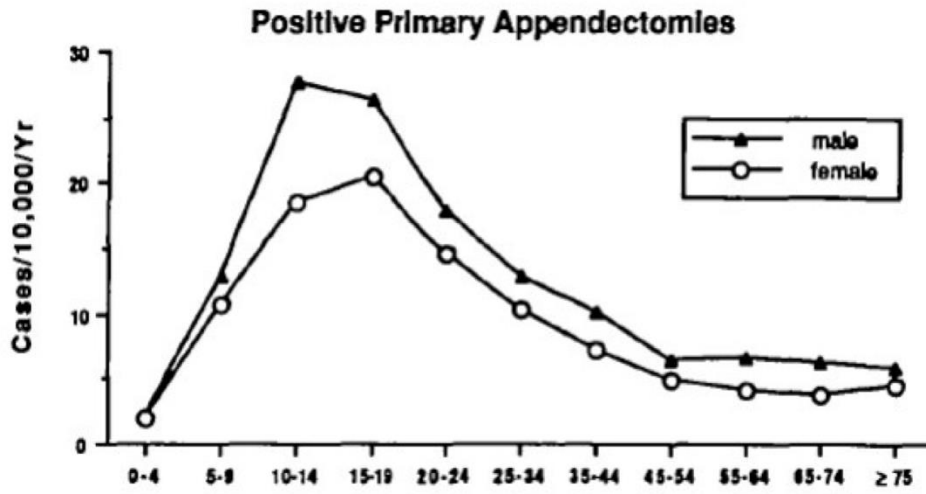
Only 20% of seniors with AA have typical clinical symptoms. Most of them have history of difficulties longer than 48h at the time of diagnosis of AA. Symptomatology of elders comes often with a minimal increase in temperature, 25% have no tenderness in the right lower abdomen, overall discreet local findings. Hence, the risk of complications increases from the more frequent finding of perforations with peritonitis. In addition, almost in half of the case difficulties may appear clinically as intestinal obstruction.

In laboratories leukocytosis is mostly absent.

The golden standard in the diagnosis of AA is an ultrasound examination and abdominal X-ray for exclusion of ileus or pneumoperitoneum. CT scan is indicated only in case of atypical symptomatology or unclear clinical picture with negative ultrasound findings.

In the differential diagnosis we focus on urinary tract infection, bladder retention, perforation of organs, intestinal ischemia or possible malignancy in the abdominal cavity.

The treatment is surgical, we prefer the laparoscopic approach, however in advanced stages of inflammation the laparotomy approach cannot be excluded.



Addiss DG, Shaffer N, Fowler BS, Tauxe RV. The epidemiology of appendicitis and appendectomy in the United States. *Am J Epidemiol* 1990; 132:910-925

## ACUTE (A)CALCULOUS CHOLECYSTITIS, COMMON BILE DUCT STONES, JAUNDICE (4)

Glombová Katarína

### **Cholelithiasis**

**Introduction and Definition:** Cholelithiasis is the presence of stones in the gallbladder (cholecystolithiasis) or in the bile ducts (choledocholithiasis). It may be asymptomatic, but it can also lead to serious complications: acute cholecystitis, pancreatitis, cholangitis, or biliary colic.

Gallstones are composed of cholesterol, bilirubin, or a combination of both. The prevalence in Western countries is around 10–20% in adults. The incidence increases with age, obesity, and certain genetic factors.

The pathogenesis of stone formation is complex and involves several factors. **Cholesterol stones:** result from an excess of cholesterol in the bile, exceeding the ability of bile acids and lecithin to keep cholesterol in micellar solution. The excess cholesterol crystallizes and forms monohydrate crystals that aggregate into stones. This process is promoted by bile stasis in the gallbladder (reduced motility of the gallbladder during pregnancy, obesity, or rapid weight loss). **Pigment stones:** non-conjugated bilirubin that precipitates in the presence of calcium. Typically found in patients with chronic hemolysis, such as those with sickle cell anemia or liver cirrhosis. Increased hemoglobin turnover leads to overproduction of bilirubin, which does not conjugate and subsequently crystallizes. **Mixed stones:** the most common, containing both cholesterol and bilirubin. They form through a combination of the pathophysiological mechanisms mentioned above.

**Risk factors for the development of cholelithiasis:** obesity and metabolic syndrome, pregnancy, rapid weight loss, medications (e.g., fibrates, hormonal contraception, somatostatin), genetic factors. Cholelithiasis is often asymptomatic and is incidentally discovered during imaging studies performed for other reasons. Symptoms include: **biliary colic** - the most common symptom of cholelithiasis. It is a sudden, intense pain in the right upper quadrant of the abdomen or epigastrium, often radiating to the back or under the right shoulder blade. Usually occurs after a high-fat meal and lasts 1–5 hours. On physical examination, the gallbladder is often tender to palpation.

### **Complications of cholelithiasis:**

**Acute cholecystitis:** occurs in 10% of patients with cholelithiasis. Characterized by persistent pain, fever, nausea, and vomiting. Clinical examination reveals a tender gallbladder, a positive Murphy's sign, and sometimes subfebrility. **Choledocholithiasis and cholangitis:** stones in the bile duct can cause obstruction leading to cholestasis and cholangitis. The classic symptoms of cholangitis are Charcot's triad: right upper quadrant pain, fever with chills, and jaundice. Untreated, it rapidly leads

to septic shock. **Pancreatitis:** stones blocking the ampulla of Vateri. Symptoms: sudden abdominal pain radiating to the back, elevated pancreatic enzymes, inflammatory response, multi-organ failure.

**Diagnosis:**

**Laboratory tests:** cholestasis - elevated bilirubin, ALP, GGT; acute cholecystitis - elevated CRP, leukocytosis. **Imaging methods:** Ultrasonography, MRCP (magnetic resonance cholangiopancreatography), ERCP (endoscopic retrograde cholangiopancreatography).

**Treatment:**

**Conservative treatment:** Asymptomatic cholelithiasis does not require treatment. Symptomatic – Ursafalk, spasmolytics, analgesics. **Surgical treatment:** laparoscopic or open cholecystectomy (subcostal incision in the right upper quadrant). **Endoscopic treatment:** ERCP.

**Prevention:** Healthy lifestyle.

**Inflammations of the Gallbladder and Bile Ducts**

Inflammations are classified as acute, subacute, and chronic.

**Acute cholecystitis:** arises due to obstruction of the cystic duct, distension of the gallbladder, ischemia of the wall, followed by inflammation with the potential for necrosis, perforation, and development of biliary peritonitis. **Cholangitis:** obstruction of the bile ducts → increased intraluminal pressure, bile stasis. Subsequently, bacteria from the GI tract enter the bile ducts → sepsis, MODS, MOF.

**Clinical presentation:**

**Acute cholecystitis:** sudden, intense pain in the right hypochondrium, radiating under the right shoulder blade (Collins' sign), nausea, vomiting, fever. Positive Murphy's sign (tenderness on palpation of the right hypochondrium during inspiration), subicterus to jaundice (biliary tract obstruction, presence of Mirizzi's syndrome). **Cholangitis:** Charcot's triad: pain, fever with chills, and jaundice. In severe cases, Reynolds' pentad (+ hypotension, mental status changes) can develop.

**Diagnosis:**

**Laboratory tests:** leukocytosis, elevated CRP, elevated ALP and GGT, elevated bilirubin.

**Imaging methods: Ultrasonography:** reveals the presence of gallstones, thickening of the gallbladder wall (>4 mm), pericholecystic edema. **ERCP:** allows for stone removal, bile duct drainage, and stent placement. **CT and MRCP:** CT is indicated in unclear diagnoses or suspected complications such as gallbladder perforation. MRCP is a non-invasive method that is highly sensitive for detecting choledocholithiasis and other bile duct abnormalities.

**Treatment:**

**Acute cholecystitis: Conservative treatment:** fluids, antibiotics, spasmolytics, analgesics. **Surgical treatment:** laparoscopic cholecystectomy within 24–72 hours, urgent cholecystectomy, cholecystostomy.

**Cholangitis: Antibiotic therapy:** immediate broad-spectrum antibiotics. In septic shock, intensive care with circulatory support. **Endoscopic treatment:** ERCP - bile duct decompression. Percutaneous transhepatic cholangiography (PTC) if ERCP is contraindicated.

**Complications:**

**Acute cholecystitis:** empyema, gangrene, and perforation of the gallbladder, biliary peritonitis, and septic shock. **Chronic cholecystitis:** porcelain gallbladder, gallbladder carcinoma.

**Cholangitis:** septic shock, liver abscesses, secondary biliary cirrhosis, and pancreatitis, MODS, MOF, death.

**Jaundice:** clinical syndrome characterized by yellowing of the skin, sclera, and mucous membranes due to elevated bilirubin levels.

**Classification:**

**Prehepatic (hemolytic):** overproduction of unconjugated bilirubin during hemolysis leading to liver overload. **Hepatic (liver-related):** due to liver cell damage, caused by viral hepatitis, cirrhosis, alcoholic liver disease, drugs, or toxins. **Posthepatic (obstructive):** caused by obstruction of bile flow from the liver – stones, tumors, strictures, or pancreatitis.



## **DIVERTICULAR DISEASE (36)**

Ledvina Tomáš, Marek Filip

Diverticulosis of the digestive tract is a condition, when pouches or pockets are formed on the digestive tube, most often on the colon in the region of the colon descendens and sigmoideum, but they can be found throughout the whole range, e.g.: esophageal diverticula, parapapillary diverticula of the duodenum, Grasser's diverticula of the jejunum or Meckel's diverticulum of the small intestine. On the basis of the aetiology, we distinguish between congenital (=right) diverticula, whose wall is formed by all layers of the digestive tube, and acquired (=false, pseudo) diverticula, whose wall is formed only by mucosa and serosa (see figure).

**Esophageal diverticula** are most often formed by the entire thickness of the wall. According to their location in the oesophagus, diverticula are divided into parapharyngeal diverticula (=Zenker's diverticulum), located just below the pharyngeal to oesophageal transition, thoracic diverticula in the middle part of the oesophagus and epiphrenic diverticula located just above the diaphragm.

Diverticula close to the sphincters (parapharyngeal and epiphrenic) are caused by a malfunction of these sphincters, leading to an increase in intraluminal pressure in the oesophagus and bulging of the weakened oesophageal wall – the diverticulum is formed. Thoracic diverticula are most commonly caused by an inflammation in the mediastinum, the inflammation process pulls out the affected part of the oesophagus and form a diverticulum. Clinically, oesophageal diverticula are manifested by swallowing disorders, coughing, foetor ex ore, heartburn, recurrent pneumonia, but they can also be asymptomatic for a long time and manifest only when large in size by pressure on the surrounding organs. Diagnosis is based on contrast X-ray/CT passage through the oesophagus, gastroscopy and manometry to exclude achalasia. In surgical treatment, we choose different surgical procedures according to the type of diverticulum. For Zenker's diverticulum, we choose endoscopic management - diverticulotomy with laser or stapler dissection. If endoscopic intervention is not possible, we choose the cervical incision approach at the inner edge of the m. sternocleidomastoideus, we perform cricopharyngeal myotomy (to release the tension of oesophageal sphincter) and resection of the diverticulum (e.g. with a stapler), be careful of a damage to the n. laryngeus recurrens. For thoracic diverticula, we choose the thoracotomy approach or the less invasive VATS - VideoAssisted Thoracoscopic Surgery. For epiphrenic diverticula, we again choose the thoracotomy / VATS approach, or we can choose the laparoscopic approach from the abdominal cavity.

**Meckel's diverticulum** (MD) is the most common congenital defect of the gastrointestinal tract. It is a true diverticulum that arises from imperfect closure of the omphaloenteric duct, lying 20-100cm from the ileocecal transition on the small intestine. Inside of the MD, we can find heterotopic tissue

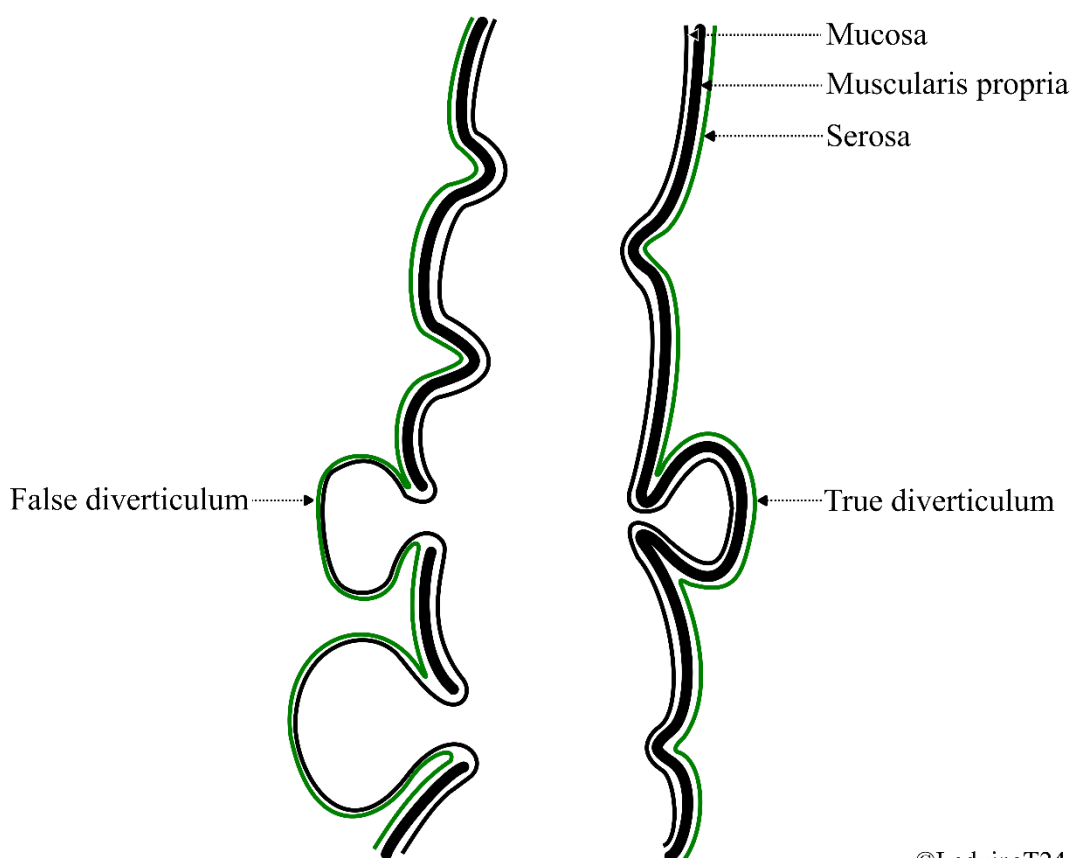
(gastric mucosa, pancreatic tissue, angiodysplasia), which may be the cause of patient's difficulties. MD is mostly asymptomatic, it manifests only in form of complications, which may be acute gastrointestinal bleeding, ileus, invagination, nausea and vomiting (mimicking gastroenteritis), diverticulitis, tumour (most often GIST - GastroIntestinal Stromal Tumour or carcinoid). The main diagnostic methods are double contrast CT scan of the abdomen and laparoscopy. MD can be an incidental finding during laparoscopic surgery, e.g.: appendectomy. Surgical treatment consists of resection of the MD, the extent of the procedure is determined by its pathology. The minimal procedure is a wedge resection, in larger lesions is necessary to perform resection of the bowel with a part of the hinge, this applies mainly in tumor involvement to preserve radicality.

**Diverticular disease of the colon** can occur in its entire length, most commonly in the colon descendens and colon sigmoideum. It is predominantly a false diverticulum, and its incidence increases with age (in 70% of people over 80 years of age). The cause is increased intraluminal pressure on the basis of a low-fibre diet, which causes mucosal extrusion between the weakened muscular layer and the formation of false diverticula. Diverticula are mostly asymptomatic and manifest only when complications occur (inflammation, bleeding, abscess, fistula, stenosis, perforation). CT scan of the abdomen and colonoscopy are the standard diagnostic procedures. The treatment of diverticulosis consists of adherence to a high-fiber diet. In symptomatic uncomplicated diverticulosis, cyclic administration of rifaximin (secondary prophylaxis) has been used in recent years.

**Diverticulitis** is an inflammation of the diverticula affecting the entire wall of the intestine and extending into the surrounding area. It is caused by stagnation of stool in diverticula, which is leading to multiplication of pathogens, pressuring of the intestinal wall and creation of decubital necrosis of the mucosa. Diverticulitis manifests by pain in the left lower abdomen sometimes even by peritoneal irritation, there may be a palpable cylindrical infiltrate. Other symptoms include fever, chills, nausea, vomiting, cessation of gas and stool output, blood in stool can be observed. Laboratory findings include leukocytosis, elevated CRP. Abdominal CT will give us a definitive answer. Differential diagnosis includes tumor, IBD, renal colic, adnexitis. We treat uncomplicated diverticulitis with parenteral antibiotics and restriction of p.o. intake with gradual transition to a low-residue diet followed by a fiber-rich diet. In case of recurrent inflammation or complications - abscess, perforation, obstruction, fistula - surgical treatment is necessary. Abscess requires drainage in addition to systemic antibiotics. In case of perforation, fistula or obstruction, acute resection of the affected part of the intestine is necessary, followed by restoration of the intestinal passage in a second period with an interval of at least 6 months. In the area of the sigmoid colon, we should consider resection of the sigmoid colon according to Harmann (closure of the aboral part of the

intestine with a stapler and construction of the terminal descendostomy / sigmoidostomy). In the case of the small bowel lesion, resection with primary anastomosis may be considered. In case of bleeding, a conservative approach with administration of haemostatic agents and blood derivatives is the first choice. In case of failure of conservative therapy we choose surgical resection. In patients with recurrent diverticulitis or post inflammatory stenosis, we consider resection with primary anastomosis at the time of calming of the inflammation (minimum interval of 8 weeks from the last attack).

## TYPES OF DIVERTICULUM



©LedvinaT24

## **INTESTINAL ISCHEMIA (28)**

Svatoň Roman

**Intestinal (bowel) ischemia** is defined as an acute or chronic, absolute or relative disorder of arterial blood supply or venous drainage of the intestine, resulting in hypoxic damage to the cells of the intestinal wall. Ischemic damage can vary from reversible microscopic damage to the mucosal epithelium to irreversible complete transmural necrosis with all its consequences. Intestinal infarction due to arterial occlusion (80–90 %) is significantly more common than that due to venous occlusion (10–20 %). Despite advances in diagnosis and treatment, the mortality rate for this condition remains high (30–80 %).

### **CLASSIFICATION**

#### **According to etiology:**

Occlusive: 85 % of all cases arise from arterial or venous mesenteric occlusion or stenosis but also due to external compression in strangulation, volvulus, or intussusception.

Non-occlusive: 15 % of all cases occur as a result of intestinal hypoperfusion and hypoxia in shock states, sepsis, hypovolemia, cardiac failure, acute myocardial infarction, arrhythmias, respiratory insufficiency, high doses of vasopressors, or rarely as a complication of tube-administered enteral feeding.

#### **According to course:**

Acute: due to arterial mesenteric embolism in atrial fibrillation (AF) or endocarditis, arterial thrombosis due to atherosclerosis, or venous mesenteric thrombosis in congenital or acquired thrombophilic states. Acute intestinal ischemia can also occur in aortic or mesenteric artery dissection or strangulation.

Chronic: arterial stenoses or chronic collateralized occlusions due to atherosclerosis, less commonly due to vasculitis, fibromuscular dysplasia, or external compression (e.g., *Dunbar syndrome* – celiac artery compression syndrome caused by the *median arcuate ligament*).

### **CLINICAL SYMPTOMS**

**Acute Intestinal Ischemia:** a sudden onset of intense abdominal pain, which may be accompanied by nausea and vomiting. In some cases, enterorrhagia occurs, or a characteristic stool with a "raspberry jelly" appearance related to the sloughing of ischemic mucosa. In the initial stages of this disease (< 6 hours), a relatively common clinical presentation is the contrast between intense, almost shock-like, subjectively perceived abdominal pain and minimal findings on physical and paraclinical examination. This persists until the development of irreversible changes in the intestinal wall and the onset of certain complications, such as *ileus*, *perforation*, *peritonitis*, or *sepsis*.

**Chronic Intestinal Ischemia:** cramp-like abdominal pain occurring 15–45 minutes after eating (*abdominal angina*), nausea, vomiting, diarrhea, or constipation, weight loss, malnutrition with cachexia, and fear of eating. Chronic intestinal ischemia often develops due to atherosclerosis, causing stenoses in the abdominal aorta and its branches, with systolic murmurs heard in their course.

## DIAGNOSIS

**CT with intravenous contrast and CT angiography (CTA)** is the gold standard in diagnosing acute and chronic intestinal ischemia. Stenoses or occlusions in visceral arteries or veins are detected. Hypoperfusion of the intestinal wall manifests on CT as reduced or absent enhancement of the affected segment by contrast agent. In venous thrombosis, edema of the wall occurs due to venous congestion. More advanced findings, indicating irreversible changes, include the presence of gas in the intestinal wall (*pneumatosis intestinalis*) (Fig. 1) or gas in the portal system (Fig. 2). In cases of intestinal perforation, pneumoperitoneum and fluid in the abdominal cavity are detected. If CTA is contraindicated (allergy to iodine contrast or renal insufficiency), an alternative is to perform **angiography using magnetic resonance imaging (MRA)**. **Digital subtraction angiography (DSA)** is currently not used as a primary diagnostic method but remains reserved as an imaging method employed in therapeutic endovascular interventions. **Endoscopic methods** such as colonoscopy and enteroscopy allow for macroscopic and biopsy assessment of mucosal changes in the intestine. **X-ray and US examinations** of the abdomen, used as first-line imaging methods for patients with suspected acute abdominal emergencies (AAE), do not allow direct evidence of intestinal ischemia. Rather, they demonstrate indirect signs, which typically develop only after a delay, often in the period of irreversible changes in the intestinal wall or as a result of complications (vascular ileus, perforation). **Doppler ultrasound** can detect occlusion or stenosis of major visceral vessels in habitually favorable patients.

In biochemical tests, we search for increases in markers of tissue hypoxia, cellular damage, thrombosis, and inflammation. Elevations may be seen in **lactate, pH, amylase, transaminases (AST, ALT), alkaline phosphatase, D-dimers, leukocytosis, interleukin-6, procalcitonin, intestinal fatty acid-binding protein (I-FABP)** and **ischemia-modified albumin (IMA)**. Unfortunately, no biomarker allows for early prediction of intestinal ischemia with sufficient sensitivity and specificity.

## TREATMENT

**Acute Occlusive Arterial Intestinal Ischemia:** this is a condition requiring urgent intervention. The goal of **surgical treatment** is early revascularization and resection of irreversibly damaged (necrotic) parts of the intestine, with sanitation of peritonitis. In the case of irreversible changes, we perform

*bowel resection*, followed by stoma creation or anastomosis construction. This procedure is always associated with the risk of developing subsequent complications, such as *short bowel syndrome*. Not always is the ischemic boundary clearly defined during the primary operation. *Intraoperative fluorescent examination using indocyanine green (ICG)* (Fig. 3) or a *second-look operation* 24–48 hours later can be used to assess bowel viability. The operation may also include a procedure on the mesenteric arteries, such as direct or indirect (using a *Fogarty catheter*) ***embolectomy or thrombectomy***.

Today, depending on availability and the patient's condition, ***endovascular treatment*** of arterial occlusion using *endovascular mechanical* (crushing of the embolus or thrombus) and *aspiration embolectomy or thrombectomy* can precede the operation. Another non-surgical option for revascularization is *local intra-arterial thrombolysis* with recombinant tissue plasminogen activator (rtPA). If atherosclerotic stenosis is identified, it can be treated with balloon *percutaneous transluminal angioplasty (PTA)*, possibly with *stent implantation*. An alternative to the aforementioned procedures is a ***hybrid approach***, combining open surgery with endovascular treatment of the arterial occlusion in a single procedure.

**Acute Mesenteric Venous Thrombosis:** in patients with mild clinical symptoms and no signs of complications, the mainstay of treatment is ***low-molecular-weight heparin (LMWH)***. In cases of clinical deterioration, selective ***endovascular treatment*** using mechanical or local thrombolysis can be considered. Severe cases – shock, sepsis, peritoneal irritation, necrosis with perforation, as well as CT signs of irreversible changes – are indications for ***surgical revision***. Fluid resuscitation, correction of electrolyte imbalances, decompressive nasogastric intubation (NGS), and broad-spectrum antibiotics (ATB) are integral parts of therapy for all acute intestinal ischemias.

**Chronic Occlusive Intestinal Ischemia:** ***conservative treatment*** is applicable for oligosymptomatic patients or as an adjunct to endovascular and surgical therapy. It involves dietary adjustments (low-residue diet), management or compensation of factors and diseases contributing to atherosclerosis (smoking, diabetes, hypertension, hyperlipidemia), antiplatelet therapy (acetylsalicylic acid, clopidogrel) primarily for arterial involvement, anticoagulant therapy (LMWH, direct oral anticoagulants – DOAC, vitamin K antagonists) primarily for venous involvement, vasodilator therapy (nitrates, pentoxifylline), and immunosuppressive therapy in vasculitis.

***Endovascular therapy*** in the form of balloon *PTA*, possibly with *stent* or *stent-graft implantation*, is indicated for symptomatic patients. There has been a shift away from primary surgical treatment. Endovascular approaches show fewer complications compared to surgical treatment, albeit with shorter long-term patency of revascularization.

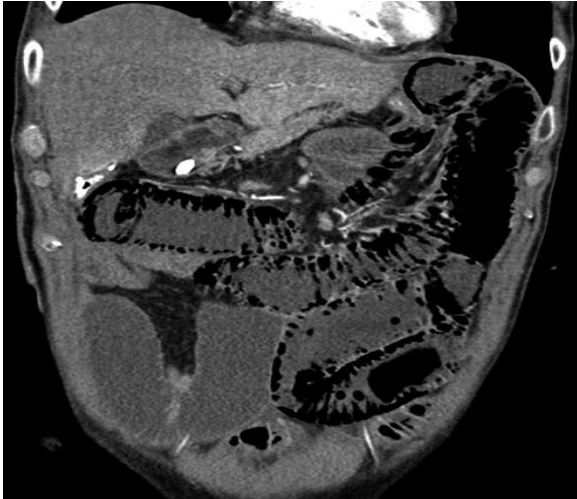**Surgical treatment** is currently indicated in cases of failure or infeasibility of endovascular treatment. Procedures performed include *bypass surgery* (connection between the abdominal aorta or common iliac artery and the SMA using a venous graft or prosthesis), *endarterectomy* (direct removal of atherosclerotic plaques) *with mesenteric artery patching*, and *surgical interruption of the arcuate ligament* in Dunbar syndrome.

**Non-Occlusive Intestinal Ischemia:** the basis of therapy for non-occlusive intestinal ischemia is the **removal or compensation of the underlying cause**. In shock states, fluid resuscitation and oxygen therapy are needed; in sepsis, infection source control and ATB; in respiratory insufficiency, mechanical ventilation. **Local intra-arterial infusion of vasodilators** (nitrates, prostaglandins, papaverine) has been successfully used to treat peripheral vasospasm. Supportive therapy includes anticoagulant and vasodilator therapy. In cases of bowel perforation, peritonitis, or poor overall condition, **surgical intervention** is indicated.

### **COMPLICATIONS**

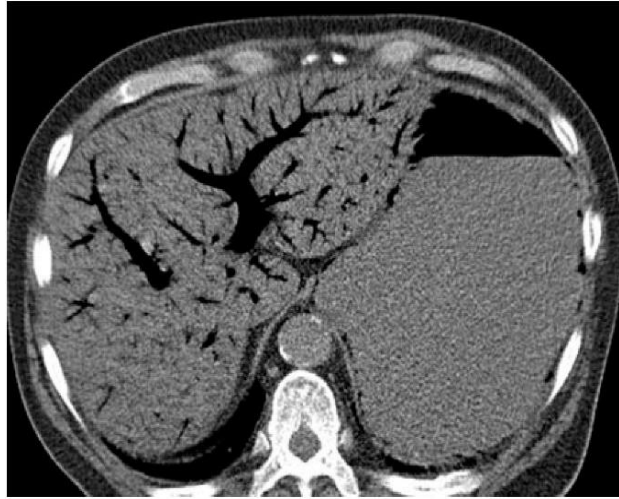
Vascular ileus, necrosis of the intestinal wall, sometimes to an extent incompatible with long-term survival, disruption of the mucosal barrier with translocation of bacteria and toxins into the bloodstream and abdominal cavity, bowel perforation, peritonitis, sepsis, multiorgan failure, and death. Short bowel syndrome, chronic fibrosis of the intestinal wall with the development of strictures and intestinal fistulas, and recurrence of acute intestinal ischemia.

**FIGURES:**



**Fig. 1: Pneumatosis intestinalis, CT**

(Albrecht HC, Trawa M, Gretschel S. Nonocclusive mesenteric ischemia associated with postoperative jejunal tube feeding: Indicators for clinical management. *J Int Med Res.* 2020;48(8):300060520929128. doi:10.1177/0300060520929128)



**Fig. 2: Portal venous gas, CT**

(Ko S, Hong SS, Hwang J, Kim HJ, Chang YW, Lee E. Benign versus life-threatening causes of pneumatosis intestinalis: differentiating CT features. *Rev Assoc Med Bras (1992).* 2018;64(6):543-548. doi:10.1590/1806-9282.64.06.543)



**Fig. 3: Absence of jejunum enhancement during ICG fluorescence examination**



## PERITONITIS (27)

Vystrčilová Tamara

**Peritonitis** is an inflammation of the peritoneum, the tissue that lines the inner wall of the abdomen and covers and supports most of the abdominal organs. Localised or diffuse peritonitis is caused by:

**Bacteria:** G+ (pneumo-, gono-, streptococci – mainly primary peritonitis), G– (colibacillary – mainly secondary peritonitis)

**Chemically toxic substances:** stomach contents, blood, pancreatic juice, bile, urine, chyle

### **Types of Peritonitis:**

#### **By origin:**

**1) Primary** – Haematogenous or lymphogenous (e.g., pneumonia, tonsillitis), more common in immunosuppressed individuals or via ascending infections through female genitalia, mostly G+ mono-infection (i.e. without primary involvement of an intra-abdominal organ).

*Spontaneous bacterial peritonitis* (SBP) can develop from ascites and is rarely haematogenous. It occurs commonly in patients with decompensated cirrhosis, especially in ascites with a protein content < 10 g/l. Bacteria from the intestine are the most common cause, with *Escherichia coli* being predominant.

**2) Secondary** – Due to transition from an inflamed organ (e.g., complications of intra-abdominal disease or injury):

a) **Per continuitatem** (by continuity - peritonitis from neighbouring spread) – mesenteric occlusion, ileus, toxic megacolon

b) **Perforation** – e.g., appendicitis, cholecystitis, diverticulitis, gastric or duodenal ulcer, bowel perforation, trauma

c) **Chemical** – Sterile peritonitis (due to bile, blood, etc.) that is clinically indistinguishable from bacterial peritonitis; the treatment is the same.

**3) Postoperative** – E.g., anastomotic leakage (the most common postoperative cause); for elective procedures, incidence should be below 2%.

**4) Special types** – TB peritonitis, plastic peritonitis (after irradiation), dialysis-related peritonitis, and spontaneous peritonitis (from ascites infection).

\* *Some authors accept the term “tertiary peritonitis” – occurring after removal of the organ causing secondary peritonitis or after abscess rupture.*

#### **By causative agent:**

1) Microbial

2) Aseptic

**By anatomical boundaries:**

- 1) Circumscribed peritonitis (*peritonitis circumscripta*)
- 2) Diffuse peritonitis

**By time course:**

- 1) Acute peritonitis
- 2) Chronic peritonitis (e.g., intra-abdominal abscesses, tuberculosis, plastic peritonitis)

**Pathology:** Peritonitis is most often sero-fibrinous, purulent, or stercoral.

**Pathophysiology:**

The peritoneum is a large surface area allowing the absorption of bacterial toxins and secretion of inflammatory exudate with fibrinogen, leading to fluid leakage into the third space (resulting in hypovolaemia and electrolyte imbalance) and formation of localised inflammatory foci.

In response to bacterial, chemical, or traumatic damage to the peritoneum, vasoactive substances are released, causing vasodilation and exudation, fibrin plaque formation, and the containment of inflammation. However, this also leads to the absorption of exo- and endotoxins, triggering a systemic inflammatory response (with TNF and IL produced by the liver). This process increases capillary permeability, reduces peripheral vascular resistance, enhances blood coagulation, and negatively affects the function of vital organs, potentially leading to MODS (multiple organ dysfunction syndrome).

Inflammation peaks on the third day after perforation; without treatment, the patient typically dies within a week from cardiorespiratory failure due to sepsis and toxemia.

The mortality rate of diffuse bacterial peritonitis is reported to be 10–30%.

**Clinical examination:****Local symptoms:**

Somatic-type pain with guarding; sudden onset in cases of perforation, gradual in other cases.

Pain may radiate to the shoulder (phrenic symptom – pneumoperitoneum, subphrenic abscess).

Palpable tenderness and muscle guarding (may lessen later); abdominal distension with dilated bowel loops (ileus).

Plenies, Blumberg, and Rovsing signs (peritoneal irritation signs).

Absent respiratory movement and bowel sounds (paralytic ileus – "dead silence" in the abdomen).

Rectal tenderness and sphincter relaxation.

A temperature difference of more than 1°C between the axilla and rectum (Lennander's sign).

**General symptoms:**

Nausea, vomiting (initially reflexive, then due to bowel paralysis), absence of stool and gas. Decreased BP, increased HR, increased temperature, tachypnoea, oliguria/anuria (shock symptoms), pallor, sweating, dry tongue.

In severe cases, late-stage symptoms may include *facies Hippocratica* (sunken eyes, sharp nose, sunken cheeks, sticky sweat) and septic encephalopathy (delirium).

**Diagnostics:**

Medical history and clinical examination.

Laboratory tests: Full Blood Count - FBC (↑leucocytes, ↑CRP), liver function tests - LFTs (↑bilirubin and transaminases), amylase, acid-base imbalances (e.g., metabolic acidosis, respiratory alkalosis, ↑lactate, ↓pO<sub>2</sub>, ↓pCO<sub>2</sub>).

**Imaging:**

Ultrasound: Free fluid in the abdomen or abscess, with ultrasound-guided puncture for microbiological and biochemical analysis.

X-ray: Pneumoperitoneum (indicative of perforation).

CT scan: The gold standard method for evaluating acute abdomen conditions.

Endoscopy: For suspected perforated ulcers if clinical and X-ray findings are unclear.

**Treatment:**

**Four main principles:**

Control the source of infection.

Eliminate bacteria and toxins.

Maintain organ function.

Control the inflammatory response.

**Specific interventions include:**

Venous access with infusion (Hartmann's solution).

Stabilisation of vital functions (maintain urine output > 0.5 ml/kg/hour).

Broad-spectrum antibiotics, later adjusted based on sensitivity testing (take a swab or blood culture perioperatively).

NG tube and urinary catheter (or puncture epicystostomy if needed).

Special procedures (e.g., NPWT for temporary abdominal closure if repeated access is needed).

Early enteral feeding and immune support for prolonged septic symptomatology.

**Surgical intervention:**

The indication is developing clinical symptomatology – worsening pain and defences, ↑ TF and ↓ BP despite intensive therapy, X-ray evidence of pneumoperitoneum, ultrasound evidence of free fluid with exclusion of ascites in liver cirrhosis and AP.

It includes laparotomy or laparoscopy for infection source control (e.g., appendectomy, cholecystectomy, ulcer repair, resection of the stomach and hemicolectomy in perforated malignancies, resection of the small intestine, e.g. in Crohn's disease, Hartmann resection in perf. diverticulitis, etc.), suture perforation (GD ulcer, bowel perforation,...), stoma construction, especially in colon malignancies, necrectomy, lavage and drainage in AP.

**Complications of Peritonitis:**

Possible complications include dehydration, ileus, hepatorenal syndrome, sepsis, septic shock, multiple organ failure, and death.

## **ILEUS (29)**

Csölle Jakub

### **1. Definition**

Ileus, or intestinal obstruction, is a form of acute abdomen where the passage of contents through the gastrointestinal tract is halted. This condition can be mechanical or functional. In mechanical ileus, a physical blockage occurs in the intestinal passage, while in functional ileus, the movement of intestinal content is impaired due to a disruption in intestinal motility.

**2. Classification and Causes of Ileus States:** Ileus conditions can be divided into three categories:

#### **Mechanical Ileus:**

**Adhesions (scar tissue):** Formation of fibrous adhesions or bands between the intestines or other organs and structures within the abdominal cavity can cause narrowing or strangulation of the intestine. Adhesions typically arise after surgeries or inflammation within the abdominal cavity. This is the most common cause of small bowel obstruction.

**Tumors:** Benign or malignant tumors obstructing the intestinal lumen. The most common cause of obstruction in the large intestine.

**Hernias:** Intestinal loops may become strangulated in hernia openings, leading to ileus.

**Volvulus:** Twisting of an intestinal loop around its axis, causing mechanical blockage.

**Intussusception:** Part of the intestine telescopes into itself, often due to a polyp being pulled by peristalsis.

**Gallstone Ileus:** A large gallstone enters the gastrointestinal tract through bile ducts or erodes from the gallbladder into the intestinal lumen via a chronic biliodigestive fistula.

#### **Swallowed Foreign Objects.**

**Neurogenic Ileus:** No physical obstruction is present, but the intestine cannot perform normal peristalsis.

**Paralytic (functional) Ileus:** Absence of peristalsis, which may occur after surgeries, infections, injuries, or metabolic disturbances such as electrolyte imbalances.

**Spastic Ileus:** A pathological spasm of the intestine, a rare form of ileus, seen in conditions affecting the CNS or lead poisoning.

**Vascular Ileus:** Occurs due to ischemic bowel disease, where blood circulation in mesenteric vessels is impaired. This can be caused by:

**Thrombosis or Embolism of Mesenteric Vessels:** A blood clot blocks the arteries supplying the intestine, leading to an interruption of blood flow.

**Insufficient Blood Flow:** Caused by shock, heart failure, dehydration, or septic states.

**3. Pathophysiology** Significantly depends on the type of ileus and the location of the blockage.

**Small Bowel Ileus:** The bacterial colonization of the small bowel is typically low. With impaired passage, bacterial overgrowth occurs, leading to hypersecretion from the mucosa and increased blood flow to the intestinal wall. Even with significant small bowel dilation, the intestinal wall's blood flow remains intact.

**High Small Bowel Ileus:** The obstruction is in the jejunum. The patient is primarily at risk of severe fluid and electrolyte loss, leading to hypovolemia and electrolyte imbalance.

**Low Small Bowel Ileus:** The obstruction is in the ileum. Stagnation of intestinal contents leads to bacterial overgrowth, mucosal hypersecretion, disruption of the mucosal barrier, and subsequent bacterial translocation. Systemic inflammatory response syndrome (SIRS) and organ dysfunction develop.

**Large Bowel Ileus:** Significant distension of the large bowel, with increasing intraluminal pressure, leads to impaired blood supply to the bowel wall, ischemia, and eventually perforation. Unlike small bowel ileus, mucosal hypersecretion and bacterial translocation do not play a major role.

**Bowel Ischemia:** Rapidly progresses to gangrene of the entire intestinal wall, followed by the development of SIRS and multi-organ failure (MOF).

#### **4. Clinical Symptoms**

**Abdominal Pain:** Usually colicky, more common in mechanical ileus. In paralytic ileus, the pain may be less pronounced.

**Abdominal Distension and Bloating:** Intestinal content accumulates, causing tension in the abdominal wall. In high small bowel ileus, distension may not be evident.

**Vomiting:** Common, especially with obstructions in the upper gastrointestinal tract. It may become fecal in prolonged obstruction. In large bowel ileus with a competent Bauhin's valve, vomiting may be absent.

**Absence of Stool and Gas:** A typical sign, indicating halted bowel activity. In cases of obstruction in the proximal bowel, stool passage may continue until the large intestine is emptied.

**Deterioration of General Condition:** Dehydration, electrolyte imbalances, hypotension, tachycardia, and shock may occur in untreated ileus.

**5. Diagnosis** The diagnosis of ileus conditions is complex and involves various methods:

**Clinical Examination:** Identifying typical symptoms (see above). Auscultation of the abdomen may reveal hyperactive bowel sounds in mechanical ileus or absent sounds in paralytic ileus. Key history elements include previous abdominal surgeries, malignancies, or inflammatory bowel diseases.

### **Imaging Methods:**

**Abdominal X-ray:** Shows dilated bowel loops and fluid levels.

**CT Scan:** The most accurate method for determining the level of obstruction and, often, its cause.

Contrast-enhanced CT is not always necessary.

**Ultrasound:** Mainly used in unclear cases and in children.

**Laboratory Tests:** Blood tests can reveal dehydration, electrolyte imbalances, or signs of inflammation.

**6. Treatment** Treatment of ileus conditions depends on the cause and severity:

**Conservative Treatment:** Mainly for functional ileus, involving bowel rest (nothing by mouth), nasogastric tube decompression, fluid and electrolyte replacement, and medications to stimulate peristalsis (for paralytic ileus).

**Surgical treatment:** If a mechanical obstruction is present, surgery is often necessary, but the indication must be carefully considered, for example, in patients after multiple abdominal operations, where any further intervention may result in the development of significant complications, up to abdominal catastrophe. The type of surgical procedure depends on the etiology of the ileus, which is often only discovered during the procedure itself. Among the most common are: **Adhesiolysis** - release of adhesions. **Resection** of a part of the intestine that is obstructed, for example, by a tumor, a chronic inflammatory process, or is affected by irreversible ischemic changes. Based on the patient's current condition and intraoperative findings in the abdominal cavity, it is necessary to decide whether the procedure will be performed with the restoration of GIT continuity (anastomosis) or with the establishment of an intestinal outlet (stomy). Volvulus **derotation, reposition** of the invaginated part of the intestine, hernia reposition. Bowel opening - **Enterotomy/colotomy**, with extraction of an obstruction blocking the passage, eg bulky gallstone, swallowed foreign body. The surgical approach is in most cases openly from laparotomy. Exceptionally, especially in patients without a history of numerous abdominal surgeries, a minimally invasive laparoscopic approach can be used.

**8. Prognosis** The prognosis for patients with ileus depends on the speed of diagnosis and treatment. Mechanical ileus often requires urgent surgery to prevent irreversible changes. In paralytic ileus, the prognosis is generally favorable unless complications like aspiration and ARDS arise.

## **HERNIAS OF THE ANTERIOR ABDOMINAL WALL, DIAPHRAGMATIC HERNIAS (11)**

Prudius Vadim

Hernia is a condition in which an organ (or organs) pathologically shifts from its natural position.

**Etiology.** The most common causes of hernias include increased intra-abdominal pressure, prostate hyperplasia, hormonal changes associated with menopause and andropause, excessive physical exertion, abdominal surgeries, congenital defects, and other genetically determined conditions.

**Symptomatology.** A patient with a hernia may not feel any discomfort (asymptomatic hernia), or may experience a wide range of symptoms (symptomatic hernia). The most common reason for seeking medical attention is the sensation of pressure and burning at the site of the hernia. Other symptoms may include pain, itching at the site of the hernia, digestive issues, and psychosocial factors (cosmetic defects, sexual dysfunction). A patient with an asymptomatic hernia may live without any issues for several years. However, the risk (and potential complication) of any hernia is incarceration (incarceratio). Incarceration is considered an acute surgical condition and falls under the category of acute abdominal emergencies. It is characterized by severe pain, a hard, extremely painful mass at the hernia site, and in cases involving a portion of the digestive tract, symptoms like bowel obstruction, vomiting, and other signs related to an ileus condition (see the relevant chapter). **Caution!** In elderly patients, an incarcerated hernia may present without typical symptoms due to reduced pain sensitivity. The first signs may instead be symptoms of a developed ileus condition.

**Diagnosis.** Most abdominal wall hernias can be diagnosed through a clinical examination of the abdomen. A key diagnostic maneuver is the Valsalva maneuver. Naturally, a thorough medical history is essential, particularly for educating the patient and preventing recurrence. Ultrasound also plays an important role, especially in unclear cases and for confirming femoral, recurrent, and incisional hernias. Standard imaging methods like CT and MRI are typically not used for diagnosing inguinal and umbilical hernias. However, CT scans may be used for large ventral hernias to assess the abdominal wall defect and the technical feasibility of its repair (discussed further in the section on preparation for surgery).

**Differential Diagnosis.** In the differential diagnosis of femoral hernias, it is important to consider lymph node syndromes, especially in elderly women. Inguinal hernias need to be distinguished from tumors, most commonly lipomas. Small umbilical hernias should be differentiated from inflammatory processes or small lipomas. The primary tools for differentiation are ultrasound and, if necessary, CT scans. For diaphragmatic hernias, conditions like achalasia or esophageal tumors (including MALT lymphomas) should also be considered.

**Classification of Hernias.** By location: External, Internal. By origin: Congenital hernias (herniae



congenitae). Acquired hernias (herniae acquisitae). By the presence of a sac: True hernias (with a hernial sac present), false hernias (without a hernial sac). By reducibility: Freely reducible (hernia libera), Irreducible, Incarcerated hernia (hernia incarcerata), Elastic incarceration (incarceratio elastica), Fecal incarceration (incarceratio stercoracea), Incarceration "in W", Adhesions between the sac and hernia contents (hernia accreta). Large hernia (hernia permagna). Richter's hernia – Incarceration of part of the intestinal wall while preserving bowel passage (temporarily). Littre's hernia – Incarceration of Meckel's diverticulum. By location: Abdominal hernias: Inguinal/scrotal, umbilical, epigastric/supraumbilical, supravesical, femoral, obturator, perineal, sciatic, incisional, parastomal

Diaphragmatic hernias: Sliding, paraesophageal (including upside-down stomach), Bochdalek hernia, Lorei's hernia. Post-traumatic (after thoracic and cardiac surgeries). Internal hernias

Classification. In herniology, the classification system of the European Hernia Society is commonly used today.

Worldwide incidence of hernias. Inguinal hernias: 75% (♂:♀ 7:1), of which 75% are indirect. Umbilical hernias: 5-14%. Incisional hernias: 10%. Femoral hernias: 3-5%.

Anatomy of hernias. Hernial opening, hernial sac, hernial contents.

Patient preparation for surgery. For the vast majority of small hernias, standard preoperative preparation is sufficient. Special preparation is required for large ventral hernias, for which we use CT scans, as mentioned above. In cases of fistulization in the area of the hernial defect with the presence of mesh from previous surgery, an MRI is advisable. This is mainly to measure the amount of free tissue needed to close the defect. For obese patients, weight reduction is recommended, which decreases intra-abdominal volume and increases the amount of usable tissue for closing the defect (altering the ratio between abdominal wall area and intra-abdominal volume). In many centers, Botox is used for this purpose, applied to the abdominal muscles under ultrasound guidance.

Hernia surgery. The effectiveness of each procedure is evaluated based on recurrence rates and postoperative complications. Minimally invasive procedures are preferred today, as they have lower recurrence rates and fewer complications compared to traditional methods. Patients also tolerate them better, and they shorten hospital stays.

Inguinal hernia surgery. Traditional methods. Without mesh (McVay, Shouldice, Bassini). With mesh (Lichtenstein). Minimally invasive methods. Laparoscopic - TEP (totally extraperitoneal approach), TAPP (transabdominal preperitoneal approach), TOM (transabdominal onlay mesh, rarely used today).

To choose the correct approach for a patient, factors such as age, physical activity, comorbidities, previous surgeries, and prostate issues in men should be considered. For younger, otherwise healthy

patients, a minimally invasive transabdominal approach like TAPP or TEP is often advantageous. Statistically, TEP has a slightly lower incidence (a difference of just a few per mille) of postoperative and perioperative complications but does not allow for simultaneous correction of bilateral inguinal hernias or abdominal organ revision, unlike TAPP. For larger defects, a traditional approach, most often Lichtenstein, is preferred. In case of inguinal hernia recurrence, the next step depends on the type of the previous surgery. For example, if the first surgery was traditional, a laparoscopic approach is preferred for recurrence and vice versa.

**Femoral hernia.** In femoral hernias, abdominal or pelvic organs pass beneath the inguinal ligament through the femoral canal. This type of hernia occurs far less frequently than inguinal hernias, at a ratio of 1:30. It is very rare in children and young adults, affecting primarily older women. About 50% of patients with femoral hernias present with incarceration, often with a parietal strangulation (Richter's hernia). For elective procedures, TAPP is preferred, while in emergency situations, laparoscopy is considered to assess the viability of the bowel loop, or the procedure is performed via traditional surgery.

**Umbilical hernia:** typically appears after the third decade, predominantly in women (80%). They account for about 5-10% of all hernias. Most are small defects, so, as mentioned, Mayo repair is primarily used. For hernias larger than 4 cm or recurrent umbilical hernias, procedures such as MILOS, eMILOS, or eTEP may be considered.

**Ventral hernia surgery.** For smaller defects, the patient's own tissues are preferred. The most commonly used method is Mayo repair. However, the defect often cannot be closed without tension using only native tissues. In such cases, mesh or extensive plastic surgery using the tissues of the anterior abdominal wall is used. Component separation of the anterior abdominal wall is not uncommon. The procedures can be divided into anterior and posterior approaches. In practice, anterior separation means separating the subcutaneous tissue, fascia, and oblique muscles, while posterior separation involves separating the peritoneum, posterior sheath of the rectus muscles, and transverse muscles. A combination of separation and the use of xenograft materials is also possible.

**Anterior component separation:** Ramirez's procedure is a typical example of anterior separation, used to close defects after "open abdomen" or in recurrent large ventral hernias. Currently, traditional Ramirez anterior component separation is being replaced by the minimally invasive eACS (endoscopic anterior component separation).

**Posterior component separation:** TAR (Transversus Abdominis Muscle Release) has two main variants: Novitsky's operation, which gradually separates the transverse fascia from the subcostal space caudally, or reverse TAR (Spanish TAR). This procedure is primarily aimed at enlarging the

area of the anterior abdominal wall. It can be performed openly, minimally invasively (eTAR), or robotically (rTAR). It is often combined with Rives-Stoppa surgery.

Rives-Stoppa operation uses posterior separation with mesh and is chosen for recurrent ventral hernias, incisional hernias, or multiloculated hernias along the midline.

MILOS surgery for large umbilical hernias or recurrent ventral hernias is a minimally invasive alternative to ventral repair with mesh. It has been gaining popularity due to a lower recurrence rate (2.2-2.4%). The improved version, eMILOS, is the endoscopic variant.

eTEP has almost the same indications as MILOS surgery but uses a completely endoscopic approach with three or more ports, usually positioned in the lower abdomen.

Robotic hernia surgeries: Recently, large abdominal wall defects, including parastomal and hiatal hernias, are increasingly being addressed robotically in Europe.

Traction methods: This procedure involves intraoperative traction of the abdominal wall defect edges. Traction time varies from 10 to 30 minutes, and the total force ranges from 8 to 18 kg. It is intended for closing large ventral defects and is usually combined with the Rives-Stoppa procedure.

Internal hernias: occur when abdominal organs are pushed into preformed recesses on the posterior wall of the peritoneal cavity, mesentery, or mesocolon. They are not true hernias, as the hernial sac does not protrude outside the abdominal wall. Internal hernias are rare and are most commonly diagnosed during surgeries for bowel obstruction or incidentally during open abdominal surgeries.

Diaphragmatic hernia. Hiatal hernia occurs when part of the stomach passes through the diaphragm into the chest, most often the cardia (upper stomach) through the esophageal hiatus. In extreme cases, the entire stomach may enter the chest. If only the stomach passes without a hernial sac and the angle of His is absent, it is called a sliding hernia. The main complication is gastroesophageal reflux. If the hernial sac is formed and the gastroesophageal junction remains in the abdominal cavity, it is a paraesophageal hernia. Complications include venous stasis with bleeding, ulcers of the distal esophagus, necrosis with perforation due to strangulation, obstruction with passage disorder (high ileus), and compression of intrathoracic structures (heart, lungs).

## SMALL BOWEL AND LARGE BOWEL NEOPLASMS (37)

Svoboda Martin, Grolich Tomáš, Procházka Vladimír

**Small bowel tumours** are rare and occur in less than 10% of all GIT tumours. The majority of small bowel tumours are **benign tumours** including adenomas, lipomas and haemangiomas. They are usually asymptomatic and manifest most often with ileus, intussusception or bleeding, which is either acute or chronic, expressed by anaemia. Although CT scanning is the method of choice (e.g., in the case of obstruction, the radiologist will describe the so-called transition zone on the bowel where the dilated section transitions to the collapsed section and, in the best case, the possible etiology of the obstruction), if the neoplasia causes anemia, the diagnosis is difficult and the CT scan may be equivocal. Small bowel examination is generally difficult and capsule endoscopy or small bowel endoscopy can be used for diagnosis. Symptomatic lesions are treated by resection of the affected section with construction of an anastomosis. **Malignant tumours** of the small intestine are rare, diagnosed late and usually manifest with obstruction. The following 4 types of tumors are responsible for 99% of small bowel malignancies. **Adenocarcinoma** is more common in the jejunum than in the ileum. Patients with m. Crohn's disease (CD), celiac disease, familial adenomatous polyposis (FAP) are more likely to be affected. Clinically, it manifests either by obstruction, invagination, anaemia or acute bleeding. The prognosis is poor, especially in patients with CD, due to late diagnosis, because of similar clinical manifestations. The method of treatment is surgical resection of at least 5 cm on each side of the tumor, including the appropriate section of the relevant part of the mesentery where the lymph nodes are located. For terminal ileal tumours, ileo-cecal resection or right-sided haemicolectomy is an adequate procedure. **Neuroendocrine tumors** (NETs, carcinoids) occur most frequently in the appendix, then in the ileum. Metastases to the lymph nodes may be larger than the primary tumor, which is usually small. NETs produce vasoactive peptides, most commonly serotonin. Liver metastases may manifest with carcinoid syndrome because the vasoactive substances are not filtered through the liver and enter the systemic circulation. Radiopharmaceuticals - somatostatin analogues - are used to image NETs (NETs often have receptors for somatostatin), and chromogranin A is detected in plasma, which can be used to monitor recurrence and prognosis. Surgical resection of NETs is usually sufficient; tumours are not sensitive to chemotherapy and radiotherapy. Patients with carcinoid syndrome (diarrhea, bronchospasm, flush, palpitations) are given somatostatin analogues during surgery to prevent carcinoid crisis. NETs grow slowly, and even patients with metastatic disease may live for several years. Small bowel **lymphomas** are most often secondary to systemic lymphoma. They are more common in patients with CD and immunodeficiency. They present with pain, weight loss, inappetence, fatigue, diarrhea,

tenesmus and acute conditions. They often occur in the region of the ileo-cerebral transition (Burkitt's lymphoma). Chemotherapy is the method of treatment. Surgical treatment is performed in the case of an acute condition of obstruction, perforation, hemorrhage, or the need for histological verification not otherwise obtainable. **Gastrointestinal stromal tumors** (GISTs) are mesenchymal tumors and the distinction between malignant and benign is difficult even on histopathological examination. Malignant potential is determined by tumor size and the degree of immunohistochemical c-kit (CD117) staining. They are most commonly found in the stomach. It is often asymptomatic and is diagnosed incidentally. It presents with fatigue, pain, nausea, haematemesis or melena. GIST is resistant to radiotherapy and conventional chemotherapy. Surgery is the most effective method of treatment and its principle is to remove the lesion without breaking its wall and without the need for lymphadenectomy or extensive resection. The tyrosine kinase inhibitor imatinib (Glivec) is used in adjuvant therapy.

**Colorectal cancer (CRC)** includes adenocarcinoma of the colon and rectum. The incidence in the Czech Republic is around 7000 cases per year and half die from it. Despite the established screening, there is still a very high proportion of patients diagnosed in the later stages of the disease (stages III and IV), which reduces the chances of a good treatment outcome and decreases survival. Hereditary forms include Lynch syndrome and FAP. Sporadic occurrence of up to 90% predominates. One of the important molecular characteristics of CRC is the detection of microsatellite instability (MSI) of the tumor (in about 15% of CRC), determined by immunohistochemistry from biopsy.

Immunotherapy can be used in MSI tumours, which allows significant regression of the tumour, or its complete disappearance (up to 90%) with avoidance of surgery and its possible complications. From the point of view of CRC management, it is necessary to strictly divide tumours into tumours of the colon and rectum. **Appendiceal tumours** are usually detected incidentally on histological examination and occur in 1% of appendixes removed. The most common tumours are epithelial adenocarcinomas, mucinous neoplasms and neuroendocrine tumours. Because of the oncological radicality, it is often necessary to perform a right-sided hemicolectomy after appendectomy. Patients with mucinous neoplasms are at risk of developing pseudomyxoma of the peritoneum; for this reason, during appendectomy when a mucinous tumor is suspected (mucocele), the mucin must not leak into the free abdominal cavity (dissemination). **Colon tumors** manifest differently depending on the localization. Up to 20 % of them present **acute abdomen** (obstruction, perforation, bleeding). Right-sided tumours usually do not present with obstruction, but more often with anaemia because the tumour grows long and bleeds slowly. On the other hand, left-sided tumours often present with ileus. In acute conditions, the priority is to save the patient's life, remediate sepsis and allow a good recovery after surgery for subsequent oncological treatment. Perforation leads to peritonitis

(mortality up to 65%) and the most common solution is to perform resection of the perforated colon with stoma creation. The construction of an anastomosis is very risky in the field of severe sepsis due to dehiscence. In case of left colonic obstruction, Hartmann's operation (resection with terminal colostomy), axial colostomy derivation or endoscopic stent insertion is possible. The last two options are based on resolving the ileus at the first time (simple procedure to stabilize a patient) and planning a radical resection with a few days' interval at the second time. Obstruction of the right colon is more often resolved by primary resection with ileo-transverse anastomosis. Before **elective surgery**, each patient must be properly examined (staging). Colonoscopy is used for biopsy, to exclude synchronous lesions and to localize the tumor (tattooing). High levels of oncomarkers (CEA) tend to be present in metastatic disease. CT of the abdomen, pelvis and chest is the primary imaging modality to exclude metastases, which occur in up to 20% of patients. The liver is most commonly affected (17%), followed by the peritoneum, lungs and lymph nodes (LU). Colonoscopic removal is sufficient for early pTis cancers, but only if risk factors are not present in pT1 (vascular invasion, grade 3, tumour budding > 1 - risk of lymph node metastasis). Treatment is sequenced as tumour resection followed by adjuvant therapy, neoadjuvant therapy is not routinely used for colon tumours. The goal of **surgical treatment** is radical resection (removal of the tumor) with lymphadenectomy, i.e. R0 resection. The basic principles include resection of the tumor with sufficient resection margins (at least 10 cm), respecting the vascular and lymphatic supply of the columns. For tumors of the right colon, a right-sided hemicolectomy is performed (resecting the terminal ileum and the oral third of the colon transversum, ligating the a. ileocolica, a. colica dextra, and the right branch of the a. colica media at the origin) with construction of an ileo-transverso anastomosis. In tumors of the hepatic flexure and the oral part of the transversum, an extended right-sided hemicolectomy can be performed. In tumors of the middle part of the transversum, segmental resection with ligation of the a. colica media with a colic-colic anastomosis is performed. In the case of tumors of the left colon, ligation of the a. mesenterica inferior is performed; in the case of tumors of the colon sigmoideum, the a. mesenterica inferior can be ligated distally to the a. colica sinistra to leave a blood supply for the colon descendens. A descendento-rectal anastomosis is performed. Removal of the entire colon leaving the rectum is called subtotal colectomy (e.g. in FAP) and proctocolectomy is removal of the colon including the rectum. Continuity is restored by ileo-pouch anal anastomosis, the pouch being a reservoir formed from the ileum. Colorectal surgery is burdened with a high morbidity rate of up to 40 % and a mortality rate of 5 %. The most feared complication is anastomotic leak, the disintegration of the anastomosis. It occurs several days after surgery and can result in peritonitis and sepsis.

**Tumours of the rectum** are often manifested by bleeding or a change in the pattern of defecation. In addition to the above diagnostic methods, rectoscopy is used and MRI of the pelvis is an essential imaging method to determine the exact extent of the tumour and other risk factors: whether the tumour extends into the mesorectal fascia (MRF), whether there is involvement of the nodes, invasion of the mesorectal vessels. The treatment strategy depends on the height of the tumor in the rectum and the presence of risk factors on staging MRI. In case of acute obstruction, the first procedure is a derivation stoma. For oral rectal tumors (10-15 cm from the anus), primary resection is usually performed (they are treated more like colonic tumors). For tumours of the mid (5-10 cm) and distal rectum (0-5 cm), neoadjuvant treatment (NAT) is often started on the basis of staging, which includes chemoradiotherapy (usually 5 weeks) or in combination with additional chemotherapy (usually 18 weeks). This is followed by radical resection of the rectum with total mesorectal excision (TME). The aim of TME is to remove the rectum with the surrounding mesorectum containing the LU in their entirety without disturbing the MRF. If the MRF and mesorectum are damaged during surgery there is a higher risk of local recurrence in the pelvis. If the tumor infiltrates the sphincters, rectal amputation is usually indicated. Sometimes, however, these patients may experience tumour disappearance after NAT, a so-called complete response. These patients are then closely monitored (Watch and Wait strategy) with repeated MRI, rectoscopy and p.r. examinations and may be spared radical resection. Standard rectal resection is performed laparoscopically, robotically and possibly transanally. Because of inferior blood supply to the anus, AL often occurs after rectal resection when the tract is connected to the anal canal. For this reason, in rectal resection after the construction of a low-lying anastomosis in the pelvis, a protective ileostomy with diversion of the passage is performed to allow the anastomosis to heal and the consequences of AL are not severe. In addition to the complications described above, another specific feature of rectal tumors is the possibility of perioperative damage to the nerves of the bladder, sphincters and genital organs and the resulting postoperative dysfunction. Adjuvant therapy is administered only selectively according to the results of definitive histology. The entire management of rectal cancer is decided by a multidisciplinary team.

## **INFLAMMATORY DISEASES OF SMALL BOWEL AND THEIR SURGICAL MANAGEMENT (34)**

Vlček Petr

### **Surgical Inflammations of the Small Intestine**

**Introduction** - Inflammatory diseases of the small intestine, including its diverticula, represent a smaller group of pathological conditions of various etiologies, but they can lead to serious complications such as obstruction, perforation, or peritonitis.

#### **1. Crohn's Disease**

**Etiology and Pathophysiology** - Crohn's disease is a chronic disease that belongs to the group of non-specific inflammatory bowel diseases. It can affect any part of the gastrointestinal tract, most commonly the ileum. The exact etiology is unknown, but it is believed to involve genetic predisposition, systemic immune dysfunction, and environmental factors.

**Clinical Presentation** - Crohn's disease presents with a wide range of symptoms, including abdominal pain, chronic diarrhea, weight loss, and anemia. A typical finding is segmental granulomatous inflammation throughout the entire thickness of the bowel wall, which can lead to strictures, fistulas, and abscesses.

**Diagnosis** - Diagnosis is based on medical history, clinical examination, and endoscopy, supplemented by histopathological examination. Imaging methods such as magnetic resonance enterography (MRE) or CT enteroclysis are useful for assessing the extent and activity of the disease, often showing characteristic skip lesions.

**Surgical Treatment** - Surgery is indicated for complications like obstruction, perforation, abscesses, or fistulas. The most common procedure is resection of the affected bowel segment with primary anastomosis. Surgical treatment should be coordinated with gastroenterologists. Abscesses are often best treated by interventional radiology, followed by resection after infection treatment. The most common surgery is ileocecal resection, primarily for stenosis resistant to conservative therapy. A laparoscopic approach with intracorporeal or extracorporeal anastomosis is preferred. A wide side-to-side anastomosis is favored, and stapling devices are not contraindicated. Recently, the KONO-S anastomosis, a wide end-to-end anastomosis using colonic (entero)plastic techniques, has become popular. Robotic systems are useful for performing this procedure intracorporeally. Strictureplasty can be used for additional skip lesions.

#### **2. Ischemic Enteritis**

**Etiology and Pathophysiology** - Ischemic enteritis occurs due to inadequate blood supply to the small intestine, leading to reactive changes. The most common causes include embolism, mesenteric vessel thrombosis, low cardiac output, or hypotension.



**Clinical Presentation** - Patients typically present with sudden, severe abdominal pain. Other symptoms may include diarrhea, bloody stools, and fever. Advanced ischemia can lead to bowel necrosis and perforation.

**Diagnosis** - Fast diagnosis is crucial for successful treatment. Key diagnostic tools include CT angiography to detect mesenteric vessel occlusions and laboratory tests showing elevated inflammatory markers and lactate levels.

**Surgical Treatment** - If bowel necrosis occurs, immediate surgery is required, usually involving resection of the affected segment with anastomosis. If diagnosed early, revascularization procedures such as embolectomy or bypass may be considered to restore bowel blood flow.

### **3. Radiation Enteritis**

**Etiology and Pathophysiology** - Radiation enteritis arises as a complication of radiation therapy, where ionizing radiation damages intestinal mucosal cells, leading to inflammation, fibrosis, and strictures. Chronic radiation enteritis can develop months to years after radiotherapy.

**Clinical Presentation** - Symptoms include chronic abdominal pain, diarrhea, nausea, weight loss, and bleeding in the stool. In severe cases, bowel obstruction or fistula formation may occur.

**Diagnosis** - Diagnosis of radiation enteritis involves endoscopy, which can reveal inflammatory changes, strictures, and ulcerations. Imaging techniques like CT or MRI are helpful in assessing the extent of damage.

**Surgical Treatment** - Surgery is indicated for bowel obstruction, perforation, or fistula formation. Resection of the affected bowel segment with anastomosis is the most common procedure, though surgery can be complicated by adhesions.

### **4. Acute Infectious Enteritis**

**Etiology and Pathophysiology** - Acute infectious enteritis is caused by infection of the intestinal mucosa by various pathogens, including bacteria (e.g., Salmonella, Shigella, Campylobacter), viruses (e.g., Norovirus, Rotavirus), and parasites (e.g., Giardia lamblia). Mucosal inflammation leads to malabsorption and fluid secretion, leading to diarrhea.

**Clinical Presentation** - Symptoms include the acute onset of diarrhea, abdominal pain, vomiting, fever, and dehydration. Some patients may develop severe complications such as toxic megacolon or bowel perforation.

**Diagnosis** - Diagnosis is typically based on clinical symptoms and laboratory tests, such as stool cultures or pathogen detection via PCR. In severe cases, imaging (CT or X-ray) is recommended to rule out complications like perforation.

**Surgical Treatment** - Surgery is generally only indicated for severe complications like perforation or toxic megacolon. In such cases, resection of the affected bowel segment with temporary diversion or laparostomy with a provisional abdominal wall closure is necessary.

## **5. Diverticulitis**

Diverticula of the small intestine are rare, but inflammation can lead to serious complications such as perforation, bleeding, or bowel obstruction. Diagnosis is often difficult due to their rarity, which can worsen the clinical picture.

**Etiology and Pathophysiology** - Diverticula of the small intestine are divided into congenital (true) and acquired (false).

Congenital diverticula involve all layers of the intestinal wall (mucosa, submucosa, and muscle layer) and most often arise from developmental anomalies during embryogenesis. An example is the Meckel's diverticulum which occurs in the ileum and is differentially diagnostic associated with appendicitis.

Acquired diverticula result from increased intraluminal pressure, causing mucosa and submucosa to push through the weakened muscle layer of the bowel wall. These diverticula are common in older patients, particularly in the duodenum near the ampulla of Vater.

**Clinical Presentation** - Most diverticula are asymptomatic and are often discovered incidentally during imaging or surgery for other reasons. When symptomatic, complications include:

**Diverticulitis:** Inflammation, presenting with abdominal pain, often localized to the epigastrium or mesogastrium, fever, nausea, and vomiting. Symptoms can mimic acute appendicitis or cholecystitis.

**Perforation:** Leads to acute peritonitis, with sudden, severe abdominal pain, abdominal wall rigidity, and sepsis, requiring immediate surgery.

**Bleeding:** Can cause melena or hematochezia, sometimes leading to anemia. Meckel's diverticulum is the most common source of painless lower gastrointestinal bleeding in children.

**Bowel Obstruction:** May be caused by inflammation, lumen narrowing from recurrent inflammation, or diverticular torsion. Symptoms include abdominal pain, vomiting, distension, and absence of stool and gas passage.

**Diagnosis** - Diagnosing small bowel diverticula can be challenging due to non-specific symptoms, often resembling other abdominal conditions. Diagnosis typically relies on a combination of clinical presentation and imaging:

**Endoscopy:** Duodenal diverticula can often be diagnosed by endoscopy, especially if located in the proximal duodenum. Meckel's diverticulum is rarely identifiable endoscopically.

**Imaging:** CT and MRI are the most commonly used imaging methods, detecting diverticula and their complications. CT angiography may be useful for localizing bleeding sources.

**Surgical Treatment** - Surgery is indicated for symptomatic diverticula or complications. Procedures vary based on diverticulum location and type:

**Meckel's Diverticulum:** If symptomatic, resection of the diverticulum or segmental bowel resection with anastomosis is usually performed. Even asymptomatic diverticula found during other surgeries may be prophylactically resected.

**Duodenal Diverticula:** Surgical resection is indicated for symptomatic or complicated diverticula. These surgeries can be technically challenging due to the duodenum's proximity to the pancreas and bile ducts.

**Jejunal and Ileal Diverticula:** Resection of the affected bowel segment with anastomosis is the standard approach, particularly for complications such as perforation or obstruction.

**Prognosis and Complications** - The prognosis for small bowel diverticula depends on timely diagnosis and management of complications. Asymptomatic diverticula generally have a good prognosis, while complicated cases may have high morbidity and mortality. Perforation or severe bleeding can be life-threatening if not treated promptly and adequately.

**Conclusion** - Inflammatory diseases of the small intestine and its diverticula are clinically significant conditions that require a comprehensive diagnostic and therapeutic approach. Surgical treatment is often necessary in the presence of complications such as obstruction, perforation, or fistulas. Correct diagnosis and timing of surgical intervention are crucial.

## **INFLAMMATORY DISEASES OF LARGE BOWEL AND THEIR SURGICAL MANAGEMENT (35)**

Marek David, Grolich Tomáš

Inflammatory bowel diseases encompass a diverse group of conditions characterized by inflammation of the large intestine. These include **acute** and **chronic appendicitis** (*discussed in Chapter 26 Acute Appendicitis*), **acute diverticulitis** (*discussed in Chapter 36 Diverticulosis of the Gastrointestinal Tract*), **infectious colitis**, **idiopathic inflammatory bowel diseases** (ulcerative colitis and Crohn's disease), **pseudomembranous colitis**, and **ischemic colitis** (*discussed in Chapter 28 Intestinal Ischemia*). Each of these conditions has its own unique etiology, pathogenesis, symptomatology, course, and treatment.

**CROHN'S DISEASE** is an idiopathic chronic transmural inflammation that can affect any part of the gastrointestinal tract from the oral cavity to the rectum, most commonly the ileum and the adjacent cecum. Typical are segmental "skip" lesions, where multiple parts of the gastrointestinal tract are affected simultaneously. **The exact cause** is unknown, however, a genetic predisposition and the influence of environmental factors such as diet and the immune response to the microbial flora are assumed.

**Symptoms** include abdominal pain, usually in the right lower quadrant, chronic diarrhea, weight loss, or fever. Extraintestinal symptoms may include ocular and skin manifestations, arthritis, and involvement of the liver, kidneys, or pancreas.

**Laboratory tests** may show elevated inflammatory parameters, anemia, thrombocytosis, hypoalbuminemia, positive ASCA antibodies, and a non-specific elevation of fecal calprotectin. The method of choice in the non-acute phase is **endoscopy** with typical "skip" lesions, focal aphthous ulcers, or linear ulcers. On **abdominal ultrasound, MRI, or CT enterography**, we can see a thickened intestinal wall (most often the terminal ileum), abscesses, fistulas, or typical multiple involvement of so-called "skip" lesions. Complications typically include the formation of fistulas (enteroenteric, enterocolic, enterovesical, rectovaginal, rectoperineal), as well as the formation of abscesses (interloop, pelvic, retroperitoneal) and strictures, which can lead to ileus. Malnutrition, anemia, or malignant transformation in chronic inflammation must not be neglected.

**Treatment** is managed by gastroenterologists and consists of administering aminosalicylates, corticosteroids, immunosuppressants, or biological agents in several consecutive lines. Surgical treatment involves managing acute and chronic complications, in case of failure of conservative therapy, and often involves multiple surgical procedures in the course of recurrent disease. The most common type is ileocecal resection with ileo-ascending anastomosis. Stricturoplasties (longitudinal incision of the stricture with transverse suture) are also performed if the stenotic lesion cannot be

treated endoscopically with balloon dilatation. Other procedures may include segmental resection, right hemicolectomy with ileo-transverse anastomosis, subtotal colectomy with ileo-rectal anastomosis, or proctocolectomy with ileostomy and management of perianal fistulas. In general, during surgery for IBD, we resect only the affected segment of the intestine without lymphadenectomy, trying to preserve the maximum length of the gastrointestinal tract.

**ULCERATIVE COLITIS** is an idiopathic chronic inflammatory disease affecting the mucosa of the colon and rectum, with a typical location in the rectosigmoid segment. The inflammation spreads continuously in an oral direction. **The cause**, like in Crohn's disease, is unknown, with the influence of environmental and genetic factors.

Gastrointestinal **symptoms** include diarrhea with blood and mucus, cramping abdominal pain associated with defecation, tenesmus, and weight loss. Extraintestinal manifestations are less common than in Crohn's disease.

Positive ANCA antibodies are found in 70% of patients, otherwise, the **laboratory diagnosis** is identical to Crohn's disease, including fecal calprotectin. In the case of **endoscopy**, which is also the method of choice here, we observe a hemorrhagic mucosa and diffuse inflammation. In biopsy specimens, typical crypt abscesses are found in the microscopic image.

The most common acute **complications** include decompensated pancolitis, toxic megacolon (significant distension of the colon with impaired motility, bacteria and toxic products begin to penetrate through the intestinal wall into the abdominal cavity when intestinal contents accumulate) and perforation. Chronic complications include the development of colorectal cancer (after 50 years in 40% of patients).

**Treatment** is managed by gastroenterologists and involves the use of aminosalicylates, corticosteroids, immunosuppressants, or biological agents. In acute cases with decompensation of the disease and failure of conservative therapy, a total colectomy with a terminal ileostomy is performed, leaving the rectal stump. In chronic courses or after sanitation of an acute condition in patients who do not respond adequately to conservative therapy, an operation is planned in two or three stages based on the severity of the inflammation. First, a colectomy is performed with the creation of a terminal ileostomy. In patients with a good colon finding, a proctocolectomy and the immediate creation of an ileal pouch (J-shaped reservoir) with an axial ileostomy is possible in the first stage, which is often constructed in the second stage. In the final stage, the continuity of the gastrointestinal tract is restored by removing the protective axial ileostomy.

**Prognosis** depends on the severity and stage of compensation of the underlying disease.

**INFECTIOUS COLITIS** is an inflammatory condition caused by infection with bacterial, viral, or parasitic agents. They can occur from insufficiently heat-treated food, expired food, or fecal-oral transmission in a collective.

They **manifest** as abdominal pain, fever, nausea, and frequent diarrhea, which may also contain mucus and blood, leading to dehydration and ion imbalance.

**Laboratory tests** show elevated inflammatory parameters, hypokalemia, elevated renal parameters, and hematocrit. On an abdominal X-ray, there may be distension of the colon, and on ultrasound, thickening of the intestinal wall and possibly complications. In clinically severe cases, we often supplement with an abdominal CT scan, while colonoscopy is contraindicated. To confirm the agent, a swab is taken from the rectum for obligatory intestinal pathogens and it is also necessary to rule out *Clostridium difficile* colitis.

Most infections have a short **course** and require only outpatient treatment in the form of dietary measures, adequate oral hydration, and possibly antibiotic therapy. More severe forms, especially in older polymorbid patients, may require hospitalization for rehydration, correction of the internal environment, and antibiotic therapy. A serious complication is the development of sepsis.

**Surgical treatment** is exceptional here and mainly represents the management of complications associated with colitis, such as uncontrollable sepsis, intestinal perforation, and toxic megacolon.

**Prevention** is adequate hygiene and heat treatment of food, and possibly vaccination (e.g., against rotavirus).

A specific example is **PSEUDOMEMBRANOUS COLITIS**. This is an acute inflammatory disease of the large intestine characterized by the formation of pseudomembranes on the intestinal mucosa. It is often caused by an overgrowth of the bacterium *Clostridium difficile* after disruption of the intestinal microflora.

It most often **occurs** after the administration of broad-spectrum antibiotics, not infrequently as a nosocomial infection. Older people are more susceptible to development, as well as immunosuppressed individuals, for example, after chemotherapy or immunosuppressive therapy. Other factors may include PPIs, which reduce stomach acidity and can thus increase the risk.

**The manifestation** is typical of watery diarrhea (in numbers of 10-15 per day). It usually has an acute onset and can have a mild to severe course.

**Diagnosis** includes, among other things, the detection of *Clostridium difficile* toxin in the stool. Even after successful treatment, pseudomembranous colitis may recur, especially with repeated use of antibiotics.

Early diagnosis is important! **Treatment** includes discontinuation of broad-spectrum antibiotics, if possible. Metronidazole is used for less severe forms, Vancomycin is preferred for more severe cases or recurrences, or Fidoxamicin as a newer antibiotic with high efficacy and a low rate of recurrence. Rehydration therapy, including electrolyte substitution, is important: Probiotics can help restore the intestinal microflora and reduce the risk of recurrence. In the progression of the disease, a total colectomy with a terminal ileostomy is performed with high morbidity, usually without a plan for destomization in a polymorbid elderly patient.

**Prognosis** depends on early diagnosis and treatment. In more severe cases, serious complications can occur that can be fatal, especially in elderly and immunosuppressed patients.

**Prevention** means the judicious use of antibiotics and, together with them, the administration of probiotics, which can reduce the risk of developing Clostridium difficile colitis. Prevention of spread is thorough hand washing and isolation of patients (barrier care regimen).

**DIFFERENTIAL DIAGNOSIS** is challenging in the most severe clinical conditions, and from a surgical standpoint, it's more about ruling out acute complications based on a combination of clinical findings (appendicitis), signs of inflammation, and imaging studies (contrast-enhanced CT scan when ischemia is suspected). This information is used to decide whether to proceed with surgical intervention or initiate empirical conservative treatment (antibiotics, intravenous fluids), often without knowing the exact etiology of the inflammation. In cases with milder courses, by supplementing with cultures, endoscopy, and laboratory tests, we can arrive at a diagnosis within a week, allowing us to target treatment specifically.

In the initial diagnostic process of sudden abdominal events with similar histories and clinical findings, it is essential to consider other conditions such as pyelonephritis, urinary tract infections, acute pancreatitis, gastroenteritis, gynecological infections, or colorectal cancer.

## HEMORRHOIDS, ANAL FISSURE (2)

Berková Alena

### **HAEMORRHOIDS**

**Definition:** Hemorrhoids are dilated, coiled blood vessels in the wall of the anal canal. Hemorrhoidal disease is a very common problem in both women and men. Hemorrhoidal plexuses are anatomical and physiological structures of the anal canal. The hemorrhoidal plexus is significantly involved in the continence of stool.

**Pathophysiology:** Currently, the pathogenesis of hemorrhoidal disease is based on two main pathological factors:

mechanical factor: in which, most often due to aging or chronic irritation, degenerative processes occur in the connective tissue of the hemorrhoidal plexus. This results in a prolapse of the mucosa with venous plexuses in the wall of the anorectum.

vascular factor: when, during prolonged strenuous defecation, the circulation in the capillaries of the arterio-venous junctions is blocked, resulting in abnormal dilatation of the cavernous tissue.

**Etiology:** The etiopathogenesis of hemorrhoids is multifactorial. The most common causes of hemorrhoids include defecation disorders, prolonged sitting, certain sports activities, pregnancy, use of hormonal contraceptives, constitutional predisposition, hypercholesterolemia, hyperlipidemia, and abnormalities in collagen quality in Ehlers-Danlos syndrome.

**Classification:** Anatomically, according to the relationship to the linea dentata, we distinguish:

internal haemorrhoids (nodi haemorrhoidales interni) are located above the linea dentata

external haemorrhoids (nodi haemorrhoidales externi) located below the linea dentata.

intermediate haemorrhoids are found directly in the submucosal part of the anal canal between the linea dentata and the anocutaneous passage.

Internal hemorrhoids are most commonly classified into four stages according to Goligher:

Stage I: minimal nodules without laceration, hemorrhoidal nodules are visible only by anoscope.

They are usually asymptomatic, but may present with bleeding or discomfort in the anorectal area;

Stage II: during defecation, the nodes prolapse but spontaneously recollapse. Symptomatic patients complain of bleeding, itching, "wet anus" sensation or discharge;

Stage III: the nodes prolapse, and manual repositioning is necessary. In addition to bleeding and discomfort, there is often spotting;

Stage IV. submucosal prolapse, which is already fixed, without the possibility of repositioning, often accompanied by prolonged discomfort, pain, bleeding and some degree of incontinence.



**Clinical signs and symptomatology:**

Problems associated with internal haemorrhoids are usually chronic and last for several weeks or months. These include discomfort in the anorectal area, foreign body sensation, itching, prolapse; bleeding that can lead to secondary anaemia, irritation of the perineum, itching. Pain can be caused by complications such as thrombosis, ischemia or inflammation, acute prolapse of internal hemorrhoids.

External hemorrhoids are very prone to thrombosis, which is accompanied by extreme pain. After healing of the perianal thrombosis, skin folds, so-called mariscs, which are oriented radially, are formed around the anocutaneous transition.

**Diagnosis:** History and clinical examination and per rectum examination are essential. In addition, an anoscopy or a rectoscopic examination is performed – typical localization of internal hemorrhoids is at number 3, 7, 11. Colonoscopic examination is indicated in all patients with past or present bleeding to exclude other pathological conditions of the rectum and colon

**Therapy:**

Conservative therapy: this includes regimen measures and reduction of risk factors, regular defecation and training of defecation reflex, diet rich in fiber. Physical activity is important, or weight reduction in case of obesity.

Local therapy: includes sitting baths, which are antiseptic, antiphlogistic and analgesic. Another option is the administration of suppositories, ointments and creams.

Systemic therapy: includes the administration of venoactive substances so-called flavonoids, which improve the tone of blood vessels. As a result, the permeability of the blood vessels is reduced, and the circulation is accelerated.

Obliteration methods are methods in which the haemorrhoidal node is obliterated and fibrosed and blood flow is restricted. These include Barron's elastic ligature, sclerotherapy, laser therapy, infrared photocoagulation, and bipolar or monopolar diathermy.

Surgical therapy: is indicated for symptomatic grade III-IV hemorrhoids in which conservative treatment does not provide relief. It is performed under general or spinal anaesthesia, in the jack knife or gynaecological position, after preoperative preparation of the rectum with an infusion. The classical methods include the Whitehead operation – in this procedure a circular resection of the mucosal prolapse is performed. Or preparation of individual haemorrhoidal nodes with vascular pedicle ligation according to Milligan-Morgan or Ferguson is performed.

Miniinvasive methods include stapler haemorrhoidopexy according to Longo or stapler haemorrhoidopexy – TST (tissue selecting therapy) – selective resection of haemorrhoidal tissue.

**Differential diagnosis:** malignant diseases: colorectal cancer, anal carcinoma, Bowen's disease;

**CAVE: Behind every rectal bleeding can be a tumor!**

perianal thrombosis, mariscus, anal fissure, perianal eczema;

hypertrophic anal papilla ("anal polyps", "cat's teeth");

inflammatory bowel disease, anal abscess, anal fissures and fistulas;

rectal polyps;

prolapse of the rectum and ulcer recti;

Condylomata acuminata (HPV infection) Condylomata lata (syphilis).

## **FISSURA ANI**

**Definition:** An anal fissure is caused by an injury to the mucous membrane in the anal canal. It is manifested by pain and bright red bleeding.

**Etiopathogenesis:** Relative ischemia and traumatization of the mucosa during defecation may play a role. Chronic increased anal sphincter tone leads to fibrosis of the muscle and the formation of a fissure.

Often there is a history of constipation, anal sexual practices, perineal infections, perianal area, Sexual transmitted diseases – STD, other anorectal diseases – hemorrhoids, cryptitis and Crohn's disease.

Chronic fissure is associated with spasm of the smooth muscle of the internal sphincter, resulting in impaired blood supply to the base of the fissure and complicated healing.

### **Classification:**

acute fissure – a minor mucosal injury that heals quickly and rarely requires treatment.

chronic fissure – persisting for several weeks.

**Clinical picture:** Symptom is severe sharp pain with each defecation localized at the site of the fissure and pelvic pain persisting hours after defecation, probably due to spasm in the pelvic floor muscles. Burning and itching of the rectum. Bleeding is not pronounced, as it originates only from the mucosal margins.

**Diagnosis:** History, clinical examination and per rectum examination are essential. Digital rectal examination can be difficult as the area is sensitive and the anus is closed by sphincter spasm. Usually the lower edge of the fissure can be seen by gently separating the buttocks. Next, anoscopy or rectoscopic examination should be performed. Usually the fissure is located in the posterior midline of the anal verge, but it may be located in the anterior midline. In a chronic fissure, a firm rim with a protrusion at the outer edge called a guarding bump develops and there is overgrowth of

the nearest anal papilla. Further investigation includes colonoscopic examination, exclusion of inflammatory bowel diseases – IBD, exclusion of Sexual transmitted diseases –STD in multiple fissures or fissures in lateral positions.

**Therapy:**

Conservative therapy: includes treatment of constipation and 6-week application of glyceryl trinitrate suppositories and ointment. Glyceryl trinitrate causes relaxation of the smooth muscles of the internal sphincter. The therapy may also include injection of botulinum toxin into the sphincter area.

Surgical therapy: is indicated mainly in chronic fissures where conservative therapy fails. Excision of the fissure may be performed. Histological examination of the lesion is always necessary to exclude malignancy. Another option is to perform an anus divulgation. Lateral sphincterotomy is nowadays only rarely performed for extensive findings.

When sphincter spasm is significant and outpatient examination is not possible, the fissure can be diagnosed and treated under general anesthesia and other important differential diagnoses, such as abscess or fistulation, can be excluded if necessary.

**Differential diagnosis:**

- malignant disease of the perianal area, anus and rectum;
- perianal fistulations and abscesses;
- haemorrhoids;
- sexual infections, condylomata acuminata (HPV infection) condylomata lata (syphilis).

## ANORECTAL FISTULA AND ABSCESS, PILONIDAL SINUS DISEASE (1)

Trenz Aleš

### **Perianal and periproctal fistulas**

Fistulation in this area is defined as pathological communication between the lumen of the anal canal or the rectum and the skin of the perianal area or perineum.

Although it is a problem in a lot related to some systemic diseases - see below, the first diagnostic and treatment steps are the domain of the surgical department. Thus, the surgeon must always bear in mind the possible multidisciplinary overlap, even if apparently small and localized lesions, especially in patients with recurrence of such problems.

In the prevalence data, we observe a significant prevalence of the disease in the male population, almost twice as much (the overall average for the population is approx. 8.5/100000).

Etiology can be traced to an infectious inflammation of one of the anal glands. These are a typical anatomical structure under the mucosa near the linea dentata in the number of 10-15, mostly on the dorsal side. The infection is further complicated by the formation of a abscess, which breaks through into the anal canal, thus giving rise to wider communication with the intersphincteric space. We call this sequence of overlapping pathologies the "cryptoglandular theory" of the formation of fistulas, and only about 10-20% of cases in which the origin can be determined in another pathology, for example, in IBD, deviate from traumatization of the area, cancers, actinomycotic/TBC/chlamydial/STD/etc. infections, post-radiation conditions, pelvic sepsis and other - rather rarer - conditions.

An unpleasant and often smelly discharge or suppuration, soreness or pruritus will bring the patient to the doctor. They can even be associated with subfebrile.

Anamnestically, one can often find a history of non-surgically resolved abscesses, sometimes intermittently and spontaneously emptying with varying lengths of remission. Other reported systemic symptoms such as diarrhea, abdominal pain, and weight loss should not escape our attention.

Diagnosis by clinical examination usually does not cause difficulties and includes, in addition to the aspect and determination of the location and size of the lesion, also determination of the nature of the secretion, palpation of the extent of induration, examination per rectum with not obvious possible verification of the internal orifice. But this is usually confirmed by anoscopy which is also necessary. It is possible to try a gentle probing and thereby better map the course of the fistula tract or inject peroxide or with a colored solution, to make it leak visualise.

Optionally, paraclinical methods are added - typically NMR (gradually displaced CT, fistulography with contrast solution and TRUS - TransRectalUltraSonography), colonoscopy.

In the differential diagnosis, we think of a fistula from the Bartholin's gland in women, advanced hidradenitis, pilonidal cyst, osteomyelitis of the pelvic bones, secreting skin affections, etc. In a simplified and general way, we can say that it is not a mistake to delegate a patient with a typical lesion in the perianal area to a follow-up and examination to a surgical department.

Before starting and choosing a specific treatment modality - the solution is surgical - it is necessary to determine the type of fistula in more detail. The aim is always to preserve the sphincter function. Generally accepted and known is the classification according to the dominant course of the tract.

- 1) submucosal
- 2) intersphincteric (most common, runs between the internal and external sphincter)
- 3) suprasphincteric (arises from supralelevator abscesses)
- 4) extrasphincteric (the rarest, runs outside the sphincters and pierces the rectum above the level of the levator ani muscle).

Furthermore, it is determined whether the fistula has an internal orifice and is therefore not/complete. In the case of uncomplicated, low and complete fistulas, we proceed to **fistulotomy or fistulectomy**, the fistula tract towards the surface is widely opened, or even excised into healthy tissue.

The technique according to **Seton** is suitable for high complete fistulas and involves cutting the external orifice of the fistula, thus inserted an elastic fiber along the entire course of the tract, leading it out through the anal canal and creating a closed circuit of the fiber. Its elastic pull causes a gradual cutting of the tissues with the simultaneous formation of a fibrous scar. As the thread progresses and loosens, it is necessary to tighten it periodically. In this way, with the correct execution and indication, fistulas can be cut or cut through to the outside in 6-8 weeks.

For practically all types of fistulas, except for very low subcutaneous fistulas, the surgical method can be used by moving the **mucosal flap** through the excised internal orifice. Alternatively, the remaining tract and external orifice can be **excochleated**, cut out or filled with tissue glue, etc. In certain situations, the use of **tissue glue** can be considered as the method of choice even on its own. There are other less commonly used treatment modalities, such as "**patch**" the fistula with **artificial biogenic material** or **ligation** of the tract in the intersphincteric space using a fistuloscope. The choice between individual methods is finally determined by the experience of the practicing workplace. Properly indicated, they may be interchangeable in their effectiveness.

### **Periproctal and perianal abscesses**

Perianal and periproctal abscesses are similar in their pathological and pathophysiological origin to the first described fistula and often follow each other in time/progressively. The developing tuber in

the area of the infected anal gland is usually formed by coliform flora and can be emptied early in the intraluminal direction, which does not cause major clinical difficulties for the patient and the condition resolves spontaneously. Less often, it spreads in the form of phlegmon to the surrounding area and a diffuse inflammation occurs, which must be widely incised immediately, treated with local antiseptics and immediately covered with antibiotics - empirically at first and targeted as soon as possible. Rapidly progressing or insufficiently early and aggressively treated phlegmon can result in putrefactive perianal involvement with irreversible damage to sphincter function and pelvic sepsis. By far, the process is bounded in the form of an abscess collection, the spontaneous regression of which is not possible. Therefore, the abscess grows and, left untreated, prolapses until it finally perforates into the rectum, anal canal or perineal skin. We recognize 6 groups of abscesses depending on their location, again reflected in the name itself.

- 1) submucosal
- 2) intersphincteric
- 3) transsphincteric
- 4) ischiorectal
- 5) pelvirectal
- 6) subcutaneous (=perianal)

The diagnosis is based on a typical anamnesis of short-lasting pains, problems with emptying, possible IBD present (up to 90% of all patients with Crohn's disease are treated surgically at least once in their life), often with a short-term febrile state, etc. Follow-up clinical examination is usually sufficient to finish diagnosis and indicate incision and evacuation of the abscess under general anesthesia. We find painful induration and inflammation in varying degrees.

Due to the usual high pain, we retreat from anoscopy, which is preferably completed only in CA at the same time as remediation of the deposit (**incision, evacuation, lavage, possibly drainage**) in order to rule out the presence of fistula into the rectum. If this is present, we mark it by inserting a **ligature**, see above. There is no alternative to conservative therapy here either. A mutually beneficial approach to the procedure under general anesthesia during hospitalization is the promise of thorough treatment without compromises that we would otherwise be forced to make due to the pain so typical in the given location. We always supplement surgical therapy with the introduction of ATB (empirical -> targeted).

### **Pilonidal sinus**

Focal disease of the soft tissues in the sacrococcygeal region is typical for the young but adult generation, significantly more often in obese men with a higher degree of pubic hair. The hormonal influence of adolescents on the sebaceous and sweat glands - men - has also been proven.

Anamnestically, patients frequently report a sedentary occupation/lifestyle. It is for this phenomenon that the disease was previously known under the eponym "jeep disease" (young soldiers-drivers in WWII.).

The manifestation is either in the form of a secreting sinus or as its complication - an acute abscess in the sacrococcygeal region. The base of the lesion consists of inverted tissue of the skin adnexa containing hairs, granulomatosis and fibrosis, which distinguishes it from a simple soft tissue abscess in other areas. There are also asymptomatic forms.

Diagnosis is based on anamnestic and clinical examination supplemented by probing with a small probe through possible fistulas. US and CT is a very exceptional paraclinical modality of choice reserved for differentially diagnostically complicated cases with an unclear connection with the pelvic space, skeleton, suspicion of a tumor process. The examiner thinks about such conditions in the differential diagnosis, as well as hidradenitis, manifestation of cleft defects, pyoderma granulorum, carbuncle, etc.

The introduction of regimen measures is an integral part of the treatment of all stages of the disease. In addition to motivating the patient for thorough hygiene, we also explain the importance of depilation of the area and the choice of clothing made of natural materials - "absorbent". In the case of asymptomatic or calmed fistulizing disease without secretion, such a procedure supplemented with **dispensary** can be considered sufficient.

Other treatment options are already instrumental/operative.

The simplest method for small and unbranched sinuses is the **instillation of phenol**, which causes limited tissue destruction, scarring and closure. The method can be applied repeatedly depending on the effectiveness.

More extensive surgical therapy is divided into 3 basic groups

- 1) **incision and drainage** (in the acute phase of an abscess, other methods may follow after
- 2)       calming down)
- 3)     2) **excision and secondary healing** (rather for smaller foci, lower risk of recurrence, without risk of
- 4)       early abscesses)
- 5)     3) **excision and primary closure** (rather smaller and medium deposits, less requirements for
- 6)       compliance patient, risk of surgical site infection, the need for longer hospitalization)

4) **excision with reconstruction by displaced skin flap** (sec. Limberg / Karydakis)

Although the last 2 mentioned methods are better tolerated by the patient due to the "immediately visible result", the level of risk of the primary suture is not negligible due to the typically significant bacterial colonization in the given location and therefore the risk of early infection incl. anaerobic. It is therefore advisable to hospitalize the patient for longer (depending on the case, even for 7 days) with simultaneous covering by ATB and directed positioning in bed. Any failure of the suture or infection leads to a sometimes unacceptable cosmetic effect of the wound.



## ESOPHAGEAL SURGERY, ANATOMY, APPROACHES, TYPES OF OPERATIONS (20)

Jaborník Martin, Marek Filip

### **Introduction:**

The esophagus, derived from the Greek words "oiso" meaning "to carry" and "phagos" meaning "to eat," is a muscular tube that transports food and liquids from the pharynx to the stomach. Due to its anatomical location anterior to the spine in the neck and posterior mediastinum, it was historically difficult to access for both clinical examination and surgical intervention. However, significant advancements in diagnostic and therapeutic techniques occurred in the 1970s and 1980s, leading to standardized procedures. Today, minimally invasive techniques have become the gold standard.

### **Anatomy:**

The esophagus is a muscular tube approximately 25-30 cm in length. It begins at the level of the C6 vertebra, connecting to the lower part of the pharynx, and ends in the region of T11, where it joins the cardia of the stomach. Based on its course, the esophagus can be divided into three topographic parts: cervical, thoracic, and abdominal. Both ends of the esophagus are equipped with sphincters: the upper esophageal sphincter (UES) or cricopharyngeal sphincter, and the lower esophageal sphincter (LES). As an organ of the digestive tract between the pharynx and stomach, it ensures the passage of food and secretions between these organs.

Unlike the rest of the gastrointestinal tract, it is composed of only three histologically defined layers, lacking a serosa except for a short intra-abdominal portion. The mucosa is lined with stratified squamous epithelium, except for the distal 1-2 cm, known as the Z-line, where there is a transitional zone with columnar epithelium. The mucosa is the strongest part of the esophagus, and therefore, its perfect suturing is crucial during surgical procedures. The muscularis externa of the esophagus is composed of striated muscle in the upper third, which gradually transitions to smooth muscle in the middle third, with the lower third being entirely composed of smooth muscle. The muscle fibers are arranged in an outer longitudinal and inner circular layer.

The blood supply to the esophagus is provided by several arteries. The cervical portion is supplied by the inferior thyroid artery. The thoracic portion is supplied by the intercostal arteries, branches of the thoracic aorta, and bronchial arteries. The abdominal portion is supplied by the left gastric artery and inferior phrenic arteries. Venous drainage occurs from the submucosal plexus to the superficial plexus, and then to the surrounding veins: inferior thyroid veins, intercostal veins, azygos and hemiazygos veins, and left gastric vein.

The innervation of the esophagus is provided by both parasympathetic and sympathetic nerve fibers. Parasympathetic innervation originates from both branches of the vagus nerves. This innervation

stimulates peristalsis and secretion. Sympathetic innervation originates from the thoracic sympathetic trunk. This innervation generally has an inhibitory effect on peristalsis and increases the tone of the sphincters. Nerve fibers branch on the surface of the esophagus and form plexuses: the submucosal plexus of Meissner, located in the submucosa, regulates gland secretion; and the myenteric plexus of Auerbach, located between the muscle layers, controls peristalsis.

### **Surgical approaches to different levels of the esophagus:**

**1/ Cervical:** Left-sided approach behind the sternocleidomastoid muscle. **2/ Thoracic:** Right-sided thoracotomy or thoracoscopy; see Figure 2. **3/ Abdominal transhiatal:** Upper midline laparotomy or laparoscopy; see Figure 1.

### **List of surgical procedures:**

#### **Heller's Cardiomyotomy**

##### Indications:

Esophagogastric achalasia - a functional disorder of the entire esophagus, characterized by decreased or absent esophageal peristalsis, progressive esophageal dilation, and impaired relaxation of the lower esophageal sphincter.

##### Diagnosis:

Gastrofibroscopy, esophageal barium swallow, distal esophageal endosonography (to rule out pseudoachalasia), esophageal manometry

##### Procedure description:

Historically performed via a transabdominal approach (upper midline laparotomy), today it is performed laparoscopically. An extramucosal longitudinal myotomy is performed approximately 2 cm distal and 6 cm proximal to the gastroesophageal junction. It is usually supplemented with a fundoplication to prevent postoperative reflux. Intraoperative endoscopy is recommended to assess the integrity of the mucosa and control the extent of the myotomy.

#### **Anti-reflux Surgery**

##### Indications:

Gastroesophageal reflux disease (GERD) is a condition where the contents of the stomach flow back into the esophagus. The cause may be functional or morphological. If the esophagus reacts pathologically to reflux, we speak of gastroesophageal reflux disease. Conservative therapy in the form of lifestyle changes and proton pump inhibitors is fully sufficient for about 80% of patients. In the remaining cases, anti-reflux surgery should be considered, especially in patients with significant regurgitation and extra-esophageal symptoms of reflux, Barrett's esophagus, or as an alternative to long-term PPI therapy.

### Diagnosis:

Gastrofibroscopy, 24-hour pHmetry, manometry

### Procedure description:

Laparoscopy is the standard approach. The principle is to create a cuff around the distal esophagus using the wall of the gastric fundus in various modifications: Nissen-Rossetti procedure - complete 360° wrap, incomplete 270° wrap according to Toupet, and others. The procedure is performed with a thick calibration probe introduced orally into the esophagus, which is then removed after the procedure.

### **Esophagectomy**

#### Indications:

Esophageal cancer, with squamous cell carcinoma being most common in the upper two-thirds and adenocarcinoma being typical for the distal esophagus and gastroesophageal junction. Other indications include Barrett's esophagus unresponsive to conservative treatment and esophageal injury associated with mechanical or chemical insult.

#### Diagnosis:

Endoscopy with biopsy, oncological staging (CT of the chest and abdomen, tumor markers), multidisciplinary team.

#### Procedure description:

In the gastroesophageal junction area, classical resection procedures vary depending on the tumor location. The Siewert classification of tumors is used. For type II (cardial) and III (subcardial) tumors, total gastrectomy with resection of the terminal esophagus and reconstruction of the passage using a Roux-en-Y loop is a radical solution. The surgical approach is laparotomy (upper midline laparotomy or transverse supraumbilical). For adenocarcinoma from Barrett's esophagus (type I adenocarcinoma of the gastroesophageal junction), due to the risk of submucosal spread of the tumor orally, as well as for other tumors in the intrathoracic esophagus, subtotal esophagectomy is indicated. The esophagus can be approached either through laparotomy - transhiatal approach or through right thoracotomy, both of which can also be performed as minimally invasive procedures. Subsequently, two approaches can be used to construct the esophageal anastomosis: cervical from the left or from the right hemithorax. There are several options for replacing the resected esophagus. The most commonly used is a tubulized stomach, other options include coloplasty or a small bowel segment.

## SURGERY FOR BENIGN GASTRIC DISEASES (31)

Chovanec Zdeněk

**Anatomy:** the stomach is divided into cardia, fundus, corpus, antrum and pylorus. It is fixed in the abdominal cavity by the *lig. gastrophrenicum, hepatogastricum, gastrolineale* and *gastrocolicum*. The arterial supply is provided by *a. gastrica dextra* (*a. hepatica propria - tr. coeliacus*), supplying the lesser curvature, *a. gastrica sinistra* (*tr. coeliacus*) supplying the lesser curvature and fundus, *a. gastroepiploica dextra* (*a. gastroduodenalis - a. hepatica communis - tr. coeliacus*) supplies the greater curvature, *a. gastroepiploica sinistra* (*a. lienalis - tr. coeliacus*) supplies the greater curvature and *aa. gastricae breves* (*a. lienalis - tr. coeliacus*) supplies the gastric fundus. The veins are marked like the arteries, draining into the *v. portae*. Besides, they have connections through the *rr. gastricae breves* to the lesser curvature and through the *v. linealis* and *vena coronaria ventriculi* to the esophageal veins (portocaval anastomosis). In portal hypertension, esophageal varices may arise via this route.

Lymphatic drainage is divided into 4 groups. There is a connection to the hepatic, suprapancreatic, linear, mesenteric, mediastinal, celiac and paraaortic lymph nodes, and lymph drains through the *ductus thoracicus* and *angulus venosus* into the venous system.

Sympathetic innervation is provided via the *gl. coeliacum*, parasympathetic innervation via the *n. vagus*.

The surgical approach can be classical, through laparotomy (transverse, longitudinal) or mini-invasive (laparoscopic, robotic).

**Indications:** Benign and malignant tumors, distal stomach obstruction, therapy of gastroduodenal ulcer disease, therapy of complications of ulcer disease (perforation, bleeding, penetration), treatment of GERD, bariatric surgery, provision of nutrition, drainage of gastric secretions and creation of a neoesophagus after subtotal esophagectomy.

**Total gastrectomy** is resection of the entire stomach.

**Subtotal gastrectomy** is the removal of a portion of the stomach, leaving the remaining portion to restore the GIT. The types of subtotal resection depending on how much of the stomach is removed, and what type of GIT reconstruction is performed. Both the distal part of the body of the stomach with antrum and pylorus can be resected, as well as the proximal part in the form of resection of the cranial part of the body, fundus and cardia of the stomach.

Reconstruction of the GIT after total gastrectomy can be performed by creating a Roux-en-Y anastomosis, interposition of the jejunum, or creation of an esophago-duodenal anastomosis.

The principle of the Roux-en-Y anastomosis is to connect a long ileum, approximately 40 cm, to the esophagus (to ensure the passage of food from the esophagus to the intestine) and then to connect the dislocated part of the duodenum (to ensure the drainage of bile and pancreatic juices) to the esophagus. GIT reconstruction consists of the creation of an esophagojejuno-anastomosis (connection options are end-to-side, end-to-end, manual, mechanical or semi-mechanical) and an entero-entero (end-to-side, side-to-side) anastomosis. The jejunum can be routed both antero-colically and retrocolically.

**Billroth I (B I)** resection is the removal of the lower part of the stomach up to the pylorus and the connection of the remaining part of the stomach directly with the duodenum (terminal gastroduodeno-anastomosis, end-to-end or end-to-side) is indicated in the treatment of complications of peptic ulcers (perforation, penetration, bleeding), the disadvantage is duodeno-gastric reflux. B I can be modified by interposition of a discarded segment of jejunum (the operation is functionally favorable for physiological food transport), there is no blind-loop syndrome and afferent-loop syndrome.

**Billroth II (B II)** resection is the removal of the lower part of the stomach up to the pylorus and the connection of the remaining part of the stomach to the jejunal branch (gastroentero-anastomosis, connection of the gastric stump to the jejunum), retrocolically or antecolically with the exclusion of the blindly closed duodenum, in modification with Braun's enteroentero-anastomosis (omega loop) or in combination with Roux-en-Y anastomosis. Complications of the omega loop can be afferent loop (congestion in the feeding loop, colonization by bacteria and stasis of pancreatic and biliary secretions), efferent loop syndrome (gastric emptying is reduced by narrowing of the anastomosis or invagination of the draining loop), blind loop syndrome (colonization of the blind loop by intestinal bacteria, deconjugation of bile acids and consumption of vit. B12).

**Pyloroplasty** is a surgical enlargement of the pylorus to improve the passage of food (longitudinal stretching of the pylorus with its transverse suture). It is usually performed in combination with vagotomy to avoid complications from excessive gastric retention.

**Vagotomy** is the severing of the vagus nerves innervating the stomach to reduce the production of stomach acid. 1) truncal vagotomy is the interruption of the main trunks of the vagus nerves, 2) selective vagotomy is the interruption of the gastric-specific branches of the vagus nerves, and 3) proximal selective vagotomy is the interruption of only the fibers leading to the parietal cells, with minimal impact on gastric motility.

Simple suture of a perforated gastric ulcer, sealing with omentum. Suture of a bleeding gastric ulcer with a puncture ligature after gastrotomy in case of impossibility to treat the bleeding by endoscopic means. Suture of a penetrating ulcer e.g. into the pancreas.

**Fundoplication** consists of wrapping the fundus of the stomach around the lower esophageal sphincter to prevent reflux of gastric contents into the esophagus and simultaneously restore the angle of His. There are countless modifications of this operation, however the most common is Nissen fundoplication (complete 360° wrapping of the fundus around the esophagus).

**Sleeve gastrectomy** is a bariatric operation for weight reduction in obese patients, tubulisation of the stomach is performed, the principle is to reduce the volume of the stomach.

**Gastric bypass** is also a bariatric operation that combines reduction of the stomach and alteration of the digestive tract (the stomach is divided into two parts, the cranial smaller part is connected to the jejunum, continuity is restored by Roux Y anastomosis, and the caudal larger part remains connected to the duodenum).

**Antrectomy** is the removal of the antrum of the stomach (distal portion), often performed in ulcerative diseases or in patients with gastrin (e.g., Zollinger-Ellison syndrome).

**Gastrostomy** is a surgical procedure used to insert a tube, often referred to as a "G-tube", through the abdomen and into the stomach. Gastrostomy is used to provide a route for tube feeding if needed for four weeks or longer, and/or to vent the stomach for air or drainage.

The tubulated stomach can also be used as a non-intact stomach in case of sub-total esophagectomy.

## GASTRODUODENAL ULCER DISEASES (32)

Petríková Laura

**Definition :** A peptic ulcer is an open sore found on the lining of the stomach or duodenum caused by an imbalance between protective and aggressive factors acting on the mucosal layer. An ulcer extends into the submucosal layer and deeper. It's a disease characterized by the appearance of one or more ulcers in the wall of the stomach or duodenum. Most often they are localized on the small curvature of the stomach and the bulb of the duodenum.

**The most common causes** of peptic ulcers include *Helicobacter pylori* infection, long term use of ulcerogenic drugs, imbalance between protective and aggressive factors acting on the mucosal layer. Protective factors include gastric mucus, mucosal regenerative ability, prostaglandins, and physiological microcirculation of the stomach. Aggressive factors include overproduction of Hydrochloric acid ("no acid no ulcer"), *H.pylori* infection, gastric motility disorders, microcirculation disorders, ulcerogenic drugs – anti-inflammatory drugs, corticosteroids, cytostatics; smoking, alcohol, caffeine.

**Diagnosis:** Begins with a comprehensive physical exam which can reveal pain in the epigastric region. Gastrointestinal endoscopy with biopsy allows us to diagnose peptic ulcer disease and to examine the mucous lining of the upper GIT. Testing for *H.pylori* infection includes urea breath tests, serologic testing, blood tests ,stool antigens and biopsy. In case of positivity, eradication with antibiotics is necessary.

**Clinical findings in gastric ulcer** are burning pain sensation in the upper abdominal region after food, lack of appetite, pyrosis, vomiting, weight loss and foetor ex ore. Antacids usually do not bring any relief. The most common symptoms of a **duodenal ulcer** are waking up at night with upper abdominal pain. The pain usually improves with eating or after taking antacids. The occurrence is rather seasonal in younger patients.

**Special types of ulcers include: Cushing's ulcer** – produced by elevated intracranial pressure caused by tumors or lesions of the CNS, overstimulation of the vagus causes higher secretion of HCL.

**Curling's ulcer** – gastric erosion resulting as a complication from severe burns when reduced plasma volume leads to ischemia and cell necrosis of the gastric mucosa. **Zollinger-Ellison**

**syndrome** - in connection with endocrinally active gastrin - producing tumors - gastrinomas, most often localized in the pancreas, resulting in overproduction of HCL. **Stress ulcer** - ischemia + disturbance of microcirculation in the mucosa.

**Complications and treatment: acute bleeding from an ulcer lesion**, clinically manifested by hematemesis (bright red blood/coffee ground vomitus ), melena (dark stool), anemia, hypotension. In

patients with GIT bleeding, PPI's are administered intravenously. Acute endoscopy is performed, it allows us to stop the bleeding with endoscopic ligation, metallic clamps or sclerotherapy.

**Classification:** during endoscopic examination, the bleeding ulcer lesion can be evaluated according to **Forrest classification** - I (active bleeding) Ia: active spurter, arterial bleeding, Ib: active oozing venous bleeding from the base of the ulcer. IIa: a visible, gaping vessel at the base of the ulcer, IIb: adherent clot, IIc: flat pigmented haematin on ulcer base. III: clean-based ulcer.

**Surgical management** is indicated in unstable patients with endoscopically untreatable bleeding. A puncture of the bleeding vessel at the base of the ulcer may be performed through gastrotomy/duodenotomy, possibly followed by ligation of the supplying artery, suturing the gastro/duodenotomy. To prevent ileus in case of significant narrowing of the duodenum due to ulcer punctures, gastroenteroanastomosis should be performed. In extreme cases of bleeding from a gastric ulcer that cannot be resolved by puncture, a partial gastrectomy may be performed.

Another complication is **perforation** into the abdominal cavity, most often the anterior wall of the duodenal bulb or the prepyloric area of the stomach, presenting as sudden, severe pain - patients assume a typical bent-forward position, in a state of shock.

Initially, iv. therapy is recommended, surgery is necessary if pneumoperitoneum is demonstrated (X-ray/CT scan). Surgical therapy involves suturing or omental plugging, biopsy to exclude perforated gastric tumour. Another complication is **penetration** of the ulcer through the stomach or duodenum into another nearby organ, most often the head of the pancreas. There is a risk of bleeding from large vessels. Any non-healing ulcer with established PPI therapy is highly suspicious for malignancy.

**Stenosis** occurs as a result of scarring of a chronic ulcer, the surgical treatment is gastroenteroanastomosis or resection of the stenotic part of the stomach (according to Billroth).

**Conservative therapy** includes regimen measures - smoking ban, restriction of irritating food, alcohol, coffee and NSAIDs. In the presence of H.pylori infection, eradication with the combination of Omeprazole, Amoxicillin and Clarithromycin is necessary for at least one week. Medical therapy and prevention include proton pump inhibitors - inhibiting HCl secretion ( Omeprazole, Pantoprazole ). Also H-2 blockers and antacids, which neutralize the pH of the stomach. Endoscopy is used for biopsy, locating the ulcer and possibly treating the source of bleeding. Vagotomy was once commonly performed to treat and prevent peptic ulcer disease, however now acid secretion control can be achieved with medication. Today, endoscopically intreatable complications of the peptic ulcer disease are addressed surgically.

Conservative treatment is most commonly used to treat gastroduodenal ulcer disease. PPI therapy significantly reduces the incidence of complications. In case of endoscopically untreatable complications, surgical treatment is indicated.





## **GASTRIC TUMOURS (33)**

Chovanec Zdeněk

**Epidemiology:** gastric cancer is the fifth most common malignancy worldwide and the third most common cause of cancer death. The highest incidence is recorded in East Asia, especially in Japan, South Korea and China, whereas in Europe and North America the incidence has been declining in recent years, probably due to reduced consumption of salts and canned foods and eradication of infection caused by *Helicobacter pylori*. In the Czech Republic, the incidence of gastric cancer is also declining, with an 18% decrease in incidence between 2006 and 2016, and according to available data, 9.16 women/15.09 men per 100 000 population will have the disease in 2021. The prognosis of patients with gastric cancer depends mainly on the stage of the disease at the time of diagnosis. Early gastric cancer has a very good prognosis, with a five-year survival rate of up to 90 %. For patients with locally advanced cancer, the 5-year survival ranges is between 30-60 %, depending on the extent of lymph node involvement and the locoregional findings.

**Etiology:** is multifactorial, involving environmental and genetic factors. In non-cardia adenocarcinoma, increased salt intake, canned foods, low fruit and vegetable intake, smoking and *Helicobacter pylori* infection leading to chronic gastritis followed by metaplasia and dysplasia are risk factors. Other risk factors are Epstein-Barr virus infection, previous gastric surgery, pernicious anemia, bile acid reflux, and blood type A. For cardia (proximal type), obesity with gastroesophageal reflux disease (GERD) leading to chronic irritation of the mucosa is a risk factor. Genetic predispositions include hereditary diffuse gastric cancer (HDGC), familial adenomatous polyposis, hereditary non-polyposis colorectal cancer, BRCA 1, BRCA 2, Li-Fraumeni syndrome, Peutz-Jeghers syndrome, and more recently gastric adenocarcinoma and gastric adenocarcinoma multiple polyposis syndrome (GAPPS).

**Diagnosis:** clinical symptoms of gastric cancer are non-specific and especially late. Usually it is the so-called small symptom syndrome (lack of appetite, aversion to meat, weakness, anaemia, weight loss). Esophagogastroduodenoscopy (EGD) has the highest sensitivity and specificity with the simultaneous possibility of biopsy. Endosonographic examination (EUS) specifies the depth of invasion (which is used to classify the TNM category T). Computed tomography (CT) of the chest, abdomen and pelvis is the standard examination for staging (N, M). Positron emission tomography (PET) is used to detect distant metastases. Diagnostic laparoscopy with peritoneal lavage is indicated for locally advanced carcinoma with suspected peritoneal spread, with the possibility of cytoreductive surgery followed by hyperthermic intraperitoneal chemotherapy (HIPEC). Tumour marker determination is not a diagnostic or screening method, but is a standard part of monitoring

disease progression and treatment effect. The most commonly used tumour markers are carcinoembryonic antigen, CEA, CA 19-9, and CA72-4.

**Histology.** The basic division is into benign and malignant tumours. Benign gastric tumours include polyps (most often inflammatory and hyperplastic), less frequently occurring leiomyomas, lipomas, fibromas, neurinomas and hemangiomas. The most common malignant tumour is adenocarcinoma (about 90 %). It is divided into intestinal type (tubular and papillary), diffuse type (poorly cohesive) and unclassified type, which includes tumours that cannot be clearly classified according to the previous categories. Mixed carcinoma contains multiple components of these types and often only one component is diagnosed, complicating the accuracy of diagnosis. There are also lymphomas (MALT lymphoma), neuroendocrine neoplasia (NET) - (gastrinoma, somatostatinoma and enterochromaffin cell carcinoid) and mesenchymal tumours - gastrointestinal stromal tumour (GIST).

**Surgical treatment** remains the mainstay of therapy for gastric cancer, especially in early and locally advanced stages. The success of surgical treatment depends on early detection, accurate diagnosis and careful surgical technique. The TNM classification of gastric cancer allows accurate determination of the extent of the disease and is essential for the choice of therapeutic approach. For localised tumours (stage I - III), the basic therapeutic approach is to perform a **total gastrectomy**, with an anastomosis between the oesophagus and the small intestine (usually Roux-en-Y reconstruction). **Subtotal gastrectomy** (preservation of the proximal part of the stomach) can also be performed for distally located tumours of smaller size, but it is not suitable for diffuse carcinomas. D2 lymphadenectomy is the standard procedure, dissecting the lymph nodes along the a. hepatica communis, a. gastrica sin., truncus coeliacus and a. lienalis up to the splenic hilum. The goal is to achieve a resection (R0) with histologically negative margins and at least 15 lymph nodes removed. Peroperatively, jejunostomy is indicated to provide postoperative enteral nutrition. Splenectomy or resection of the pancreatic duct is not a standard part of the procedure, but it can be performed if the radicality of the operation requires it.

For early stage I carcinoma (TIS, T1a, T1b), tumour resection can be performed using endoscopic technique, in the form of **endoscopic mucosal resection (EMR)** for T1a less than 2 cm or **endoscopic submucosal dissection (ESD)** for T1b without lymph node involvement. Surgical resection is indicated for early tumors with a higher risk of lymphatic metastasis (T1b) or when endoscopic resection is not feasible, namely subtotal or total gastrectomy with D2 lymphadenectomy.

In locally advanced T2-4 or N+ M0 disease, the standard procedure is the application of perioperative chemotherapy aimed at shrinking the primary tumor and eradicating micrometastases.

Laparoscopic and robotic-assisted approaches offer patients the advantages of less postoperative pain, faster recovery, and lower complication rates without compromising the oncologic radicality of the procedure.

In patients with advanced gastric cancer with metastases (stage IV), surgical treatment is rarely curative. In these cases, palliative surgery is often performed to relieve symptoms caused by the tumor, such as gastric obstruction or bleeding. Palliative gastrectomy may be indicated for patients with localised symptoms, such as an obstruction in the pyloric region that prevents the passage of food. This procedure helps to improve the patient's quality of life, although it does not lead to prolonged survival. Bypass surgery is in cases where resection cannot be performed, gastrojejunostomy or other bypass surgery can be performed to allow food passage and relieve obstructive symptoms.

A multimodal approach combining surgery with chemotherapy, radiotherapy and targeted therapy is increasingly being advocated. The goal of neoadjuvant therapy is to shrink the primary tumor and eradicate micrometastases. Adjuvant therapy aims to improve overall survival and reduce the risk of disease recurrence.

**In conclusion,** gastric cancer remains a serious health problem in the Czech Republic, mainly due to the high mortality associated with late diagnosis. Despite the decline in incidence, treatment remains challenging, with surgical resection playing a key role in therapy, especially in early and intermediate stages of the disease. More effective screening and early detection are key factors in improving the prognosis of patients with this disease. Therapy should always be assessed by a multidisciplinary medical team. After gastrectomy, lifelong vitamin B12 replacement is required.

## STAGES OF GASTRIC CANCER AND CORRESPONDING TREATMENT

Stage	Description	Treatment
<b>Stage 0 (Tis, N0, M0)</b>	Intraepithelial tumor (carcinoma in situ), limited to the mucosa without lymph node involvement or metastases.	EMR/EDS Regular follow up is important
<b>Stage I (T1, N0/N1, M0)</b>	Tumor limited to the mucosa or submucosa (T1), with involvement of 0–2 regional lymph nodes, no distant metastases	Subtotal or total gastrectomy with D1 lymphadenectomy Early tumors limited to the mucosa may be treated with endoscopic therapy (EMR/ESD) Often no neoadjuvant or adjuvant therapy is required if complete resection is achieved
<b>Stage II (T2/T3, N0-N2, M0)</b>	Tumor invades the muscular layer (T2) or serosa (T3), with involvement of 0–6 regional lymph nodes, no distant metastases	Total or subtotal gastrectomy with D2 lymphadenectomy Neoadjuvant chemotherapy is often indicated to reduce tumor size and improve prognosis Adjuvant chemotherapy/radiotherapy post-resection based on histopathological findings
<b>Stage III (T3/T4, N0-N3, M0)</b>	Tumor invades the serosa (T3) or adjacent organs (T4), with involvement of more than 7 lymph nodes, no distant metastases	Total gastrectomy with D2 lymphadenectomy Neoadjuvant chemotherapy (or chemoradiotherapy) Adjuvant chemotherapy post-resection Sometimes palliative resection if curative surgery is not possible
<b>Stage IV (any T, any N, M1)</b>	Any primary tumor with lymph node involvement and distant metastases (M1).	Surgery is usually palliative to relieve symptoms like obstruction, bleeding, or perforation Palliative chemotherapy and radiotherapy aimed at improving quality of life Bypass surgery or stenting in cases of gastric outlet obstruction

### LIVER SURGERY – ANATOMY, APPROACHES, TYPES OF OPERATIONS (3)

Penka Igor

Liver surgery focuses on focal liver involvement. The liver itself is located in the area of the right subphrenium, where it is partially fixed by suspension apparatuses, which are represented by the falciform ligament (ligamentum falciforme) and coronary ligament (lig. coronarium), including their duplications and round ligament of the liver (lig. teres hepatis), which divides the anatomically liver parenchyma into the left and right lobes. However, this anatomical classification does not correspond to the surgical anatomical classification. The division of the two lobes (right and left) is an imaginary line principal fissure (fissura principalis), or Rex-Cantlie line, which runs from the fundus of the gallbladder through the convexity of the liver to the middle of the inferior vena cava and thus surgically divides the right and left liver lobes. This line is essential from a surgical point of view and corresponds to the intraparenchymal course of the middle hepatic vein. Each lobe is further divided into hepatic segments, each of which has its own portal triad, which includes the hepatic artery, portal vein and bile duct for each segment so that each hepatic segment has its own "hilus" (also known as hilus, the inferior surface where major blood vessels, lymphatics, and ducts enter or exit the organ). The division into individual segments is determined by the imaginary lines of the, at first glance, invisible intraparenchymal course of the liver veins.

The left lobe consists of three segments (segments II, III, and IV, which are further divided into segments IVa and IVb), and the right lobe contains four segments V, VI, VII, and VIII.

The caudate lobe, or segment I, is located posteriorly. It has an exceptional position because it has a different vascular supply, including venous and bile drainage. This **Couinaud's classification of liver segments** allows surgical resections to be performed.

From a surgical point of view, the anatomy of the hepatic hilum – the place where the main vascular and bile structures enter the liver parenchyma on the visceral surface of the liver - is also of great importance. At the site of the hepatic hilum, the hepatic artery, portal vein and the main bile duct enter the liver via the hepatoduodenal ligament. The hepatic artery itself sends a separate right and left branch to both lobes shortly before the hepatic hilum. The common hepatic bile duct also divides into a right and left branch in the area of the hepatic hilum, similar to the portal vein, and forms the main right and left portal triad. Since the purpose of liver surgery is to remove a pathological hepatic focus, it is necessary to identify the main structures, i.e. the relevant hepatic artery, portal vein and bile duct, treat them with a ligature – or ligate and intersect them. However, it is equally important to treat and cancel venous drainage into the inferior vena cava, where the venous blood of the hepatic vein gradually forms the main right, middle and left branches. The

corresponding liver parenchyma supplied by the above-mentioned magistral structures is then gradually removed by transparenchymal resection.

In this way, entire lobes (right or left) or individual segments (1st – 8th) are removed. Of course, it is possible to remove more segments during one surgery or to perform the extended liver resection, where the entire 4th segment is removed together with the right lobe (extended right-sided hemihepatectomy) or with the left lobe (enlarged left-sided hemihepatectomy).

All these resection procedures, where we interrupt the main vascular supply and bile duct, are called **anatomical resections**. Because the pathological lesion itself is removed together with the surrounding liver (usually healthy) parenchyma, these resections are referred to as non-sparing parenchyma. Unlike the **non-anatomical resections**, which are referred to as sparing parenchyma because they remove only the pathological focus of the liver and only a minimum of the surrounding liver parenchyma with the safety margin. Non-anatomical resections do not respect the segmental arrangement of the liver parenchyma. Treatment of individual segmental structures is unnecessary since only individual small vascular and bile structures in the resection line of the parenchyma around the pathological focus are interrupted. Essential for the possibility of performing extraanatomical resection is the favourable – mostly marginal – peripheral location of the pathological lesion and, of course, the nature of the lesion (primary tumour, secondary tumour, benign lesion). No structure of the magistral triad of the left liver parenchyma should be damaged, which would lead to subsequent serious complications (necrosis, abscess etc.). A classic example of extraanatomical resection is the wedge-shaped resection: **wedge resection**.

The basic surgical approaches in liver surgery are similar to those in other issues. We choose either an **open laparotomy** approach or a minimally invasive **laparoscopic** approach followed by mini-laparotomy to extract the resected liver parenchyma. The most frequent types of laparotomies in liver surgery are – subcostal laparotomy on the right and transverse bilateral subcostal laparotomy or supplemented with a longitudinal incision towards the gladiolus in the midline. In some cases, it is possible to choose a median laparotomy from the gladiolus towards the symphysis. The laparoscopic approach means the establishment of a capnoperitoneum with the introduction of a camera and working ports. The following dissection techniques are currently used for **resection of the liver parenchyma** – crushing of the liver tissue using fingers (**finger fracture technique**) or peans (**Kelly fracture technique**) with the treatment of individual vascular-biliary structures with clips or ligatures. Modern dissection devices are also used for resection of the liver parenchyma: harmonic scalpel, CUSA (Cavitron Ultrasonic Surgical Aspirator) aspirator, Water-Jet, Radiofrequency Ablation (RFA), Microwave Ablation (MWA, Thunder-beat, Ligasure, Argon spray, etc. The use of

local haemostatic drugs, including Tachosil, Gelaspon, fibrin adhesives and many other local agents, is also advantageous.

### **Indications for liver resection**

**Primary liver tumours** (hepatocellular carcinoma, cholangiocellular carcinoma), **secondary malignant tumours** (metastases mainly of colorectal cancer, but also of mamma carcinoma, renal cell carcinoma and possibly others), **benign tumours** (mainly liver adenomas, only very large hemangiomas are a relative indication), **cysts and parasitic cysts**. Associated liver resections (for primary biliary tract tumours, ingrowth of tumours from the surrounding area into the liver parenchyma etc.) **Liver injury** is a separate chapter.

Each of these nosological units has its specific aetiology, anamnesis, symptomatology and specifics for the diagnostic and therapeutic process. In general, it should be noted that depending on the nature of the basic diagnosis, each indication for liver resection must be a **multidisciplinary decision** of the participating specialists such as radiologists, medical oncologists, gastroenterologists, pathologists, radiation oncologists, anaesthesiologists, infectologists, and haematologists. Anamnesis and clinical examination play a crucial role in **diagnosis**, which in themselves must lead to an initial working diagnosis, which is then only refined by imaging methods and supplemented by laboratory examination. The most important imaging methods are ultrasound examinations and contrast ultrasound examinations. An essential preoperative standard is a current contrast CT examination of the liver. To exclude extrahepatic metastases, a PET/CT examination is necessary, which is sometimes suitable to refine the character of the liver focus. An important role is played by the volumetry of the liver parenchyma, which provides us with preoperative information on how much functionally fit liver parenchyma remains after the resection procedure – the residual liver parenchyma (future liver remnant – FLR). On average, 60-70 % of liver tissue can be removed, but only in the case of a functionally fit parenchyma. It is obvious that in the affected parenchyma (hepatocellular carcinoma most often in the field of cirrhosis, conditions after chemotherapy), functional liver parenchyma cannot be assumed (see Fig. Child-Pugh classification), and the extent of the resection must be significantly smaller. Insufficient FLR value can be increased by embolisation of the main branch of the portal vein, which leads to hypertrophy of the non-embolized liver parenchyma. Interventional radiology plays an important role not only in preoperative but also in the case of postoperative complications (embolisation in bleeding, angiointervention in ischemia, percutaneous transhepatic drainage – PTD with the possibility of dilatation of stenoses and insertion of stents in biliary tract obstruction, percutaneous CT-guided drainage of liver abscesses and perihepatic collections, etc.).



## **Treatment:**

In **oncological indications**, radical anatomical resections are preferred in primary tumours. In secondary malignant tumours – metastasis of colorectal carcinoma (the most common indication for surgical resection of the liver in our conditions), on the other hand, parenchyma-sparing non-anatomical resections are performed, if possible. In general, in cancer patients, the optimal timing of the resection procedure in connection with the ongoing oncological treatment is crucial so that the benefit from the surgical procedure is maximal, and therefore, a commission interdisciplinary agreement is absolutely necessary – see above.

For benign tumour lesions, surgical removal of adenoma with its potential for malignancy is indicated. Treating **parasitic cysts** is in the full competence of infectious medicine, and the surgeon acts as a consultant after the cyst has been treated. In addition to imaging methods, immunological examination with the detection of specific serum antibodies (ELISA) plays a crucial role in the diagnosis. Treatment of **non-parasitic symptomatic cysts** – usually very voluminous, which cause the patient difficulties due to compression of neighbouring organs with pressure pain – is performed in most cases by laparoscopic fenestration of the cyst into the free abdominal cavity and biopsy of the cyst wall for histological examination. **Liver abscesses** are indicated for surgical treatment quite exceptionally. The originally exclusive position of the surgeon in the treatment of these lesions has been completely replaced by interventional radiology and the possibilities of CT-guided drainage with antibiotic treatment.

**Complication:** After liver resection therapy, the following complications may occur: Bleeding, biliary leakage, infection and liver abscess, subphrenic abscess, abdominal abscess, pleural effusion, wound infection – laparotomy. Serious complications include hepatic insufficiency due to a lack of functionally fit liver parenchyma (future liver remnant – FLR). Late postoperative complications include the formation of a hernia in the area of the scar. General complications occurring after any major intra-abdominal procedure (pulmonary embolism, heart failure, myocardial infarction, stroke, thrombosis of the lower limbs and others) are understandable.

**Liver injury** is a separate chapter. Most often, it is a blunt, non-penetrating trauma in high-energy injuries (traffic injuries, falls from heights). Intra-abdominal organs in high-energy injuries can also injure the spleen, pancreas, GIT, or the suspension apparatus of the intestine or large blood vessels. Patients should be transported from the field by emergency medical assistance (EMS) to the emergency departments of hospitals. The circulatory stability of the injured person and the state of consciousness are essential for further progress. If an abdominal (liver) injury is suspected, it is necessary to perform a bedside ultrasound examination urgently. In more severe traumas, a whole-body CT scan will provide us with immediate information about the condition of the body

cavities. In the most severe cases of circulatory instability, urgent surgical revision is necessary. To evaluate the extent and severity of liver parenchyma injuries, there are many classification schemes according to which the next steps are determined. The most serious are deep fissures with injuries to the main vascular and bile trunks. During an urgent surgical revision, laparotomy is used to treat bleeding liver according to the principles of Damage Control Surgery (DCS) – performing life-saving procedures with the aim of circulatory stabilisation of the patient. The primary requirement is to stop bleeding. For this purpose, we most often perform liver tamponade using abdominal drapes or packing the liver using a mesh. After the operation, the patient is usually transferred to the Anesthesiology and Resuscitation Department, where further treatment occurs. In the case of persistent bleeding, interventional radiology can significantly help us by using methods of selective embolisation of bleeding vessels. In the postoperative period, CT-guided drainage is performed in the development of perihepatic collections and Percutaneous Transhepatic Drainage (PTD) in bile leakage.

## NEOPLASMS OF THE LIVER (5)

Farkašová Martina

Primary - benign x malignant

Secondary - metastasis

**Symptoms** - 1/ Asymptomatic in early stages 2/ Pain in the right upper quadrant 3/ Icterus 4/

Fatigue and weakness, weight loss

**Diagnosis** – 1/ Laboratory tests, including oncomarkers (AFP, CEA, CA 19-9), 2/ Imaging (ultrasound, contrast-enhanced ultrasound, CT, MRI) 3/ Biopsy 4/ Assessment of functional reserve of liver parenchyma (e.g. ICG - indocyanine green clearance)

**Treatment** – 1/Surgical 2/ Radiofrequency ablation and embolization 3/ Chemotherapy, radiotherapy, immunotherapy

**Surgical procedures** – 1/ Fenestration 2/ Extra-anatomical resection 3/ Segmentectomy 4/ Hemihepatectomy 5/ Extended hemihepatectomy 6/ Liver transplantation

### **Resectability**

- Removability of the tumor lesion (R0: no microscopically visible tumor residue, R1:- with microscopically positive resection margin, R2: with macroscopically visible tumor residue left in the patient's body)
- Up to 70-80% of liver parenchyma can be removed without liver failure. However, in case of liver parenchyma involvement (e.g. liver cirrhosis) the functional reserve of liver tissue decreases.
- Preservation of the arterial and portal supply is necessary
- Preservation of venous and biliary drainage is essential
- Most important is the relationship to critical anatomical structures (inferior vena cava, hepatic veins, portal vein, hepatic artery, surrounding organs - stomach, colon, and diaphragm).

### **Benign tumors**

**Haemangiomas** - They are the most common benign lesions of the liver. These are mesenchymal lesions that consist of cavities of varying sizes filled with blood. They can occur at any age and are usually diagnosed incidentally in adulthood. Women are affected 5 times more often than men. In diagnosis, ultrasound in healthy people is sufficient. If the lesion is found in patients with cancer, it is necessary to supplement MRI, CT or contrast-enhanced ultrasound, to exclude metastasis. Treatment is conservative and regular follow-up is not necessary. Surgical treatment is indicated only in case of symptomatic lesions.

**Focal nodular hyperplasia** - This is the second most common benign tumor of the liver. It is conditioned by proliferation of hepatocytes as a hyperplastic response to congenital arteriovenous malformation. It occurs more in women aged 30-40 years. It is usually asymptomatic, typically less than 5cm in size and 80% solitary. It is diagnosed incidentally on ultrasound examination. There is no malignant relapse or increased risk of bleeding, therefore no therapy is required.

**Adenomas** - Relatively rare benign tumors arising from hepatocytes. Etiology is associated with hormonal contraception, anabolic steroid use, obesity, DM, hepatic steatosis, and inborn errors of metabolism such as glycogenosis and galactosemia. They most commonly affect women of reproductive age, but rarely occur in men, children or elderly patients. The course is usually asymptomatic. Abdominal pain is occasionally observed, especially in the case of larger adenomas. Diagnosis relies on imaging. The most sensitive method of diagnosis is liver MRI. Complications include bleeding and malignant reversal.

Clinically significant are 4 main subtypes of adenomas:

**Inflammatory (35-40%)**

- Women with high BMI (steatosis), alcohol
- Higher risk of bleeding (>30%).

**HNF-1alpha mutated**

- More in women (contraceptive).

**B-catenin activated**

- Risk of malignant transformation
- Men,
- Glycogenosis,
- Anabolic steroids,
- Familial adenomatous polyposis

**Unclassified**

- Diagnosis by exclusion method

Treatment is conservative, but there are criteria for which resection is indicated. Men, adenoma larger than 5cm, B-catenin activated, inflammatory and adenomas that do not shrink in women after discontinuation of hormonal contraceptives. In these cases, there is a high risk of malignant reversal. In the case of adenoma bleeding, the method of choice is adenoma feeding artery embolization, which is performed by an interventional radiologist.

Adenomatosis of the liver

It is defined by the presence of 10 or more adenomas in the liver. Treatment is conservative. Surgical treatment is indicated in some cases for lesions larger than 5cm, smaller lesions are regularly monitored by imaging. Exceptionally, liver transplantation is performed.

**Liver cysts** - They are divided into congenital and acquired. Congenital occur either as solitary or as polycystic. Solitary arise from a malformation of the bile ducts. They tend to be small and asymptomatic. If growth and associated symptoms occur, laparoscopic fenestration is performed. Polycystosis is an autosomal inherited disease where 10 or more cysts are present. It is associated with polycystic kidney disease. Complications include bleeding, portal hypertension, liver failure and infection. Treatment is pharmacological and surgical, combining resection procedures with fenestrations. Transplantation is performed in exceptional cases.

Acquired cysts include mainly echinococcal cysts. This is a parasitic disease caused by larvae of tapeworms of the genus echinococcus. Infestation can occur after ingestion of contaminated fruit, vegetables, water or direct contact with an infectious animal (dogs, sheep, rodents). They are divided into two forms:

**Alveolar form - *E. Multilocularis***

- Ultrasound, MRI, serology
- Primarily affects the liver
- Invasive growth
- Satellite foci (brain, lungs)
- albendazole therapy during one year and resection after metastatic lesions are excluded

**Cystic form - *E. Granulosus***

- Liver, brain, lung, bone
- Typical appearance of a cyst
- Albendazole, resection

**Malignant tumors**

- **Hepatocellular carcinoma**
- **Cholangiocellular carcinoma**
- Epithelial hemangioendothelioma
- **Hepatoblastoma**
- Neuroendocrine neoplasia (NEN)- carcinoid
- Lymphoma
- Sarcoma - angiosarcoma, embryonal sarcoma, rhabdomyosarcoma, leiomyosarcoma,
- Teratoma

- Yolk sac tumor

**Hepatocellular carcinoma (HCC)** - It is the most common primary malignant tumors of the liver arising from hepatocytes. It accounts for up to 80% of primary malignant tumors. It is mainly associated with cirrhosis of the liver and chronic hepatitis B and C. More recently, it has also been associated with non-alcoholic fatty liver disease (NAFLD). HCC is usually clinically silent and small tumors are picked up in screening or as an incidental finding. Clinical symptoms such as abdominal pain and pressure, fatigue, abdominal distension or weight loss are more common in advanced stages. Sometimes the tumor will manifest itself by distant metastases. Laboratory findings include elevated liver function tests and AFP. Fibrolamellar HCC is a separate entity. It occurs in young individuals around 20-30 years of age. These are patients without chronic liver disease. There is no elevated liver enzyme in the laboratory and the AFP level is normal. At the time of diagnosis, 80% are advanced. Treatment is surgical (resection, transplantation), radiofrequency ablation for small foci, chemoembolization, systemic therapy for advanced inoperable tumors.

**Cholangiocellular carcinoma (CCC)** - It is a primary malignant tumor of the biliary tract. It is divided into intrahepatic (from the intrahepatic bile ducts) and extrahepatic, which affects the large bile ducts. A special category is the hilar type, which is known as Klatskin's tumor (65% of all CCCs).

**Hepatoblastoma** - It is the most common liver tumor of childhood. It is a highly malignant embryonal tumor. About 90% of cases occur before the 5th year of life of the child. The tumor is most commonly found as a painless palpable mass in the right upper quadrant in the poorly thriving child. Laboratory values tend to include anemia, thrombocytosis, coagulopathy, and elevated alpha-fetoprotein levels. Diagnosis is based on CT and MRI scans, which are important for assessing the operability of the tumor. If technically feasible, radical resection is performed. If it is not possible, chemotherapy is administered, which may shrink the tumor and allow radical resection. In some cases, liver transplantation is performed. If curative treatment is not possible, locoregional treatment (radiofrequency ablation, chemoembolization, radiotherapy) can be used to prolong the patient's life. The 5-year survival rate is more than 75% in children.

**Secondary tumors** - They account for 90% of all malignant liver tumors. Colorectal, pancreatic, breast or gastric cancers are the most common to metastasize to the liver. Metastases can be synchronous (detected at the same time as the primary tumor) or metachronous (with a varying time lag from the diagnosis of the primary tumor). Diagnosis relies on a combination of imaging methods. CT has a sensitivity of 73% for liver metastases, PET CT 93.9%. Treatment includes: surgical resection, radiofrequency ablation, stereotactic radiotherapy, chemotherapy or immunotherapy.

## **SPLEEN SURGERY – ANATOMY, APPROACHES, TYPES OF OPERATIONS (6)**

Vytešňíková Martina., Španková Markéta

The spleen is the organ filling the left diaphragmatic vault. It is covered by the 9th to 11th ribs, the so-called splenic ribs. It is normally not palpable, weighs about 120 to 160 grams, measures 12 x 7 x 4 cm, and is commonly compared to the shape of a coffee bean.

The vascular supply is secured by the lienal artery, which branches off from the truncus coeliacus. A. lienalis divides into several segmental branches in the hilum of the spleen, each supplying one of the 4-6 segments of the spleen. Part of the vascular supply is provided by aa. gastricae breves in the gastrosplenic ligament. Blood is drained through the lienalis vein to the portae vein.

The suspensory apparatus of the spleen consists of lig.phrenicolienale, lig. pancreaticolienale and already mentioned lig. gastrosplenic. The spleen is adjacent to the cauda of the pancreas, the stomach, the left kidney and adrenal gland, and the lienal flexure of the colon. Sometimes there are also smaller accessory spleens in the abdominal cavity, the so-called splenuncles, most often in the vicinity of the spleen itself. Their presence should be excluded using imaging methods (CT) before splenectomy from the hematological indication.

The spleen is part of the immune system with the production of lymphocytes, its other function is the absorption and destruction of old and non-functional erythrocytes, it also has the function of a blood reservoir, around 250 ml; in the prenatal period it is one of the organs of erythropoiesis.

### **Types of surgeries and their indications:**

Splenectomy, or removal of the spleen, is indicated, for example, in case of injury to the spleen (injury passing through the hilum, larger fissures and untreatable bleeding from the parenchyma).

Trauma to the spleen can result in massive bleeding with hemorrhagic shock immediately after a traumatic stroke, if it occurs delayed, this is a so-called two-stage rupture of the spleen. It arises on the basis of a subcapsular hematoma of the spleen, which gradually increases in size, as a hyperosmolar agent it binds fluid from the surroundings, thereby increasing its volume even more. Subsequently, without further trauma after approx. 10 to 14 days after the original stroke, under the pressure of the hematoma, the capsule can burst and bleed.

Another indication for splenectomy can be splenomegaly unresponsive to systemic treatment in a malignant lymphoproliferative disease (lymphoma, leukemia,...), or hematological indications (sickle cell anemia, hereditary spherocytosis...), infection of the spleen.

A special chapter is represented by cysts and pseudocysts of the spleen. They tend to be parasitic (e.g. Echinococcal pseudocyst) and non-parasitic (often post-traumatic). With a larger size, they can

cause discomfort and pressure in the left subclavian, or pressure on the surrounding structures. When malignancy is ruled out, cysts up to 4 cm can only be observed, above 4 cm in diameter, splenectomy or fenestration of the cyst is considered (does not apply to Echinococcosis, where fenestration is not possible due to the risk of the parasite spreading to the abdominal cavity and the risk of anaphylaxis).

Splenectomy is also performed as part of an oncosurgical procedure, when tumors of the surrounding structures either directly infiltrate the spleen and its vascular structures, or can spread to the lymph nodes in the splenic hilum. E.g. tumor of the stomach, pancreas, lienal flexure colon...

Another type of procedure is a partial splenectomy - more rare, e.g. in children's patients, when it is important to preserve at least part of the spleen as part of the development of immunity.

### **Operational approaches**

Splenectomy can be performed laparoscopically or as an open abdominal procedure. A limitation for laparoscopic surgery is a bulky spleen, the assumption of adhesions in the abdominal cavity in a patient who has already been operated on several times, or the urgency of the procedure due to a traumatological indication, when we assume reduced visibility in the abdominal cavity in the case of massive hemoperitoneum.

In the case of both approaches, dissection of the suspensory apparatus of the spleen and interruption of the supply and drainage vessels is required. Advantageously, the lienal artery is ligated/clipped first to stop the blood flow to the spleen, followed by the lienal vein. In the case of laparoscopy, the spleen is extracted from the abdominal cavity, either through one of the ports, when the spleen is previously crushed in an endobag. We choose this type of extraction if we do not need to preserve the spleen in its entirety for histopathological analysis (e.g. for a hematological indication). If the spleen needs to be preserved intact (due to oncological indication), we perform the extraction through a separate incision

### **Complications**

As with any surgery, complications can occur during a splenectomy. Most often, there is bleeding, injury of the surrounding structures, especially the cauda of the pancreas, and complications resulting from the patient's internal comorbidities or the underlying hematological disease. A feared complication is OPSI (overwhelming postsplenectomy infection), when a serious immune disorder after splenectomy can result in life-threatening, rapidly progressing sepsis in the case of infection caused mainly by encapsulated agents (pneumococci, meningococci, haemophilus inf. B). Therefore, post-splenectomy patients should be vaccinated against pneumococci, meningococci, hemophilus influenzae type B, and other vaccinations are also recommended, e.g. against influenza. In the case



of a planned procedure, it is advisable to ensure some vaccinations before the operation through infectious medicine.

**Conclusion:**

Indications for spleen surgery can be hematological, oncological or traumatological. After splenectomy, it can disrupt immune processes in the body, therefore it is necessary to observe measures to prevent the development of life-threatening sepsis either by vaccination or early initiation of ATB therapy immediately upon suspicion of symptoms of a developing infection.

## ACUTE AND CHRONIC PANCREATITIS (7)

Glombová Katarína

### **Pancreatitis**

Inflammatory disease of the pancreas that can occur acutely or chronically. Both types of pancreatitis have distinct pathophysiology, clinical presentations, diagnostic approaches, and treatment strategies.

#### **1. Acute Pancreatitis**

**Definition:** Acute pancreatitis is a sudden inflammatory disease with varying degrees of severity—from mild interstitial pancreatitis to severe necrotizing pancreatitis with multi-organ failure. The primary mechanism is the premature activation of pancreatic digestive enzymes, especially trypsin, leading to autodigestion of pancreatic tissue and a subsequent inflammatory process.

#### **Pathophysiology:**

**Initiation:** Obstruction of the pancreatic duct (e.g., by gallstones) or toxic damage to pancreatic cells (e.g., alcohol). Obstruction leads to the accumulation of digestive enzymes, which become activated within the pancreas, while alcohol promotes oxidative stress and disruption of lysosomal and zymogen membranes, leading to trypsin activation. **Autodigestion:** Activation of trypsin triggers a cascade of other enzymes, including elastase and phospholipase A2, which destroy acinar cells and cause pancreatic necrosis. The inflammation can spread to surrounding tissues, leading to pancreatic edema, necrosis, and pseudocyst formation. **Systemic inflammatory response:** Release of inflammatory mediators (e.g., TNF- $\alpha$ , IL-6, IL-8) into the systemic circulation, which can result in multi-organ failure, including acute respiratory distress syndrome (ARDS), renal failure, and septic shock.

#### **Causes:**

**Biliary pancreatitis:** The most common in Europe, caused by obstruction of the pancreatic duct by a gallstone. Associated with sudden onset of abdominal pain and a high risk of complications.

**Alcoholic pancreatitis:** Long-term alcohol consumption is the second most common cause and can trigger acute pancreatitis, particularly after the abuse of large amounts of alcohol. **Idiopathic**

**pancreatitis:** In about 10–20% of cases, no clear cause is identified. It is suspected that these cases may be related to microlithiasis or genetic factors. **Other causes:** Hypertriglyceridemia,

hypercalcemia, medications (e.g., azathioprine, thiazides), infections (e.g., mumps), trauma, ERCP (endoscopic retrograde cholangiopancreatography), and genetic factors (e.g., CFTR mutations).

#### **Clinical manifestations:**

**Abdominal pain:** Sudden, intense pain in the epigastrium radiating to the back, nausea, vomiting. In biliary pancreatitis, jaundice may be present. **Systemic symptoms:** Fever, tachycardia, hypotension,

and signs of hypovolemic shock are common in severe forms. Patients with necrotizing pancreatitis may show signs of peritoneal irritation (Cullen's and Grey-Turner's signs), indicating the presence of retroperitoneal bleeding.

### **Diagnosis:**

**Laboratory tests:** Elevated serum levels of amylase and lipase, with lipase being more specific.

Elevated liver enzymes (ALT, AST, ALP) and bilirubin may indicate a biliary etiology. CRP is a useful marker of inflammation severity.

**Imaging:** Abdominal ultrasound is the initial method of choice to detect biliary stones. Contrast-enhanced CT is recommended to assess the extent of pancreatic necrosis and identify complications such as pseudocysts or abscesses. MRCP and ERCP can be used for the diagnosis and treatment of biliary pancreatitis.

**Treatment:** Mild acute pancreatitis can be managed conservatively (hospitalization, intravenous fluids, analgesia with opioids, and possibly antibiotics). Fasting is recommended until symptoms improve. For biliary pancreatitis, urgent ERCP is appropriate. In complicated cases with necrosis or abscess, surgical intervention, such as necrosectomy or drainage, may be necessary. In severe pancreatitis with multi-organ failure, intensive care is critical, including monitoring of vital signs, respiratory support, dialysis in renal failure, and prevention of DIC (disseminated intravascular coagulation).

### **Complications:**

**Local:** Pancreatic necrosis, abscesses, pseudocysts, obstruction of the pancreatic duct or bile ducts.

**Systemic:** SIRS (systemic inflammatory response syndrome), multi-organ failure, septic shock, and ARDS (acute respiratory distress syndrome).

**Prognosis:** Mild pancreatitis has a good prognosis, while severe necrotizing pancreatitis is associated with high mortality. Prevention of recurrences includes addressing the underlying cause (e.g., cholecystectomy, alcohol abstinence).

## **2. Chronic Pancreatitis**

Chronic pancreatitis is a long-term, progressive inflammation of the pancreas, leading to permanent structural changes, fibrosis, and loss of both exocrine and endocrine function. Repeated inflammation results in gradual destruction of acinar and ductal tissue, replaced by fibrotic tissue, leading to loss of pancreatic function and complications such as diabetes mellitus and malabsorption.

### **Pathophysiology:**

**Oxidative stress:** In alcoholic pancreatitis, oxidative stress caused by alcohol metabolites damages pancreatic cell membranes and activates inflammatory cascades. **Obstruction of pancreatic**

**ducts:** Strictures or calcifications lead to increased pressure within the ducts, causing atrophy and necrosis of acinar tissue. **Genetic factors:** Mutations in genes like CFTR (cystic fibrosis

transmembrane conductance regulator), PRSS1 (encoding cationic trypsinogen), and SPINK1 (serine protease inhibitor) contribute to disease development.

### **Main causes:**

**Alcohol consumption:** Up to 70% of cases in the Czech Republic. **Genetic factors:** Conditions like cystic fibrosis and hereditary forms linked to mutations in genes like PRSS1, which cause premature activation of trypsin within the pancreas. **Obstructive causes:** Obstruction of the pancreatic duct by a tumor, stricture, or lithiasis. **Autoimmune pancreatitis:** A rare form, chronic inflammation of the pancreas often associated with diffuse enlargement of the gland and elevated IgG4 levels, responds well to corticosteroid treatment.

### **Symptoms:**

**Abdominal pain:** Recurrent or persistent pain in the epigastrium that may radiate to the back, often worsened by eating. **Exocrine insufficiency:** Loss of exocrine function leads to malabsorption, steatorrhea (fatty, bulky stools), and weight loss. Steatorrhea occurs when exocrine function is reduced to less than 10% of normal capacity.

**Endocrine insufficiency:** Development of diabetes mellitus, known as pancreatic diabetes or type 3c, characterized by low insulin production and increased risk of hypoglycemia.

### **Diagnosis:**

**Laboratory tests:** Measurement of pancreatic elastase-1 in stool. Low levels indicate exocrine insufficiency. Abnormal glucose levels are common with endocrine insufficiency.

**Imaging:** Ultrasound and CT may show calcifications, ductal dilation, and structural changes in the pancreas. ERCP provides direct visualization of the pancreatic ducts, revealing strictures, dilations, or calcifications, and allows for treatment. MRCP is a non-invasive method that is highly sensitive for detecting ductal changes and provides detailed assessment of pancreatic anatomy.

**Treatment:** Aimed at symptom relief, complication prevention, and improving the patient's quality of life.

**Conservative management:** Alcohol abstinence, glycemic control, dietary modifications with fat restriction, and pancreatic enzyme supplementation. **Pharmacological treatment:** Analgesics (NSAIDs, tramadol, or opioids). **Endoscopic interventions:** Dilation of strictures, stone removal, or stenting of pancreatic ducts. **Surgical procedures:** Resection of the affected part of the pancreas (e.g., Whipple procedure) or drainage procedures (e.g., Puestow procedure) in patients with severe pain unresponsive to conservative treatment.

### **Complications:**

**Pancreatic diabetes (type 3c):** Common complication, resistant to insulin treatment, requiring careful glycemic control. **Malabsorption:** Due to exocrine insufficiency, leading to nutrient

malabsorption, especially fats, resulting in weight loss and nutritional deficiencies such as fat-soluble vitamin (A, D, E, K) deficiency. **Pancreatic pseudocysts:** Fluid-filled formations that may become infected or rupture. **Increased risk of pancreatic adenocarcinoma:** Especially in patients with long-standing alcoholic pancreatitis.

**Prognosis:** Chronic pancreatitis prognosis depends on its etiology, the extent of pancreatic damage, and the patient's adherence to the treatment regimen, particularly alcohol abstinence. Long-term complications can significantly reduce the quality of life and increase mortality risk. Prevention includes alcohol abstinence, early diagnosis, and treatment of predisposing factors, and regular monitoring of patients at risk for developing chronic pancreatitis.

## **PANCREATIC NEOPLASMS (9)**

Moravčík Petr, Zatloukal Martin, Hlavsa Jan

### **1. PRIMARY PANCREATIC TUMOURS**

#### **1.1 Ductal adenocarcinoma of the pancreas**

It is the most common pancreatic tumour - it accounts for more than 90% of all pancreatic cancers. It is the most frequently surgically treated and also the most aggressive pancreatic cancer. Its incidence is increasing in a long-term trend. In 2018, this disease was the 7th most frequently diagnosed neoplasm in the Czech republic. The mortality rate is very similar to the incidence rate. In the year 2018, pancreatic adenocarcinoma was the 3rd most common cause of cancer death in the Czech Republic. It mostly affects patients over 60 years of age. The majority of tumors are diagnosed late - at clinical stage III and IV, which is closely related to the unfavorable prognosis of this disease. Clinical symptoms are non-specific - abdominal pain, lack of appetite, weight loss, back pain, and in the case of most common localization of the tumour - in the head of the pancreas - typically painless jaundice. Computed tomography (CT) play a key role in diagnosis. The typical CT image for the tumor lesion in the head of the pancreas is double duct sign - dilatation of the bile duct and the pancreatic duct before tumor obstruction.

Complementary examinations are: magnetic resonance imaging (MRI) - better for the evaluation of cystic lesions, to assess the biliary tract and pancreatic duct. It has a higher sensitivity to detect liver metastases. Also PET CT/MR - for detection of distant metastatic disease and assessment of disease recurrence. EUS - endoscopic ultrasonography - good visualization of the pancreas, has higher sensitivity in lesions below 2 cm, increases the accuracy of the assessment of resectability, in indicated cases allows targeted fine needle aspiration biopsy FNAB.

Surgical resectability of a tumour is defined by its anatomical relationship to the surrounding structures, especially blood vessels. In case of infiltration of surrounding arteries or larger vein infiltration, the tumor is evaluated as locally advanced and the treatment of choice is neoadjuvant or palliative systemic cancer therapy. In the case of a resectable tumour, resection of the tumour without prior oncological treatment is currently indicated in a patient in good clinical condition and with favourable oncomarker levels (CEA, CA 19-9).

The extent of the resection procedure depends on the tumor localization. The goal is complete macroscopic and microscopic removal of the tumor - RO resection and adequate lymphadenectomy. Most commonly, 3 types of procedures are performed - see operation diagrams below. For tumours in the head of the pancreas (but also of distal bile duct and the Vater's papilla) we perform proximal pancreatectomy – also called hemipancreatoduodenectomy (HPDE) or Whipple's surgery. Distal

pancreatectomy (splenopancreatectomy) is done for tumors in the body or in the tail of the pancreas. Total duodenopancreatectomy is a possible option for multiple pancreatic lesions or for inferior tissue of the remaining pancreas that does not allow reimplantation into the gastro-intestinal tract. Pancreatic procedures are characterized by high postoperative morbidity of up to 40% and a non-negligible 5% mortality.

## 1.2 Cystic tumours of the pancreas

The detection of pancreatic cystoid tumors has been increasing in recent years with the spread of imaging techniques. Cystic lesions are often diagnosed incidentally during examinations performed for other reasons.

Four types of cystic pancreatic tumors are encountered in clinical practice:

**Serous cystadenoma:** it is benign, affecting more often women (in 75%). It can be localized throughout the pancreas. If large in size or located in the head of the pancreas, it may be symptomatic. Patients with asymptomatic tumors are only followed up. Surgical management is indicated only for symptomatic and tumors.

**Mucinous cystic adenoma:** usually localized in the body and tail (95%), surgical management is indicated due to malignant potential. It typically affects females (>95%), in the 4th-5th decade.

**Intraductal papillary mucinous neoplasia (IPMN):** grows from the main duct or its branches. It has malignant potential. Surgical resection may be beneficial in certain cases. Communicates with the pancreatic ductal system. May present with epigastric pain with frequent irradiation to the back.

**Solid pseudopapillary tumor (Frantz tumor):** The specificity of this type of cystic tumor is the diagnosis at a young age. It typically affects women, less so men of the 2nd and 3rd decennia. Rarely, it can occur in adolescents. Surgical resection is always indicated for malignant potential.

## 1.3 Neuroendocrine tumours

Neuroendocrine cells are diffusely distributed in various organ systems (GIT, lung, nervous tissue, etc.) and like other cells can undergo neoplasia or malignancy. They are divided - according to the degree of differentiation - into NET G1, G2, G3 and neuroendocrine carcinomas (NEC). The degree of dysplasia corresponds to the aggressiveness of the tumor and the prognosis of the patient. The most common localization of NETs is the gastrointestinal tract, including the pancreas.

### Neuroendocrine tumours of the pancreas

They account for about 2-5% of all pancreatic tumors. They are hormonally active in 70-85%. They arise from islet cells of Langerhans. According to the cell type and their hormonal production, they have corresponding clinical manifestations. In general, they have a better prognosis than ductal adenocarcinoma. Hormonally non-functional tumours are usually found incidentally, or, when they

progress in size, they manifest themselves by oppression of surrounding structures or non-specific manifestations - abdominal pain, weight loss, lack of appetite.

Hormonally active (functional) syndromes resulting from hormonal overproduction (Whipple's triad, Zollinger Ellison syndrome, ..)

**Insulinoma:** is the most common endocrine tumor of the pancreas. It is mostly benign.

Manifestations result from hypoglycaemia due to overproduction of insulin - weakness, confusion, tremor, sweating to unconsciousness. Diagnostically, the so-called Whipple's triad is demonstrated (hypoglycaemia during fasting, glycaemia below 2 mmol/l during an attack, resolution of symptoms after glucose administration).

**Gastrinoma:** most often located in the duodenum or pancreas, secreting gastrin causing hypersecretion of gastric acid with severe ulcer disease and reflux - Zollinger-Ellison syndrome.

Other hormonally active tumors (VIPoma, glucagonoma, somatostatinoma) are very rare.

Hormonal inactive pancreatic neuroendocrine tumors often grow inaparently. They are often discovered incidentally during an examination indicated for another reason (e.g. CT scan for nephrolithiasis). Histological verification by EUS FNAB is always necessary to determine malignant potential. Tumours up to 2cm in diameter with low malignant potential can only be followed up. Larger tumours are usually indicated for resection. In contrast to pancreatic cancer, where metastatic liver involvement is considered a contraindication to resection of the primary tumour, resection can be considered for PNET even in the case of metastatic liver involvement, provided that all metastatic lesions are completely removed.

## **2. SECENDARY PANCREATIC TUMOURS**

Metastases of tumours of other origin.

They represent 2-5% of all pancreatic malignancies. They do not have a predilection site. Most often they are solitary metastasis, but multiple metastasis are not an exception. The most common primary origin of metastases is renal cell carcinoma (RCC), followed by lung adenocarcinoma, melanoma, colorectal cancer, breast cancer and sarcomas. Secondary pancreatic tumours are only about 30% synchronous (occurrence of metastasis at the same time as the primary tumour), so metachronous metastases (occurring later) are more common. Late metastases are a specific feature - typically in RCC, where 10% of patients develop metastases up to 10 years after treatment of the primary tumour. Secondary tumors of the pancreas do not have a typical characterization on imaging methods, so differentiation from primary tumours can be difficult in the absence of biopsy confirmation of the diagnosis. Resection is indicated in patients with a good prognosis of the primary tumour (e.g. meta RCC, meta breast).



## **OBSTRUCTIVE JAUNDICE (30)**

Žák Jan

### **Objectives**

This is an elevated serum bilirubin level due to biliary obstruction. Icterus is clinically manifested at levels above  $35\mu\text{mol/l}$ .

#### **The metabolism of bilirubin**

The production of unconjugated bilirubin is 250-300 mg/day. It is produced by the breakdown of Hb by the reticuloendothelial system, predominantly in the spleen. Unconjugated bilirubin is water-insoluble and is transported by albumin in the bloodstream. It is taken into the liver by active transport and conjugated to glucuronide in hepatocytes. Conjugated bilirubin is water soluble and can be excreted in the urine as bilirubinuria. When excreted into the duodenum, bilirubin is bound to cholesterol, lipids and bile salts as micelles. In the terminal ileum, conjugated bilirubin is converted to urobilinogen by bacterial proteases. 90 % of urobilinogen is oxidised to stercobilinogen and excreted in the faeces. The portal system reabsorbs 10 % and is finally excreted by the urine. It is taken into the liver by active transport and conjugated to glucuronide in hepatocytes. Obstructive icterus is manifested by conjugated hyperbilirubinemia, dark urine with bilirubin present, and pale stools due to decreased stercobilinogen.  $\text{ALP} > \text{ALT}$ . PT is prolonged but correctable with vitamin K.

#### **Classification of biliary obstruction according to aetiology:**

- intraductal
- mural
- extra ductal

#### **Aetiology:**

##### **1. Intraductal**

- choledocholithiasis – loosening of the gallbladder stone – the most common cause
- tumours
- strictures (90 % of iatrogenic, postlithiatic strictures)
- parasites (roundworms, liver flukes, bile flukes)
- AIDS-related cholangiopathy, possible involvement of opportunistic pathogens such as CMV, crypto spores
- biliary tuberculosis

- sump syndrome – a complication of side-to-side choledochojejunostomy - due to stagnation of sludge distal to the anastomosis
2. **Mural abnormalities of the biliary tract**
- biliary stricture – intra-/extrahepatic
  - primary sclerosing cholangitis – males between 20-40 years, cause unknown, association with IBD, mainly ulcerative colitis
  - chronic cholangitis
  - primary biliary cirrhosis
  - iatrogenic, traumatic disabilities
  - tumours (cholangiocarcinoma, periampullary, pancreatic tumours)
  - congenital atresia
1. **Extraductal** – tumours, pancreatitis, pseudocyst, lymphadenopathy

### **Differential diagnosis of icterus:**

**In the differential diagnosis, excluding other types of icterus is necessary.**

Pre-hepatic icterus is hemolytic, with increased red blood cell breakdown. Unconjugated hyperbilirubinemia, normal-coloured stools and urine, and no bilirubin in the urine manifest it.

Its aetiology is most commonly:

- haemolytic anaemia
- congenital abnormalities of the structure of red blood cells (spherocytosis, sickle cell anaemia)
- transfusion reactions
- drug reactions

Hepatic icterus results from failure of bilirubin conjugation in hepatocytes, with enzyme deficiency or failure of uptake. There are elevated levels of mainly conjugated bilirubin. Mixed jaundice is manifested by dark urine and normal stools. Elevated ALT > ALP levels are seen in the laboratory. PT is elevated and not correctable with vitamin K.

Most common aetiology:

- cirrhosis
- infection: viral (hepatitis A/B/C, eBV, CMV); bacterial (liver abscess); parasitic (amoebic)
- Crigler-Najjar syndrome – congenital inability to conjugate bilirubin due to enzyme inhibition
- Gilbert syndrome – inhibition of conjugation and defective uptake by hepatocytes, exacerbated by concomitant disease

- sepsis
- medications (excess paracetamol, amiodarone, diclofenac, fluconazole)
- non-infectious hepatitis (alcohol-related)
- liver tumours (malignant and benign)

### **Diagnosis of obstructive icterus**

- Anamnesis should include key features to obtain a list of likely differential diagnoses. Important questions include family history of blood disorders, recent travel abroad, medications, gallstones, alcohol, weight loss, recent infections, and colour and consistency of urine and stool.
- Similarly, the clinical examination and presentation depend on the cause, but it usually includes yellowing of the sclera and skin, dark urine, and pruritus.
- Examination findings such as spider nevi, xanthomas, and hepatosplenomegaly should be sought, and these may suggest an underlying pathophysiology.
- Pruritus - its cause is not clear. It may be related to the deposition of bile acids in the skin or to the release of endogenous opioids. Excoriation of the skin indicates a long-standing course of icterus.

The investigation of jaundice should focus on elucidating the underlying cause, and the history and clinical examination should guide such investigation.

### **Painful versus painless jaundice?**

To further diagnose and treat obstructive icterus, it is necessary to determine whether jaundice is painful or painless.

**Collinson sign** – radiating pain under the right scapula is present in biliary colic.

It is important to differentiate simple biliary colic from acute cholecystitis. In simple colic, there is no temperature or peritoneal irritation, and the pain is visceral, nonspecific, and poorly localisable.

**Charcot's triad** – icterus, abdominal pain and fever are manifested in acute cholangitis of various etiologies (carcinoma, Mirizzi syndrome, ascending cholangitis, acute pancreatitis, biliary ileus).

**The painless manifestation of obstructive icterus** is associated with carcinoma of the pancreatic head and biliary tract. It requires first investigation as an ultrasound/CT with assessment of local findings and staging.

Blood tests:

KO including differential, liver function tests, coagulation, Coombs test (hemolytic disorders), reticulocyte count, hepatitis screening, EBV, CMV, ferritin,  $\alpha$ 1-antitrypsin, immunoglobulins, smooth muscle antibodies (chronic active hepatitis), antimitochondrial antibodies (primary biliary

cirrhosis), autoantibodies, AFP, copper (Wilson), tumour markers in suspected underlying malignancy.

Urinalysis: presence or absence of bilirubin, urobilinogen. As in hepatic icterus, only conjugated haemoglobin leaks into the urine. Paper tests are extremely sensitive, and sometimes bilirubinuria can be detected before serum bilirubin takes time to make icterus.

Imaging methods:

- **Ultrasonography:** excludes the presence of extrahepatic obstruction and can identify the underlying pathology
- **MRCP:** more sensitive to identify underlying lesions as the cause of biliary obstruction
- **CT:** cross-sectional imaging may be useful depending on the cause
- **EUS:** micro lithiasis, lesions in the head of the pancreas
- **Liver biopsy:** for suspected hepatitis and cirrhosis

## Treatment

In general, treatment of acute obstructive icterus depends on the underlying cause.

As part of the basic treatment, the following is needed:

- Hydration and adjustment of the internal environment

The patient with obstructive icterus is often dehydrated. Fluid balance must be monitored, and caution is required in patients with pre-existing or suspected liver disease.

- Treat sepsis with antibiotic therapy.
- Adjustment of coagulation - administer vitamin K 10 mg if PT is prolonged.
- Nutritional assessment if parenteral/enteral nutrition is provided.

Specific treatment for obstructive icterus is mechanical biliary decompression to help:

- ERCP and sphincterotomy with extraction of choledocholithiasis, and possible stent placement (plastic or expanded metal). It also allows biopsies and cytology to be performed when malignancy is suspected
- Percutaneous transhepatic cholangiogram (PTC) – injection of bile ducts under X-ray control. It allows, among other things, the insertion of a stent and temporary external drainage of the blocked biliary tree, including tissue collection for histology.
- Surgical treatment:

- cholecystectomy with bile duct revision (conventional, laparoscopic, robotic)

- drainage and/or surgical resection (chronic pancreatitis, pancreatic and biliary tumours)

**Complications of obstructive icterus:**

- Infection: cholangitis is typically caused by gram-negative bacteria (Escherichia coli, Pseudomonas).
- Hepatorenal syndrome is caused by a combination of dehydration, underlying sepsis and high bilirubin levels with toxic effects on the kidneys. High associated mortality in patients over 65 years of age
- coagulopathy – decreased synthesis of vitamin K-dependent coagulation factors (II, VII, IX, X) and impaired platelet function
- Immunosuppression - hyperbilirubinemia predisposes to opportunistic systemic infection and poor wound healing due to decreased protein synthesis

Poor prognosis is associated with risk factors such as:

- Age > 65 years.
- Elevated serum urea
- bilirubin in the serum > 200 g/L.
- underlying malignancy
- sepsis and multi-organ failure

## **RETROPERITONEAL TUMOURS (10)**

Hrabec Roman, Staník Michal, Šimůnek Radim

### **1/ Definition**

Retroperitoneal tumours are tumours that arise in the retroperitoneum, which is defined ventrally by the posterior layer of the peritoneum and dorsally by the transversal fascia located on the posterior abdominal wall (back muscles, vertebrae). Cranially, the boundary of the retroperitoneum is the diaphragm, and caudally, it gradually transitions into the subserous space of the pelvis (for more details, see the respective question on retroperitoneal anatomy). Retroperitoneal tumours are extremely rare. They are classified as malignant or benign. Malignant tumours represent 0.1-0.2% of all malignant tumours. Tumours originating from organs within the retroperitoneum are not considered retroperitoneal tumours, as they are the subject of other discussions.

### **2/ Etiology**

Retroperitoneal tumours are classified as primary or secondary.

Primary tumours originate from the soft tissues of the retroperitoneum and are very rare, often reported as case studies. They arise from mesenchymal and nerve tissue and embryonic remnants of the urogenital system, known as extragonadal germ cell tumours. Among mesenchymal tumours, both benign and malignant, the most common benign tumours are myolipomas or lipomas, followed by fibromas, hemangiomas, lymphangiomas, etc. Among malignant variants (up to 80% of all mesenchymal tumours), the most common are liposarcomas, followed by leiomyosarcomas, fibrosarcomas, high-grade sarcomas SFT (solid fibrous tumours). There are more than 50 histological subtypes of sarcomas. Neurogenic tumours most commonly include neurinomas (schwannomas), ganglioneuromas, neuroblastomas (in children), and their malignant variants. Primary extragonadal germ cell tumours are very rare but highly aggressive. Their development is explained by the persistence of gonadal cells in the retroperitoneum that remained after the descent of the testes, with histological types primarily including seminomas and teratomas.

Secondary tumours in the retroperitoneum are much more common than primary ones. These tumours metastasise to the retroperitoneum (most commonly to the retroperitoneal lymph nodes) or invade by contiguity (urological, gynaecological, or gastrointestinal tumours). Systemic tumors such as lymphomas also occur in the retroperitoneum.

### **3/ Pathogenesis**

Due to the varied histological findings, it is difficult to specify the mechanisms and causes of

retroperitoneal tumours. In some cases, a history of prior radiation therapy, especially for childhood cancer, can be traced. In these patients, the risk of developing retroperitoneal tumours is up to 11 times higher than in the healthy population. Another risk factor is a genetic predisposition; in families with a history of cancer, the risk of developing tumours in the retroperitoneum increases in subsequent generations. The occurrence of some tumours is also associated with genetic disorders. For example, patients with neurofibromatosis type 1, retinoblastoma, or tuberous sclerosis have a higher incidence of retroperitoneal sarcomas. In general, primary malignant tumours most commonly affect people between 50-80 years of age, with an equal distribution between genders.

#### **4/ Clinical symptoms and assessment**

a) **Clinical symptoms:** Due to their location, retroperitoneal tumours do not show specific symptoms in the early stages, making clinical diagnosis very challenging. However, as the tumour grows, it may cause a heterogeneous group of symptoms. The most common initial symptoms include pressure discomfort, a palpable mass in the abdomen, or even abdominal wall bulging. The tumour may compress the spinal roots if located near the spine, causing corresponding irritation or paretic symptoms. The upper urinary tract is often affected, with ureter compression leading to dilatation of the renal collecting system. Other possible symptoms include vague back pain, digestive disorders, ileus, loss of appetite, constipation, and cachexia. Tumours may also compress major blood vessels, potentially leading to oedema and varicosities in the lower limbs or thrombotic complications.

Retroperitoneal tumours should be considered in cases of unclear abdominal symptoms.

b) **Paraclinical assessment** – blood test, imaging, and biopsy: Laboratory abnormalities associated with retroperitoneal tumours are mainly due to their expansive growth. In cases involving the upper urinary tract, renal insufficiency may develop. Depending on the tumour's location and its radiological characteristics, the adrenal function should be assessed (as retroperitoneal tumours are often mistaken for adrenal tumours), and tumour markers for testicular tumours should be evaluated. So, as in the clinical and ultrasonographic assessment of testes in men, A differential blood count can help identify lymphoproliferative diseases. Specific tumour markers for retroperitoneal tumours are currently under research. Imaging modalities are crucial for diagnosing retroperitoneal tumours. The first choice is a CT scan, which provides basic information about the tumour's position, size, contact with surrounding structures, and blood supply. More accurate imaging is achieved with MRI, especially indicated before surgical treatment. PET/CT is often used to exclude tumour generalisation, which provides higher sensitivity. If a primary retroperitoneal tumour or an atypical appearance of a tumour in retroperitoneal organs is suspected, a critical step for solid tumours is performing a needle biopsy, preferably under CT guidance. Pathological examination of biopsy

samples can help determine the exact histological nature of the tumour, guiding the oncological team towards a more precise treatment plan.

## **5/ Prognosis**

The essential condition for prognosis is the histological type of the tumour. This is a heterogeneous group of tumours, varying from benign to semi-malignant and even extremely aggressive forms. It greatly depends on tumour differentiation (grading), size (diameter in cm), and distant metastases.

## **6/ Differential diagnosis**

When assessing pathological lesions of the retroperitoneum, pseudotumors may also be encountered, most commonly cystic formations. These arise due to inflammatory diseases of certain retroperitoneal organs (e.g., pancreas, kidney) or after injuries (bleeding into the retroperitoneal space). Treatment is surgical. A rare disease of unclear aetiology is idiopathic retroperitoneal fibrosis, also known as Ormond's disease. It involves the development of pathological fibrous tissue of unclear aetiology around large vessels, nerves, and especially ureters, which gradually thickens and most commonly leads to ureteral compression with the development of renal failure. Treatment is challenging and includes corticosteroids and immunosuppressants. In advanced stages, surgical treatment is performed to release the ureters from the infiltrate and perform their peritonealization.

## **7/ Treatment**

Due to the rarity and heterogeneity of this group of tumours, studies have demonstrated better treatment outcomes for patients when managed at specialised oncology centres.

The retroperitoneal tumour treatment and prognosis depend on the histological form of the tumour; that is why the primary biopsy is crucial and essential.

In some types of retroperitoneal tumours can, primary chemotherapy be a curative option, i.e. lymphomas in retroperitoneum and Ewing sarcoma.

Other types can be used, such as radiotherapy or chemotherapy before operation (neoadjuvant radiotherapy, neoadjuvant chemotherapy). The objective of this pretreatment is downsizing and downstaging the tumour. This can make the operation easier and shrink the amount of the resection needed to achieve a complete resection – R0 resection. Due to the rarity of these diseases, the rules of neoadjuvant treatment are still not clearly stated.

In many retroperitoneal tumours, the only curative option is radical surgical resection; the margins of the resection depend on the histological type of the tumor.



The most extensive resections are needed in retroperitoneal liposarcomas. In these cases, according to worldwide recommendations is necessary to resection of all organs in contact with the tumor. It means left hemicolectomy, nephrectomy adrenalectomy, splenectomy, distal pancreatectomy and resection of the psoas muscle in left-site located tumours. In right-site located tumours then: right hemicolectomy, nephrectomy, adrenalectomy and psoas muscle resection.

For extragonadal tumours, a so-called template resection is performed, where not only the pathological finding is removed but also the entire lipo lymphatic tissue on the corresponding side of the major vessels (paracaval, inter-aortocaval, and paraaortic lymph nodes).

Unfortunately, the primary diagnosis of these tumours often comes in the distant metastatic stage.

## **ADRENALECTOMY - ANATOMY, APPROACHES, TYPES OF OPERATIONS (8)**

Cabanová Lucia, Španková Markéta

### **Anatomy**

The adrenal glands are a pair of endocrine organs that lie on the upper poles of the kidneys. They are placed retroperitoneally at the level of Th11. Due to the lower position of the right kidney, the right adrenal gland is also located lower. The right adrenal gland is pyramid-shaped and lies dorsal to the liver, the left is crescent-shaped and lies dorsal to the stomach and in close proximity to the spleen. The vascular supply of the adrenal glands is important. It consists of three arteries - superior suprarenal artery (branch of the inferior phrenic artery), middle suprarenal artery (branch directly from the abdominal aorta) and inferior suprarenal artery (branch of renal artery). Further, the arteries in the adrenal gland branch and form a plexus in the cortex of the gland, from which they flow into the veins of the medulla. The veins from the right adrenal gland join into the right suprarenal vein that flows directly into the inferior vena cava, on the left side the veins join into the left suprarenal vein that flows into the left renal vein.

### **Adrenal function disorders**

The adrenal gland consists of cortex and medulla. The cortex produces glucocorticoids and mineralocorticoids, while the medulla produces catecholamines. The hormonal secretion regulated by the adrenal cortex is ensured by ACTH from the adenohypophysis. The medulla is formed by postganglionic sympathetic neurons.

Cortical pathology - hyperfunction includes several syndromes. Conn's syndrome or primary hyperaldosteronism, is manifested by hypertension and mineral imbalance (hypokalemia and hypernatremia). Furthermore, Cushing's syndrome is overproduction of glucocorticoids and it manifests as centralized obesity, a crescent-shaped face, skin changes, especially purple striae and easy formation of hematomas, the development of osteoporosis and a variety of other symptoms. Another cortical pathology - hypofunction includes Addison's disease which means reduced production of aldosterone and cortisol. The symptoms include fatigue, weight loss, diarrhea, hypotension due to sodium loss and potassium accumulation.

The pathology of the adrenal medulla is pheochromocytoma, which is a rare neuroendocrine tumor. The tumor releases hormones that can cause various symptoms such as hypertension, palpitations, headache and other systemic manifestations. It can also occur in hereditary MEN II syndromes that cause tumors in various endocrine glands (medullary carcinoma of the thyroid gland, often bilateral pheochromocytoma, primary hyperparathyroidism or mucosal neuromas).

## **Diagnostics**

Adrenal tumor is often detected as an incidental finding on imaging during the investigation of another disease. We refer to these findings as so-called incidentalomas. Due to the development and availability of imaging methods, their incidence is increasing. It is mostly an unilateral pathology. The basic imaging method is nativ CT or MR. When detecting an incidentaloma, malignancy must always be excluded first. Smaller benign tumors without hormonal activity do not need further follow up. Borderline CT findings with normal hormone levels are indicated for CT follow-up. If the CT findings show malignancy or the tumor is hormonally active, then the adrenalectomy is indicated. Hormonal examination includes assessment of cortisol level, aldosterone level in the blood and possibly examination of metanephrines.

## **Adrenalectomy**

The surgical procedure of the adrenal gland is either unilateral, bilateral or partial adrenalectomy. Indication for the surgical treatment is made by an endocrinologist. The pathologies that are indicated for adrenalectomy include: CT tumors suspected of malignancy, findings that increase in size within a few months and hormone-producing findings. Another pathology of the adrenal glands can be metastases of other tumors, e.g. breast cancer, kidney cancer, or bronchogenic cancer. Today the gold standard is laparoscopic adrenalectomy. An open approach is indicated for bulky tumors and tumors with signs of local invasion.

## **Complication**

Like any surgical operation, adrenalectomy has its complications. The complications include for example, the wound infection, bleeding, or intraoperative injury to surrounding organs. Other complications may be related to the patient's internal comorbidities, or they may be directly related to the function of the adrenal glands such as hormonal imbalance, arterial hypertension or hypotension. A serious complication is an adrenal (Addisons) crisis, adrenal insufficiency with manifestation of symptoms as heart rhythm disorders, hypotension, tachycardia, abdominal pain, vomiting, weakness, dehydration.

## **Conclusion**

Adrenal tumors can cause abdominal discomfort, pressure pain in case of larger tumors or systemic symptoms depending on the hormones produced in hormonally active findings. Some adrenal tumors are detected incidentally on imaging examinations. If the indication criteria are met, an adrenalectomy is performed by the surgeon. Monitoring of patients with adrenal pathology is further done by endocrinologists.

## **DIAGNOSTIC METHODS IN UROLOGY . EXAMINATION, LABORATORY TESTS, ENDOSCOPIC AND IMAGING METHODS (39)**

Trinh Tuan, Fedorko Michal

Basic evaluation of a patient involves taking a detailed history and performing a physical examination.

### **1. Anamnesis**

Anamnesis (previous illnesses) entails a basic medical history. Emphasis is placed on the urological history, where we document information related to urological diseases and operations.

### **2. Clinical examination of the patient**

A complete and thorough physical examination is an essential part of the evaluation of patients with urological diseases. Correct execution helps to choose the appropriate diagnostic examination. The visual examination of the patient provides a general overview. We notice the colour of the skin (icterus, pallor), nutritional status (cachexia as a frequent symptom of malignancy, obesity as a possible manifestation of a hormonal disorder). This is followed by examinations focused in urology, typically on the abdomen, pelvis and genitals.

#### **2.1 Examination of the kidneys**

With the patient lying on his back, we perform the so-called bimanual palpation of the kidneys (Israeli's sign). Palpating the kidneys in men can be difficult due to the resistance of the back and abdominal muscles and a more fixed position than in women. Tapotement of the kidneys is an examination in which the doctor taps the kidney area with the edge of the palm. A positive finding (pain reported by the patient) is a symptom of inflammatory kidney disease or renal colic.

#### **2.2 Examination of the bladder**

The bladder can be felt or identified by percussion if it is filled with at least 150 ml. At a filling of around 500ml, the filled bladder is visible in slim patients as an oval bulge in the lower abdomen. Bimanual examination of the bladder is performed under general anaesthesia and is part of the examination to determine the extent of bladder tumours or other pelvic tumours (in men, we palpate the bladder between the abdominal wall and the rectum, in women between the abdominal wall and the vagina).

#### **2.3 Examination of the male genitalia**

When examining the penis, we retract the foreskin (if the patient is not circumcised) and examine the entire glans to exclude a tumour or balanoposthitis. If it is not possible to retract the foreskin, we recommend surgical correction (dorsal slit or circumcision). We note the position of the urethral orifice (hypospadias, epispadias) and changes on the penis (herpes simplex, condylomata, ulceration,

fibrous plaques in Peyronie's disease). Symmetrical enlargement of the scrotum may correspond to swelling due to anasarca or lymphedema in the case of lymphatic obstruction (e.g. after operations in the small pelvis, in endemic parasitic filariasis). Asymmetrical enlargement may be caused by involvement of the testis, epididymis or spermatic cord. It could be a hydrocele or a cyst of the epididymis, if it is outside the scrotum, it is necessary to think of a scrotal hernia. In a patient with epididymitis, it is difficult to distinguish between the testicles and the epididymis (orchioepididymitis), there is usually a painful induration, and the skin of the scrotum on the affected side is red and tense.

Resistance of the spermatic cord can be caused by funiculocoele (hydrocele of the spermatic cord) or varicocele (dilated veins of the pampiniform plexus).

A life-threatening condition is an infection of the soft tissues of the perineum, perianal area and external genitalia, the so-called Fournier's gangrene (necrotizing fasciitis), manifested by painful swelling on the genitals with necrotic areas of the skin and surrounding redness. Any solid resistance on the testis should be considered a malignant tumour until it is excluded. Resistances on the epididymis are almost always benign.

#### **2.4 Examination of the genitals and pelvis in a woman**

It is performed in the standard lithotomy position with abduction of the lower limbs. Evaluate the external genitalia and introitus (atrophic changes, erosion, discharge, condylomas). On the urethra, we can identify caruncles, cysts, urethral prolapse or a tumor. Furthermore, we can evaluate the severity of stress incontinence (Marshall and Froevius test).

#### **2.5 Rectal examination**

Digital rectal examination (DRE) is a basic examination method and the only way to examine the prostate, it is an integral part of a man's urological examination. It should be done for men over the age of 40. We perform a DRE at the end of the clinical examination after instructing the patient and with his consent. The most suitable is the standing position, when the patient bends over the edge of the examination bed with legs slightly apart, or the position on the knees and elbows. The normal prostate has the shape and size of an edible chestnut, with a groove in the midline, is elastic, smooth and painless. The consistency is similar to a contracted thenar. Of patients with prostate biopsy due to suspected DRV, 18% have prostate cancer. Any suspicious finding (hard nodule, asymmetrically harder lobe, prostate stone) on the prostate is an indication for biopsy. In inflammatory diseases, the prostate is palpably painful and boggy or is a palpable fluctuation in the presence of an abscess.

### **3 Laboratory examination**

#### **3.1 Examination of urine**

Physical (color, turbidity, specific gravity, osmolality, pH) and qualitative chemical examination of urine are among the basic examinations. A fresh midstream urine sample must be collected after genital hygiene (or disinfection) into a clean container. A urine sample can also be obtained by catheterization, it is routinely performed mainly in women, in some indicated cases in men. A urine dipstick test is a quick way to evaluate urine (pH evaluation, presence of blood, proteins, leukocytes, nitrites, glucose, etc.).

Urinalysis is a laboratory test involves chemical and microscopic analysis of urine sample, it is a more accurate examination. In a urological patient, we notice pH values do not depend only on the nature of the diet and individual metabolism, the physiological pH range of urine is between 4.5-7.0. For example, in the case of urinary infection with ureolytic bacteria, the pH of the urine is above 7.0. The specific gravity of urine indicates the ability of the kidneys to concentrate urine, a low value of the specific gravity (hyposthenuria) can be a sign of altered kidney function. In the sediment examination, we mainly evaluate the presence of erythrocytes and leukocytes. An abnormal amount of erythrocytes may indicate a higher permeability of the glomerular membrane, or bleeding in the urinary tract. The number of leukocytes with relation to the patient's dysuria symptoms indicates a possible inflammation of the urinary tract.

Microbiological examination of urine is an integral part of diagnostics. In the collected material, the microbiologist identifies the infectious agent and determines the pathogen's sensitivity to antibiotics, the so-called antibiogram. Prostatic secretion, ejaculate, urethral or any purulent discharge can also be sent for microbiological examination. For cytological examination of the urinary tract, urine can be obtained by spontaneous voiding or catheterization, or from the upper urinary tract during an endoscopic procedure. We use cytological examinations especially in the diagnosis or follow-up of uro-oncological patients.

### **3.2 Prostate-specific antigen (PSA) testing**

PSA is a protein produced in the prostatic tissue, is released from the prostatic epithelia and can be found in ejaculate and blood serum. Physiologically, PSA occurs in very small amounts in the blood. PSA is organ-specific, not tumour-specific. It increases with benign enlargement of the prostate or with prostate tumours. Values can be altered in case of urinary infections or when a urinary catheter is inserted. The level of PSA in the blood increases with age. PSA determination is used to detect the risk of prostate cancer early (typically in men aged 50-70 years) and to evaluate the effectiveness of treatment. Patients with a PSA value above 3ug/l should undergo an examination to rule out prostate cancer.

## **4. Endoscopic examination**

Endoscopy in urology enables the visualization of the urinary tract, from the external meatus to the renal calyces. Endoscopy requires irrigation fluid, a light source, and an endoscope.

#### **4.1 Urethrocystoscopy (UCSK)**

Endoscopy of the lower urinary tract is the most common procedure in urology. It is performed under both local and general anaesthesia, allowing examination of the urethra and bladder. The most common indications for UCSK are microscopic or macroscopic hematuria, recurrent urinary tract infections, persistent dysuria problems, urinary incontinence or urethral stricture. During the examination, flushing cytology, biopsies for histological examination, or retrograde ureteropyelography (UPG) and insertion of a ureteral stent can be performed. Another routine indication is the monitoring of patients diagnosed with non-invasive urothelial bladder cancer.

#### **4.2 Examination of the upper urinary tract**

The most common indications for examination of the upper urinary tract are management of urolithiasis, ureteral obstruction and the diagnosis of a tumour of the renal pelvis and ureter. It is performed using a ureterorenoscope (URS) exclusively under general anesthesia. Endoscopes have a working channel enabling the introduction of instruments, e.g. extraction forceps, laser fibers, ultrasonic or electrohydraulic lithotriptors. Nephroscopy is a percutaneous examination of the renal collecting system. Nephroscopy is used for treatment of large kidney stones over 2 cm (percutaneous nephrolithotripsy - PCNL).

### **5. Imaging examination**

Ultrasonography (US) is a basic imaging method in urology. With ultrasound, a urologist most often examines the kidneys, bladder, prostate and scrotal organs. A whole range of interventions are performed using ultrasound (e.g. introduction of nephrostomy, puncture and drainage of cysts or abscesses, introduction of epicystostomy, prostate biopsy, etc.). Non-contrast CT of the urinary tract is the method of choice when renal colic is suspected, if we want to confirm or rule out the presence of urolithiasis. CT urography (with the administration of an iodine contrast agent) is mainly used to investigate hematuria, recurrent infections and tumours of the kidneys or urinary tract. Another option is magnetic resonance imaging. At present, the most common indication for magnetic resonance imaging is prostate examination, in the case of suspicious findings, the patient is indicated for targeted fusion biopsy of the prostate. Other imaging tests include urethrocytography, retrograde or antegrade pyelography and nuclear medicine scans (phase scintigraphy of the kidneys, bone scintigraphy). State-of-the-art PET/CT or PET/MR are reserved for uro-oncological indications, mostly within the re-examination and follow-up of patients with prostate cancer.



## ARTERIAL ANEURYSMS (12)

Novotný Tomáš

### 1/ definition

An arterial aneurysm is an enlargement of the diameter of an artery by at least 50% of its normal size. It can affect any artery, but there are predilection sites: the abdominal aorta (up to 8% of the population of age 65+) and its main branches, the popliteal artery, the visceral arteries (most commonly the splenic artery), and the large intracranial arteries (Intracranial aneurysms are not the subject of this chapter). In other arteries, aneurysms occur sporadically.

### 2/ etiology

The etiology is multifactorial. The strongest risk factors are genetic risk, hypertension, dyslipidemia, smoking, atherosclerosis (but it is not a pathogenetic factor), age, male sex, race, infection, arterial injury, and hereditary connective tissue disorders.

### 3/ pathogenesis

The vast majority of aneurysms are of degenerative type. The pathogenesis is a complex process, and little is known about its details. In general, there is a progressive disruption of the structure and function of the layers of the vascular wall, especially the media, and adventitia. The consequence of the loss of wall strength is a gradual progressive widening of the given arterial segment. Other types of aneurysms with different pathogenesis are less common.

## 4/CLINICAL MANIFESTATION

### a) clinical symptoms and signs

The vast majority of aneurysms are asymptomatic and are discovered accidentally. Lean individuals may find a pulsating mass in the abdomen or limb. In a small group of patients, manifestations may be due to the pressure of the aneurysm on the surrounding area, e.g. pain, and swelling. Other symptoms are usually caused by aneurysm complications.

Signs depend on the location and size of the aneurysm. Abdominal aortic aneurysms can be palpated in thinner individuals, usually as a pulsatile resistance to the left of the umbilicus. In obese individuals, they are not so easily palpated. An aneurysm of the popliteal artery is also usually palpable, but again with the limitation in overweight patients. Visceral aneurysms are difficult to find during physical examination.

### b) paraclinical investigations - laboratory, imaging, and functional testing

Of the paraclinical examinations, imaging is the main one used for accurate diagnosis and decision-making. Ultrasonography is an inexpensive, radiation-free examination that can confirm the aneurysm in most patients. Often, aneurysms are detected during examinations indicated for other

diseases. CT angiography is the gold standard for treatment decisions. This imaging modality provides the most accurate morphological information. The contribution of magnetic resonance imaging for the diagnosis and management of vascular disease is lower - the examination is more expensive, less accessible, and has numerous artifacts. Digital subtraction angiography might be limited for the diagnosis of aneurysms by the presence of an intraluminal thrombus, so the aneurysm may not be visualized at all on the scan.

#### 5/ course of the disease

Most aneurysms develop during a lifetime, with their formation and enlargement taking place over a period of years, and therefore usually affect older patients. A large proportion of them remain asymptomatic throughout life. However, some patients develop complications.

#### 6/ complications

Rupture of the aneurysm and life-threatening bleeding is the most serious and common complication. It is a typical complication of aneurysms located in the abdominal and thoracic cavity. The usual symptom triad for abdominal aortic aneurysm rupture is abdominal pain, pulsatile abdominal mass, and shock. Bleeding from visceral aneurysms manifests similarly, except that these aneurysms are usually not palpable.

Peripheral embolization is another complication. It is typical for limb aneurysms - mainly aneurysms of the popliteal artery. This aneurysm rarely ruptures and bleeds, but its early treatment is necessary because of the risk of successive embolization into the tibial arteries and its subsequent closure with limb loss. Embolization as a complication of abdominal aortic or pelvic artery aneurysm is less common. The clinical manifestation varies from asymptomatic to acute lower extremity necrosis to chronic critical limb-threatening ischemia or acute limb ischemia.

Aneurysm thrombosis may be a separate complication where major arteries remain patent distally to the aneurysm or final thrombotic closure of the aneurysm in the absence of outflow after its closure by emboli. The clinical picture may vary from asymptomatic, through variable chronic ischemic symptoms, to acute ischemia of the limb.

#### 7/ prognosis

The prognosis of the disease is determined by the size of the aneurysms, the location, and especially the complications. Small asymptomatic aneurysms with no or minimal intraluminal thrombus usually do not develop complications. Large aneurysms and aneurysms with intraluminal thrombus, on the other hand, represent serious diseases with a high risk of life-threatening bleeding or possible lower limb loss.

## 8/ differential diagnosis

In the differential diagnosis, tumors at intra-abdominal localization should be considered in the first place in clinically diagnosed pulsatile resistance. In popliteal aneurysms, the Baker's cyst should be considered. Ultrasonography or CT angiography as the main diagnostic method will safely differentiate the conditions.

## 9/ TREATMENT

Small aneurysms that are not treated by intervention are monitored at regular intervals using imaging methods (ultrasonography, CT), usually annually. There is no drug treatment for the disease. Risk factor modification such as treatment of hypertension, treatment of dyslipidemia, and smoking cessation is recommended.

Interventions are performed based on indication criteria that are specific to each site.

### Abdominal aortic aneurysm

The indication margin for elective intervention for abdominal aortic aneurysm is an aortic diameter of 55 mm. When this size is reached, the patient's health status should be considered in terms of perioperative risks and aneurysm repair may be offered. Recent data show that the risk of aneurysm rupture below this threshold is up to 3 times higher in women than in men. Therefore, in women, intervention can be considered as early as 50 mm in diameter. However, it must also be taken into consideration that aortic aneurysm interventions in women are associated with twice the mortality rate according to the available evidence. The available data do not allow analysis of the cause, but it is suggested that age may be a factor, as aortic aneurysms in women reach a clinically relevant size at an older age.

The treatment options are: 1) open surgery - resection of the aneurysm and aortic replacement with an artificial vascular prosthesis, 2) endovascular surgery - implantation of an aorto-iliac stent graft. Only in a few centers in the world, resections are performed laparoscopically or robotically.

Open surgery is burdened with slightly higher periprocedural mortality and morbidity, but it is a better method in terms of long-term results (a large number of stent graft complications occur 8-10 years after implantation). Therefore, recent guidelines from the European Society for Vascular Surgery recommend that open surgery should be preferred in patients with a life expectancy of more than 10-15 years and endovascular surgery in older patients with a life expectancy of less than 10 years. Patients with a short life expectancy of less than 2 years (terminal stages of cancer, etc.) should be managed conservatively.

Planned procedures in asymptomatic patients should ideally be performed within 2 months of indication, as recommended. Symptomatic patients are managed acutely after the necessary preoperative preparation. Patients with aneurysm rupture are operated urgently.

### Aneurysm of the popliteal artery

The indication threshold for elective surgery is a diameter of 2 cm (to prevent thromboembolic complications and limb loss). In high-risk patients, surgery may be delayed up to 3 cm in diameter. However, if an intraluminal thrombus is present, the aneurysm should always be treated, even if the diameter is less than 2 cm. Surgical management has two options: 1) replacement of the popliteal artery with a venous graft or exclusion of the aneurysm (ligation of the inflow and outflow arteries) and venous bypass. Endovascular options for treatment are very limited in this aneurysm. In case of acute ischemia, the procedure is urgent (see Acute arterial occlusions).

### Aneurysms of visceral arteries

The indication thresholds for visceral aneurysms are not supported by strong evidence. Generally accepted indication margins are 3 cm for splenic and renal artery aneurysms and 2 cm for other visceral arteries. The approach is individual according to morphology and is performed using an open procedure or endovascularly. Ruptures of visceral aneurysms are managed as acute abdomen.

### 10/ prevention

Prevention options are very limited due to the unknown pathogenesis. Prevention and treatment of risk factors is recommended. In some European countries, screening for abdominal aortic aneurysms at the age of 65 years and older has been introduced.

## PERIPHERAL ARTERIAL DISEASE OF LOWER EXTERMITIES (13)

Kysela Petr

Introduction: There are roughly 1/3 of people dying of malignant tumours and nearly 2/3 (i.e. twofold more) of cardiovascular diseases in the civilised world. The peak incidences of both diseases fall in the same age group – above 65 years.

Aetiology and risk factors: Peripheral arterial disease (PAD) comprises the occlusive and the non-occlusive diseases. Solution to non-occlusive ischaemia can be tricky with unpredictable outcomes. The **non-occlusive** group contains namely A-V fistulas (steal, high output heart failure), aneurysms (thrombi formation, embolisation, rupture), medial sclerosis (inability to open collaterals) and compression syndromes (TOS, popliteal artery entrapment). The **occlusive** diseases comprise atherosclerosis in more than 90 %, cystic adventitial degeneration (i is not to be treated endovascular), vasculitides (including Buerger's one related to tobacco abuse), fibromuscular dysplasia of the external iliac artery in sportsman (bikers), vasoneuroses (vibrating tools, back pain), and Raynaud's syndrome (known underlying disease) or Raynaud's phenomenon (not known underlying illness). It is atherosclerosis that causes the occlusive ischaemia the most often. It develops due to vessel wall trauma by high blood pressure and sharp pulses, leading to vessel wall inflammation. That is why it affects mainly arterial forks and mechanically traumatised parts of arteries (heart ligaments, Hunter's canal orifice). In addition, blood pressure in the lower extremities is higher by 20%. Their diameter is also larger on top of that. It leads to much higher wall tension (i.e. trauma). **Risk factors** include (in their significance order) smoking, diabetes, hypertension, hyperlipoproteinemia, thrombophilia, and increased CRP. **PAD revascularisation thus needs no one but diabetics and smokers.** Conventional smoking is even more harmful as it blocks the binding capacity of Hb to O<sub>2</sub> due to irreversible poisoning with CO.

Epidemiology: The incidence of lower limb ischaemia is estimated at 50-100 / 100.000 per year. Its prevalence symptomatic is around 12 %. 50 % of patients suffering from critical limb ischaemia survive less than 6 years (quite a malignancy). Similarly, cerebral stroke incidence reaches about 195 / 100.000 in Europe, being the 2nd most frequent cause of death after myocardial infarction – 1.1 million a year in Europe. Cerebral haemorrhage is to be blamed in 10 – 20 % 10 – 20 % Mesenteric ischaemia comes out in 3-9 / 100.000 a year. However, its mortality reaches 93 %.

Symptoms: Pain upon strain is the main sign of ischaemia. In the case of, for example, diabetic neuropathy, pain needn't be expressed. If this is the case, pain is substituted with weakness/loss of function upon strain or development of necroses. Differential diagnosis is VERY complex.

Symptoms of ischaemia arise due to the depletion of energetic sources (glycogen consumption and

lack of glucose) and toxic waste gathering, rather than the absence of oxygen. The purvey of glucose is fundamental to maintaining the Krebs cycle, which breaks down and stops the neutralisation of free oxygen radicals.

Examination: Medical history of worsening claudications – i.e. blunt pain or weakness and loss of function of the affected region upon constant dynamic strain. On the contrary, entrapment of the popliteal artery leads to pain upon static foot plantar flexion. Neuropathic hot and sharp pain usually appears during the night.

**Physical examination** contains palpation of pulsations and auscultation of all main arteries. The presence of pulsations at the very periphery completely excludes significant occlusive disease. The murmurs do not correspond to the significance of stenoses. Skin colour changes represent late symptoms and need not correspond to ischaemia. Open skin collaterals may belay the chronic mainstream arteries occlusion. There is vasoconstriction in healthy skin.

According to the **blood tests**, the D-dimer (**DD**) elevation may point to ongoing acute thrombosis. There is no other specific marker to prove acute ischaemia. Lactate and acidosis are late signs of a generally bad medical condition (shock). Chronic elevation of **CRP** and **ANCA** supports the diagnosis of possible vasculitis if it fits the clinical appearance.

The first choice imaging method should be the Doppler ultrasound (US), with a sensitivity of 88 % and specificity of 96 %. It provides information about the location and degree of stenoses and visualises A-V fistula or dissection. US measures ankle pressure or toe pressure and ankle-brachial index (ABI). CT angiogram is necessary whenever one thinks of some revascularisation (sensitivity of 90 %). MR angiogram is mandated in patients allergic to iodine contrast medium. Digital subtraction angiography (DSA) usually serves as a treatment method.

Therapy: **1.) Lifestyle rearrangements** in all patients and as prevention: Absolute smoking cessation is necessary, including alternative ways (VAP, heated tobacco) due to the direct toxic effect of nicotine on the endothelium and vessel wall. These means include an appropriate diet, more aerobic exercises – 30 minutes of active walking daily and fighting hypertension and diabetes (mind gluconeogenesis blocking agents which may worsen existing diabetic ulcers).

**2.) Pharmacotherapy** in all symptomatic patients: Antiplatelet drugs – acetylsalicylic acid (ASA) is the cornerstone of the treatment. Addition (dual antiplatelet therapy) or switching to ADP P2Y<sub>12</sub> receptor blockers (clopidogrel, ticagrelor), GP IIb/IIIa inhibitors (fibans, abciximab) in case of drug resistance or specific cases, may be indicated. Vasodilating agents and rheologics can be offered to highly symptomatic, non-revascularizable patients, along with beta-blockers withdrawal (due to their vasospastic effect). These include pentoxifylline, naftidrofuryl, nicotinic acid (niacin) or capillary antithrombotic agents like sulodexide, namely in diabetic microangiopathy. Critical chronic limb

ischaemia can improve after a series of intravenous prostaglandin E1 as salvage therapy in patients with rest pain without necroses. Hypolipidemic drugs are used as a secondary prevention. Blood thinning medication is not routinely indicated in PAD. An angiologist is responsible for the treatment.

**3.) Endovascular treatment:** Seldinger access to vessels through well-compressible arteries (common femoral, radial or cubital arteries) inserts a sheath as a way for catheters and other instruments. It is possible to perform local thrombolysis, mechanical thromboaspiration and percutaneous balloon transluminal angioplasty (PTA). Placement of stents may sometimes be necessary. Drug-eluting balloons and stents (DEB, DES) can be used when re-des are needed or in very tiny arterioles (paclitaxel, everolimus). An interventional radiologist or interventional angiologist is in charge here. Thorough antiplatelet medication is required after procedures. It is very often dual (ASA + clopidogrel). Endovascular methods should be favoured in treating the aortic arch and its branches, intracranial and visceral arteries, and small arteries at the very periphery of limbs. Carotid artery stenting (CAS) is not deemed the treatment of choice and should be limited to specific cases. CAS must always use distal protection to prevent cerebral embolisation.

**4.) Surgical revascularisation:** A vascular surgeon performs it after gaining direct access to target vessels according to underlying pathology. He may do a thrombectomy, direct or indirect. Plaque removal can be achieved either directly or distantly. The narrow part of an artery can be enlarged with a patch, i.e. arterioplasty. However, the typical is bypass surgery. According to the material used, we recognise autologous (great saphenous vein), allogenic (aortoiliac graft) or artificial (část or knitted) bypasses. Anatomic bypasses accompany bypassed arteries, whereas non-anatomic ones connect naturally directly not connected arteries. Nearly all surgical procedures on vessels start with a shot of heparin (100 IU/kg of body weight) and may but needn't be terminated with protamin. As its effect is anticoagulation, it must not be administered excessively.

Combining the endovascular and open approach at once may bring about certain advantages – so-called hybrid procedures. They are better to be performed in the hybrid operating theatres.

**5.) Sympathectomy** as additional therapy: It is the upper thoracic sympathectomy or alternatively US-guided stellate ganglion blockade on the upper extremities. One can perform CT-guided coeliac ganglion lysis in cases of visceral ischaemia. We can offer retroperitoneal lumbar sympathectomy or CT-guided sympathetic blockade on the lower extremities. It is of little effect in diabetic patients.

**6.) Hyperbaric oxygen therapy** is not indicated

Classification: As elsewhere, any classification should mirror either treatment or prognosis. The invasivity of treatment is chosen according to **clinical classification** according to **Fountain or Rutherford** (the latter developed two classifications – one for acute and one for chronic ischaemia).

The higher the clinical stage, the shorter the survival rate. **Morphologic TASC** (TransAtlantic interSociety Consensus) criteria guide decision-making between endovascular and open approaches. Carotid artery endarterectomy (CAE) is the only surgery that is also indicated according to the complication rate of the particular surgeon. Asymptomatic stenoses can be intervened, given the complication rate below 1.5 %. If the complication rate falls between 1.5 and 3,0 %, it is allowed to operate on symptomatic stenoses only. If the rate is 3.0 – 4.5 %, only both-sided stenoses on the symptomatic side can be treated. If you have more than 4.5 % of complications, you should not operate on carotid arteries at all. The indisputable indication of CAE is represented by symptomatic stenosis of more than 70 % or even asymptomatic one of more than 60% if the plaque is unstable/risky. The **ABCD2 score** gives timing. Treatment of ischaemic wounds is guided by the **WIFI score** (Wound, Ischaemia, Foot Infection).



Modified Font ain's clinical classification

Class	Symptoms	Ultrasound
I	N symptoms	ABI usually > 1,0
II	a	Claudication more than 200 m
	b	20 – 200 m
	c	less than 20 m
III	Rest pain – non-critical	Ankle pressure 50 mm Hg
	Rest pain - critical	Ankle pressure 50 mm Hg
IV	a	Necrosis – non-critical
	b	Necrosis - critical

Classification of cerebral ischaemia

Transitory ischemic attack TIA	Symptoms disappear within 24 hours –no detectable ischaemia on CT or MRI
Minor stroke	National Institute of Health Stroke Scale <= 3
Completed stroke	Detectable ischaemia, more than 24 hours
Stroke in evolution	Symptoms progressively worsen over time
Crescendo TIA	Periods between two following TIAs get shorter, or symptoms get worse

ABCD2 Risk of Stroke after TIA

<b>A</b> ge	>60	1
<b>B</b> P	>140/90	1
<b>C</b> linical	Paresis	2
	Fatic imp.	1
<b>D</b> uration	10min-1h	1
	More 1h	2
<b>D2</b> =	DM	1
Sum A + B + C + D + D2 = ABCD2		

Timing of carotid endarterectomy after TIA

ABCD2	7-days risk of stroke
6	24 – 31 %
5	12 %
4	1-9 %
3	0 %
6-7	2-days risk of stroke = 8-10 %
ABCD 0-3 delayed, ABCD 4-5 early,	
ABCD 6-7 acute surgery.	

## **ACUTE LIMB ISCHEMIA (14)**

Novotný Tomáš

### 1/ definition

Acute arterial occlusion is the blockage of flow through a peripheral artery, resulting in ischemia of the supplied body part. The subject of this chapter is acute occlusions of the large arteries of the systemic circulation, of which the most common are acute occlusions of the limb arteries, especially in the lower. Acute occlusions of organ arteries are a separate topic.

### 2/ etiology

The cause of arterial occlusion may be embolism, thrombosis, or injury (including iatrogenic).

### 3/ pathogenesis

In embolism, the artery is occluded by a piece of material (embolus). The most common embolus is a thrombus, the source of which is usually the heart. Other possibilities are atherosclerotic masses from feeding arteries, tumor fragments, amniotic fluid, or foreign bodies (including, e.g. broken-off instrument parts). The embolus is carried by the bloodstream to a point where its size no longer allows further movement and it occludes the artery at this point. Arterial thrombosis most often occurs at the site of an atherosclerotic lesion due to reduced blood flow or plaque complications. The risk increases dehydration, hypercoagulable states, or shock. However, it can be caused by other arterial pathologies such as aneurysms, vasculitis, etc. In trauma (including iatrogenic), the arteries might be transected or their internal layers are injured with subsequent dissection and closure. The consequence is impaired blood supply to the tissues, anaerobic metabolism, and tissue necrosis. When blood flow is restored after a prolonged period, reperfusion injury adds to the ischemic damage.

### 4/ CLINICAL MANIFESTATION

#### a) clinical symptoms and signs

The patient's complaints are variable, ranging from asymptomatic to symptoms of severe acute ischemia. It depends on several factors: the size of the artery, the size of the area supplied, and the collateral circulation. In symptomatic ischemia, patients complain of pain and coldness of the limb, tingling or numbness of the limb, and later the inability to walk.

Objectively, the limb is cold and pale, peripheral pulses are absent, and there is a gradual impairment of the sensory and motor function of the periphery of the limb (numbness and motor dysfunction of fingers, then the same at the ankle level, etc.). However, sensory and motor dysfunction may affect larger limb parts if the arterial closure is proximal to the groin.

The clinical picture can be memorized using the so-called 'six Ps': 1) Pain, Pulselessness - absence of peripheral pulses, Pallor - initially with insufficient blood flow but may progress to cyanosis, Poikilothermia - coldness, Paresthesia - tingling (gradually changes to anesthesia progressing from the periphery of the limb), Paralysis - impaired movement, inability to control the limb (the disability progresses from the periphery of the limb towards center too).

Acute limb ischemia is classified into grades according to Rutherford classification (Table 1).

b) paraclinical investigations - laboratory, imaging, and functional testing

When acute occlusion of a limb artery is suspected, potassium levels are important among laboratory tests, as well as creatine kinase and myoglobin levels. Creatine kinase is not as specific as myoglobin, so we usually determine both values at the initial stage. Creatine kinase alone can be used later while treating reperfusion syndrome (lab test is cheaper).

Among imaging methods, ultrasonography may be used. However, CT angiography is always the main imaging modality in acute limb ischemia. This examination is performed in virtually all patients except those with aortic thrombosis and sometimes in clinically highly probable cases of embolism, especially in the upper limbs. The examination will provide the most accurate diagnostic information to choose the correct management. It should also be mentioned that, due to the aging of the population, patients with embolism tend to have concomitant atherosclerosis, which may influence the choice of adequate treatment. Other imaging modalities are rarely used in the diagnosis of acute ischemia.

5/ course of the disease

The course of the disease in symptomatic patients varies depending on the collateral vessel and the localization and type of occlusion. It generally takes place within a few units of hours. It begins with pain and coldness of the limb, which is gradually joined first by impaired sensory function and then by impaired motor function. In the most severe forms, immediate treatment is required, as revascularization within 6 hours of the onset of ischemia is needed to save the limb and its function.

6/ complications

The most severe complication of acute limb ischemia is loss of life or limb because of late or inadequate treatment. Most affected patients are polymorbid.

The typical complication in prolonged ischemia (more than 6 hours) is the postoperative development of compartment syndrome. It occurs after successful revascularization (usually within hours). The only possible solution is to perform decompressive fasciotomy. For more details, see the chapter Compartment syndrome.

After prolonged ischemia and revascularization, reperfusion syndrome should be expected. It is caused by the washout of potassium, myoglobin, toxic metabolites, inflammatory mediators, and oxygen radicals from the ischemic limb. It leads to metabolic acidosis as well.

#### 7/ prognosis

The prognosis is given by the extent and severity of ischemia as well as the patient's medical condition and comorbidities. In the most severe cases, the patient might lose the limb or die (usually because of reperfusion syndrome or due to other complications).

#### 8/ differential diagnosis

In the differential diagnosis, we try to differentiate clinically between embolism and thrombosis. In embolism, the onset of ischemia is usually sudden, patients tend to be younger, have a known potential source of embolism, have no history of lower limb ischemia and peripheral pulsations are usually present in the contralateral extremity. In thrombosis, the onset is more gradual, the patients are older, have no known source of embolism, have a history of claudication, and pulsations are absent even on the unaffected limb. However, it must be said that in reality, cases of embolism may occur in patients with peripheral arterial disease of the lower limbs and thrombosis can also occur in patients without a history of ischemia and with cardiac arrhythmia. Therefore, the distinction is often not easy. Among other diseases, the possibility of vertebrogenic disorders should be considered.

#### 9/ TREATMENT

Initially, full anticoagulation is appropriate unless contraindicated. Unfractionated heparin should be preferred and applied as early as possible to prevent the progression of thrombosis. Other measures are supportive - painkillers, oxygen therapy, and hydration.

Conservative management is possible only in a minimum of cases, and most often when a patient refuses care. Treatment options can be divided into surgical and endovascular. The timing of the procedure must correspond to the severity of the ischemia. Stages I and IIa should be treated within hours. For stage IIb, immediate revascularization is necessary. In irreversibly affected limbs, only amputation is possible.

The surgical methods used are embolectomy or thrombectomy with a Fogarty catheter. In this procedure, a long catheter with a balloon at the end is introduced into the exposed artery in the groin or other access site. If we can pass the catheter through the site of the artery occlusion, we then inflate the balloon and use it to remove thrombi and emboli from the arteries as we pull out the catheter. If this procedure is not successful, we choose other revascularization options - endarterectomy (removal of the plaque at the site of the occlusion), or bypass (creating a new path for blood over the occlusion with a vein or vascular prosthesis). In trauma, we use the same

reconstructive methods with the specificity of using artificial implants only as a last resort because of the risk of infection.

Among endovascular methods, intra-arterial thrombolysis is possible. This involves the injection of a thrombolytic agent (usually alteplase) into the blood clot using a microcatheter inserted into the artery. Systemic thrombolysis is not effective for limb occlusions. This procedure is possible in patients with ischemia I and IIa (the usual time required for clot dissolution is 24-48 hours) and needs judicious indication when the outflow tract distally to the occlusion is patent. The procedure may be complicated by peripheral embolization of dissolved clots, which is subsequently difficult to manage. An endovascular method that is adequate in speed to surgical revascularization is aspiration or mechanical thrombectomy. Its use is limited mainly by the availability of equipment and interventionalists outside working hours.

Reperfusion syndrome treatment should be considered a part of the management. Potassium levels (dialysis may help) and myoglobin levels must be monitored. The only way to get myoglobin out of circulation (and prevent kidney damage) is forced diuresis. The patient is given continuous furosemide and infusions to achieve a urine production of about 250mL/hr.

10/ prevention

Prevention of embolism is provided by proper medical management of patients with a known source of embolism. Prevention of thrombosis in patients with peripheral arterial disease is by medication (antiplatelet therapy, statins). Treatment of patients with coagulation disorders is also prevention. Prevention of traumatic ischemia is ensured by general injury prevention at all social, occupational, and other levels.

Grade	Prognosis	Sensory function	Motor function	Doppler signal – arterial	Doppler signal – venous
I	Viable limb	+	+	+	+
IIa	Limb marginally threatened – prompt treatment	+/-	+	+/-	+
IIb	Limb immediately threatened – immediate treatment	-	+/-	-	+
III	Limb irreversibly damaged	-	-	-	-

Table 1. Acute Limb Ischemia Classification (adapted from Rutherford RB. Clinical Staging of Acute Limb Ischemia as the Basis for Choice of Revascularization Method. 2009)

## TREATMENT OF VARICOSE VEINS (15)

Vaverka Vítězslav, Štefela Horváthová Erika

**Varicose veins of the lower limbs** represent a common condition, in which the superficial veins (epifascial) become dilated, predominantly on the lower limbs. These veins, as part of the capacitive bloodstream, are often visibly enlarged, twisted and protrude above the surface of the skin, often with a blue-violet discoloration.

**Etiology:** the most common cause of varicose veins is an insufficiency of venous valves, which under normal circumstances prevent blood from flowing backwards (**reflux**). If the valves do not function properly, blood accumulates in the veins and causes their expansion. Other important causes include pressure transfer from the deep venous system localised at so-called **junctions** and hydrostatic pressure. The main risk factors are genetic disposition, prolonged standing, obesity, pregnancy and hormonal changes. With increasing age and sedentary lifestyle, the risk of developing varicose veins increases. The incidence increases with age, while in younger adults (20-30 years) the incidence can be 5-10%, in people over 60 it can be up to 50% and more. Women are more prone to developing varicose veins than men, the incidence in women is estimated at 25-33%, while in men it is 10-20%. In developing countries, the incidence is generally lower.

**Division of the venous systems of the lower limbs:** proper understanding of the varicose veins problematic requires knowledge of the venous systems of the lower limbs, which are divided into a superficial system, a deep system and their connection (perforators), which are direct and indirect.

**The superficial venous system** is located just under the skin and drains about 10% of venous blood from the lower extremities. The main veins are **the great saphenous vein** (vena saphena magna, VSM), which originates at the medial ankle and runs along the inside of the leg to the groin, where it flows through the saphenofemoral junction (SFJ) into the deep system. **The small saphenous vein** (vena saphena parva, VSP) begins at the lateral ankle and continues along the back of the calf to the region of the popliteal fossa, where it empties into the deep system via the saphenopopliteal junction (SPJ). **The deep venous system** drains approximately 90% of the venous blood and includes veins such as vena femoralis (the main vein of the thigh), vena poplitea (vein in the popliteal fossa), vena tibialis anterior and posterior (veins of the lower leg) the vena peronea (vein running along the calf bone). **The connector veins (perforators)** are veins that connect the superficial and deep venous systems and ensure the one-way flow of blood from the superficial to the deep system. The most known perforators are **Dodd's** (in the thigh), **Boyd's** (in the knee area) and **Cockett's perforators** (in the lower leg).

**Classification of varicose veins:** varicose veins are classified using the **CEAP classification** (Clinical, Etiological, Anatomical, Pathophysiological). **C0:** no visible or palpable signs of venous disease. **C1:** spider veins (telangiectasia) or reticular varicose veins. **C2:** true varicose veins. **C3:** swelling of the lower extremities without skin changes. **C4:** skin changes caused by chronic venous insufficiency (pigmentation, eczema, lipodermatosclerosis). **C5:** healed ulcer. **C6:** active venous ulcer.

Varicose veins are further divided into **primary** and **secondary**: primary varicose veins arise independently, without connection to another disease. They are most often caused by congenital weakness of the vein wall or valves, while prolonged standing, pregnancy and obesity contribute to their development. Secondary varicose veins are result of another condition, such as chronic venous insufficiency or deep vein thrombosis. In these cases, the venous system is damaged, which leads to the development of varicose veins. **Morphologically**, varices can be of different shapes and sizes. Some are fine and thin (reticular), while others can be large, coarse, and prominent. Changes in the vein wall include thinning of smooth muscle layer, loss of elasticity, and changes in connective tissue.

**Treatment:** treatment of varicose veins can be **conservative** or **invasive**. **Conservative treatment** includes wearing compression stockings to improve venous return and reduce swelling. Lifestyle changes such as increased physical activity, weight reduction and avoidance of prolonged standing, venotonics are also recommended. **Invasive treatment** includes various **surgical** and **non-surgical** methods. A high-quality ultrasound examination and mapping of the pathology is very important. Traditional surgical treatment, such as **crosectomy** of the saphenofemoral/-popliteal junction, or possibly another source of reflux (perforator) and **stripping** (removal of the vein), is now often being replaced by less invasive procedures such as laser and radiofrequency **ablation** or **sclerotization**, in which the lumen of the affected veins is injected with a substance causing damage to the endothelium and resulting in its closure.

**Prevention:** Varicose vein prevention is key, especially for those at increased risk. Regular exercise, avoiding prolonged standing and sitting, wearing compression stockings and maintaining a healthy weight are recommended. Maintaining an active lifestyle and weight control can make a significant contribution to preventing and delaying the development of varicose veins, especially in people with genetic predispositions.

## GOITRE, SURGERY OF THYROID GLAND (17)

Ivanecká Dominika, Linhartová Marcela

The **thyroid gland** is an endocrine gland. Thyroid cells produce the hormones triiodothyronine (T3), tetraiodothyronine, i.e. thyroxine (T4) and calcitonin, produced by parafollicular cells. The diagnosis of functional disorders is dealt with by the branch of internal medicine, endocrinology. Functional disturbances caused by inflammation or neoplasia then lead to morphological changes in the thyroid gland, especially its volume increase. The enlargement of the thyroid gland is called a goiter. The indication of a patient for thyroid surgery is therefore dependent on close collaboration between the endocrinologist and the surgeon. A fully examined patient is indicated for surgery by the endocrinologist, the final procedure is then modified by the surgeon according to the perioperative findings. The basic examination consists, in addition to the history and clinical examination, in the determination of thyroid hormone levels and ultrasound examination. If the ultrasound shows the presence of nodules or diffuse volumetric enlargement of the thyroid gland, further investigation is indicated. For suspicious nodules, the endocrinologist performs a needle aspiration biopsy with the aim of cytological examination of the collected sample. Cytological findings are then evaluated according to the Bethesda classification, which establishes diagnostic categories, their risk of malignancy and recommends algorithms for further therapeutic management. In the case of large goiter extending retrosternally, the addition of a native CT scan of the chest is necessary. At the time of surgery, the functional thyroid disorder must be medically compensated to normal (eufunction). According to the size, there are 4 grades of goiter (Bavarian classification): 0: neither visible nor palpable, enlargement is only demonstrated on ultrasound, I: palpable, visible only when the head is tilted, II: visible enlargement, III: goiter oppressing the surrounding organs.

Depending on the cause of thyroid enlargement we distinguish goiter: 1. endemic - caused by iodine deficiency in the diet, 2. thyrotoxic - caused by an autoimmune disease M. Basedow, 3. malignant - caused by tumor 4. inflammatory.

According to morphology, goiter is divided into diffuse (homogeneous parenchymatous enlargement) and nodular.

### **Indications for thyroid surgery are:**

**Polynodous eufunctional goiter** - caused by iodine deficiency in the diet. The earliest diffuse enlargement gradually progresses to nodular remodeling. Initially asymptomatic, with increase in volume oppression of surrounding structures occurs, especially the trachea, manifested by dyspnoea, hoarseness and swallowing disorders. If the enlarging thyroid gland propagates to the mediastinum, we speak of retrosternal goiter.



## **Functional disorders:**

### **Hyperfunction:**

*Graves-Basedow disease* is an autoimmune disease caused by the production of stimulatory autoantibodies against TSH receptors, resulting in increased production of thyroid hormones and volumetric enlargement of the gland. Typical symptoms of Merserburg's triad are: tachycardia, goiter and exophthalmos. The mainstay of treatment is thyreostatics, in the case of tachycardia beta-blockers. If conservative treatment is unsuccessful, thyroidectomy is indicated.

*Toxic adenoma* - a nodule of the thyroid gland, which produces hormones at an increased rate. It does not manifest with exophthalmos, otherwise symptoms and treatment are similar to Graves-Basedow disease

**Hypofunction:** treated with hormone replacement, not an indication for surgical intervention

### **Inflammation:**

**Acute** - bacterial or viral, surgical intervention only in case of abscess

### **Chronic**

*Hashimoto's goiter* - an autoimmune disease caused by antibody production resulting in lymphocytic infiltration of the gland, clinically manifested by hypofunction. Indicated for thyroidectomy only when oppressed, represents a risk factor for carcinoma.

*Riedl's goiter* - fibrous transformation of the gland with signs of compression

### **Malignant goiter - Tumors of the thyroid gland:**

**Benign tumors** - adenomas, may be eufunctional, manifesting as oppression, or may be toxic adenomas, inducing a state of hyperthyroidism. Surgical treatment is indicated if they grow or cytological examination shows cellular atypia.

**Malignant tumours** - 99% of malignant tumours are carcinomas

**Differentiated carcinomas** - have preserved iodine uptake capacity. This can be used in adjuvant radioiodine therapy after total thyroidectomy. At the same time, suppressive thyroxine therapy is administered postoperatively. Differentiated tumors have a good prognosis, with long-term survival of 90% of patients.

*Papillary carcinoma* - typical of childhood and adulthood. Metastasizes to lymph nodes

*Follicular carcinoma* - is more common between the ages of 50-60, in women, invades the surrounding area and blood vessels

**Undifferentiated carcinomas** - have no ability to uptake iodine, are aggressive, grow rapidly and metastasize early. They have a poor prognosis.

*Anaplastic carcinoma* - occurs in older people, significantly poor prognosis

*Medullary carcinoma* - a carcinoma of parafollicular cells (C cells) that produce calcitonin. As a result of its elevated levels, bone tissue resorption and disturbances in calcium and phosphate metabolism occur. It is typical of MEN 2A and MEN 2B multiple endocrine neoplasia syndrome

### **Surgical procedures on the thyroid gland**

Correspond to the anatomical part of the gland that is removed. Complete removal of the thyroid gland is called total thyroidectomy. For benign diagnoses, only one of the lobes can be removed, in which case we speak of lobectomy (right-sided or left-sided), or only the isthmus can be removed (isthmectomy). The surgical approach is provided by a collar incision 2 cm above the jugule (Kocher incision). Current trends in minimally invasive surgery can also be applied in thyroid surgery by video-assisted transoral endoscopic thyroidectomy (TOETVA).

**Complications** of surgical procedures on the thyroid gland are based on its anatomical localization. The most feared complication is injury to the n. laryngeus recurrens, which innervates the vocal cords and is responsible for their proper mobility. In case of bilateral injury, the vocal cord ligaments become paralyzed and remain in a relaxed position, obstructing airflow through the trachea and the patient is unable to ventilate spontaneously (inspiratory stridor). The surgical technique is therefore focused on a thorough investigation of this nerve, its visualization and verification by neurostimulation.

Another dreaded complication is bleeding. The anatomical space of the neck is a constricted area with many vital structures; therefore, even a small bleed will cause great compression of the surrounding structures, especially the trachea. If a postoperative hematoma is suspected, immediate dissolution of the wound at the patient's bedside is necessary to reduce the pressure in the cervical compartment.

Hypoparathyroidism is a risk in case of manipulation of the parathyroid glands or their complete removal in case of intraparenchymal placement.

Less common complications: lymphoedema (in lymphadenectomy, especially left-sided), pneumothorax (in large retrosternal stroma), wound complications (keloid).

### **Parathyroid glands**

The parathyroid glands are endocrine organs producing parathyroid hormone. Usually four, they are normally located on the posterior surface of the thyroid gland. Their localization is variable. It is not unusual that one of the glands may be located in the upper mediastinum. Parathyroid hormone regulates the levels of calcium and phosphorus in the blood. Its increased level is called hyperparathyroidism, decreased hypoparathyroidism.

### **Hyperparathyroidism**

**Primary** - caused by an adenoma of the parathyroid gland. Manifestations are general, caused by high levels of calcium in the blood. Typical symptoms include gastrointestinal discomfort, arrhythmia, nephrolithiasis, osteodystrophy, joint and muscle pain, psychological disorders. Therapy is surgical, involving removal of the hyperfunctioning gland. Parathyroid carcinoma is a rare but serious cause of primary hyperparathyroidism. It is a slow-growing tumor with infiltrative growth into the thyroid gland, blood vessels, muscles, and esophagus.

Primary hyperthyroidism is often the first manifestation of multiple endocrine hyperplasia (MEN) syndromes. These include 3 syndromes whose typical presentations are endocrine gland tumors. These are autosomal dominant diseases. MEN 1 syndrome is characterized by parathyroid adenoma, pancreatic neuroendocrine tumors such as insulinoma or gastrinoma, and pituitary adenomas. MEN 2A syndrome includes trias medullary thyroid carcinoma, parathyroid adenoma and pheochromocytoma. MEN 2B syndrome includes trias medullary thyroid carcinoma, pheochromocytoma and mucinous neuromas.

**Secondary** - high parathyroid hormone levels are due to feedback in low blood calcium levels, most commonly in renal disease

**Tertiary** - autonomic parathyroid hyperplasia in dialysis patients

### **Hypoparathyroidism**

Low parathyroid hormone levels lead to hypocalcemia and hypophosphatemia, primarily treated by endocrinologists. However, it can be induced by the surgeon as a complication of thyroid surgery.

## GYNECOMASTIA, INFLAMMATORY DISORDERS OF THE BREASTS (16)

Berková Alena

### **Gynaecomastia**

**Definition:** Abnormal enlargement of the breast in men due to hypertrophy of the gland or pathology of the reproductive tissue. It can occur unilaterally but also bilaterally. Physiological gynecomastia is seen in newborns, at puberty and in old age. Pseudogynecomastia is lipid deposition in obesity (lipomastia) or may be caused by tumors (e.g. lipomas).

**Etiology:** In 50% of cases, it is idiopathic gynecomastia. It may also be hormonal or metabolic or medically conditioned. Gynecomastia as a paraneoplastic manifestation is found in bronchial carcinoma, Basedow's disease, myotonic dystrophy. Gynecomastia can be associated with abuse of alcohol, cannabis, heroin, and anabolic steroids in athletes (bodybuilding).

### **Classification:**

- Stage I - mild gynecomastia - no excess breast skin
- Stage II - moderate gynecomastia - mild excess breast skin
- Stage III - severe gynaecomastia - significant excess breast skin

**Clinical findings:** Manifested by concentric enlargement of breast tissue unilaterally/bilaterally, may be associated with tenderness and galactorrhea may be present.

**Diagnosis:** The basic history and clinical examination is based on examination of both breasts and both axillae, examination of the genitalia - testes, checking the type of pubic hair. Genetic examination of the sexes. Laboratory determination of hormones - mainly levels of estrogen, testosterone, prolactin, LH, alpha-fetoprotein (AFp),  $\beta$  - hCG, thyroid hormones and liver tests. Sonography is needed to exclude cysts, nodules and tumours. To exclude tumors (pituitary, lung, adrenal glands) perform CT or MRI. To exclude breast cancer, mammography, breast ultrasound + core-cut biopsy, abdominal sonography/CT, X-ray/CT lung staging, multidisciplinary team is needed.

**Therapy:** Gynecomastia in newborns, adolescents and the elderly is physiological and requires no therapy. For pathological conditions, treatment may be:

1. Conservative: androgen replacement in cases of proven hypogonadism with testosterone deficiency, in medicamentous origin it is advisable to change the medication.
2. Surgical: usually elective surgery (psychological or cosmetic reason). The types of procedures vary according to the size of the excess skin. One can choose liposuction, open excision with or without reduction of excess skin. The removed tissue must always be sent for histological examination to exclude carcinoma.

**Differential diagnosis:**

- fibromas, fibroadenomas, lipomas, retromammary angiomas
- male breast cancer (unilateral enlargement !histology required!)
- obesity (lipomastia) = pseudogynecomastia

**Inflammations of the breast**

**Definition:** Mastitis affects women exclusively in most cases. The predisposing age is between 20-30 years and between 50-60 years. It is primarily caused by local transfer of infection most commonly from injury to the mamilla. Inflammatory breast cancer, which may manifest similarly to mastitis, should always be considered.

**Pathophysiology of mastitis:** The production of excessive amounts of keratin leads to the formation of keratin plugs and obstruction of the ducts of the mammary gland. Infection with bacteria leads to subareolar abscess formation and continued bacterial colonization. Further spread of inflammation to the surrounding area is predominantly via the lymphatic route. Infection can also spread per continuitatem most commonly from the injured mamilla, areola and breast skin. Here Staphylococcus aureus is most commonly present, rarely Proteus, Bacteroides, E.Coli or mixed infection, mycoses. Tuberculosis or parasites can also spread hematogenously, but these infections are very rare.

**Etiology of mastitis:** From the etiological point of view, mastitis is classified into:

1. Puerperal mastitis - 70% of all mastitis. Infection is caused by ragades on the mamilla, further aggravated by milk retention, lack of hygiene during breastfeeding, transmission of pathogens from the nasopharynx of the newborn.
2. Non-peripheral mastitis - arises from injury to the breasts, nipples, for example, during nipple piercing. Or in eczematous changes in the area of mamilla and areola. It can also occur in men.

**Clinical picture:** Mastitis manifests as a palpable, painful, firm infiltration of the skin and subcutaneous tissue. Redness, heat of the affected skin is present. Swelling extending to the axillary region and enlarged axillary nodes may be present. Of the general symptoms, subfebrile to febrile and chills are typical. Periductal mastitis causes retraction and inversion of the nipple. In puerperal mastitis, patients complain of painful breastfeeding.

**Diagnosis of mastitis:** History and clinical examination of both breasts and axillae is essential. In addition, sonography of the breast, laboratory examination of the blood count, CRP, hormonal examination - prolactin are performed. When pus is evacuated, microbiological examination is

recommended to perform. In case of suspicion of a tumor, it is necessary to analyze the tumor marker Ca 15-3, do mammography and core-cut biopsy of the lesion.

## **Therapies:**

### Thelitis

This is an isolated inflammation of the mamilla. Treatment is conservative, topical agents with an antiseptic or antibiotic in the form of a solution or ointment are used.

### Puerperal mastitis

As part of the treatment, it is therefore recommended to continue breastfeeding, which is safe. Abrupt weaning of the baby is likely to worsen the course of the inflammation. As part of the general therapy, it is recommended to administer anti-inflammatory drugs, antibiotics (most common penicillin) for 7-10 days. Surgical therapy is indicated in case of abscess formation, see below.

### Non-peripheral mastitis

Conservative therapy is based on the administration of anti-inflammatory drugs and antibiotics. Antibiotics should cover anaerobic bacteria and gram-negative microbes (e.g. amoxicillin + metronidazole combination). Surgical therapy is indicated if an abscess develops, see below. If a fistula is present, extirpation with histological verification is recommended. In case of early recurrence, resection of the retroareolar duct is recommended.

## **Complications of mastitis:**

Subcutaneous (preglandular) abscess, intramammary (glandular) abscess, paramammary abscess, retromammary abscess, subpectoral cellulitis, MONTGOMERY abscess - furuncle of Montgomery's gland of the glandula areolaris, and last but not least, necrosis of the mammary gland.

### Breast abscess

It can occur in lactational but also non-lactational mastitis. A pus-filled cavity develops in the mammary gland.

Clinical picture: febrile, induction of skin and subcutaneous fluctuations. A yellowish purulent secretion from the nipple may also be present.

Diagnosis: see above

Therapy: in small abscess cavities, aspiration of the contents with a needle can be performed, preferably under ultrasound guidance. If the abscess cavity is larger and mature, incision and drainage should be performed as part of acute treatment, preferably under short general anaesthesia. If necrosis is present, the procedure is supplemented by necrectomy. If malignancy is suspected, histology should be taken. Surgical therapy is always supplemented by general therapy, i.e.

administration of anti-inflammatory drugs and antibiotics preferably according to bacteriological culture.

### **Other less common mastitis**

#### Tuberculous mastitis

It is very rare, the causative agent is *Mycobacterium tuberculosis*. This form of mastitis is characterized by a stiff, bumpy induration with abscess formation and fistulation. It most often originates from the pulmonary form of tuberculosis, spreading haematogenously or per continuitatem from the affected ribs and soft tissues. The mainstay of therapy is antituberculous drugs and abscess therapy as mentioned above.

#### Granulomatous mastitis

A rare unilateral, chronic, breast disease with the possibility of recurrence. Affects young women of childbearing age (28-40 years). It arises from an autoimmune background. Diagnosis is by histology from core-cut biopsy or surgical excision. Therapy is based on the administration of corticosteroids. Surgical therapy is indicated only in case of abscess development.

#### Malignant tumours of the mammary gland associated with manifestations of infection

Outside of adenocarcinoma of the breast, the following can manifest as mastitis:

- inflammatory (inflammatory) carcinoma. It is manifested by enlargement of the breast, reddening of the skin. Early metastasis.
- Paget's carcinoma is a rare subtype of ductal carcinoma, it grows around the nipple, resembling a non-healing boil in the nipple area.

These forms are associated with numerous abscesses but only mild overall signs of inflammation. Early biopsy and histological verification contribute to the diagnosis. Treatment is complex oncological.

## **BREAST TUMORS (24)**

Coufal Oldřich, Krésová Pavlína, Gabrielová Lucie, Krsička Petr

Breast tumours can be classified as benign, malignant, or tumours of uncertain biological nature.

### **Benign tumours**

The most common is **fibroadenoma (FA)**. It occurs mainly in young women and may regress later in life. It is usually a solitary unilateral lesion, but occasionally, it occurs as multiple lesions in one or both breasts (**fibroadenomatosis**). Macroscopically, it is usually a smooth and oval lesion; however, sometimes, it has a lobular shape. Tumours larger than 5 cm are called "**giant fibroadenoma**". On clinical examination, FA manifests as a palpable lump, but it is sometimes an impalpable lesion, which is diagnosed as an incidental finding on ultrasonography (US). A US-guided core-needle biopsy (also called tru-cut or core-cut biopsy) is recommended in that case.

FAs usually do not require surgical resection if they are asymptomatic and have a stable size. The question of the necessity of dispensary and repeated US examinations is debatable.

We consider surgery, especially in the case of more rapid growth (over 3 cm) or if tumours is symptomatic, palpable and painful. Surgical treatment consists of extirpation, which usually does not cause breast deformity. Surgery is performed in general anaesthesia.

**Intraductal papilloma** usually occur centrally in larger ducts and sometimes cause nipple discharge. In these cases, breast ductography can show filling defects in the contrast-filled duct or ductal dilatation, ductal irregularity, and abrupt cut-off. Most of the intraductal abnormalities on ductography are identified as forms of filling defects. Extirpation (resection with a clear margin) is recommended due to both possible symptoms and the possibility of cellular atypia or transition to papillocarcinoma. Macroscopically, it tends to be soft and friable, and it is necessary to resect with a margin of surrounding tissue. **Ductal papillomatosis** means multiple papillomas, usually of microscopic dimensions in the central or peripheral ducts. It also slightly increases the risk of breast cancer. However, if the process is not limited to a smaller area, the surgical solution would have to consist of a total mastectomy, which may be considered too mutilating in this situation, so all that remains is to monitor the patient more carefully. Other benign breast tumours (e.g. lipoma, etc.) are uncommon.

### **Tumours of uncertain biological nature**

**Phyllodes tumours** are similar to FA; they histologically consist of epithelial and stromal components but have a higher cellularity. Based on histological characteristics (cellularity, atypia, mitotic activity, nature of growth into the surrounding tissue), they can be divided into benign, borderline and malignant forms. Histological diagnosis is challenging as it presents a morphologic



continuum from benign to malignant tumour, and the nature of the tumour can sometimes only be established from its biological behaviour over time. Compared to FA, they occur in middle-aged women (over 35 years of age). Macroscopically, they tend to be rather pink to greyish, but they are mainly characterised by rapid growth. In extreme cases, they can reach the size of a soccer ball within weeks to months. This is also why rapidly growing FA should be surgically resected, as it could also be FN. Differentiation based only on clinical examination is impossible, and core-cut biopsy must always be performed. Surgical treatment consists of resection, ideally with a resection margin of 10 mm. However, this is not always possible, and it is challenging to achieve. Large tumours can only be treated with a total mastectomy, even if the tumour is benign. The dispensary is required after surgery, as malignant forms (also called **cystosarcoma phyllodes**) may return in the form of either local recurrence or rarely distant metastases, thus clinically resembling sarcomas. On the other hand, the behaviour of benign variants may not be very different from FA, so even unjustified extensive surgical radicality may not always be appropriate. Fortunately, FNs are relatively rare, accounting for less than 1% of all breast tumours.

### **Malignant tumours**

The most common and clinically important malignant tumour of the breast is **breast cancer**, and it is the most common malignancy in women, apart from skin tumours. The lifetime risk for a woman in the general population is reported to be in the range of 6-10%. Since 2002, a **screening program** has also been introduced in the Czech Republic consisting of mammography (MG) assessment of asymptomatic women from the age of 45 in two-year intervals. The majority of cancers develop as sporadic cancers; however, some cancers occur due to hereditary genetic predisposition, which can be diagnosed by genetic testing. The most well-known are mutations in the BRCA1 and BRCA2 genes. A positive family history or the occurrence of cancer at a young age will draw attention to the possibility of a predisposition. In women diagnosed with those mutations, bilateral prophylactic mastectomy can be considered.

Approximately half of the cancers in our population are screen-detected; the others are **symptomatic**, manifested by clinical symptoms, most often palpable painless breast lump. Less often, it is diagnosed based on skin or nipple changes, skin retraction or infiltration, deformity or stiffness of the breast. Rarely, the first symptom of breast cancer is a painless enlarged palpable axillary node.

The most aggressive form of breast cancer is **inflammatory carcinoma** (stage T4d), associated with redness and lymphoedema of the skin, which can imitate orange peel (**peau d'orange**). This can affect a larger part of the breast or even the entire breast, which may look similar to inflammation disease.

**Breast cancer diagnosis** is based on two pillars:

**1 Histological verification** – US-guided core-cut biopsy, less often stereotactic biopsy on mammogram or MRI. A larger amount of tissue can be removed with a vacuum biopsy (VAB) in case of diagnostic discrepancy. When pathologists report the biopsy findings, they include these features: the histological type of the tumour (e.g. invasive ductal, lobular, or other subtypes of breast cancer), tumour grading, expression of oestrogen and progesterone receptors (steroid receptors), HER2-neu expression and proliferation index (Ki67 index), which together form the tumour "phenotype".

**2 Assessment of the extent of the disease** - in the local-regional site (breast + axillary nodes) and distant organs (most frequently bones, lung, liver, GI tract, or brain). This is described using the TNM classification. The assessment consists of bilateral MG in two basic projections - a mediolateral oblique (MLO) view and a craniocaudal (CC) view - and bilateral US of breast and axilla. In some cases, we also request magnetic resonance imaging (MRI), which has high sensitivity but low specificity, so it often leads to additional biopsies, frequently reported as "false positives". MRI is recommended, especially for invasive lobular cancer (ILC), which is characterised by infiltrative growth that increases the risk of multicentric contralateral disease. Consequently, the estimation of the extent of the disease in ILC using basic methods (US and MG) is often underestimated and requires MRI. The staging assessment should be detailed based on the tumour stage (How detailed the staging assessment should be based on the tumour stage) and the availability of a particular imaging method. The minimum for staging of early breast cancer is a Chest X-ray and US of the liver. Compared to bone scans, CT chest, abdomen and pelvis or even PET/CT scans in advanced disease. Additionally, in early breast cancer, the finding of synchronous distant metastases at the diagnosis is fortunately rare.

The treatment strategy is based on the phenotype and extent of the disease. For the reason that breast cancer is considered a systemic disease, treatment is always multimodal, a combination of surgery, systemic treatment, and radiotherapy.

Primary surgery is mainly applied in the phase of the absence of signs of distant metastases in localised disease. Timing of surgery can be either primary - systemic treatment and radiotherapy follows surgery), or surgery follows neoadjuvant (systemic) chemotherapy (NACT). In cases where its administration can improve the conditions for surgery, NACT is used. NACT is frequently recommended in patients with more aggressive phenotypes ("triple-negative" and "HER-positive", high grade, high Ki67), large tumours or involved axillary nodes. **Treatment should never be decided by the surgeon alone but in collaboration with collaborating specialities in a multidisciplinary team (MDT), also called a "breast committee."**

The surgery itself then consists of resection of the breast tumour and the lymph node removal. The goal is to resect the primary tumour with a negative resection margin, which can be achieved through **partial mastectomy** (also called wide local excision) for smaller solitary or multifocal lesions, while for larger or multicentric tumours, the entire breast must be removed (**total mastectomy**). The decision on the scope of the operation cannot be standardised; it is individual, often difficult, and based on the competence of the surgeon and the patients should agree. Modern breast surgery incorporates **oncoplastic techniques**, enabling the removal of larger tumours while minimizing cosmetic deformity.

A prerequisite for partial mastectomy in uncertainly palpable tumours is the use of one of the intraoperative localisation techniques, e.g. iodine or magnetic seeds. Partial mastectomy must always be supplemented with adjuvant radiotherapy (RT), while after total mastectomy, RT is only indicated for more locally advanced tumours. Surgery on the lymph nodes aims to determine the level of their involvement by histological examination. The therapeutic effect of lymphadenectomy is not as noticeable as it was assumed in the past, and a clear trend is **the reduction of surgical radicality in the axilla**. The traditional Axillary Lymph Node Dissection (ALND), burdened with the risk of iatrogenic secondary lymphedema, can now be avoided in most women. Conservative procedures such as Sentinel Lymph Node Biopsy (SLNB) and, in recent years, the Targeted Axillary Dissection (TAD), consisting of removing the most prominent initially pathological node if it regressed during adjuvant chemotherapy, dominate. Here, too, the use of **localisation techniques** is necessary. Surgery is usually followed by adjuvant treatment, systemic or RT, depending on the phenotype and stage of the tumour.

After a total mastectomy, suitable candidates can consider **breast reconstruction**, either immediate (immediately at the time of the mastectomy) or delayed. A breast substitute can be created using your own tissue (typically an abdominal flap) or using foreign material (mammary implant). It is always a demanding one-stage or multi-stage operation burdened with the risk of complications, so not all patients are suitable candidates. Also, the availability of breast reconstruction in the Czech Republic is generally lower than most patients would like.

**Ductal carcinoma in situ (DCIS)** is worth mentioning, often asymptomatic and presenting on MG with the image of "microcalcifications". Histopathologically, it is preceded by **atypical ductal hyperplasia (ADH)**, which can thus be described as a typical "precancer". DCIS is considered a direct precursor to invasive carcinoma and requires surgical treatment. If invasion is not demonstrated even during the histological examination of the surgical resection, no adjuvant treatment is often necessary. On the other hand, **lobular carcinoma in situ (LCIS)** is more of an

indicator of an increased risk of invasive cancer in the future (anywhere in the breast), so a surgical approach is not so clearly defined.

**Other malignant breast tumours** are rare. In addition to the already described malignant variant of FN, it is worth mentioning an extremely rare but even more aggressive (secondary) angiosarcoma arising as a late side effect of adjuvant radiotherapy, which develops many years after treatment. Primary breast sarcomas, or metastases of other malignancies (e.g. melanoma) to the breast, are rare.

## **THORACIC OUTLET SYNDROM, NERVE COMPRESSION SYNDROMES OF ARM AND FOREARM (21)**

Topolčaniová Lenka, Váňa Vladimír, Ferkodičová Iveta, Holoubek Jakub

### **Introduction**

Entrapment syndromes are conditions characterized by localized damage to peripheral nerves caused by compression at anatomically defined narrow and rigid passageways. This compressive neuropathy typically occurs in areas where nerves pass through bony, muscular, or fibrous structures. The most common entrapment syndromes include carpal tunnel syndrome (CTS) and cubital tunnel syndrome, while less frequent ones are Guyon's canal syndrome, anterior interosseous nerve syndrome, pronator syndrome, supinator syndrome, and thoracic outlet syndrome (TOS).

The etiology of entrapment syndromes is multifactorial. It can be caused by anatomical factors, such as congenital anomalies or abnormal structures. Inflammatory conditions, such as rheumatoid arthritis and tenosynovitis, can lead to swelling of the surrounding tissues and subsequent nerve compression. Other causes include metabolic disorders, such as diabetes, postoperative states, trauma, tumors, iatrogenic damage during medical procedures, and various external factors, such as repetitive pressure or overuse. In some patients, the exact cause cannot be determined, and the condition is classified as idiopathic. Pathophysiologically, nerve compression leads to damage to the myelin sheath, axons, and disruption of the nerve's blood supply (vasa nervorum). This results in demyelination and, in more severe cases, axonal injury.

The clinical manifestations of these syndromes include pain, often localized at the site of compression, which may radiate to the area innervated by the affected nerve. Patients frequently report sensory disturbances such as paresthesia (tingling or numbness) and hypesthesia (reduced sensitivity). Night pain is also characteristic and can wake the patient from sleep. As the condition progresses, motor disturbances occur, leading to muscle weakness in the muscles innervated by the affected nerve. Symptoms often worsen after physical exertion or repeated strain on the affected area.

### **Carpal Tunnel Syndrome (CTS)**

CTS is caused by compression of the median nerve in the area of the so-called carpal tunnel beneath the transverse carpal ligament. CTS is the most common peripheral neuropathy, accounting for up to 90% of all entrapment syndromes of the upper extremity. It is more frequently seen in women and in individuals engaged in manual labor. The syndrome manifests as pain in the wrist area, paresthesia in the sensory innervation area of the median nerve (affecting the thumb, index, middle, and half of the ring finger), deterioration of fine motor skills, and in advanced stages, atrophy of the thenar muscles and limitation of thumb opposition. Paresthesia and pain often awaken the patient at night in the later

stages. Diagnosis involves taking a thorough history and conducting provocative tests, such as Tinel's sign (tapping on the site of compression leads to paresthesia in the fingers) and Phalen's test (flexing the wrist for 60 seconds leads to paresthesia). Additionally, electromyographic (EMG) testing is necessary during the diagnostic phase; a positive result indicates the need for surgical intervention. Treatment for mild cases can be conservative (nighttime static splinting, vitamin B supplementation, corticosteroid injections), but in most cases, open or endoscopic surgical solutions are required, which involve cutting the transverse carpal ligament under local anesthesia. During the surgical procedure, the ligament cutting is often supplemented by epineurotomy and release of the fascicles of the median nerve. Rehabilitation begins on the fifth postoperative day.

### **Cubital Tunnel Syndrome**

Compression of the ulnar nerve behind the medial epicondyle of the humerus, leads to cubital tunnel syndrome. It is the second most common entrapment syndrome, accounting for up to 9% of all upper extremity entrapment syndromes, with men being affected more frequently. Typical symptoms include paresthesia or hypesthesia and motor disturbances in the area innervated by the ulnar nerve, along with atrophy of the hypothenar muscles. In advanced cases, muscle atrophy may occur in the interosseous muscles and the adductor pollicis, resulting in a claw-like deformity of the hand. Diagnosis is based on clinical symptoms, a positive Tinel's sign, and EMG examination. Mild cases can be managed conservatively with lifestyle modifications or steroid injections. In severe cases, surgical decompression of the ulnar nerve is necessary, involving cutting the Osborn ligament, or anterior transposition of the nerve. Endoscopic in situ neurolysis has shown the best results and is the recommended approach.

### **Ulnar Tunnel Syndrome**

In ulnar tunnel syndrome, the nerve is compressed in Guyon's canal between the pisiform and hamate bones, beneath the ulnar part of the flexor retinaculum, above the transverse ligament. Due to the branching of the nerve within the canal, the clinical symptoms depend on whether the trunk is compressed before branching or only one of the branches. This may manifest as a motor deficit in the hypothenar region and the adductor pollicis muscle or as a sensory deficit in the palmar innervation area of the nerve; when the trunk is compressed, a combination of both symptoms can occur. Unlike cubital tunnel syndrome, there is never a sensory deficit in the ulnar nerve innervation area on the dorsum of the hand. Diagnosis involves EMG, and possibly ultrasound (US) and magnetic resonance imaging (MRI). Treatment typically involves surgical decompression of the nerve in combination with epineurotomy.

### **Pronator syndrom**

In cases of compression of the median nerve in the proximal forearm between the two heads of the pronator teres, a very rare condition known as pronator syndrome can occur. This syndrome is characterized by pain on the volar side of the forearm and paresthesia in the innervation area of the median nerve. Depending on the location of the branch for the pronator teres, there may be weakness and pain during resisted pronation. The compression is primarily due to hypertrophy of the muscle from professional overuse, leading to nerve compression (long-term pronation and finger flexion). Diagnosis includes a clinical examination to identify painful pronation against resistance or palpation over the pronator teres muscle. EMG can confirm our hypothesis and determine the extent of nerve involvement. Treatment typically consists of conservative measures, such as limiting the strain on the forearm and applying anti-inflammatory medications; in rare cases, surgical intervention for decompression may be necessary.

### **Anterior Interosseous Nerve Syndrome (AINS)**

AINS is a very rare isolated involvement of the motor branch of the median nerve. This branch innervates the flexor pollicis longus (FPL), flexor digitorum profundus (FDP) for the second and third fingers, and the pronator quadratus (PQ). Clinically, it presents with pain and paresis of the affected muscles without sensory symptoms, which distinguishes AINS from other entrapment syndromes. The patient is unable to pinch the tips of the thumb and index finger together to form an "O" shape, which is a key diagnostic sign known as the "pinch sign." Instead, during attempts to perform this movement, a flat grip is formed. Diagnosis is made clinically, and EMG confirms the diagnosis. Treatment is primarily conservative, involving lifestyle modifications and anti-inflammatory medications. Surgical treatment consists of nerve decompression.

### **Thoracic Outlet Syndrome (TOS)**

TOS refers to a group of disorders caused by the compression of blood vessels (subclavian artery/vein, axillary artery/vein) or the brachial plexus in the area of the upper thoracic aperture. Anatomical structures in this region, such as the scalene muscles, clavicle, first rib, cervical rib, subclavius muscle, pectoralis minor muscle, and others, contribute to this condition. Thoracic outlet syndrome (TOS) can be classified into neurogenic (95%), arterial (3-5%), or venous (2%) types. The syndrome presents with weakness, pain, thermoregulatory disturbances, and paresthesia throughout the entire upper limb, with worsening symptoms when the limb is elevated above shoulder level. In cases of vascular compression, symptoms may include claudication, cyanosis, and swelling of the limb. Diagnosis involves clinical examination using maneuvers such as Adson's, Kelley's, or hyperabduction (Wright's) maneuver. Imaging methods such as CT scans, angiography, and ultrasound are also utilized. Treatment is primarily conservative, involving posture correction,

lifestyle modifications, and physical therapy. If conservative measures fail, surgical decompression is indicated, most commonly through complete resection of the first rib via an axillary approach.



## ACUTE MEDIASTINITIS (18)

Peštál Adam

### **Nosology a)**

**Concept** - Acute mediastinitis is a severe purulent inflammatory involvement of the mediastinal space

**Etiology** - the infection arises from the spread of purulent inflammation from the head, neck or transfer of infection from the organs of the mediastinum, primarily the esophagus and airways in association with perforating involvement. A less frequent cause is the occurrence of infection in connection with direct injury to the mediastinum - penetrating injuries (stab wounds, gunshot wounds,...). A specific etiology is infection associated with sternotomy after cardiac surgery.

**Pathogenesis** - along the deep cervical fascia, spine, esophagus and trachea, the infection spreads through the mediastinum. Given the anatomical conditions, the organism does not have the ability to prevent the spread of infection in the mediastinal space and contain the infection. The mediastinal pleura is a certain anatomical barrier, but this is subject to early necrosis. The mediastinal pleura prevents the spread of infection only initially, when it limits the spread to the pleural spaces, but minimally prevents the spread of infection in the craniocaudal direction. Despite the macroscopically intact mediastinal pleura, secondary empyema collections soon arise in the pleural cavities. Acute mediastinitis is usually accompanied by pneumonia. The infectious microbiological agents are varied, and culture examination is necessary, including examination for anaerobes. However, it is always necessary to initiate intensive broad-spectrum antibiotic therapy immediately at the beginning of treatment.

### **Nosology b)**

**Clinical symptoms:** the development of acute mediastinitis is often rapid. From "full health" the patient goes into progressive severe septic shock. High fever, tachycardia, hypotension, dyspnoea, dysphagia, neck pain, headache, chest tightness, anxiety and respiratory failure are the main clinical manifestations of the disease. In case of perforation of the oesophagus, airway, or gas formation in the context of ongoing infection, subcutaneous emphysema may be palpated. This may not always be expressed, but together with skin redness and oedema is a prognostically important factor.

Laboratory tests: to diagnose and monitor the course of treatment, we determine serum levels of CRP, lactate, procalcitonin, examine KO and specific indicators of MODS - Astrup's test, U, creatinine, JT, coagulation parameters, CB, prealbumin...

**Imaging methods:** the most beneficial is the CT scan, this is performed in both native and contrast imaging. Contrast agent is administered both parenterally and per os to exclude or confirm oesophageal perforation. In the case of an intubated patient, an aqueous iodine solution is injected via a probe behind the sphincter of Kilian. According to CT findings, fibroscopic examination of the oesophagus or airways is indicated.

**Treatment:** it is always combined, it is surgical, antibiotic and sepsis treatment in ICU or ARO. The principle of surgical therapy is the basic rule of surgical treatment of infection, i.e. "ubi pus ibi evacua". It is therefore the opening and sanitation of the mediastinal space. According to the extent of the inflammation and its etiology, determined on the basis of CT, from the cervical or pleural space, combined approaches are common. The cervical approach is the jugular incision in the jugulus, in the case of ENT etiology of inflammation extended also by bilateral approach along the clavicles. In collaboration with ENT, rehabilitation of these foci is necessary, and it is not infrequently necessary to establish a tracheostomy. The intrathoracic approach is VATS or thoracotomy. The principle of surgical treatment in the pleural cavity is longitudinal intersection of the mediastinal pleura from the tip to the diaphragm with evacuation of purulent secretions, purulent masses and necrotic tissue of the mediastinum, with introduction of a lavage drainage system into the mediastinal space. In a minority of cases, if the mediastinitis is confined to the upper mediastinum, then revision of the caudal portion of the mediastinum is not necessary. Very often it is also necessary to resuscitate the accompanying empyema in the pleural cavities. Repeated dressings under general anesthesia, both in the ENT area with necrectomy and repeated revisions of the mediastinal space in the subsequent period by transthoracic route are common practice. Lavage drains, Penrose drains or modern treatment methods in the sense of NPWT are essential. Regular follow-up of the local findings with CT scanning is necessary. In case of persistent purulent foci, surgical revisions and targeted drainage are indicated. In case of perforating etiology of mediastinitis, suturing of the esophagus, trachea or bronchus can be considered in the initial phase. Tissue viability and anatomical location should be assessed. Another solution is to bridge the perforation with a stent. In case of oesophageal perforation, endosponge with active suction is also possible. In the case of extensive necrosis of the oesophagus, resection and blinding or complete extirpation is necessary. For the future, the patient is referred to enteral nutrition, which is most often applied through a nutritive jejunostomy. In a certain percentage of cases, esophageal replacement may be attempted with the passage of time, usually several months. Early recognition of the emerging acute mediastinitis and its urgent active intensive treatment has a higher probability of treatment success as well as a reduction in the number and severity of late complications.

### **Nosology c)**

**Complications** - early complications of acute mediastinitis are presented by all manifestations of advanced sepsis, i.e. MODS, ARDS, DIC,... which often lead to death. In the case of advanced fulminant mediastinitis, mortality is reported to be more than 50%. Late complications include those associated with subsequent scarring of the mediastinum, e.g. mediastinal fibrosis with dysphagic manifestations. Dyspnoeic problems are possible, also in connection with tracheal stenosis after tracheostomy. Complications may also arise in connection with artificial nutrition or the condition after pneumonia.

**Prevention** - sufficient attention when eating and drinking, proper chewing of food (swallowing bones, solid morsels), prevention of accidental ingestion of acid or lye, it is desirable to avoid the risk of swallowing foreign bodies. Prevention also includes dental care with emphasis on possible complications associated with the VIIIth tooth, as well as treatment of tonsillitis and other infections in the ENT area. Specific prevention includes adequate sparing of instrumentation such as OT intubation and flexible and rigid examination of the esophagus and airway.

## MEDIASTINAL TUMORS, SUPERIOR VENA CAVA SYNDROM (19)

Tomáš Ledvina, Jan Ledvina, Teodor Horváth

Mediastinal neoplasms represent miscellaneous group of diseases with manifold symptomatology correlating with their site in the – anterosuperior, medial or posterior compartments – and with the biological character of the illness. They include benign and malignant findings too, both primary or metastatic.

### **I**

#### **In the anterosuperior compartment occur**

##### A Thymic lesions

1/ Thymic lymphoid hyperplasia usually causing the enlargement of the gland is related to myasthenia gravis. 2/ Thymomas – the tumours created with epithelial cells of thymus are infiltrated with various amount of reactive lymphocytes. 3/ Thymolipomas are rare soft and pliant tumours. They do not affect adjoining structures, therefore they grow up to considerable size. 4/Thymic cysts are commonly asymptomatic. They are quite often of no consequence. But as thymic cyst can be present as e.g. Hodgkin lymphoma. 5/ Thymic carcinoid can be asymptomatic or may cause symptoms because of compression of adjoined tissues. They are malignant and benign forms. They can be a part of multiple endocrine neoplasia (MEN) 6/ Germ cells neoplasms (GCN). The males tend to develop malignant GCN, while in females these tumours tend to be benign.

B Mediastinal goiter is in most cases benign. Quite large thyroid gland enlargement causes dyspnea, hoarseness, dysphagia and/or superior vena cava syndrome.

C The lymphadenopathy in the anterosuperior mediastinum is most often caused by lymphoma or metastatic adenopathy.

D There are sporadically to be found miscellaneous tumours – benign: ectopic parathyroid gland adenoma, cystic hygroma, hemangioma, lipoma,, further rare neuroendocrine paraganglioma and out of malignancies liposarcoma.

### **II**

#### **In the middle part of the mediastinum**

arise 1/ enlargement lymphadenopathy based on sarcoidosis, lymphoma, metastatic lung or other carcinomas or Castleman disease 2/ primary tumours of the trachea, 3/ bronchogenic cysts localised frequently in the region of main carina, commonly with mucous content. They communicate with

central airways rarely 4/ Mesothelial pericardial cysts. Both last-mentioned are suitable for fine-needle CT guided aspiration, diagnostic and/or therapeutic.

### **III**

#### **The posterior compartment**

can contain 1/ neurogenic tumours of peripheral nerves – neurofibroma; neurilemmoma (benign Schwannoma); neurogenic sarcoma (malignant Schwannoma); They usually arise of intercostal nerves, seldom of phrenic or vagal nerve. Their expansion into intervertebral foramina threat of perinvertebral injury of spinal nerves. 2/ Gastroenteric (Duplication) cysts can be lined by nonkeratinizing squamous, ciliated columnar, gastric, or small intestinal epithelium. Communication with upper GIT is uncommon. 3/ Paravertebral masses are the demonstration of primary or metastatic tumours of vertebrae, or these can be simulated under the cover of spondylodiscitis. The role of surgery is important for diagnosis and treatment in this space.

There are used these approaches:

1/ **Cervical mediastinoscopy** – The entrance to anterosuperior mediastinum represents jugular incision for diagnosis and treatment of enlarged lymphatics Recent options a) videoassisted mediastinoscopy b) extended cervical (video)mediastinoscopy access subaortic space c) open transcervical procedure for extended mediastinal lymphadenectomy.

2/ **The parasternal mediastinotomy** through the parasternal bed of second or third rib, or their intercostal spaces both left and right sides, for the purpose of surgical biopsy of the retrosternal mass.

3/ **The subxiphoidal access** represents way to get to overwhelming majority of the spaces of anterior mediastinum. Using this way enables the formation of pericardial window into the peritoneal cavity.

4/ **Thoracoscopic right- or left-**hand sided according to the location of the tumours of posterior mediastinum or for the formation of pericardial window opened to interpleural space for prevention of cardiac tamponade in patients with malignancies metastasizing into pericardium.

5/ **Through median sternotomy** or its partial modifications to the structures of the anterior or through lateral thoracotomy to the pathology of middle and /or posterior mediastinum.

#### **Superior vena cava syndrome (VCS)**

The term evaluating consequences of the compression or infiltration of superior vena cava. VCS is caused by lung cancer, metastatic lymphadenopathy, lymphoma, rarely by sarcoma. Other causes are represented by retrosternal goiter, mediastinitis, aneurysm of the thoracic aorta, or postradiation changes. They give rise to increasing of blood pressure (take care of hemoptysis) and decreasing of venous return to the right atrium. Slow down of venous return participates onto edema of soft tissues

of head and neck and causes phlebothrombosis of superior vena cava. They are formed venous collaterals caused the decompression. Surgical intervention on the congestive region, even though diagnostic, is usually at high risk or contraindicated. Causal treatment is aimed onto the illness and diseased region. Supportive or palliative therapy ameliorates the difficulties and swelling using diuretics, corticotherapy, analgetics / NSAIDs, oxygen, and in advanced cases anodyne.

## **PULMONARY ABSCESS, EMPYEMA (22)**

Prudius Vadim

Empyema of the chest refers to the accumulation of infected fluid in the pleural cavity, most commonly pus. It remains a serious condition worldwide, with a reported mortality rate of 4-10%, with a median of about 8%. In centers specializing in thoracic surgery, mortality is around 4%.

### **Causes of Empyema:**

- Pneumonia and parapneumonic effusions
- Pleural effusion (usually due to repeated punctures of chronic effusions)
- Mediastinitis, esophageal injury
- Iatrogenic causes (previous thoracic surgeries)

### **Clinical Symptoms of Empyema:**

- Shortness of breath
- Dry, irritating cough
- Fever (CAVE: patients receiving pneumonia treatment may have minimal symptoms)
- Chest pain during breathing
- Loss of appetite
- Clinical signs of sepsis

### **Patient Examination:**

- Medical history: usually linked to a previous pneumonia, chronic pleural effusion, thoracic surgery, or trauma (including hemothorax)
- Pharmacological history: prolonged antibiotic use can lead to an oligosymptomatic or latent course until stage 3
- Auscultation: weakened breathing on the affected side
- Chest X-ray
- Laboratory tests: CBC, CRP, lactate, urea, creatinine, electrolytes, coagulation; IL-6 in septic cases
- Ultrasound (mandatory for empyema, as septated effusions may not be visible on CT)
- Chest CT for stage II-III empyema
- MRI (rarely used, for suspected fistulas into adjacent organs, spinal cord involvement, etc.)

### **Stages of the Disease:**

1. Stage I (exudative, acute):\*\* Thin pleural effusion with low cellular content develops. Duration: 1-2 weeks.
2. Stage II (fibropurulent, transitional):\*\* The effusion thickens, containing many polymorphonuclear cells. Fibrin deposits form a membrane encasing the effusion. Duration: from the 2nd-3rd week to the 5th-6th week of the disease.
3. Stage III (organizing, chronic):\*\* Capillaries and fibroblasts grow into the empyema cavity. The pleural effusion is thick and contains up to 75% sediment. Occurs 4-6 weeks after the disease onset. The condition of a trapped lung gradually develops.

### **Treatment:**

- Stage I:\*\* Drainage with a large-bore drain (Ch 24-32, preferred Ch 28). Targeted antibiotic therapy and symptomatic treatment.
- Stage II:\*\* VATS (video-assisted thoracoscopic surgery) debridement, evacuation of empyema masses, and intraoperative lavage of the pleural cavity. Targeted antibiotic therapy.
- Stage III:\*\* VATS revision, pleural cavity debridement, decortication. If decortication cannot be performed technically, conversion is done. Postoperative lavage of the pleural cavity (preferably with a 3% betadine solution or Prontosan). A primary goal of surgery is complete re-expansion of the lung parenchyma.

### **Surgical Approaches:**

- VATS: Multi-portal, bi-portal. Although the uniportal procedure is possible, its benefits are unclear.
- Thoracotomy: Dorso-lateral or anterolateral approach.

Currently, the preferred initial procedure is a VATS revision. For stage III empyema, conversion to thoracotomy is not uncommon to complete decortication or manage intraoperative complications. In cases where empyema is combined with other conditions such as bronchopleural fistula, phlegmon, or necrotizing fasciitis of the chest wall or lung necrosis, a primary thoracotomy revision is preferred.

Alternative options: Robotic-assisted thoracic surgery (RATS) allows chest debridement and decortication. However, experiences are still limited globally, including in the Czech Republic, and the benefits over VATS have not been proven yet.

### **Postoperative Management:**



- Monitoring in the ICU for at least 12 hours postoperatively
- Antibiotic therapy according to sensitivity
- Pleural cavity lavage with 3% betadine solution at a rate of 8-10 ml/h
- Flutter valve and rehabilitation
- Chest X-ray
- Follow-up chest ultrasound 48-96 hours postoperatively
- Follow-up chest CT 2-4 weeks postoperatively

### **Postoperative Complications:**

- Incomplete lung re-expansion: A risk factor for empyema recurrence.
- Prolonged postoperative air leak: Managed by attaching a Heimlich valve to the chest drain. If unsuccessful, a chest revision, usually via thoracotomy, may be required.
- Relapse of empyema: Small collections can be managed with CT-guided drainage, while full relapse necessitates VATS/thoracotomy revision.
- Postoperative bleeding and hemothorax: Commonly occur after decortication, often requiring revision and lavage of the affected hemithorax.
- Lung necrosis, thoracostomy, and similar complications are rare today.

- **Lung Abscess:**

A lung abscess is a pathological cavity in the lung parenchyma, surrounded by a pyogenic membrane and filled with pus (infected secretions). It may communicate with the bronchus. It typically develops from necrosis of lung tissue due to severe infectious inflammation. Lung abscesses are relatively rare in the Czech Republic today.

- **Causes of Lung Abscess:**

- Complicated pneumonia (especially in immunocompromised patients)
- Aspiration pneumonia (including aspiration during anesthesia induction)
- Advanced lung tumors (central necrosis and tumor breakdown)
- Septic pulmonary embolism
- Pulmonary infarction

### **Clinical Symptoms of Lung Abscess:**

- Shortness of breath
- Cough with sputum production
- Fever or high fever
- If the abscess ruptures into the bronchus, massive expectoration of purulent sputum can occur within hours or days, often providing temporary relief.

- Chest pain (usually when the infection spreads beyond the focus)
- Loss of appetite, nausea

**Patient Examination:**

- Medical history (previous surgeries, ENT area diseases)
- Auscultation: Weakened breathing on the affected side in larger abscesses
- Chest X-ray
- Blood tests: CBC, CRP, lactate, urea, creatinine, electrolytes, coagulation. Sputum culture for microbiological and cytological examination.
- Bronchoscopy
- Chest CT

**Treatment:**

- CT-guided drainage for smaller peripheral abscesses.
- Surgical revision and lung resection: For small abscesses, an atypical lung resection may be performed. For larger or centrally located abscesses, lobectomy is preferred, usually performed via thoracotomy. For smaller abscesses under 5 cm, VATS resection may be considered.
- Targeted antibiotic therapy

## LUNG CANCER AND MESOTHELIOMA (23)

Pospíšil Jan

Lung tumors are the most frequently occurring tumor of the respiratory system. Histologically, **bronchogenic carcinoma** predominates. It is the most common tumor in men over 40 years of age and the maximum incidence is between 55 and 65 years. It is also very common in women and ranks 3rd in incidence among them. Bronchogenic carcinoma ranks second overall among all malignant tumors and accounts for about 1/3 of all deaths from malignant oncological diseases.

### Classification

#### Benign lung tumors

#### Primary lung tumors

The primary lung tumor is bronchogenic carcinoma, which can be divided according to histological classification into - **non-small cell** (squamous cell carcinoma, adenocarcinoma, large cell carcinoma), **small cell** and **lung carcinoid**

#### Secondary lung tumors

These are metastases of other tumors to the lungs

### Etiology

The influences that cause bronchogenic carcinoma can be divided into endogenous and exogenous.

**Endogenous** influences are, for example, increased activity of cytochrome P450 (increased, for example, in smokers) or mutation of the P53 gene. The most significant **exogenous** influence is smoking. 90% of lung cancer occurs in smokers. Passive smoking also poses an increased risk. Other exogenous influences are e.g. increased exposure to radon, asbestos, inorganic compounds of arsenic, sulphur, chromium, nickel or PVC compounds and ionizing radiation.

### Symptomatology

Symptomatology can be of different types

**Intrathoracic** - Cough (initially dry, irritating, then may be productive), hemoptysis, stridor (with narrowing of major airways), bronchopneumonia (with bronchus obstruction), superior vena cava syndrome (as a result of pressure from enlarged lymph nodes), Horner's triad, hoarseness (when oppressing the recurring laryngeal nerve), shortness of breath and chest pain (for example, when growing into nerve plexuses)

**Extrathoracic** - neurological (in the case of metastasis to the CNS), bone marrow function disorders, possibly pathological fractures (in the case of metastasis to the bones), hepatobiliary symptomatology (in the case of metastasis to the liver), weight loss, loss of appetite

**Paraneoplastic manifestations** - they are very common in bronchogenic carcinoma, they can also be the first manifestation of the disease. These are, for example, hypercalcemia with hypophosphatemia (with ectopic secretion of parathyroid hormone), hyponatremia (with inadequate secretion of ADH), Cushing's syndrome with hypokalemia (with ectopic secretion of ACTH). It can also be skin (dermatomyositis), neurological (peripheral neuropathy, muscle myopathy), muscle and hematological symptoms.

## **Diagnostics**

### **Clinical examination**

Less extensive tumors may be clinically silent. In the case of a more extensive impairment, there is usually an auditory finding with the occurrence of secondary phenomena - especially whistling or wheezing. Alternatively, listening to breathing is absent and the percussion is shortened, which indicates a pleural effusion or atelectatic changes caused by non-airy parenchyma in the case of obstruction of the bronchus by tumors. It is necessary to palpate the lymph nodes - supraclavicular, axillary and cervical. Also, if we palpate the enlarged liver, it may already be metastatic.

### **Imaging methods**

Among the basic imaging methods in the diagnosis of lung tumors are **X-ray** - back-front and side projections, **CT** - lungs and mediastinum, **EBUS** (endobronchial ultrasonography), as well as **PET**, possibly **scintigraphy**. A less important method is **MRI** - suitable for diagnosing Pancoast tumor (tumor growing into the subclavicular space where it can affect nerve fibers and vascular bundle).

### **Histological sample collection**

Among the methods of sampling are in particular - **Bronchoscopy** (using a brush and forceps), **Video-assisted thoracoscopy (VATS)** - biopsy/resection of part of the lung parenchyma, or **transparietal biopsy** - under X-ray/CT control (mainly for peripheral lesions).

If it is not possible to perform a sampling examination for the patient, we can cytologically examine sputum (3-5 doses) or pleural effusion.

## **Therapy**

### **Small cell carcinoma**

Small cell carcinomas have a short doubling time, a high growth fraction and a tendency towards early regional and distant metastasis. Therefore, surgical treatment of these tumors is rare.

Chemotherapy and radiotherapy targeting the tumor and metastases are indicated, as well as preventive brain irradiation. Surgical treatment is indicated only in very limited cases and must always be followed by systemic treatment

### **Non-small cell carcinoma**

Therapy depends on the clinical stage (which is determined according to the TNM classification)

Stage I – III a – primarily surgical treatment – resection procedure, followed by systemic treatment  
Stage IIIB and IV inoperable – systemic treatment + chest RT.

### **Surgical treatment**

Resection procedures for lung tumors are possible from thoracotomy or minimally invasive - video-assisted (VATS), or robotically. According to the extent of the tumor, its location and possibly affecting important structures, various types of performance can be performed. Part of the procedure also includes the removal of lymph nodes - mediastinal lymphadenectomy. The main types of performance are

Lobectomy - one or two lobes of the lung organ are removed. This method is often used in patients with an early stage lung tumor, when the tumor is limited to the area of one or two lung lobes.

Lobectomy makes it possible to remove the affected part of the lung and minimize the loss of healthy tissue.

Pneumonectomy – the entire wing of the lung is removed. This method is used in patients with a more extensive tumor, possibly growing into the lung hilum, which cannot be removed by lobectomy. A pneumonectomy is a major operation and may have a greater risk of complications,

Segmentectomy - sublobar resection - involves the removal of 1 lung segment. This procedure is used in patients with small tumors or those who cannot undergo a lobectomy because of medical problems or limited lung function.

A wedge resection is another type of sublobar resection in which a small wedge-shaped piece of the lung with the tumor is removed with a smaller border of healthy tissue. This procedure may be suitable for patients with small tumors, metastases, or patients with limited lung function. It is also one possibility to collect a sample for histological verification of the tumor.

### **Malignant mesothelioma**

Mesothelioma is a tumor arising from the mesothelium (the lining of body cavities originating from the coelomic epithelium). The biological nature of mesothelioma can be benign or malignant (malignant mesothelioma is characterized by implantation metastases - dissemination through the serosa (the so-called diffuse malignant mesothelioma). Plate-like thickening of the visceral and parietal serous sheet occurs, and the tumor invasively grows into the body wall and internal organs). The localization of mesotheliomas is mainly – pleura, pericardium, peritoneum, possibly. periorchium

**Malignant mesothelioma of the pleura** is an occupational disease - it is usually related to many years of exposure to asbestos. Symptoms include chest pain, shortness of breath, and pleural effusion. It usually takes up to several decades (even more than 50 years) from exposure to the formation of a tumor. Therapy is primarily systemic treatment and chemotherapy. Surgical treatment

is possible only in the case of localized tumors penetrating into the parenchyma, possibly the surgical procedure is used to take a biopsy from the pleura.

