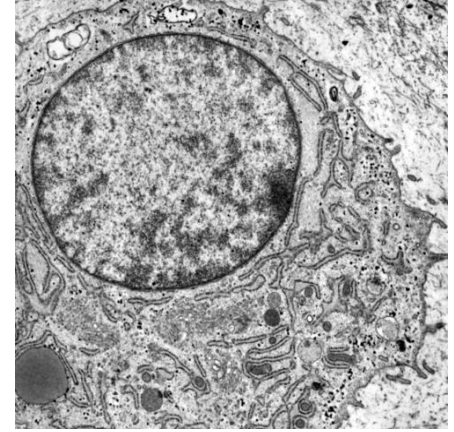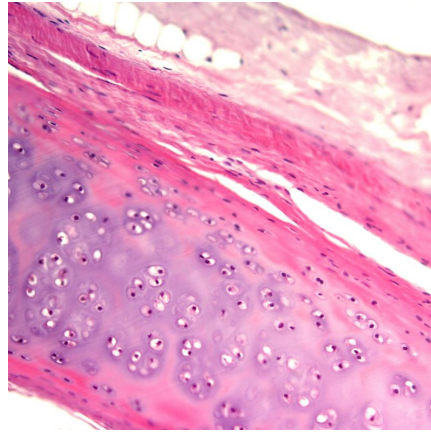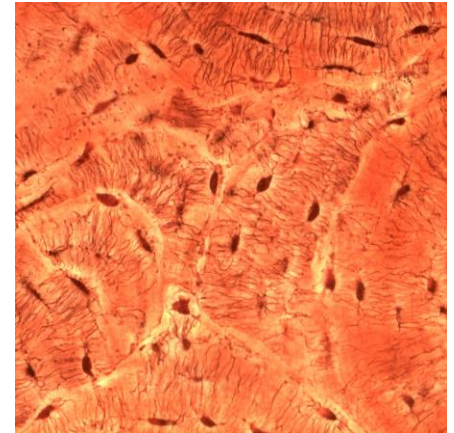


Connective tissue II 2024



Cartilage and bone

Petr Vaňhara

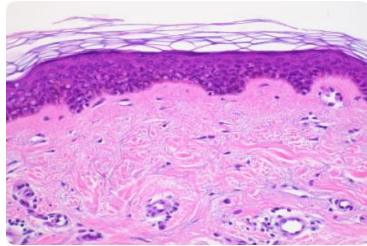
Department of Histology and Embryology,
Faculty of Medicine MU

pvanhara@med.muni.cz

CONTEMPORARY TISSUE CLASSIFICATION


Tissue classification is based on **morphology** and **function**:

Epithelial tissue



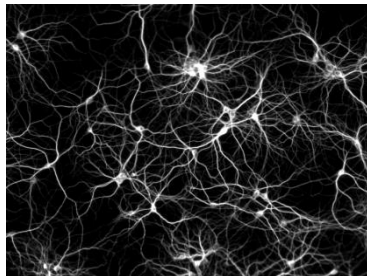
Continual, avascular layers of cells with different function, oriented to open space, with specific junctions and minimum of ECM and intercellular space.
Derivates of all three germ layers

Muscle tissue



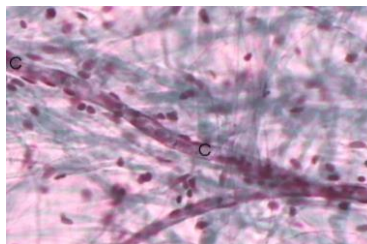
Myofibrils → contraction
Mesoderm – skeletal muscle, myocard, mesenchyme
– smooth muscles

Nerve tissue



Neurons and neuroglia
Reception and transmission of electric signals
Ectoderm

Connective tissue



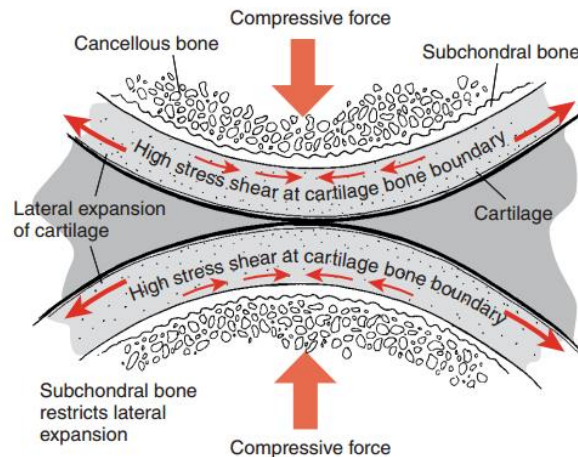

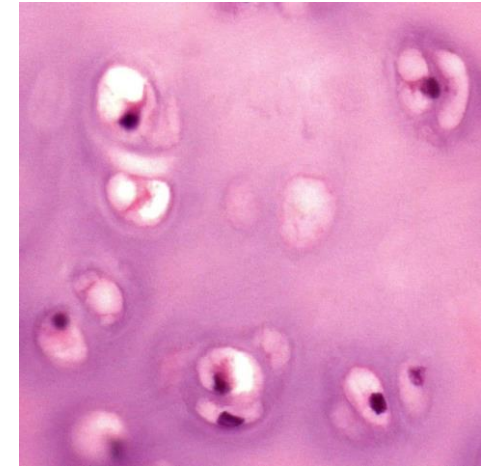

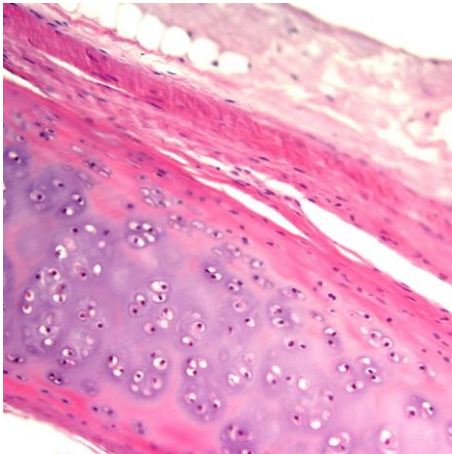
Dominant extracellular matrix
Connective tissue, cartilage, bone...
Mesenchymal origin

TISSUE =

ECM

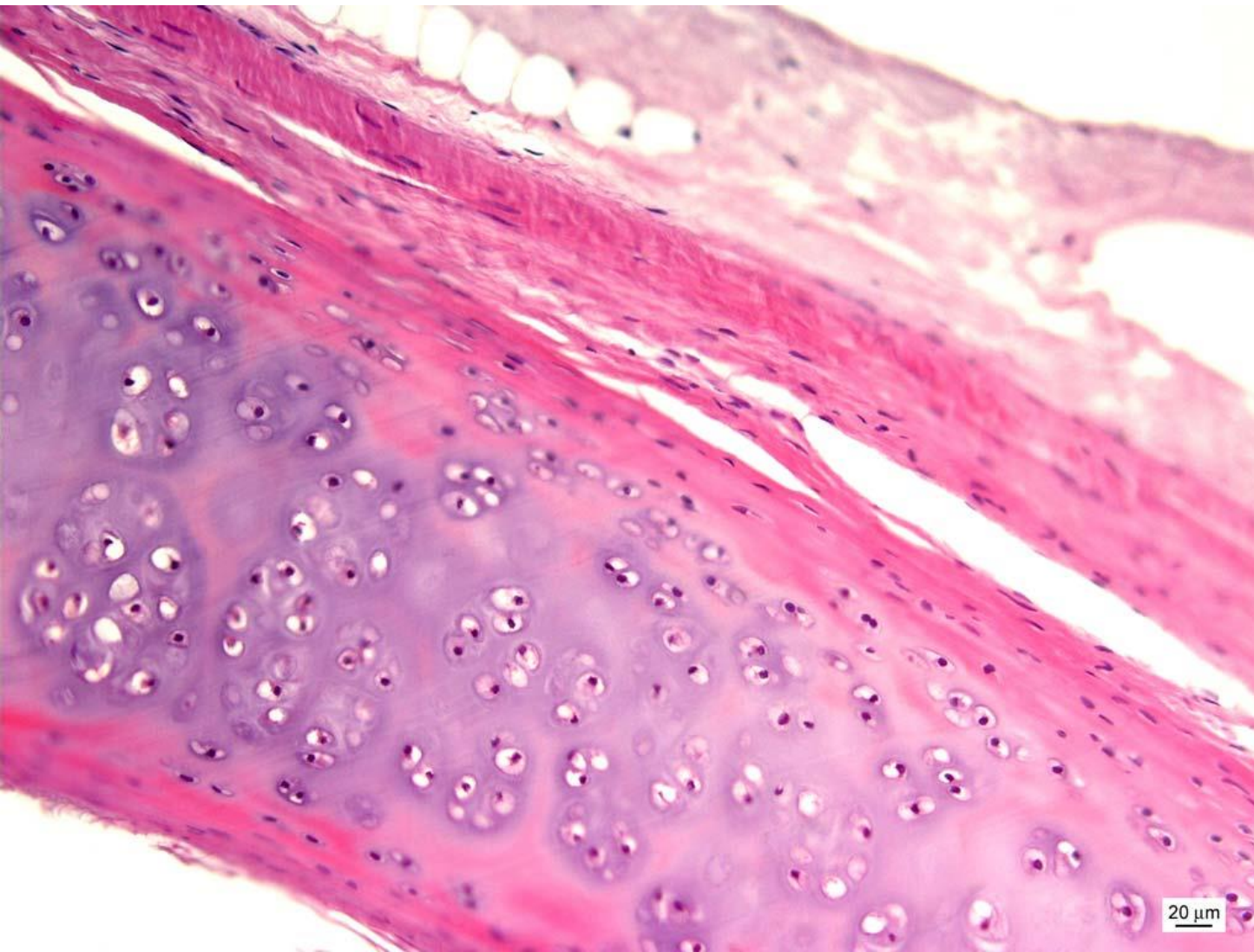
+

Buňky



Biochemical and biomechanical properties

CARTILAGE

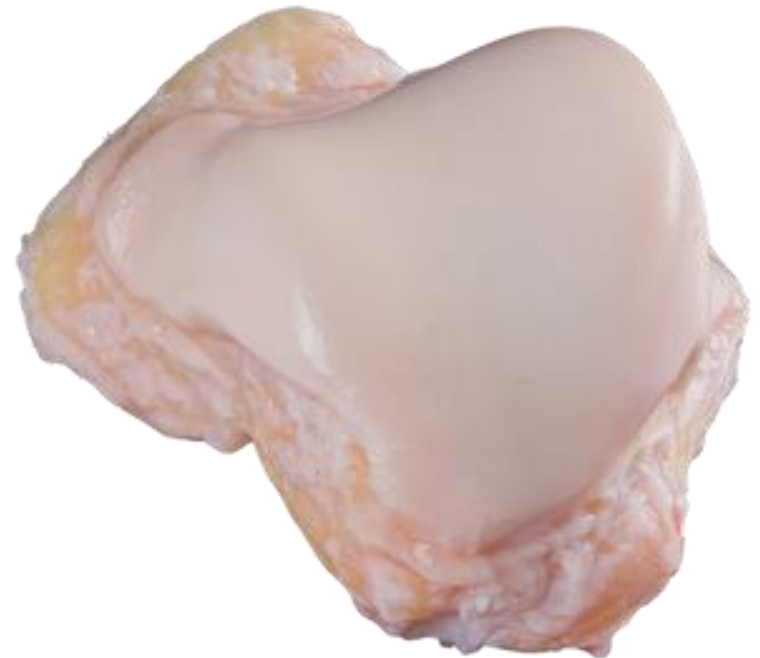

CARTILAGE

General features:

- **specialized connective tissue** with continuous ECM
- flexible, mechanically resistant
- avascular, non-innervated
- support of soft tissues - trachea, larynx
- skeletal support - costal cartilages
- diarthrosis - joints
- bone growth

1. **cells**
2. **protein fibrils**
3. **amorphous ground substance**



CARTILAGE – COMPOSITION AND STRUCTURE

- **Perichondrium** – connective tissue around cartilage (except joints)

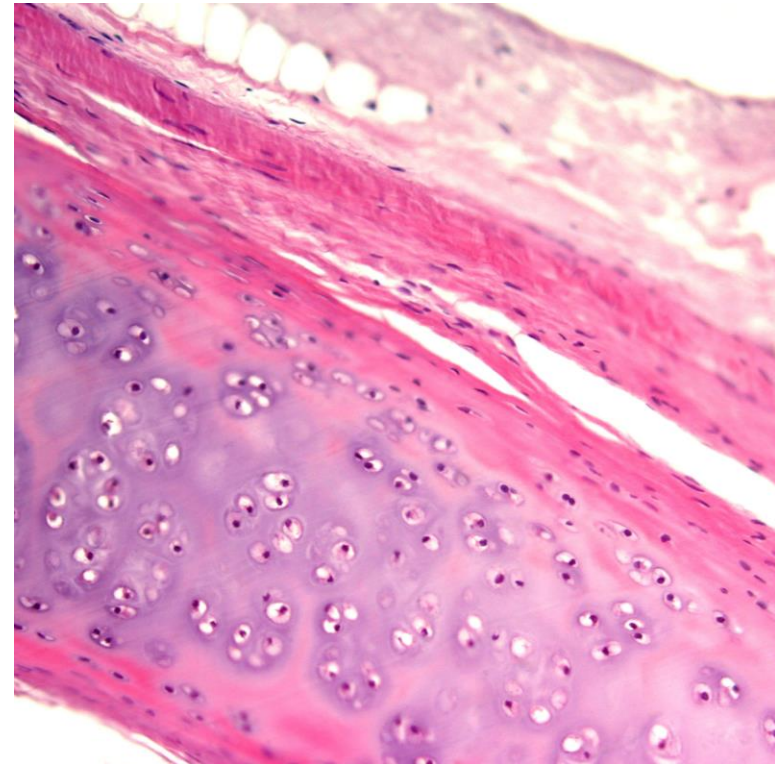
Nutrition
Growth

- **Extracellular matrix** – water, proteoglycans and collagen fibrils

Solid consistence
Pressure elasticity

- **Cells** of cartilage - chondroblasts, chondrocytes

Growth
ECM production



Hyaline

Elastic

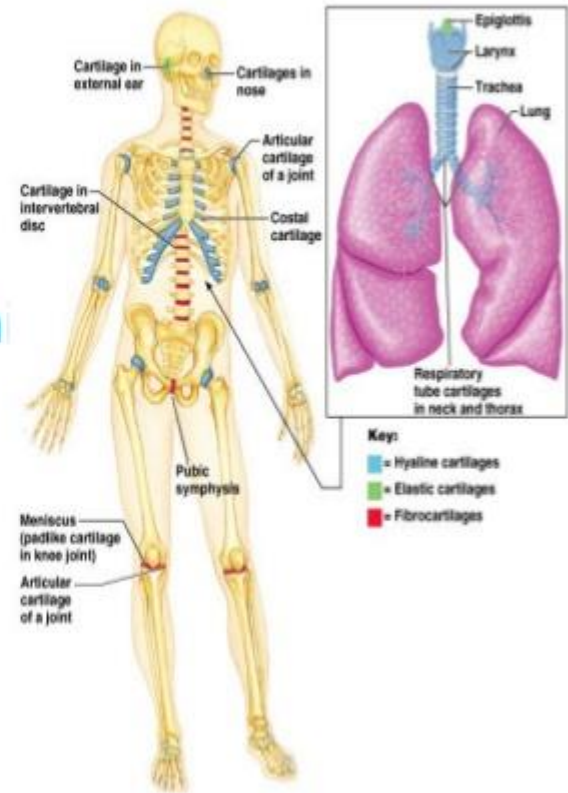
Fibrous

cartilage in adults

- Nose
- Joint surfaces
- Costal
- Larynx - voice box
- rings of trachea & bronch

- External ear
- Epiglottis
- Eustachian tube

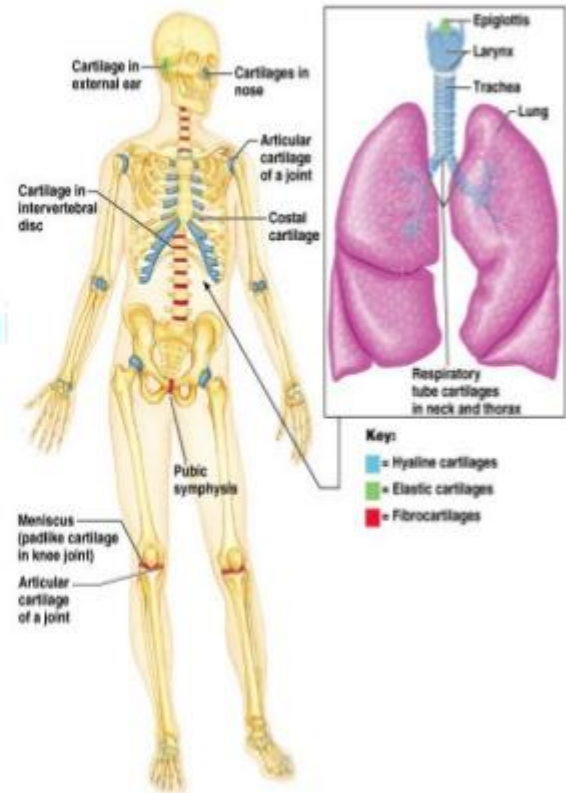
- IVDs
- Pubic symphysis
- meniscus in knee joint



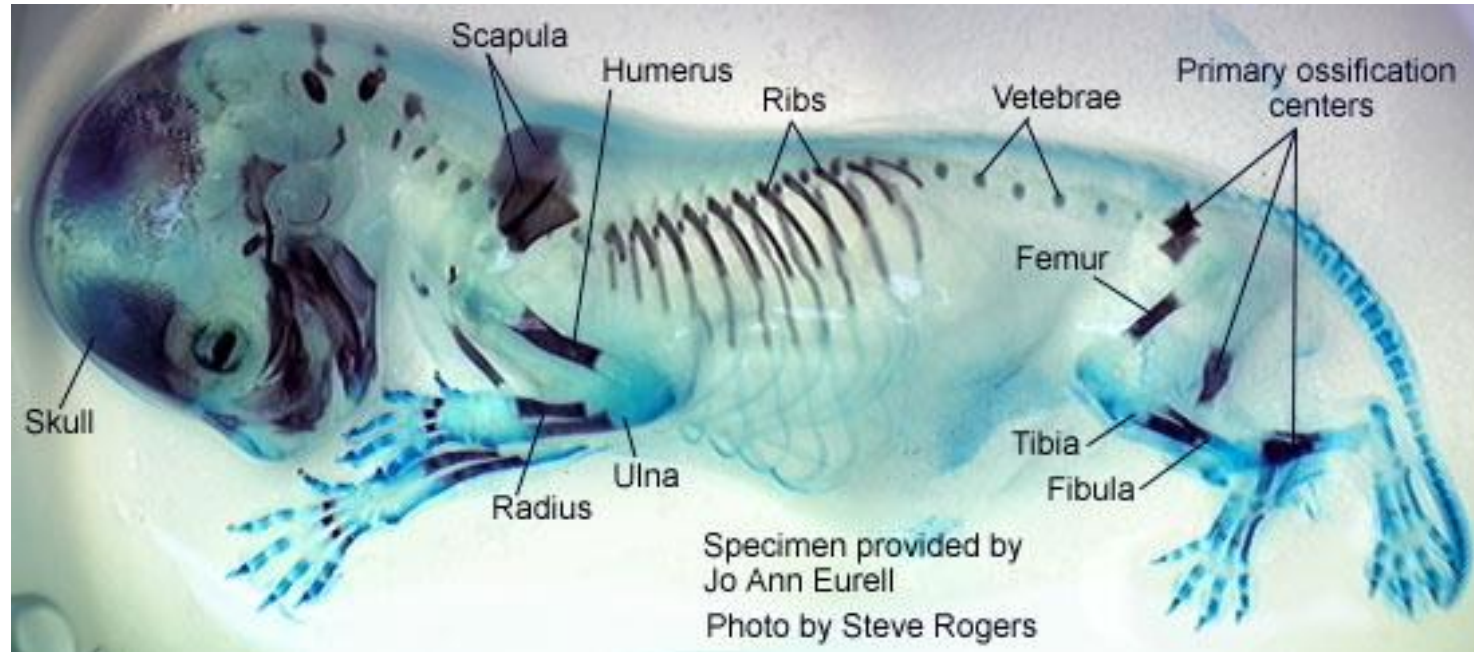
Hyaline

cartilage in adults

- Nose
- Joint surfaces
- Costal
- Larynx - voice box
- rings of trachea & bronch



Hyaline



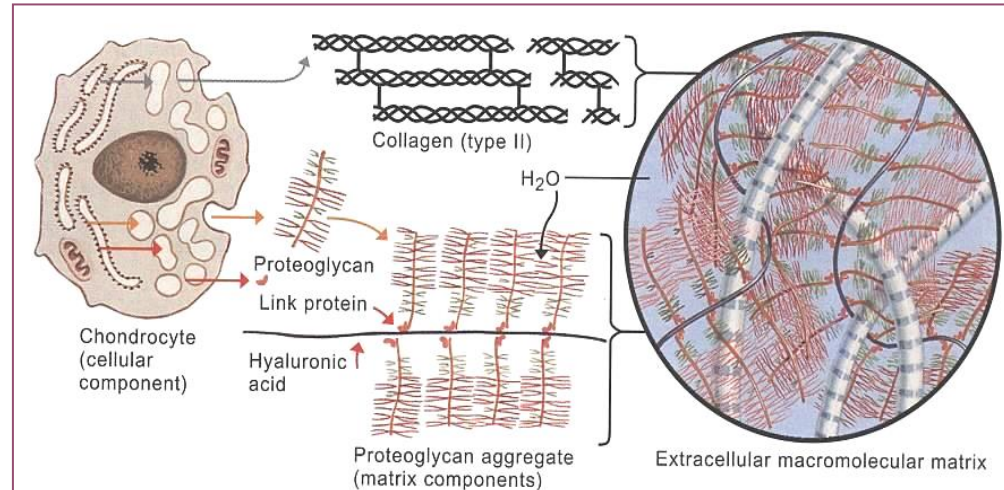
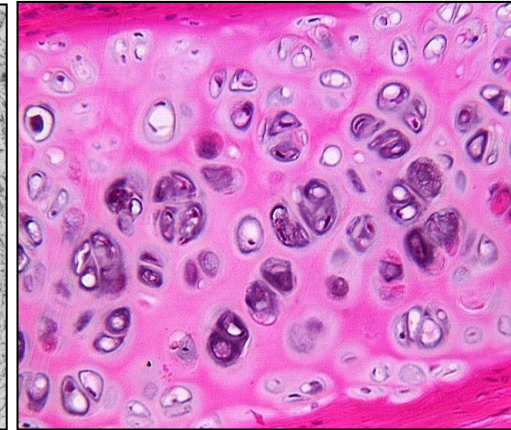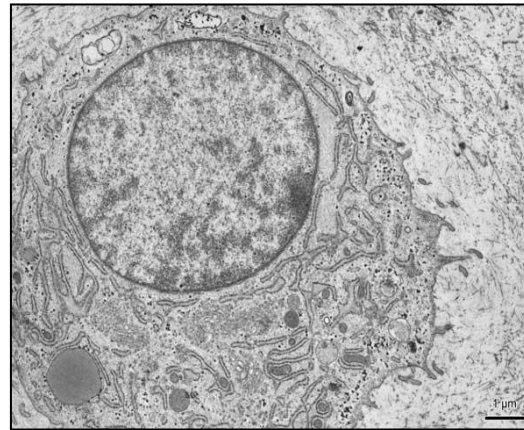Alcian Blue&Alizarin Red

- most abundant
- temporary embryonal/fetal skeleton
- epiphyseal growth plate
- articulation (joints) respiratory passages

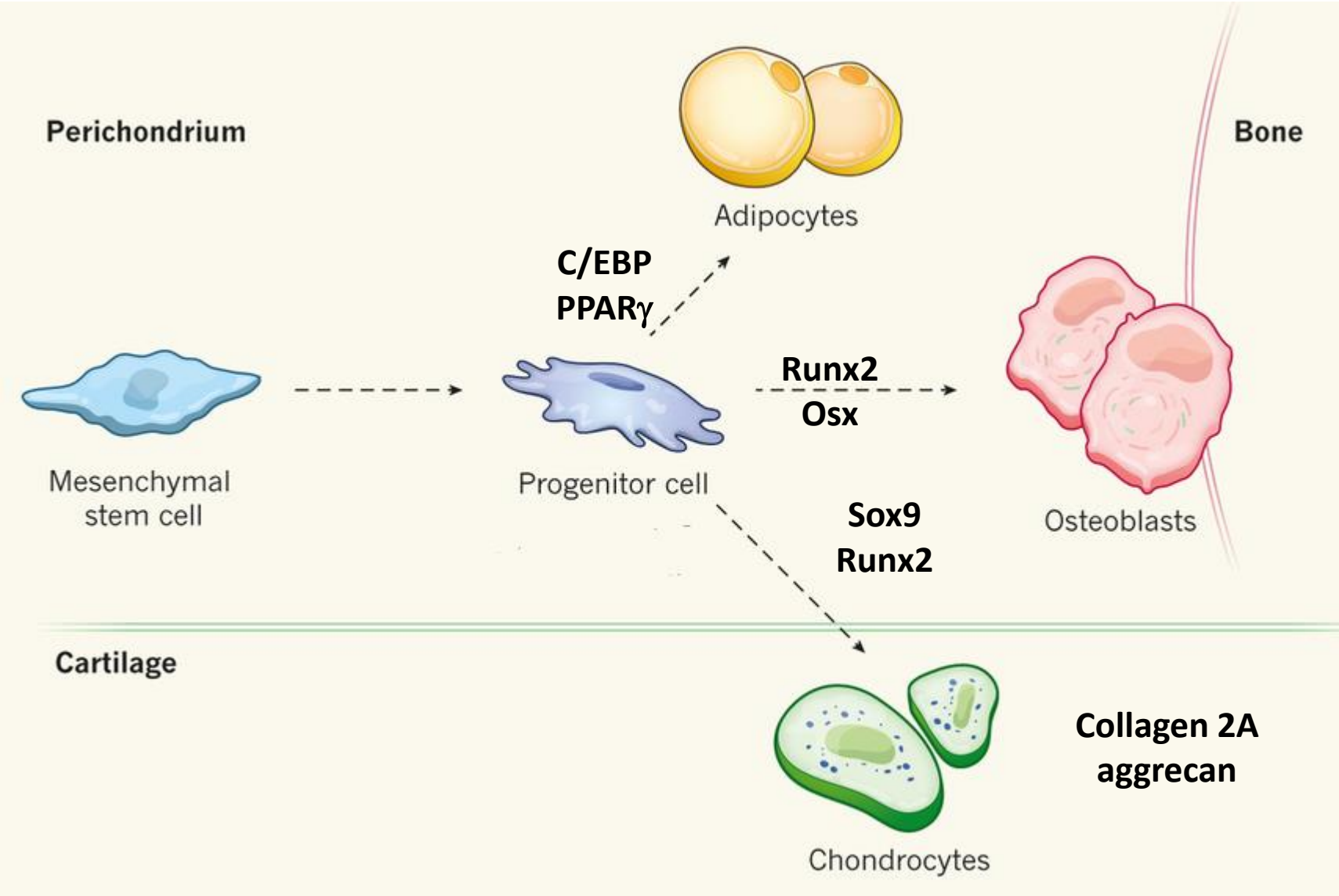
CELLS OF CARTILAGE

Chondroblasts and chondrocytes

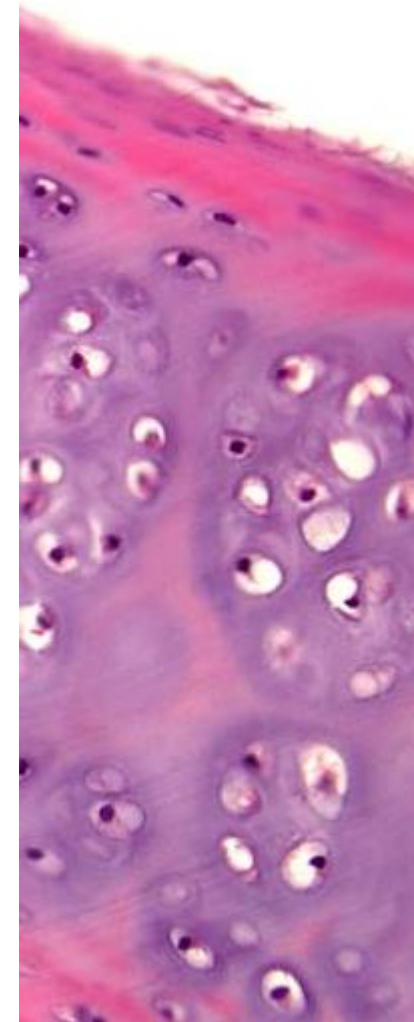
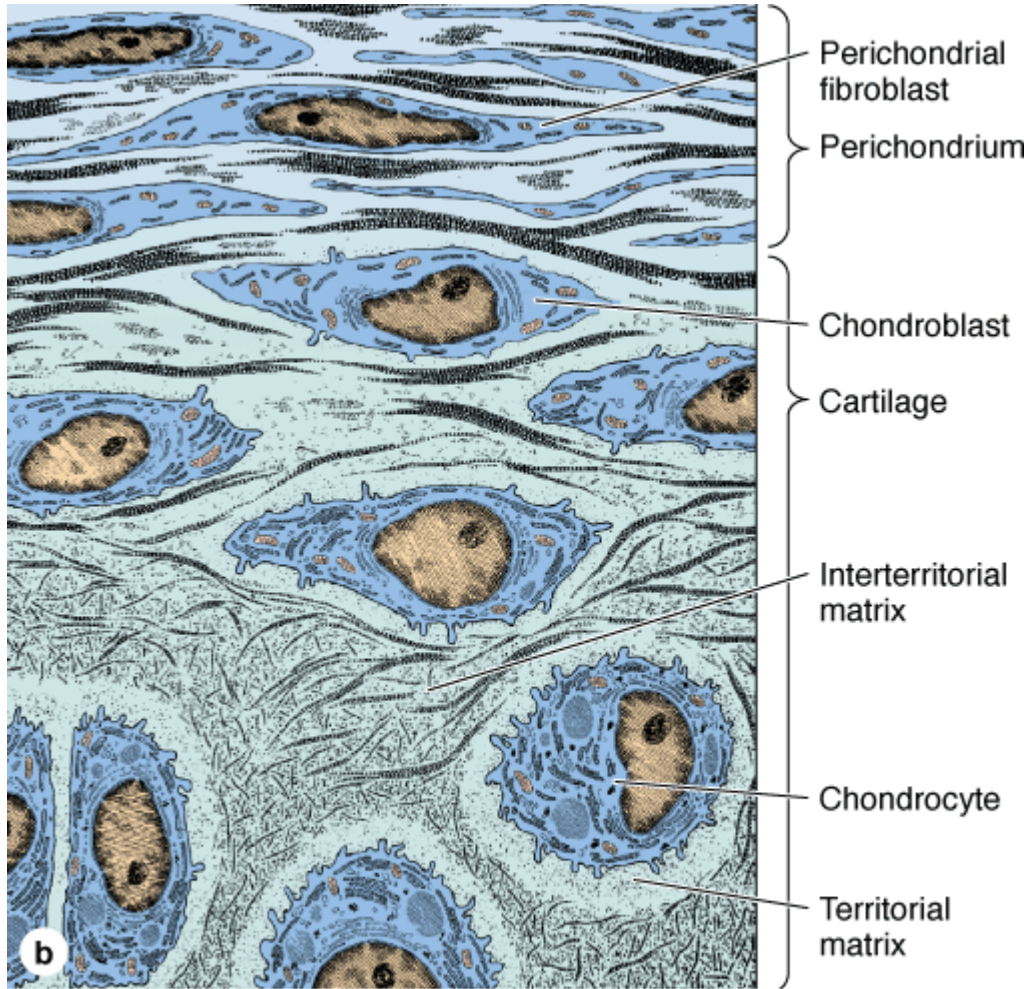
- mesenchymal origin
- typical ultrastructure of proteosynthetically active cells
- production of extracellular matrix
- interstitial proliferation
- isogenous groups, lacunae



DIFFERENTIATION OF CHONDROBLASTS



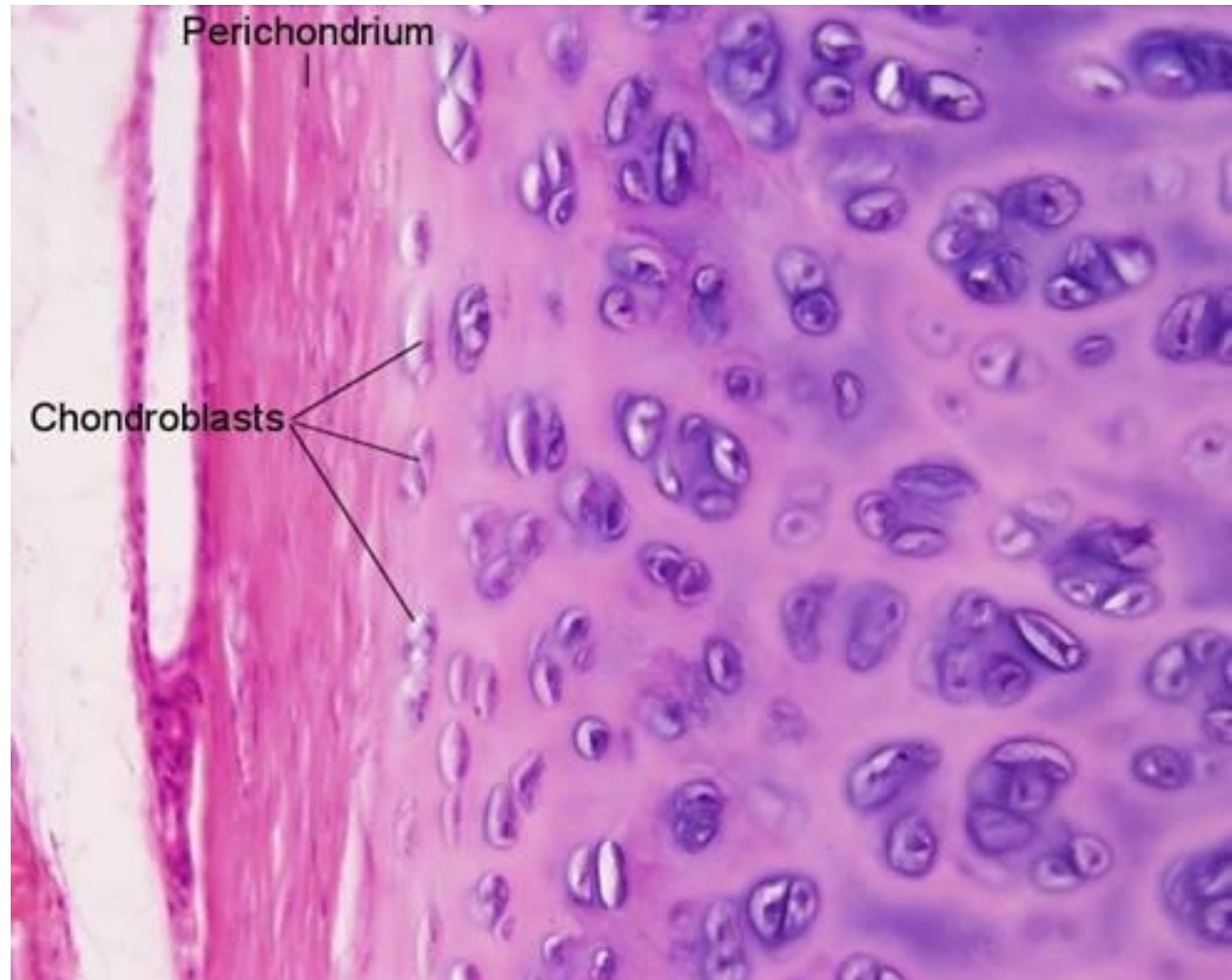
DIFFERENTIATION OF CHONDROBLASTS AND CHONDROCYTES



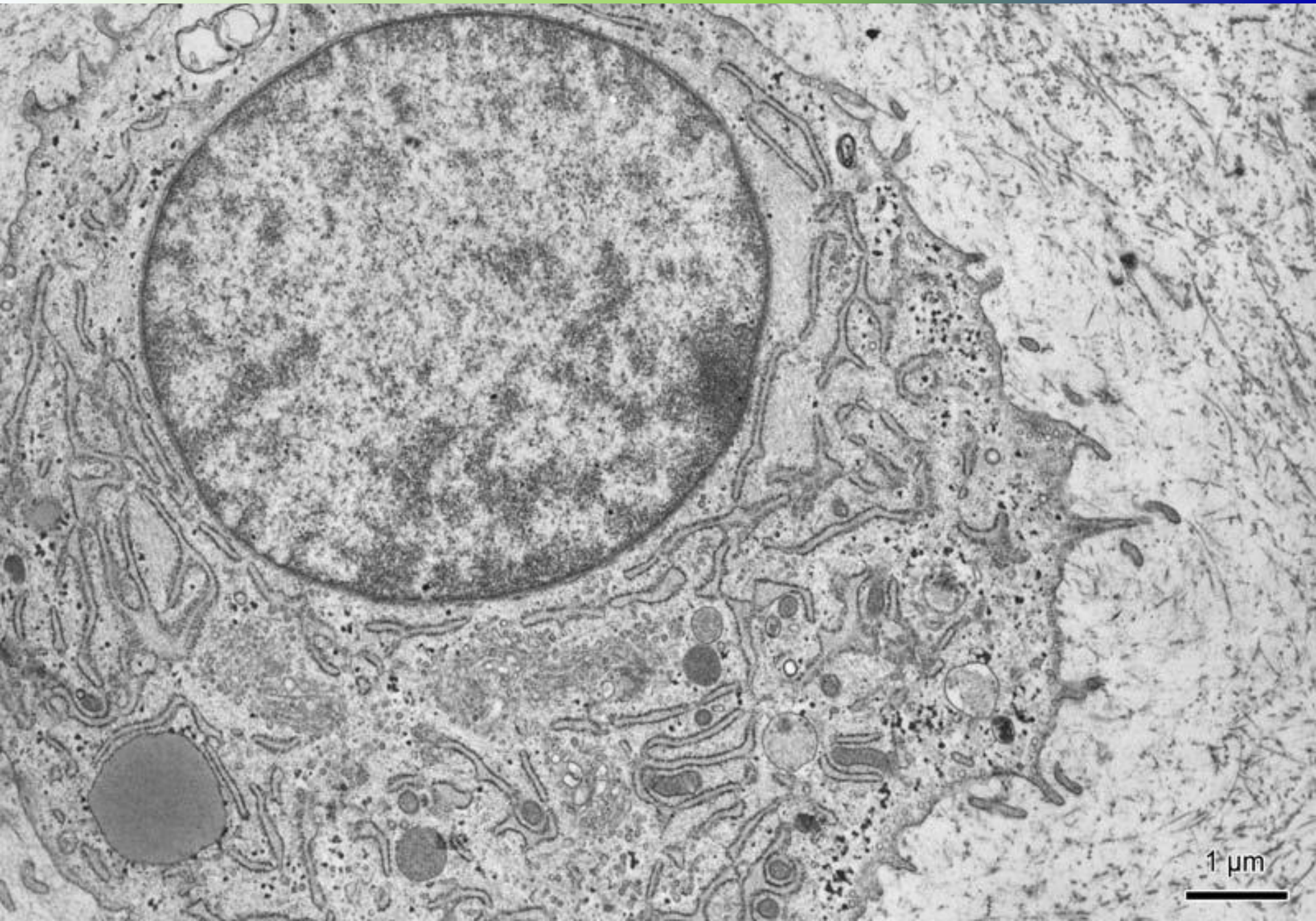
Source: Mescher AL: *Junqueira's Basic Histology: Text and Atlas, 12th Edition*: <http://www.accessmedicine.com>
Copyright © The McGraw-Hill Companies, Inc. All rights reserved.

ULTRASTRUCTURE OF CHONDROCYTES

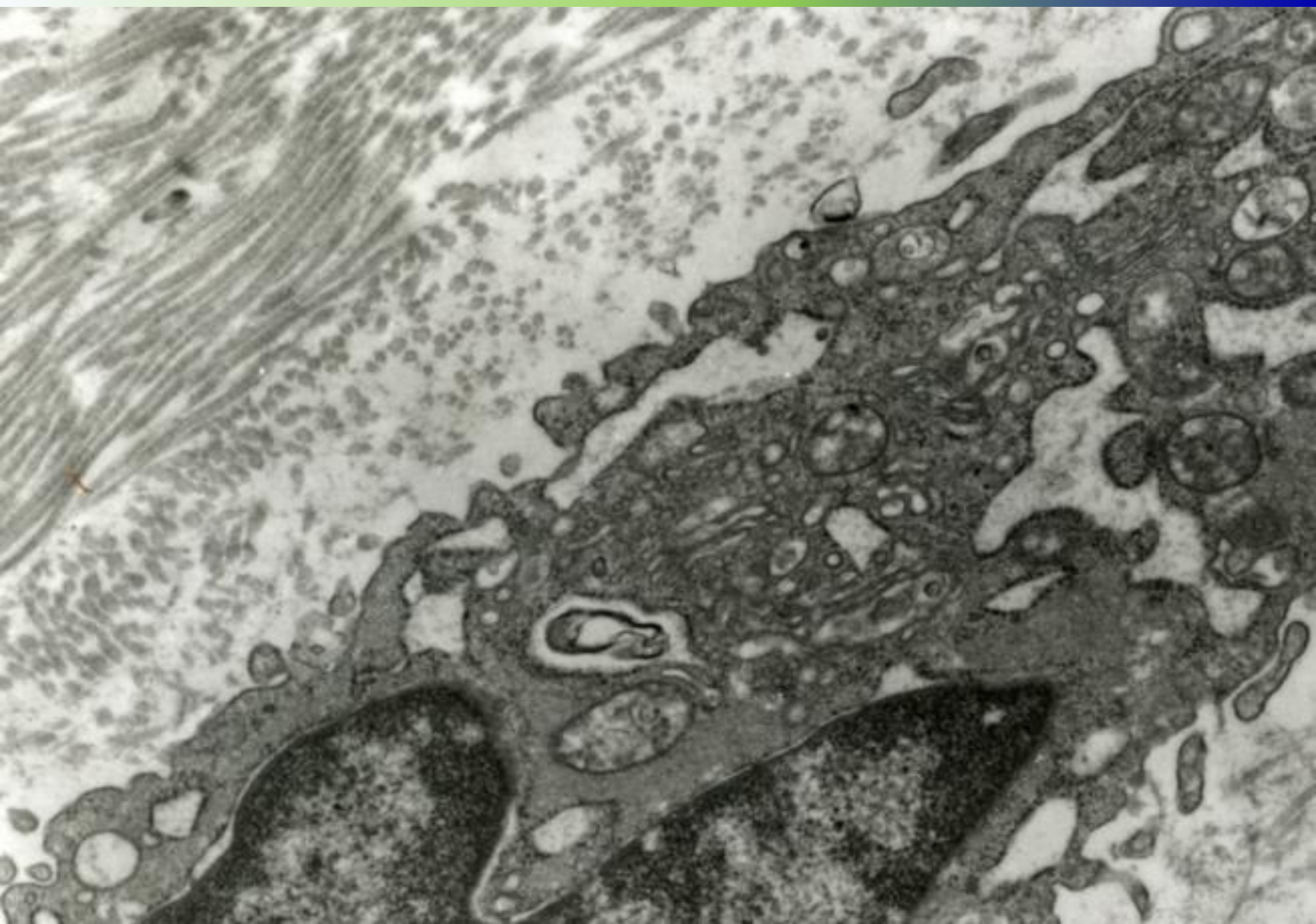
- oval → round cells
- rich in organelles: rER and GA
- glycogen granules (anaerobic metabolism)
- occasionally lipid droplets



ULTRASTRUCTURE OF CHONDROCYTES



ULTRASTRUCTURE OF CHONDROBLASTS




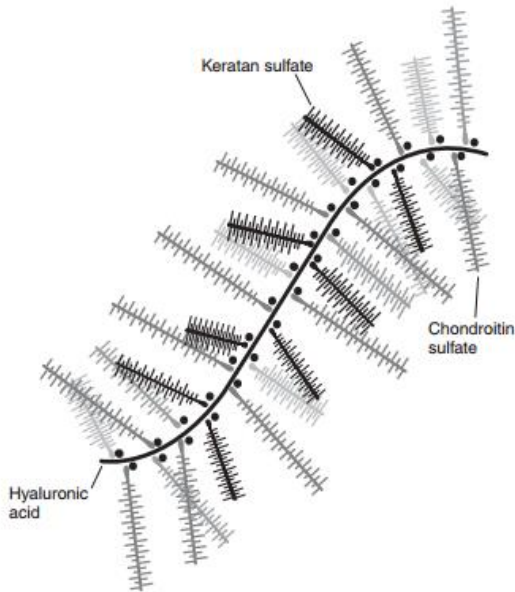
Extracelular matrix

glycosaminoglycans

proteoglycans

fibers

water



biomechanical properties

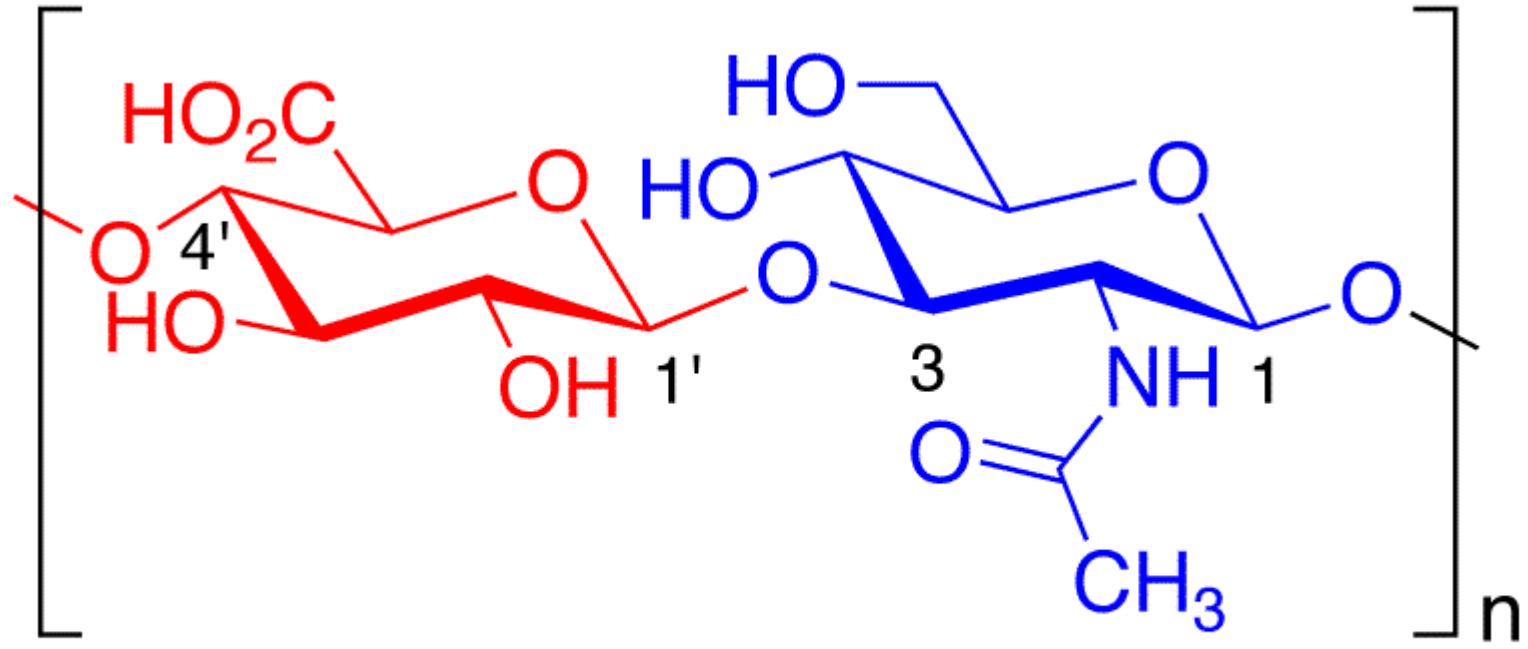
GLYCOSAMINOGLYCANS IN CARTILAGE

linear unbranched polysaccharides containing a repeating disaccharide unit:

1. *N*-acetylgalactosamine (GalNAc) or *N*-acetylglucosamine (GlcNAc)
2. uronic acid (glucuronate (GlcA)) or iduronate.



hyaluronic acid



Glucuronic Acid N-Acetyl-D-glucosamine

GLYCOSAMINOGLYCANS IN CARTILAGE

Glycosaminoglycan

Localization

Hyaluronic acid

Umbilical cord, synovial fluid, fluid of corpus vitreum, cartilage

Chondroitinsulphate

Cartilage, bone, cornea, skin, notochord, aorta

Dermatansulphate

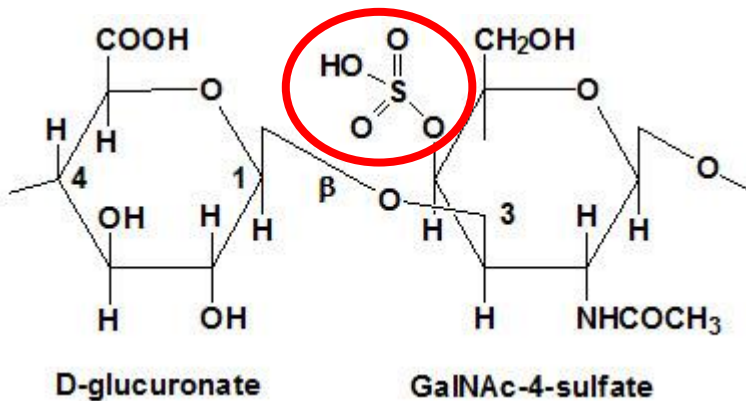
Skin, ligaments, adventitia of aorta

Heparansulphate

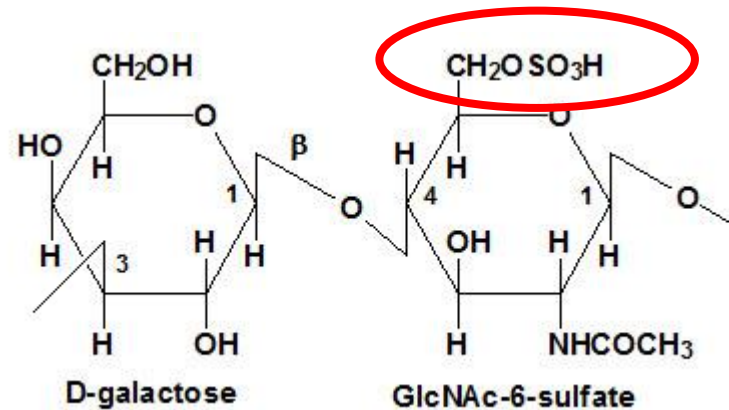
Aorta, lungs, liver, basal membranes

Keratansulphate

Iris, cartilage, nucleus pulposus, anulus fibrosus



Chondroitinsulphate



Keratansulphate

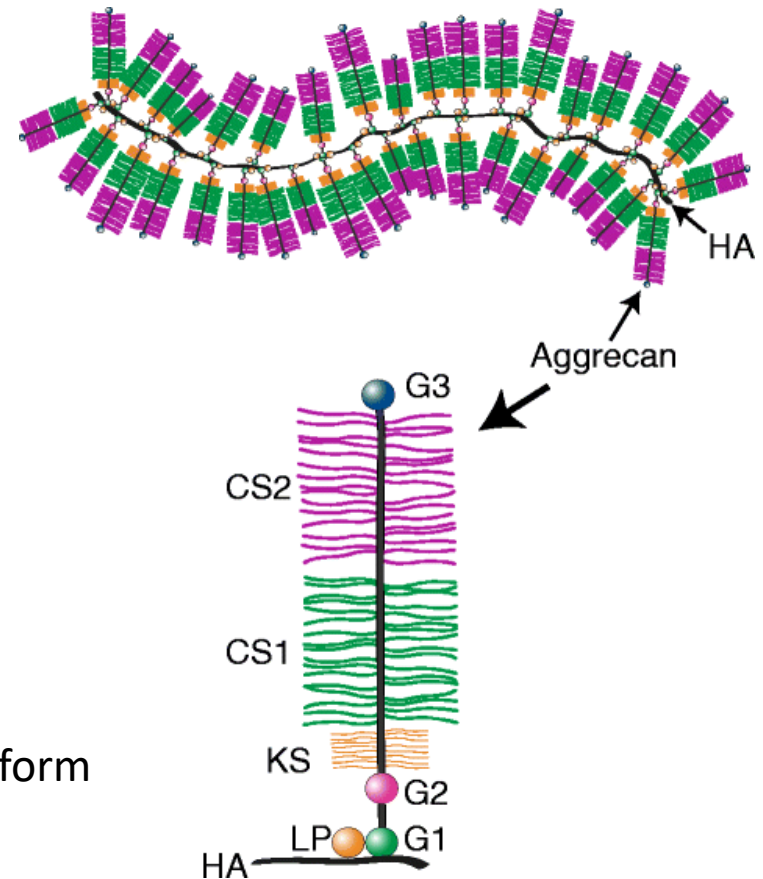
PROTEOGLYCANS AND FIBERS

- **proteoglycans**

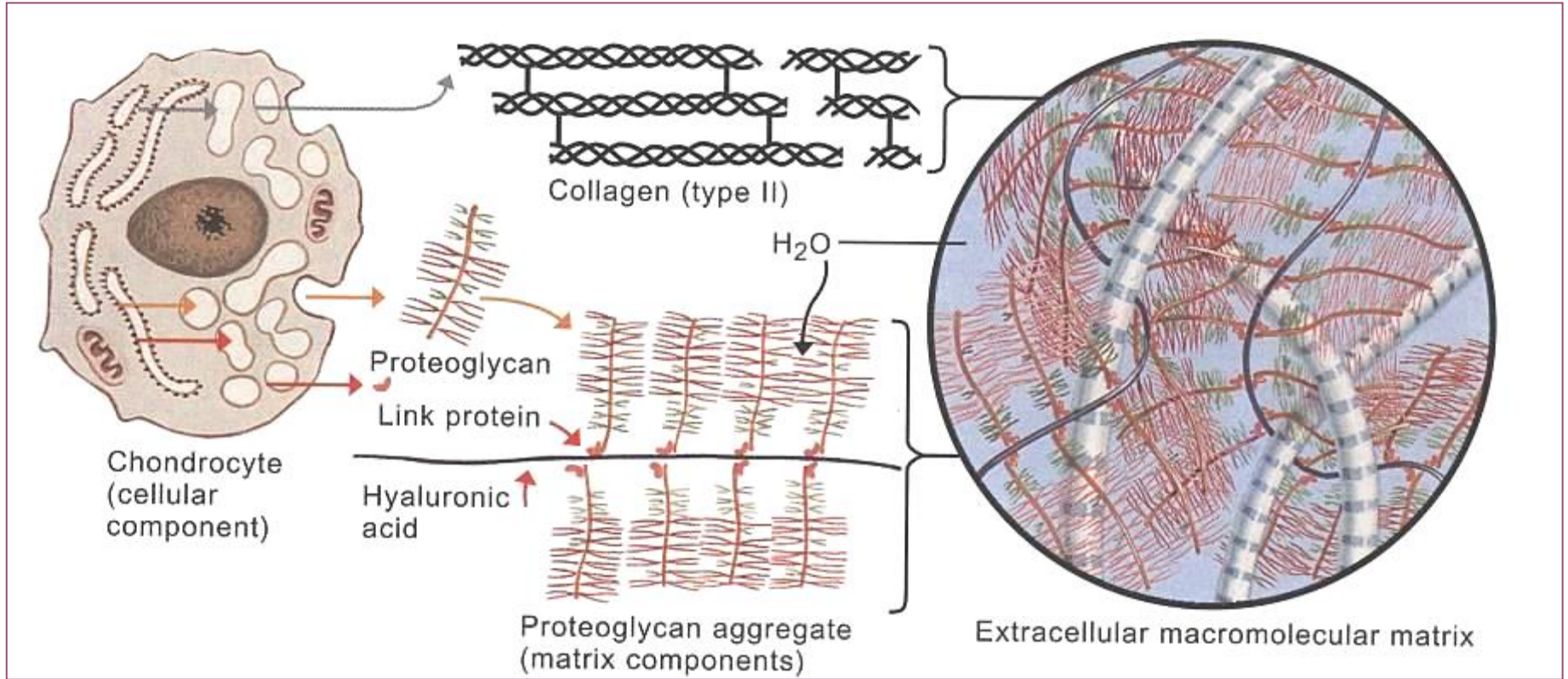
- protein + dominant linear saccharide component
- proteoglycan aggregates
- water-binding – 80%, volume dependent of hydration
 - **aggrecan (cartilage)**
 - syndekan
 - fibroglykan

- **collagen fibrils**

- col II + col IX/XI
- thin fibrils (15-20 nm → no striation) that do not form fibers like col I
- interconnected with perichondrium
- elastic fibers



TISSUE ARCHITECTURE OF CARTILAGE ECM

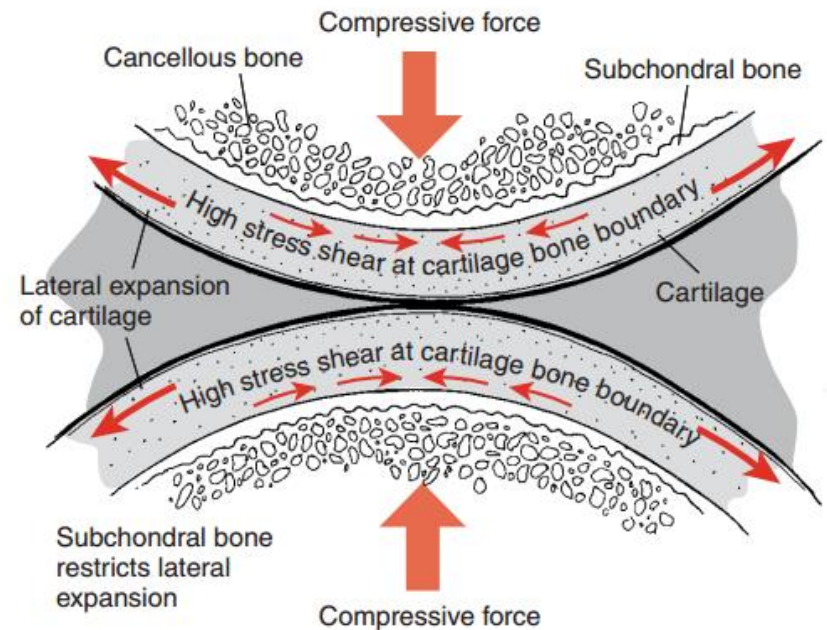


transduction of biochemical and biomechanical signals

TISSUE ARCHITECTURE OF CARTILAGE ECM

- **pressure elasticity**

- proteoglycans – polyanionic (COO^- , $\text{SO}_4^{\text{II}-}$)
- expansion prevented by collagen fibrils
- repulsion forces



- **biphasic model of cartilage** → ECM composition

- proteoglycans, collagen, cells, and lipids constitute the solid phase of the mixture
- interstitial fluid that is free to move through the matrix (fluid phase)
- under impact loads, fluid flows through the framework, until the cartilage starts to behave as a single-phase, incompressible, elastic solid - the fluid does not flow
- after load release, fluid returns
- nutritive aspect

TISSUE ARCHITECTURE OF CARTILAGE ECM

- **synovial cartilage**

I. tangential (superficial) zone

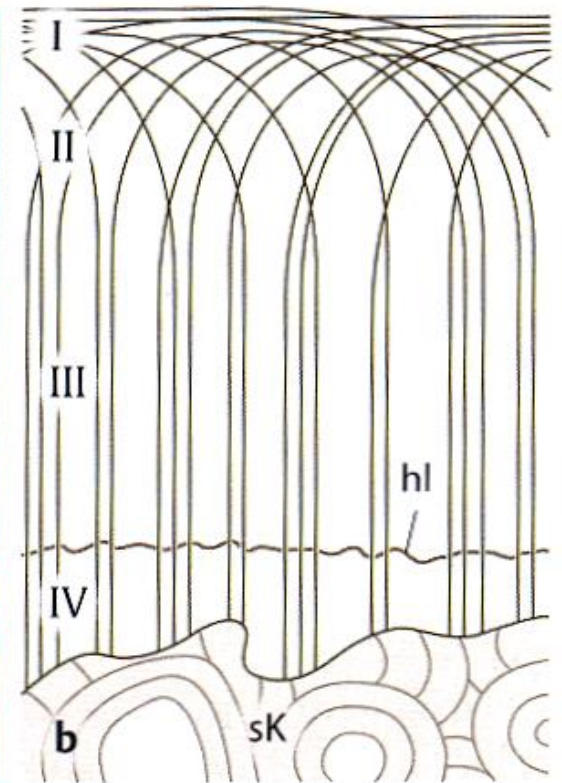
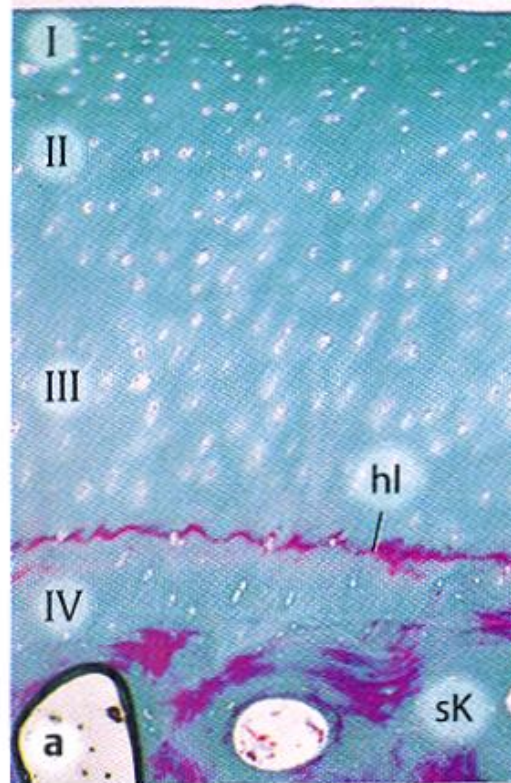
II. transitional zone

III. radial (deep) zone

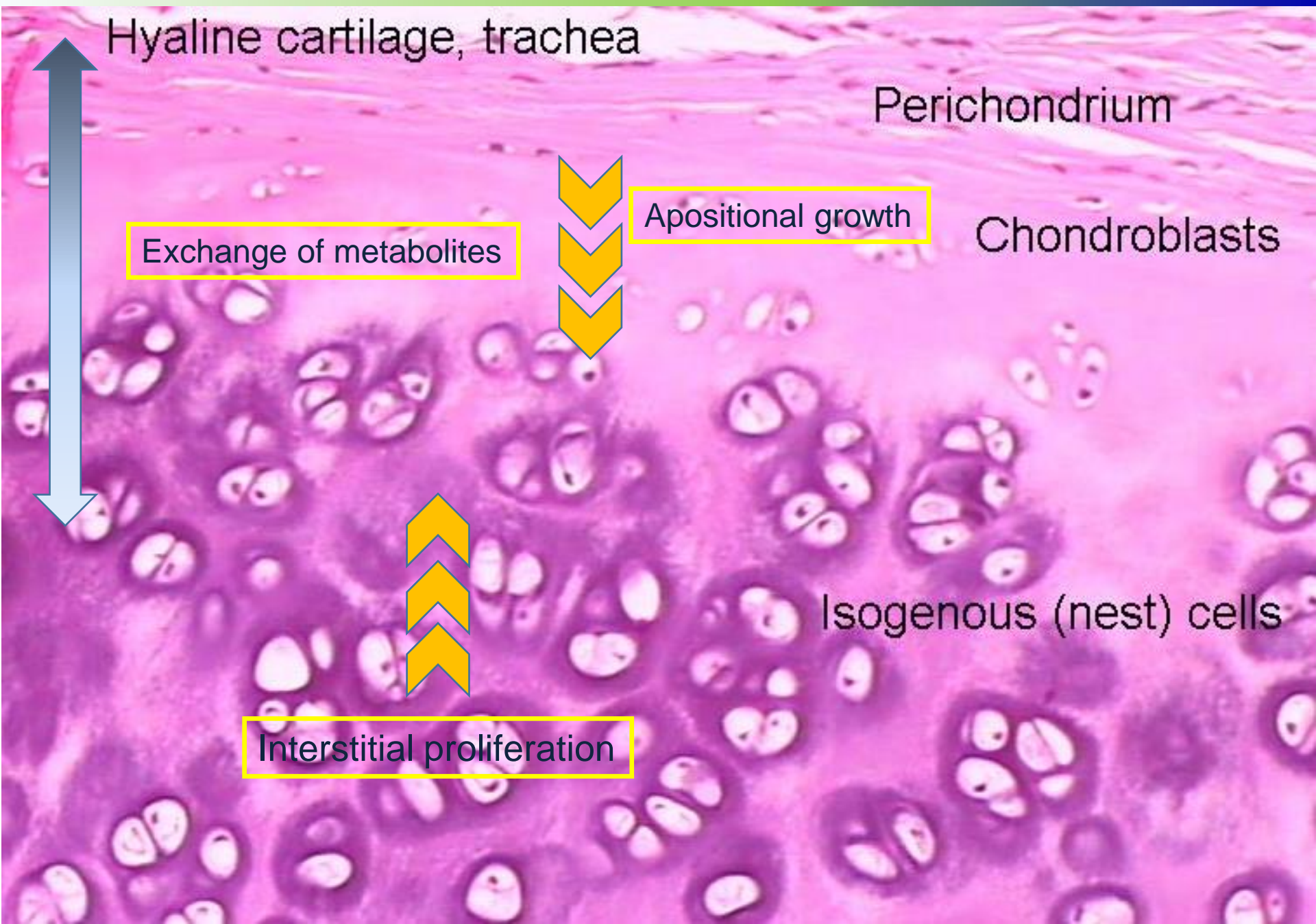
tide mark

I. mineralized cartilage zone

subchondral bone



NUTRITION AND GROWTH



PERICHONDRIUM

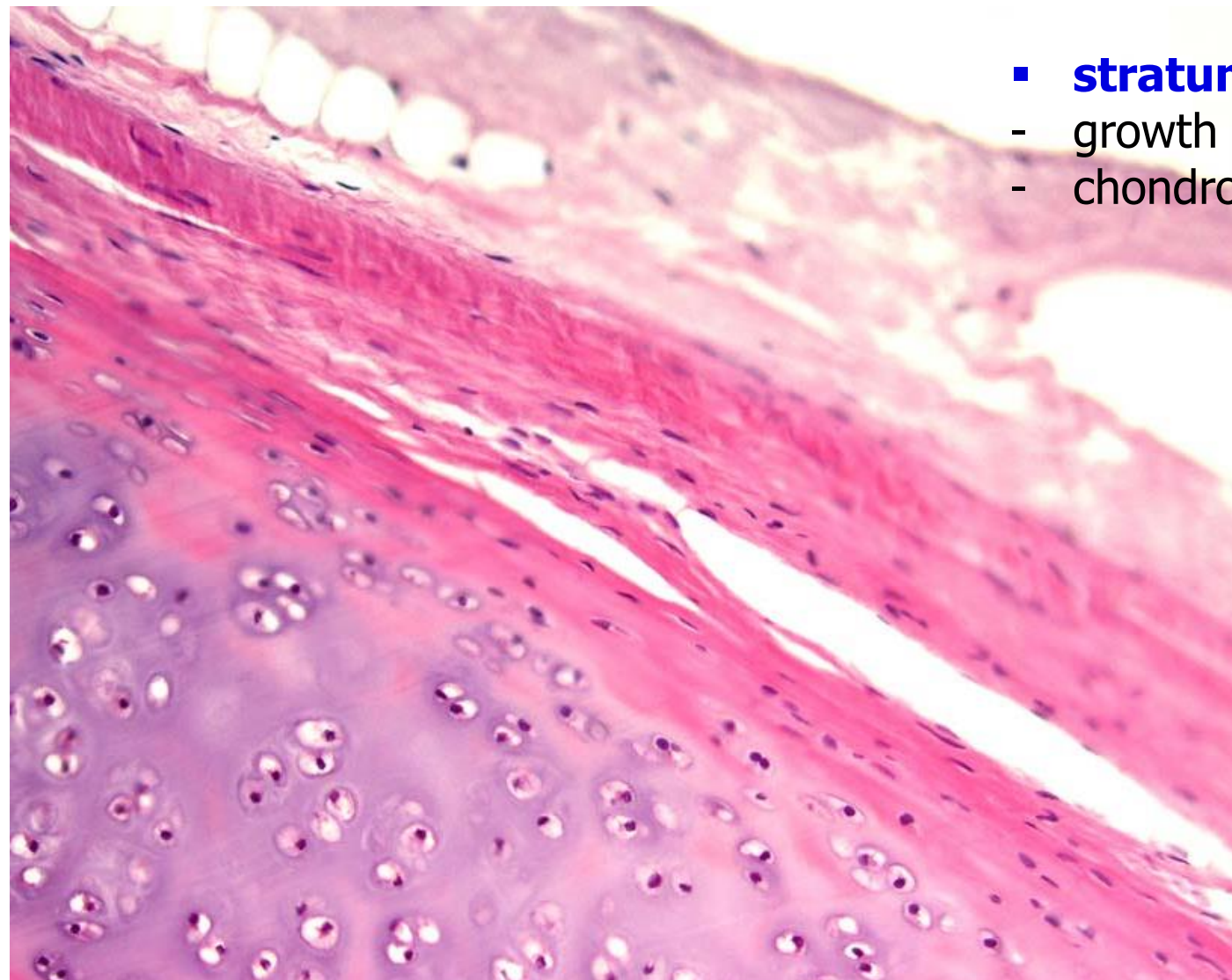
- **stratum fibrosum**

- biomechanics

- **stratum chondrogenicum**

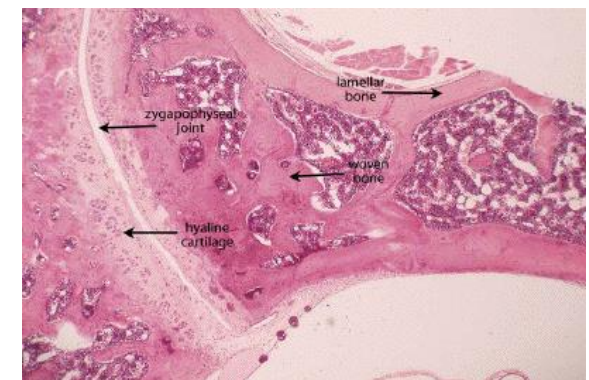
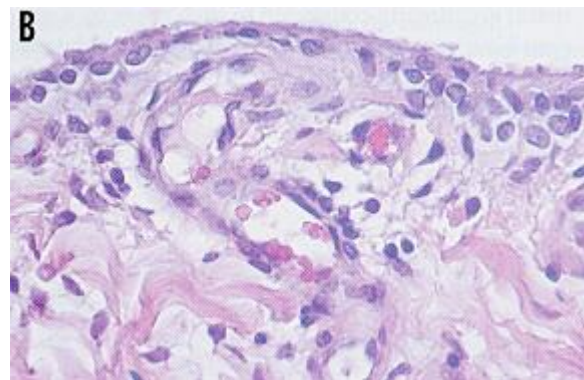
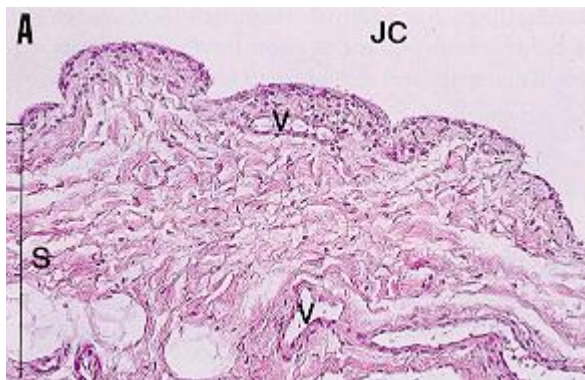
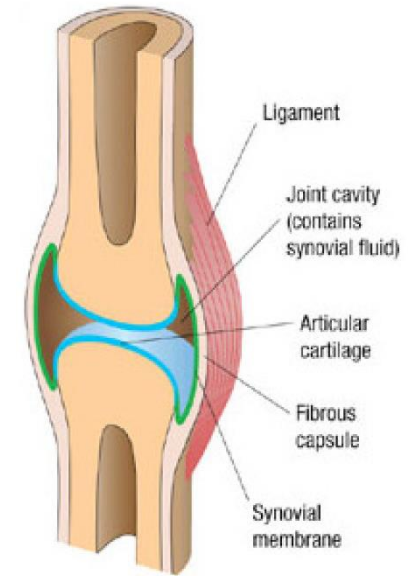
- growth

- chondroprogenitors



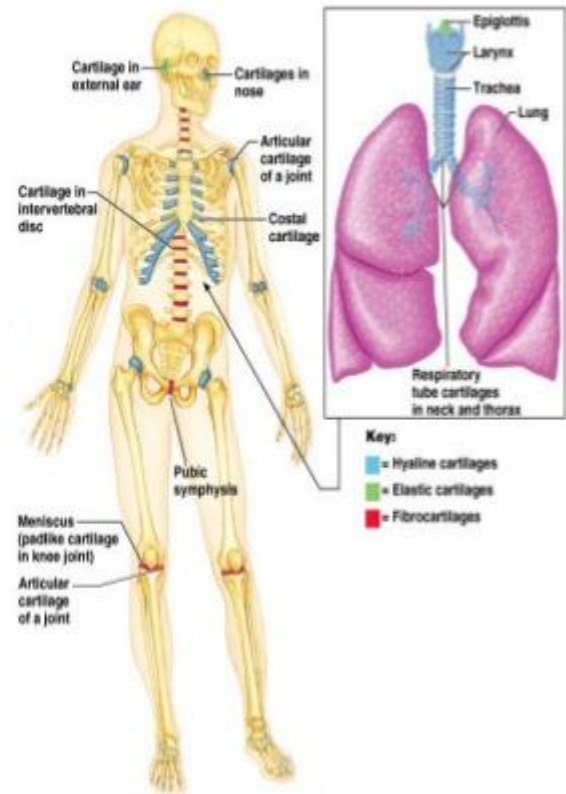
SYNOVIUM

- **membrana fibrosa**
 - dense collagen c.t.
- **membrana synovialis**
 - intima, subintima
 - folds extending to the joint cavity
 - numerous blood and lymphatic vessels, nerves
 - discontinuous cell layers (synovialocytes)
 - basal membrane and intercellular junctions absent - not epithelium: mesenchymal (c.t.) origin
 - synovial fluid rich in hyaluronans
 - *bursae synoviales, vaginae tendineum*



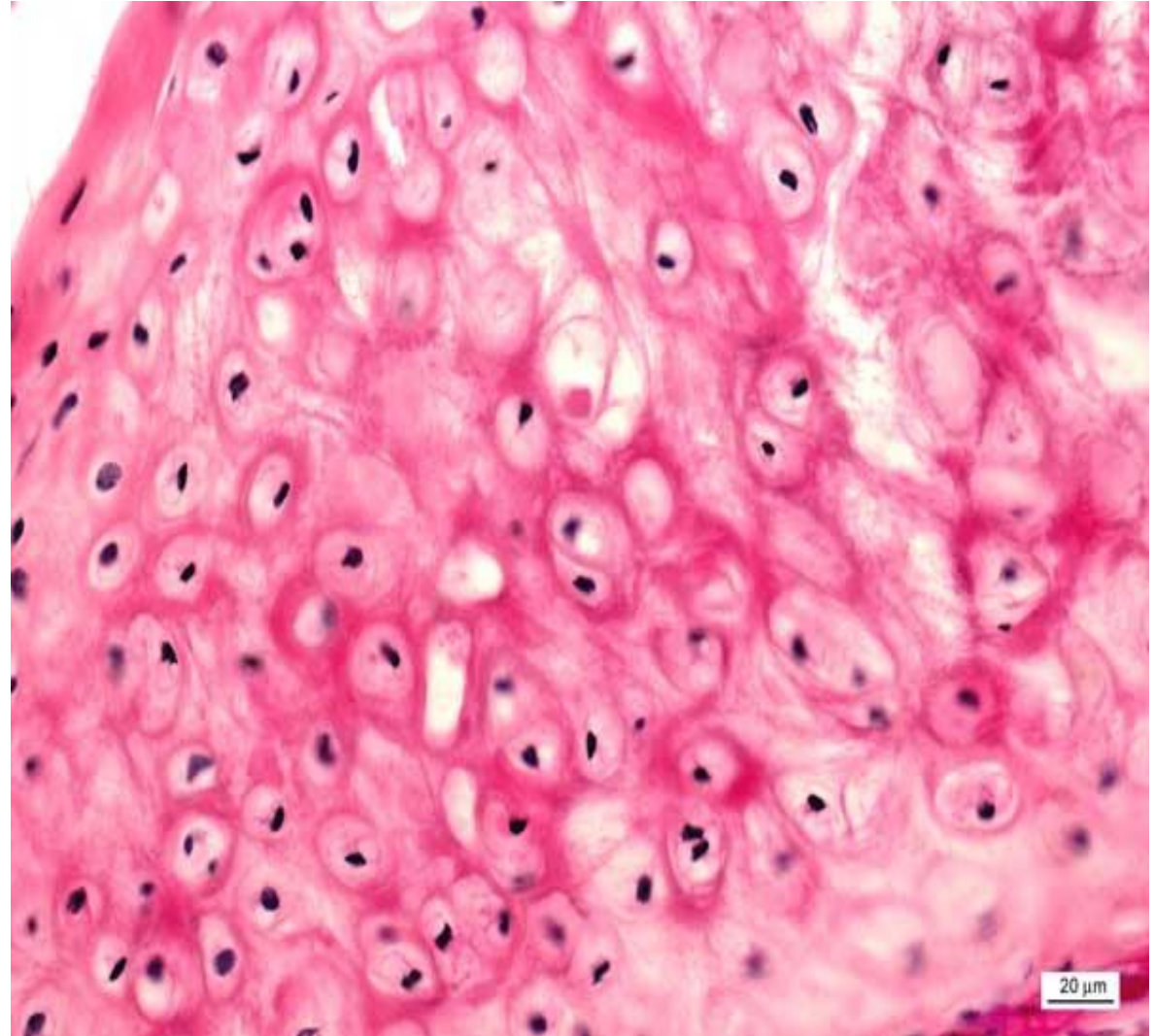
Elastic

- External ear
- Epiglottis
- Eustachian tube



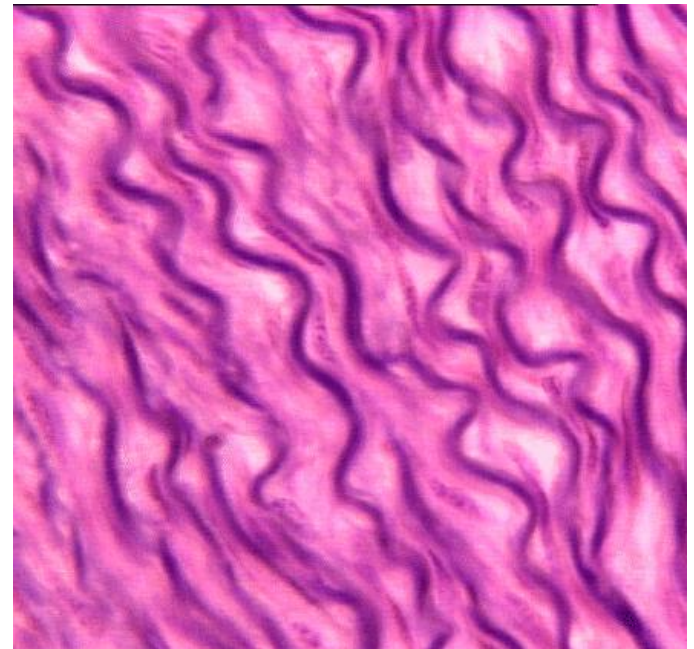
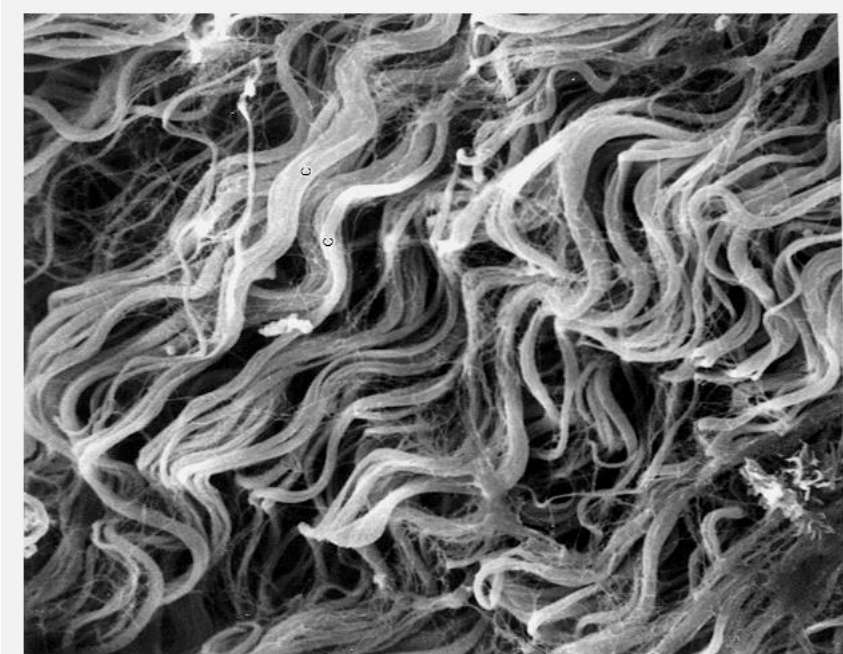
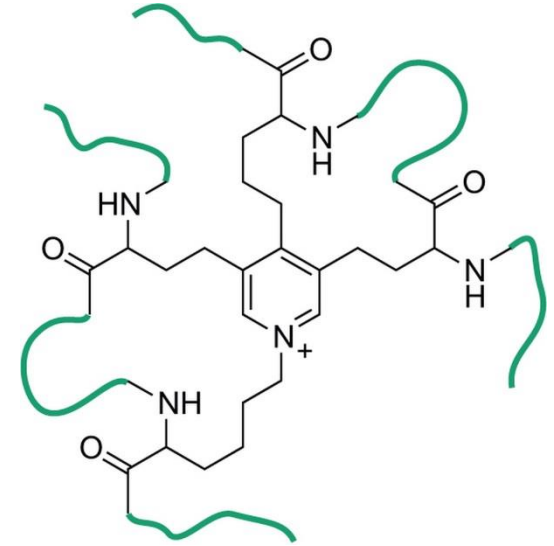
ELASTIC CARTILAGE

- acidophilic elastic fibers dispersed in matrix
- no isogenetic groups
- auricula, meatus, larynx, epiglottis

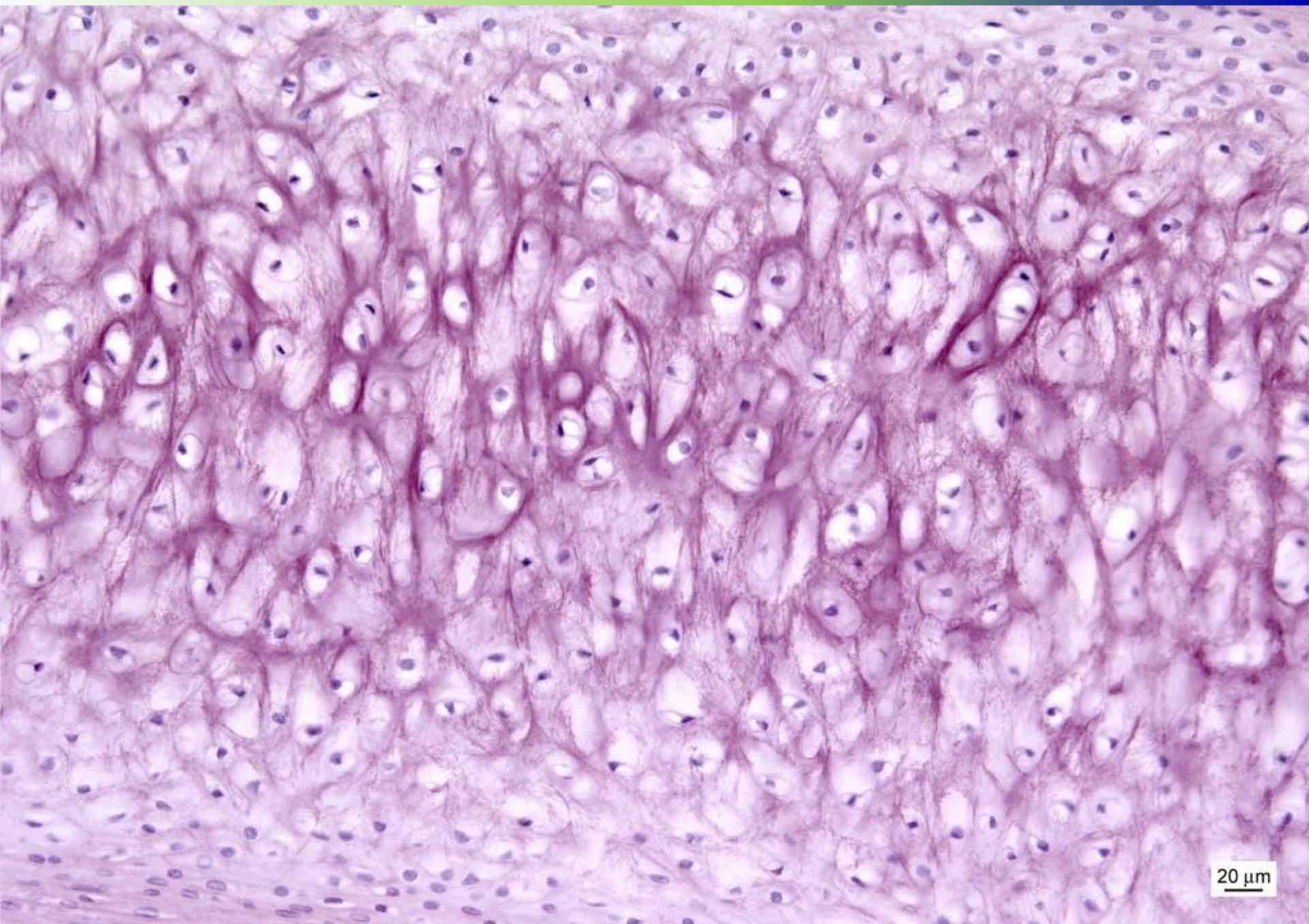


ELASTIC FIBERS

- less abundant than collagen
- polymer – tropoelastin
- minimal tensile resistance, loss of elasticity if overstretched
- reduction of hysteresis = allow return back to original state after mechanic change

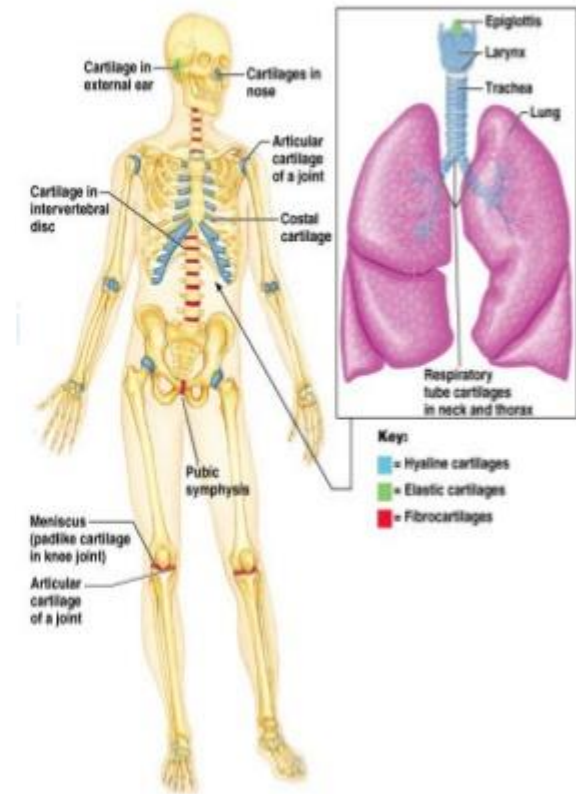


ELASTIC CARTILAGE



20 μ m

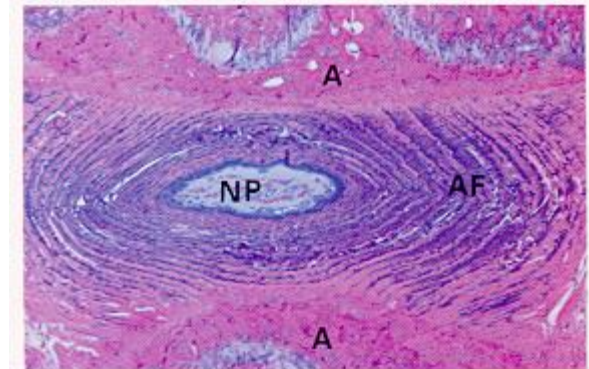
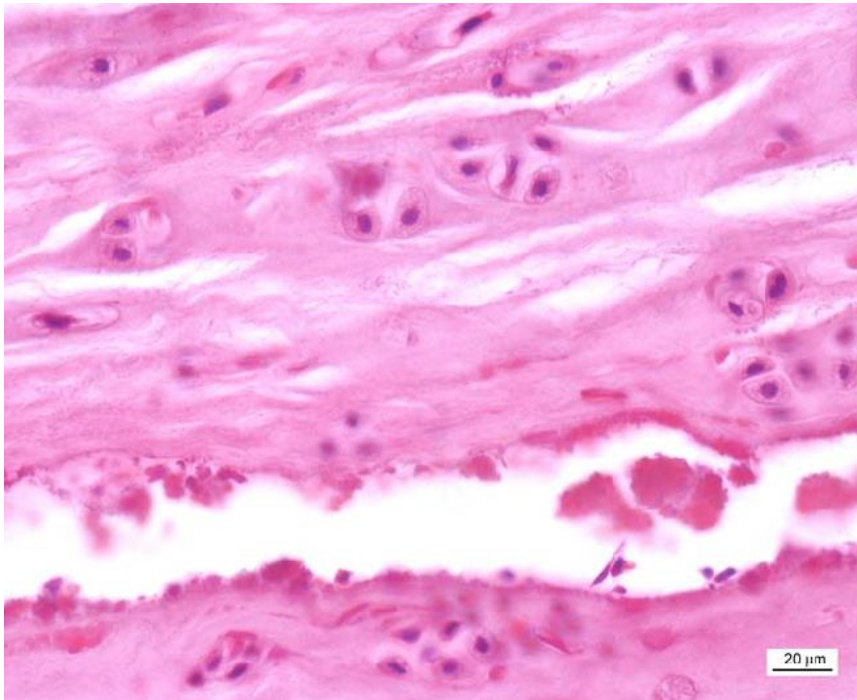
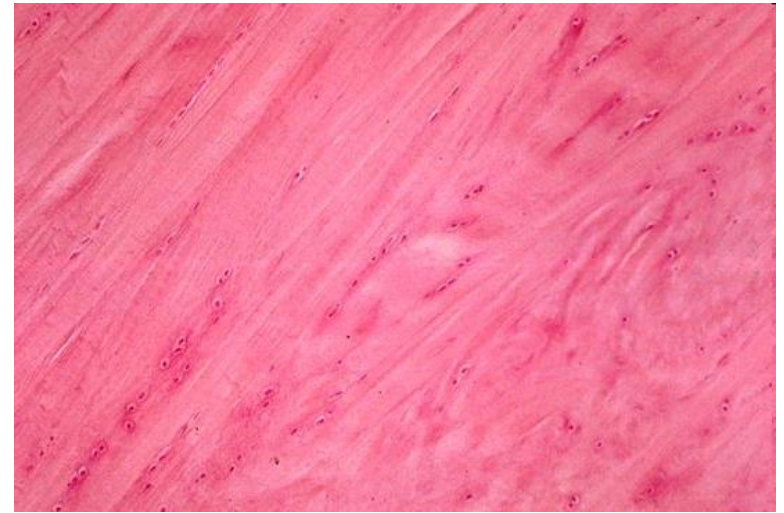
- IVDs
- Pubic symphysis
- meniscus in knee joint



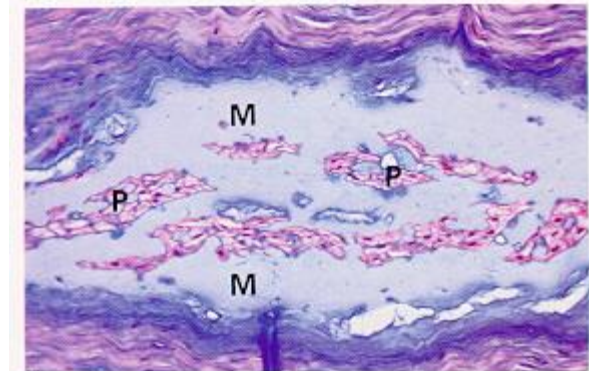
Fibrous

FIBROCARILAGE

- fibrous compound dominant – collagen I and II
– mechanical durability
- minimum of amorphous matrix-fibers visible
- intervertebral discs, symphysis pubis, articular discs, meniscus



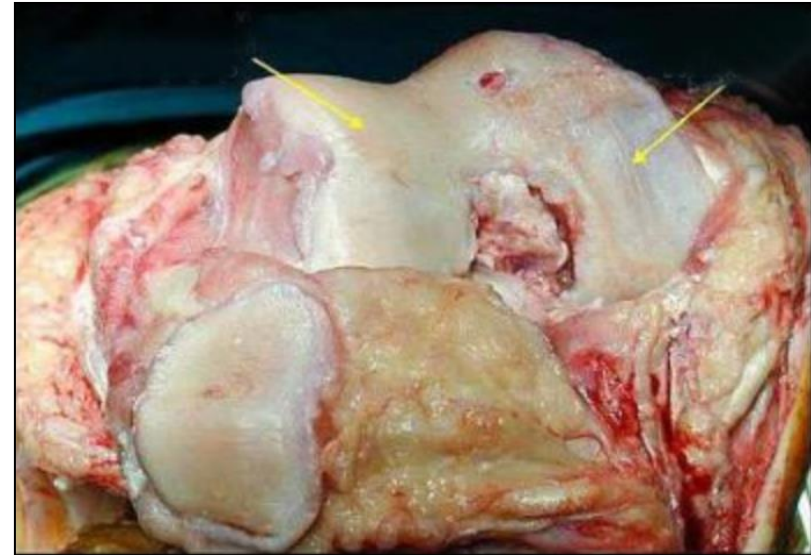
(a)



(b)

CLINICAL CORRELATION

- Cartilage – no innervation, no vascularization
– no spontaneous regeneration
- No migration of chondrocytes to site of damage
- Initiation of other degenerative events leading to cartilage erosion (arthritis)



Therapy:

- joint mobility
- restoration of biochemical and biophysical parameters of cartilage
- prevention of further damage
- removal of damaged tissue, autologous transplantation
- MSCs on biocompatible scaffolds (still only experimental)

Further reading:

Stem Cell Research 44 (2020) 101738




ELSEVIER

Contents lists available at [ScienceDirect](https://www.sciencedirect.com)

Stem Cell Research

journal homepage: www.elsevier.com/locate/scr



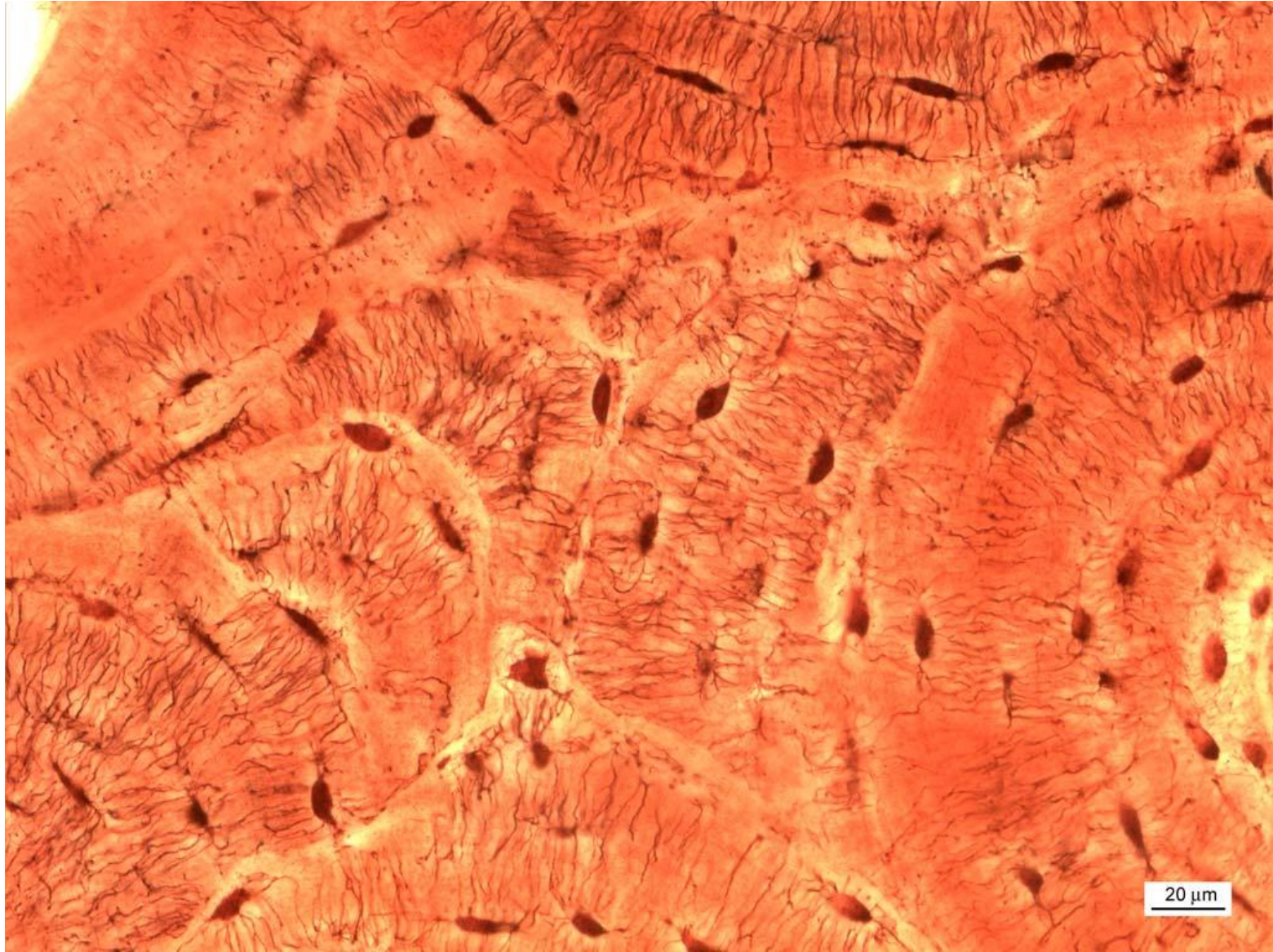
Human mesenchymal stem cell therapy for cartilage repair: Review on isolation, expansion, and constructs

Alan T.L. Lam*, Shaul Reuveny, Steve Kah-Weng Oh

Bioprocessing Technology Institute, A*STAR (Agency for Science, Technology and Research), Singapore 138668, Singapore



BONE

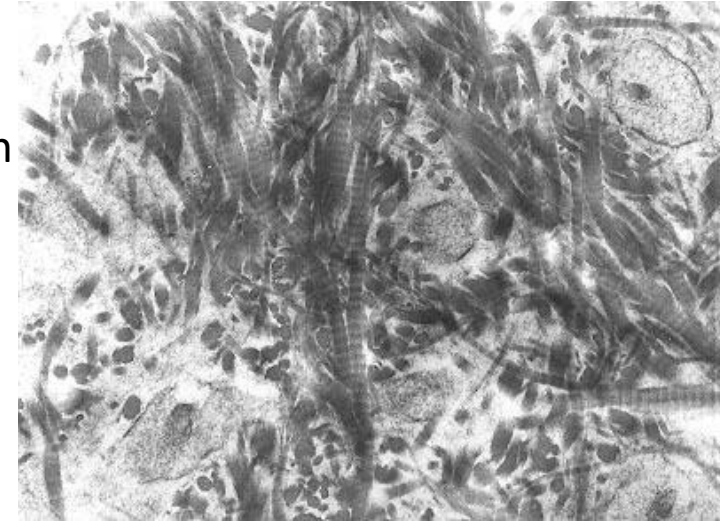


20 μ m

HISTOLOGICAL CLASSIFICATION OF BONE TISSUE

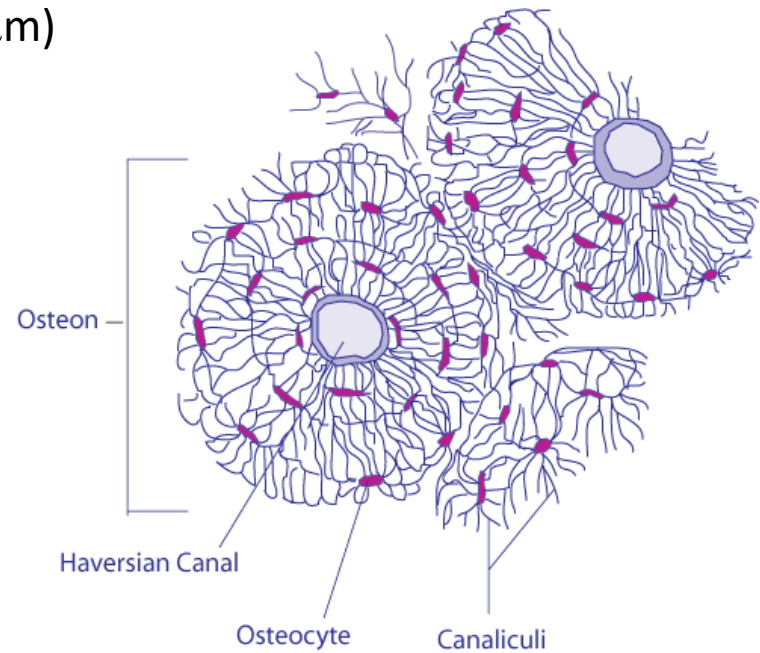
- **Primary (woven, fibrous)**

- Temporary, growth and regeneration of bones, collagen fibrils woven
- Replaced by secondary bone
- Remains only in some parts of body - sutures of skull, *tuberositas ossium*, tooth cement



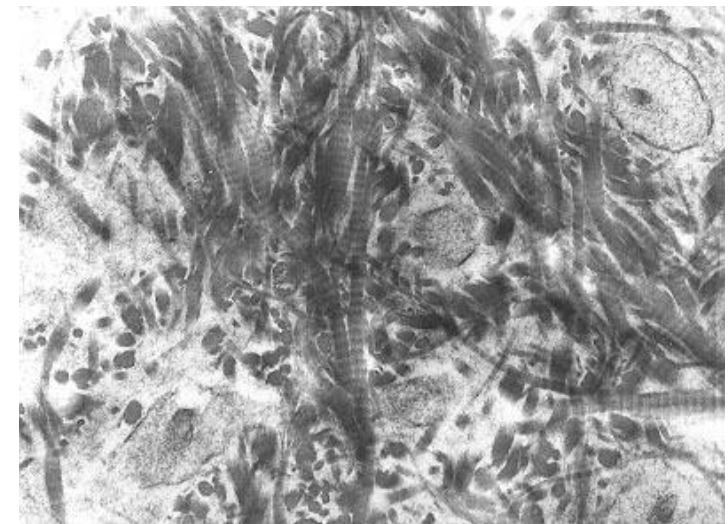
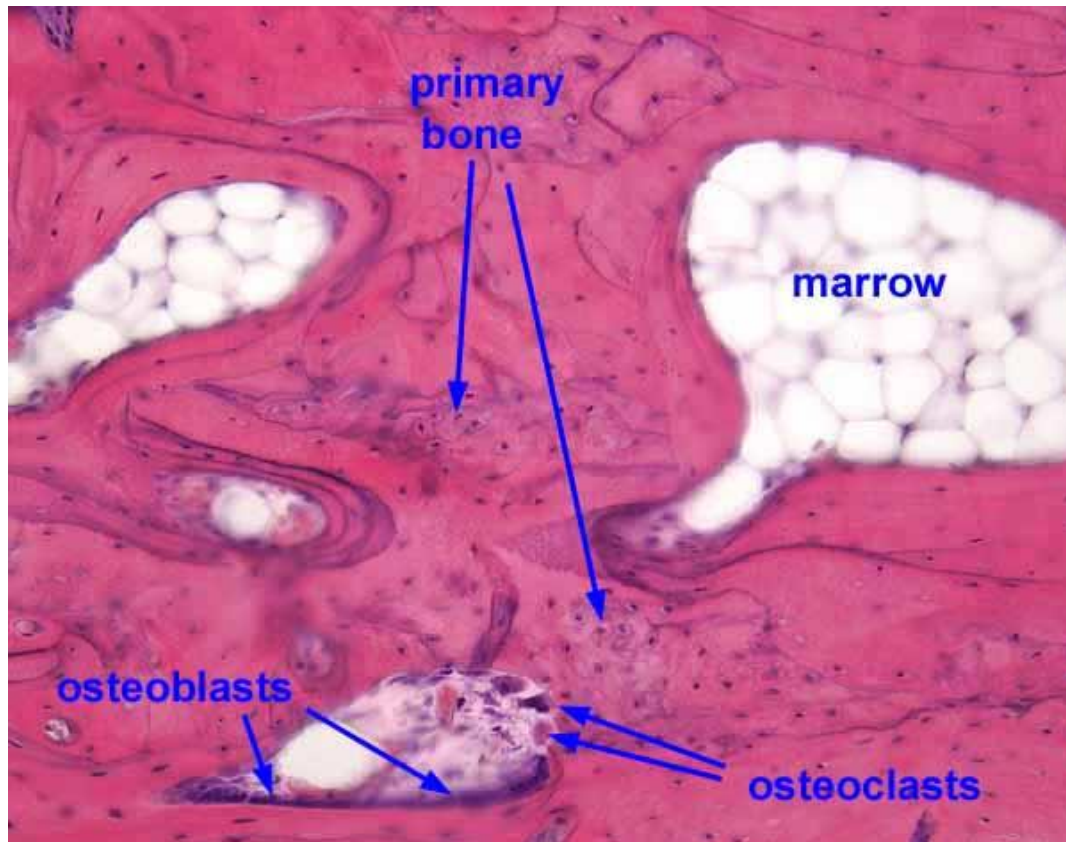
- **Secondary (lamellar)**

- Lamellae – collagen fibers in concentric layers (3-7 μ m) around a canal with capillaries = Haversian system (osteon)



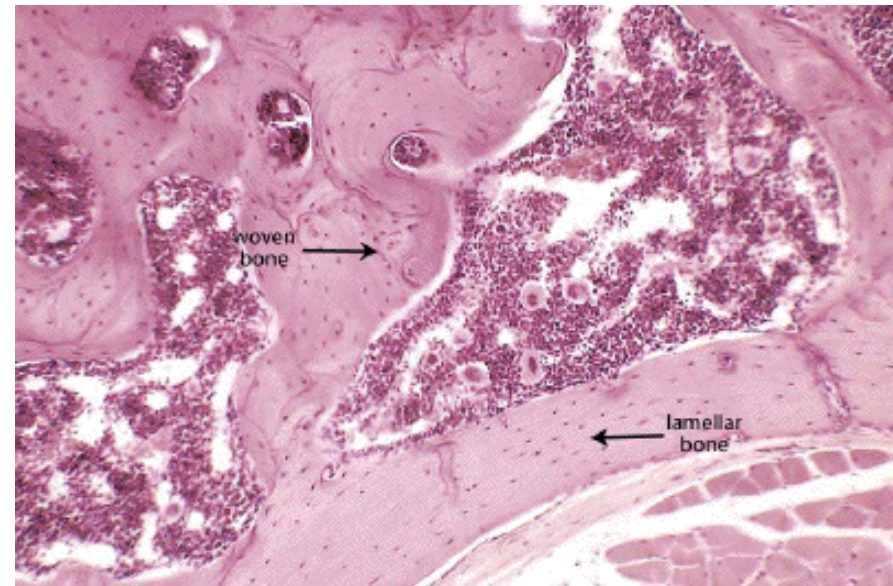
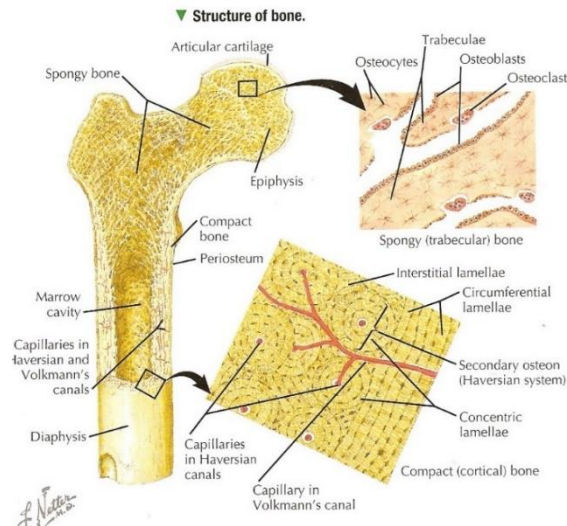
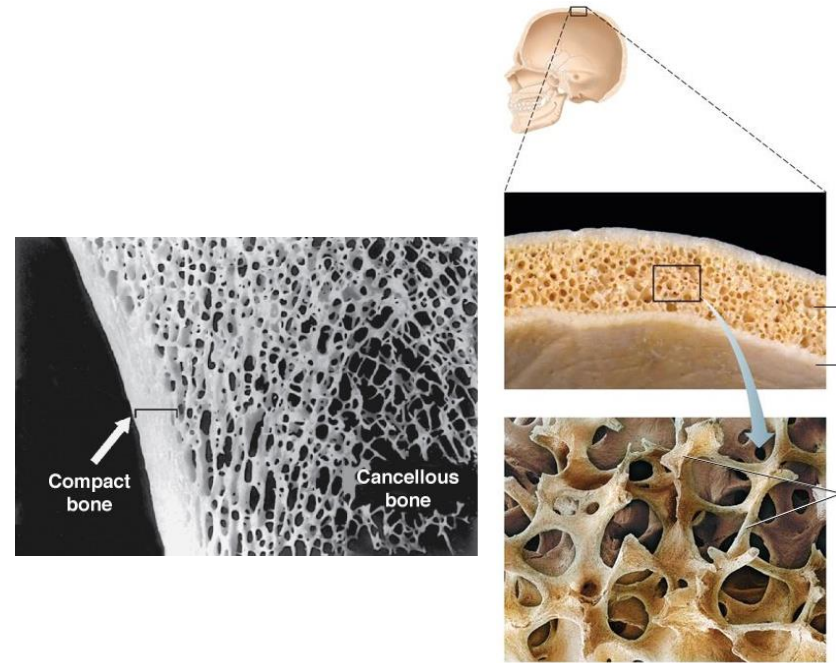
PRIMARY (WOVEN) BONE

- Temporary, growth and regeneration of bones, collagen fibrils woven
- Replaced by secondary bone
- Remains only in some parts of body - sutures of skull, *tuberositas ossium*, tooth cement



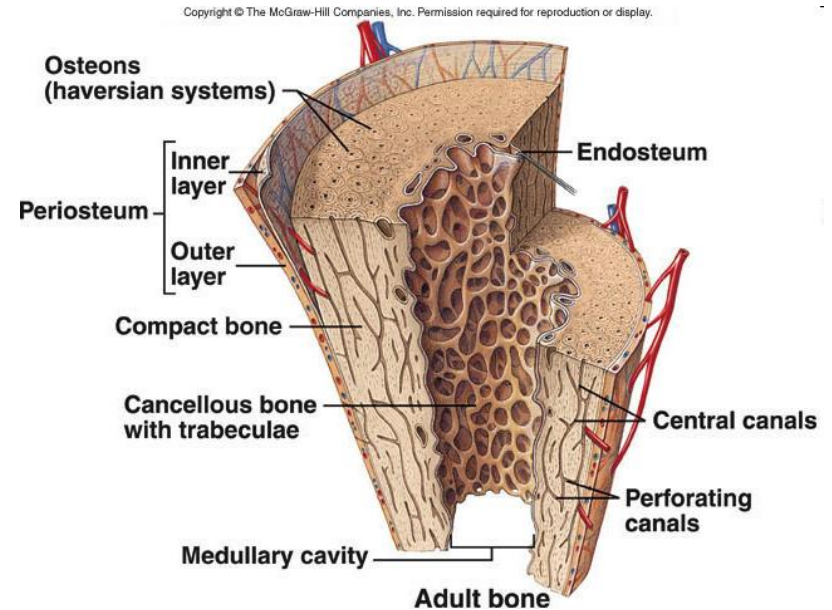
SECONDARY (LAMELLAR) BONE

- Lamellae – collagen fibers in concentric layers (3-7 μ m) around a canal with capillaries = Haversian system (osteon)
- **Spongy (trabecular)**
 - Trabeculae, similar to compact
 - Epiphyses of long bones, short bones, middle layer of flat bones of the skull (*diploe*)
- **Compact**
 - Outer and inner coat lamellae typical Haversian systems
 - Volkmann's canals
 - Interstitial canals

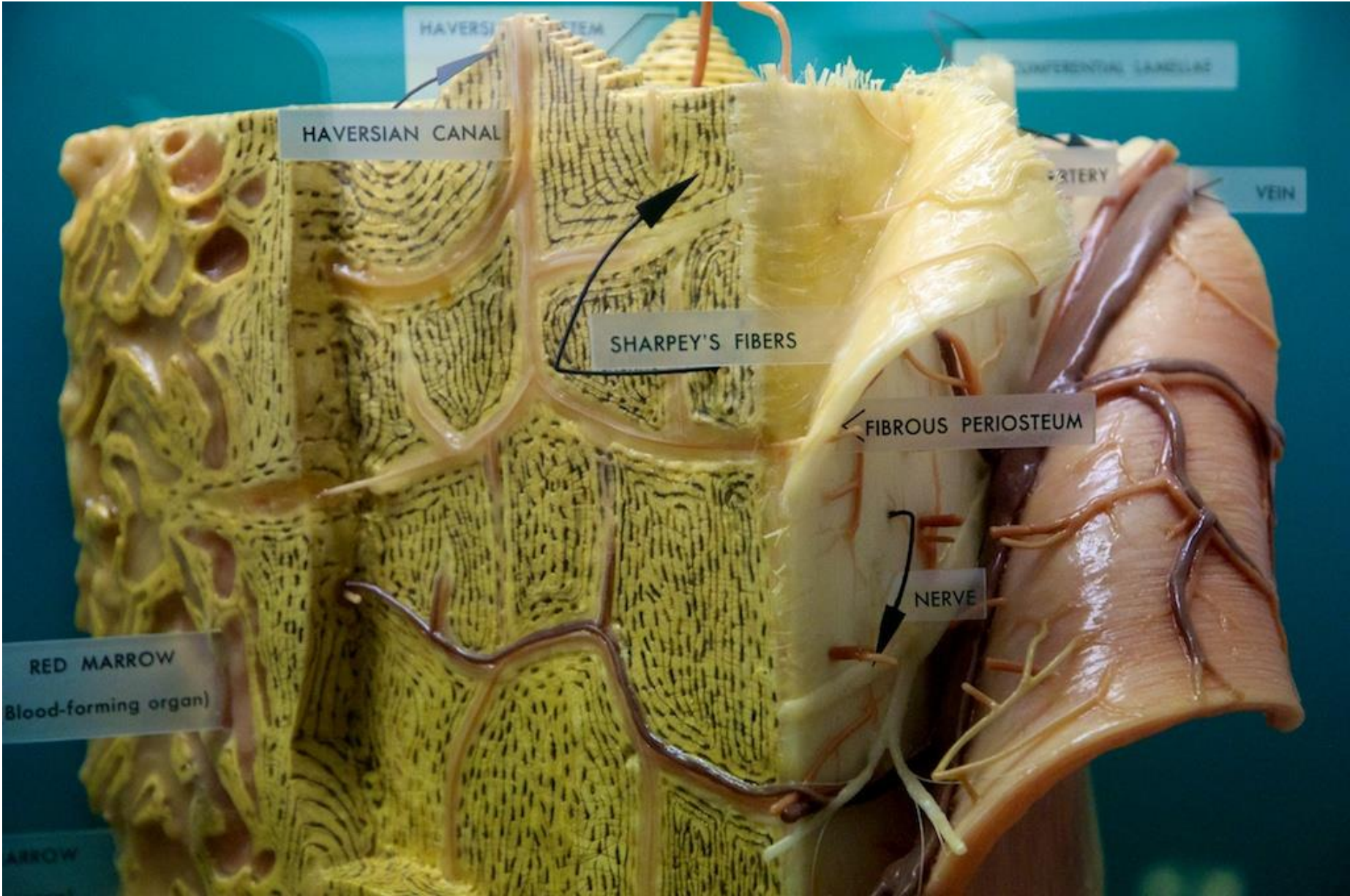


BONE SURFACES

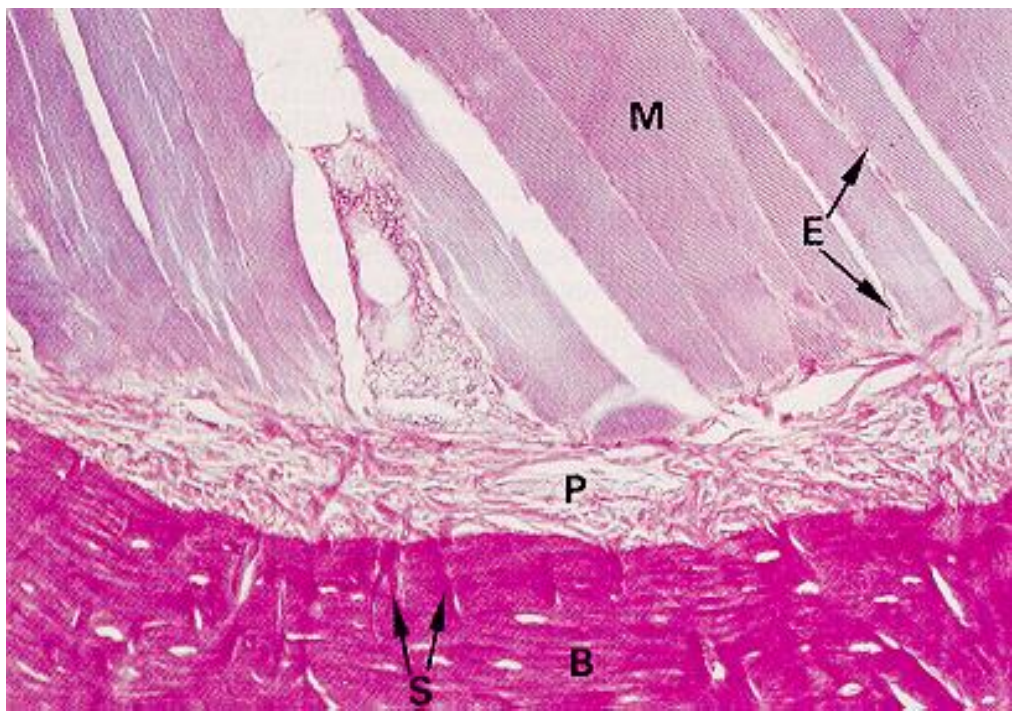
- **Outer surface**
- Synovial joint – hyaline cartilage
- **Periosteum (periost)** – membrane – dense CT, inner layer (osteoblasts) and outer layer (fibrous CT)
- Inactive bone - fibrous CT in periost dominant
- Collagen fibers – parallel to the bone surface
- Sharpey's fibers fix periost to the bone



BONE SURFACES

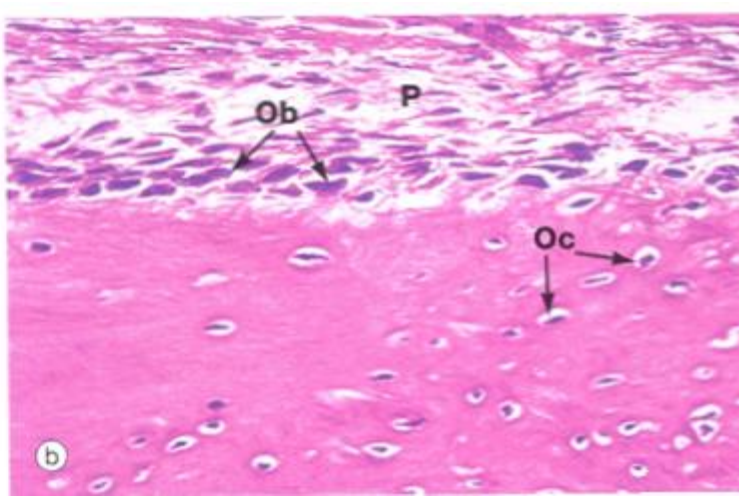
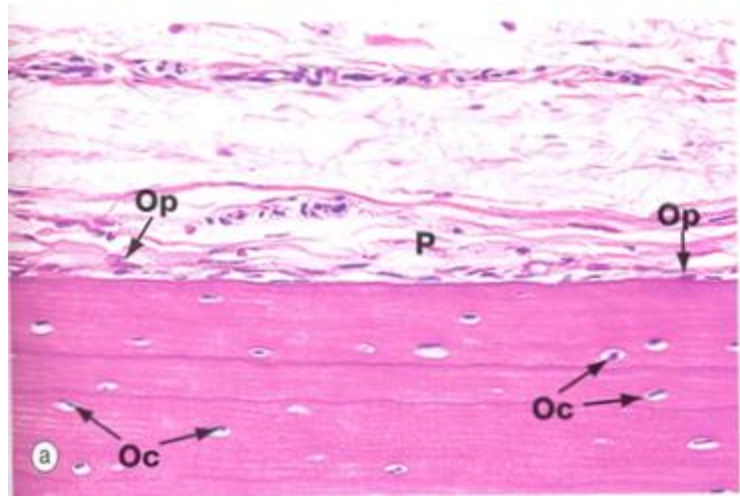


BONE SURFACES



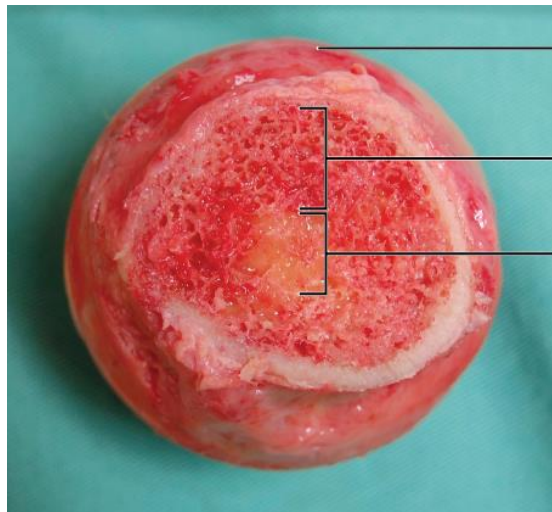
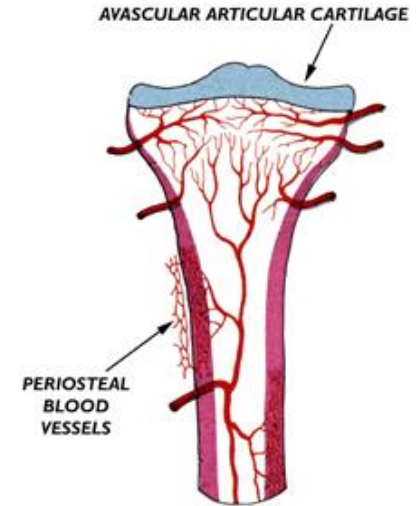
Inactive

Active



BONE SURFACES

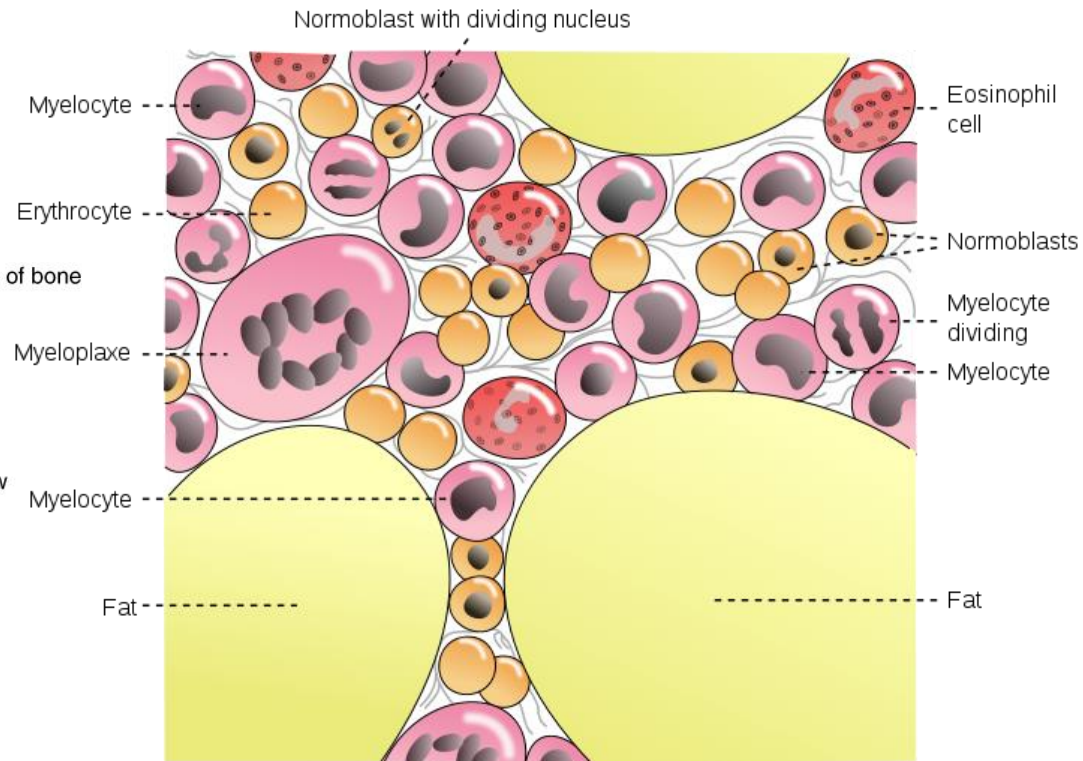
- **Inner surface** – lining of cavities
 - medullar cavity
 - endosteum (endost) – single cell lining – bone remodeling
 - red bone marrow – hematopoiesis
 - yellow and gray bone marrow – adipocytes or CT
 - rich vascularization
 - hematopoietic niche



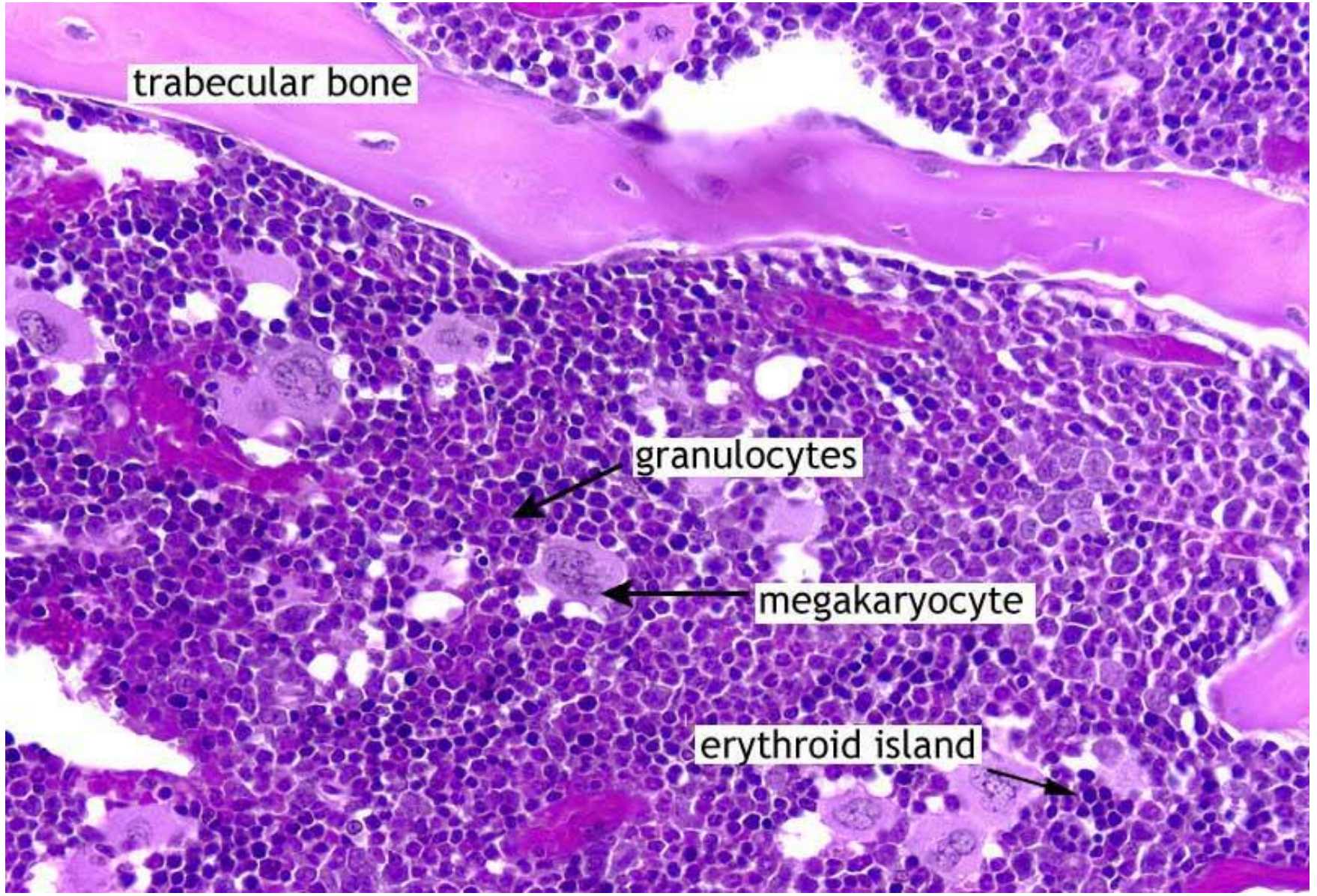
Outer surface of bone

Red marrow

Yellow marrow

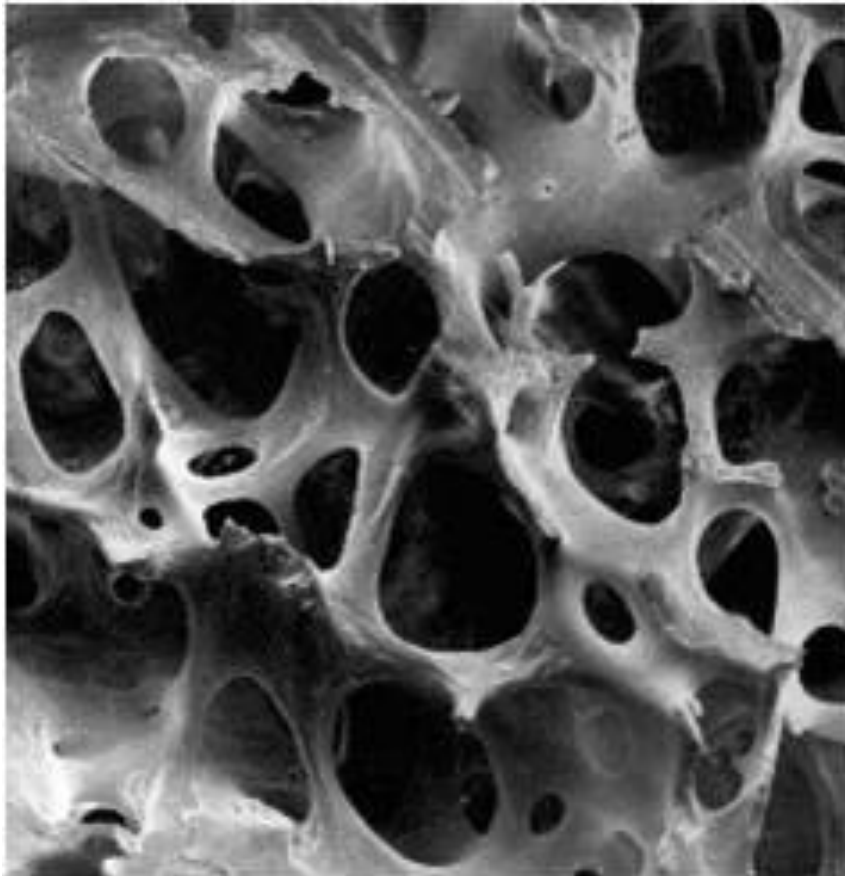


ENDOSTEAL SURFACE OF COMPACT BONE

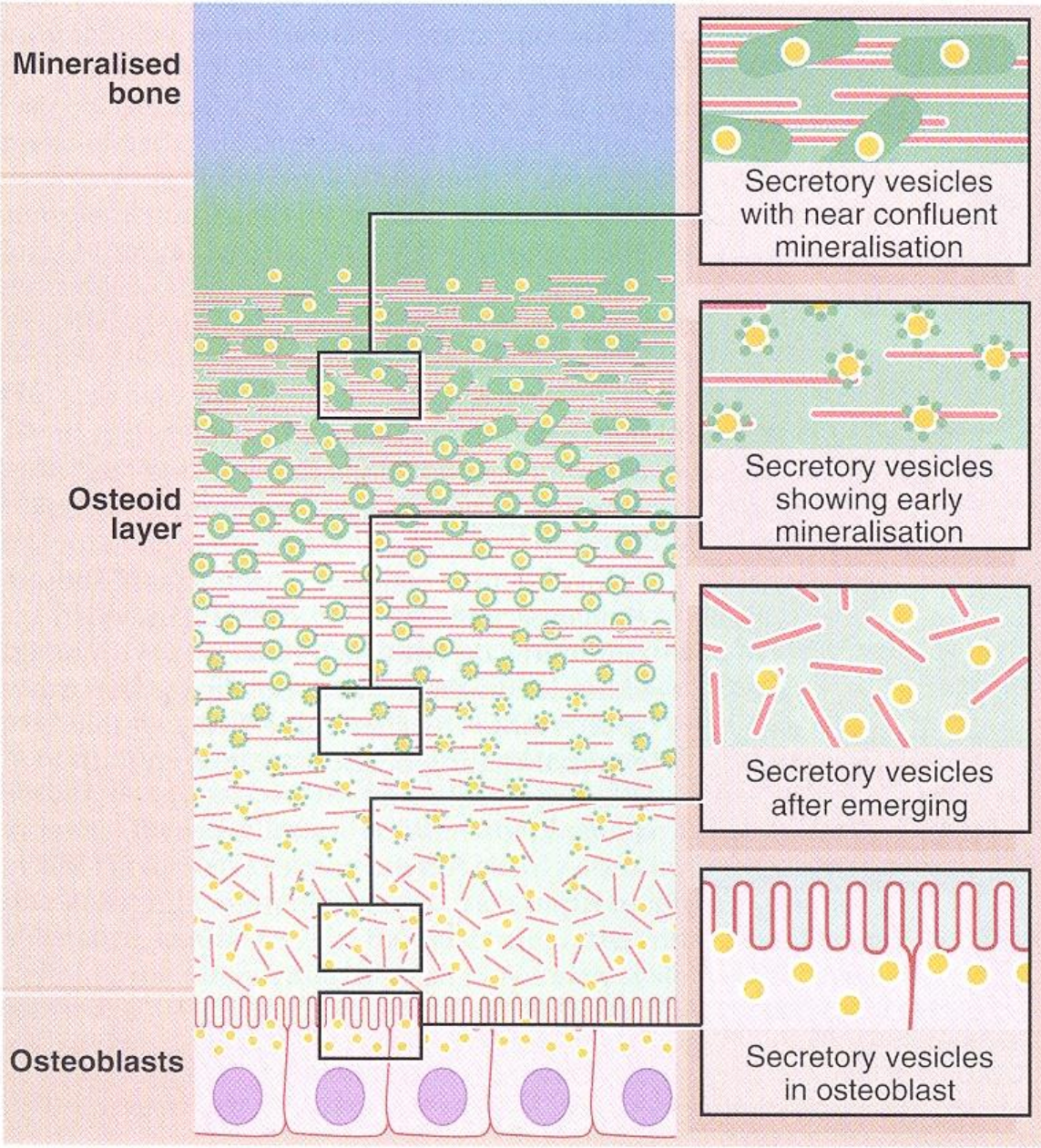



BONE MATRIX

- 60% mineral compound, 24% organic compound 12% H₂O, 4% fat
- crystals – calcium phosphate, hydroxyapatite



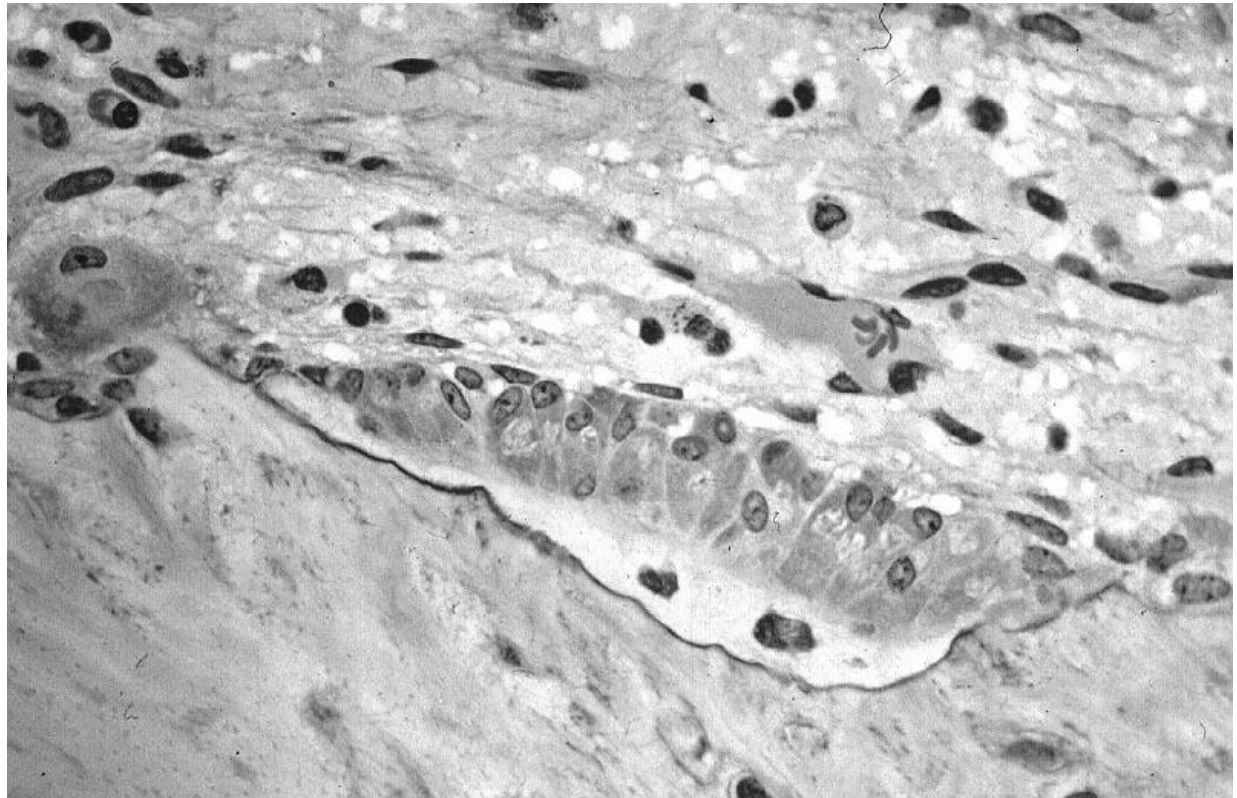
BONE MATRIX



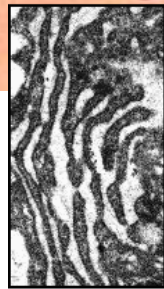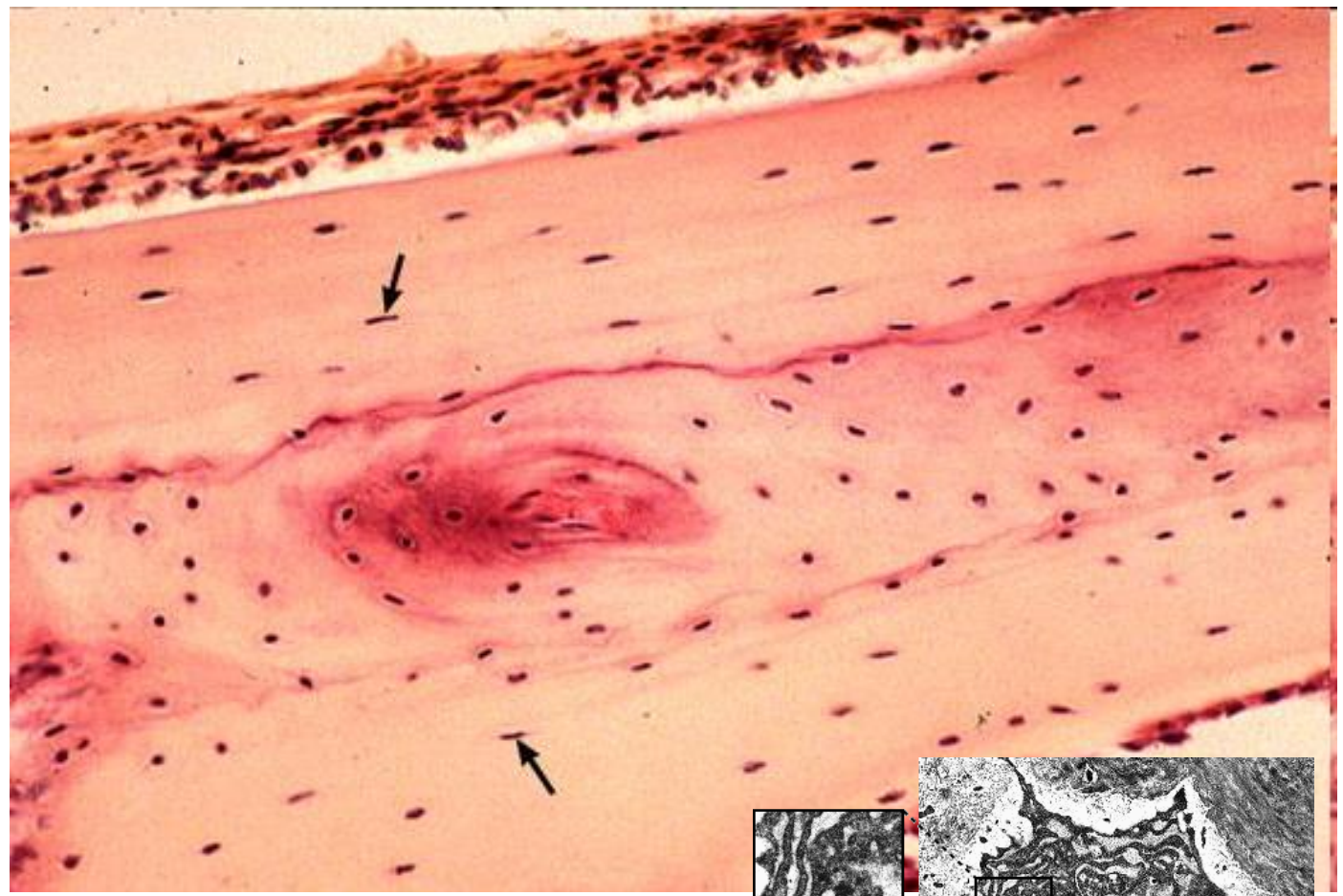
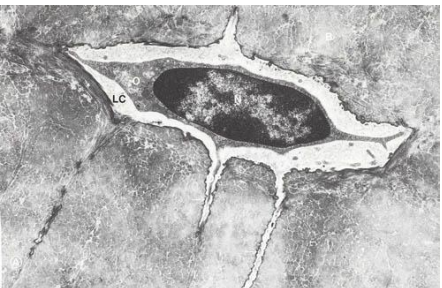
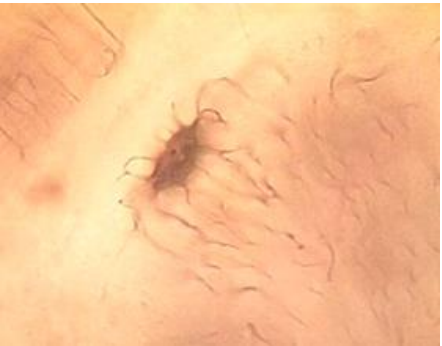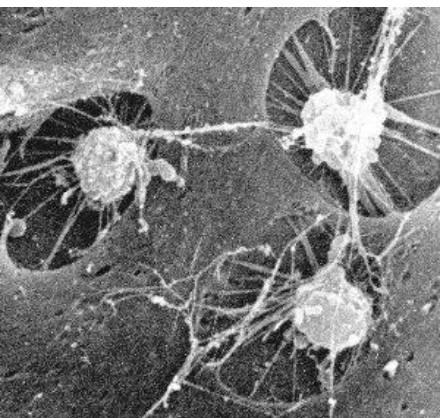
CELLS OF BONE – OSTEOBLASTS

- lining bone surface
- produce ECM – collagen (I) and noncollagenous proteoglycans, glycoproteins
- basophilic cytoplasm, rER, well developed Golgi Apparatus
- euchromatin nucleus

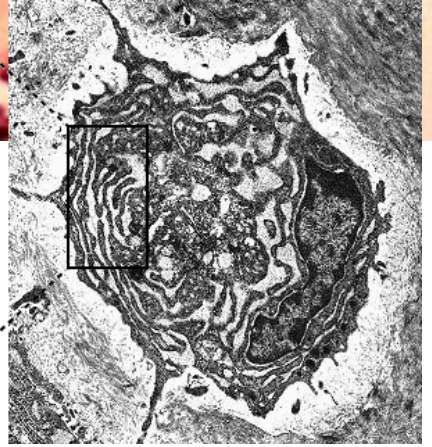
- **osteocytes** embedded in matrix
- *canaliculi ossium*



CELLS OF BONE – OSTEOCYTES

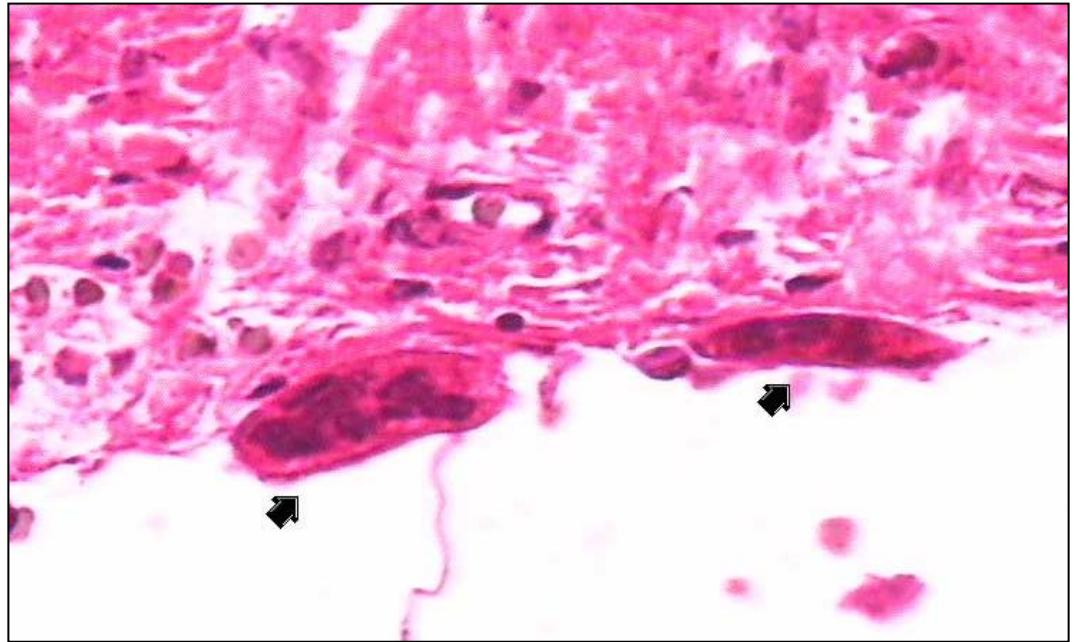
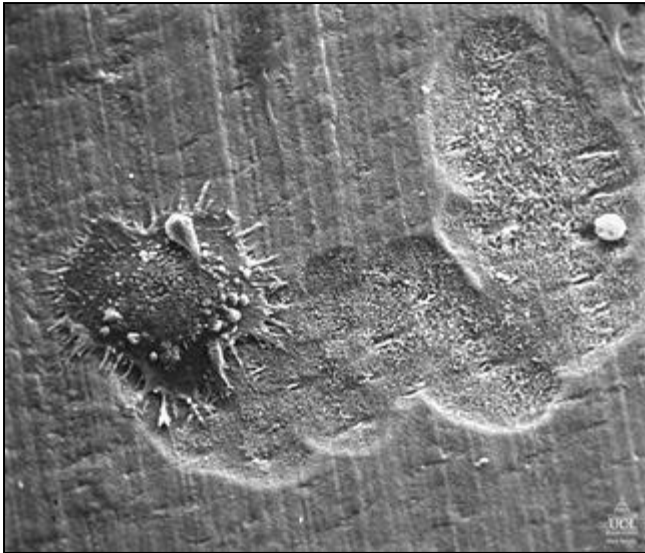


RER
-rough
endoplasmic
reticulum

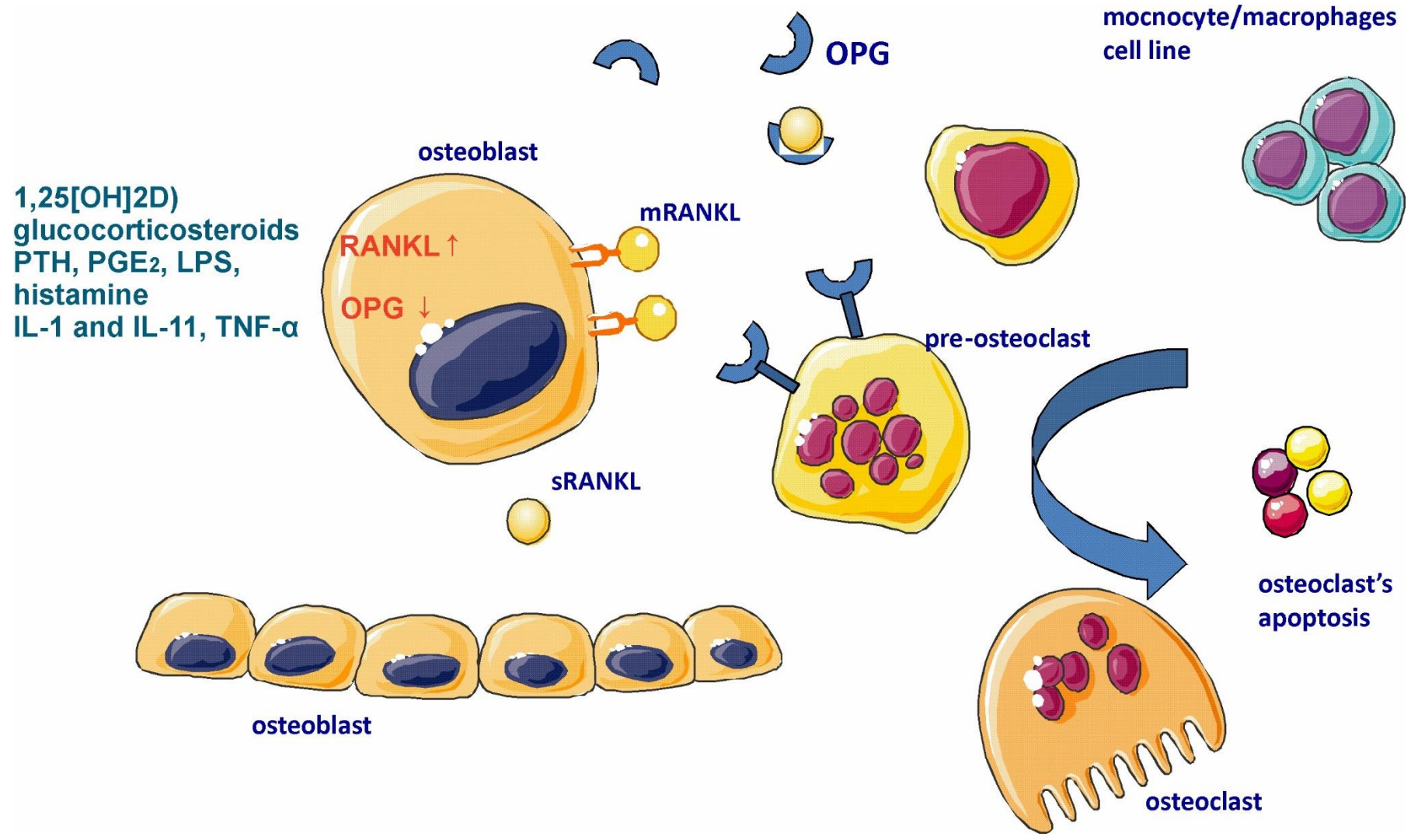


CELLS OF BONE – OSTEOCLASTS

- multinuclear, formed by fusion of mononuclear macrophages
- bone matrix resorption

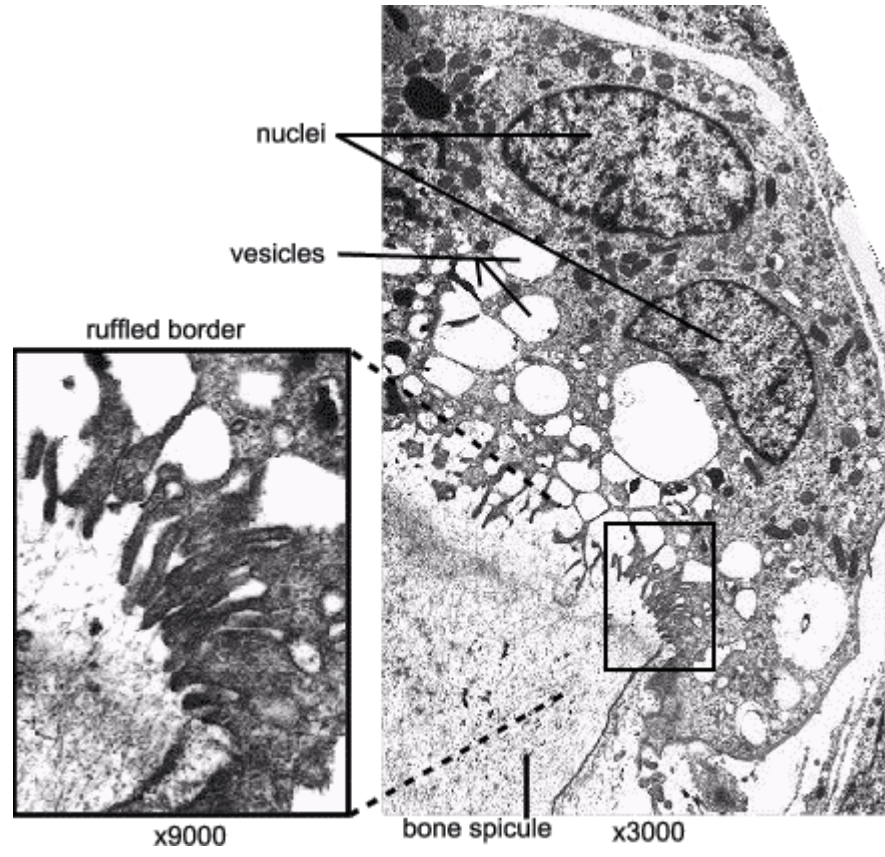
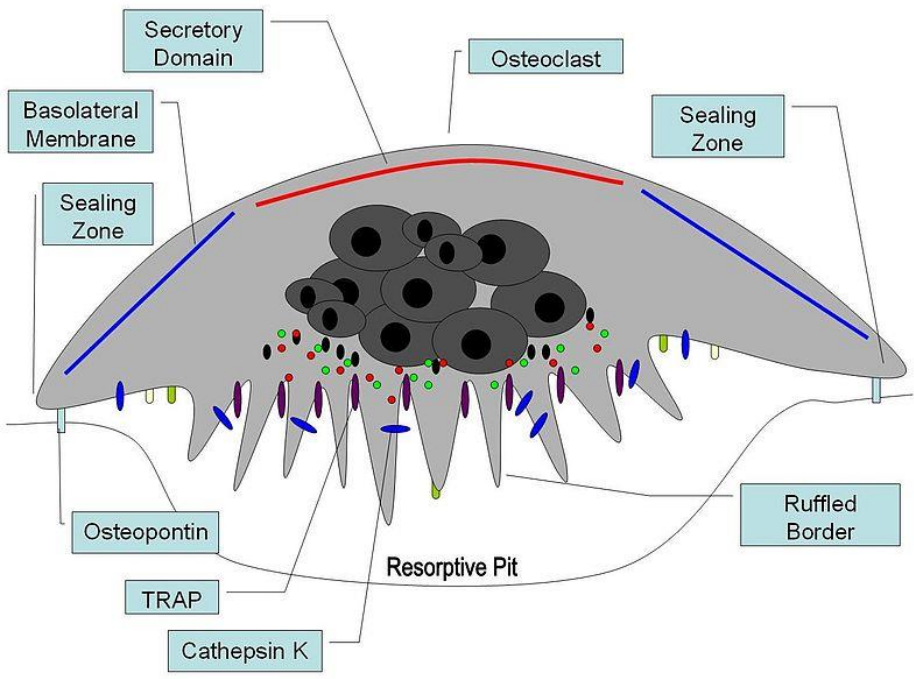


CELLS OF BONE – OSTEOCLASTS



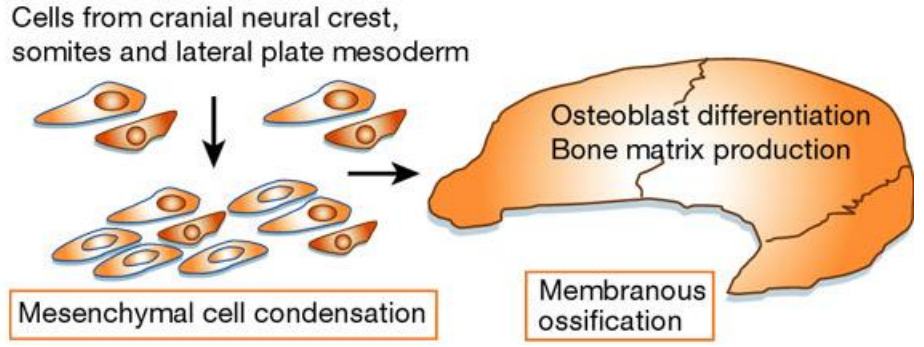
CELLS OF BONE – OSTEOCLASTS

- complex cellular architecture
- enzymes degrading organic matrix
- HCl

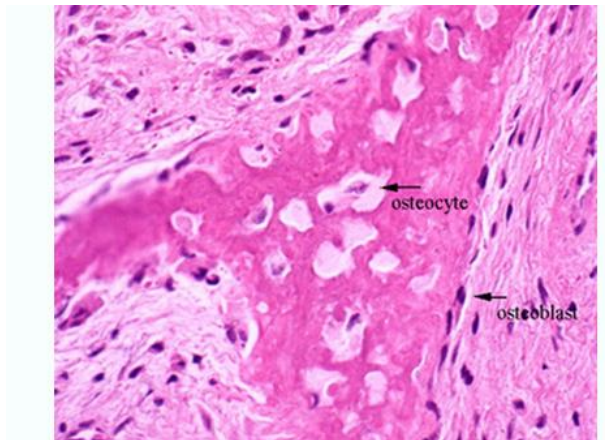
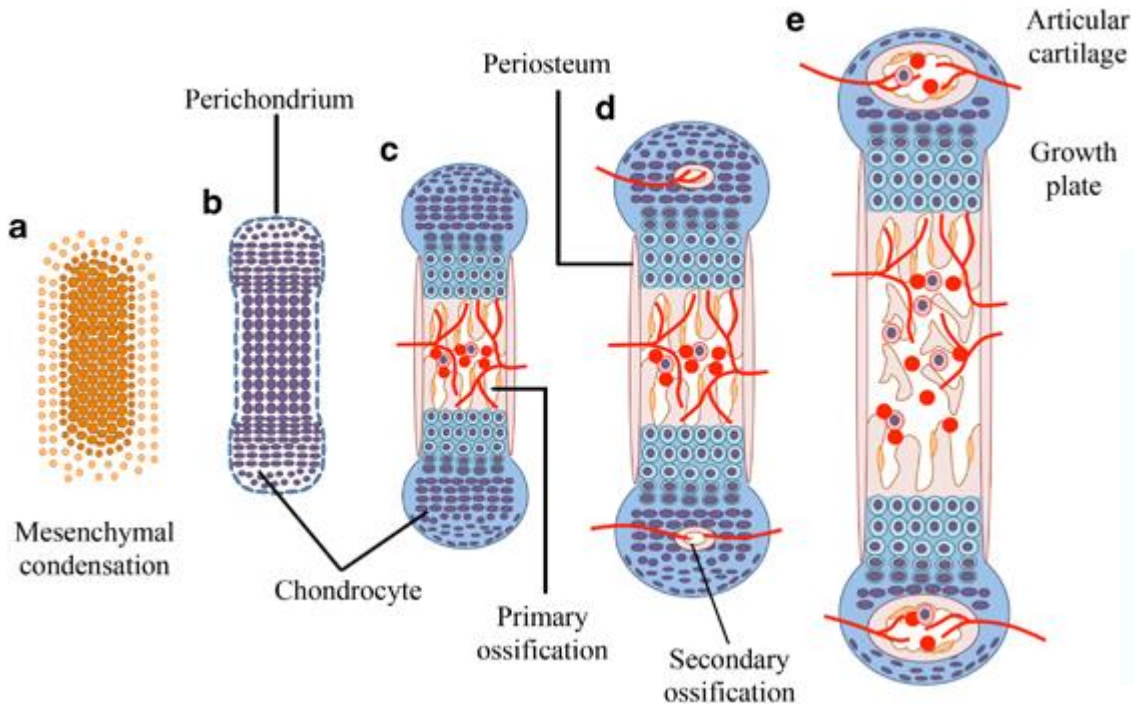


BONE OSSIFICATION

Intramembraneous

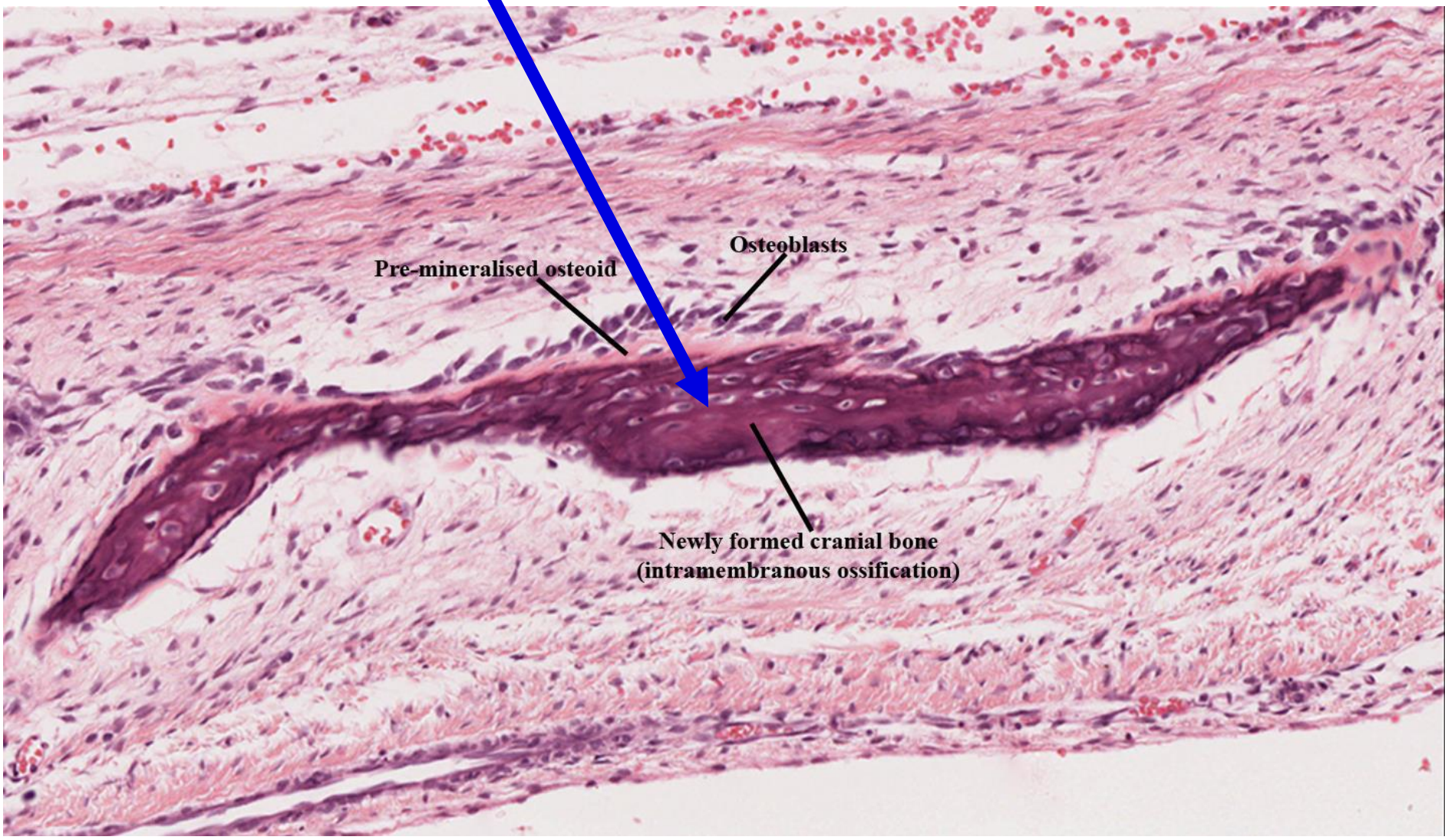


Endochondral

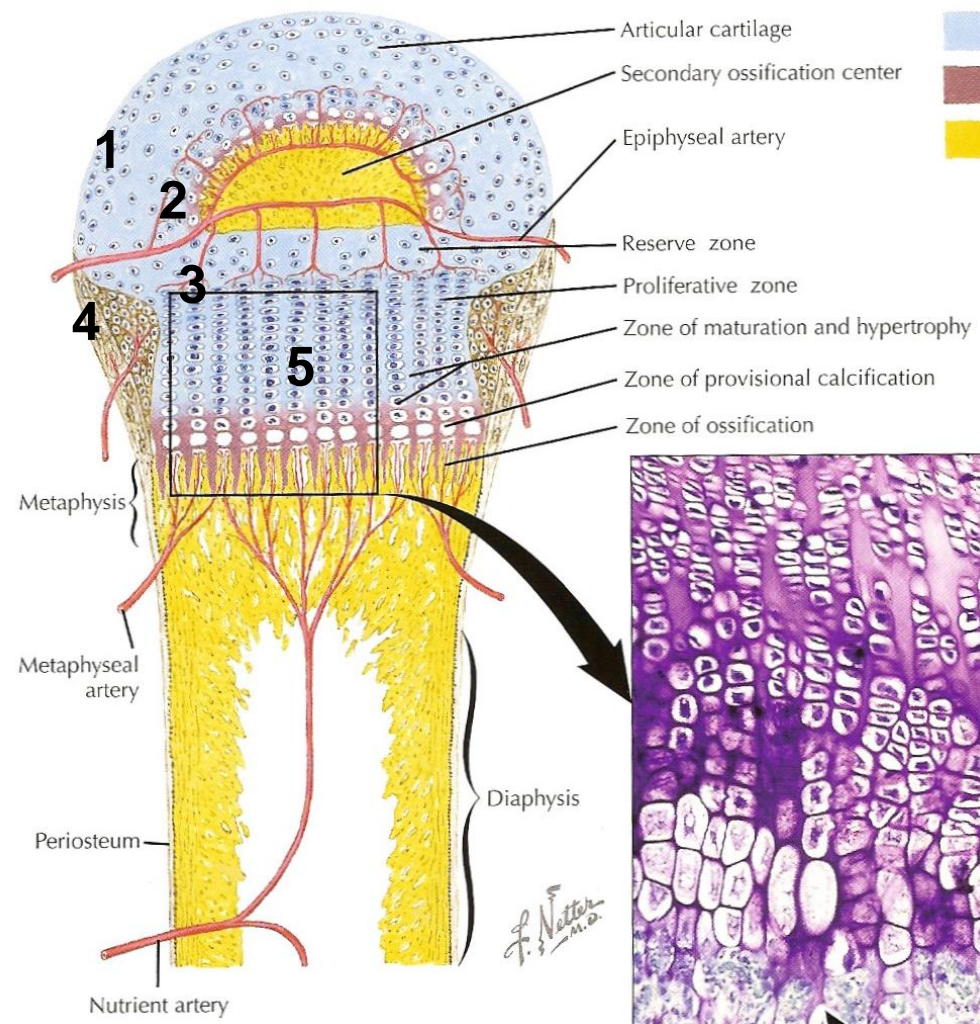


INTRAMEMBRANEOUS OSSIFICATION

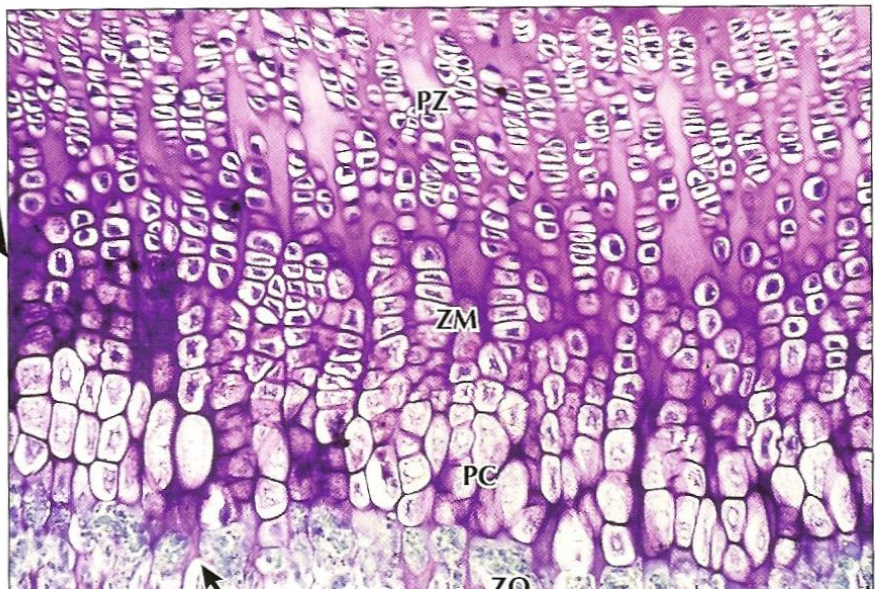
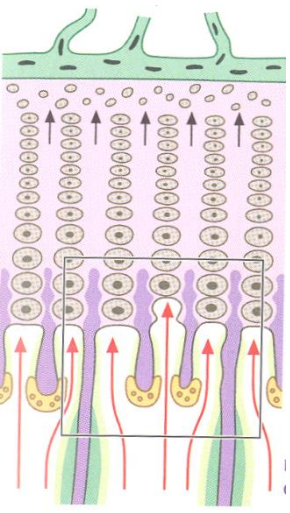
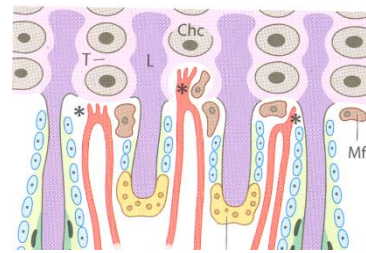
Intramembraneous



ENDOCHONDRAL OSSIFICATION

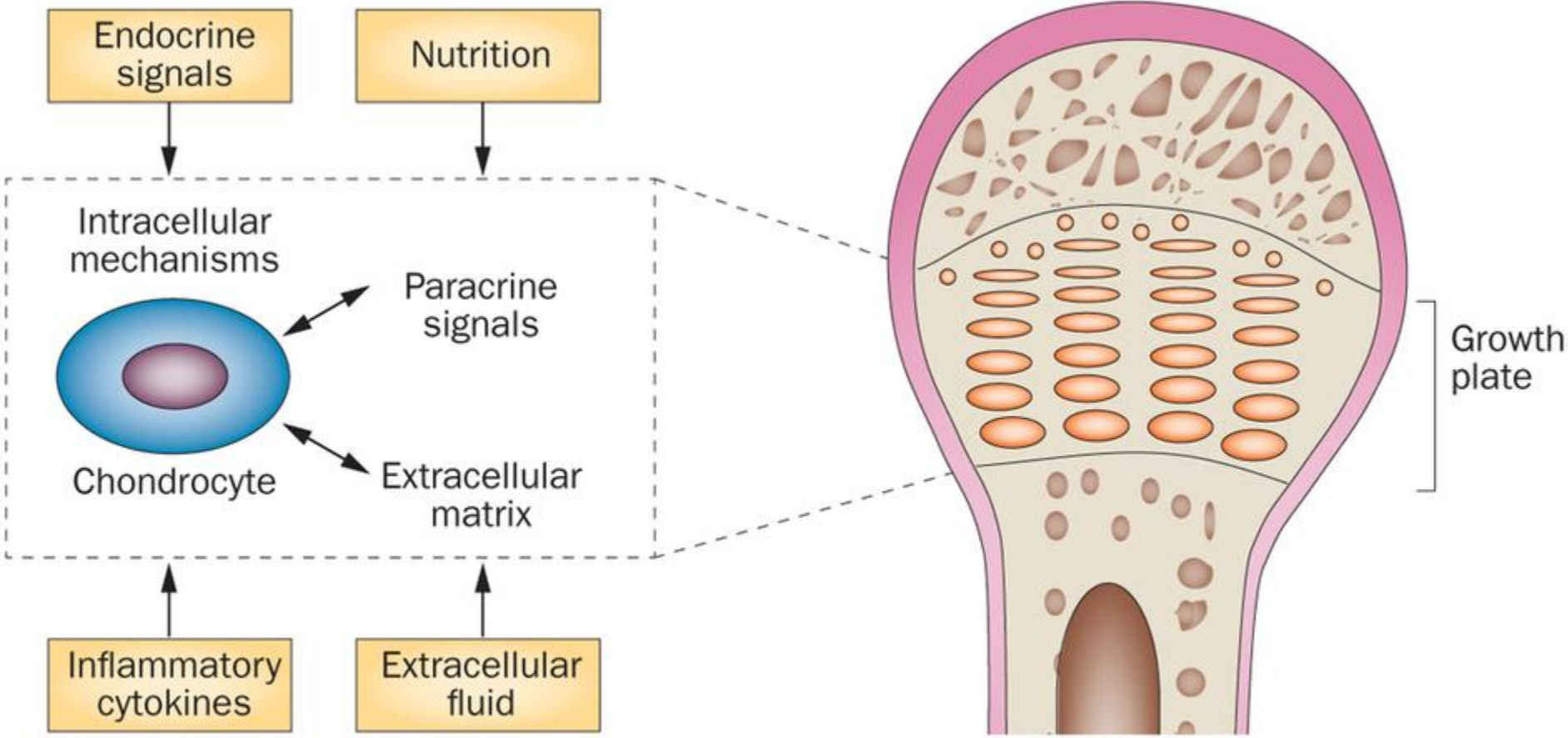


	Cartilage
	Calcified cartilage
	Bone

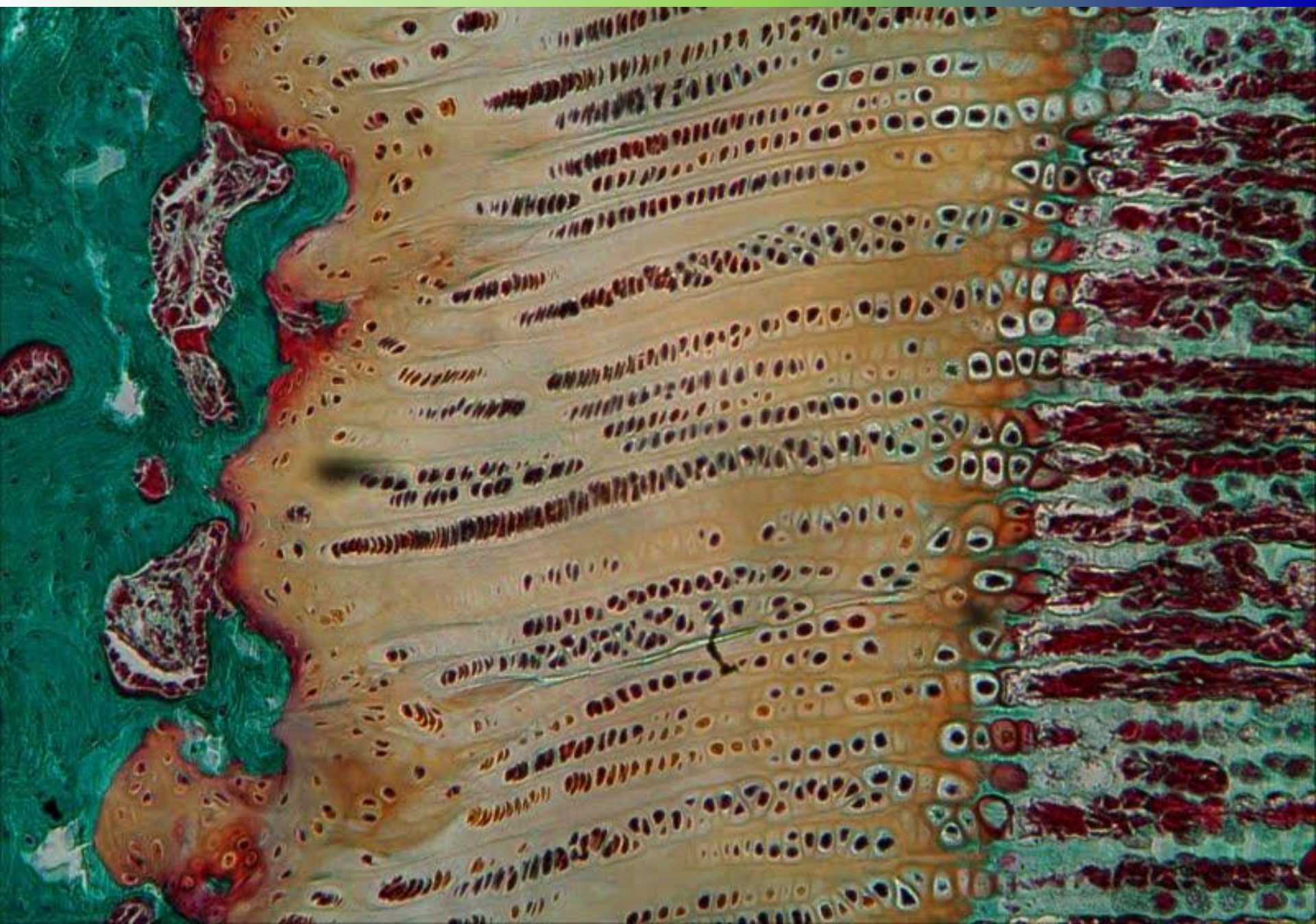


F. Netter M.D.

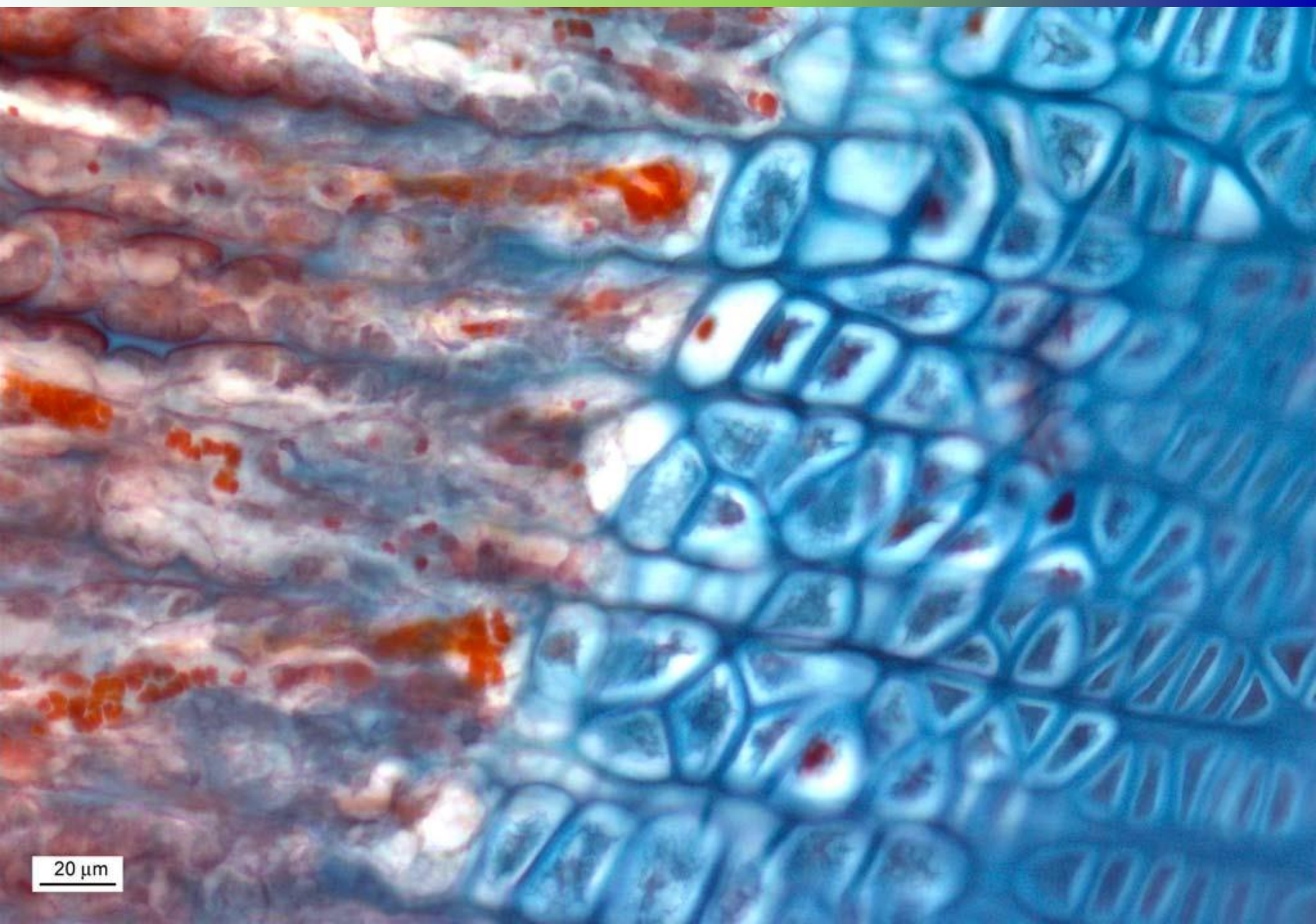
ENDOCHONDRAL OSSIFICATION



GROWTH PLATE

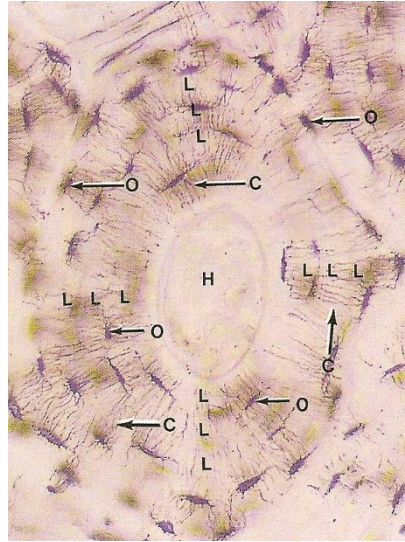

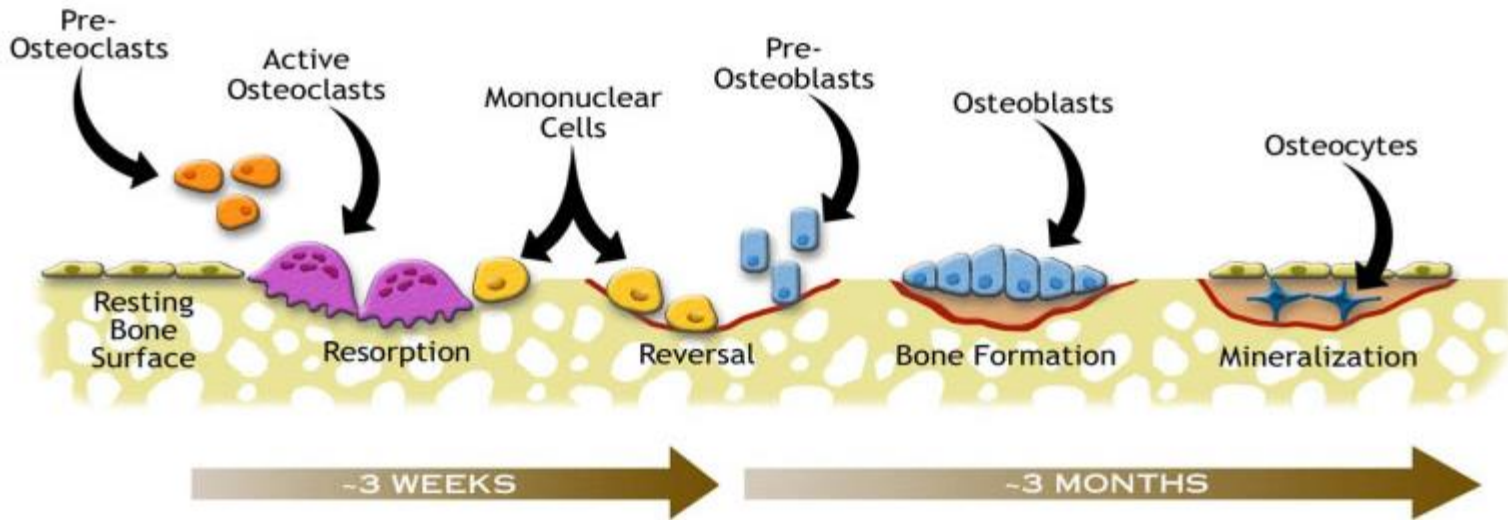


GROWTH PLATE

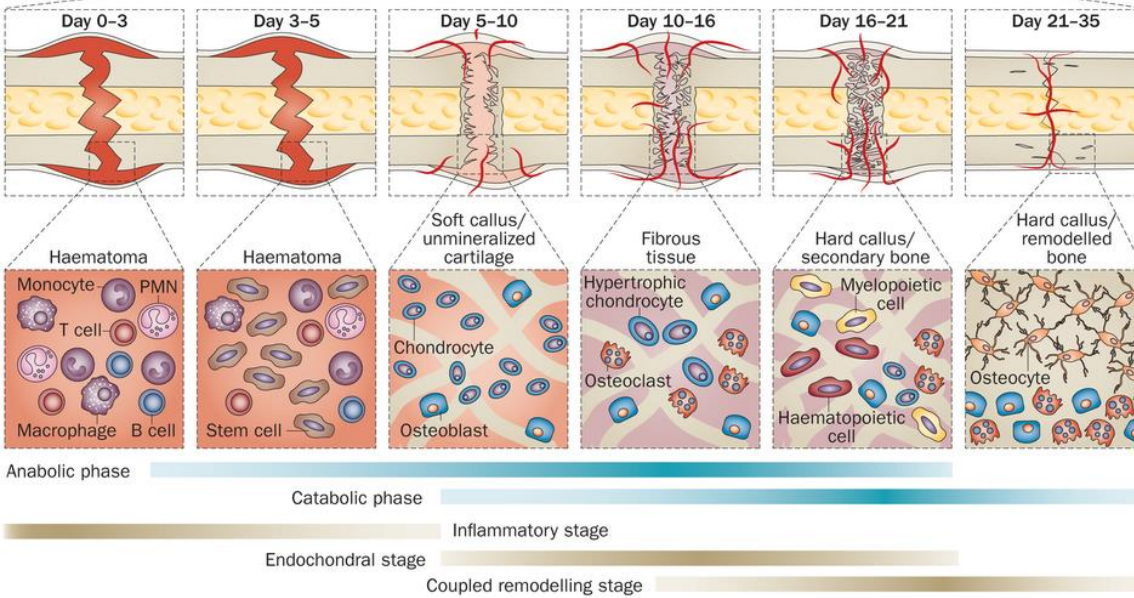
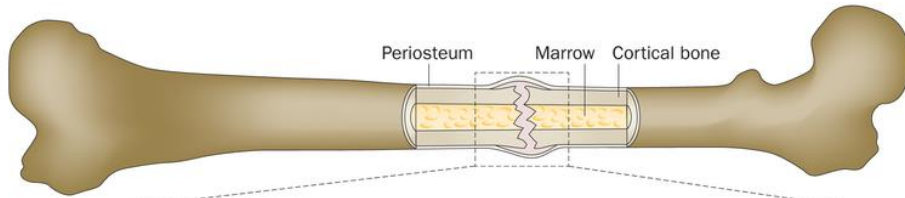


20 μ m

BONE REMODELLING



CLINICAL CORRELATIONS – FRACTURE HEALING



Reactive phase

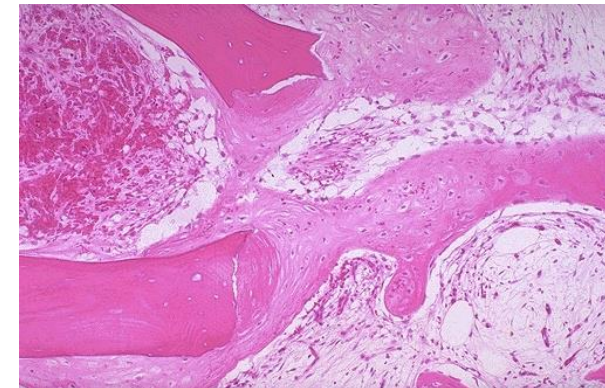
- fracture and inflammatory phase
- granulation tissue formation

Reparative phase

- cartilage *callus* formation
- lamellar bone deposition

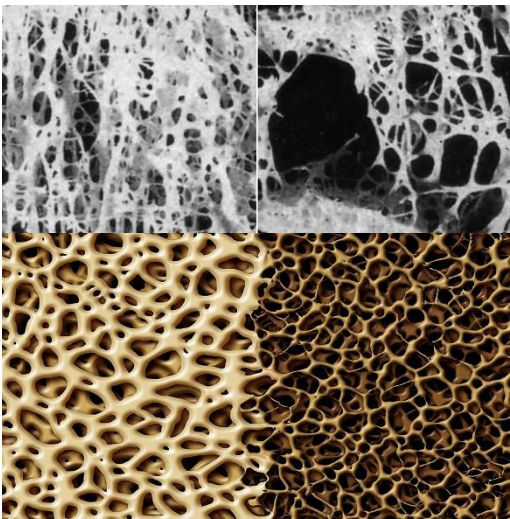
Remodeling phase

- remodeling to original bone shape

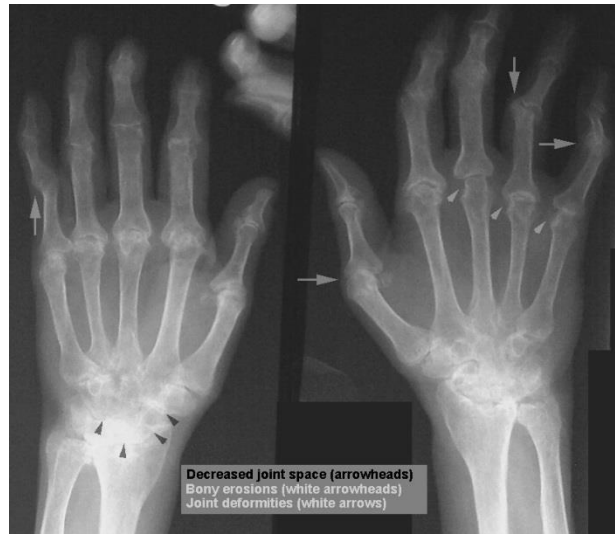

CLINICAL CORRELATIONS – DISBALANCE OF BONE HOMEOSTASIS

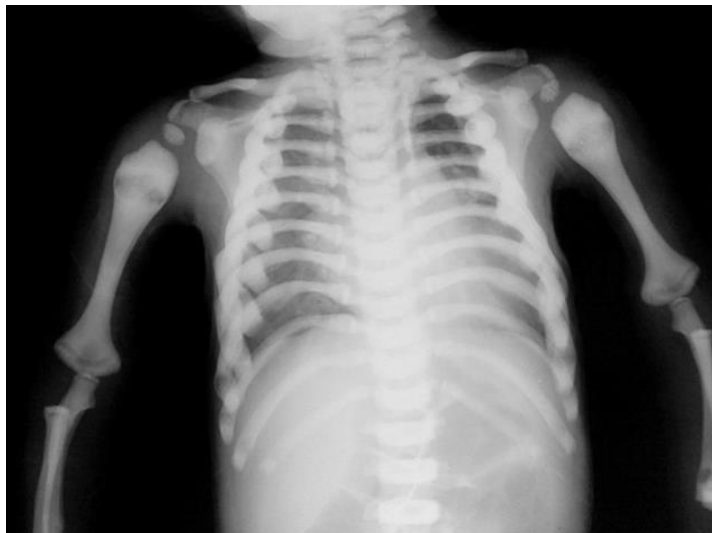- OSTEOPOROSIS**



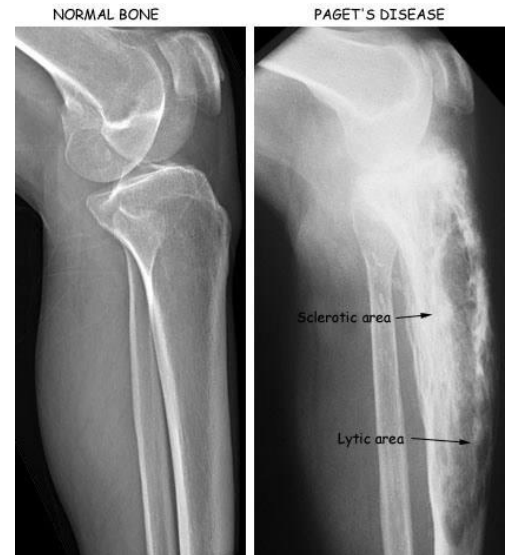- REVMATOID ARTHRITIS**



- OSTEOPETROSIS**



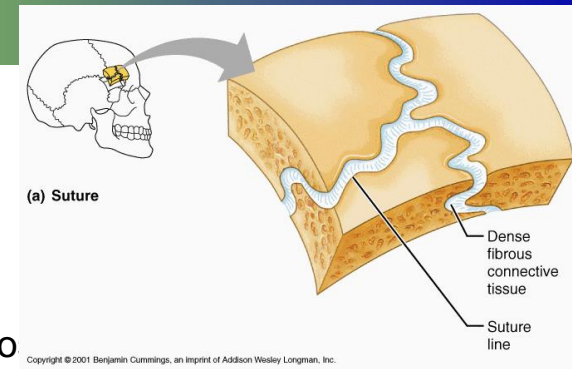
- PAGET DISEASE**



JOINTS

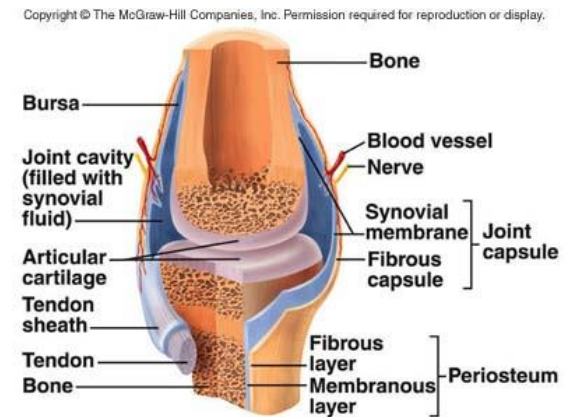
Synarthrosis

- joint by intercalated tissue (cartilage, bone or c.t.)
 - **Synostoses** – joint by bone tissue – os coxae, os sacrum
 - **Synchondrosis** – joint by hyaline cartilage – development of synostosis
 - **Symphysis** – joint by fibrocartilage – os pubis, intervertebral discs
 - **Syndesmosis** – dense collagen regular c.t. – sutures of skull, gomphosis

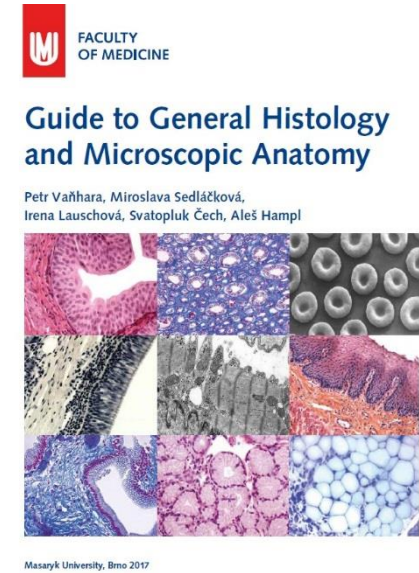

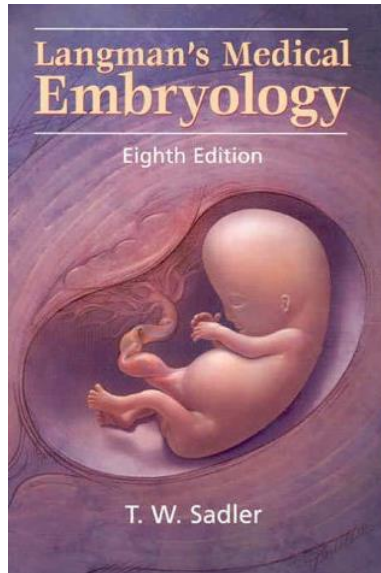

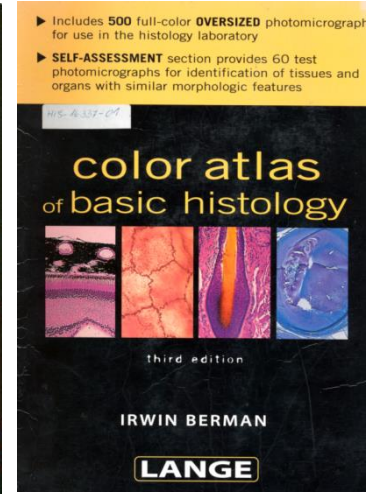





Diarthrosis

- synovial joint
 - hyaline cartilage without perichondrium
 - cartilage calcification in site of attachment to the bone
 - joint capsule
 - *Stratum fibrosum*
 - *Stratum synoviale*
 - meniscus – fibrocartilage, avascular, without innervation
 - tendons – dense collagen regular c.t., elastic fibers
 - bursae – like joint capsule



FURTHER STUDY



Thank you for attention