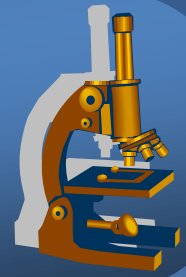
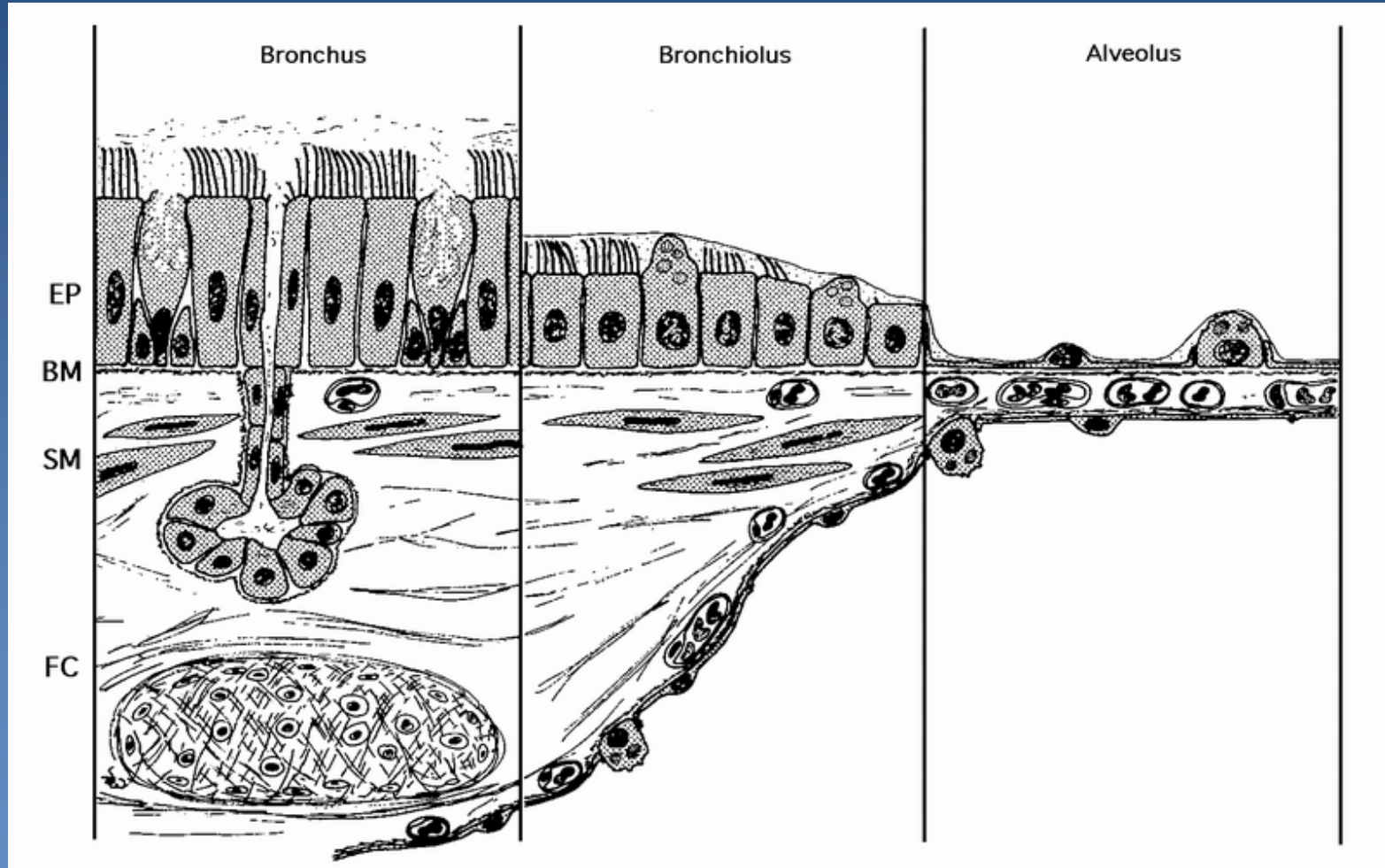


# *Systemic pathology*

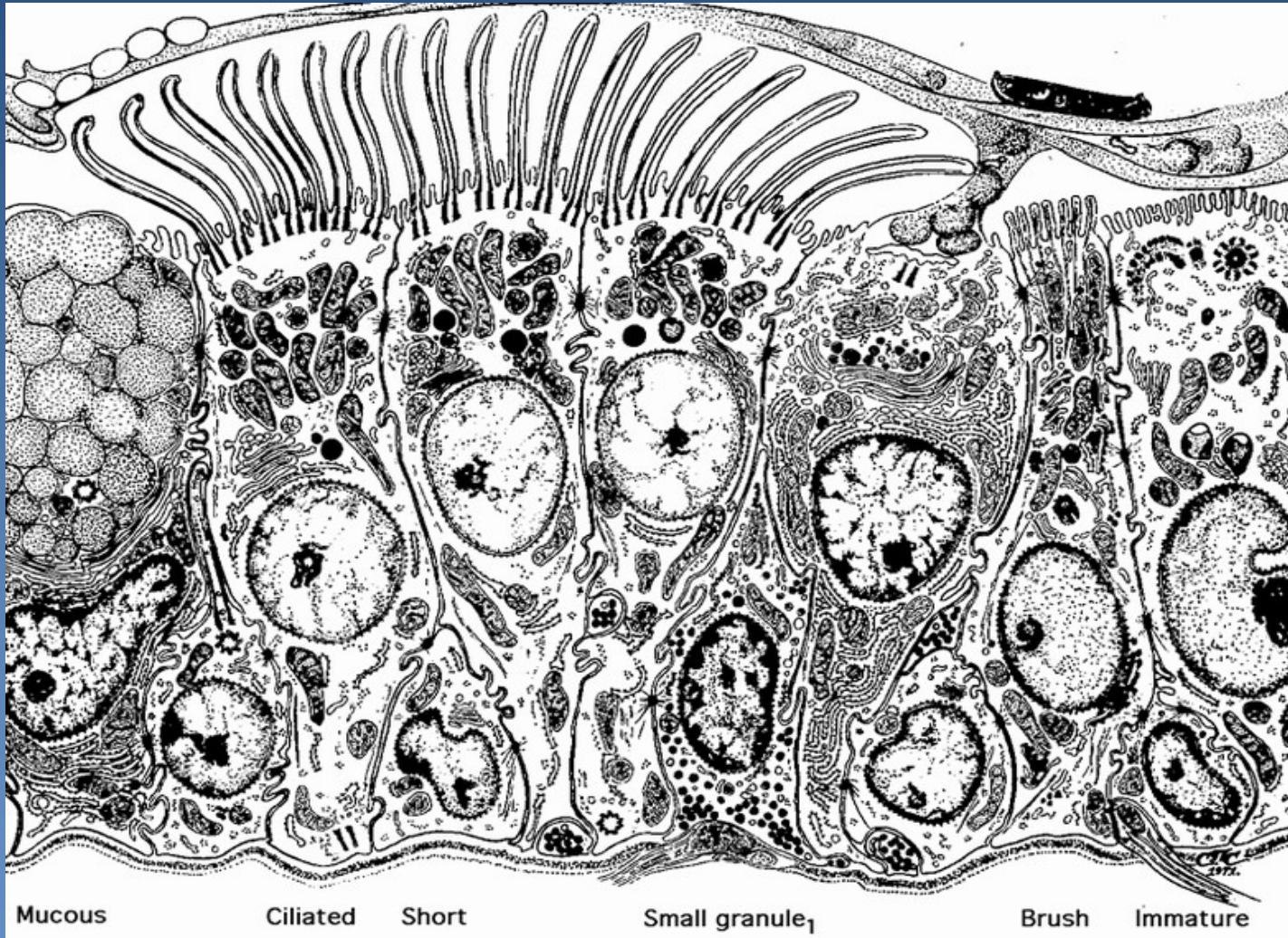


The respiratory tract

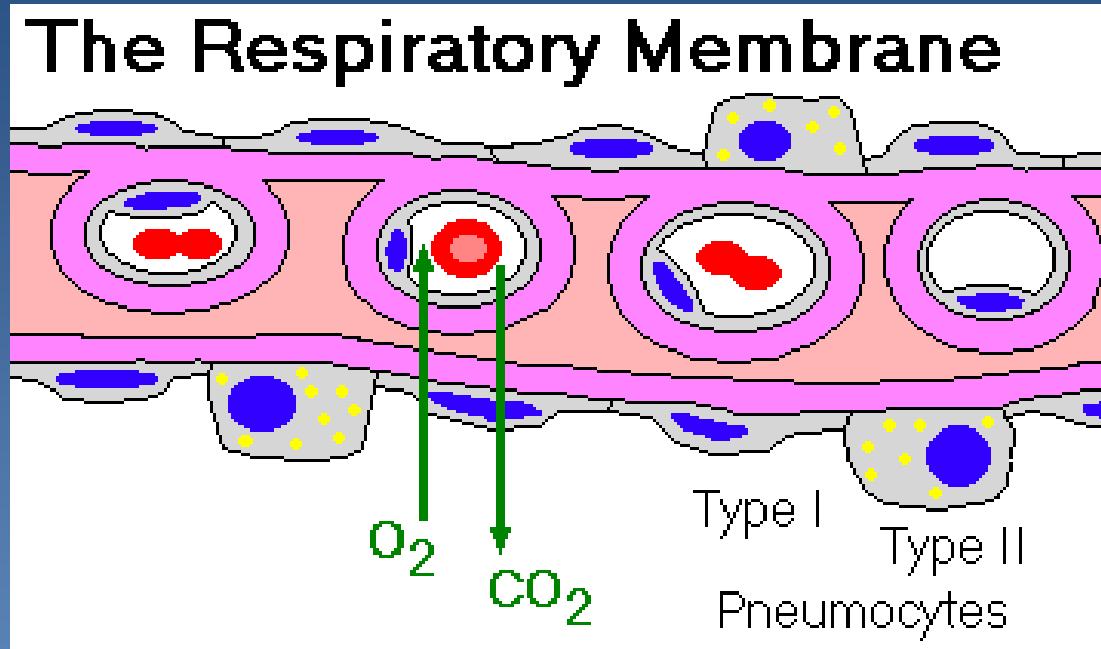
# *Histology of respiratory tract*



# Cellular components of bronchial mucosa



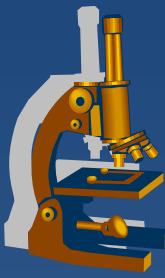
# The respiratory membrane





# *Chronic polypous rhinitis*

---



x chronic proliferative inflammation

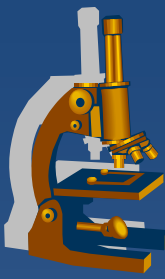
x etiology:

⇒ *chronic irritation*

⇒ *allergy*

⇒ *repeated acute inflammations*

# Chronic polypous rhinitis



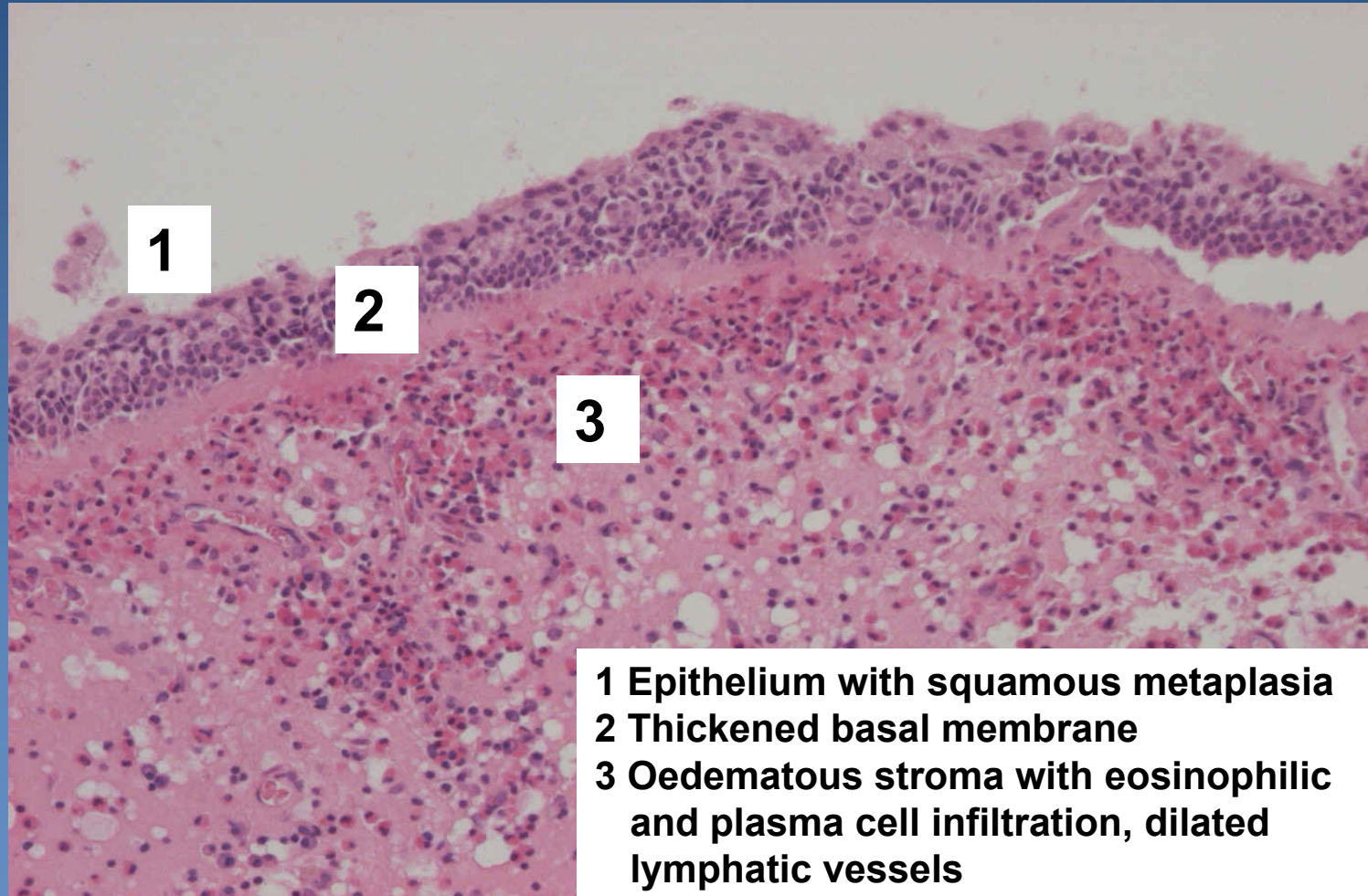
## x Gross:

- ⇒ *mucosal polyps, often multiple*
- ⇒ *variable size (mm – 2 cm)*

## x Micro:

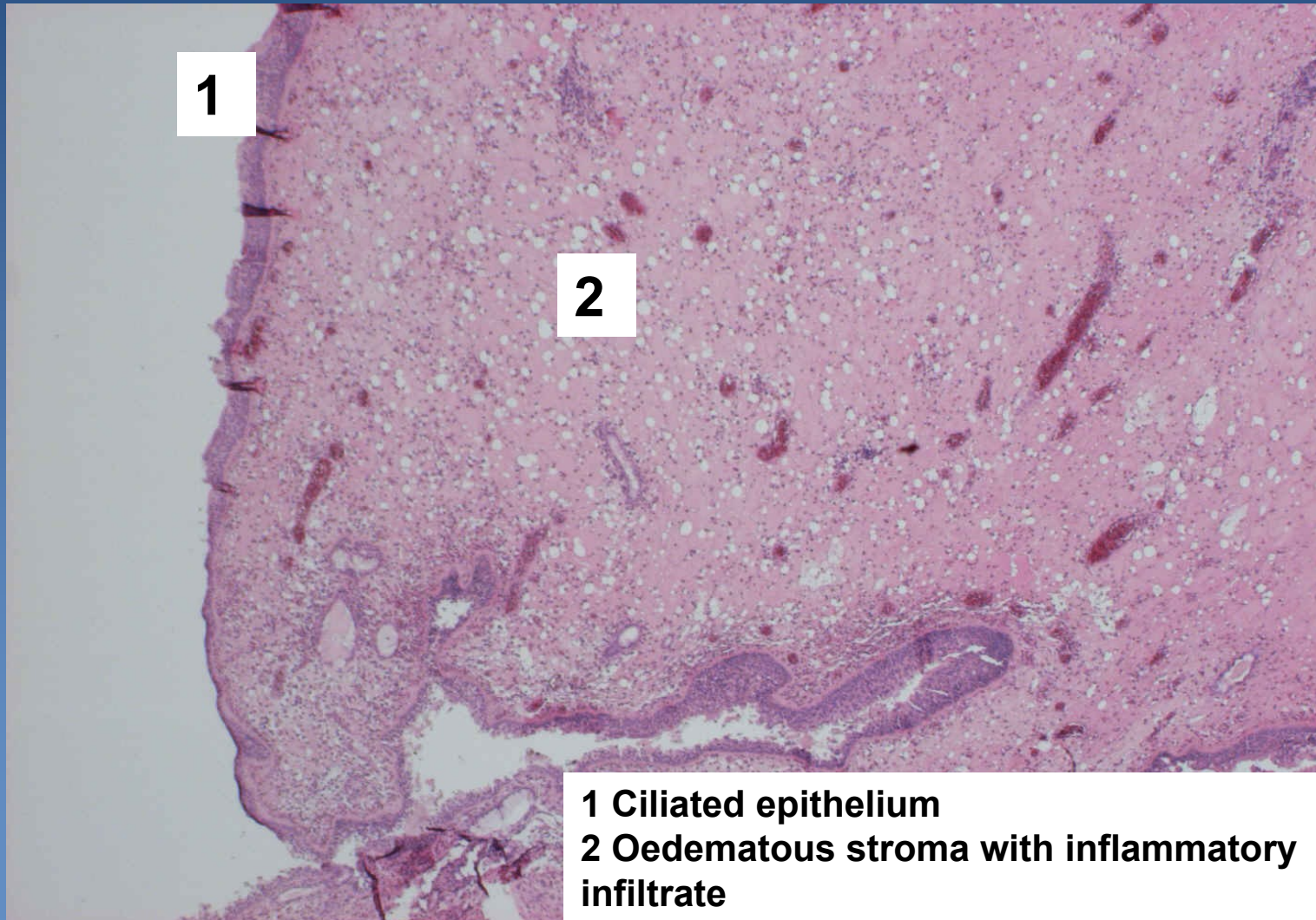
- ⇒ *oedematous mucosal connective tissue*
- ⇒ *lymphoplasmocytic reactive infiltration, admixture of eosinophils, +/- neutrophils*
- ⇒ *mucinous hyperplasia*
- ⇒ *covered by hyperplastic respiratory epithelium, squamous metaplasia possible*

# *Polypous chronic rhinitis*



- 1 Epithelium with squamous metaplasia**
- 2 Thickened basal membrane**
- 3 Oedematous stroma with eosinophilic and plasma cell infiltration, dilated lymphatic vessels**

# *Polypous chronic rhinitis*



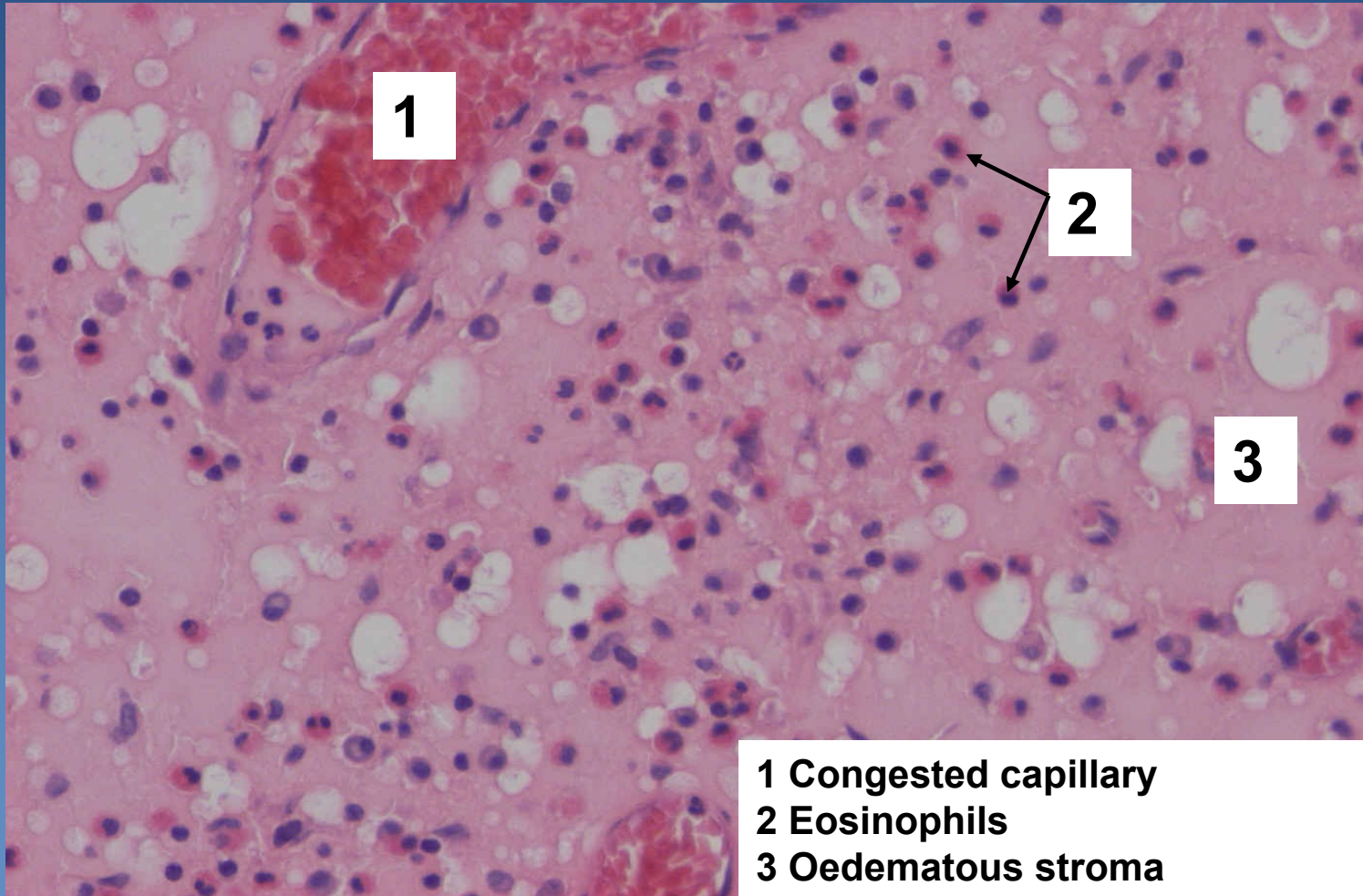
1

2

**1 Ciliated epithelium**  
**2 Oedematous stroma with inflammatory infiltrate**



# *Polypous chronic rhinitis*



- 1 Congested capillary
- 2 Eosinophils
- 3 Oedematous stroma

# *Laryngeal carcinoma*



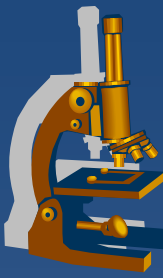
- ✘ **Sequence:** in **squamous** epithelium: hyperplasia – atypical hyperplasia – intraepithelial neoplasia (dysplasia – carcinoma in situ) – invasive carcinoma.
- ✘ In **respiratory** epithelium: squamous metaplasia - intraepithelial neoplasia (dysplasia – carcinoma in situ) – invasive carcinoma.
- ✘ Commonly multiple dysplastic foci and/or sequential carcinomas in upper respiratory/GIT – same oncogenic factors, field theory

# *Laryngeal carcinoma*



- ✗ **Risk factors:** smoking, alcohol, HPV, (asbestos, irradiation)
- ✗ **Papilloma:** HPV, solitary (adults) x multiple (papillomatosis in children). Benign, possible recurrence
- ✗ **Carcinoma:** mainly squamous cell ca, rare adenocarcinoma
- ✗ **On vocal cords, supravocal, infravocal**
- ✗ **Clinical features:** hoarseness, later pain, dysphagia, bleeding

# *Pseudomembranous tracheitis*



- 
- ✗ Diphtheria, influenza, scarlet fever, mumps, etc.
  - ✗ Iatrogenic – intubation; uremia.
  
  - ✗ Risk of ulceration – chondromalacia – cartilage breakdown – perforation - mediastinitis



# ***Pulmonary infarction***



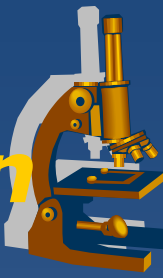
- × aetiology:
  - ⇒ *thrombembolism of a. pulmonalis branches in the setting of compromised cardiovascular status (passive venous congestion)*
- × typically hemorrhagic
- × often in lower lung lobes adjacent to pleura
- × often multiple
- × healing:
  - ⇒ *granulation tissue, later formation of fibrous scar*

# *Pulmonary infarction*



- × aetiology:
  - ⇒ *thrombembolism of a. pulmonalis branches in the setting of compromised cardiovascular status (passive venous congestion)*
  - ⇒ *uncommonly local thrombosis/arterial closure (in carcinoma)*
- × typically hemorrhagic
- × often in lower lung lobes adjacent to pleura
- × often multiple
- × healing:
  - ⇒ *granulation tissue, later formation of fibrous scar*

# ***Hemorrhagic pulmonary infarction***



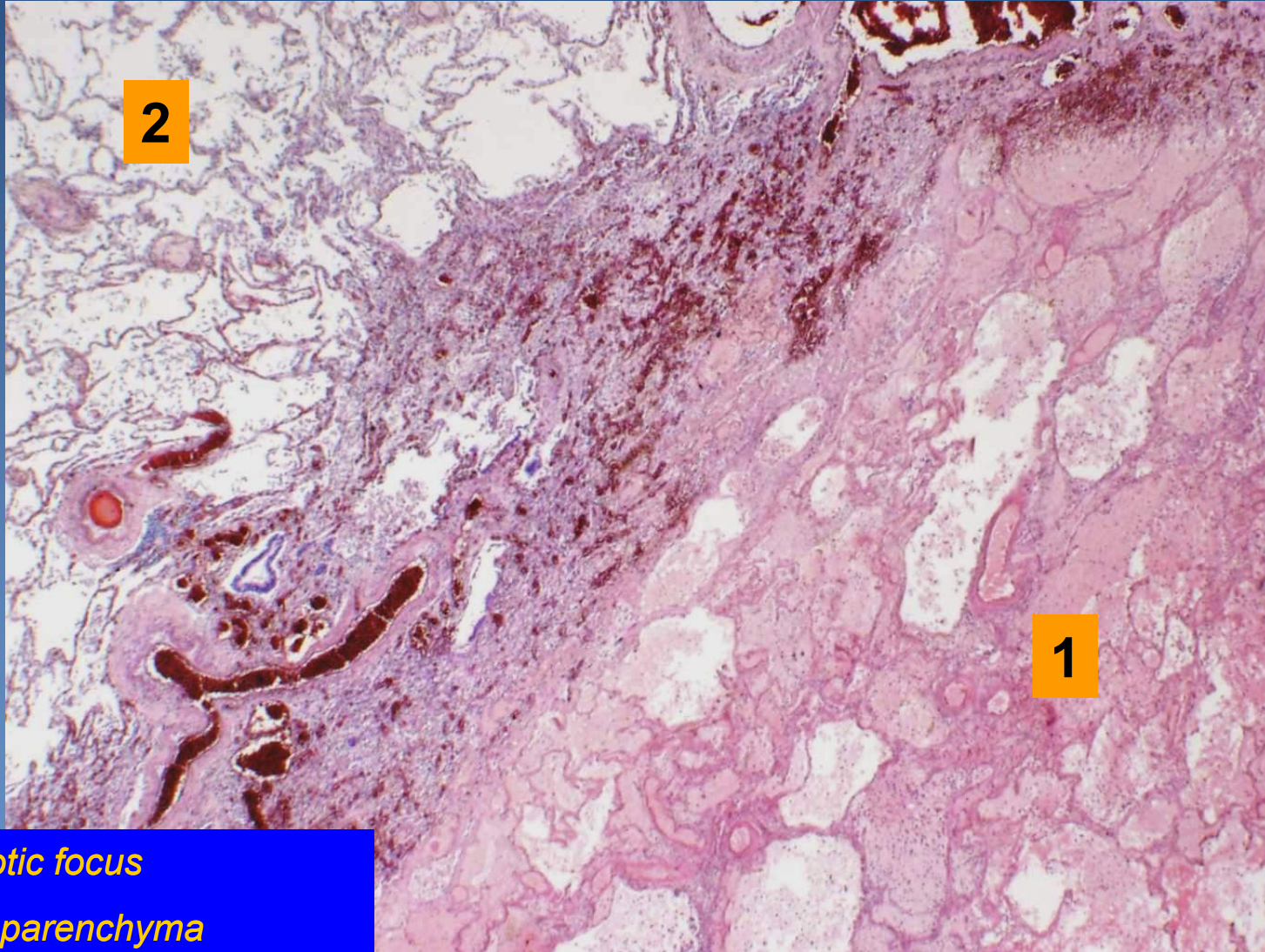
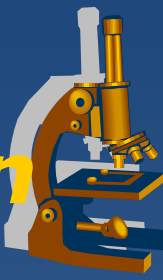
## **x Gross:**

- ⇒ *wedge-shaped sharply demarcated focus*
- ⇒ *dark red-blue (new), yellowish-grey (older)*
- ⇒ *variable size*
- ⇒ *firmer consistency*

## **x Micro:**

- ⇒ *coagulative necrosis of lung parenchyma*
- ⇒ *large extravasations of erythrocytes*
- ⇒ *formation of abscess by secondary infection*
- ⇒ *reactive acute fibrinous pleuritis*
- ⇒ *healing – scarring + emphysema (diff.dg. x tumor)*

# *Hemorrhagic pulmonary infarction*



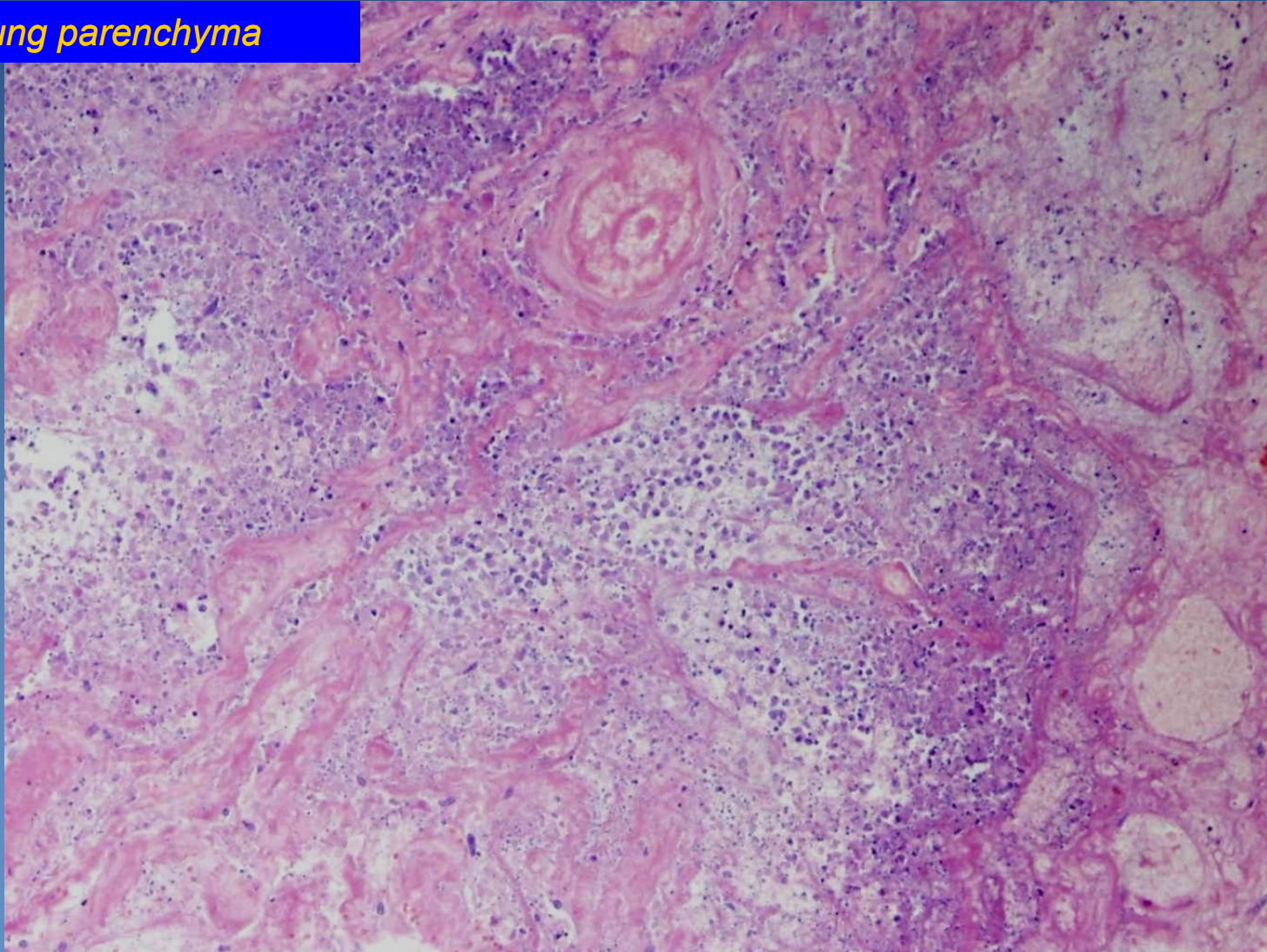
- 1. *Necrotic focus*
- 2. *Lung parenchyma*



# *Hemorrhagic pulmonary infarction*



*Necrotic lung parenchyma*



# Alveolar oedema



- ✗ fluid accumulation in alveoli
  
- ✗ clinically:
  - ⇒ *expectoration of bubbly watery pinkish sputum*
  
- ✗ pathogenesis:
  - ⇒ *↑ vascular permeability (injury to the alveolar-capillary wall)*
  - ⇒ *↑ vascular hydrostatic pressure*
  - ⇒ *↓ intravascular osmotic pressure*
  - ⇒ *lymphatic drainage obstruction*

# Alveolar oedema



✗ Complications: ↑ risk of infection

✗ Gross:

⇒ *lungs enlarged, heavy, congested*

⇒ *bubbly fluid flowing out of the tissue +/- present in bronchi*

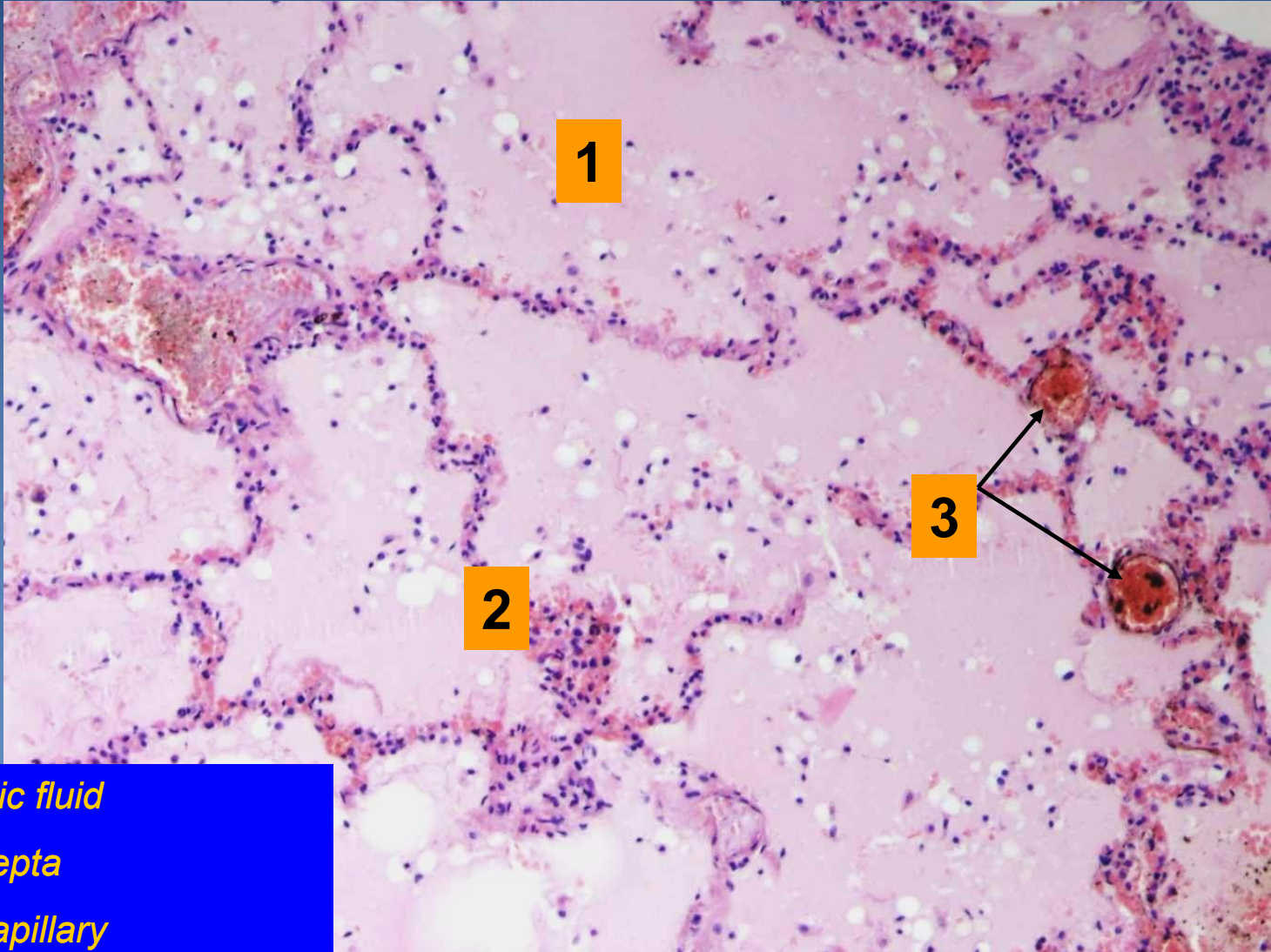
✗ Micro:

⇒ *alveoli filled with pink, homogenous fluid + air bubbles*

⇒ *dilatation and hyperemia of alveolar wall capillaries*



# *Alveolar oedema*



1

2

3

*1. Oedematic fluid*

*2. Dilated septa*

*3. Dilated capillary*



# Amniotic fluid aspiration



- ✘ minor aspiration usual during birth
  - ⇒ *clinically insignificant*
- ✘ massive aspiration associated with fetus asphyxia
  - ⇒ *umbilical cord or placental disorders*
- ✘ clinic:
  - ⇒ *changes in fetal heart rate – immediate medical intervention necessary!*

# *Amniotic fluid aspiration*



## *x Micro:*

*⇒ keratin masses in bronchi and alveoli*

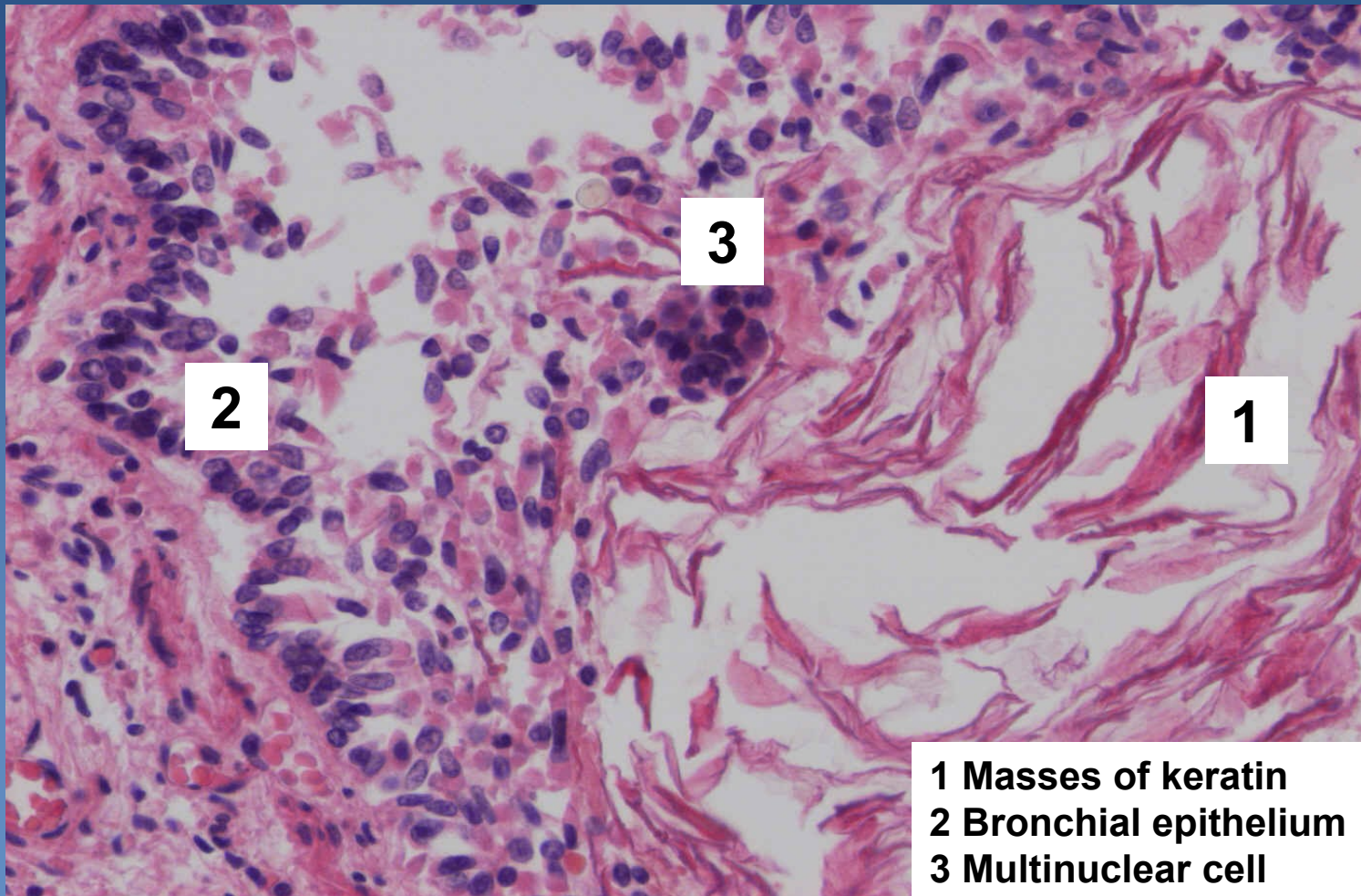
*⇒ amniotic cells*

*⇒ lanugo (thin primary hairs)*

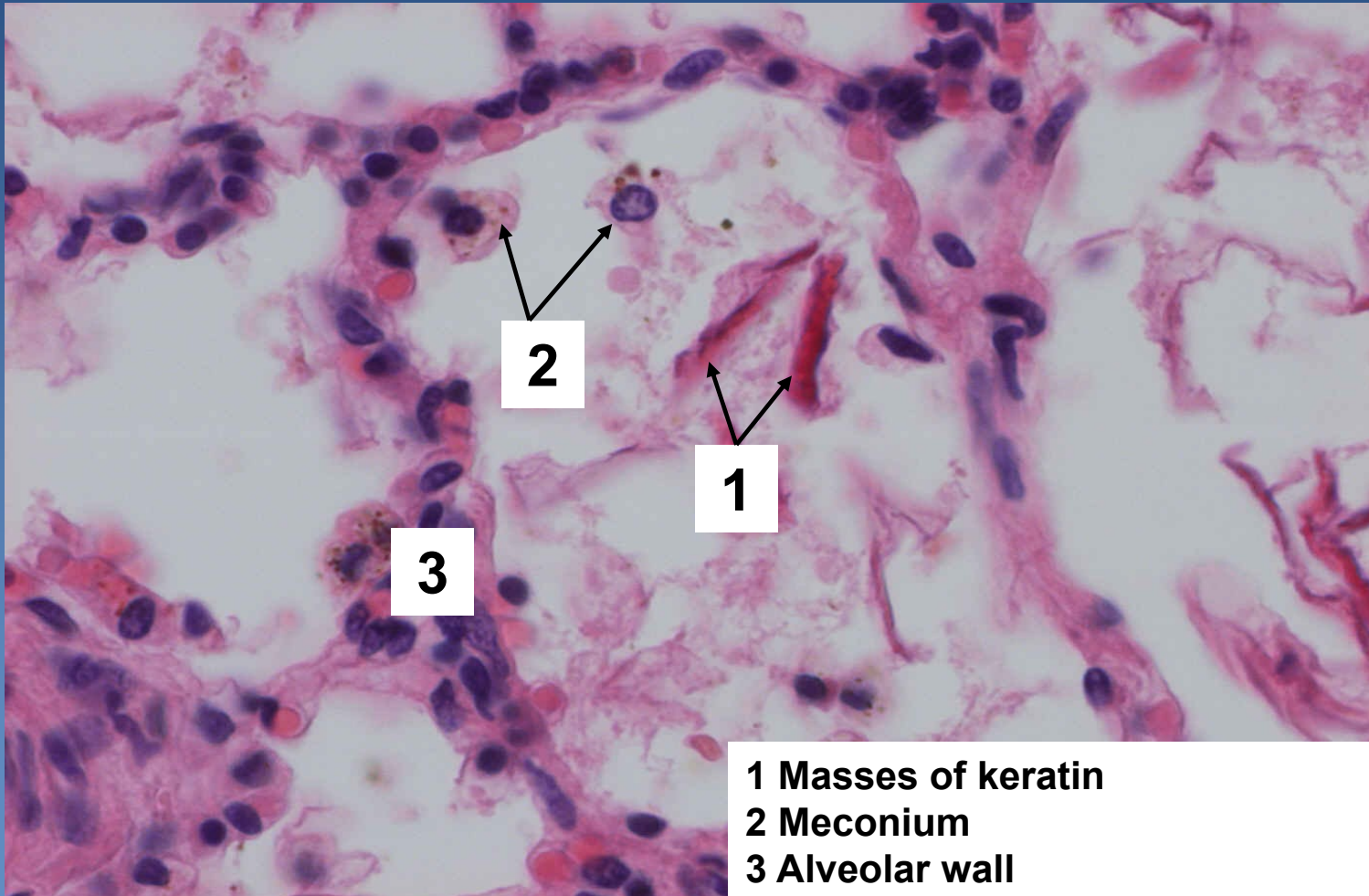*⇒ meconium bodies (from fetus intestinal content)*

*⇒ infected amniotic fluid → fetal death, adnate **pneumonia***

# *Amniotic fluid aspiration, keratin in bronchiole*



# *Amniotic fluid aspiration, keratin in alveoli*



# Chronic pulmonary venous congestion



✘ associated with chronic left-sided cardiac insufficiency

⇒ **etiology:**

- ischemic heart disease, systemic hypertension, valvular disorders, cardiomyopathy

✘ clinically („asthma cardiale“):

⇒ **cough**

- rusty sputum

⇒ **shortness of breath (dyspnoea)**

- ortopnoea
- paroxysmal nocturnal dyspnoea
  - relieved by sleeping with elevated head („additional pillows needed“)



# ***Chronic pulmonary venous congestion***



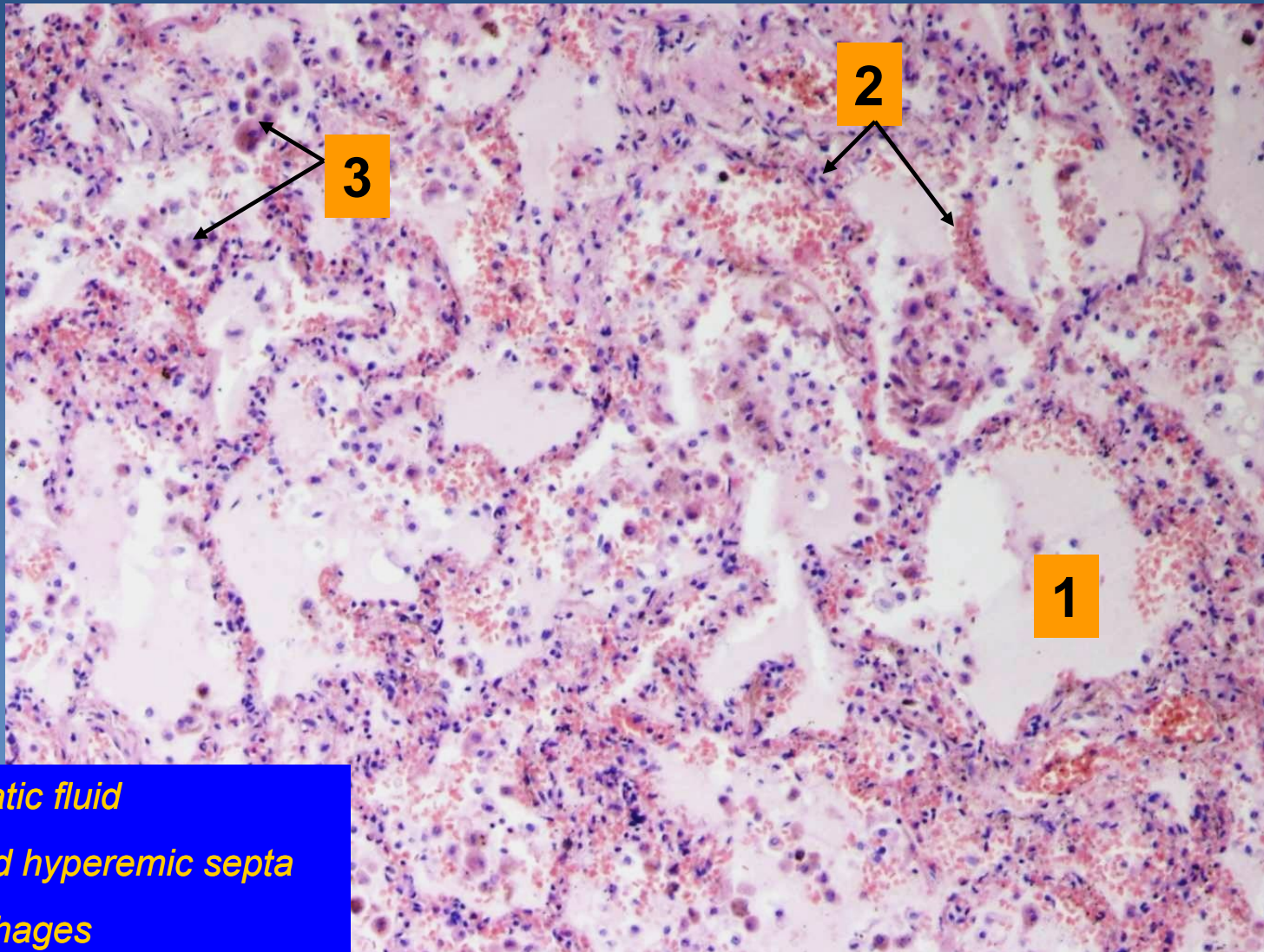
## **x Gross:**

- ⇒ *slightly enlarged lungs*
- ⇒ *solid consistency*
- ⇒ *rusty-brown color*
  - rusty/cyanotic lung induration

## **x Micro:**

- ⇒ *congestion of alveolar capillaries*
- ⇒ *alveolar hemorrhage with siderophages:*
  - histiocytes with cytoplasmic granules of hemosiderin
- ⇒ *fibrotization of alveolar walls*

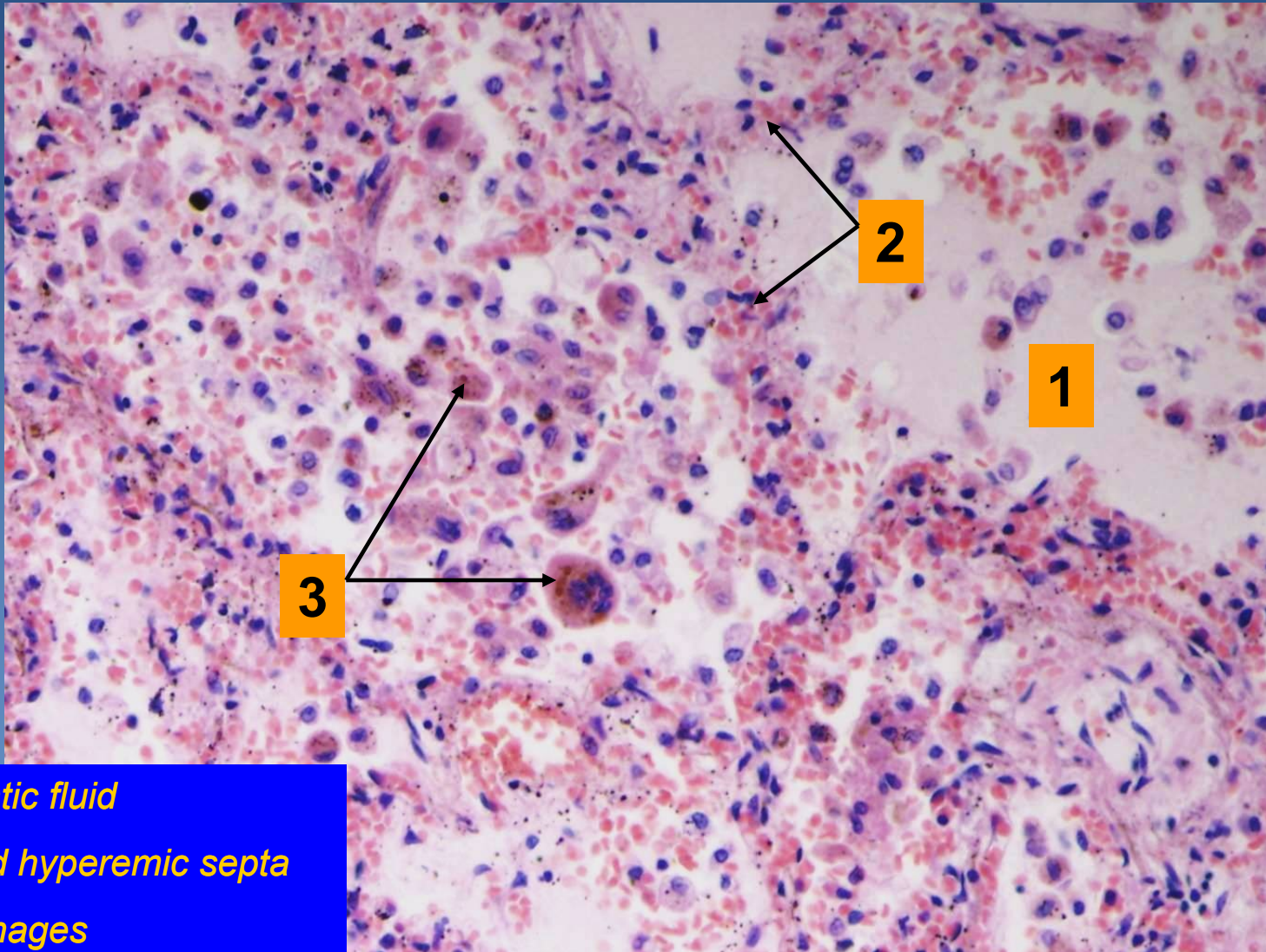
# *Chronic pulmonary venous congestion*



- 1. Oedematic fluid*
- 2. Enlarged hyperemic septa*
- 3. Siderophages*



# *Chronic pulmonary venous congestion*

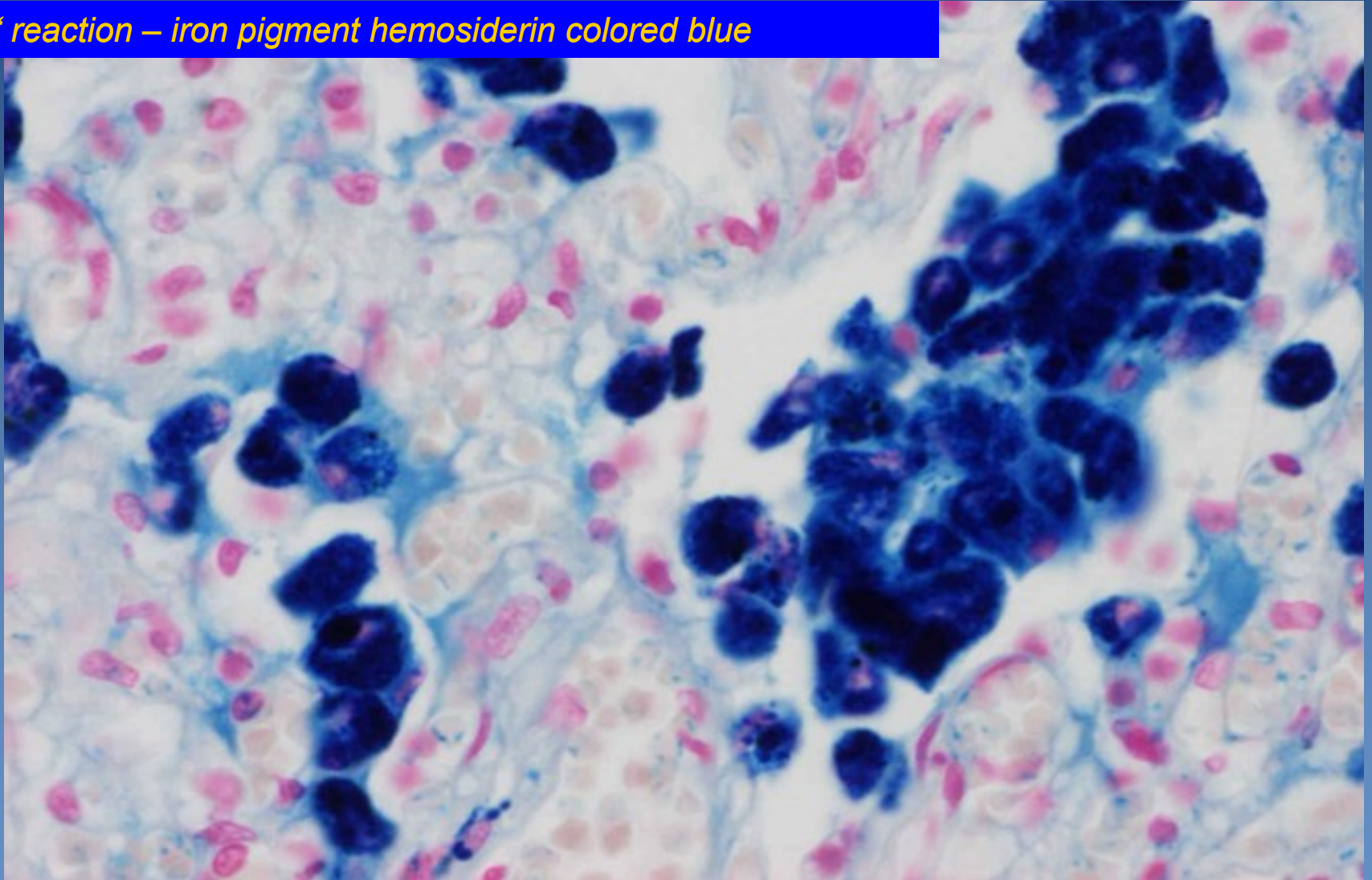


- 1. Oedematic fluid*
- 2. Enlarged hyperemic septa*
- 3. Siderophages*

# *Chronic pulmonary venous congestion*



*Pertl's reaction – iron pigment hemosiderin colored blue*



# Chronic pulmonary diseases



- ✘ **Obstructive** – airway d.-↑in resistance to airflow due to partial/complete obstruction at any level (trachea – bronchi – bronchioles)
  - ⇒ *chronic bronchitis*
  - ⇒ *bronchiectasis*
  - ⇒ *asthma*
  - ⇒ *bronchiolitis*
  - ⇒ *emphysema*
- ✘ **Restrictive** – reduced expansion +/- decreased total lung capacity.
  - ⇒ *chronic interstitial and infiltrative disorders*
  - ⇒ *chest wall disorders*



# ***Chronic obstructive pulmonary disease***



- x Clinical syndrome** – productive cough, dyspnoea, end-stage – respiratory failure
- x Pathology:** chronic bronchitis +/- emphysema
- x Major trigger** – cigarette smoking, air pollution
- x Complications:** recurrent bacterial/viral infections, cor pulmonale, pneumothorax, lung cancer, may progress to respiratory failure

# Chronic bronchitis



- ✘ part of spectrum of ch. obstructive pulmonary disease, duration at least 3 months in 2 years
- ✘ Simple ch. b.
  - ⇒ *productive cough, no airflow obstruction*
- ✘ Chronic asthmatic bronchitis
  - ⇒ *intermittent bronchospasm, hyperreactive bronchi*
- ✘ Obstructive ch. b.
  - ⇒ *chronic obstruction, usually + emphysema*

# Asthma bronchiale



- ✗ chronic inflammatory disease of bronchial tree, recurrent attacks of bronchospasm with expiratory dyspnoea, cough, mucus hypersecretion
- ✗ increased irritability of the bronchial tree with paroxysmal narrowing of the airways.
- ✗ status asthmaticus:
  - ⇒ *increased frequency of attacks – permanent bronchospasm*
  - ⇒ *may be lethal*
- ✗ variants:
  - ⇒ **atopic (extrinsic):**
    - environmental factors, type I hypersensitivity reaction, IgE, mast cells degranulation, increased vascular permeability and mucus secretion + eosinophils activation
    - bronchioconstriction, distal collapse or overinflation
  - ⇒ **non - atopic (intrinsic):**
    - triggered by infection (viral), subsequent hyperreactive state of vagal receptors, reaction after nonspecific irritation
  - ⇒ **drug-induced:** i.e. aspirin, NSAID, cytokine dysbalance, commonly + urticaria, rhinitis
  - ⇒ **occupational:** variable etiology (type I+III hypersensitivity) and stimulating agents

# Asthma bronchiale



## × Gross:

- ⇒ *acute changes: bronchospasm + emphysema/collapse, mucus plugs in peripheral bronchi and bronchioles, bronchial inflammatory infiltrate*
- ⇒ *chronic airway remodeling: hypertrophy/hyperplasia of smooth muscle and mucous glands*

## × Micro:

### ⇒ *intraluminal:*

- mucus (Curschmann spirals), eosinophils, Charcot-Leyden crystals, cellular detritus

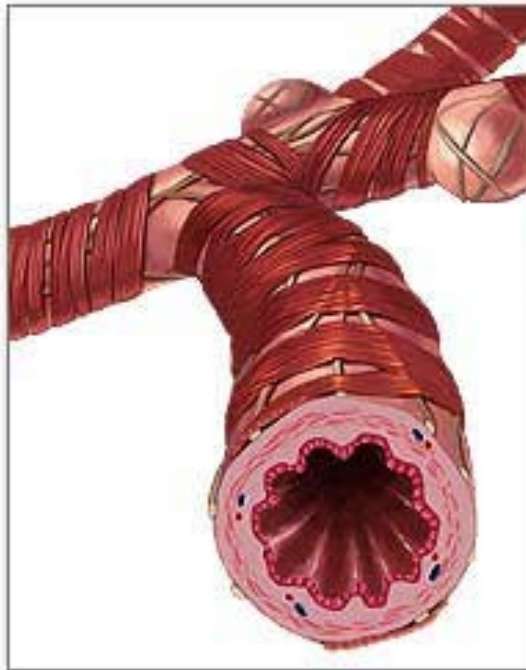### ⇒ *bronchial wall:*

- oedema of the mucous membrane
- thickening (collagenisation) of the sub-basement membrane tissue
- mucous glands hypertrophy, eosinophil-rich inflammatory infiltrate, ↑ vascularity, MALT

# *Asthma bronchiale*



Normal bronchiole



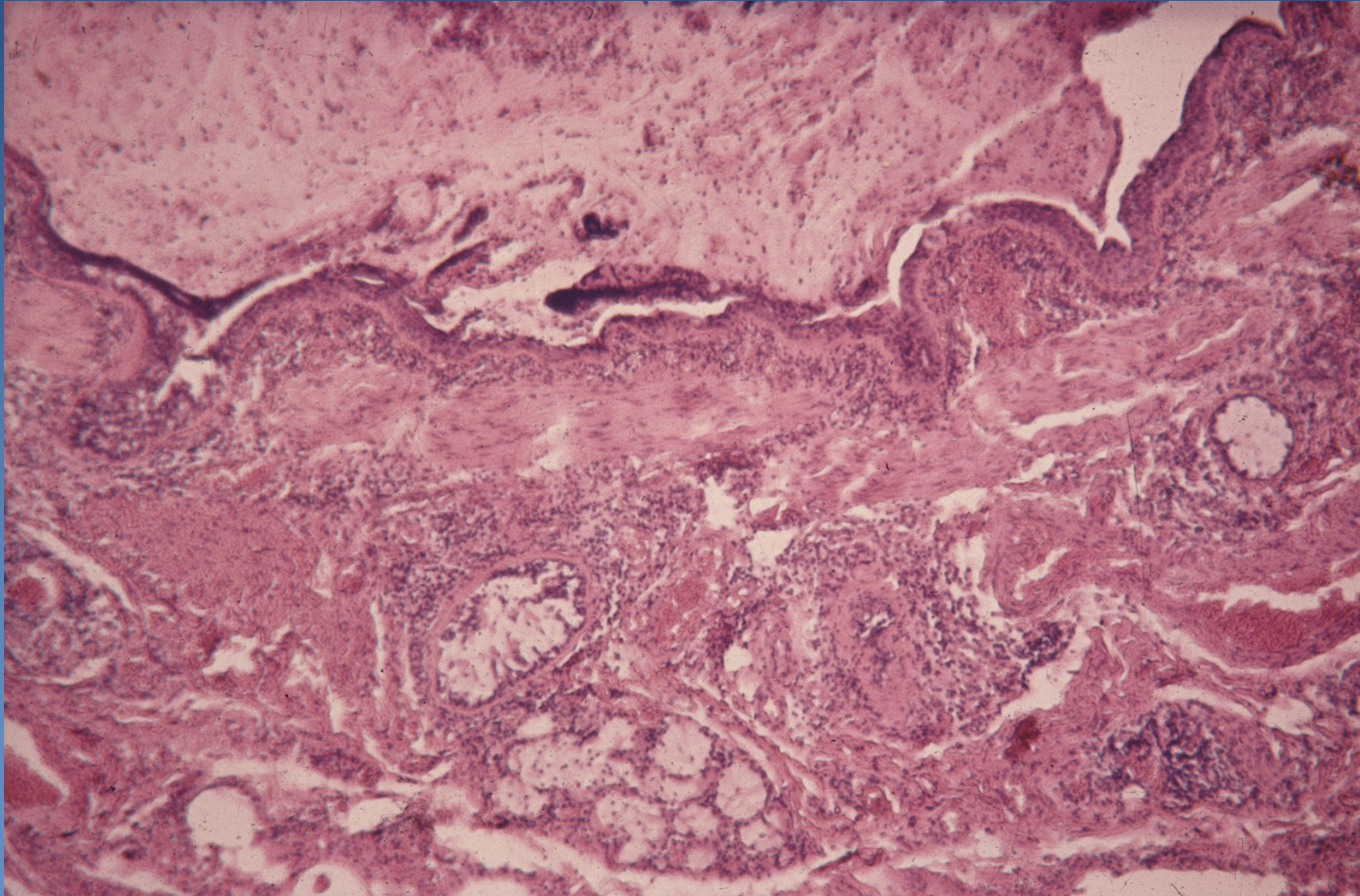
Asthmatic bronchiole



copy



# *Asthma bronchiale*



# *Bronchiectasis*



- ✘ permanent abnormal dilatation of bronchi
- ✘ arising from the weakening of the walls or changes in air pressure
- ✘ morphology:
  - ⇒ *cylindrical*
  - ⇒ *saccular*
  - ⇒ *fusiform*

# Bronchiectasis



## × aetiology:

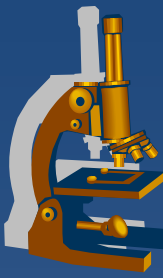
### ⇒ *congenital/hereditary conditions:*

- cystic fibrosis
- Kartagener syndrome (structural abnormalities of the cilia, leading to persistent infections)

### ⇒ *acquired:*

- chronic inflammations
  - Postinfectious ( incl. necrotizing pneumonia)
  - Bronchial obstruction (tumor, foreign bodies, mucus)
  - Other (SLE, rheumatoid arthritis, etc.)
- radiotherapy
- changes of the pressure
  - chronic pulmonary collapse

# Bronchiectasis



## x complications:

### ⇒ *inflammations:*

- chronic purulent bronchitis
- bronchopneumonia including abscess formation
- secondary infection incl. fungal (aspergilloma)
- metastatic infection (brain abscess)

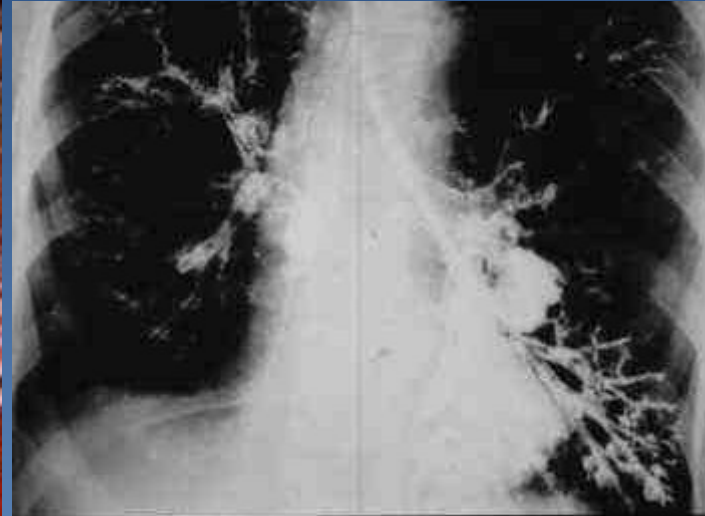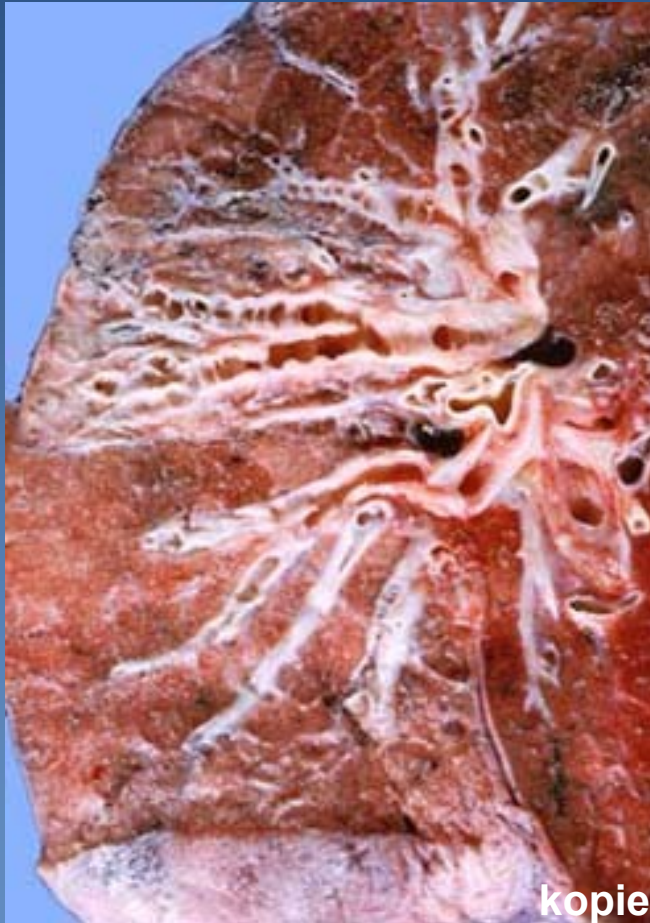### ⇒ *emphysema*

### ⇒ *fibrosis, pulmonary hypertension and cor pulmonale*

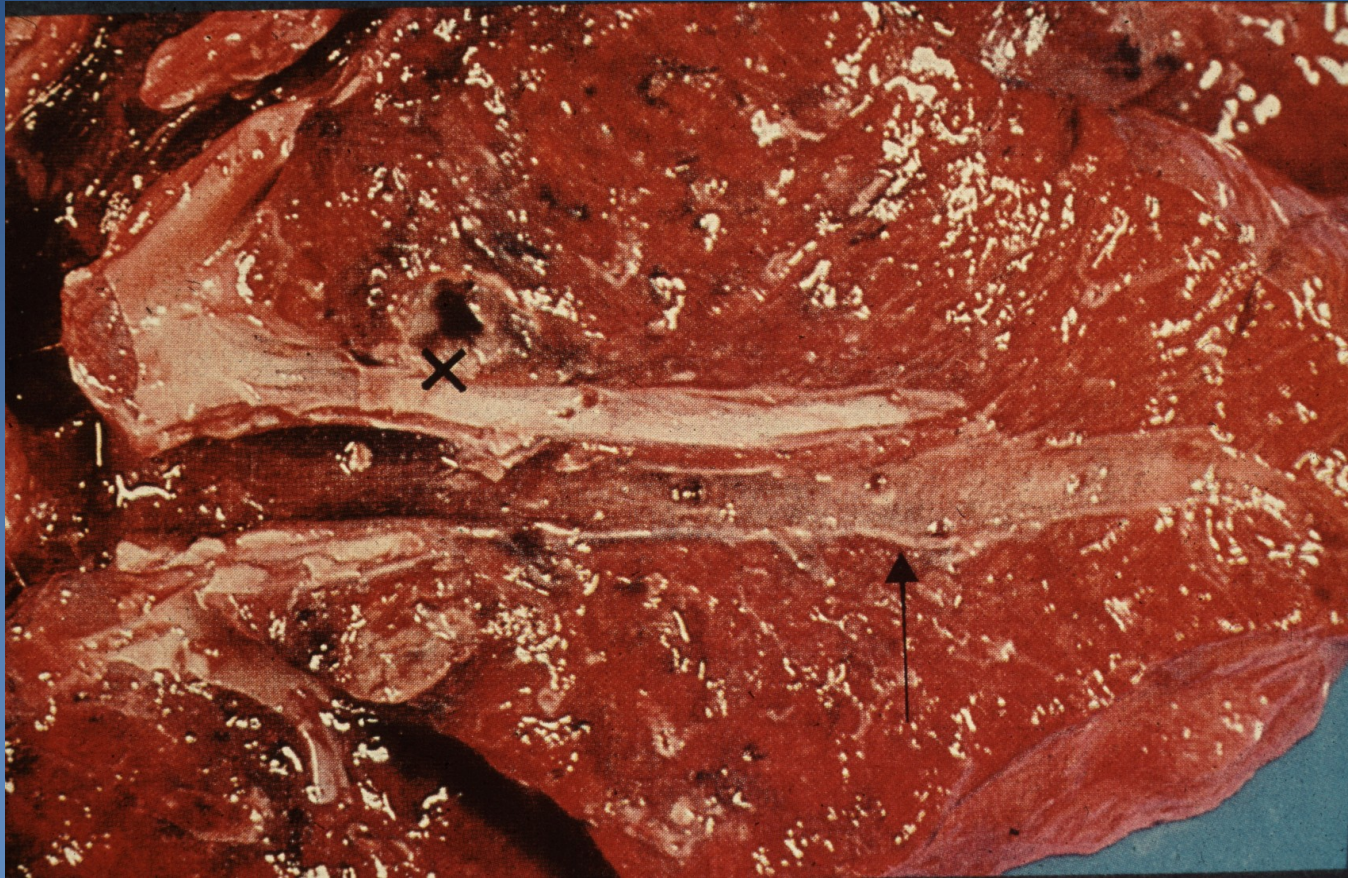
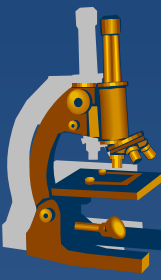
### ⇒ *secondary AA amyloidosis*



# *Bronchiectasis*



# *Bronchiectasis*



# *Pulmonary emphysema*



- × regressive change
  
- × abnormal permanent enlargement of the airspaces + alveolar wall destruction in the pulmonary tissue
  
- × aetiology (combination of several factors):
  - ⇒ *smoking*
  - ⇒ *deficiency of  $\alpha$ 1-antitrypsin*
  - ⇒ *other*
  
- × types:
  - ⇒ *alveolar:*
    - acute
    - chronic
  
  - ⇒ *interstitial – airway rupture (trauma)*

# *Alveolar emphysema*



## **x** acute:

- ⇒ *alveolar septa are not destroyed*
- ⇒ *rather pulmonary hyperinflation or distention*

## **x** chronic:

- ⇒ *permanent enlargement of airspaces distal to terminal bronchioles*
- ⇒ *destruction of alveolar walls*
- ⇒ *part of COPD (chronic obstructive pulmonary disease)*
  - combination of chronic bronchitis and chronic emphysema



# Emphysema



✗ pathogenesis and complications: protease-antiprotease + oxidant-antioxidant imbalance in the setting of inflammatory response, bronchiolitis, later possible maladaptive immune response

*thinning of alveolar walls and capillaries →*

*reduced blood supply →*

*complete destruction of alveolar walls →*

*difficult expiration + decreasing of lung capacity →*

*hypoxemia → endothelial cell dysfunction*

*medial hypertrophy, intimal fibrosis + vasoconstriction →*

*secondary pulmonary hypertension → →*

*cor pulmonale*



# Alveolar emphysema



## × types:

### ⇒ **centrilobular (centriacinar):**

- upper lobes – apex, more in males,
- most commonly seen in smokers without congenital       -antitrypsin deficiency (but + chronic bronchitis), possible professional disease - dust

### ⇒ **panacinar:**

- often lower lung zones; significant microscopic changes;       -antitrypsin deficiency, old age

### ⇒ **distal acinar (paraseptal):**

- adjacent to pleura, upper lobes foci of fibrosis, formation of cystlike structures – **bullae** (pneumothorax risk)

### ⇒ **irregular:**

- associated with scarring, usually postinflammatory

# *Alveolar emphysema*



## **x** Gross:

⇒ *enlarged, voluminous lungs, light, pale, dry, emphysematous bullae*

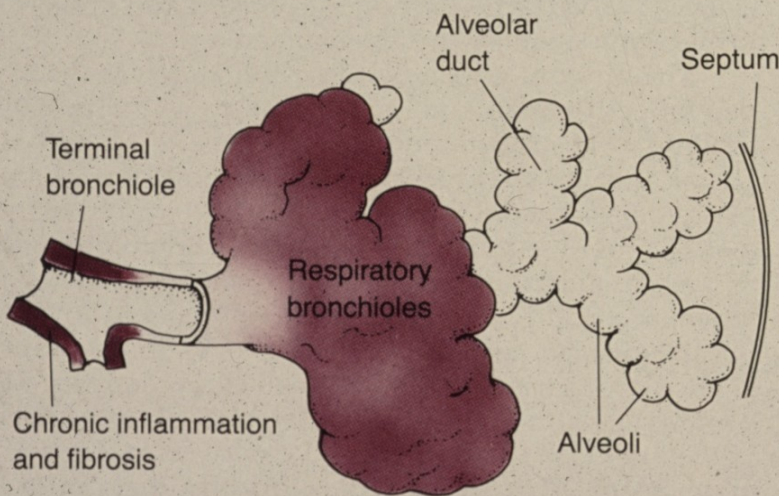
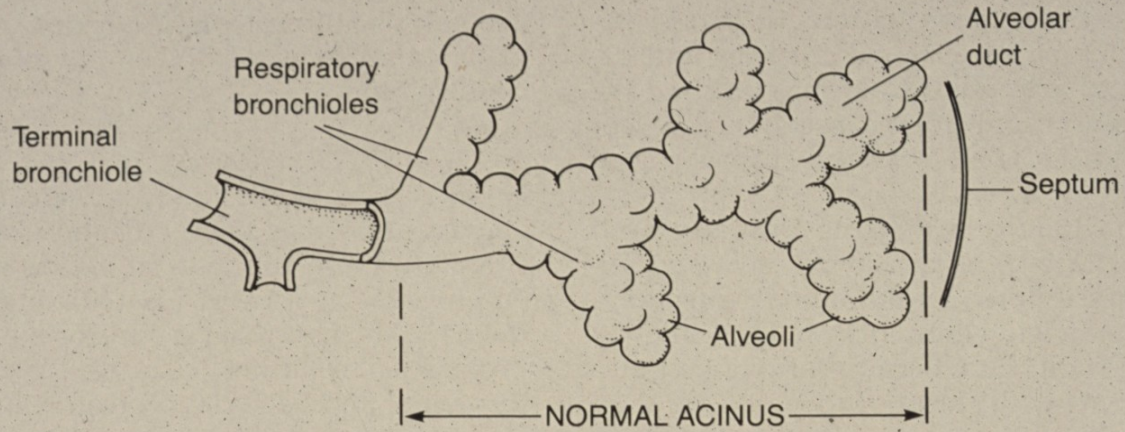
## **x** Micro:

⇒ *thinning and destruction of alveolar walls*

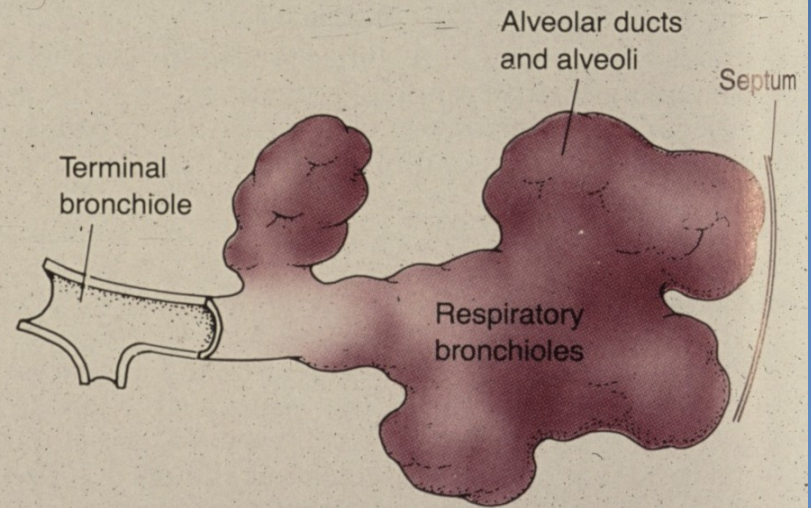
⇒ *deformation of bronchiolar walls*

⇒ *chronic inflammatory changes*

# Emphysema



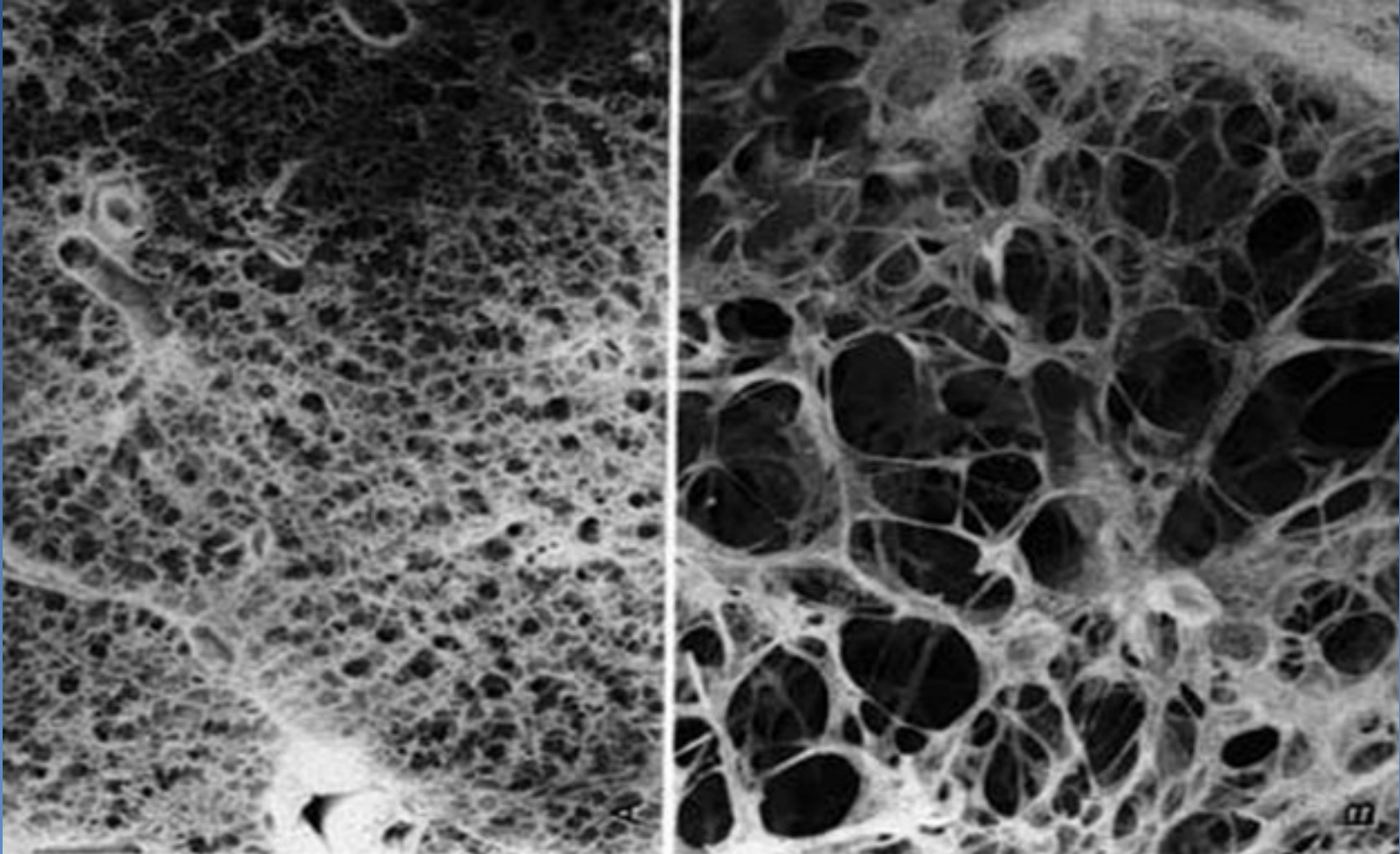
CENTRILOBULAR EMPHYSEMA



PANACINAR EMPHYSEMA

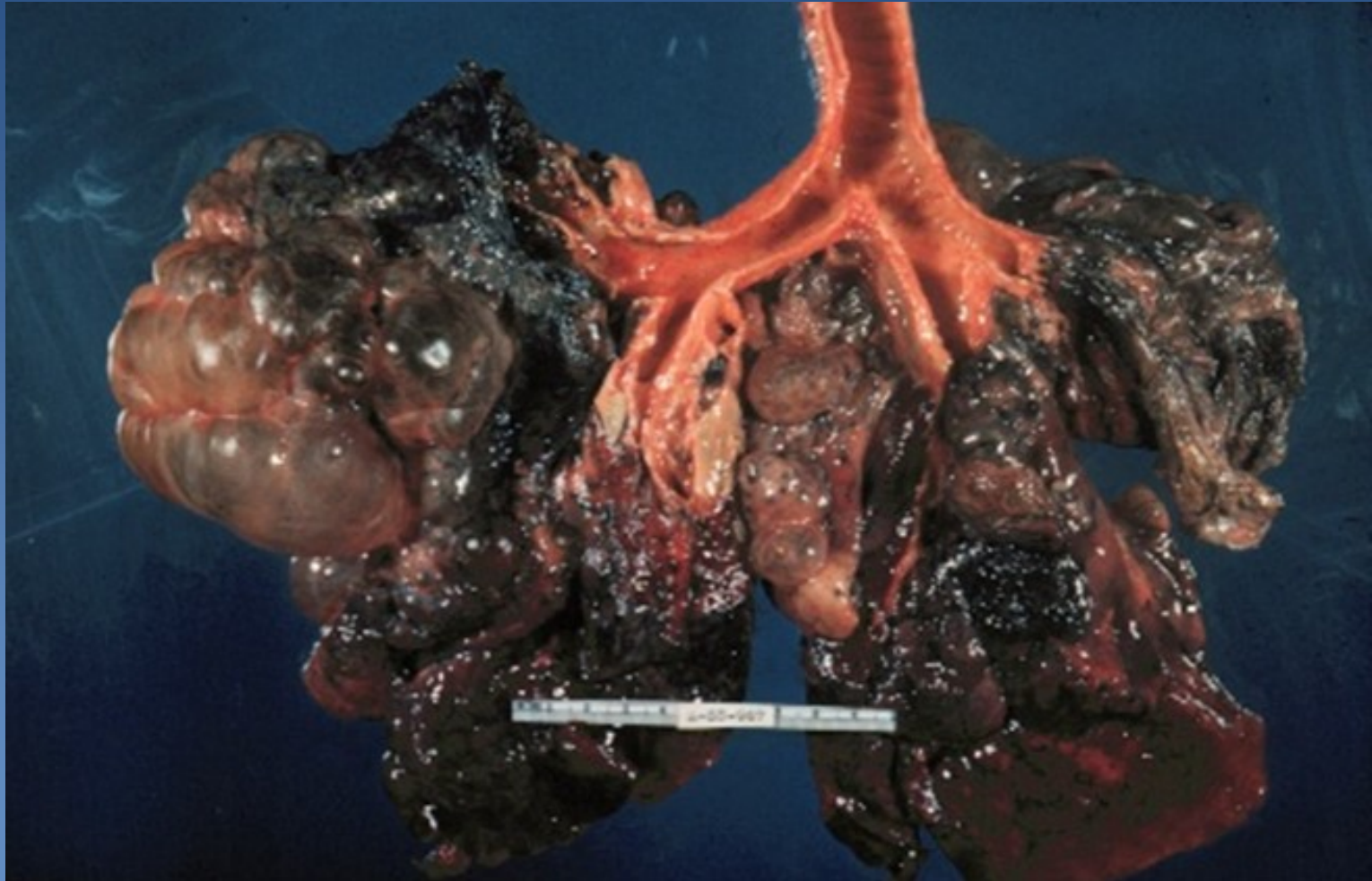
FIGURE 12-32

# *Normal lung and pulmonary emphysema*



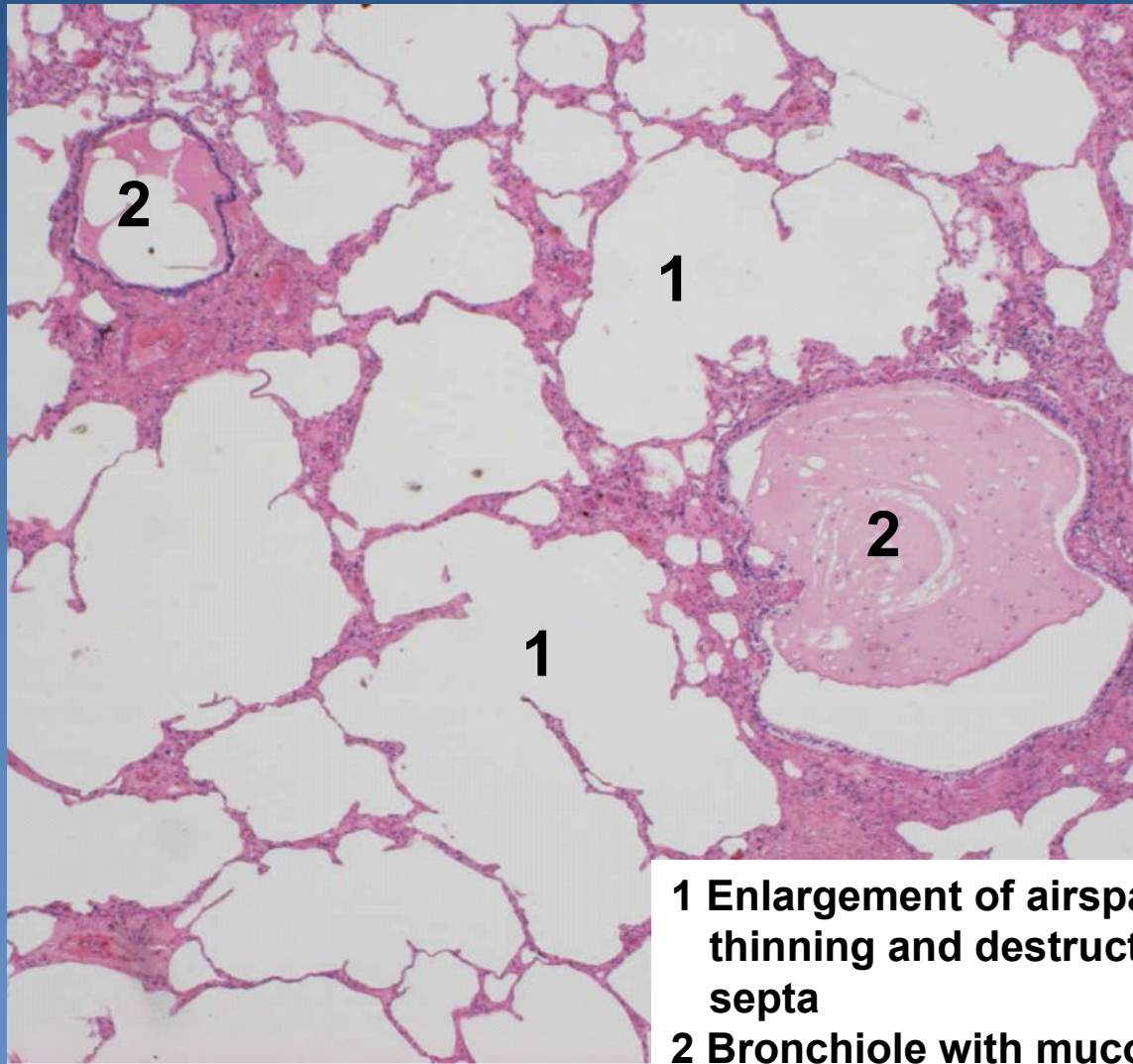


# ***Bullous emphysema***





# *Panacinar emphysema*



- 1** Enlargement of airspaces with thinning and destruction of alveolar septa
- 2** Bronchiole with mucous secretions

# *Pulmonary inflammations - classification*

---



## Etiology

- ✘ Infections
- ✘ **Non-infectious**, commonly from the group of chronic interstitial lung disease (hypersensitivity pneumonitis, nonspecific interstitial pneumonia, etc.)

# ***Pulmonary inflammations - classification***



## **x superficial:**

⇒ *lobar pneumonia*

⇒ *bronchopneumonia*

## **x interstitial**

⇒ *purulent (abscess, gangrene)*

⇒ *non-purulent*

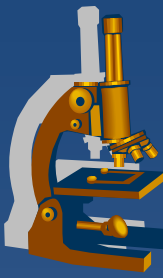
- infectious (acute) – atypical pneumonia
- non-infectious (chronic)

# Pneumonias



- ✘ Community acquired acute pneumonia
  - ⇒ *Str. pneumoniae*
  - ⇒ *Haemophilus influenzae*
  - ⇒ *Staph. aureus*
  - ⇒ *Legionella pneumophila*
  - ⇒ *Klebsiella pneumoniae*
  - ⇒ *Pseudomonas*
  - ⇒ others (*Moraxella*, ...)

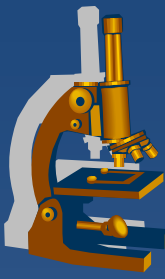# *Pneumonias*



- ✘ Community acquired atypical pneumonia
  - ⇒ *Mycoplasma pneumoniae*
  - ⇒ *Chlamydia ssp.*
  - ⇒ *Coxiella burnetii* (Q-fever)
  - ⇒ *viruses* – SARS-CoV-2, influenza, parainfluenza, adenovirus, RS virus, etc.



# Pneumonias



- ✘ Hospital acquired pneumonias
  - ⇒ *G- rods, Enterobacteriaceae (Klebsiella, E.coli, Pseudomonas)*
  - ⇒ *Staph. aureus (methicillin resistant)*
  
- ✘ Aspiration pneumonia
  - ⇒ *anaerobic oral flora + aerobic bacteria (incl. Str., Staph., Haemophilus etc.)*

# Pneumonias



## x Chronic pneumonia

⇒ *Nocardia*

⇒ *Actinomyces*

⇒ *Granulomatous: mycobacteria (TBC, atypical), Histoplasma, other fungi*

## x Necrotizing pneumonia and lung abscess

⇒ *Anaerobic bacteria (+/- mixed aerobic infection)*

⇒ *Staph. aureus, Klebsiella, Str. pyogenes*

⇒ *some anthroponozoses (plague, anthrax)*

# *Pneumonias*



- ✘ P. in the immunocompromised host
  - ⇒ *CMV*
  - ⇒ *Pneumocystis jirovecii*
  - ⇒ *Mycobacterium avium-intracellulare*
  - ⇒ *Invasive aspergillosis*
  - ⇒ *Invasive candidiasis*
  - ⇒ „usual“ infections

# *Lobar pneumonia*



- ✗ superficial diffuse **fibrinous** inflammation
- ✗ affecting major part / entire lobe of a lung
  - ⇒ *similar histological features in the same time*
  - ⇒ *older/immunocompromised patients → lethal without antibiotic therapy*
- ✗ untreated – 4 stages:
  - ⇒ *congestion (+ oedema)*
  - ⇒ *red hepatization (inflammatory infiltrate + congestion)*
  - ⇒ *grey hepatization (fibrin)*
  - ⇒ *resolution (resorption)*



# *Lobar pneumonia*



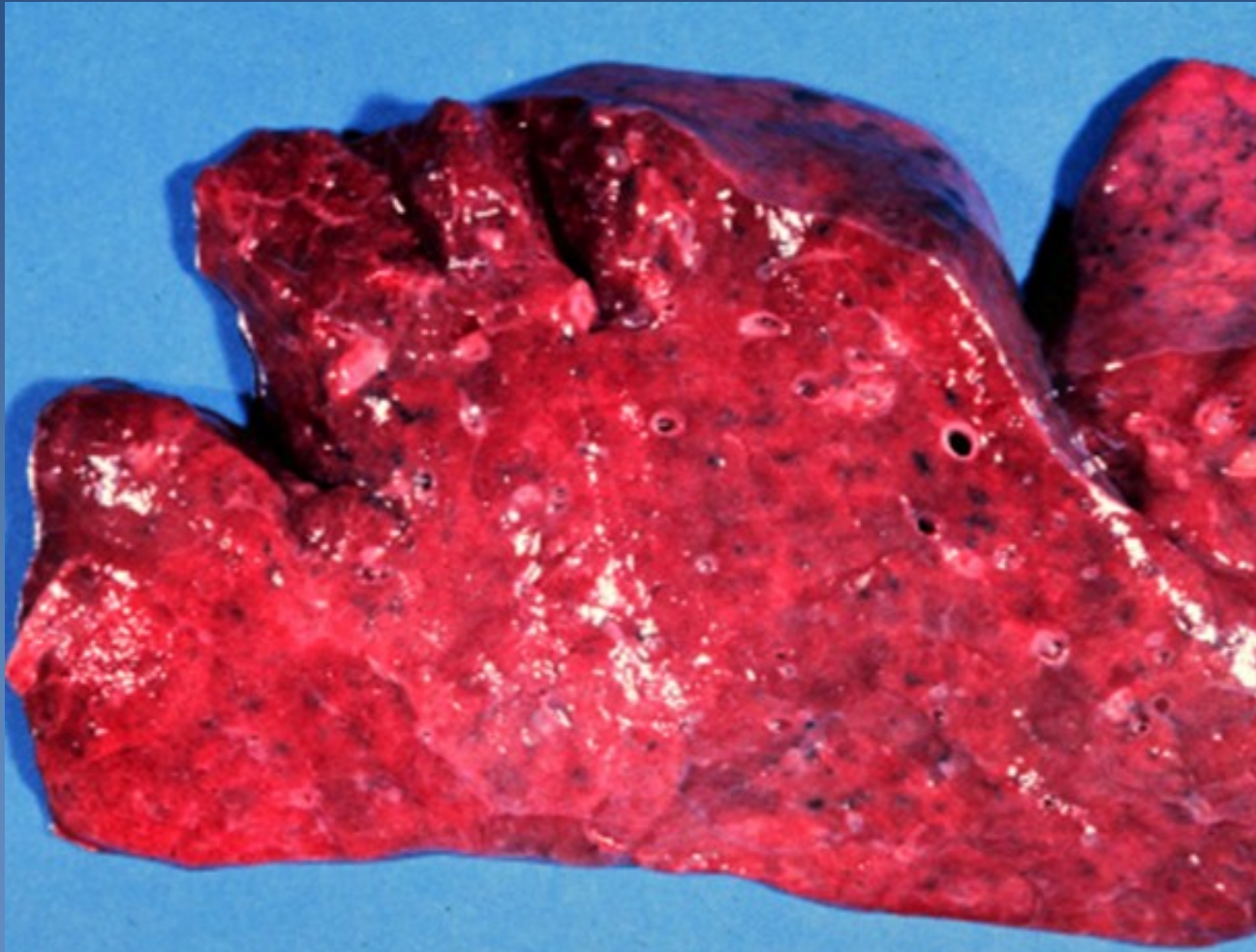
## **x** healing:

⇒ *ad integrum*

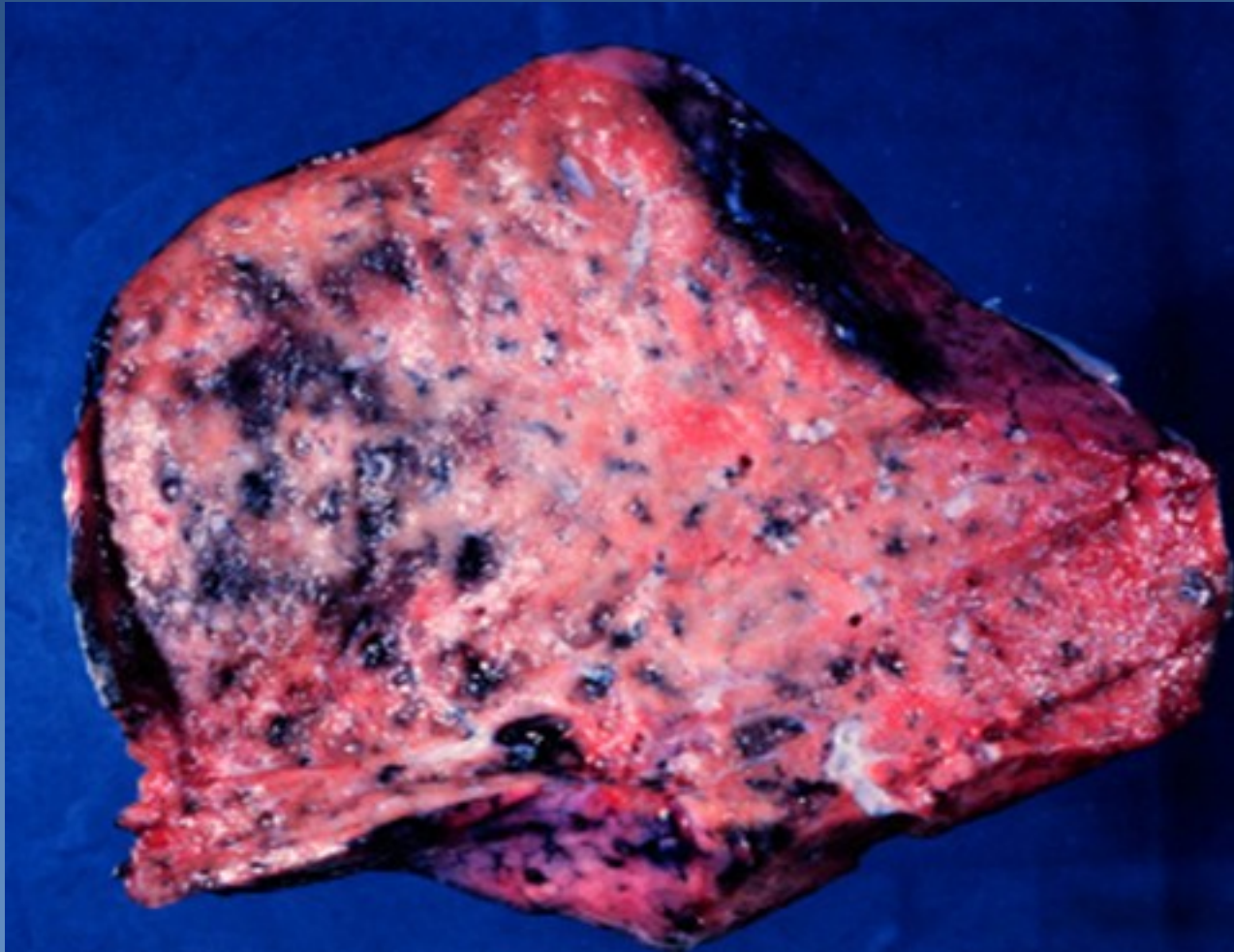
⇒ *complications:*

- empyema
- abscess
- carnification
- sepsis
- metastatic purulent inflammation
  - e.g. leptomeningitis, pericarditis, endocarditis...

# ***Lobar pneumonia, red hepatization***

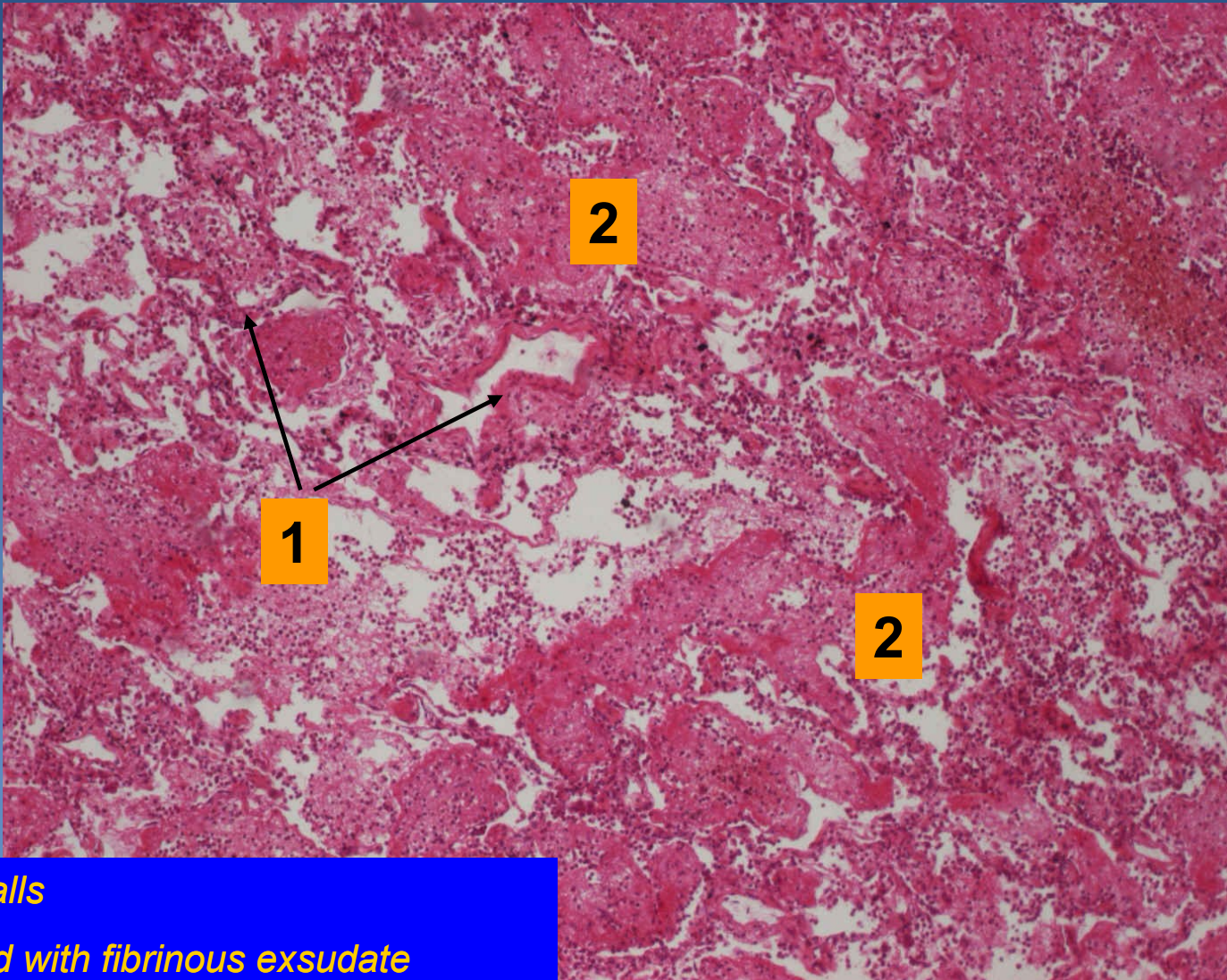


# *Lobar pneumonia, grey hepatization*





# *Lobar pneumonia*

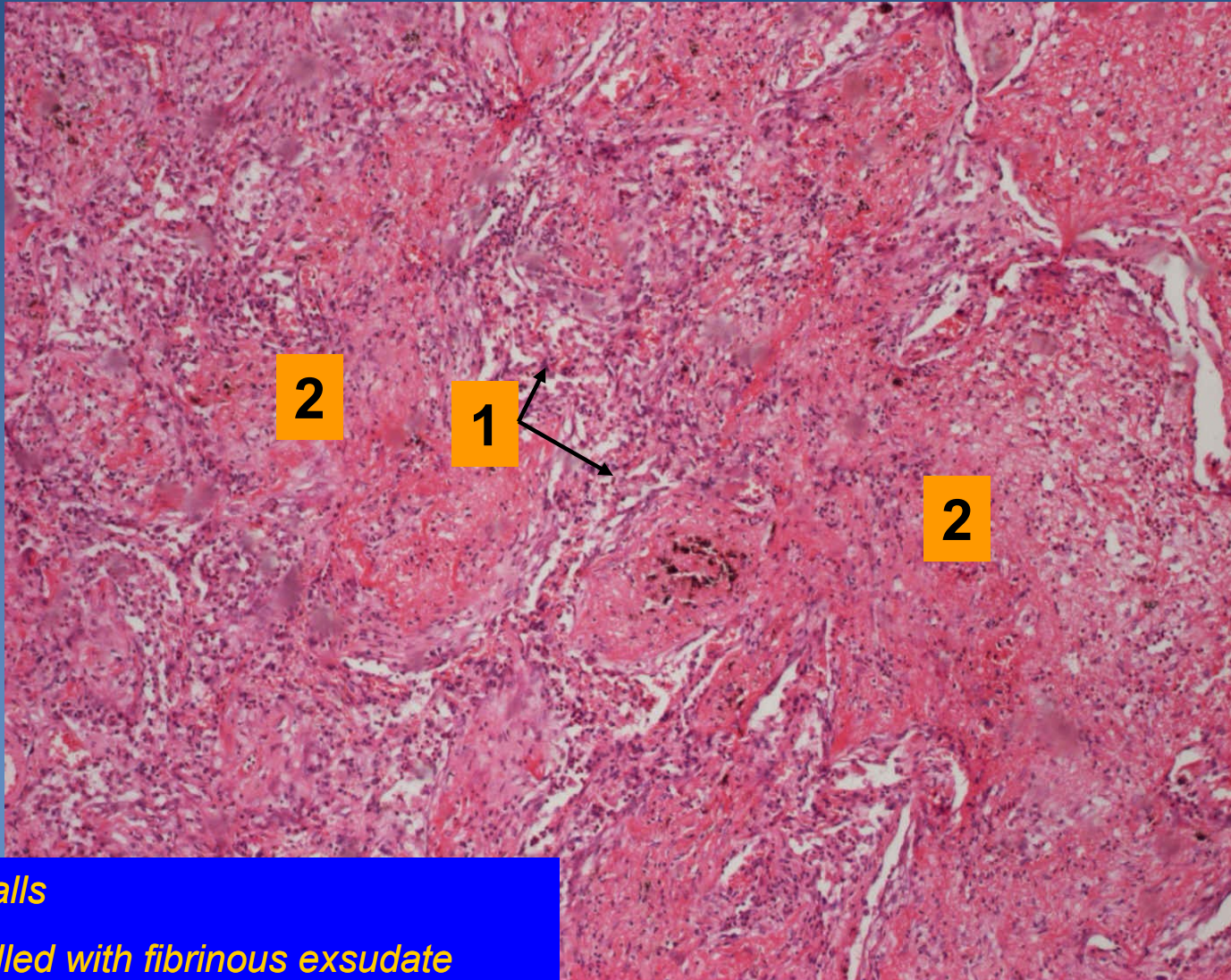


*1. Alveolar walls*

*2. Alveoli filled with fibrinous exudate*



# *Lobar pneumonia*

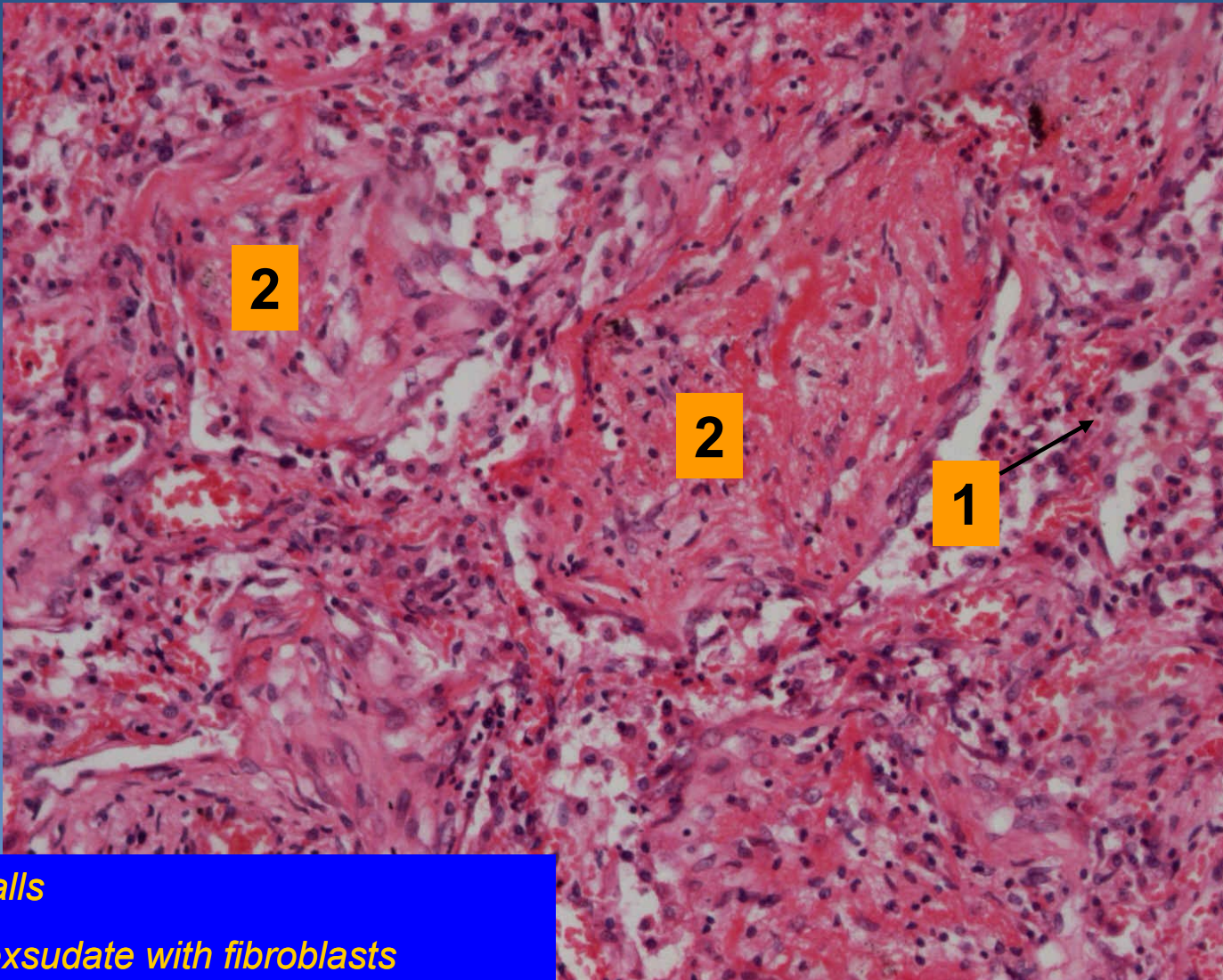


*1. Alveolar walls*

*2. Alveoli fulfilled with fibrinous exsudate*



# *Lobar pneumonia*



*1. Alveolar walls*

*2. Fibrinous exsudate with fibroblasts*

# Bronchopneumonia



- ✗ superficial type of pneumonia characterized by multiple foci of isolated, acute consolidation, affecting one or more pulmonary lobules
- ✗ inflammation spreads from bronchi
- ✗ aetiology:
  - ⇒ *streptococcus, staphylococcus, haemophilus, klebsiella*
  - ⇒ *legionella – micro:*
    - fibrinous purulent bronchopneumonia associated with fibrinous pleuritis
- ✗ possible secondary confluent inflammation, overlap patterns
- ✗ inflammatory complications:
  - ⇒ *pleuritis*
  - ⇒ *abscess*
  - ⇒ *sepsis*

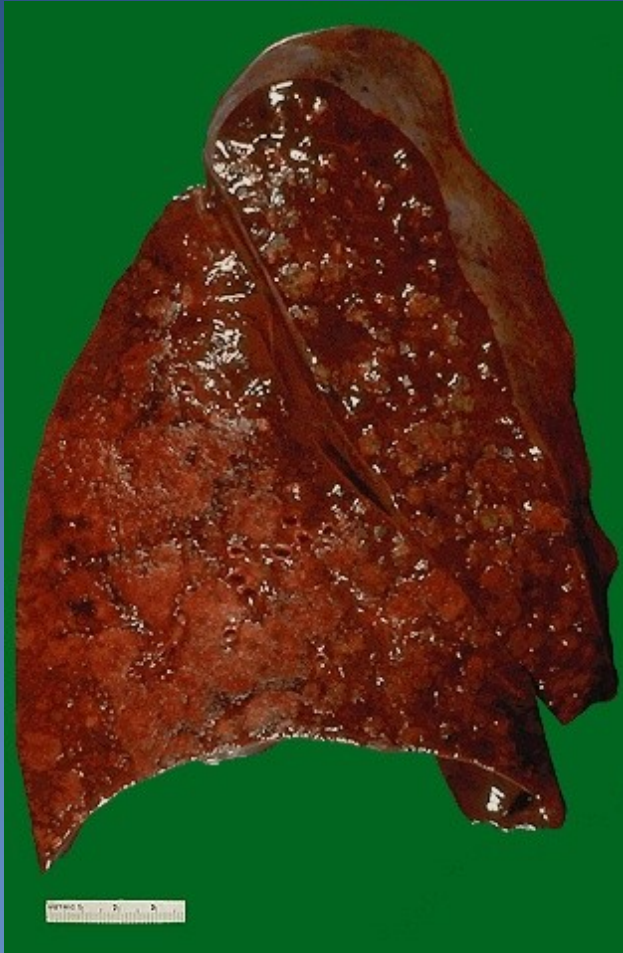# Bronchopneumonia



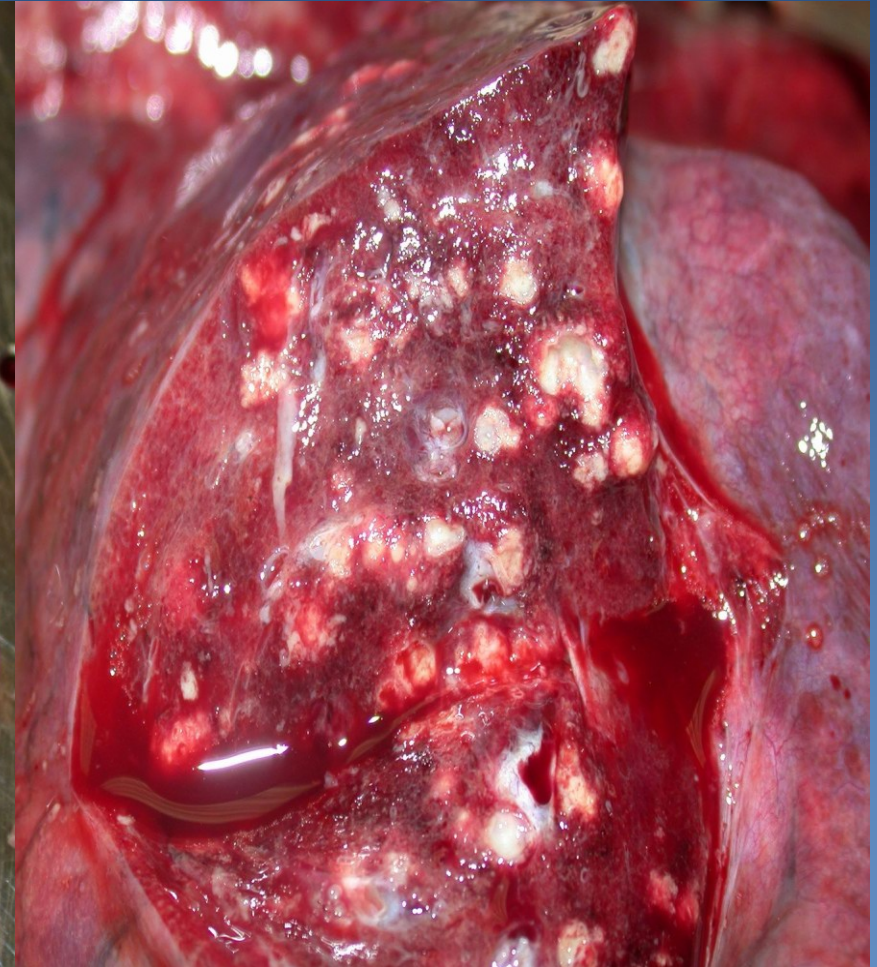
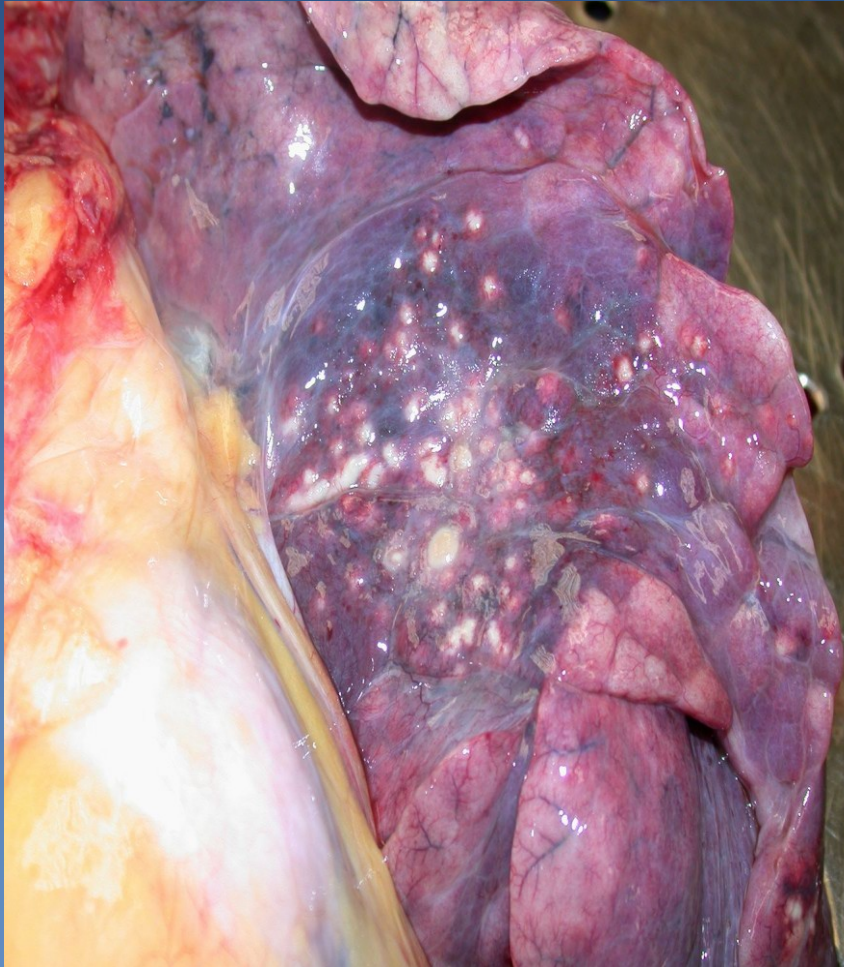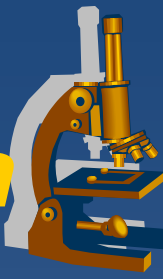- ✗ **Commonly secondary** — *prior viral pneumonia, in chronic lung diseases, debilitating diseases, immunologic defect, aspiration, coma ...*
  - ⇒ *various stages of inflammation in the same time*
- ✗ **Gross:**
  - ⇒ *oedema, hyperemic tissue with small grey-yellow foci*
- ✗ **Micro:**
  - ⇒ *types of exsudate:*
    - serous
    - suppurative (purulent) +/- fibrinous
  - ⇒ ***abscessing form*** — *suppurative destruction of alveolar walls*



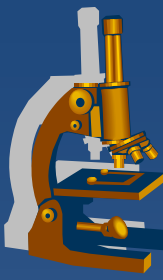
# *Bronchopneumonia*



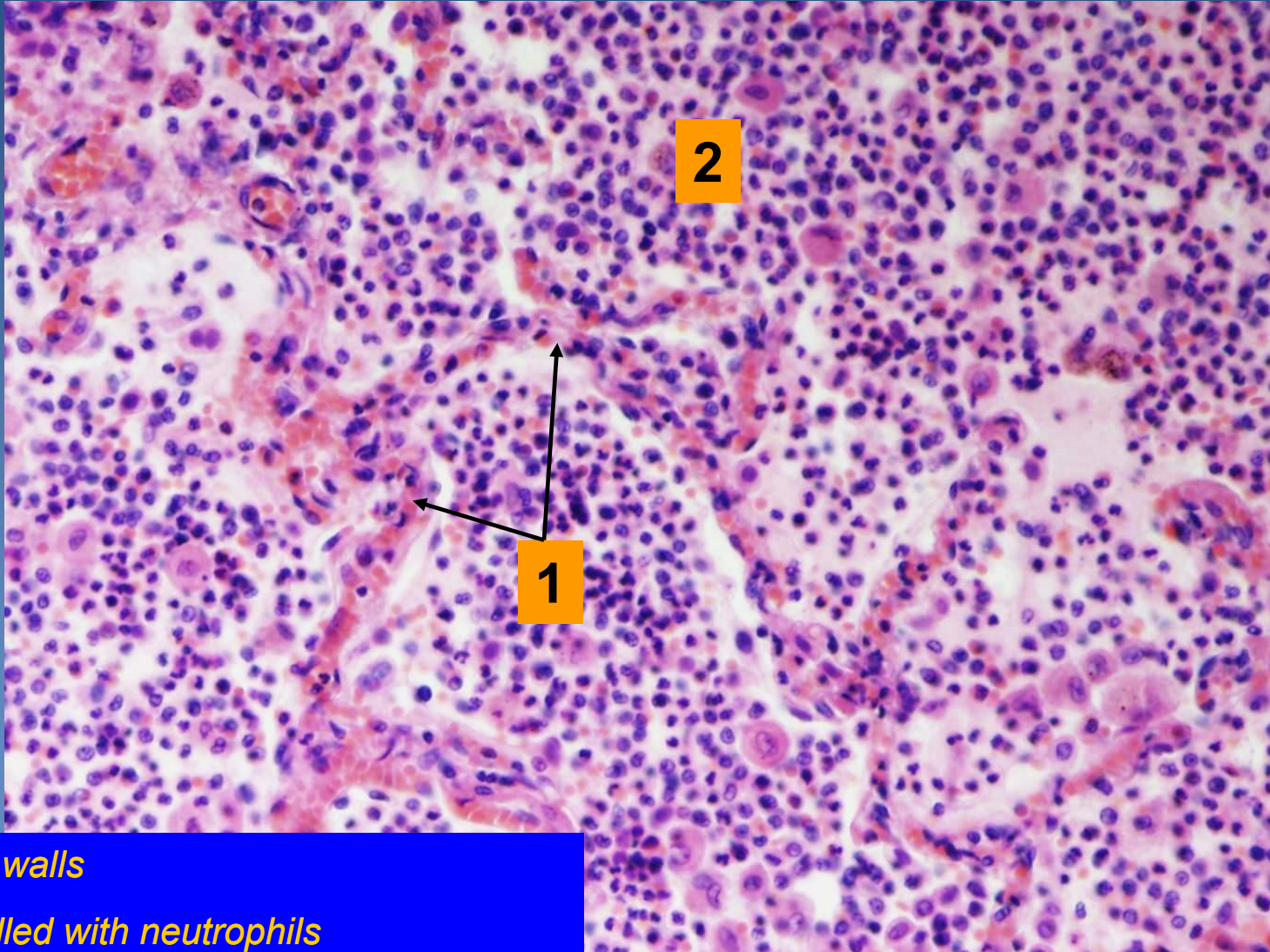
# ***Abscessing bronchopneumonia***







# *Purulent bronchopneumonia*

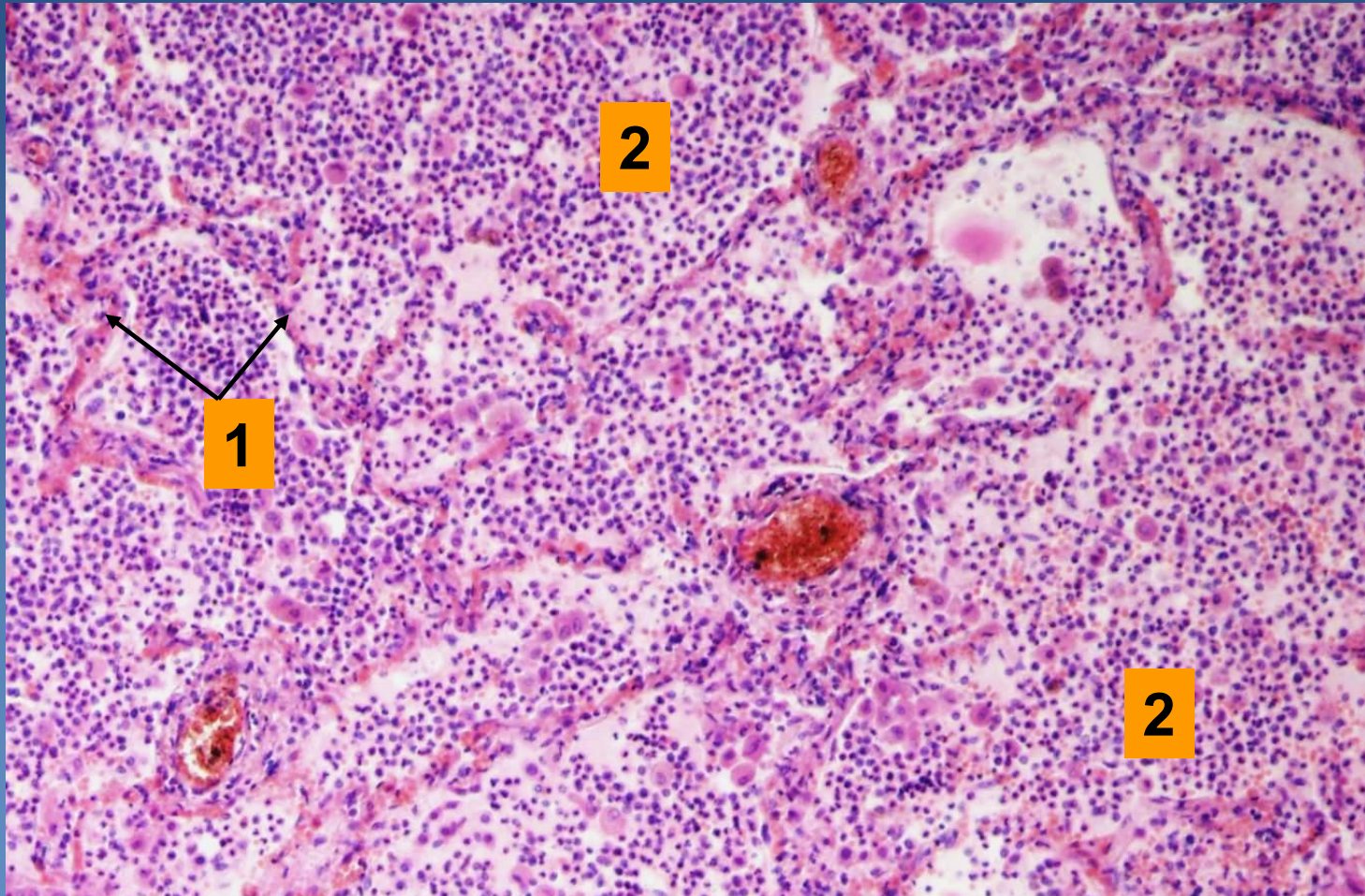


*1. Alveolar walls*

*2. Alveoli filled with neutrophils*



# *Abscessing bronchopneumonia*



*1. Alveolar walls*

*2. Abscess with destruction of alveolar walls*

# *Infectious interstitial pneumonia*



## **x** Etiology:

- ⇒ *viruses (incl. in COVID-19, rubeola, varicella)*
- ⇒ *mycoplasma, chlamydia, coxiella, etc.*
- ⇒ *pneumocystis*

## **x** Symptoms:

- ⇒ *fever, dyspnoea, dry cough, auscultation may be normal (empty alveoli), x massive changes on X-ray*

## **x** Healing:

- ⇒ *ad integrum*
- ⇒ *progression incl. ARDS*
- ⇒ *secondary bacterial pneumonia*
- ⇒ *cryptogenic organizing pneumonia possible*

# ***Infectious interstitial pneumonia***



**x Gross:** focal / confluent, red-blue, congested, usually no pleuritis

**x Micro:**

⇒ ***1) common histological features:***

- oedema and dilatation of alveolar walls
- interstitium with mononuclear infiltrate (lymphocytes, macrophages, plasma cells)
- possible ARDS - „hyaline membranes“ formation
  - necrotic pneumocytes and fibrin
  - eosinophilic material lining the lumen of alveoli

# *Infectious interstitial pneumonia*



## ⇒ 2) *inclusion pneumonia:*

- typical inclusions and cytopathologic changes of pneumocytes
- **CMV:**
  - large pneumocytes with basophilic intranuclear inclusions
- **Varicella, adenovirus:**
  - intranuclear inclusions
- **Measles:**
  - giant cell pneumonia
  - multinucleated cells in alveoli and bronchioli (Warthin-Finkeldey cells)
- **Pneumocystis pneumonia**



# *Covid -19 in the lungs*



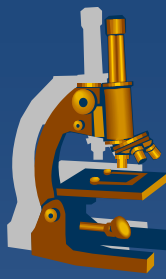
- ✘ General appearance of interstitial viral pneumonia
- ✘ Pathogenesis
  - ⇒ *Cytopathic viral effect on mucosa + cilia damage*
  - ⇒ *Surface S protein binding on ACE2 receptor*
- ✘ Vasculopathy of the alveolocapillary membrane, microangiopathy + thrombosis
- ✘ Complications: ARDS, septic shock, secondary bacterial superinfection

# ***COVID-19 lung pathology***

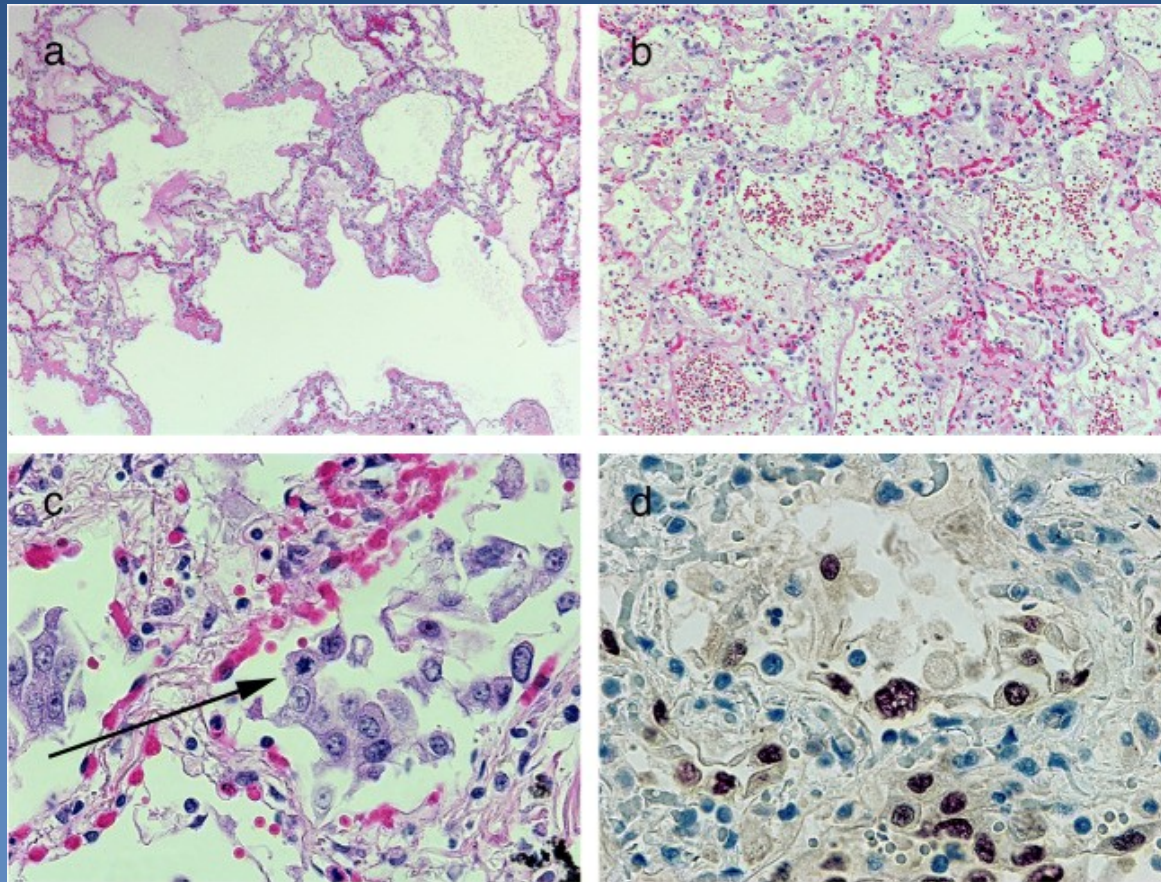
---



- ✗ Interstitial pneumonia w. lymphocytic infiltration
- ✗ intracellular viral particles incl. in pneumocytes
- ✗ Giant/hyperplastic pneumocytes
- ✗ Diffuse alveolar damage – DAD/ARDS
  
- ✗ Vascular changes incl. stasis of inflammatory cells, fibrinoid necrosis, microthrombi, deposition of intraalveolar fibrin

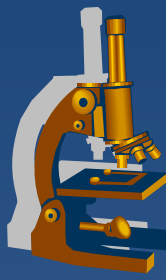


# COVID-19 lung pathology

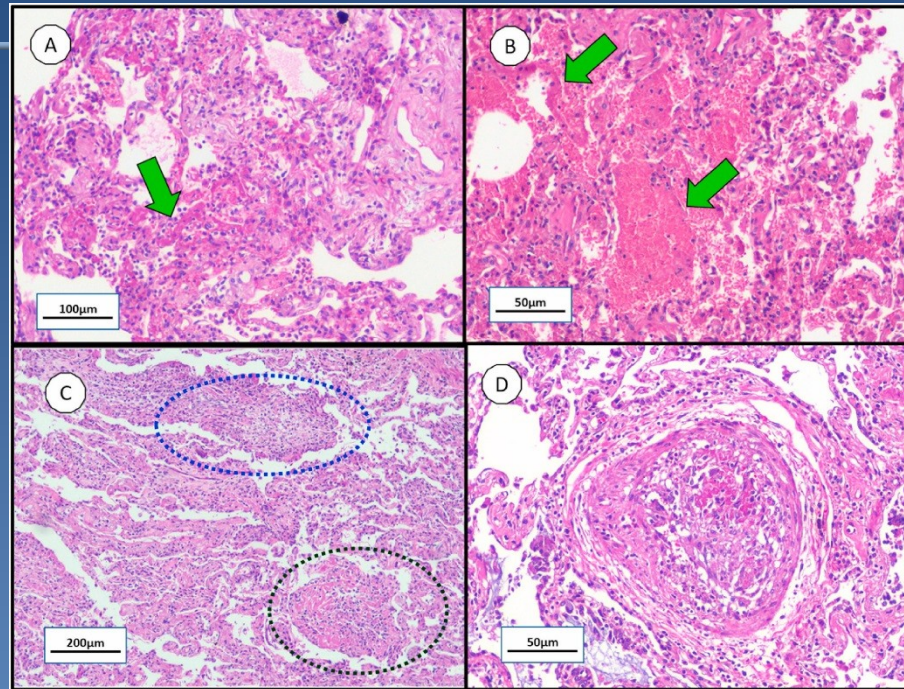


PMC full text: [Int J Legal Med. 2020; 134\(4\): 1285-1290.](#)  
Published online 2020 Jun 5. doi: [10.1007/s00414-020-02319-8](#)

DAD, oedema, haemorrhage,  
fibrin deposition, TTF-1+ atypical  
pneumocytes



# *Covid -19 in the lungs*



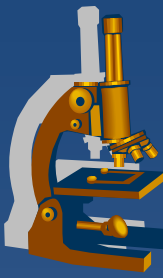
copy

- ✦ **Histopathological findings in COVID-19 lungs:** the virus-induced lung injury with temporal heterogeneity: **A** - alveolar hyaline membrane (green arrow); **B** - alveolar-capillary barrier injury with hemorrhage (green arrows); **C** - acute fibrinous organizing pneumonia (dark blue circle) and organizing pneumonia (dark green circle); and **D** - pulmonary intravascular thrombotic events.

# **COVID-19**

## ***Cell virus-induced changes***

---

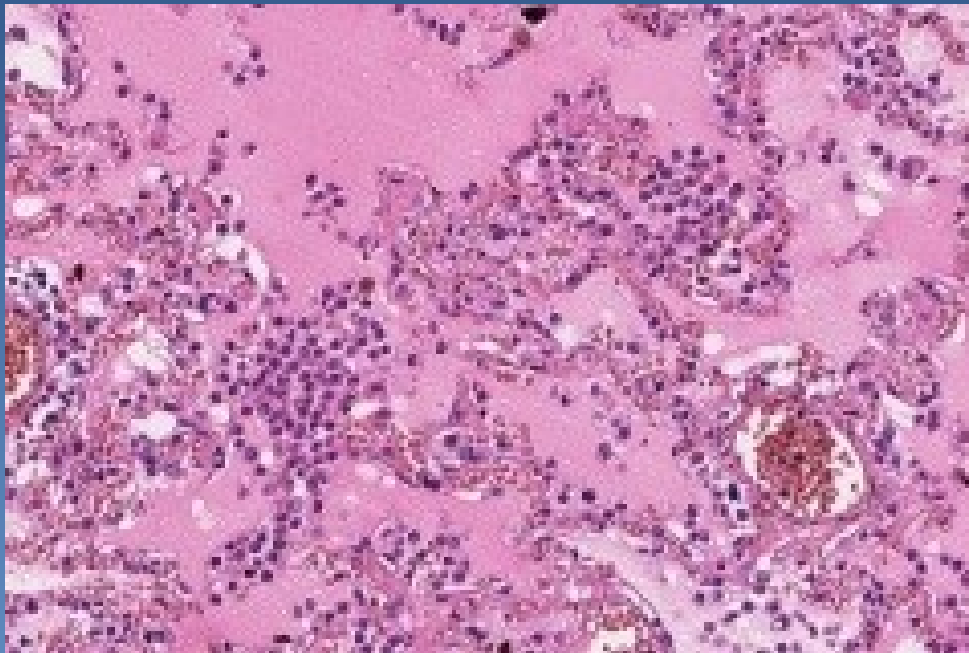


- ✗ Multinucleated enlarged pneumocytes (or other cells incl. endothelial - syncytia) with large nuclei, prominent nucleoli in alveolar spaces and other tissues
- ✗ Intranuclear inclusions

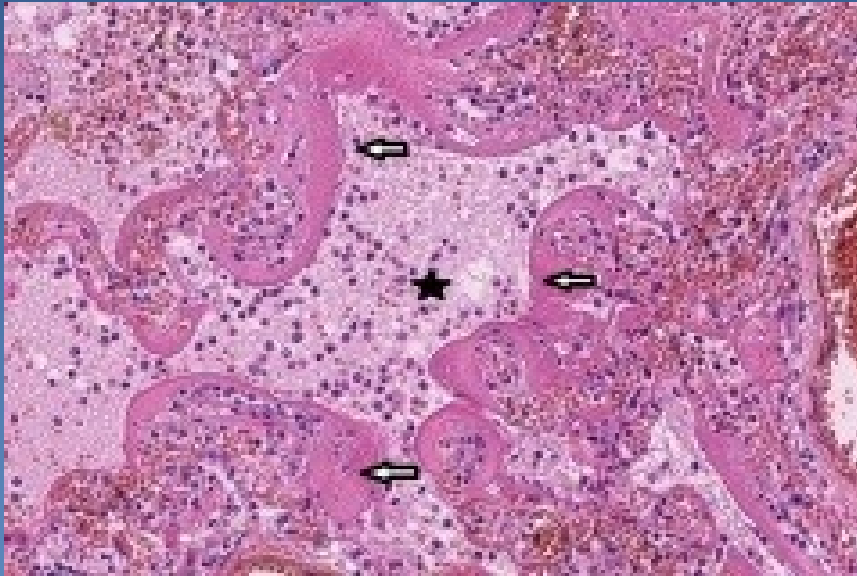


# *Acute capillaritis/alveolitis*

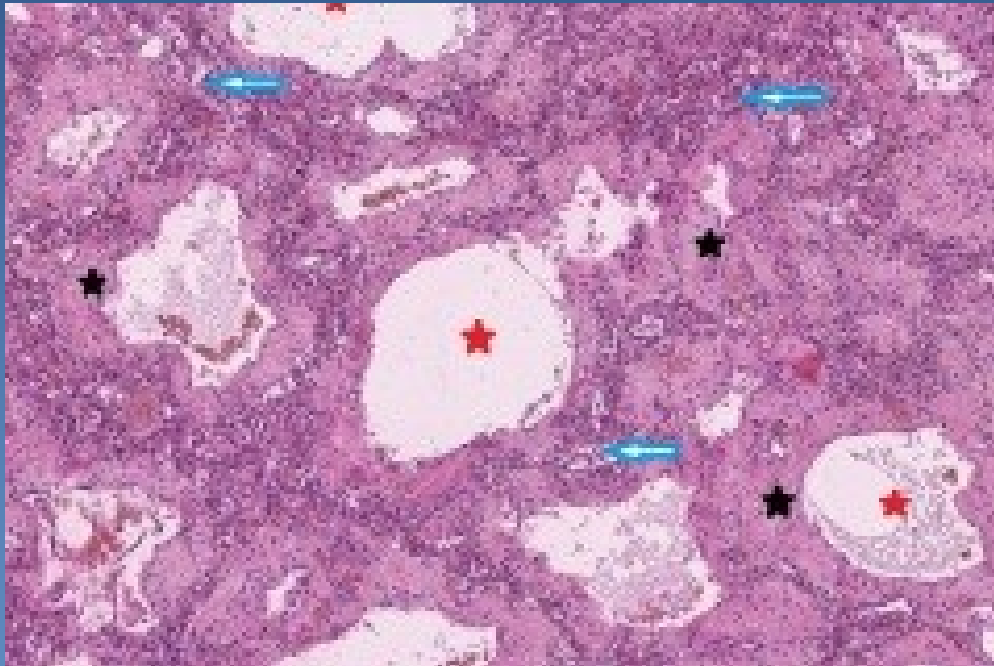
---



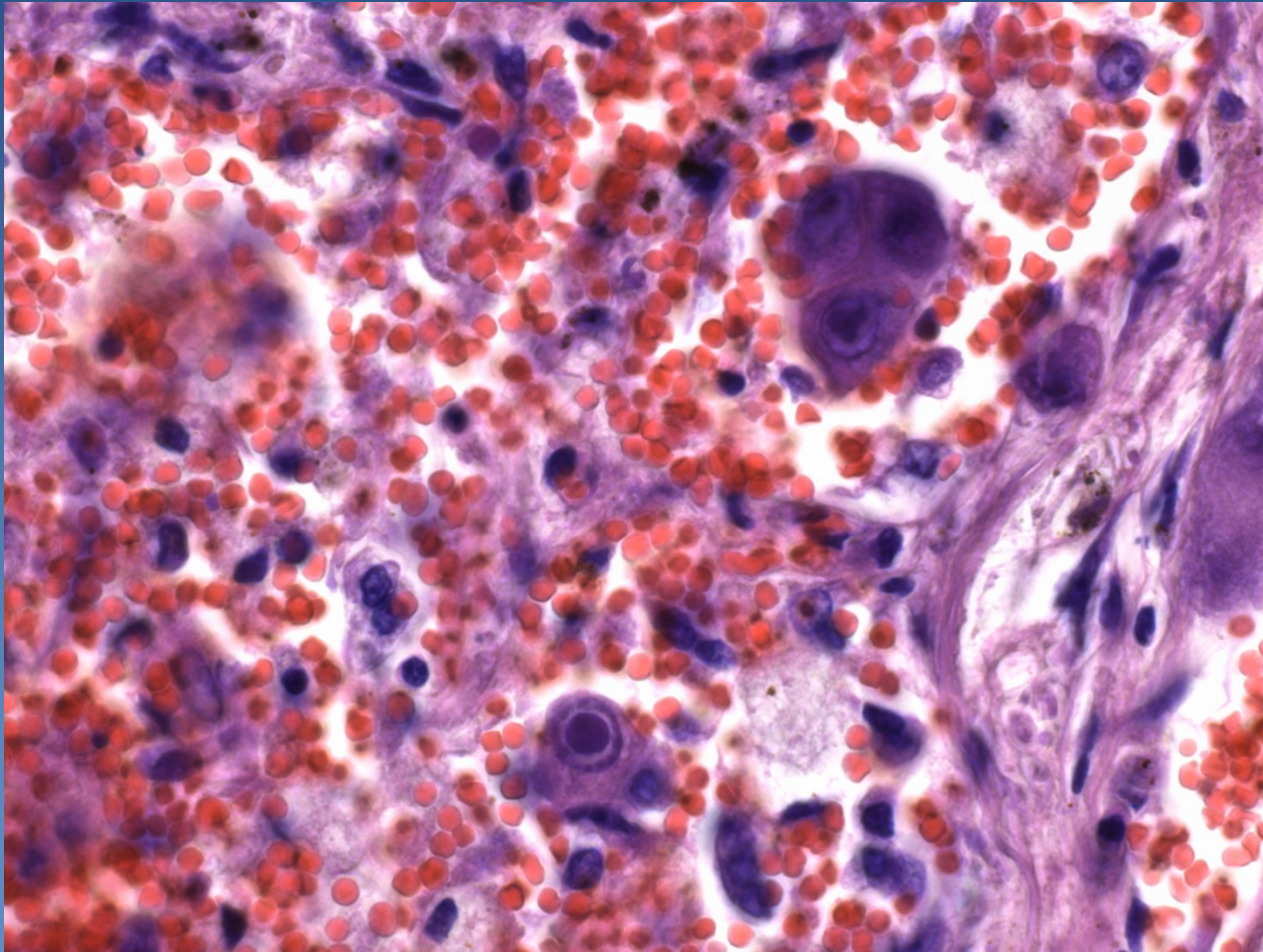
# *DAD - 14th day*



# *Chronic DAD – lung fibrosis*



# *CMV pneumonia*





# *Pneumocystis pneumonia*



## x etiology:

⇒ *Pneumocystis jirovecii*

(opportunistic fungal infection, immunocompromised patients)

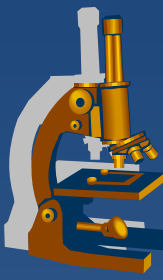
## x Micro:

⇒ *widened alveolar septa, intraalveolar bubbly eosinophilic material:*

- pneumocystis capsules

⇒ *special histological stains:*

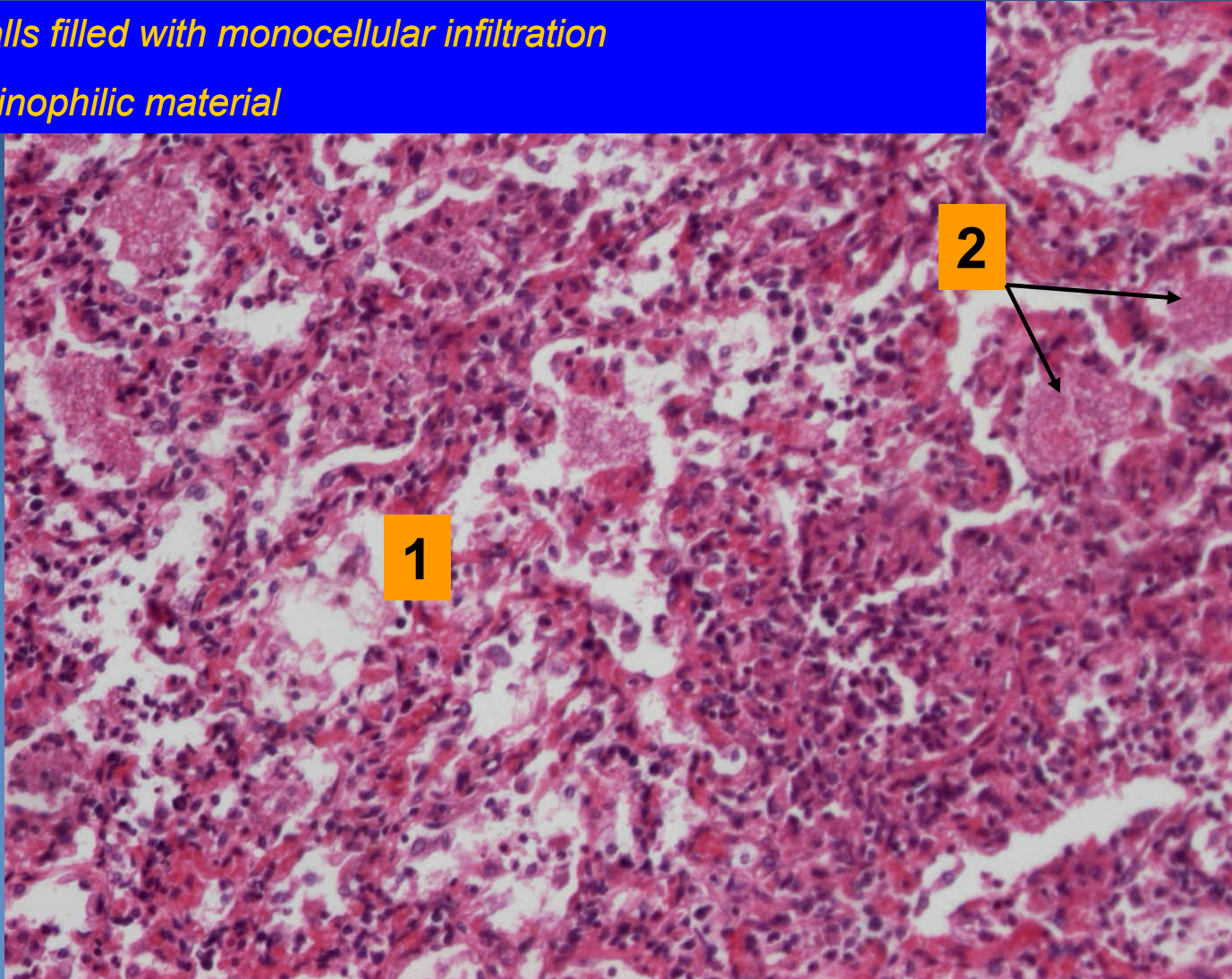
- Grocott silver impregnation (black)
- Giemsa (blue)
- PAS



# *Pneumocystis pneumonia*

1. Alveolar walls filled with monocellular infiltration

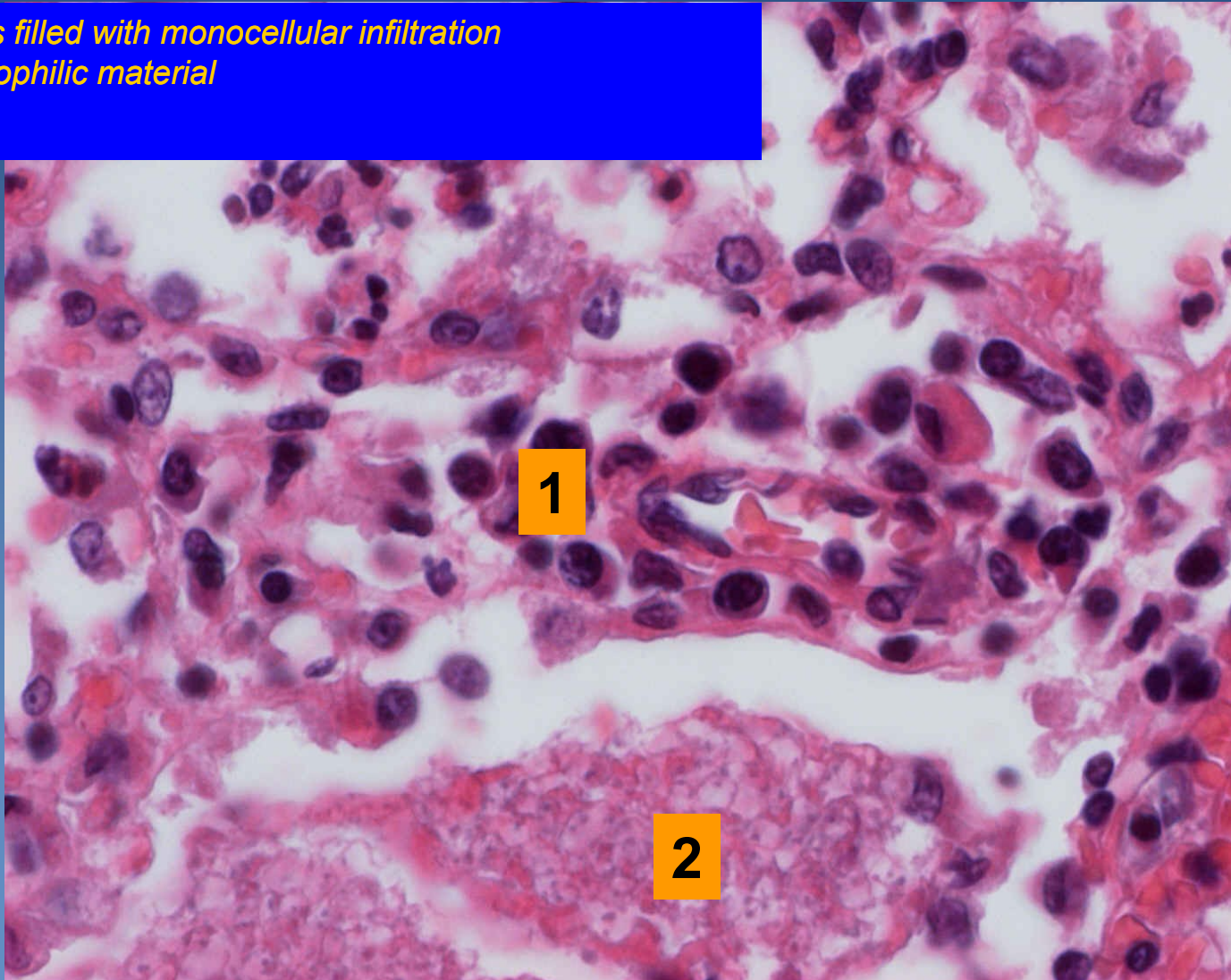
2. Bubbly eosinophilic material



# *Pneumocystis pneumonia*

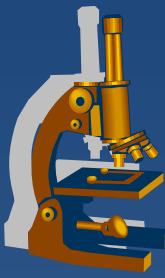


1. Alveolar walls filled with mononuclear infiltration
2. Bubbly eosinophilic material





# Interstitial lung diseases



## x Form:

⇒ **acute alveolar damage** (ARDS, radiation pneumonitis, diffuse intrapulmonary haemorrhage – Goodpasture' sy)

⇒ **chronic interstitial lung disease**

- **Fibrosing**

- Idiopathic pulmonary fibrosis (Usual interstitial pneumonia)
- Nonspecific interstitial pneumonia
- Cryptogenic organizing pneumonia
- Associated w. connective tissue diseases (rheumatoid arthritis)
- Drug reaction
- Pneumoconioses

- **Granulomatous** (sarcoidosis, hypersensitivity pneumonitis - extrinsic allergic alveolitis)

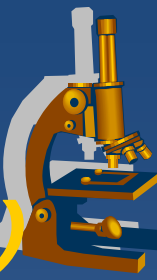
- **Eosinophilic**

- **Smoking related** (desquamative interstitial pneumonia etc.)

- **Other**

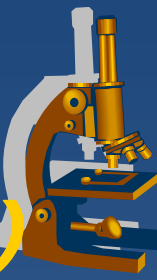


# ***Diffuse alveolar damage (Acute Respiratory Distress Syndrome)***



- × DAD (ARDS, RDS)
- × clinical:
  - ⇒ *progressive respiratory insufficiency associated with shortness of breath and hypoxia, high mortality*
- × Etiology:
  - ⇒ **Primary ARDS:**
    - lung inflammation/infection, aspiration of gastric content, mechanical trauma incl. chest contusion, fat embolism, near-drowning, ionizing radiation, inhaled irritants (smoke, chemicals),
  - ⇒ **Secondary ARDS:**
    - trauma (head) or sepsis
    - acute pancreatitis
    - renal insufficiency (uremia)
    - burns
    - hematologic conditions – DIC, multiple transfusions
    - chemical injury (heroin overdose, acetylsalicylates, ...)

# ***Diffuse alveolar damage (Acute Respiratory Distress Syndrome)***



## **x Gross:**

- ⇒ *heavy lung*
- ⇒ *dark red color*
- ⇒ *boggy*

## **x Micro:**

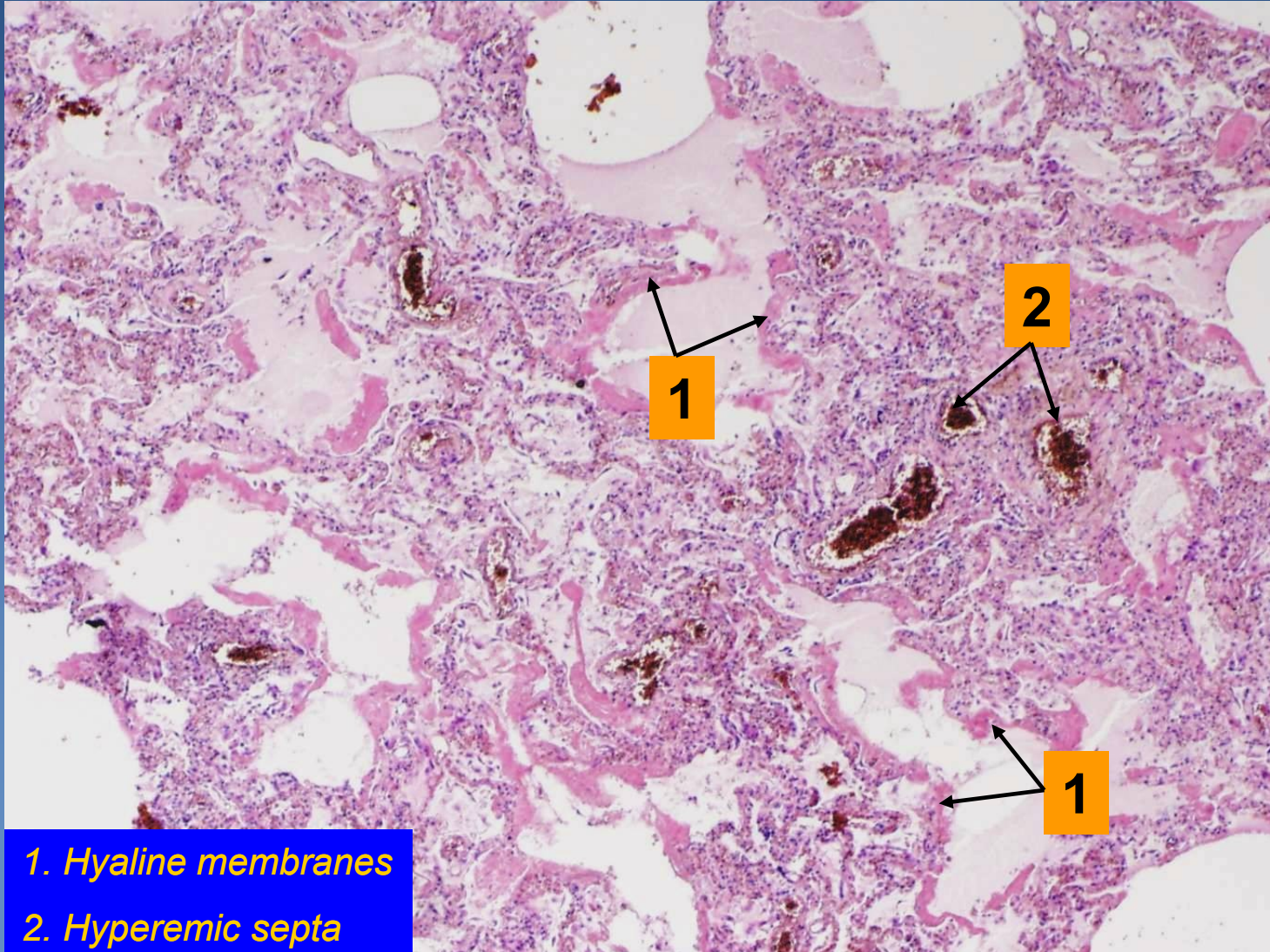
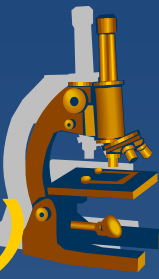
### ⇒ *exsudative phase:*

- capillary congestion, oedema, hyaline membranes formation within 48 hours

### ⇒ *proliferative phase:*

- epithelium regeneration (type II. pneumocytes)
- hyaline membranes ingested by macrophages
- proliferation of fibroblasts in alveolar walls -> pulmonary fibrosis possible

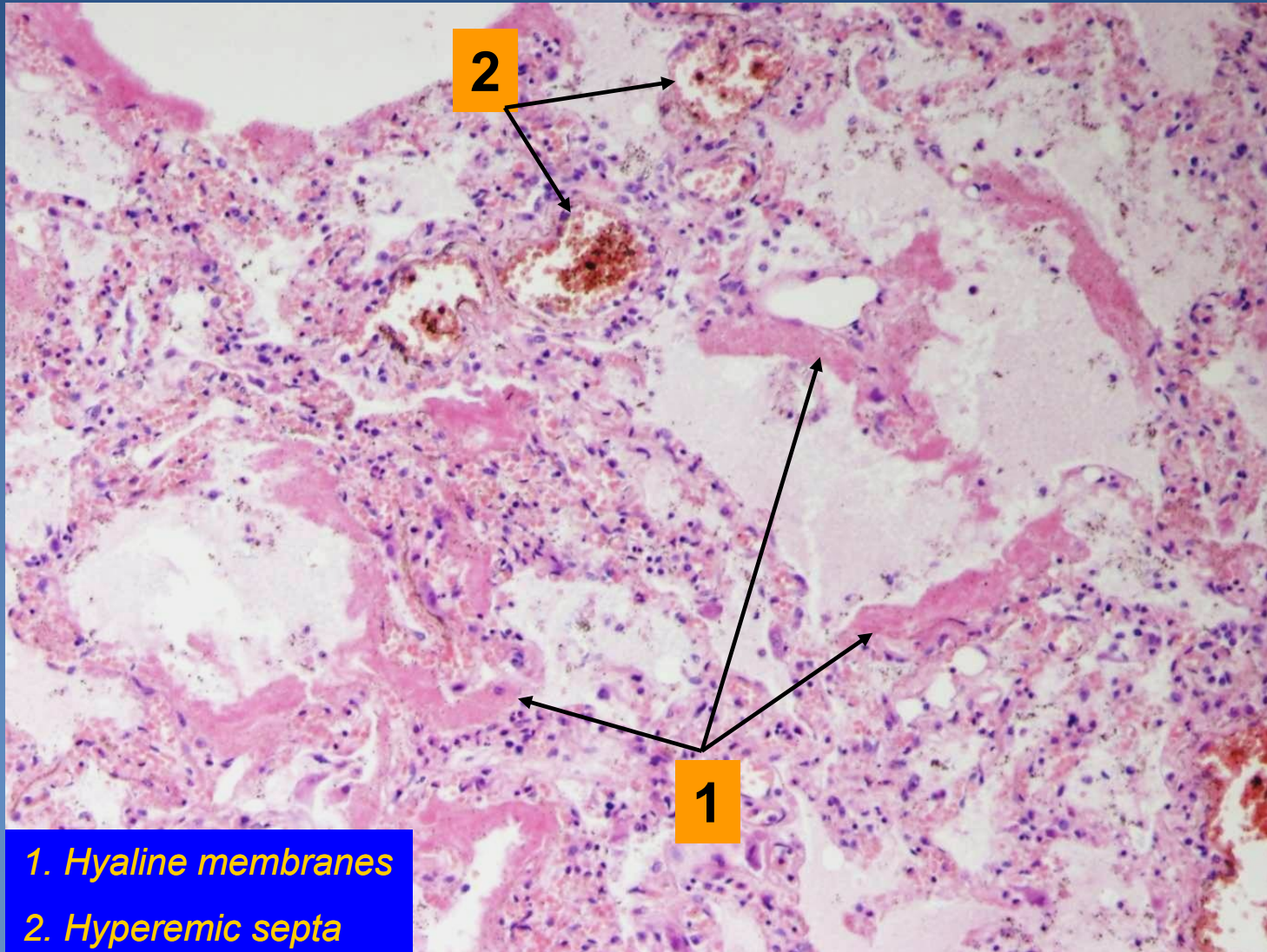
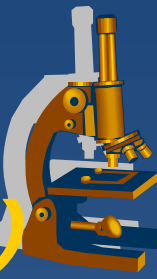
# *Diffuse alveolar damage (Acute Respiratory Distress Syndrome)*



1. Hyaline membranes
2. Hyperemic septa



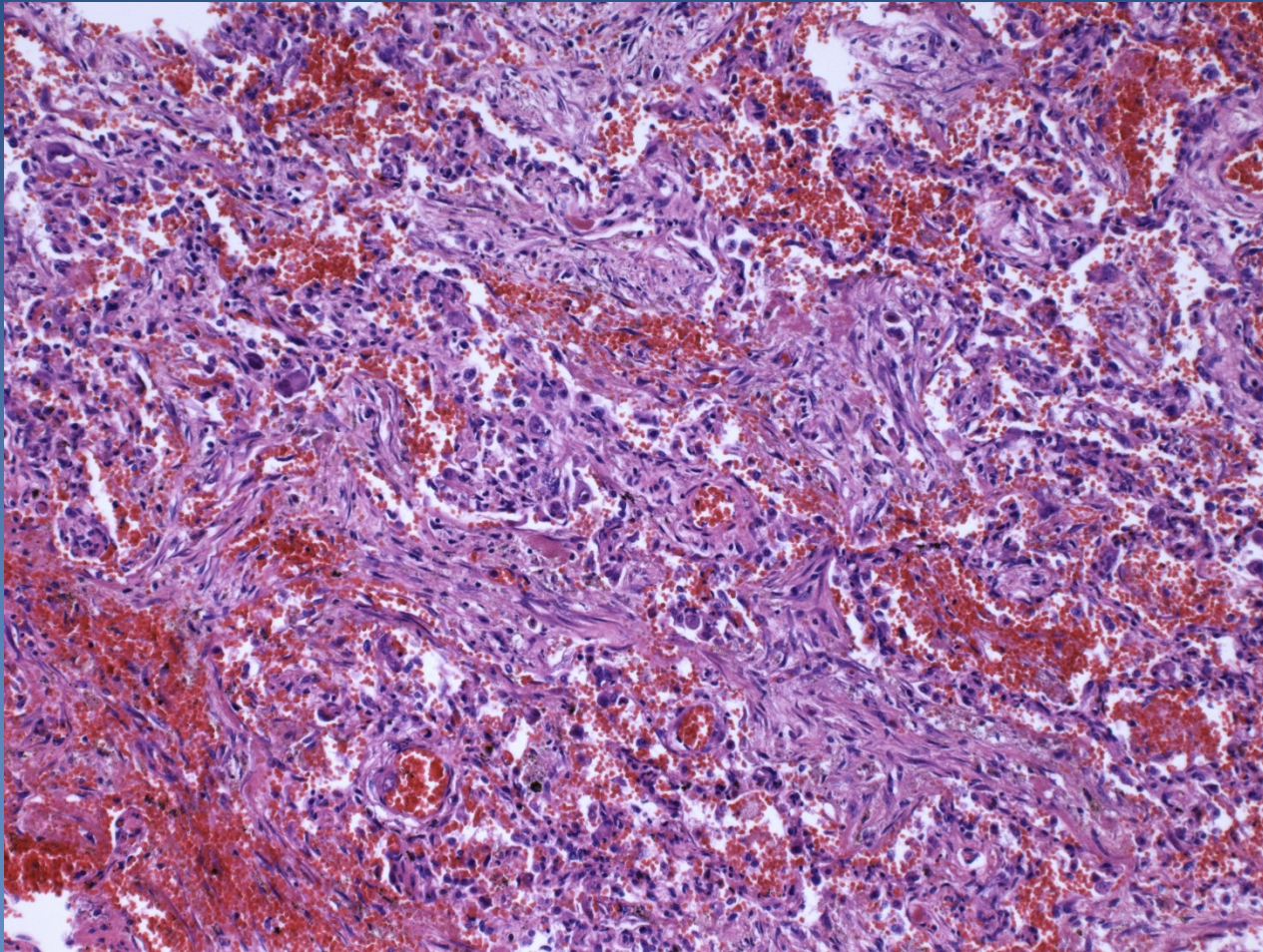
# *Diffuse alveolar damage (Acute Respiratory Distress Syndrome)*




- 1. Hyaline membranes
- 2. Hyperemic septa

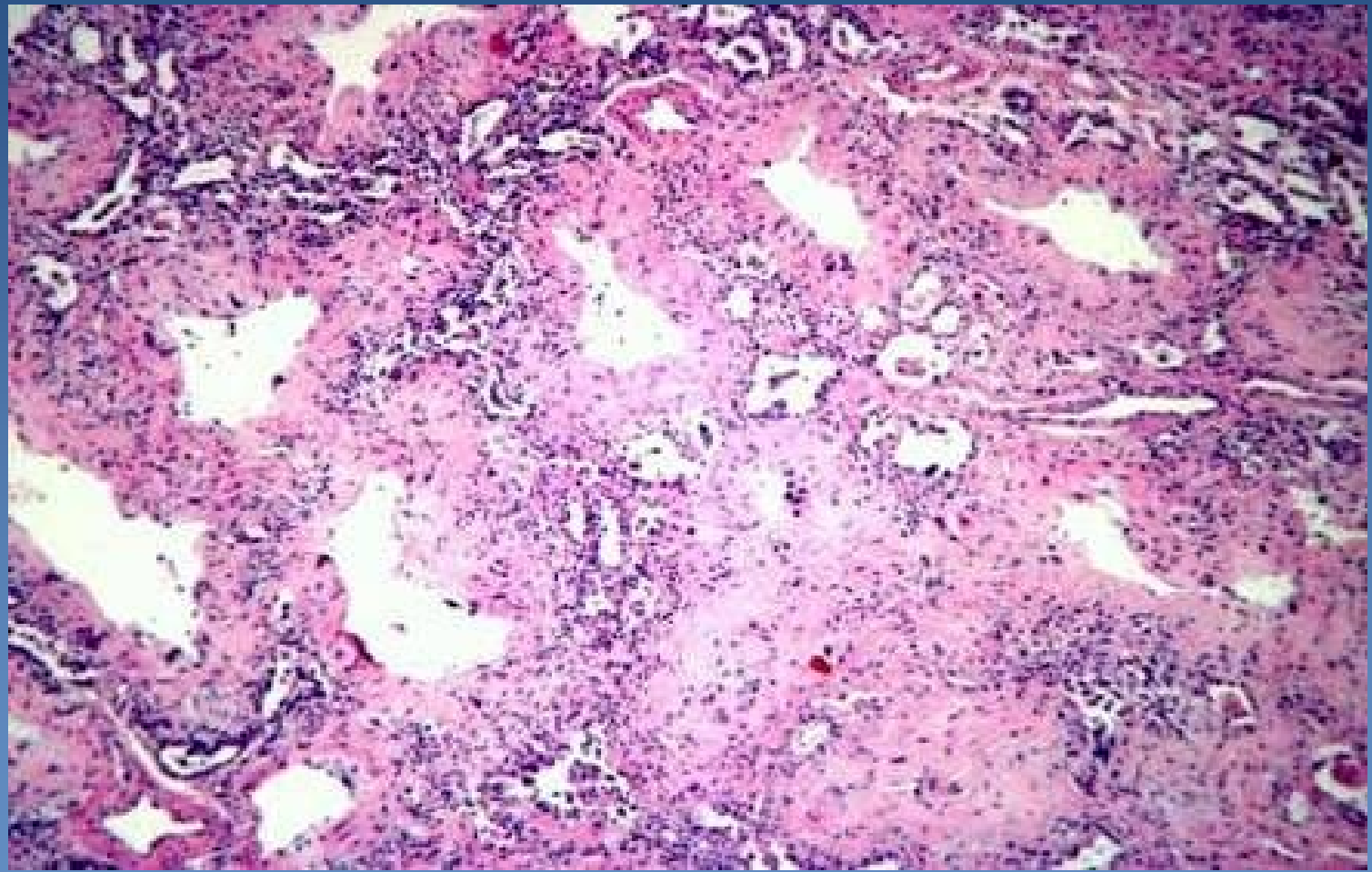


# ***CMV pneumonia - ARDS***





**6.3 DAD, proliferative phase - fibrotic stage – distinctly thickened interalveolar septa with a chronic inflammatory infiltrate.**



# *Idiopathic pulmonary fibrosis*



## Clinical-radiologic-pathologic diagnosis

---

- ✗ synonymic – cryptogenic fibrosing alveolitis
- ✗ histologic pattern of „usual interstitial pneumonia“ (UIP):
- ✗ Etiology: **abnormal epithelial repair – myo/fibroblastic proliferation**
  - intrinsic problem + exogenous factor (? occupational, smoking)
- ✗ **Dismal prognosis:** progressive dyspnoea, hypoxemia, lung failure in cca 3 yrs, therapy - lung transplantation only

# *Idiopathic pulmonary fibrosis*



✗ usual interstitial pneumonia“ (UIP):

⇒ *70% of all of idiopathic interstitial pneumonias*

⇒ *etiology:*

- in some connective tissue diseases or in association with abnormalities of serum proteins
- smoking, asbestosis
- unclear

⇒ *Micro:*

- subpleural and a paraseptal foci of fibroblasts/fibrosis and chronic inflammatory infiltrate, cystic spaces - honeycombing
- irregular distribution of histological features – temporal heterogeneity



# *Idiopathic pulmonary fibrosis*



## **x non-specific interstitial pneumonia (NSIP):**

⇒ *different histologic/clinical pattern*

⇒ *commonly women, without smoking association*

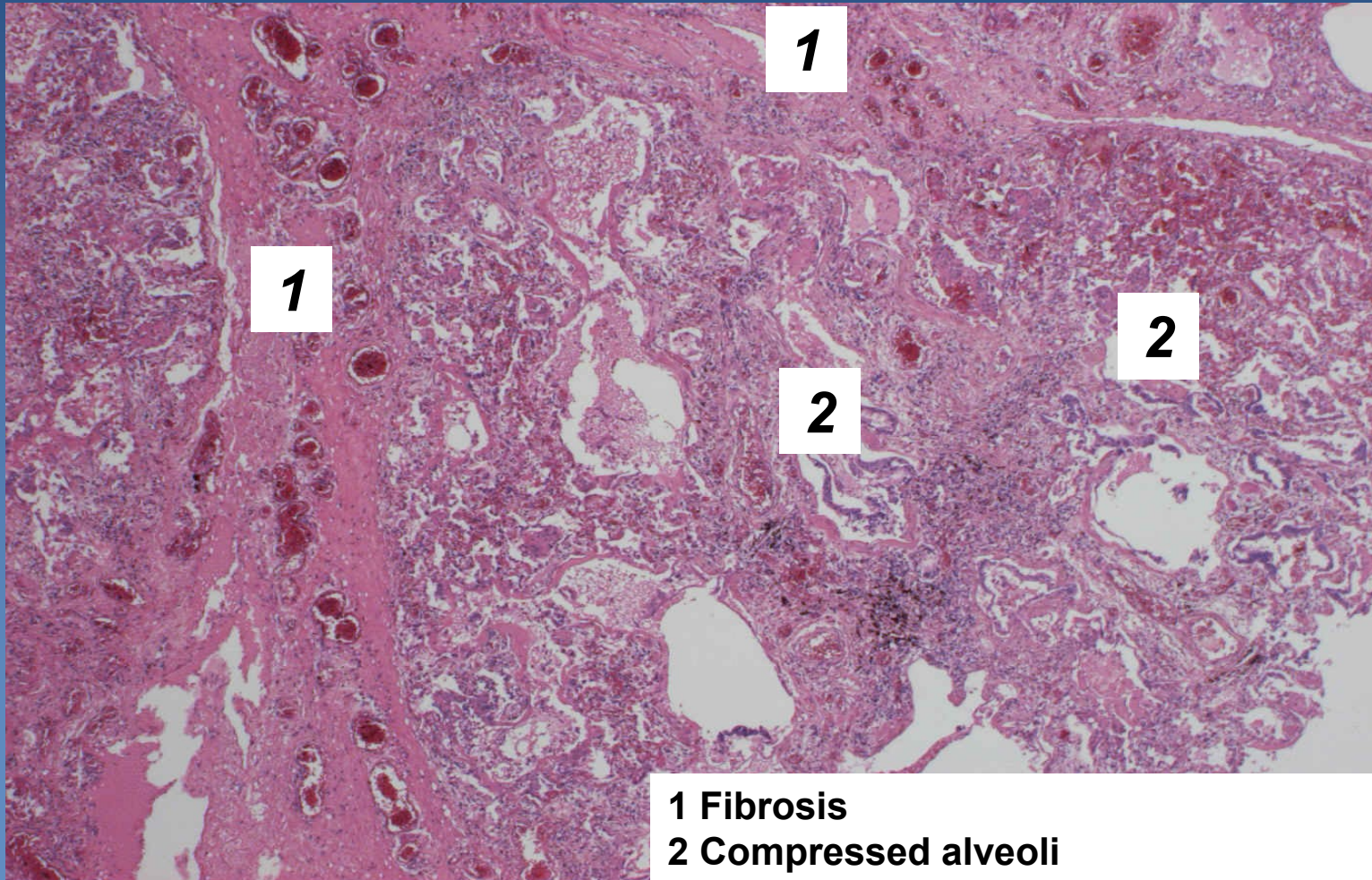
⇒ *better prognosis*

- treated with corticosteroids

⇒ **Micro:**

- chronic interstitial inflammation +/- fibrosis
- no honeycombing
- regular distribution of changes

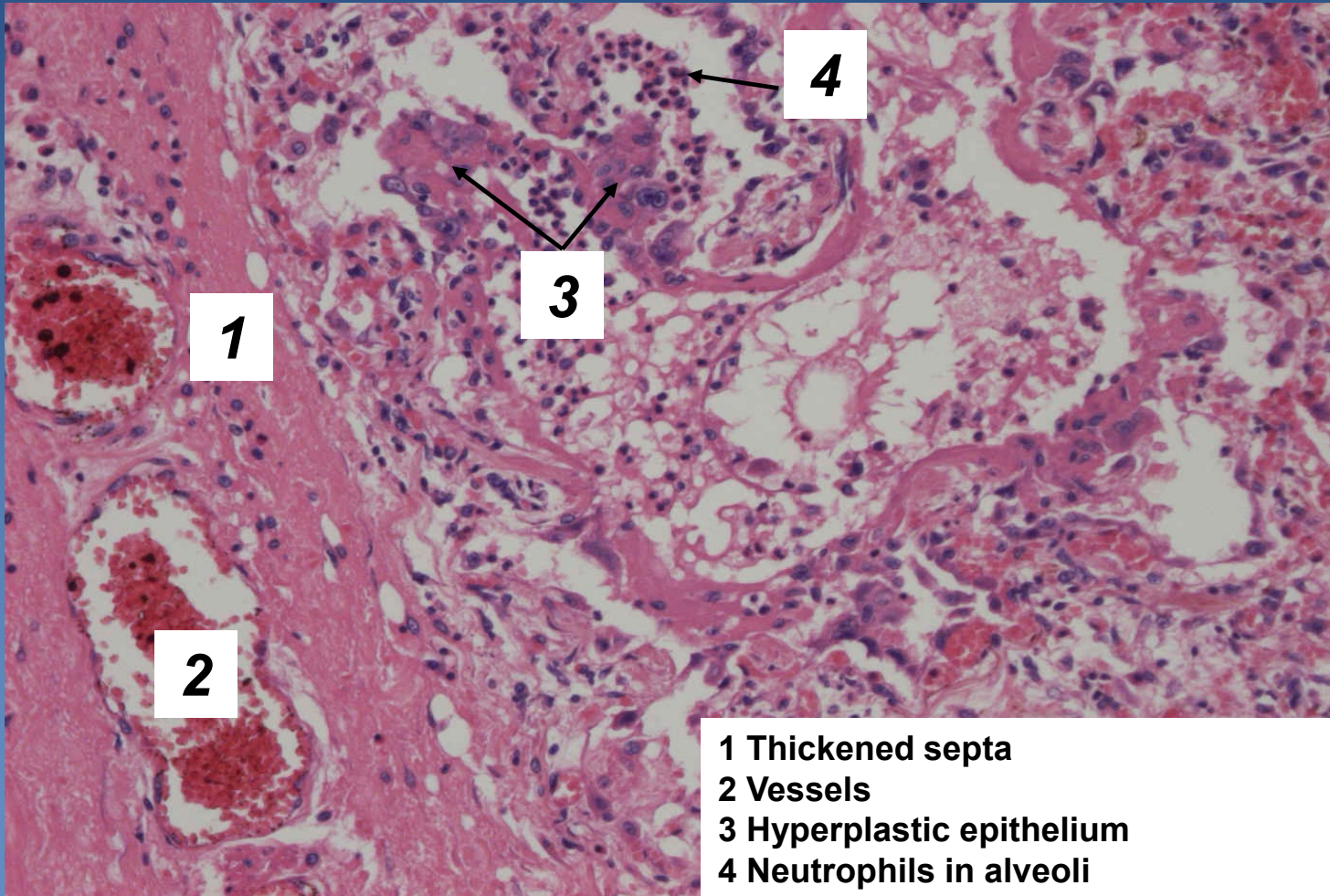
# *Usual interstitial pneumonia*



**1** Fibrosis  
**2** Compressed alveoli

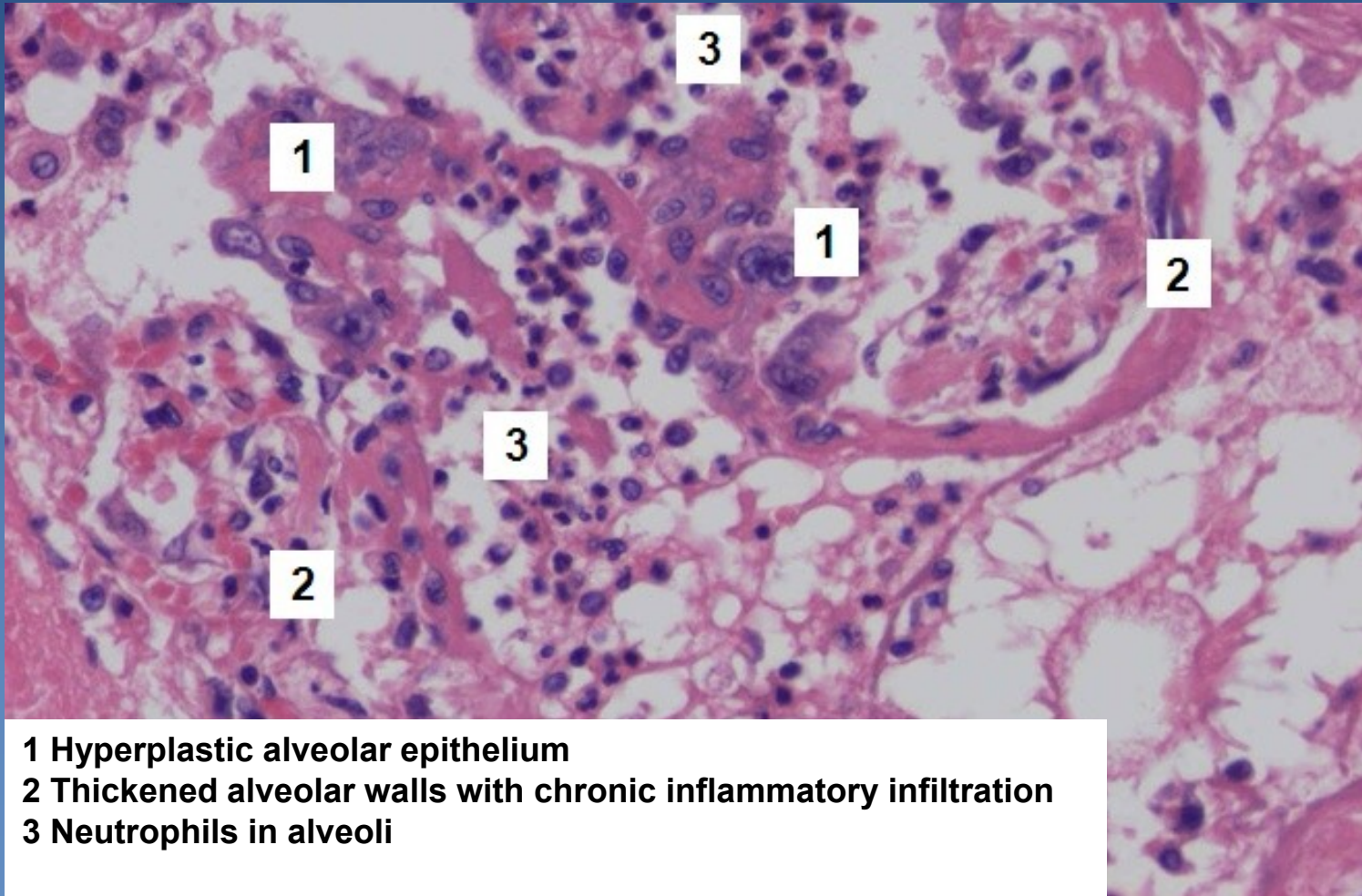


# *Usual interstitial pneumonia*



- 1 Thickened septa
- 2 Vessels
- 3 Hyperplastic epithelium
- 4 Neutrophils in alveoli

# *Usual interstitial pneumonia*



- 1 Hyperplastic alveolar epithelium
- 2 Thickened alveolar walls with chronic inflammatory infiltration
- 3 Neutrophils in alveoli



# Pneumoconiosis



- ✗ an occupational and restrictive lung disease caused by the inhalation of specific dust
- ✗ sequels: inert (simple), fibrous, allergic, neoplastic
- ✗ high fibrogenicity of cristalline silica dust and asbestos
- ✗ 3 basic types:
  - *coal-worker`s pneumoconiosis*
  - ⇒ *silicosis*
  - ⇒ *asbestosis*

# *Silicosis*



- ✘ Chronic progressive pneumoconiosis
- ✘ Silicene dioxide particles (0,2-2 $\mu$ m) toxic to macrophages – focal necrosis + release of fibrogenic factors - fibrosis
- ✘ X-ray – reticular fibrosis, nodules, diffuse fibrosis
- ✘ lung insufficiency
- ✘ cor pulmonale

# Silicosis



- × Gross (stages):

- ⇒ *reticular fibrosis*

- ⇒ *silicotic nodules*

- ⇒ *progressive massive fibrosis*

- × Micro:

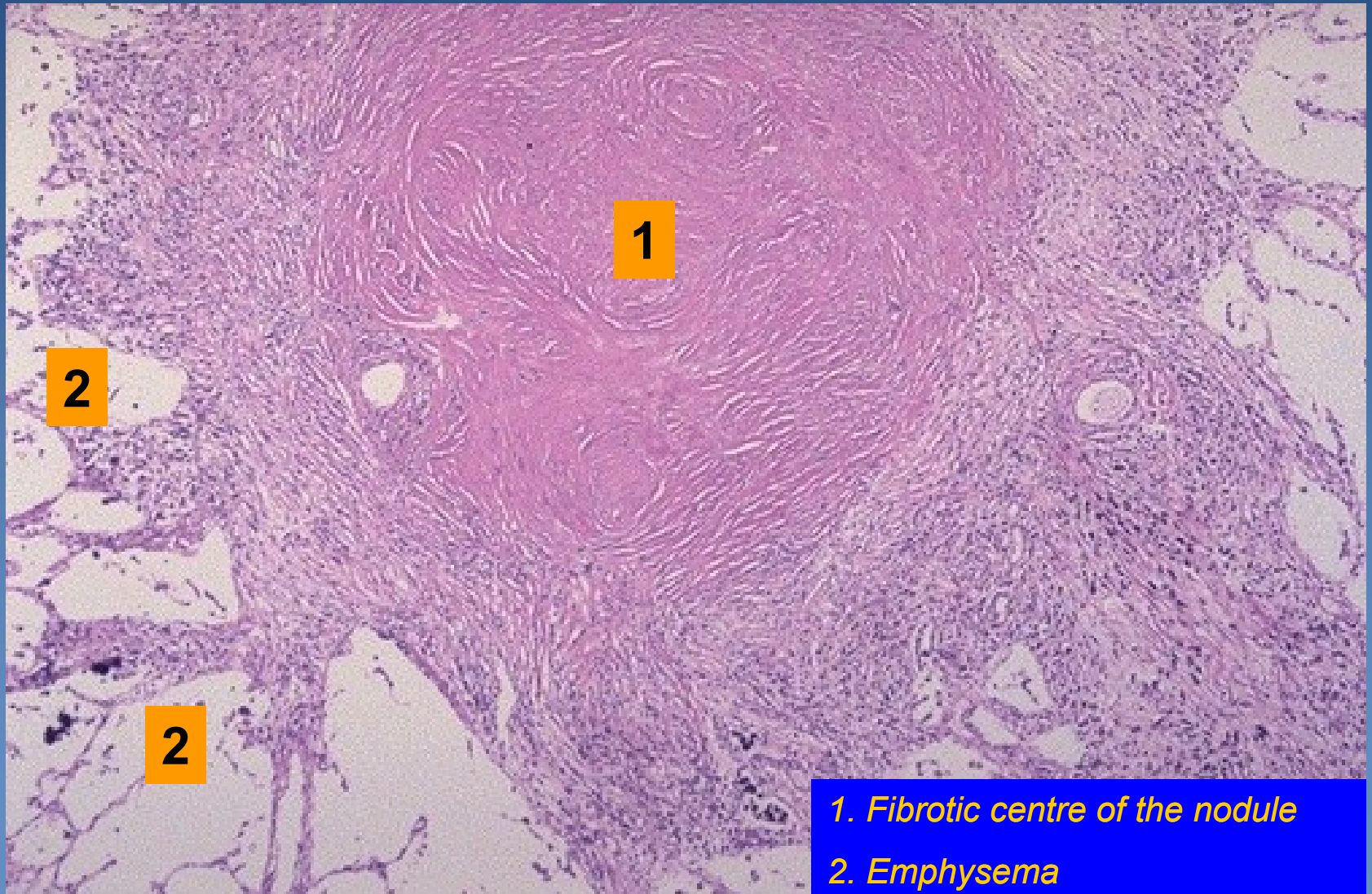
- ⇒ *nodules with concentric arrangement of hyalinized fibers and necrosis*

- ⇒ *anthracophages in the periphery of the nodule*

- ⇒ *emphysema in adjacent pulmonary tissue*

- ⇒ *particles seen under polarized light*

# *Silicotic nodule - lung*



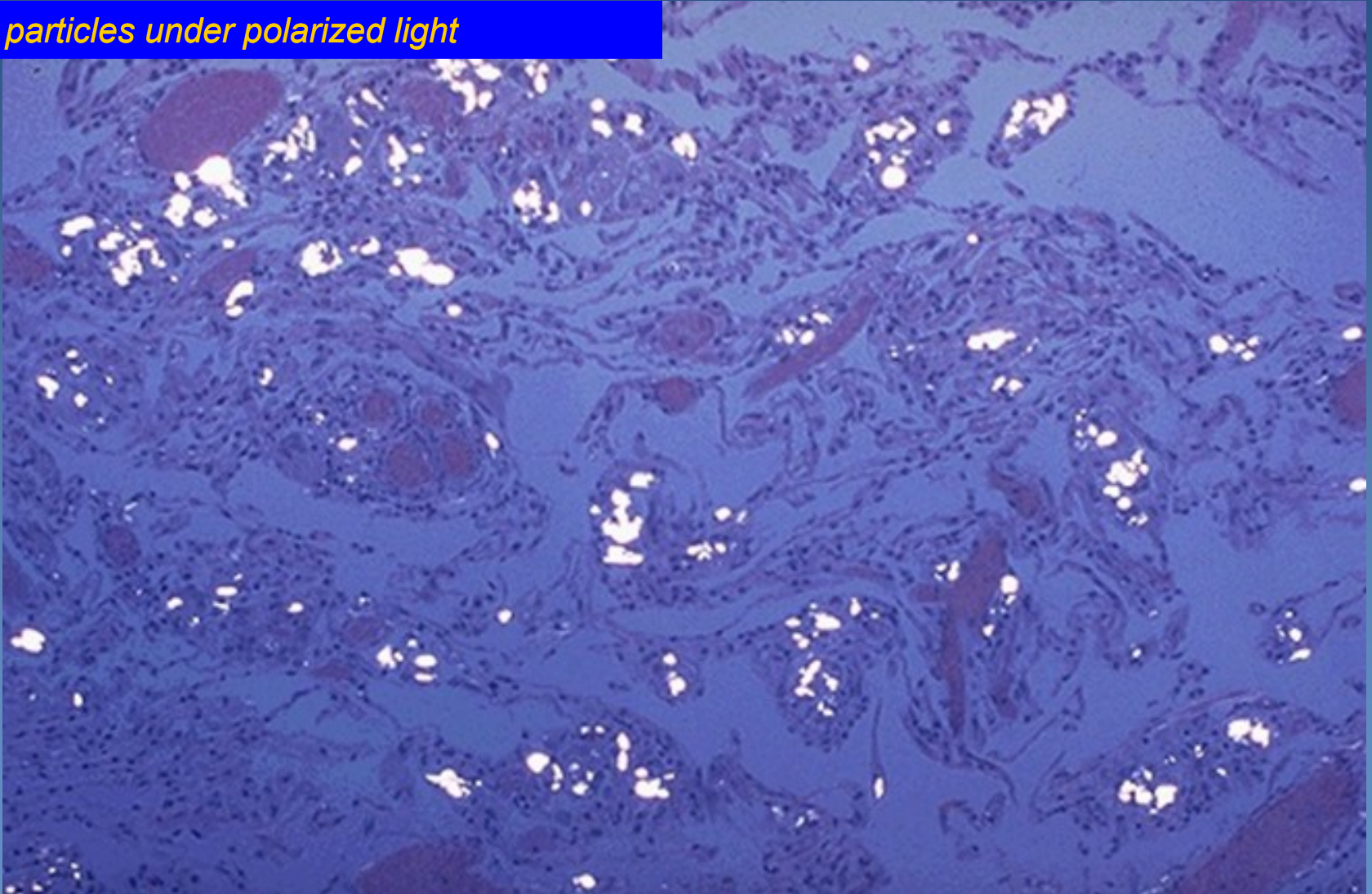
- 1. Fibrotic centre of the nodule*
- 2. Emphysema*



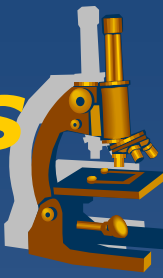# *Pulmonary silicosis*



*Silica particles under polarized light*



# Granulomatous inflammations - Tuberculosis



## x aetiology

⇒ *Mycobacterium tuberculosis*, *M. bovis*

⇒ special *Ziehl-Neelsen stain*

- PCR more sensitive

## x delayed-type hypersensitivity

(type IV. hypersensitivity)

⇒ *T cells-mediated immune memory response to TBC antigens (granulomas)*

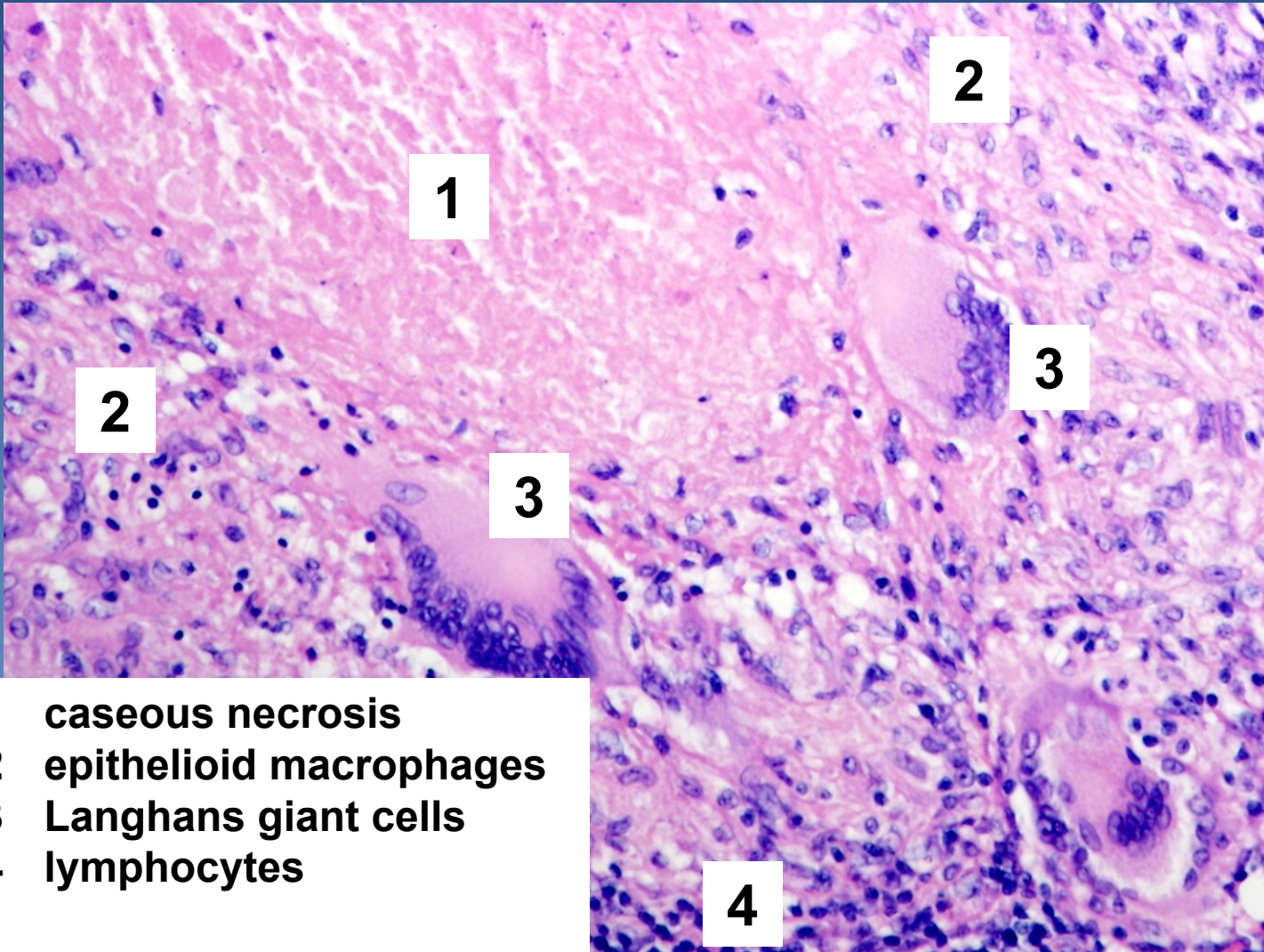
# Tuberculosis – morphological features



- × **tbc granuloma** – *proliferative form*
  - ⇒ *host resistance*
  - ⇒ *specific granulation tissue: epithelioid macrophages + Langhans giant cells*
  
- × **tbc exsudate** – *exsudative form (meningitis)*
  - ⇒ *allergy*
  - ⇒ *serofibrinous exsudate + Orth cells (macrophages)*
  
- + **caseification**
  - ⇒ *cheese-like, caseous necrosis – sensitization?*
  
- + **colliquation (liquefaction)**
  - ⇒ *after release of proteolytic enzymes by neutrophils*
  
- + **calcification**



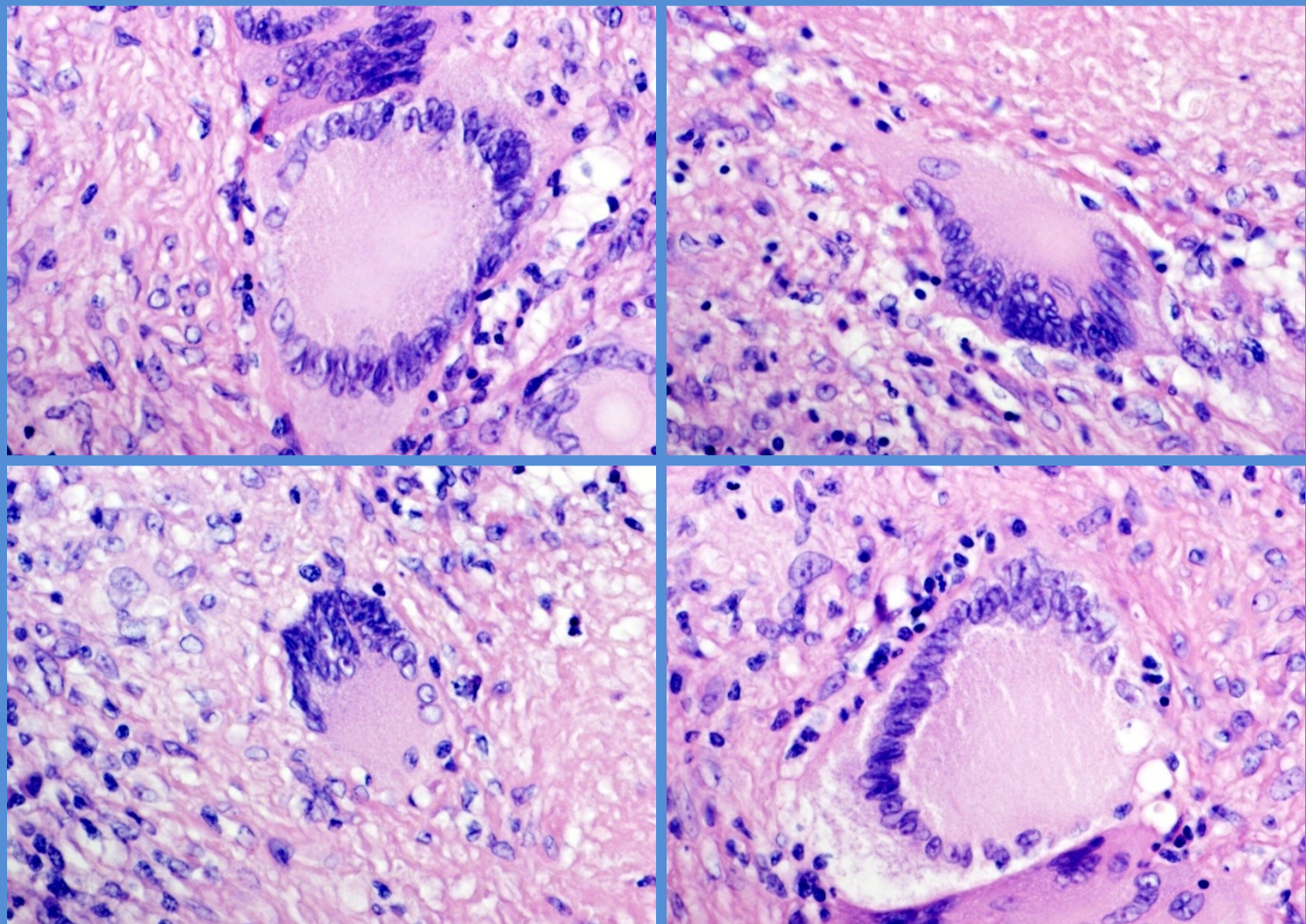
# *Tbc granuloma*



- 1 caseous necrosis
- 2 epithelioid macrophages
- 3 Langhans giant cells
- 4 lymphocytes

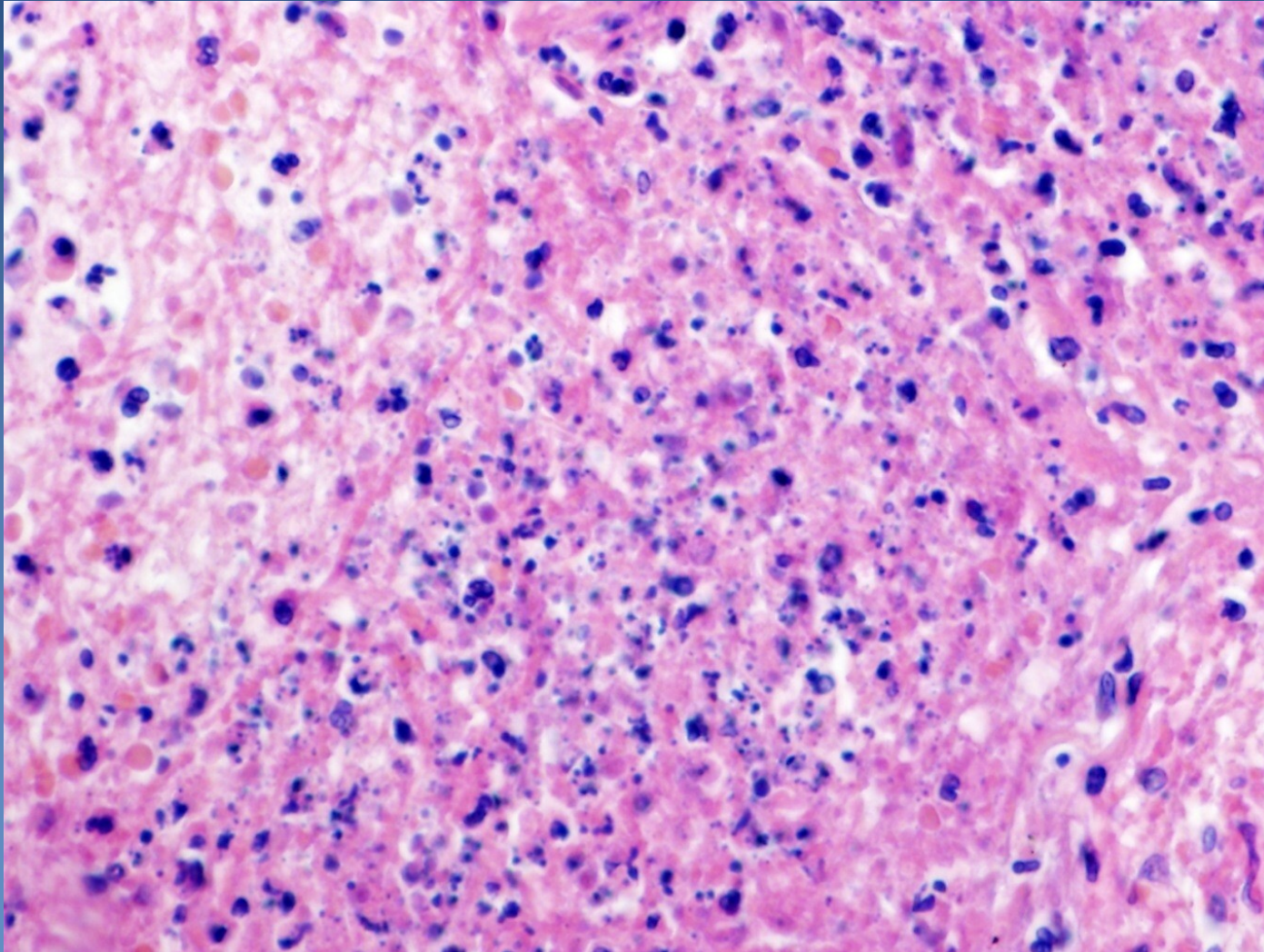


# *Langhans giant cells*





# *Caseous necrosis*



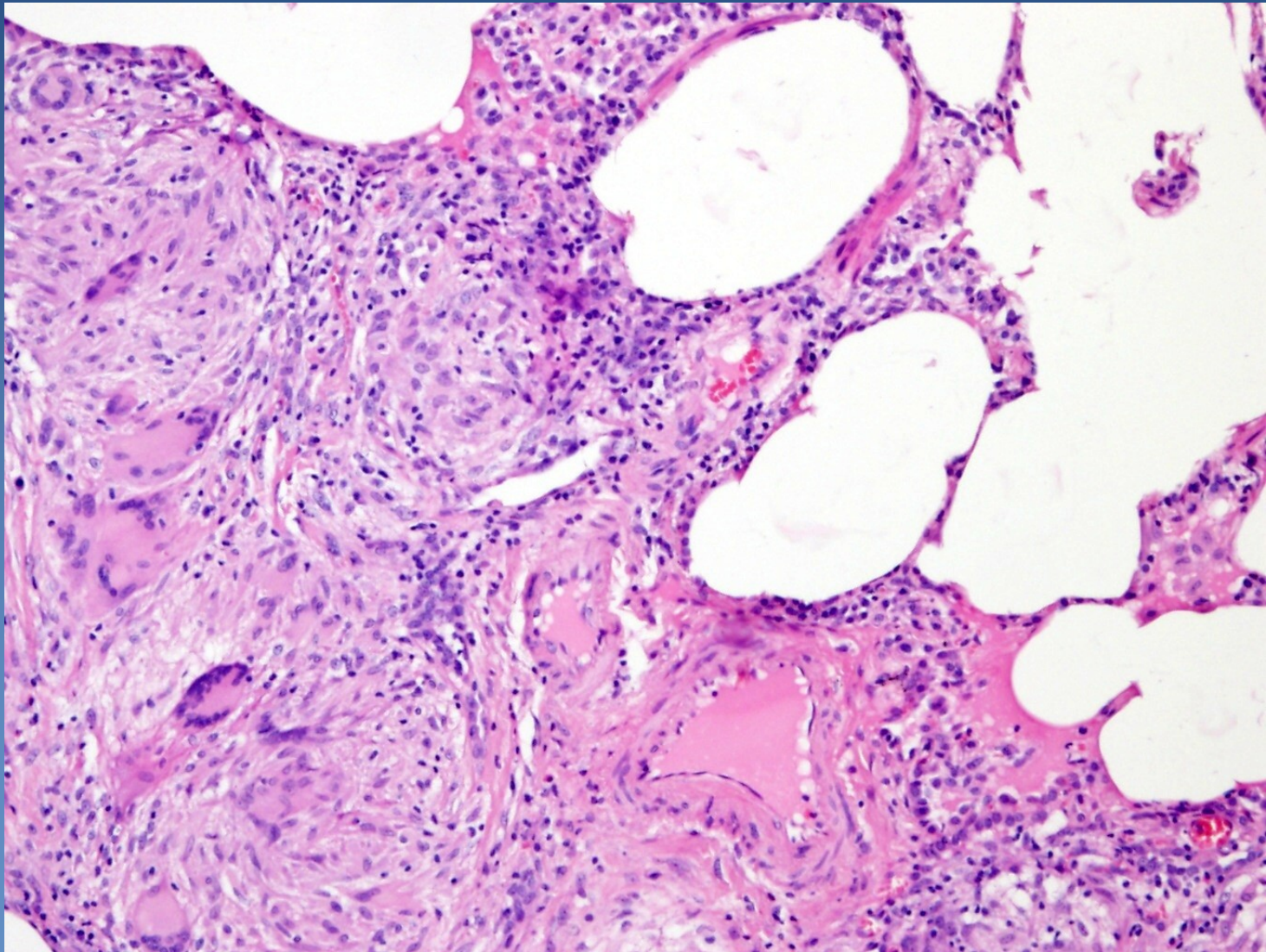
# Sarcoidosis



- ✗ chronic granulomatous inflammatory disease of unknown aetiology
  
- ✗ affected tissue:
  - ⇒ *mediastinal lymph nodes, lungs, skin, eye*
  - ⇒ *granulomas can affect any organ*
  
- ✗ small regular granulomas similar to TBC granulomas, but without caseous necrosis, fibrosis usually more pronounced
- ✗ cytoplasmic bodies of Langhans giant cells, not specific:
  - ⇒ *asteroid inclusions*
  - ⇒ *Schaumann bodies*
  
- ✗ dg. *per exclusionem* – necessary elimination of TBC, fungal infection etc.



# *Sarcoidosis*





# *Pulmonary chondrohamartoma*

---



- ✘ hamartoma? benign tumor?
- ✘ incidental X-ray finding
- ✘ differential diagnosis x malignant tumors important!

# *Pulmonary chondrohamartoma*



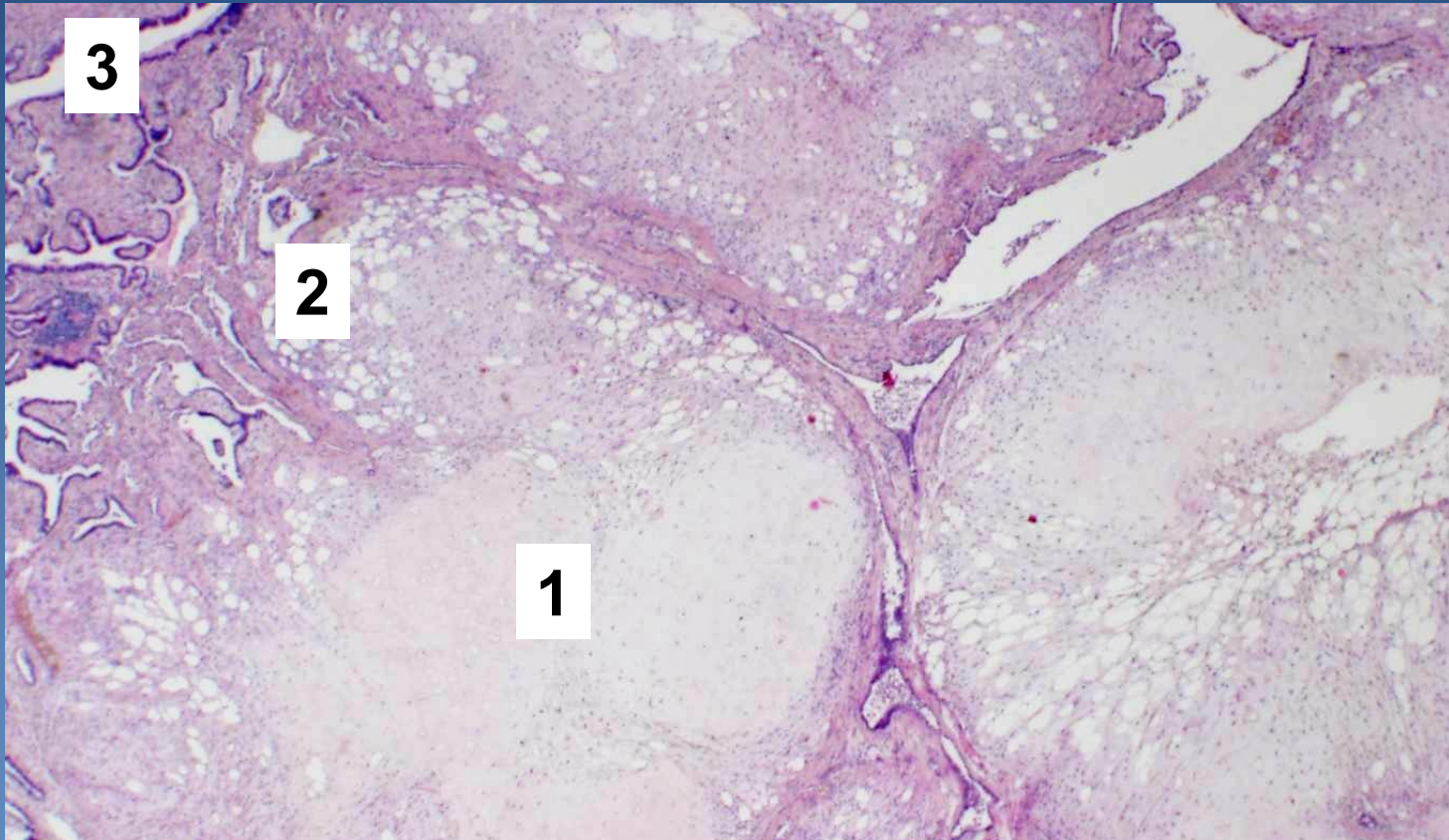## *x Gross:*

- ⇒ whitish yellow*
- ⇒ well demarcated*
- ⇒ lobular structure*

## *x Generally formed of mixture of homologous non-organised afunctional tissues :*

- ⇒ cartilage*
- ⇒ connective tissue*
- ⇒ fat*
- ⇒ tubular structures with epithelium*

# *Pulmonary chondrohamartoma*

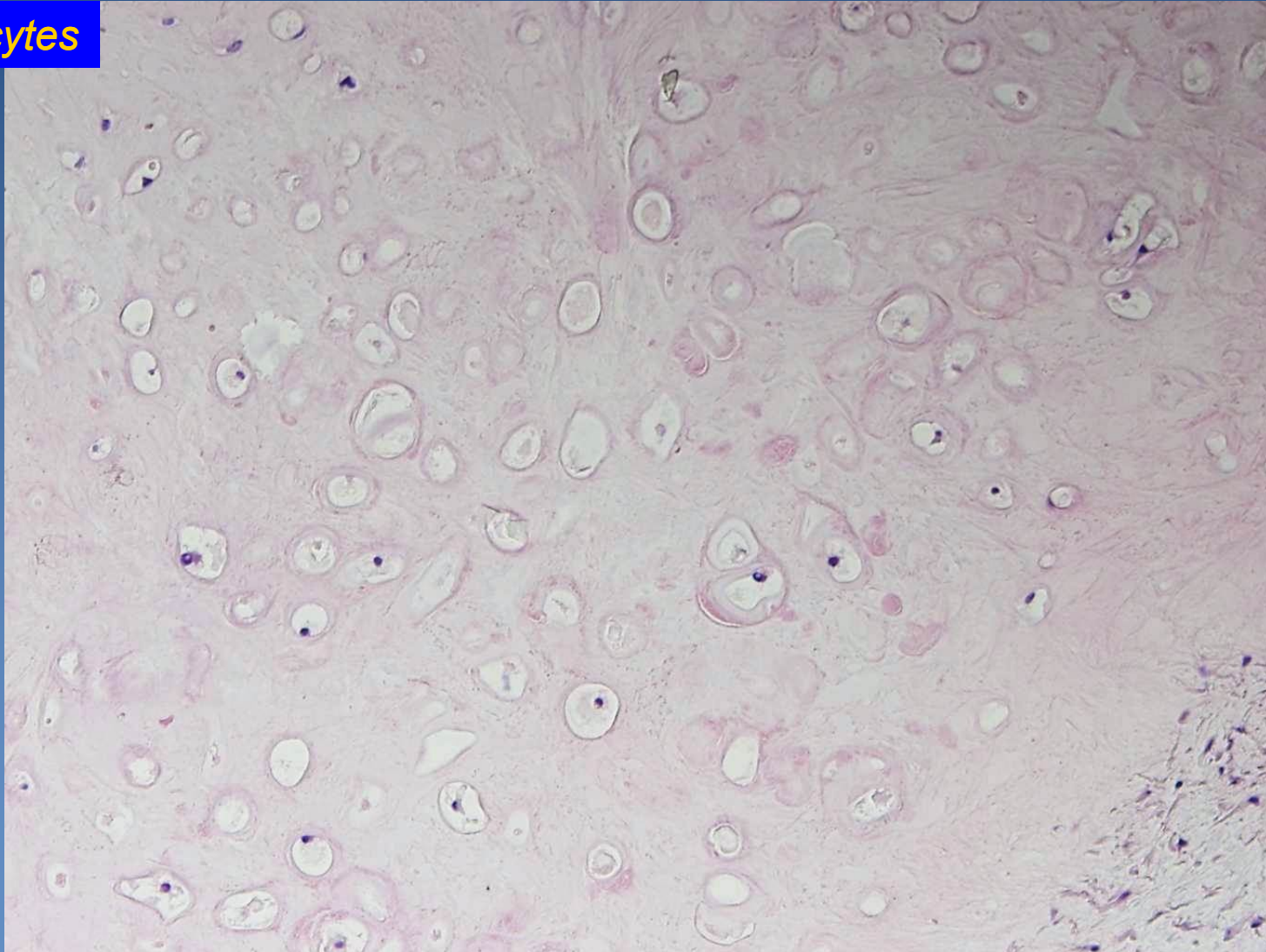


- 1. Cartilage*
- 2. Fat tissue*
- 3. Tubular structures with respiratory epithelium*

# *Pulmonary chondrohamartoma*



*Chondrocytes*

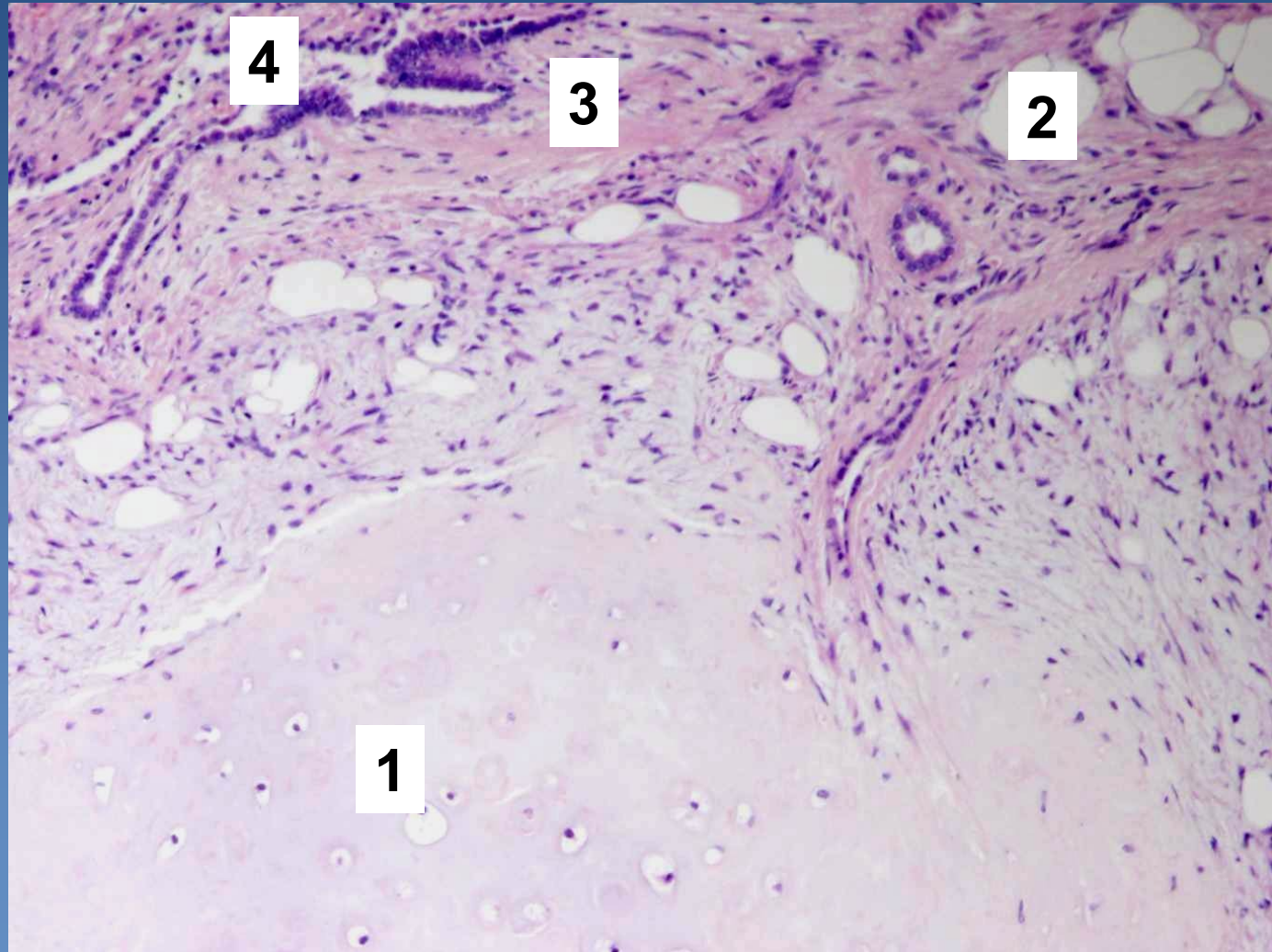




# *Pulmonary chondrohamartoma*



1. Cartilage
2. Fat tissue
3. Connective tissue
4. Tubular structures



# *Malignant lung tumors*



- ✘ Primary epithelial tumors – carcinomas
  - ⇒ *Squamous cell*
  - ⇒ *Small cell (undifferentiated neuroendocrine ca)*
  - ⇒ *Adenocarcinoma*
  - ⇒ *Large cell undifferentiated carcinoma*
  - ⇒ *Other types (carcinoid tumors, adenosquamous ca, salivary gland tumors)*
- ✘ Primary mesenchymal tumors – sarcomas
- ✘ Lymphoproliferative neoplasias
- ✘ Metastatic tumors

# ***Bronchogenic carcinoma***



- x** Very common primary malignancy
- x** 5 year survival 5 – 7 %
- x** 4 – 7 decenium, more commonly males
- x** Clinical symptoms: late
  - ⇒ *weight loss, chronic cough, haemoptysis, dyspnoea, chest pain, paraneoplastic syndromes (ACTH, ADH, PTH)*

# Bronchogenic carcinoma



## × incidence:

- ⇒ *in CZE males 100/100 000 (the most common malignancy of men),*
- ⇒ *females 25/100 000 (the 3rd most common malignancy of women, ↑ tendency)*

## × aetiology:

- ⇒ *smoking*
  - generally 20X higher risk in smokers
  - 20 cigarettes/day = 20 years, 40 cigarettes/day = 10 years...
- ⇒ *asbestos, Hg, Ni, As*
- ⇒ *ionization*
- ⇒ *radioactive radon*
- ⇒ *dust particles*
- ⇒ *familial predisposition*



# Bronchogenic carcinoma



## ✘ local complications:

⇒ *depends on the localization of the tumor:*

- lung collapse, bronchiectasis, bronchopneumonia, gangrene
- widespread necrosis (more extensive in squamous cell ca)
  - destruction of vascular wall by tumor
  - fatal bleeding

## ✘ clinical types:

⇒ *small cell lung carcinoma (SCLC)*

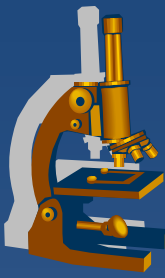
⇒ *non-small cell lung carcinoma (NSCLC)*

# *Neuroendocrine carcinomas*



- ✘ **Neuroendocrine differentiation** – typical organoid growth pattern, neurosecretory granules, may be paraneoplastic syndromes – aberrant production of peptide hormones
- ✘ **Well-differentiated neuroendocrine tumor, G1 – NET G1**, carcinoid, i. e. in GIT, bronchi ...
- ✘ **Moderately differentiated n. t., NET G2** – atypical carcinoid,
- ✘ **Neuroendocrine tumor NET G3**
- ✘ **Neuroendocrine carcinoma** – variable cell size, most common small cell carcinoma

# *Small cell lung carcinoma*



- × undifferentiated (high grade) neuroendocrine tumor
- × 20 % of all bronchogenic carcinomas
- × associated with **smoking**
- × localized in **lung hilus**
- × early metastatic spread, widespread dissemination
  - ⇒ *lymphatic and hematogenous (LN, liver, brain, bones, kidney, adrenals, ...)*

# Small-cell lung carcinoma



## × histologic types:

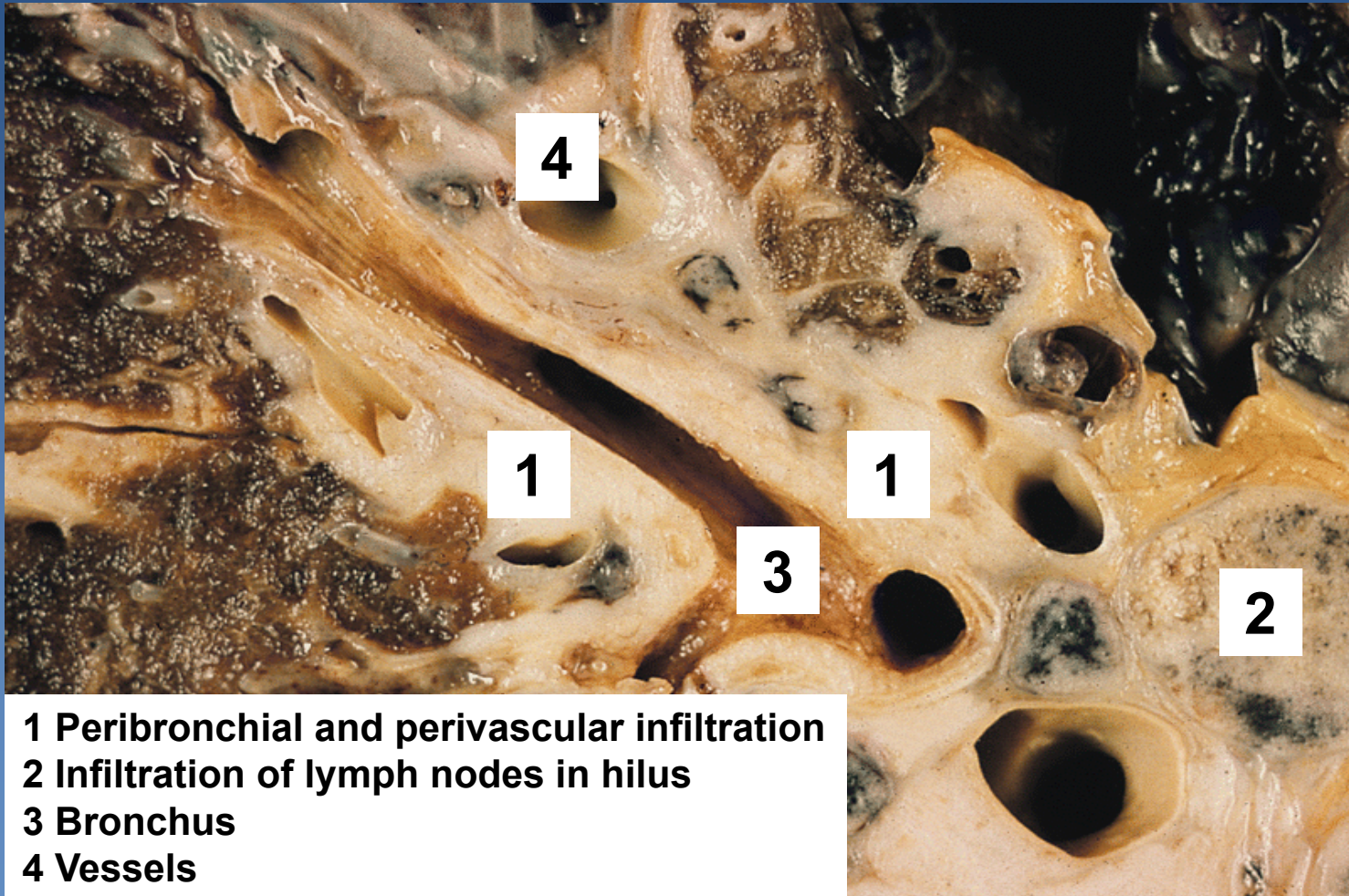
- ⇒ *small cell („oat cell carcinoma“)*
- ⇒ *intermediate (now included into small cell type)*
- ⇒ *combined*

## × Micro:

- ⇒ *small cells with scant cytoplasm (size < 3 lymphocytes)*
- ⇒ *small round - elongated dark blue nuclei without obvious nucleoli (oat cell carcinoma)*
- ⇒ *solid growth*
- ⇒ *neurosecretory granules in cytoplasm*
  - chromogranin, synaptophysin



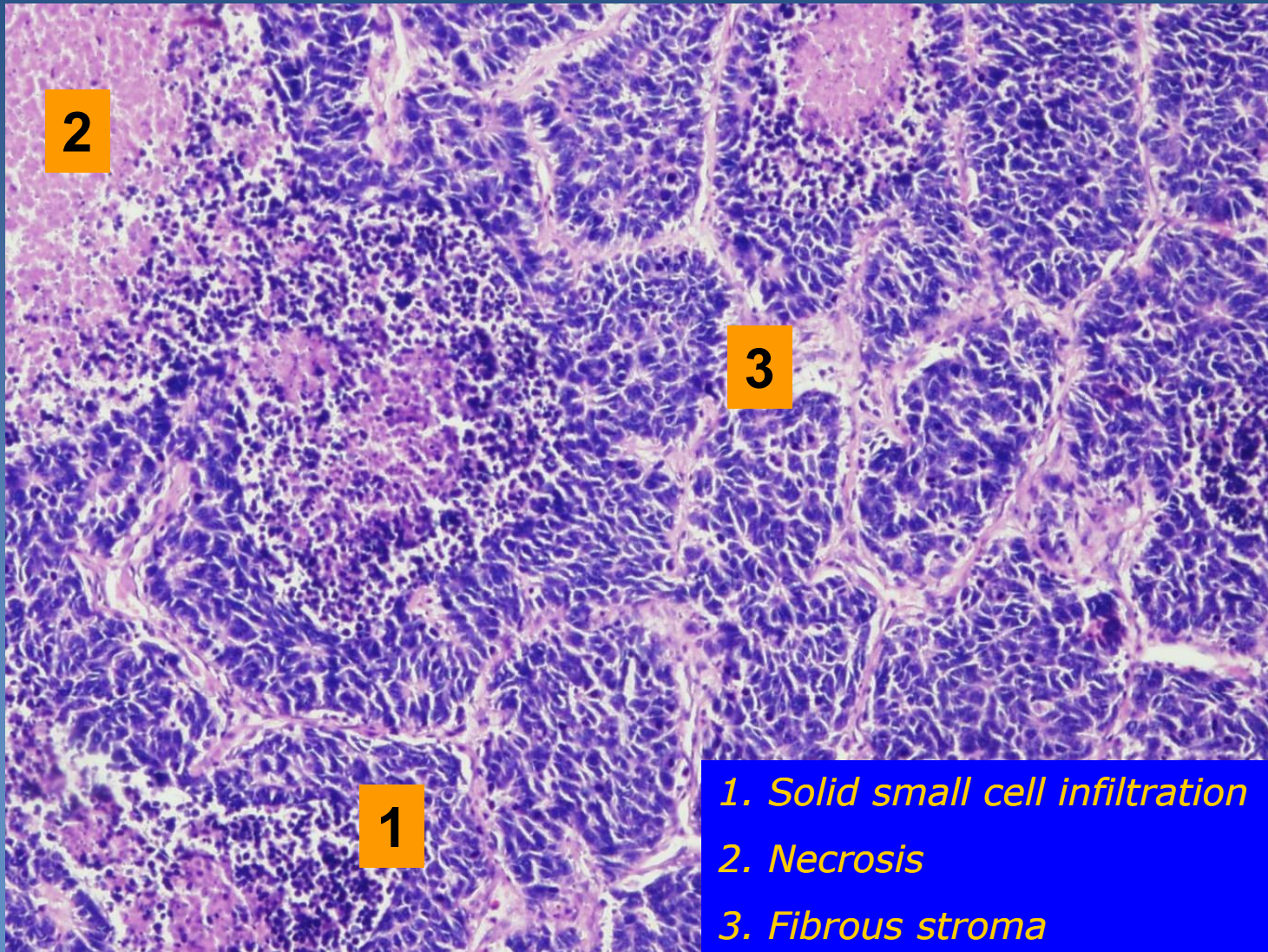
# Small-cell lung carcinoma



- 1 Peribronchial and perivascular infiltration**
- 2 Infiltration of lymph nodes in hilus**
- 3 Bronchus**
- 4 Vessels**

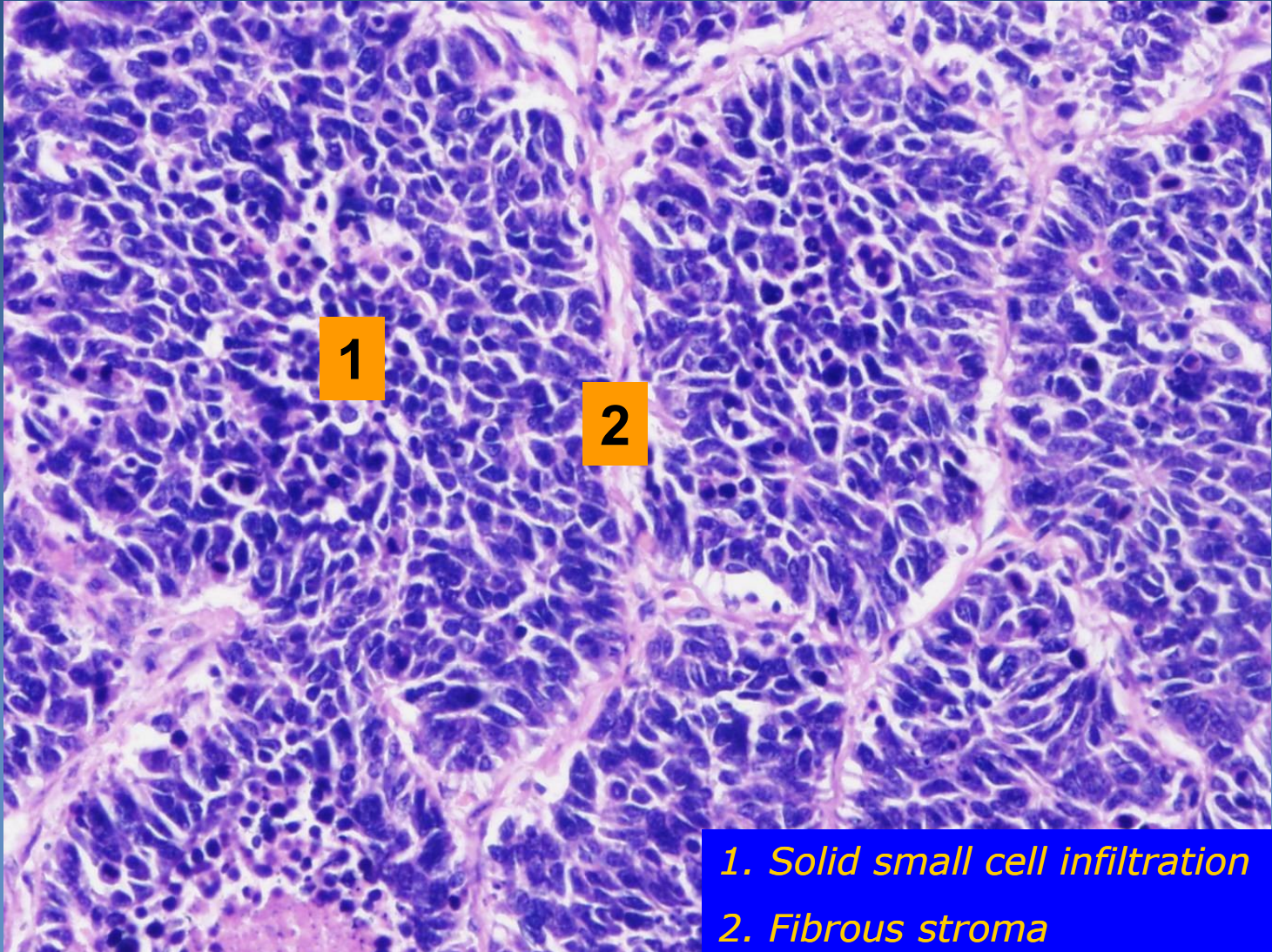


# Small-cell lung carcinoma





# *Small-cell lung carcinoma*



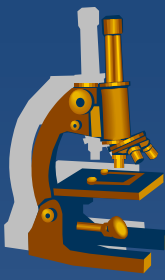
- 1. Solid small cell infiltration*
- 2. Fibrous stroma*

# Non-small cell lung carcinoma



- × squamous cell carcinoma
- × adenocarcinoma
  - ⇒ *adenocarcinoma in situ*
  - ⇒ *minimally invasive:*
    - non-mucinous
    - mucinous
    - mixed
  - ⇒ *invasive:*
    - lepidic
    - acinar
    - papillary
    - micropapillary
    - solid
- × large cell lung carcinoma
- × other, incl. mixed





# *Squamous cell carcinoma*

- ✗ male 40%, female 20%
- ✗ strongly associated with smoking
- ✗ typical perihilar localisation (central > peripheral)
- ✗ commonly slow progression from squamous metaplasia – dysplasia – ca in situ
  - ⇒ *late metastases*
- ✗ Micro:
  - ⇒ *squamous cell carcinoma of common type*
    - polygonal shaped cells in solid nests, keratin pearls, cell junctions
  - ⇒ *variable differentiation*

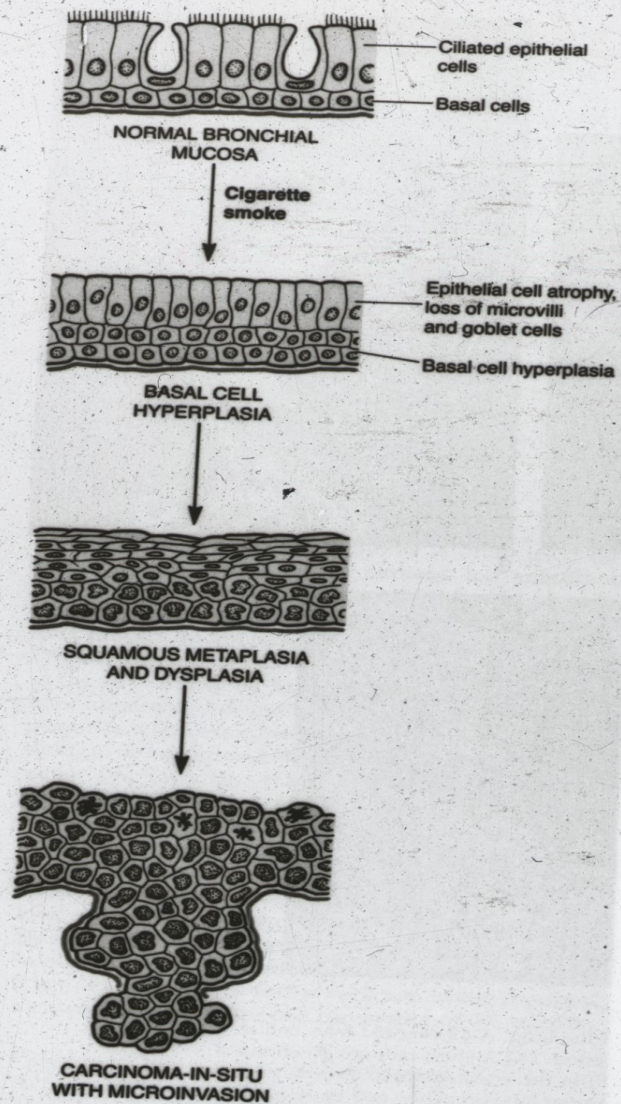
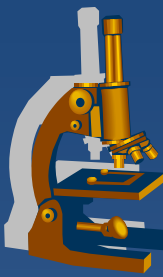
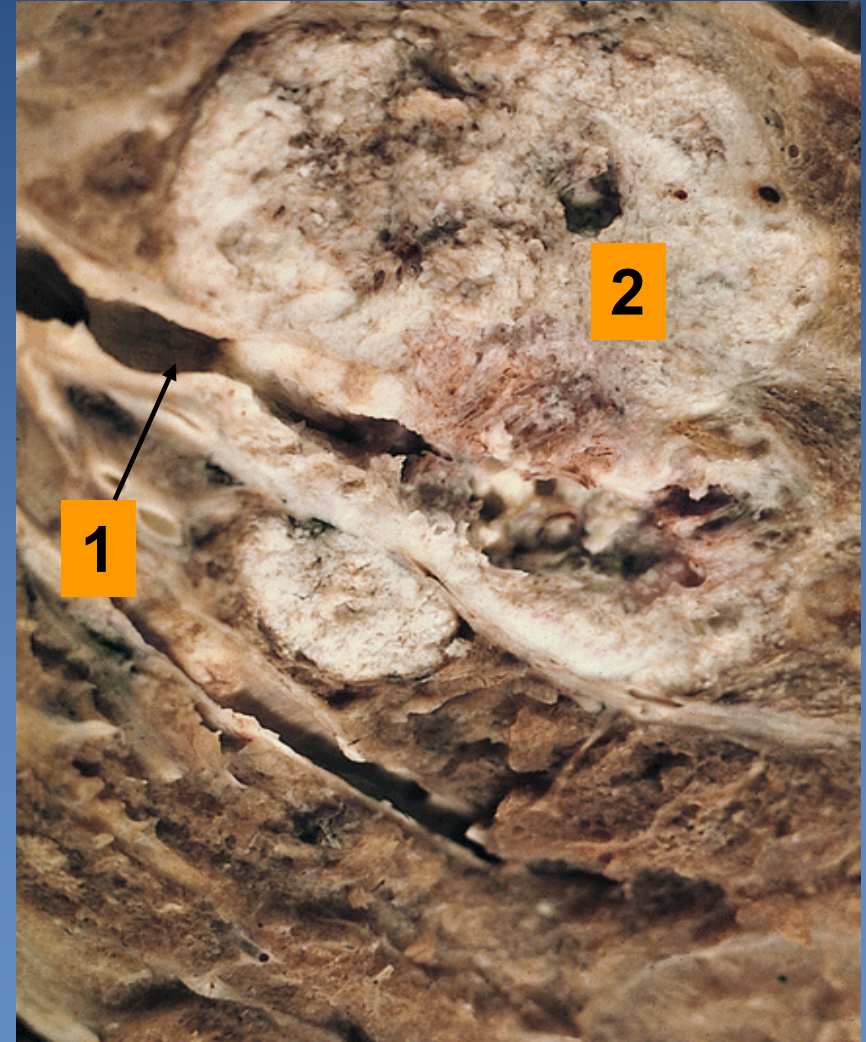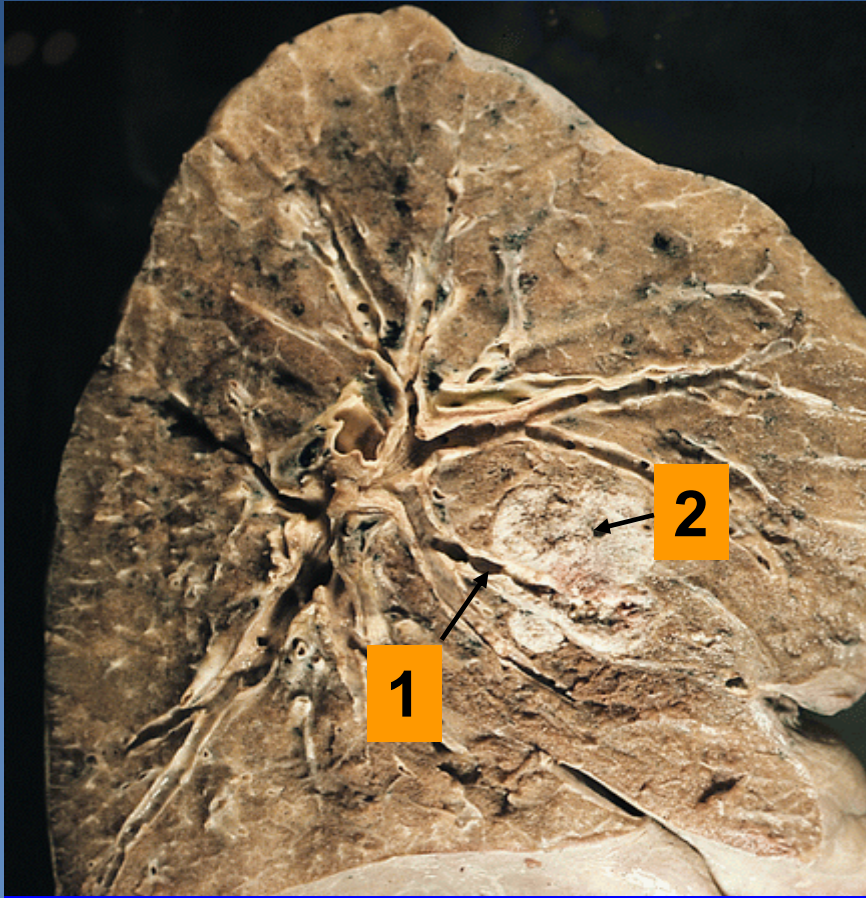

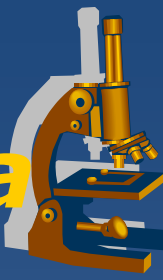
Figure 12-8. The development of squamous cell carcinoma. First, minor changes occur in the bronchial epithelium (basal cell hyperplasia), followed by squamous cell metaplasia with dysplasia. Then carcinoma in situ ensues, first localized to the epithelium and then extending to bronchial glands and penetrating the basement membrane. Extensive invasion and metastases follow.





# Squamous-cell lung carcinoma

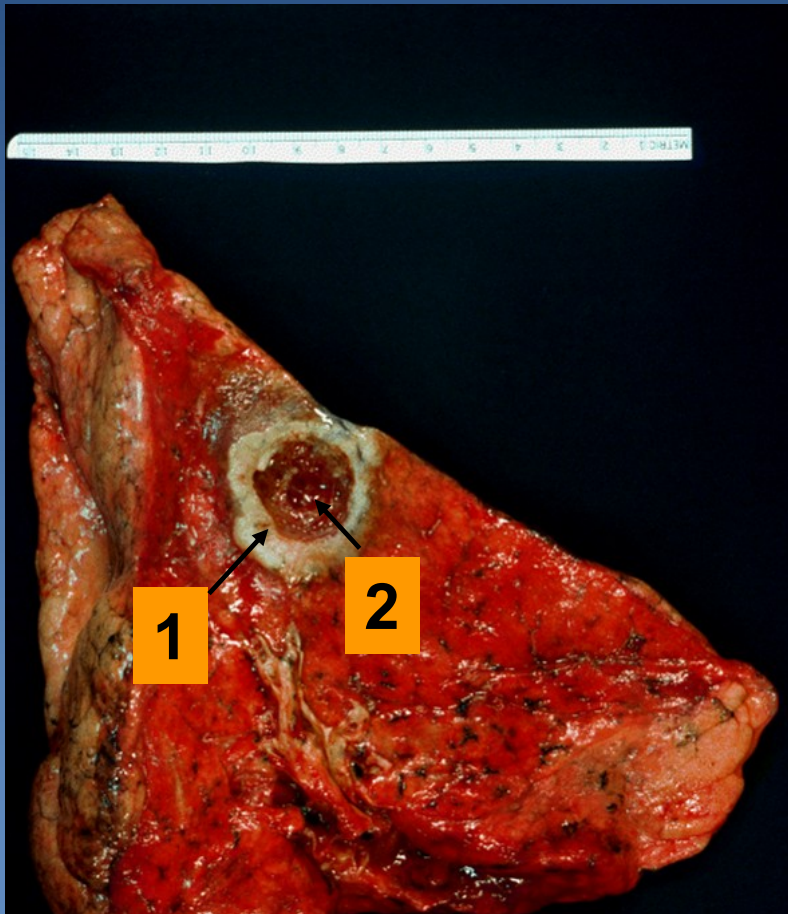
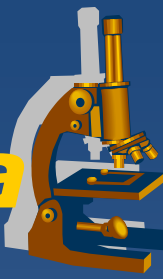


1. Segmental bronchus

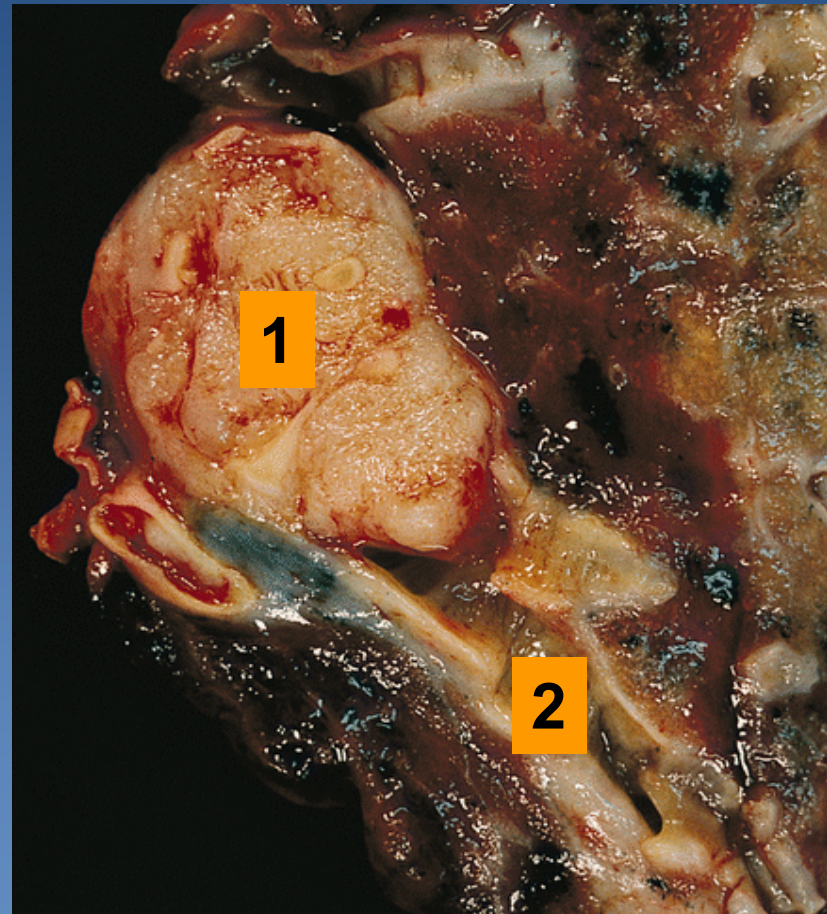
2. Tumor



# Squamous cell lung carcinoma

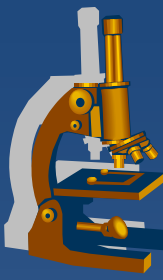


1. Tumor localized in the periphery
2. Central necrosis



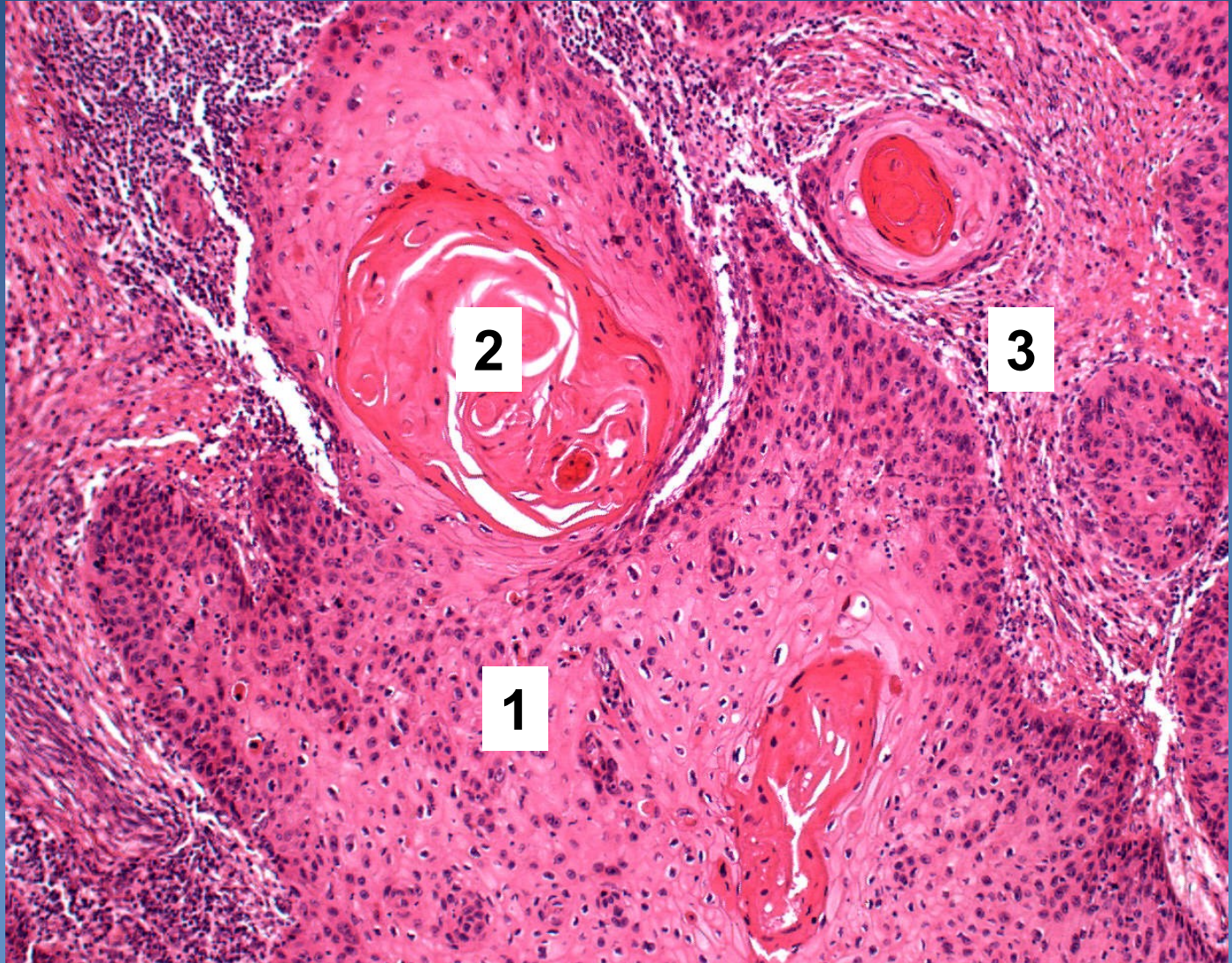
1. Tumor in bronchus
2. Segmental bronchus



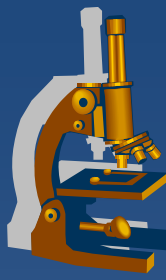


# *Squamous cell carcinoma*

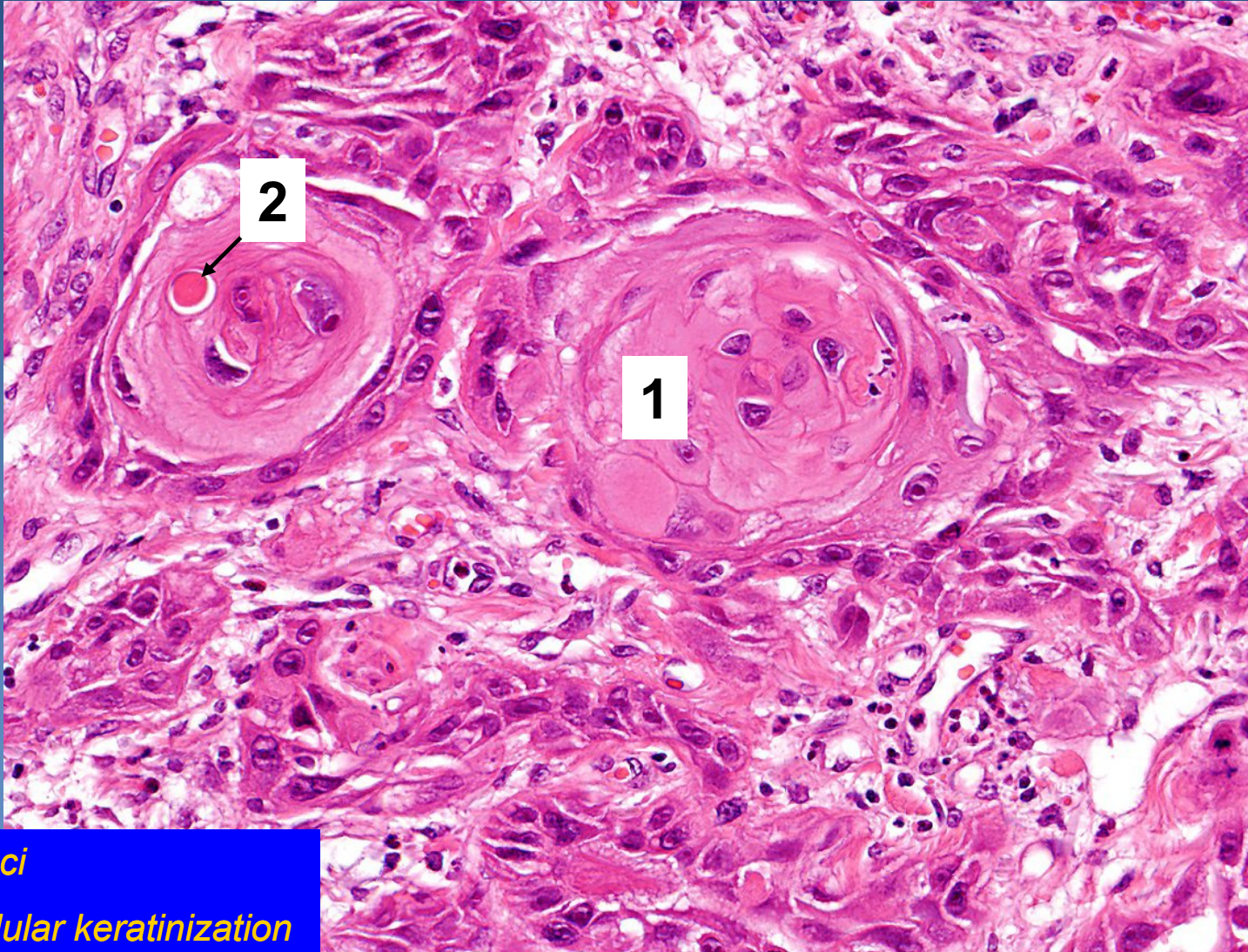
1. *Solid nests of malignant keratinocytes*
2. *Keratin pearls*
3. *Stroma of the tumor*







# *Squamous cell carcinoma*



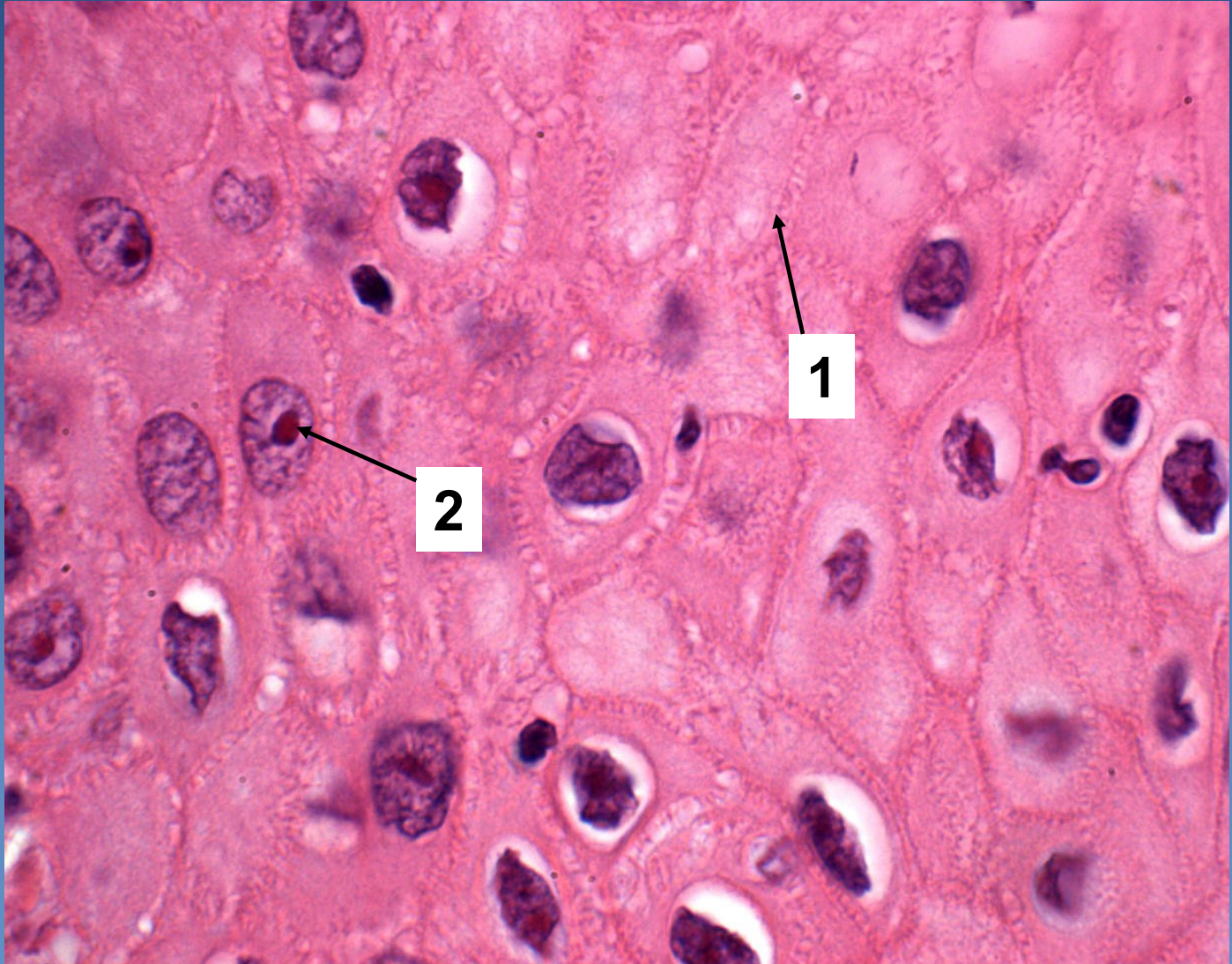
- 1. *Tumor foci*
- 2. *Monocellular keratinization*





# *Squamous-cell carcinoma*

1. *Cell junctions*
2. *Nucleus with prominent nucleoli*



# Adenocarcinoma



- ✗ male 20%, female 40%;
- ✗ most cases in smokers, but the most common type in non-smokers
- ✗ typically localized in the periphery, subpleural
  - ⇒ *late symptoms !!!*      *Commonly accidental finding on X-ray/CT*
- ✗ formerly used term:
  - ⇒ *bronchioloalveolar adenocarcinoma (BAC) no more in use (but still present in WHO classification of lung tumors)*



# Adenocarcinoma



## × classification:

### ⇒ *Adenocarcinoma in situ - AIS (size $\leq 3$ cm):*

- non/mucinous (earlier BAC),
- mucinous
- mixed
- no stromal/vascular/pleural invasion present

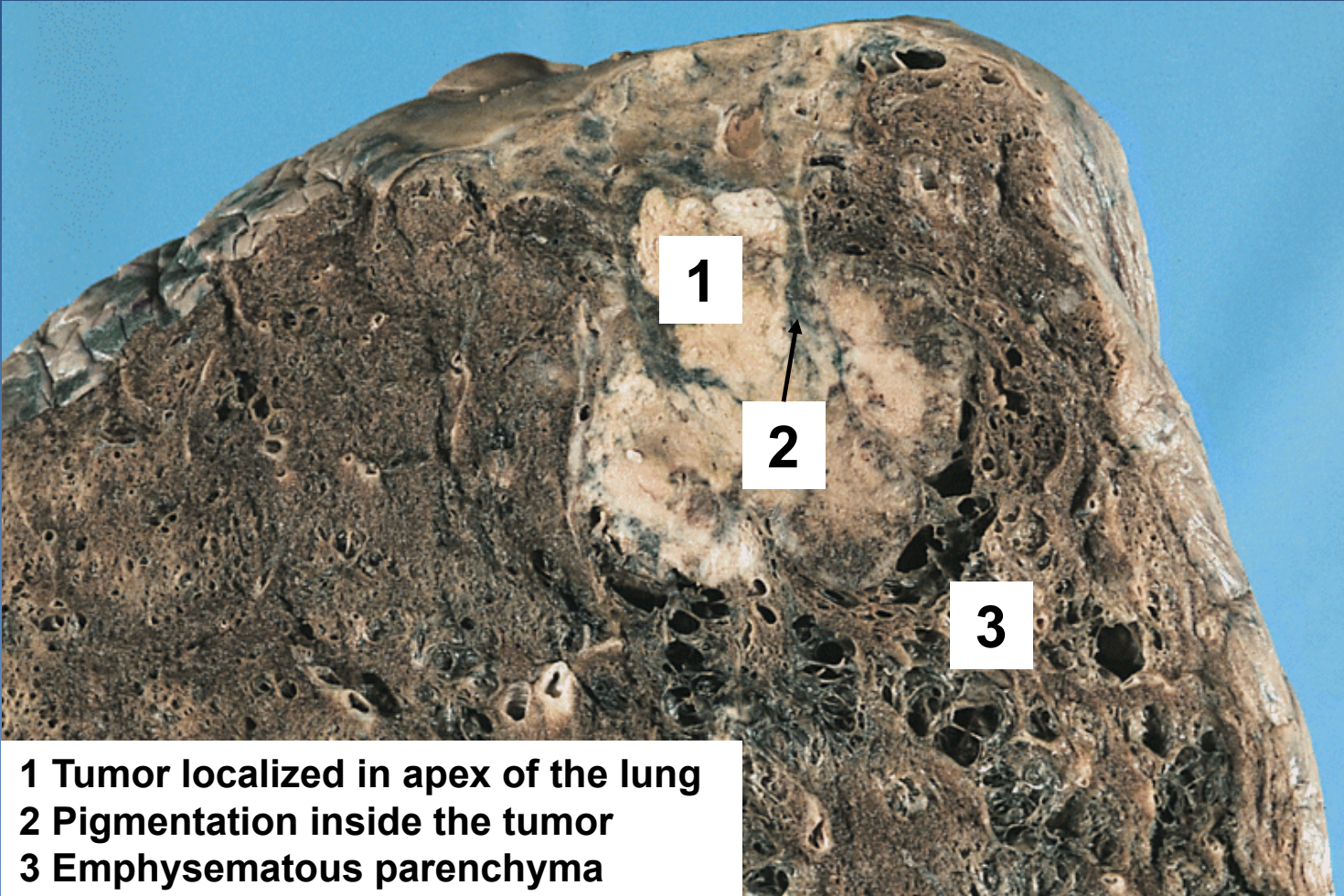
### ⇒ *Minimally invasive ACA (size $\leq 3$ cm and $\leq 5$ mm invasion): idem*

- apart of lepidic growth other types of spread (papillary, solid....) or stromal invasion present
- no vascular/pleural invasion present

### ⇒ *Invasive ACA:*

- Lepidic
- Acinar
- Papillary
- Micropapillary
- Solid

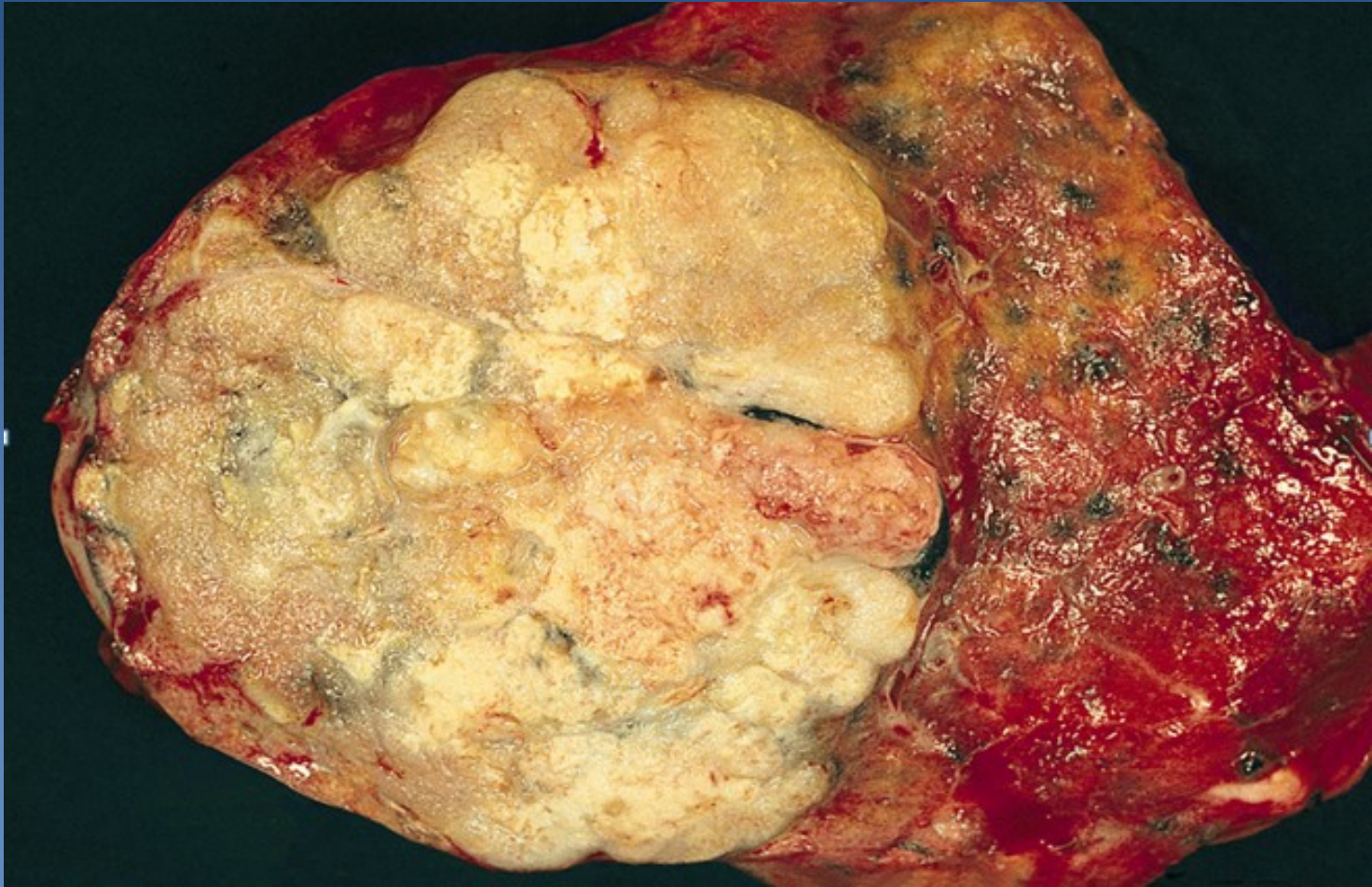
# Adenocarcinoma



- 1 Tumor localized in apex of the lung
- 2 Pigmentation inside the tumor
- 3 Emphysematous parenchyma

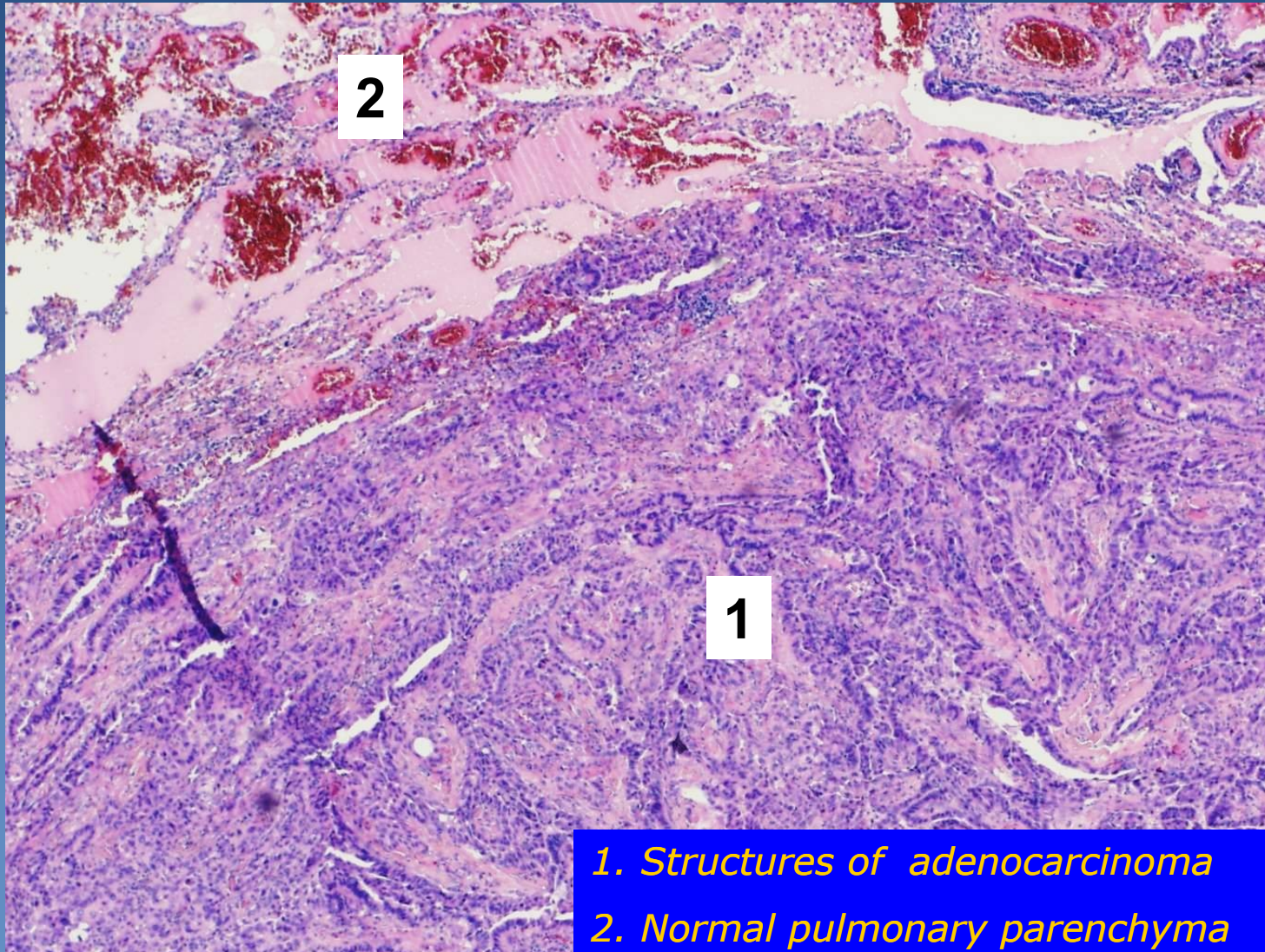


# *Adenocarcinoma*





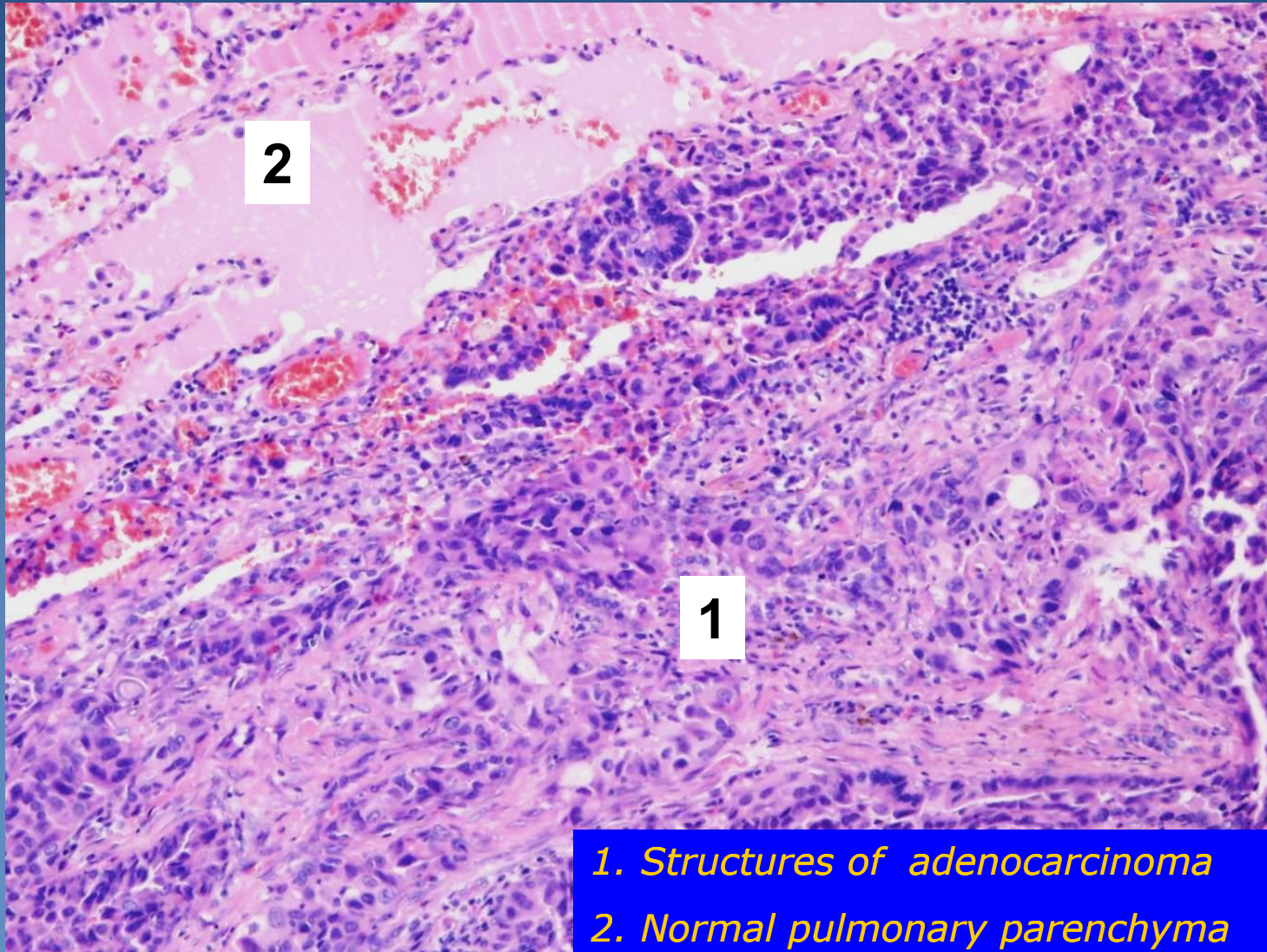
# Adenocarcinoma



1. Structures of adenocarcinoma
2. Normal pulmonary parenchyma

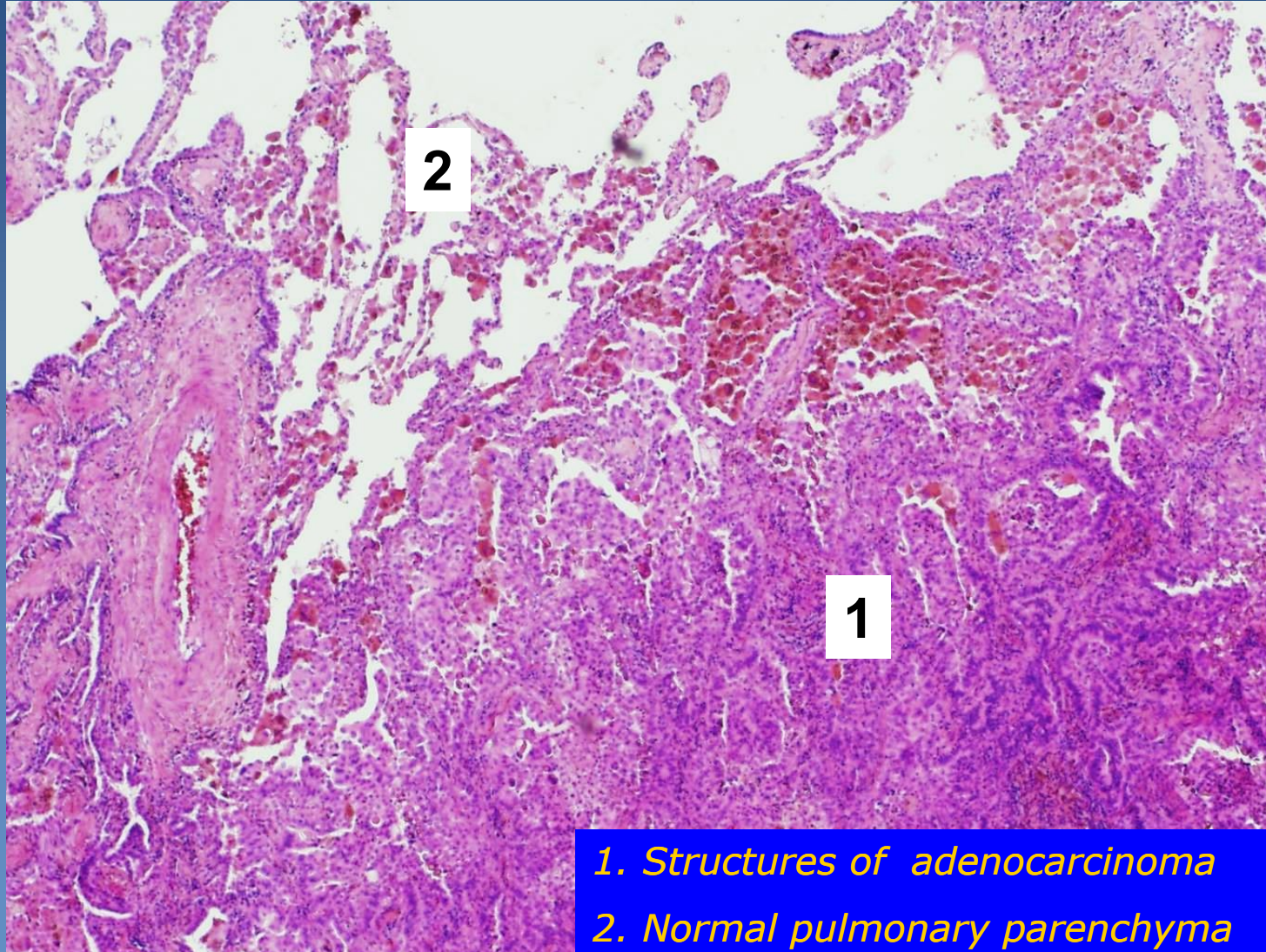


# Adenocarcinoma





# Adenocarcinoma



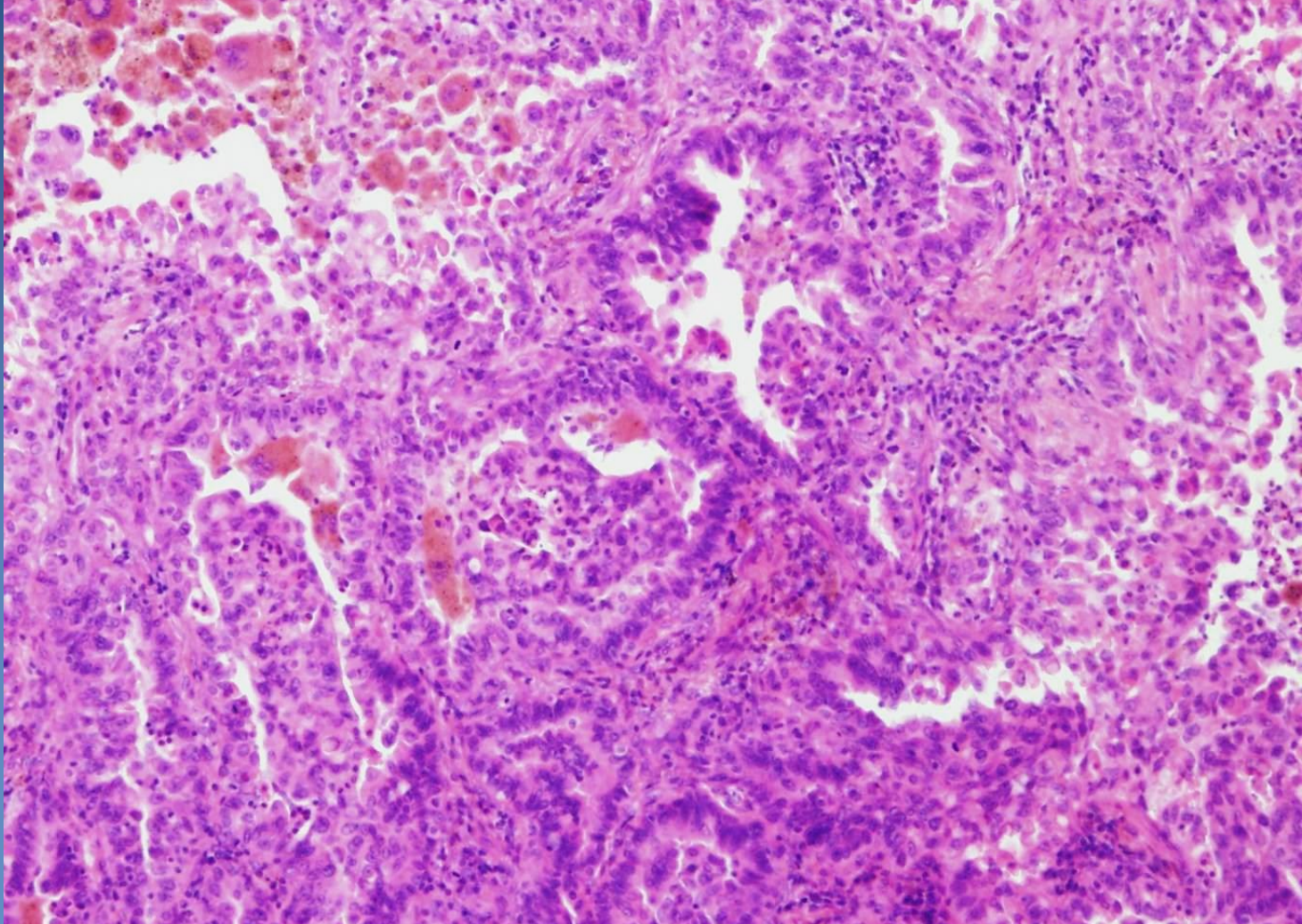
1. Structures of adenocarcinoma
2. Normal pulmonary parenchyma



# Adenocarcinoma



*Structures of an acinary and papillary formed adenocarcinoma*

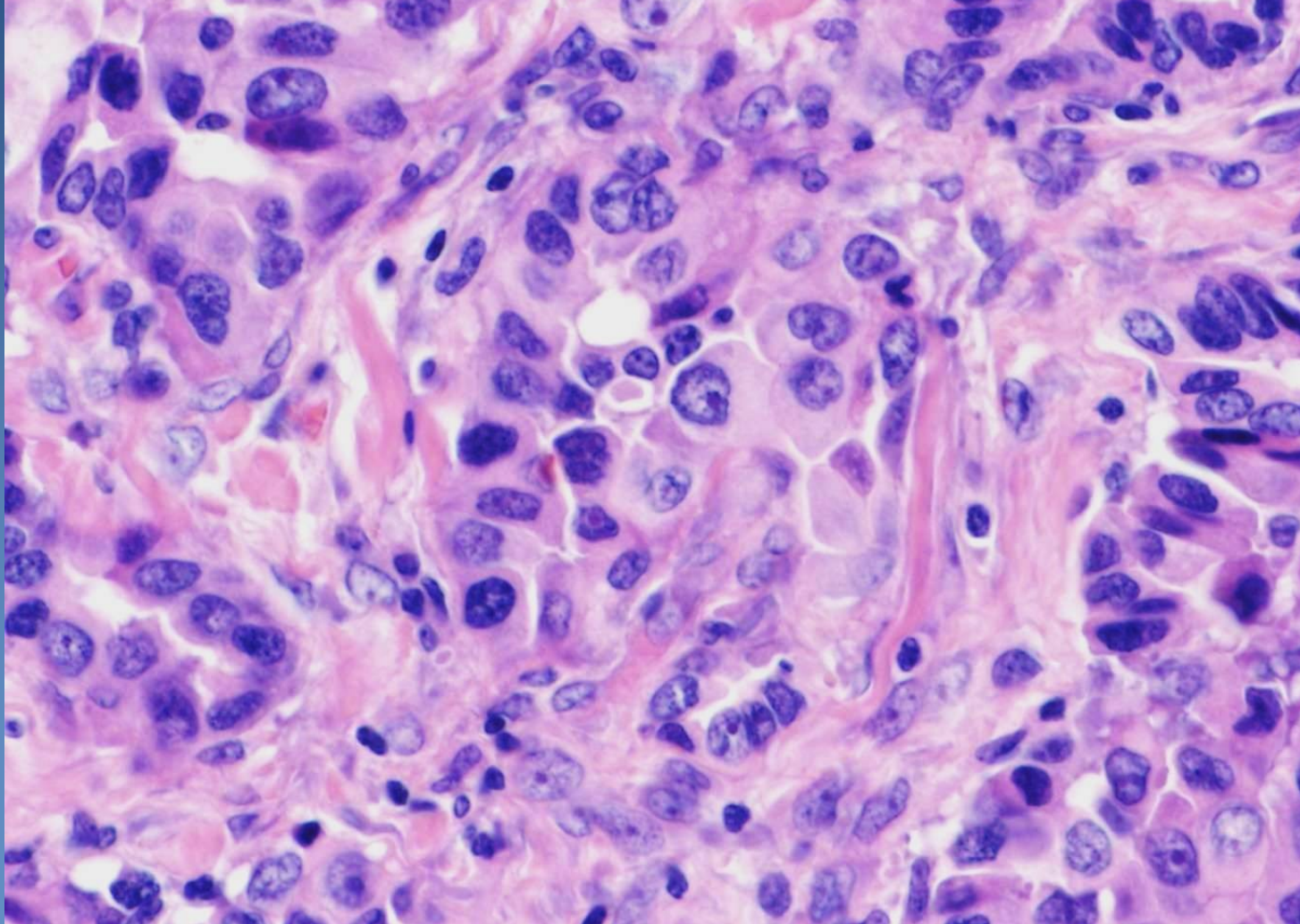




# Adenocarcinoma



*Cytology of malignant cells - anisocytosis and anisokaryosis*

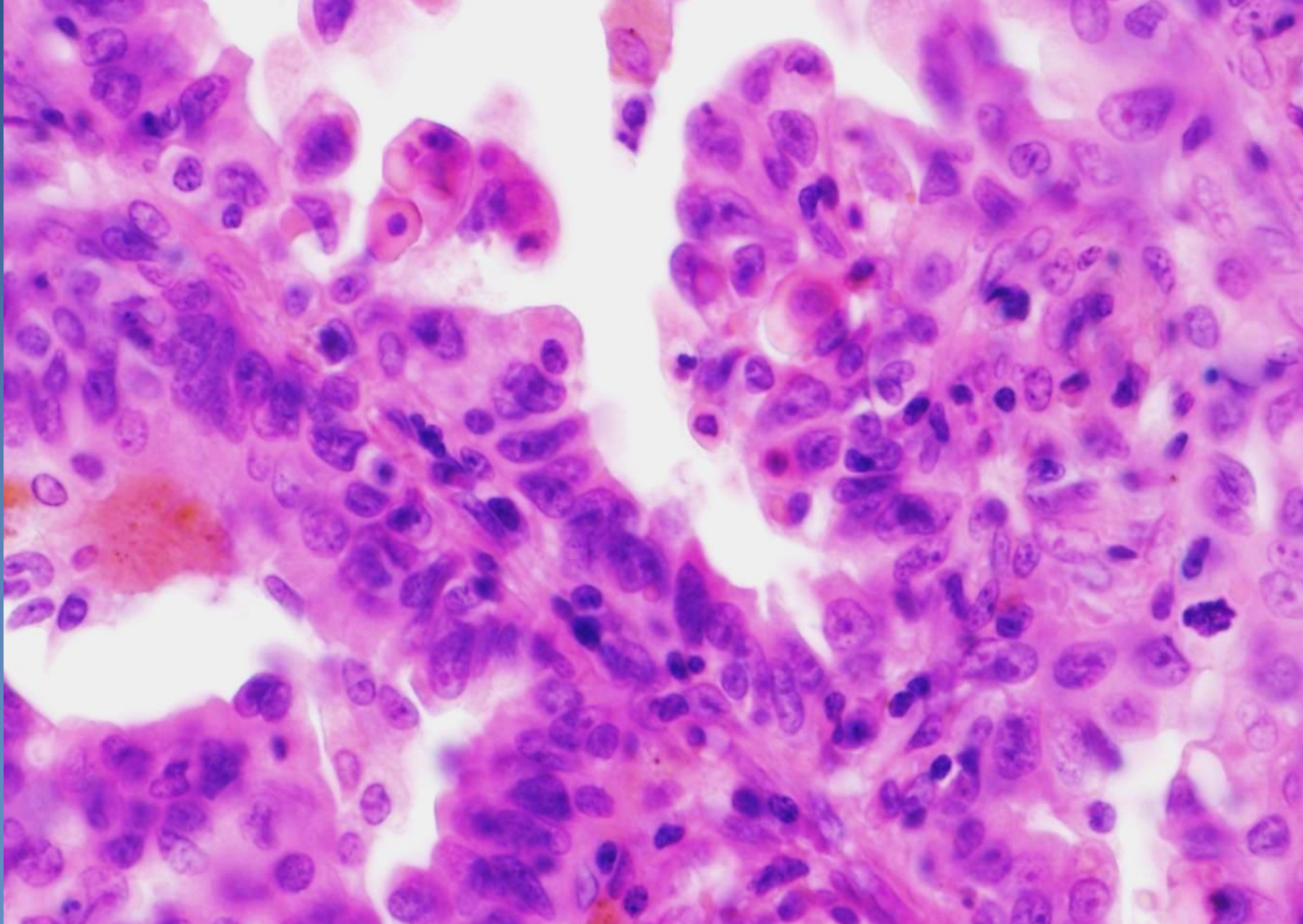


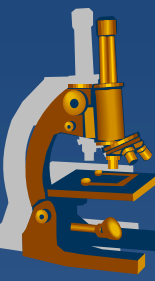


# Adenocarcinoma

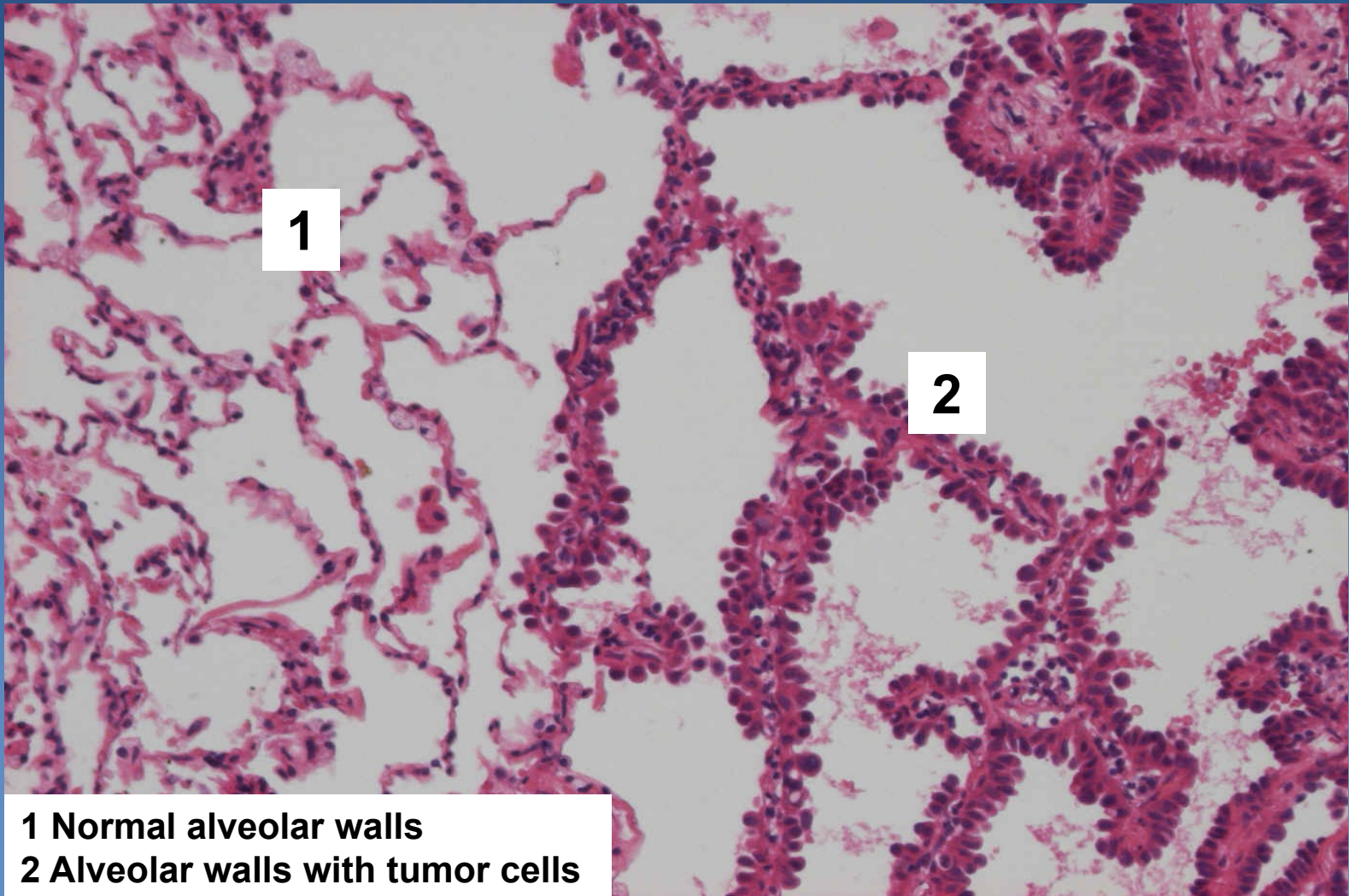


*Cytology of malignant cells - anisocytosis and anisokaryosis*





# ***AIS/minimally invasive ACA non/mucinous (earlier BAC)***

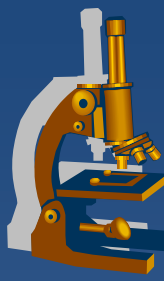


**1**

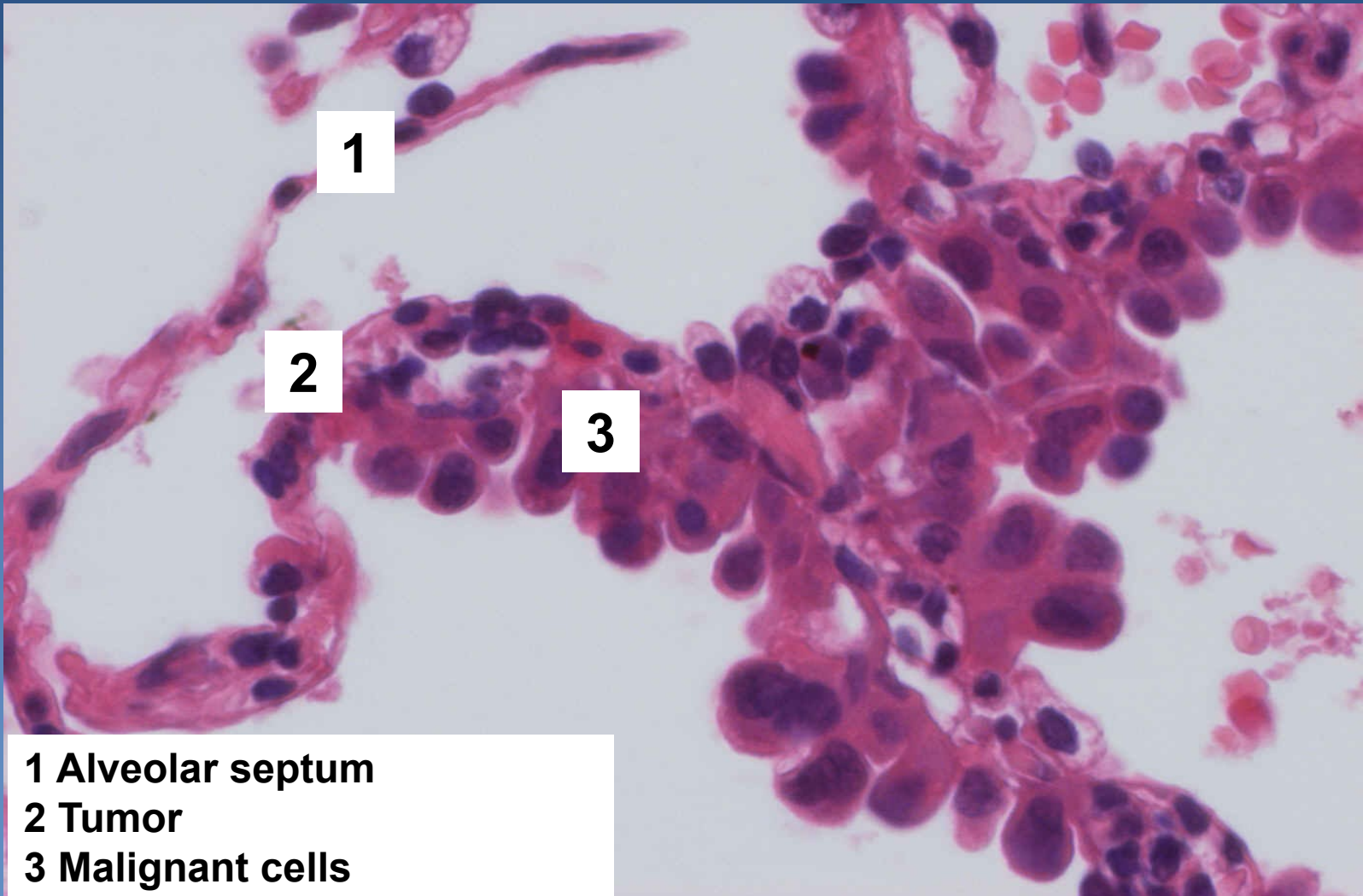
**2**

**1 Normal alveolar walls  
2 Alveolar walls with tumor cells**





# ***AIS/minimally invasive ACA non/mucinous (earlier BAC)***



- 1 Alveolar septum
- 2 Tumor
- 3 Malignant cells

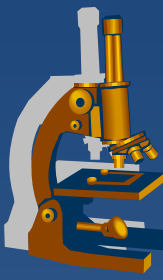




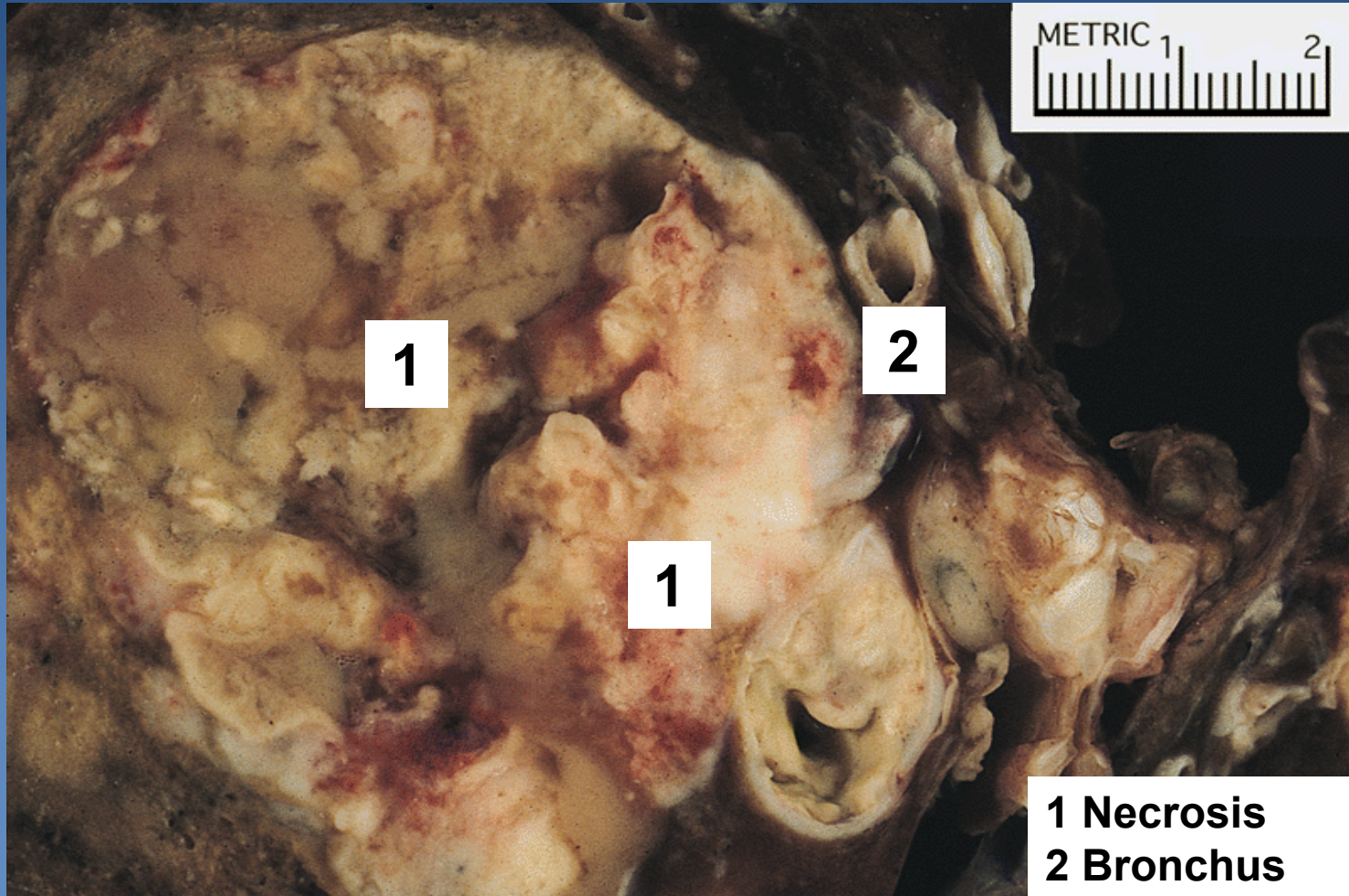
# *Large cell lung carcinoma*

---

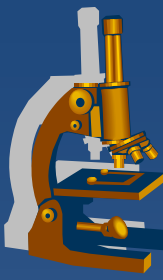
- x undifferentiated non-small cell carcinoma*
- x Micro:*
  - ⇒ atypical pleomorphic cells*
  - ⇒ absent features of small cell carcinoma, adenocarcinoma or squamous cell carcinoma*



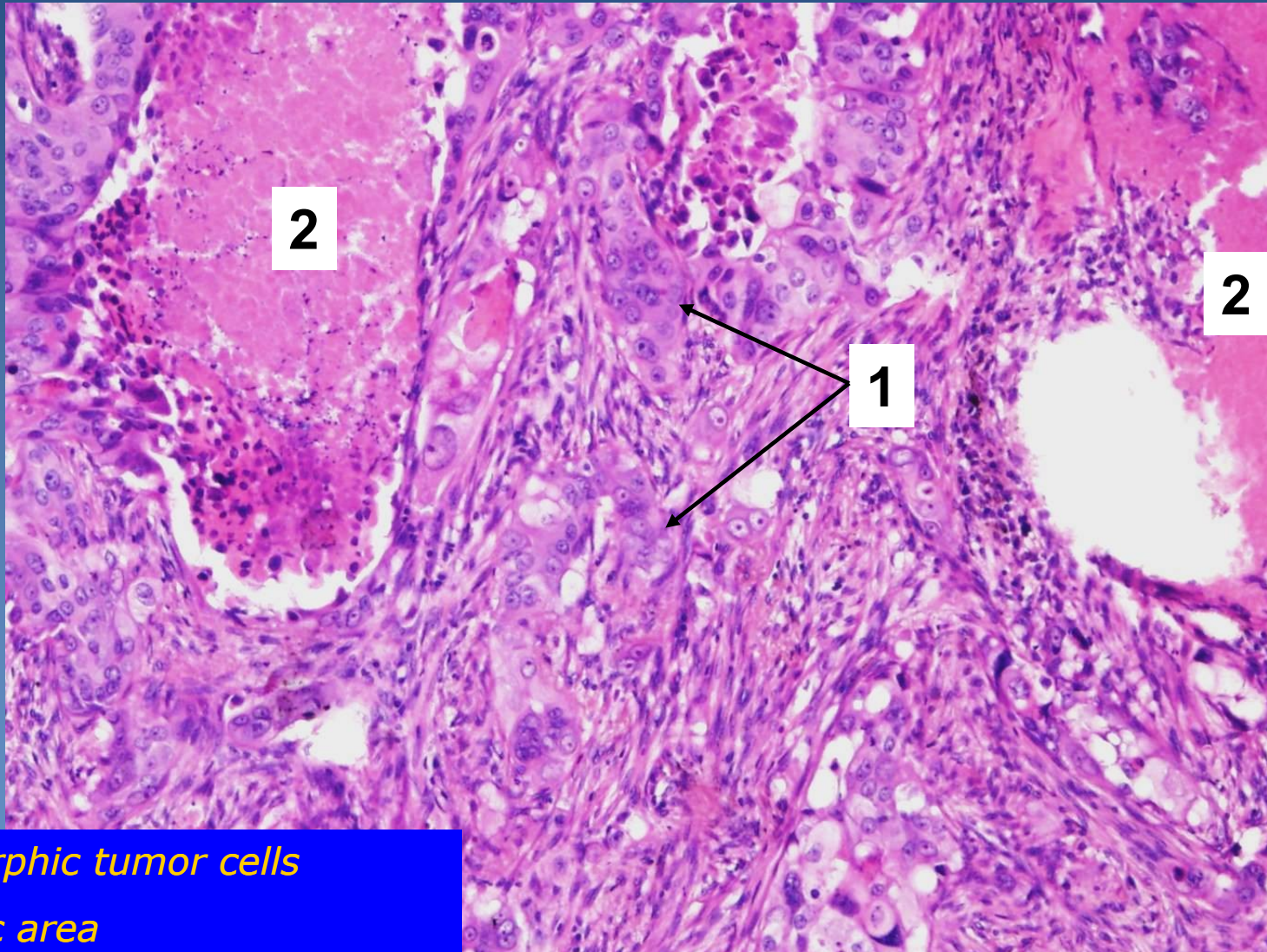
# *Large cell lung carcinoma*





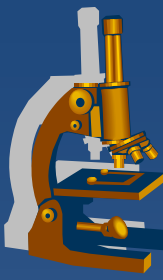


# *Large cell lung carcinoma*

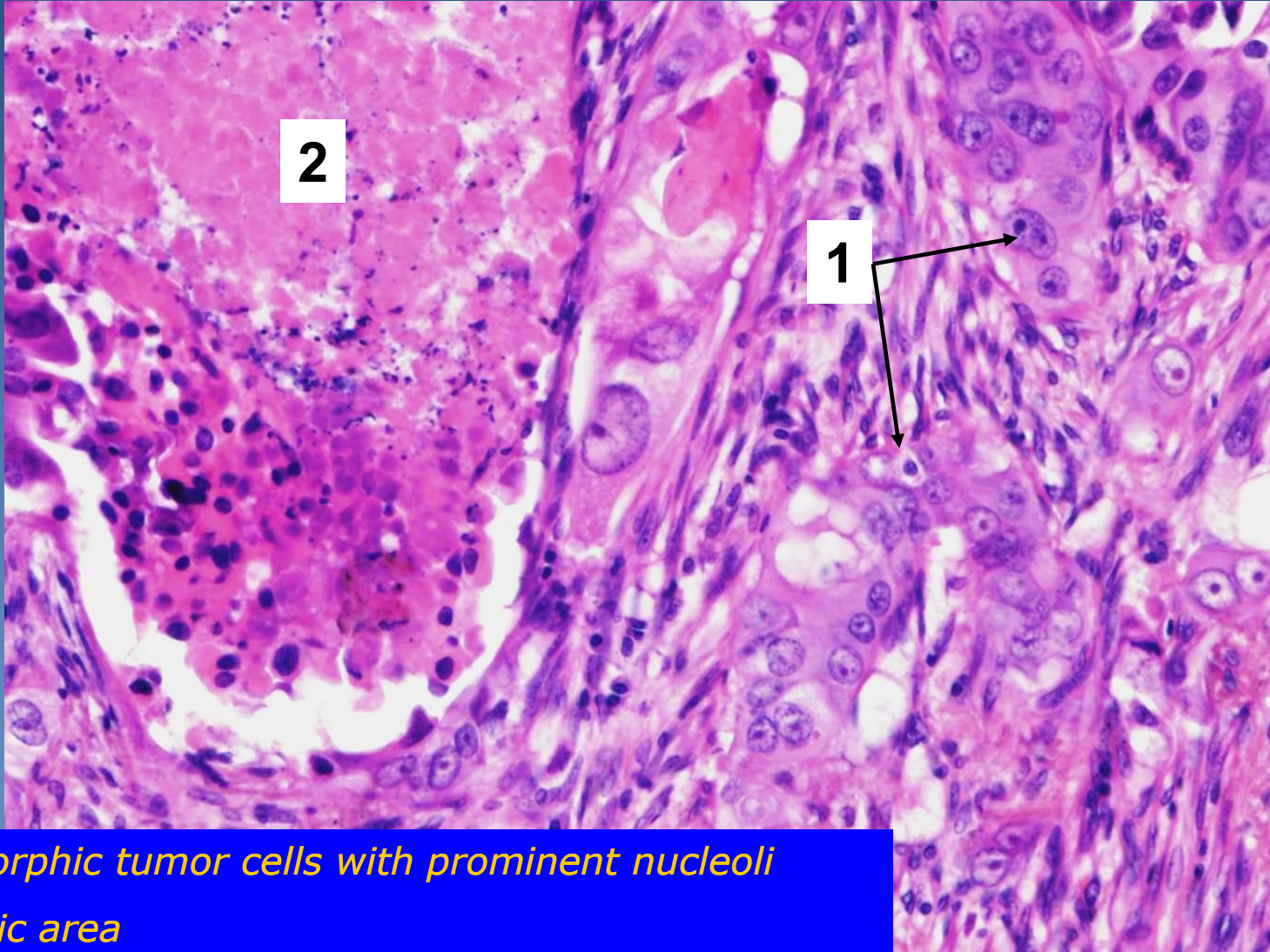


- 1. Pleomorphic tumor cells*
- 2. Necrotic area*





# *Large cell lung carcinoma*



- 1. Pleomorphic tumor cells with prominent nucleoli*
- 2. Necrotic area*

# Mesothelioma



- ✗ primary pleural tumor
- ✗ by far less common than secondary metastases of other tumors
- ✗ mostly malignant
- ✗ risk factor: chronic exposition to asbestos
- ✗ Gross:
  - ⇒ *localized form*
  - ⇒ *diffuse form*
- ✗ Micro:
  - ⇒ *epithelioid, sarcomatoid, biphasic, desmoplastic*