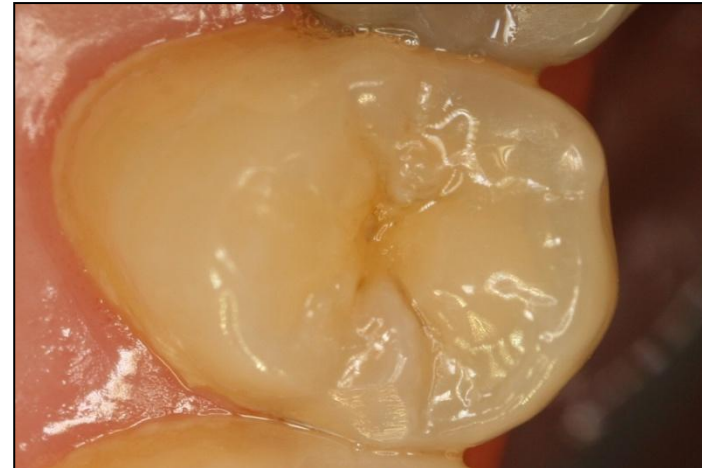


Class II.

Location:

Defects affecting one or both proximal surfaces of posterior teeth.



Proximal surface in posterior area

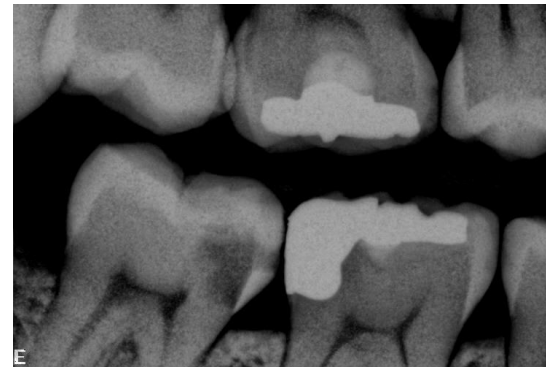- Proximal surface is caries danger area (below the contact point) – high plaque accumulation
- Interdental space is infilled with interdental papilla, that moves apically during the time and the space is open
- Dental caries originates below the contact point.

Class II.

Origin:

Proximal surface below the contact point

Propagation of dental caries from
the occlusal surface

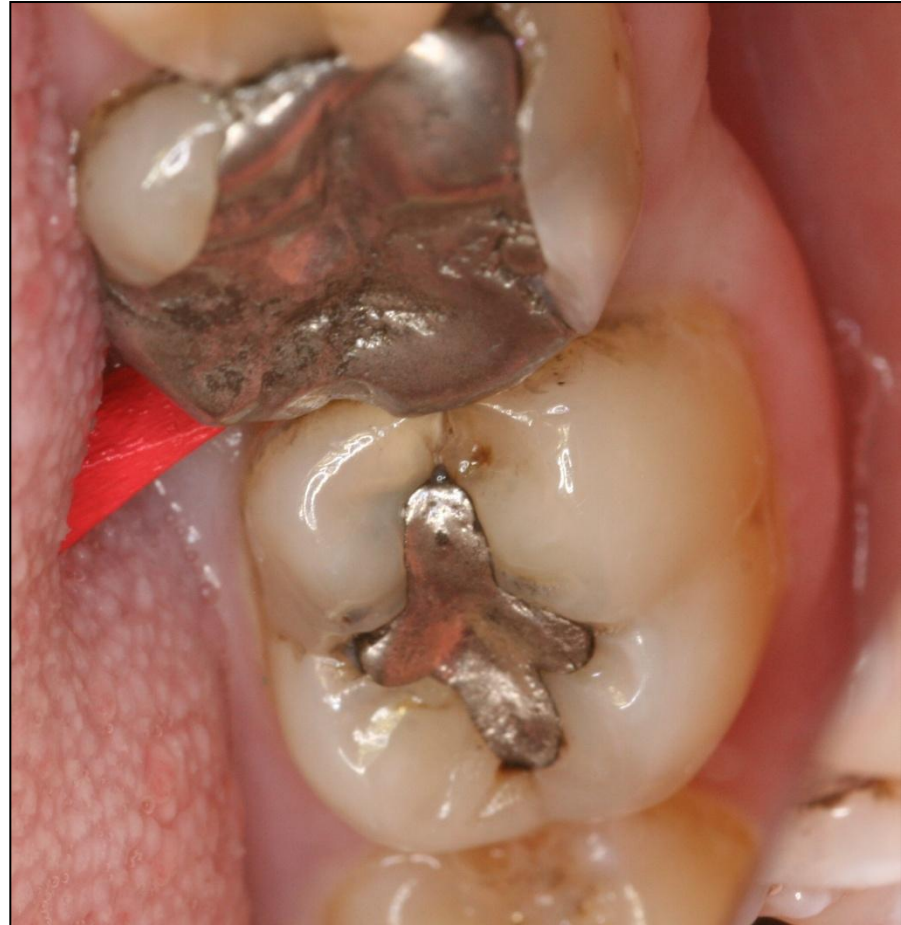
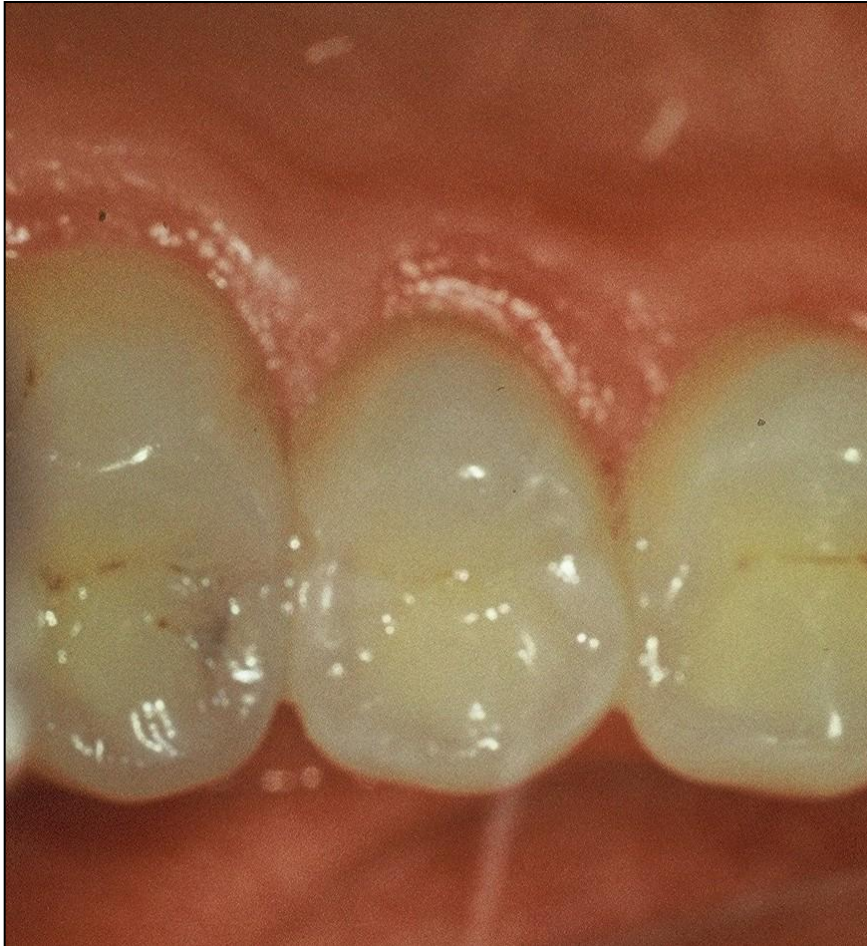
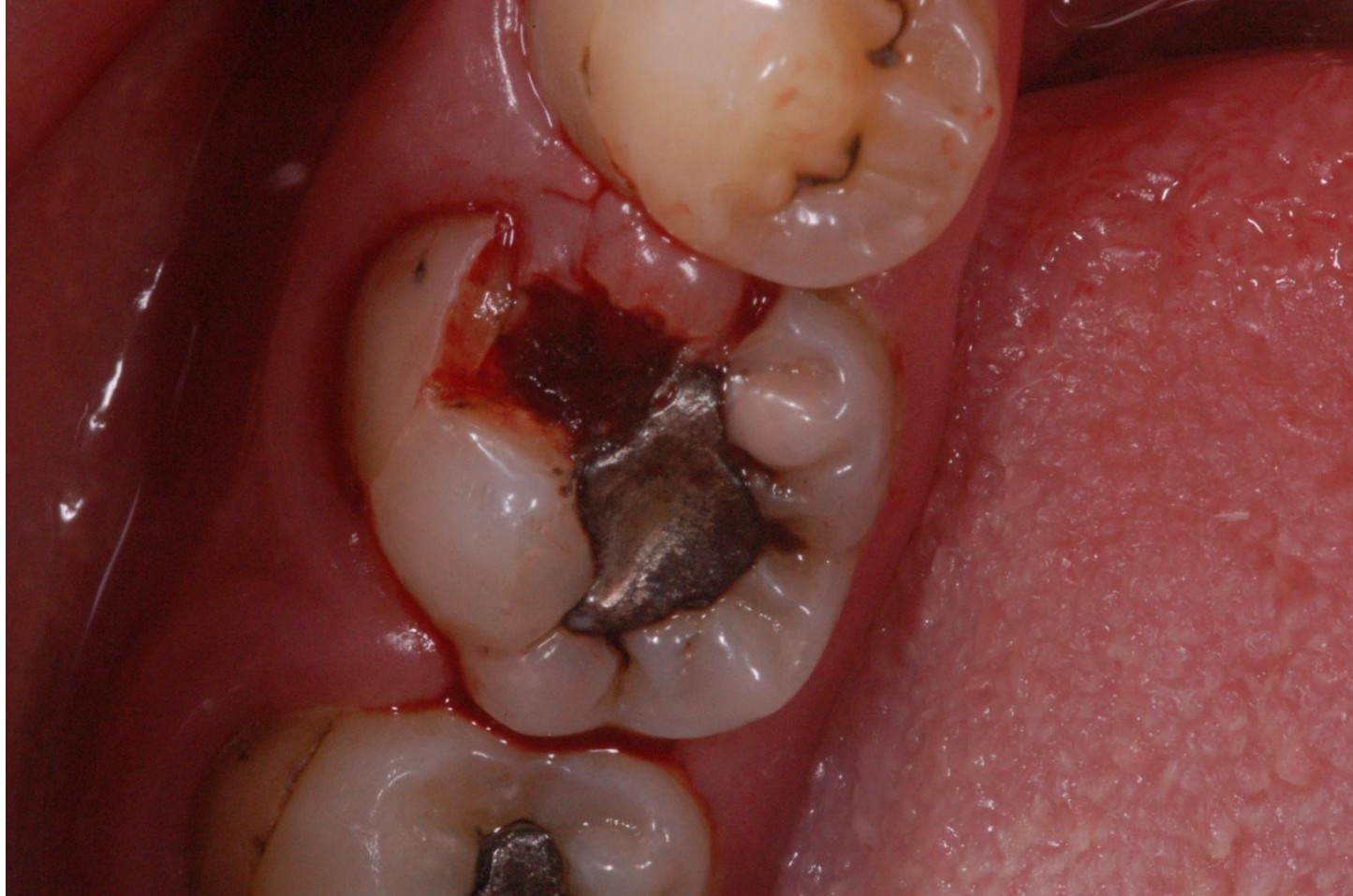Symptoms

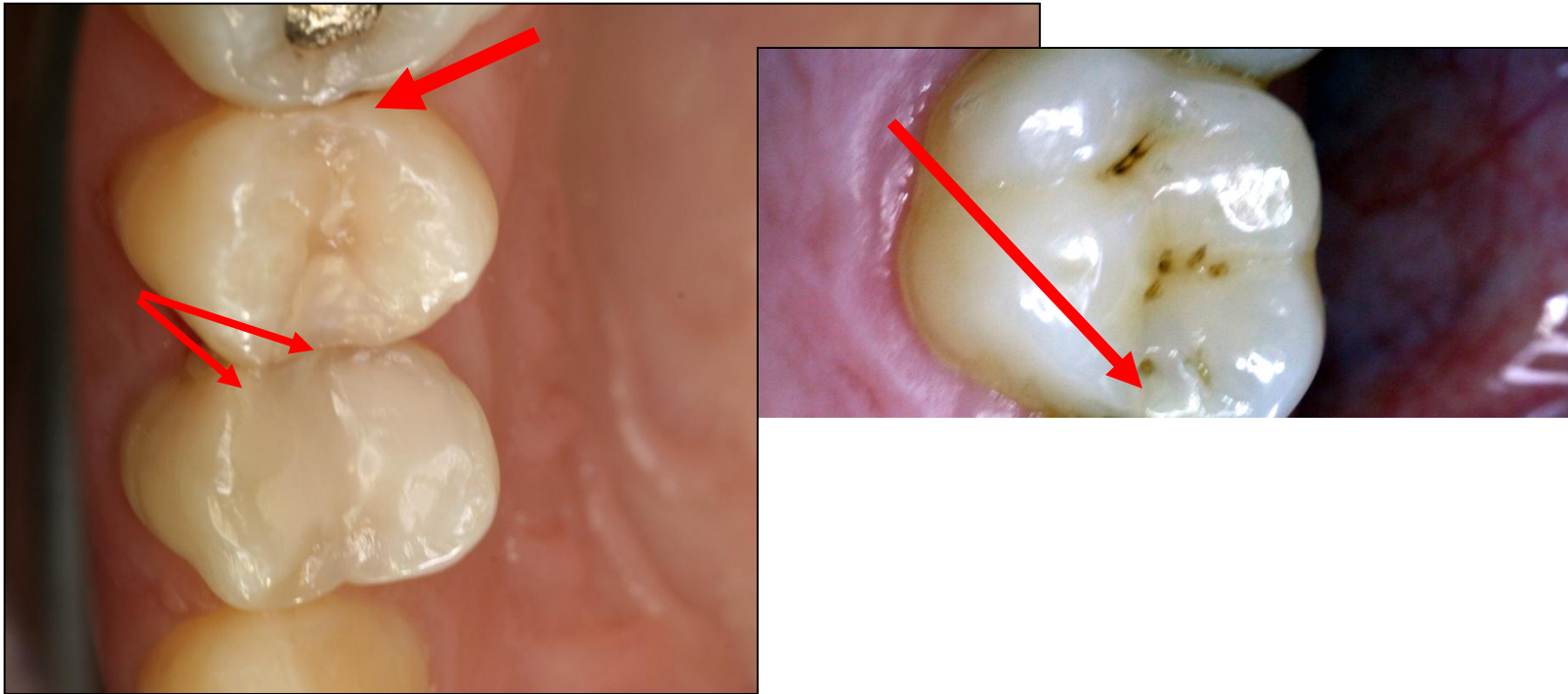
- No symptoms
- Increased sensitivity (cold, sweet)
- Retention of food
- Defect (cariou lesion is open – the enamel is broken)
- Bite sensitivity (when cariou lesion is open)

Diagnosis

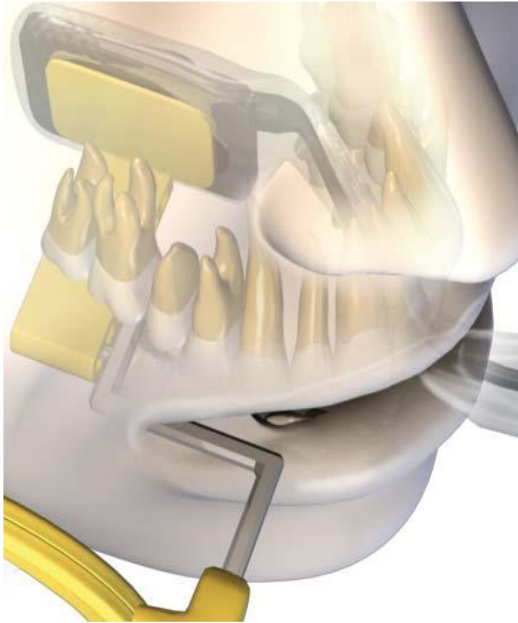
- Visual changes of tooth structure (chalk white colour).
- Transillumination (white light, or Diagno Cam).
- Radiography



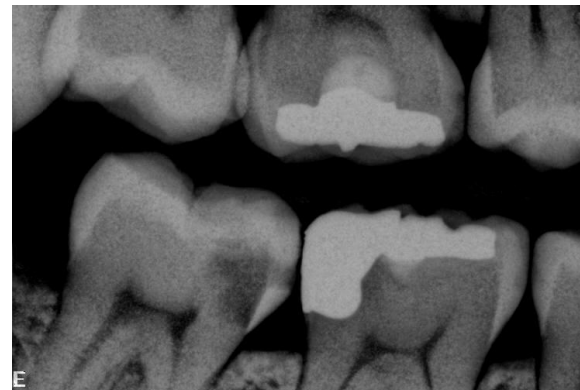
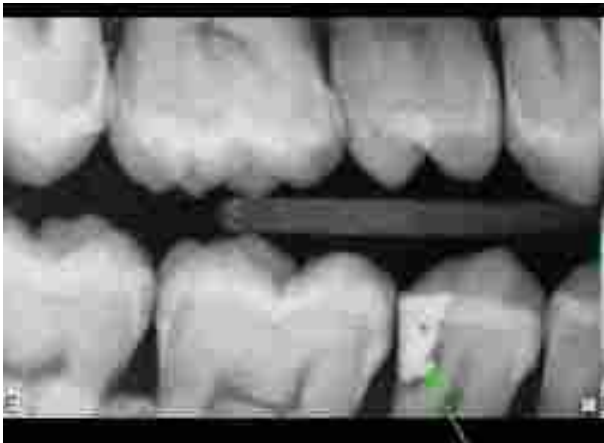


Bite wing projection



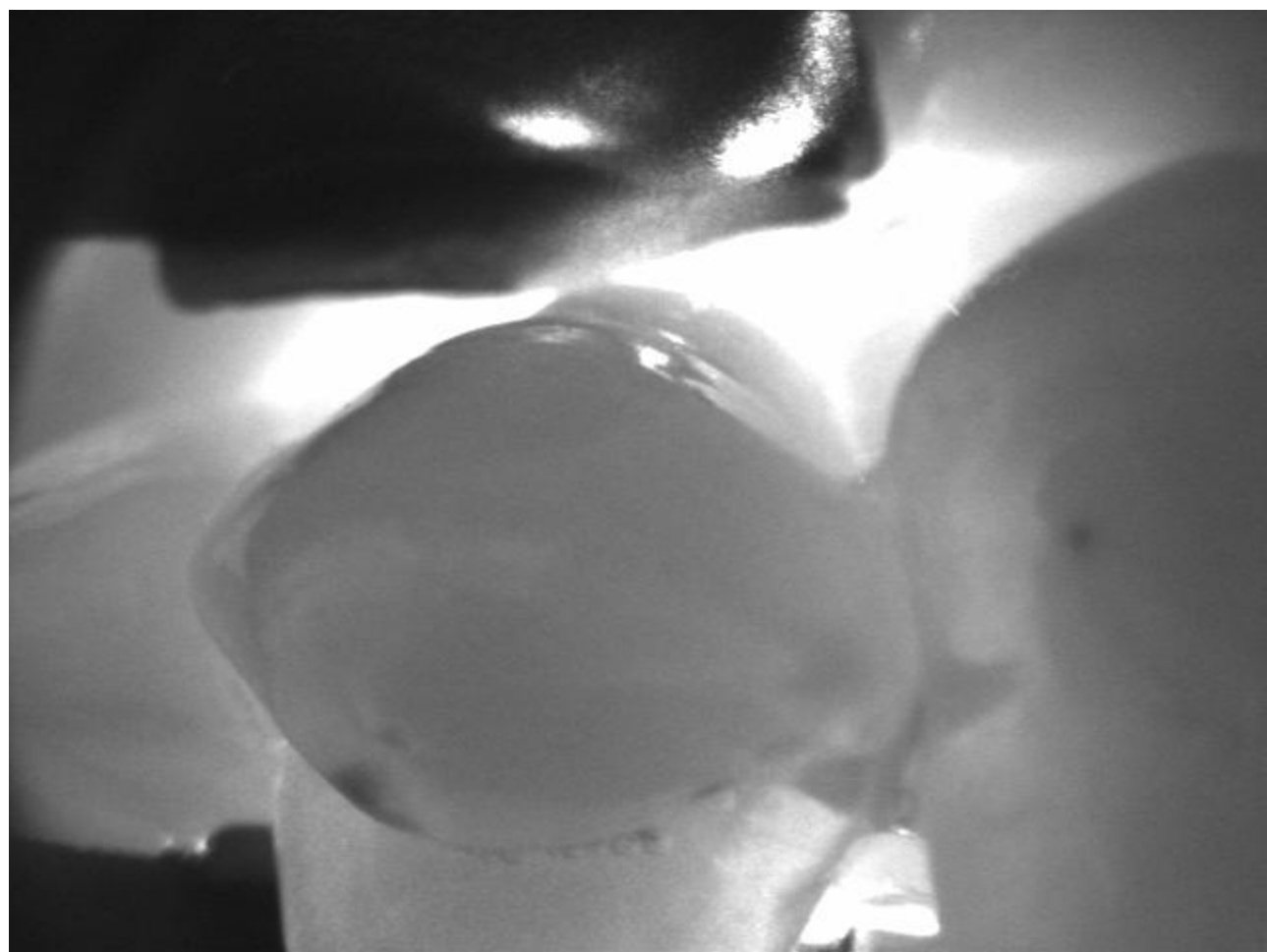
The sensor is placed in a special holder
Central beam goes perpendicular
to the sensor as well as the long axis of the tooth
And parallel with interdental septa

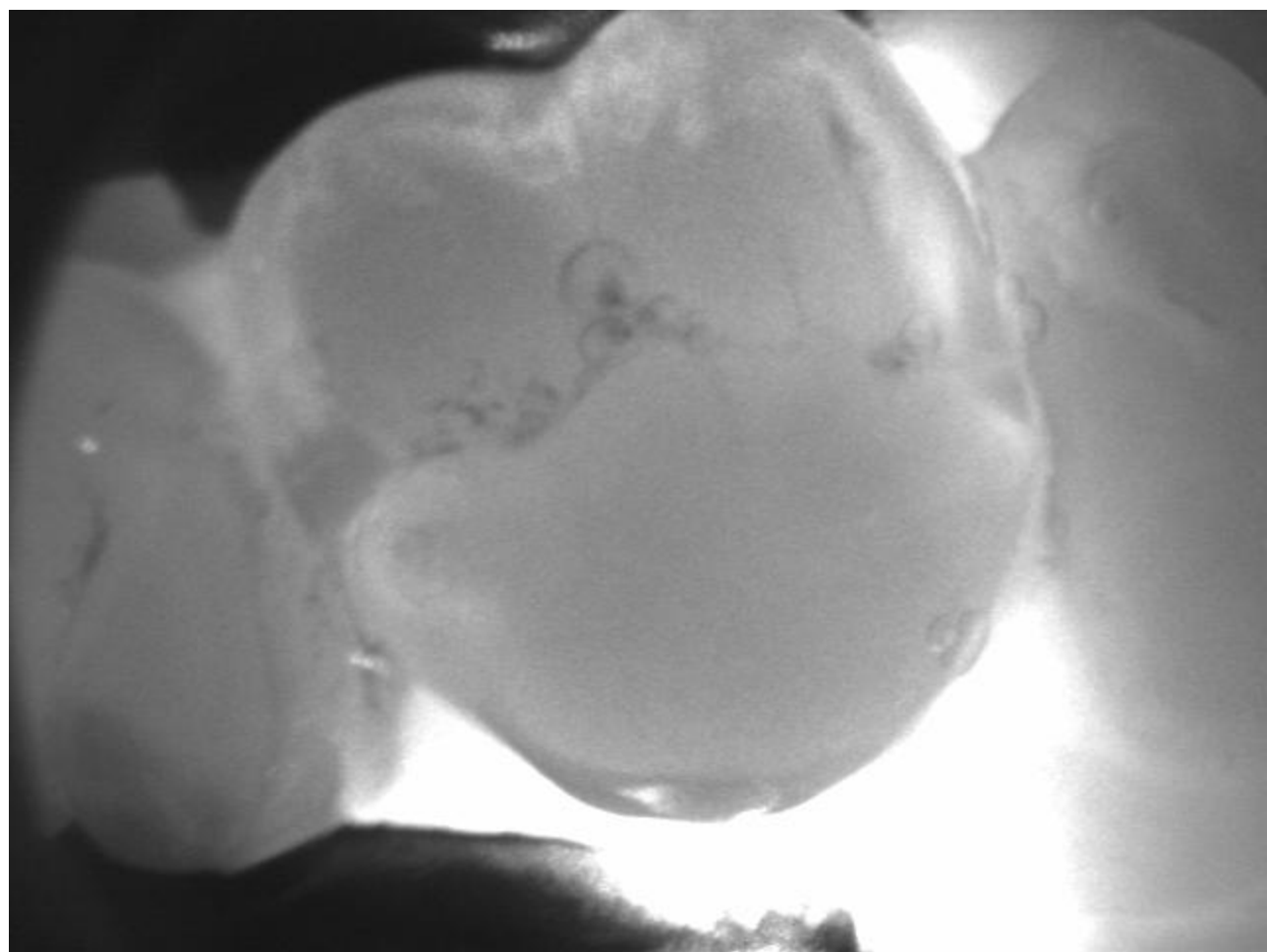


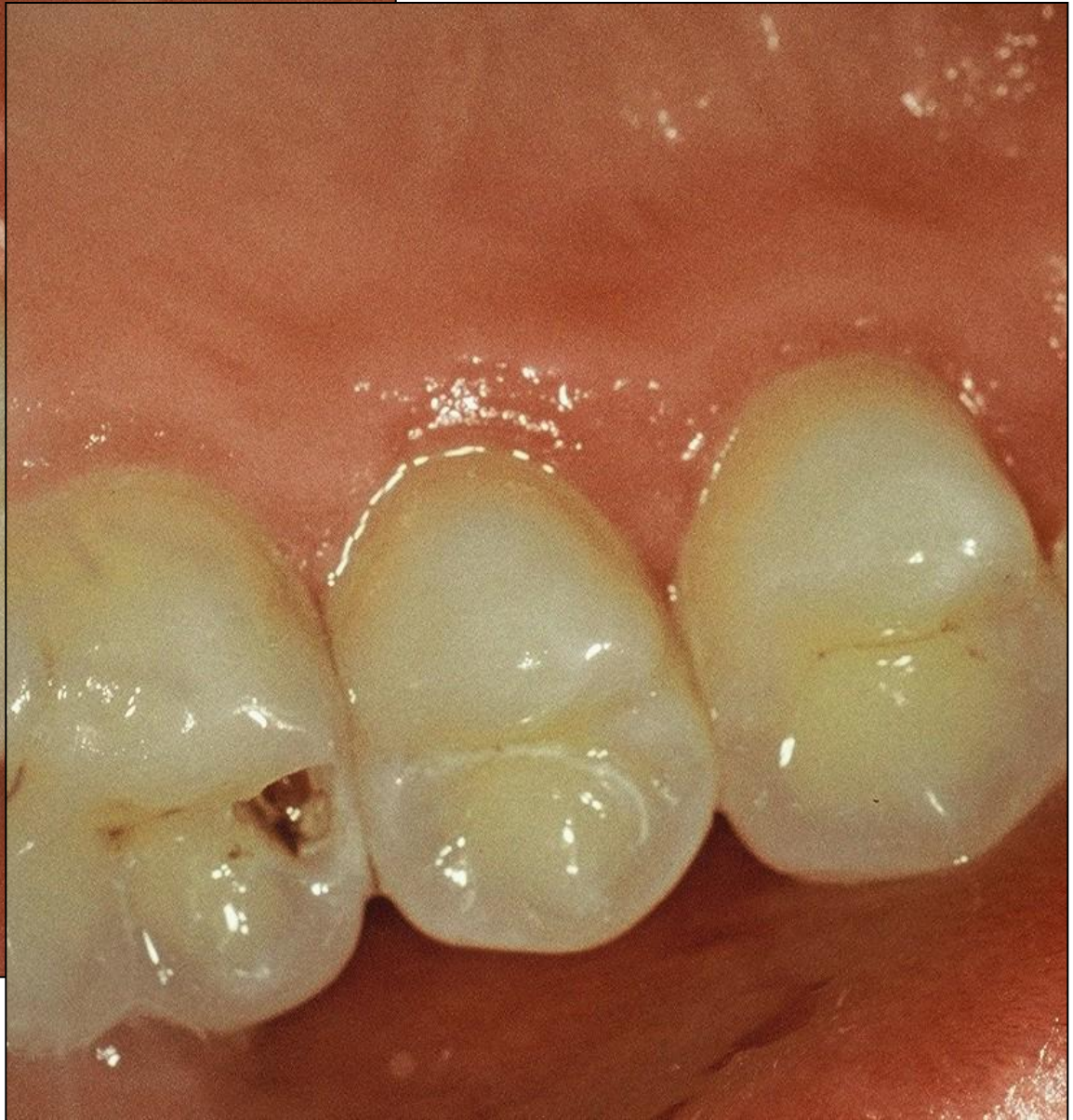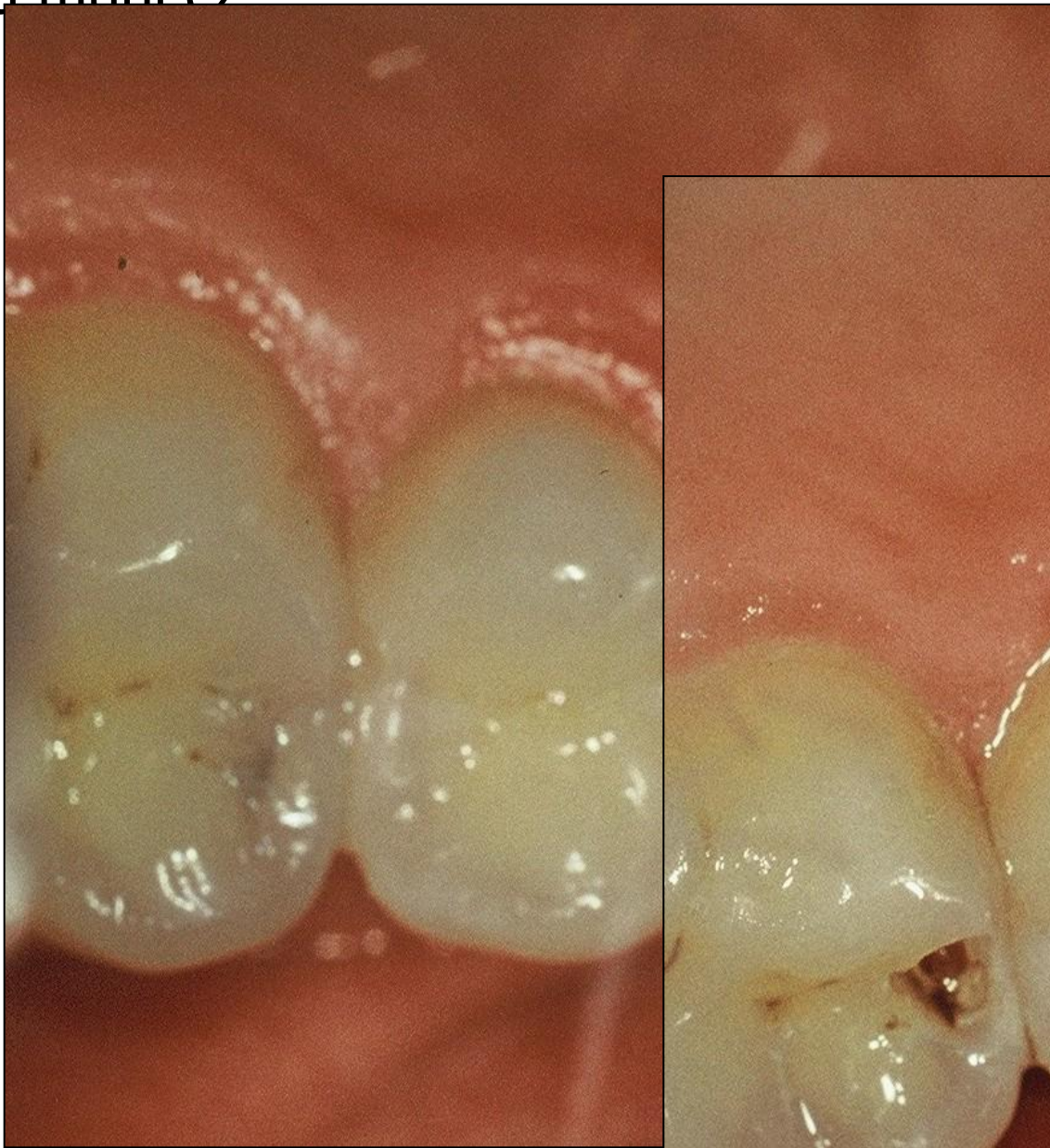DIAGNOCam

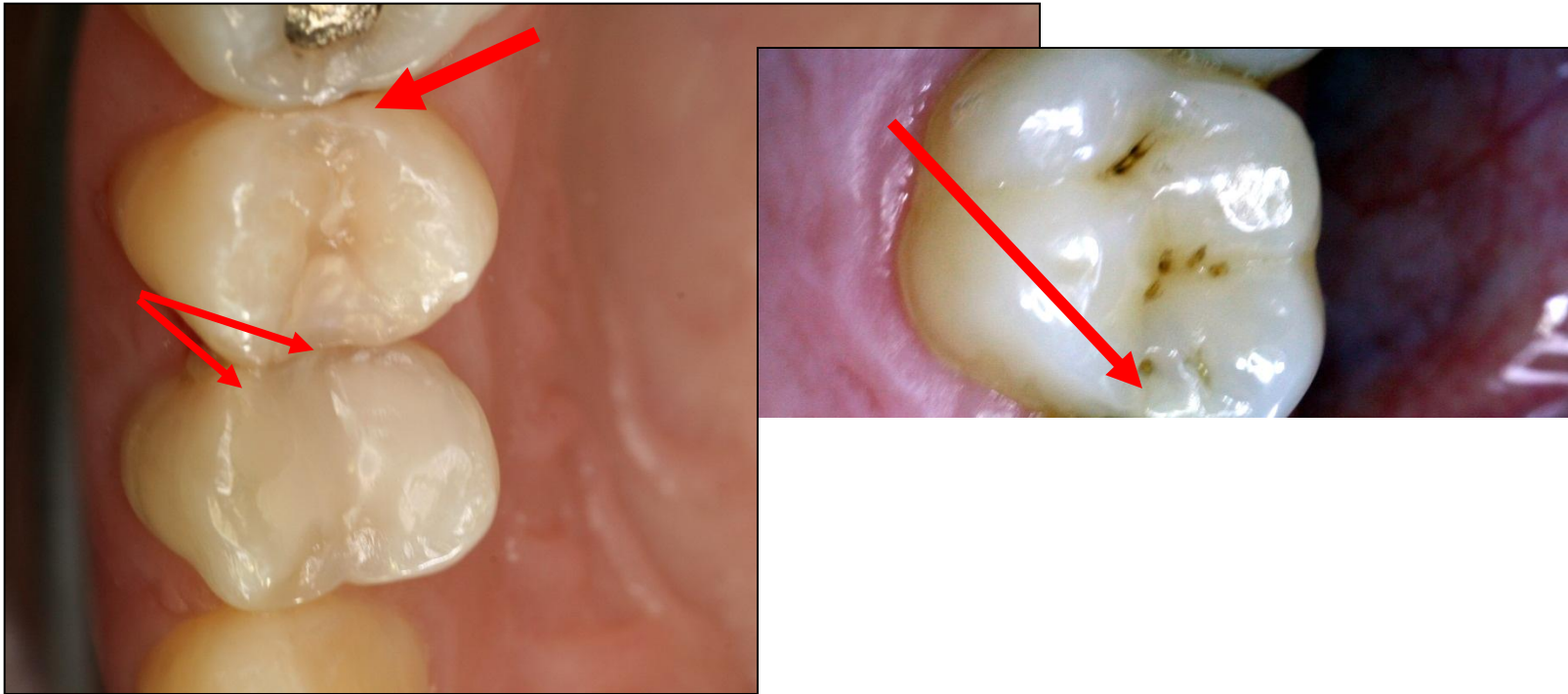
Transillumination using infrared transillumination – near infrared NIR





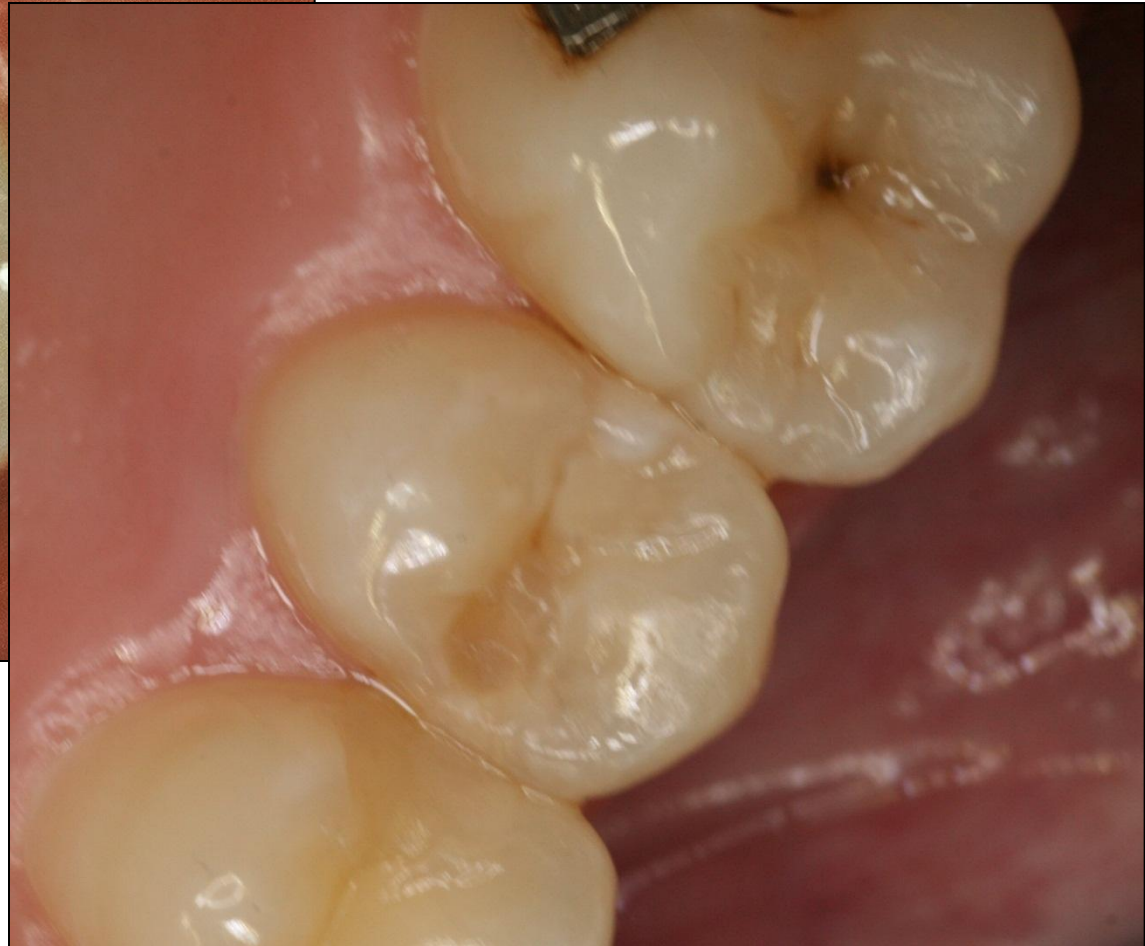
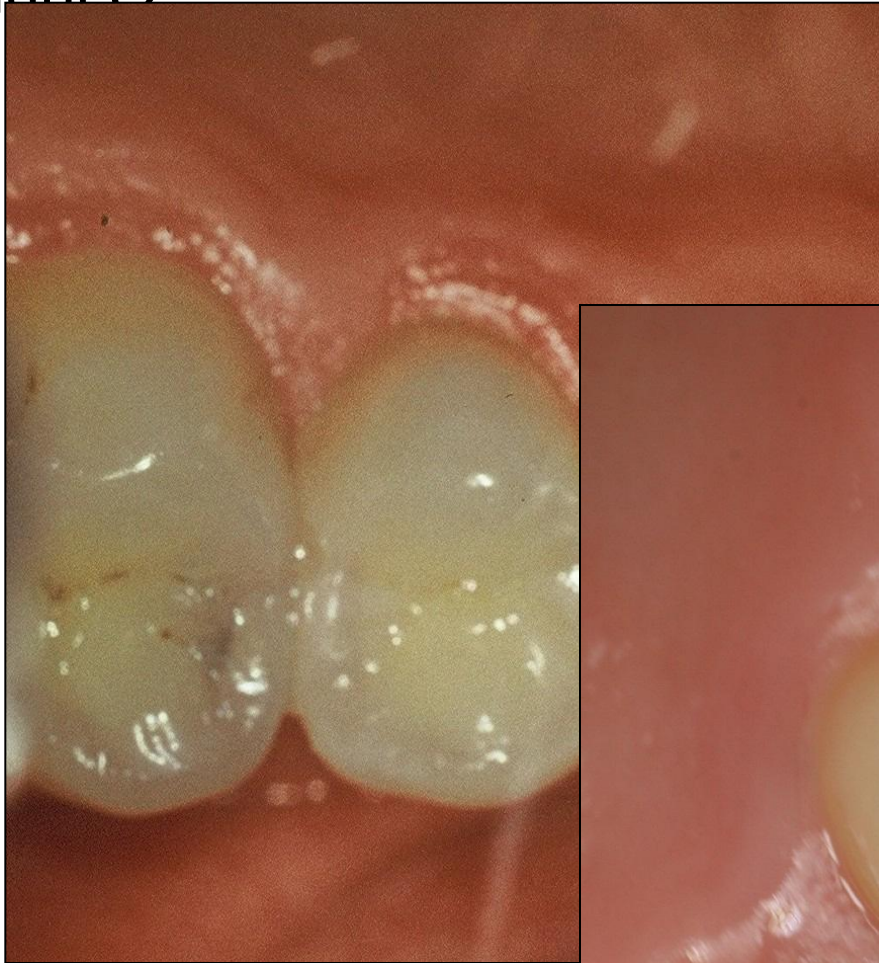
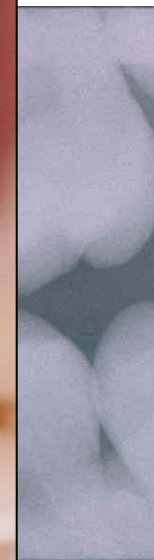
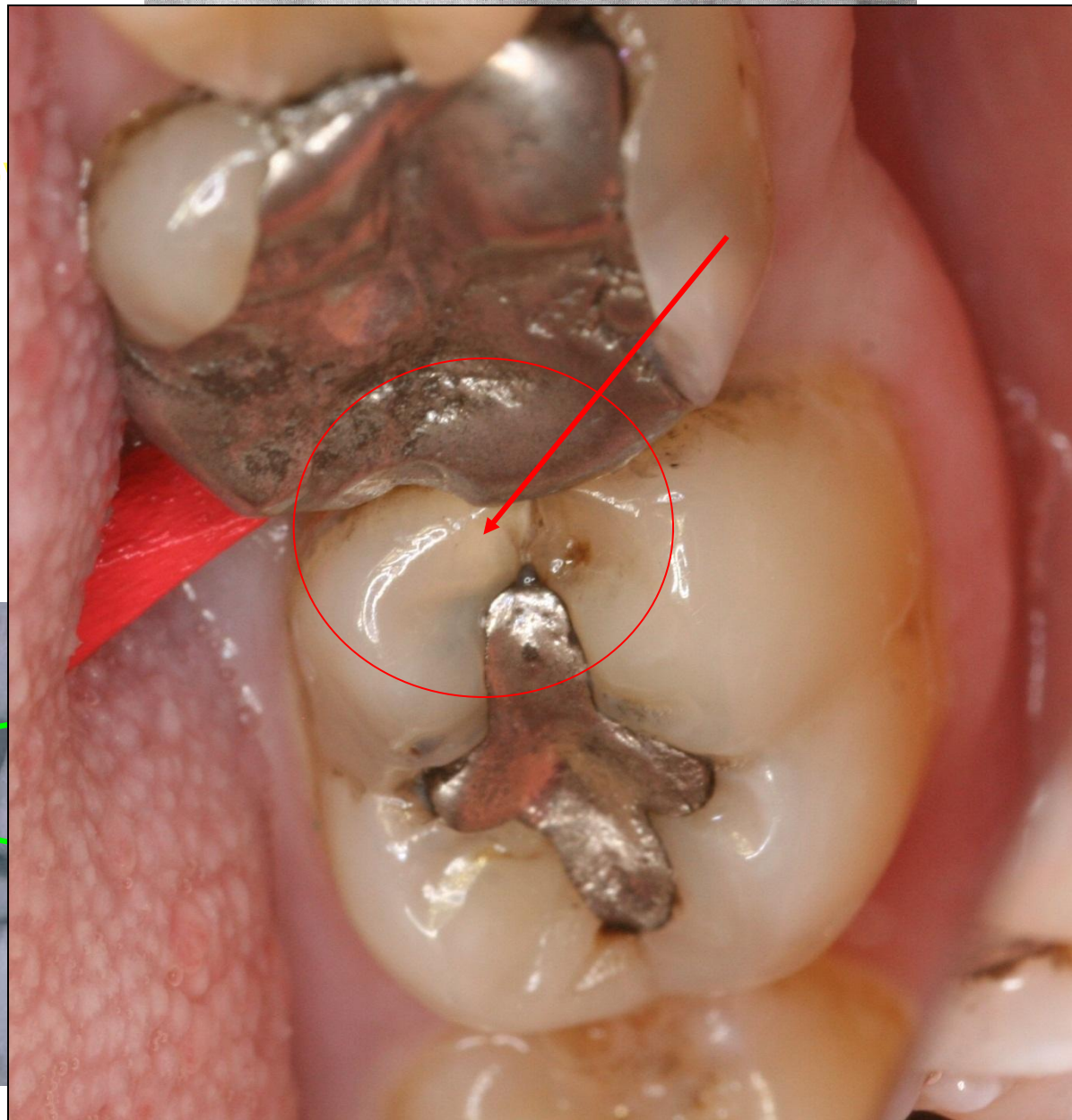
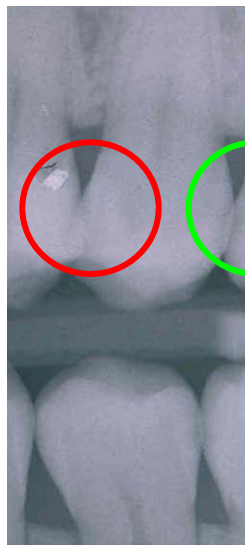








4 stupňo
grading



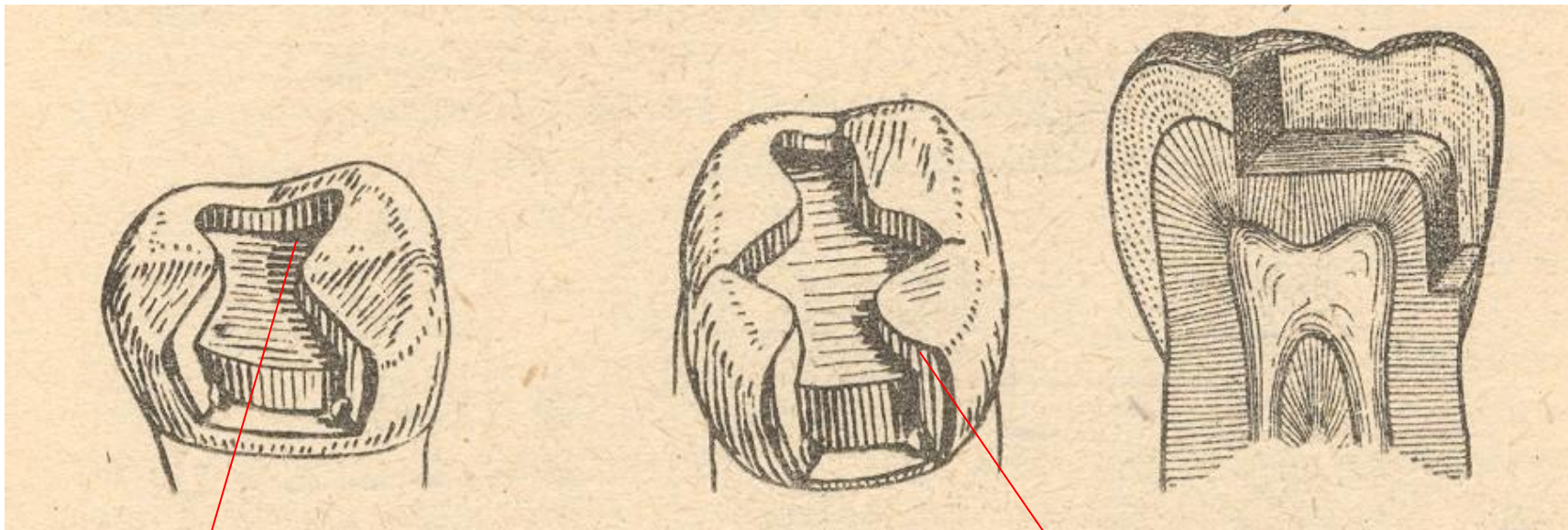
Preparation

- Conventional preparation
- Slot preparation
- Large preparation – cusp(s) involved

Preparation - adhesive materials (composites, glass ionomers)

- Conventional preparation for composites
- Adhesive slot
- Tunnel preparation

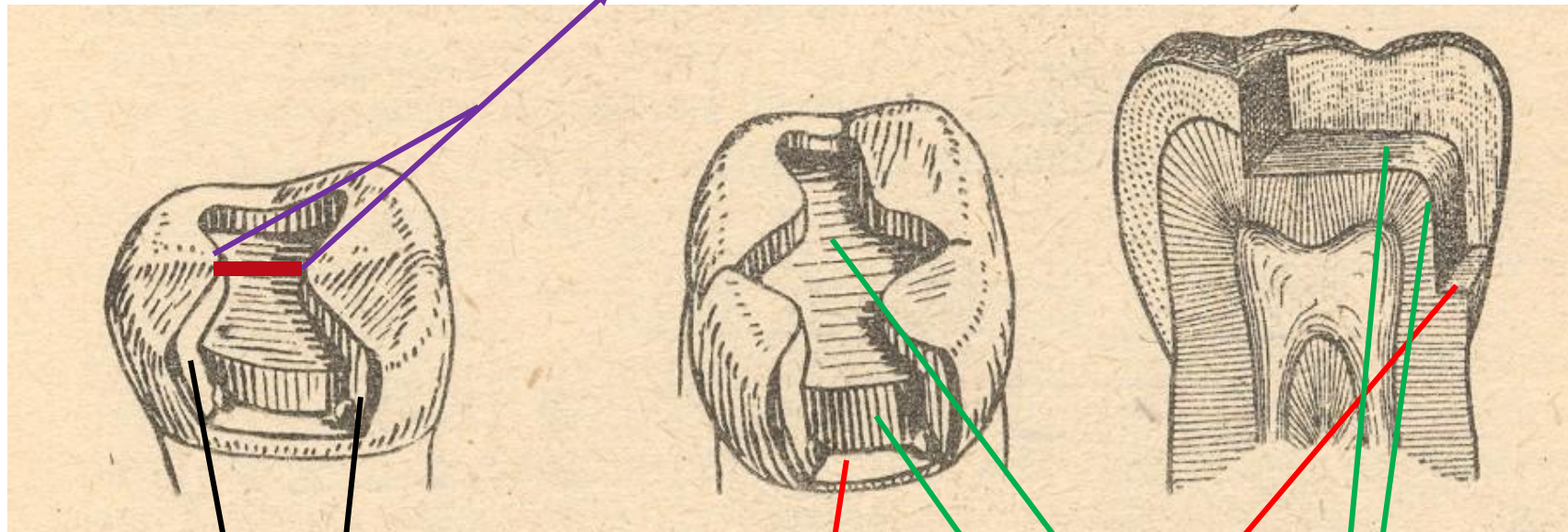
Conventional preparation amalgam



Occlusal cavity

Proximal cavity - box

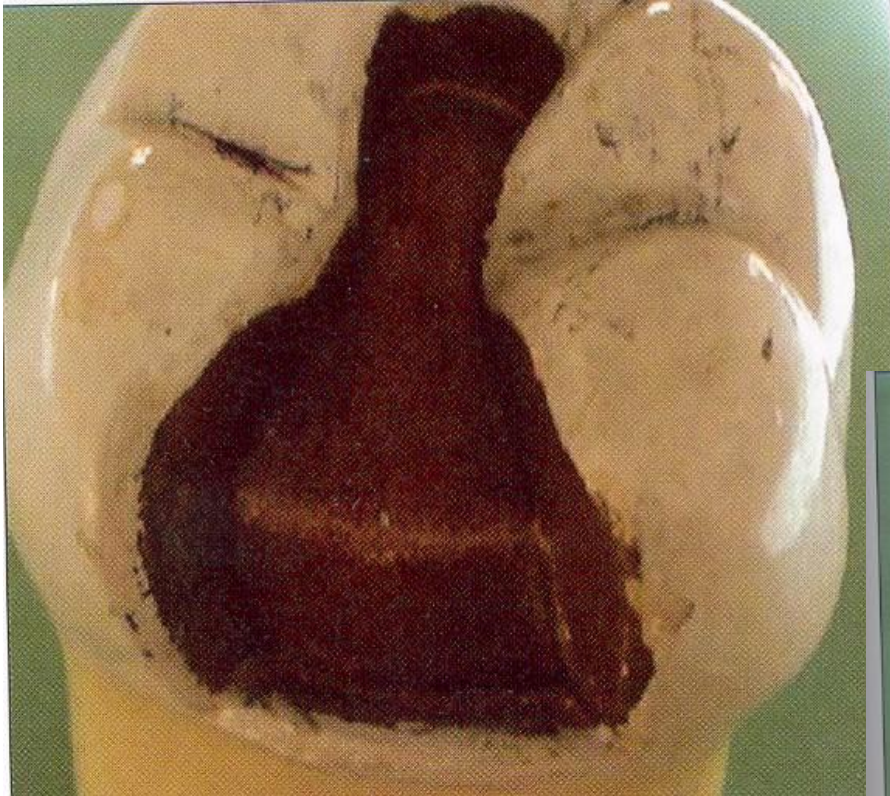Isthmus



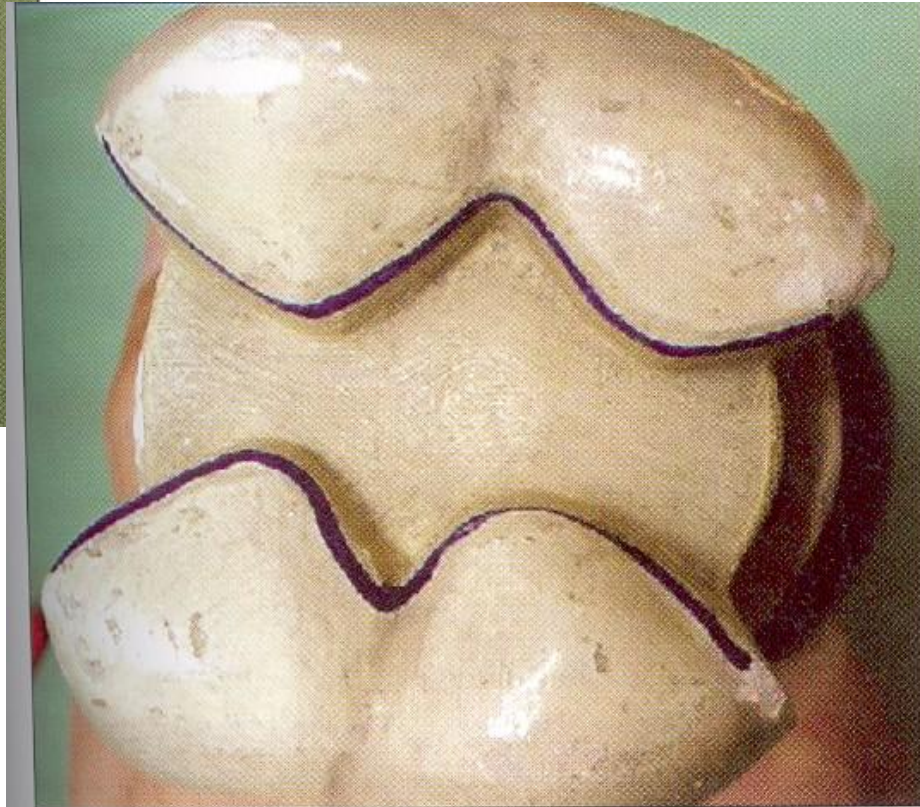
Axial wall

Gingival wall

Pulpal walls



MO, OD: one proximal surface affected – mesio occlusal distoocclusal



MOD: mesiodistoocclusal

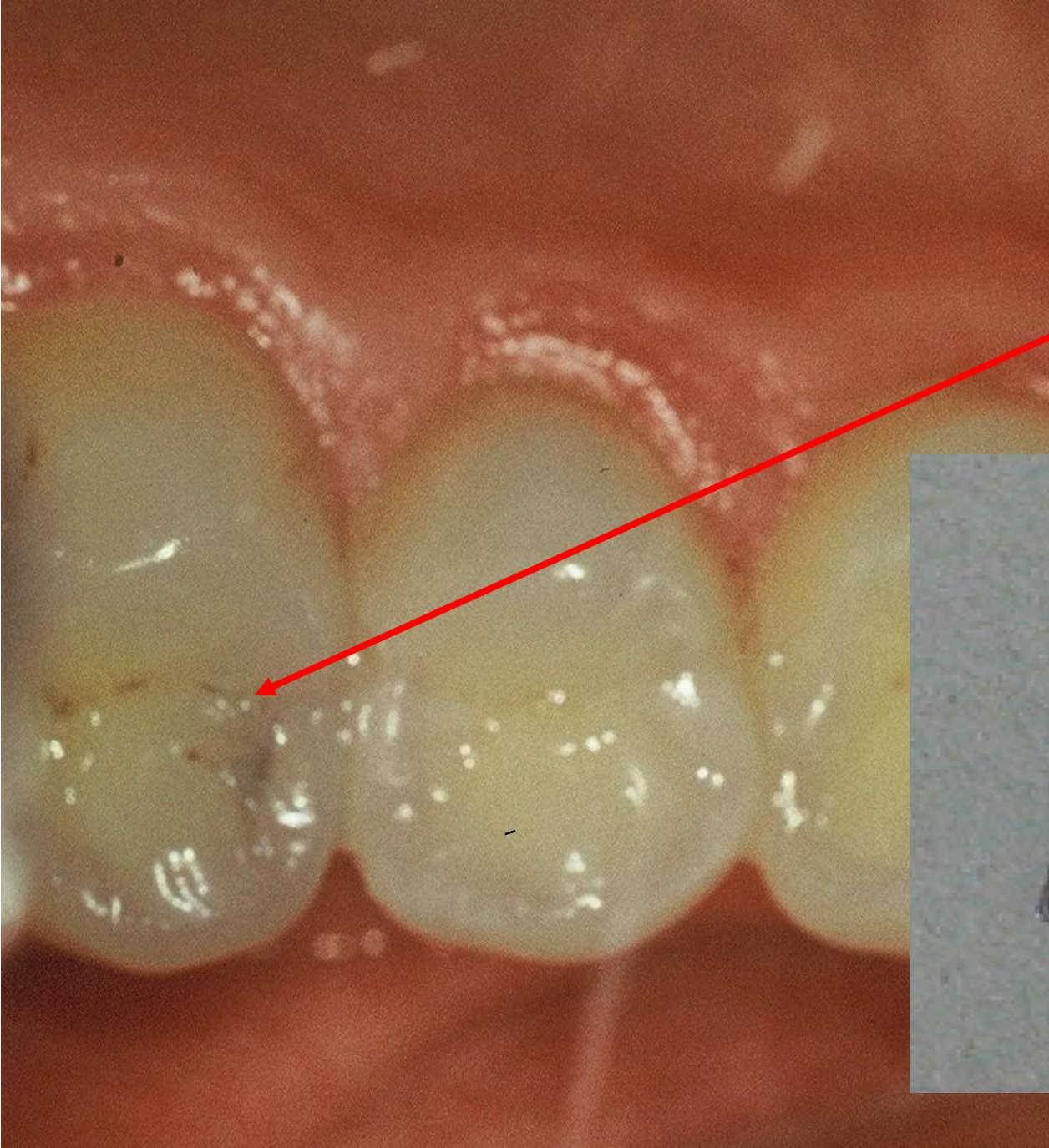
Access to the cavity

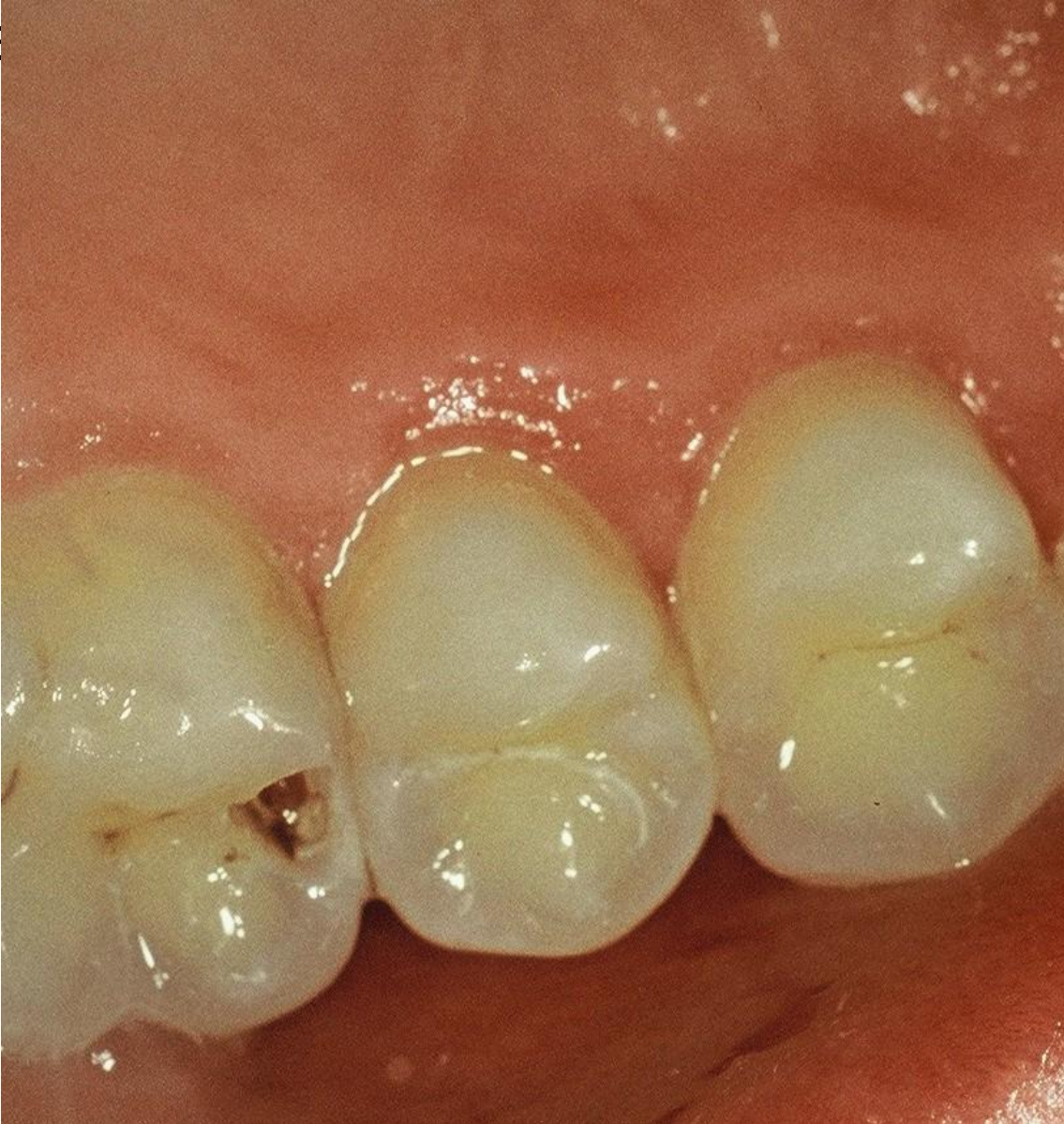
From the occlusal surface

Through the undermined enamel

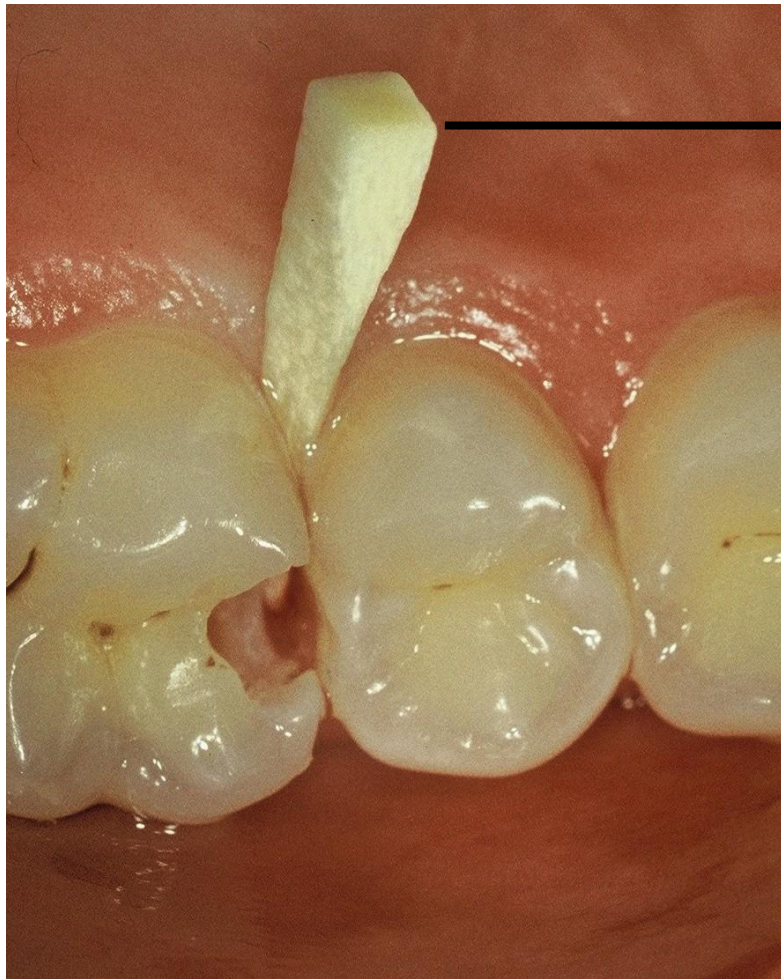Separation using wooden wedges is useful

Pre op

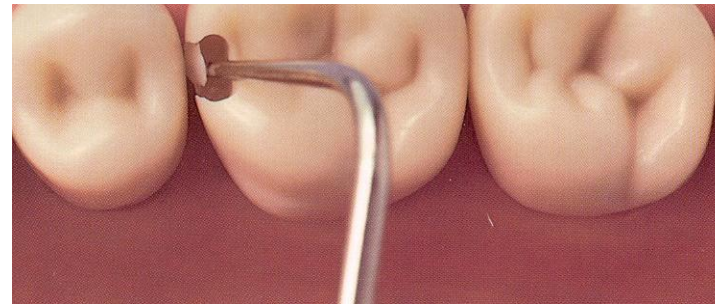




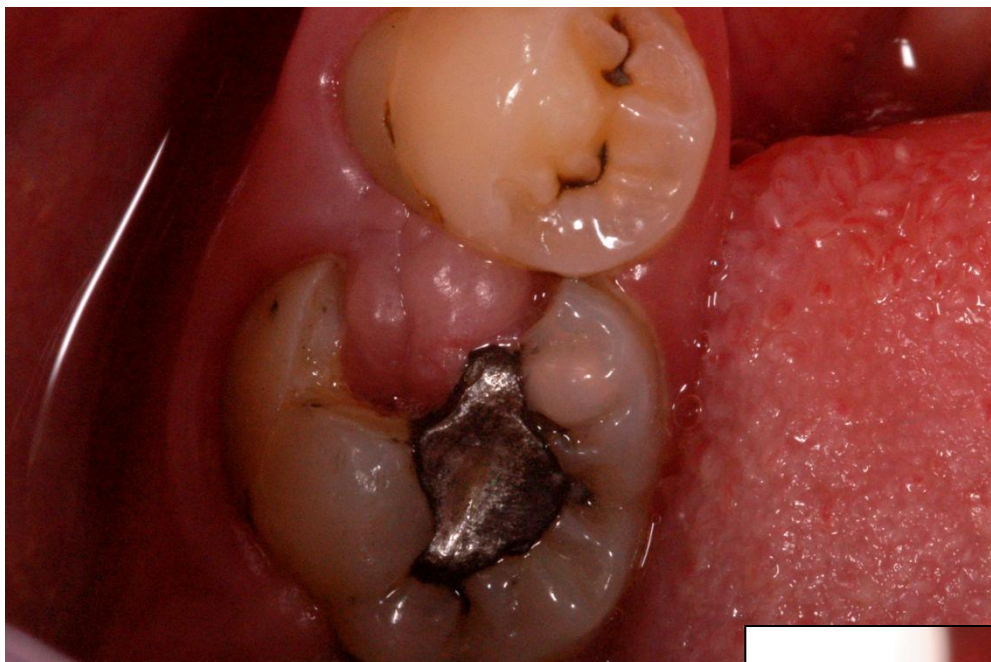
Access to the cavity



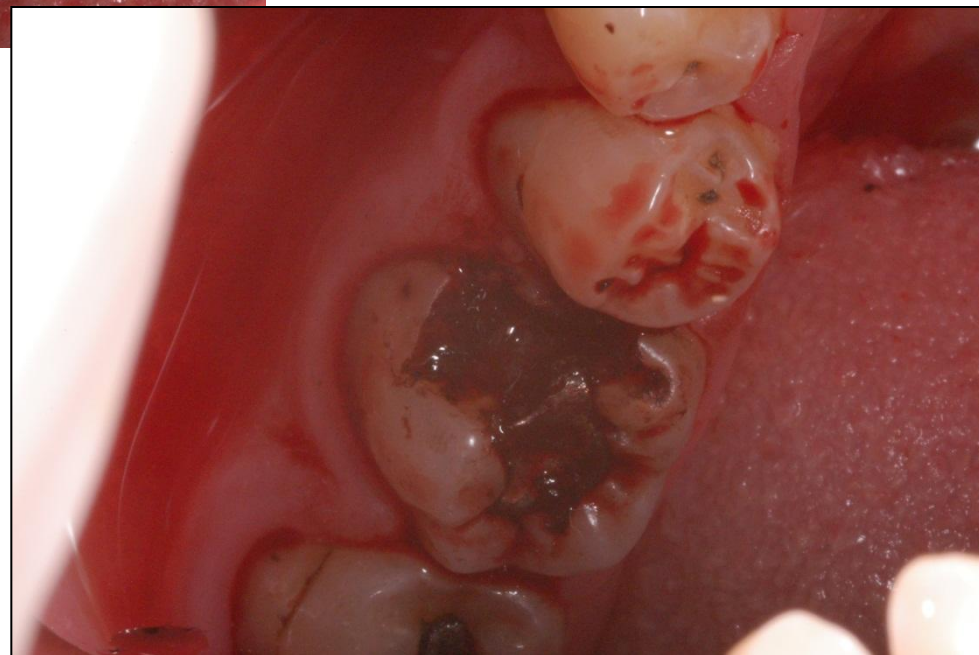Wooden wedge



Breaking the thin enamel layer out of the cavity



➤ Remove of the gingiva that grows into the cavity



Cavosurface margin and extention for prevention

Proximal box:

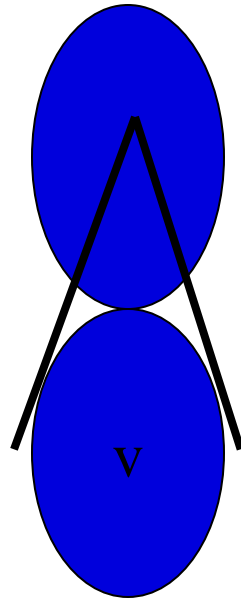
Vestibullary and orally – axial walls (the border between the oral/vestibular and proximal surface.

Below the free gingiva (0,5 mm)

Occlusal

Class I.

American rule



Tangents from the middle of treated tooth to the next tooth – where these cross the treated Tooth there are borders of the preparation

Retention - macroretention for amalgam

➤ Occlusal cavity

➤ Undercuts

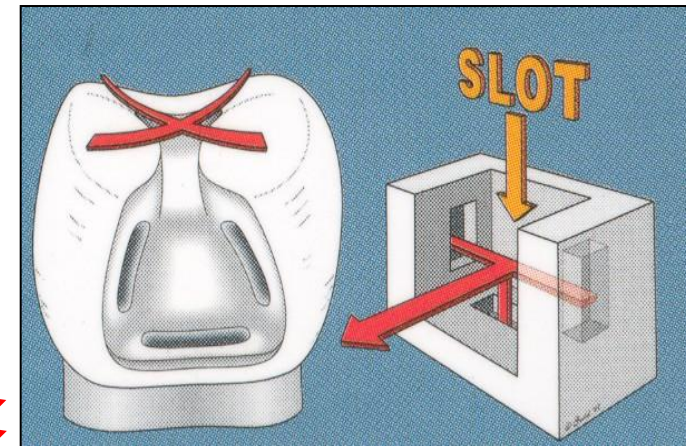
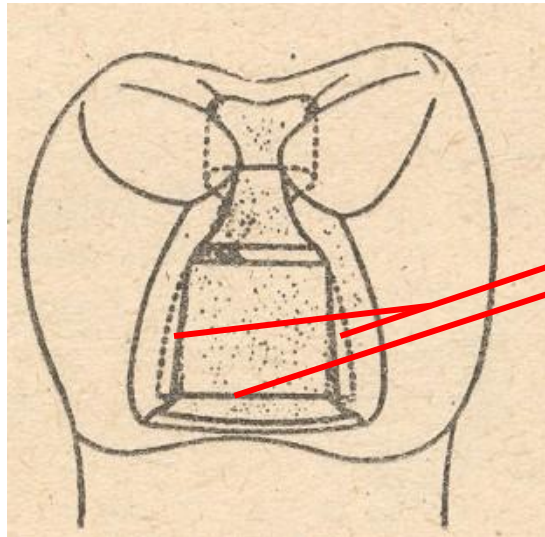
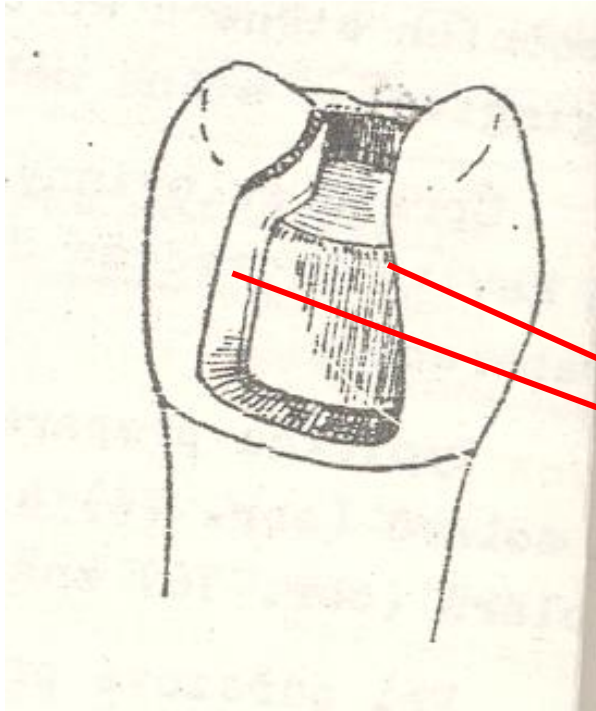
➤ Grooves

Proximal cavity – box

Slight divergency of axial walls

Gingival wall follows the cementsoenamel junction

Gingival wall is below free gingiva



Autoretention

Grooves

For amalgam only !

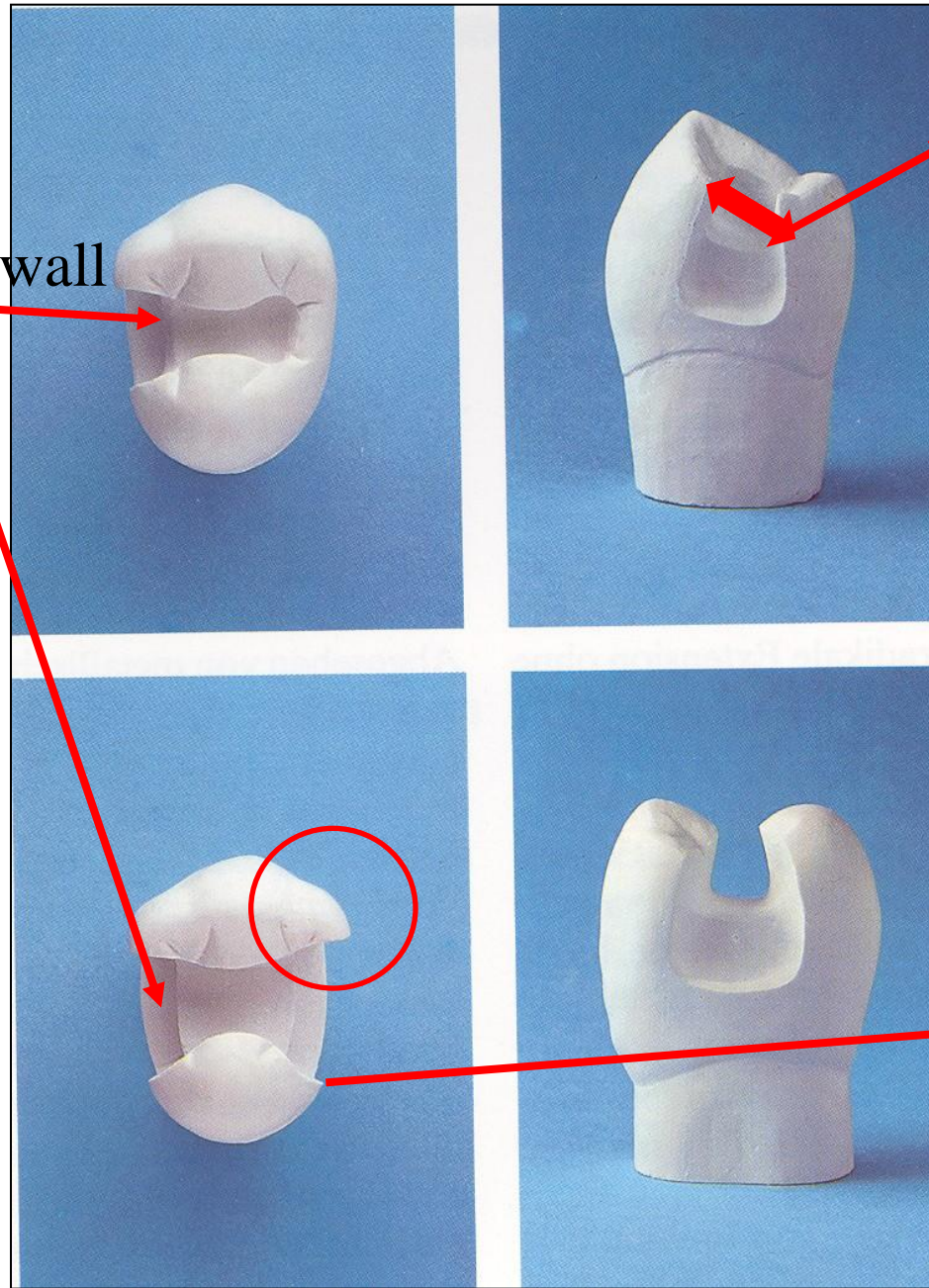
Retention - microretention for composite

- Removal of the aprismatic enamel
- Bevel enamel on axial walls and outer edge of the gingival wall
- Do not bevel the enamel in the occlusal cavity

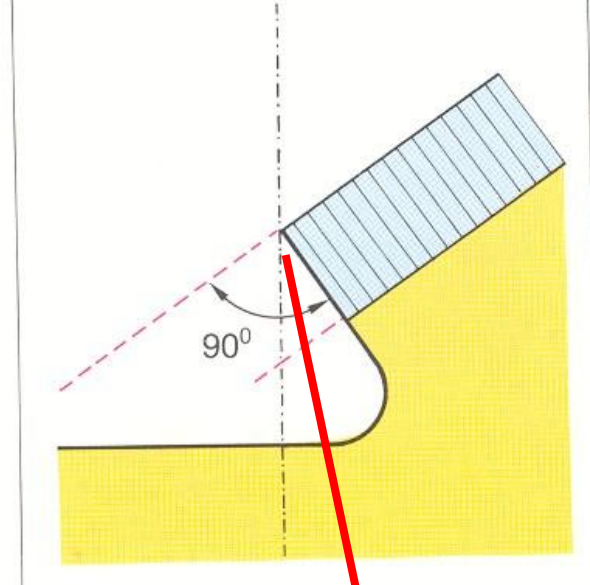
Resistance

- No undermined enamel
- No sharp edges
- Isthmus is $1/3 - 1/4$ intercuspidal distance
- Angle between axial and gingival wall: 90° , or 85°
- Width of gingival wall is 1 mm at least
- Thickness of the filling 2 – 4 mm (4mm if cusp replacing)

Gingival wall



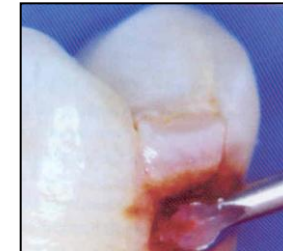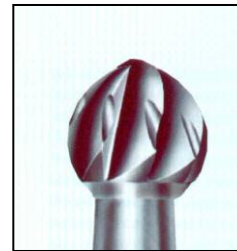
Isthmus



Cavosurface angle

Excavation of carious dentin

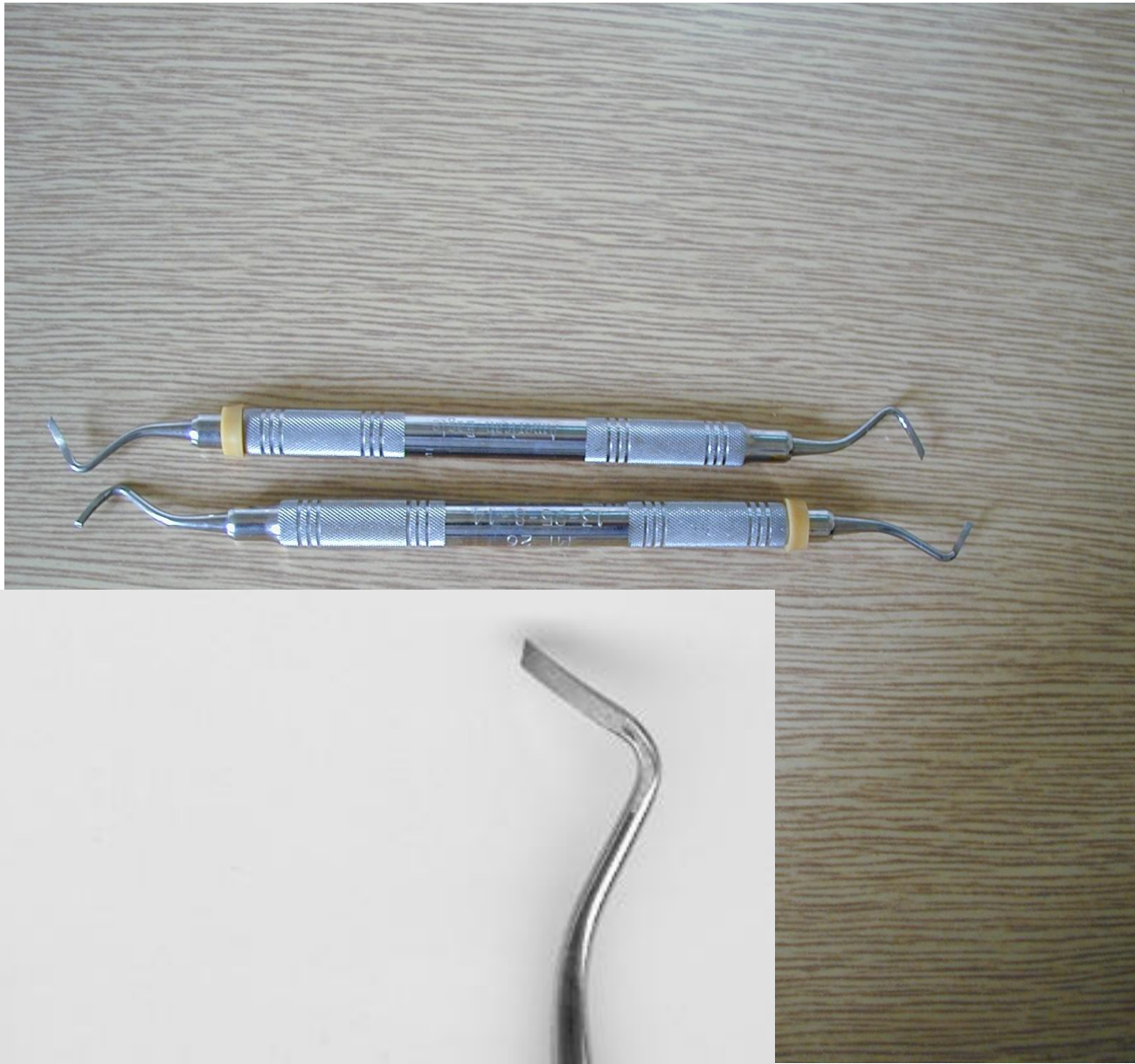
Rounded bur

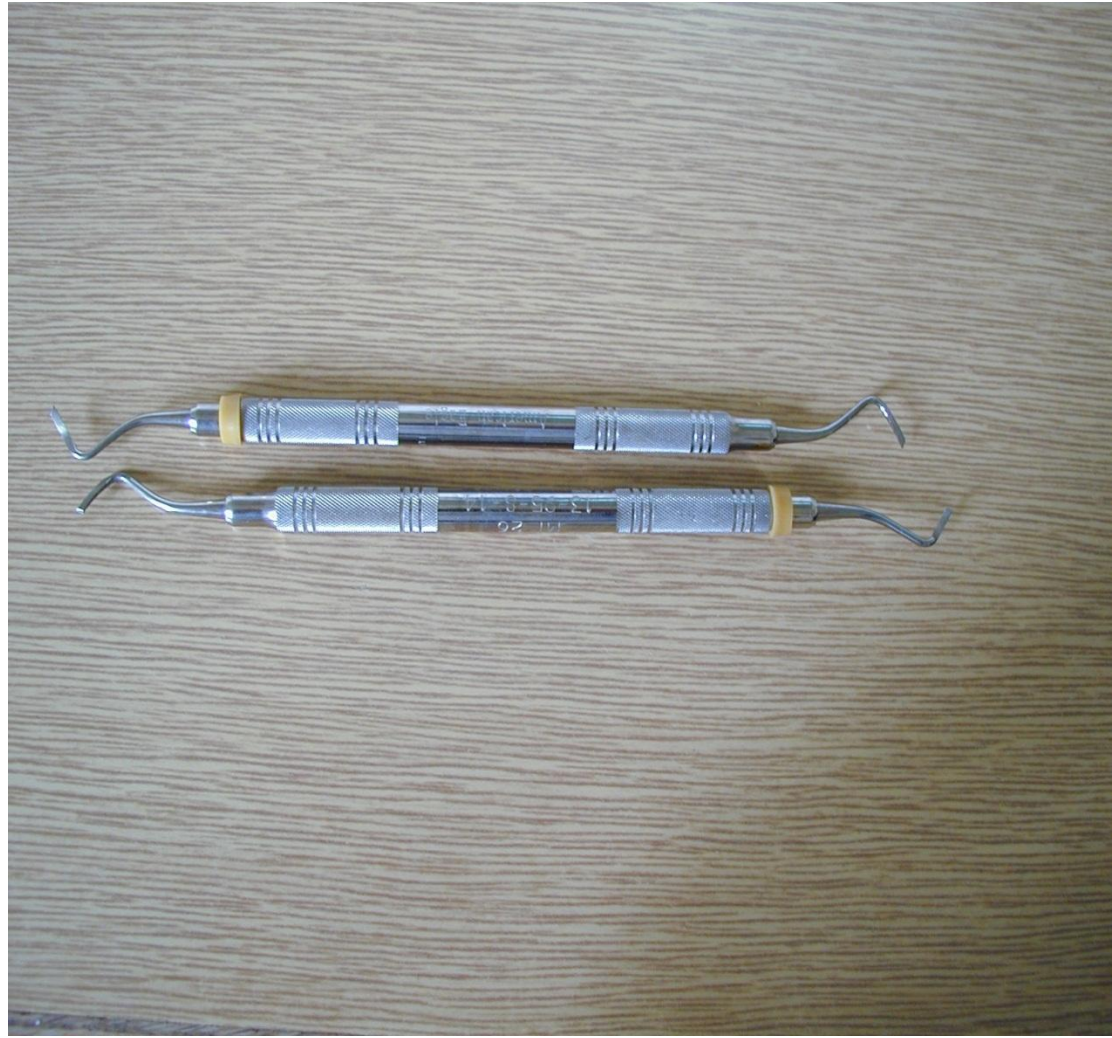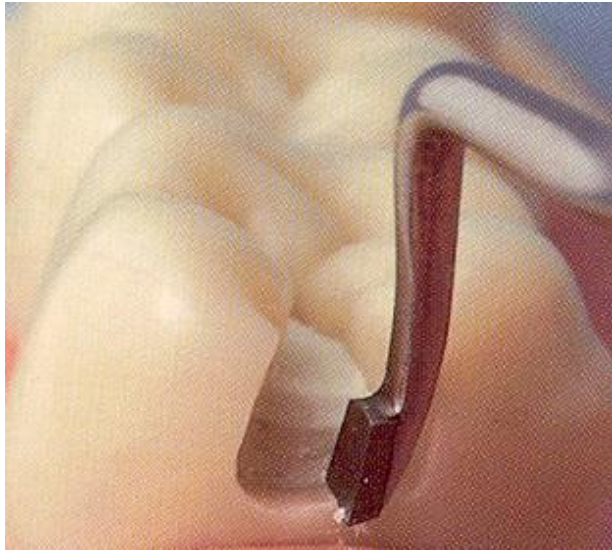
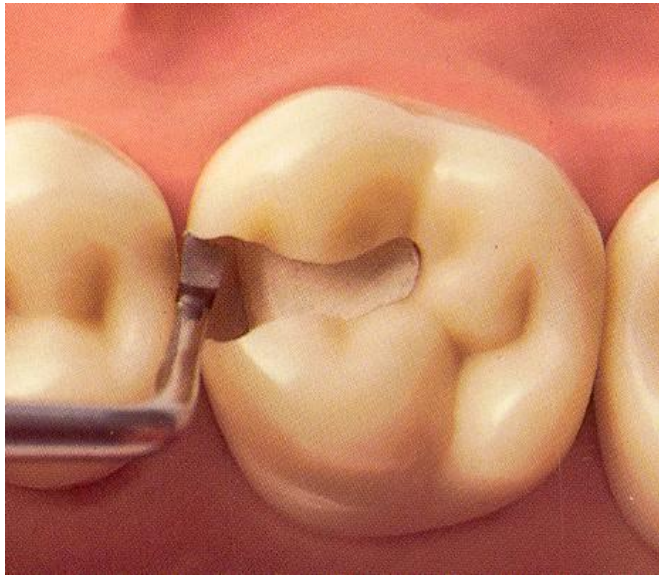


(Caries Detector, Kuraray, Japonsko; Caries Marker, VOCO, Německo)

Finishing of the walls of the cavity

- Red coded diamond bur
- Chisel on the gingival wall (if in enamel)







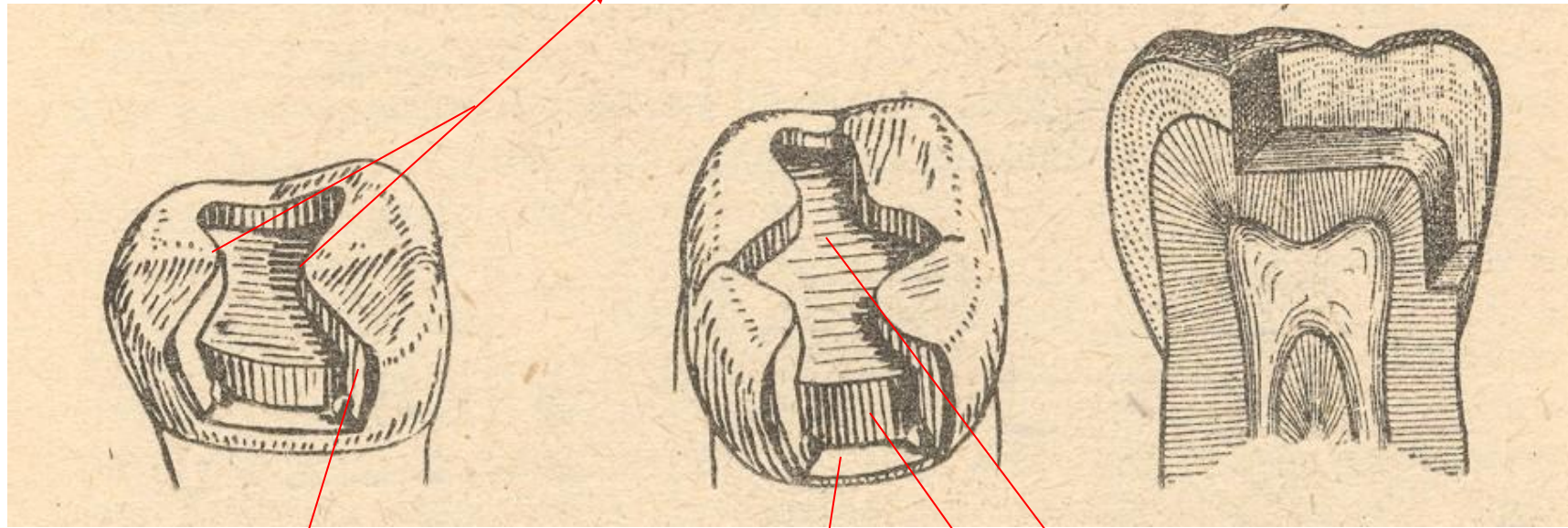
Final check

➤ Goog light, mirror

For cavities where more than one wall is missing we need matrix

- Matrix is a small tool that replace a missing wall (walls) and enable to give the filling the proper contour

Isthmus



Axial wall

Pulpal wall

Gingival wall

Matrix

➤ Matrix primarily is used when a proximal surface is to be restored

The objectives:

- Provide proper contact
- Provide proper contour
- Confine the restorative material
- Reduce the amount of excess material

In some cases it is important for good setting of the material

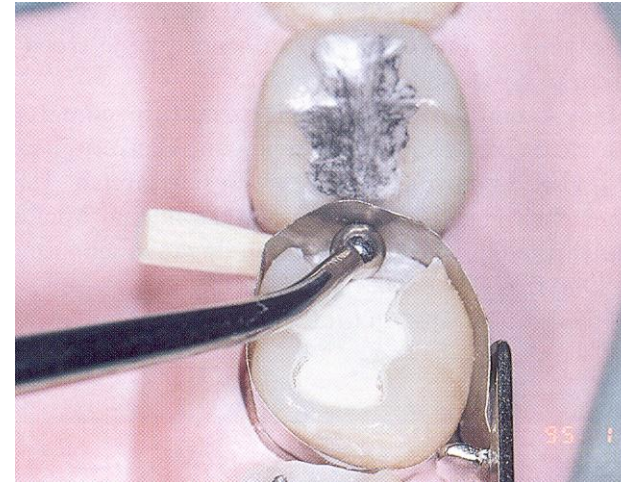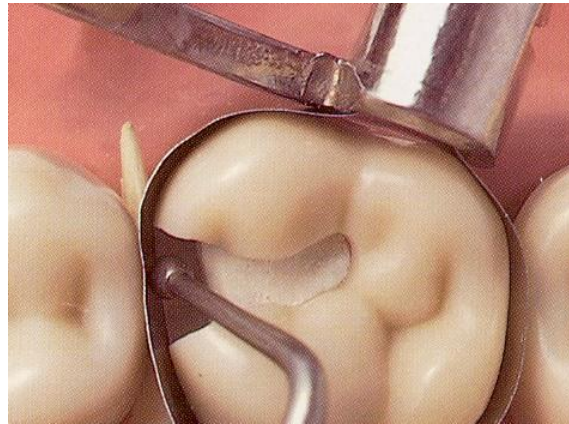
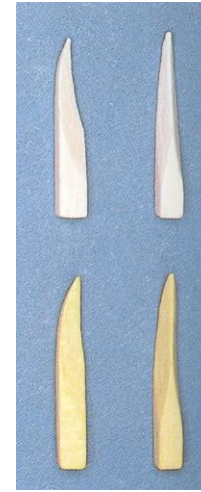

Matrices for II.nd class

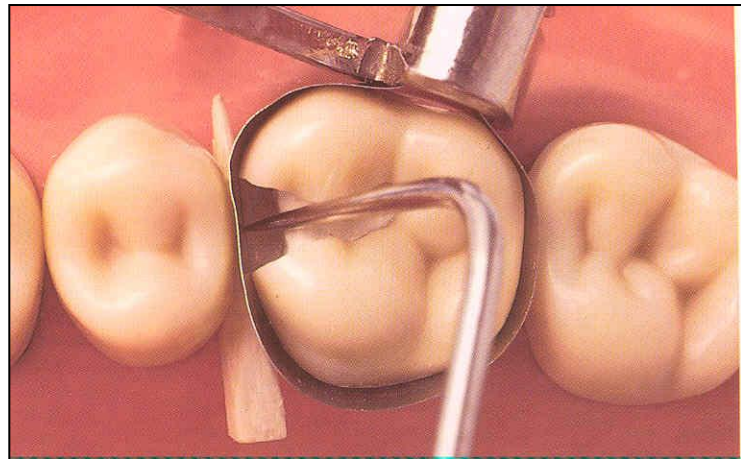
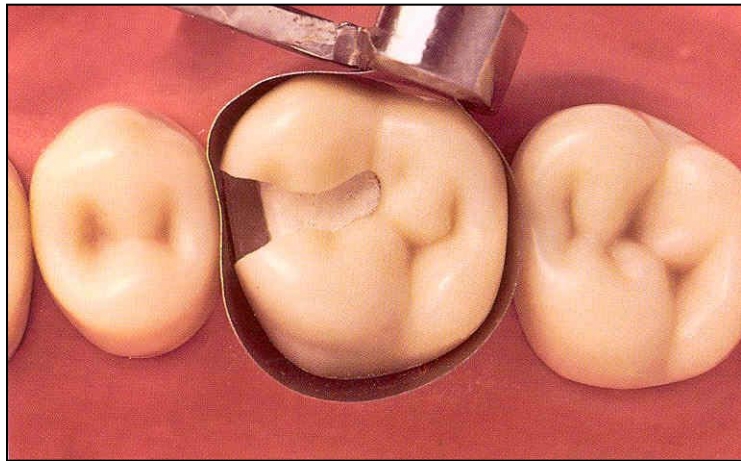

Circular and sectional matrices

➤ Circular matrices round the tooth

They are used in combination with the matrix retainer.

➤ Sectional matrices do not round the tooth, the proximal surface only.

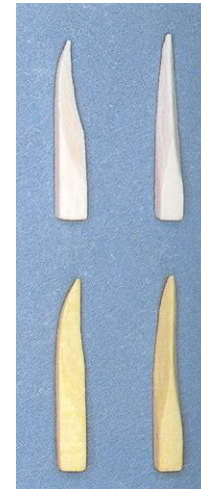




Wedges

➤ Wooden wedges

- tighten the matrix band
- compress the gingiva
- separate the teeth




Wedging

- Slip the matrix band over the tooth (apical to the gingiva margin – 0,5, - 1 mm)
- Tighten the matrix, check it with probe
- Place a wedge
- Turn the retainer $\frac{1}{4}$ counterclockwise
- Contour the band

Sapin



Discoid-cleoid



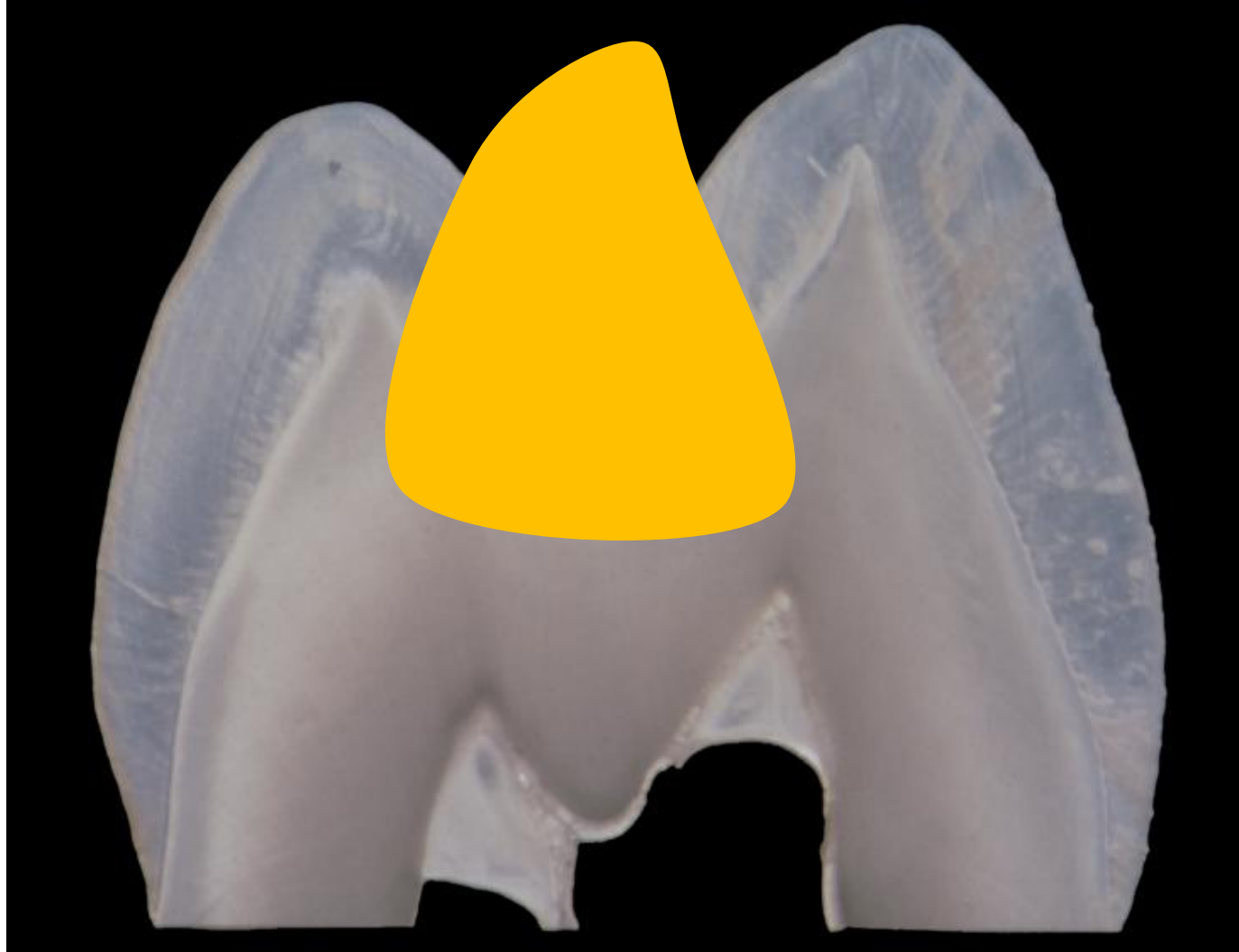Composites - indication

- Small – moderate cavities
- Good level of oral hygiene
- No heavy occlusal stress
- Dry operating field

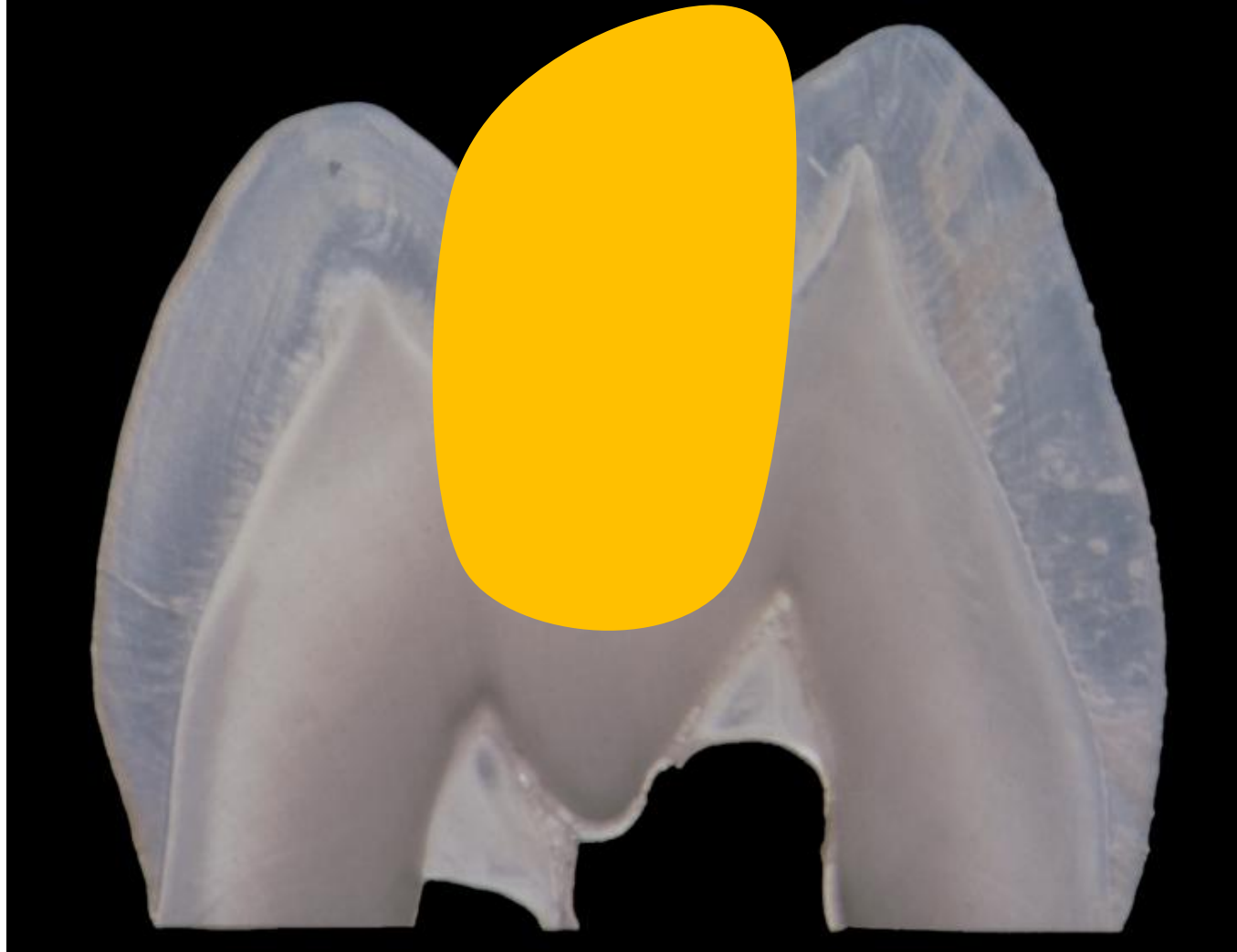Preparation for adhesive materials – composites

- Not too big extension for prevention (adhesion)
- No grooves
- No undercuts
- Rounded box
- Bevel the axial walls and the outer edge of the gingival wall
- Small isolated cavities are possible

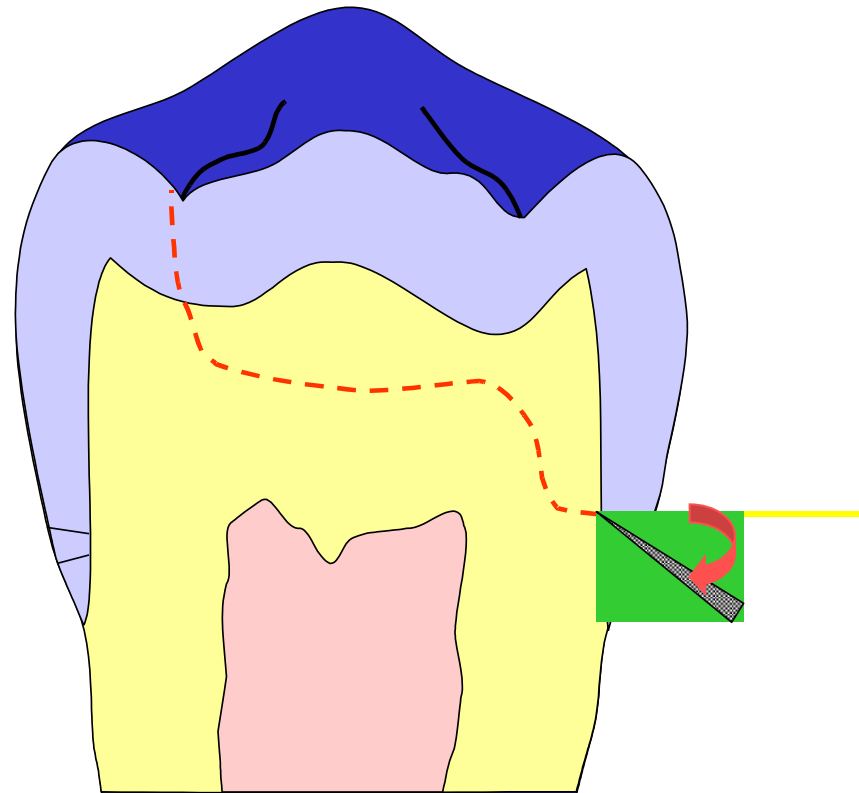
Cavity for amalgam



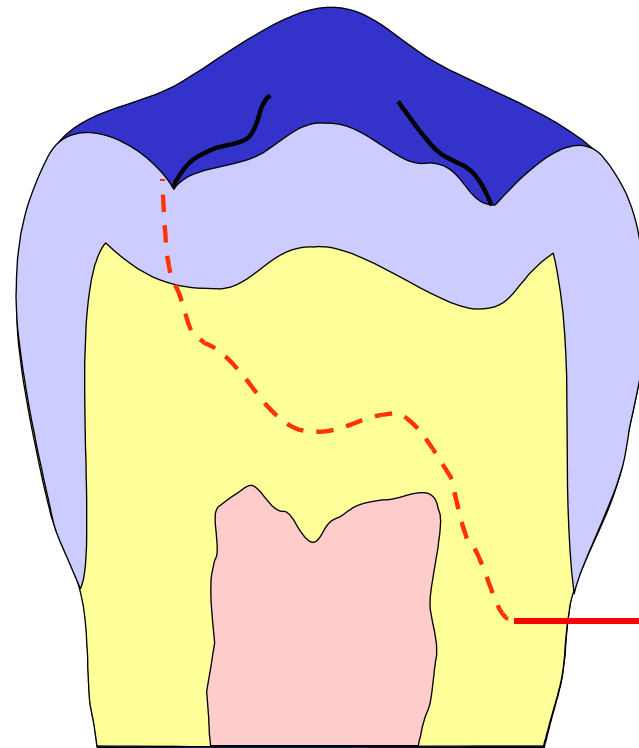
Cavity for composite



Bevel on the gingival wall

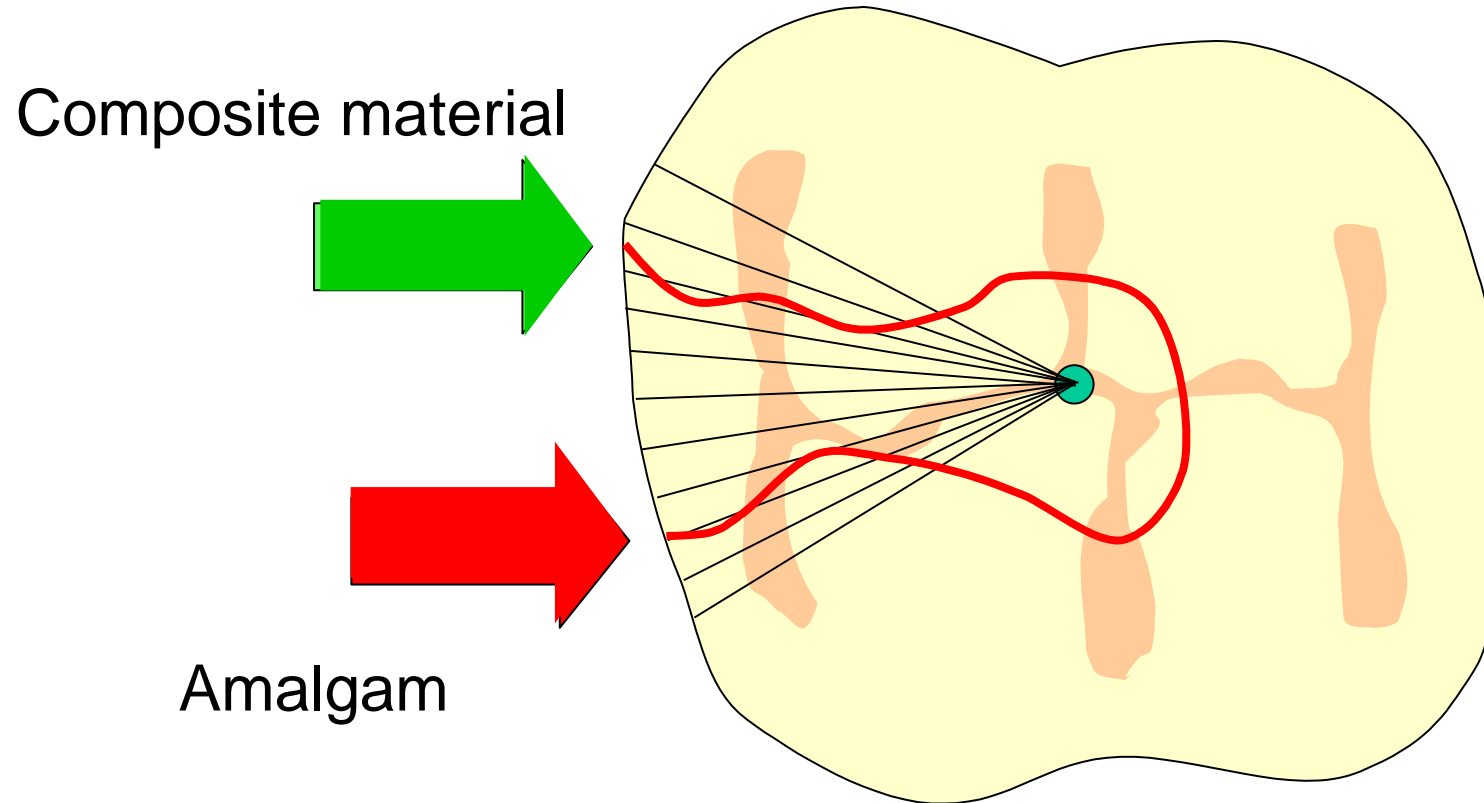


If out of enamel



Preparation
do not bevel!!!

Bevel of enamel on axial walls



Matrices for composites in class II.

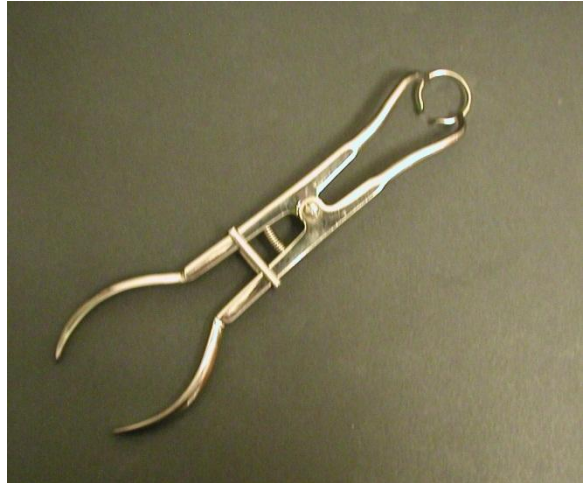
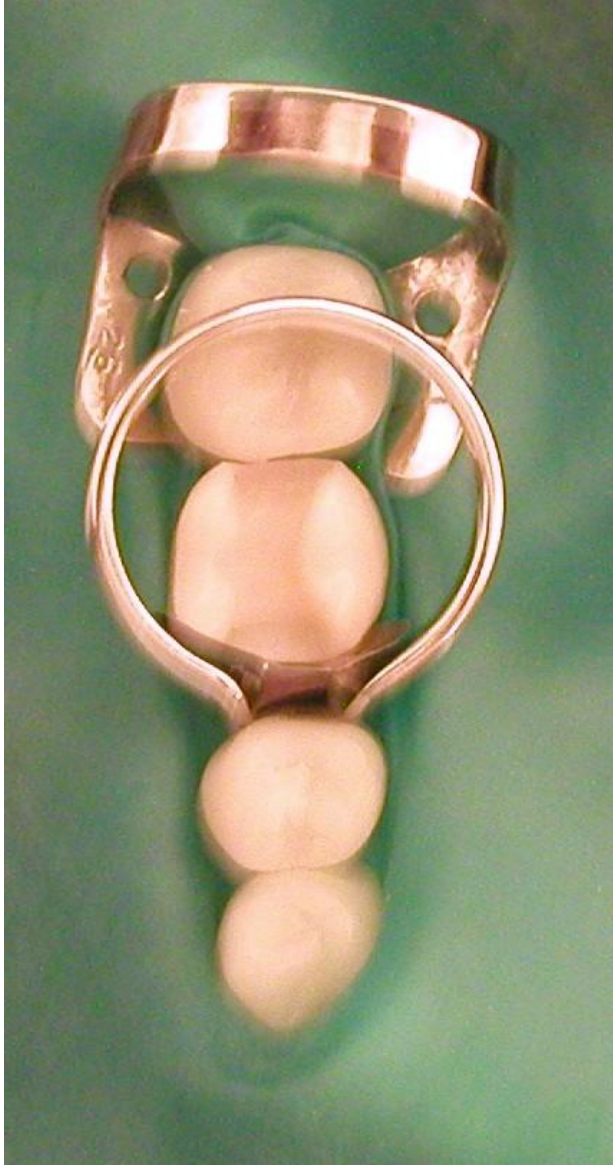– Matrix band + matrix retainer (circular matrices – see above)

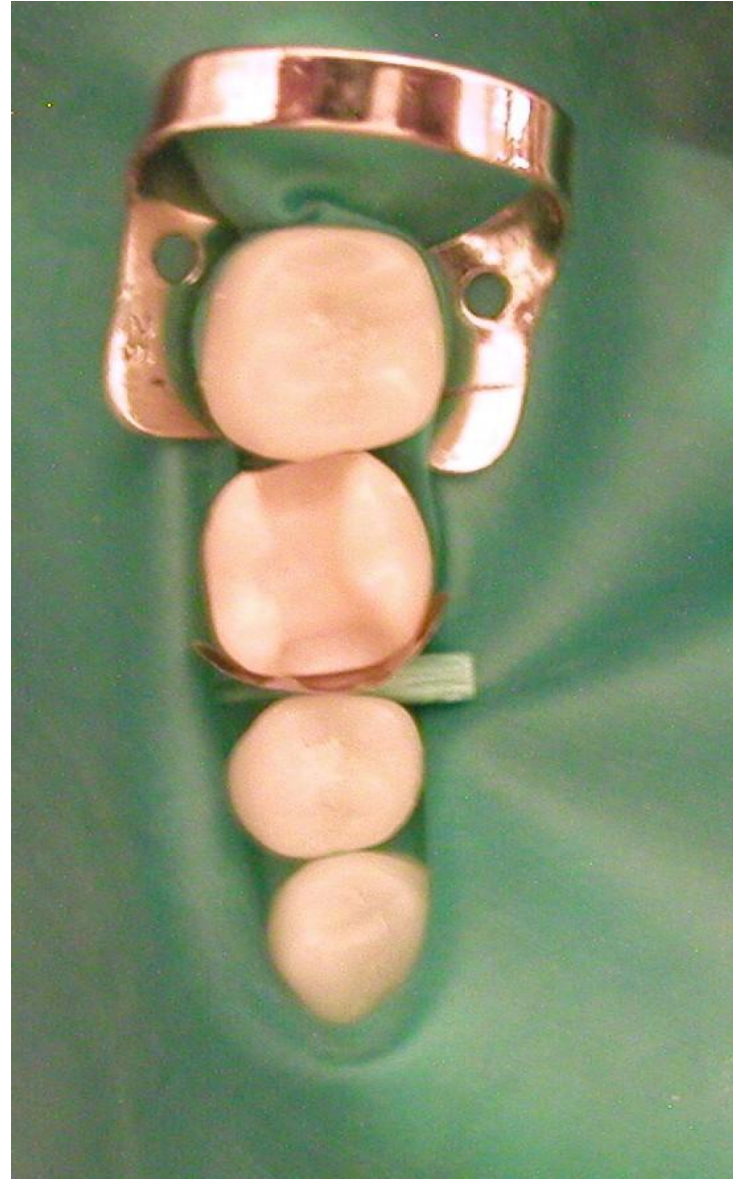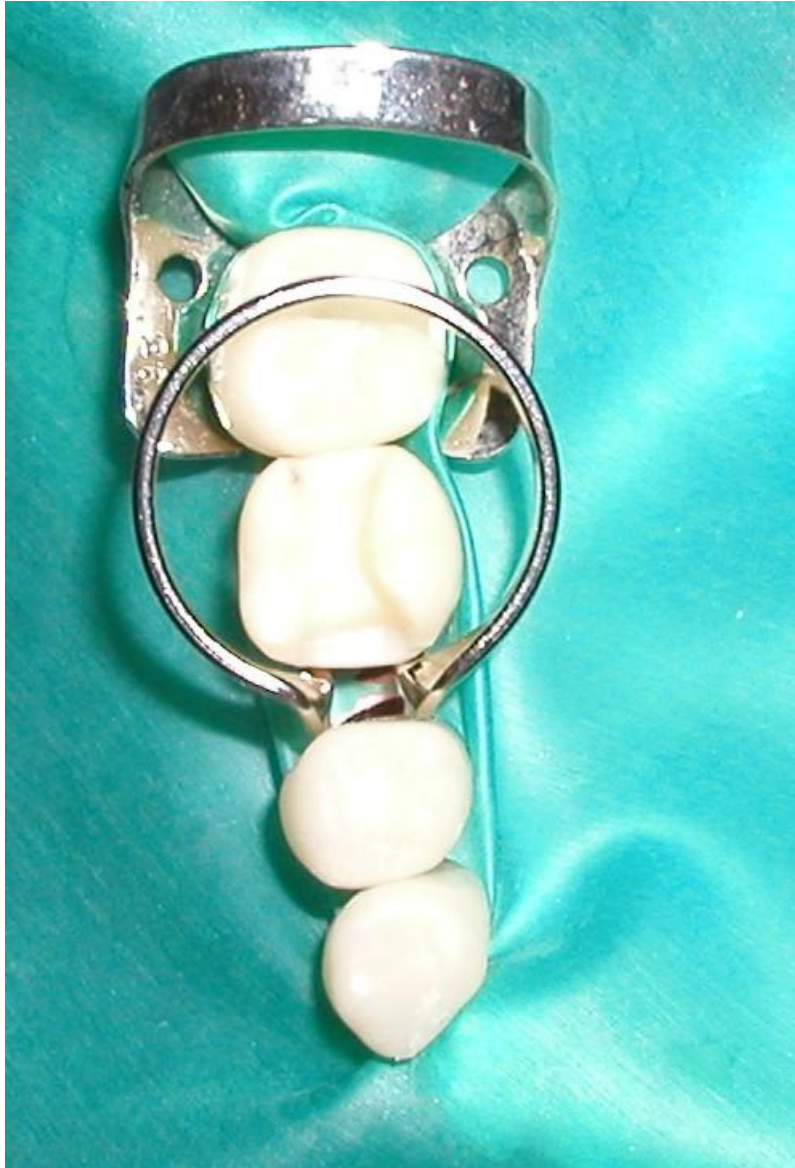– Segmental matrix (sectional matrices) + separator

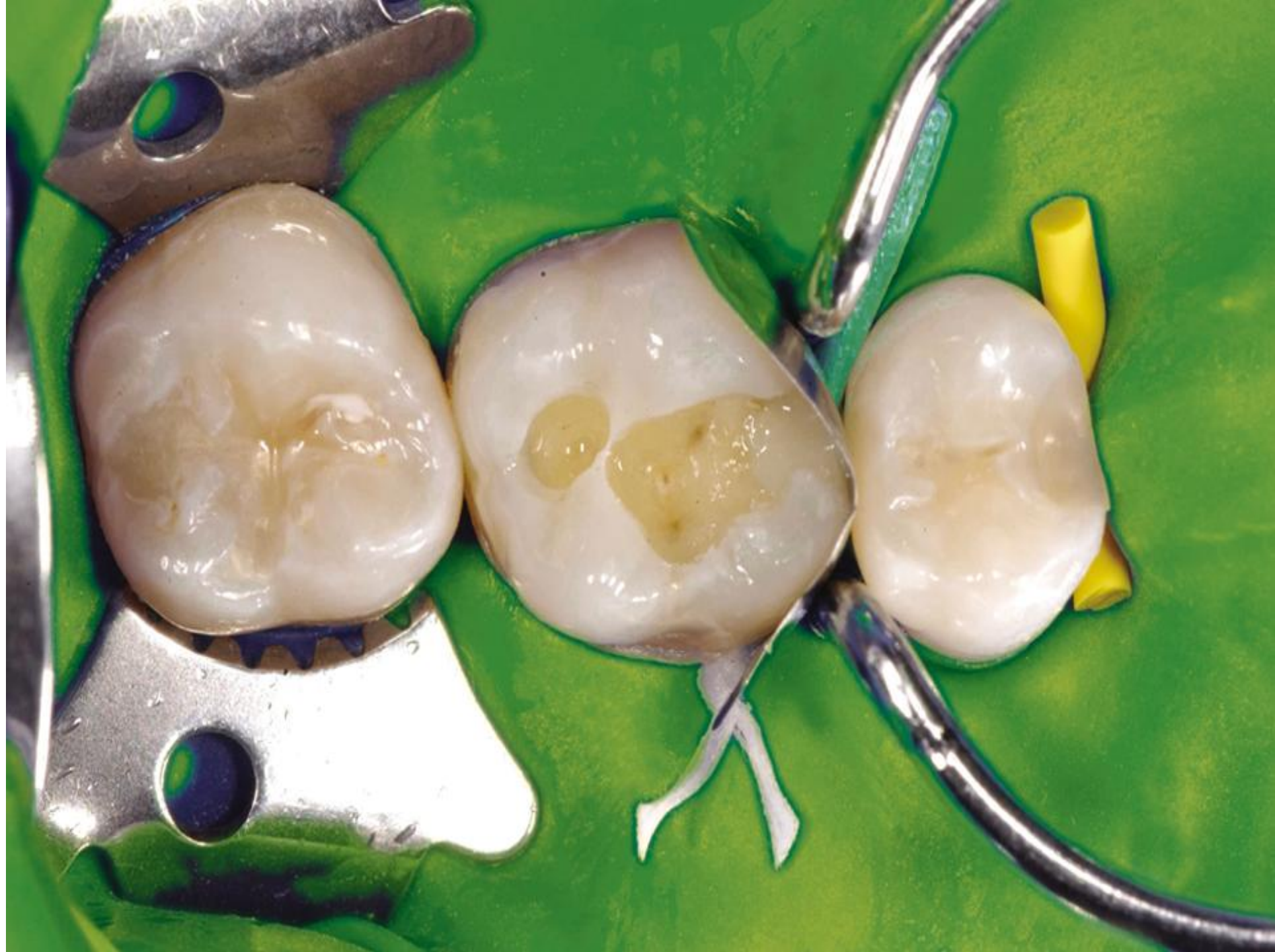Forceps for handling

Composi-Tight 3D XR. ❷

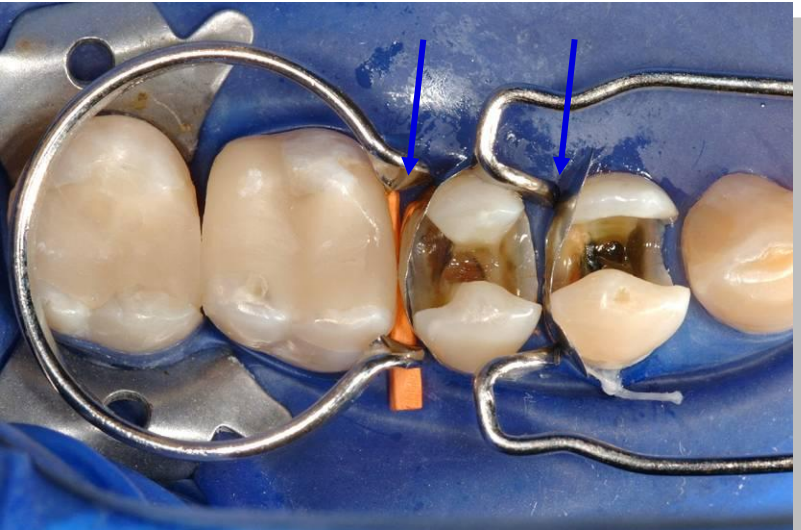
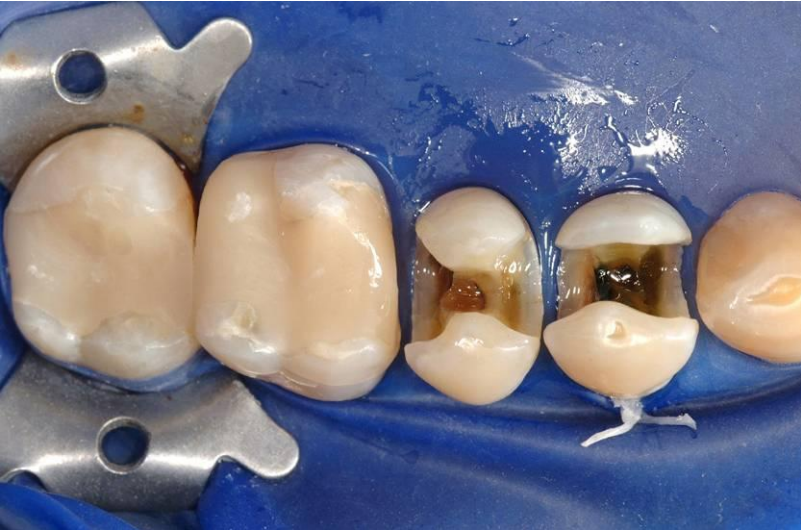
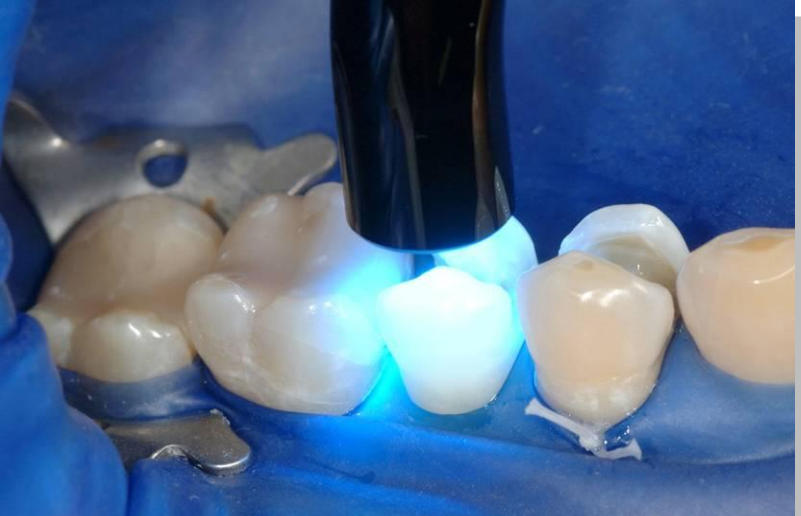
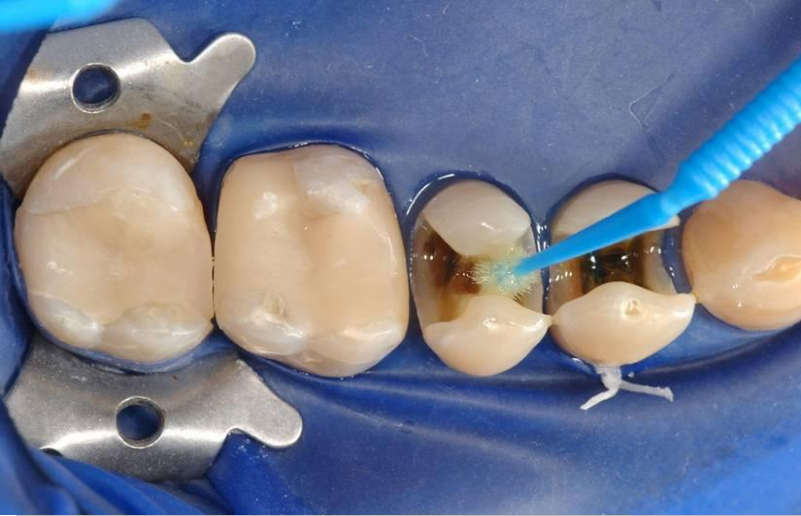




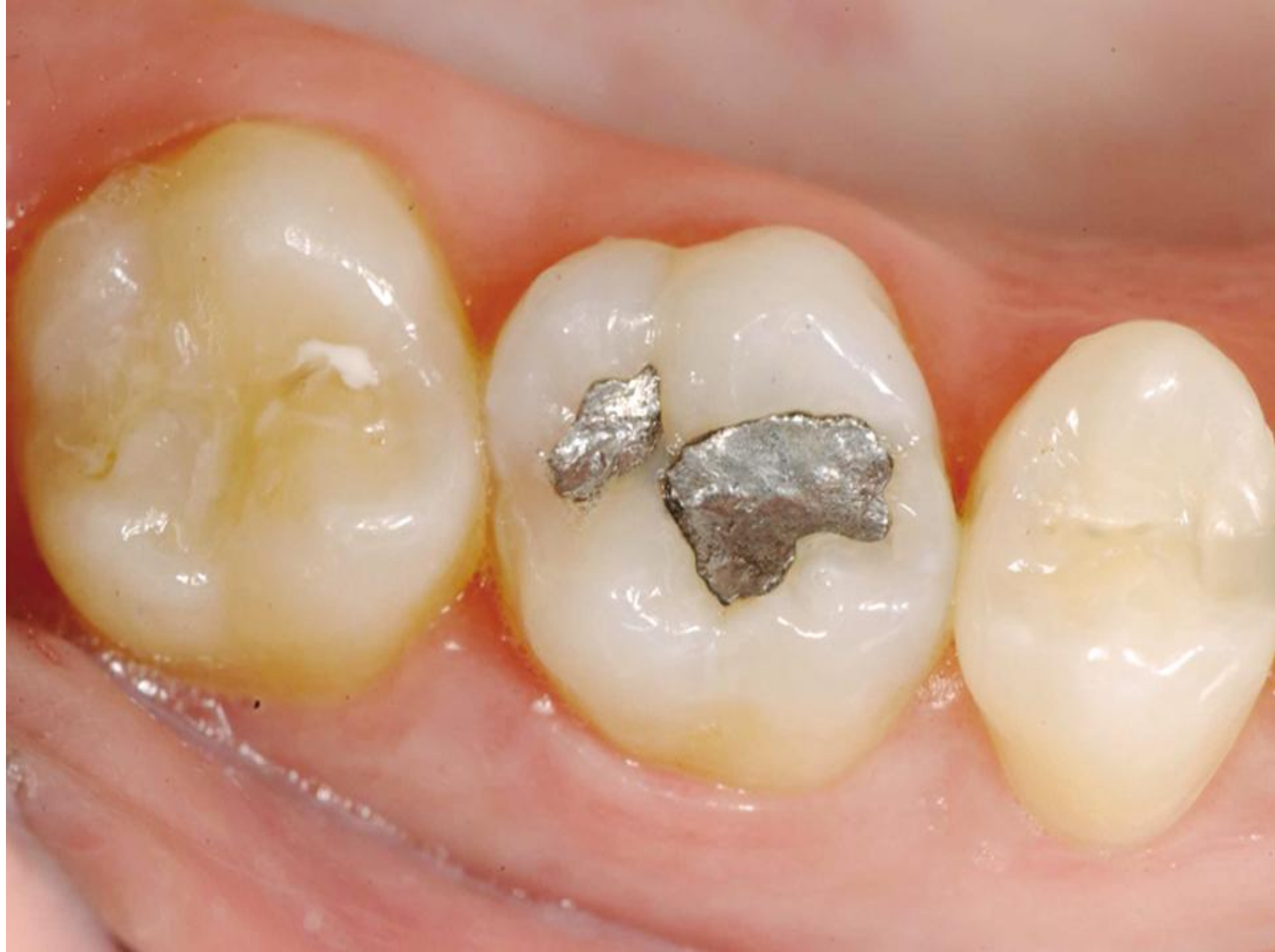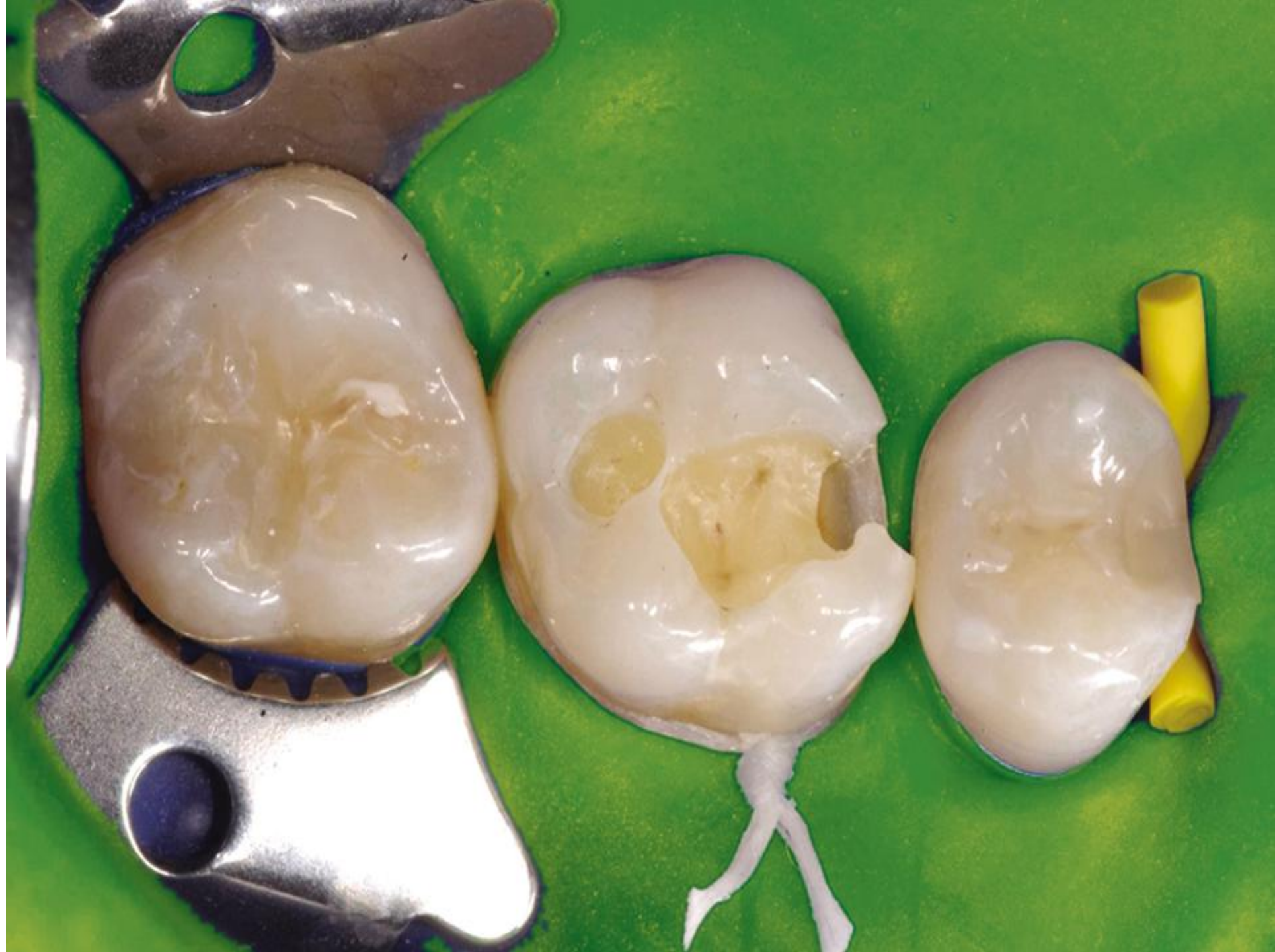Sectional matrices

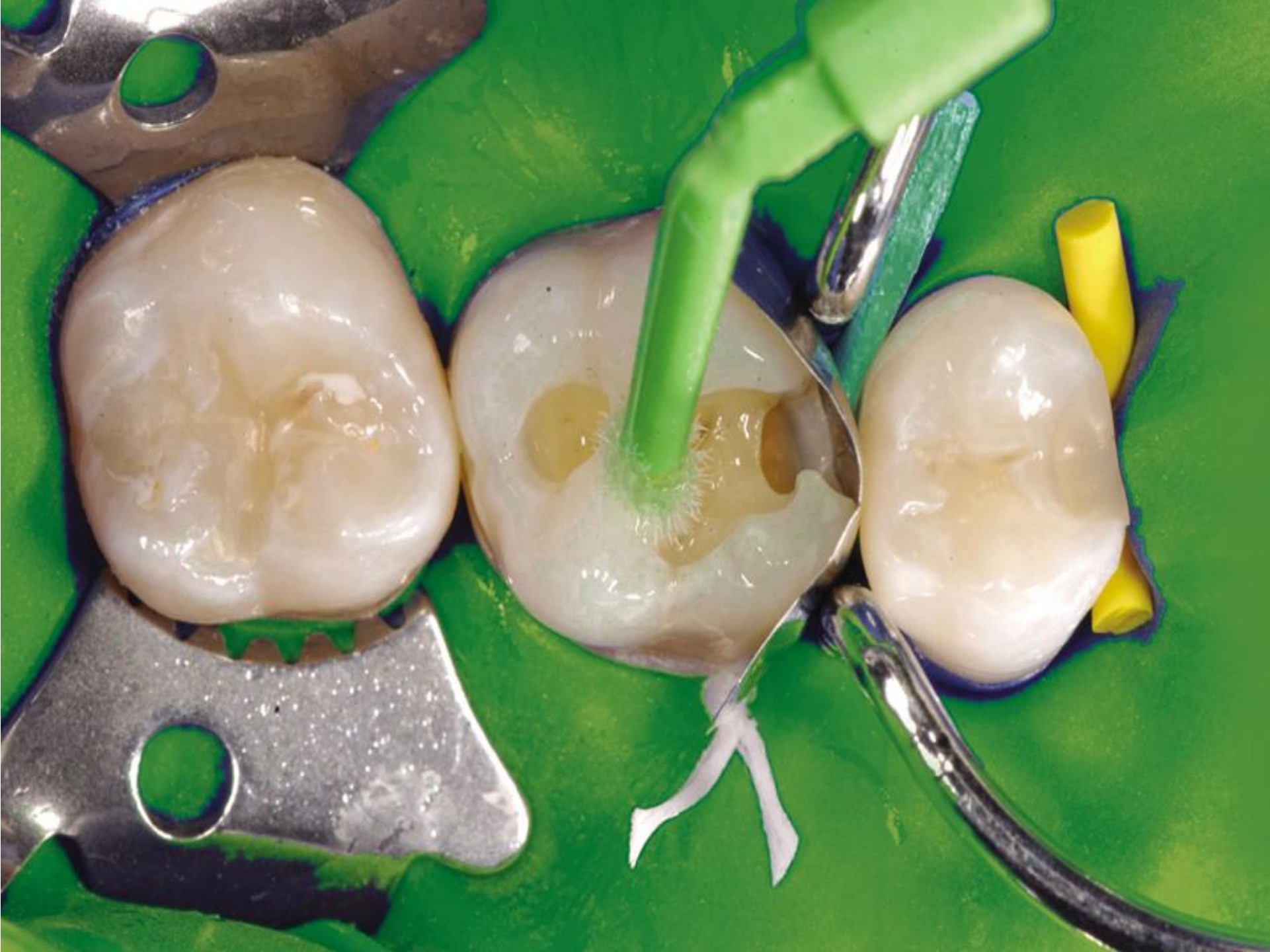

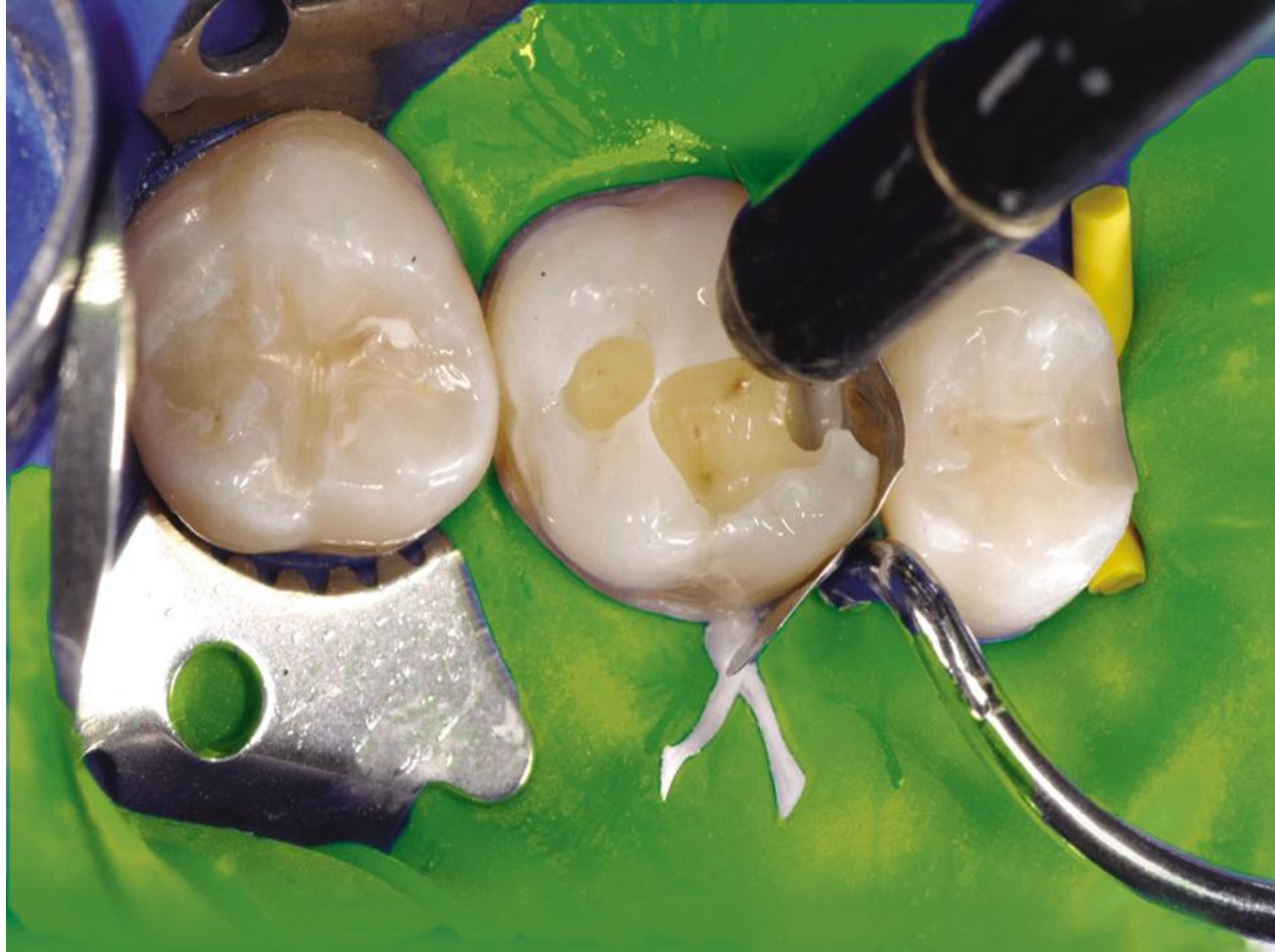Sequence of operation

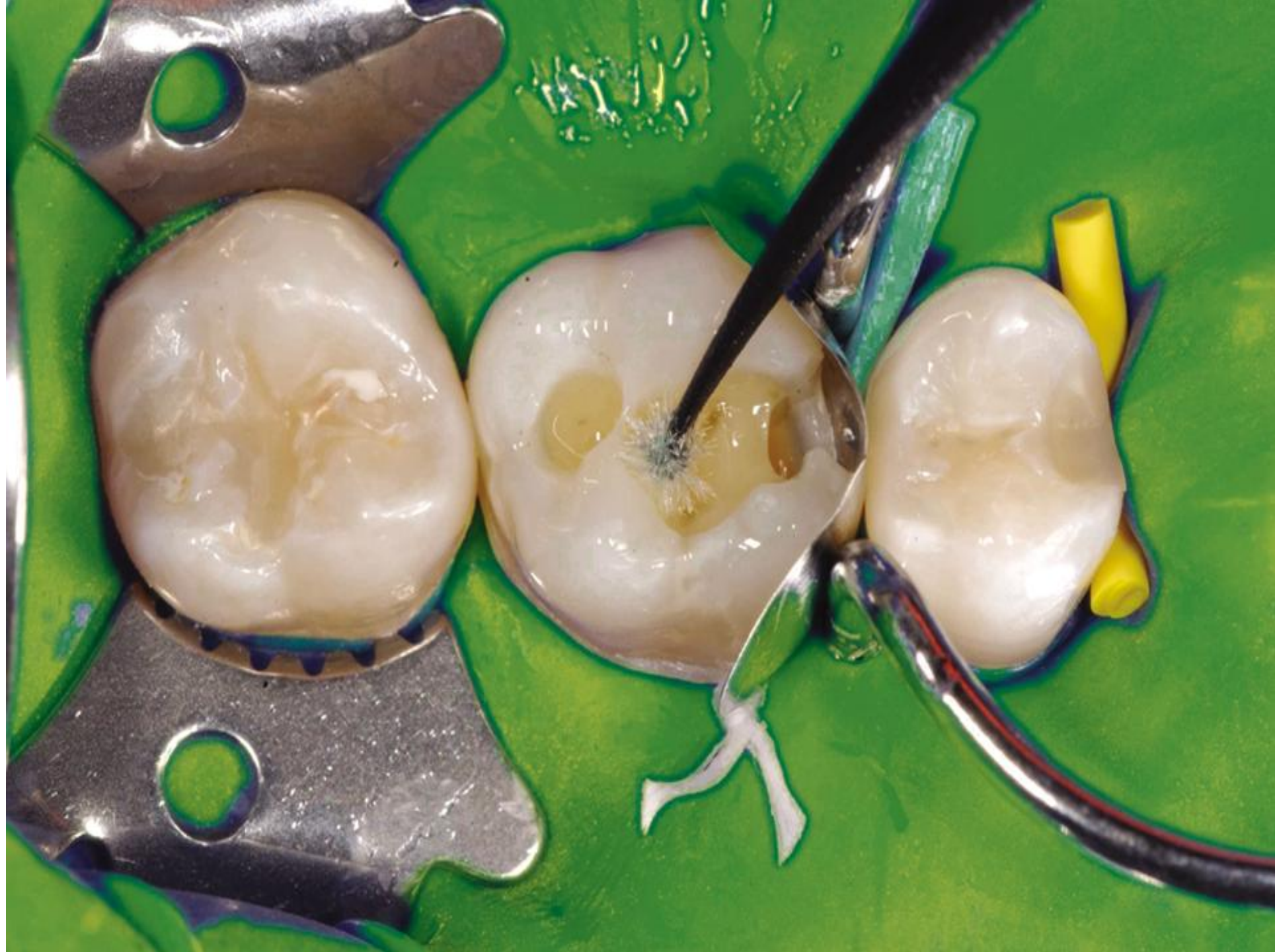- Preparation
- Bevel the enamel on axial walls and outer edge of gingival wall (if located in enamel)
- Placement of the matrix
- Adhesive procedure (acid etching, washing, priming and bonding)
- Placement of the composite material layer by layer
- Curing
- Finishing and polishing

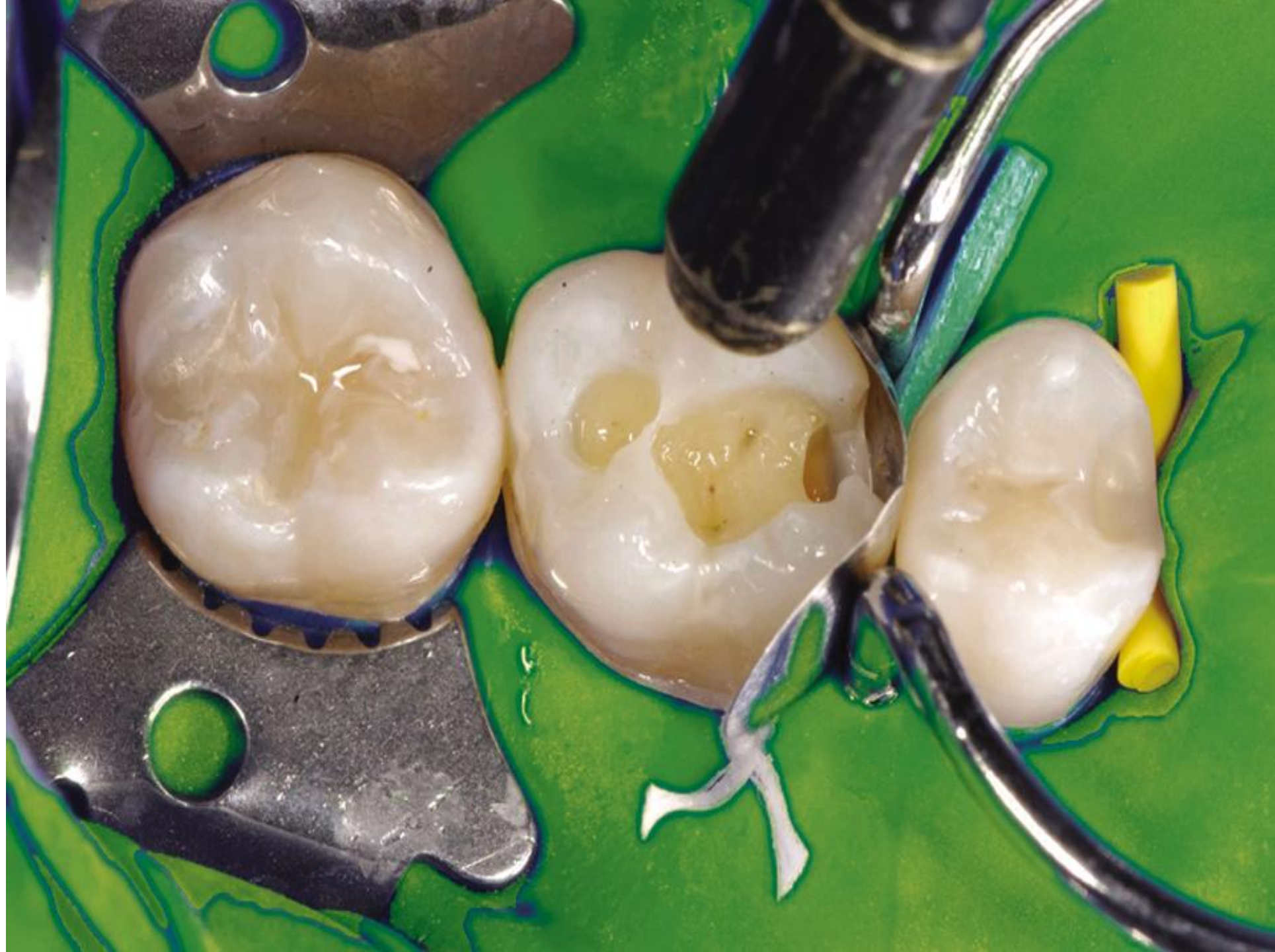


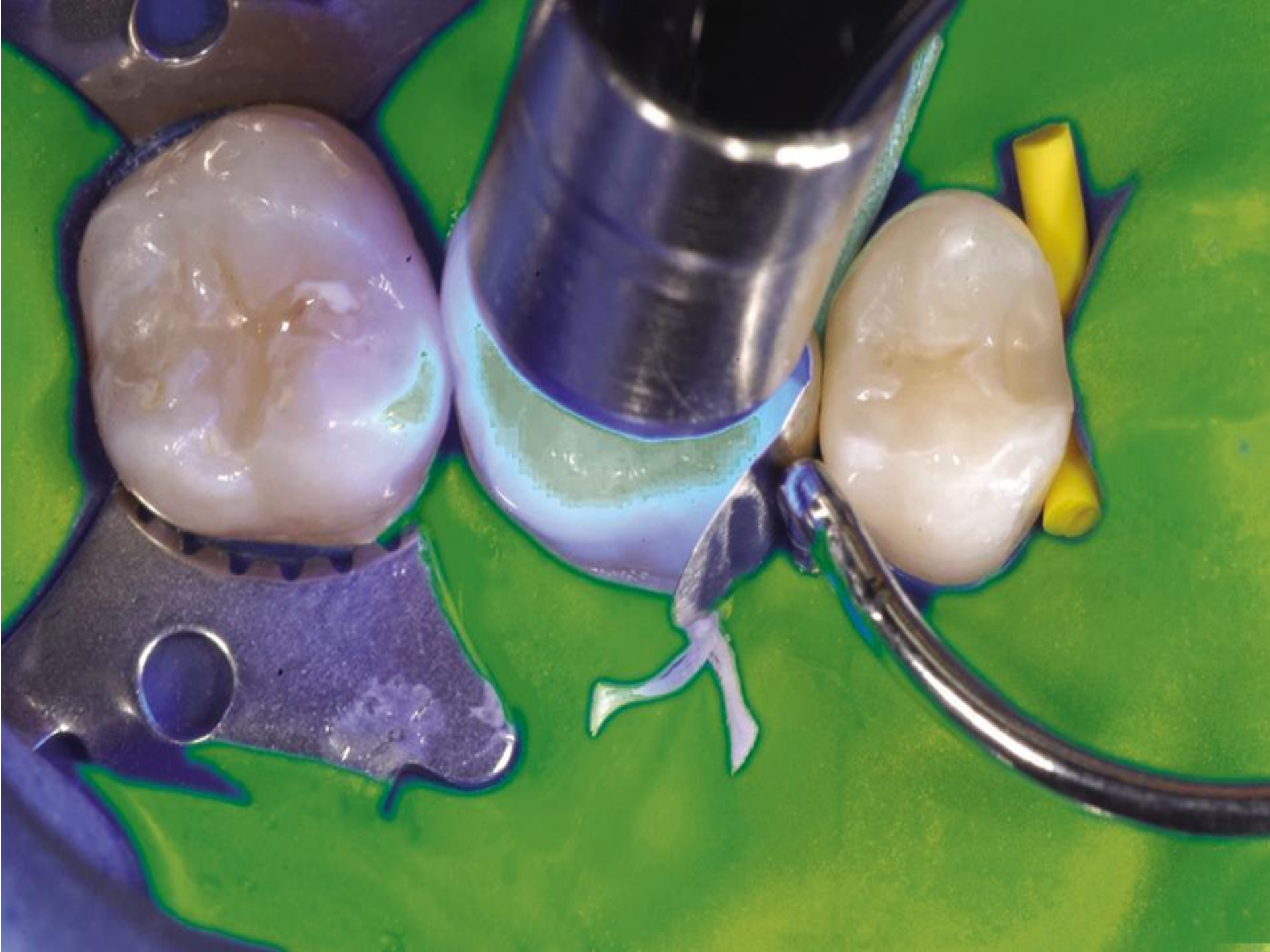


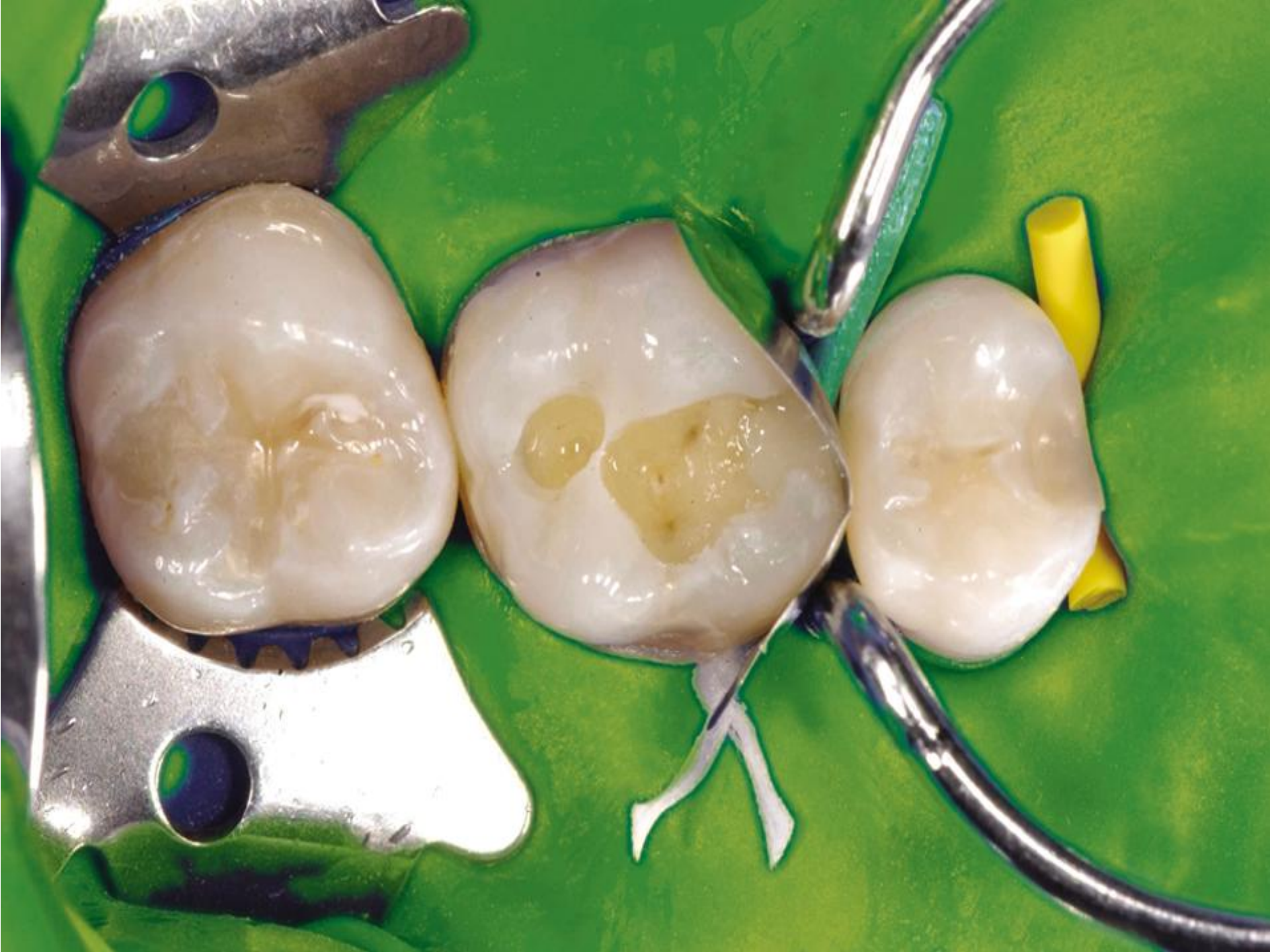


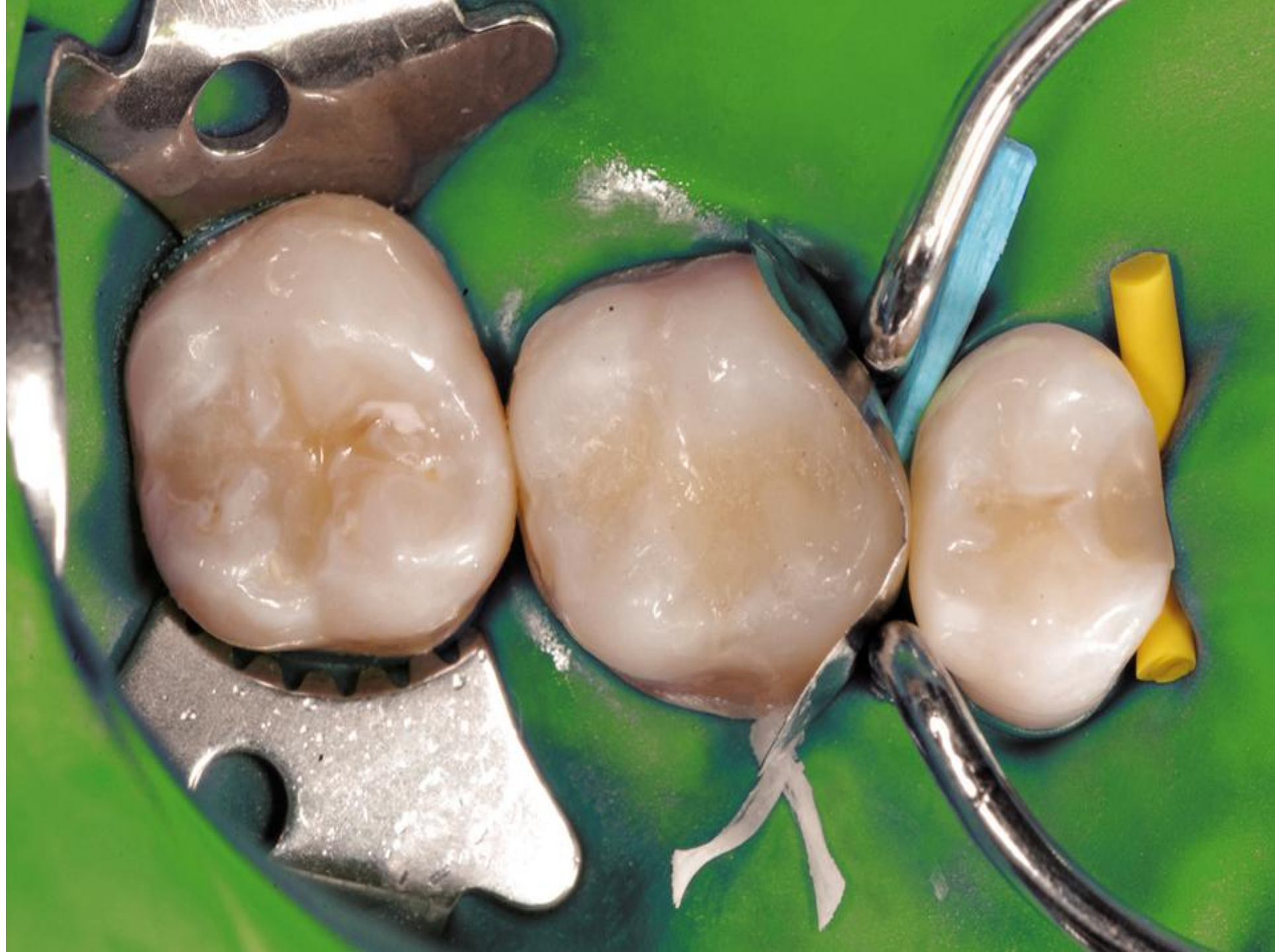


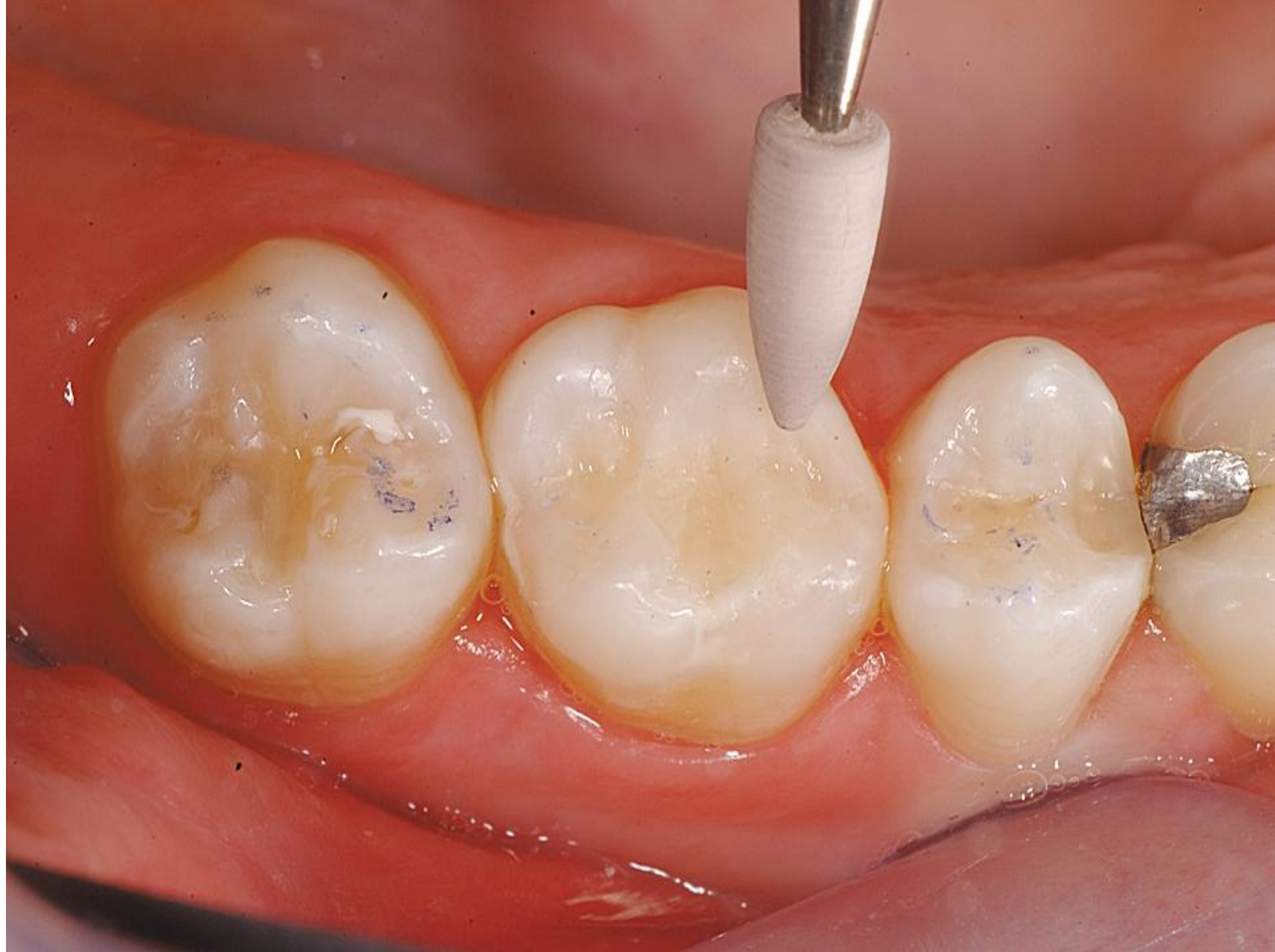

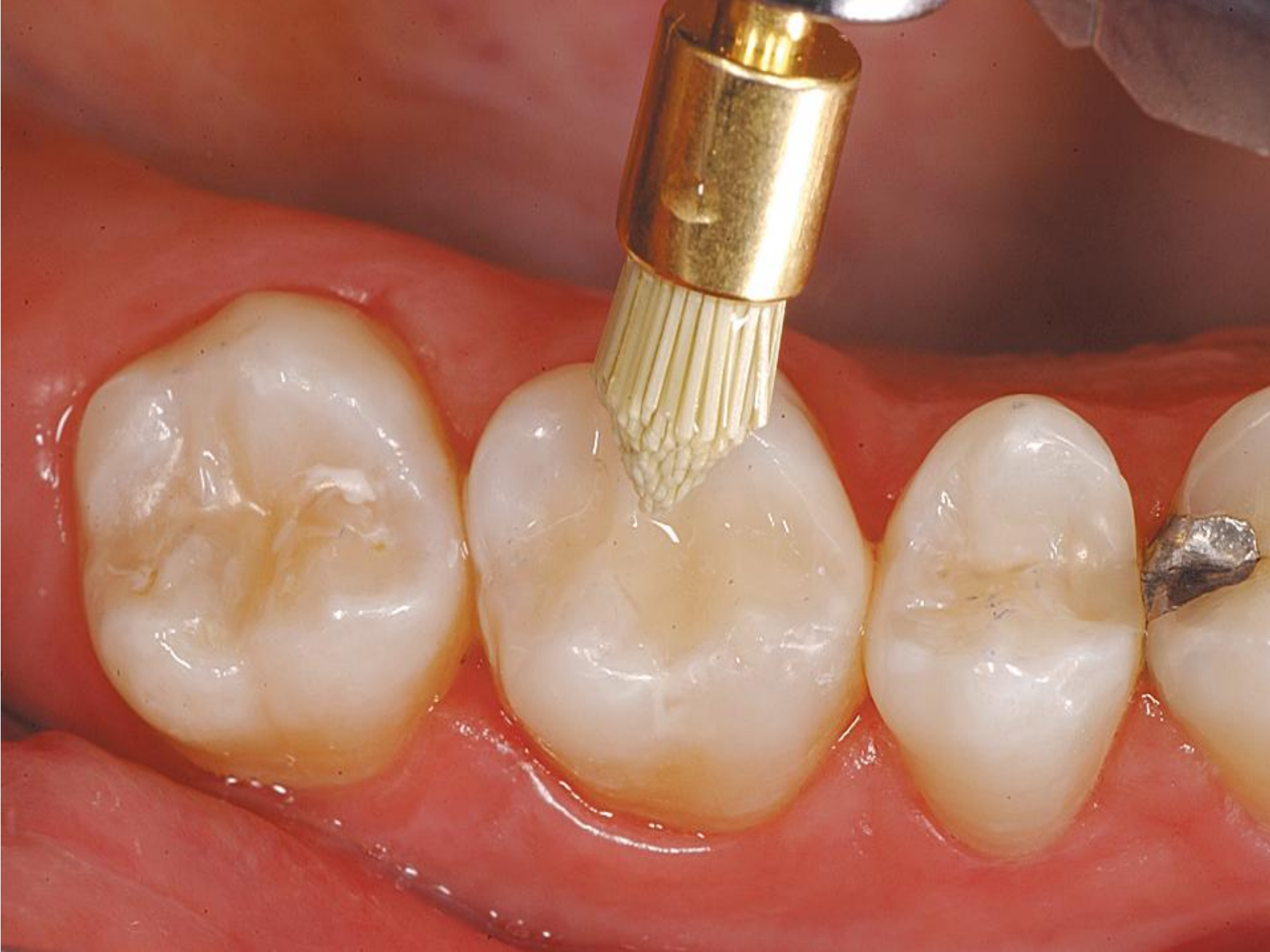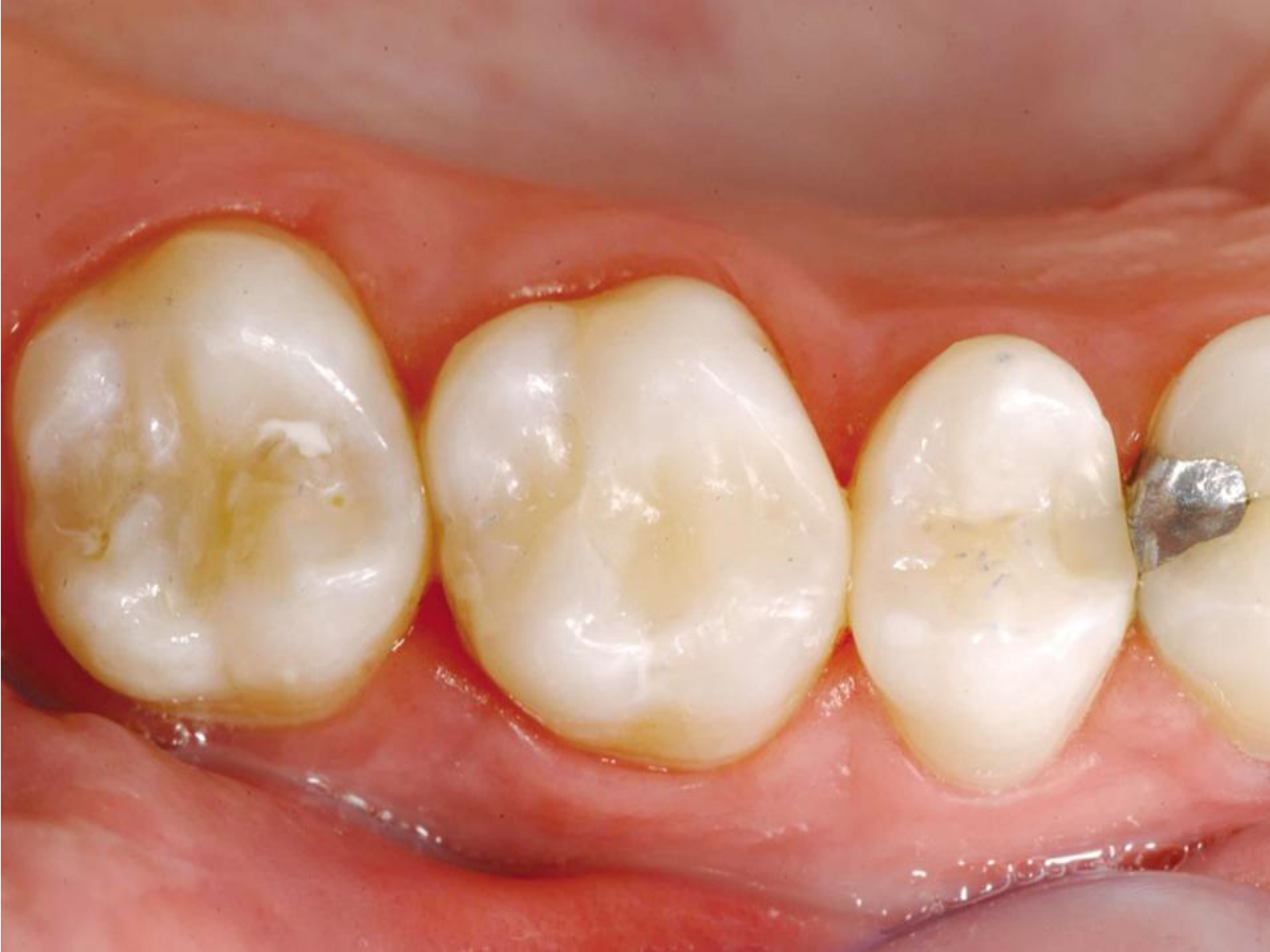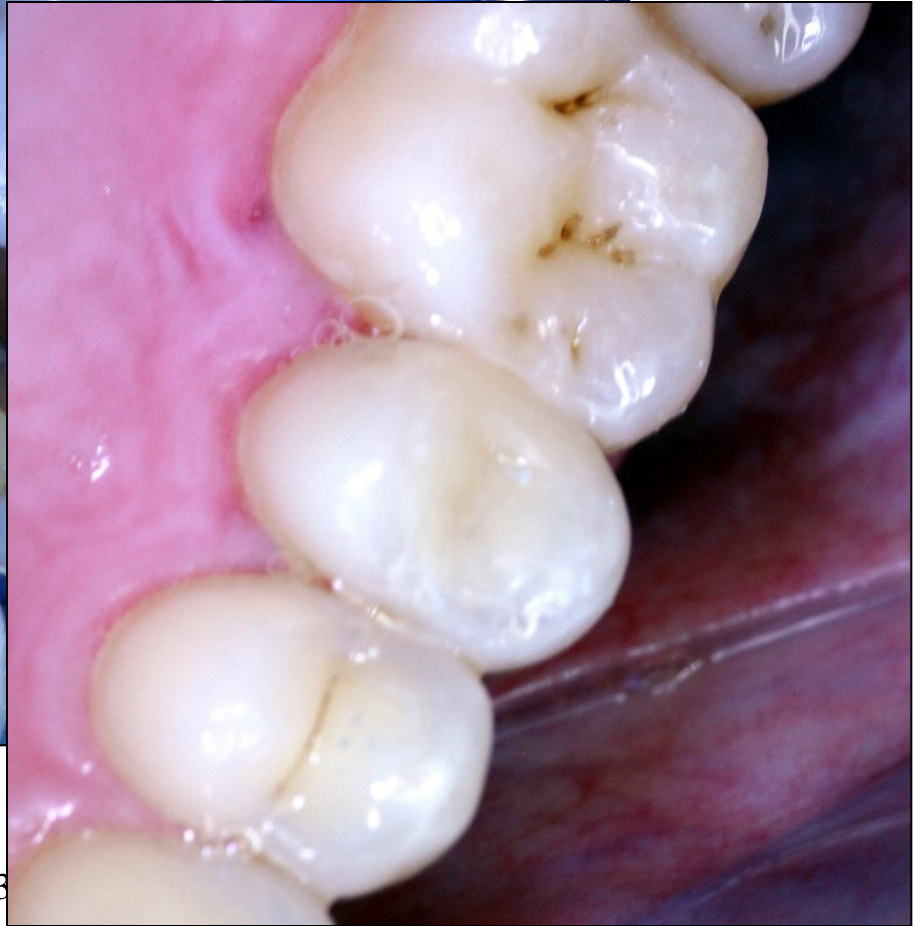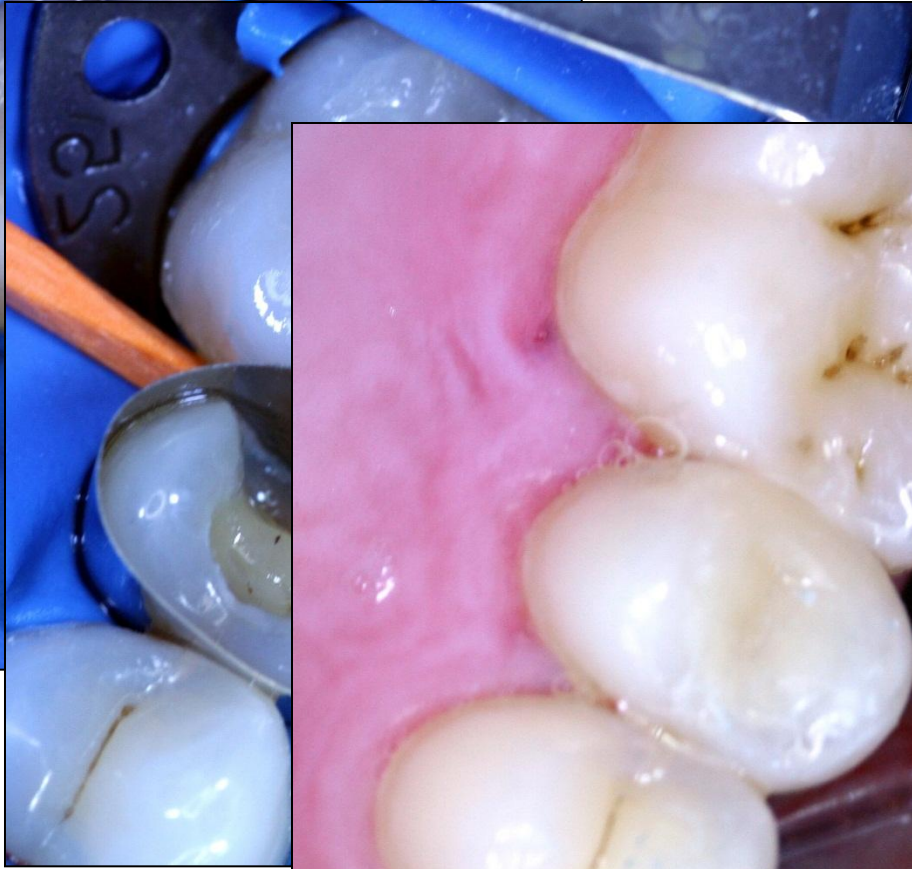
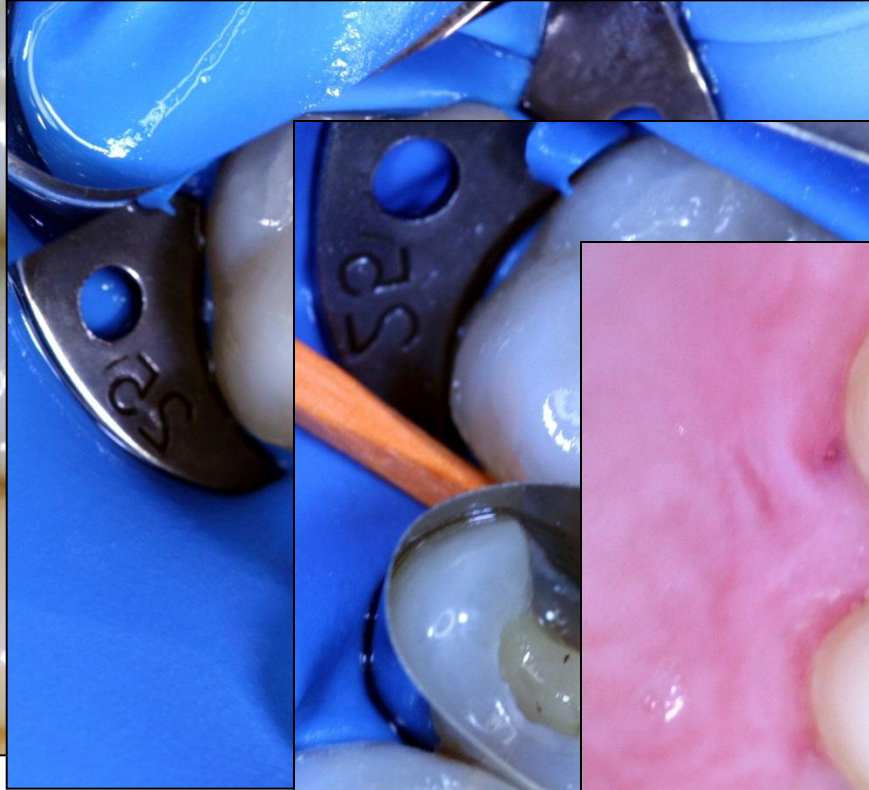
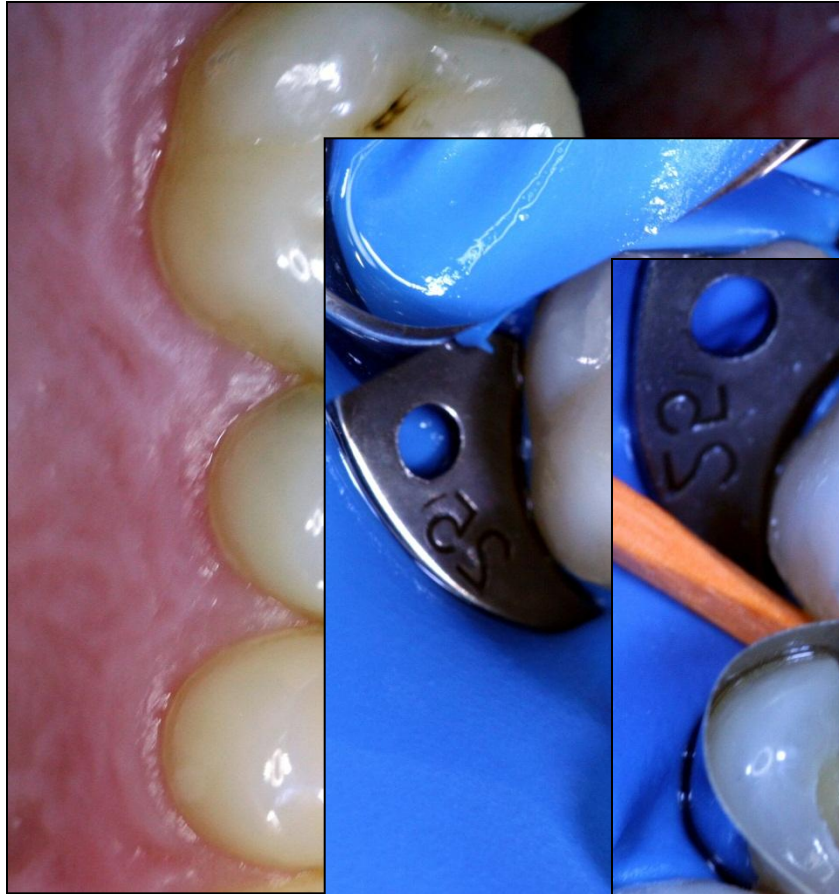






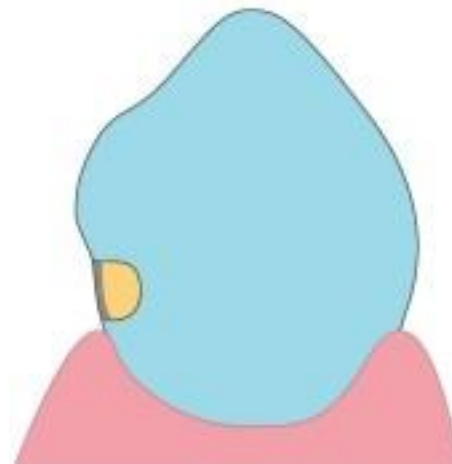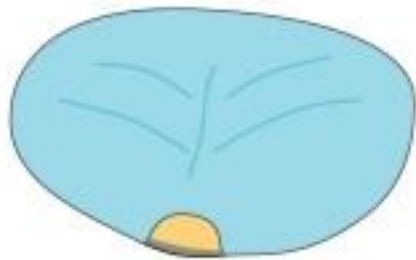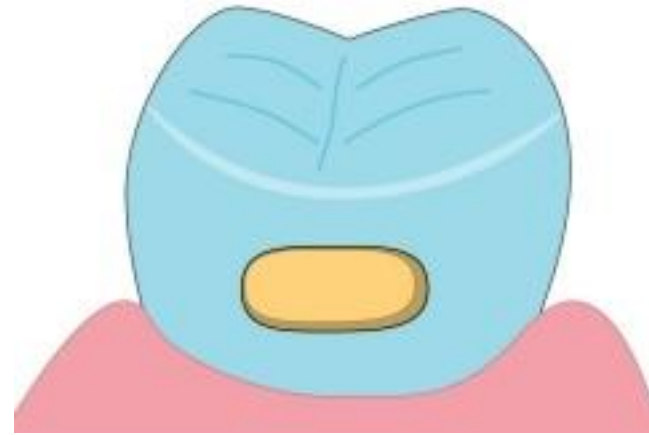
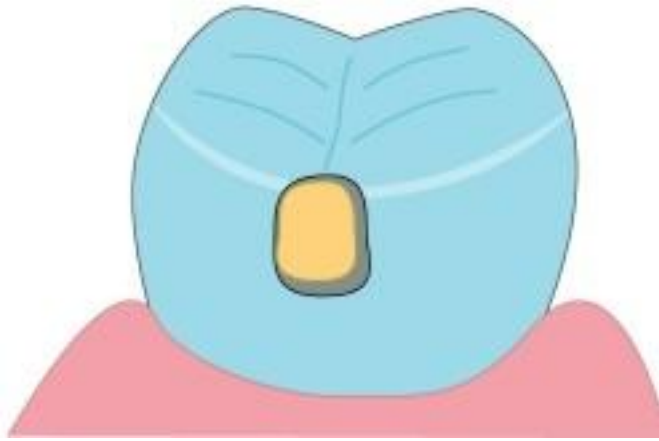


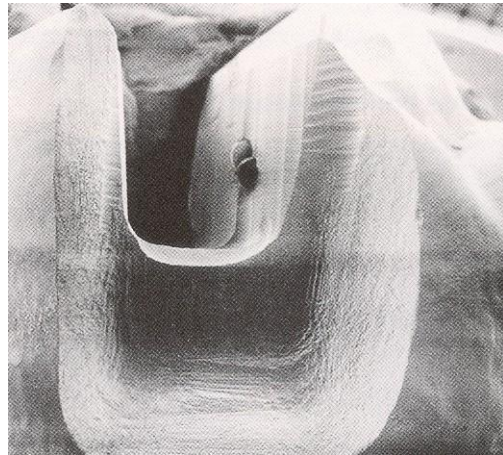




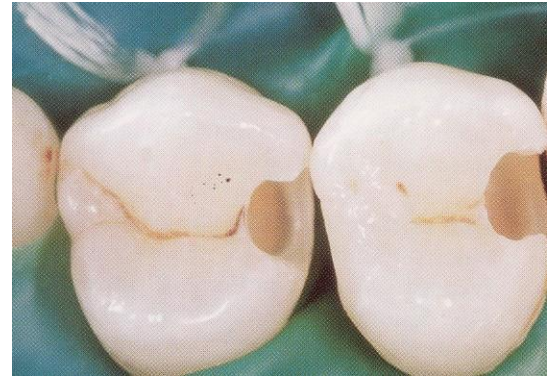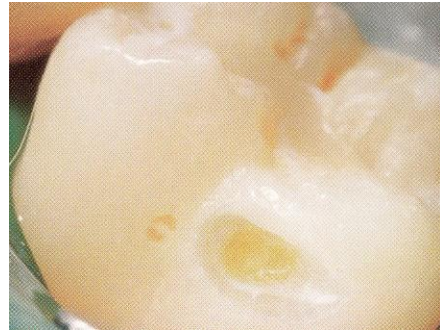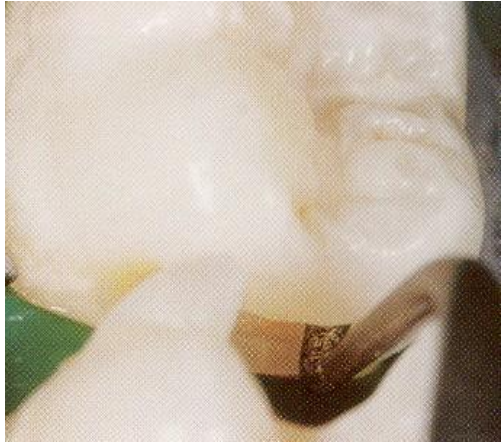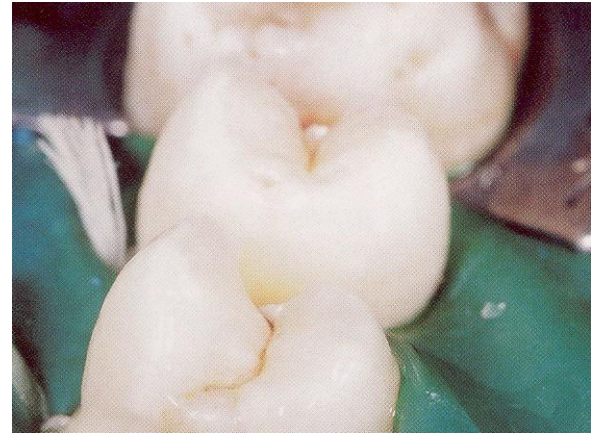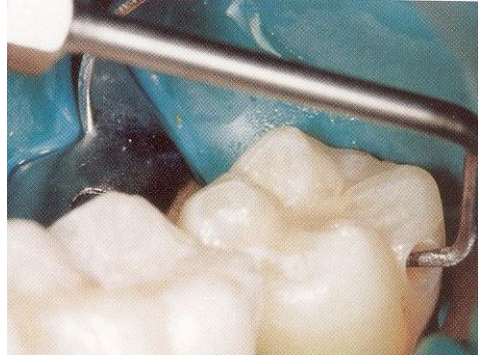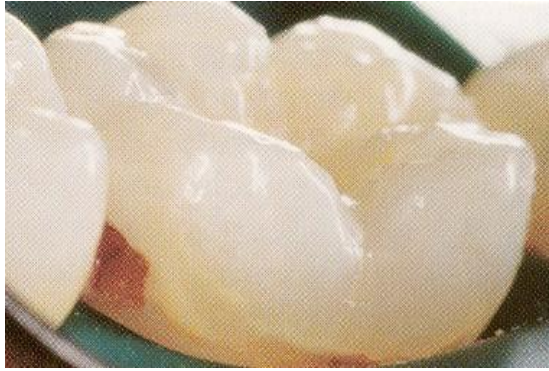Alternative preparation – adhesive slot

Fissures are not involved





Tunnel preparation

