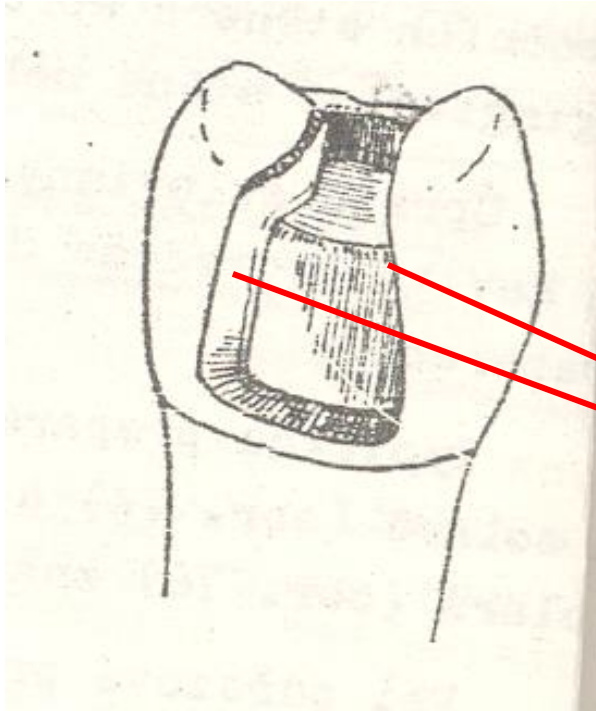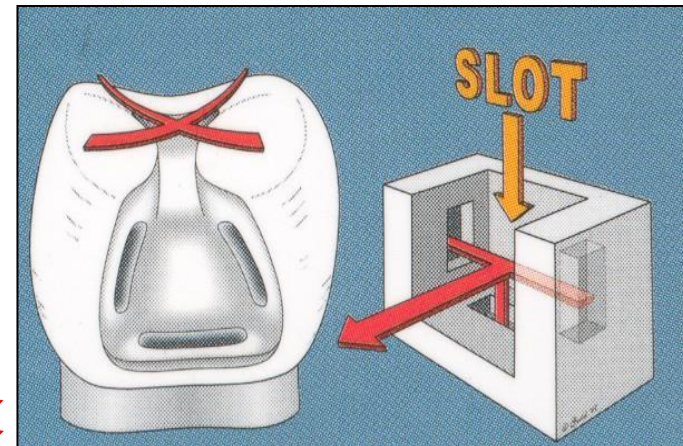
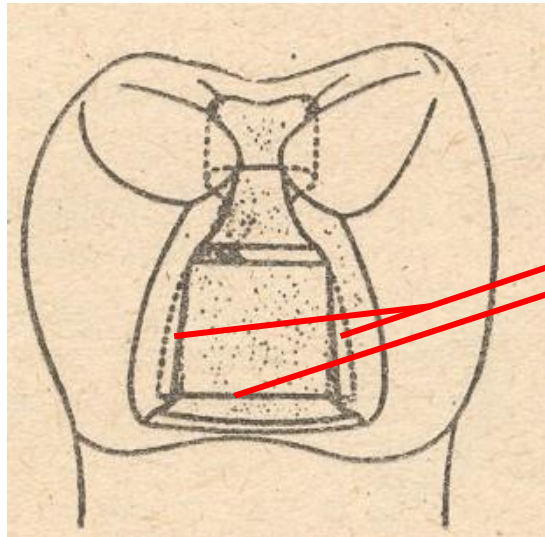


Proximal cavity – box

Slight divergency of axial walls

Gingival wall follows the cementoenamel junction

Gingival wall is below free gingiva



Autoretention

Grooves