




RTG zubů a čelistí

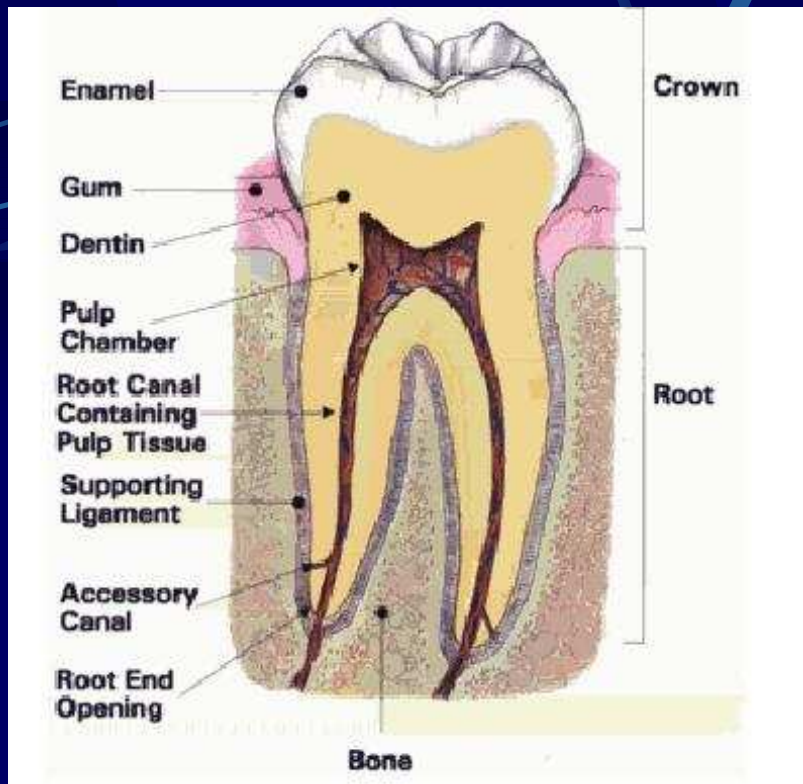
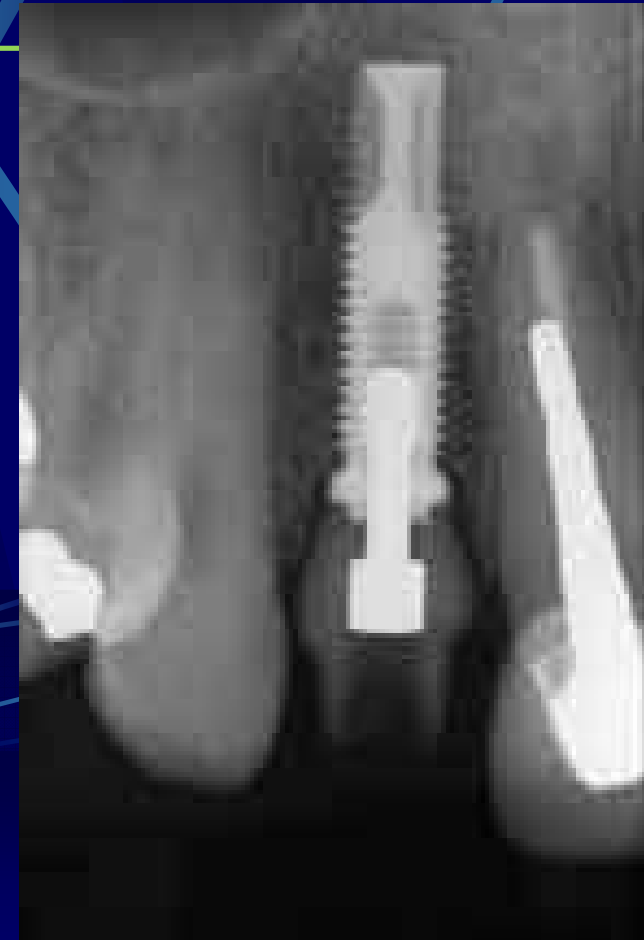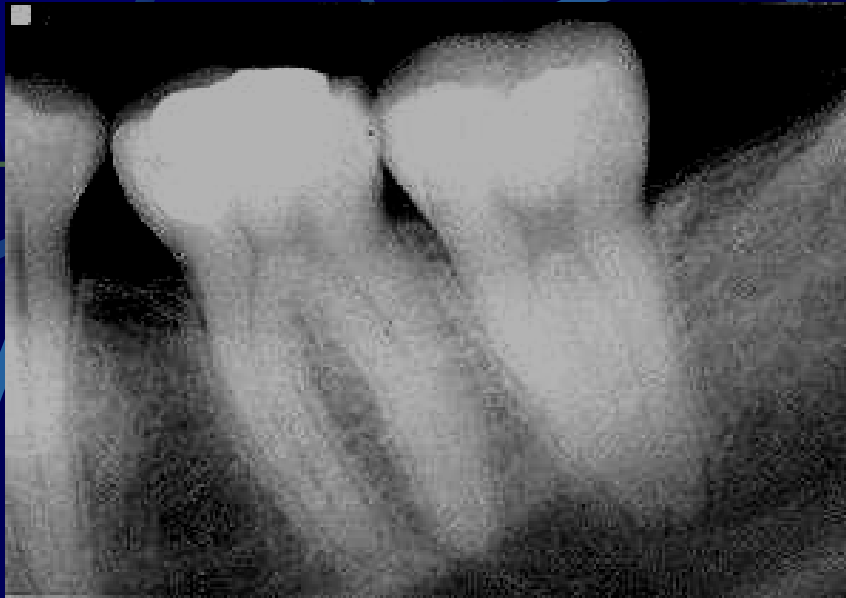Válek V. A.
Radiologická klinika LF, MOU Brno




Anatomie

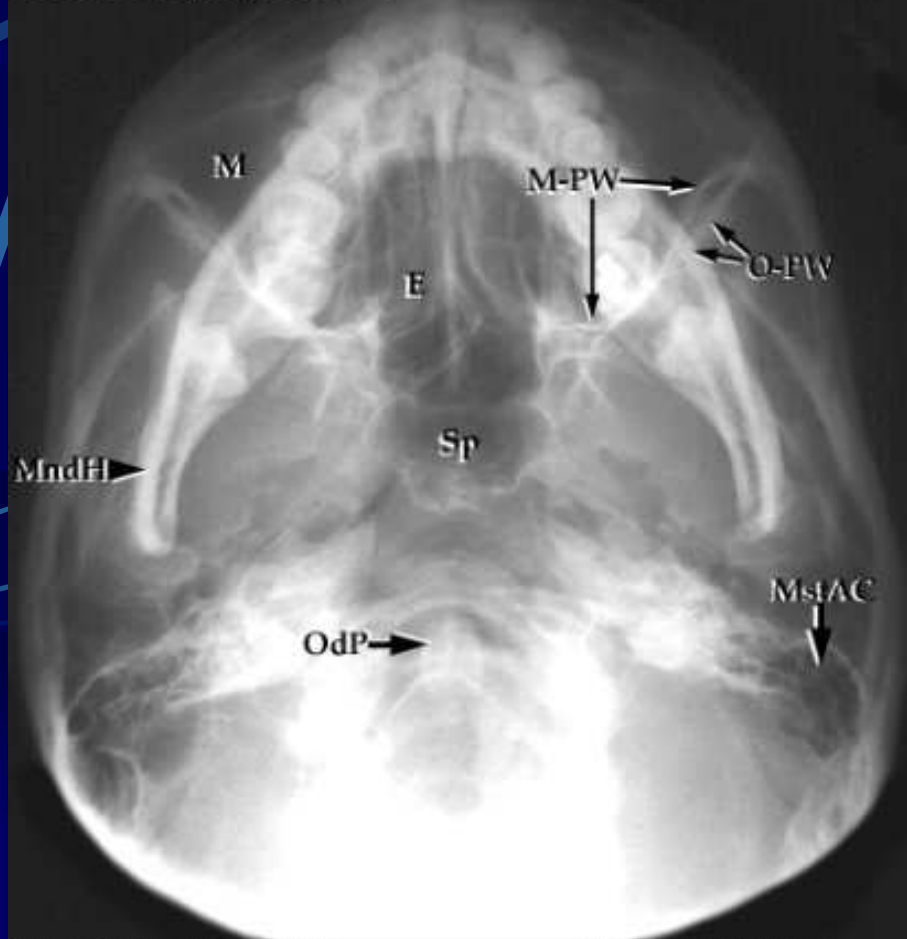


Anatomie

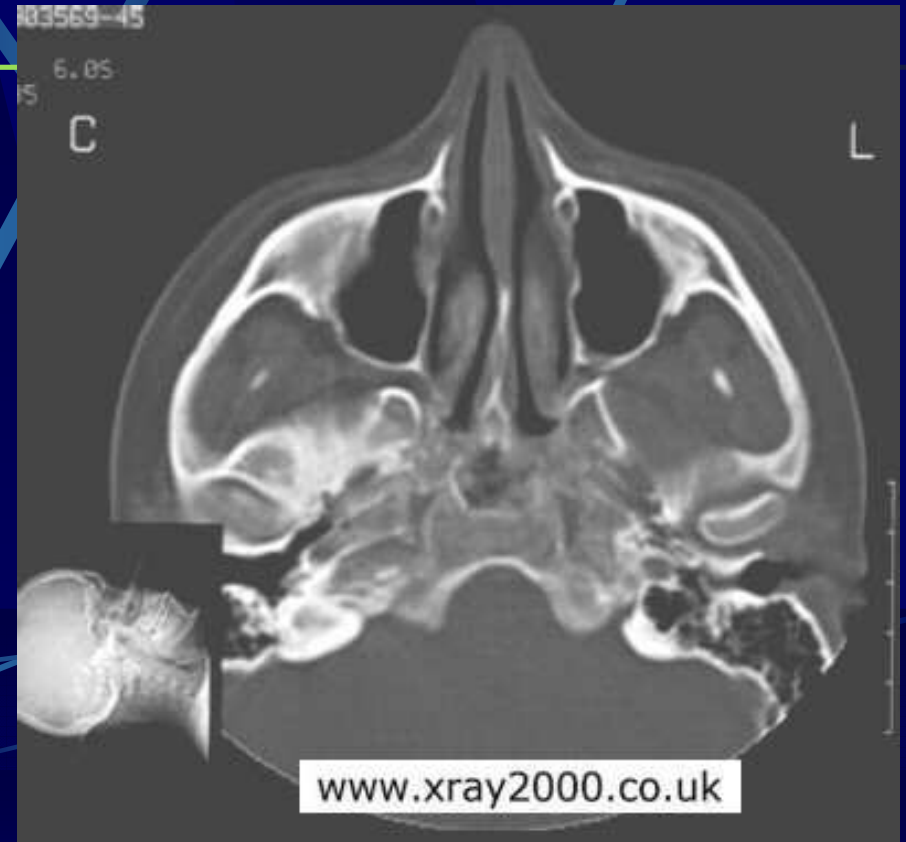




Base of the Skull

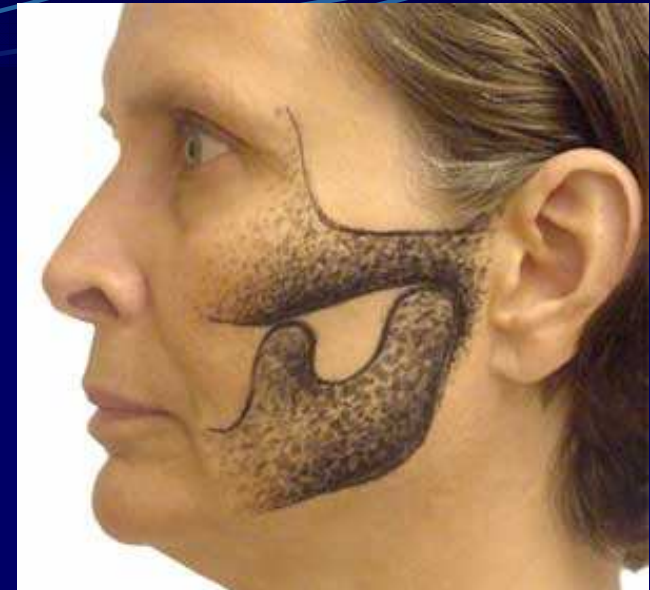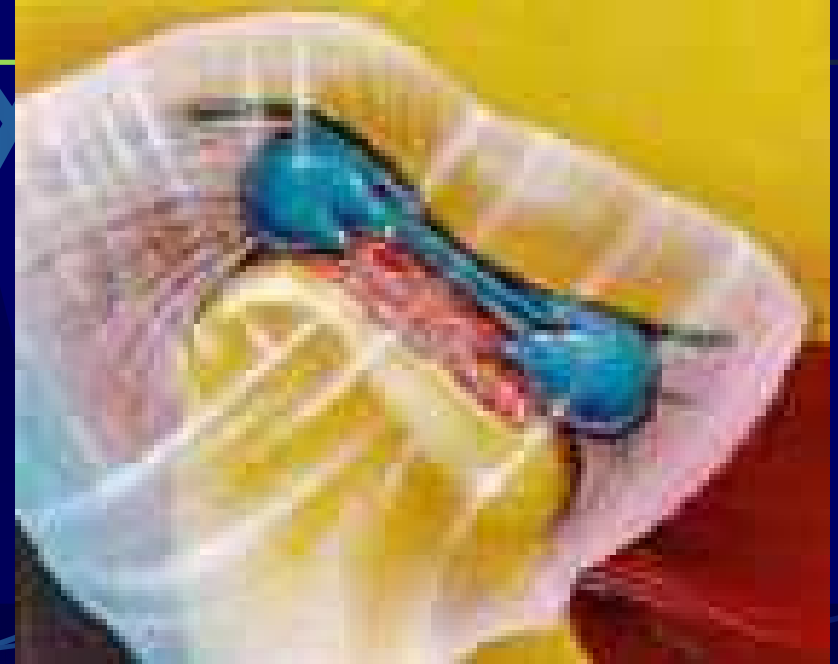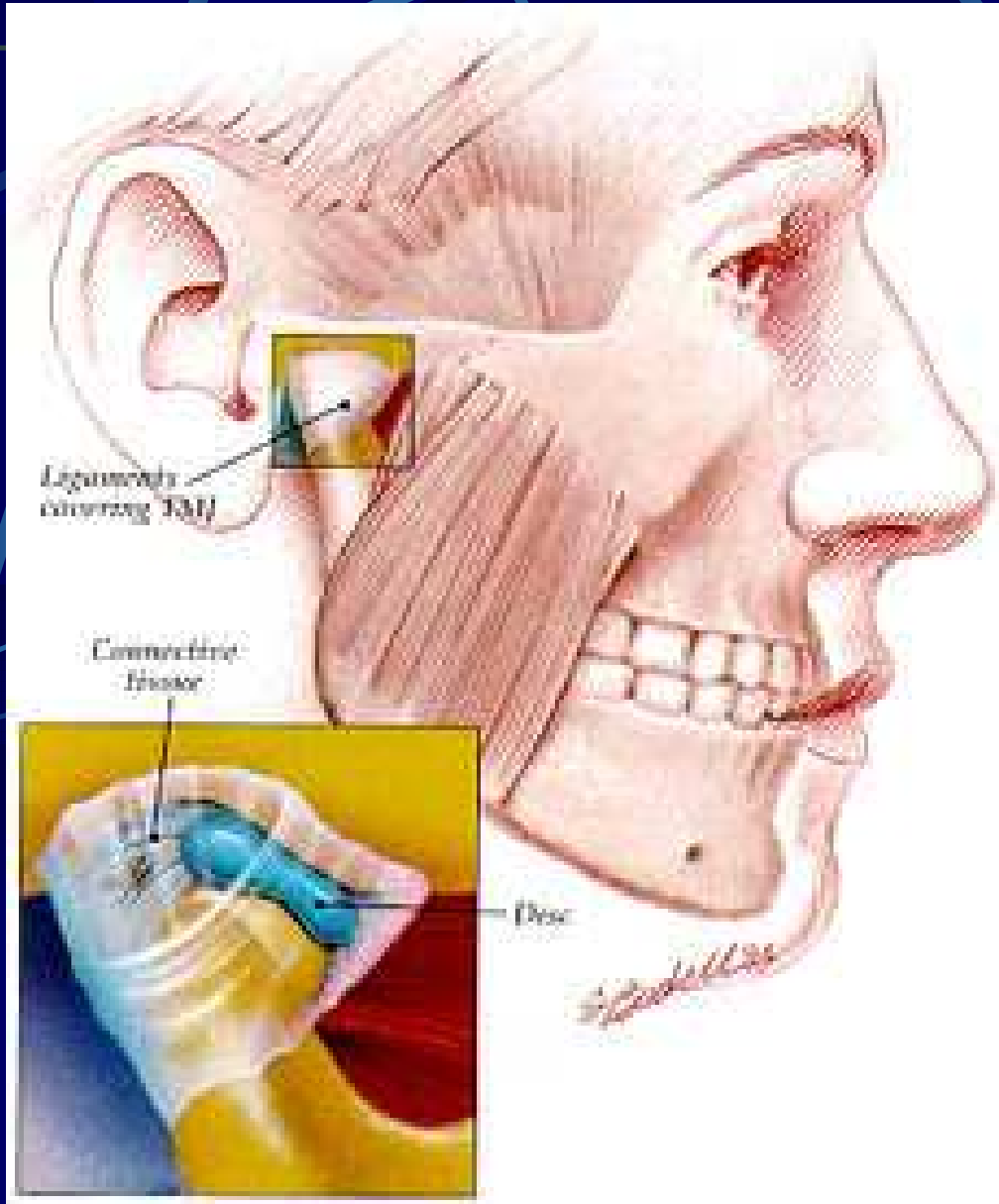


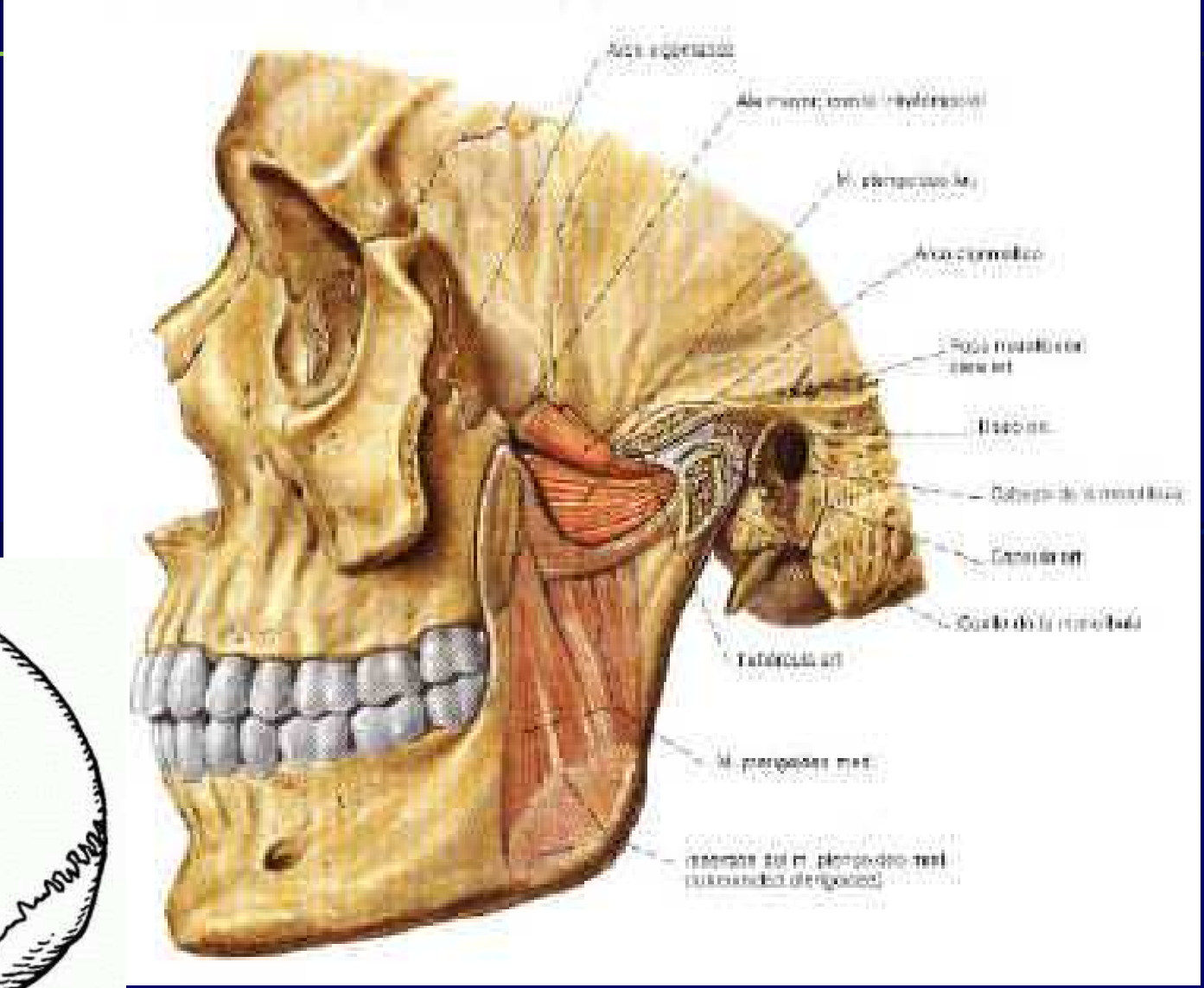
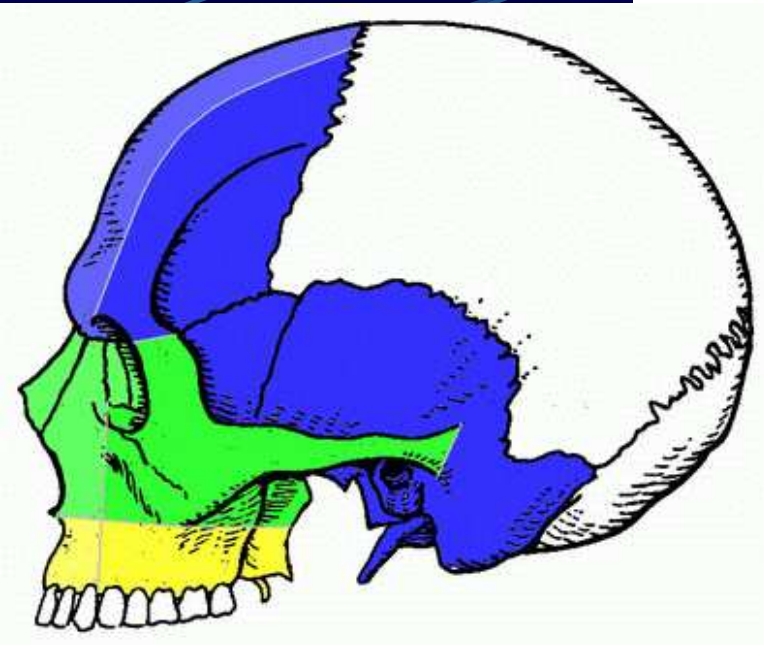

MstAC=Mastoid Air Cells	Sp=Sphenoid Sinus
E=Ethmoid Sinus (Air Cells)	M=Maxillary Sinus
O-PW=Posterior Wall of Orbit	MndH=Head of Mandible
M-PW=Posterior Wall of Maxillary Sinus	OdP=Odontoid Process





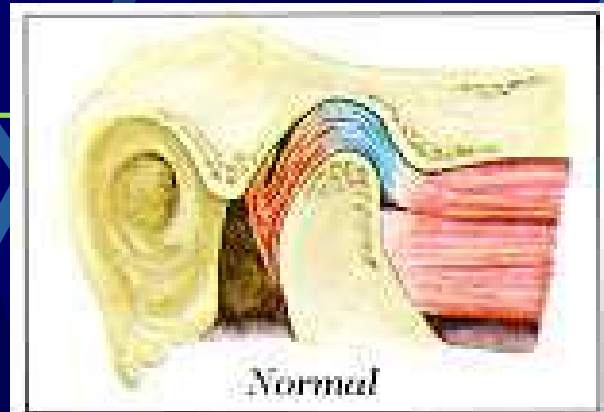

Anatomie



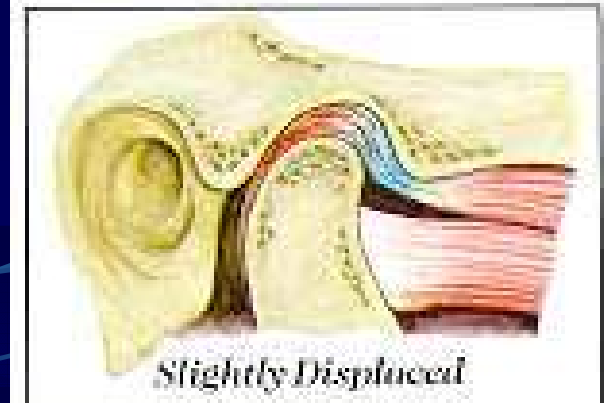




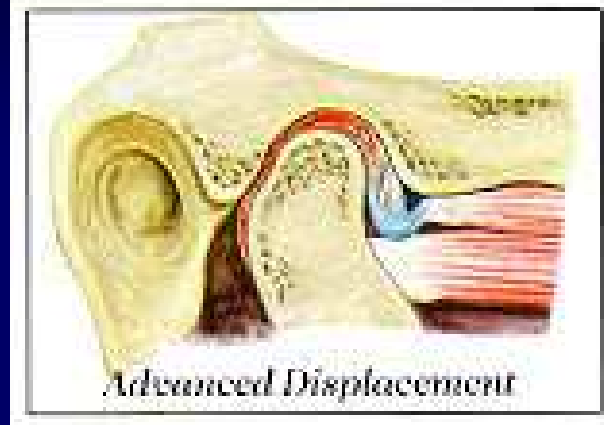Anatomie



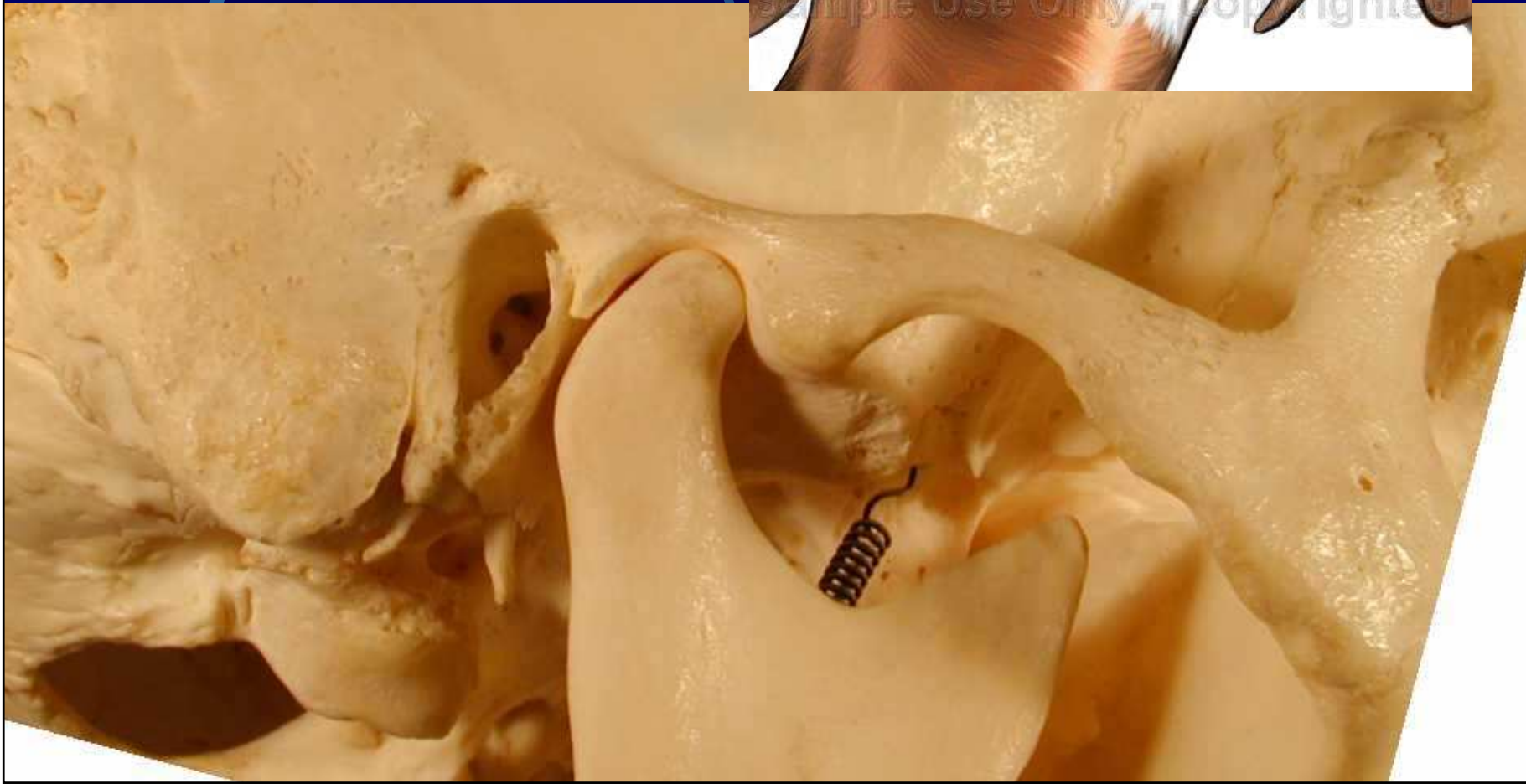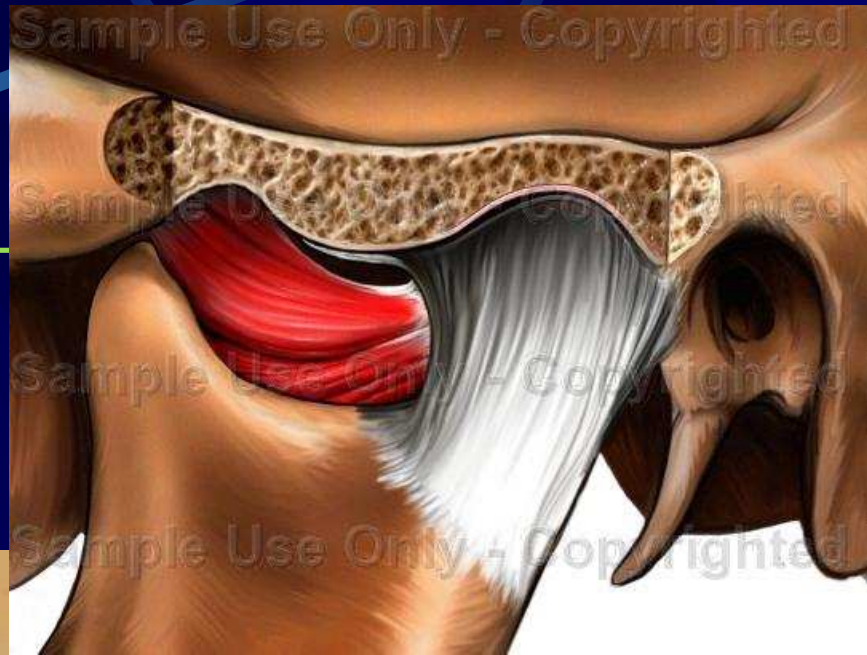
Normal



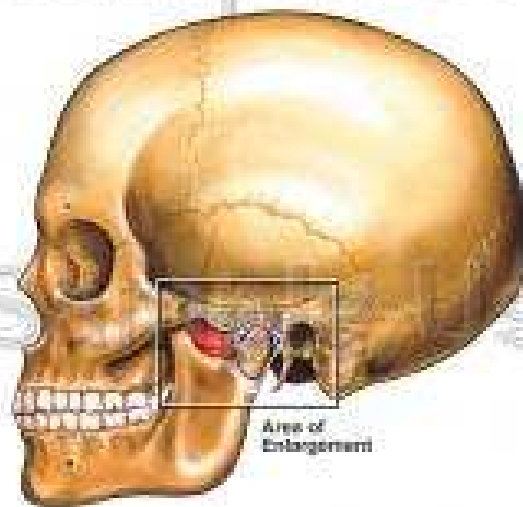
Slightly Displaced



Advanced Displacement



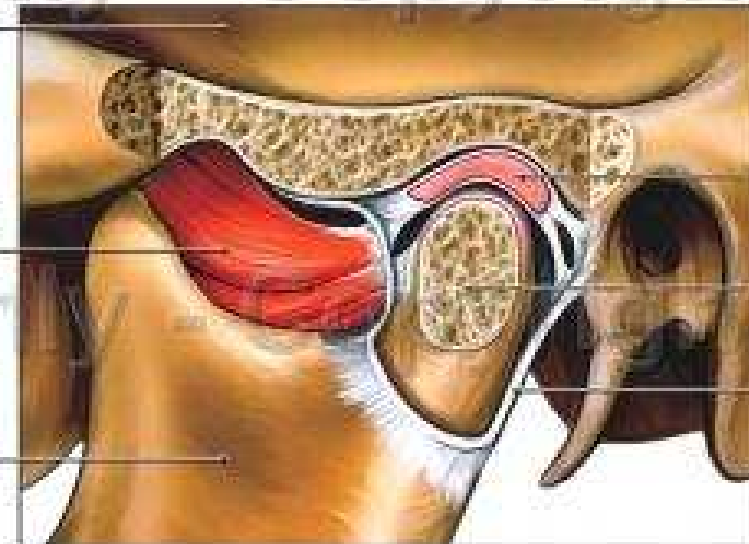
Anterior Displacement of the Left Temporomandibular Joint (TMJ)



Temporal bone

Pterygoid muscle

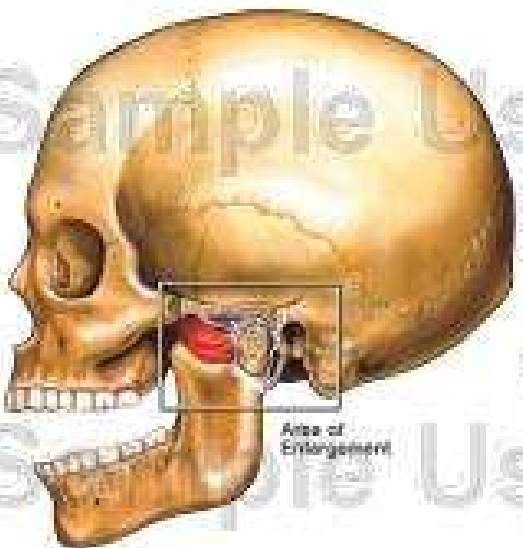
Mandible



Meniscus

Condyle

Joint capsule

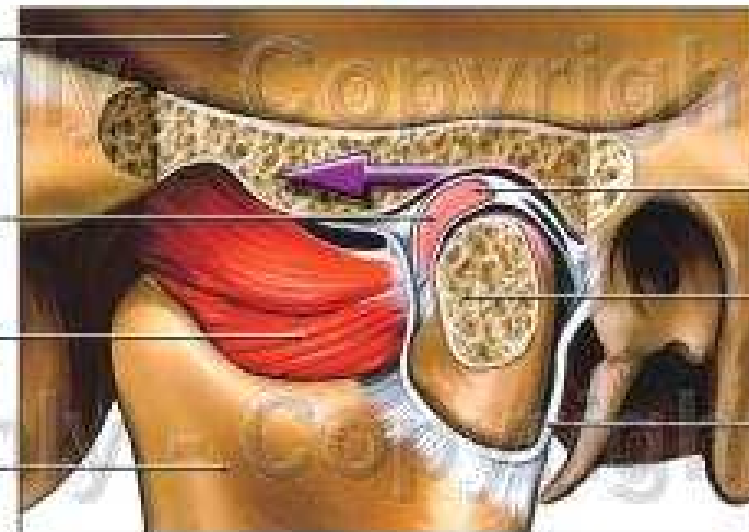


Temporal bone

Anterior displacement of TMJ meniscus

Pterygoid muscle

Mandible




Meniscus

Condyle

Joint capsule

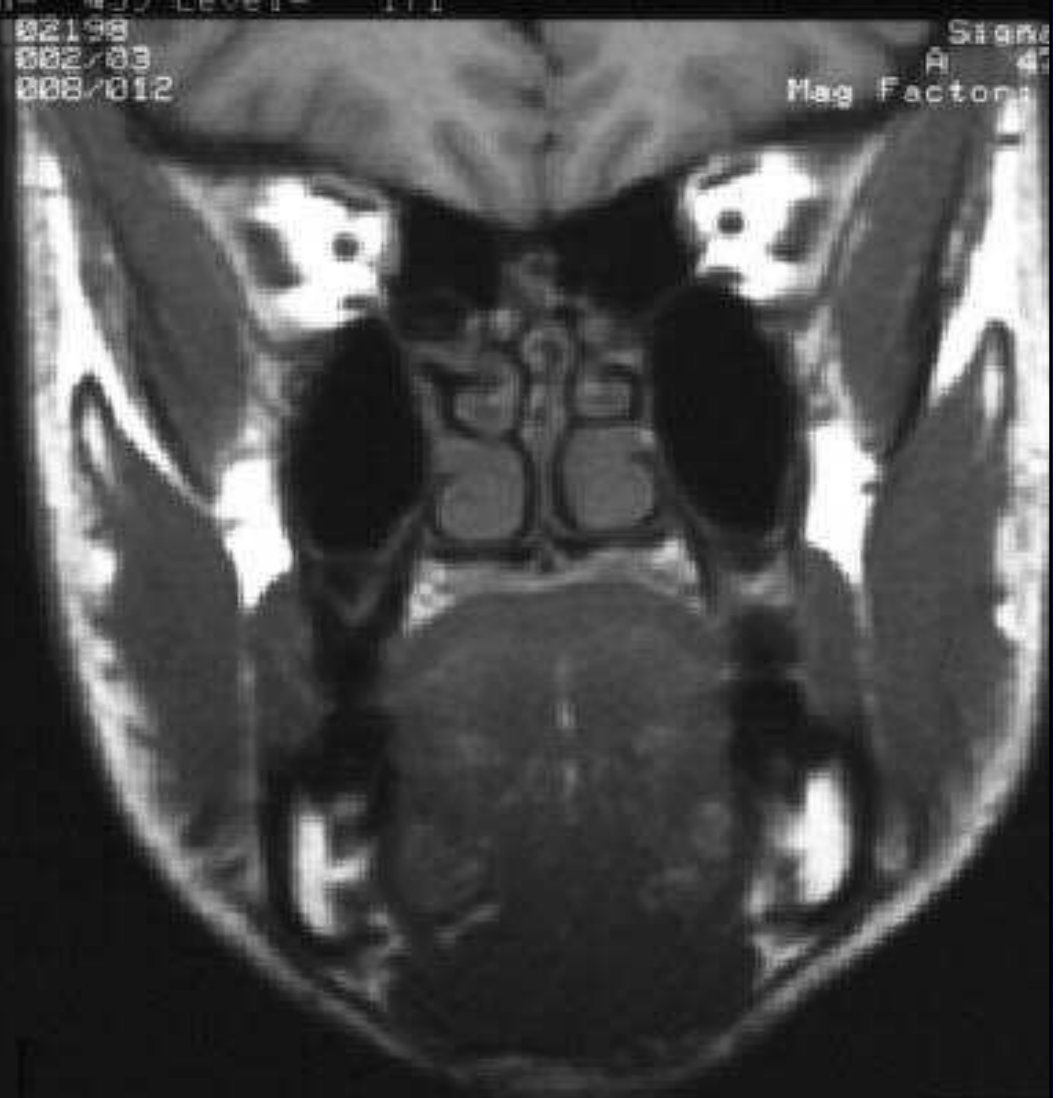
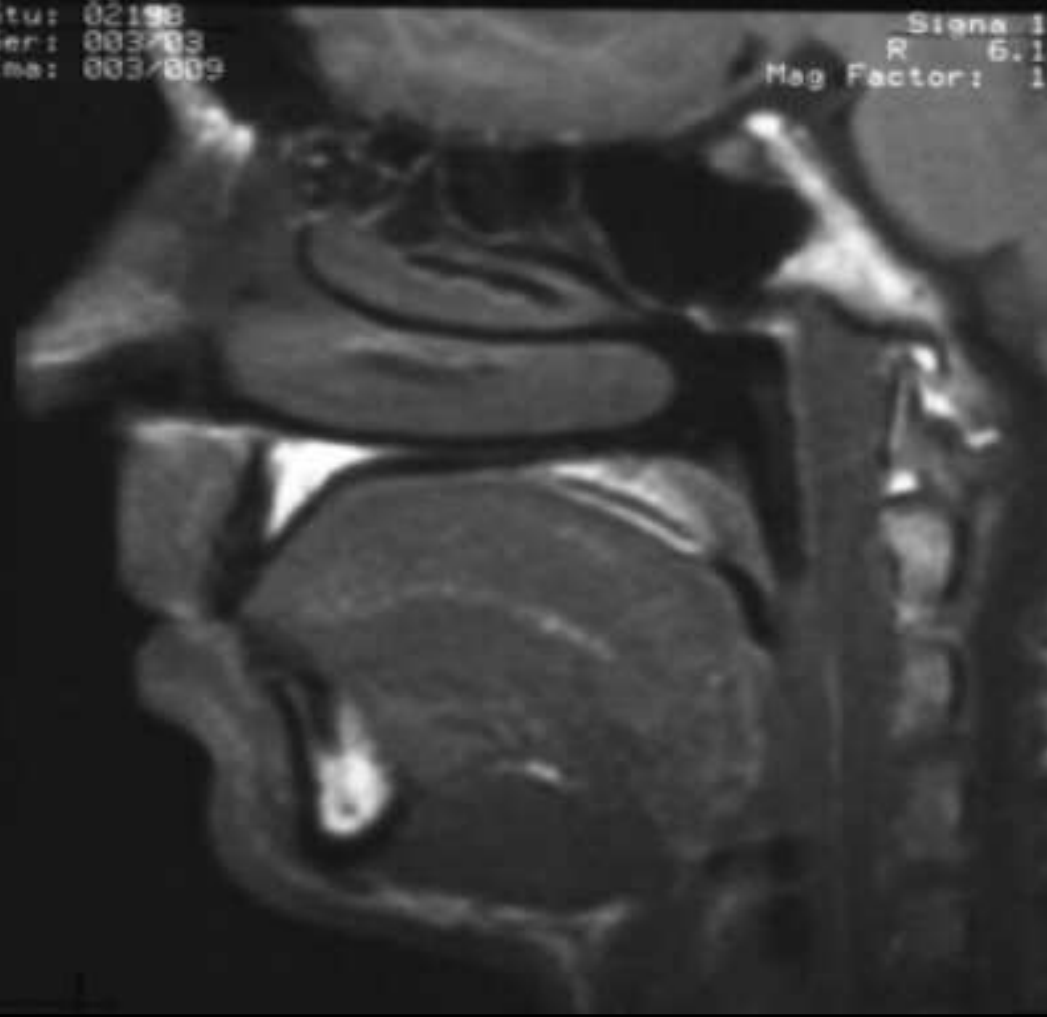
Anatomie



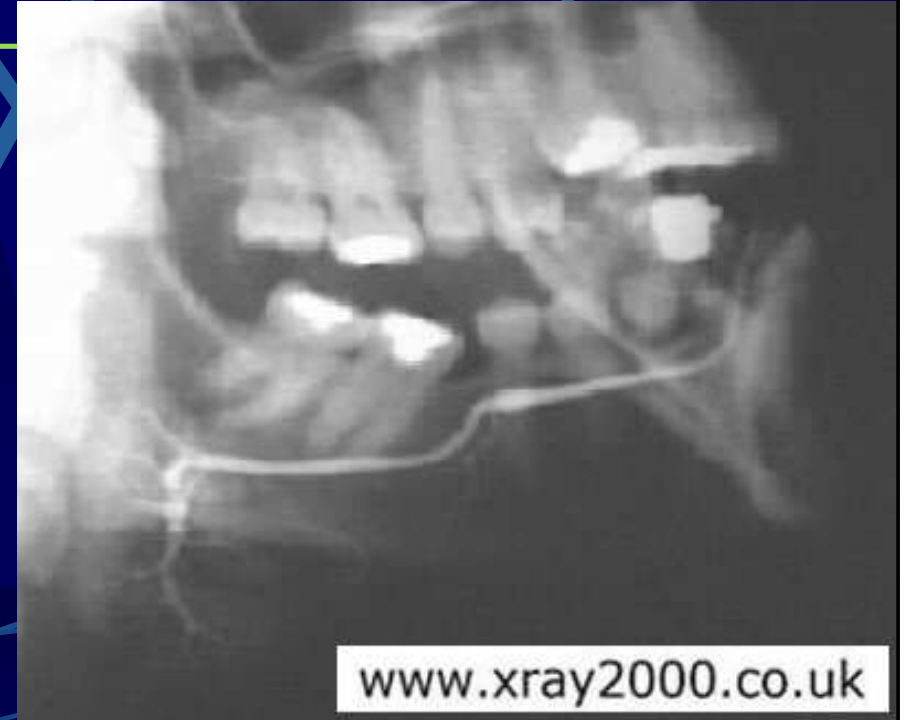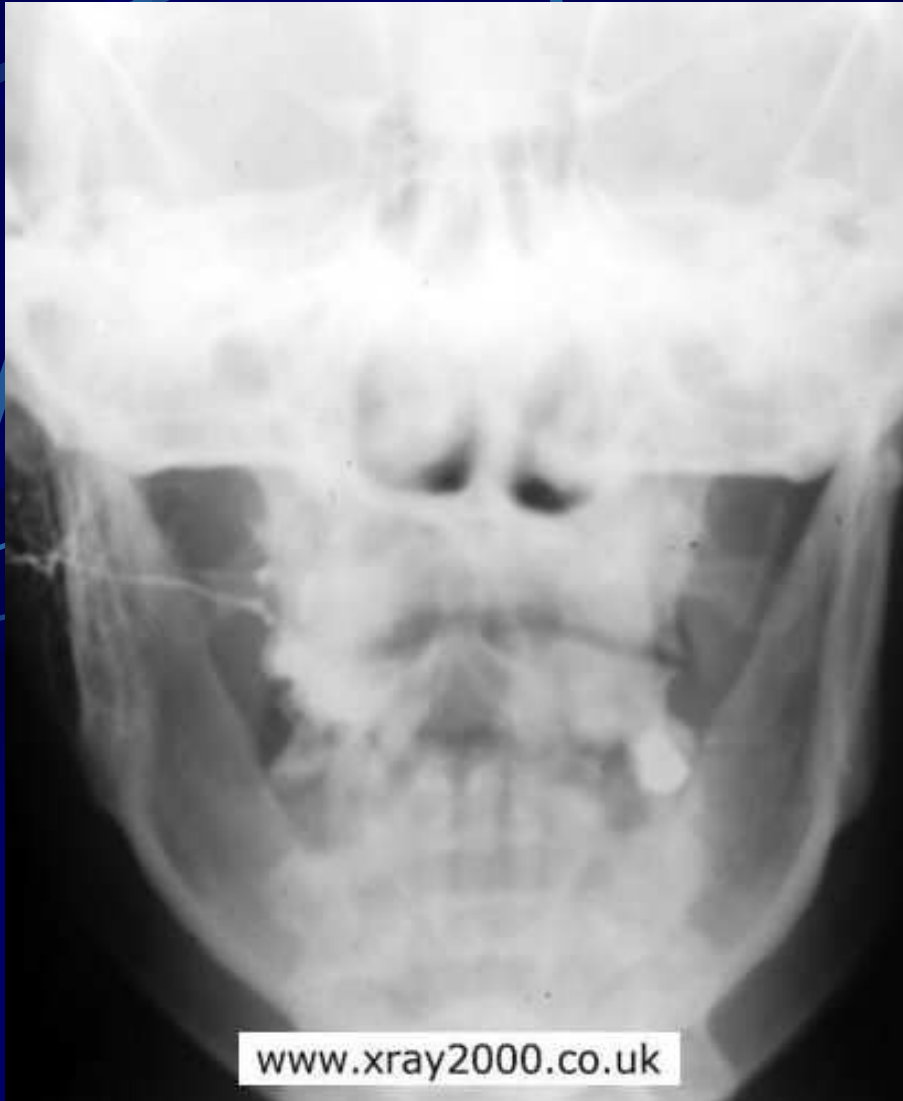tu: 02198
er: 003/03
na: 003/009

Signa: 1
R: 6.1
Mag Factor: 1






Anatomie

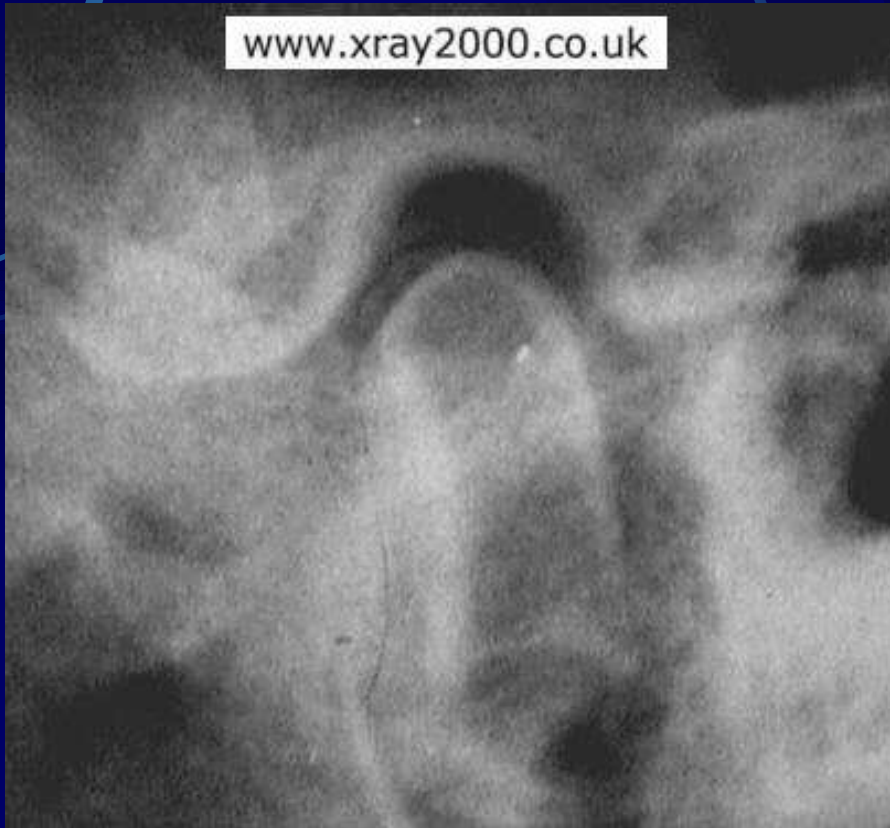



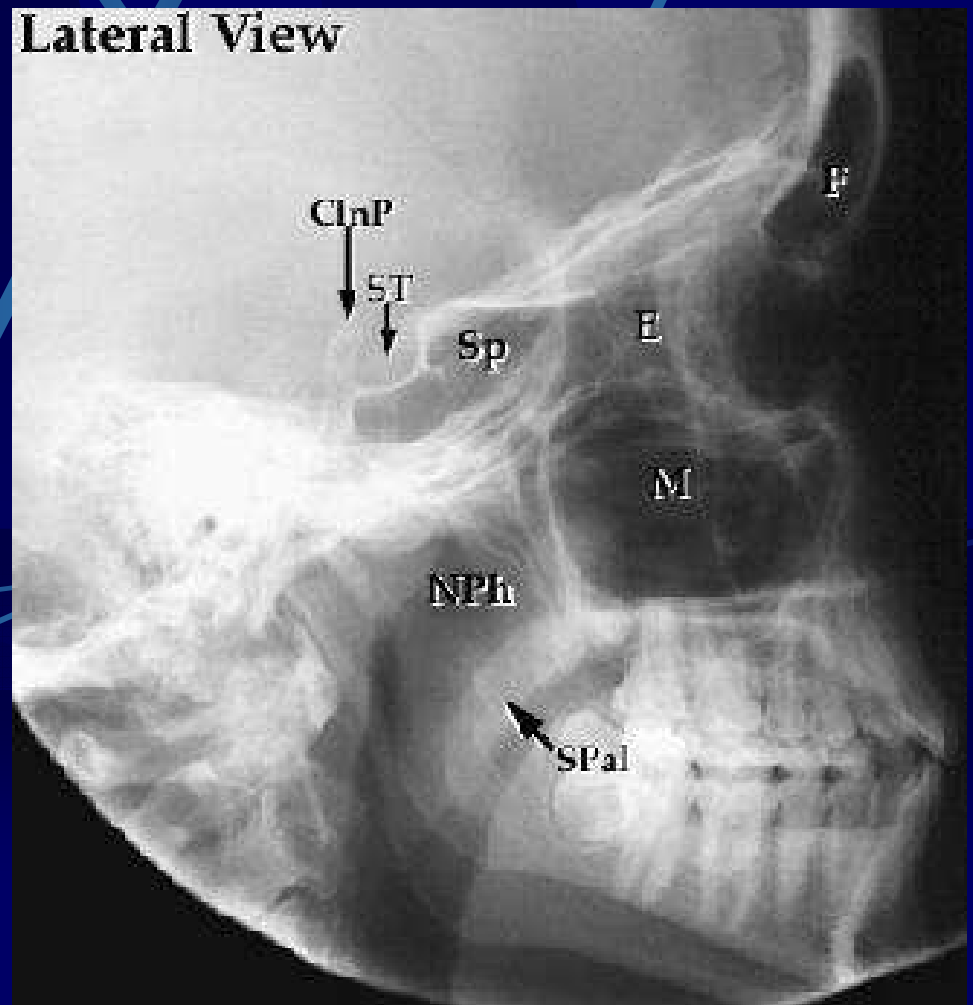
Anatomie



www.xray2000.co.uk



Lateral View



F=Frontal Sinus
E=Ethmoid Sinus
Sp=Sphenoid Sinus
M=Maxillary Sinus

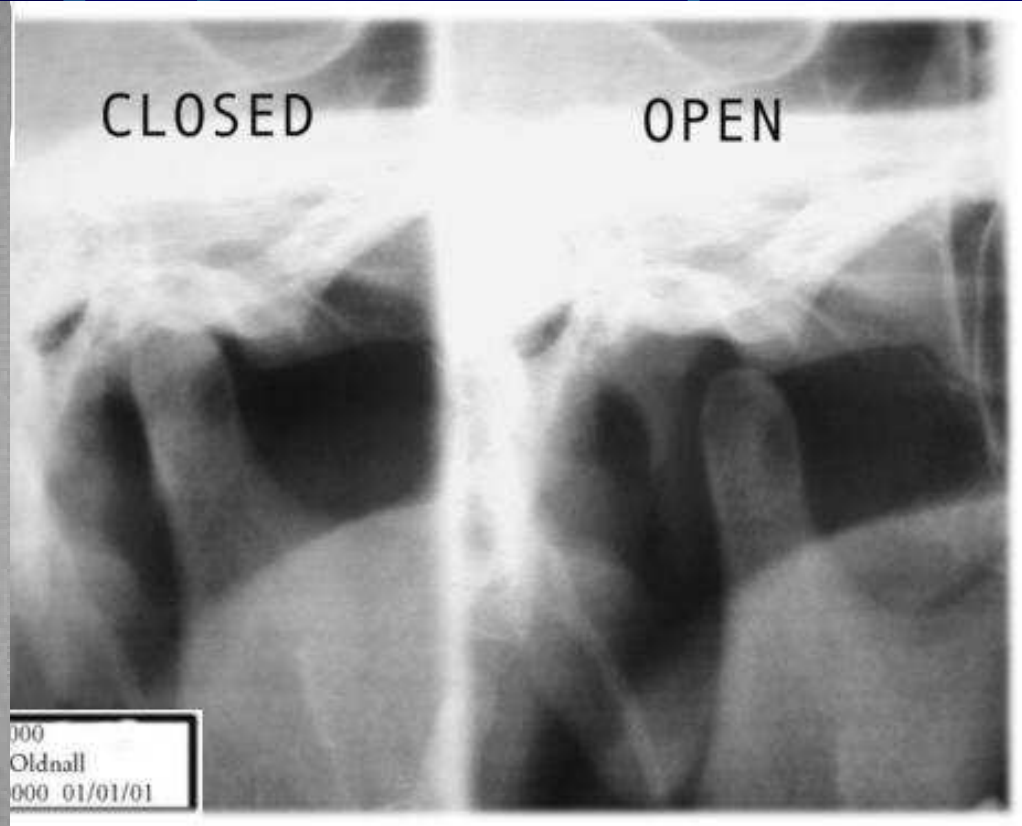
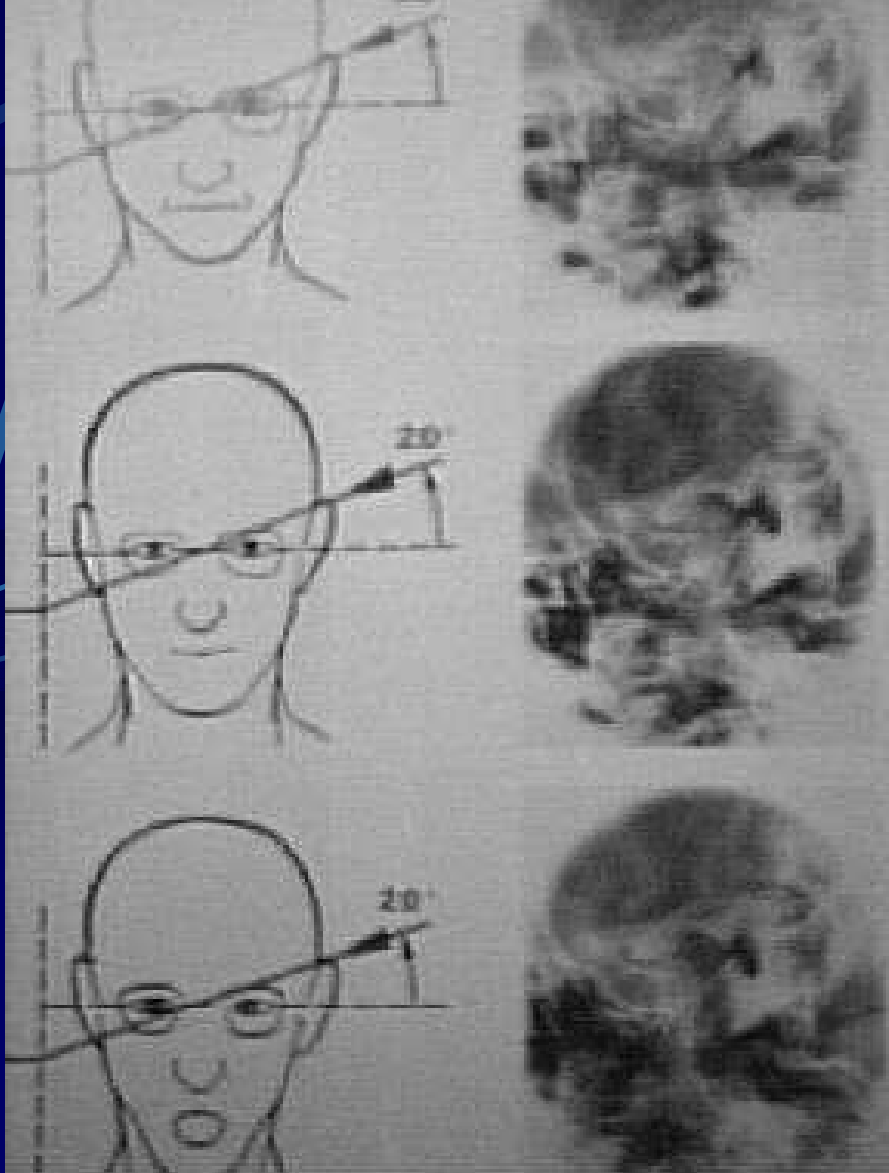
ST=Sella Turcica (Pituitary Fossa)
ClnP=Posterior Clinoid
NPh=Nasopharynx
SPal=Soft Palate



Anatomie

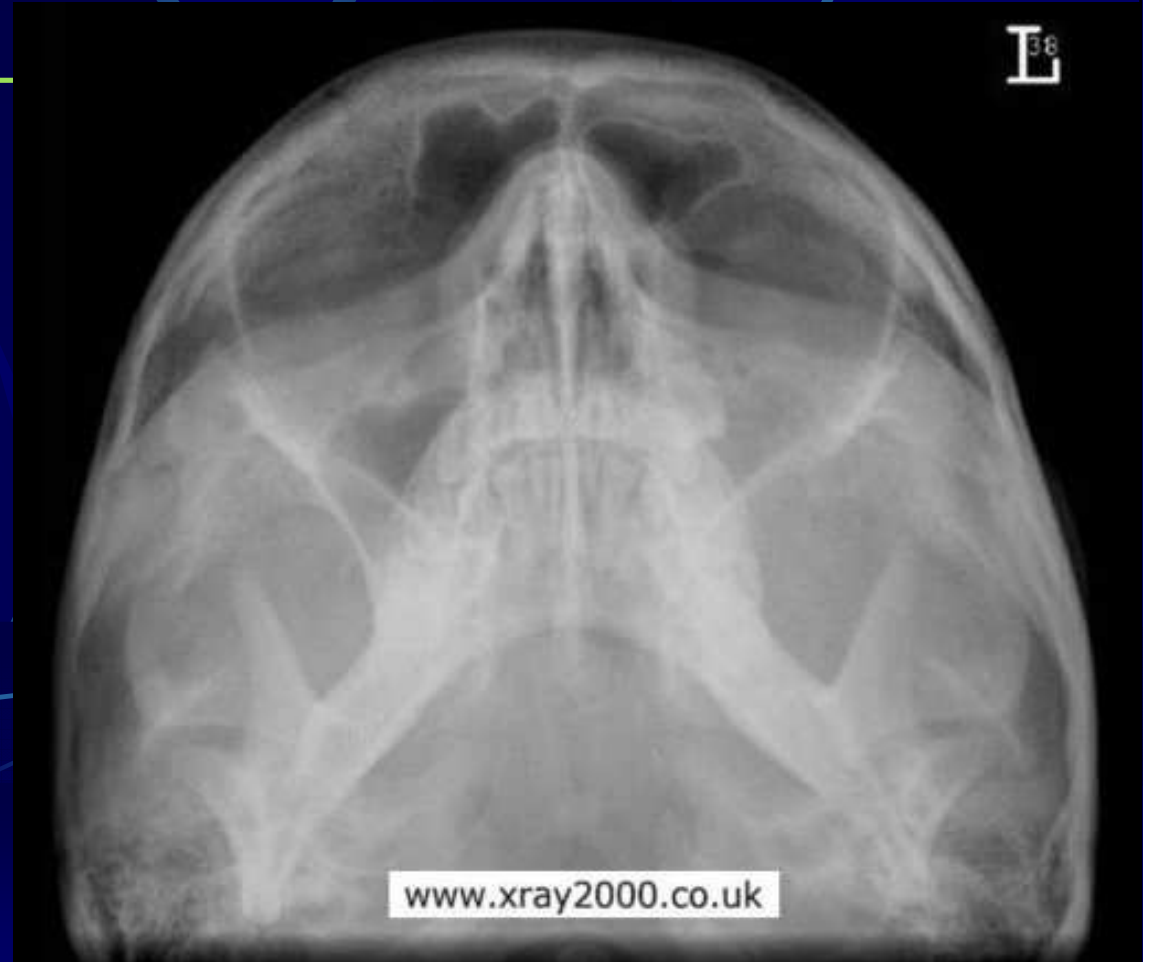

Anders Movin Karlison



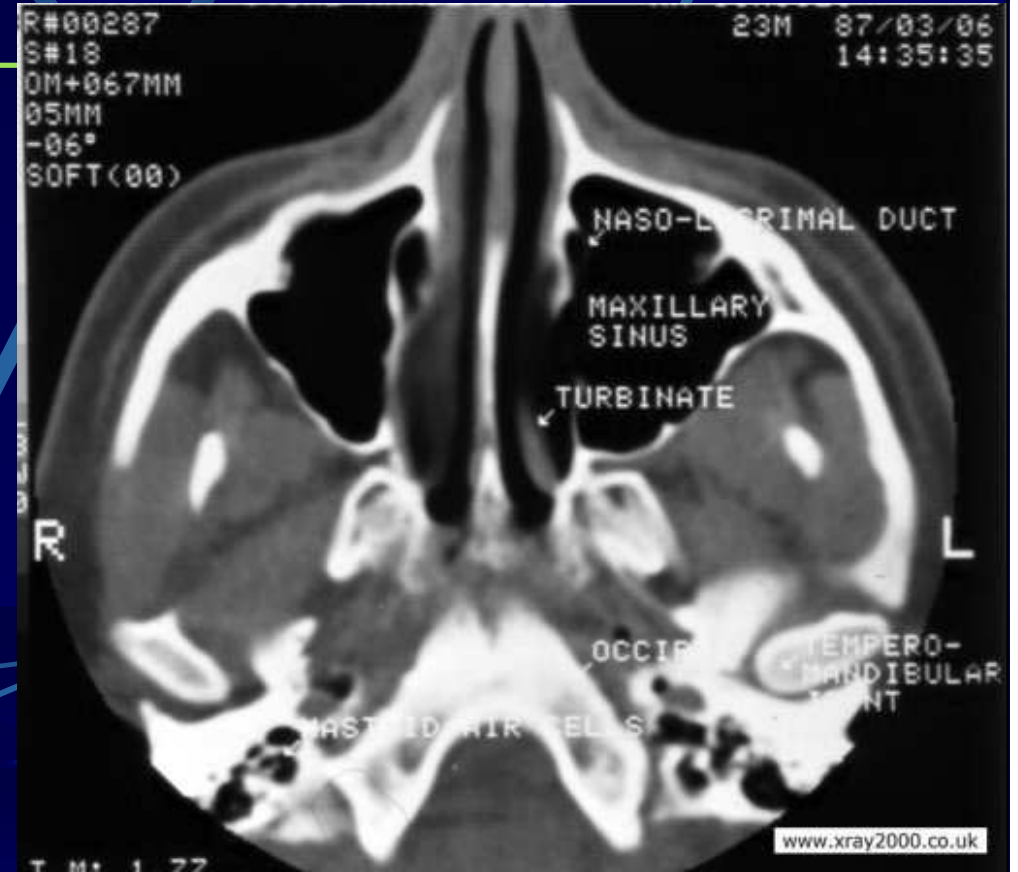
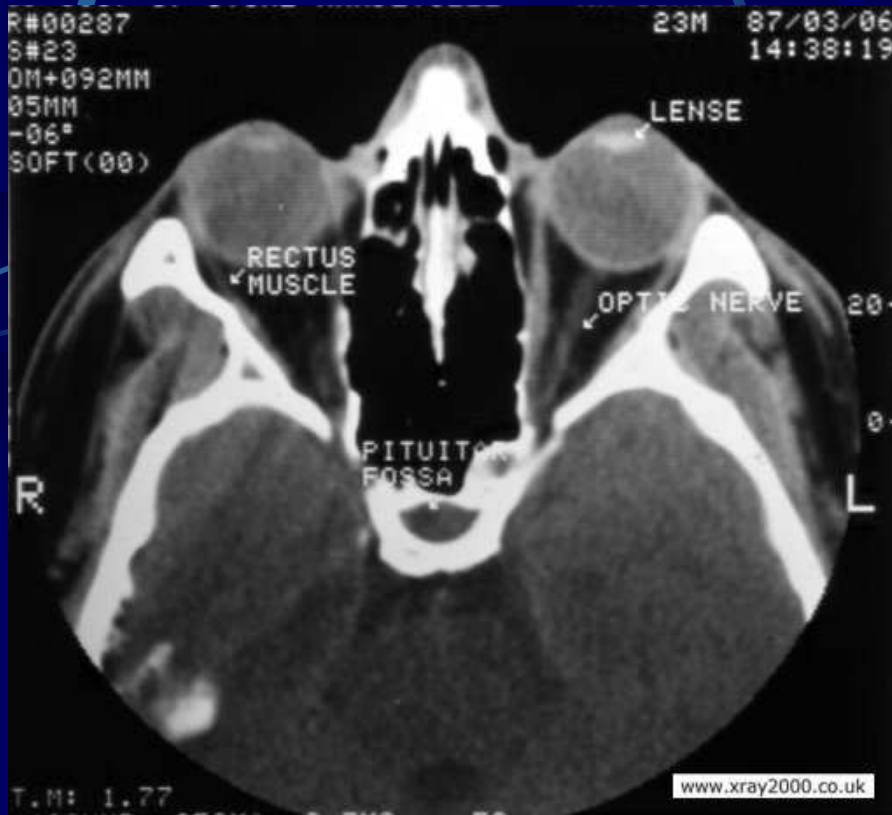


Anatomie





Anatomie

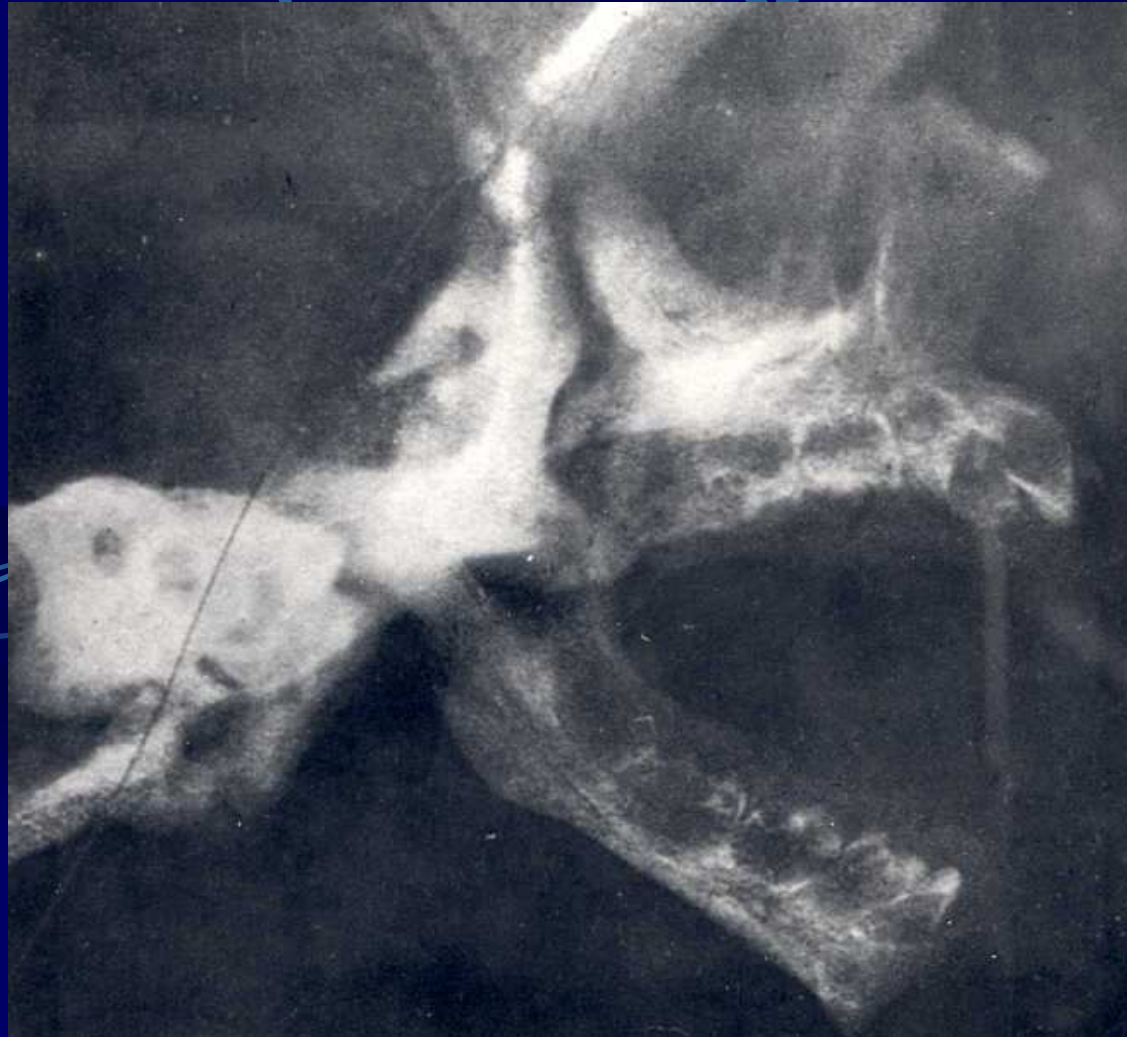





Vývoj zubu

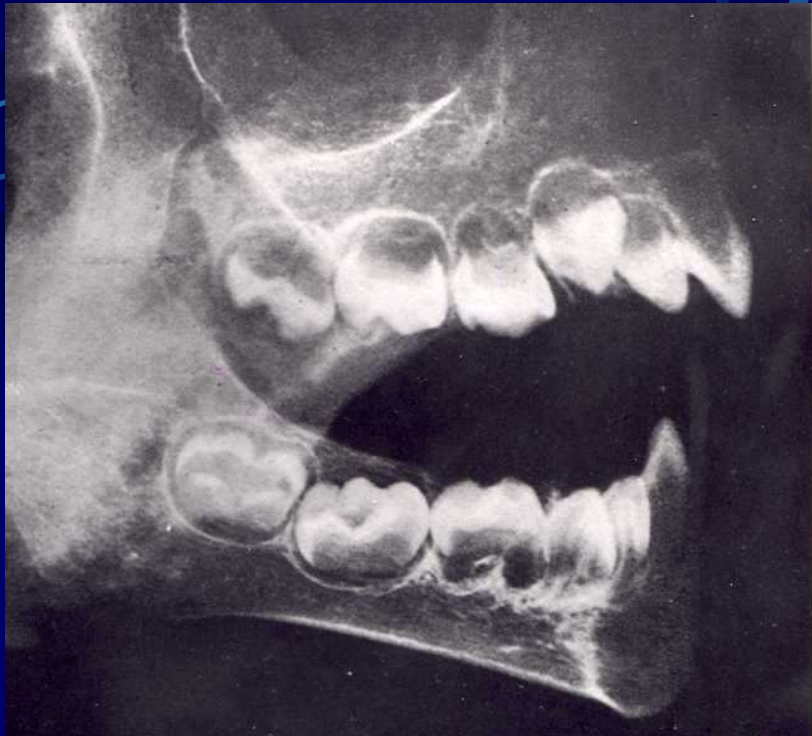
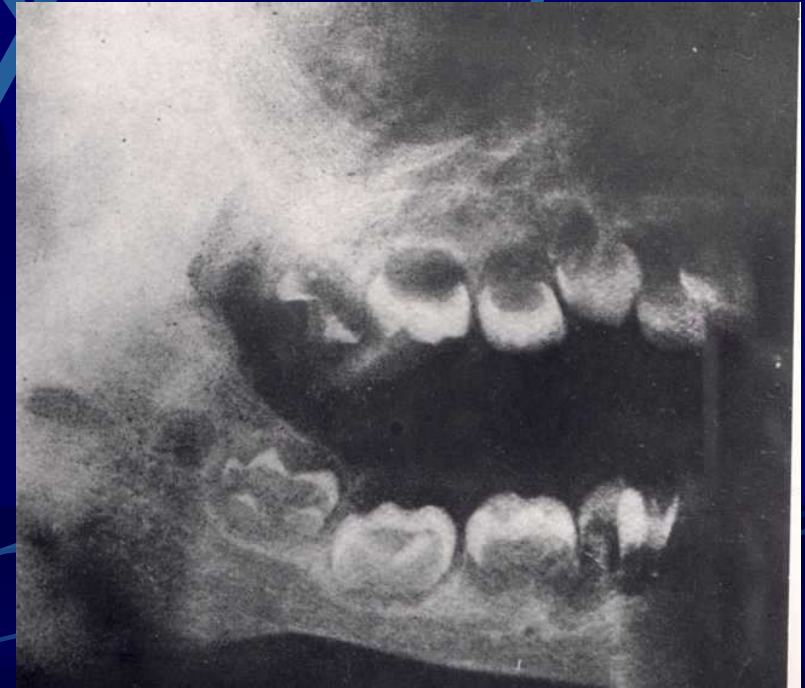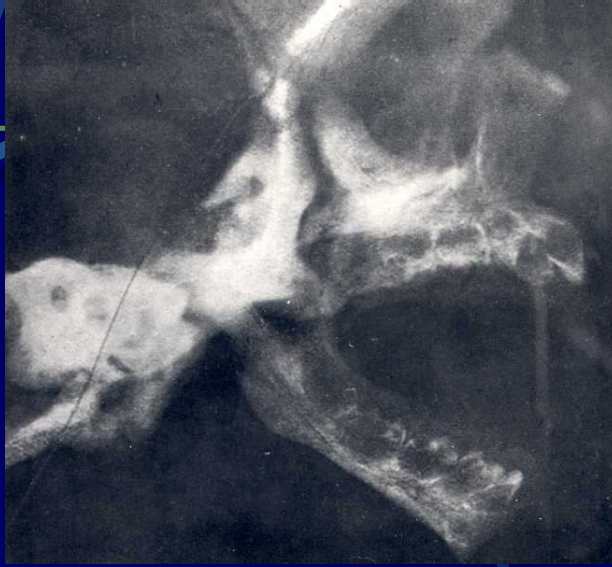



Zuby – vývoj - novorozenec

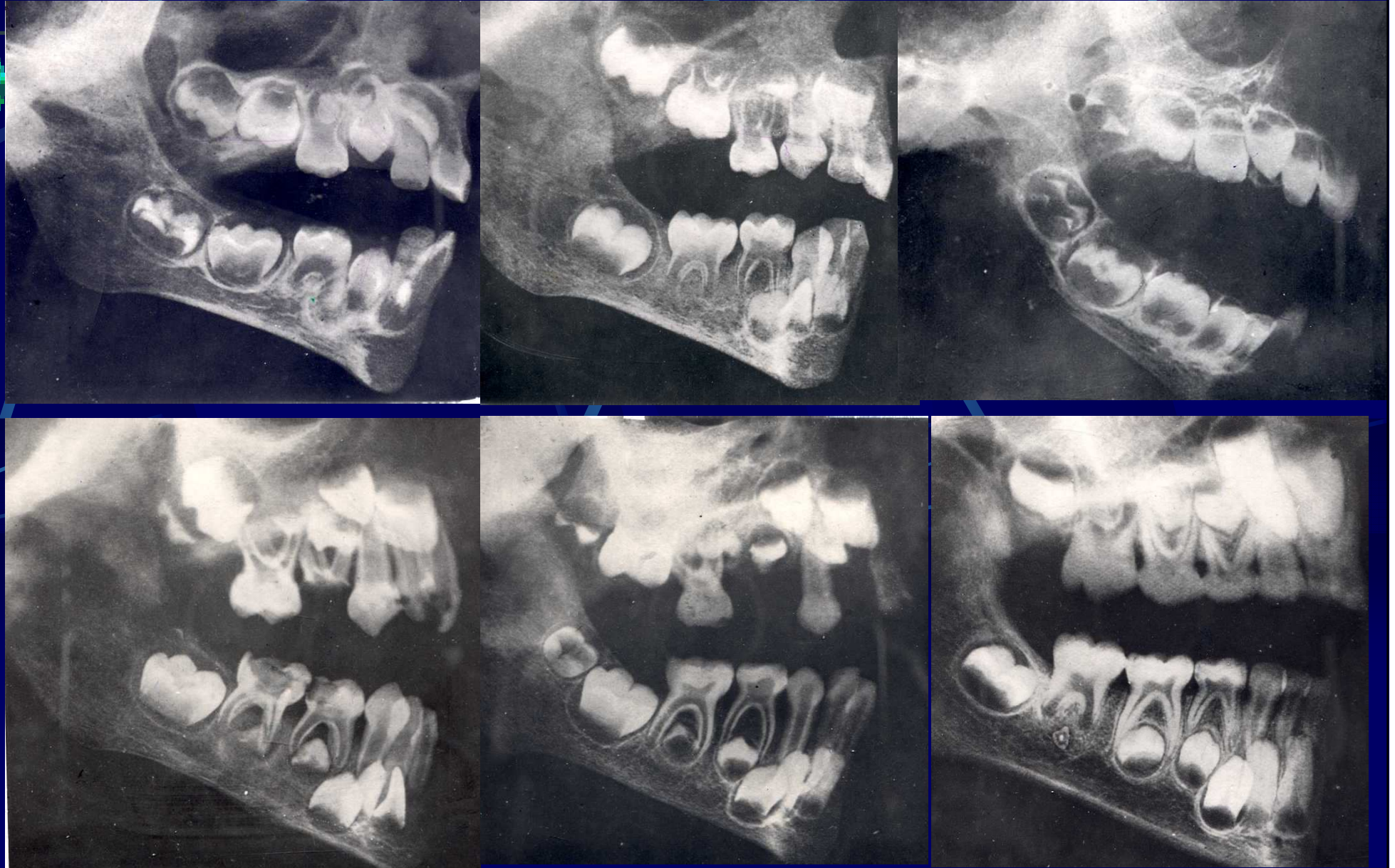




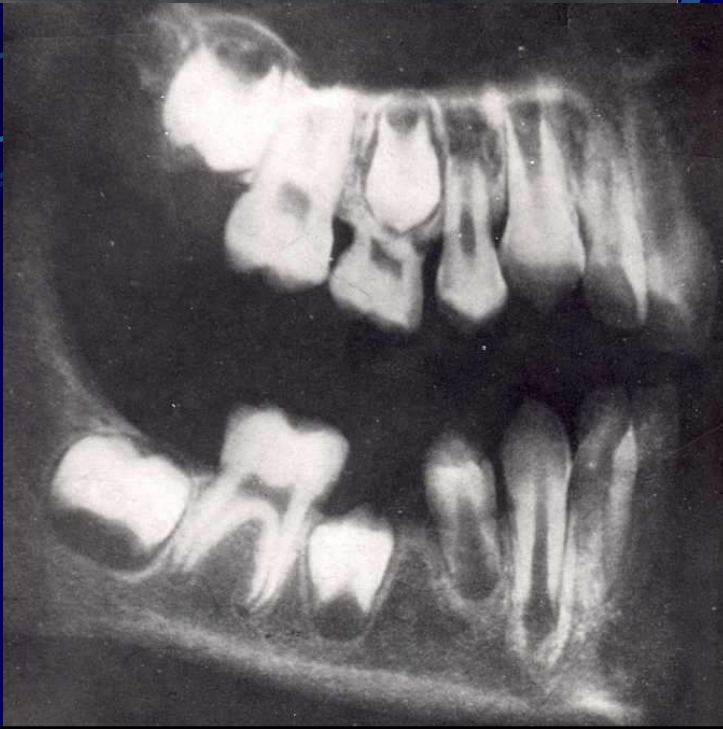
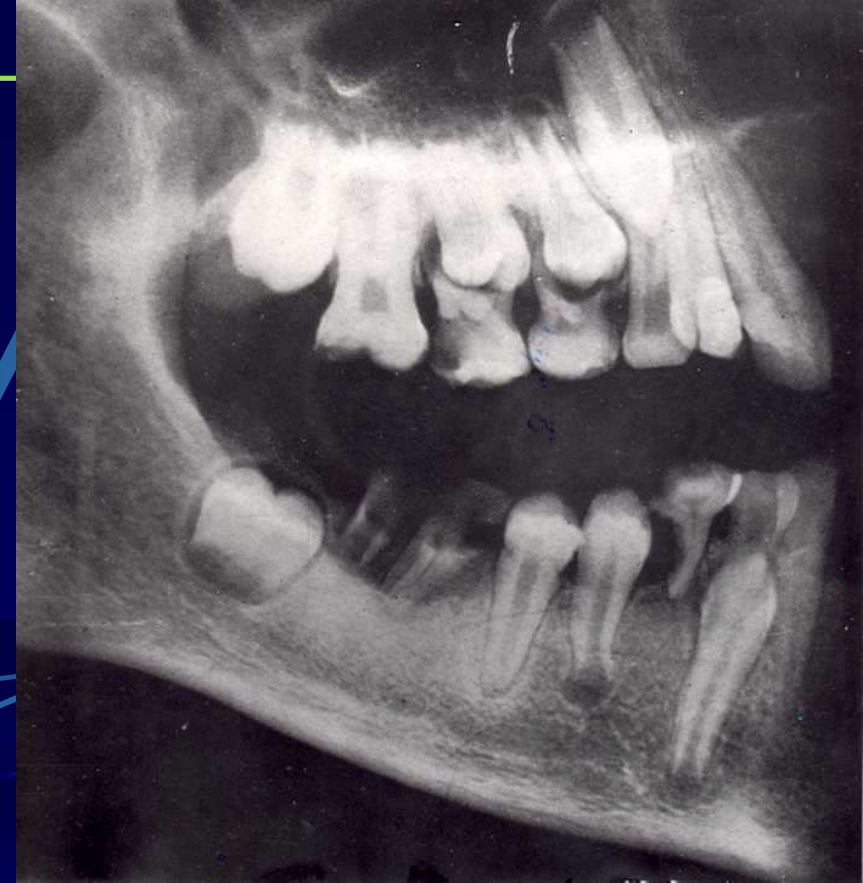
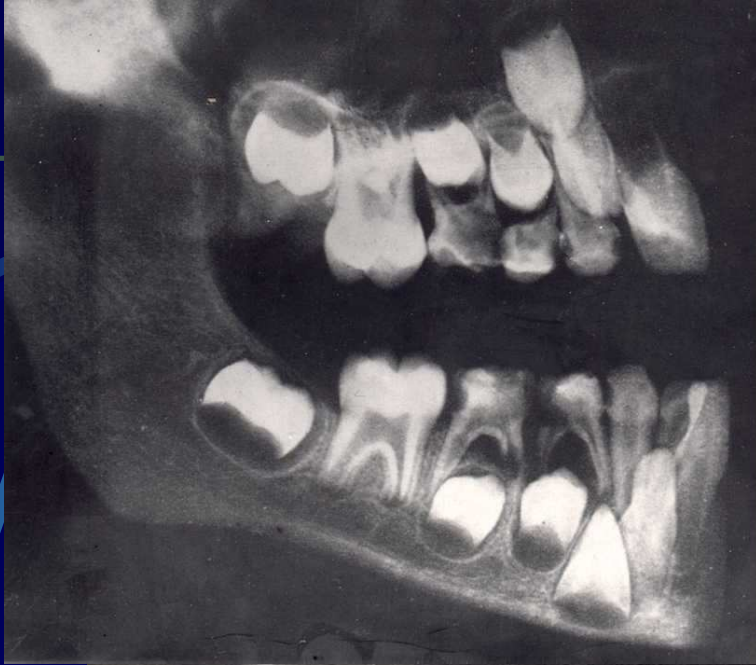
Zuby – vývoj – 6 a 9 měsíc



Zuby – vývoj – 1 – 6 rok




Zuby – vývoj – 7-10 let

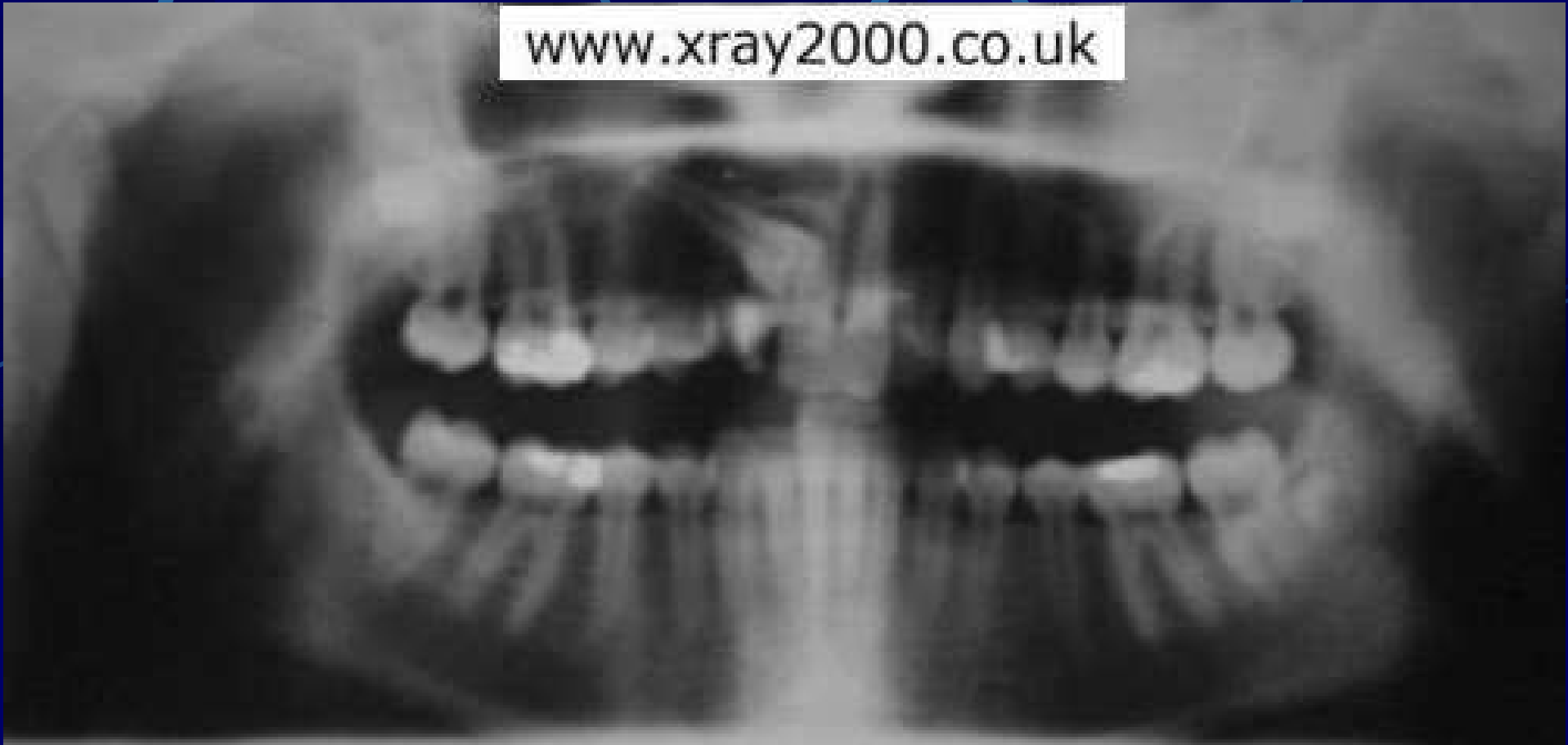



Zuby – vývoj – ektopický zub



www.xray2000.co.uk

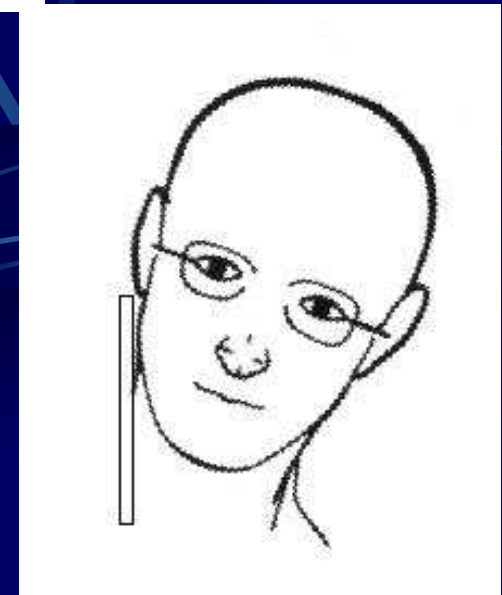
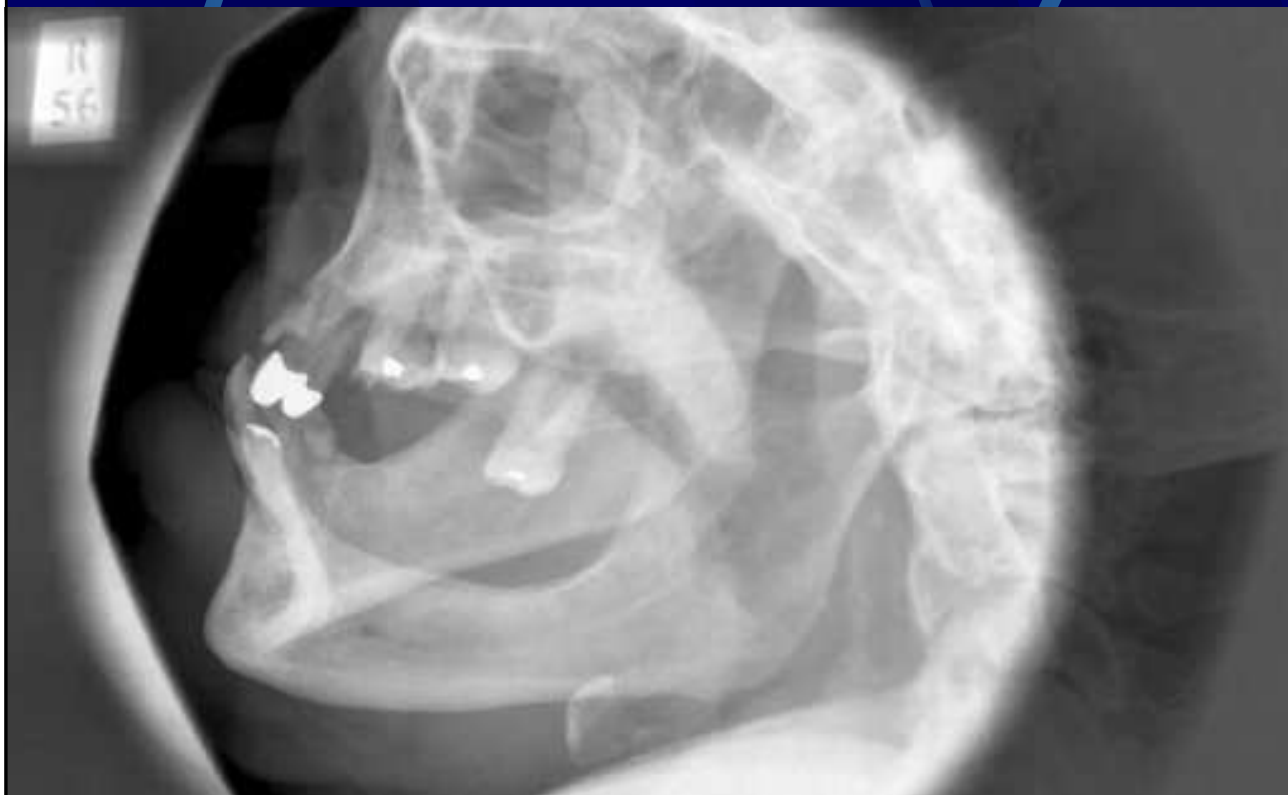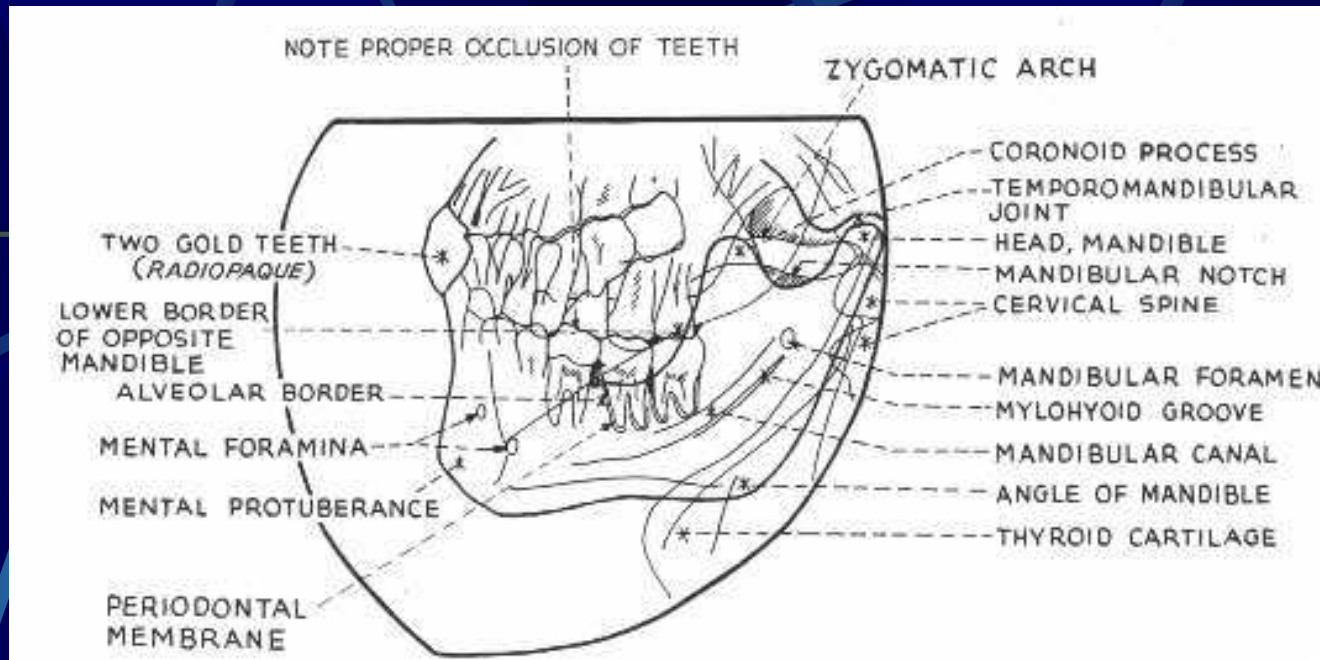




Projekce

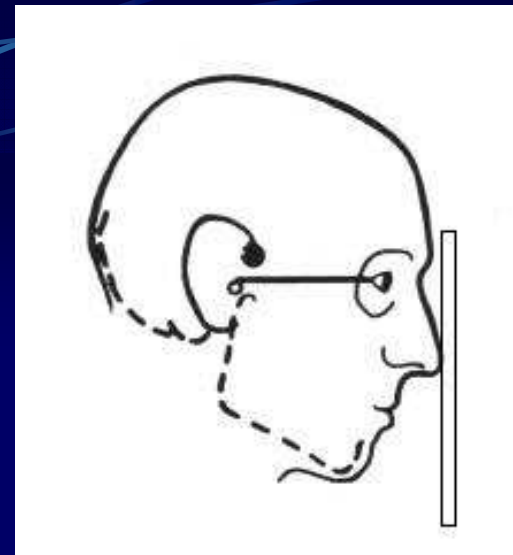
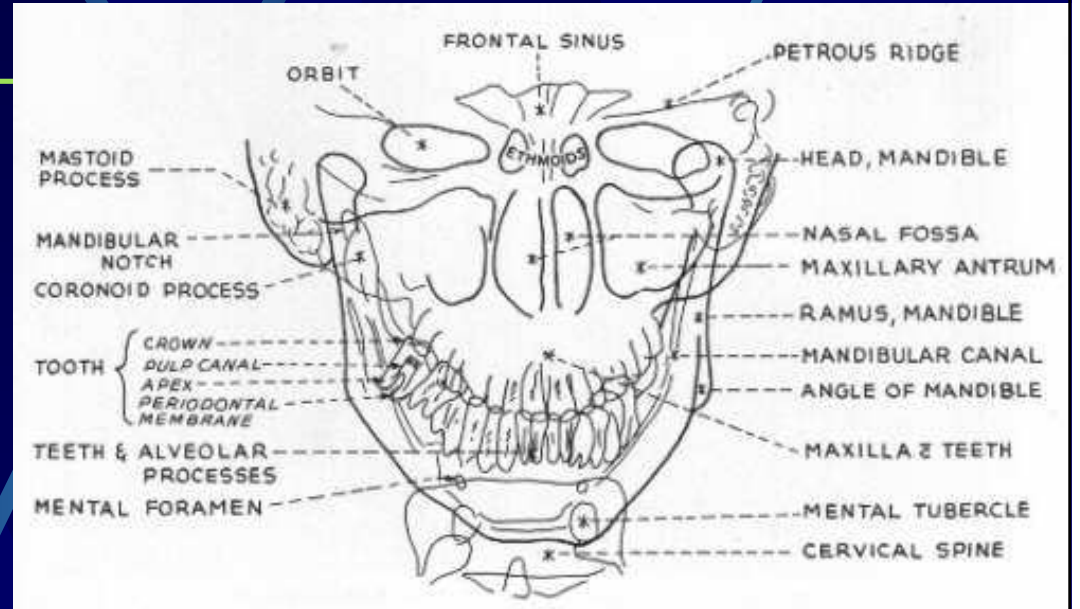
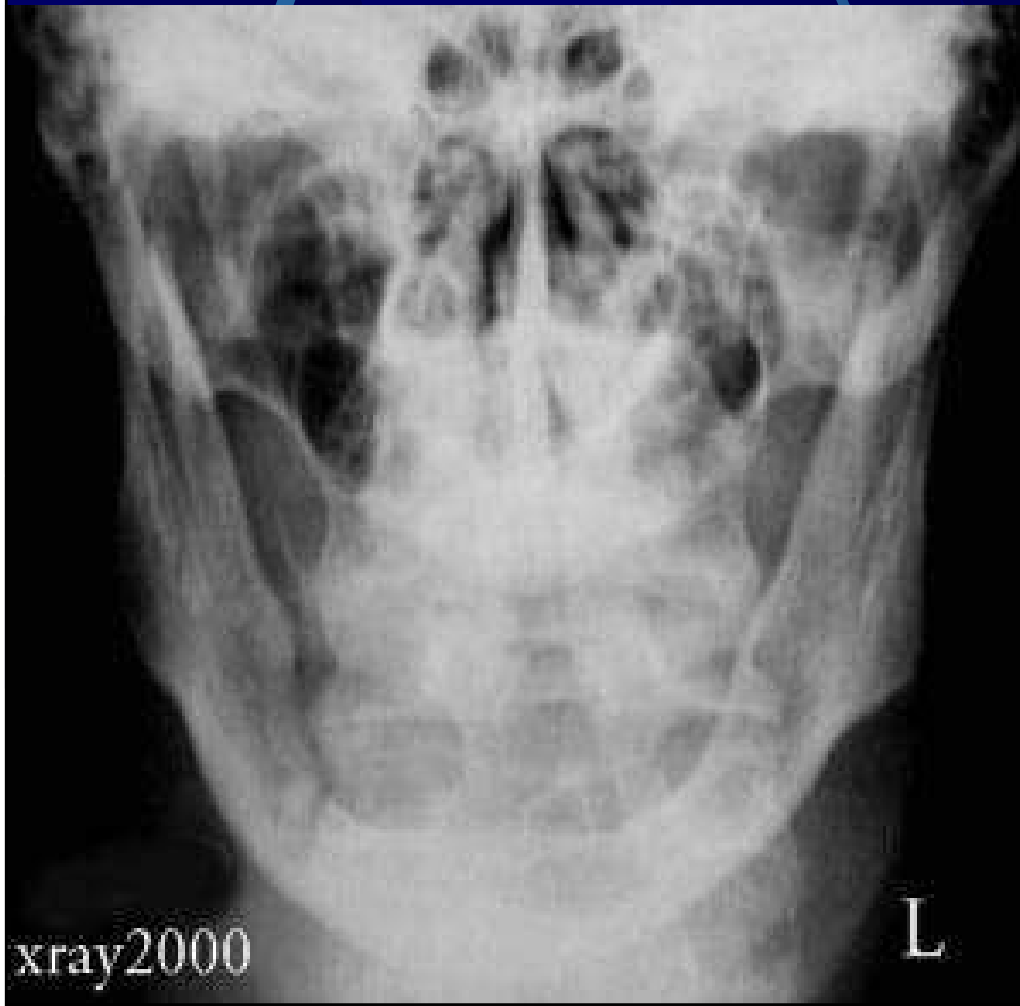


Šikmá projekce mandibula – faciomaxilární



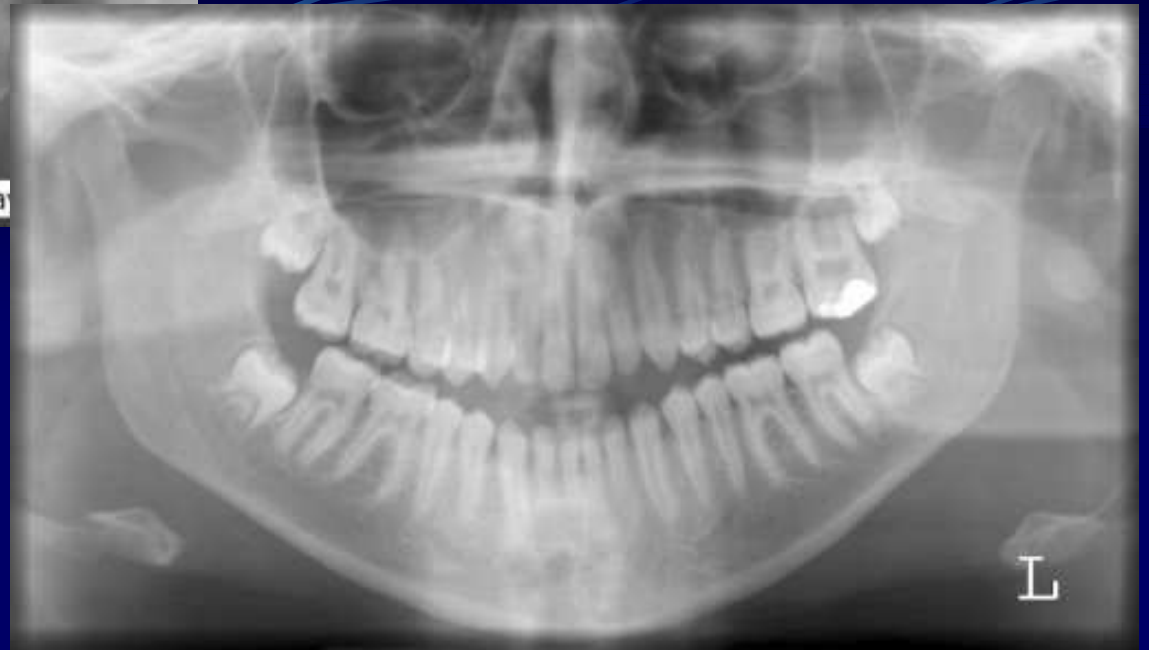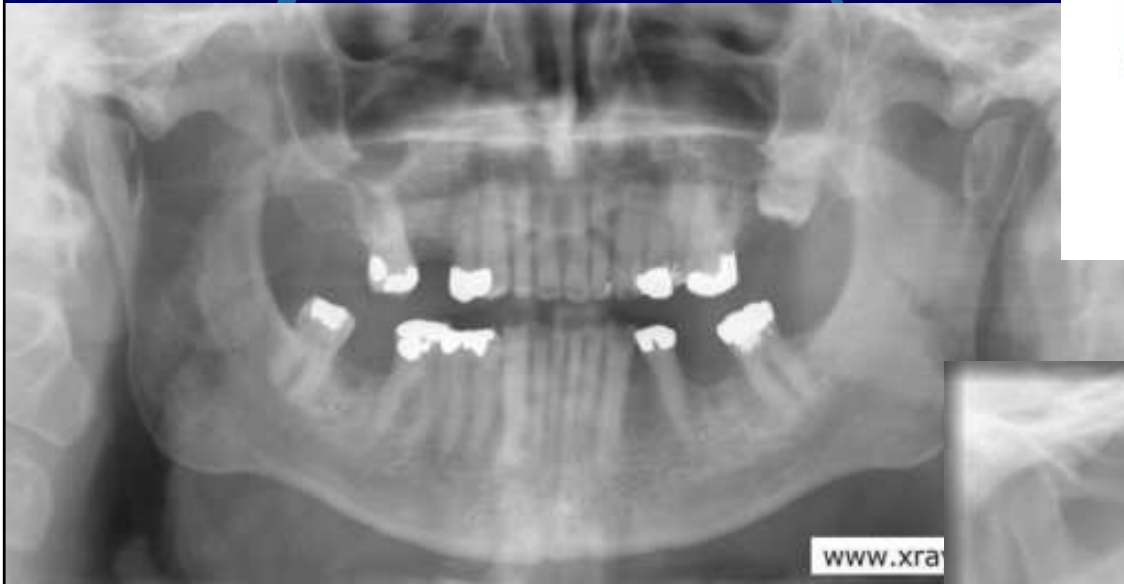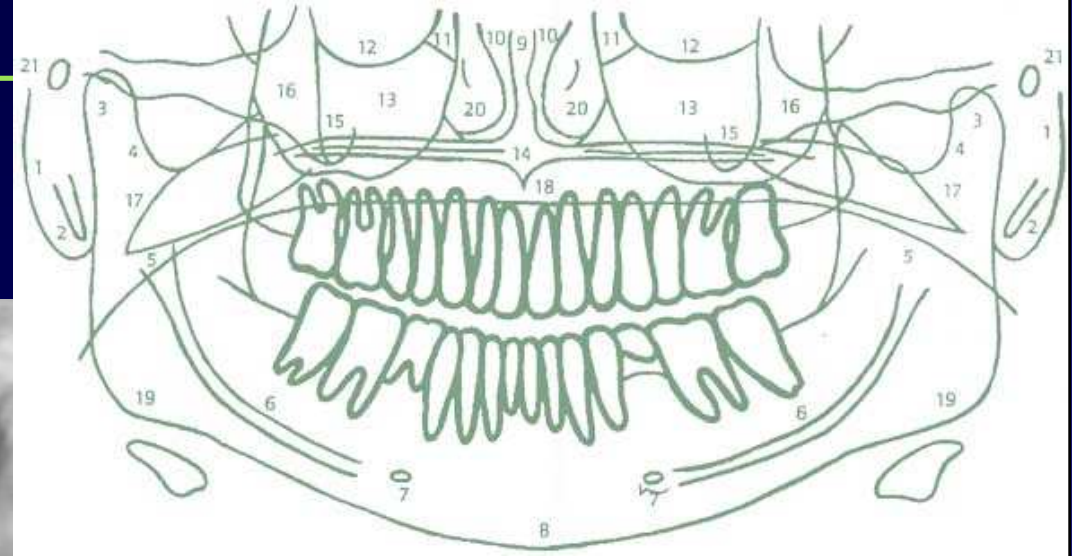



Mandibula PA



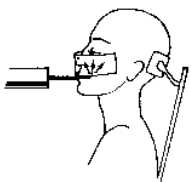
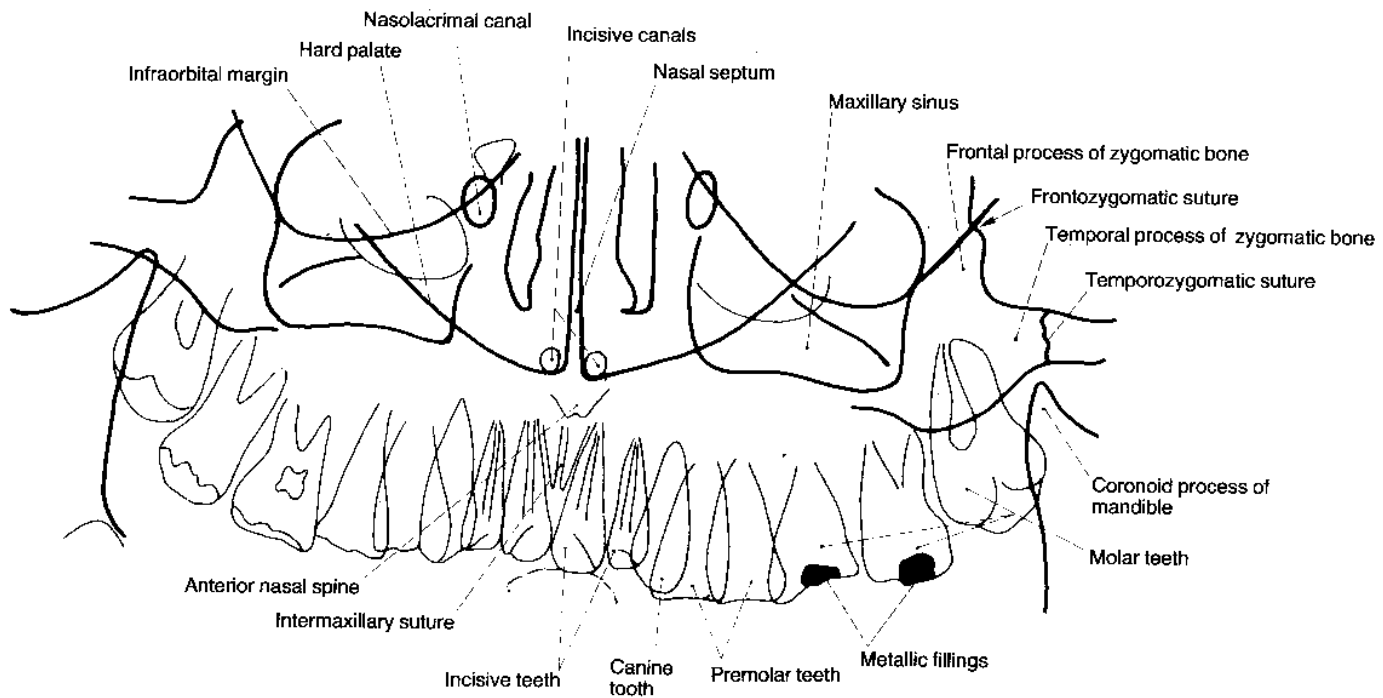
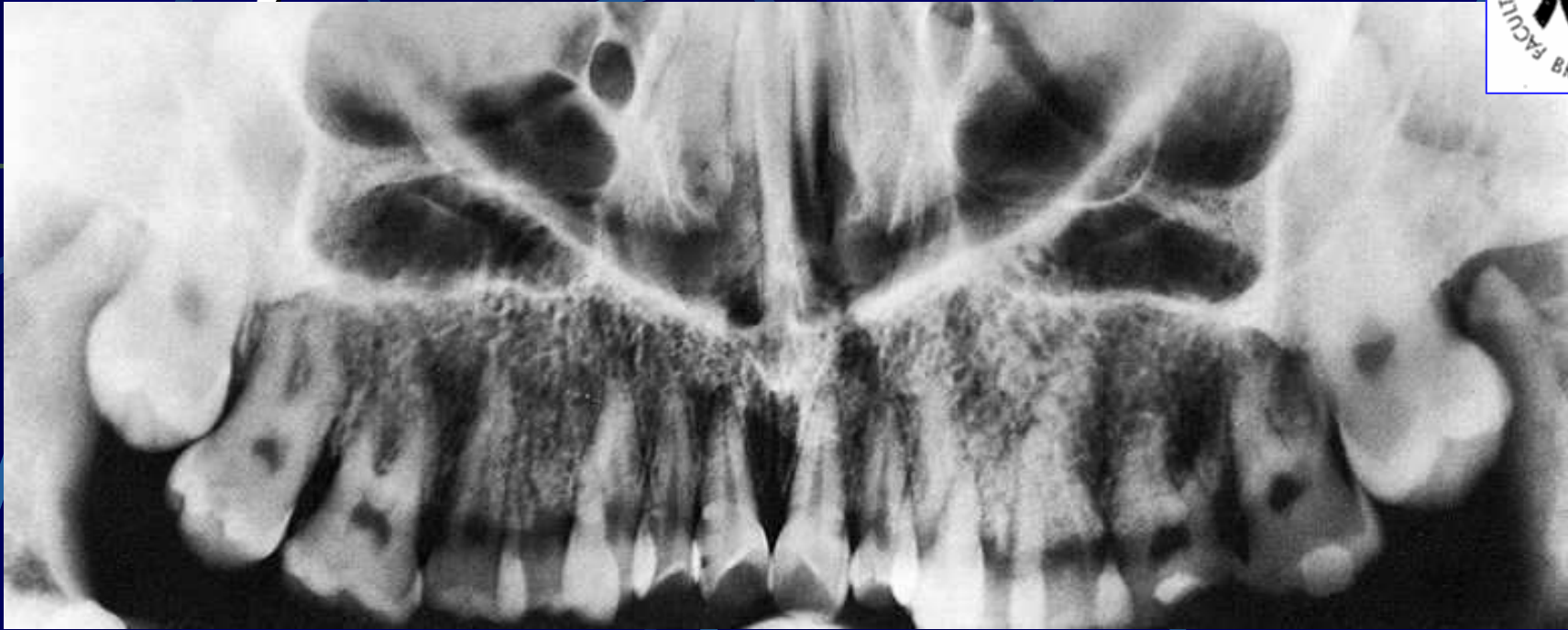


Projekce



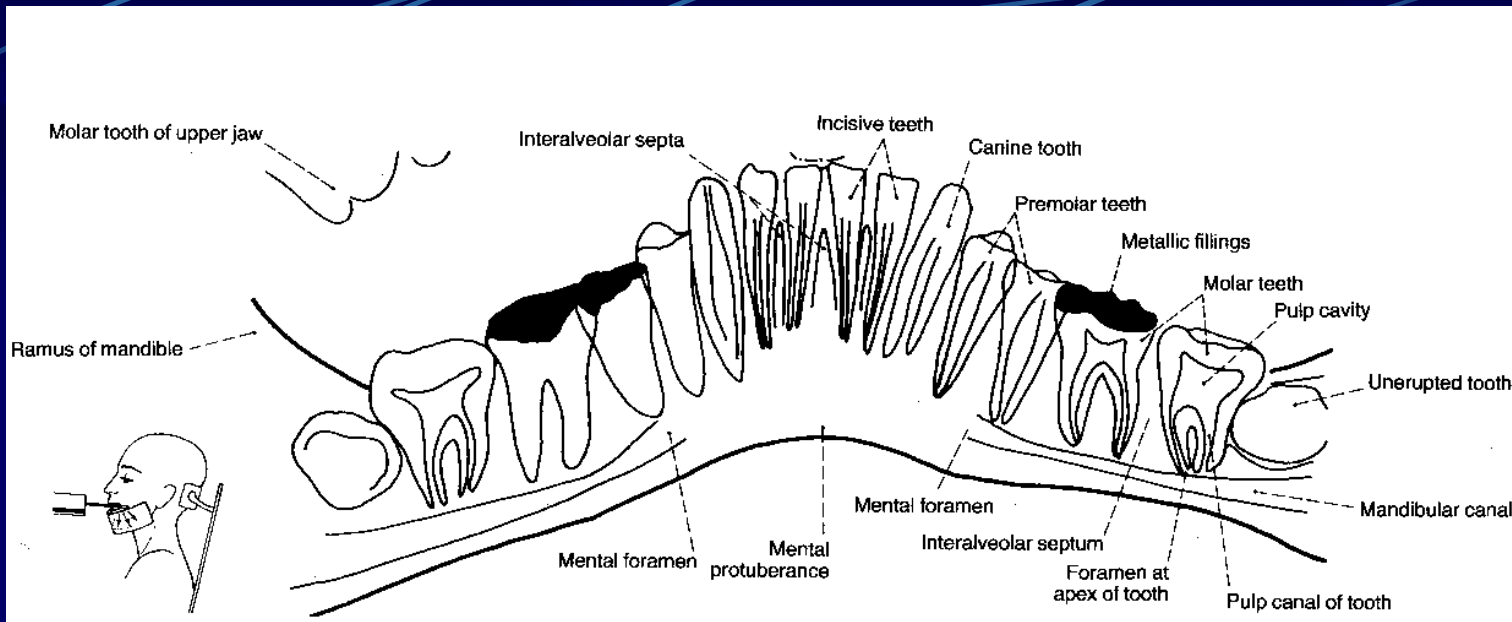
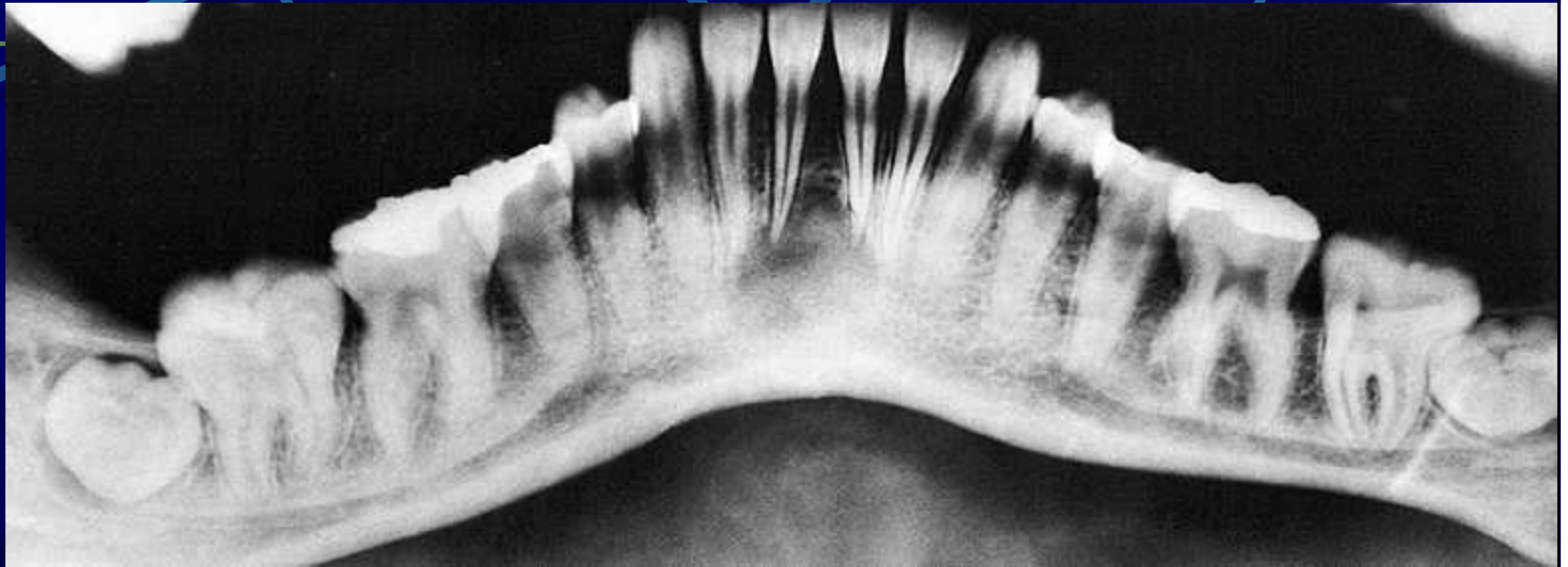


Projekce



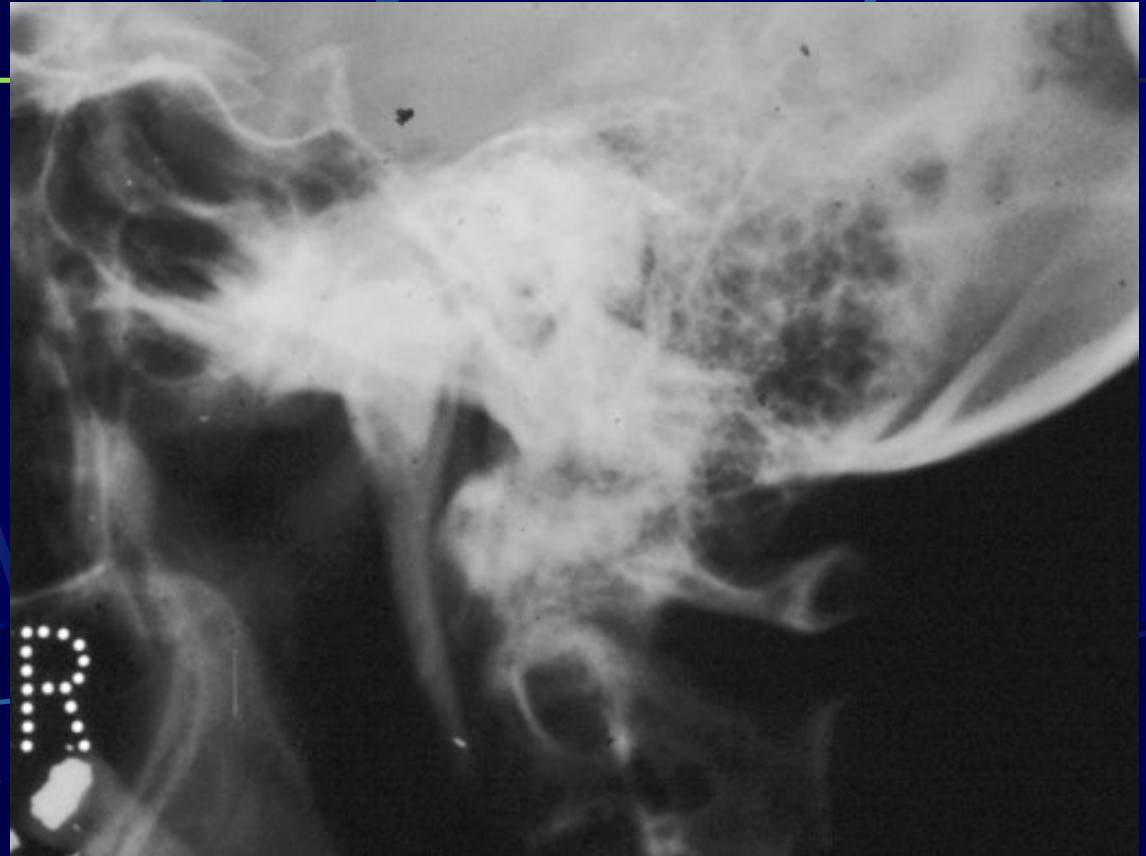
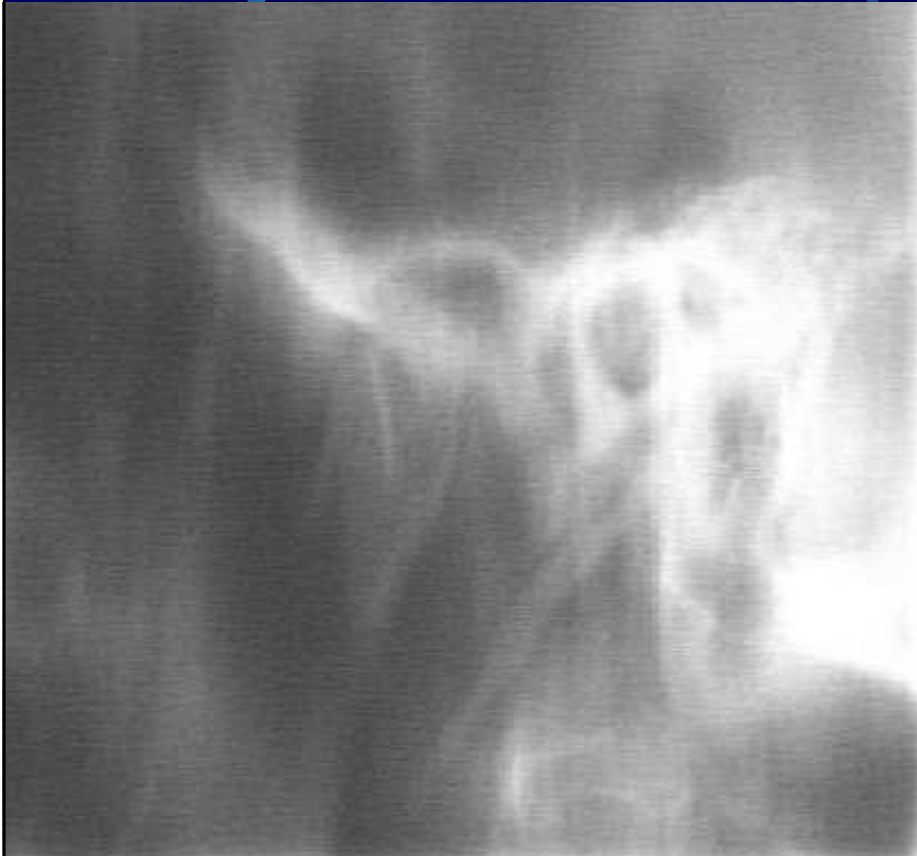


Projekce



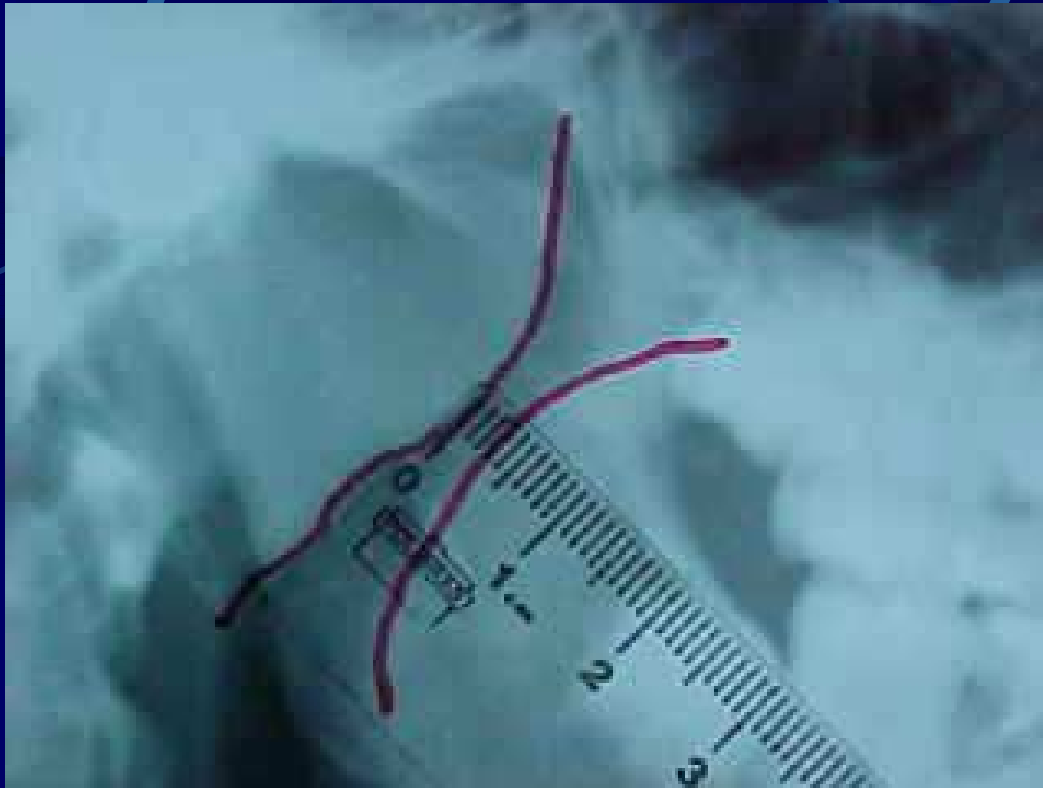
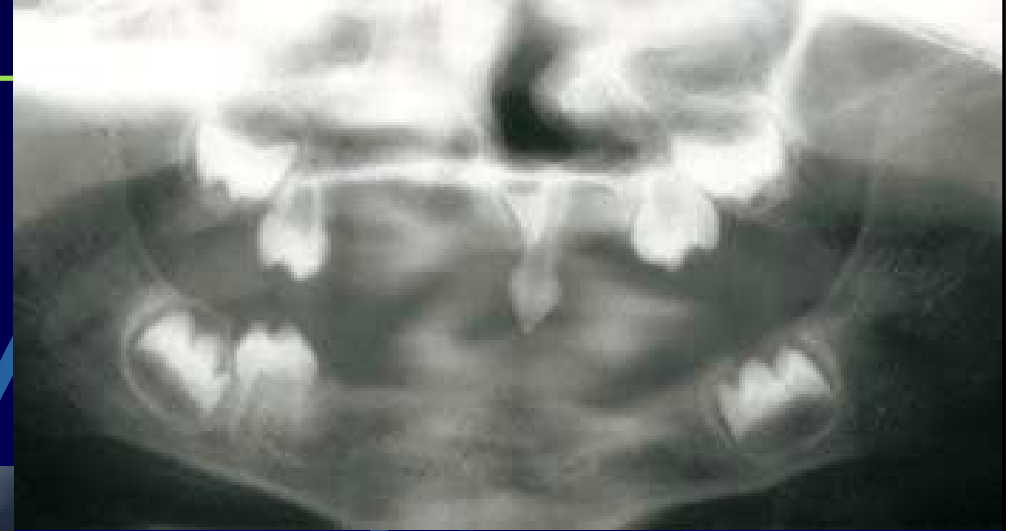


Projekce



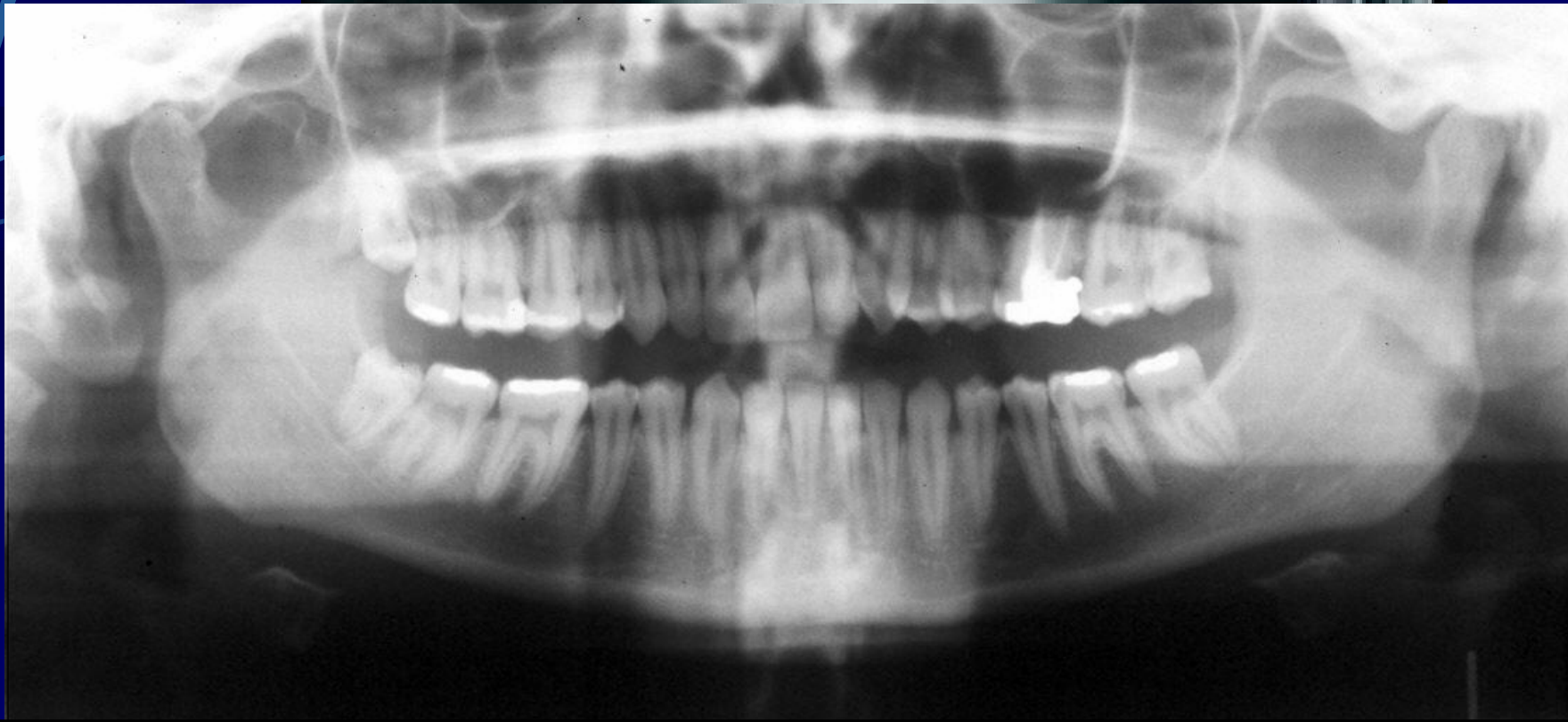
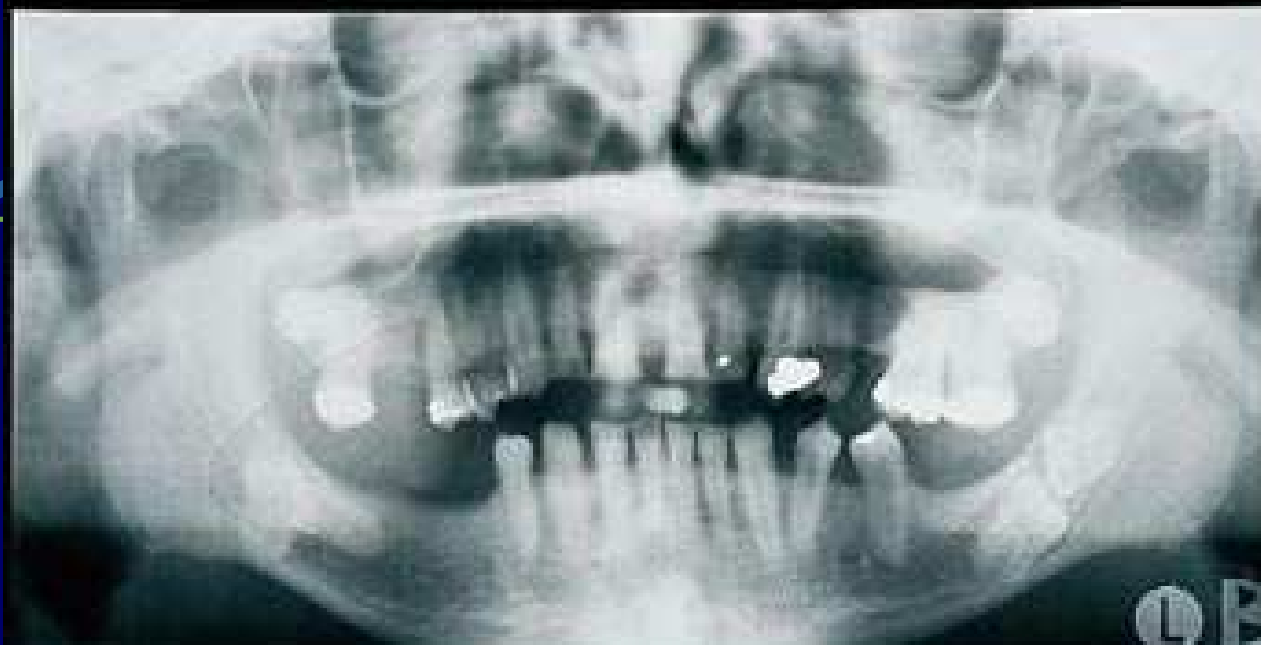
Projekce



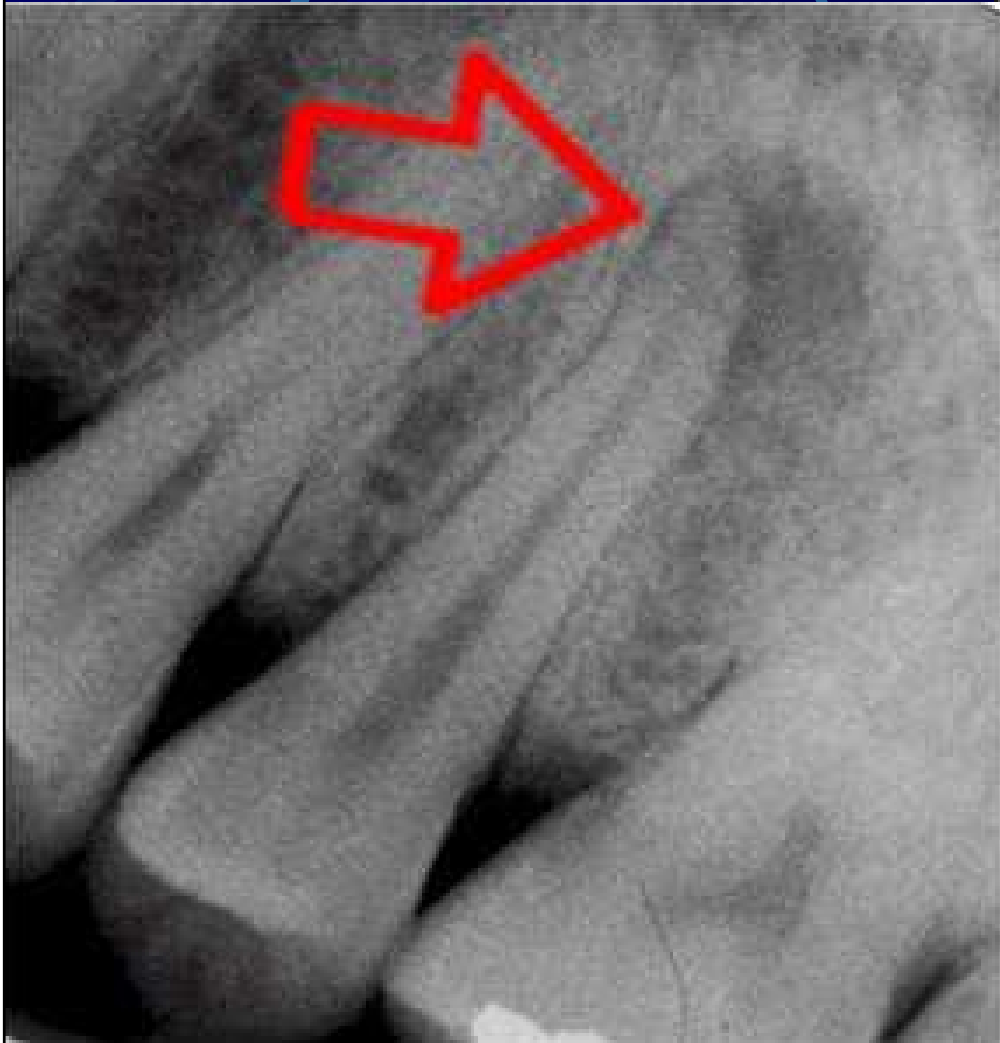


Projekce



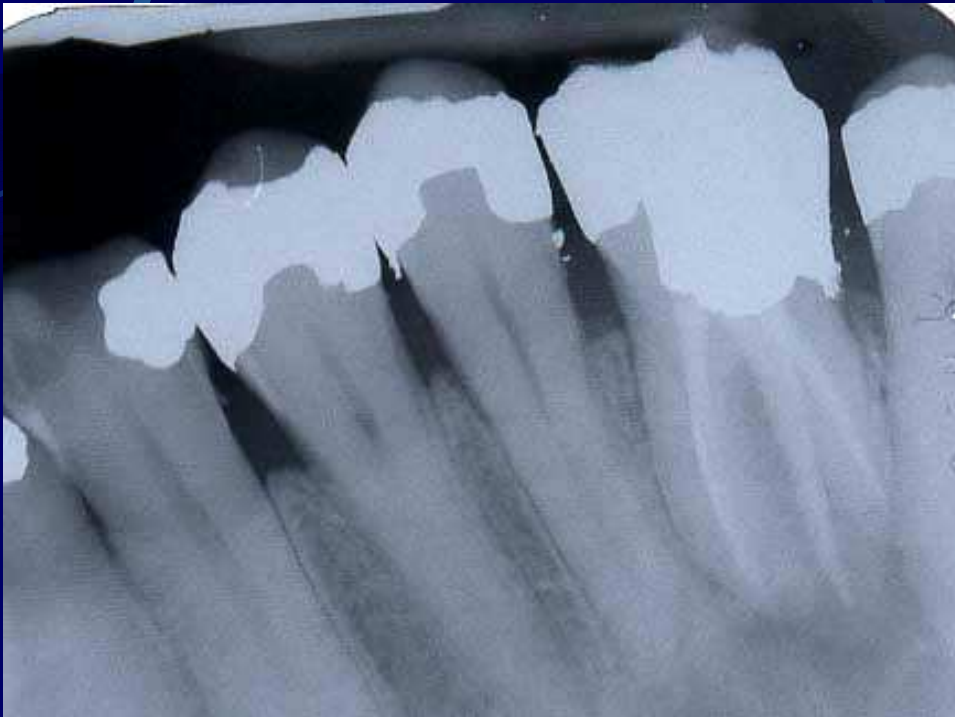
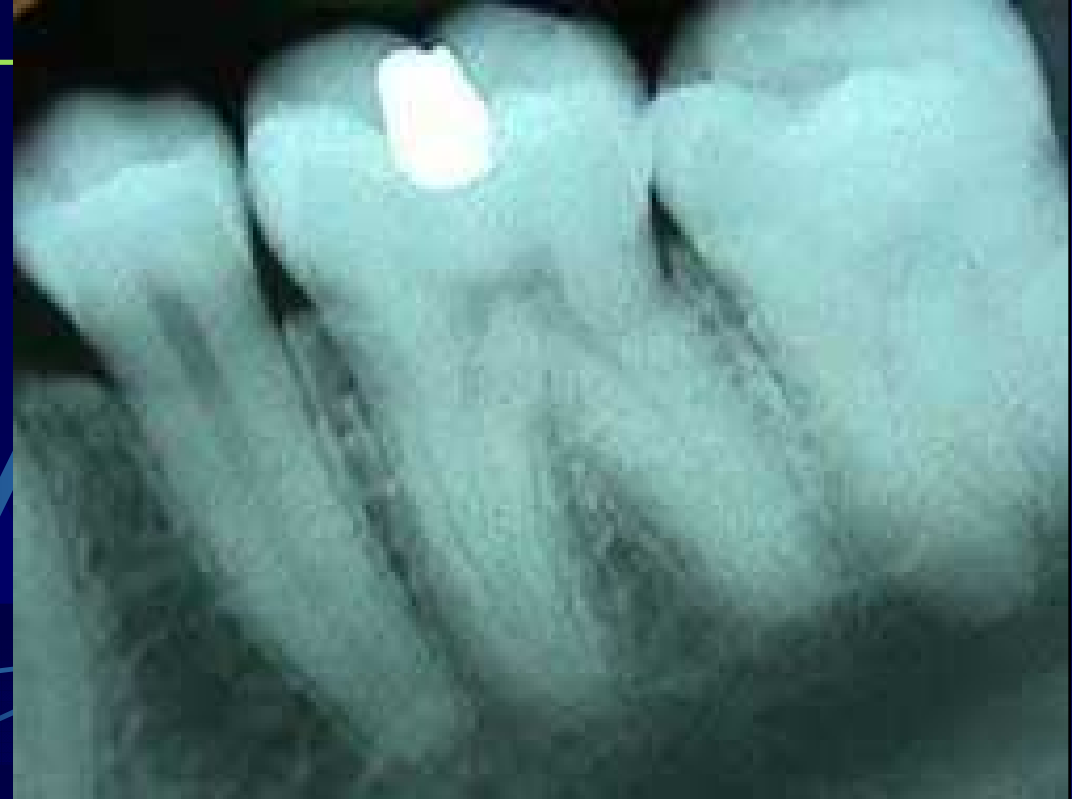


Projekce



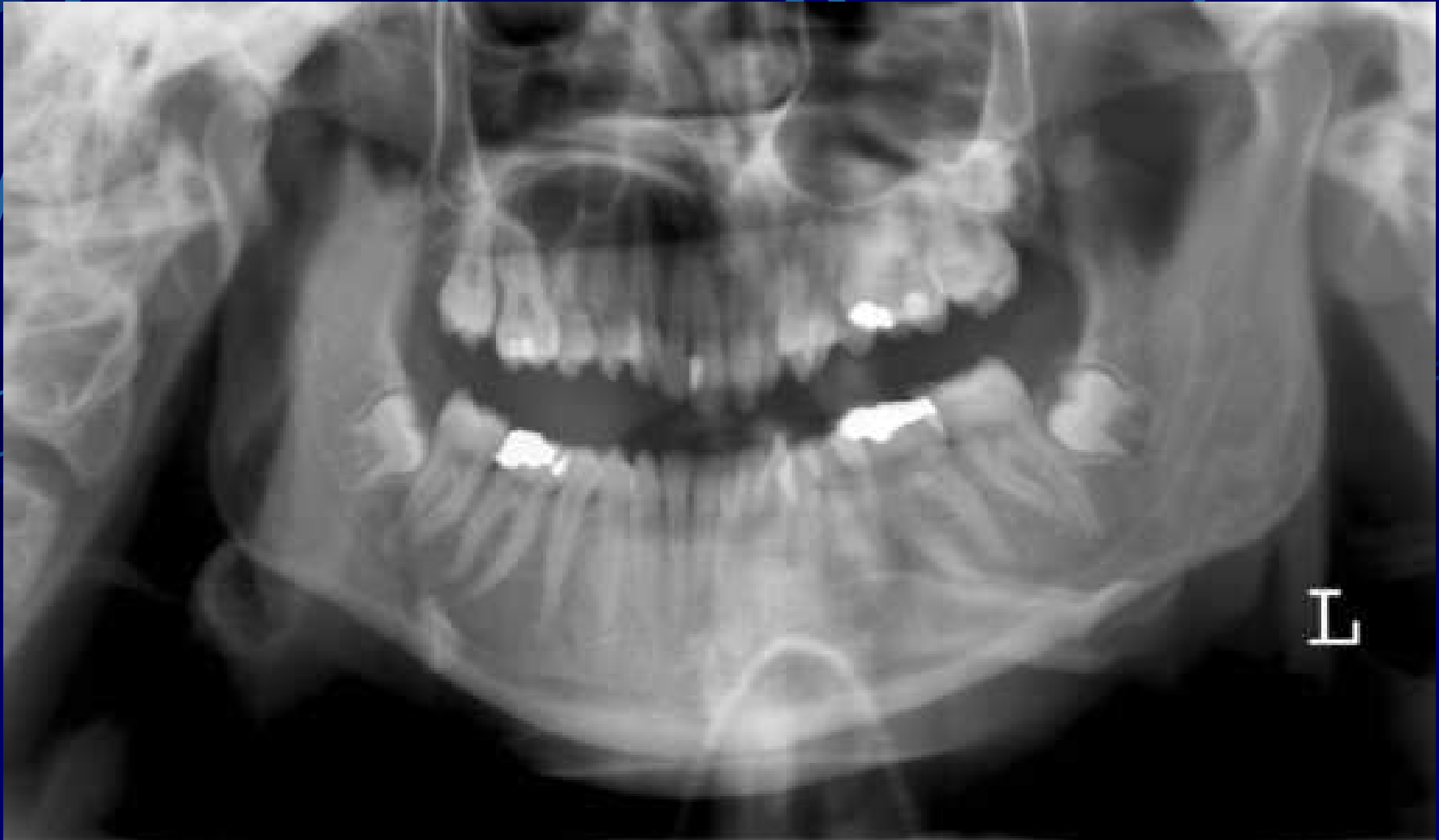



Projekce





Zuby - artefakt

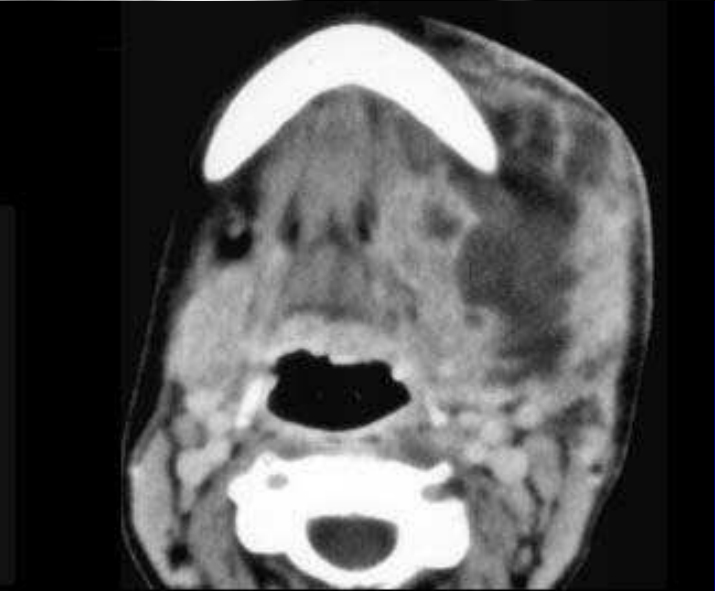
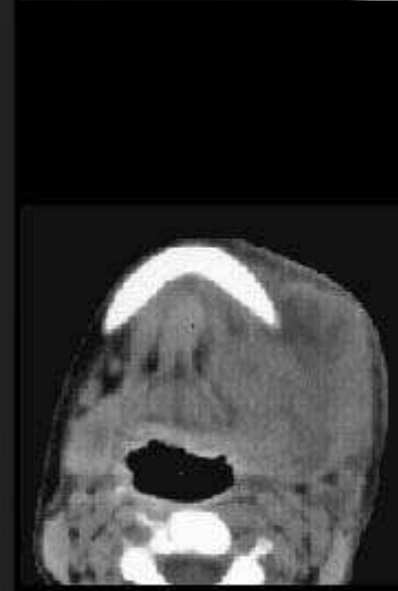
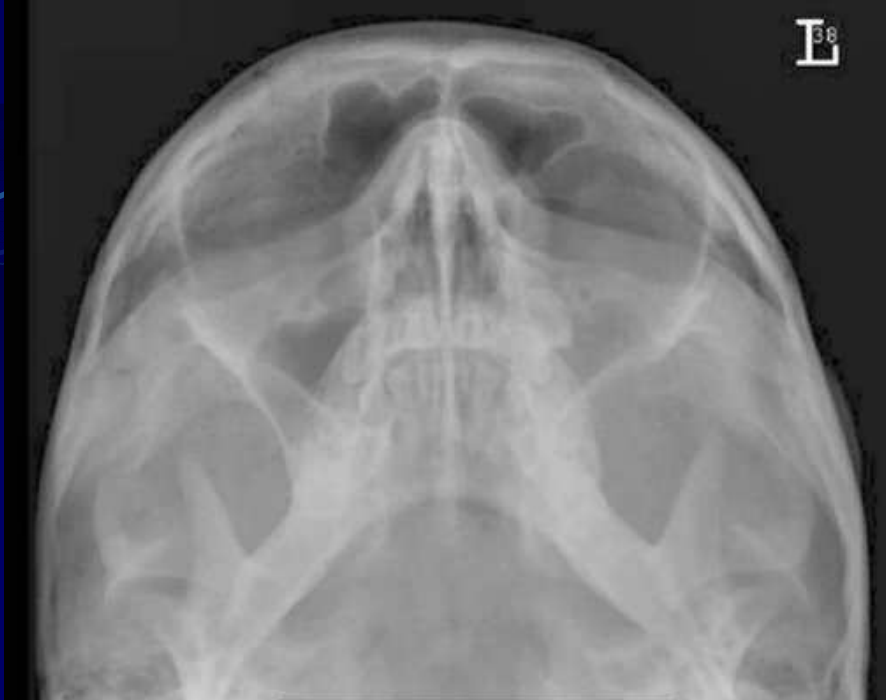
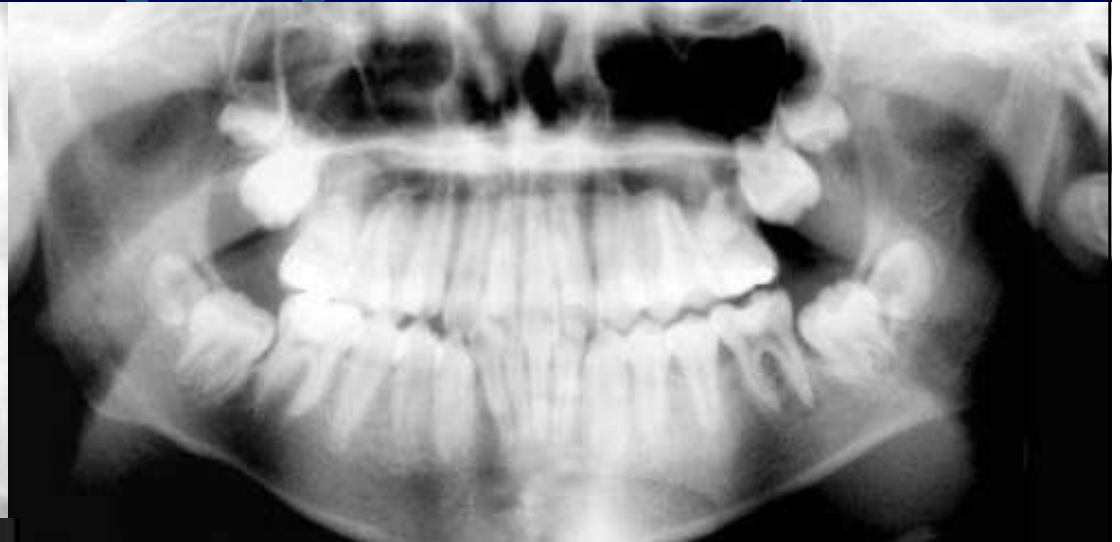
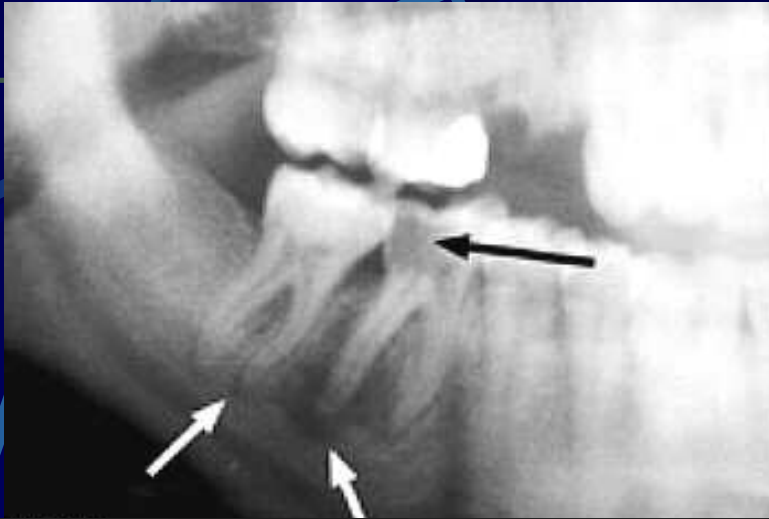


Patologie

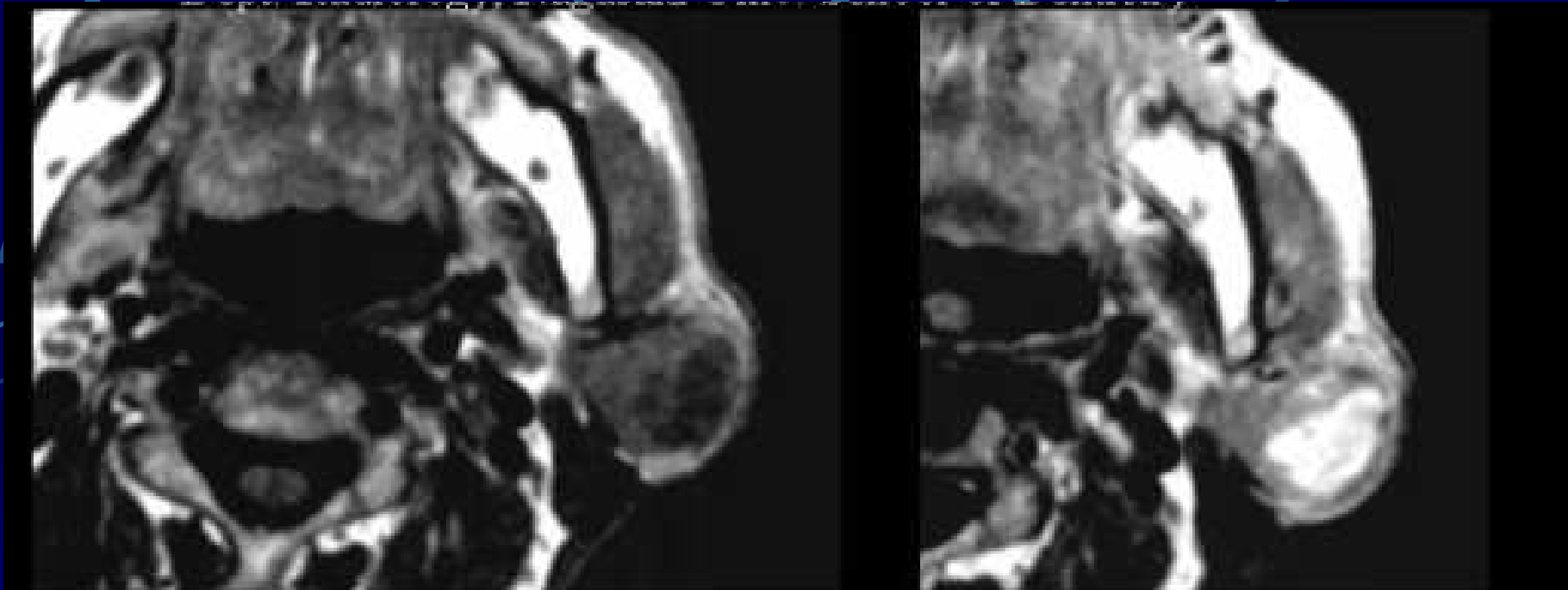


Absces



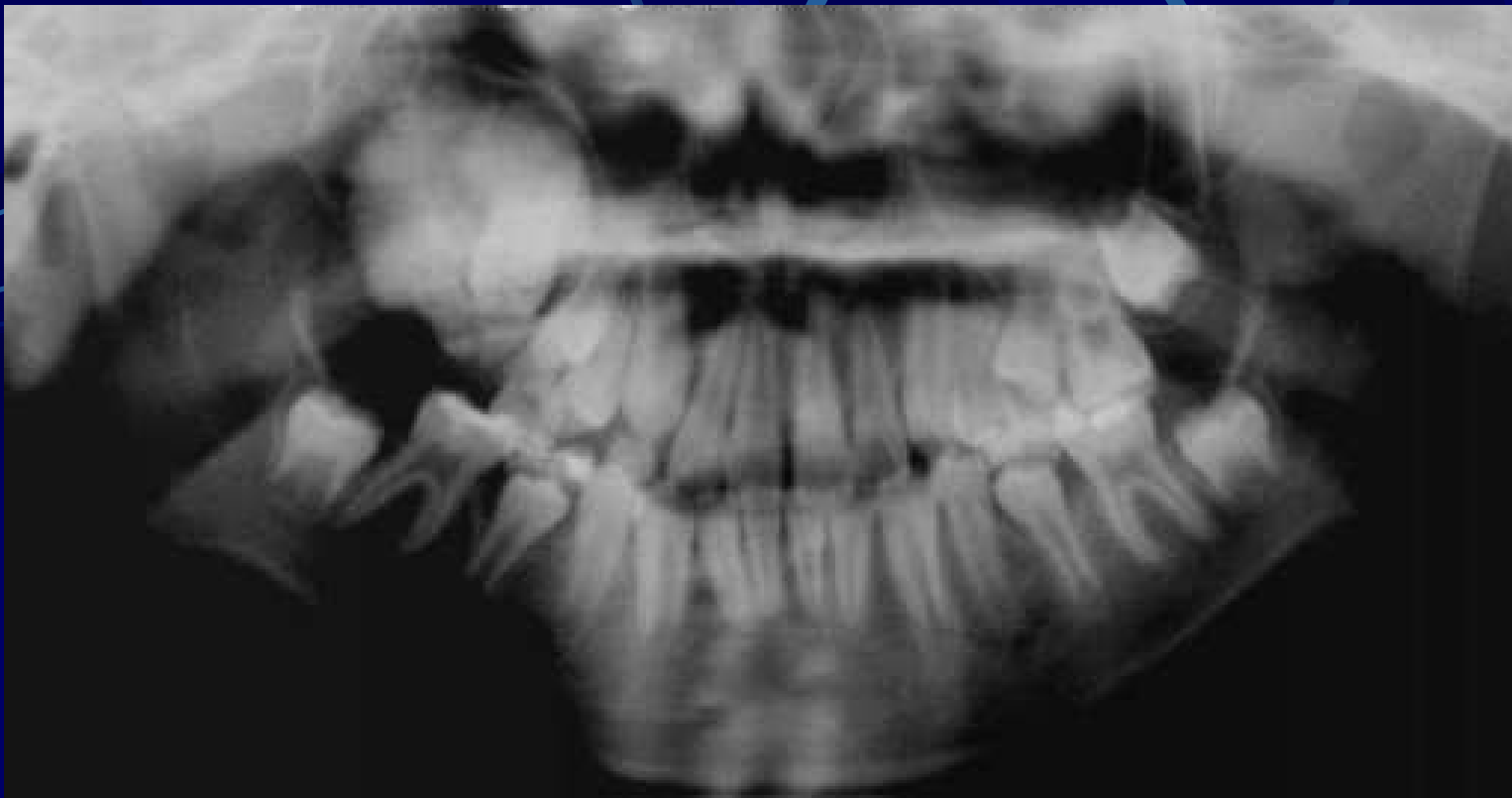
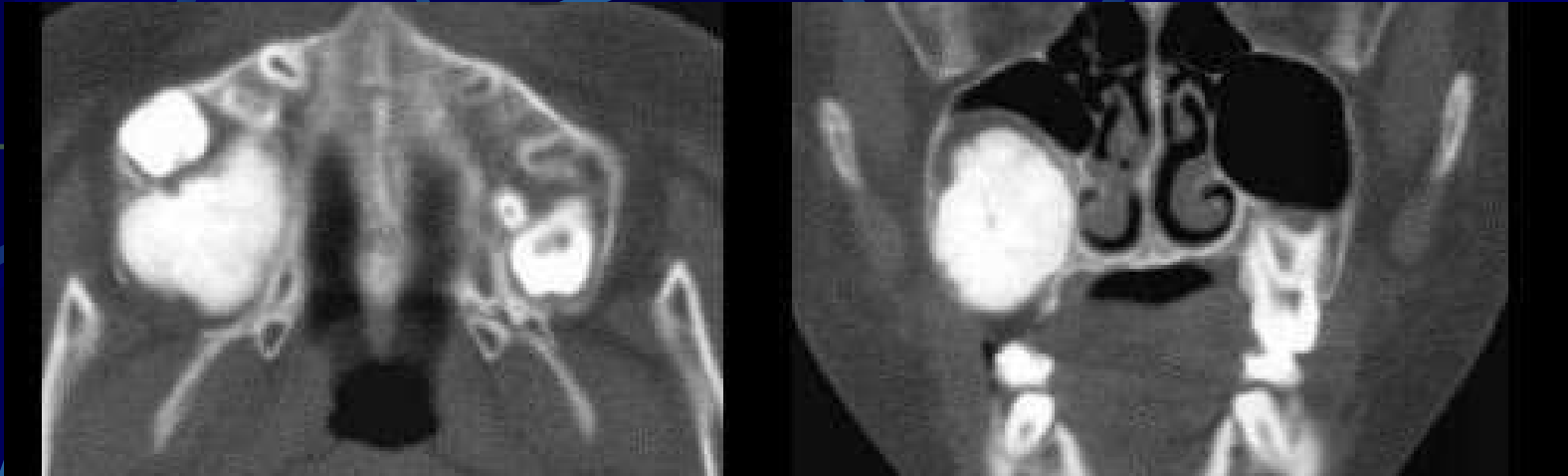


Adenolymfoma



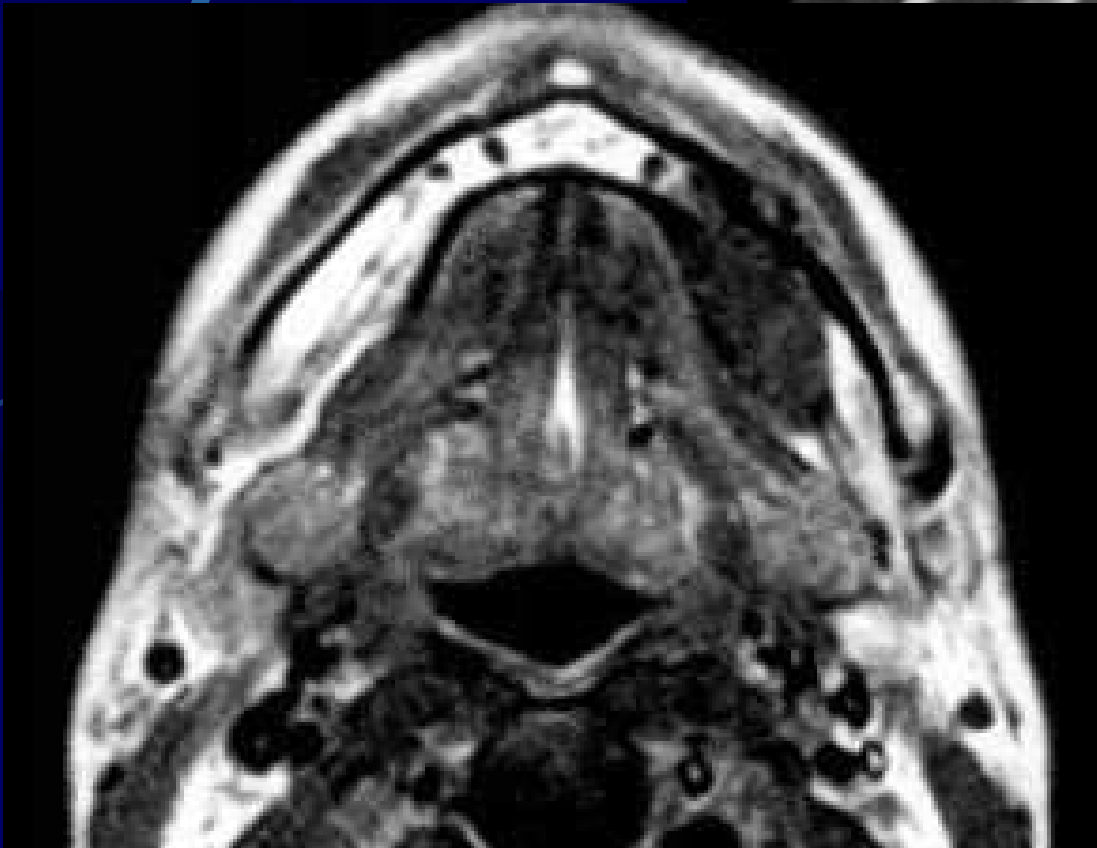
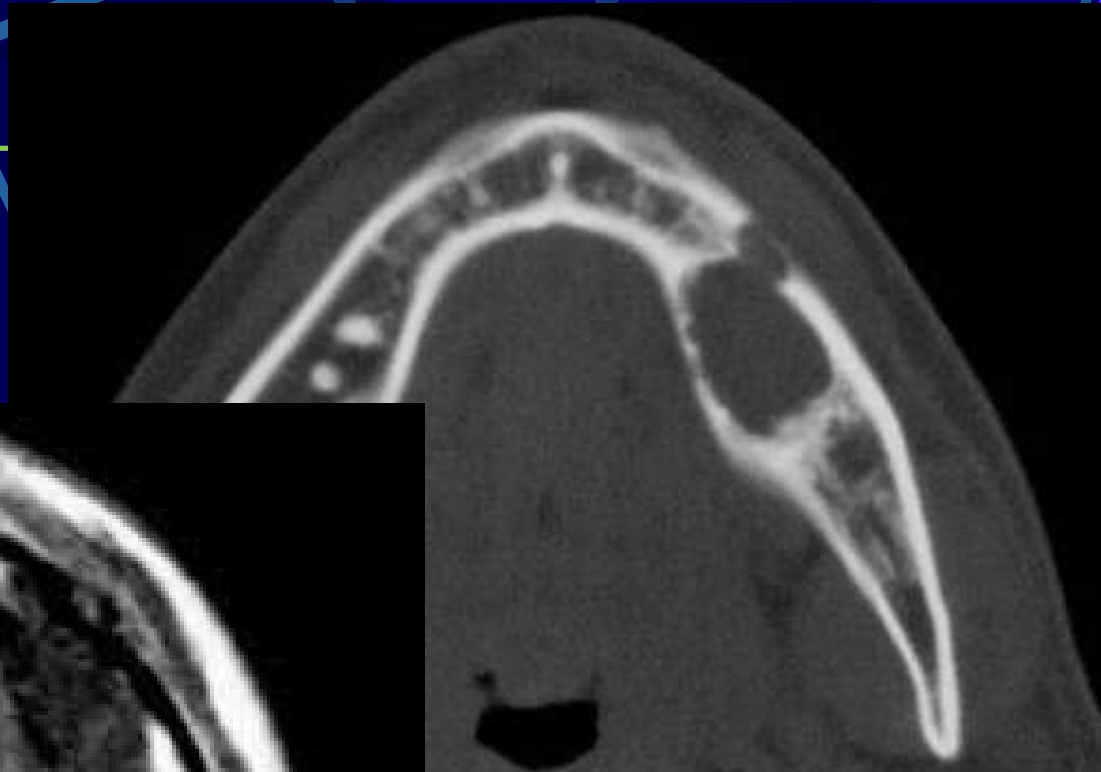



Facionmaxilární ameloblastický fibrom



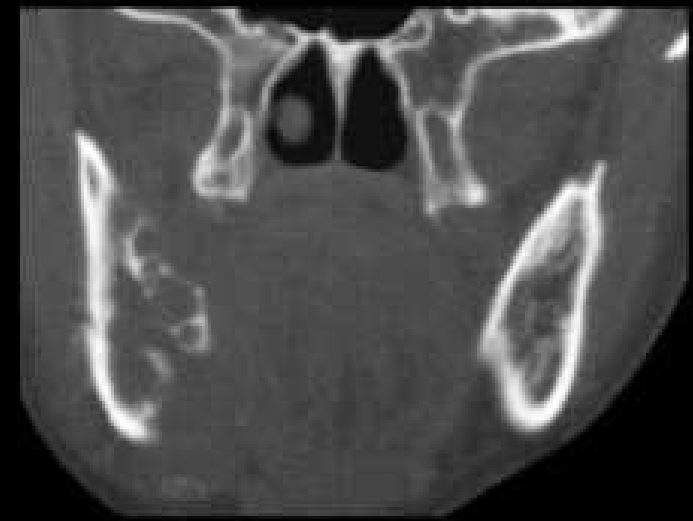
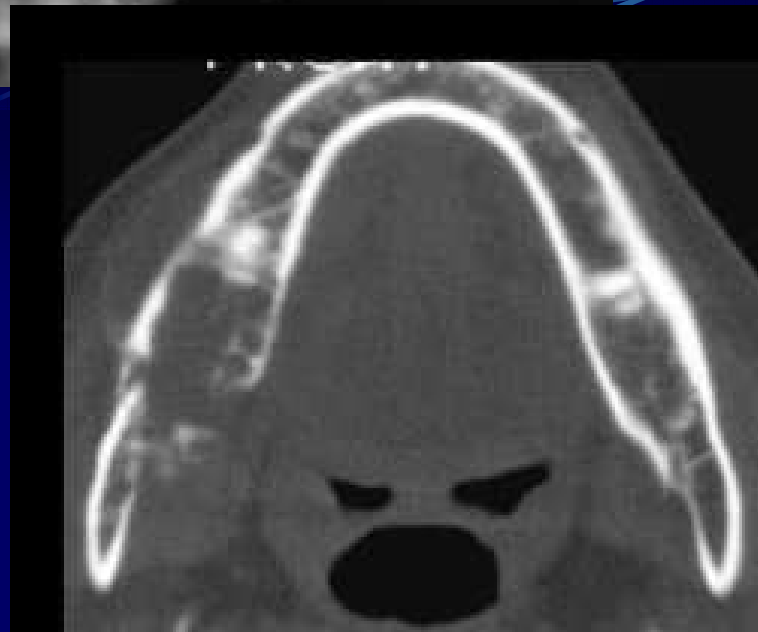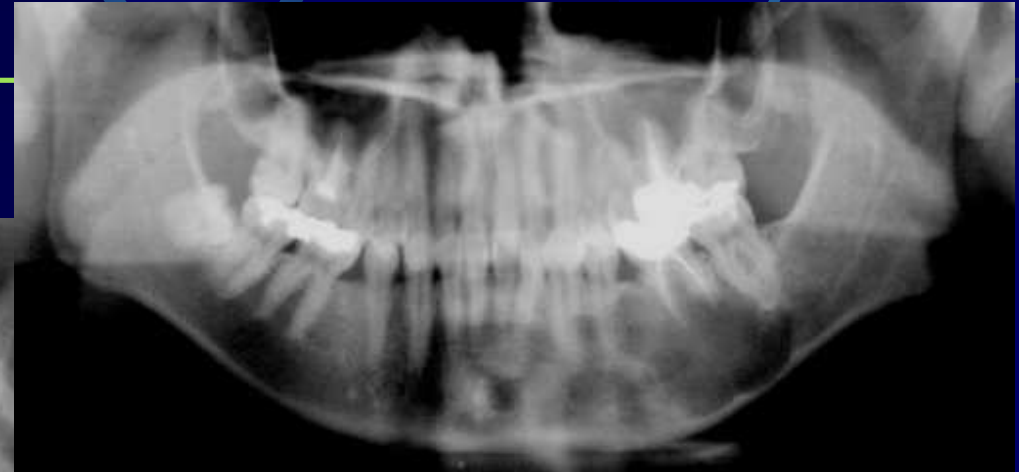

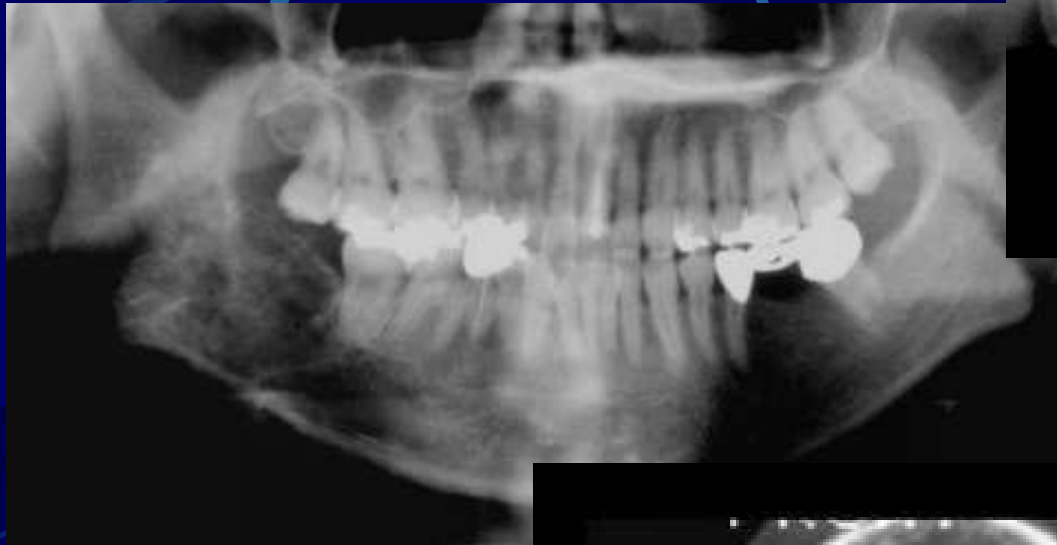
Fibrom



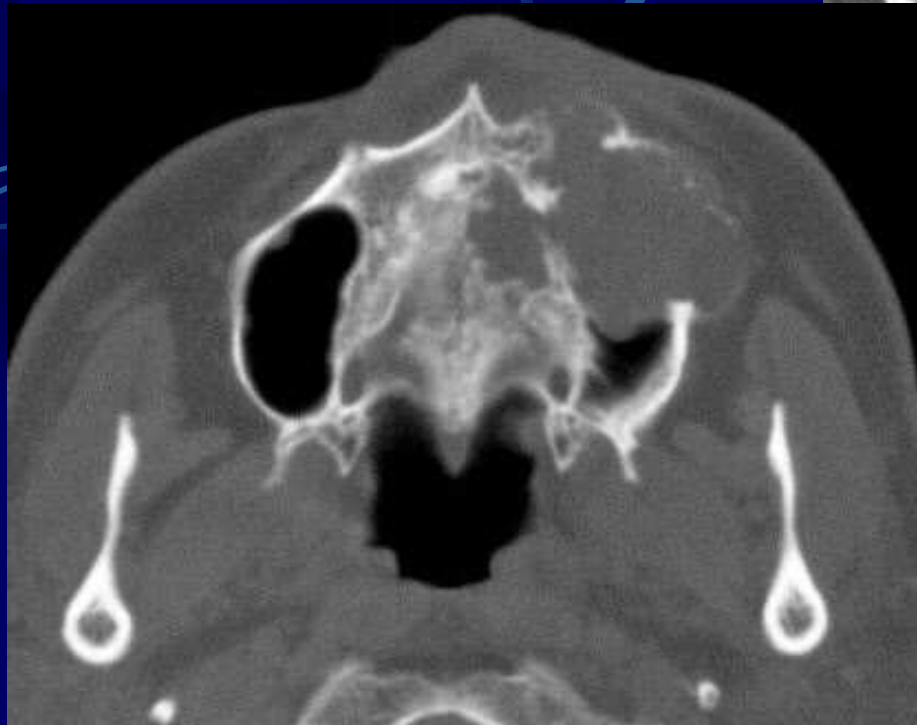
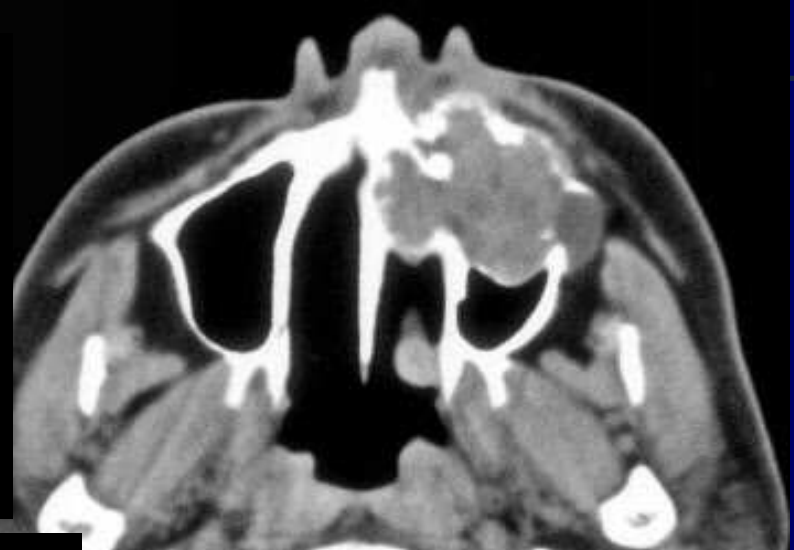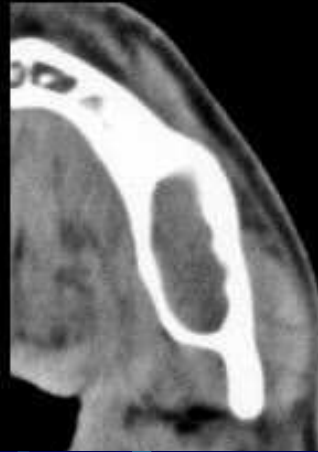
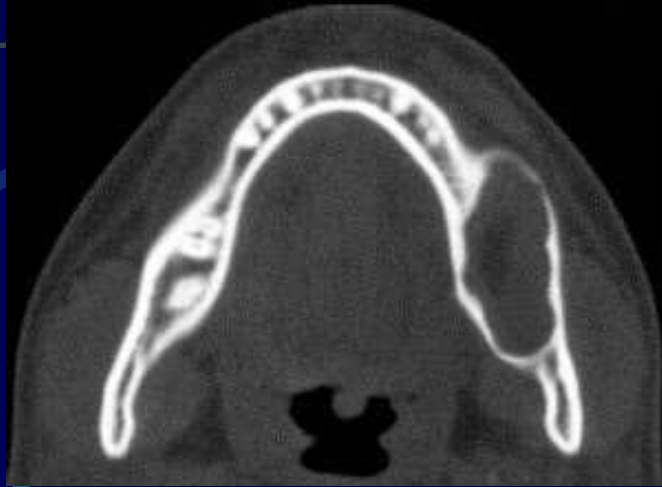



Facionmaxilární ameloblastický fibrosarkom



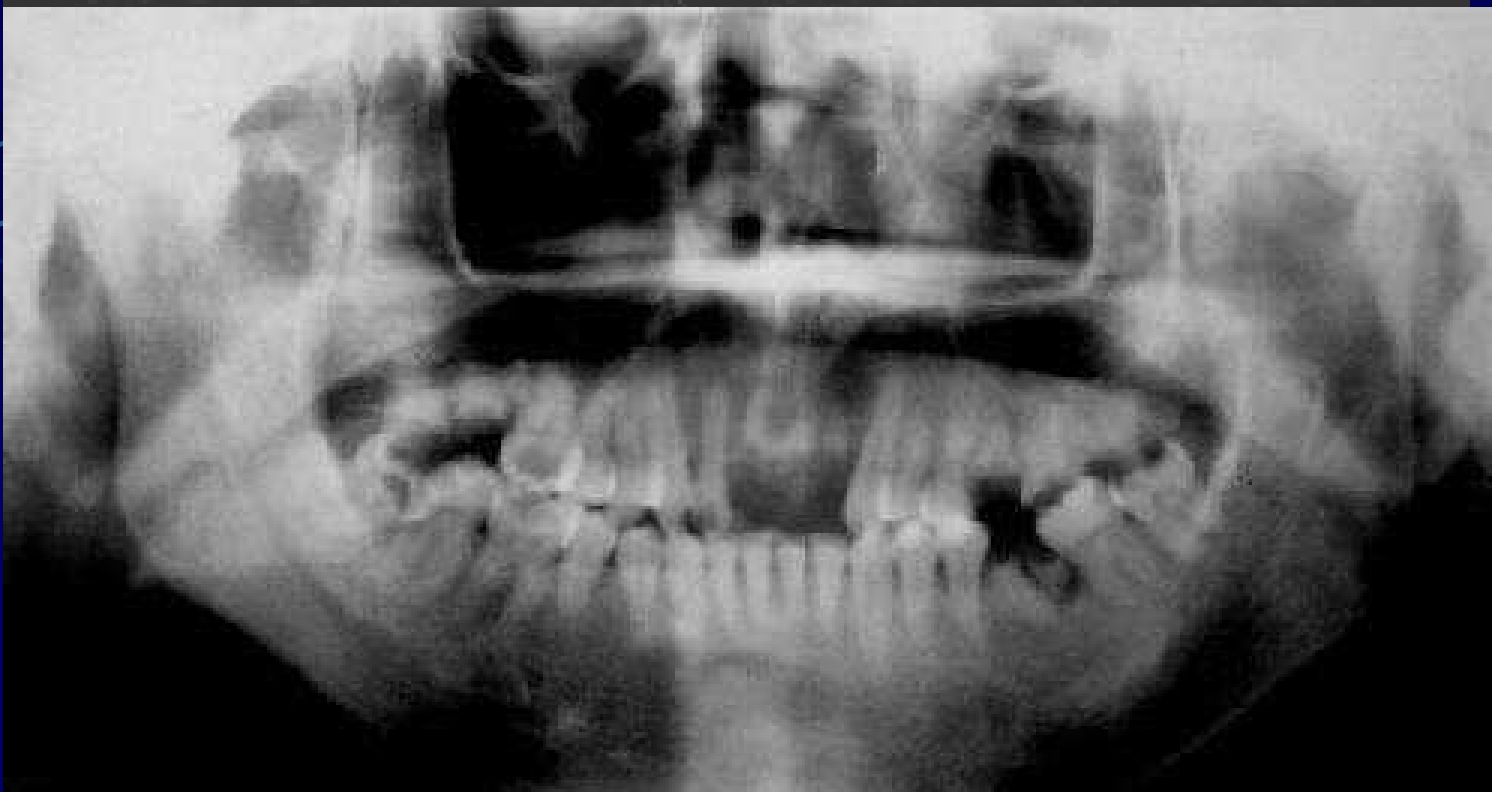
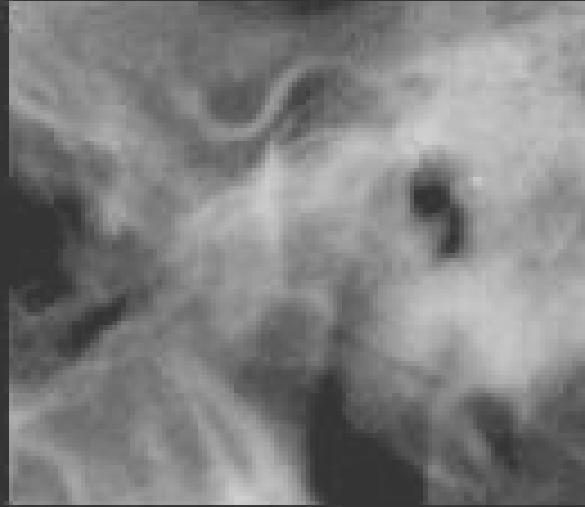
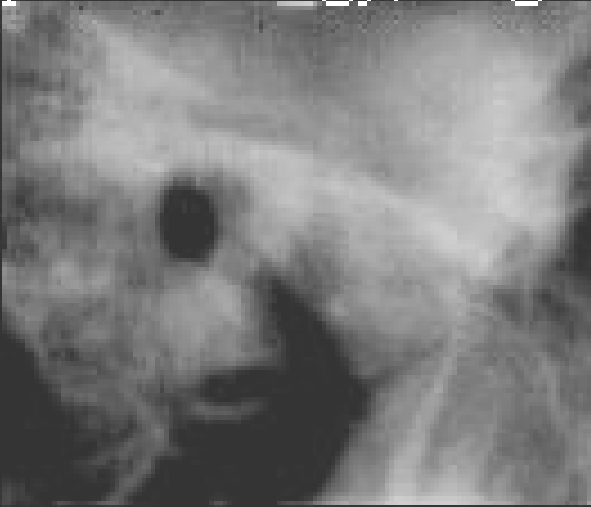
Ameloblastom



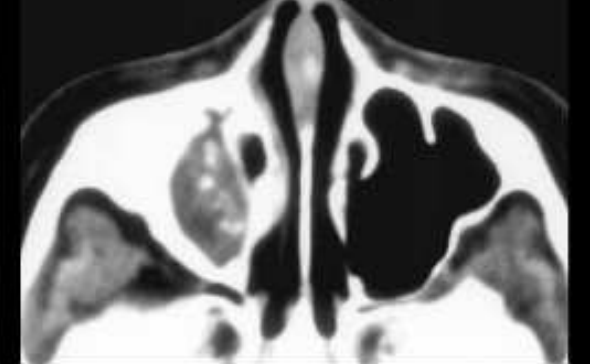
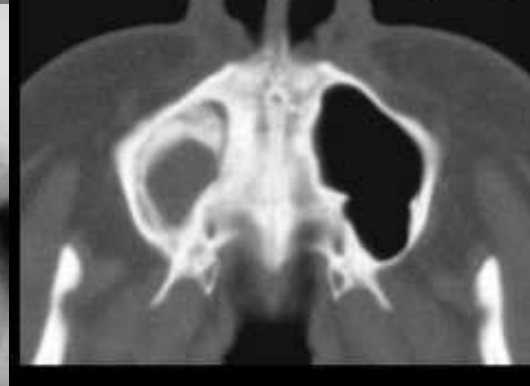
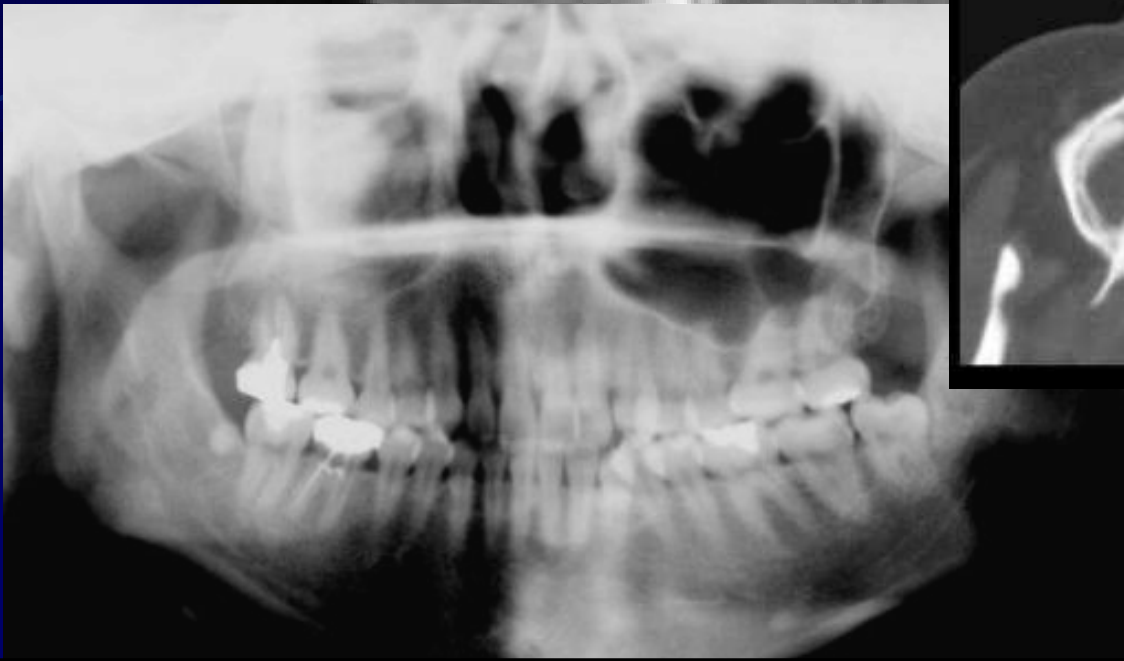
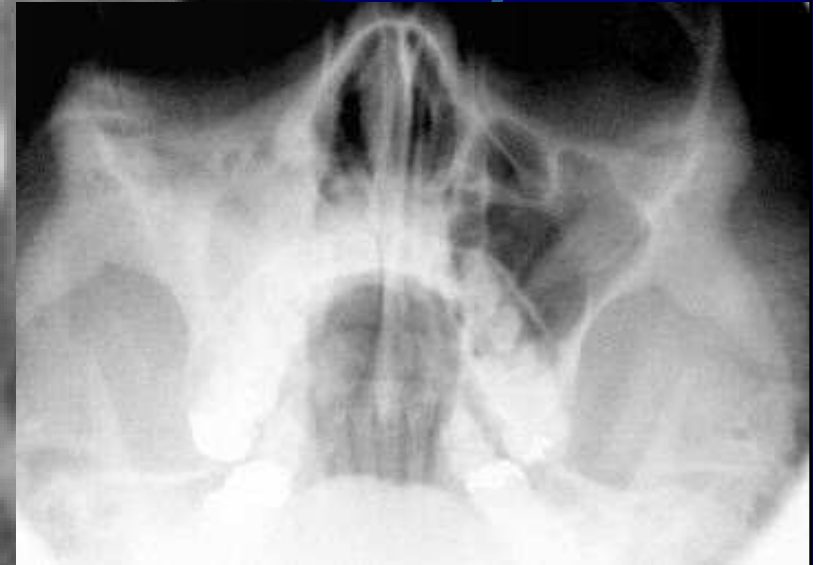
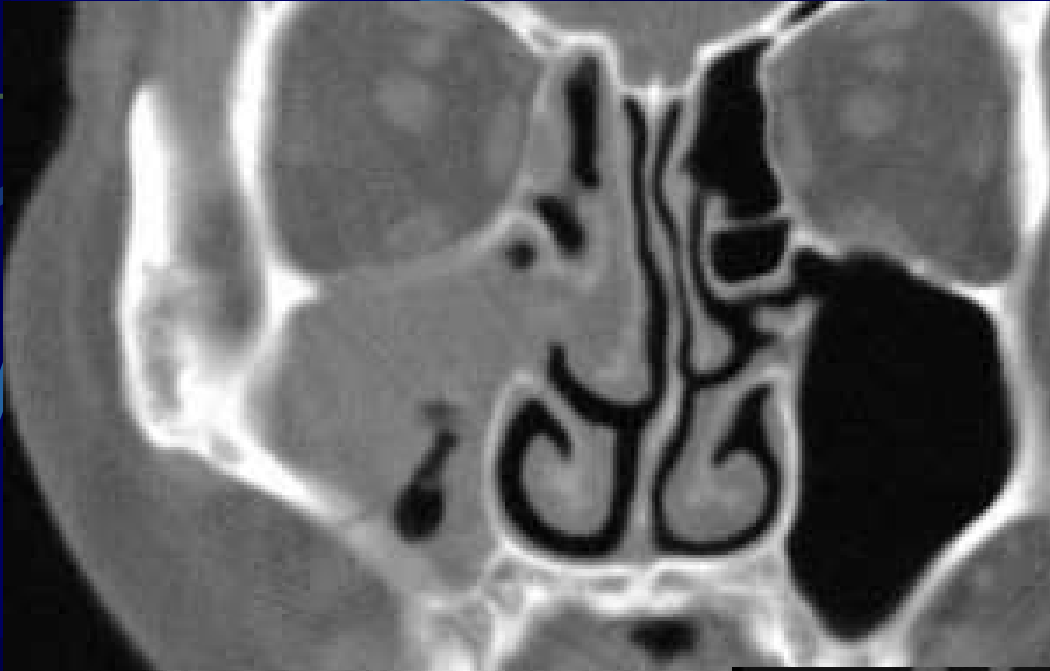Ankylozující artritida



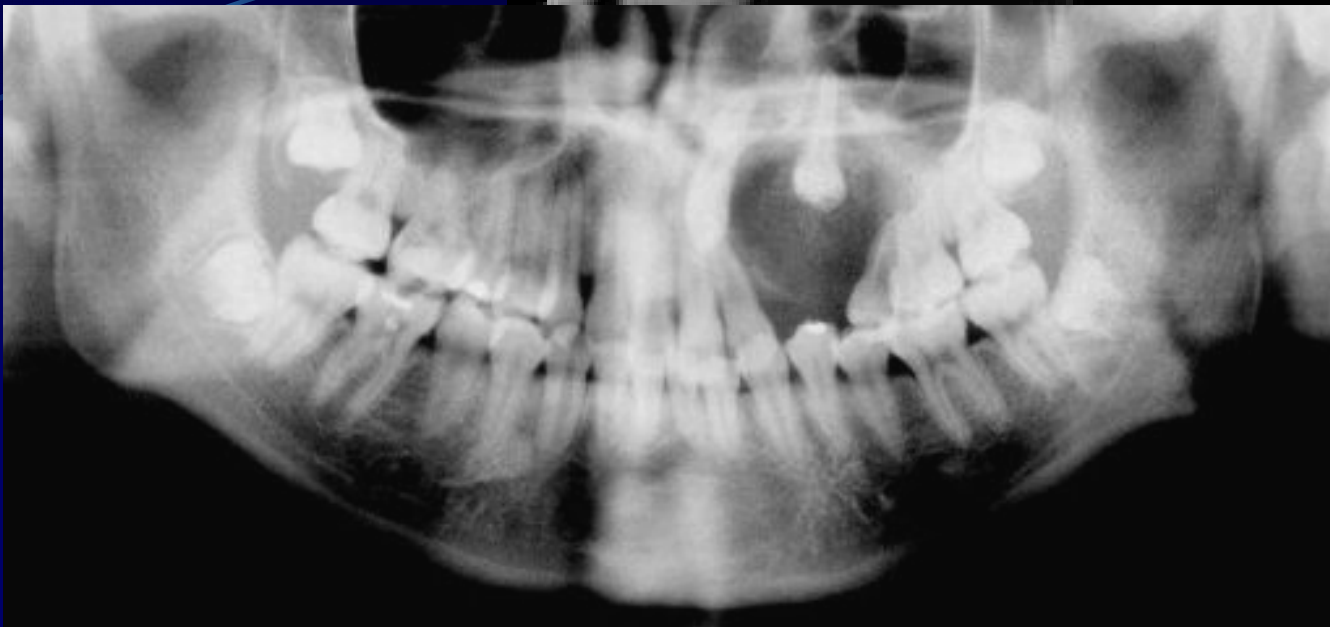
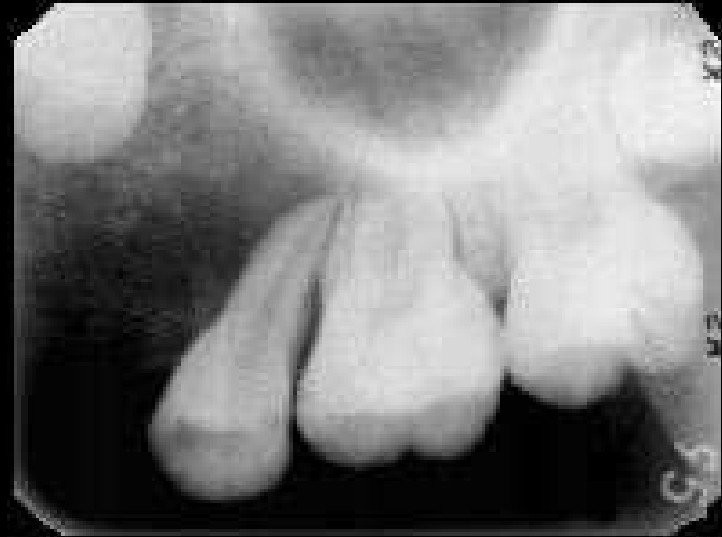
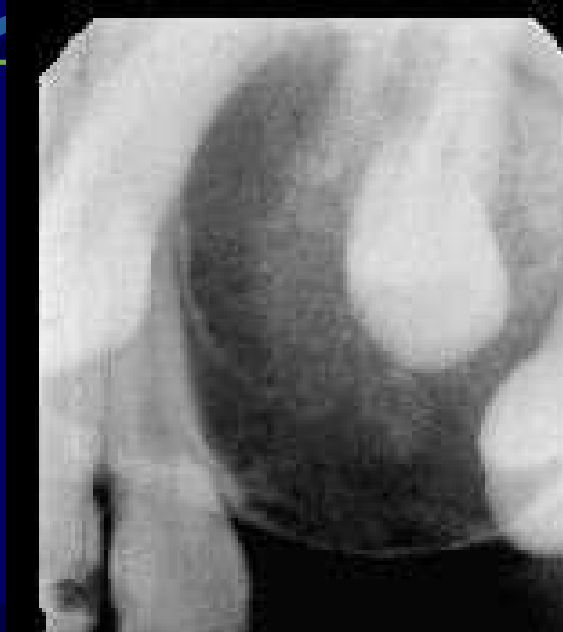Aspergilóza



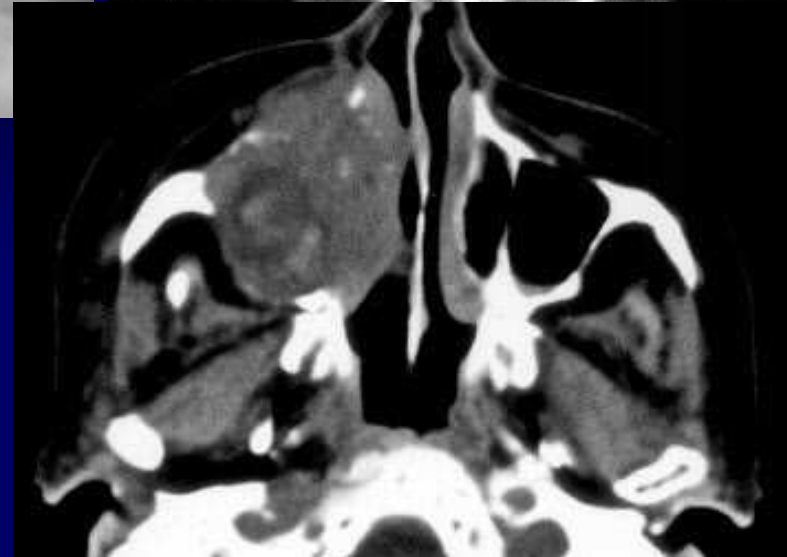
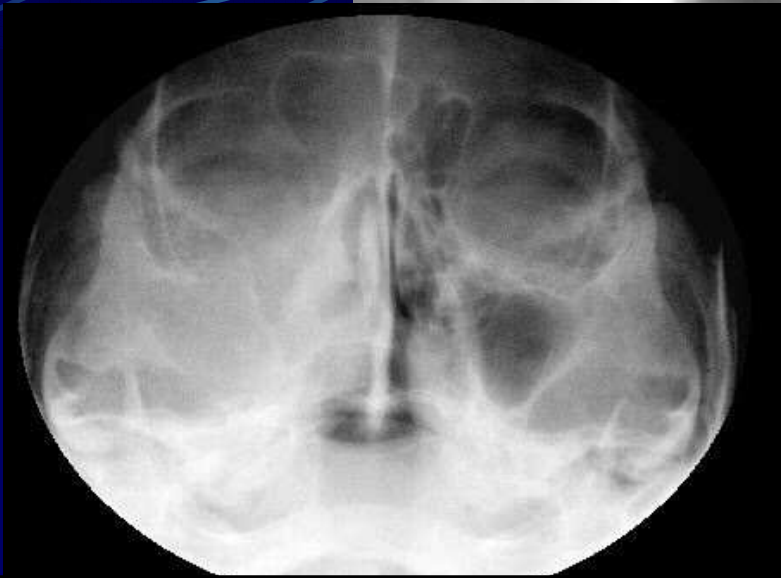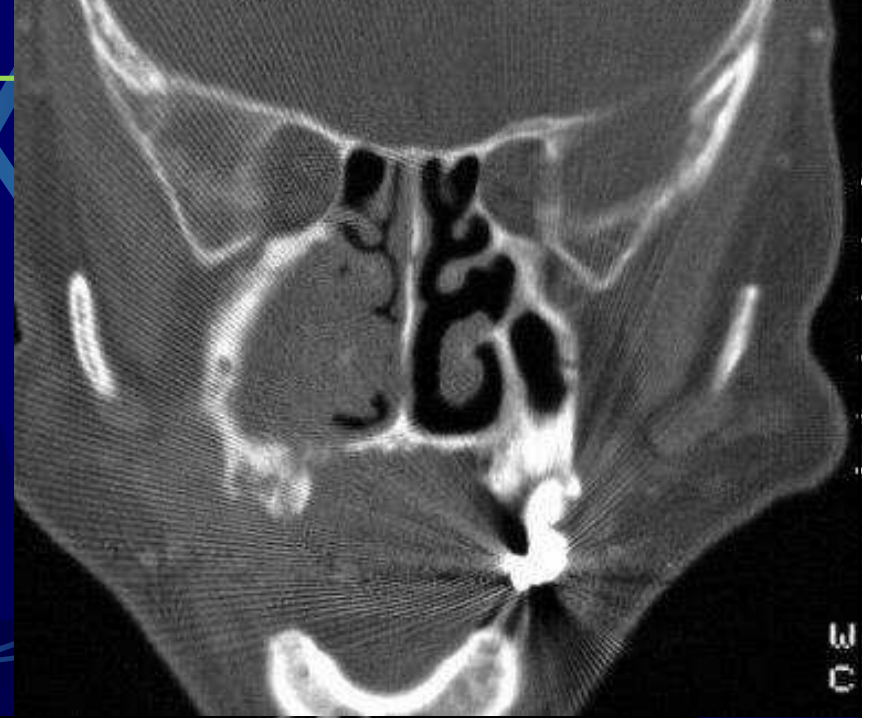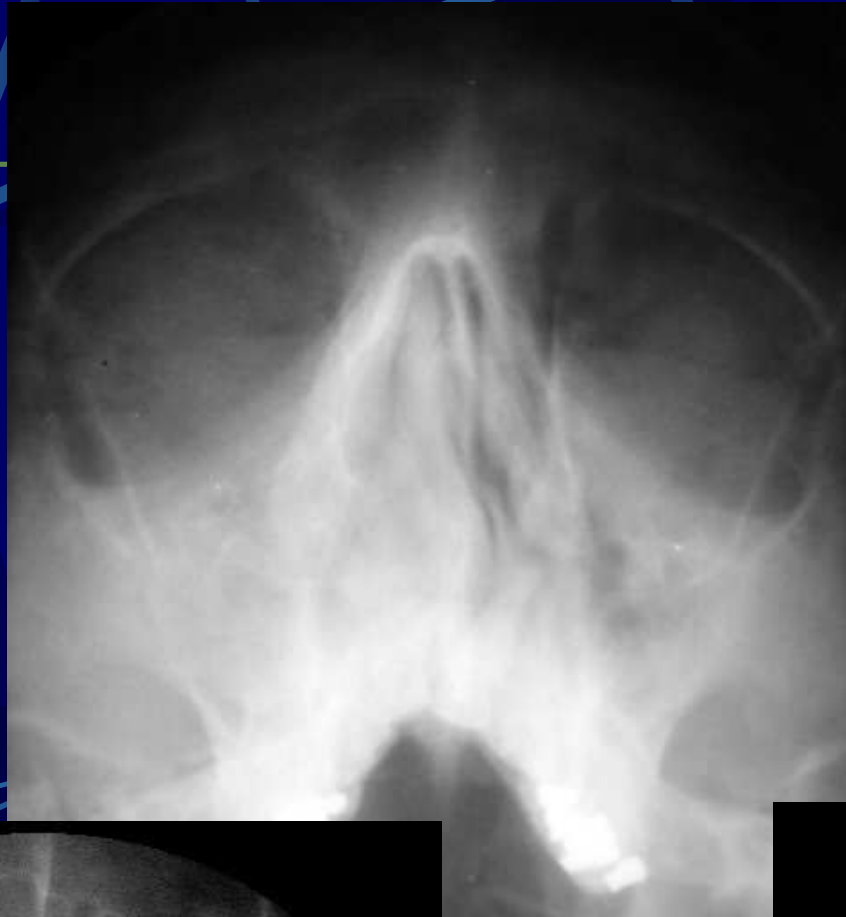



Ca – odontogenní tumor



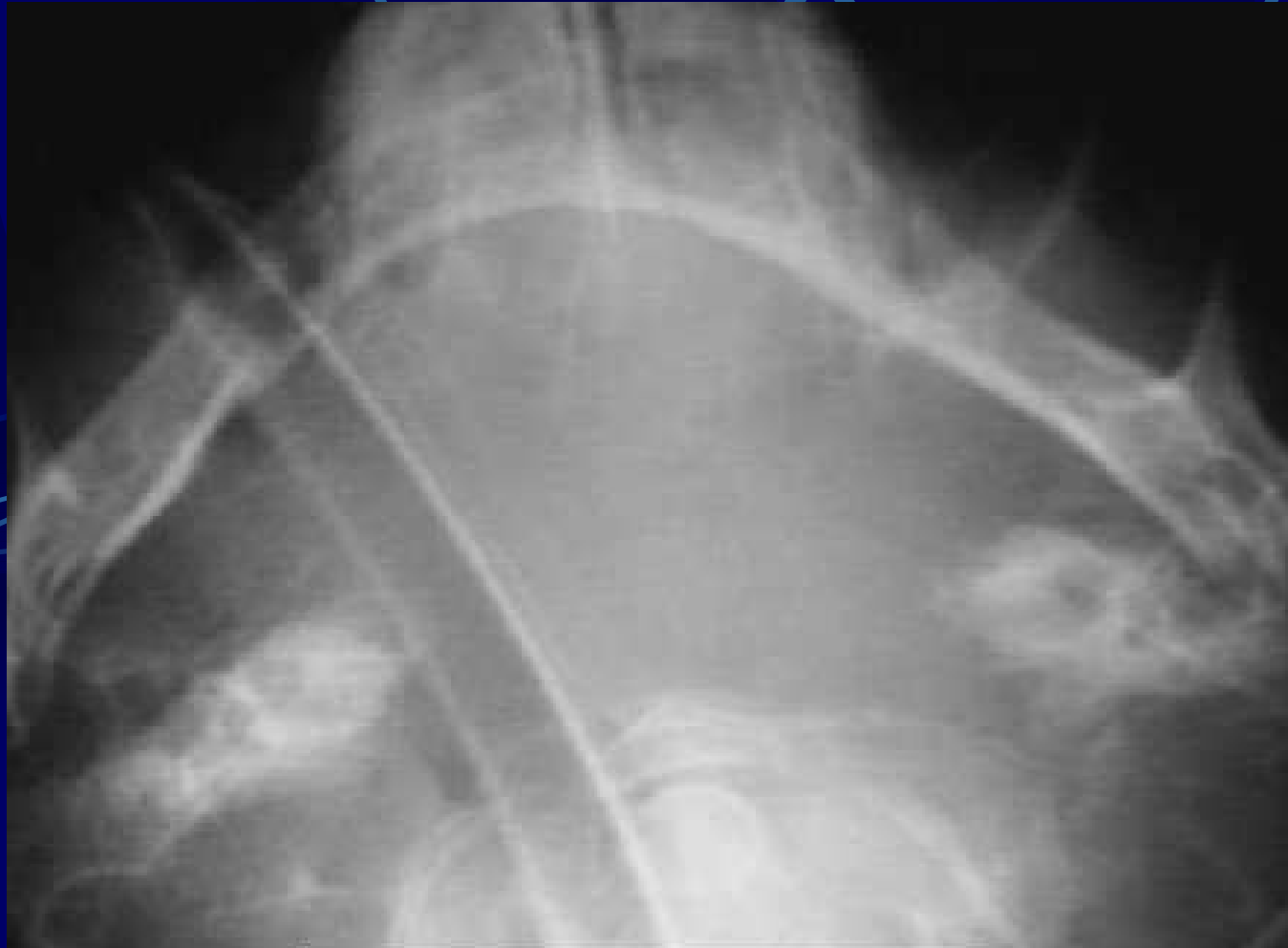


Ca maxilly



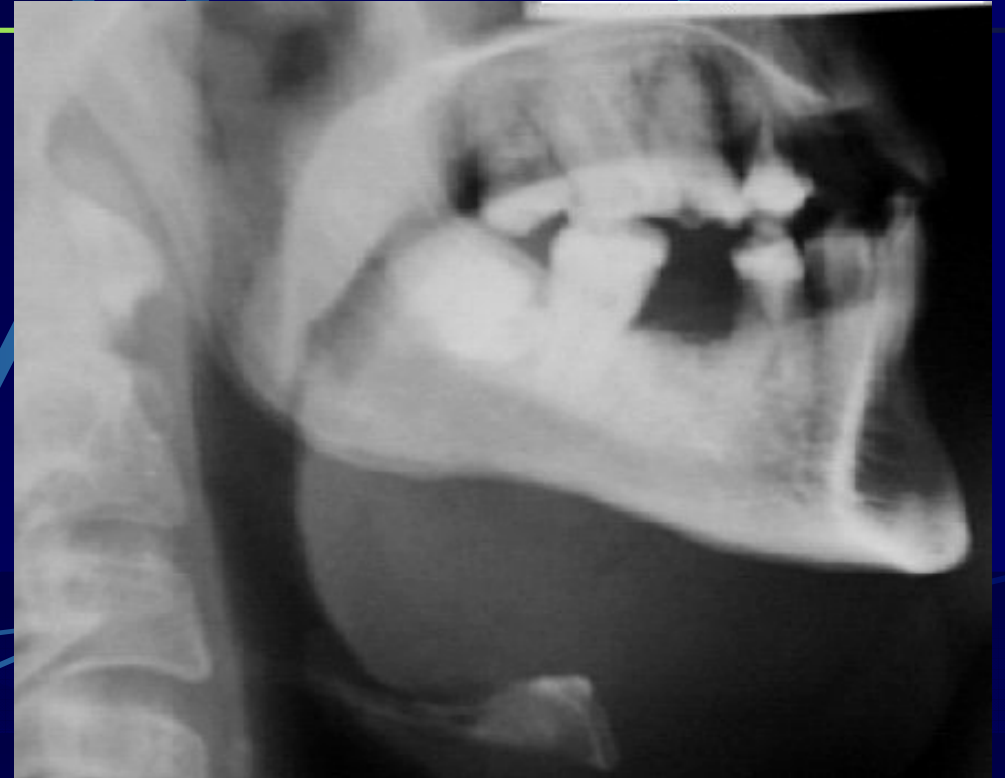
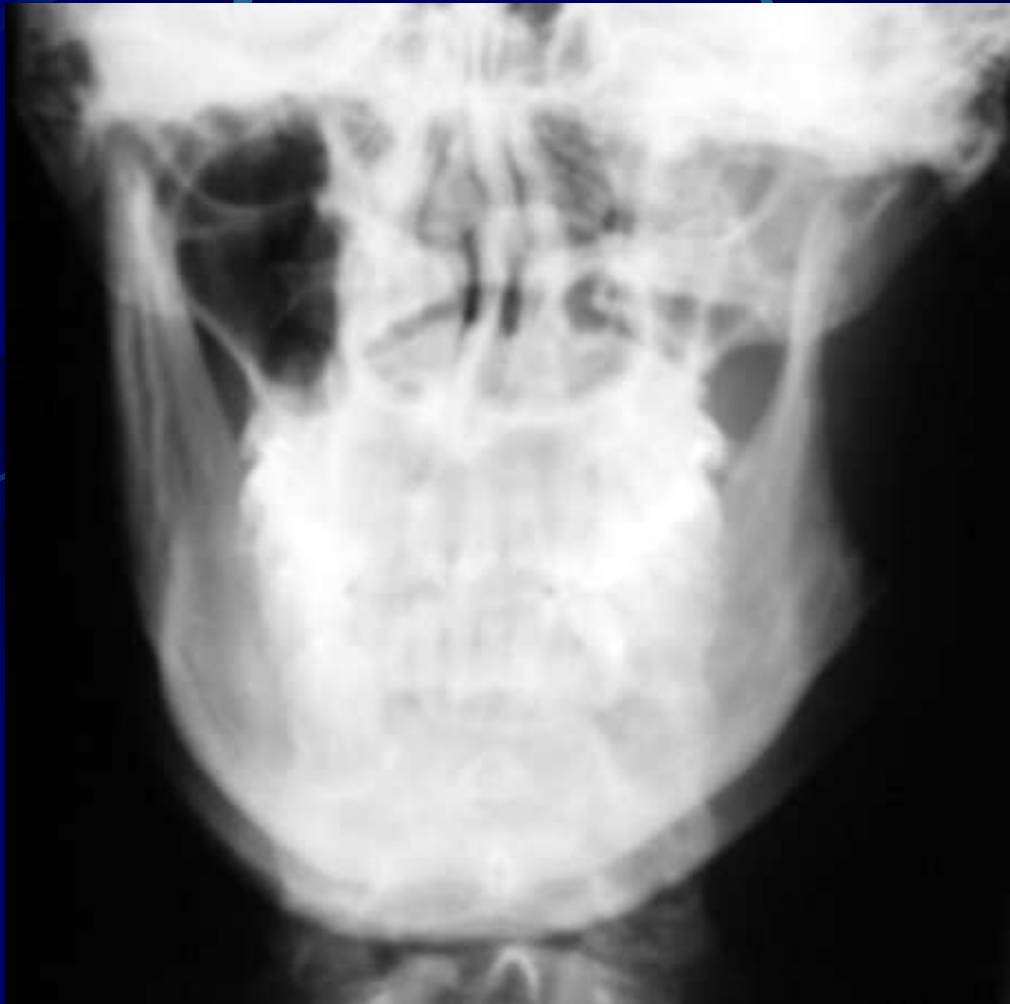
Ca nasopharyngu



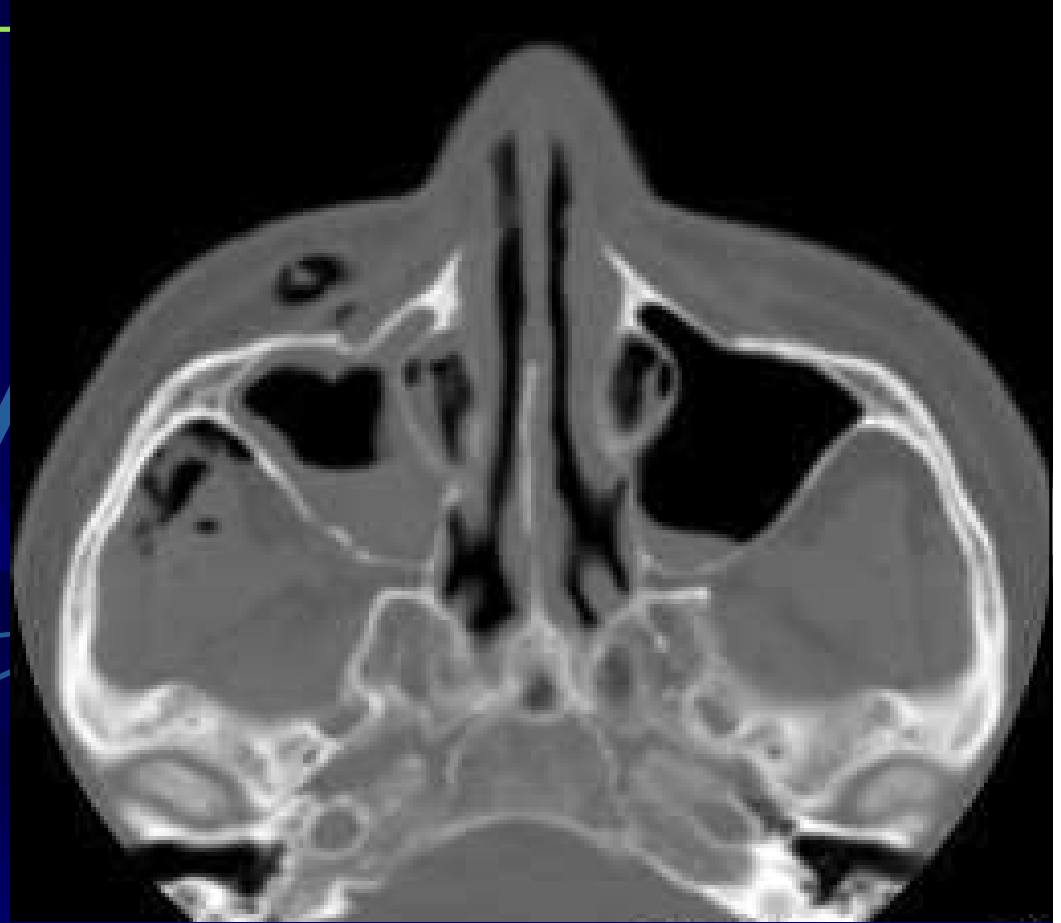
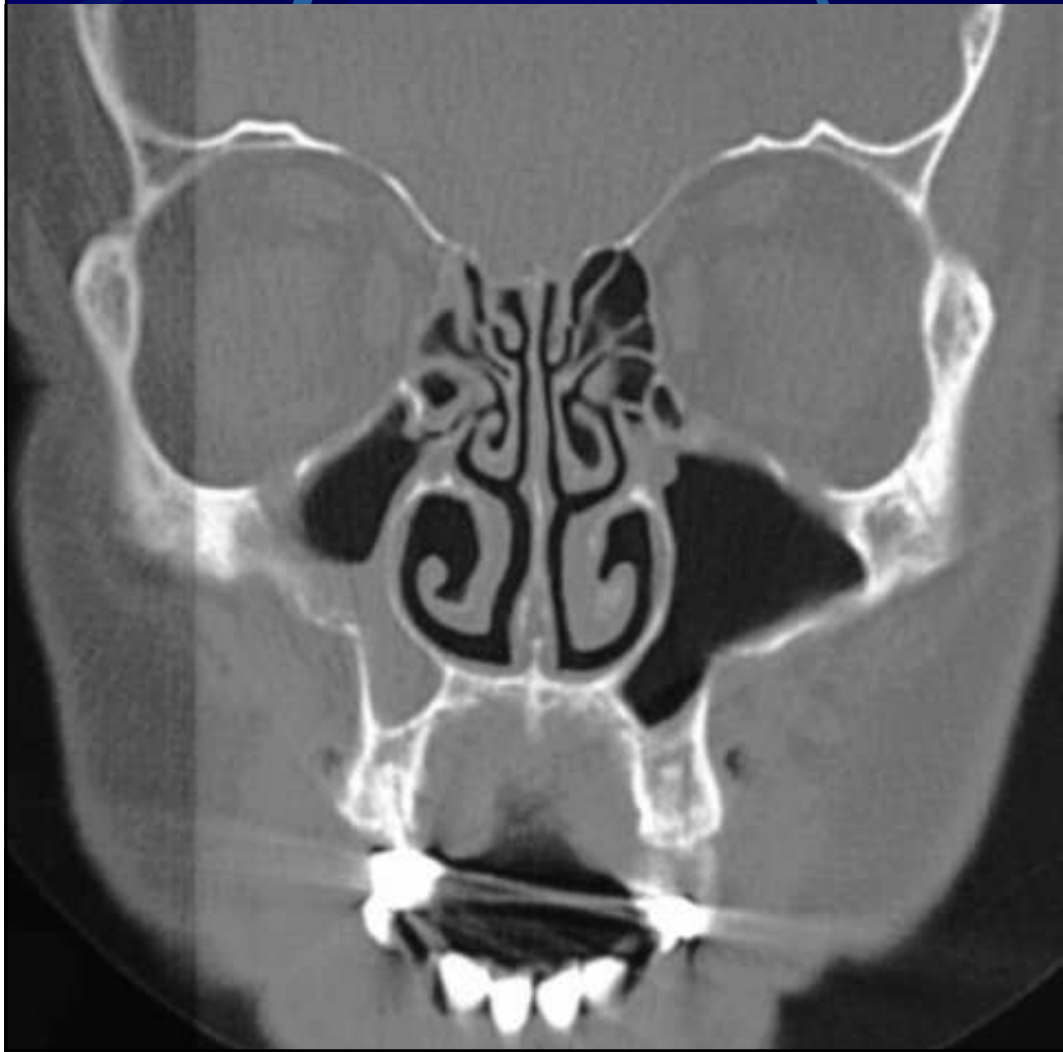

Sarcom mandibuly



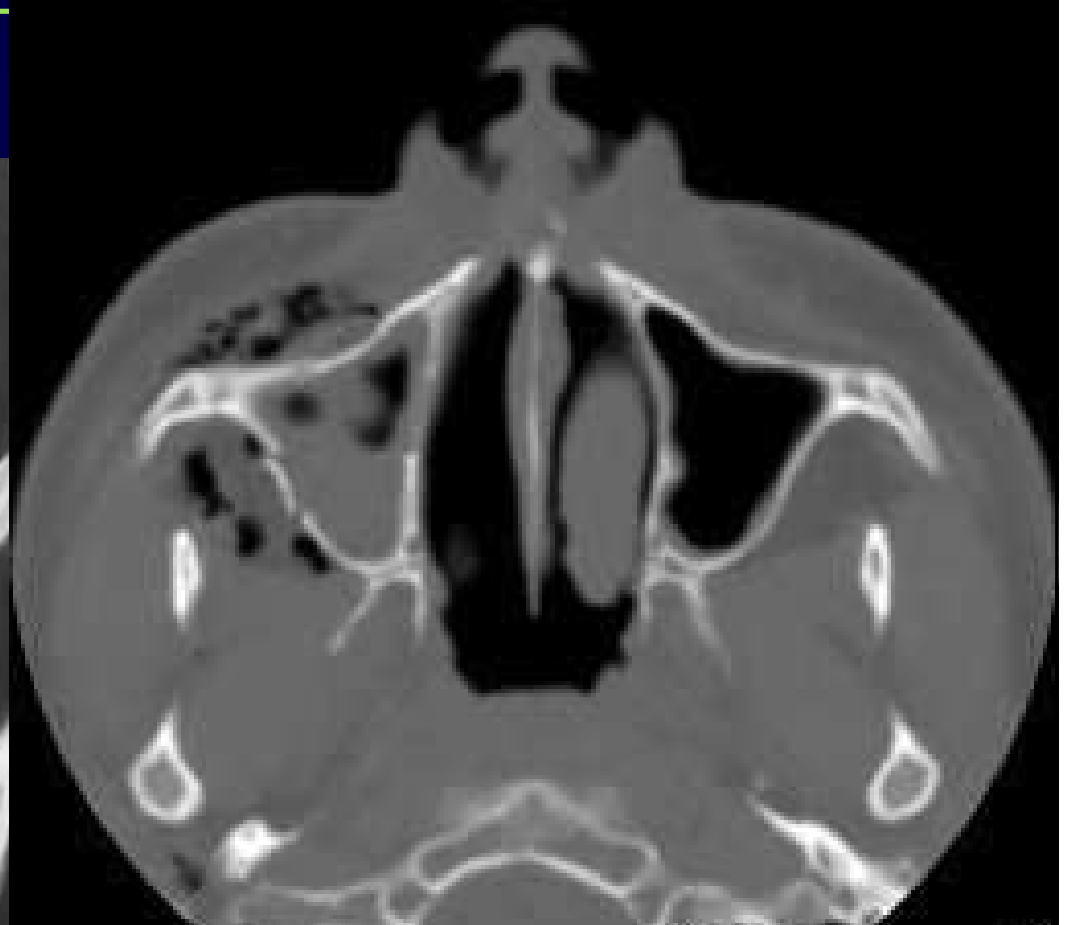
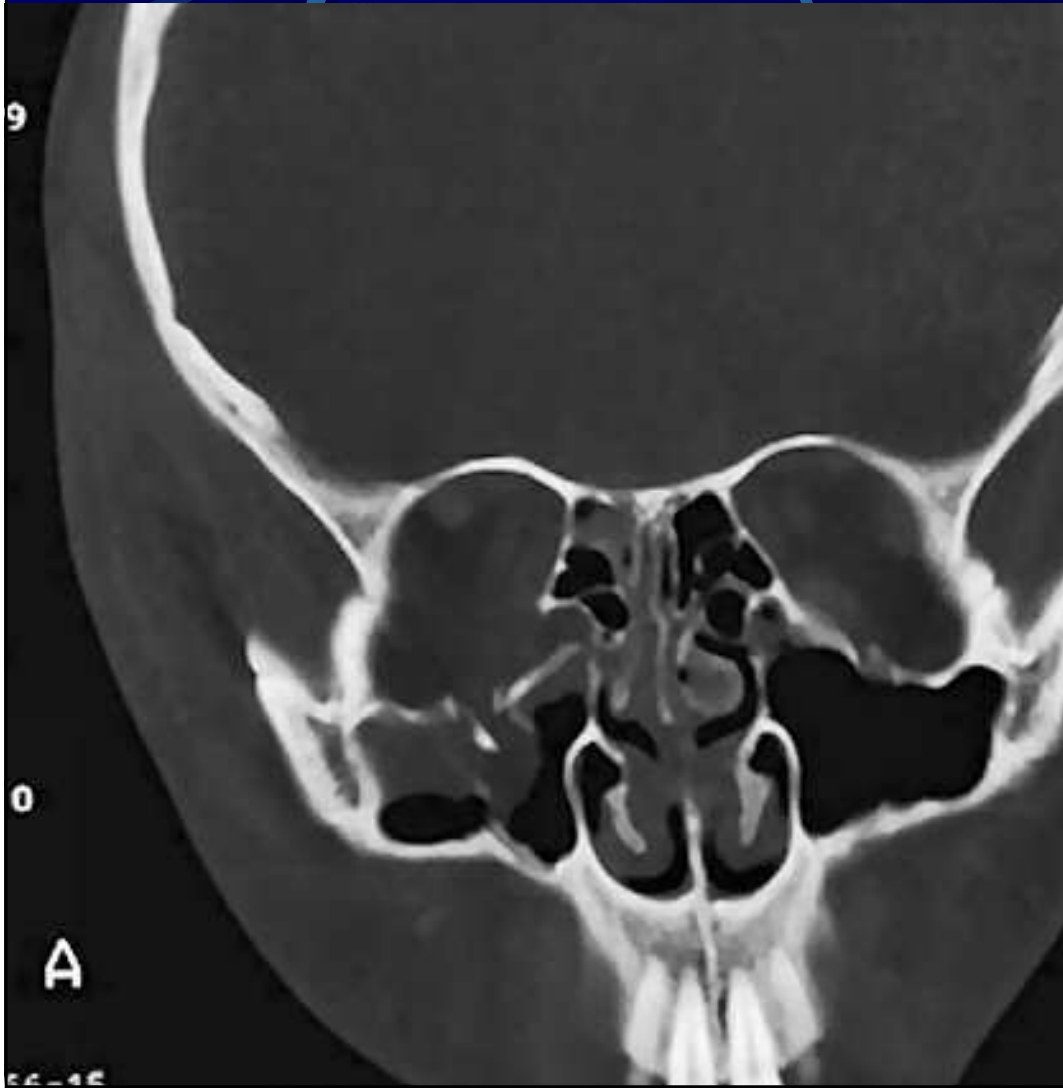
Fraktura



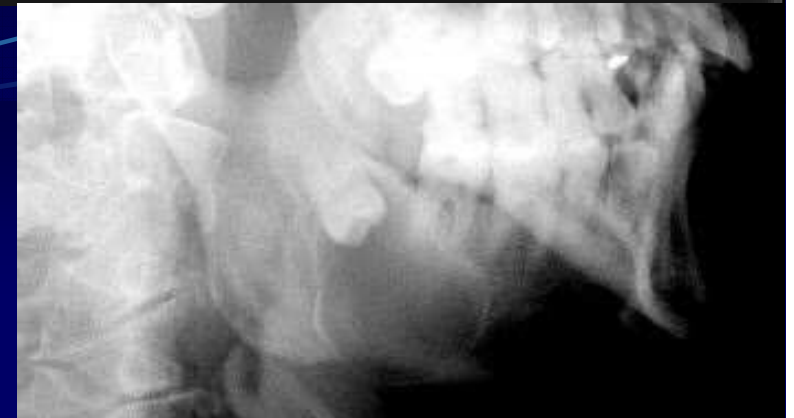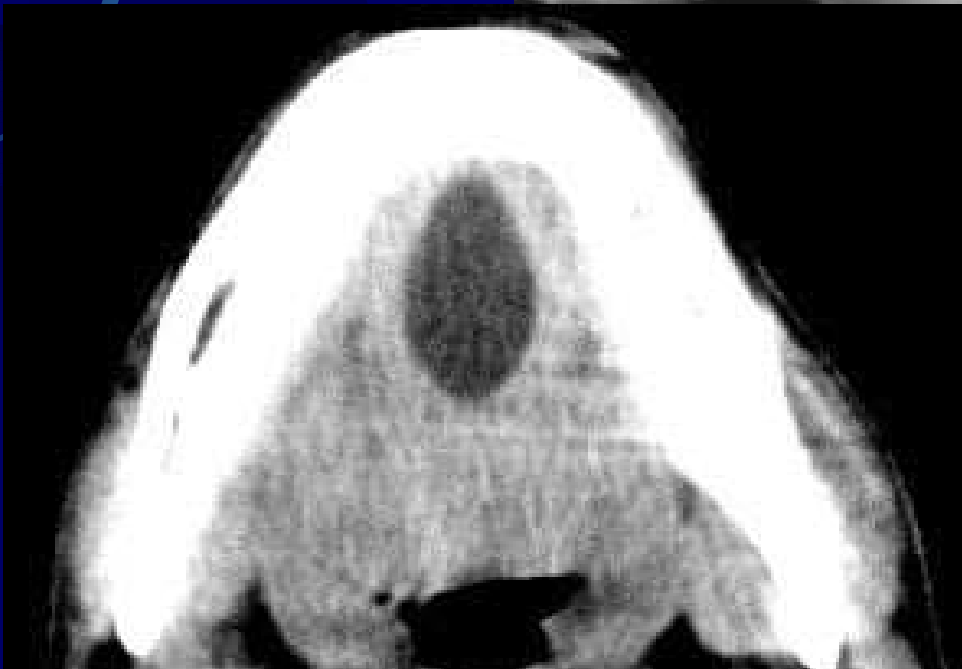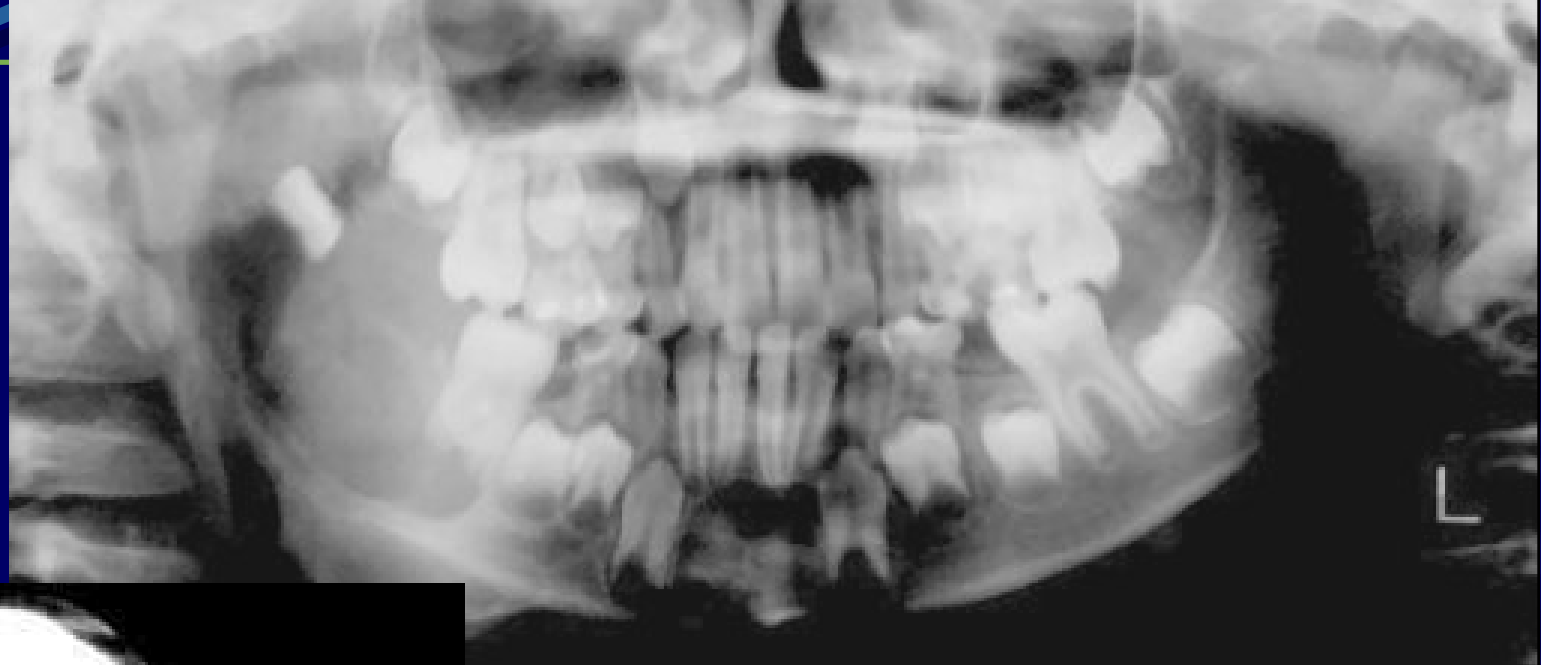



Fraktura



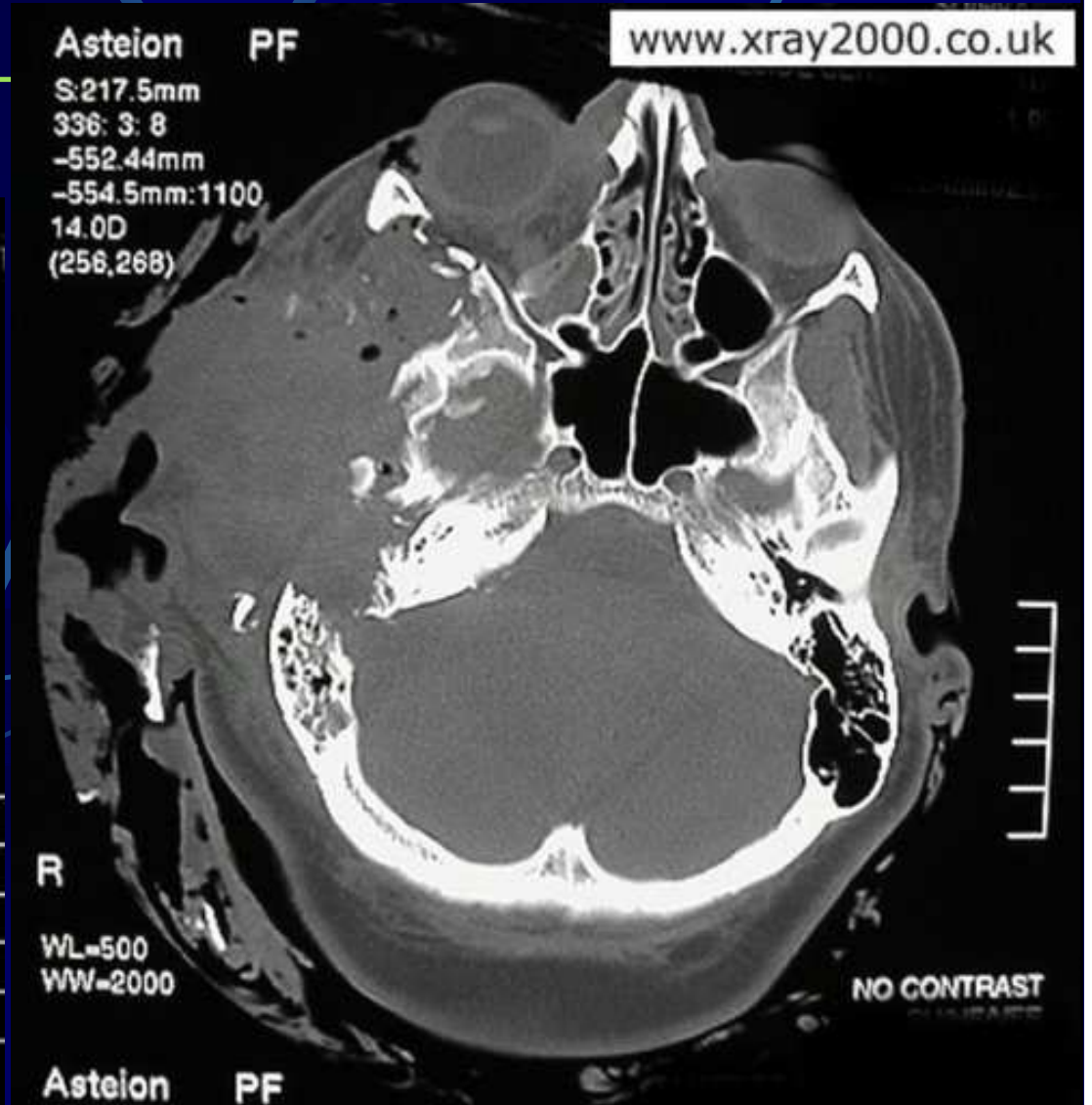
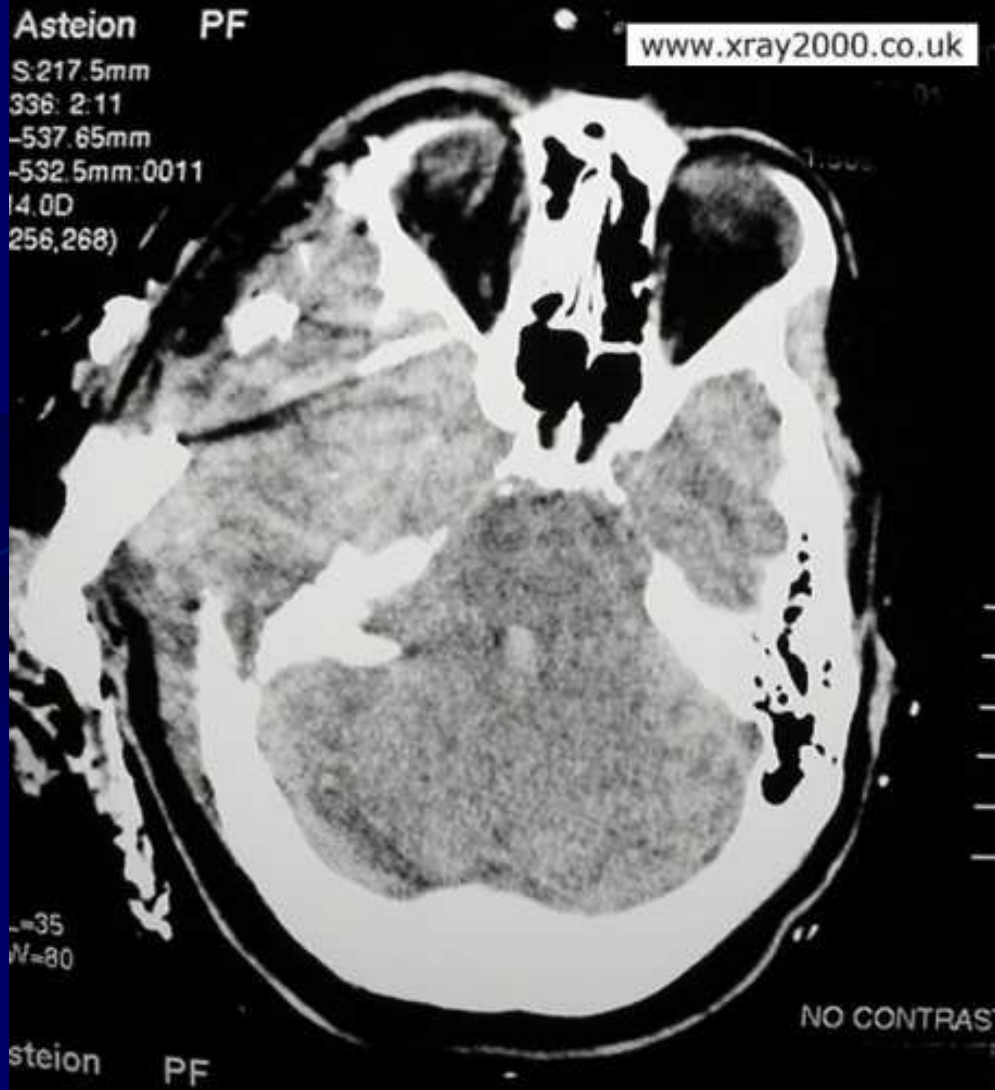


Cysta





Frantura

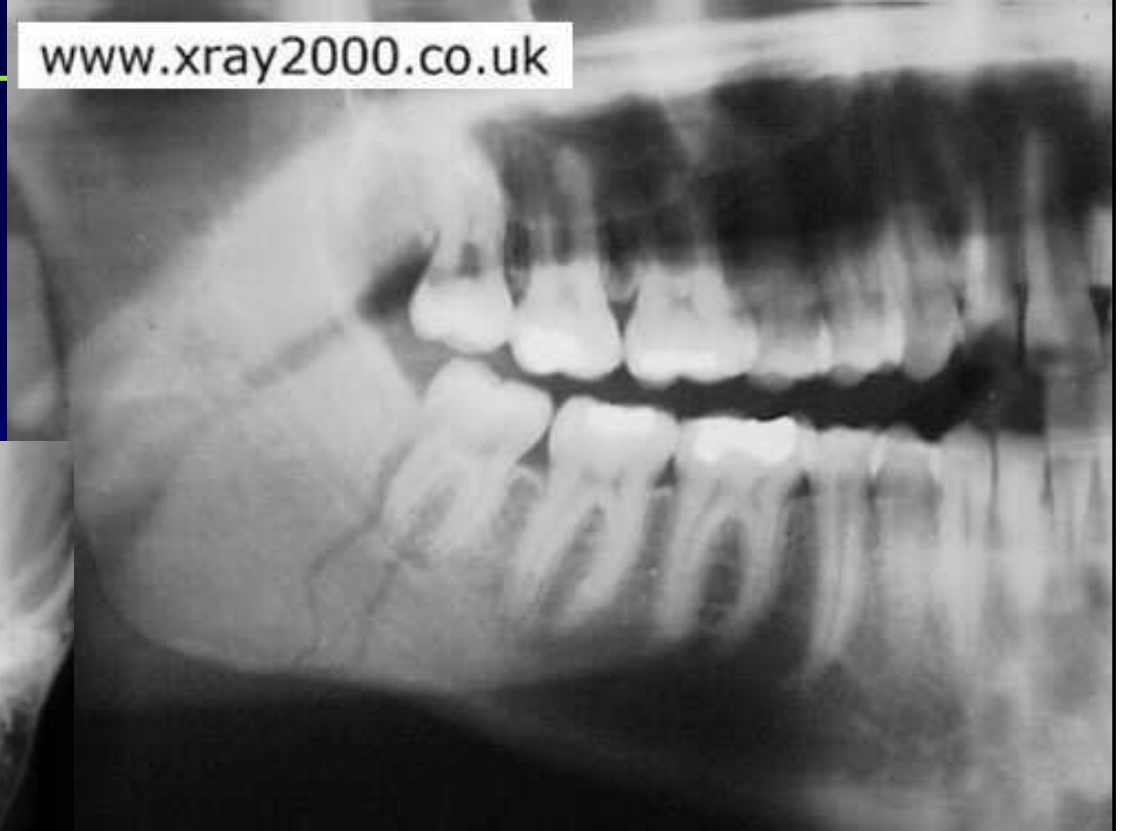



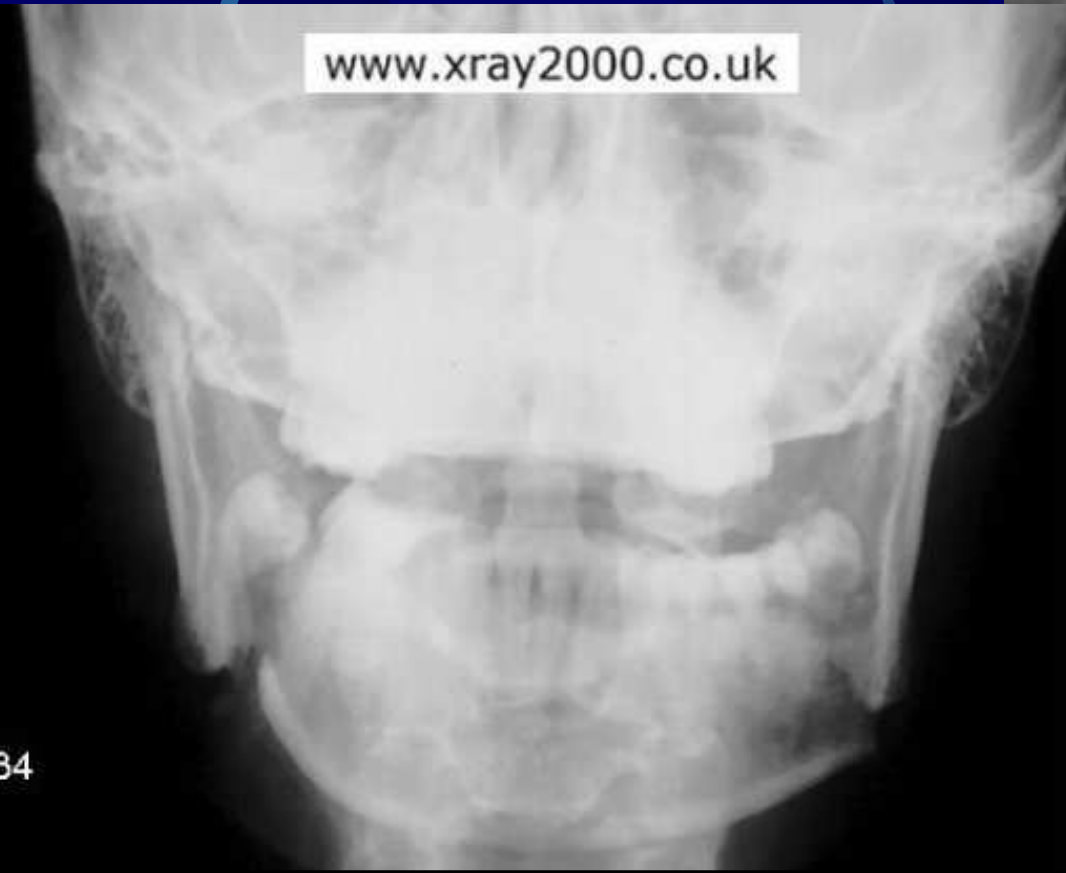Frantura



www.xray2000.co.uk



www.xray2000.co.uk

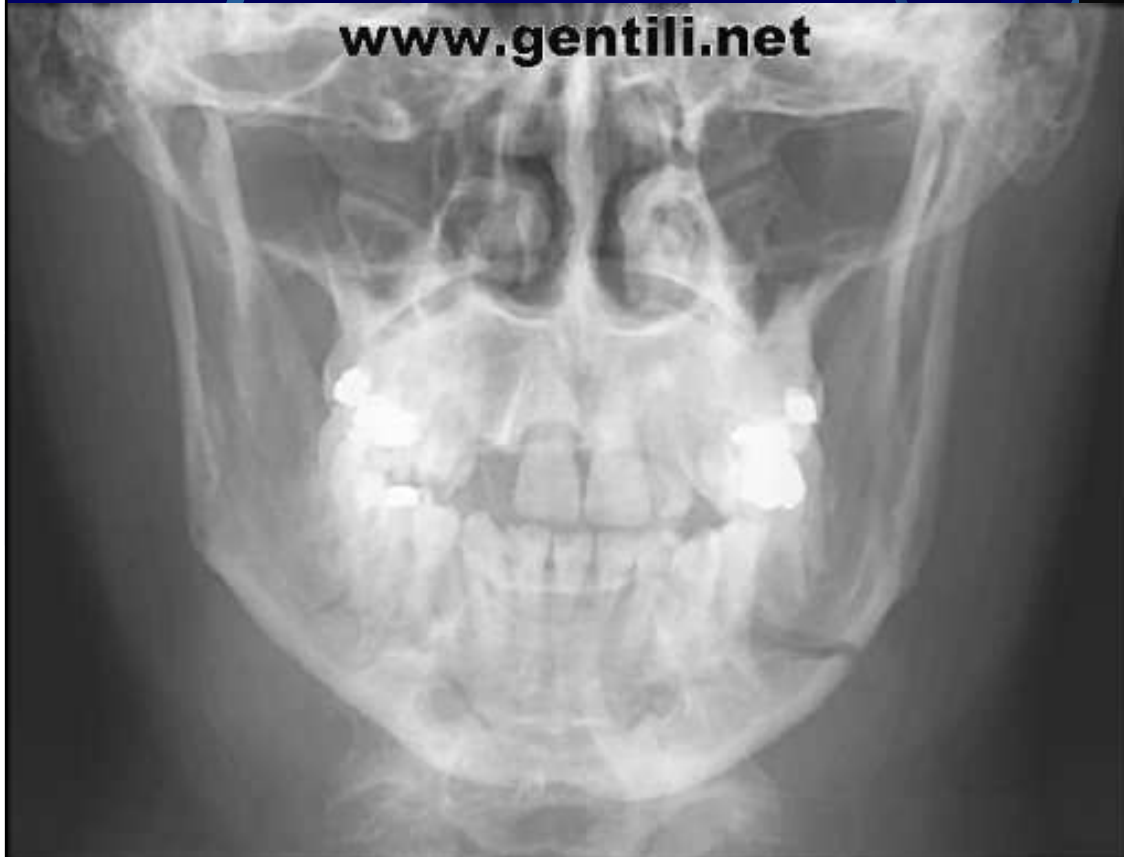
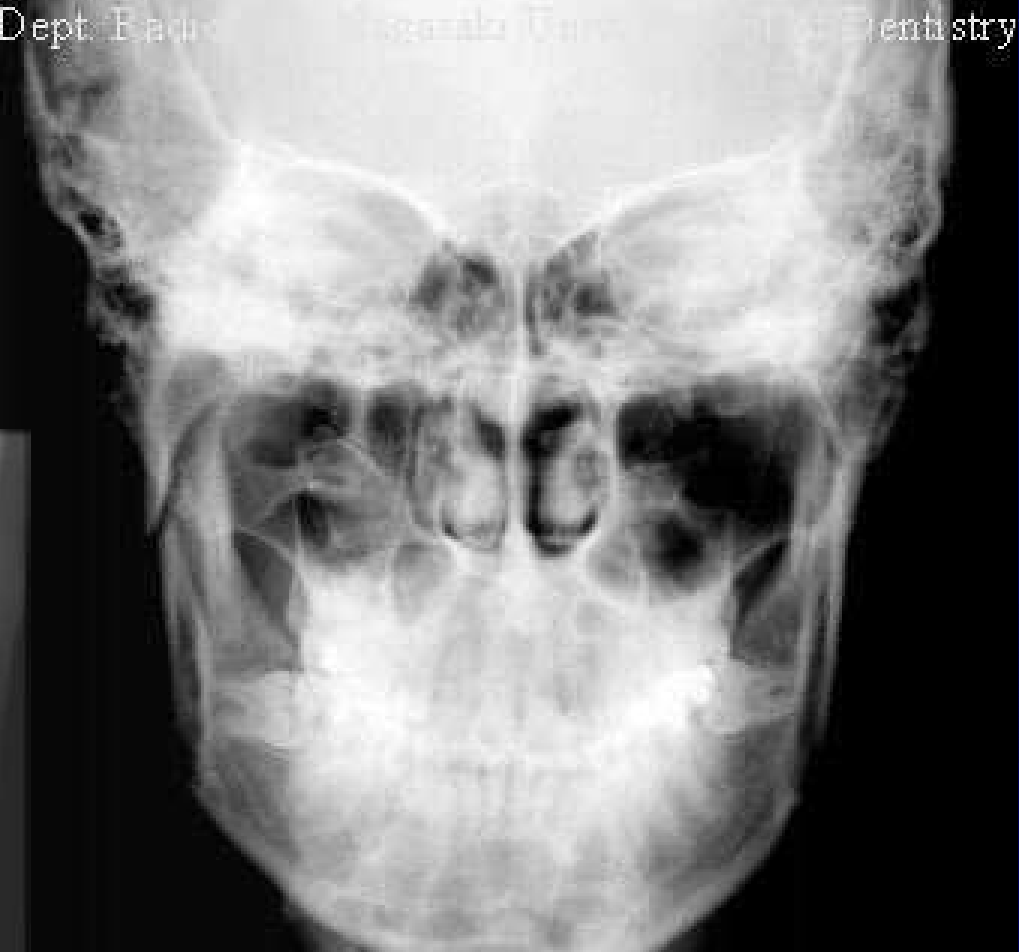



Frantura



Dept. Radiology, Masaryk University Brno, Faculty of Medicine, Brno, Czech Republic

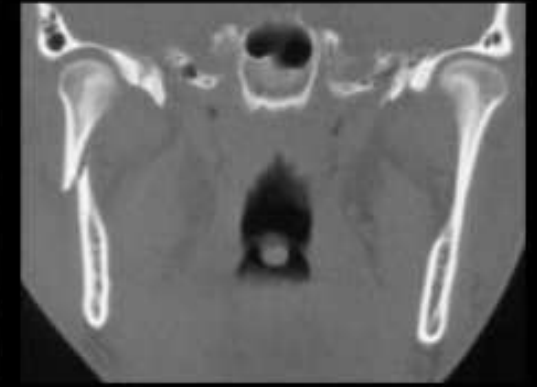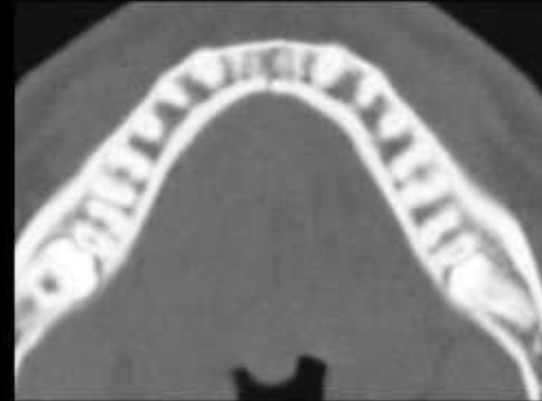

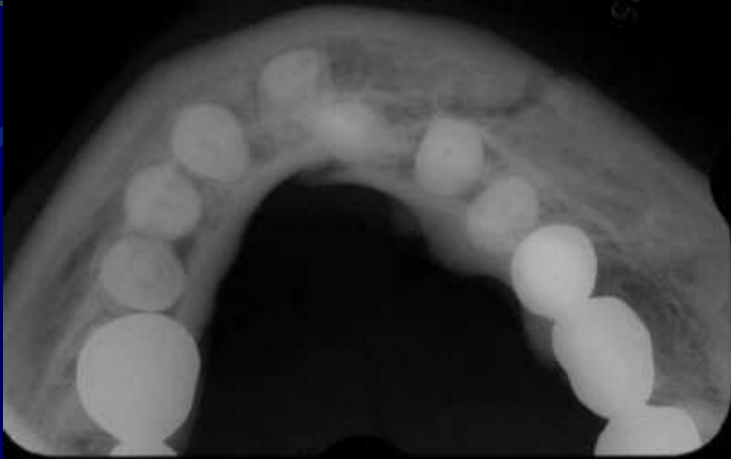


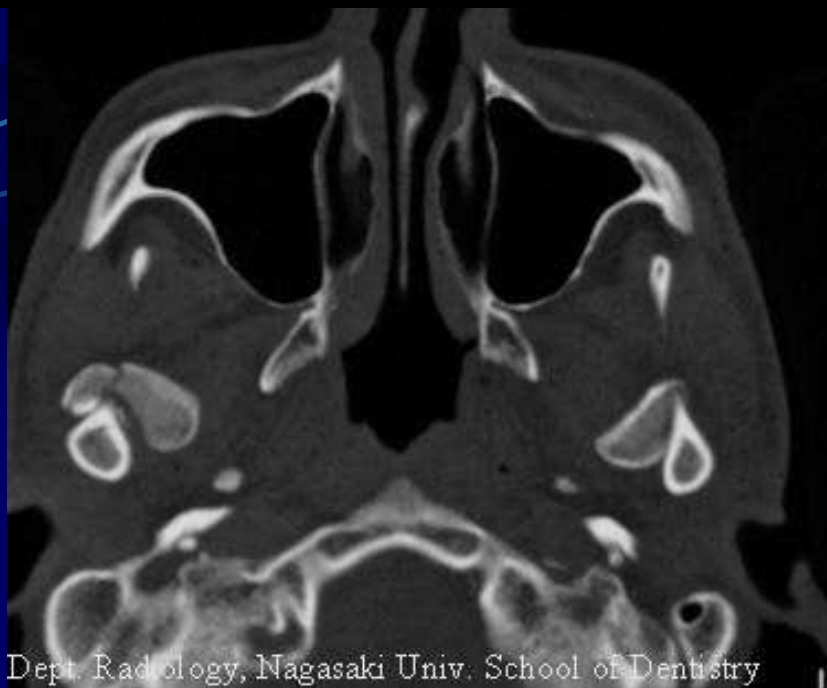
Frantura



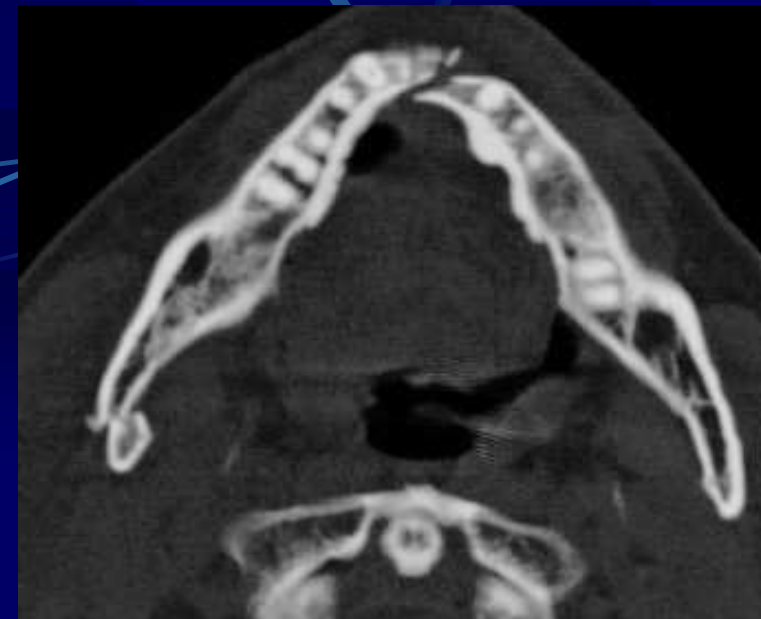
Dept. Radiology, Nagasaki Univ. School of Dentistry



Dept. Radiology, Nagasaki Univ. School of Dentistry



Dept. Radiology, Nagasaki Univ. School of Dentistry

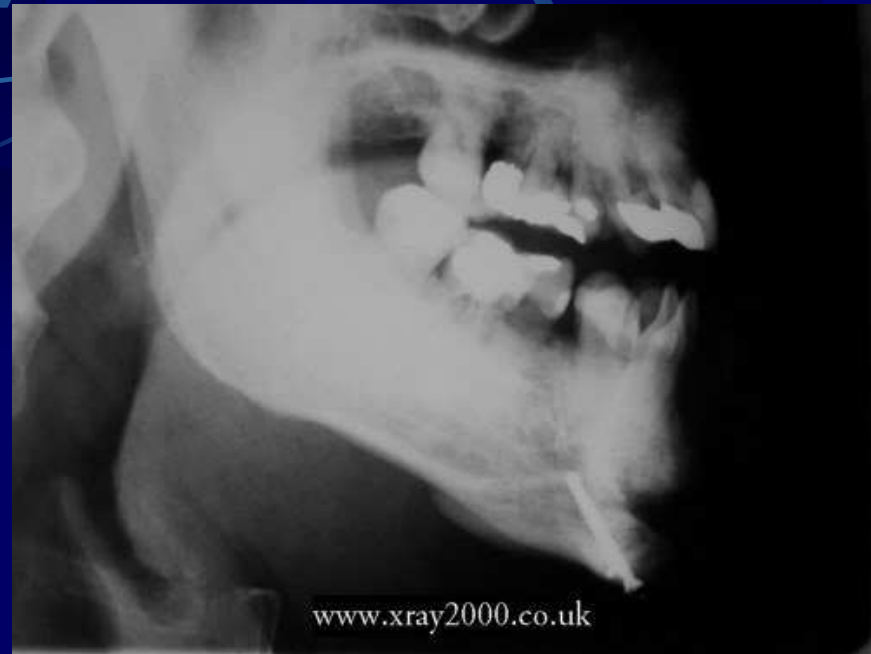
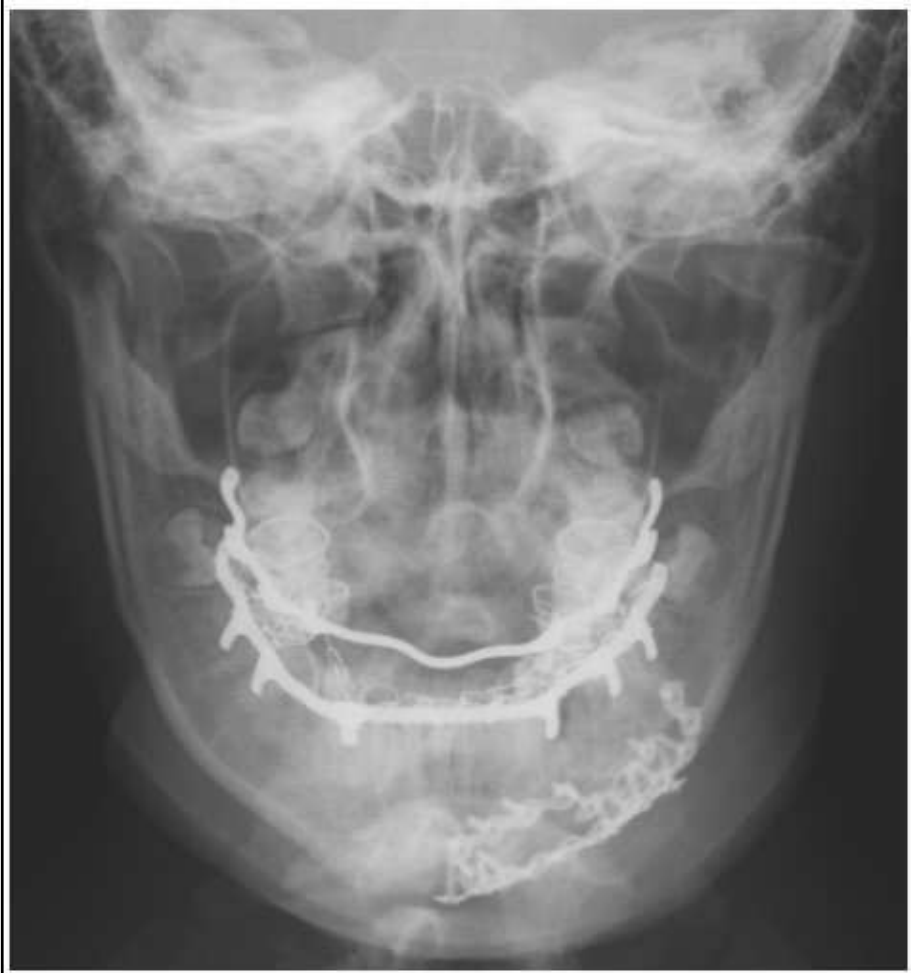
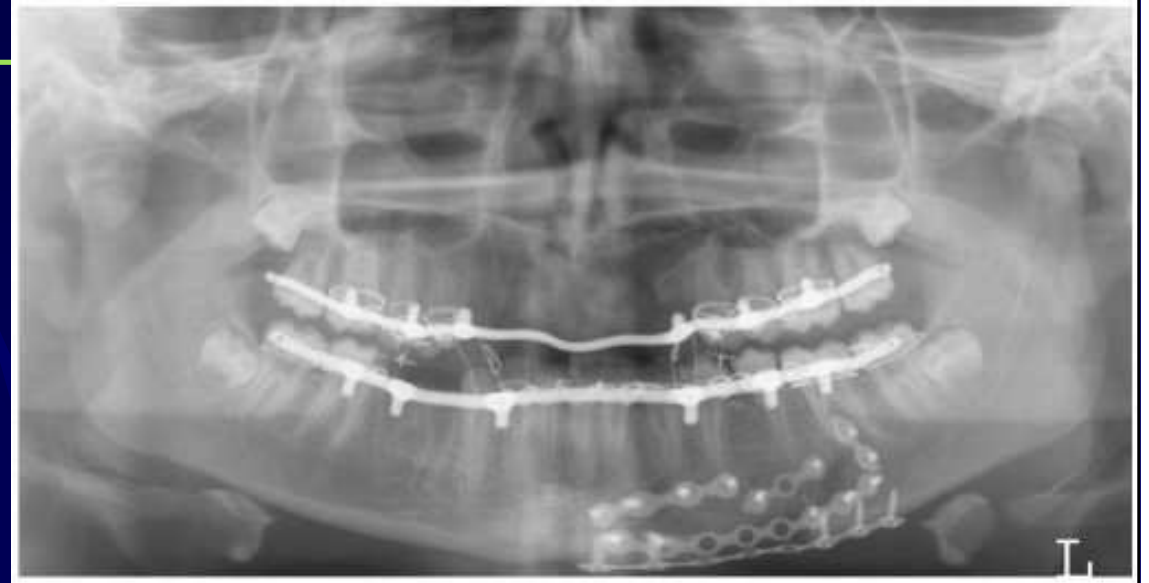Dept. Radiology, Nagasaki Univ. School of Dentistry





Frantura

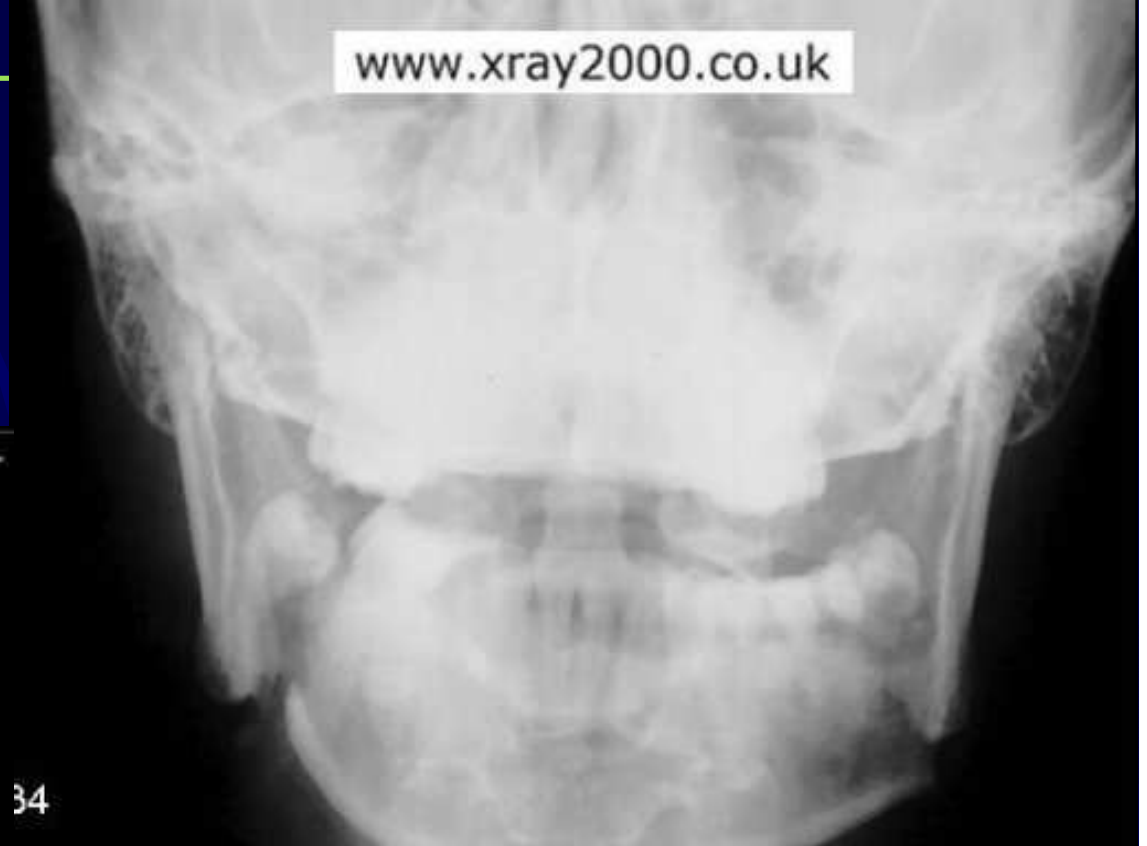



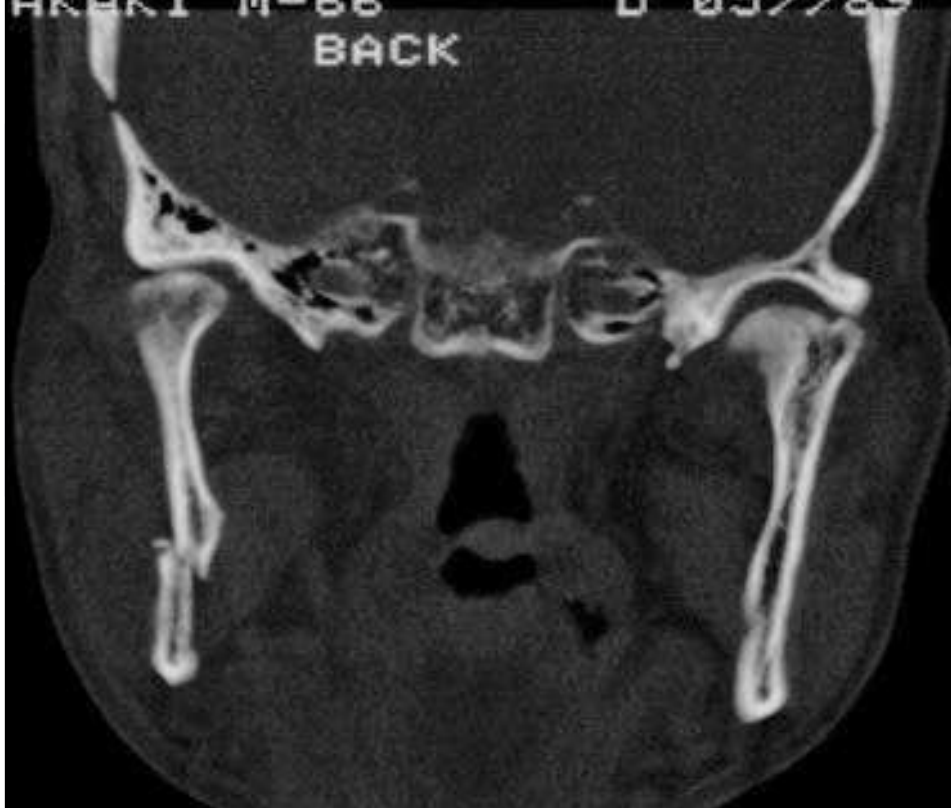Frantura



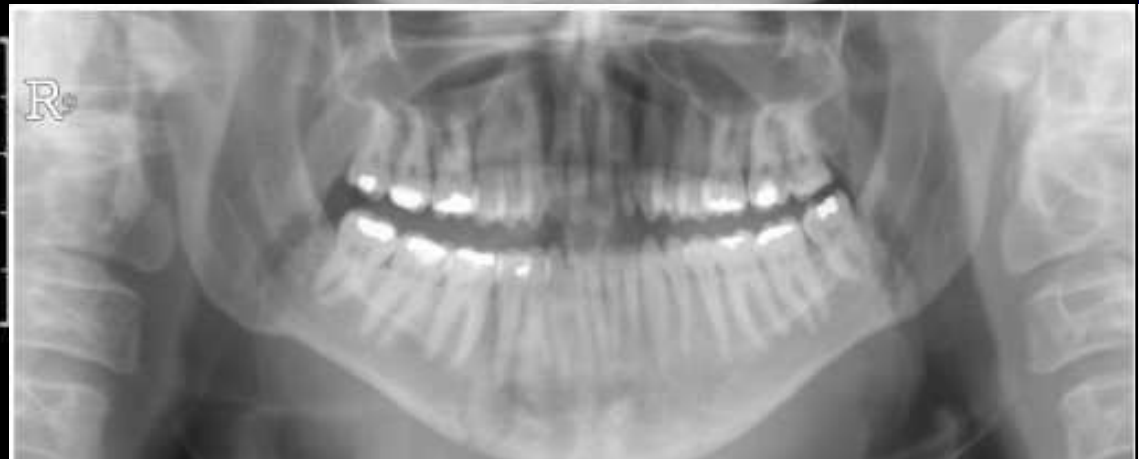www.xray2000.co.uk



R-H NAGASAKI UNIV. DENTAL
AKAKI M-66 D 057789
BACK

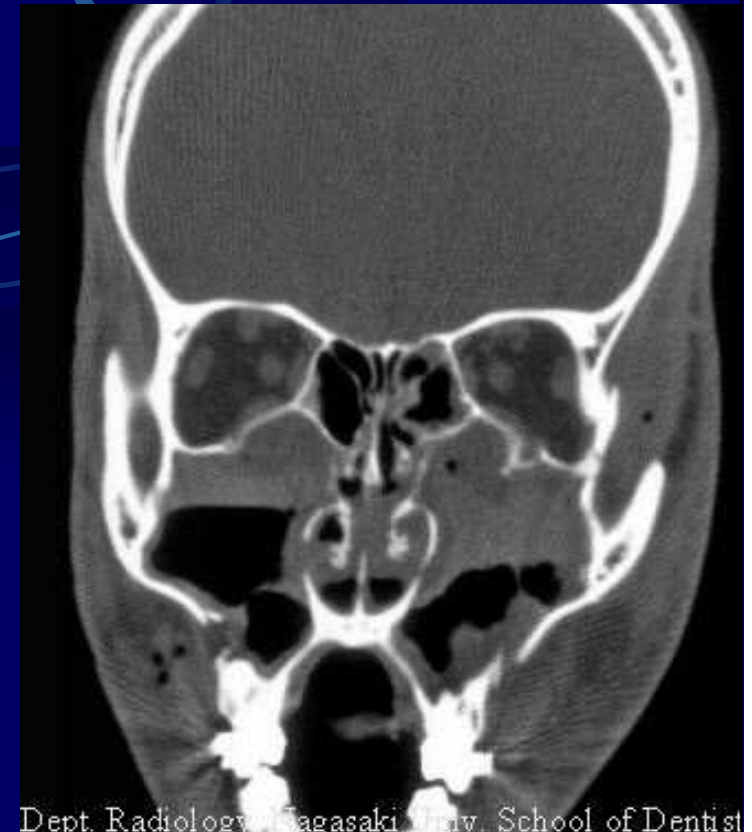
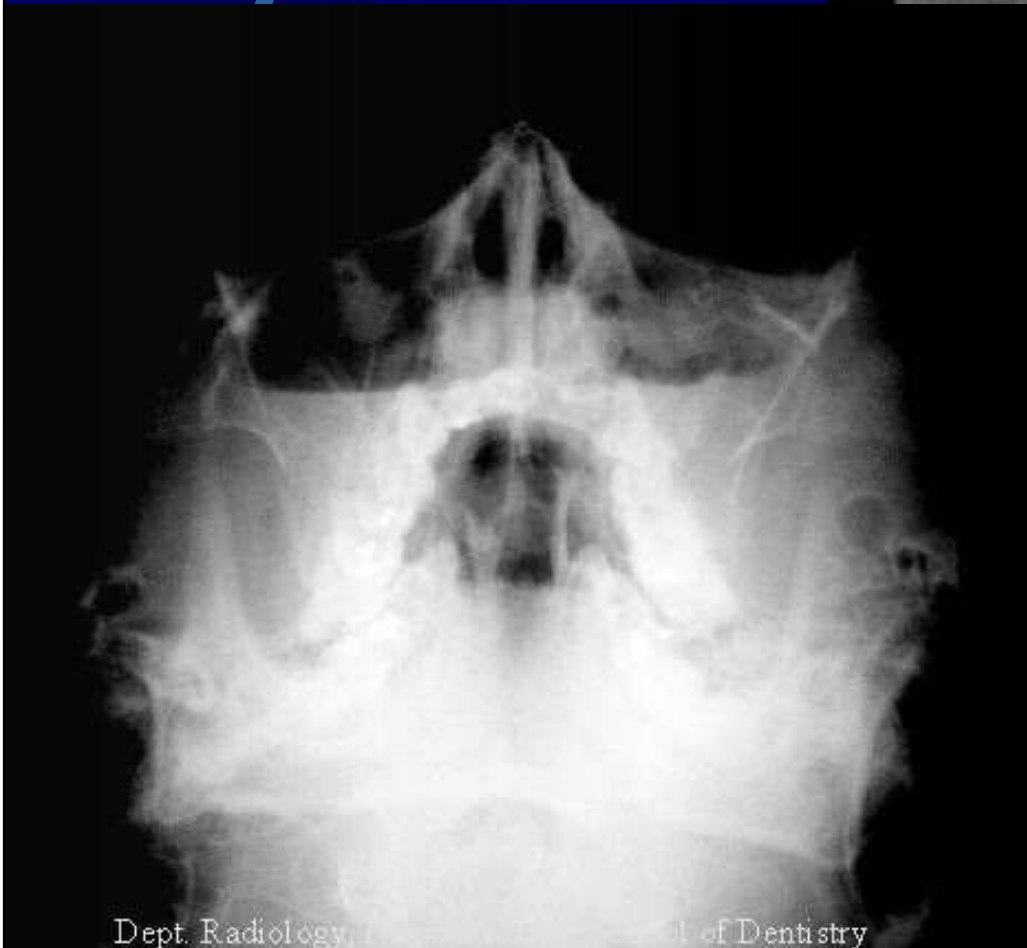
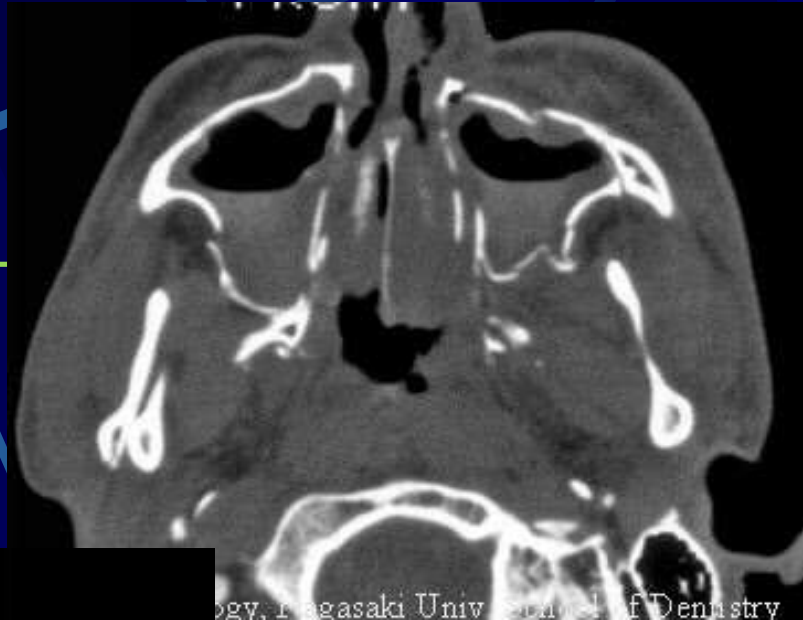

34



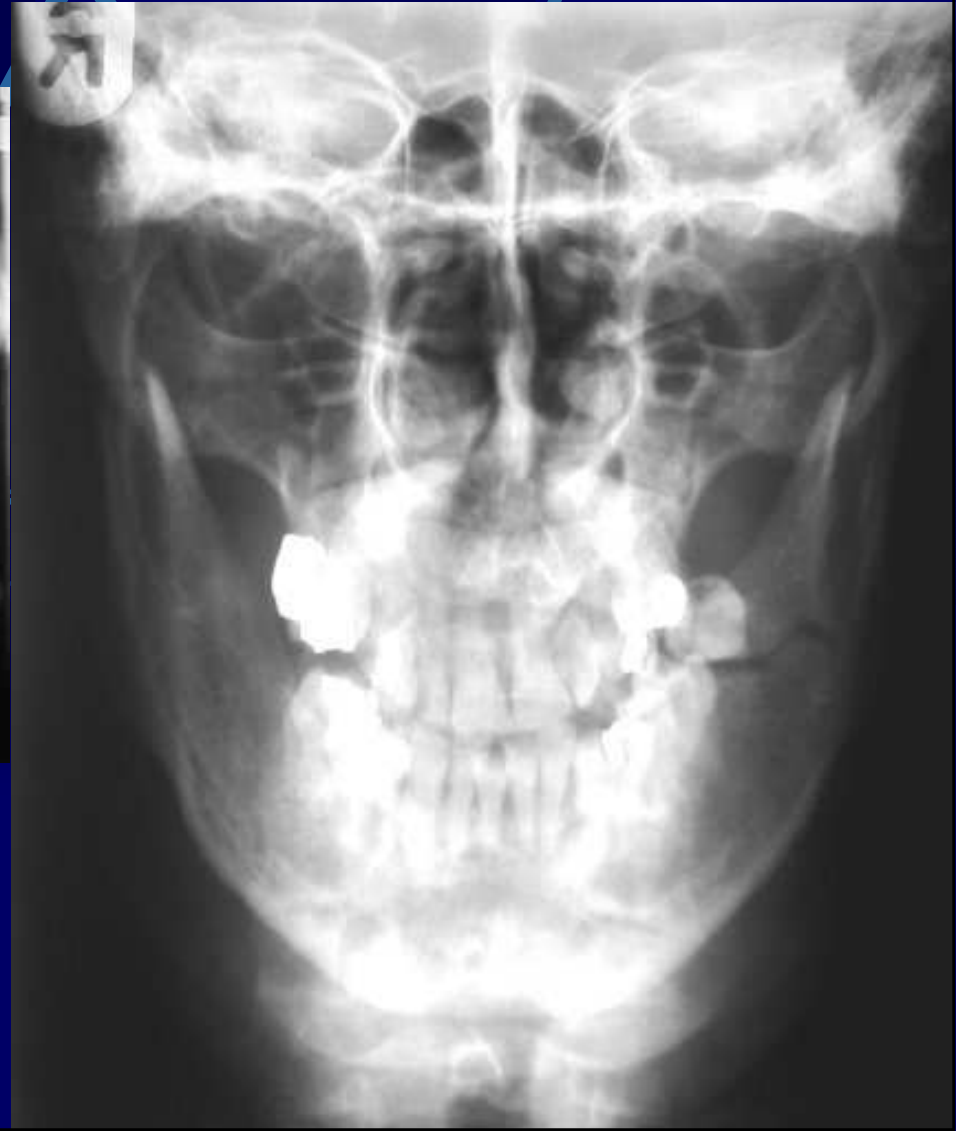
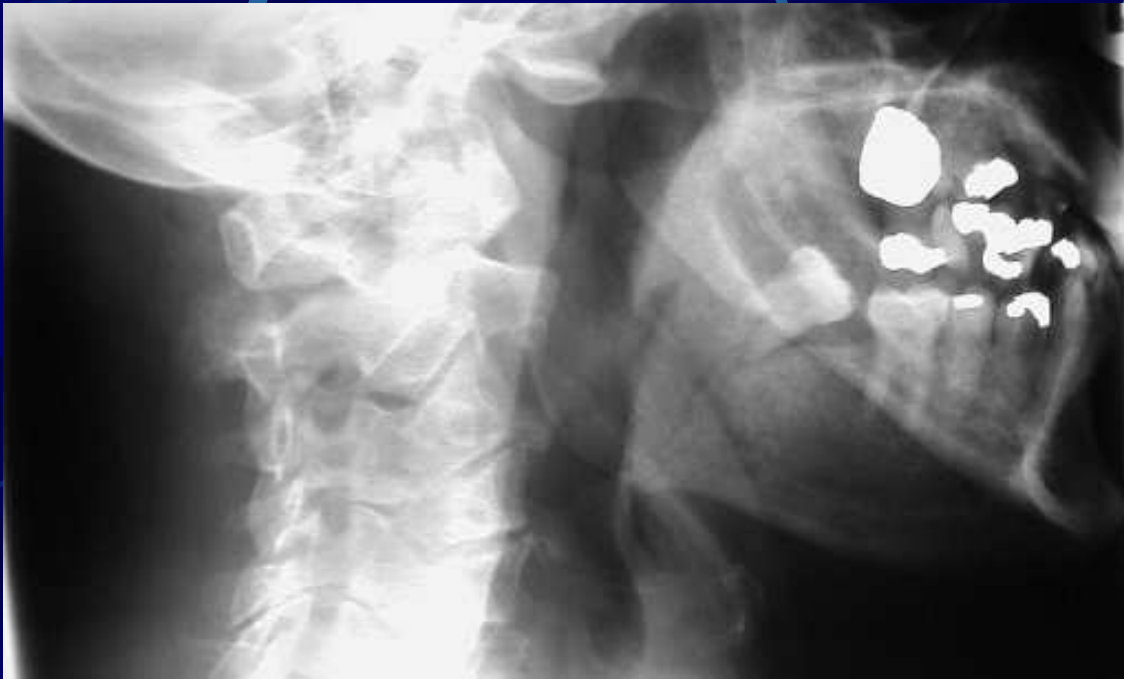

Frantura



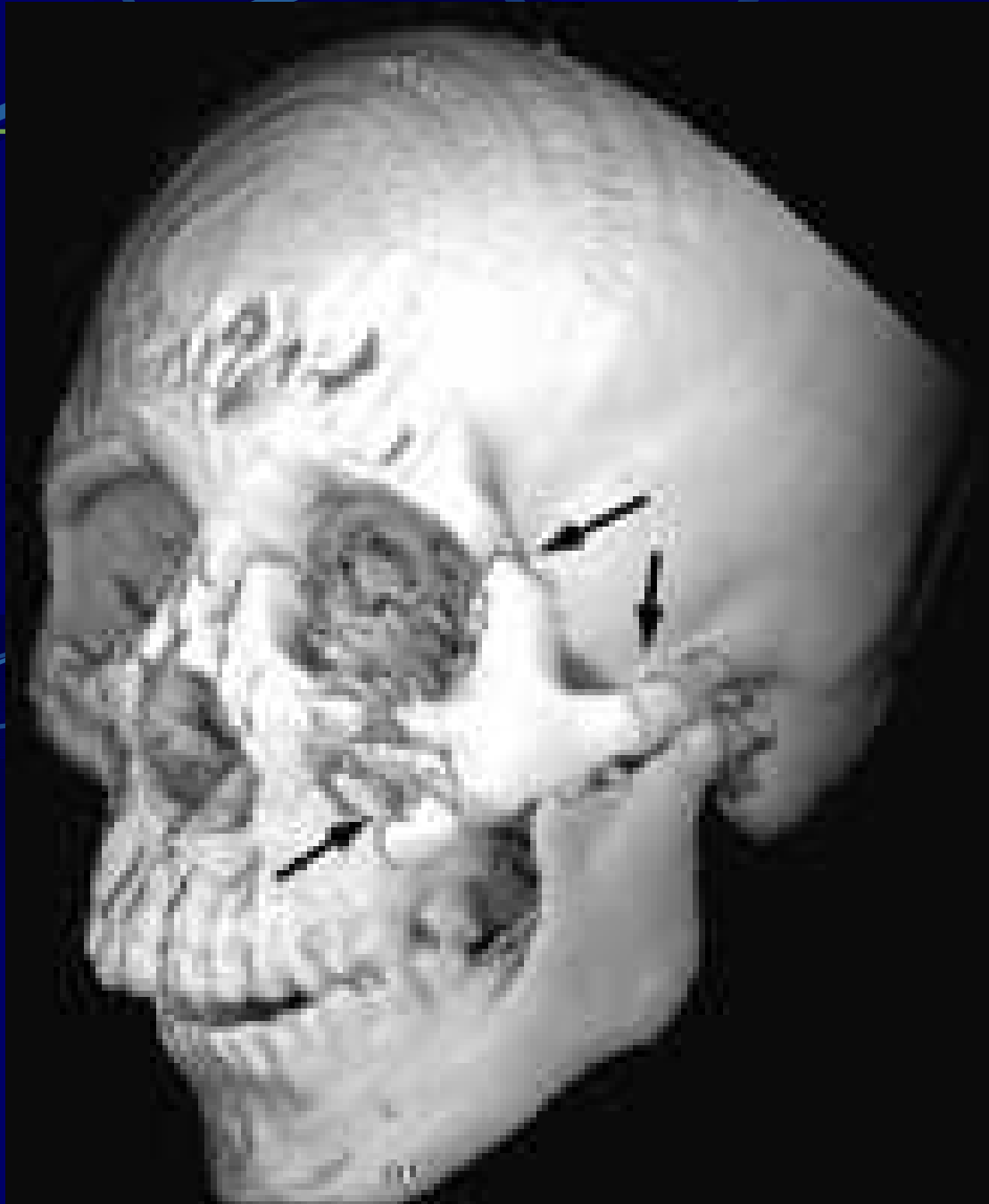

Frantura





Frantura





Zuby – náhrada

