


RTG zubů a čelistí

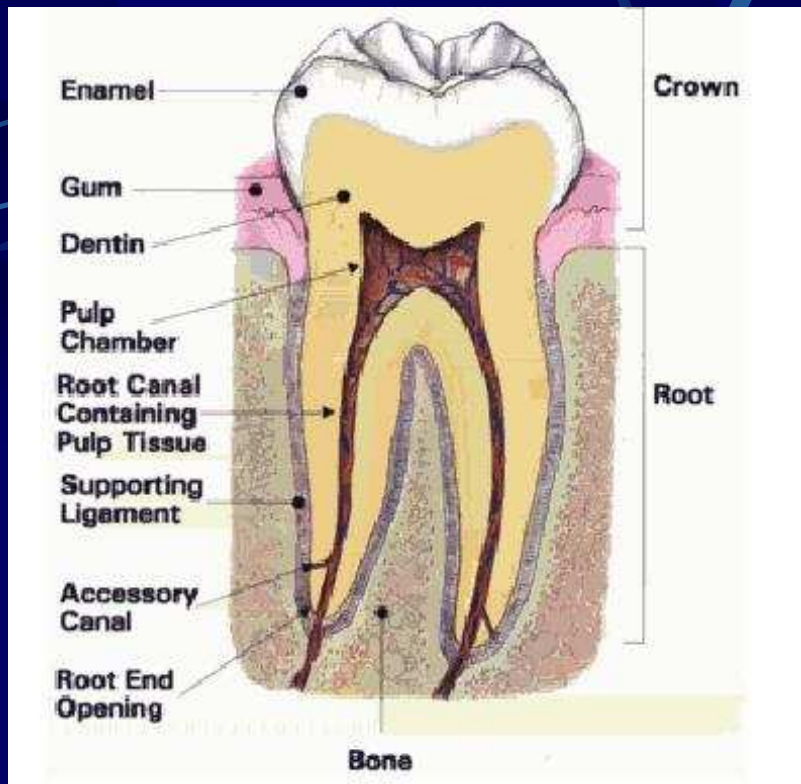
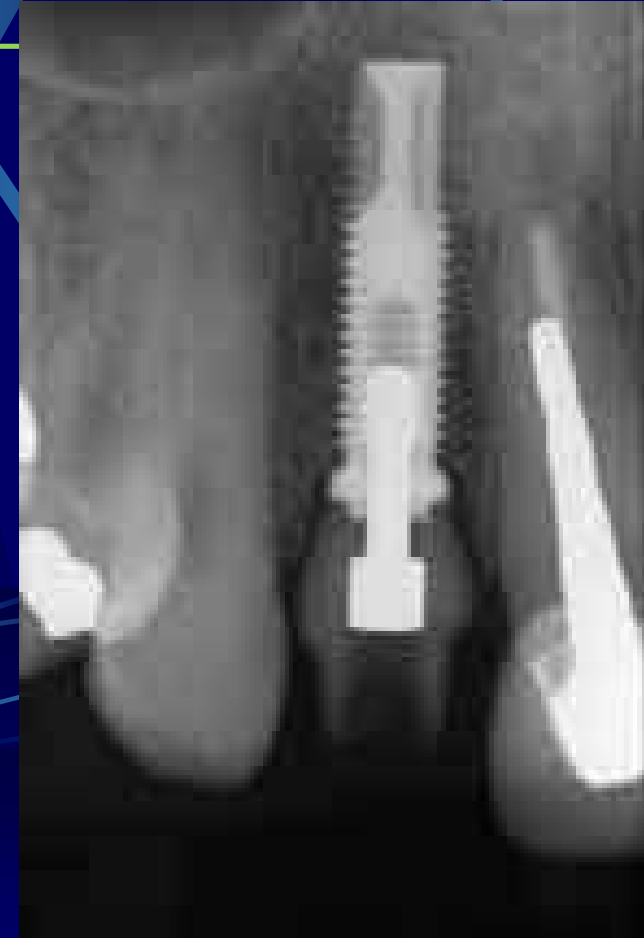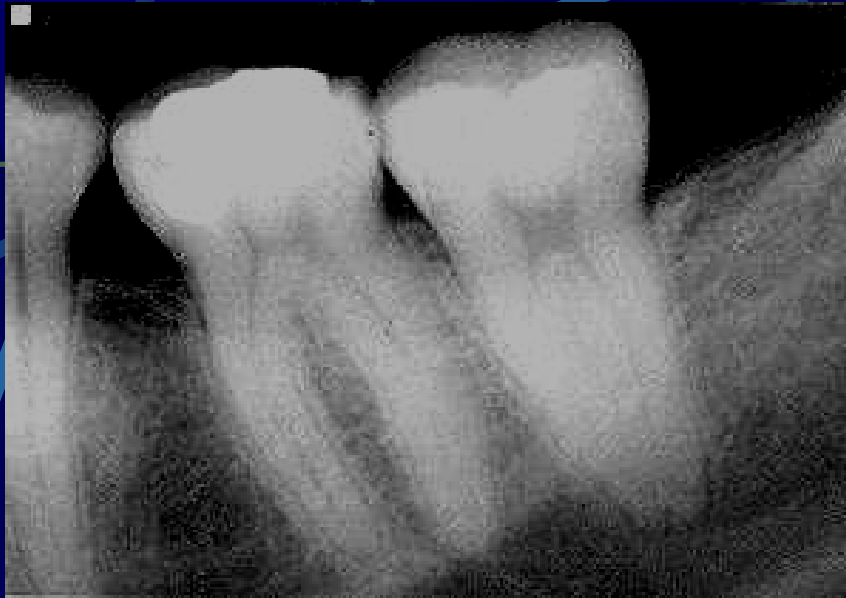Válek V. A.
Radiologická klinika LF, MOU Brno




Anatomie

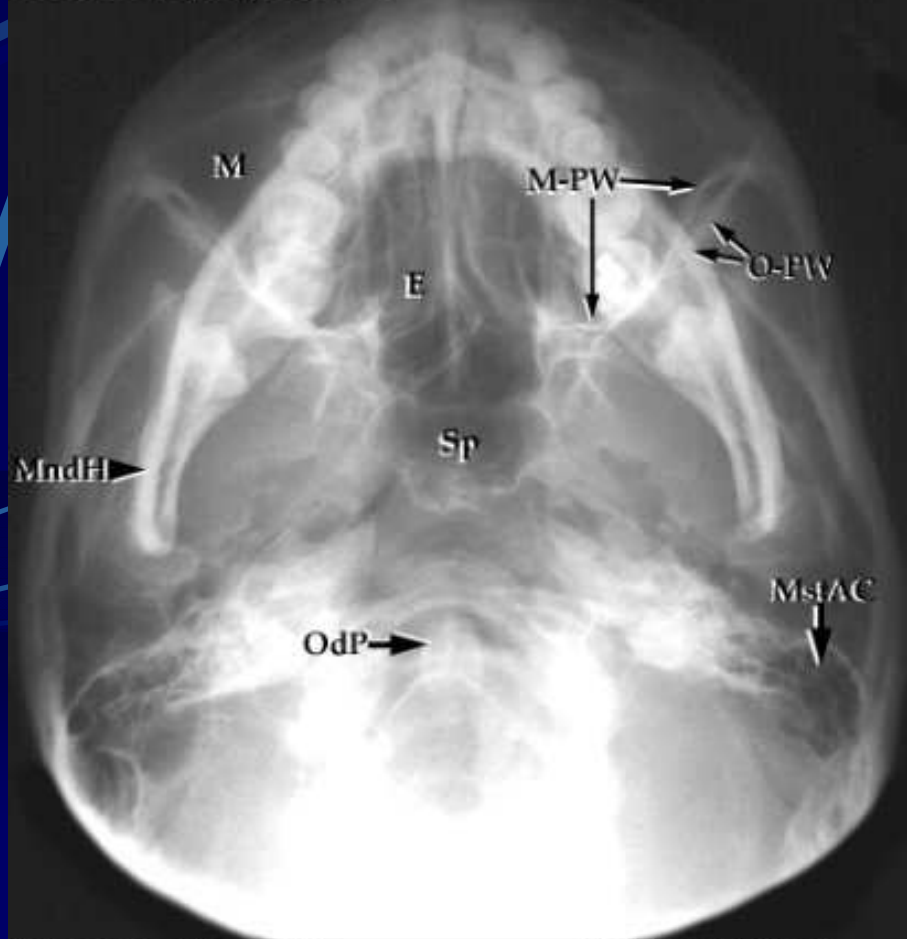


Anatomie

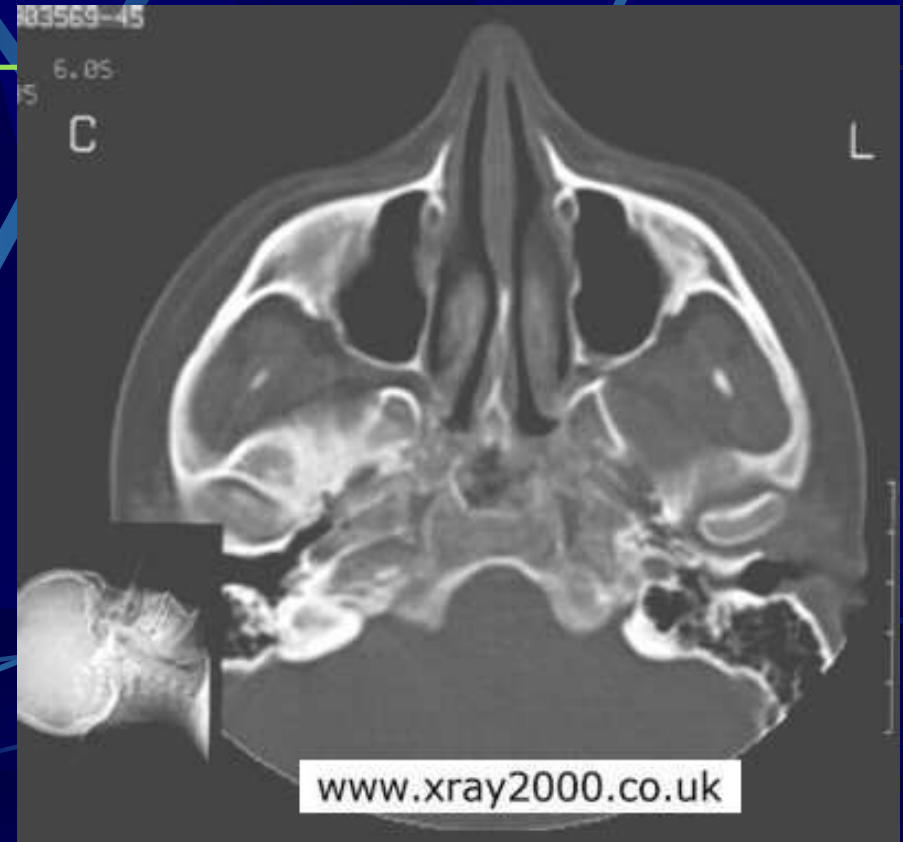



Base of the Skull

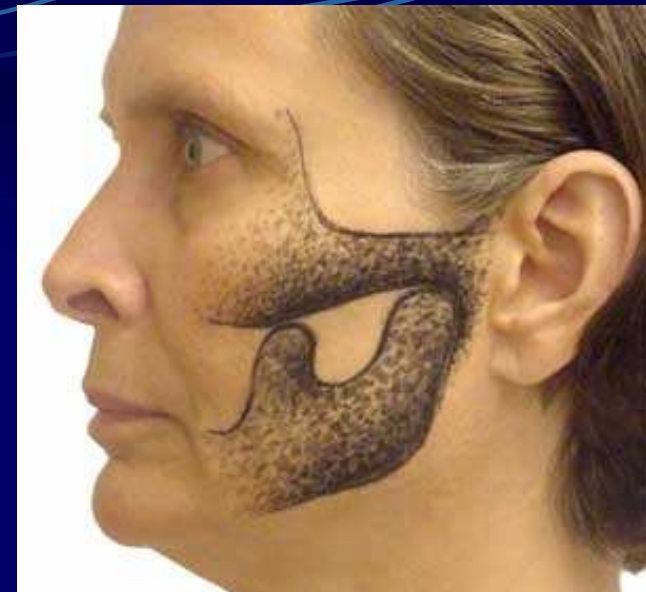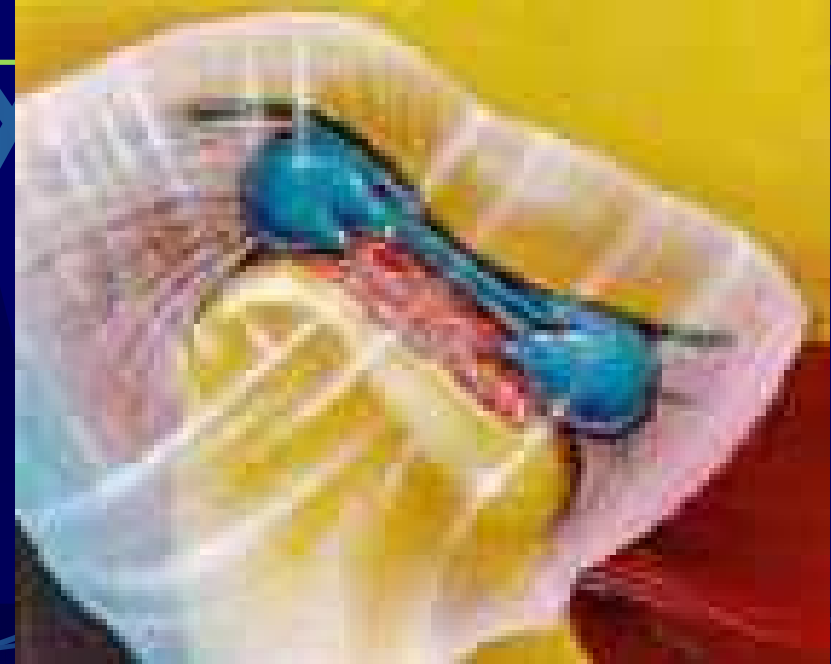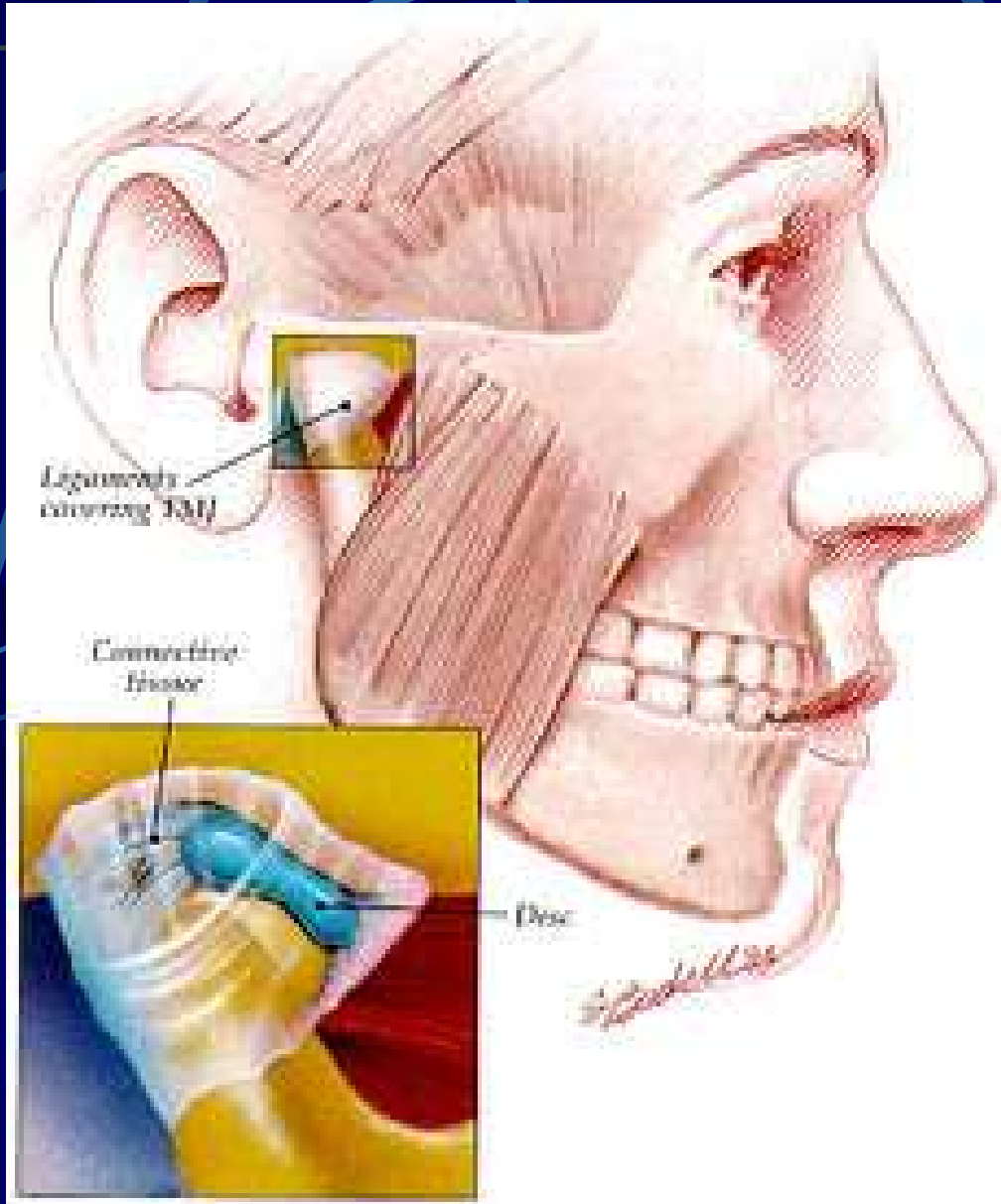


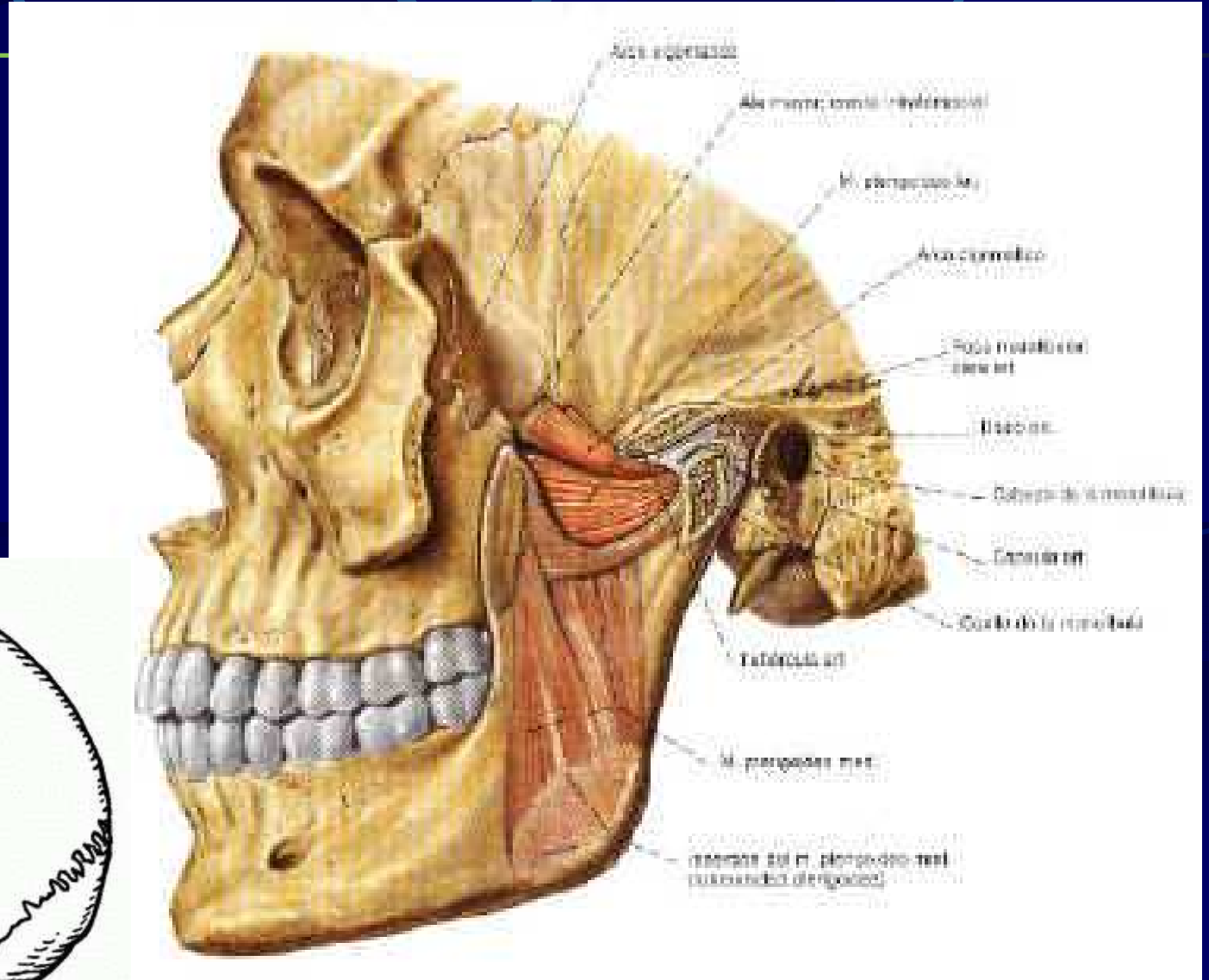
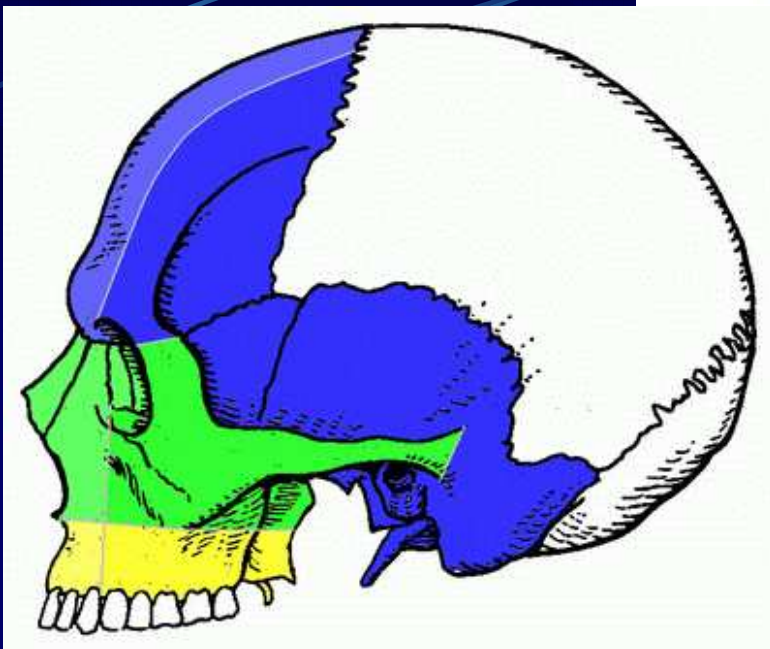

MstAC=Mastoid Air Cells	Sp=Sphenoid Sinus
E=Ethmoid Sinus (Air Cells)	M=Maxillary Sinus
O-PW=Posterior Wall of Orbit	MndH=Head of Mandible
M-PW=Posterior Wall of Maxillary Sinus	OdP=Odontoid Process





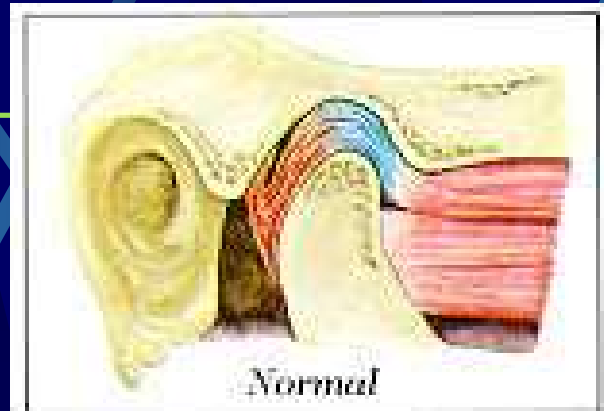

Anatomie



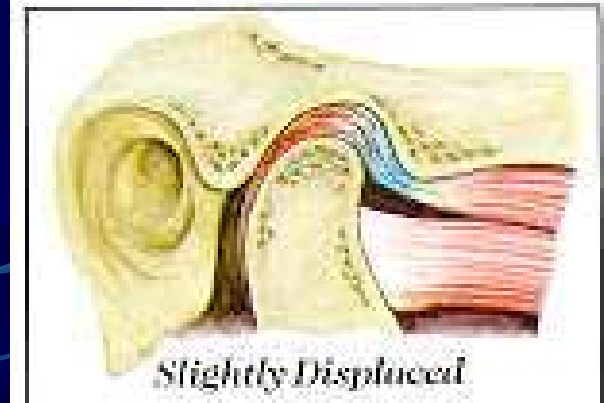




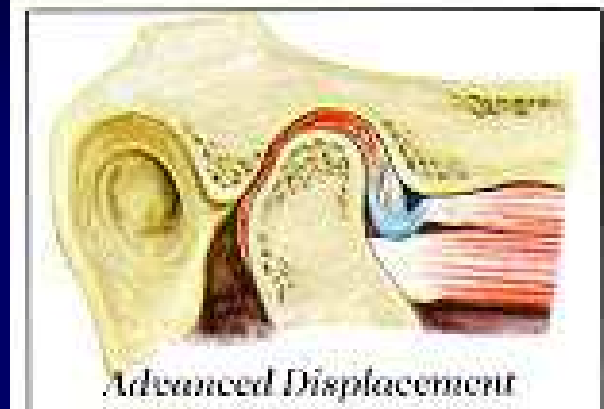
Anatomie



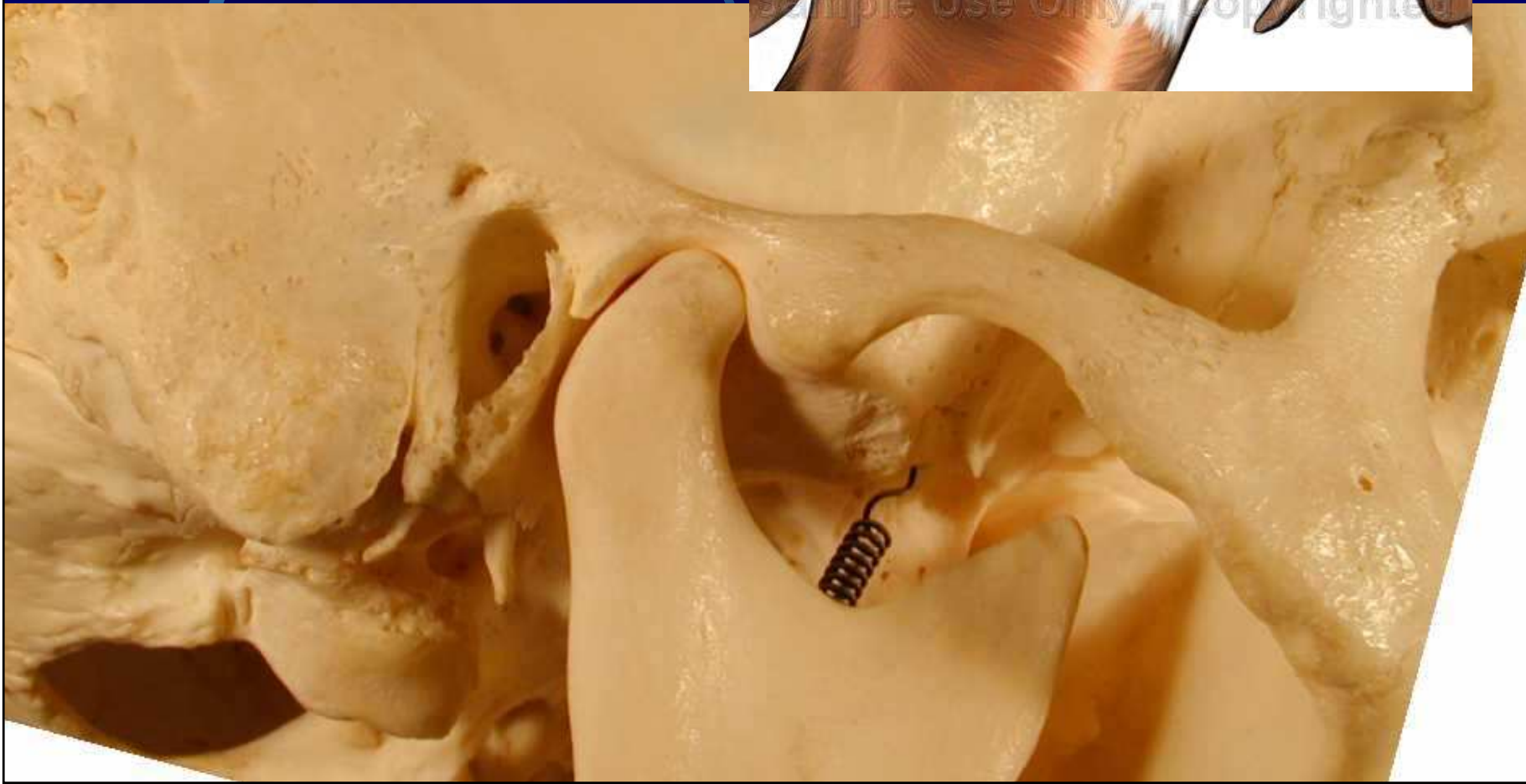
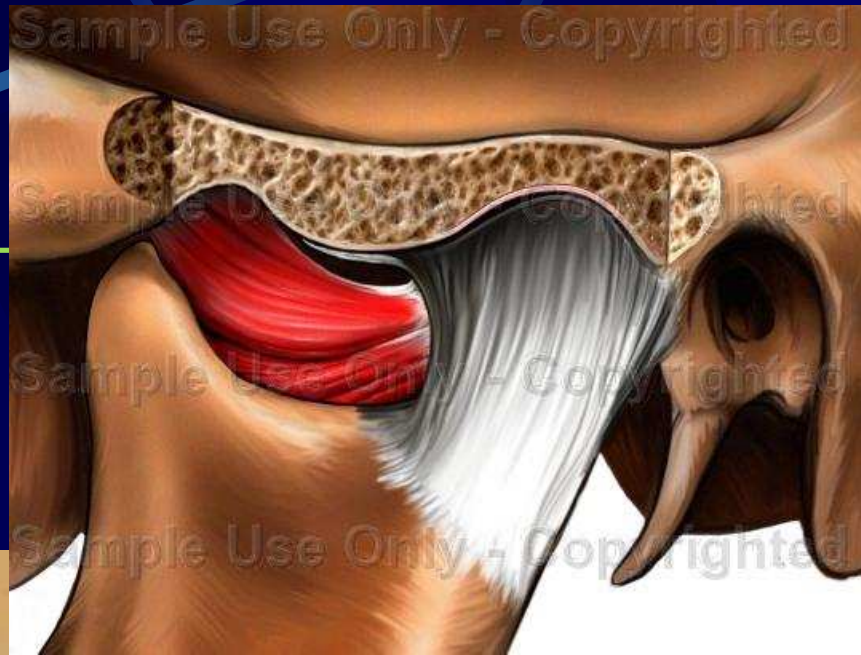
Normal



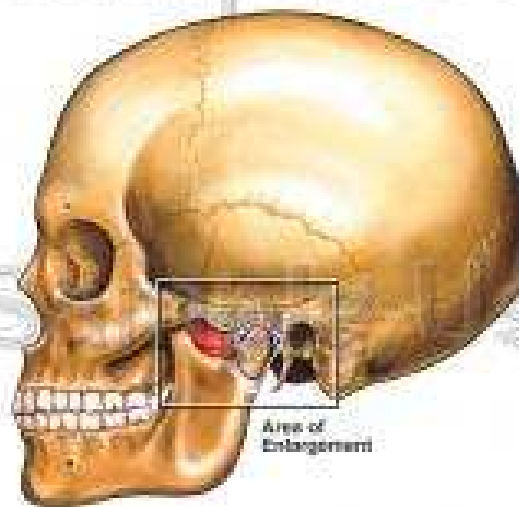
Slightly Displaced



Advanced Displacement



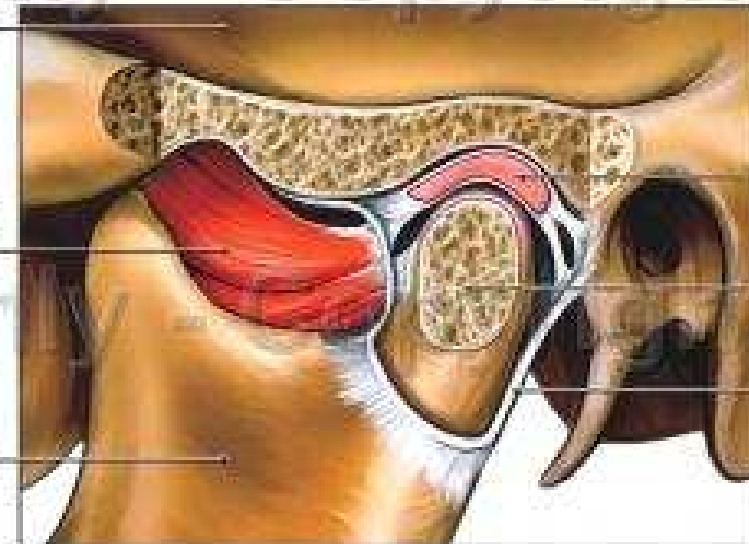
Anterior Displacement of the Left Temporomandibular Joint (TMJ)



Temporal bone

Pterygoid muscle

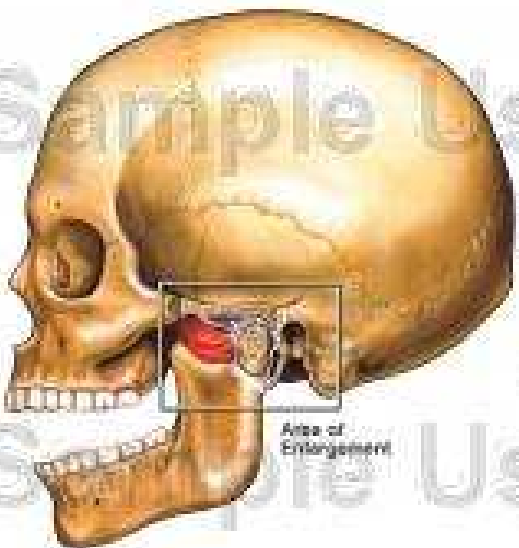
Mandible



Meniscus

Condyle

Joint capsule

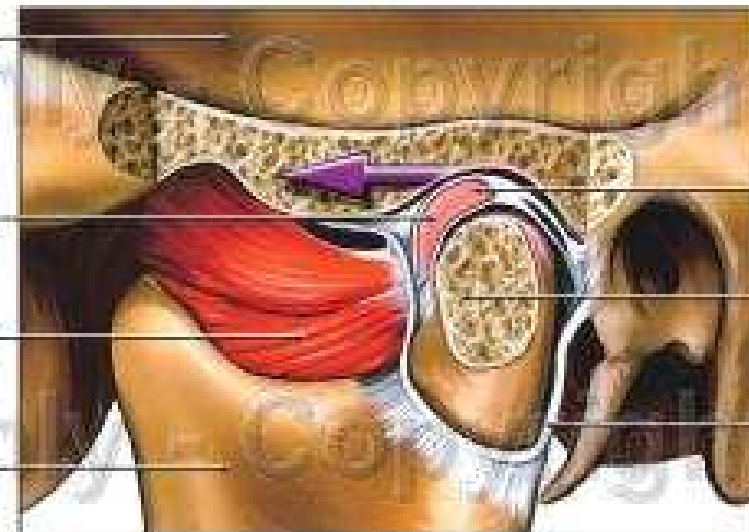


Temporal bone

Anterior displacement of TMJ meniscus

Pterygoid muscle

Mandible




Meniscus

Condyle

Joint capsule

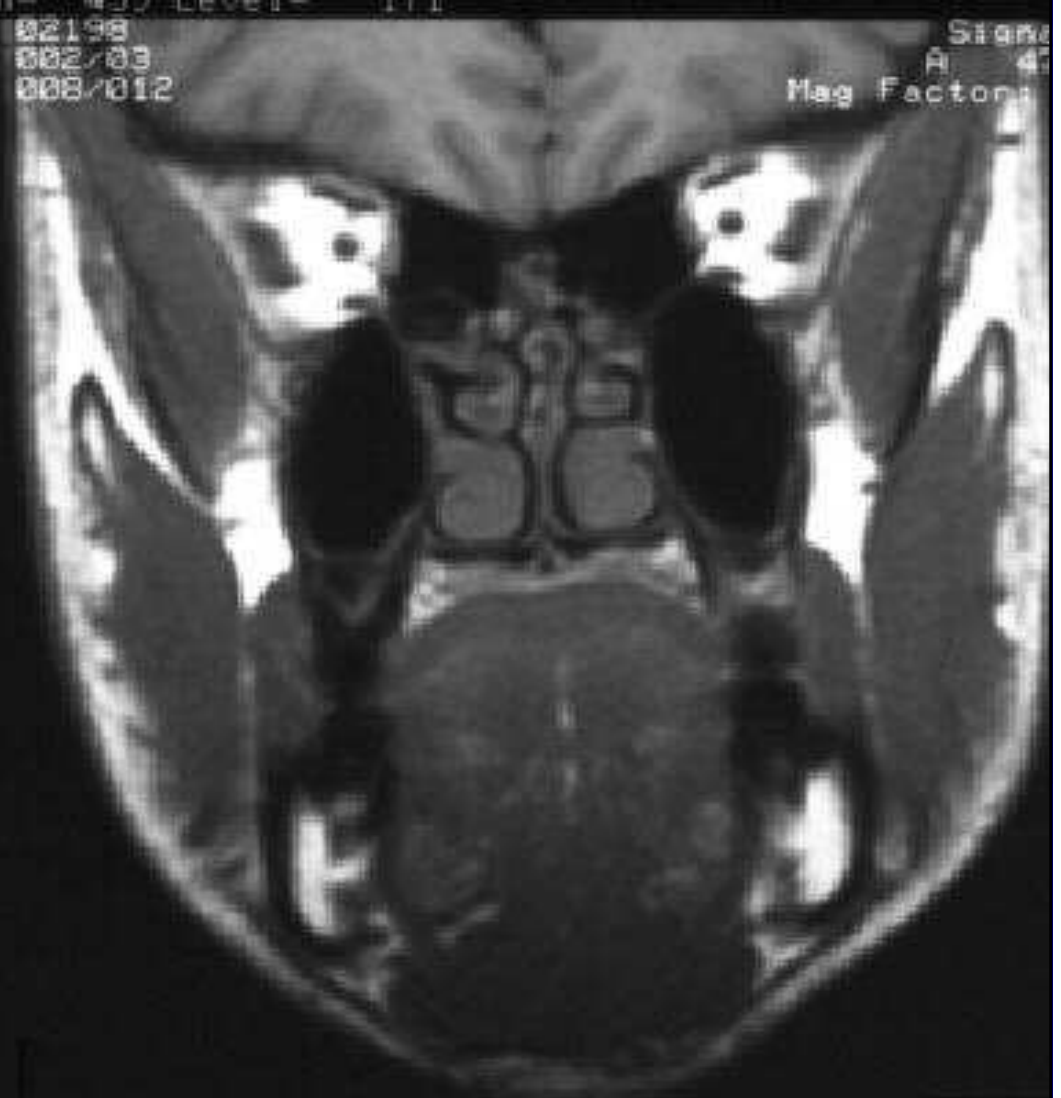
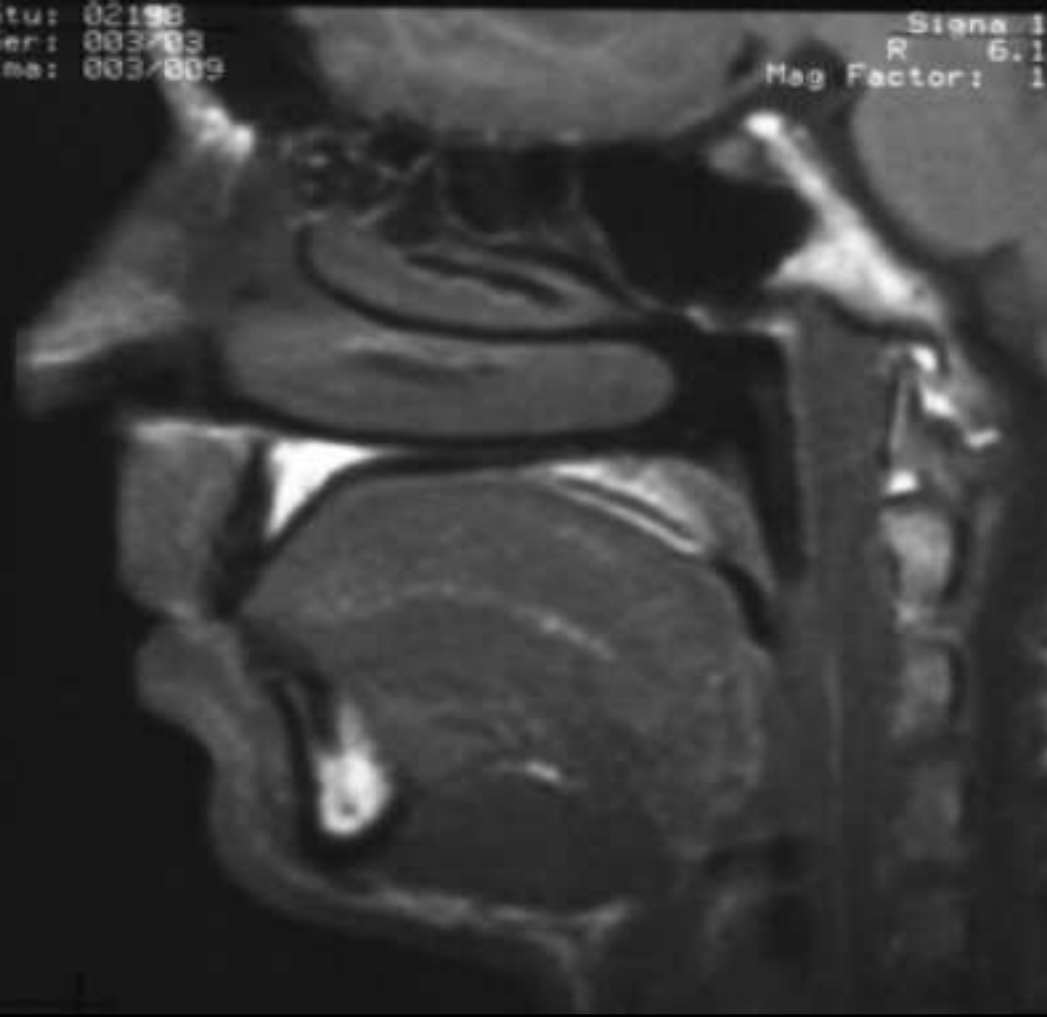
Anatomie



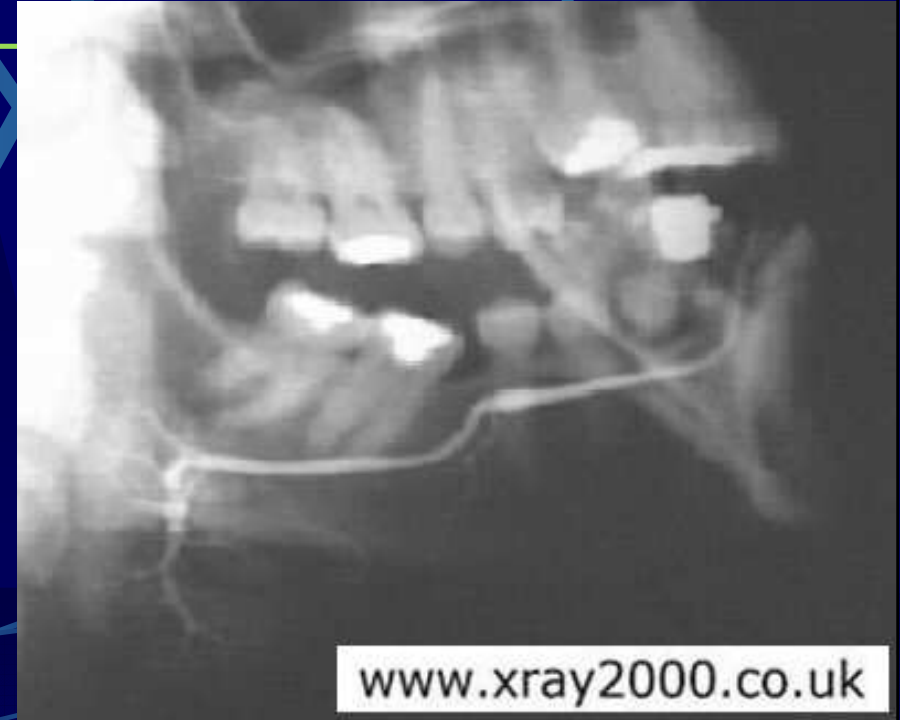
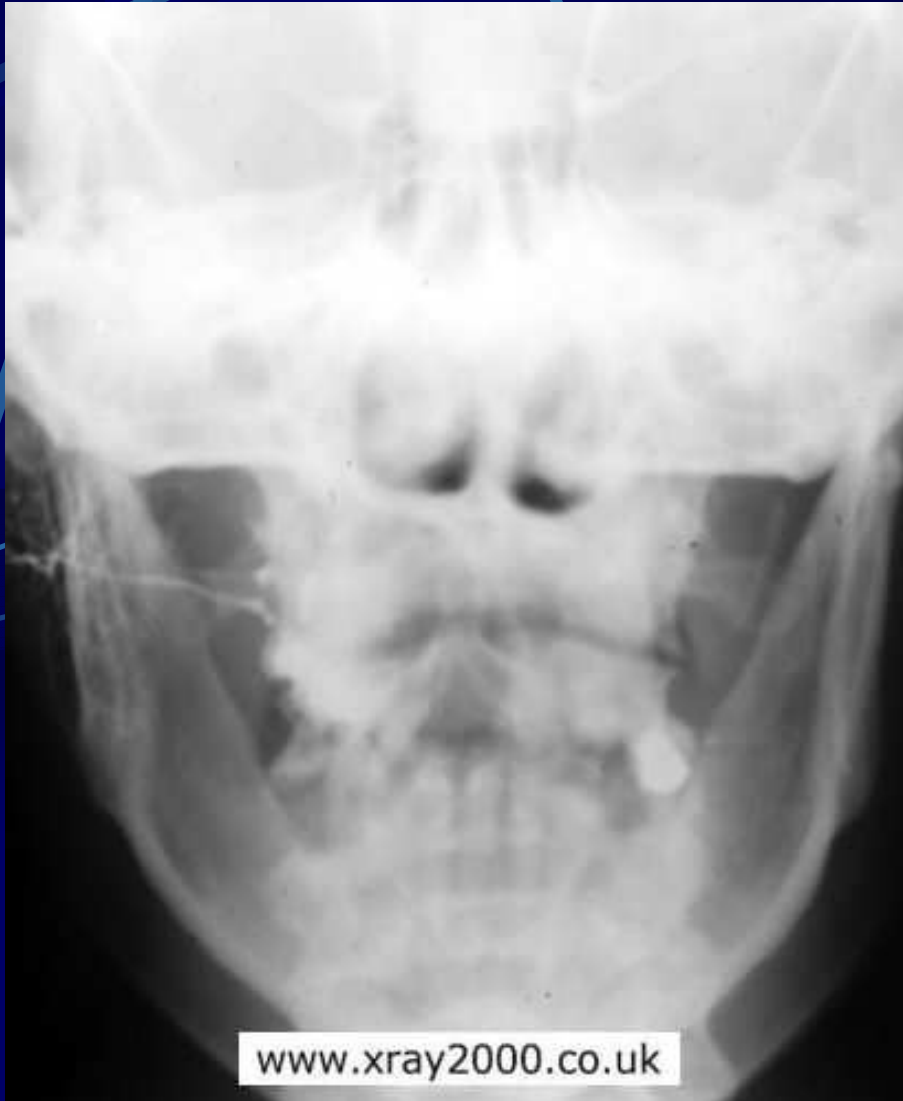tu: 02198
er: 003/03
na: 003/009

Signa: 1
R: 6.1
Mag Factor: 1






Anatomie

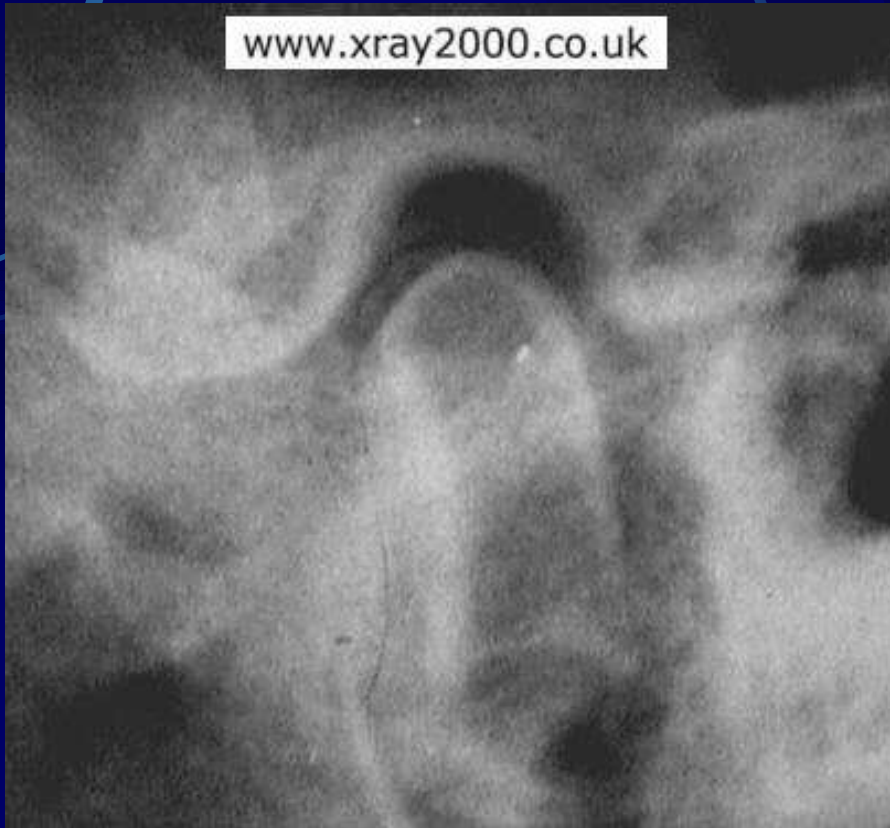



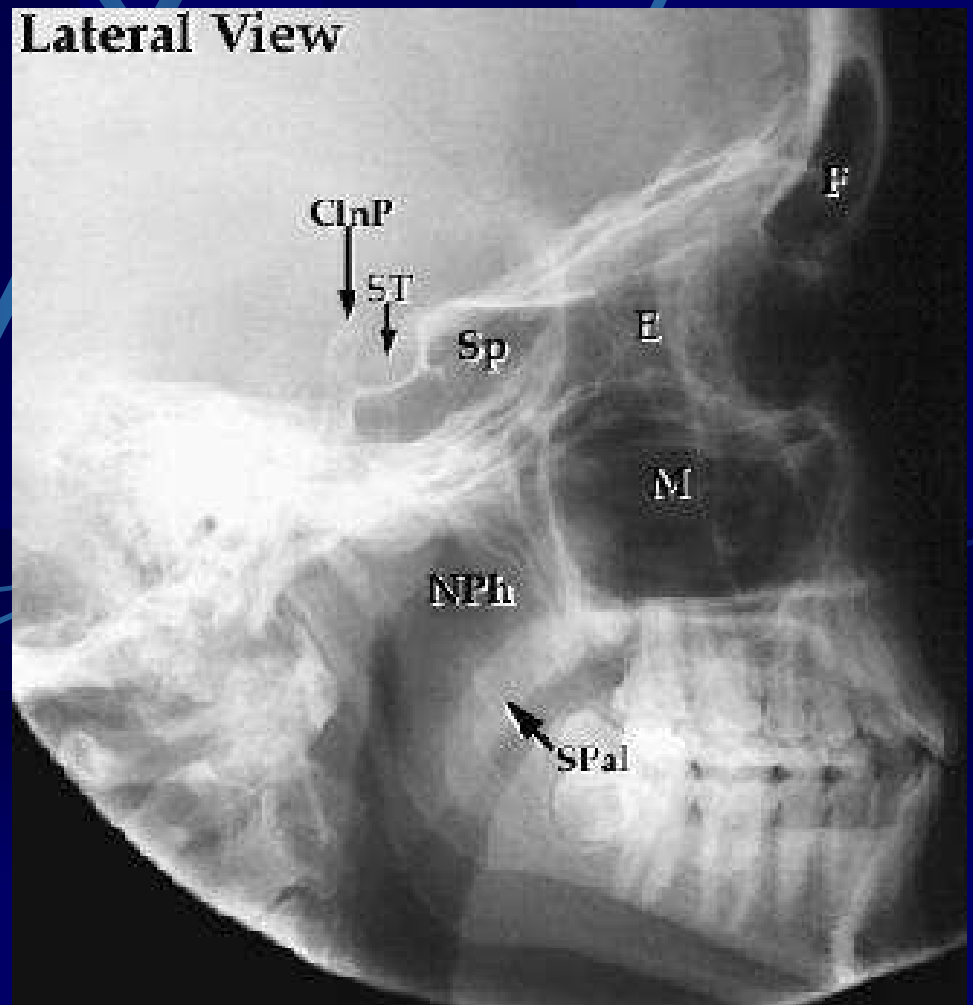
Anatomie



www.xray2000.co.uk



Lateral View



F=Frontal Sinus
E=Ethmoid Sinus
Sp=Sphenoid Sinus
M=Maxillary Sinus

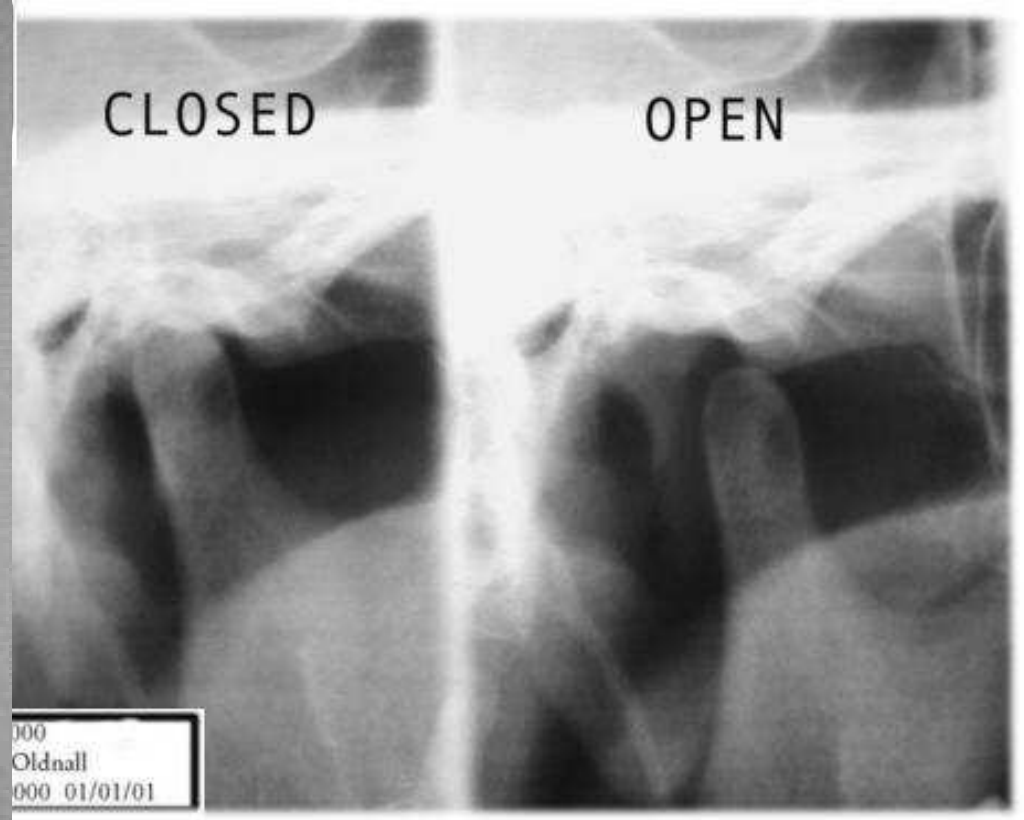
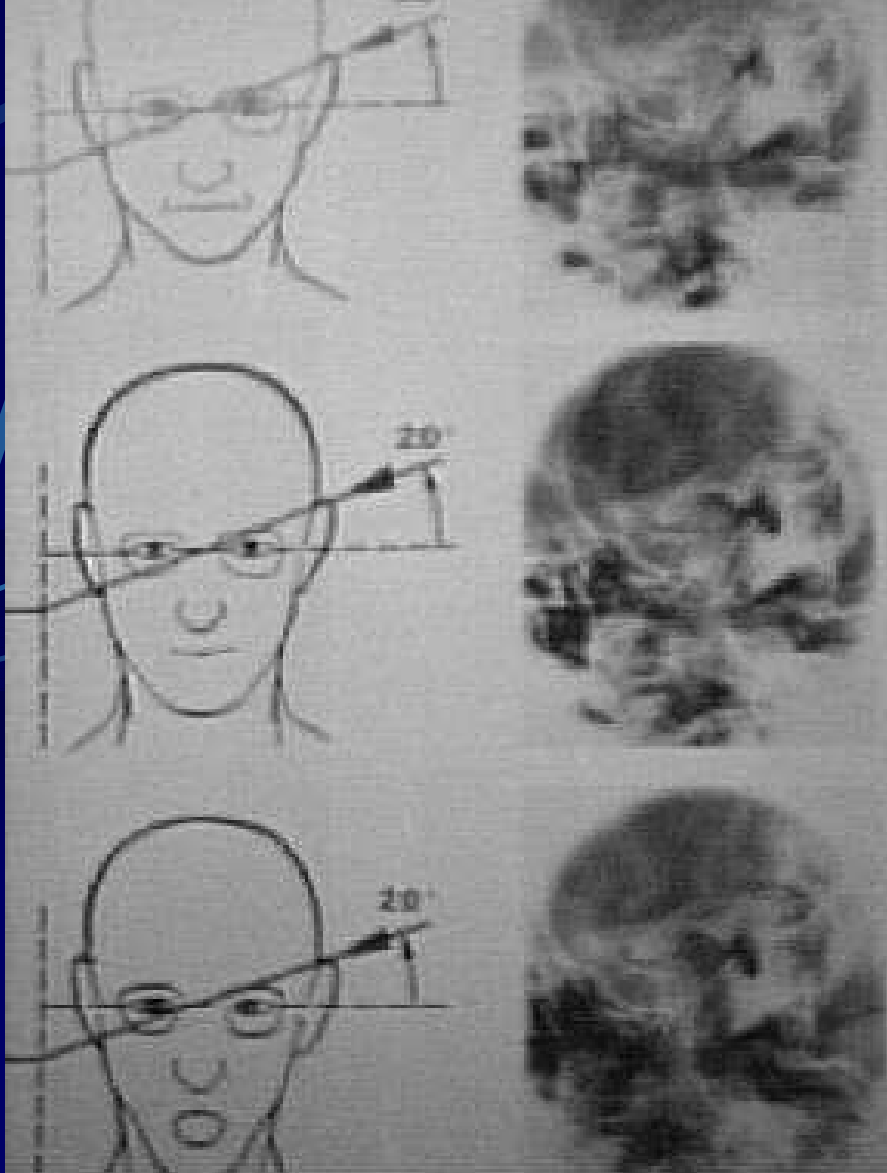
ST=Sella Turcica (Pituitary Fossa)
ClnP=Posterior Clinoid
NPh=Nasopharynx
SPal=Soft Palate



Anatomie

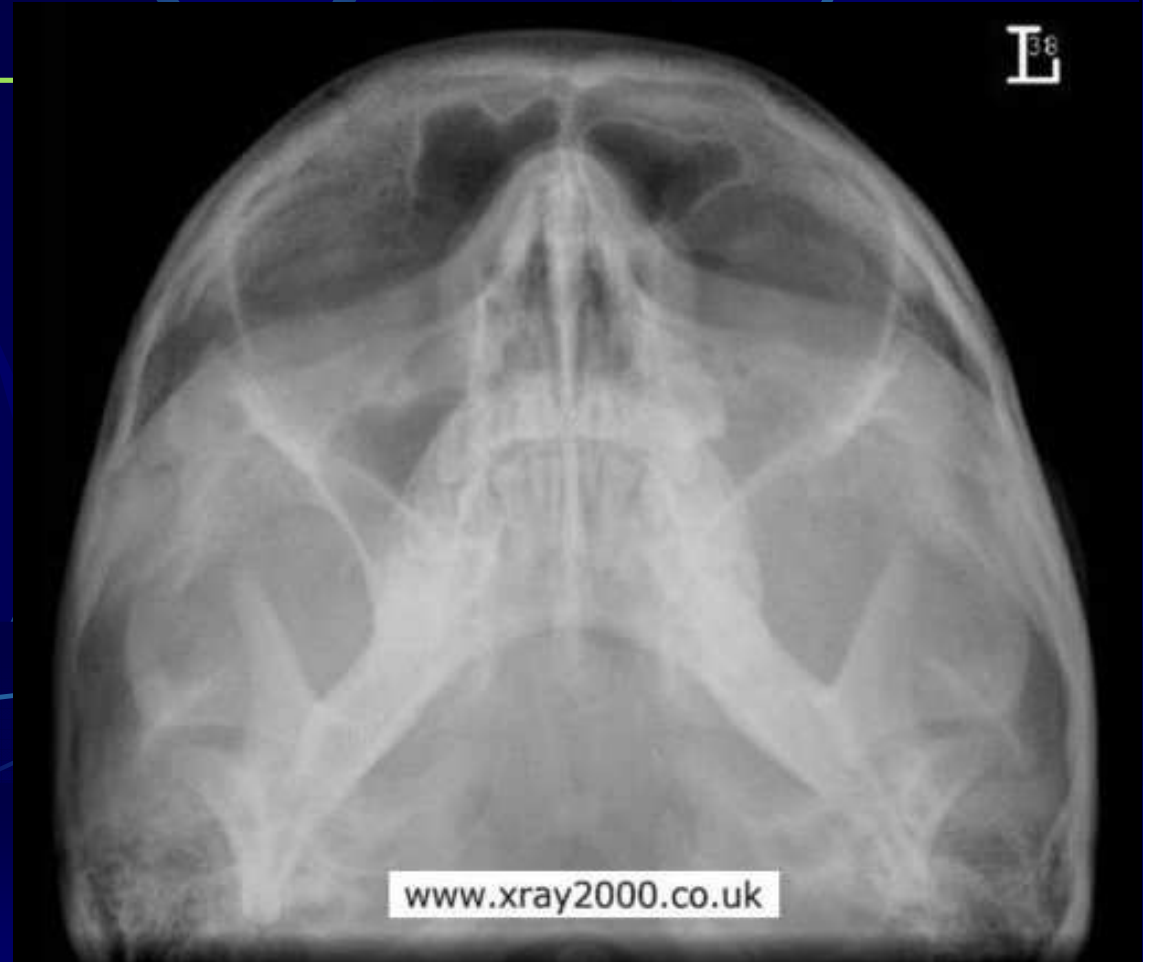

Anders Movin Karlison



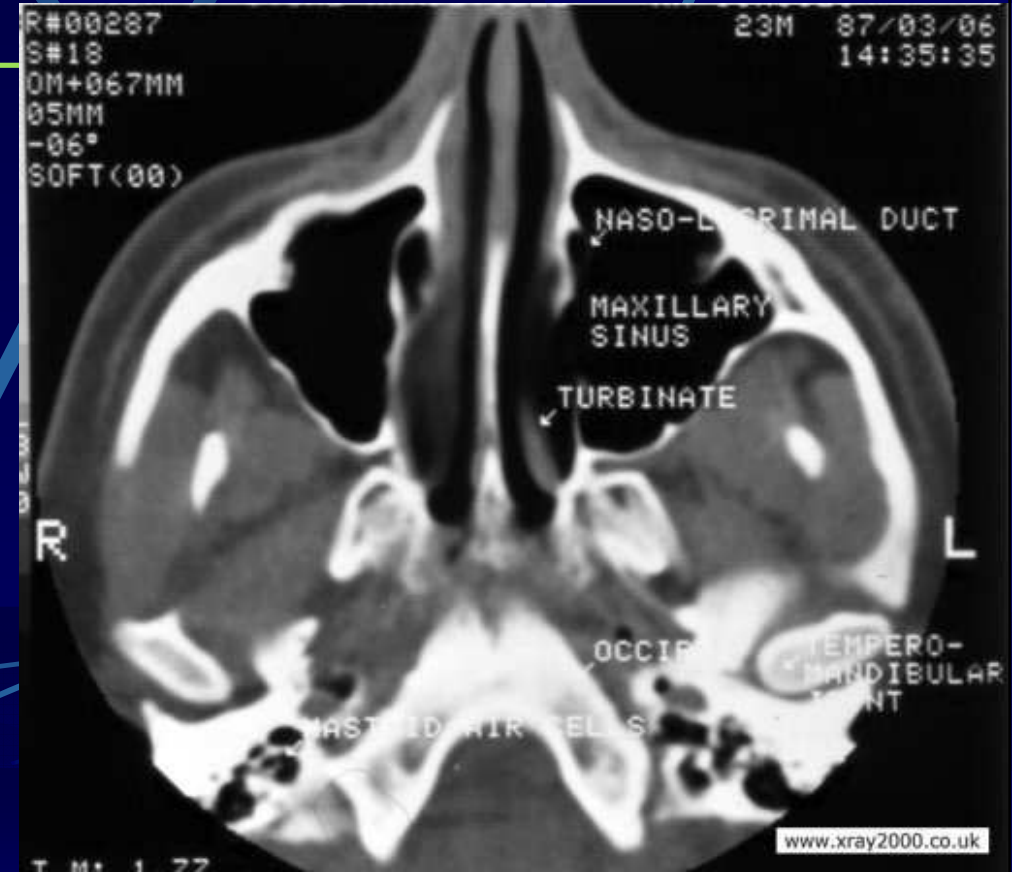
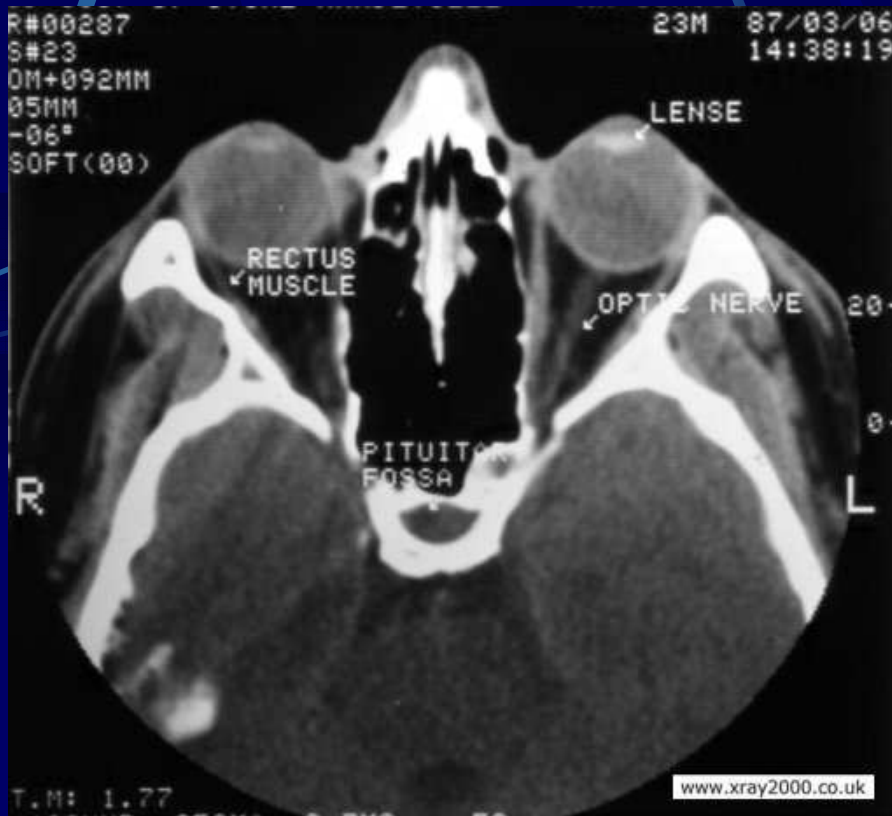

Anatomie





Anatomie

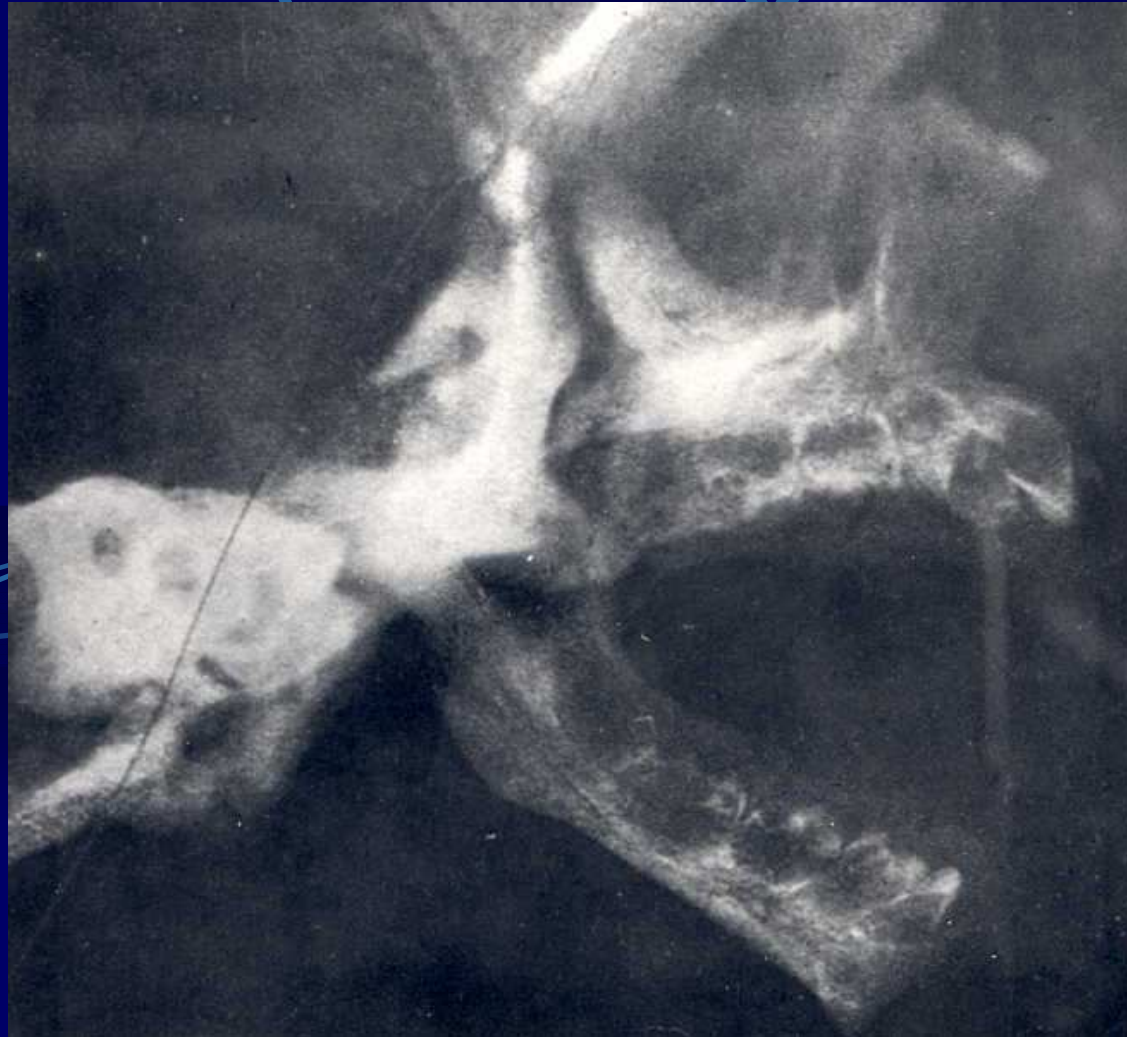




Vývoj zubu

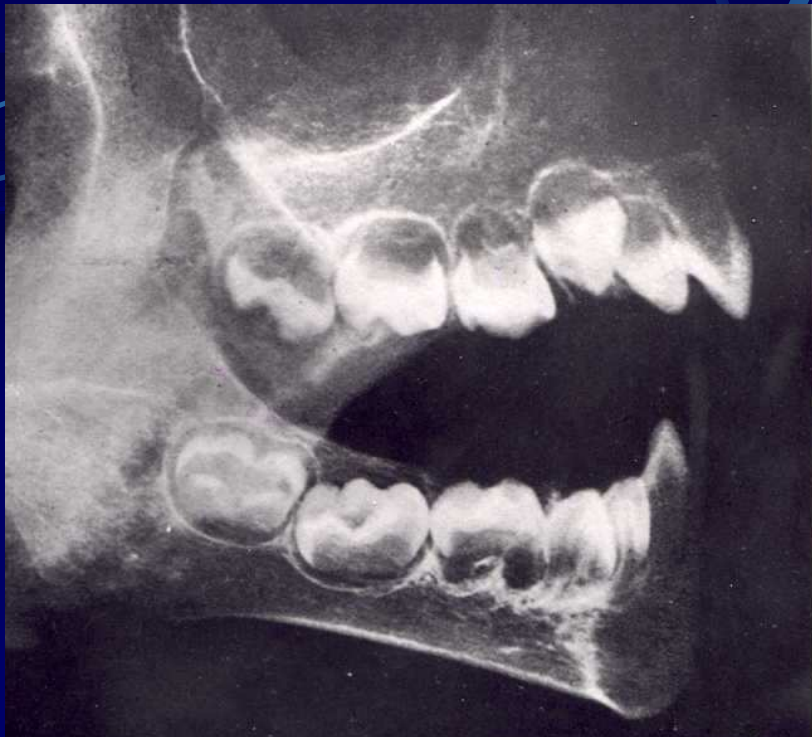
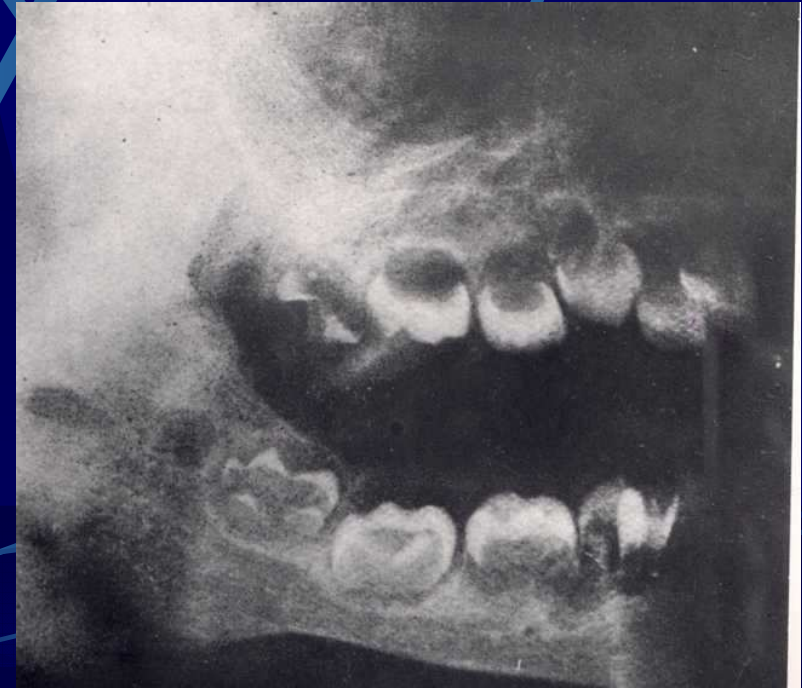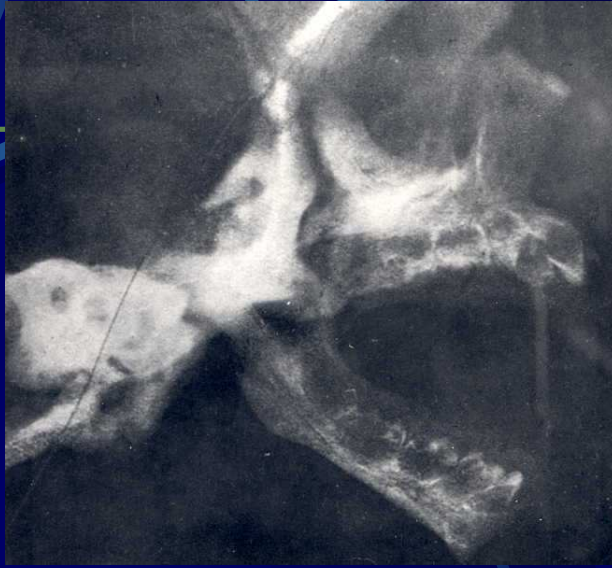



Zuby – vývoj - novorozenec



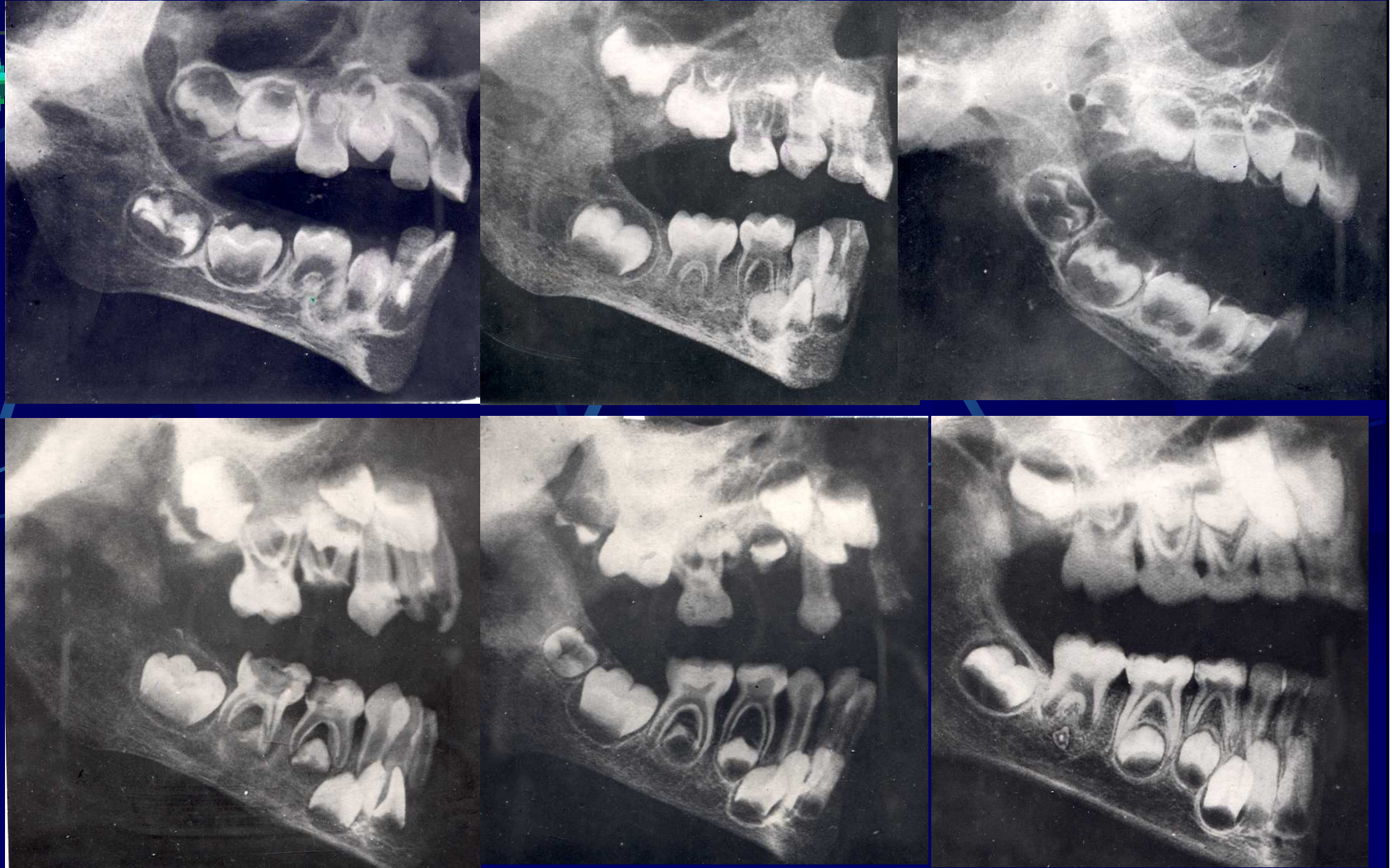

Zuby – vývoj – 6 a 9 měsíc



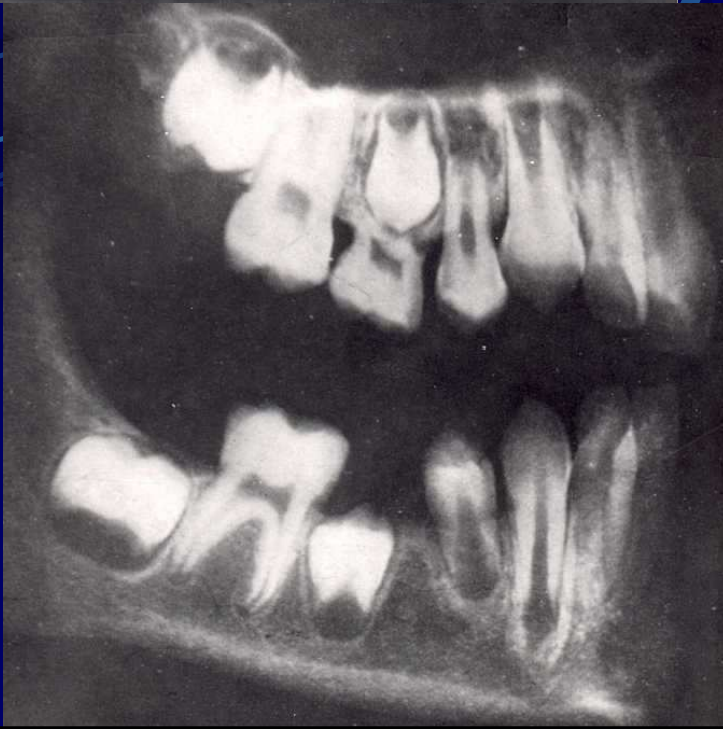
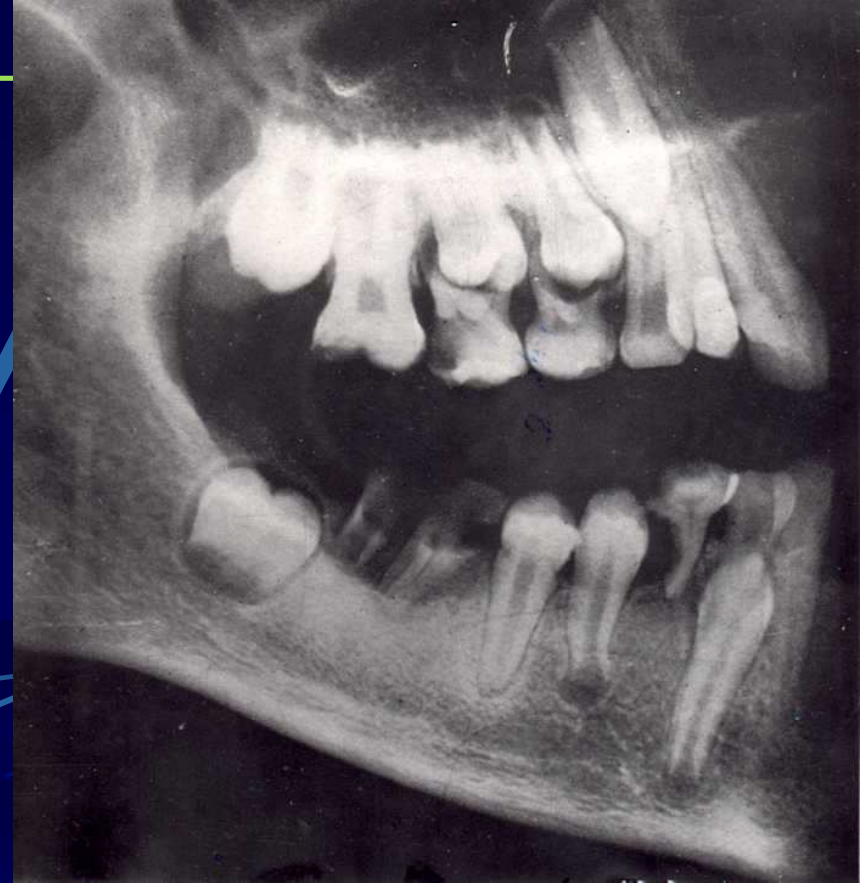
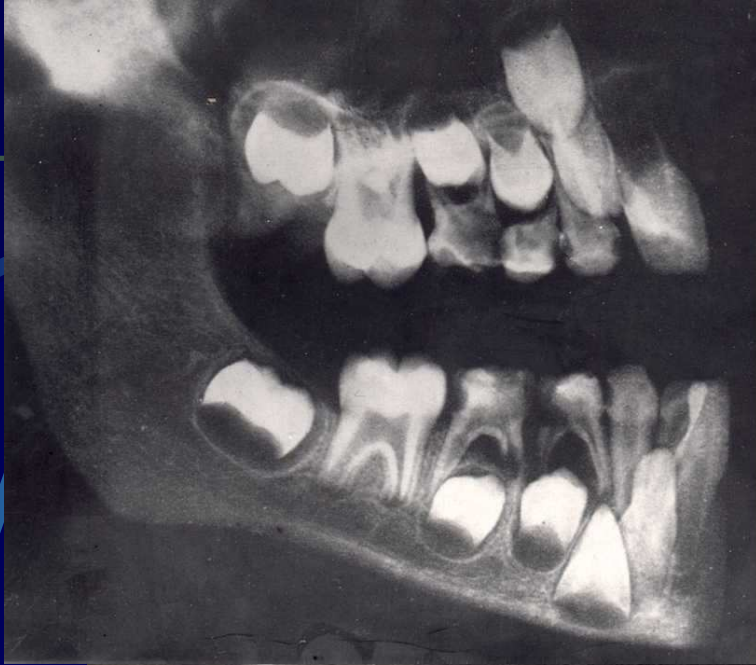


Zuby – vývoj – 1 – 6 rok





Zuby – vývoj – 7-10 let

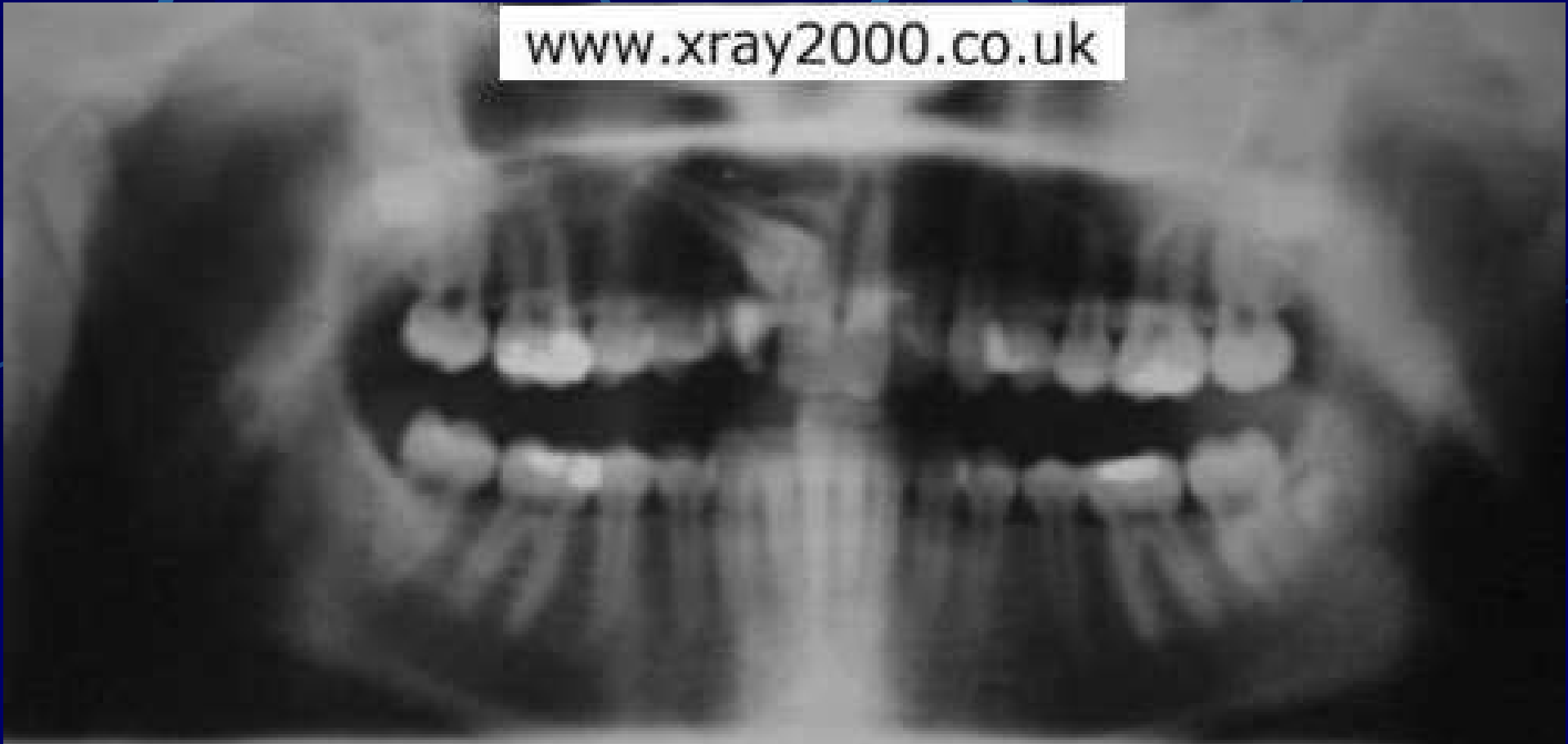



Zuby – vývoj – ektopický zub



www.xray2000.co.uk

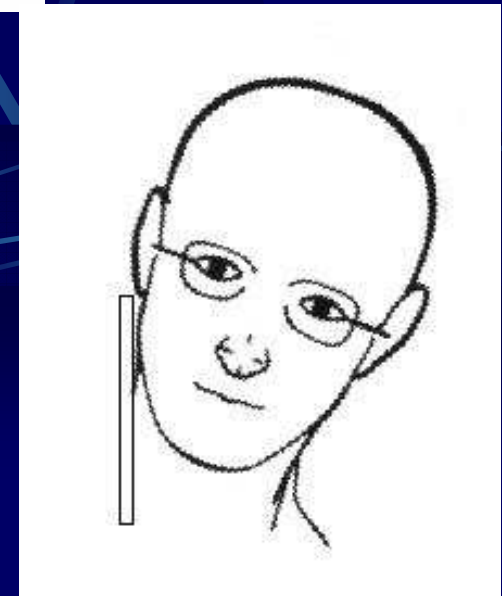
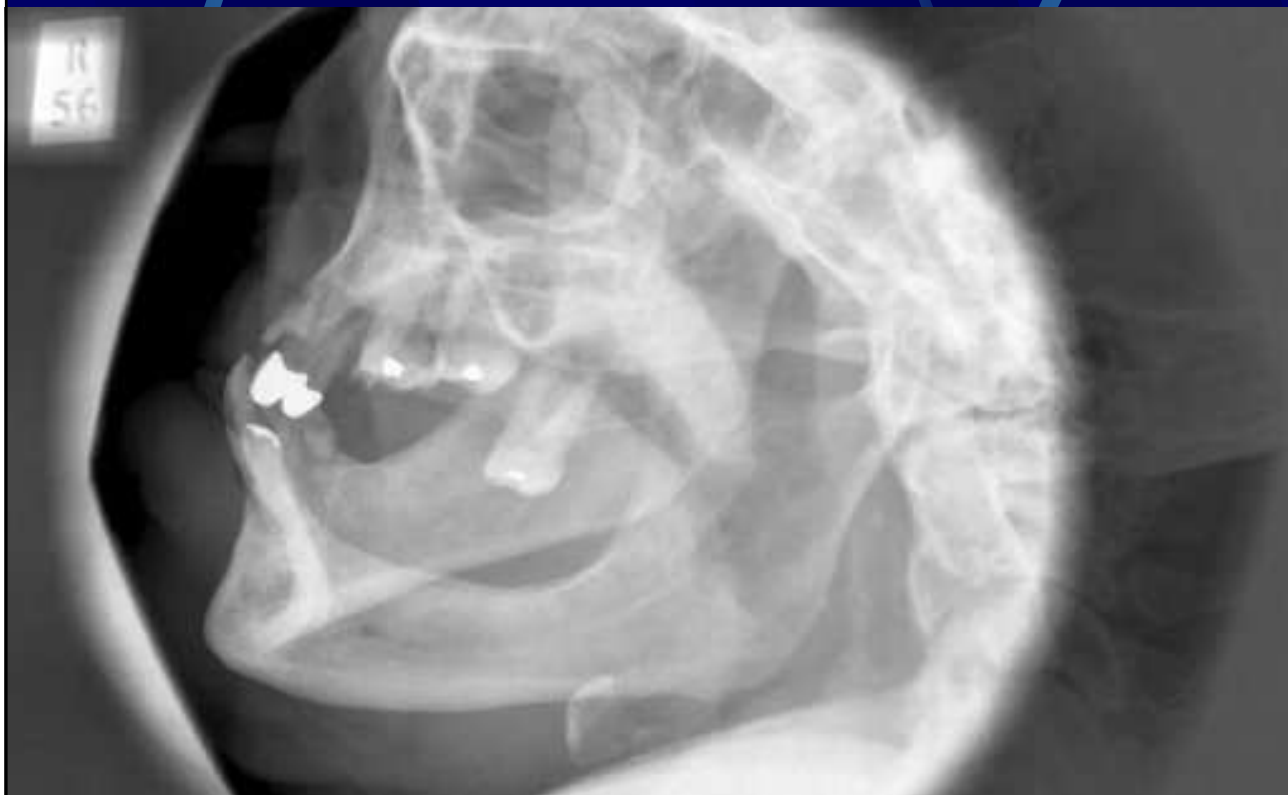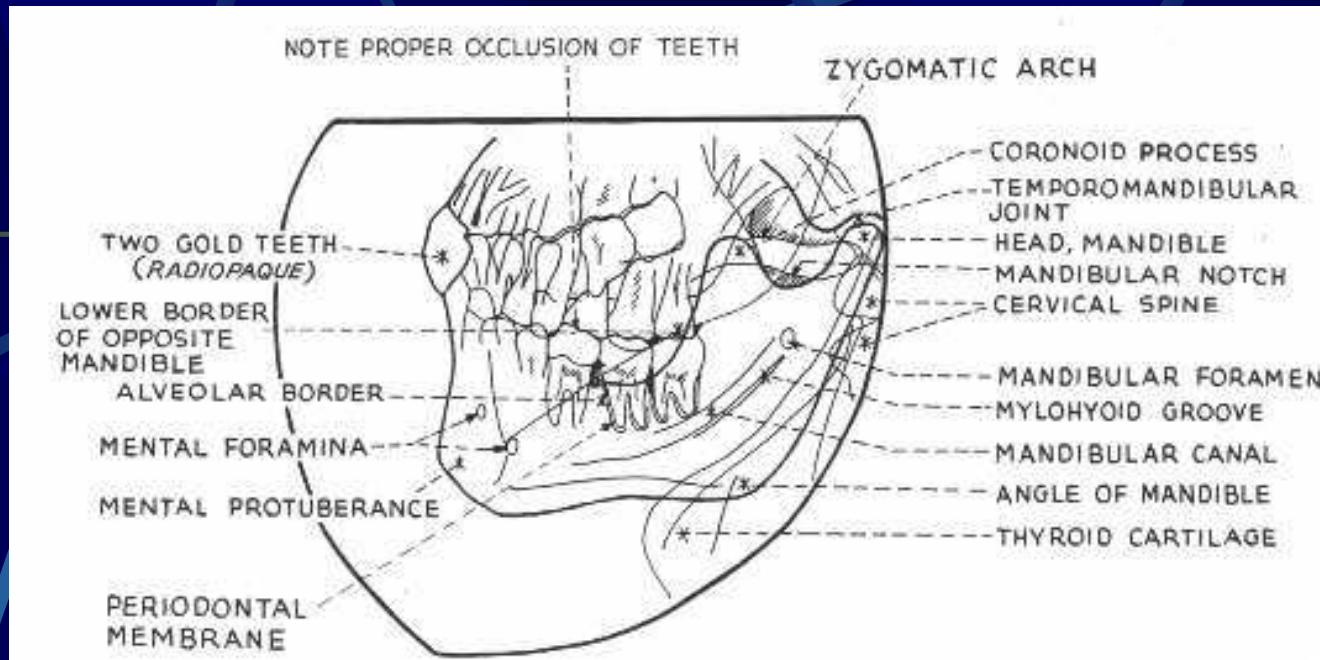




Projekce

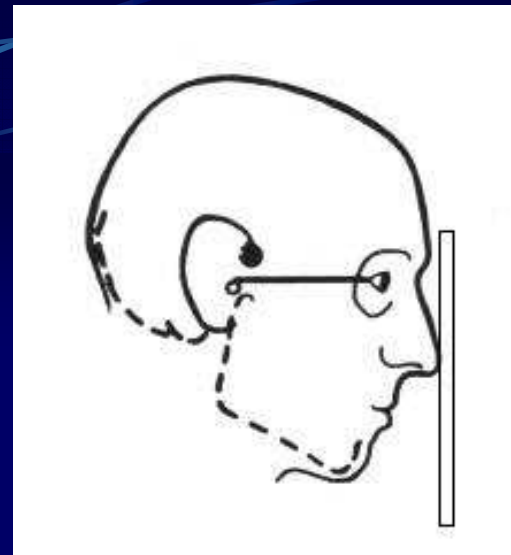
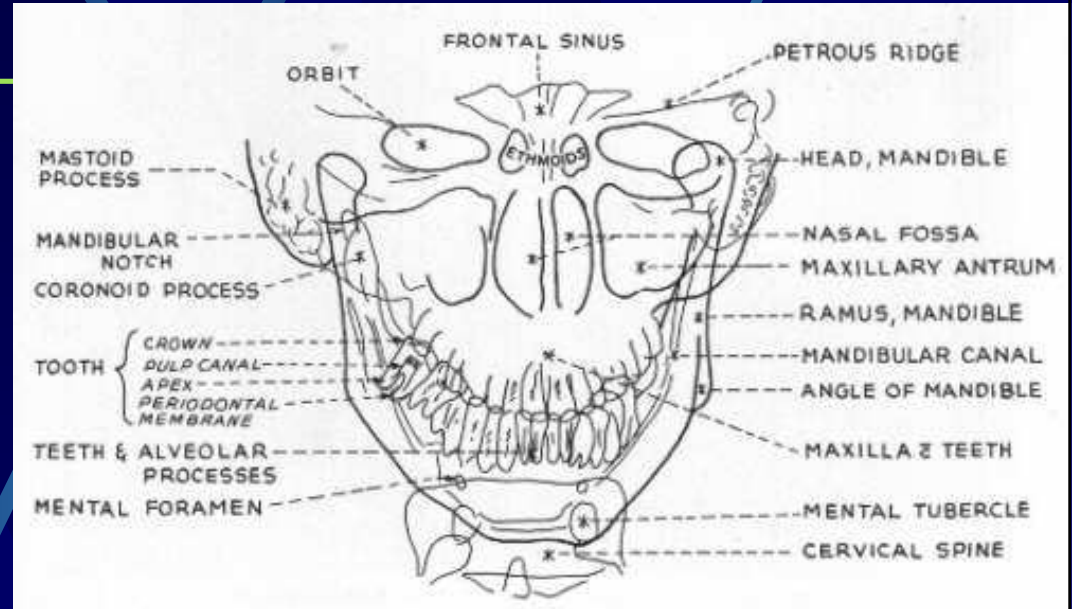
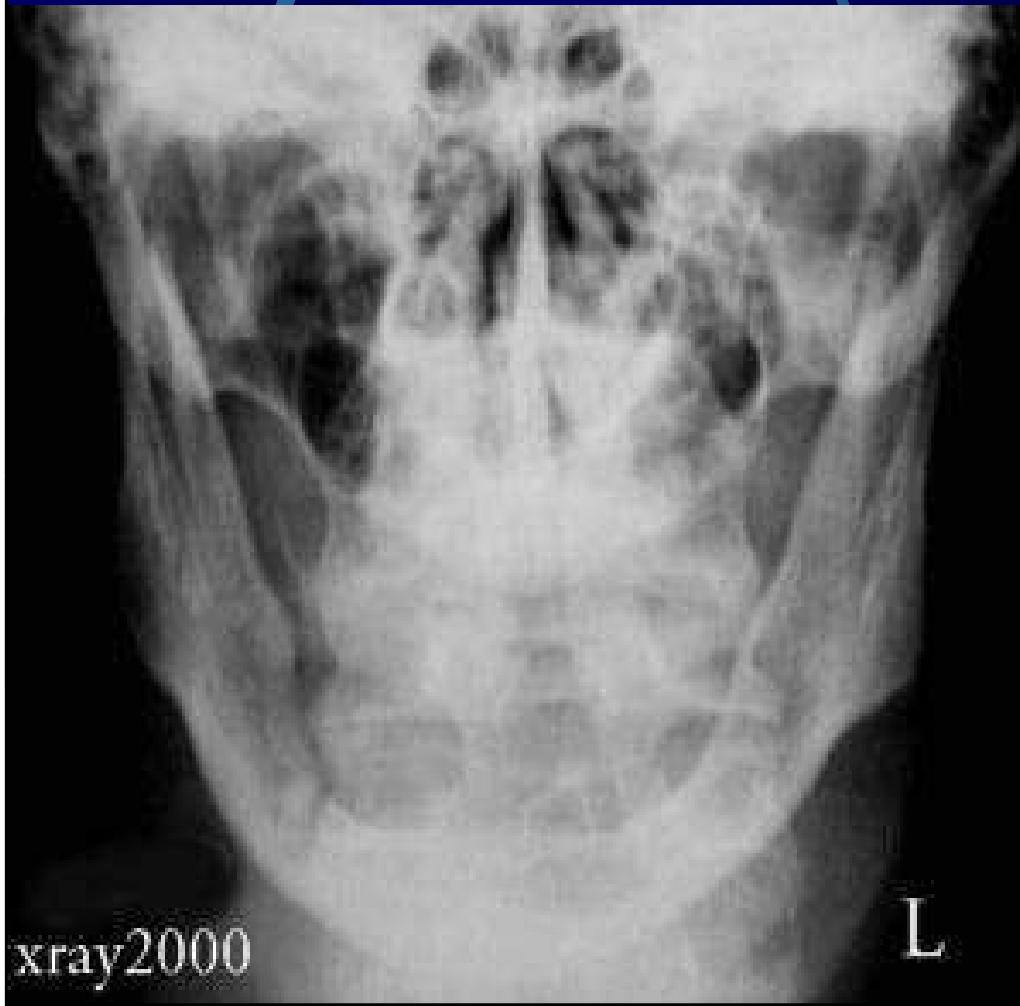



Šikmá projekce mandibula – faciomaxilární



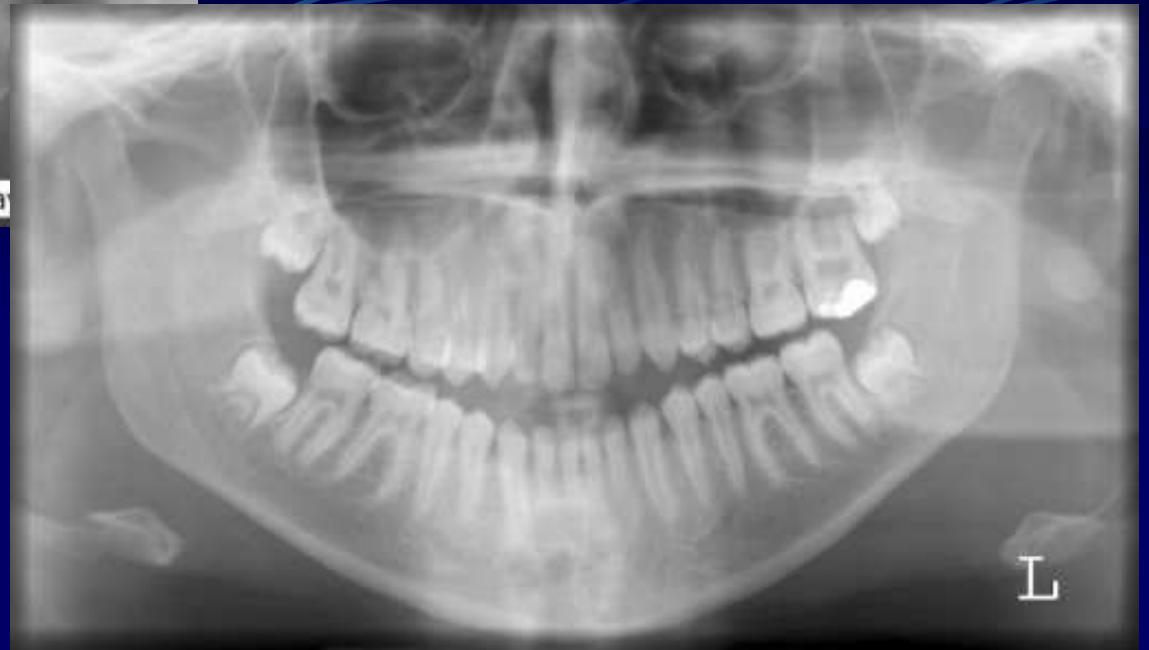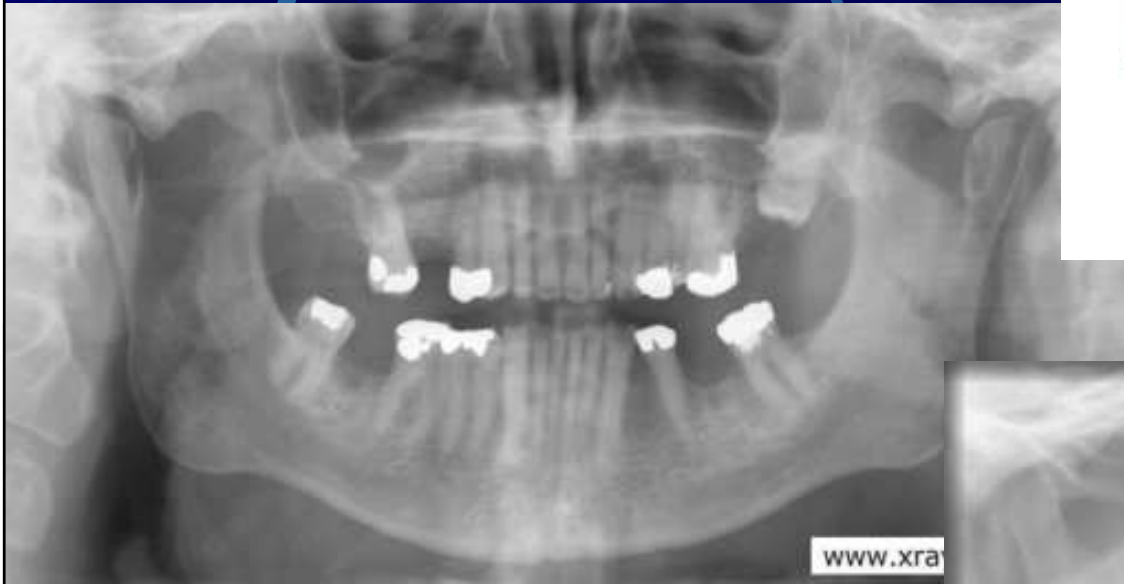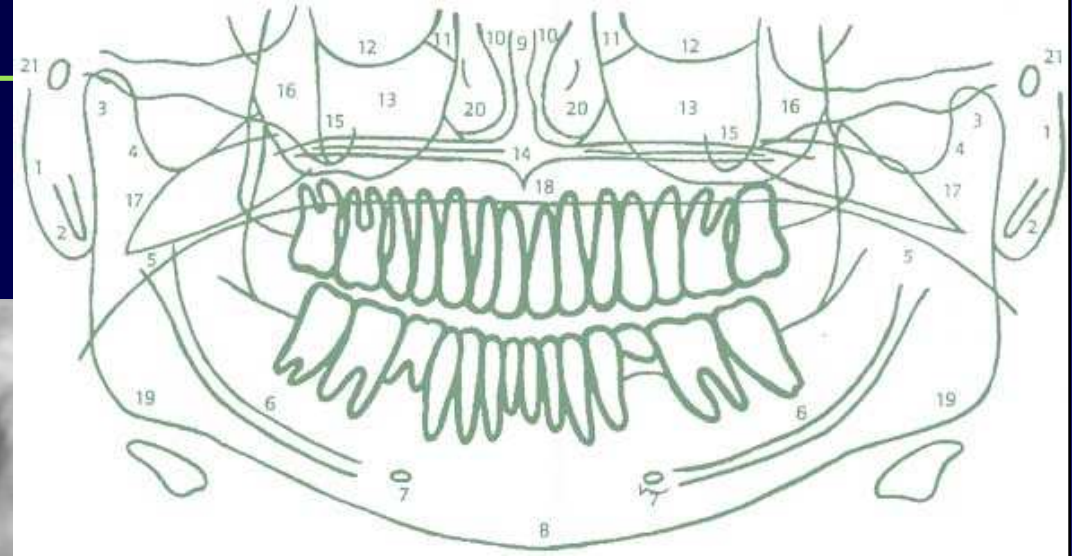



Mandibula PA



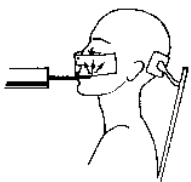
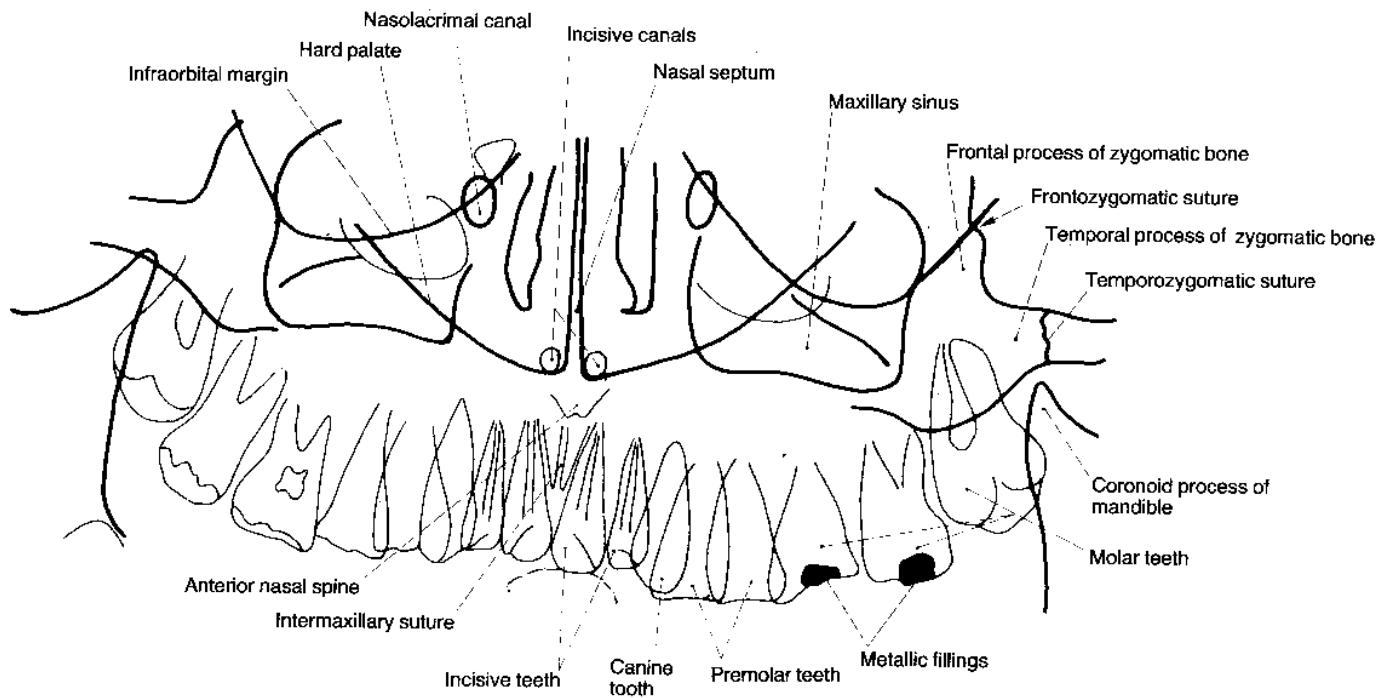
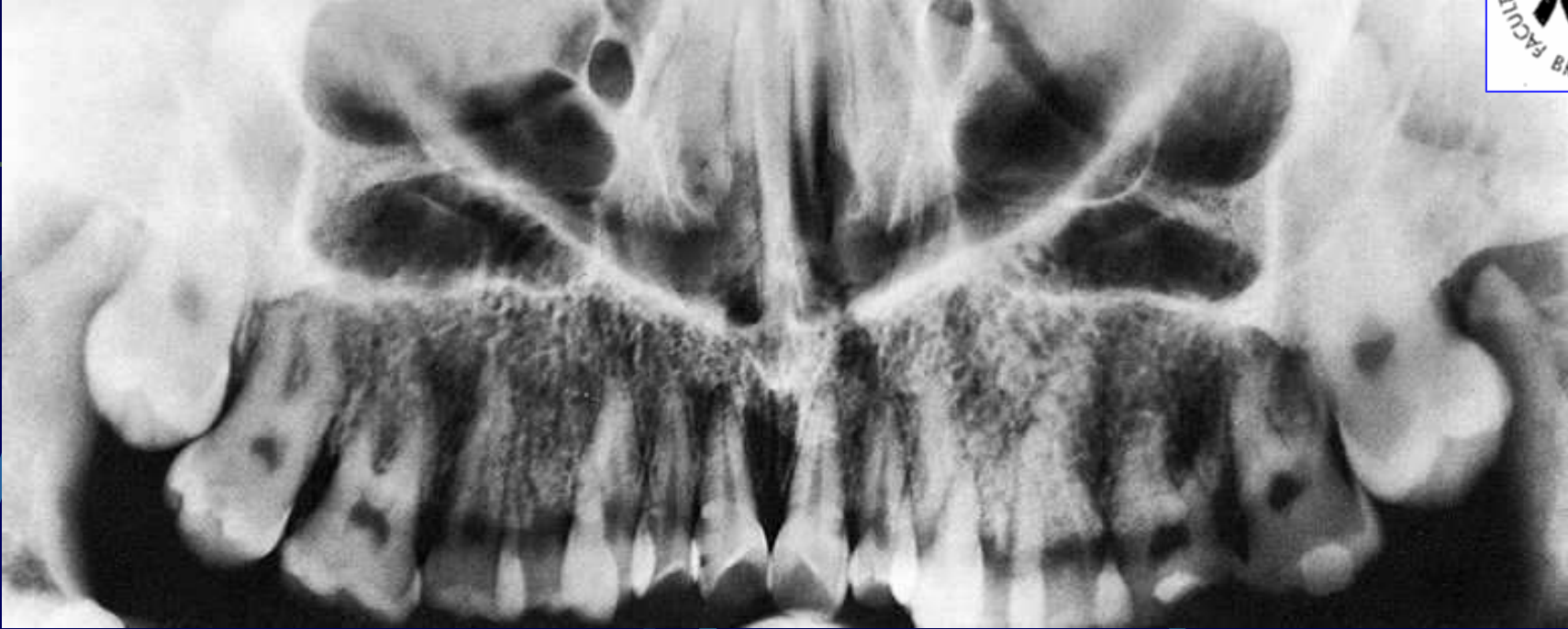


Projekce



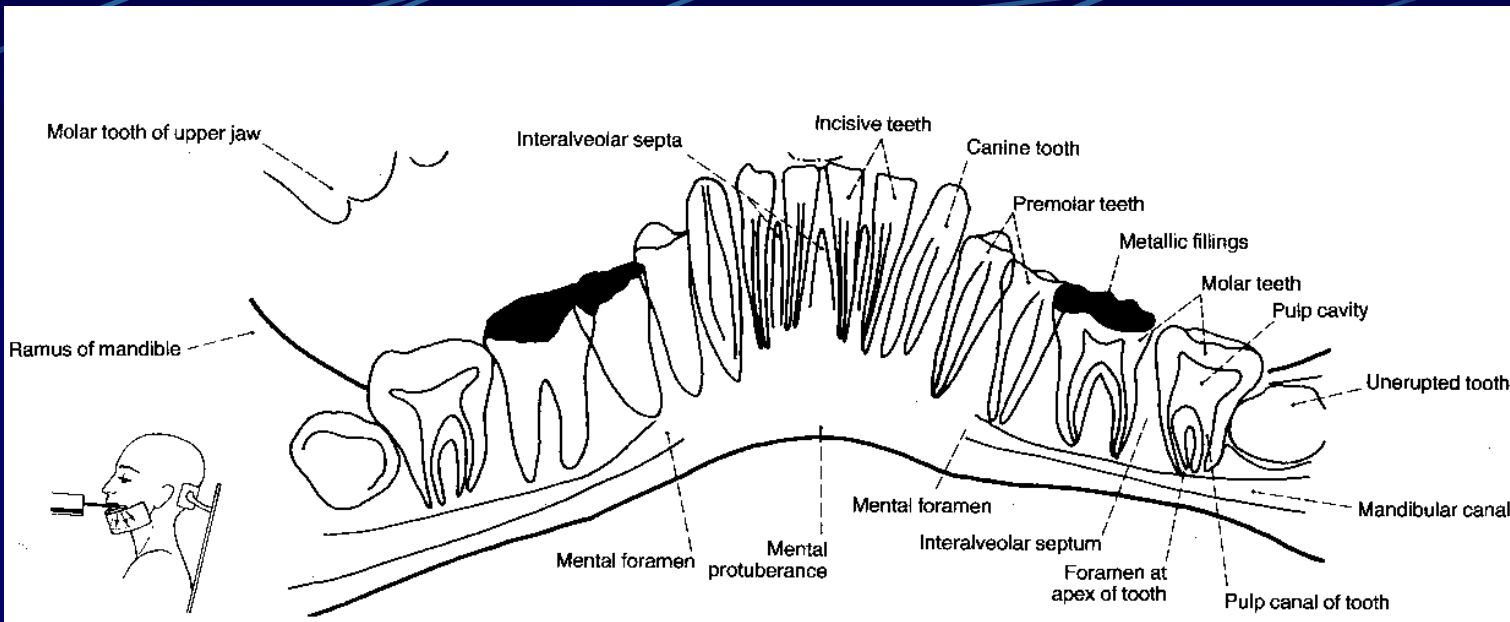
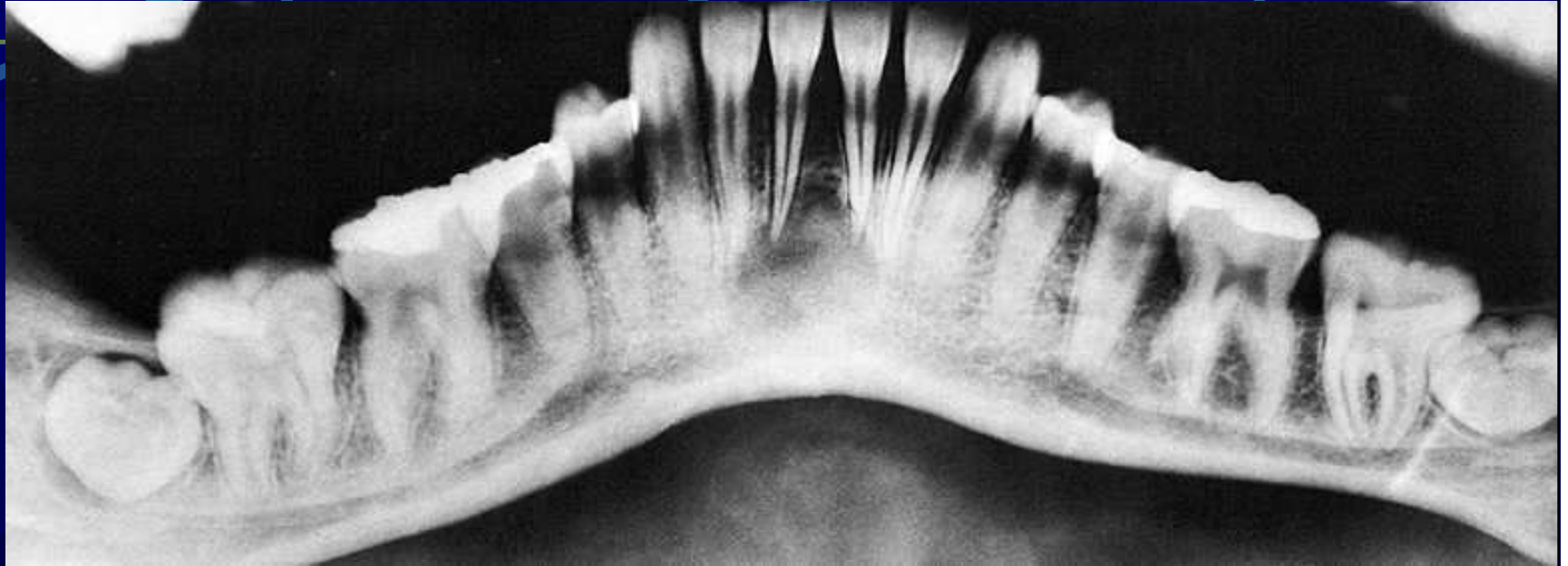


Projekce



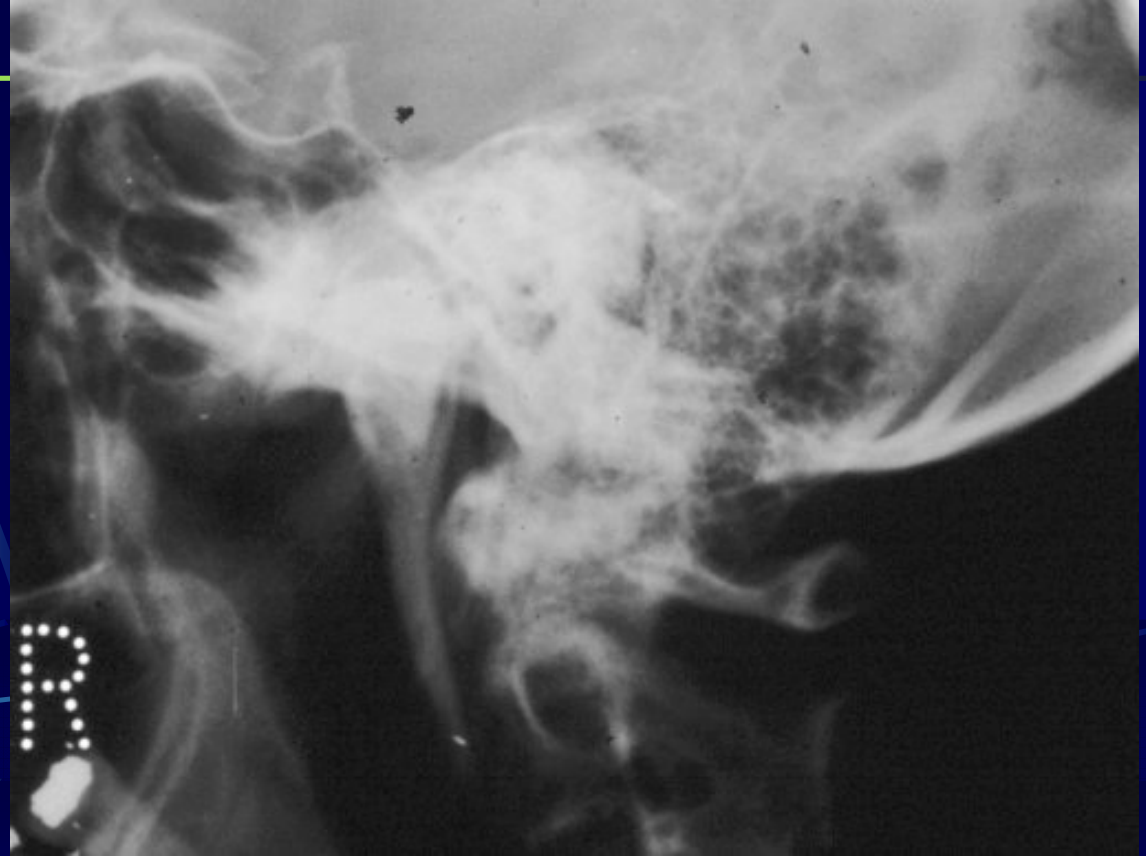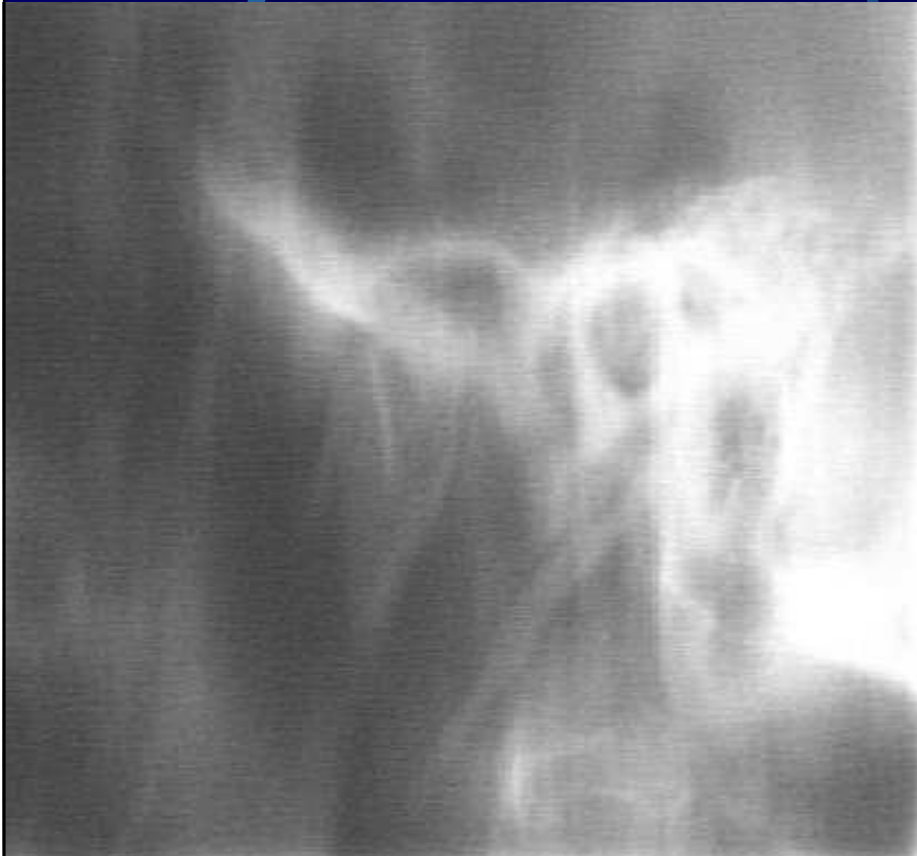


Projekce



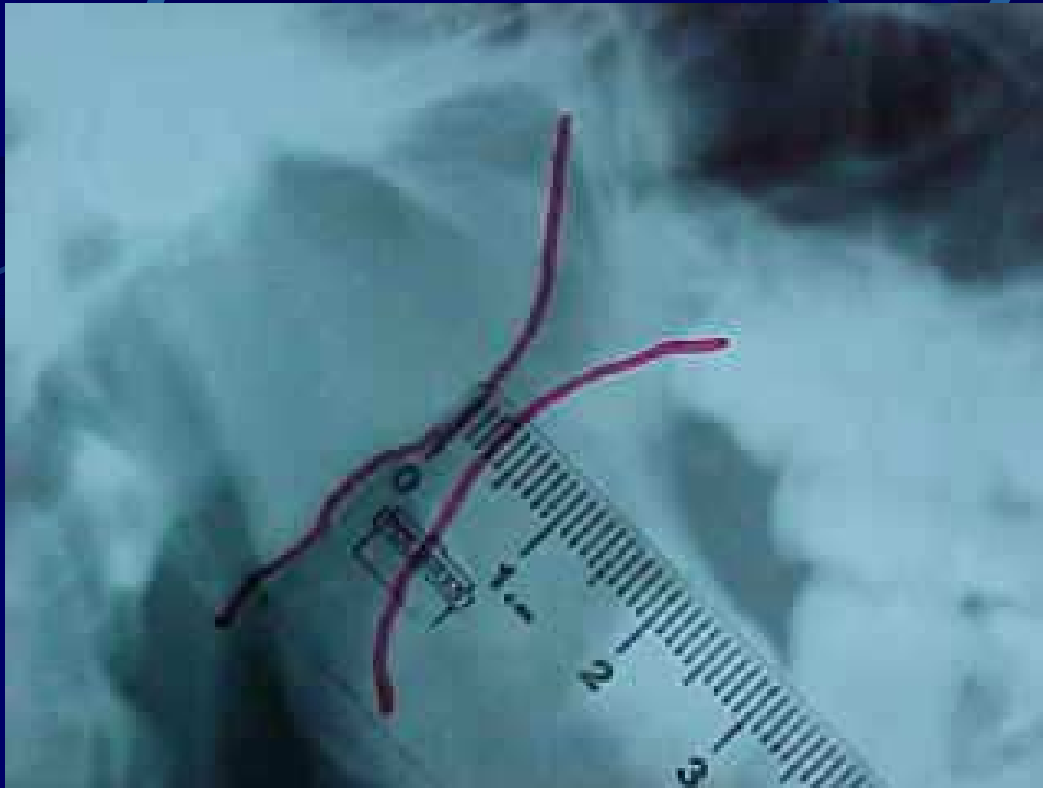
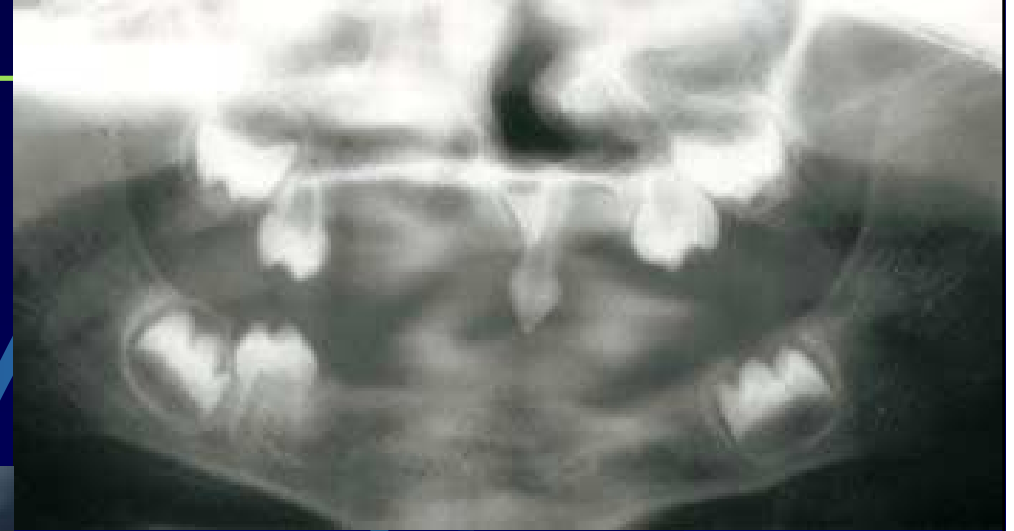


Projekce



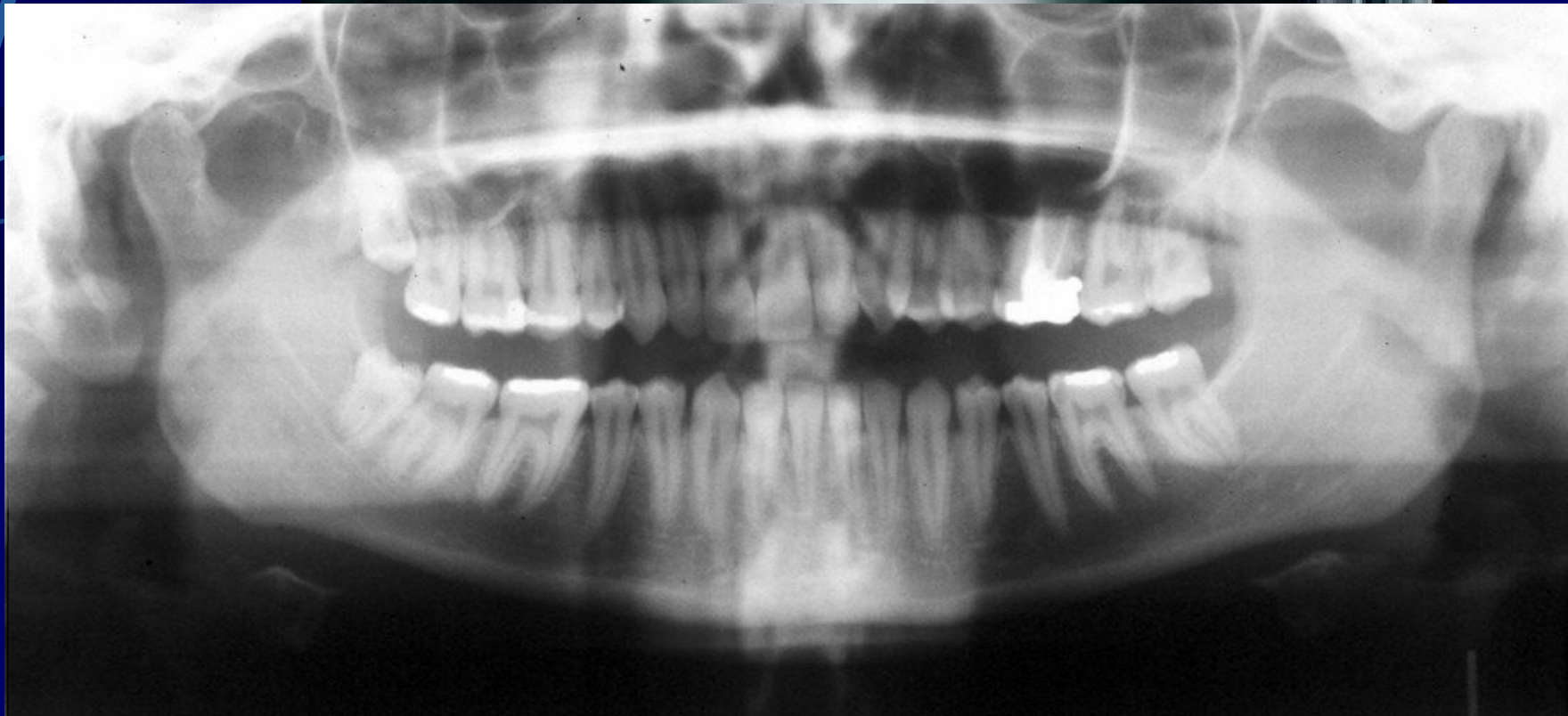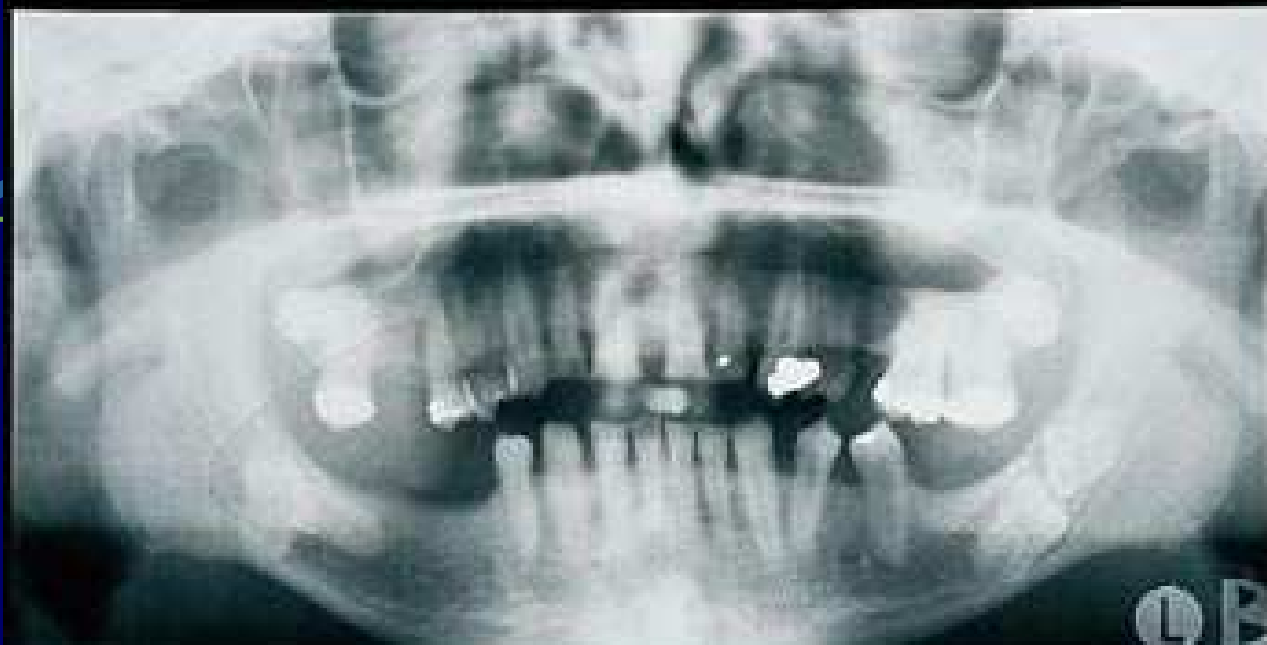


Projekce



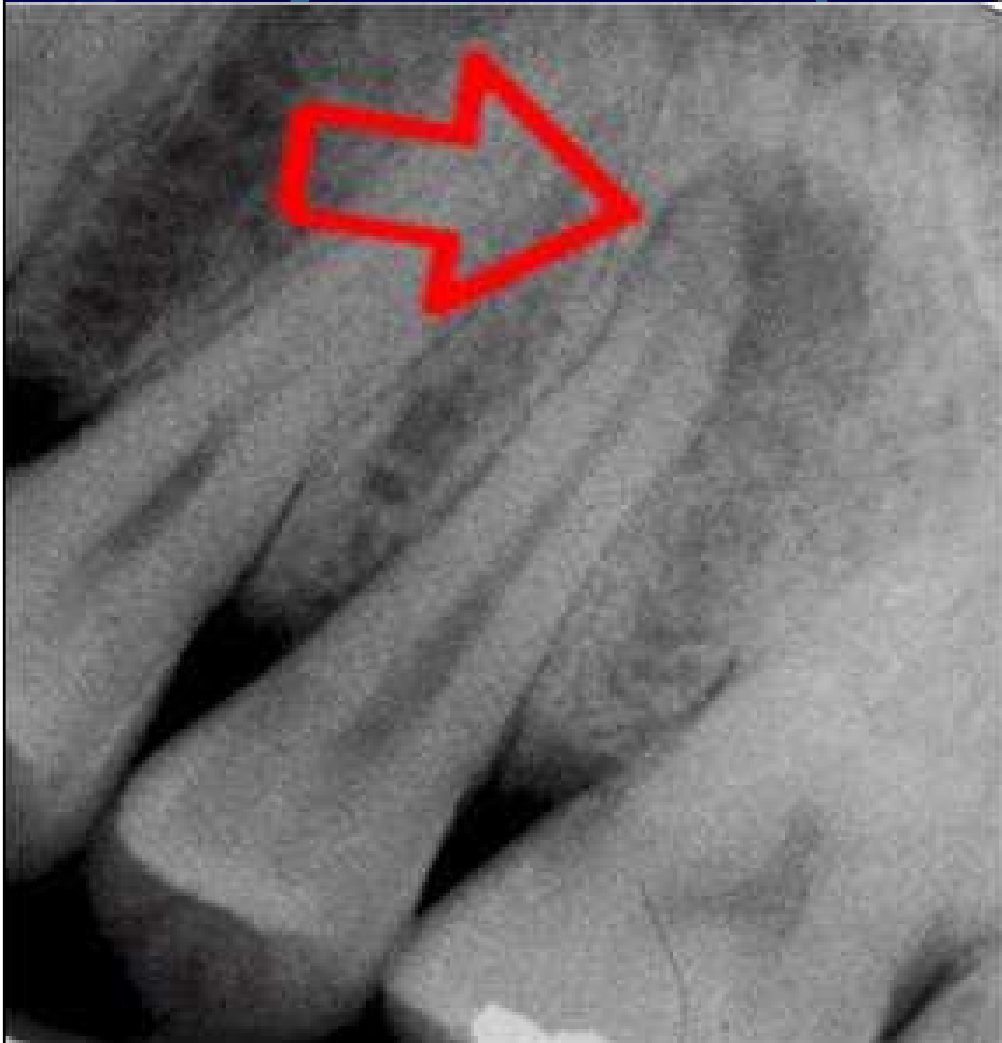


Projekce



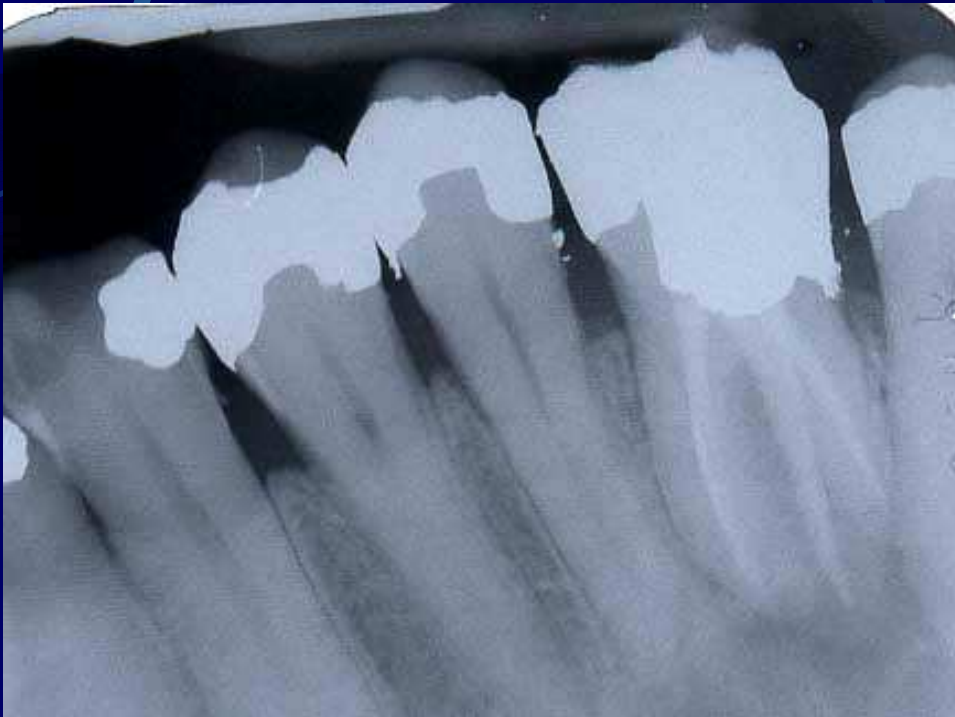
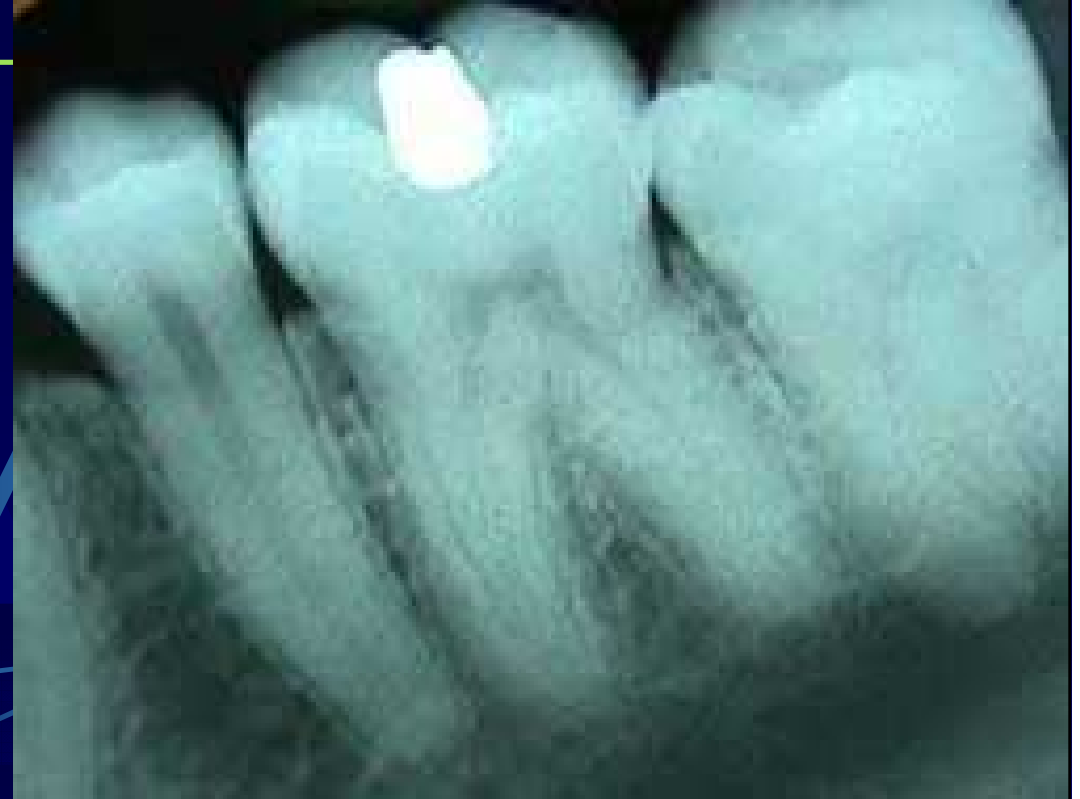

Projekce



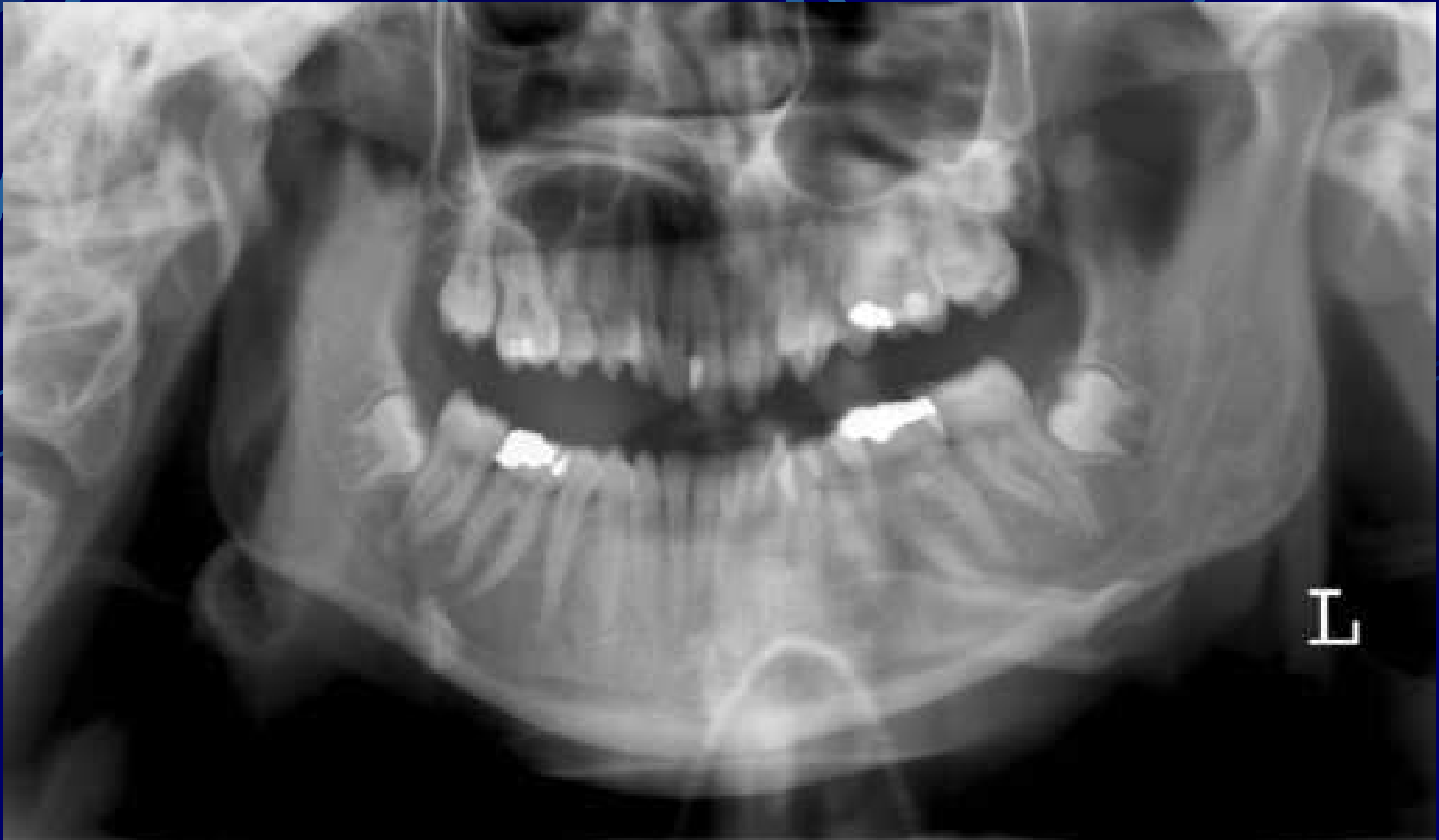



Projekce





Zuby - artefakt

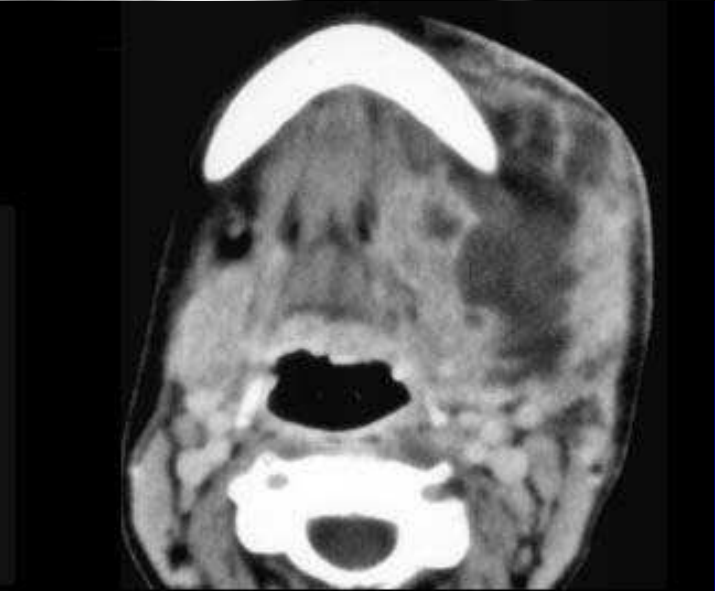
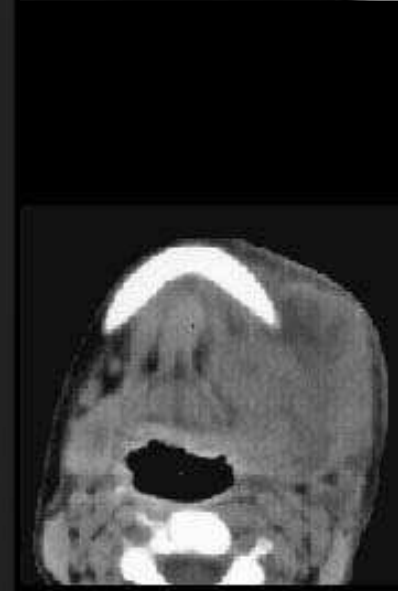
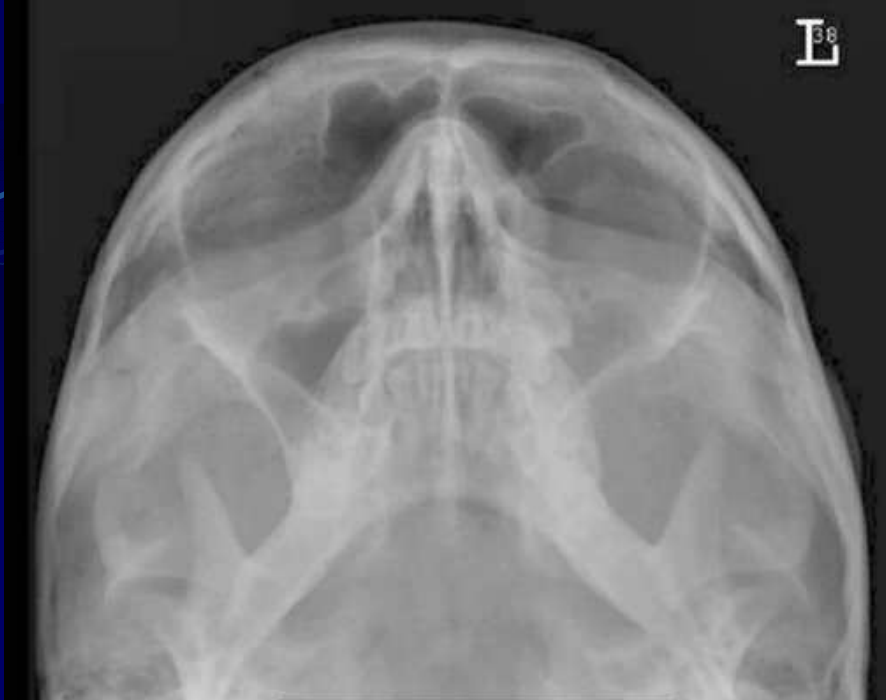
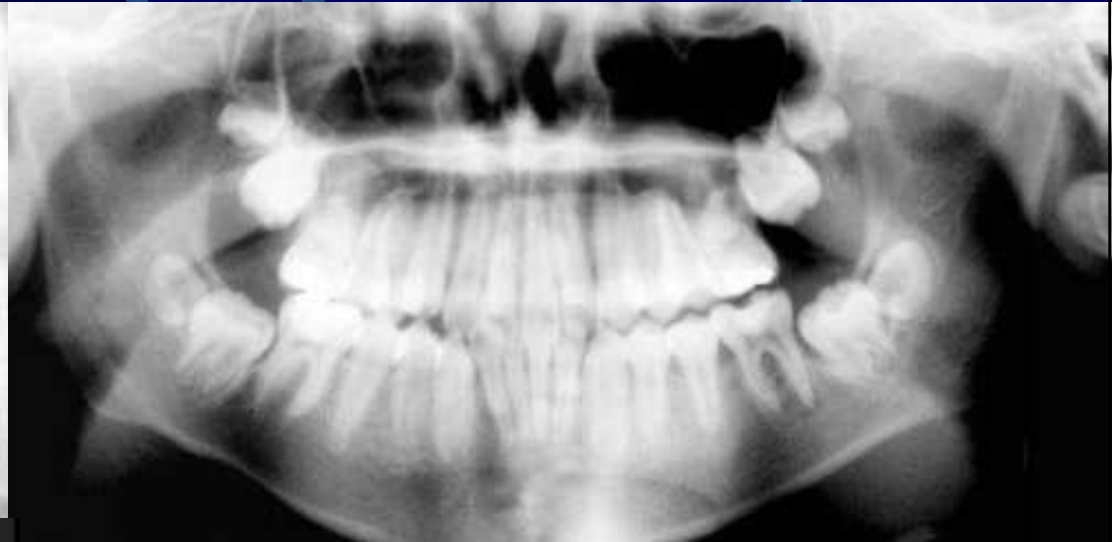
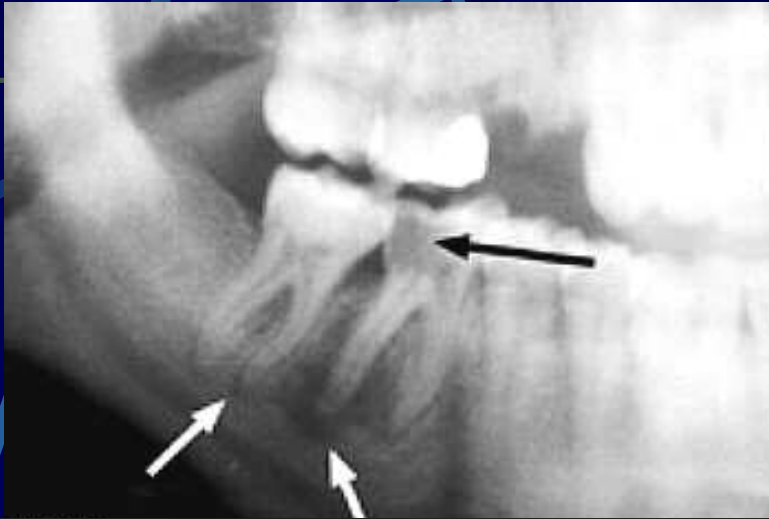


Patologie

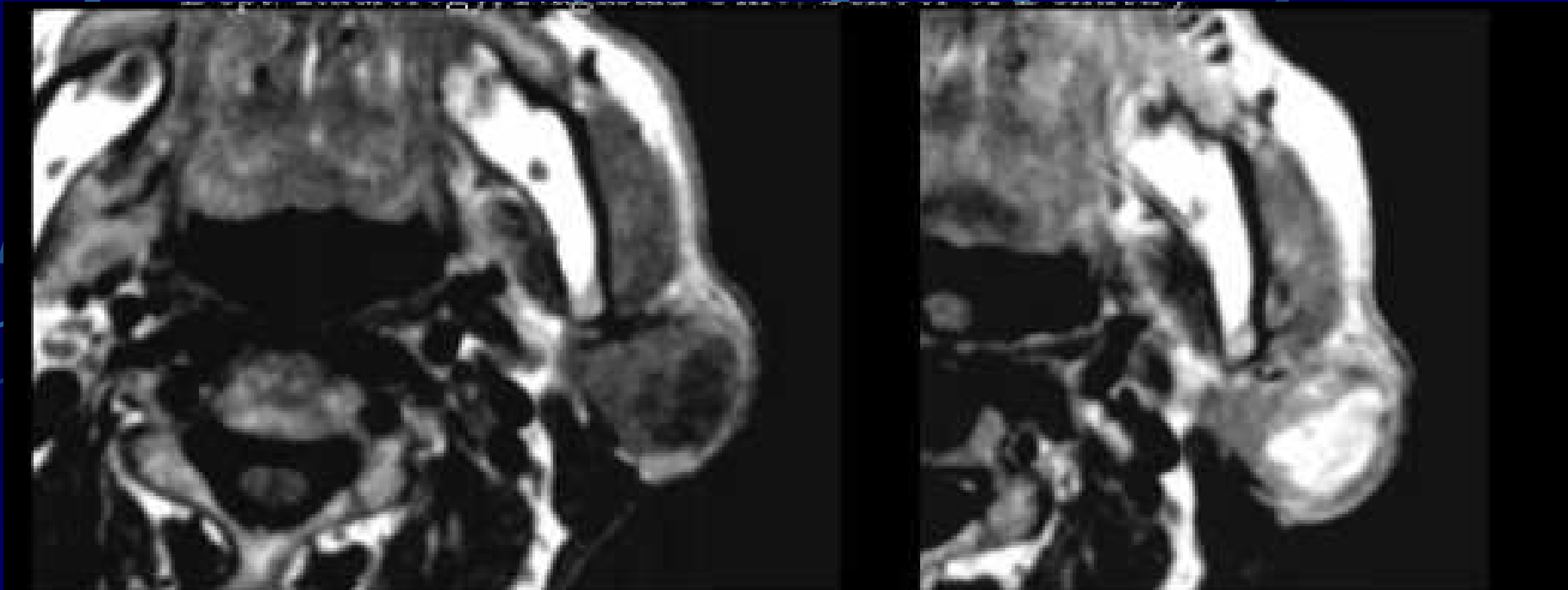


Absces



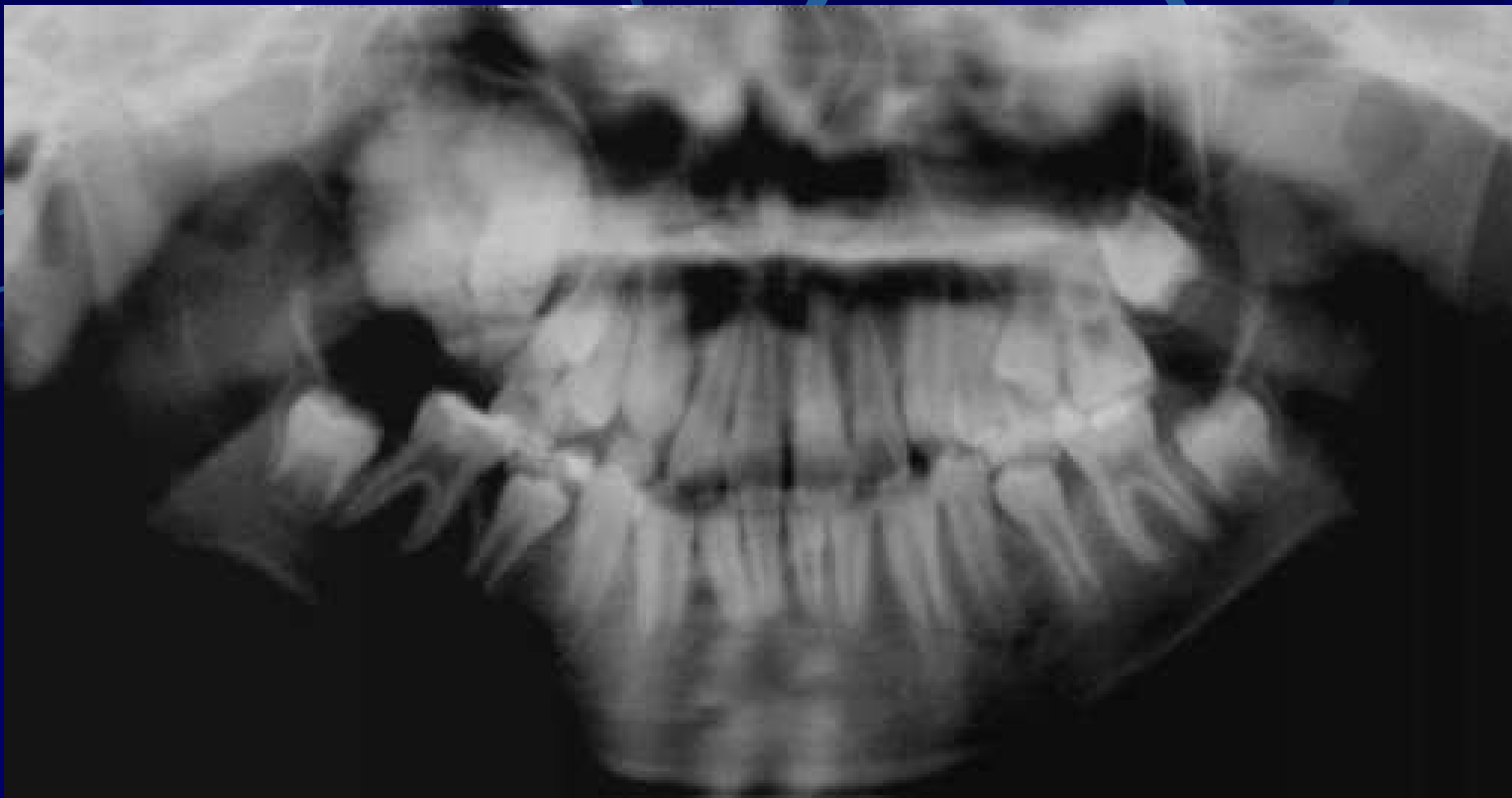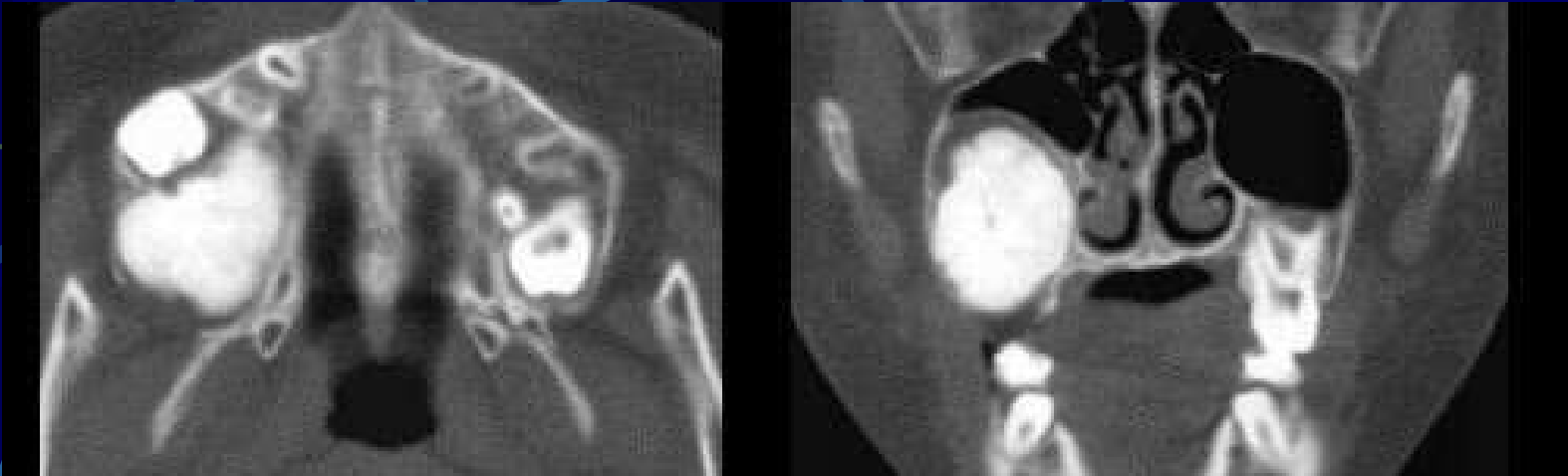


Adenolymfoma




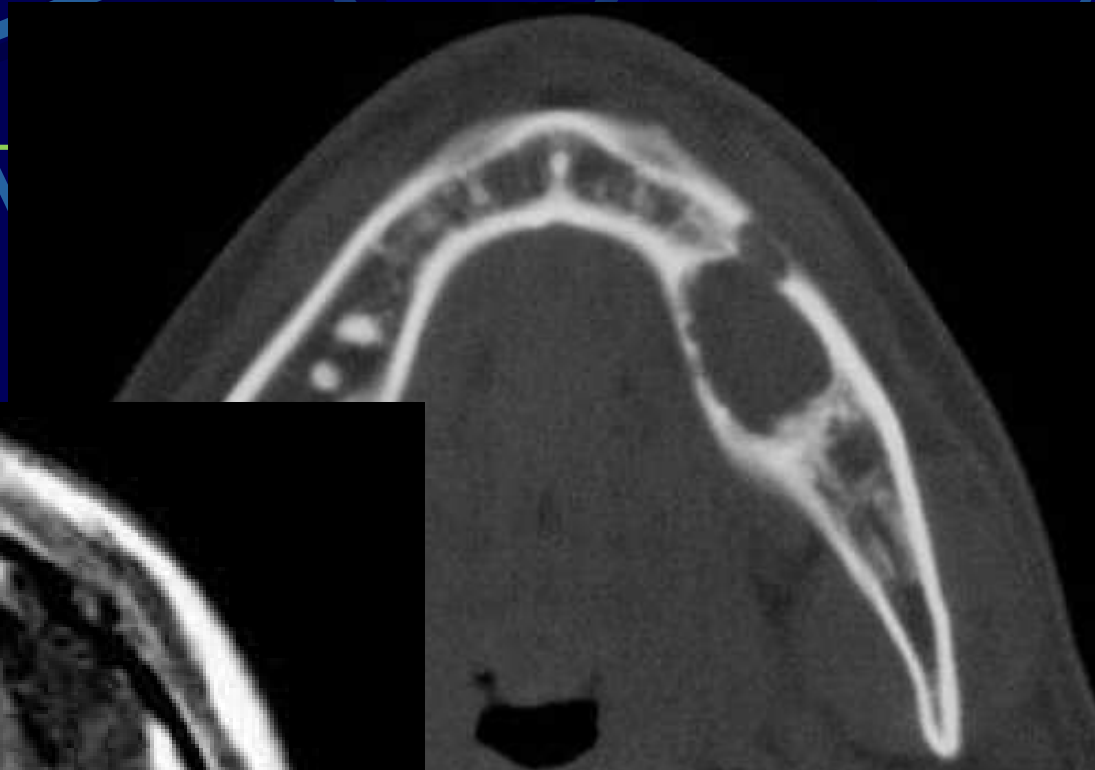
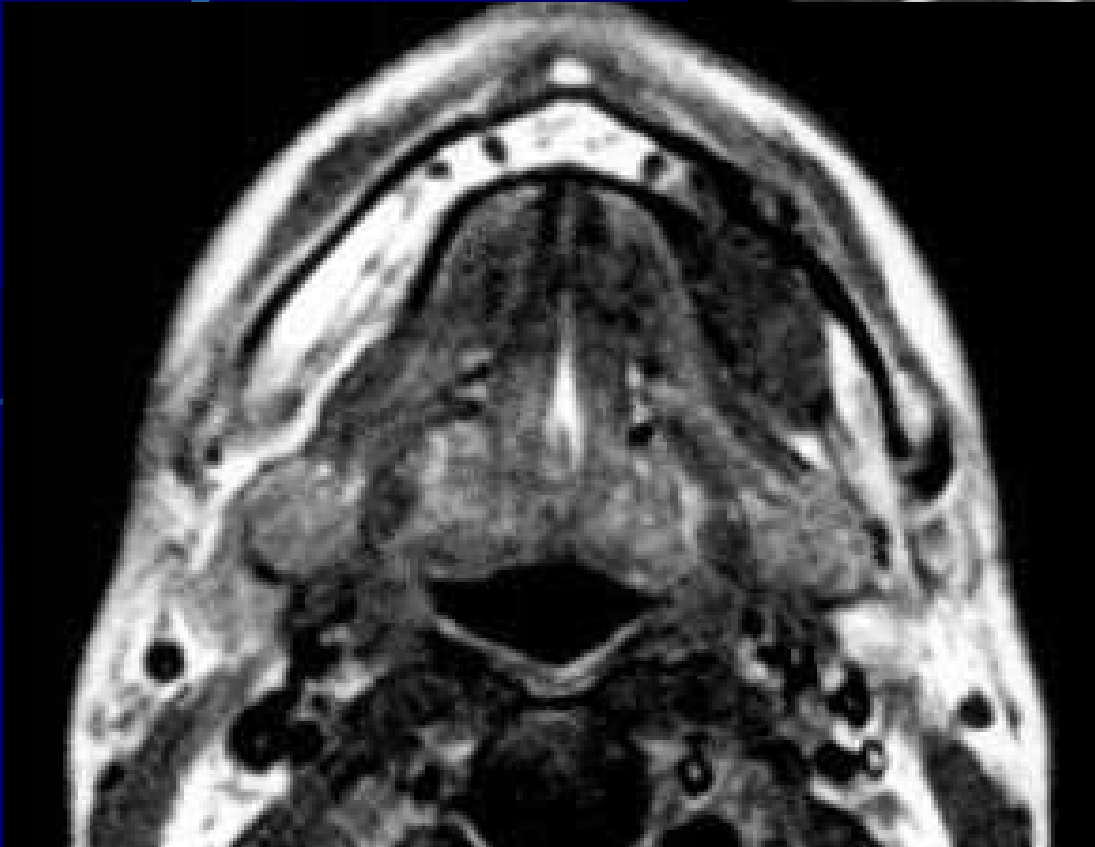


Facionmaxilární ameloblastický fibrom



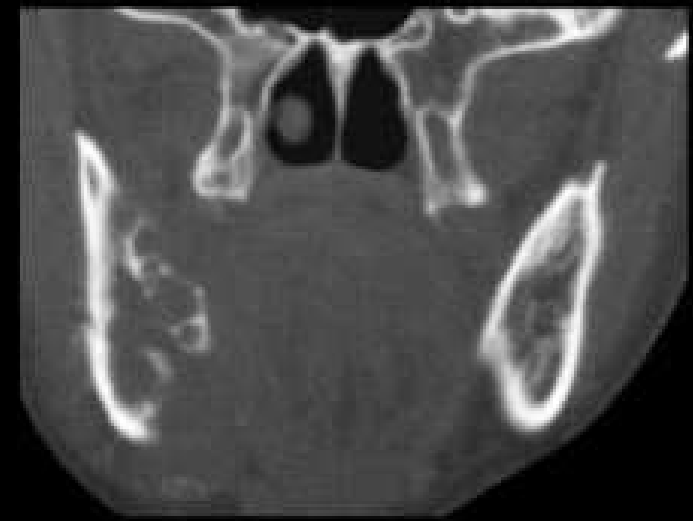
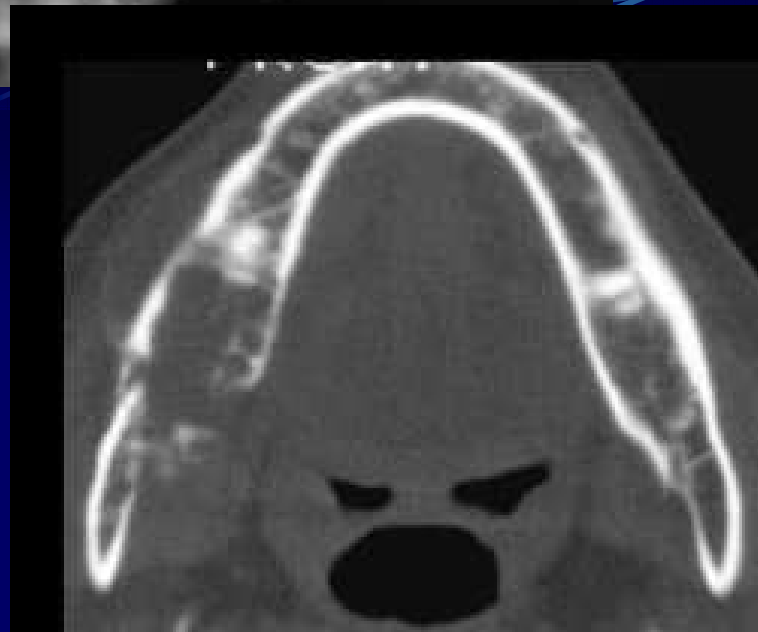
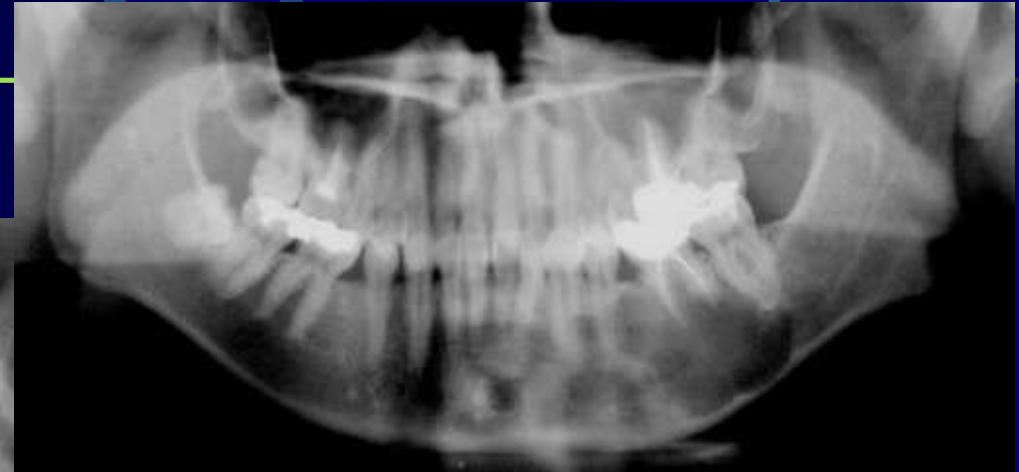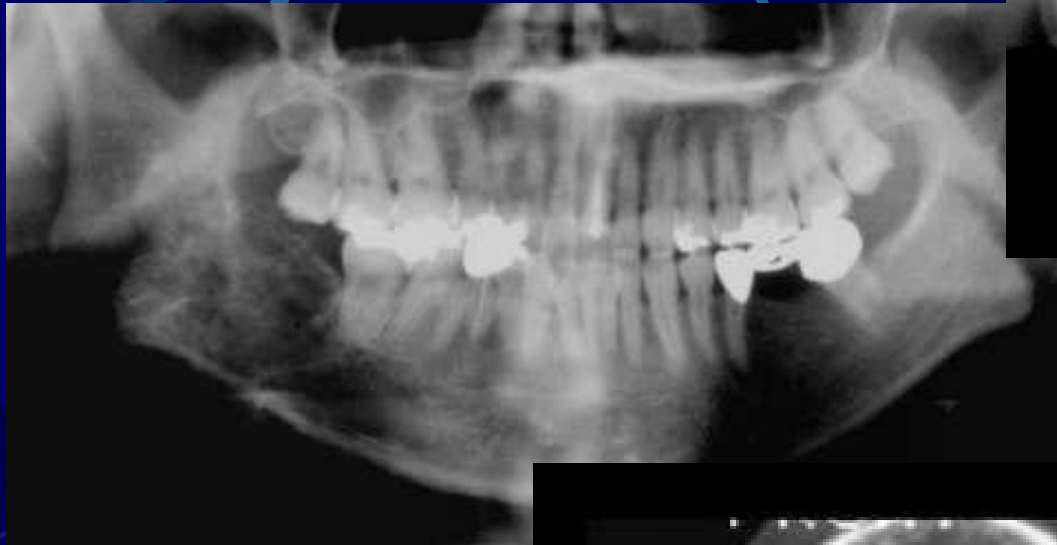Fibrom



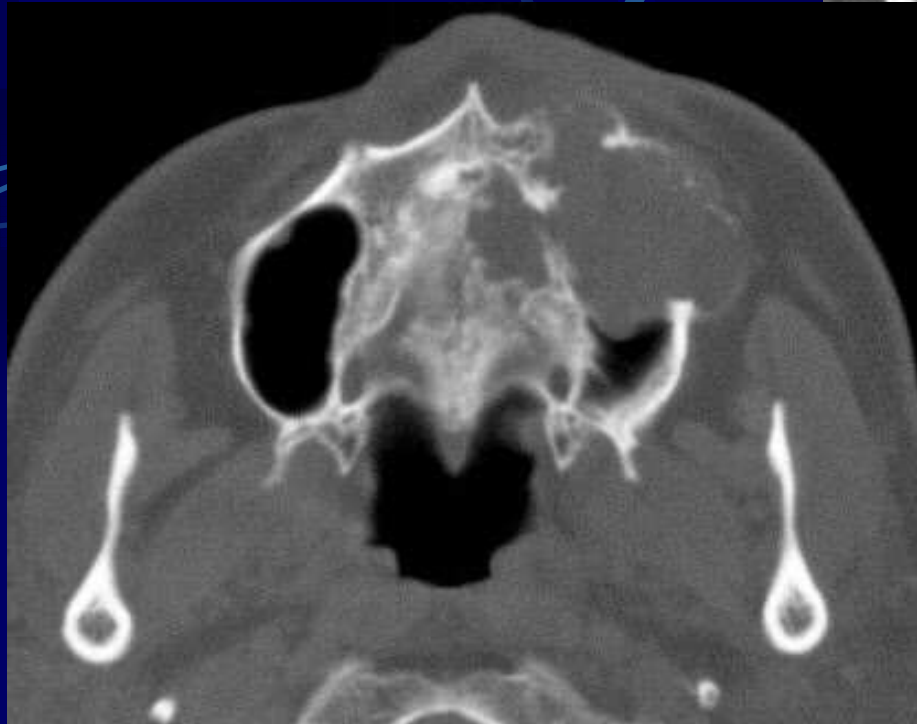
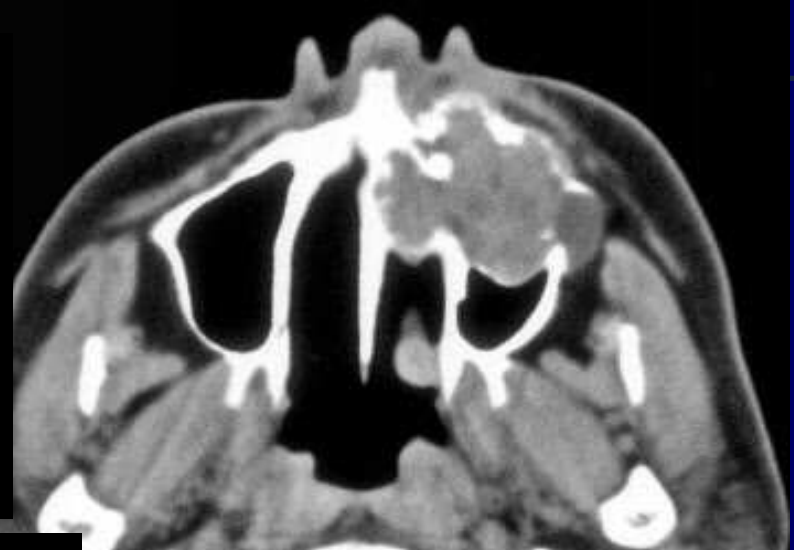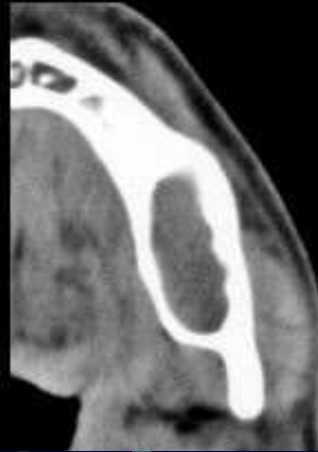
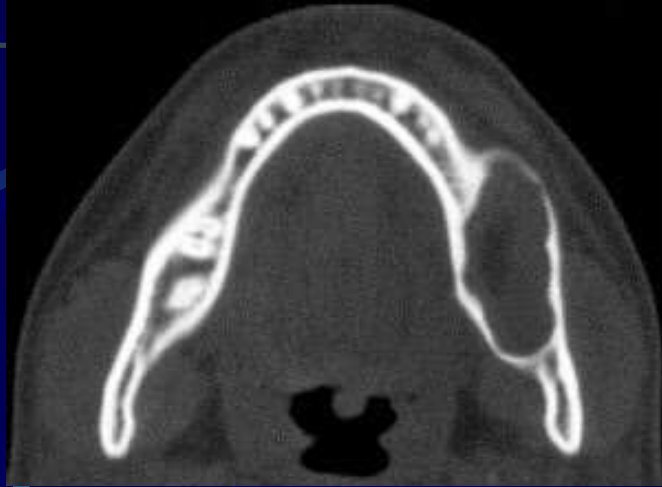



Facionmaxilární ameloblastický fibrosarkom



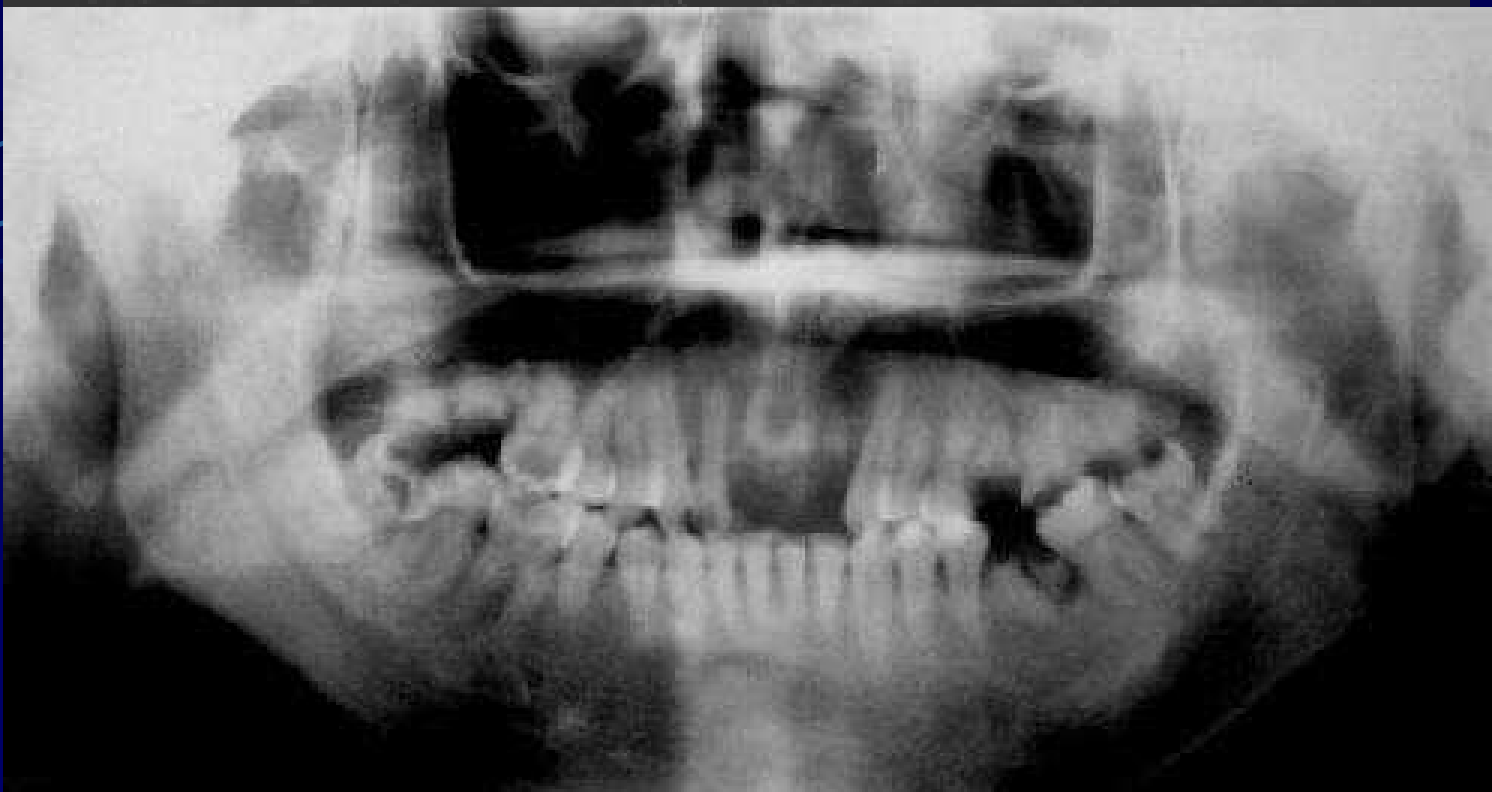
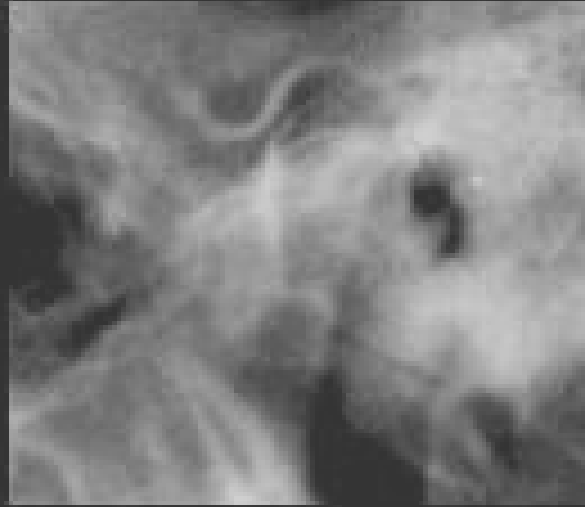
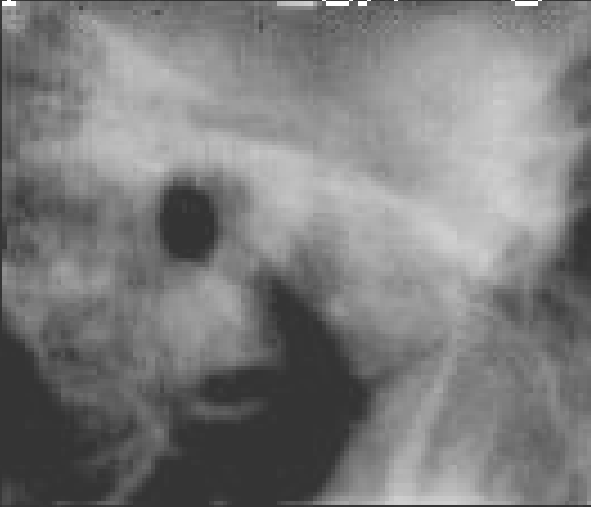
Ameloblastom



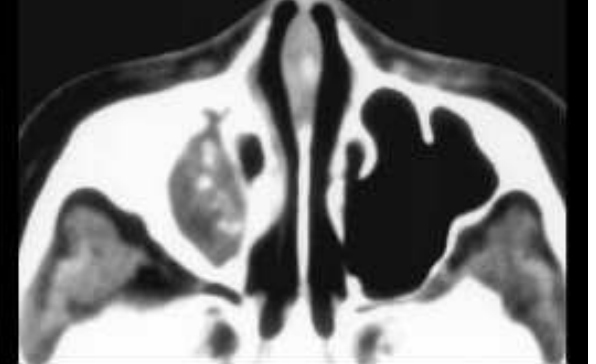
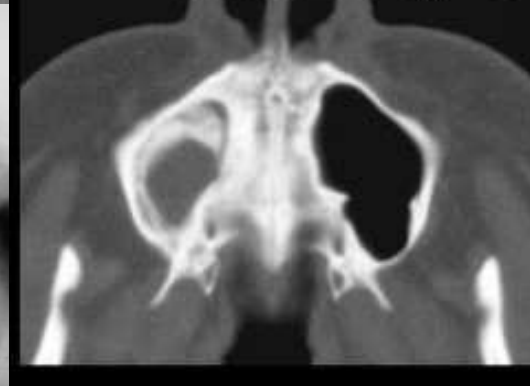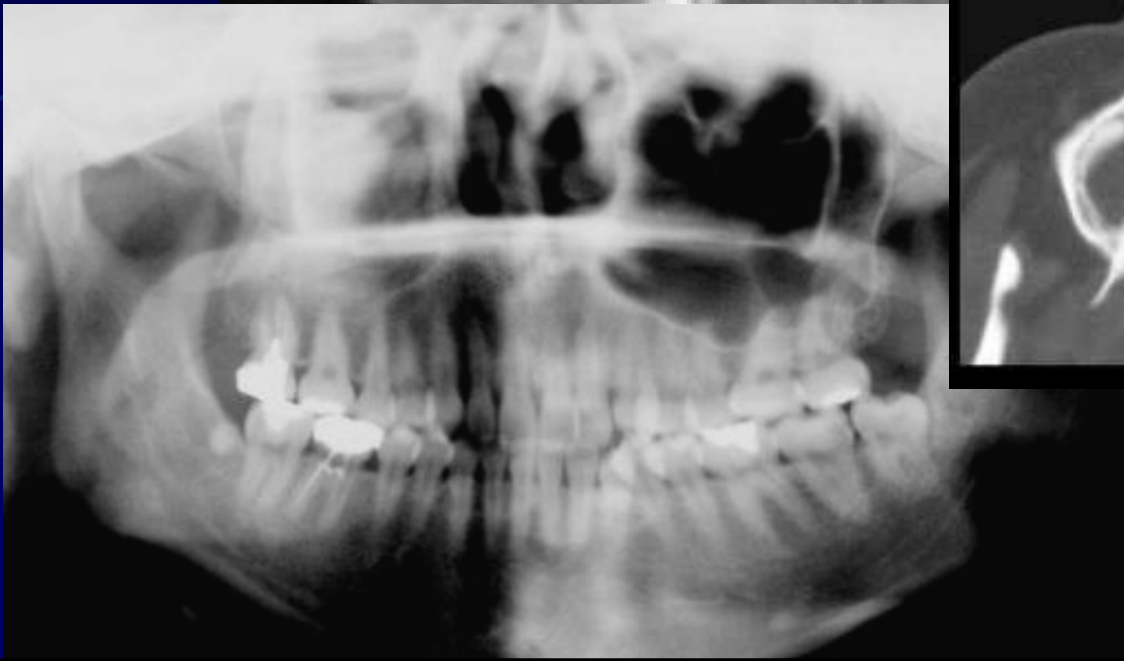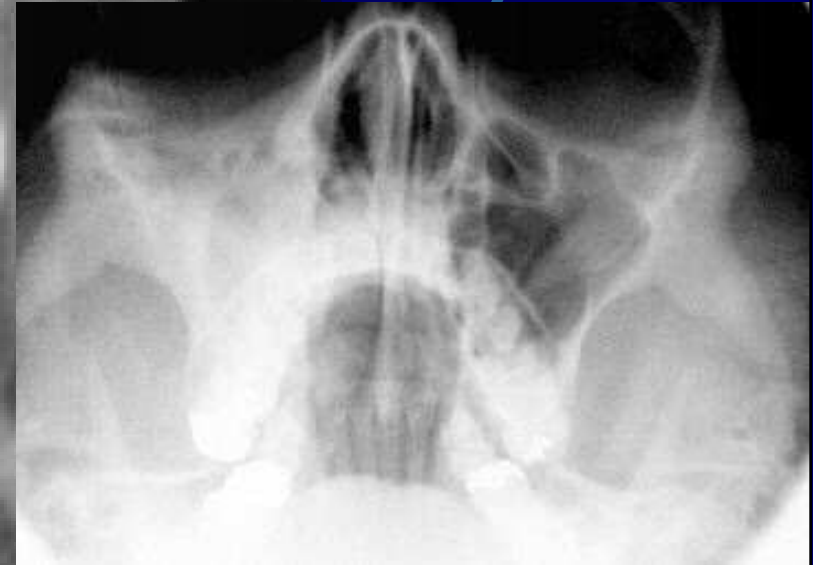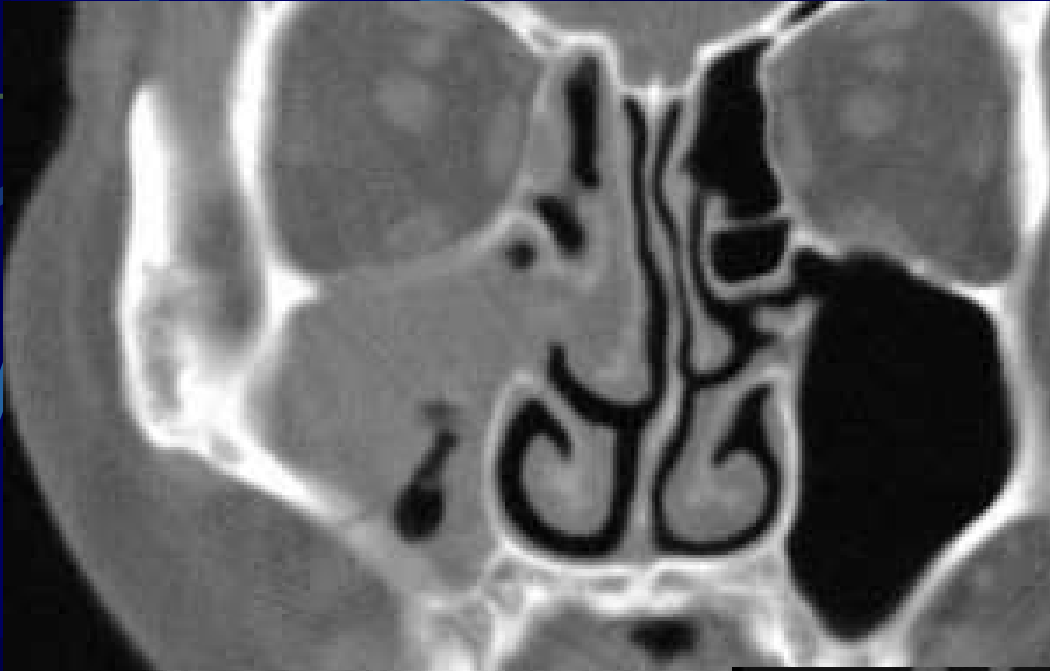


Ankylozující artritida



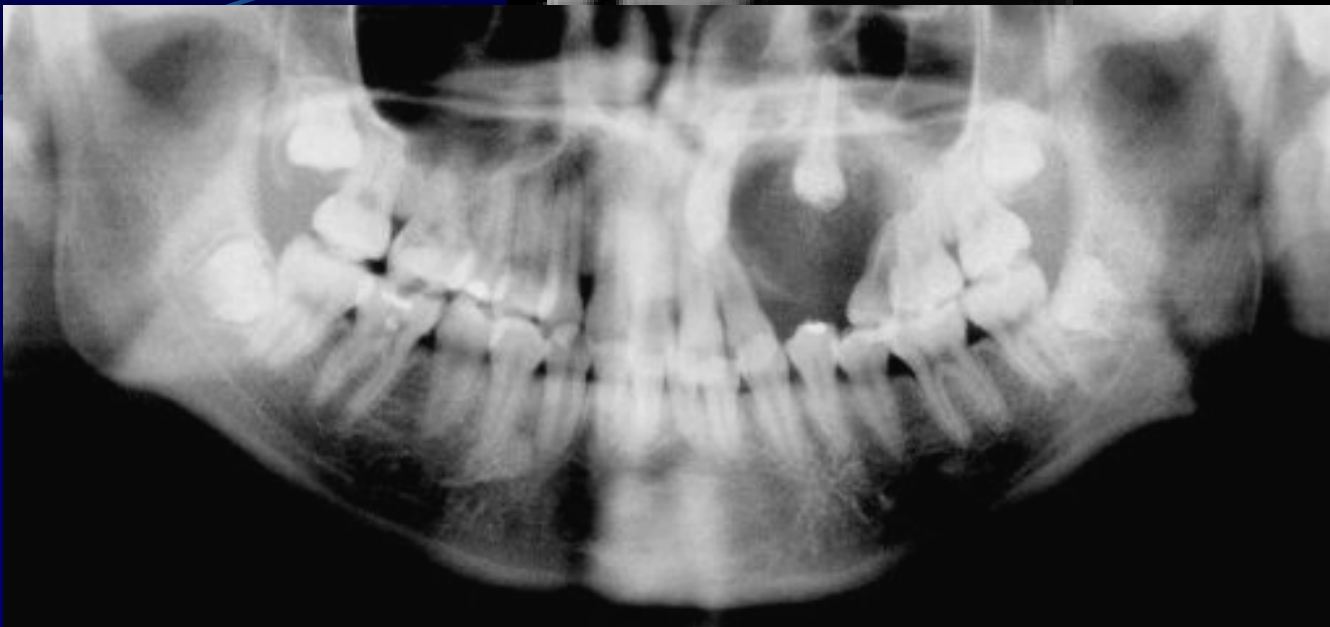
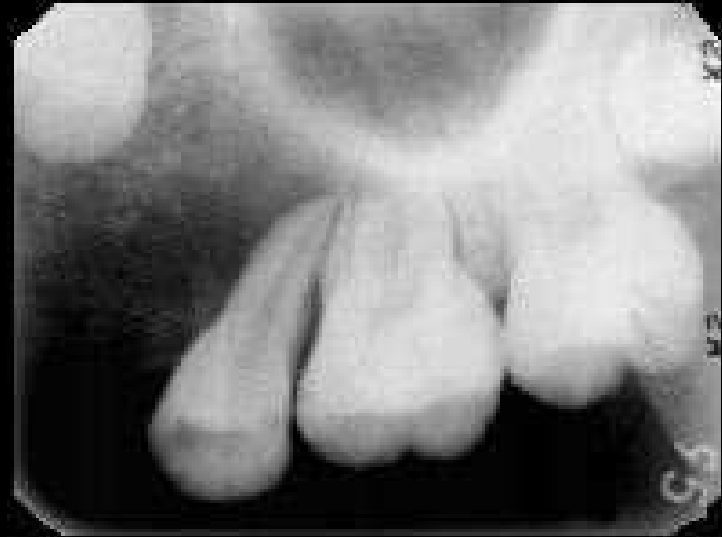
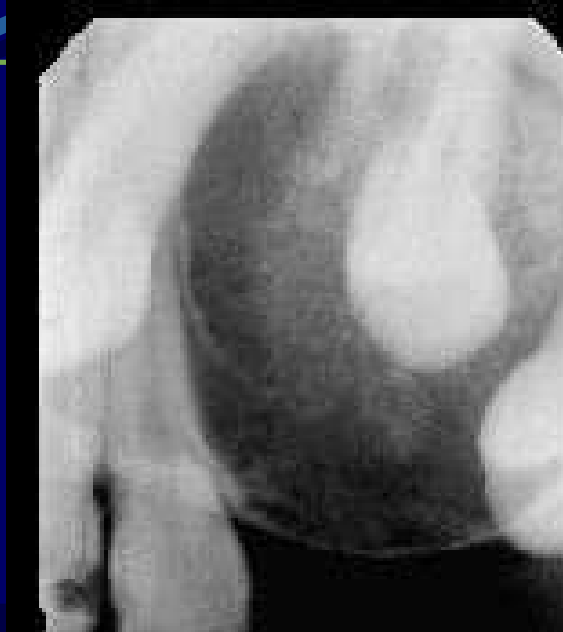Aspergilóza



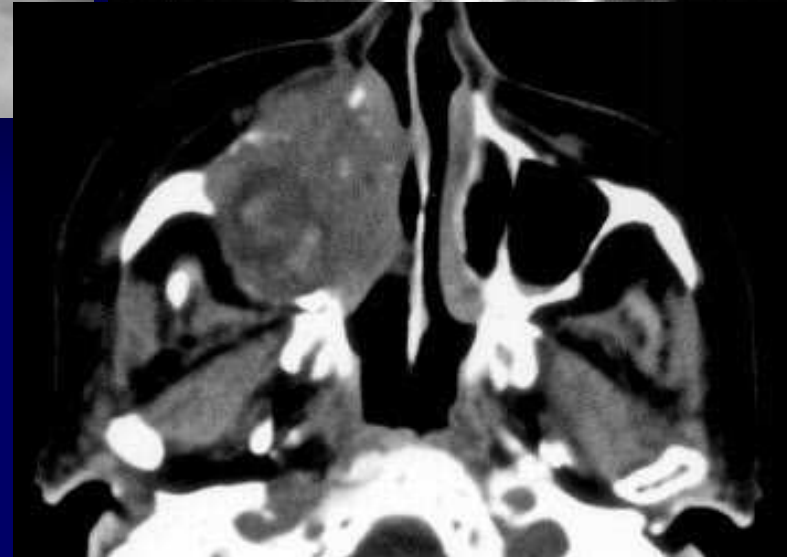
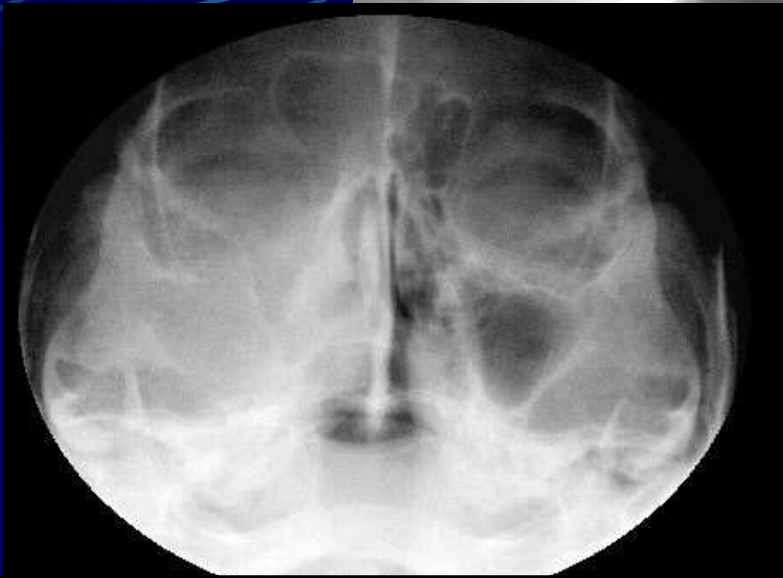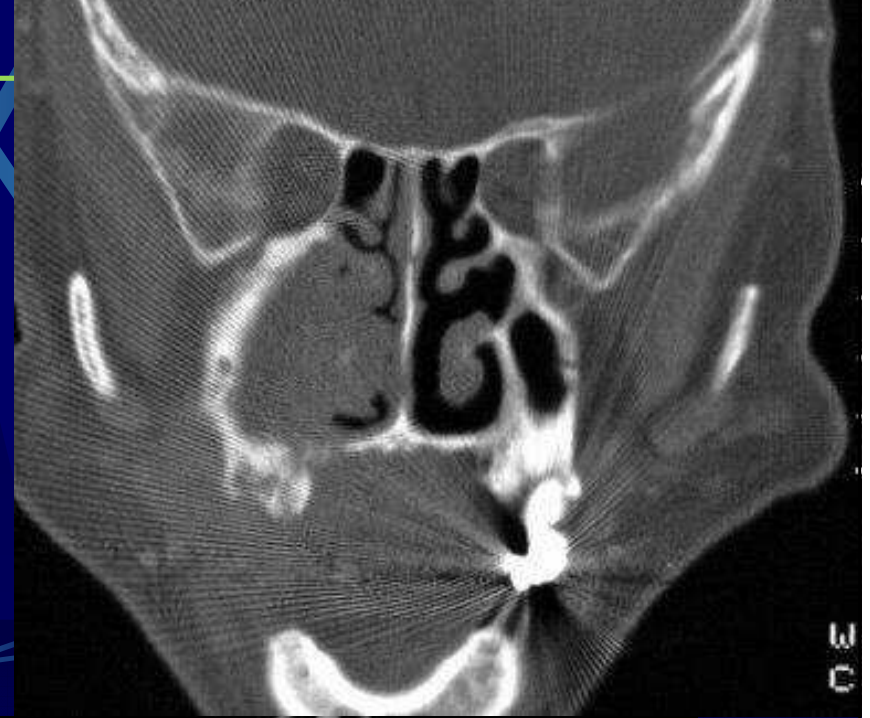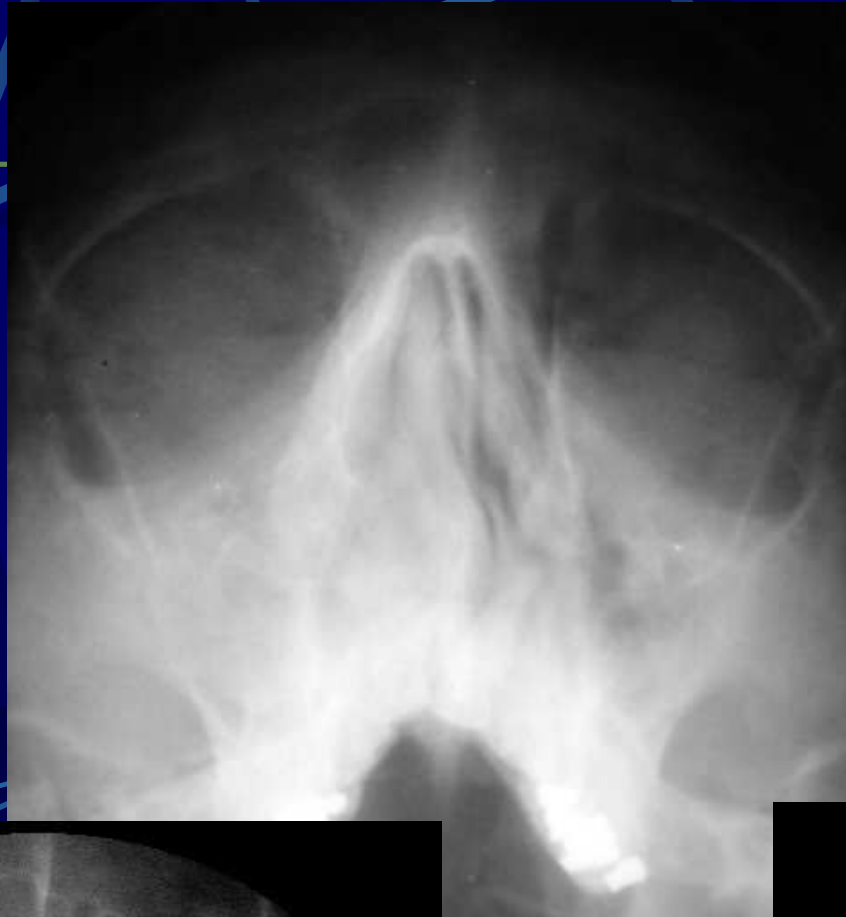


Ca – odontogenní tumor



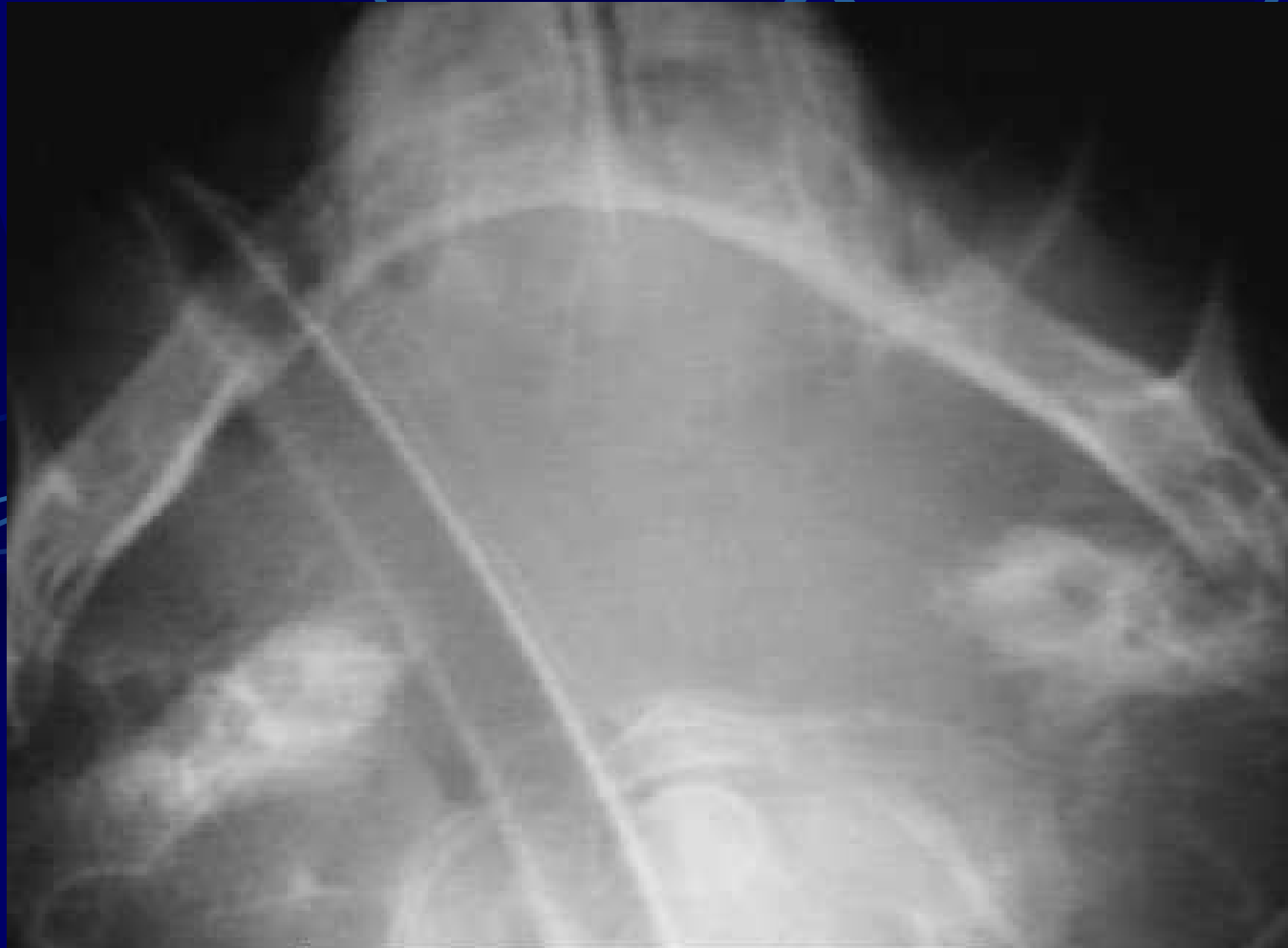

Ca maxilly



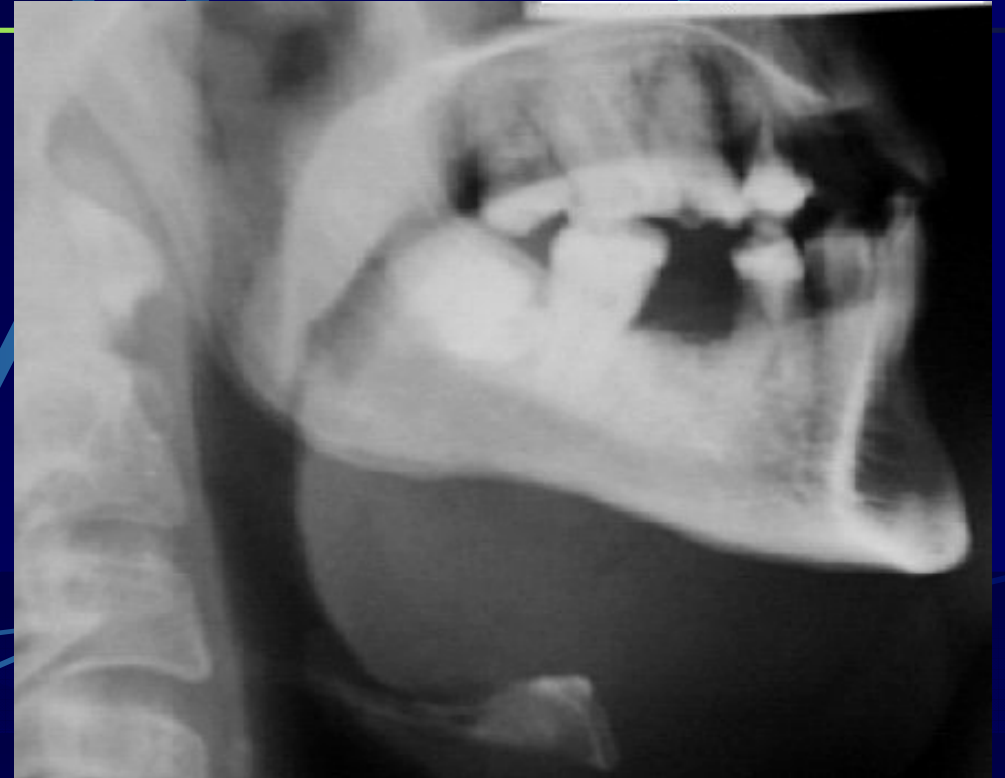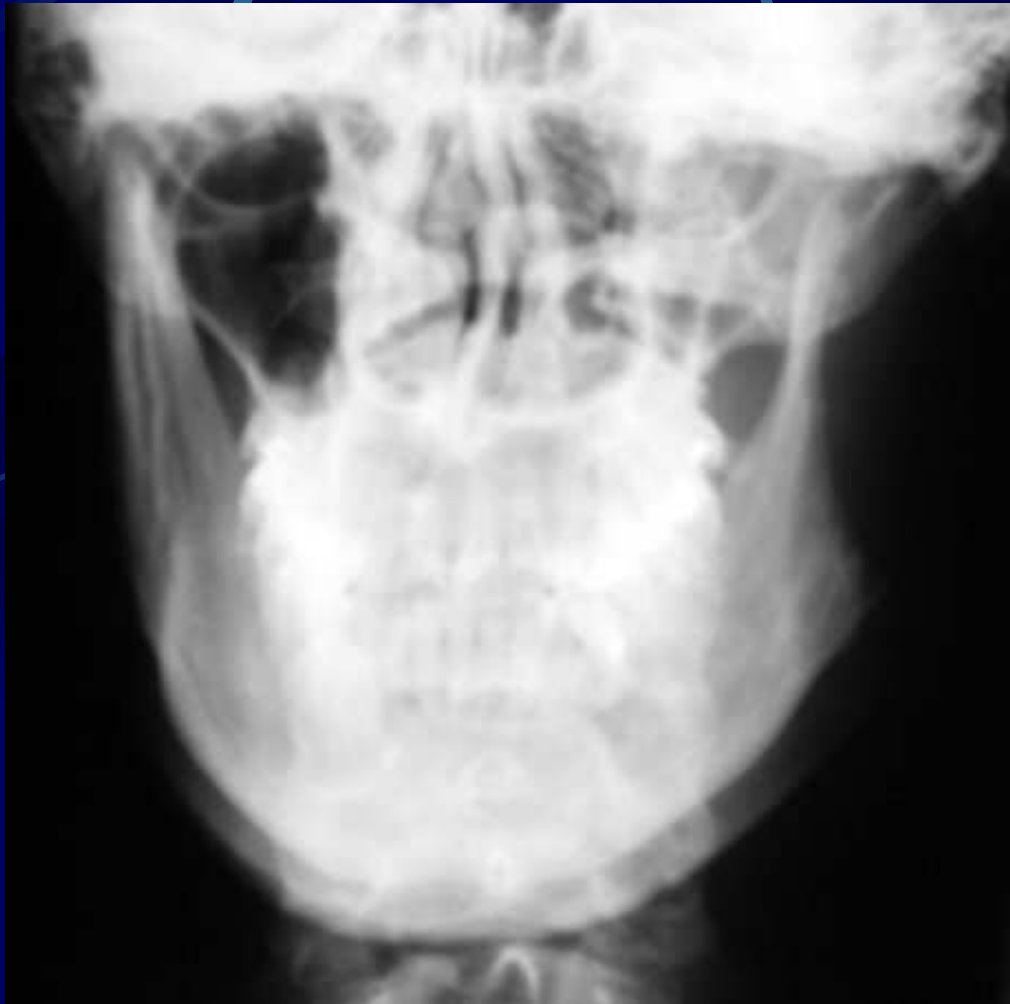


Ca nasopharyngu



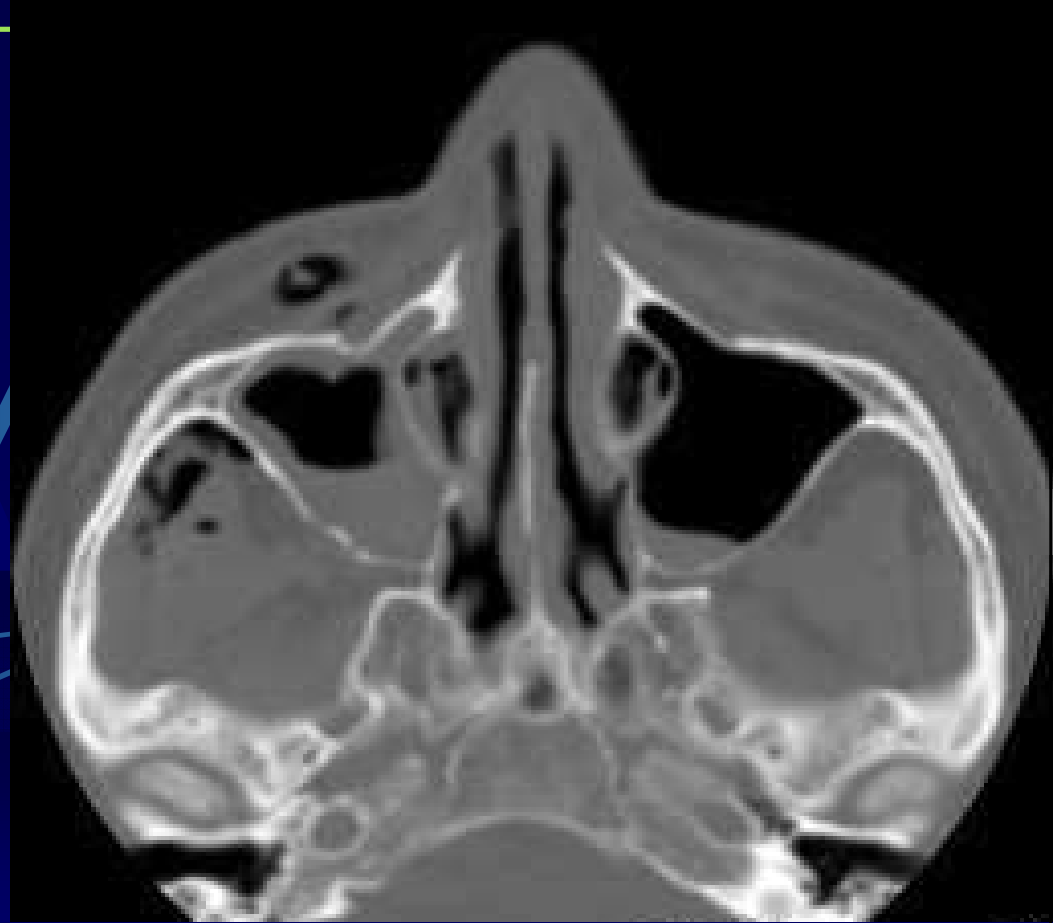
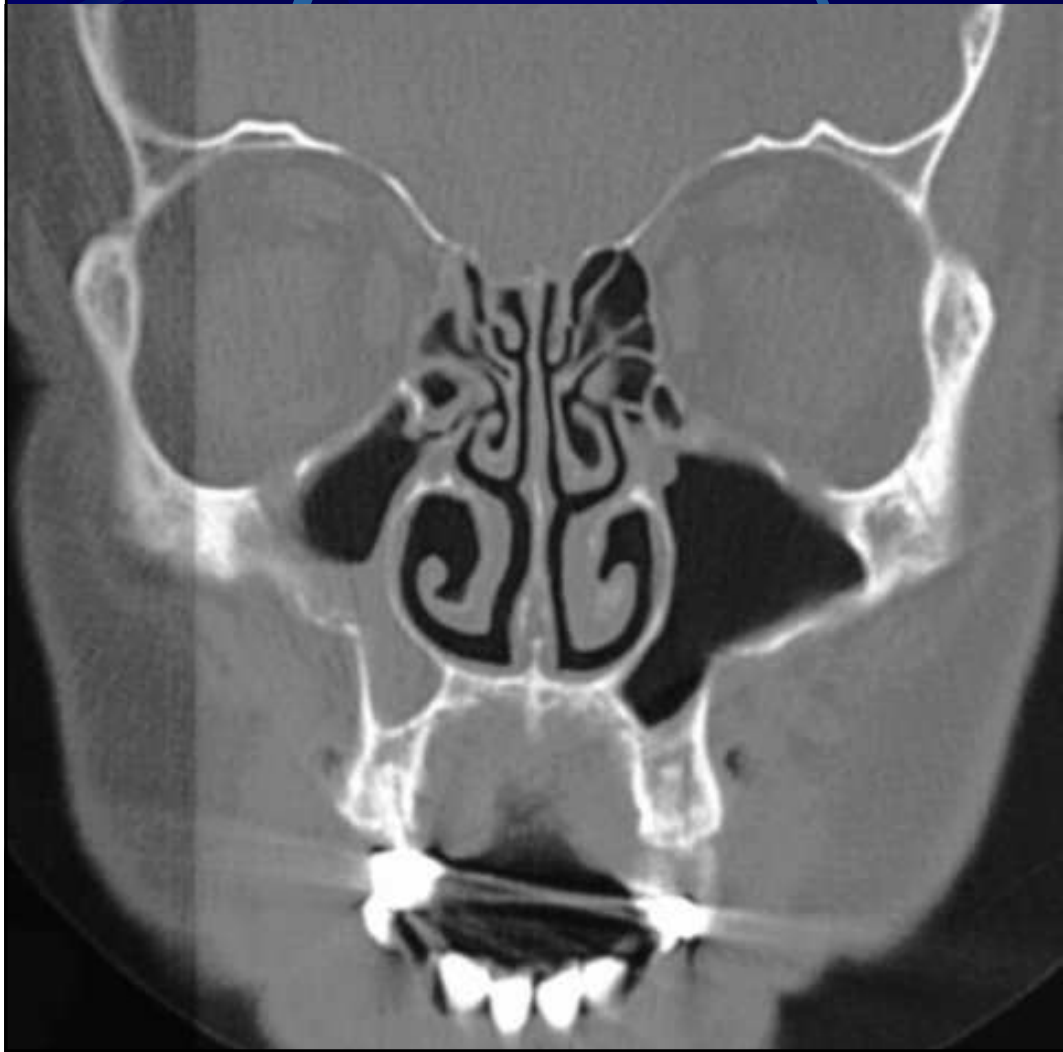

Sarcom mandibuly



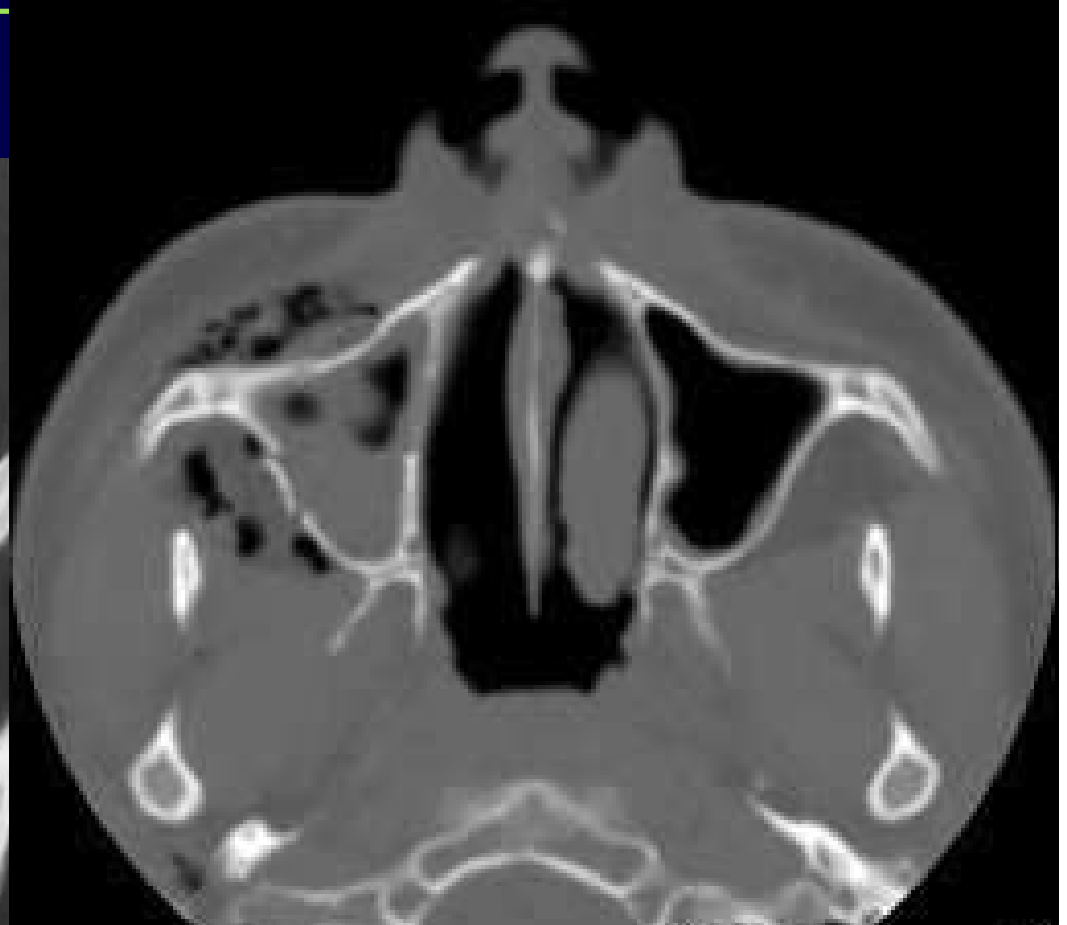
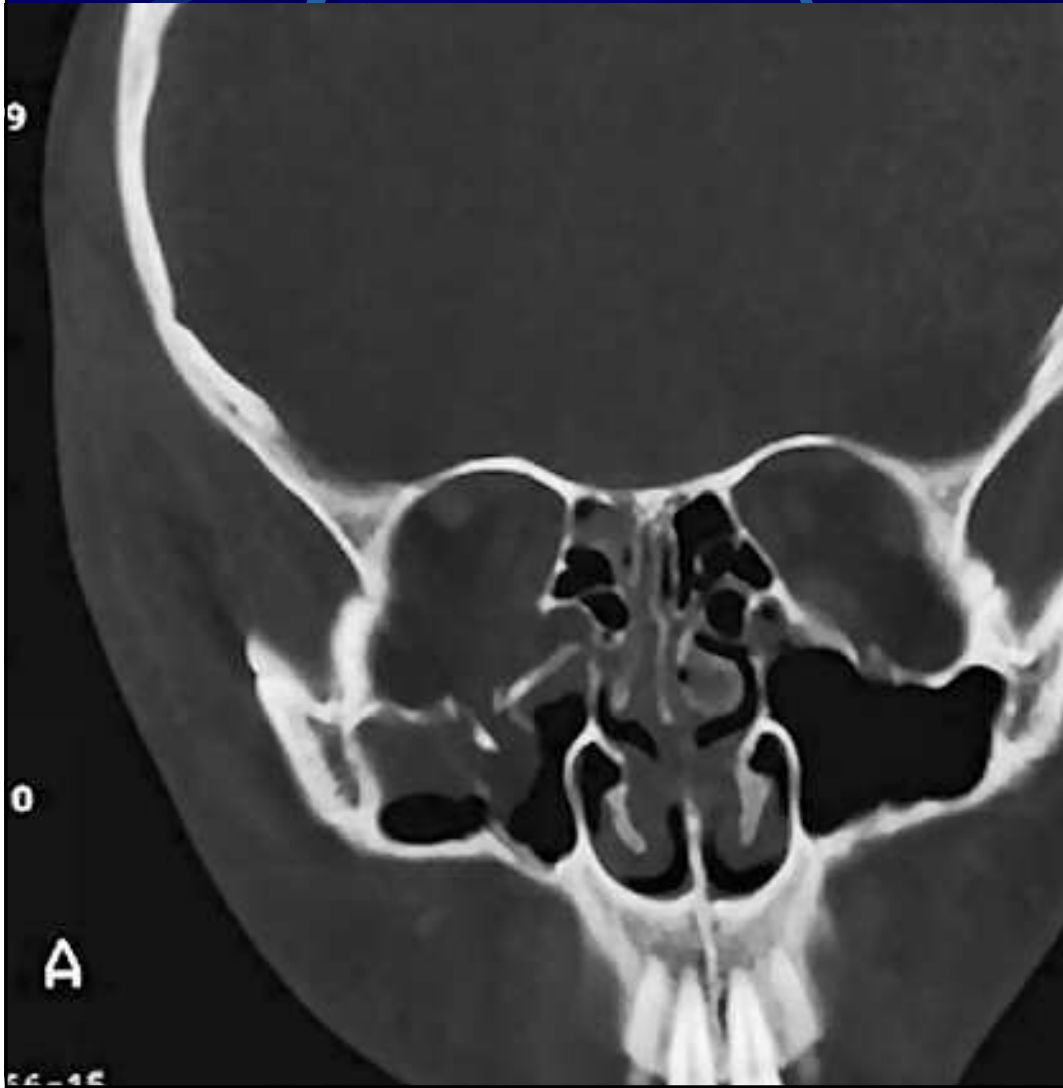
Fraktura



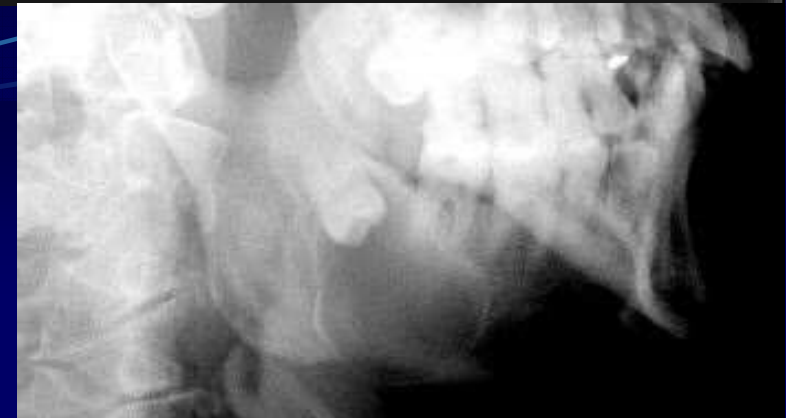
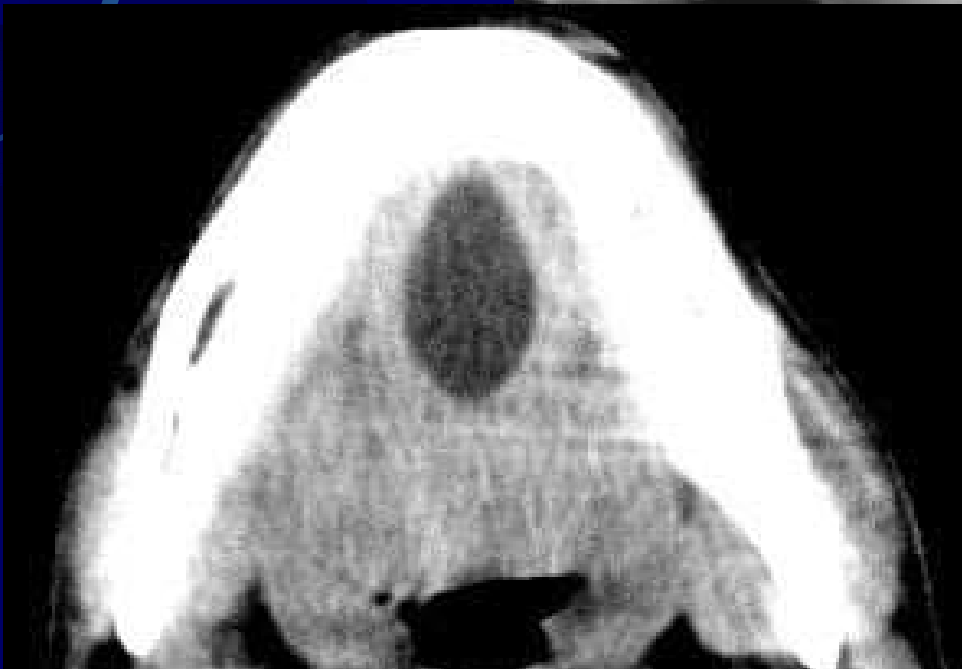
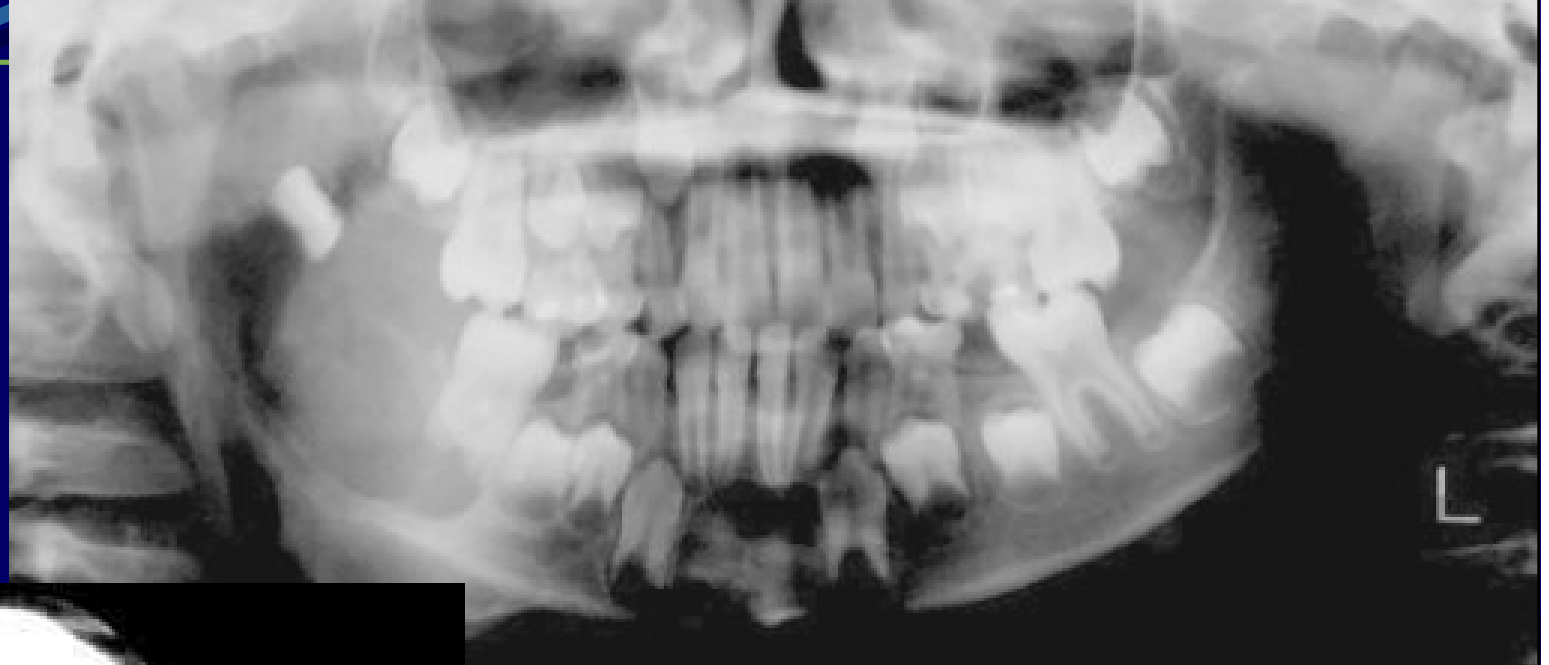
Fraktura



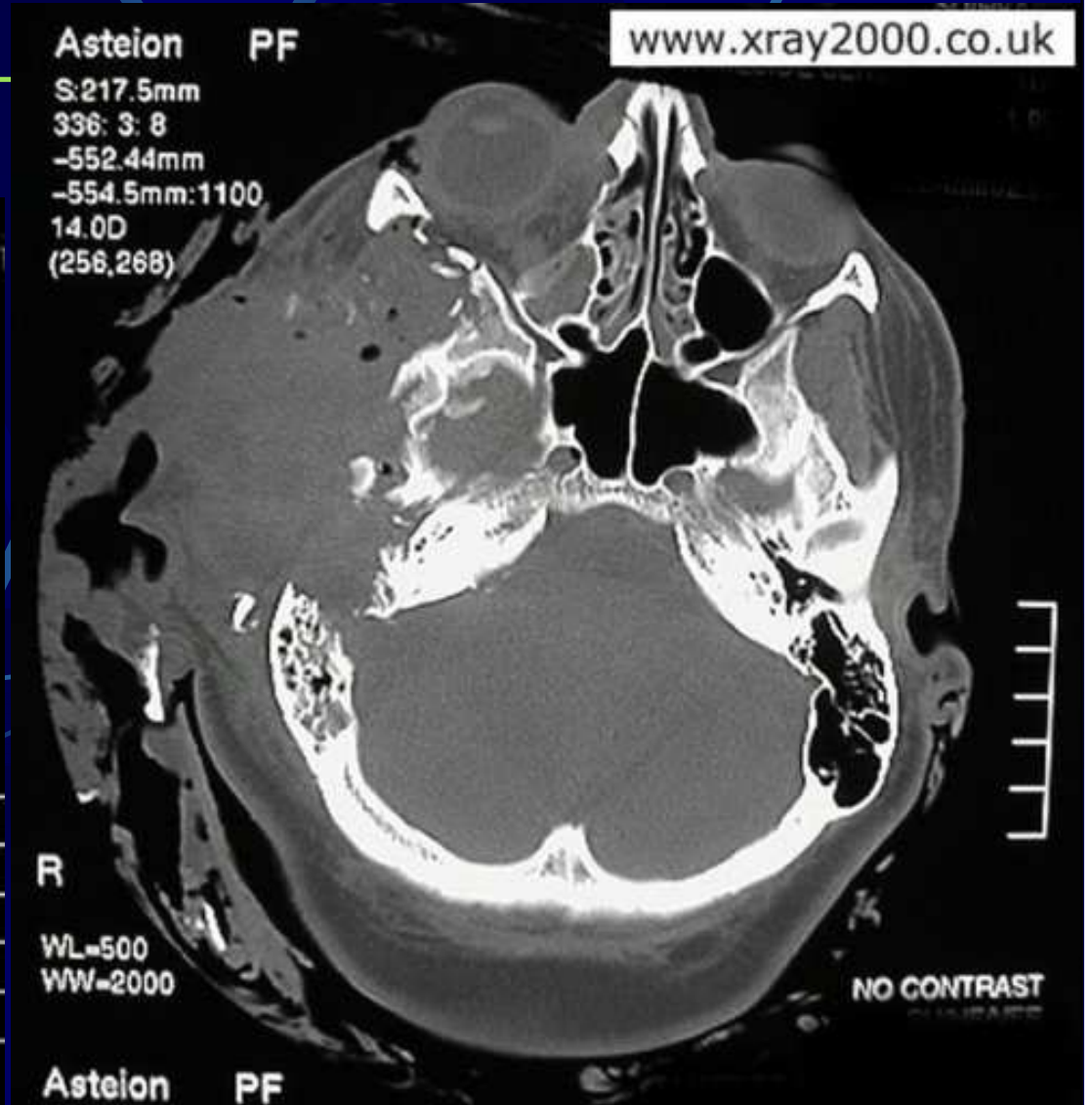
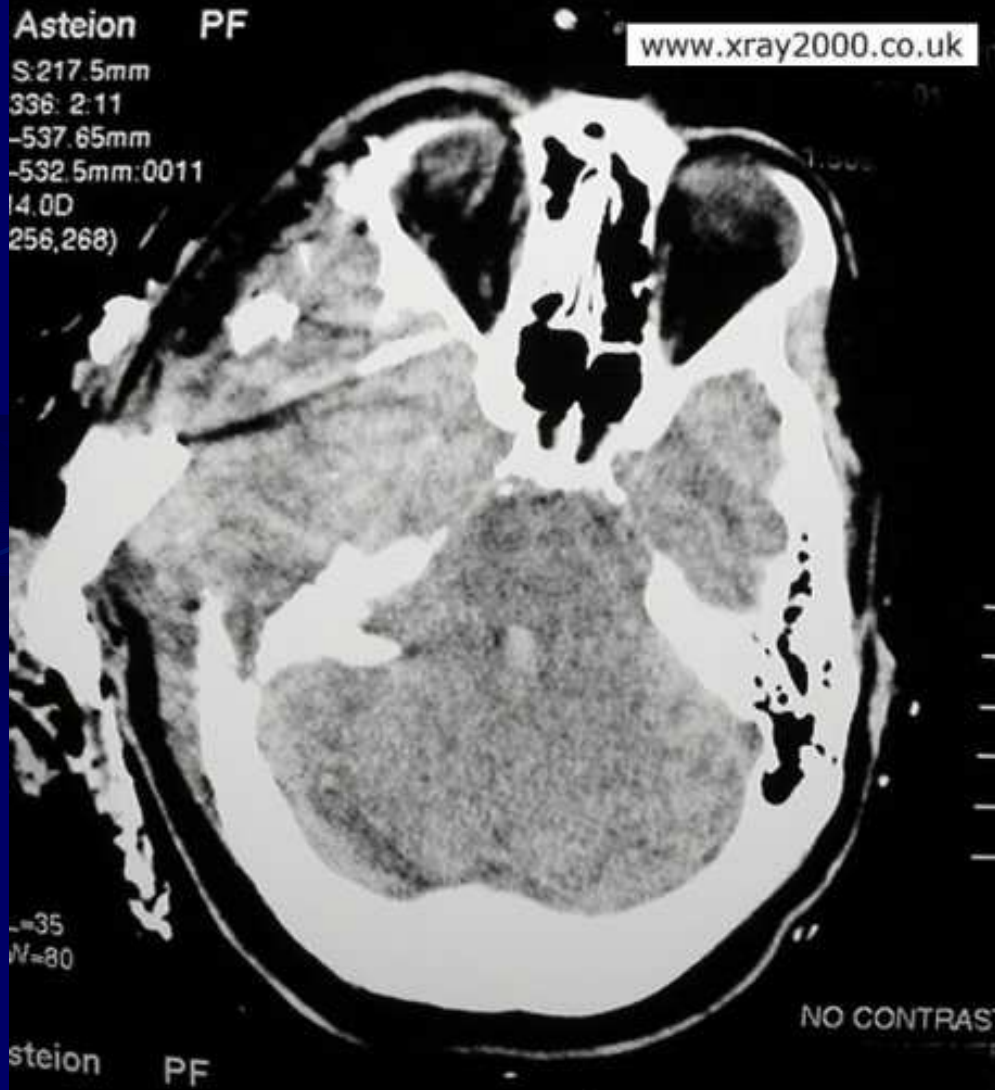


Cysta





Frantura

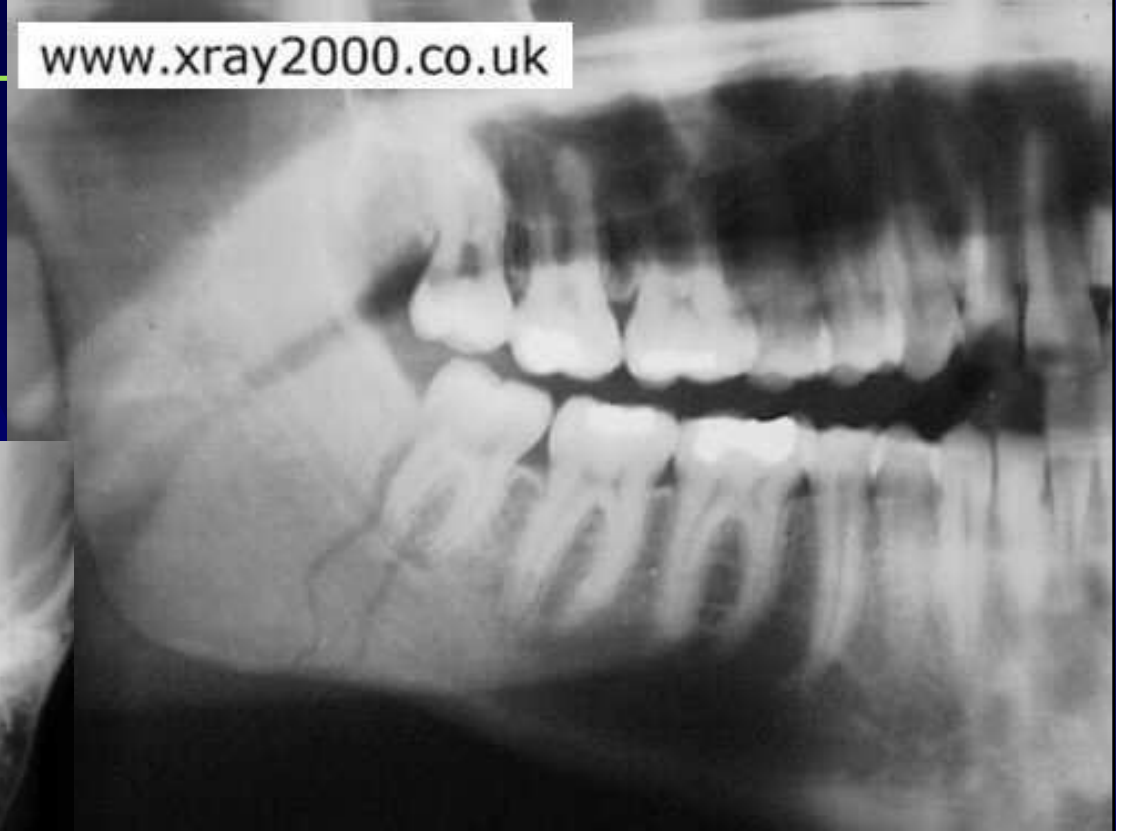



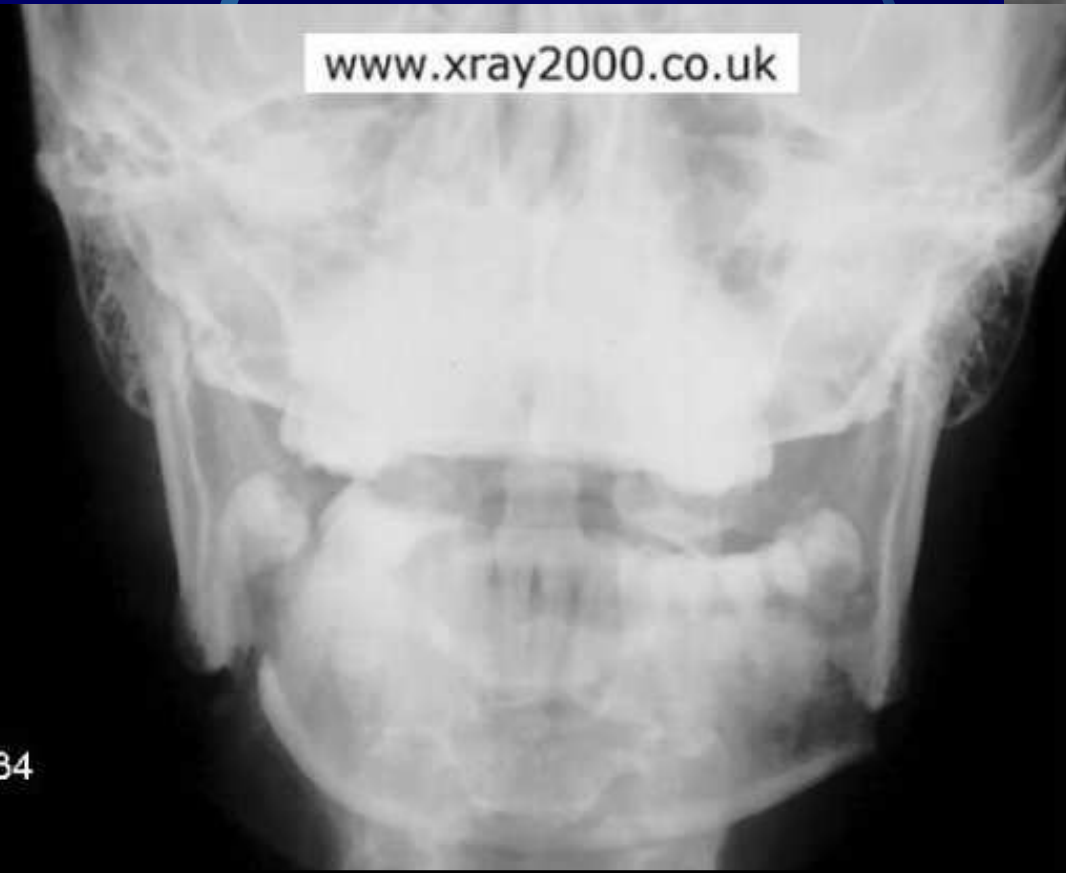Frantura



www.xray2000.co.uk



www.xray2000.co.uk





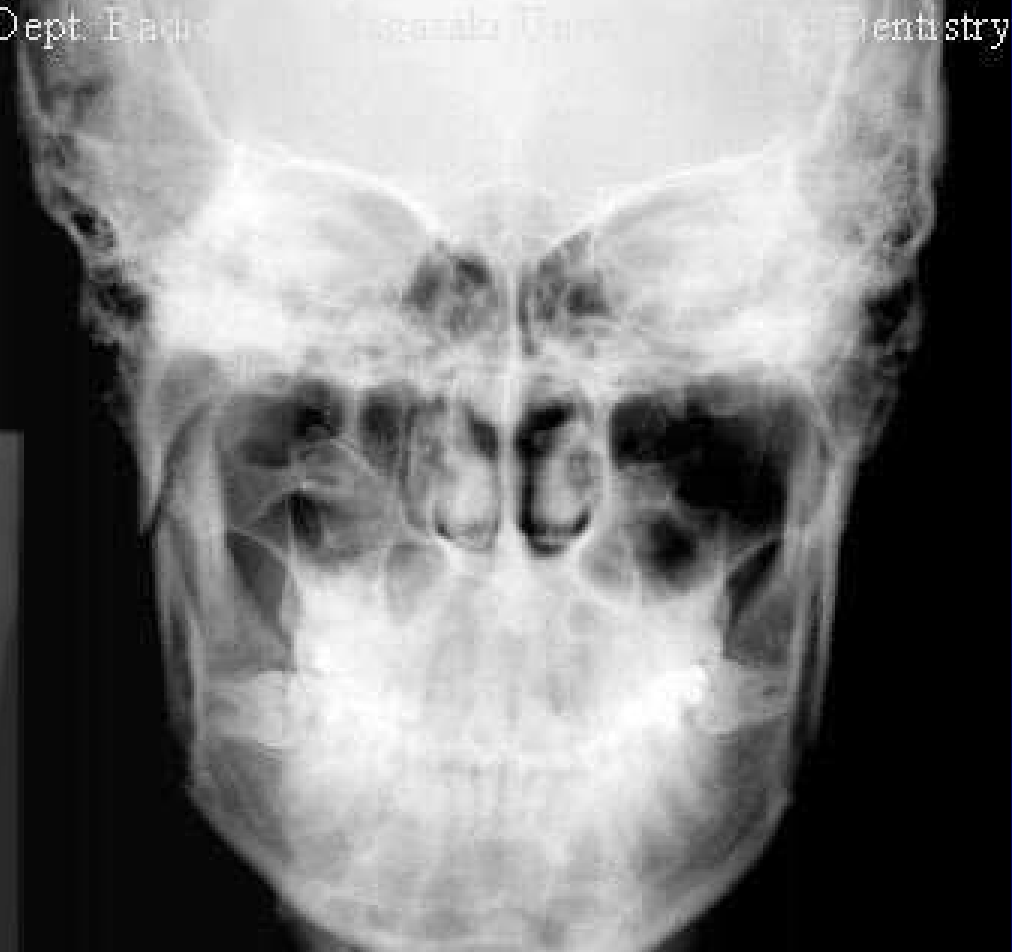
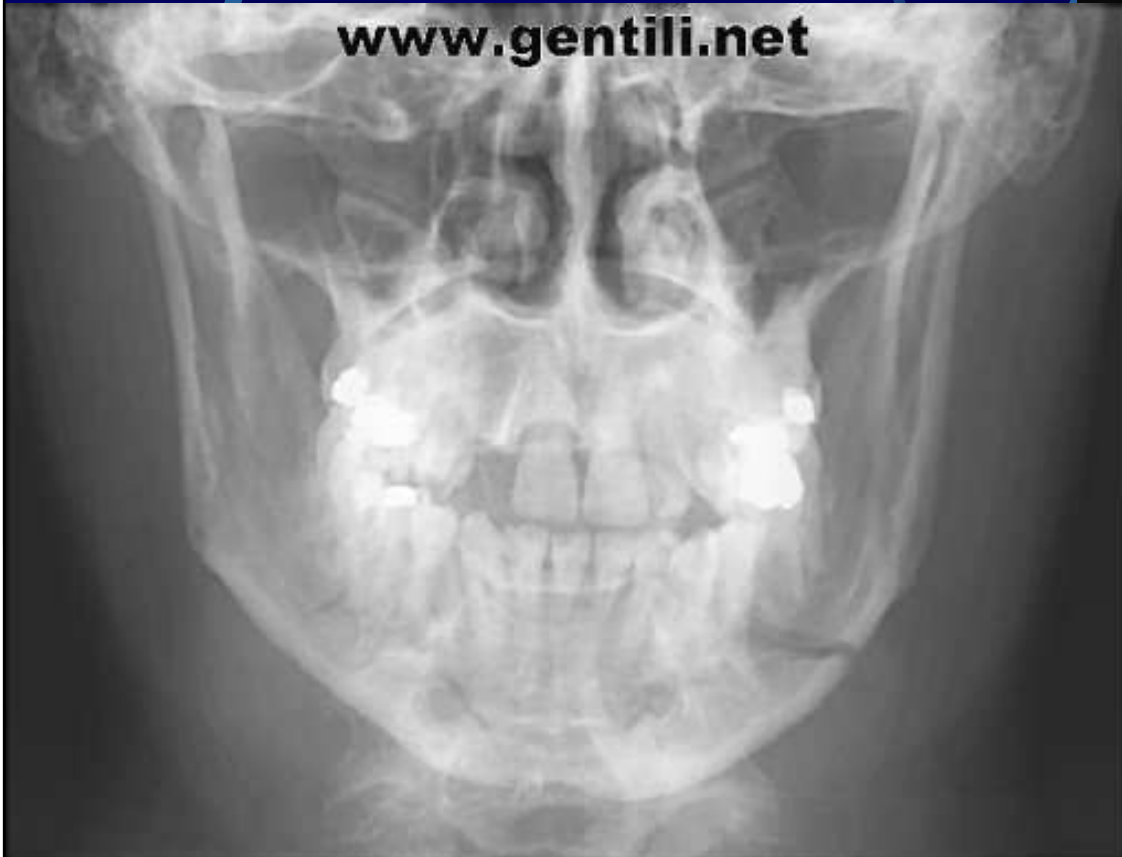Frantura



Dept. Radiology, Masaryk University Brno, Faculty of Dentistry



www.gentili.net

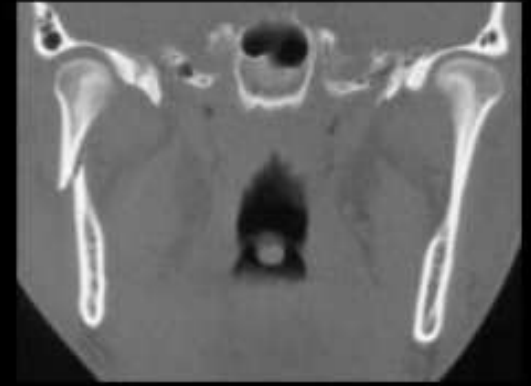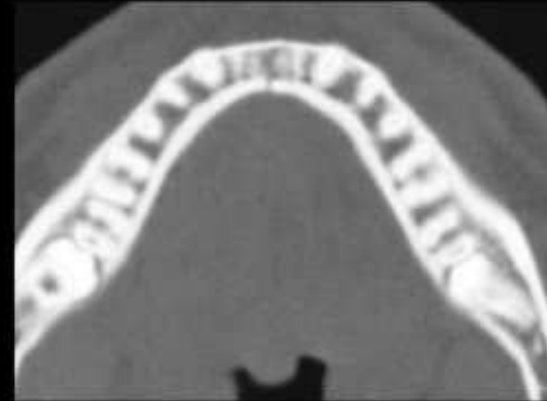

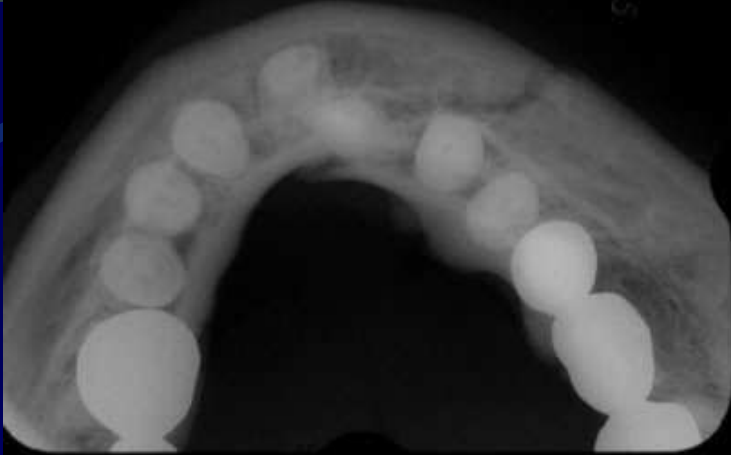


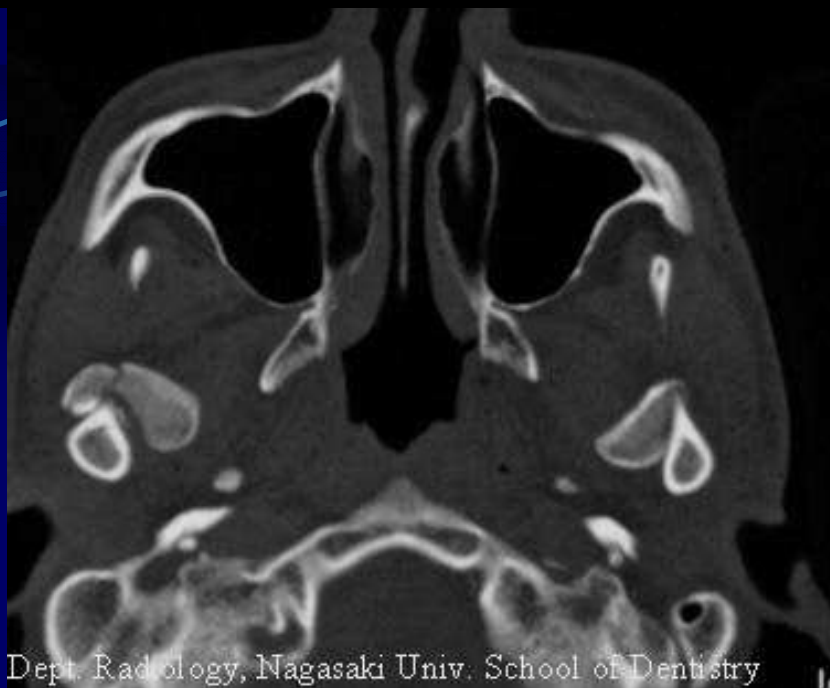Frantura



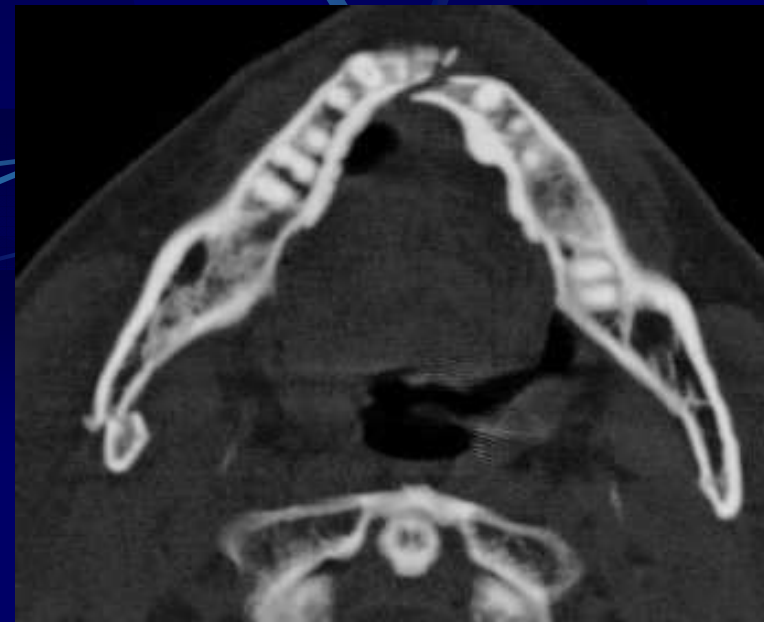
Dept. Radiology, Nagasaki Univ. School of Dentistry




Dept. Radiology, Nagasaki Univ. School of Dentistry



Dept. Radiology, Nagasaki Univ. School of Dentistry

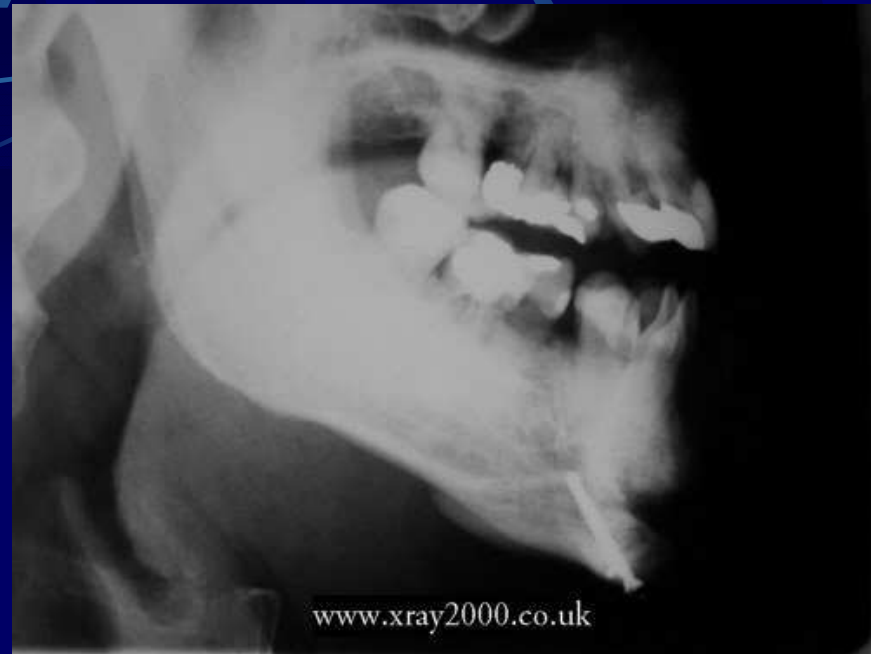
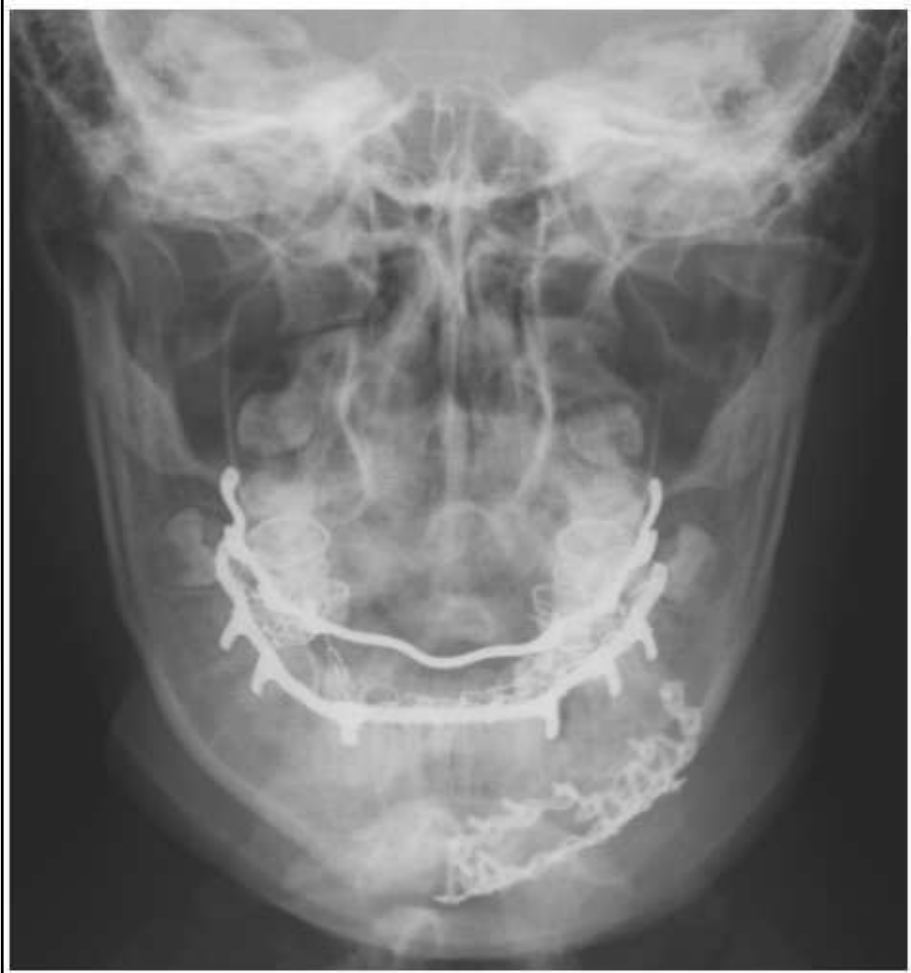
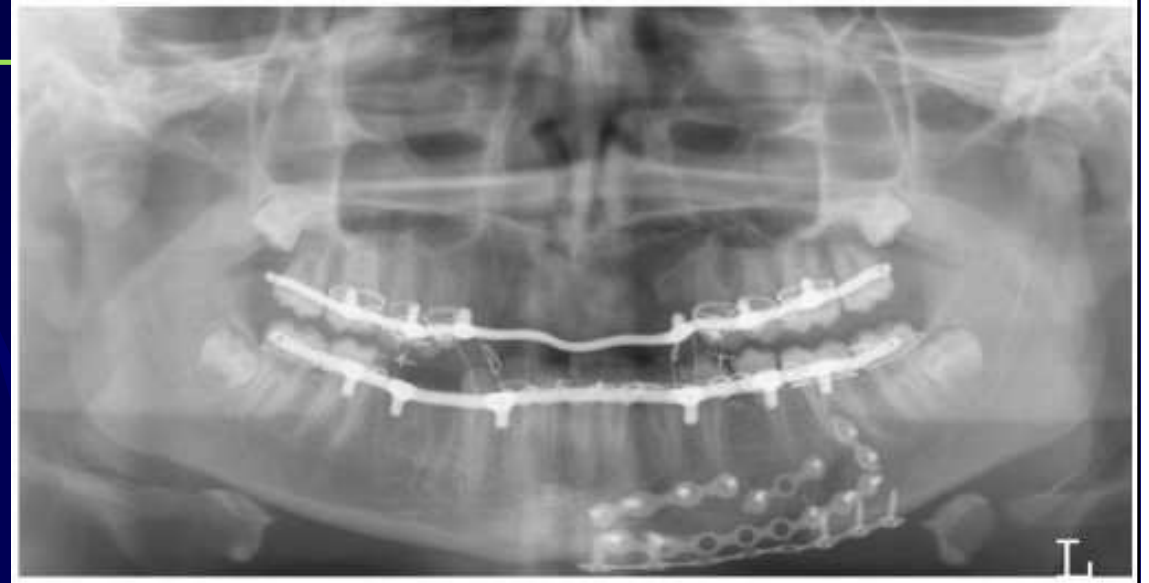
Dept. Radiology, Nagasaki Univ. School of Dentistry





Frantura

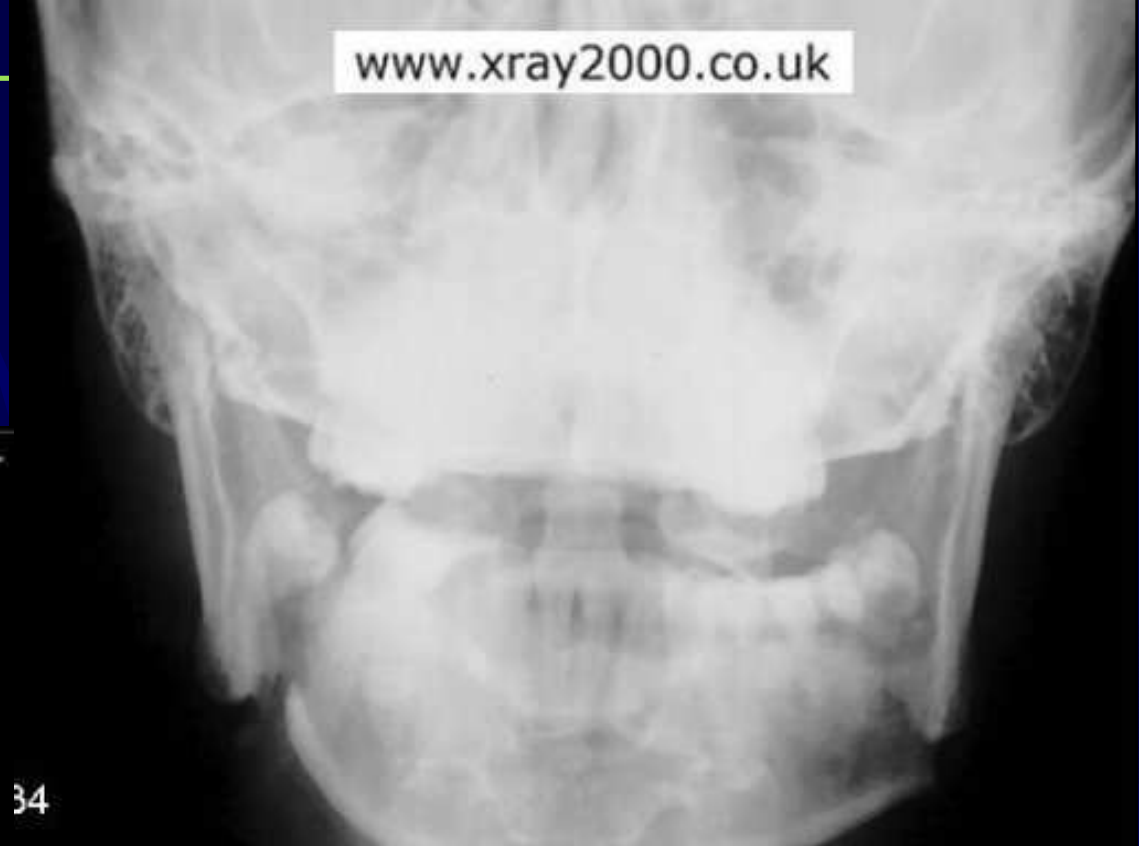



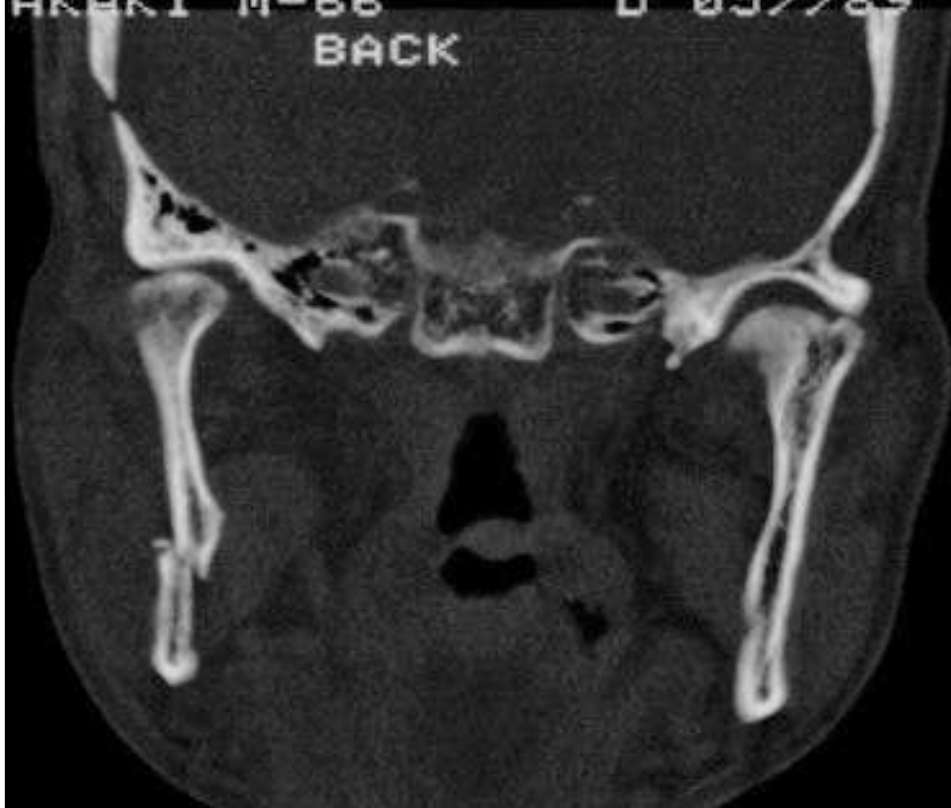Frantura



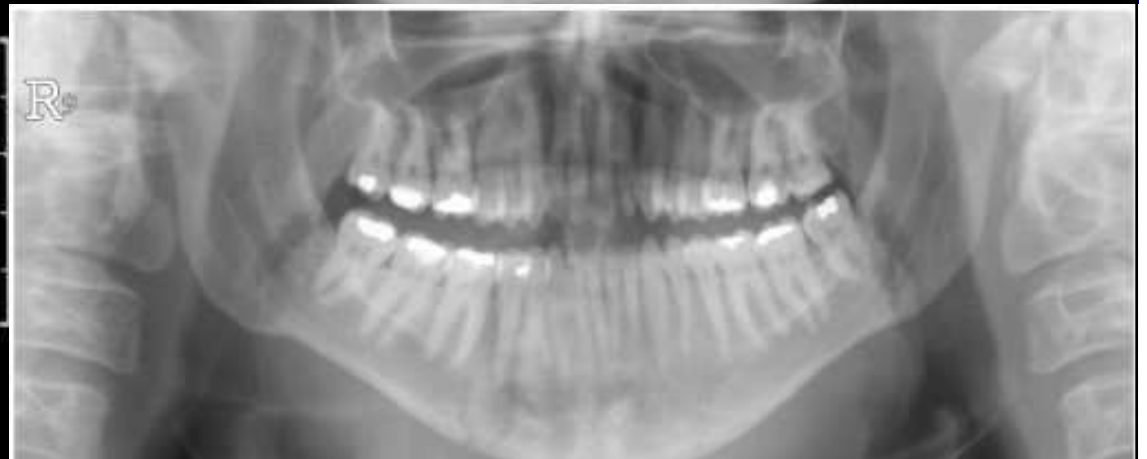www.xray2000.co.uk



R-H NAGASAKI UNIV. DENTAL
AKAKI M-66 D 057789
BACK

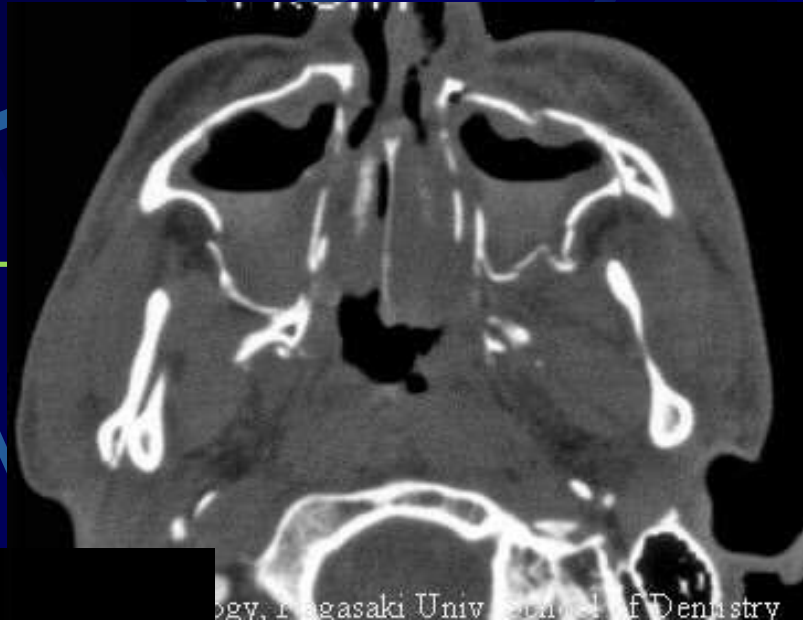


34

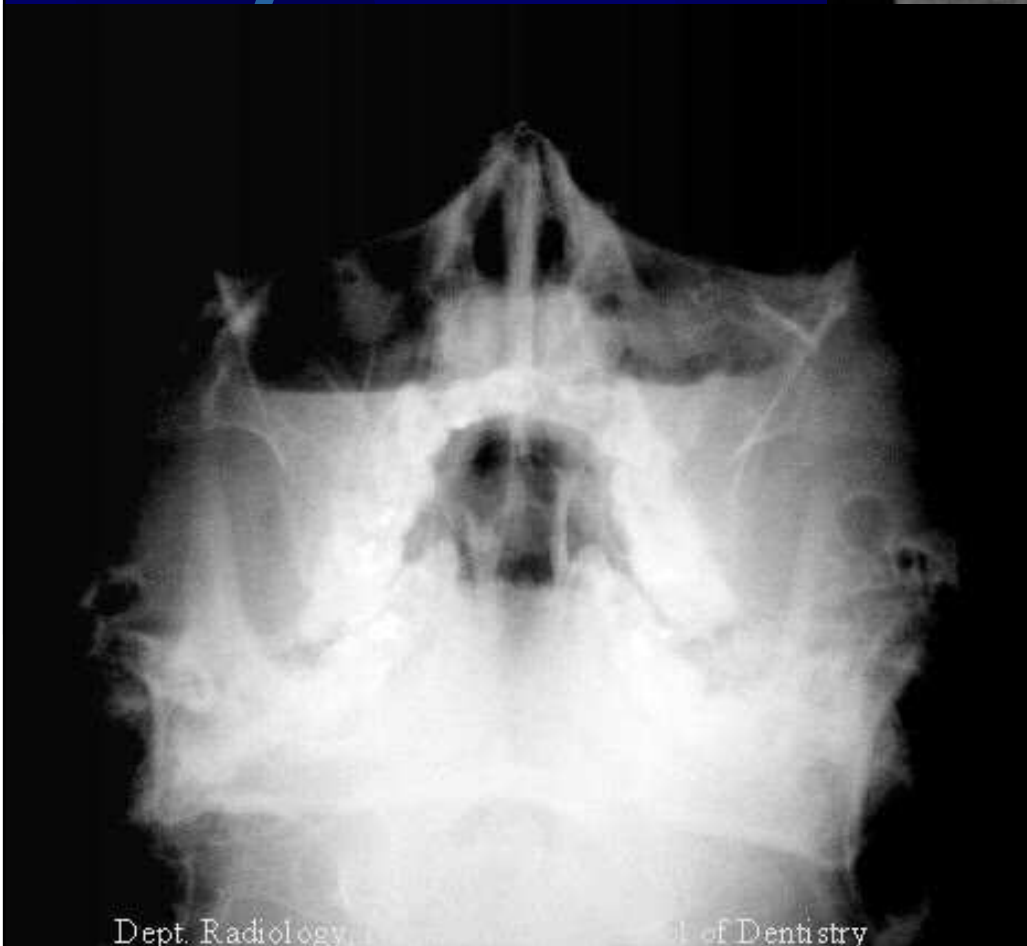



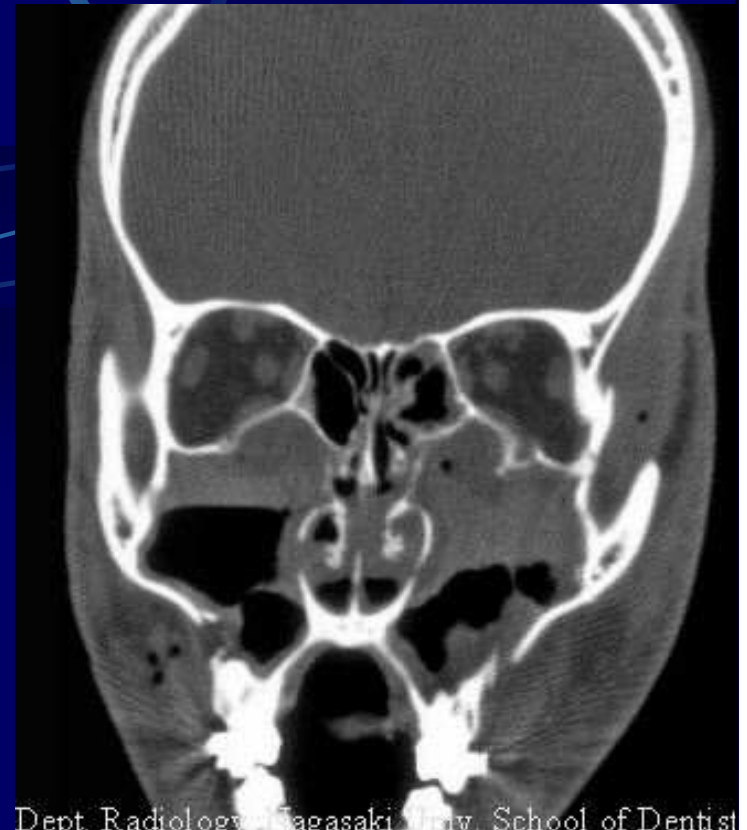Frantura



Dept. Radiology, Nagasaki Univ. School of Dentistry



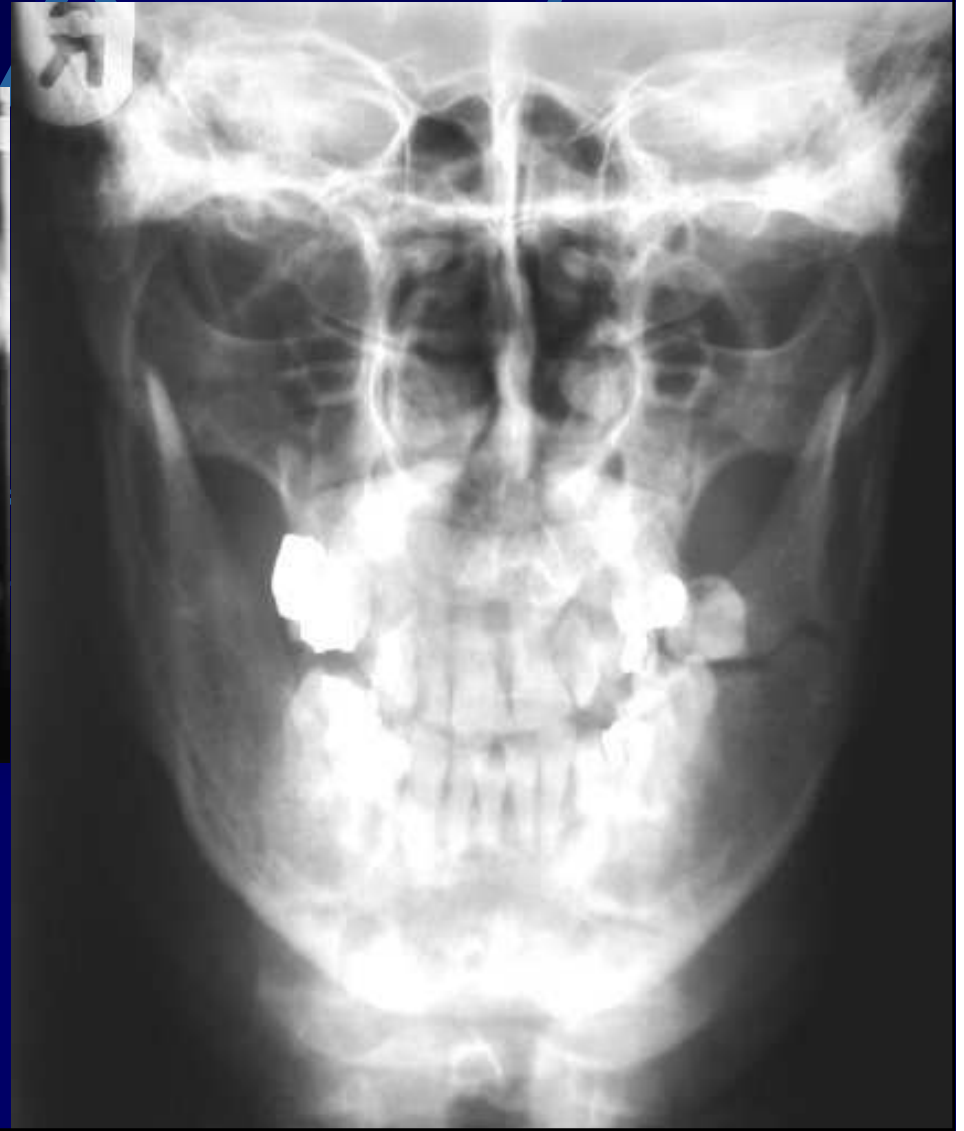
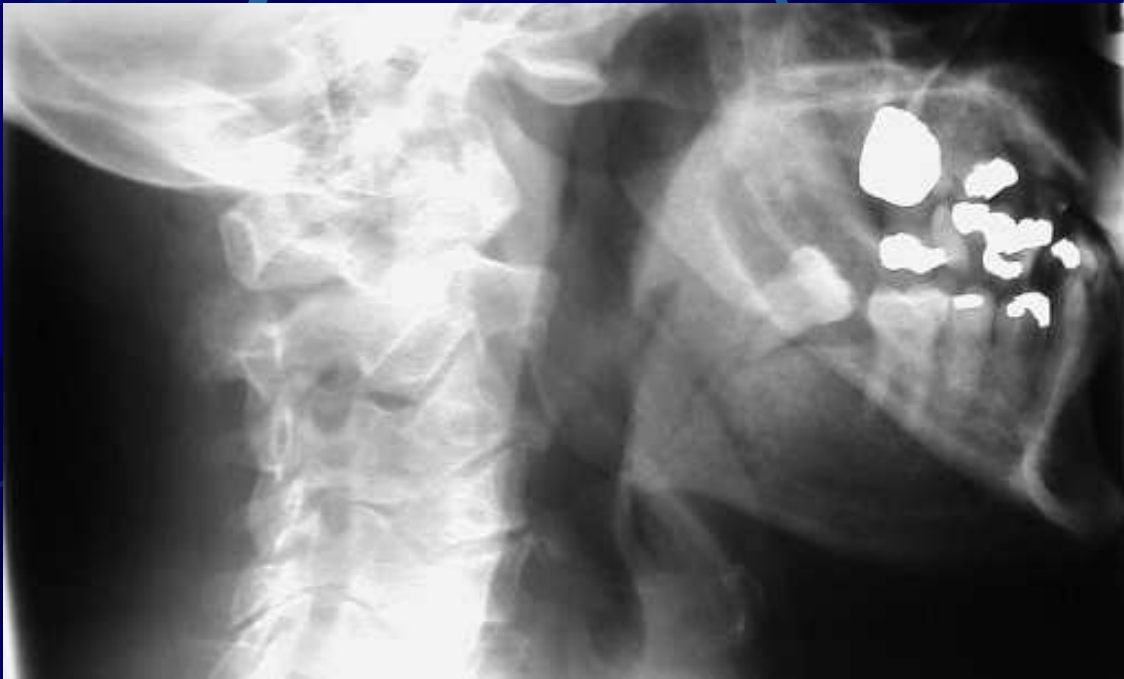Dept. Radiology, Nagasaki Univ. School of Dentistry



Dept. Radiology, Nagasaki Univ. School of Dentistry

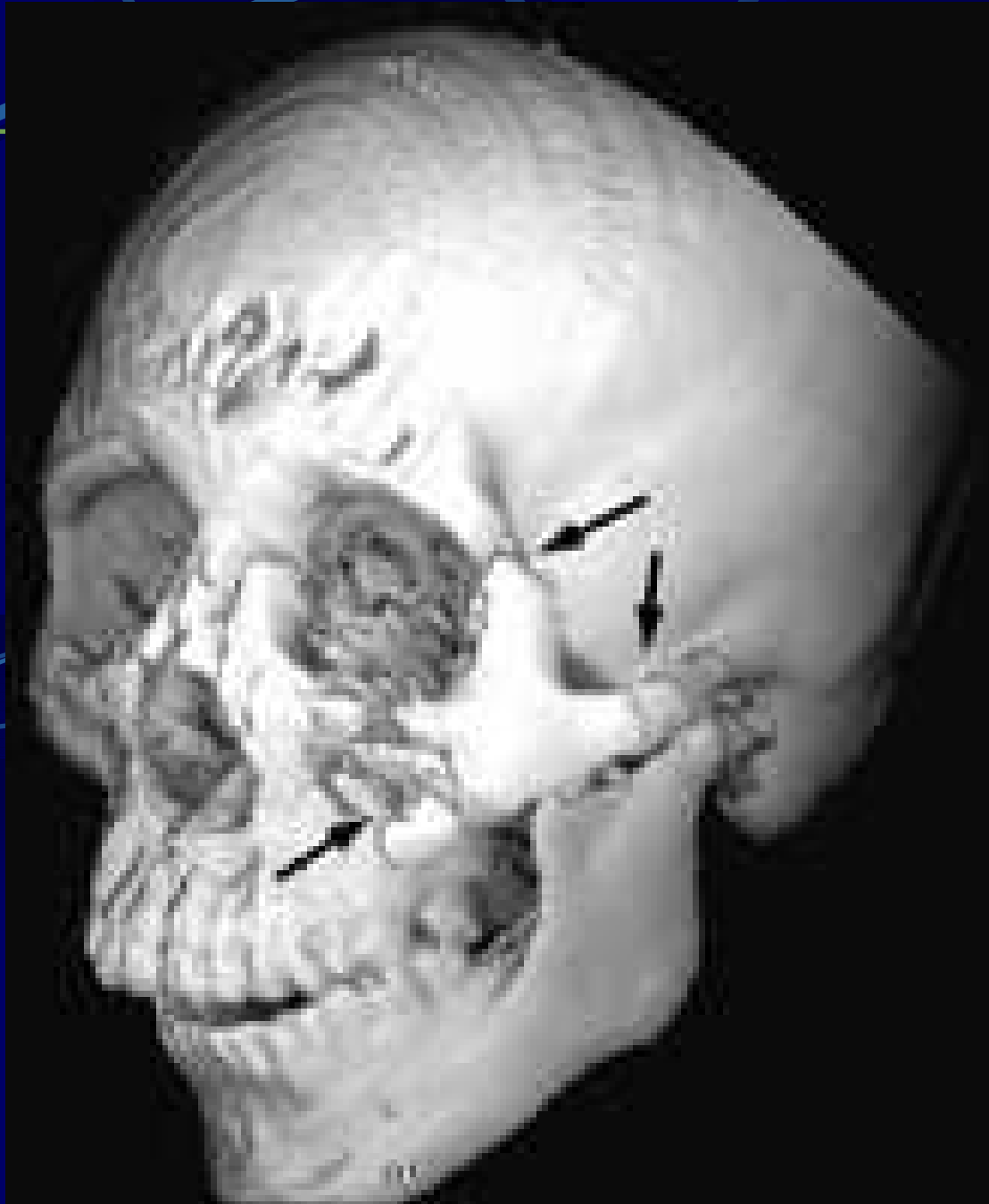

Frantura





Frantura





Zuby – náhrada

