




RTG zubů a čelistí

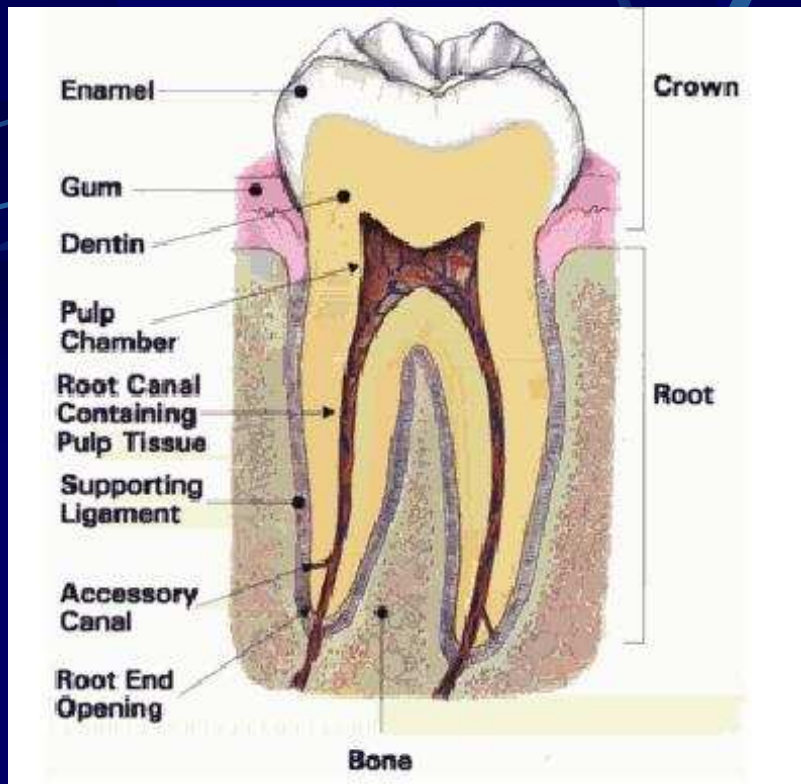
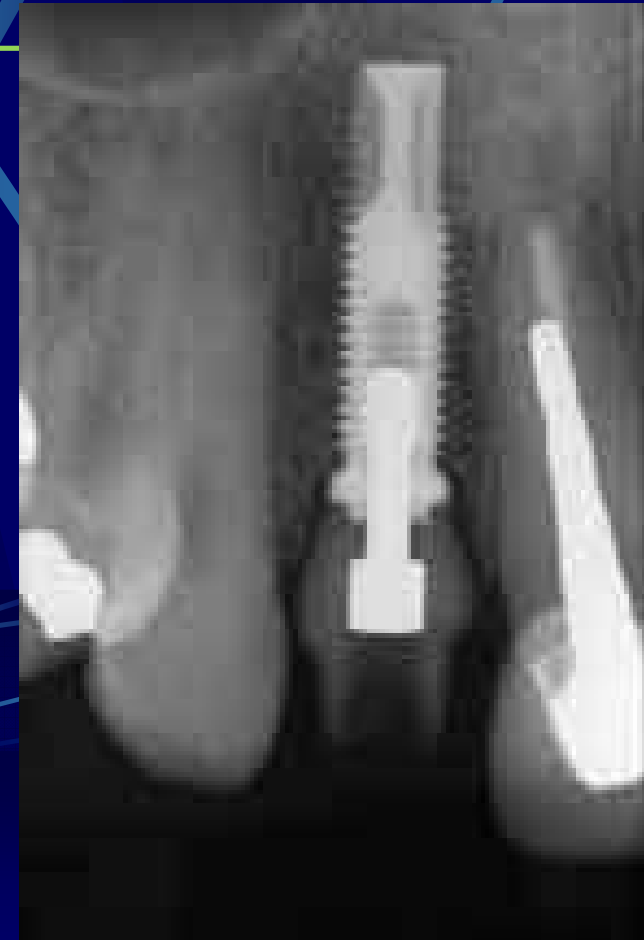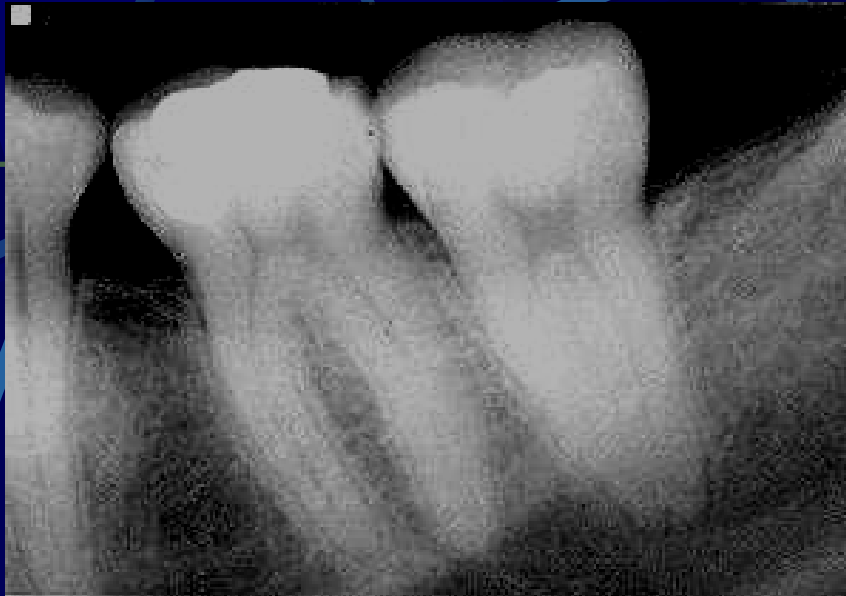Válek V. A.
Radiologická klinika LF, MOU Brno




Anatomie

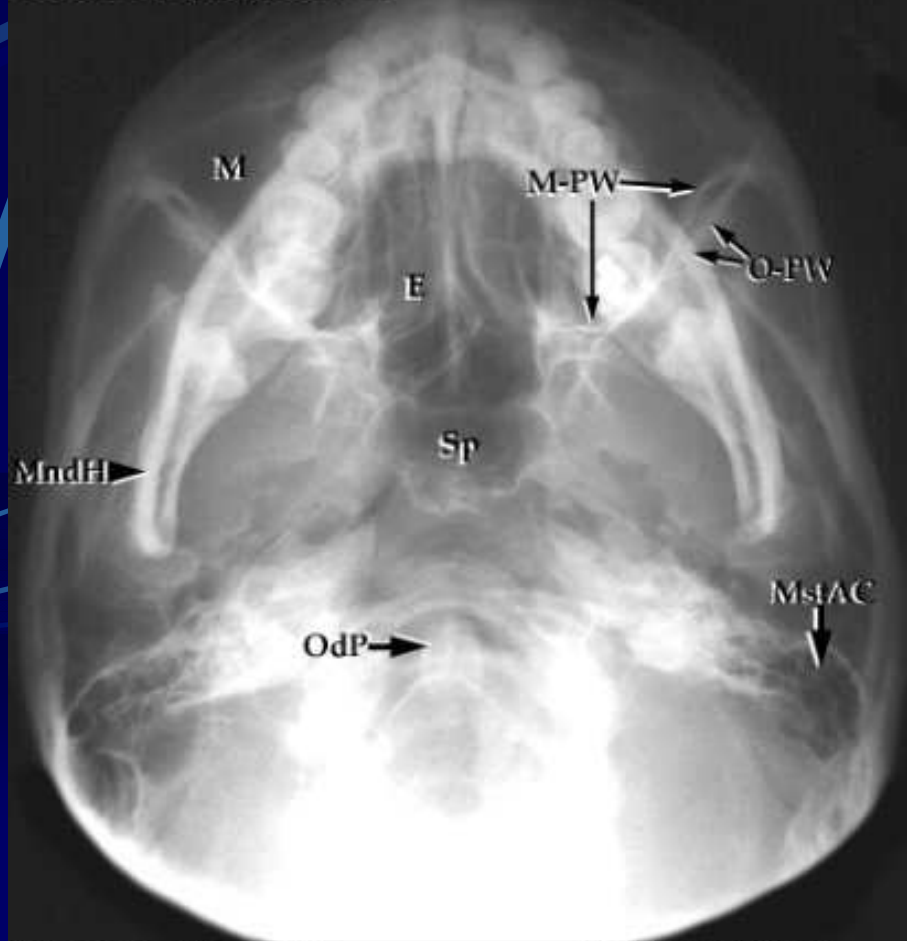


Anatomie

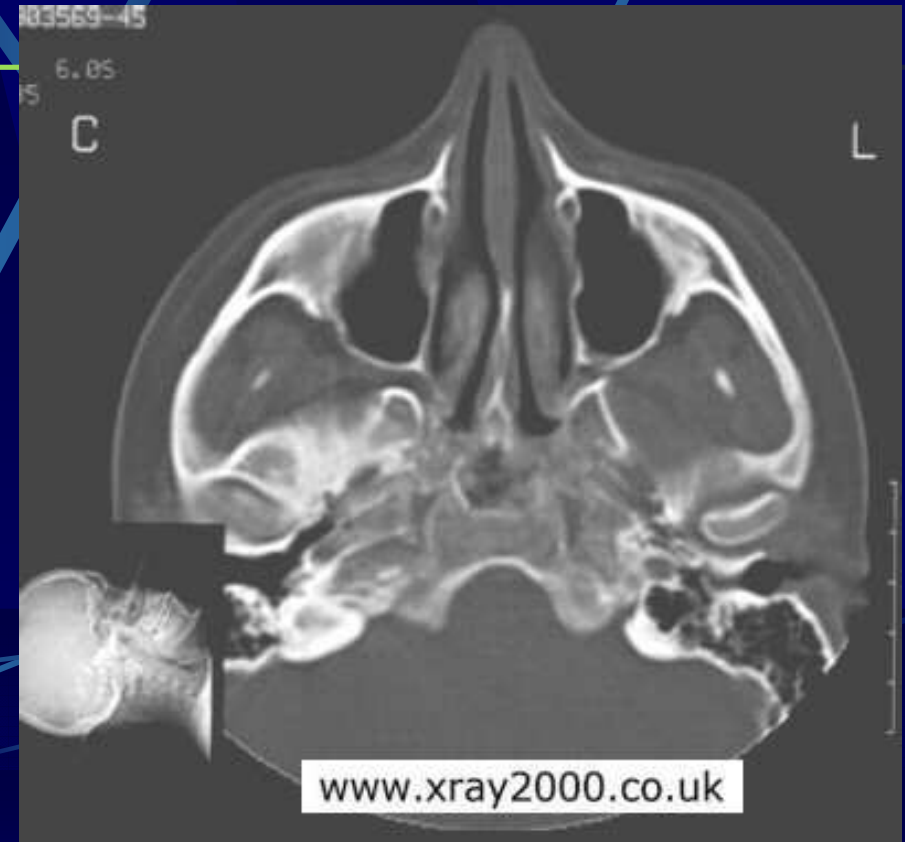



Base of the Skull

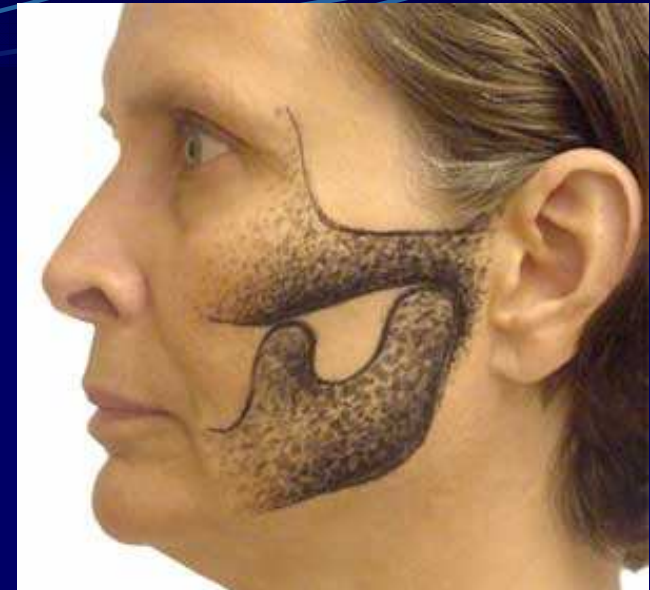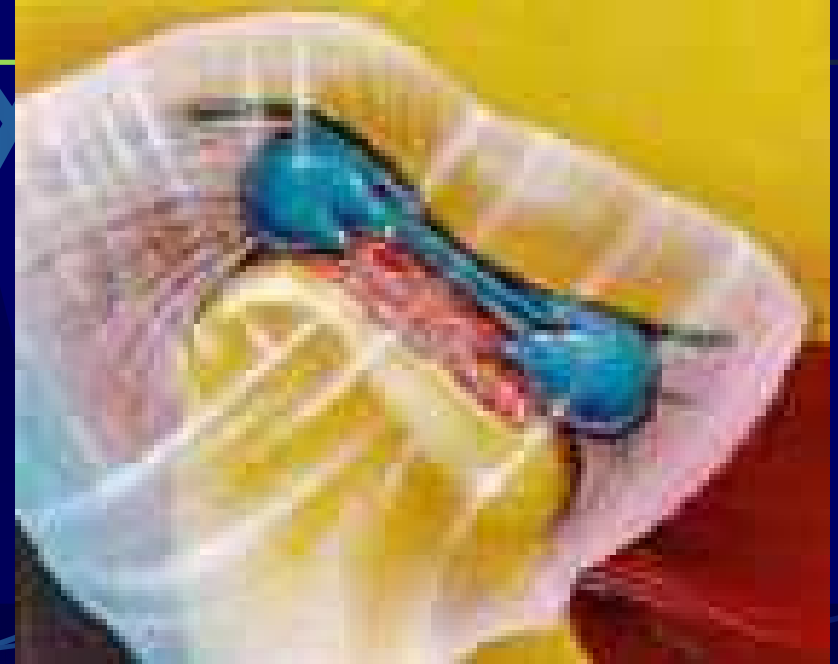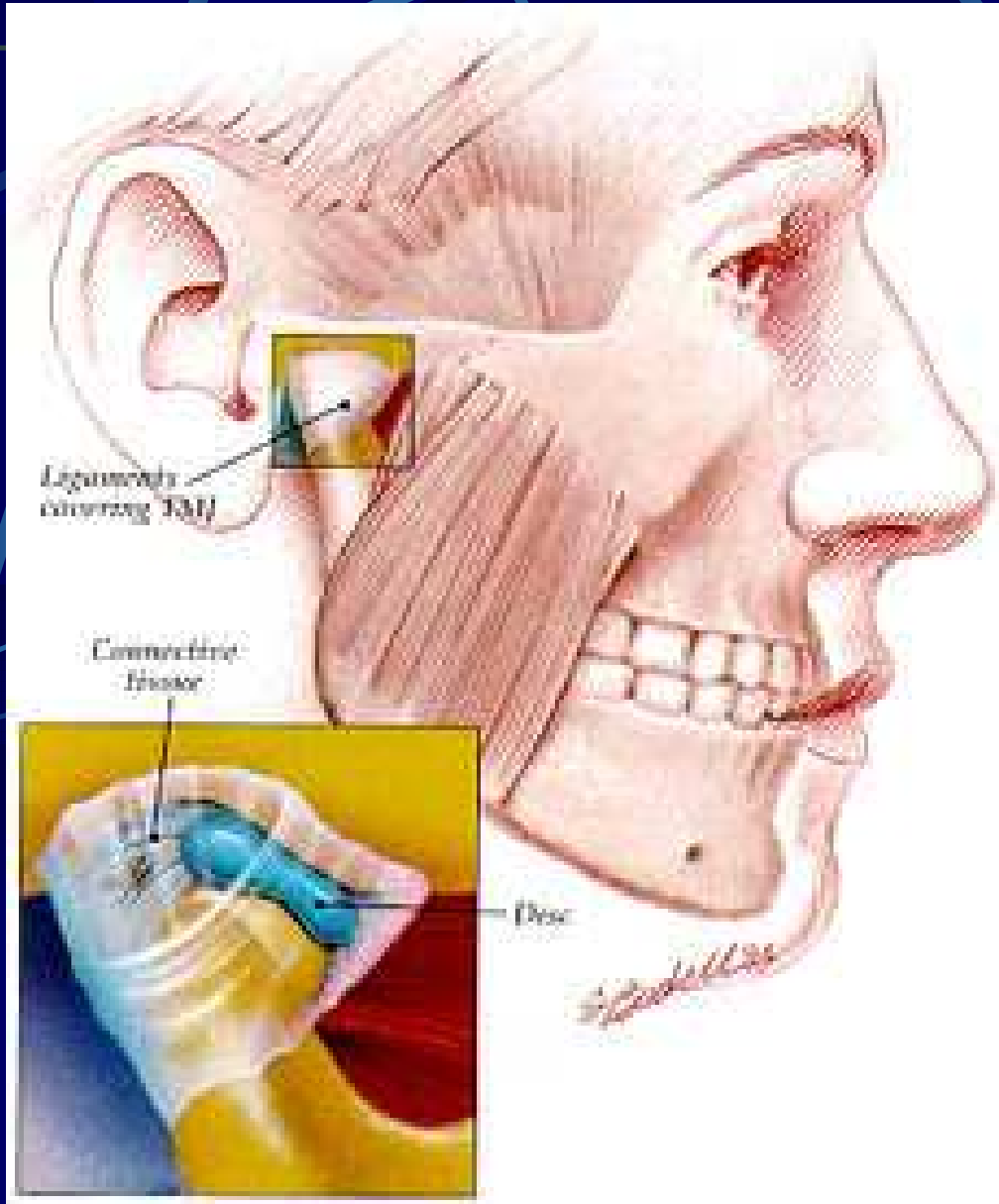


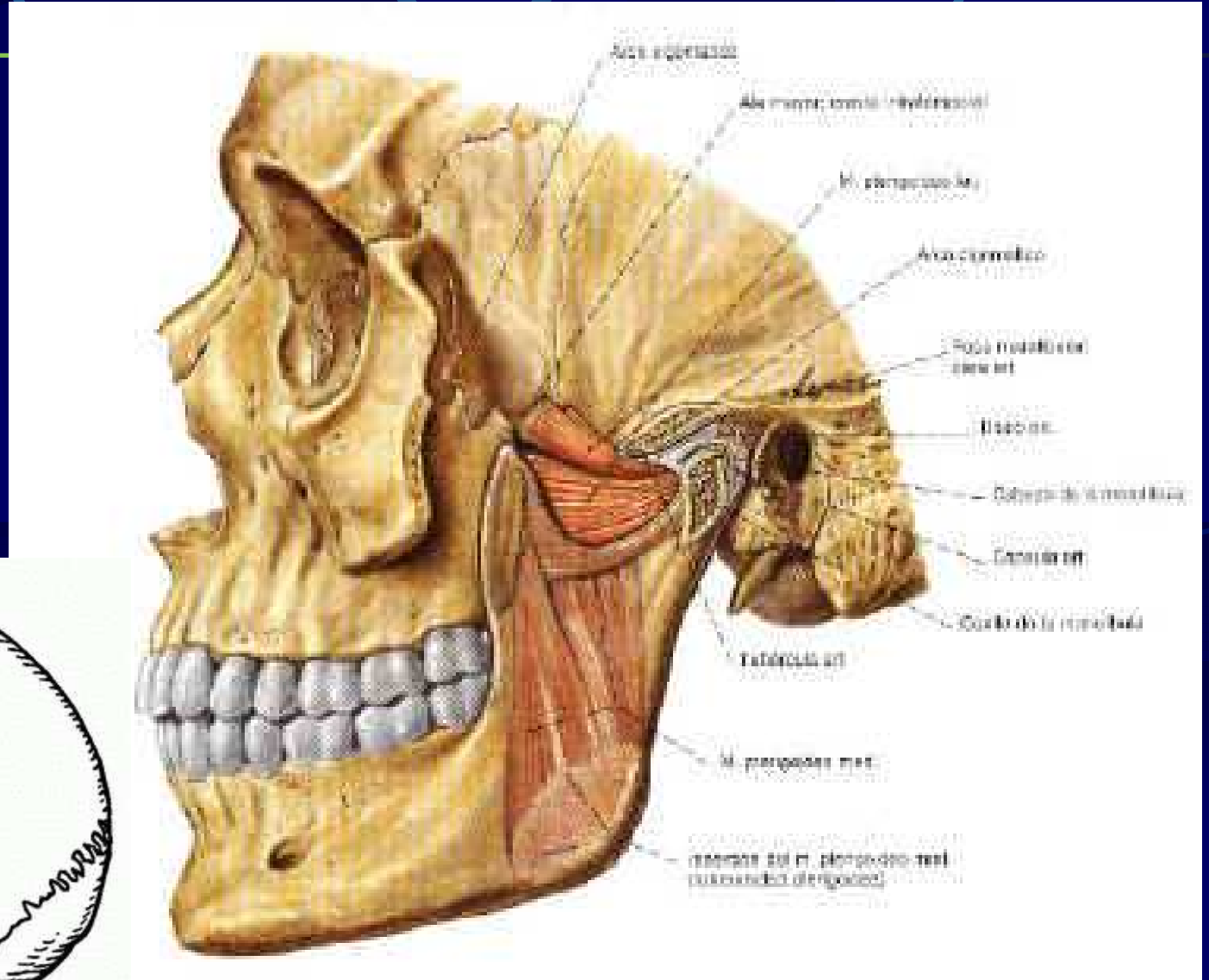
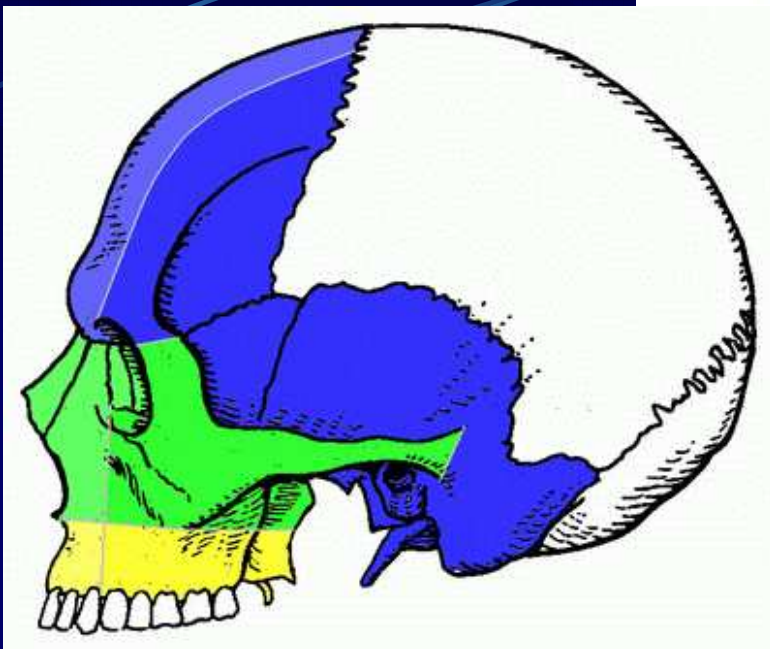

MstAC=Mastoid Air Cells	Sp=Sphenoid Sinus
E=Ethmoid Sinus (Air Cells)	M=Maxillary Sinus
O-PW=Posterior Wall of Orbit	MndH=Head of Mandible
M-PW=Posterior Wall of Maxillary Sinus	OdP=Odontoid Process





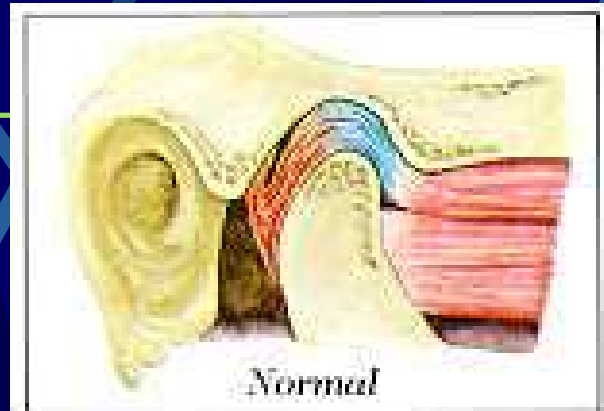

Anatomie



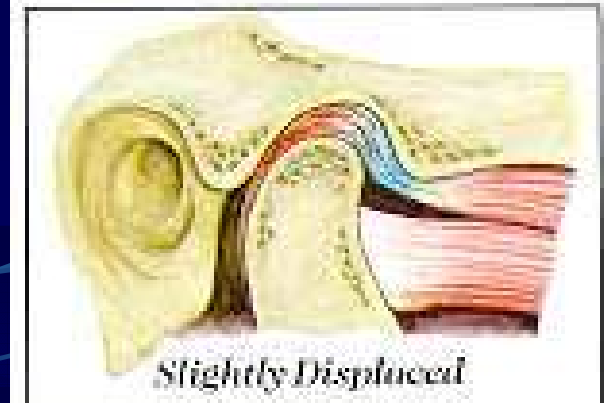




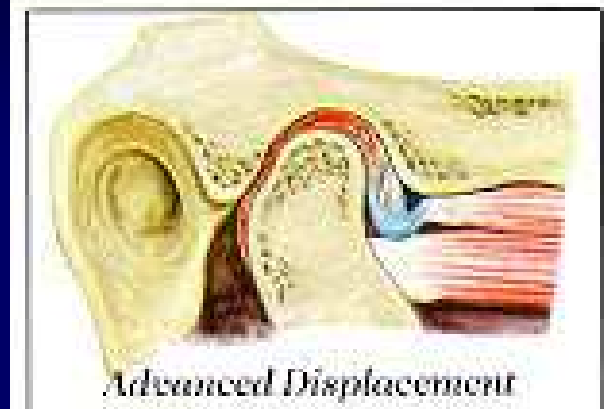
Anatomie



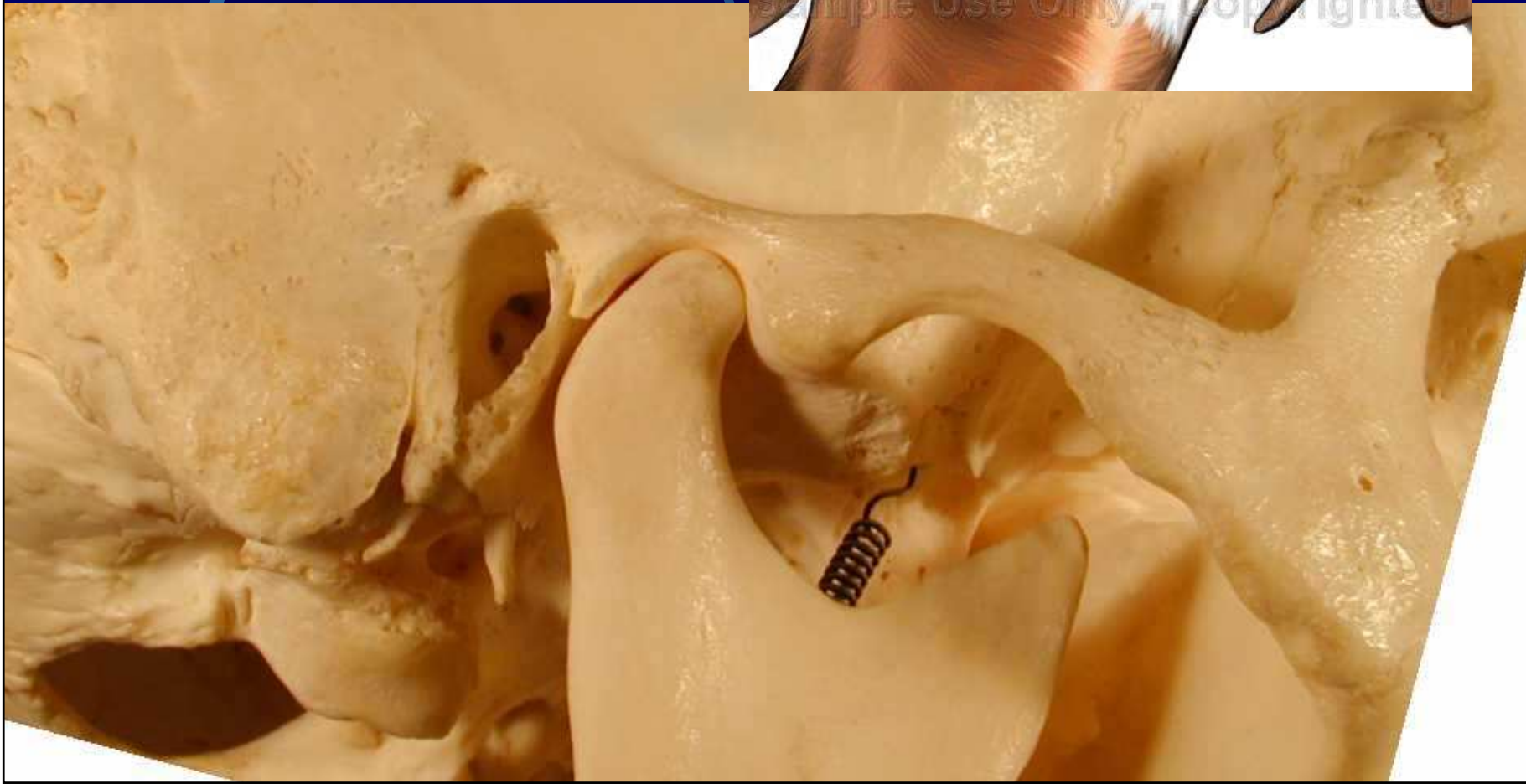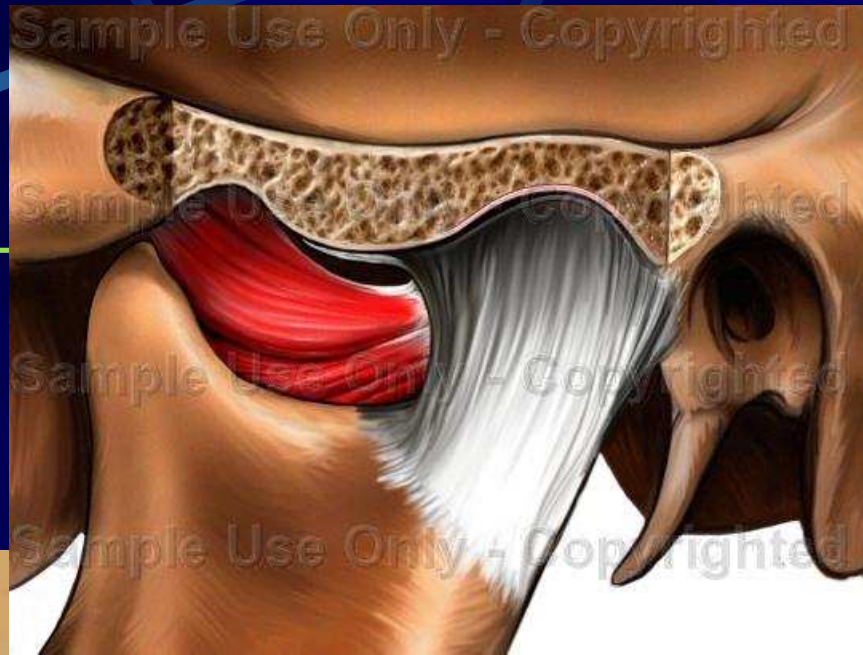
Normal



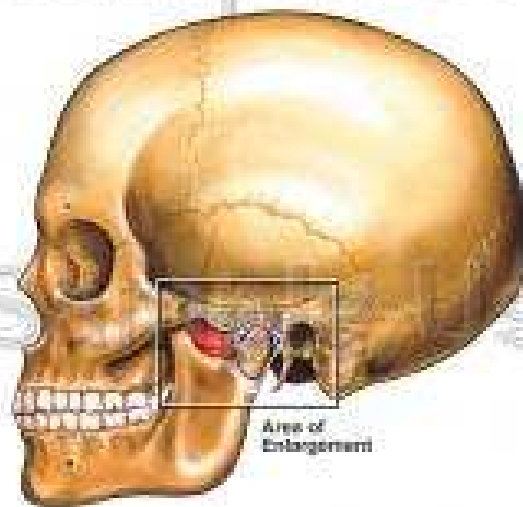
Slightly Displaced



Advanced Displacement



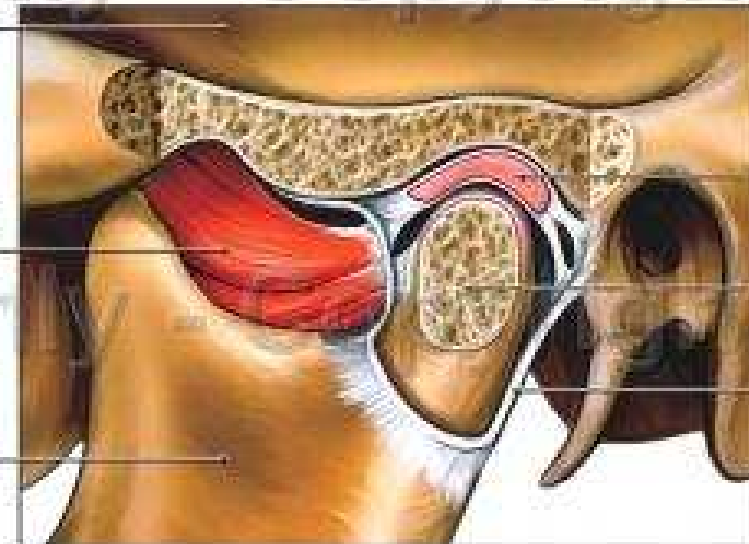
Anterior Displacement of the Left Temporomandibular Joint (TMJ)



Temporal bone

Pterygoid muscle

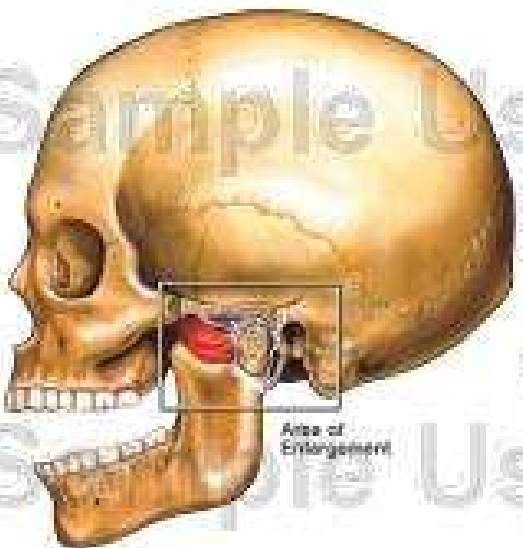
Mandible



Meniscus

Condyle

Joint capsule

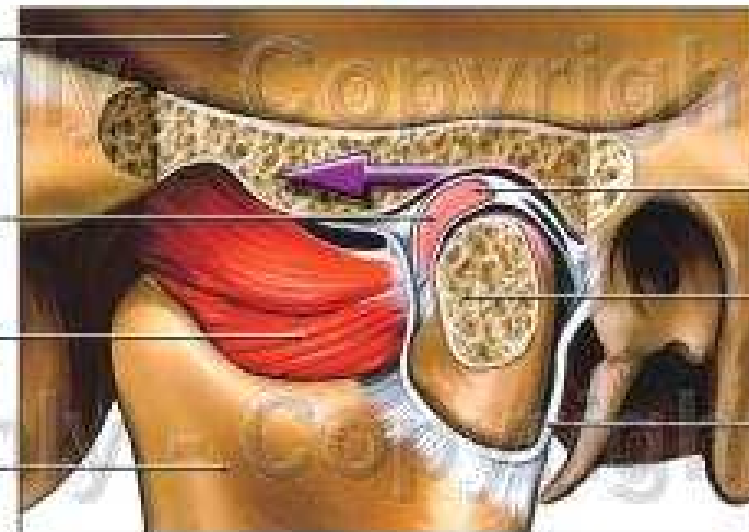


Temporal bone

Anterior displacement of TMJ meniscus

Pterygoid muscle

Mandible




Meniscus

Condyle

Joint capsule

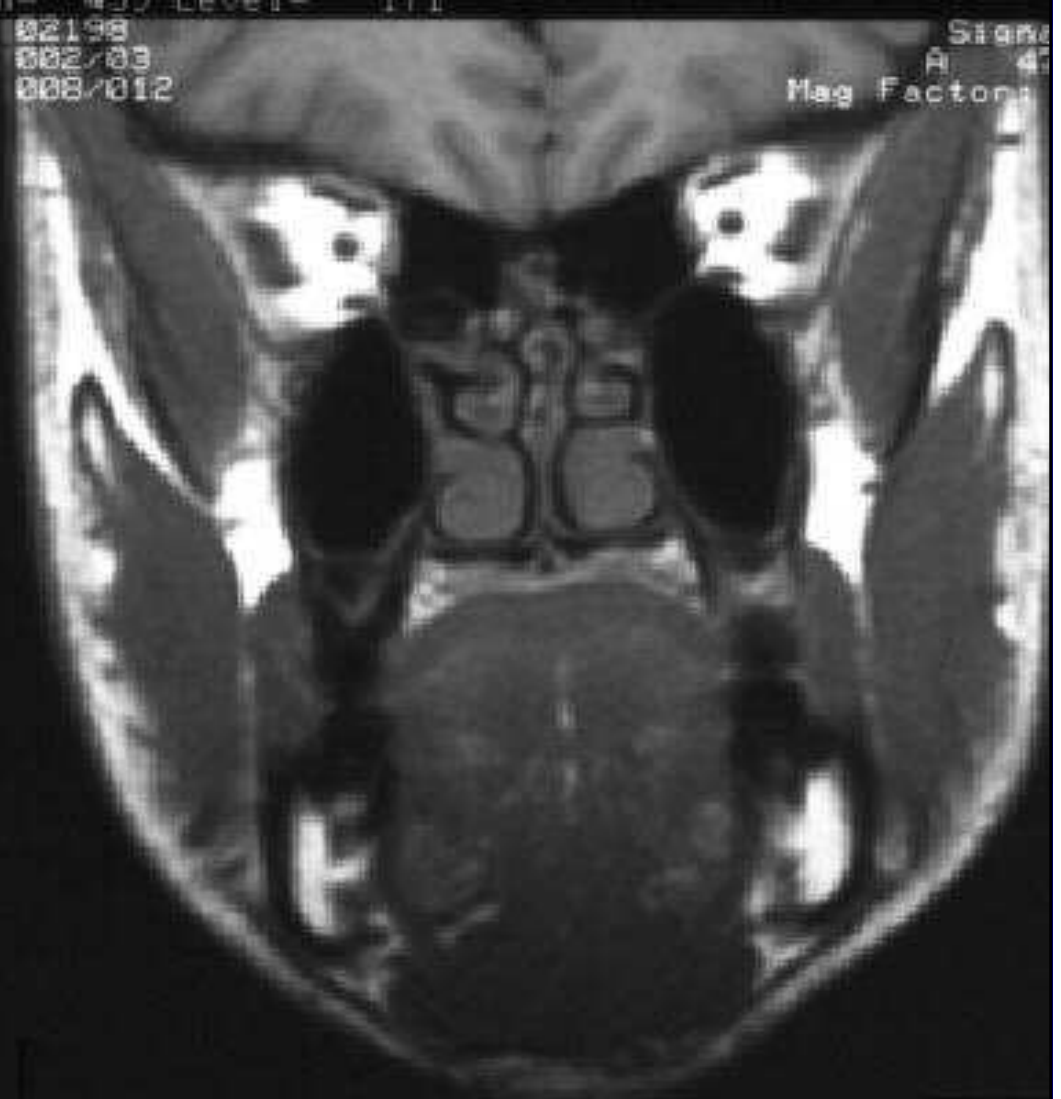
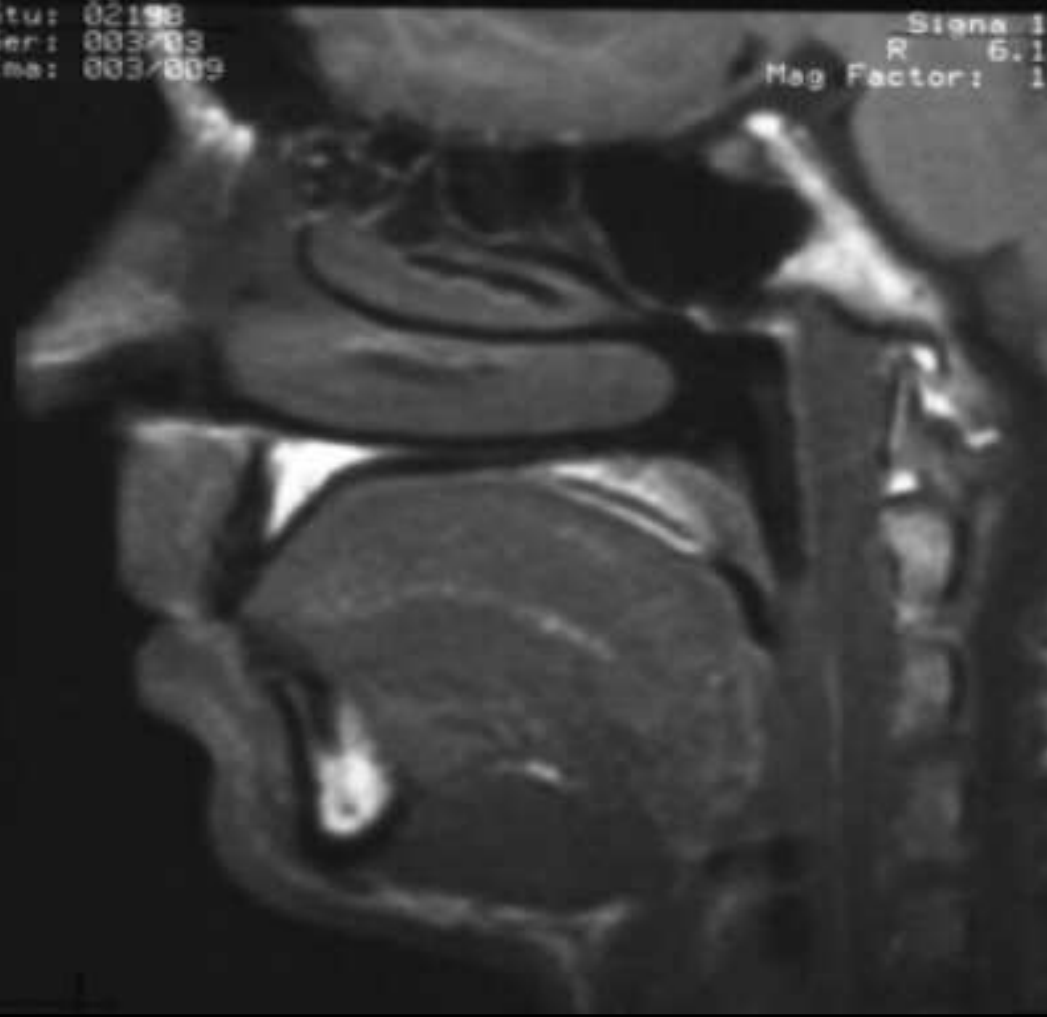
Anatomie



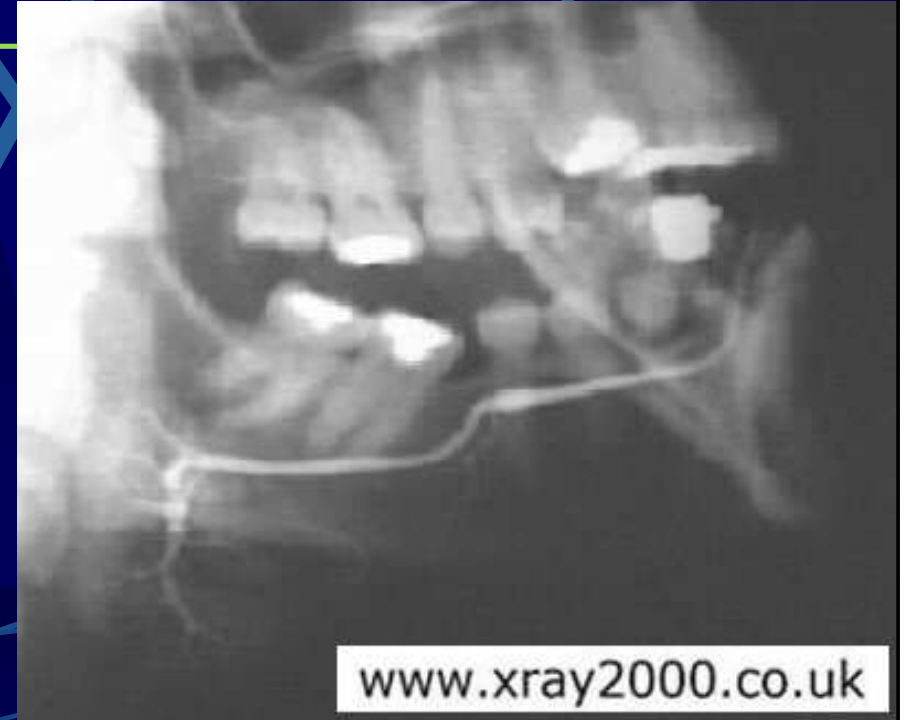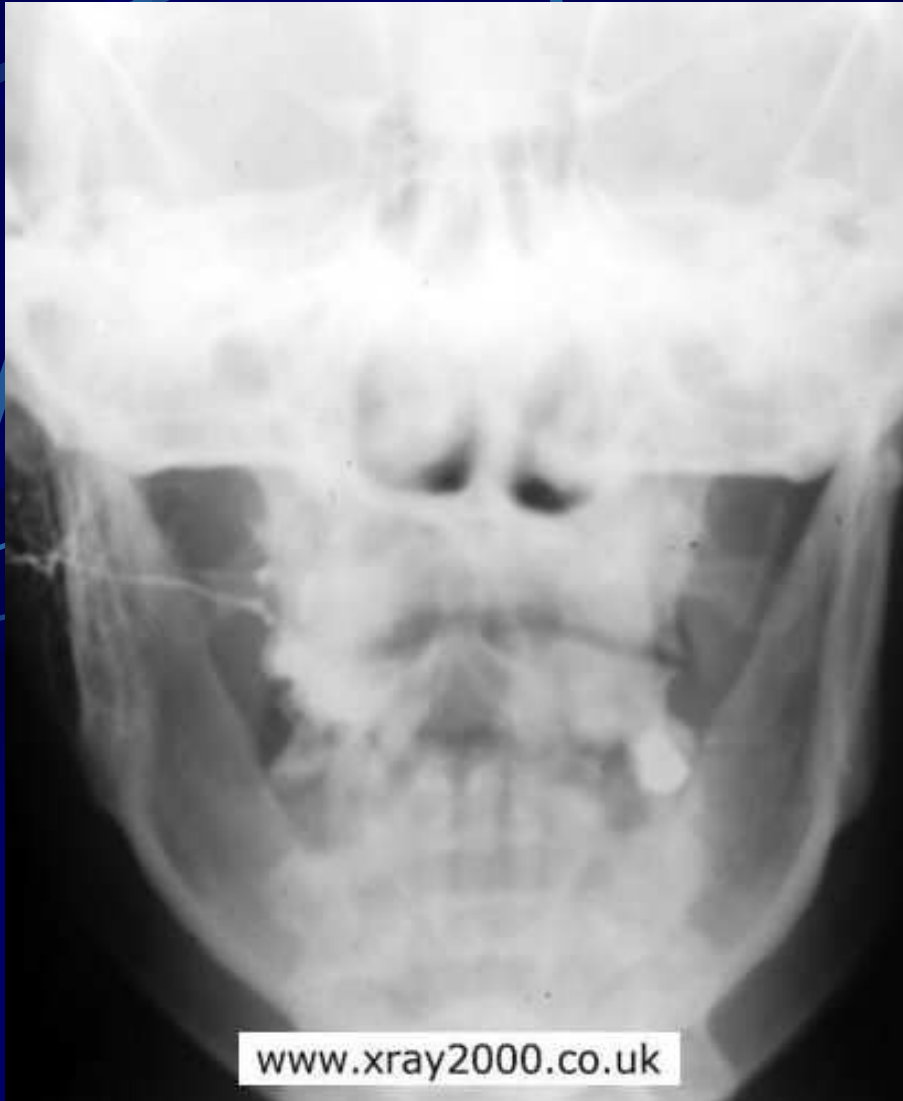tu: 02198
er: 003/03
na: 003/009

Signa: 1
R: 6.1
Mag Factor: 1



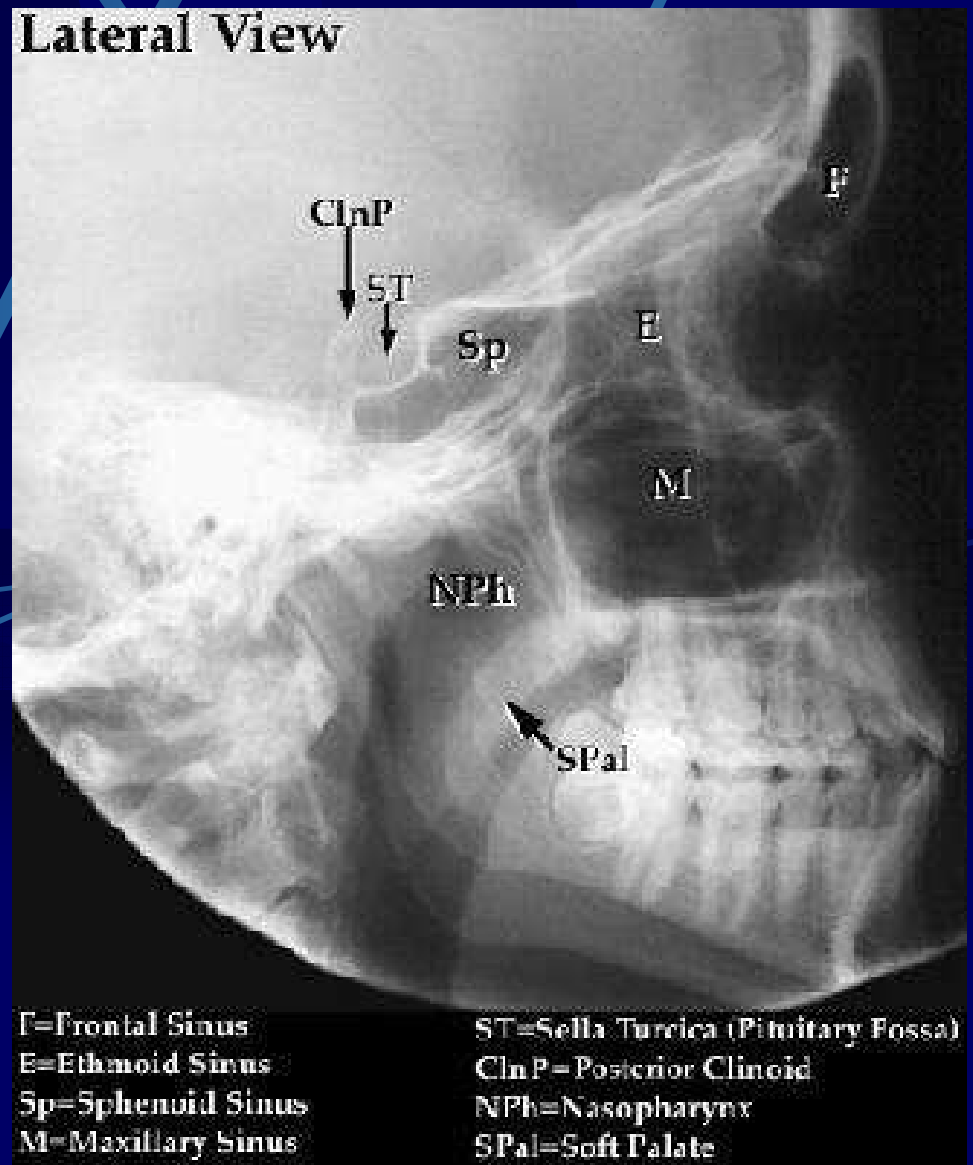
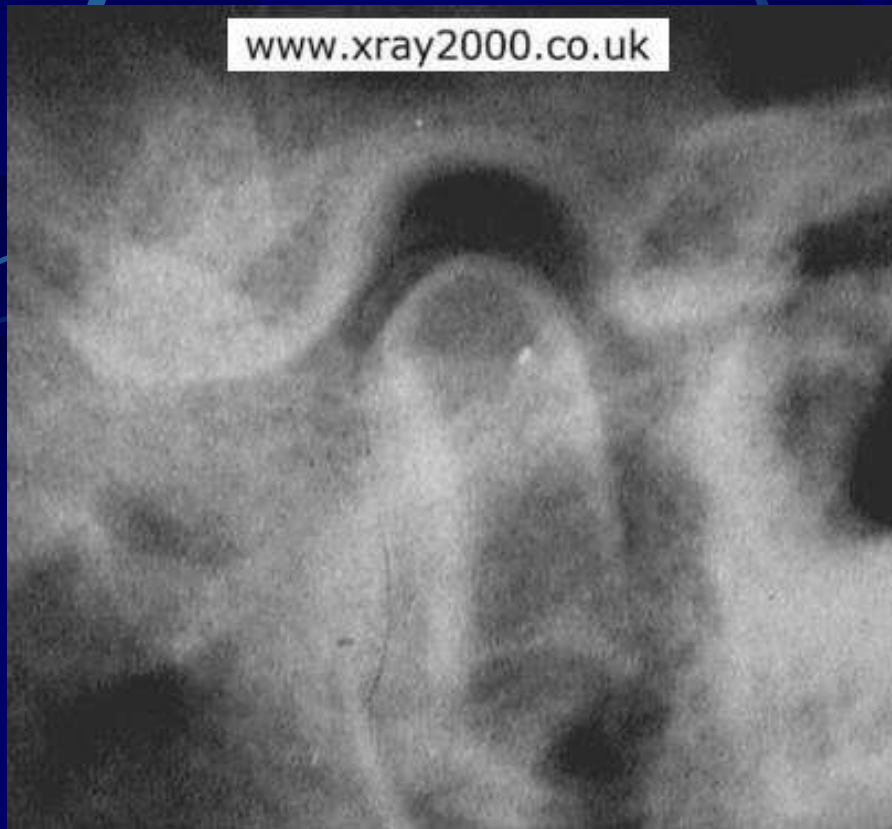


Anatomie





Anatomie

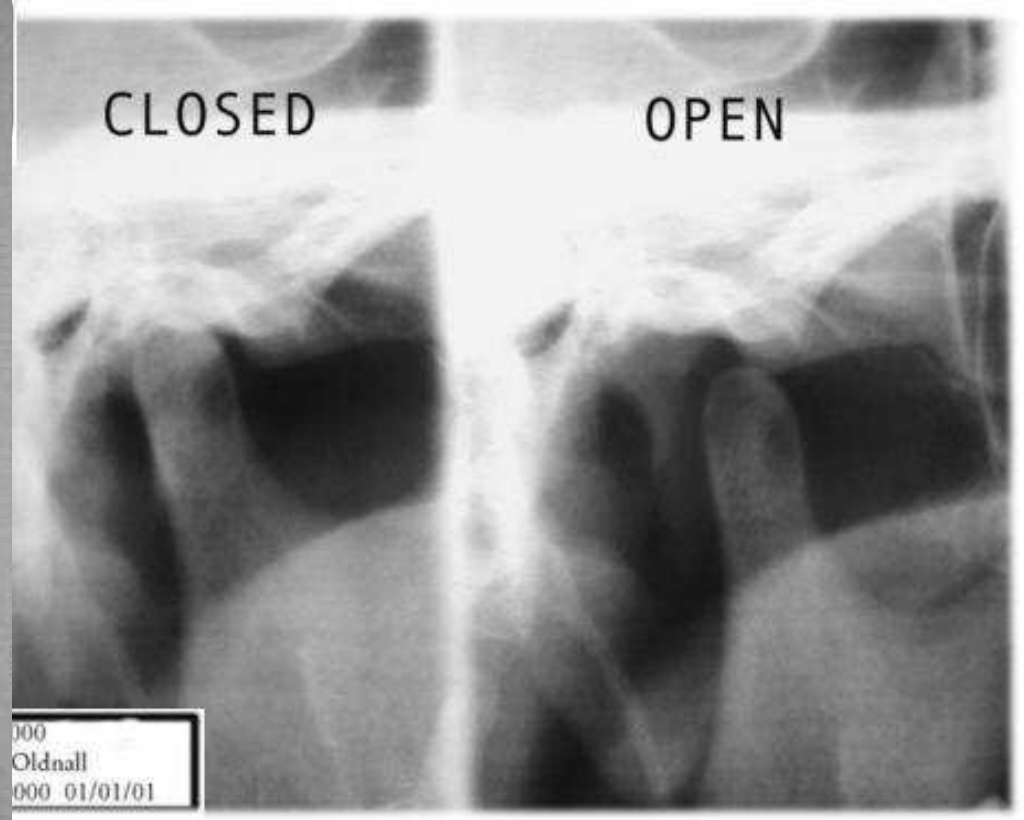
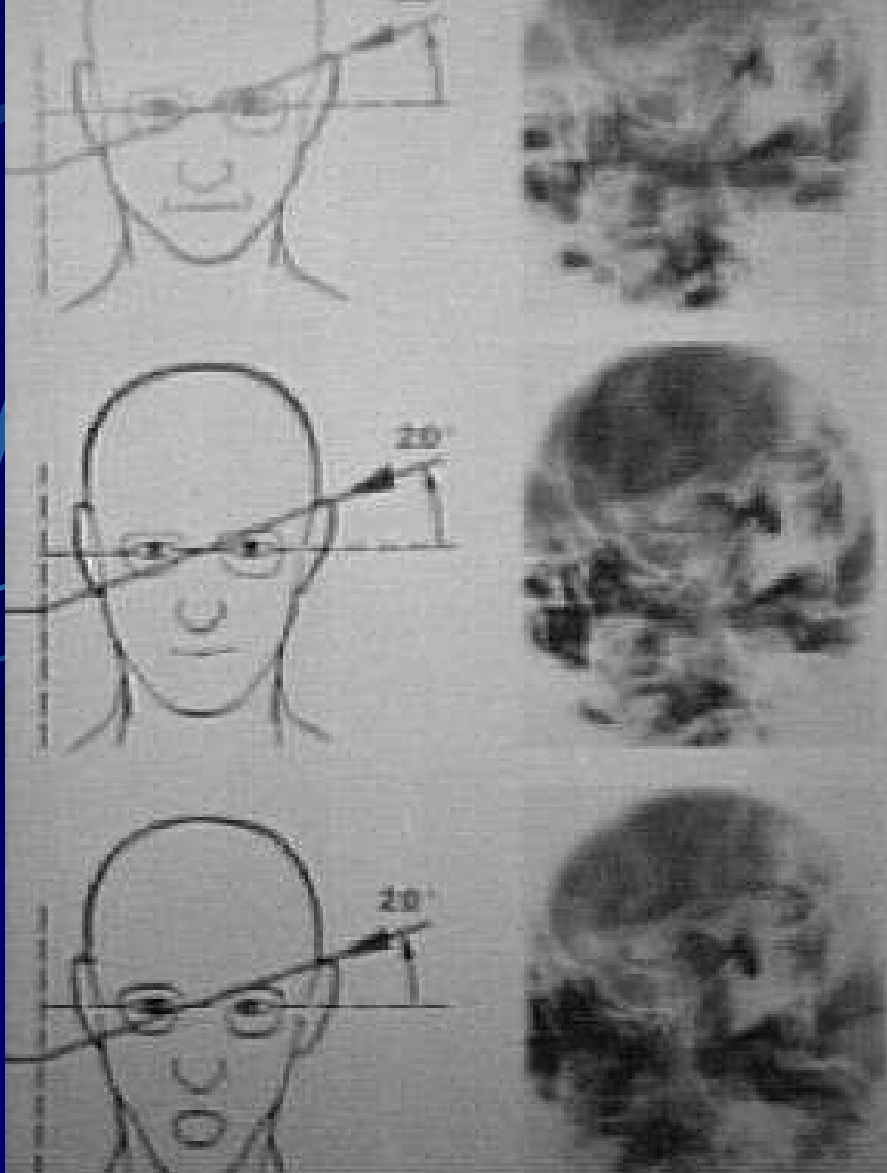




Anatomie

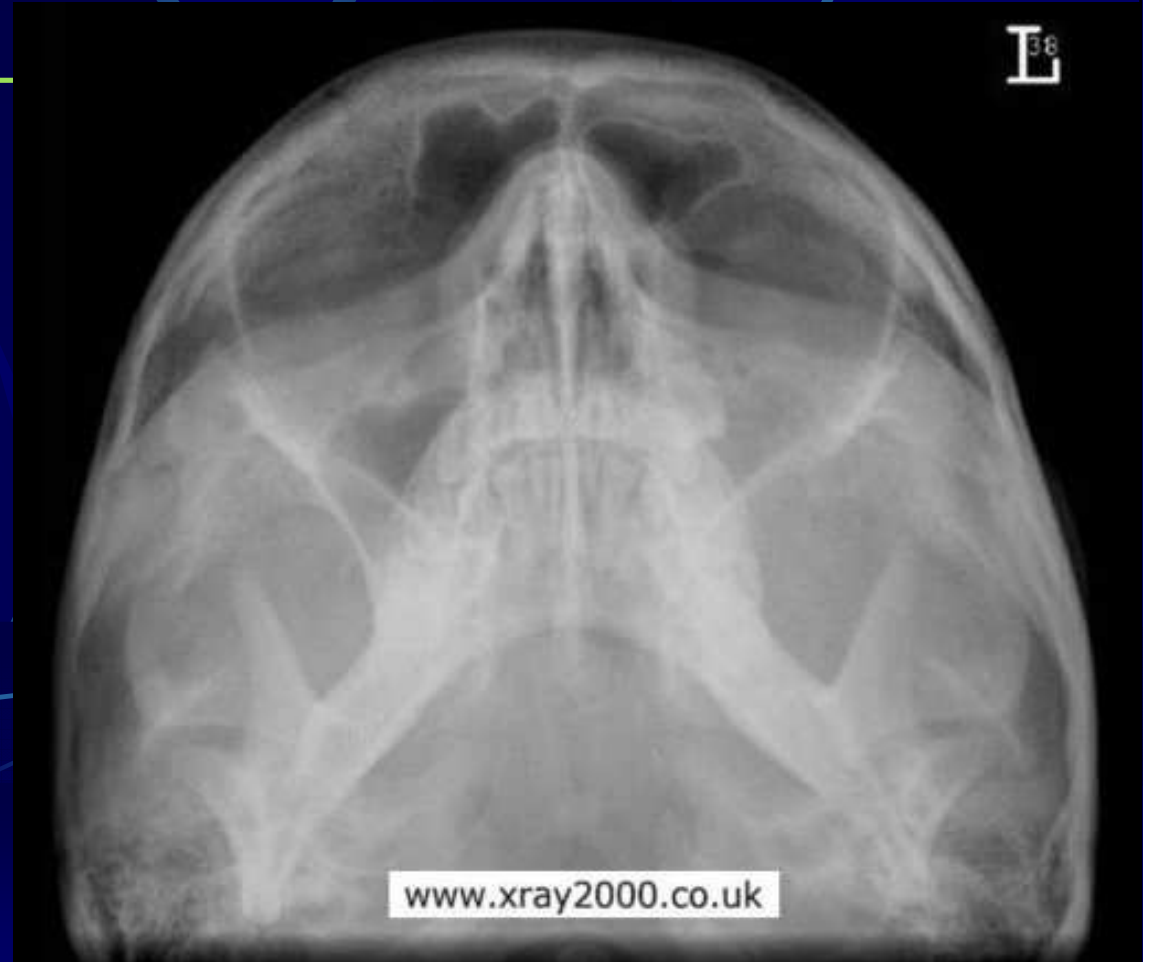

Anders Movin Karlison



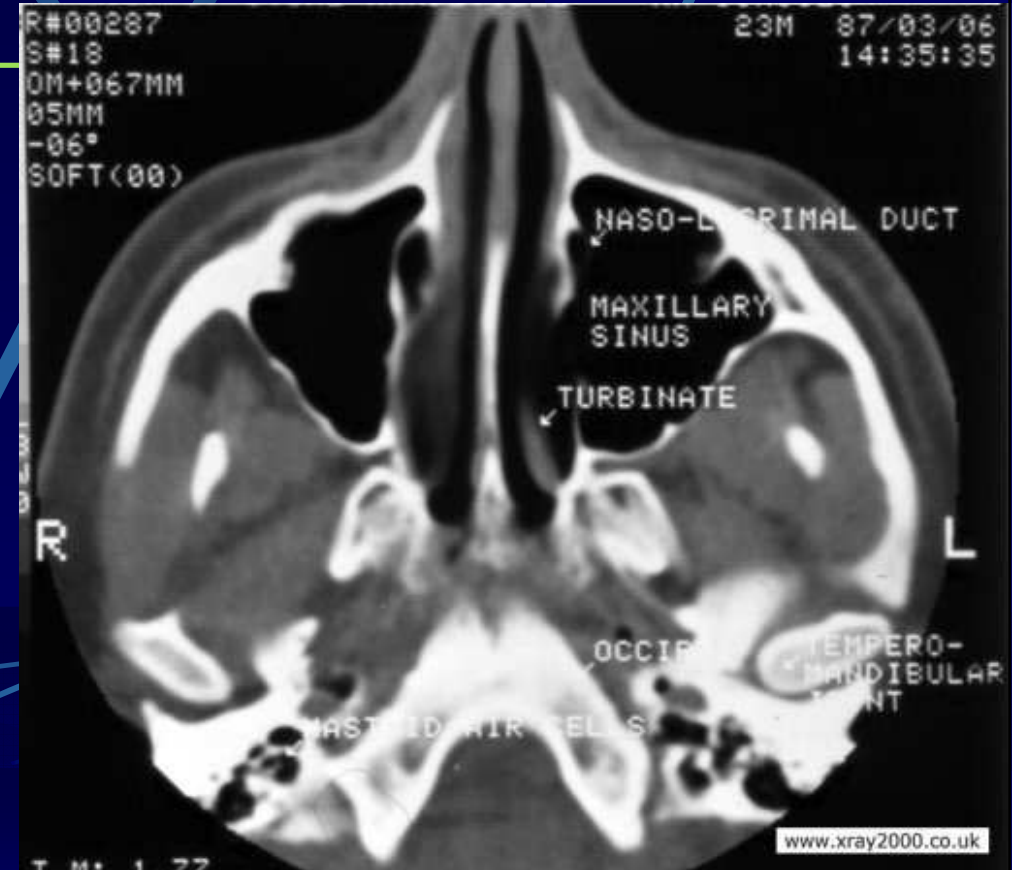
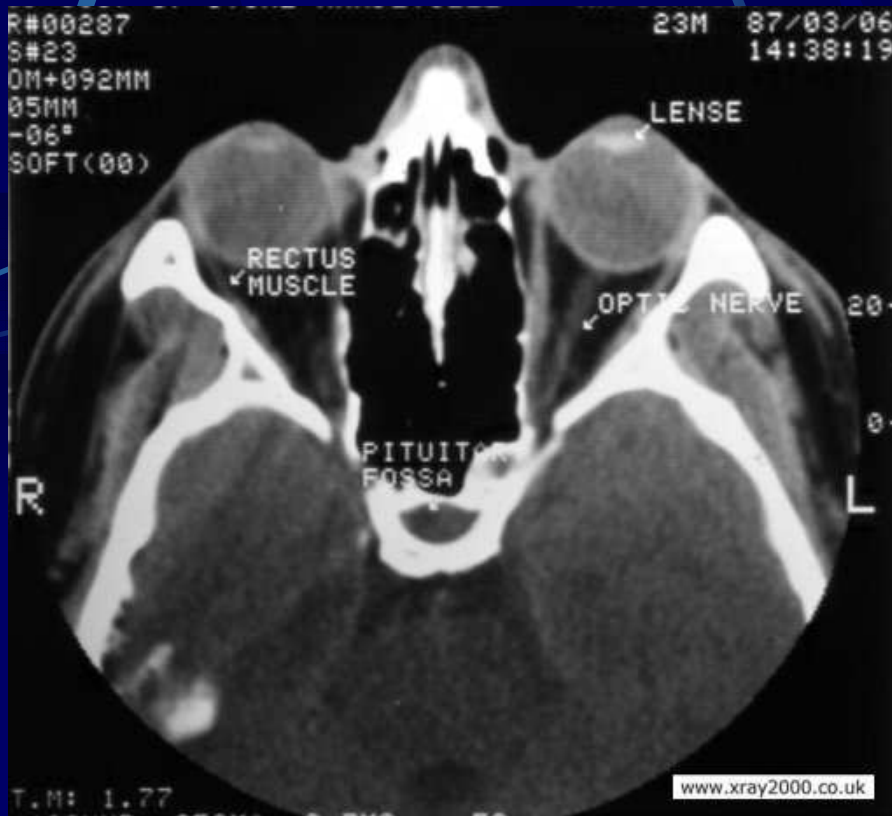

Anatomie





Anatomie

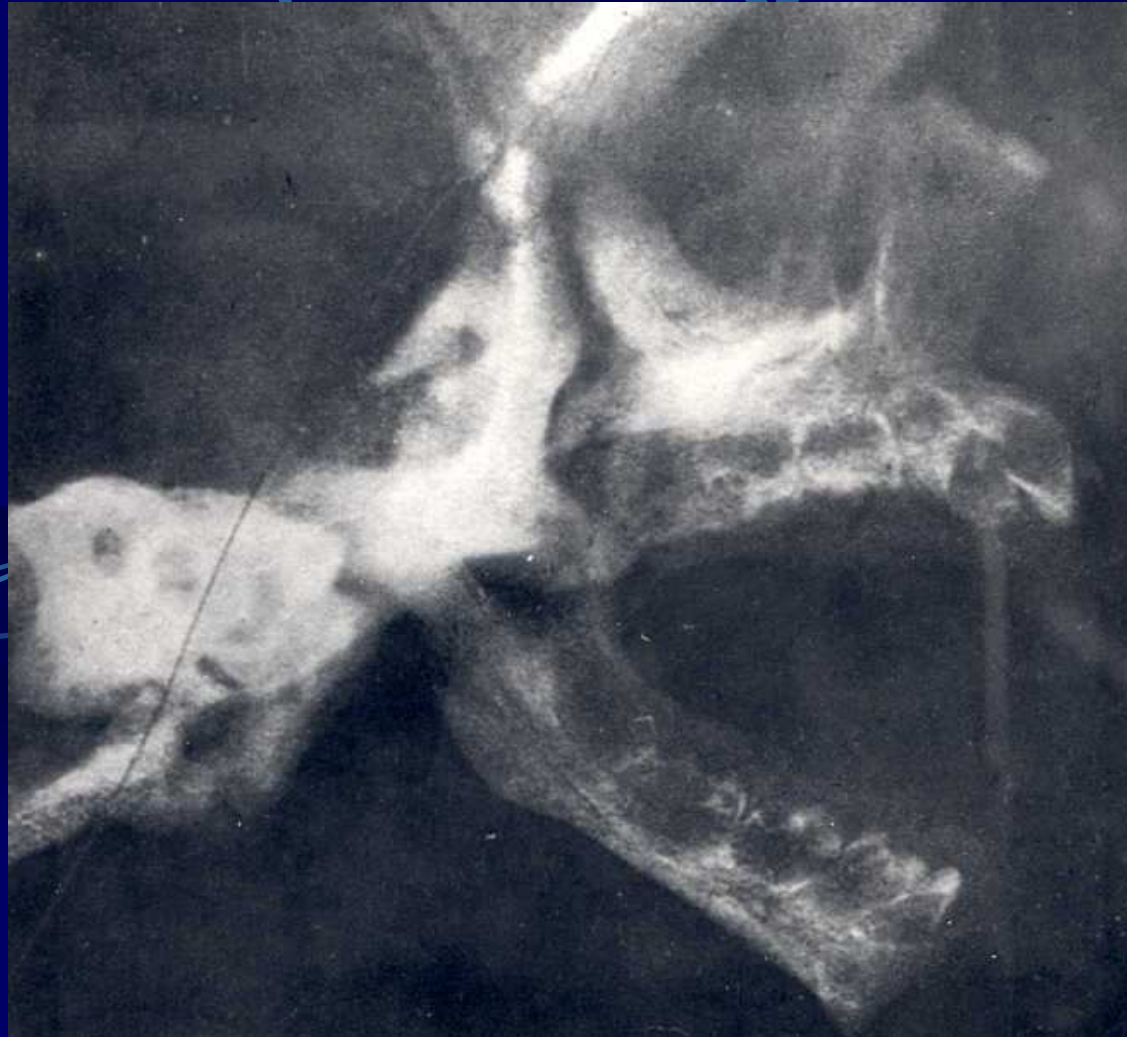





Vývoj zubu

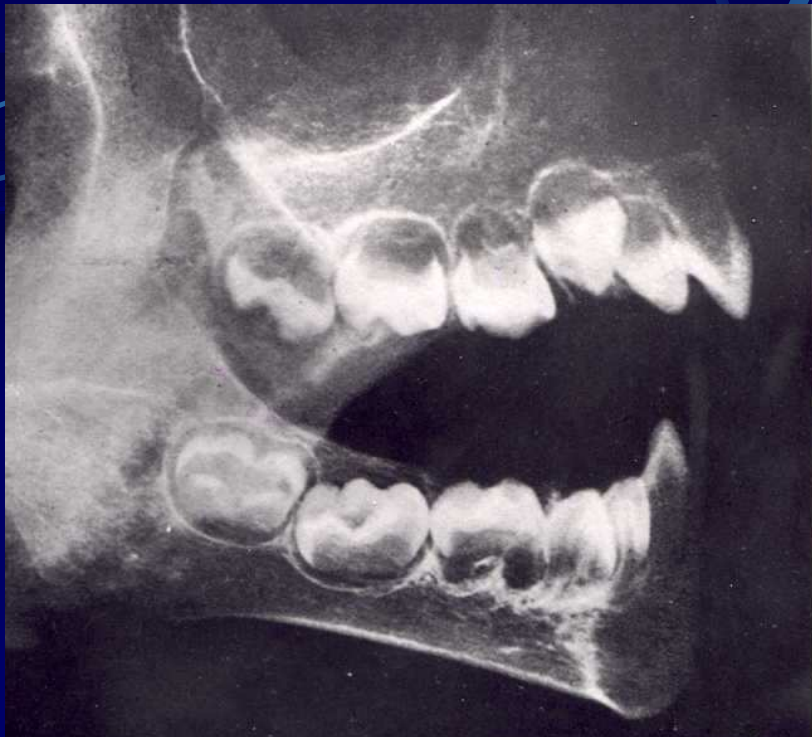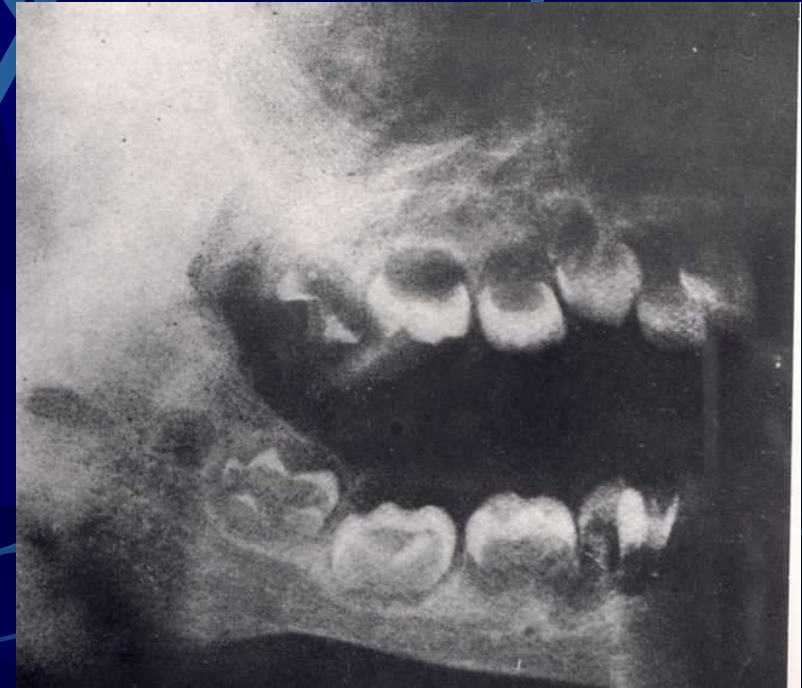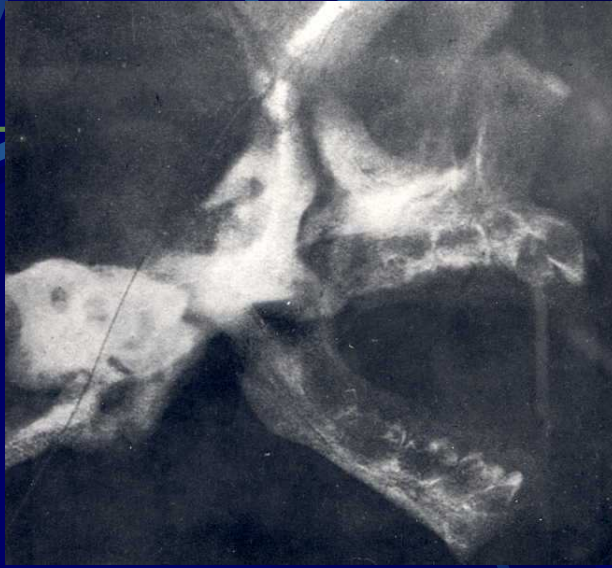



Zuby – vývoj - novorozenec

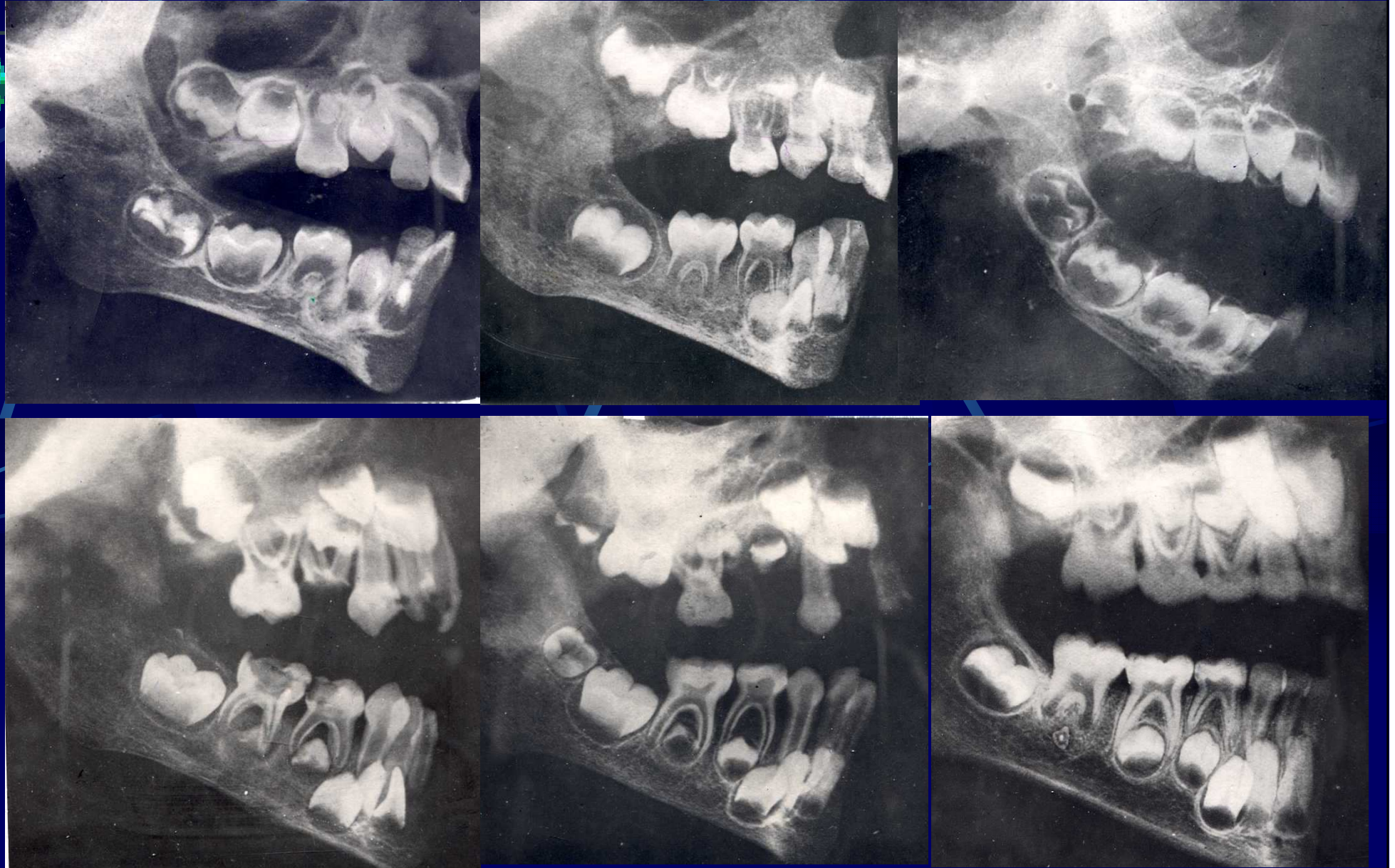




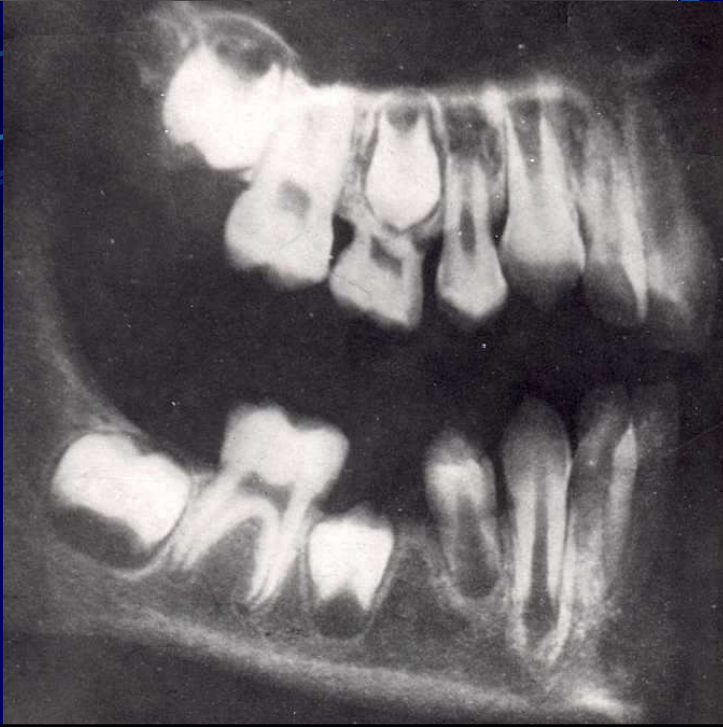
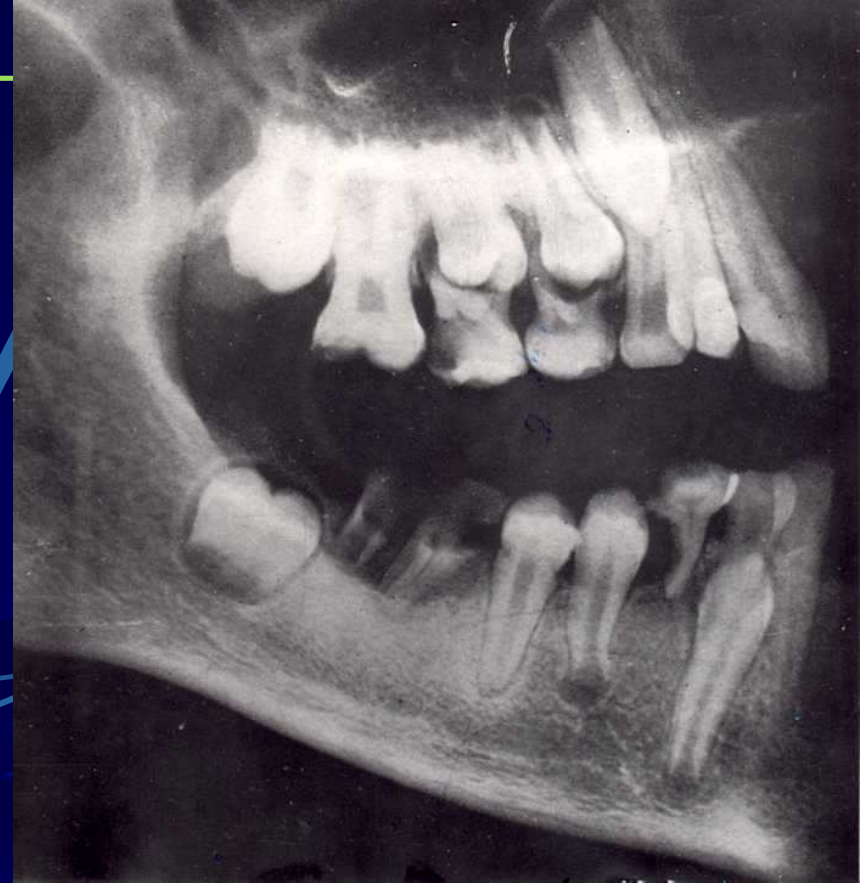
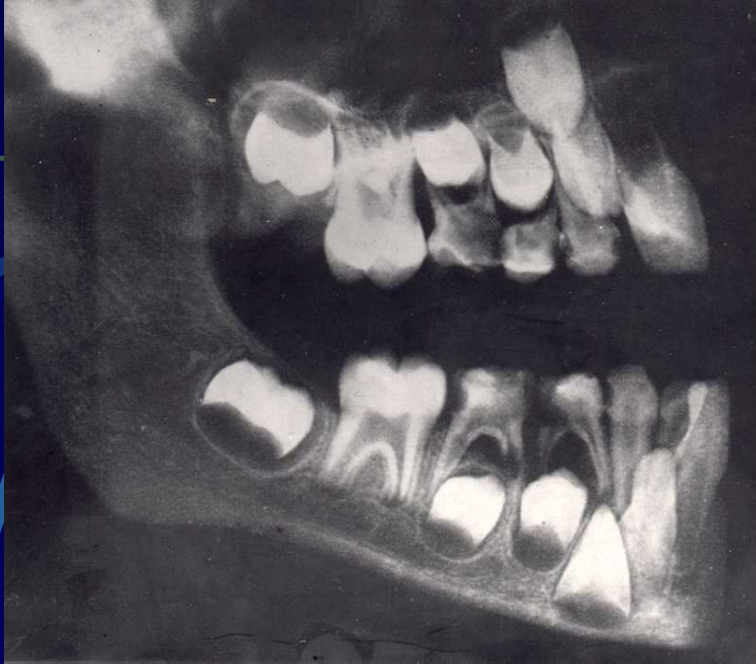
Zuby – vývoj – 6 a 9 měsíc



Zuby – vývoj – 1 – 6 rok




Zuby – vývoj – 7-10 let

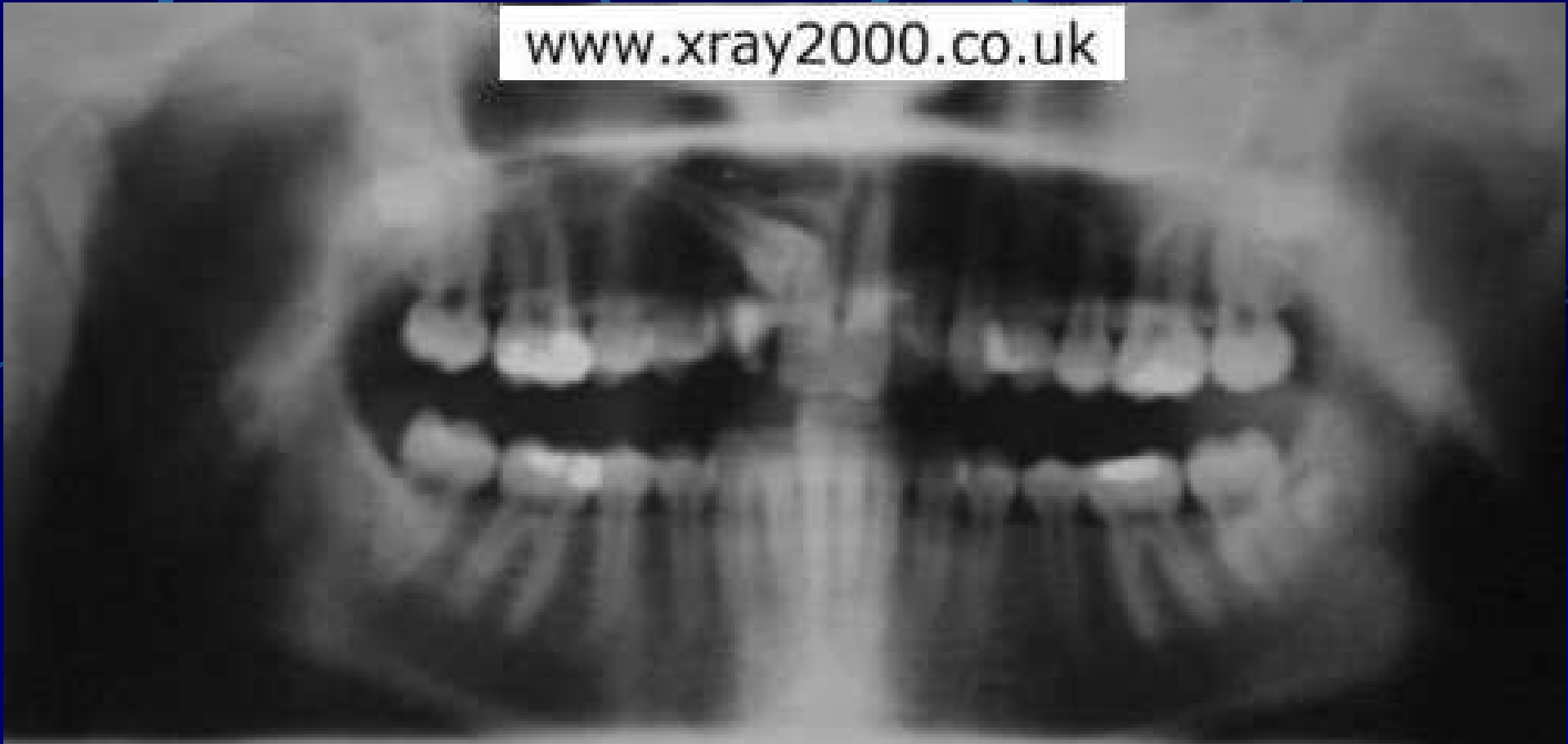



Zuby – vývoj – ektopický zub



www.xray2000.co.uk

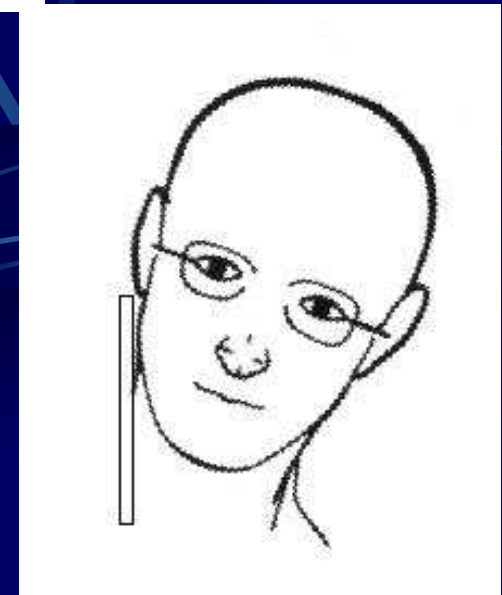
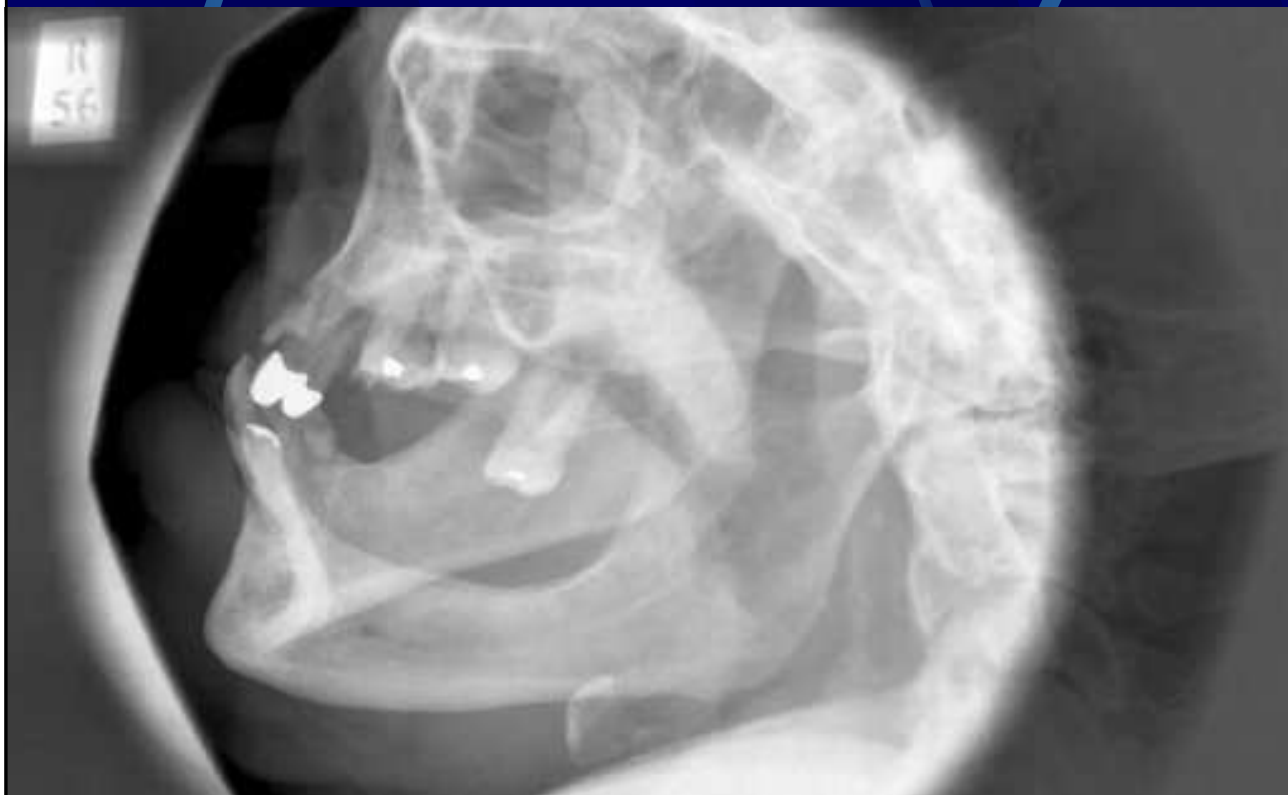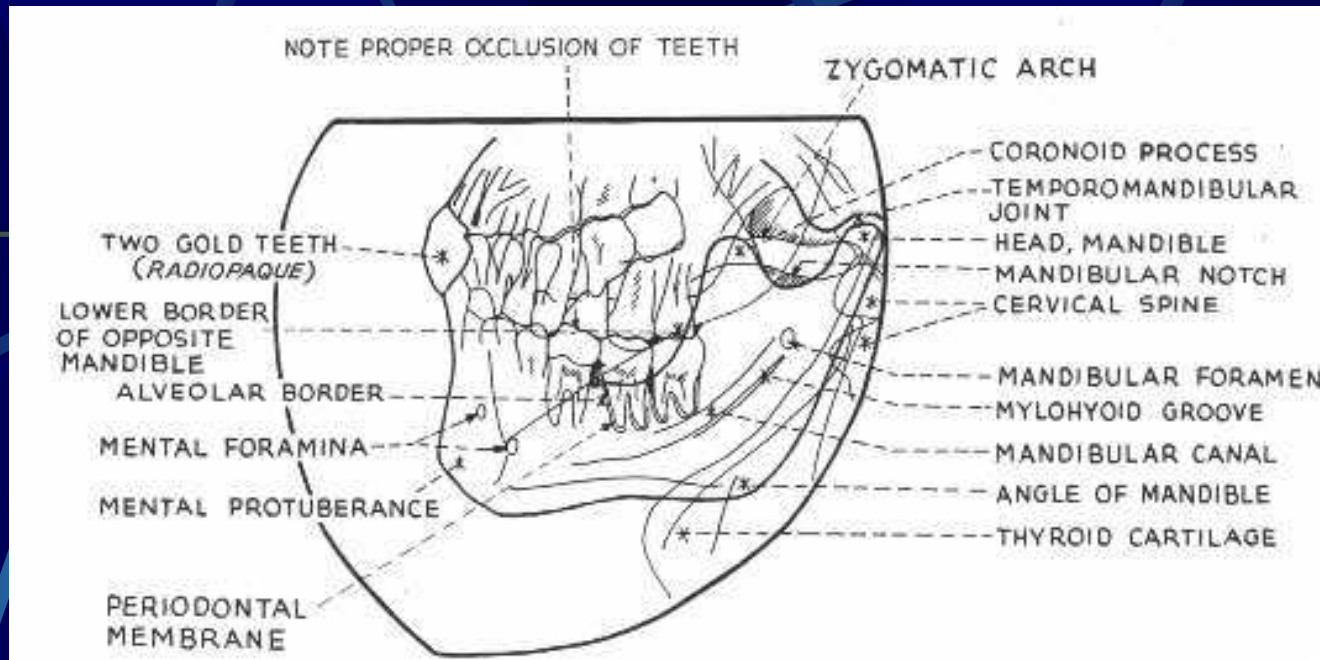




Projekce

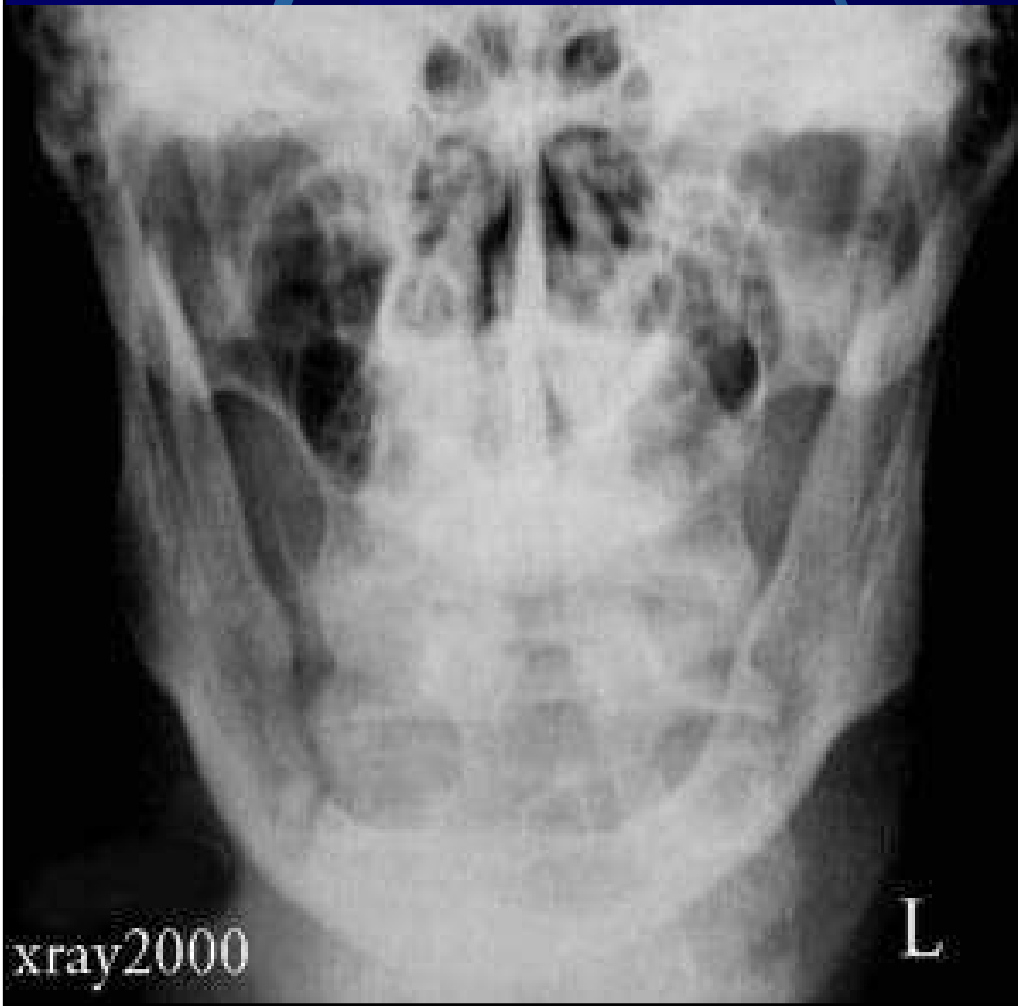


Šikmá projekce mandibula – faciomaxilární



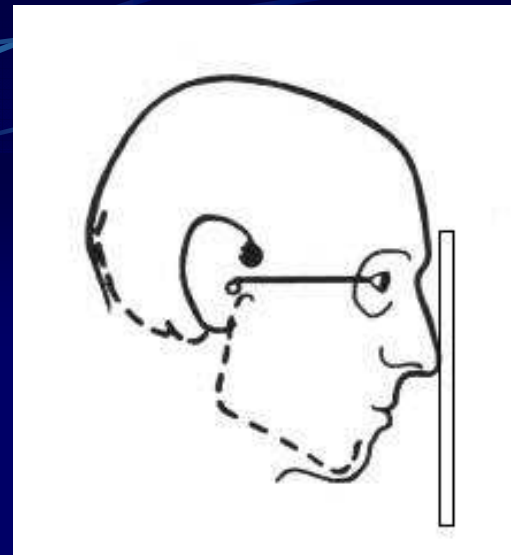
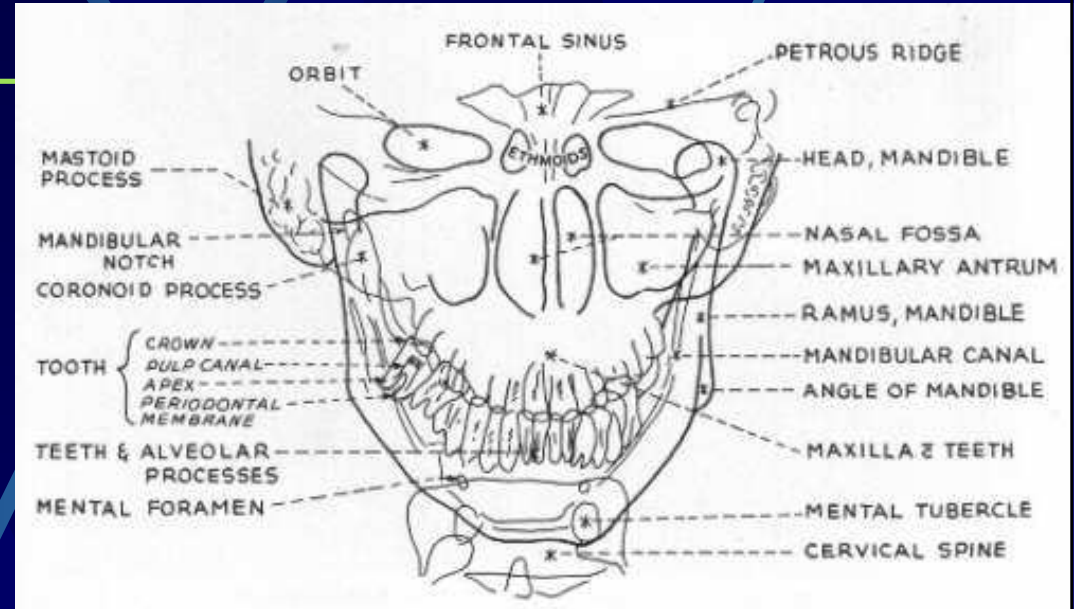


Mandibula PA



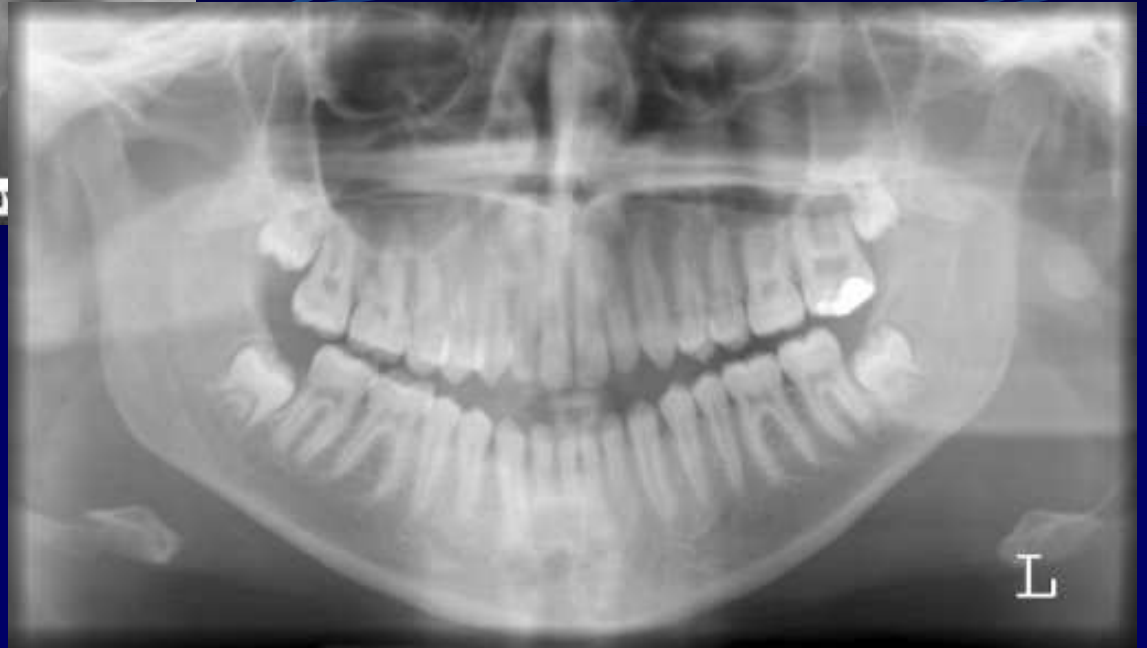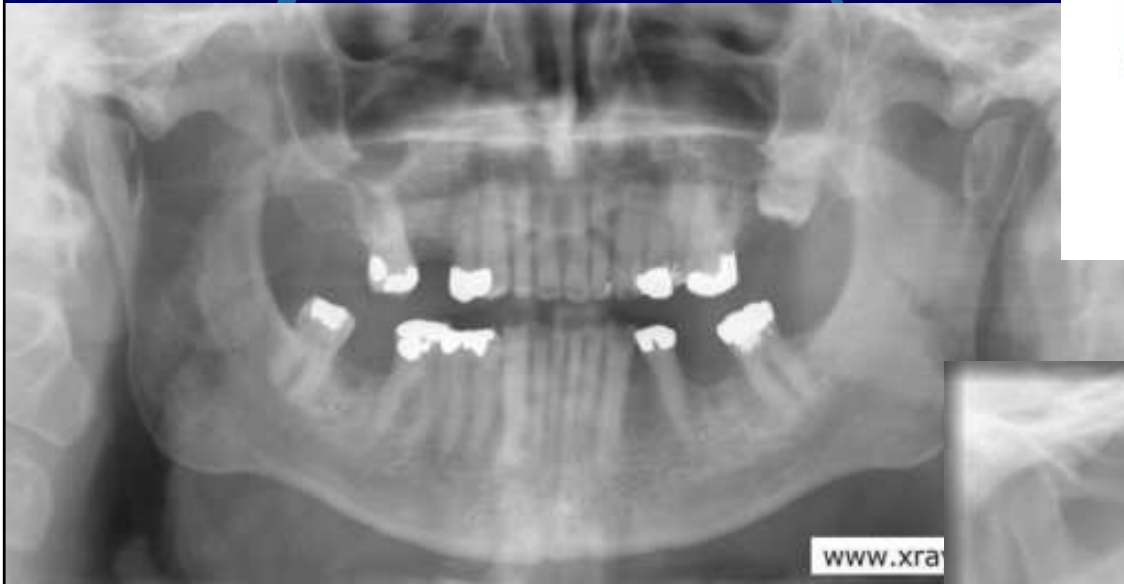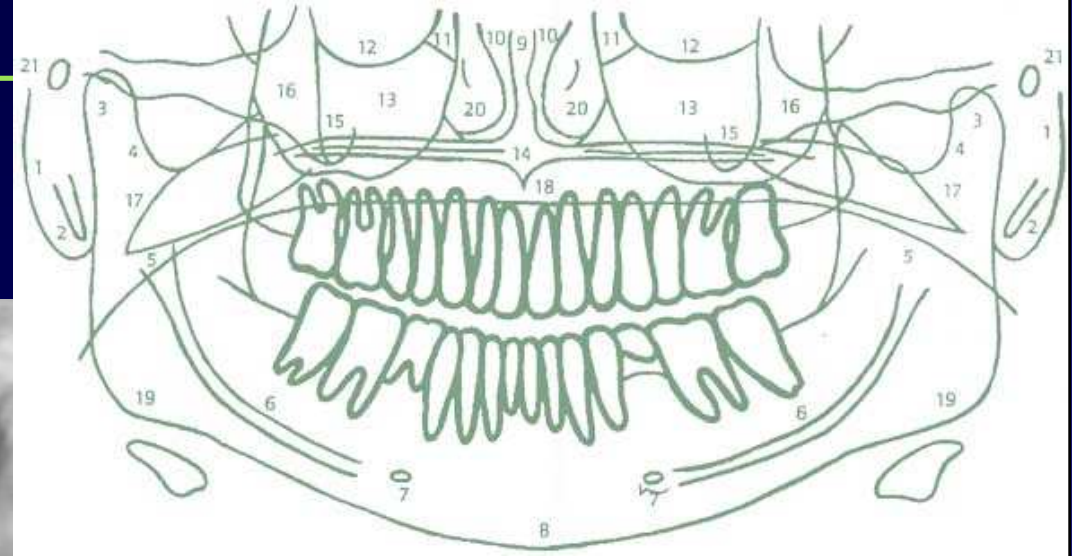

xray2000

L



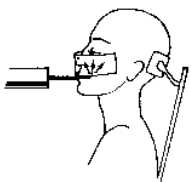
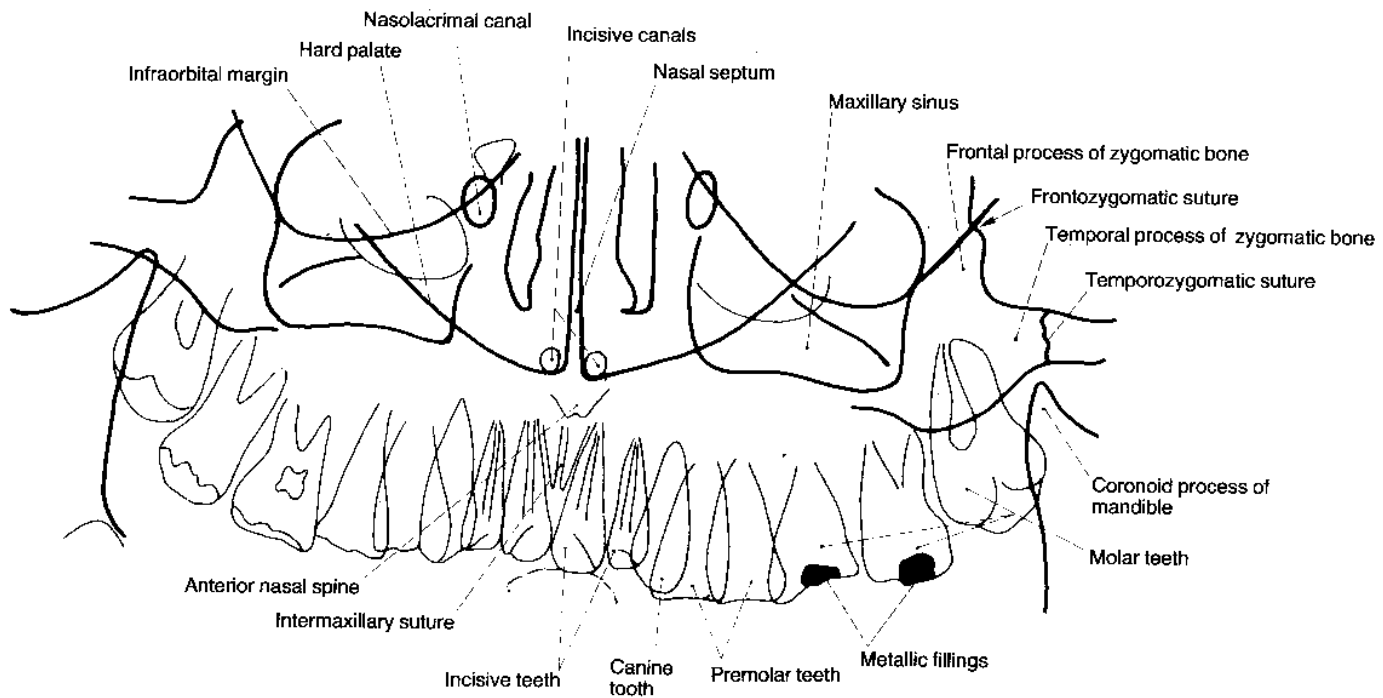
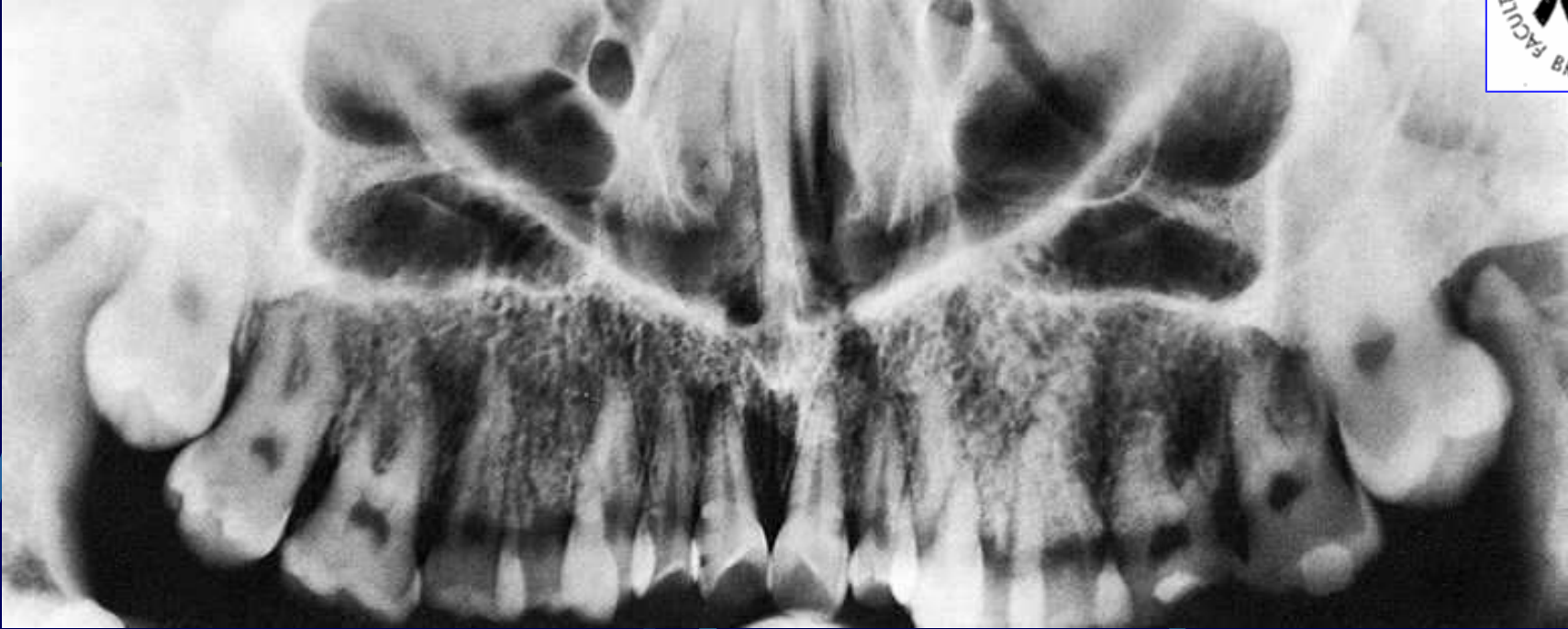


Projekce



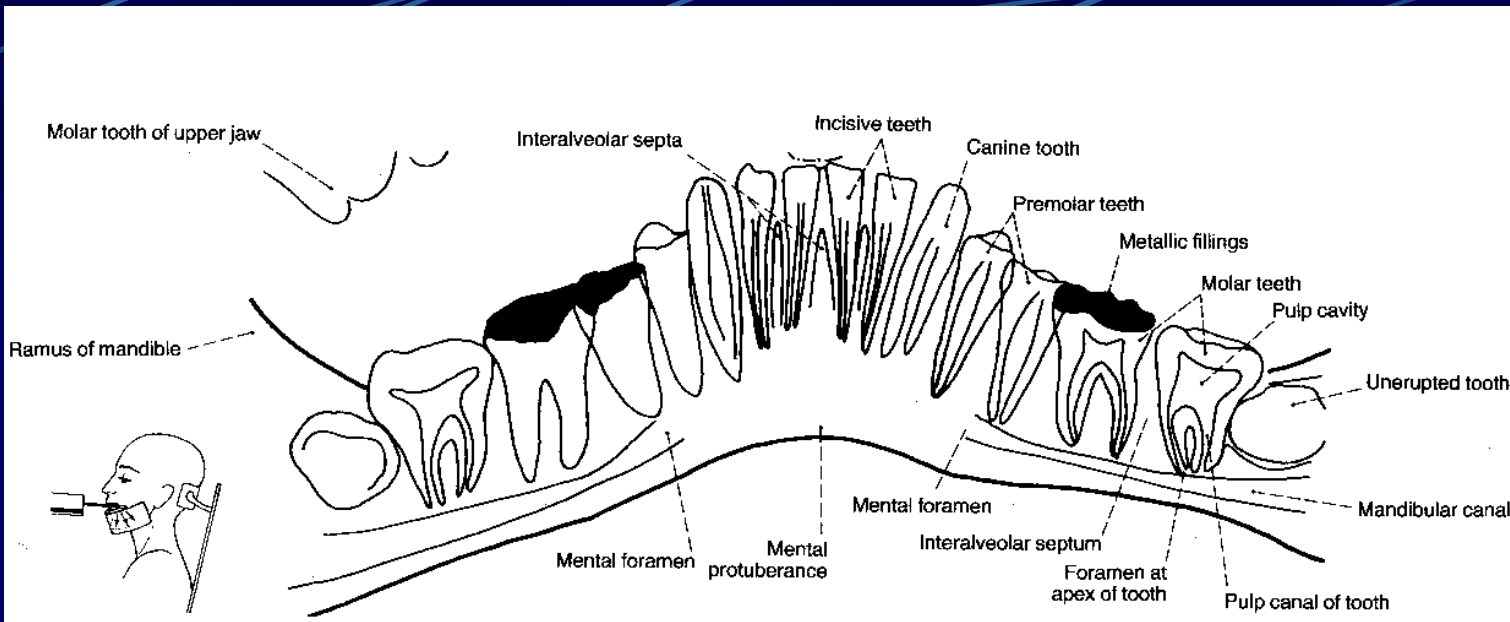
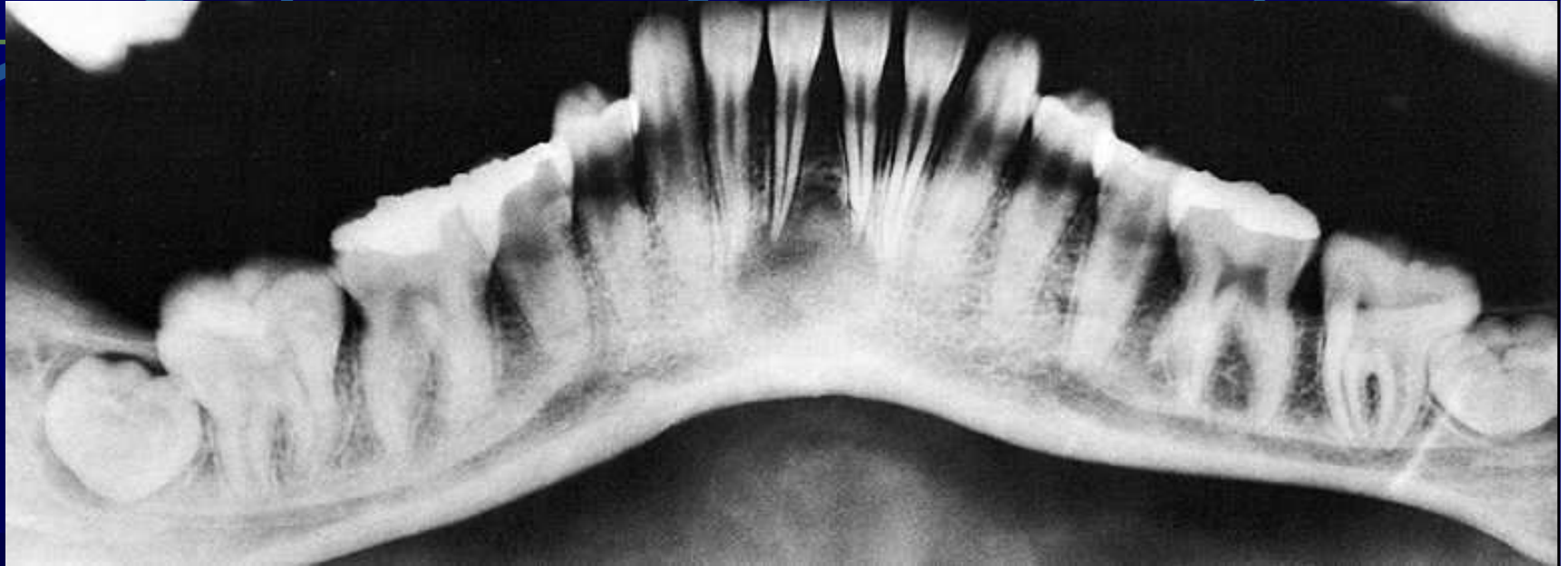


Projekce



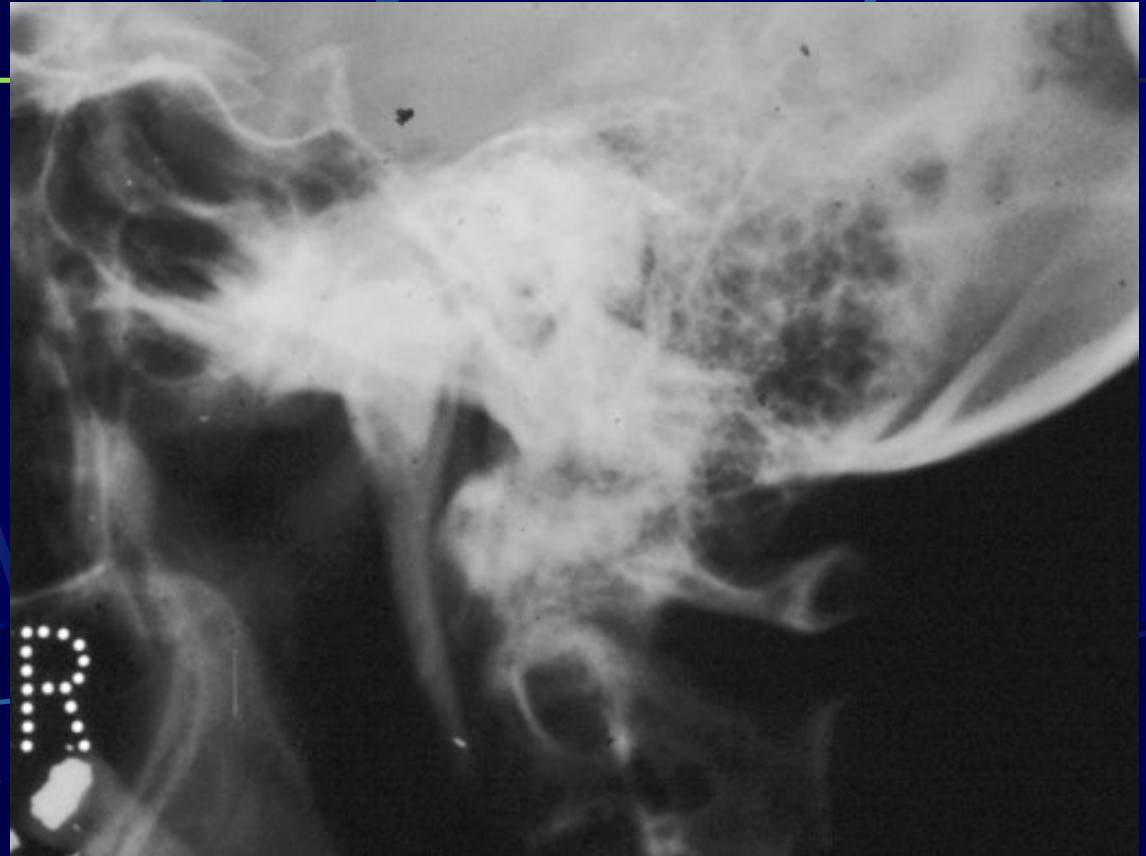
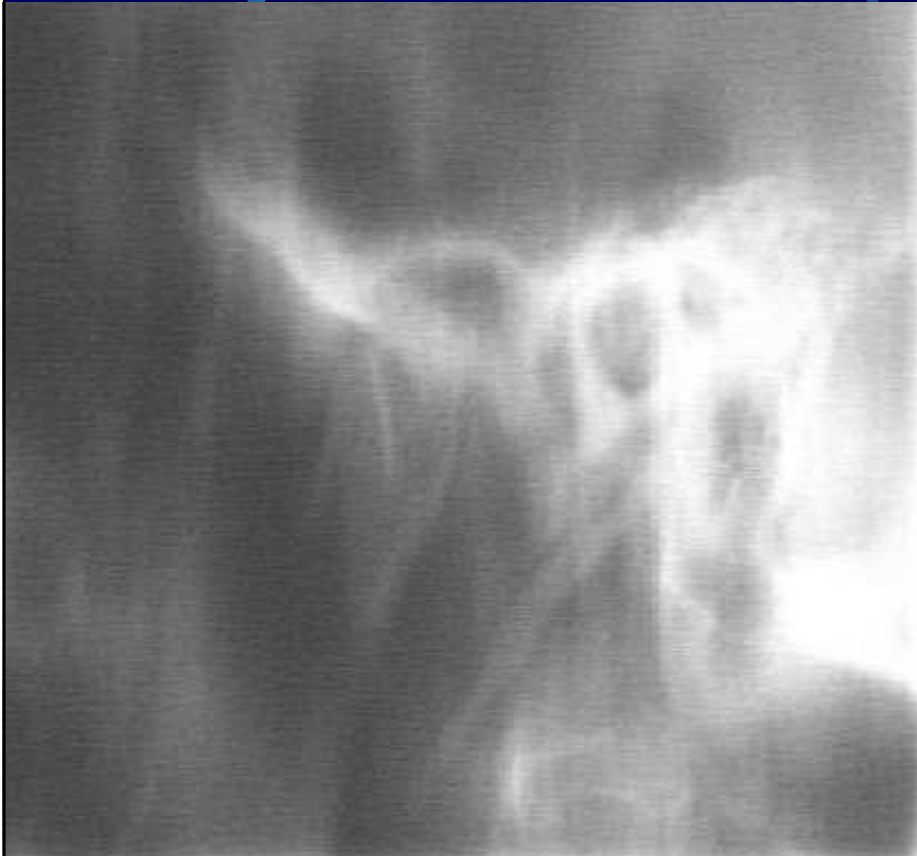


Projekce



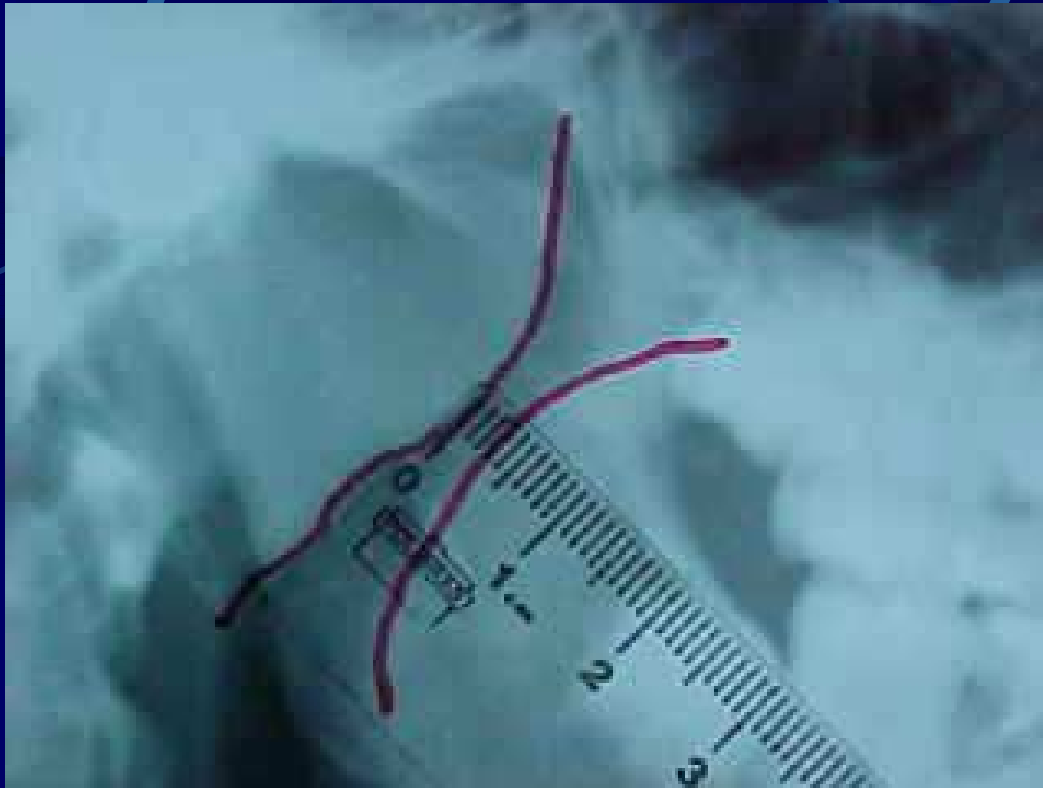
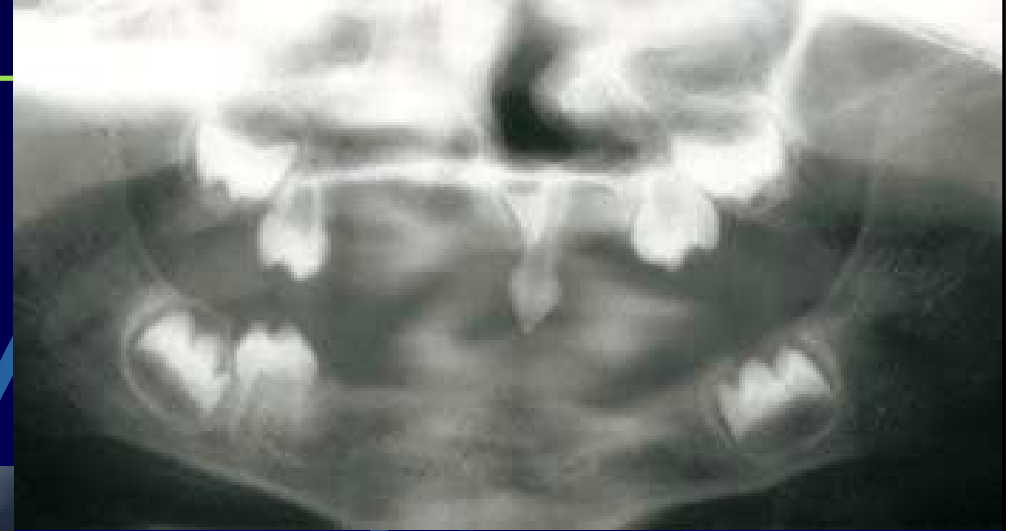


Projekce



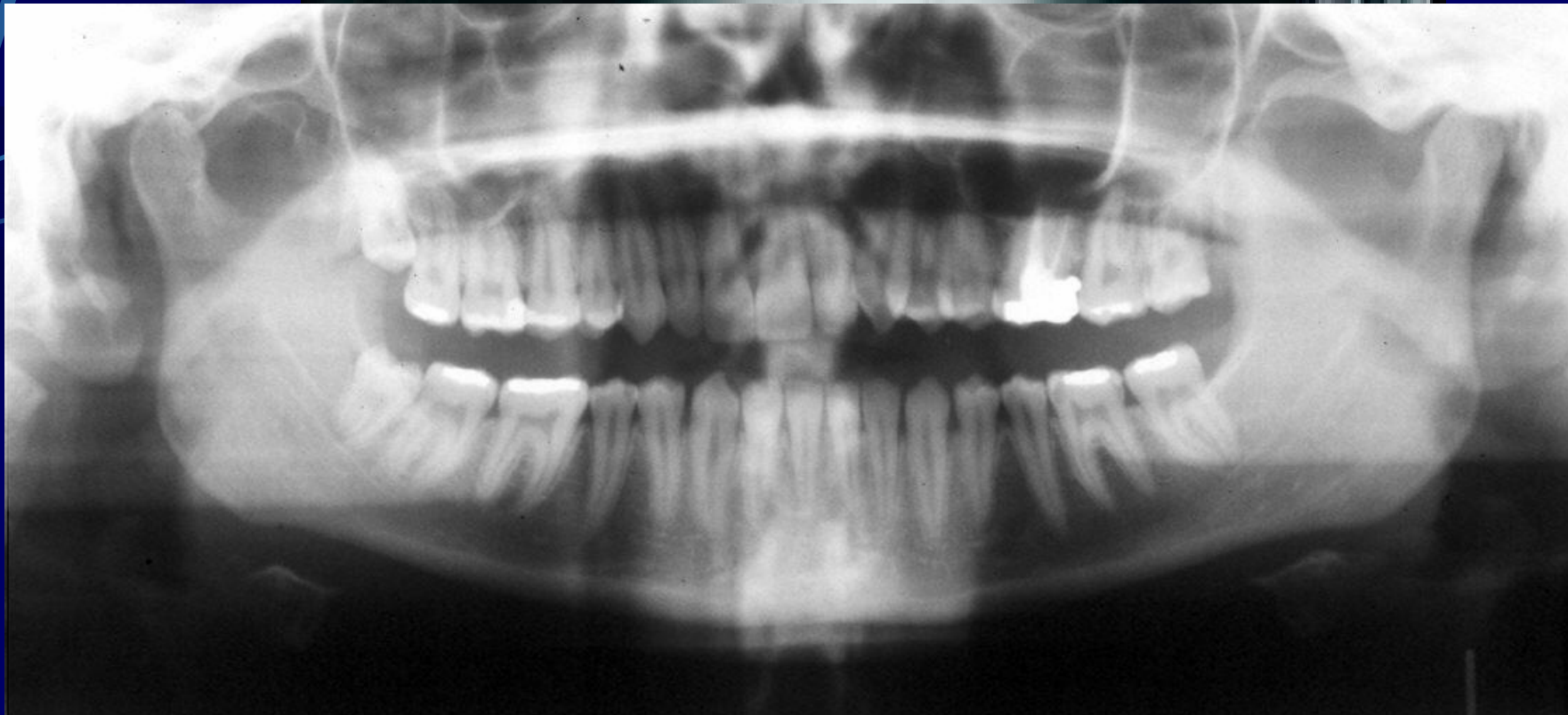
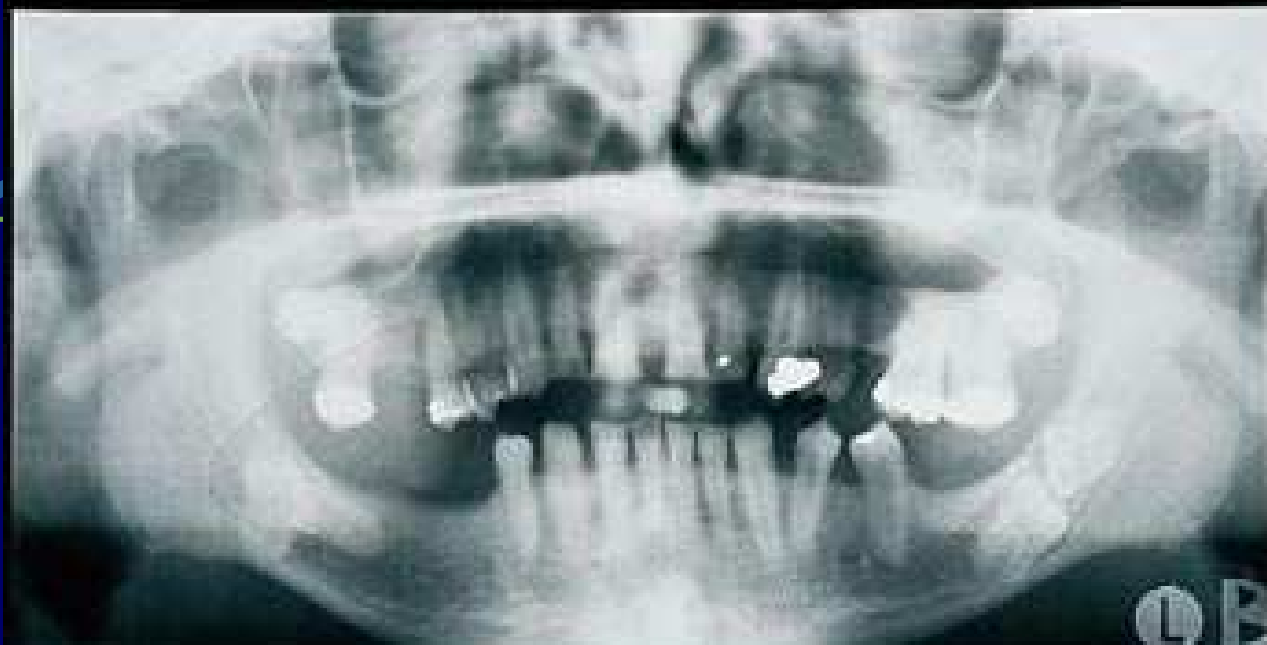
Projekce



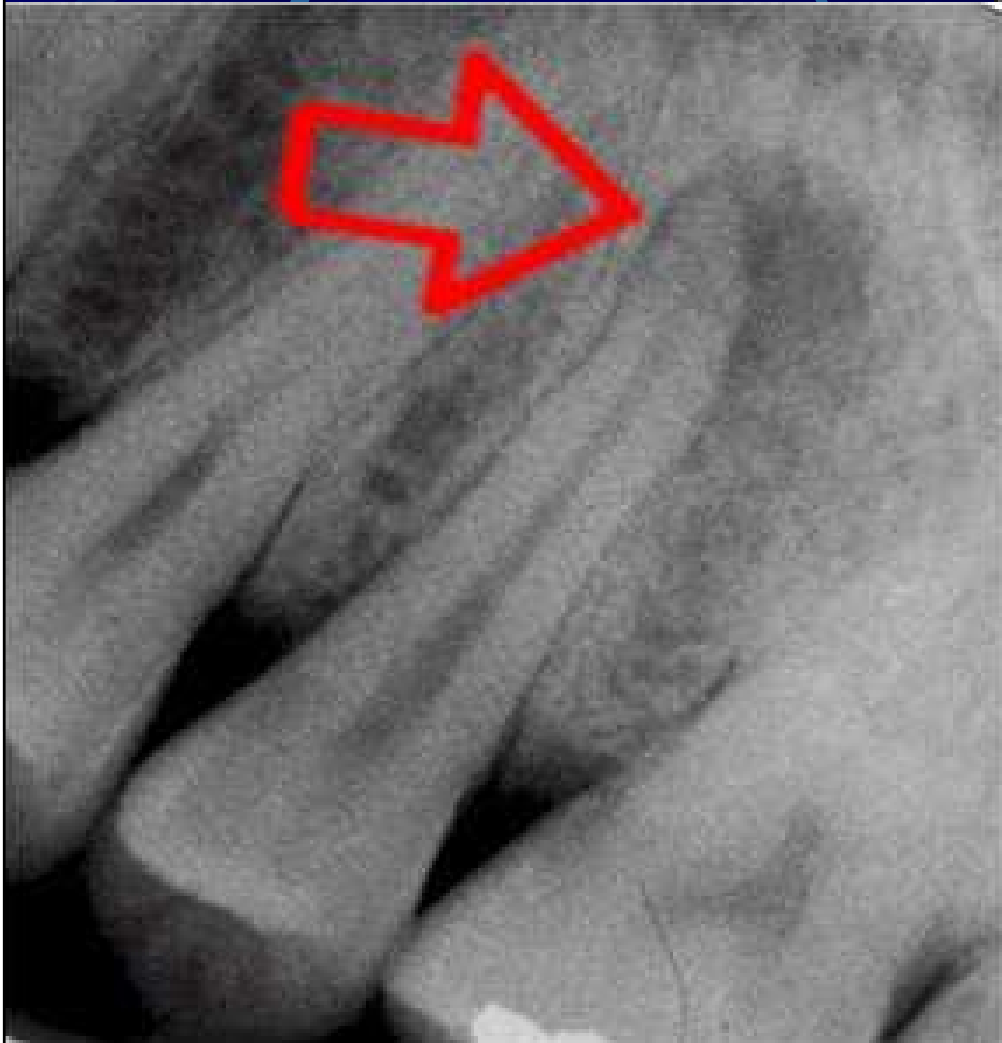


Projekce



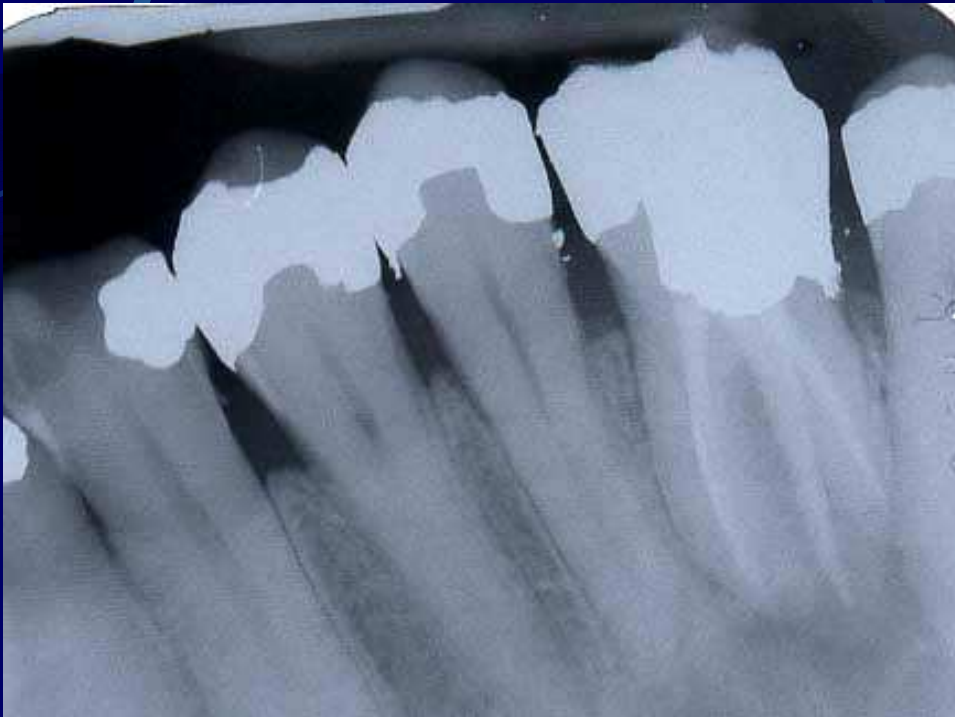
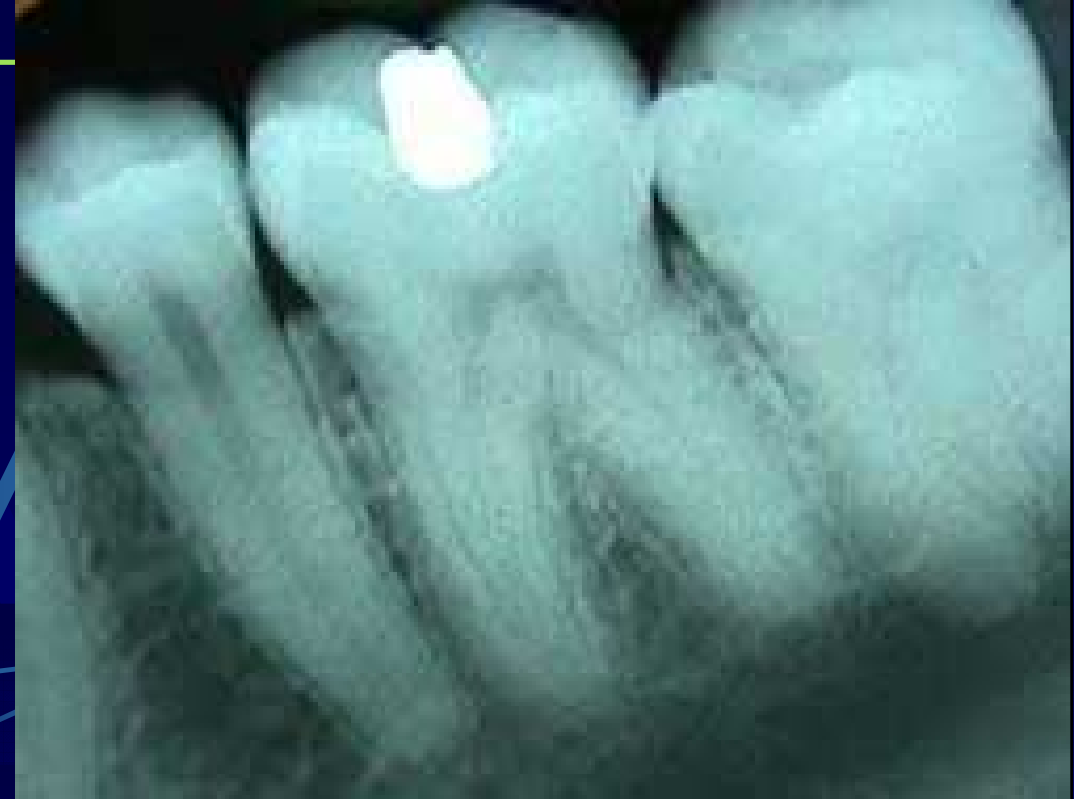


Projekce



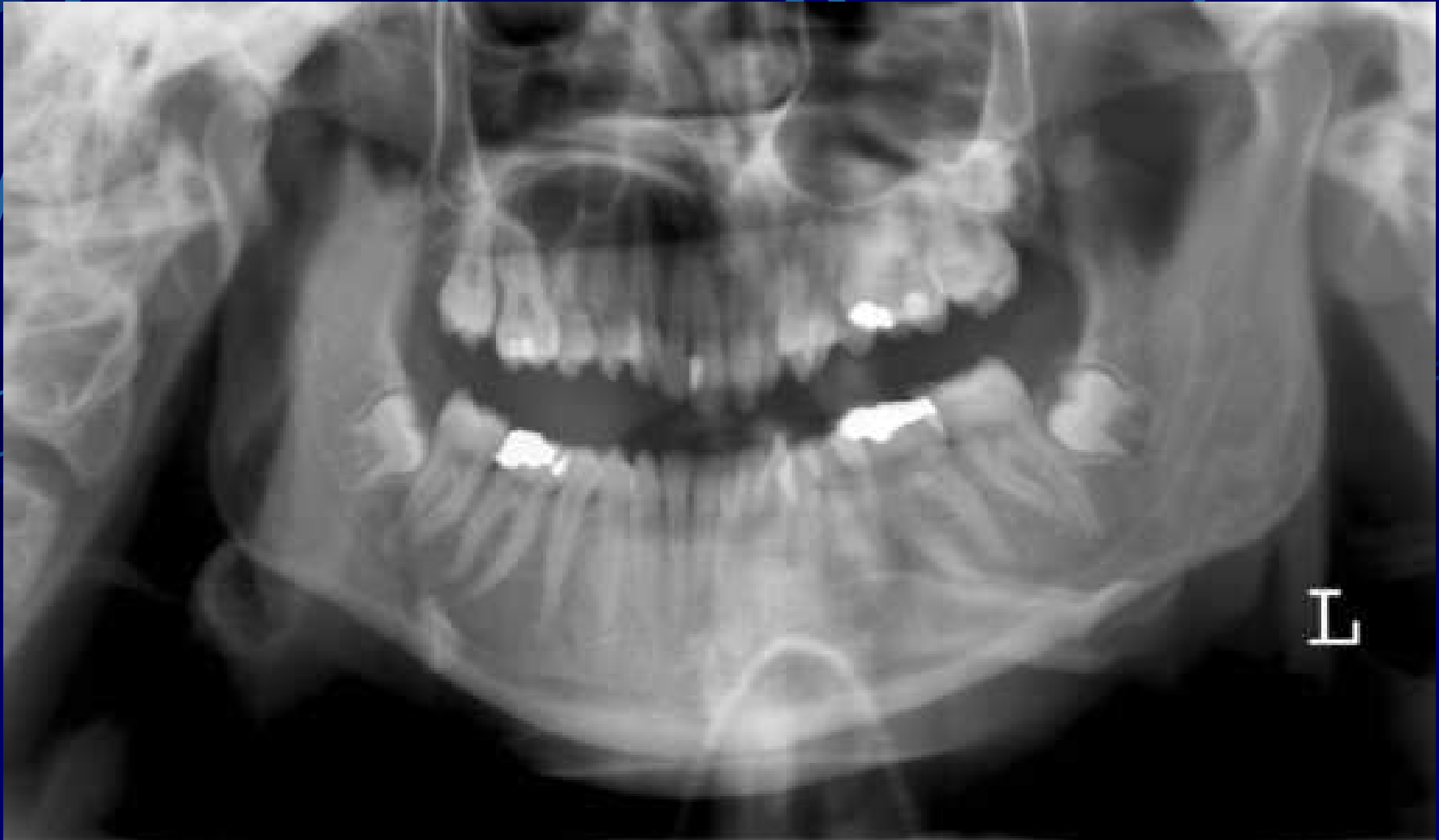



Projekce





Zuby - artefakt

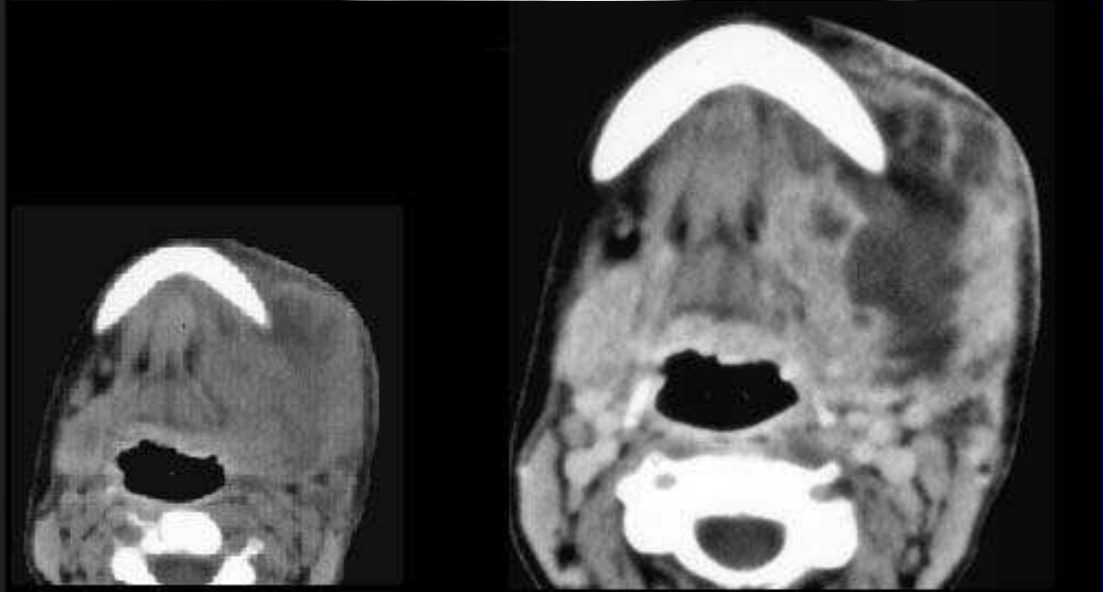
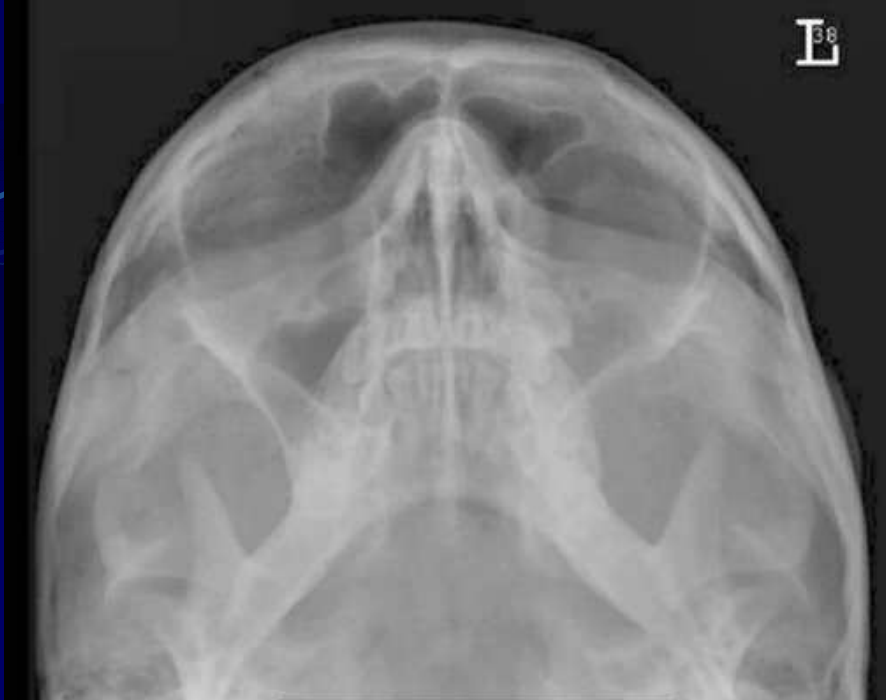
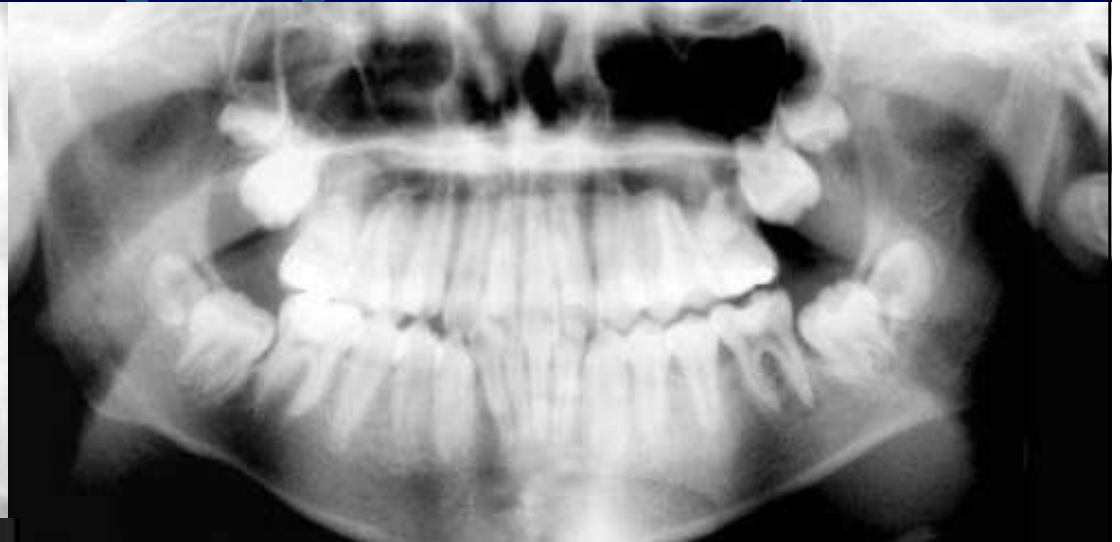
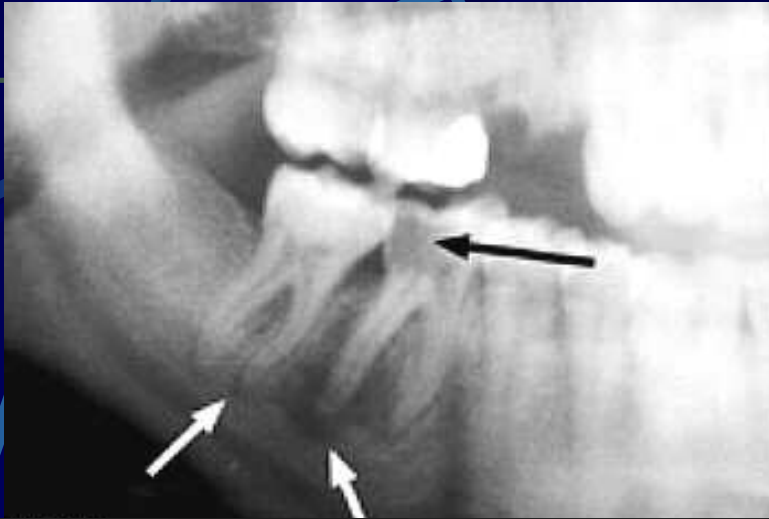


Patologie

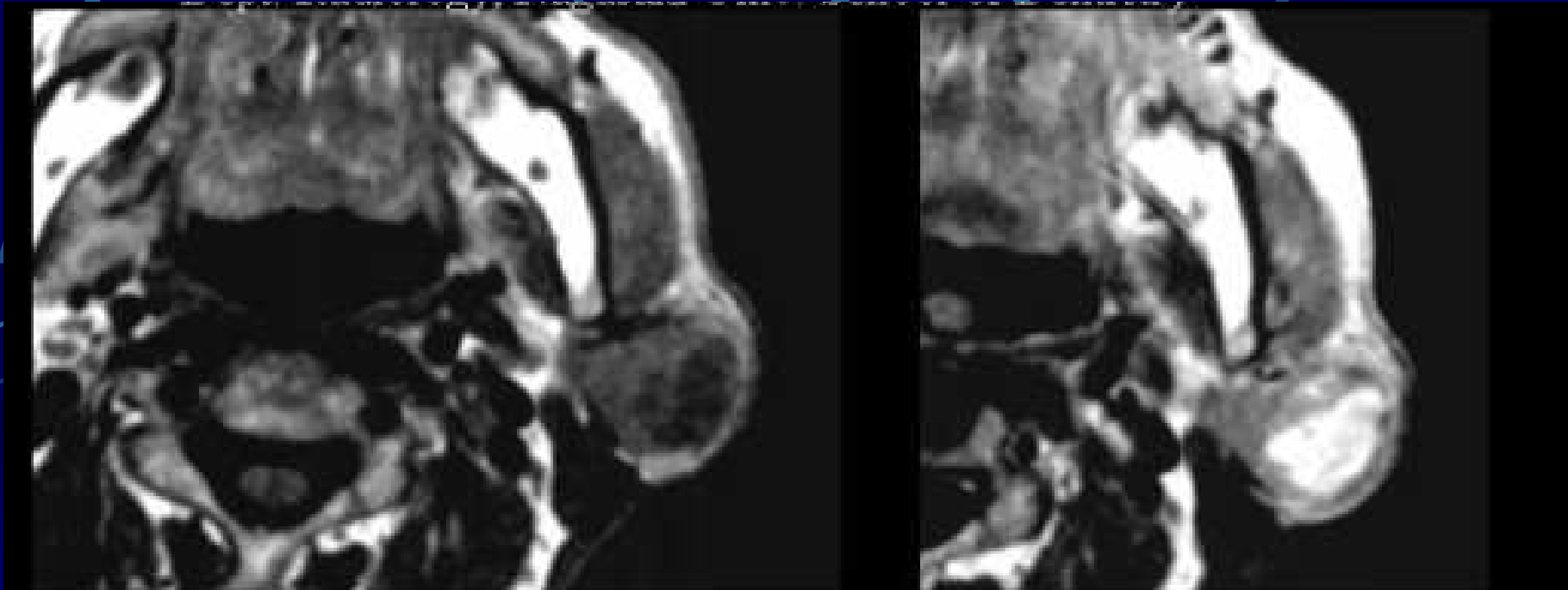


Absces



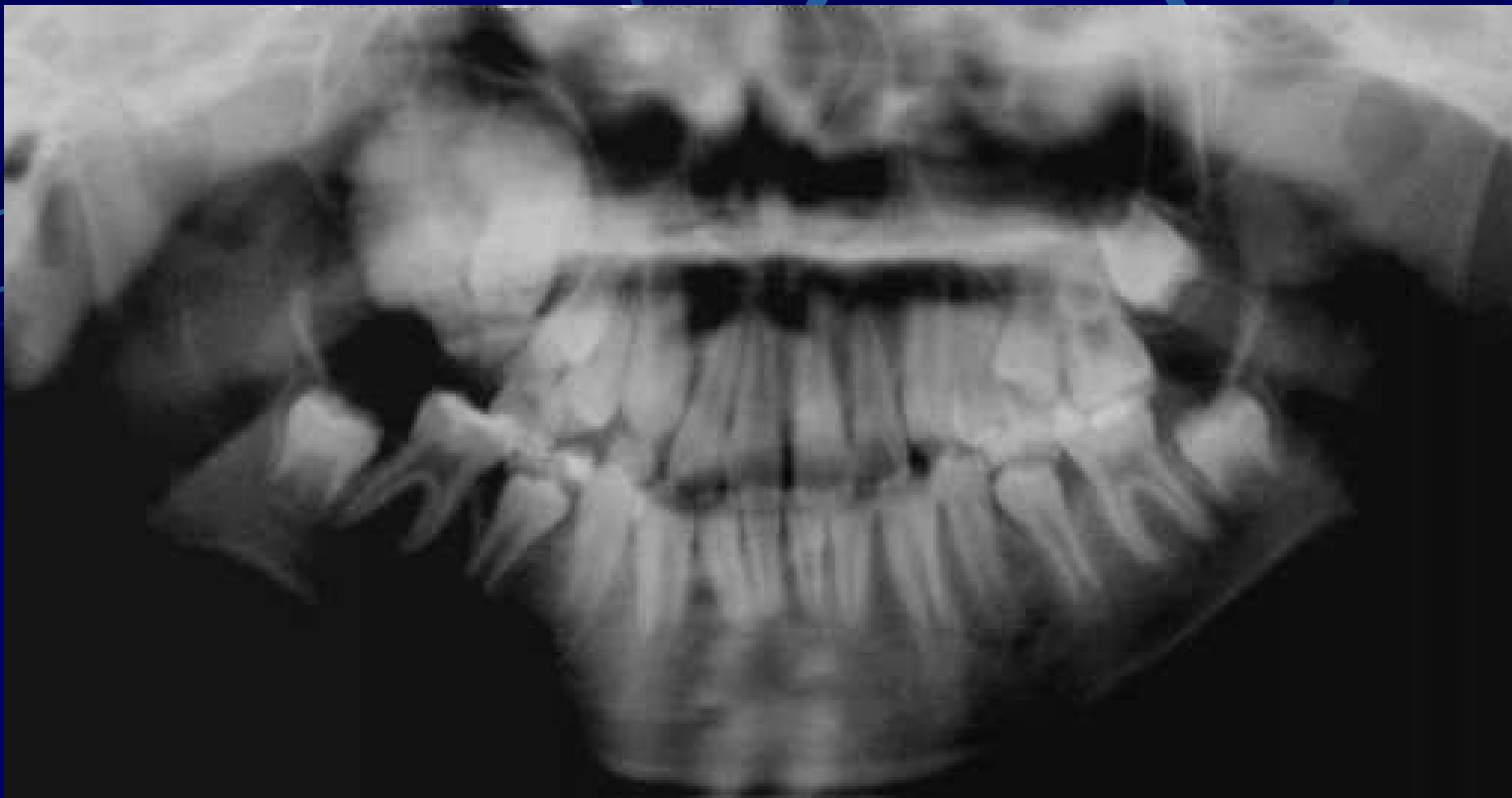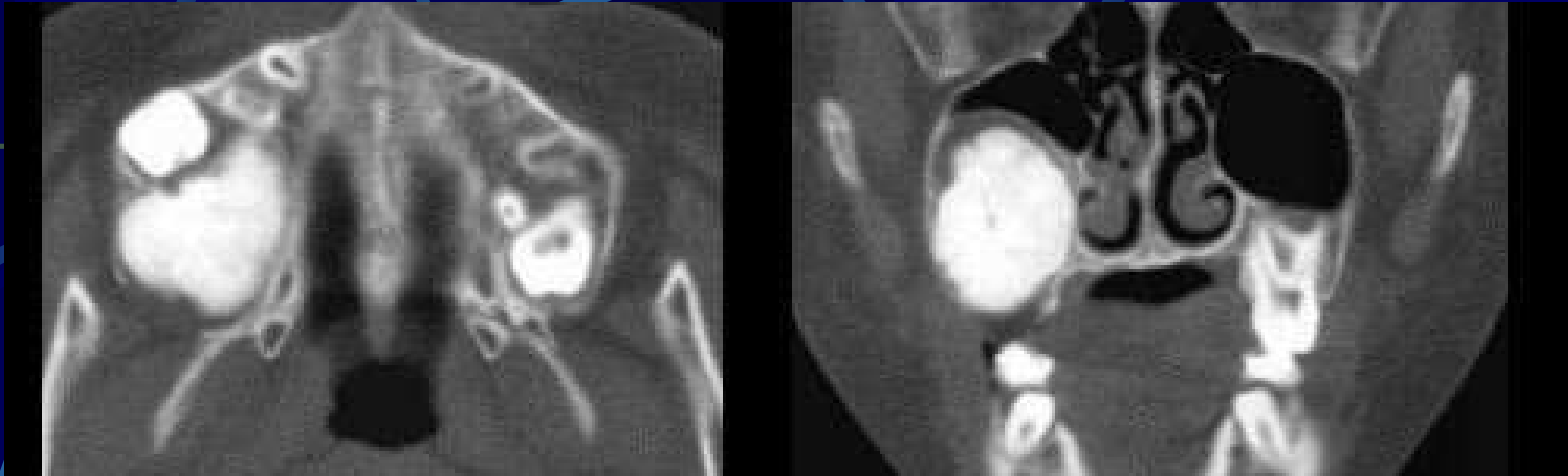



Adenolymfoma



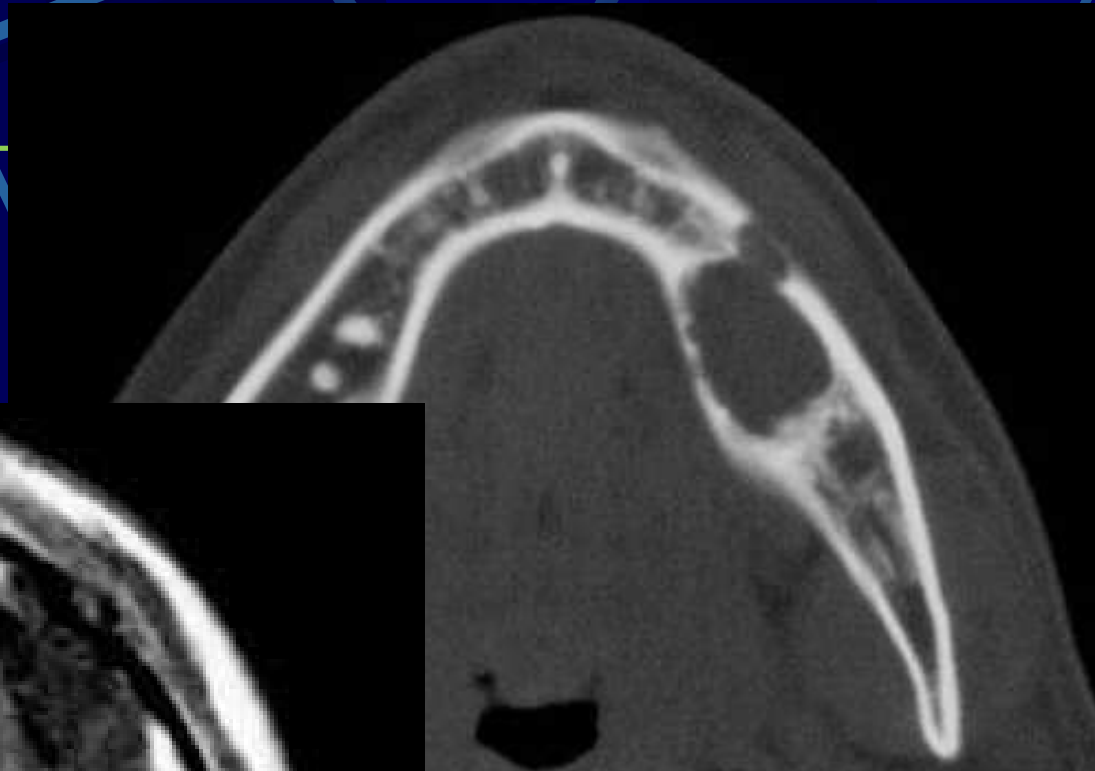
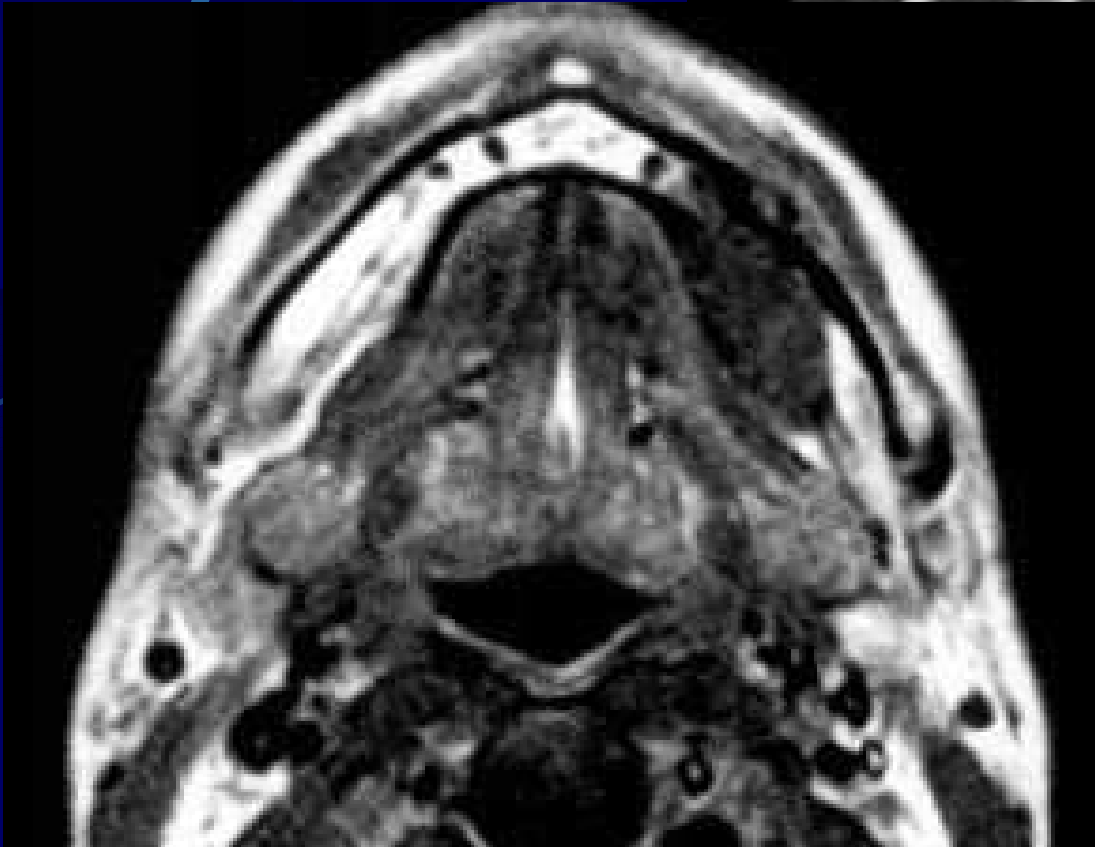


Facionmaxilární ameloblastický fibrom



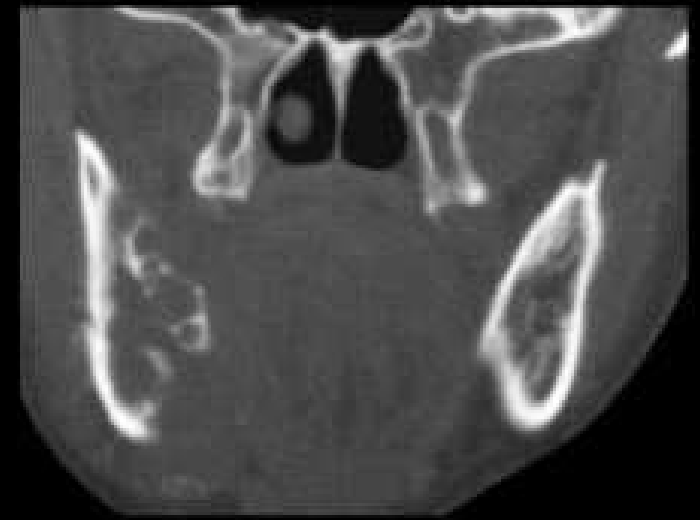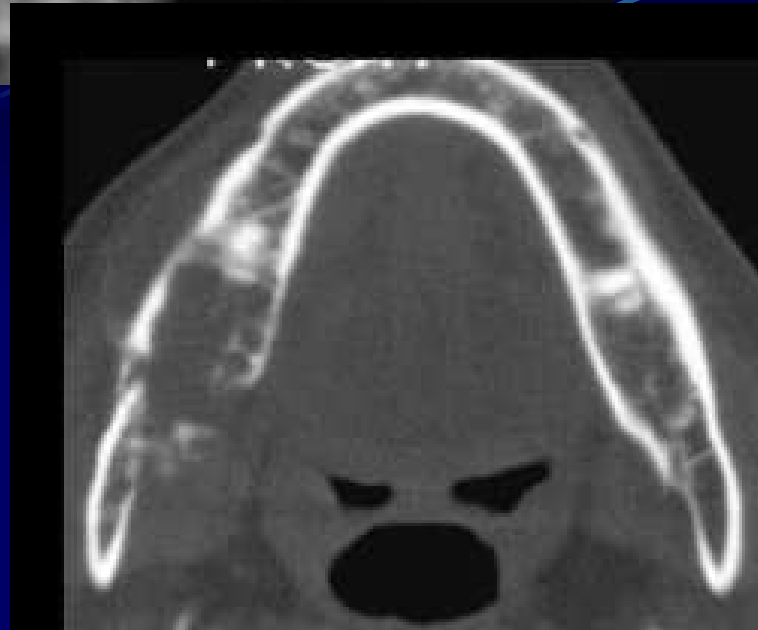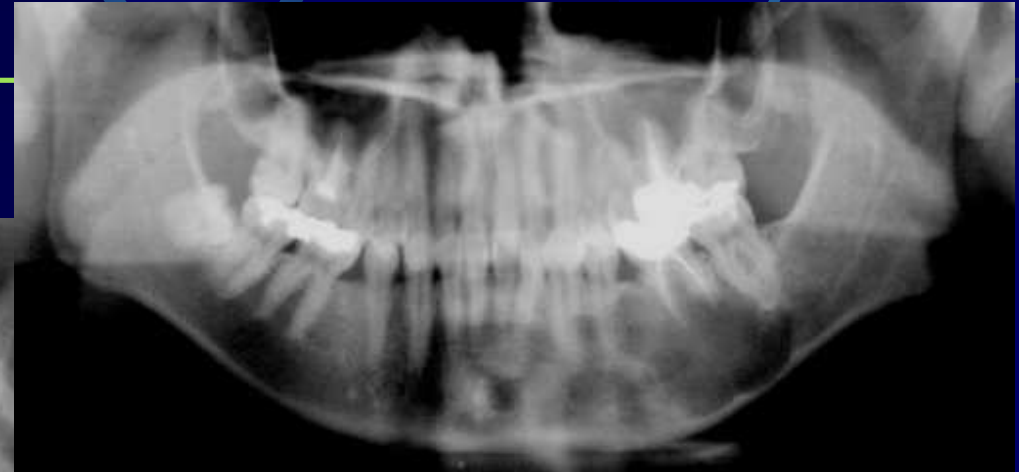


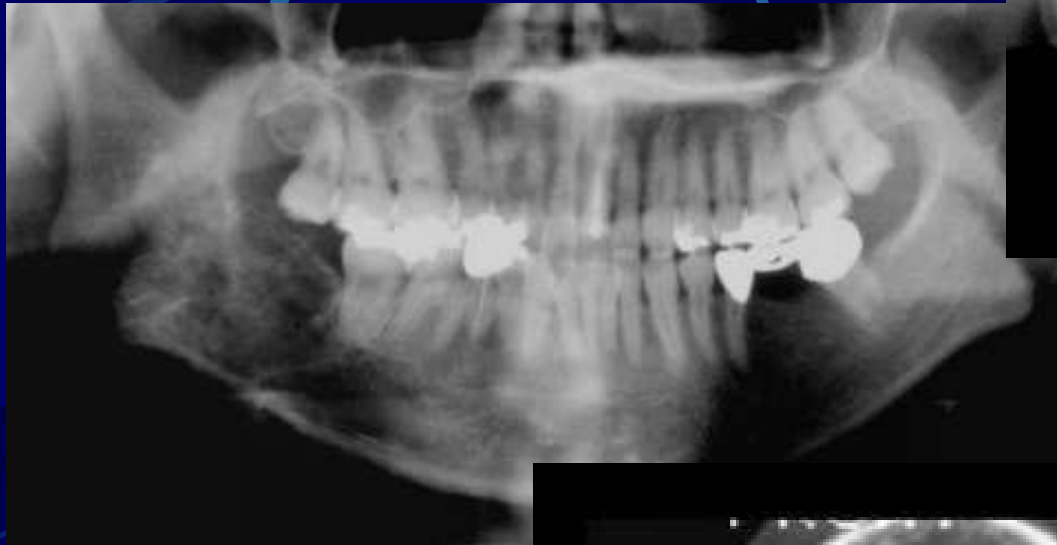Fibrom



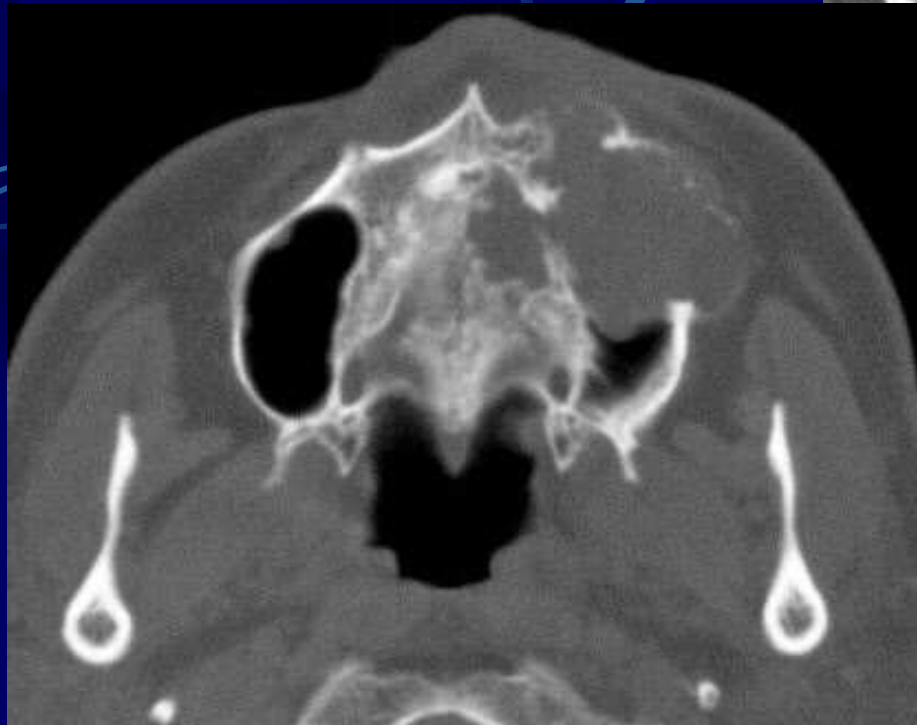
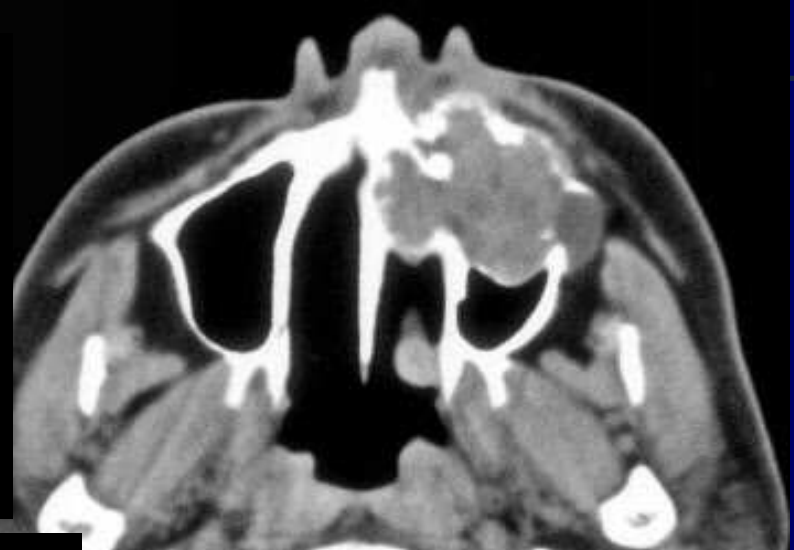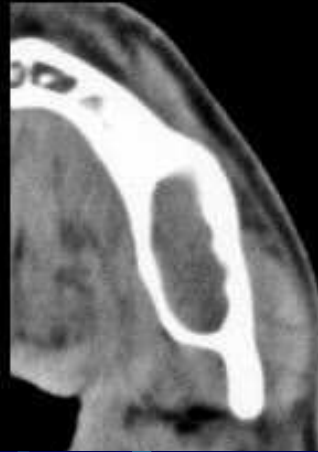
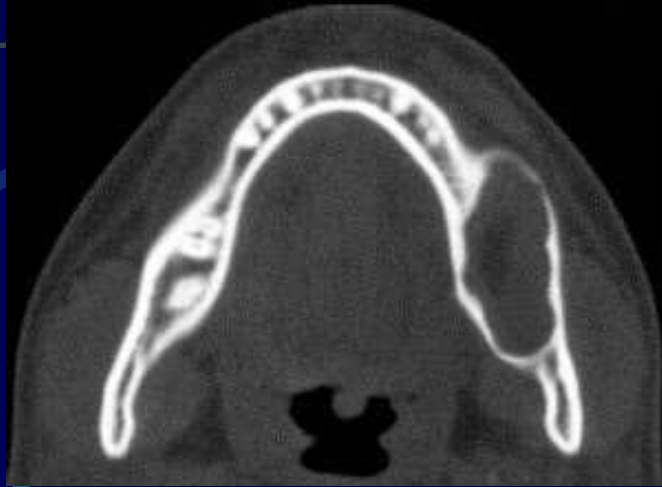



Facionmaxilární ameloblastický fibrosarkom



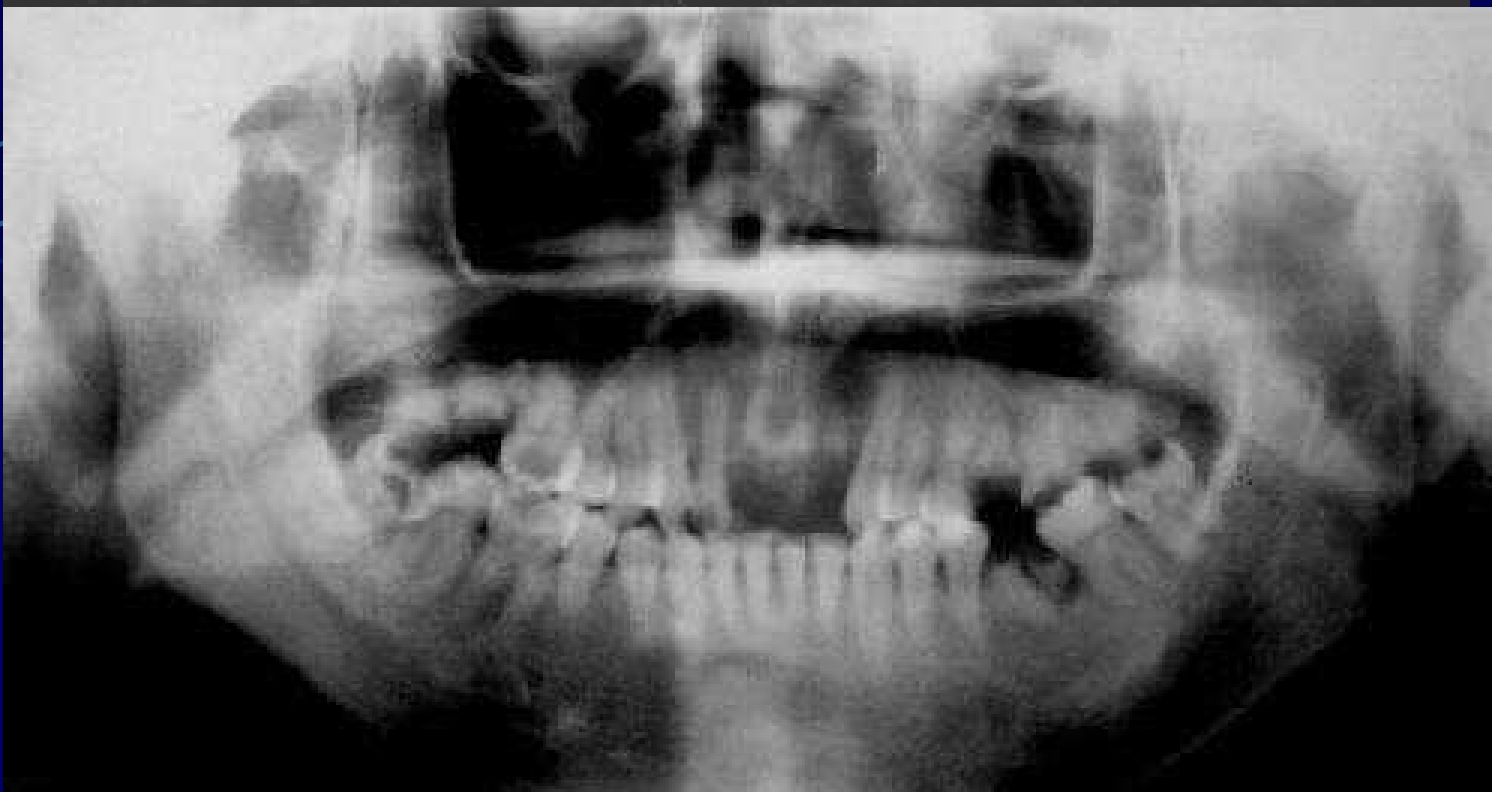
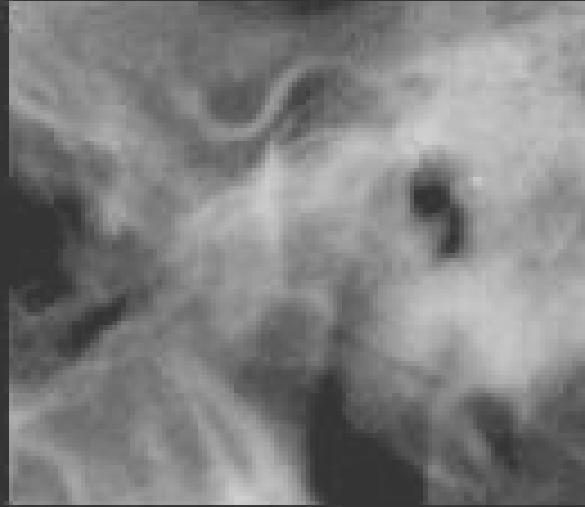
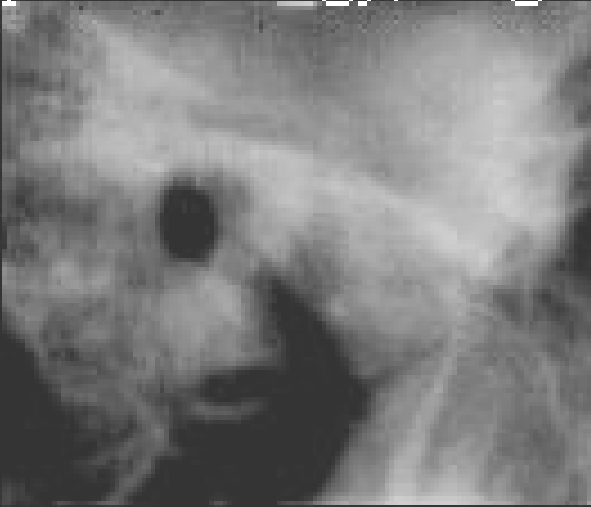
Ameloblastom



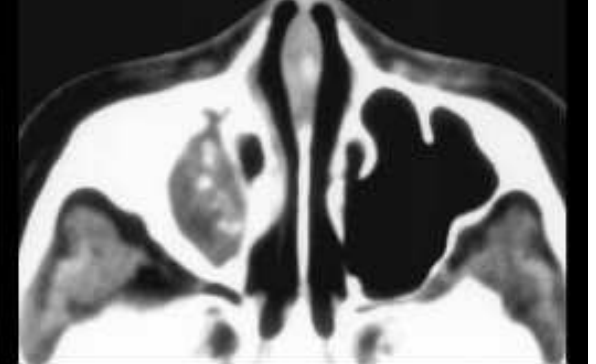
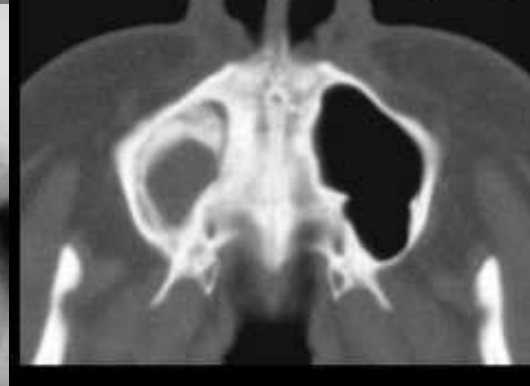
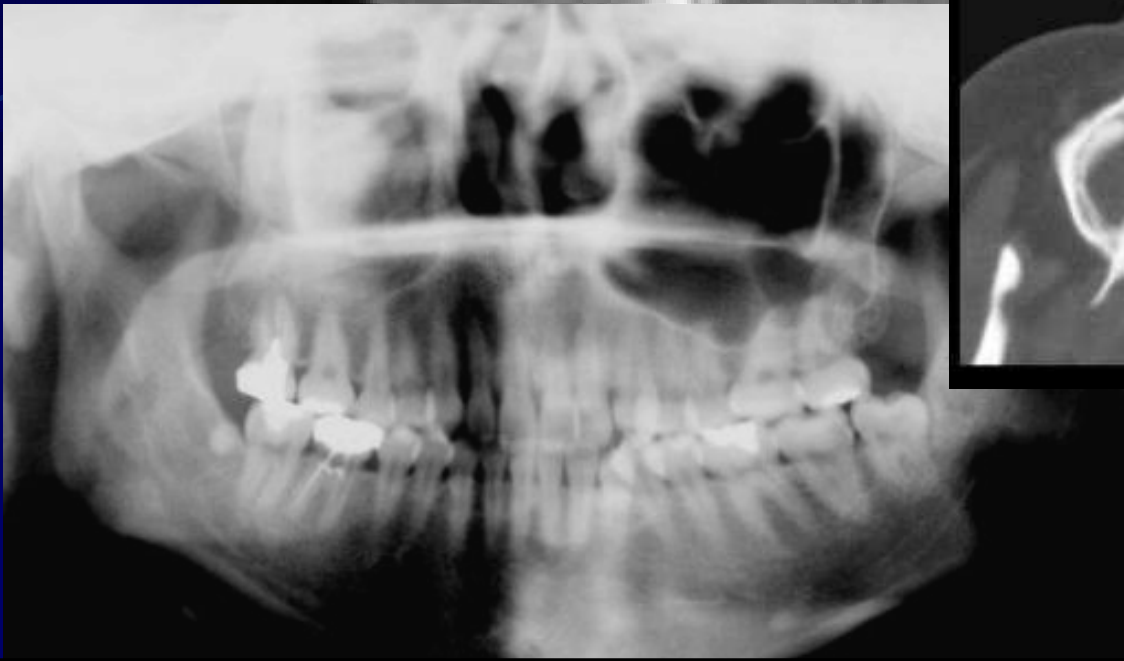
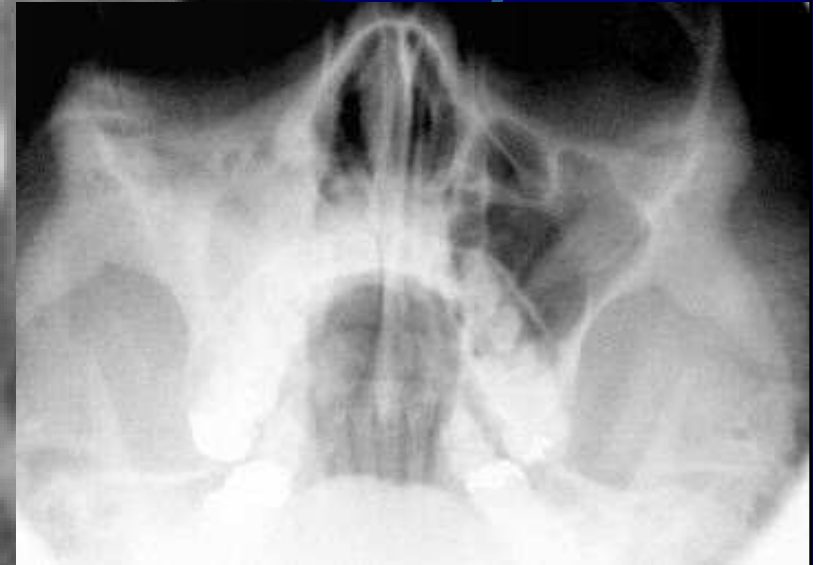
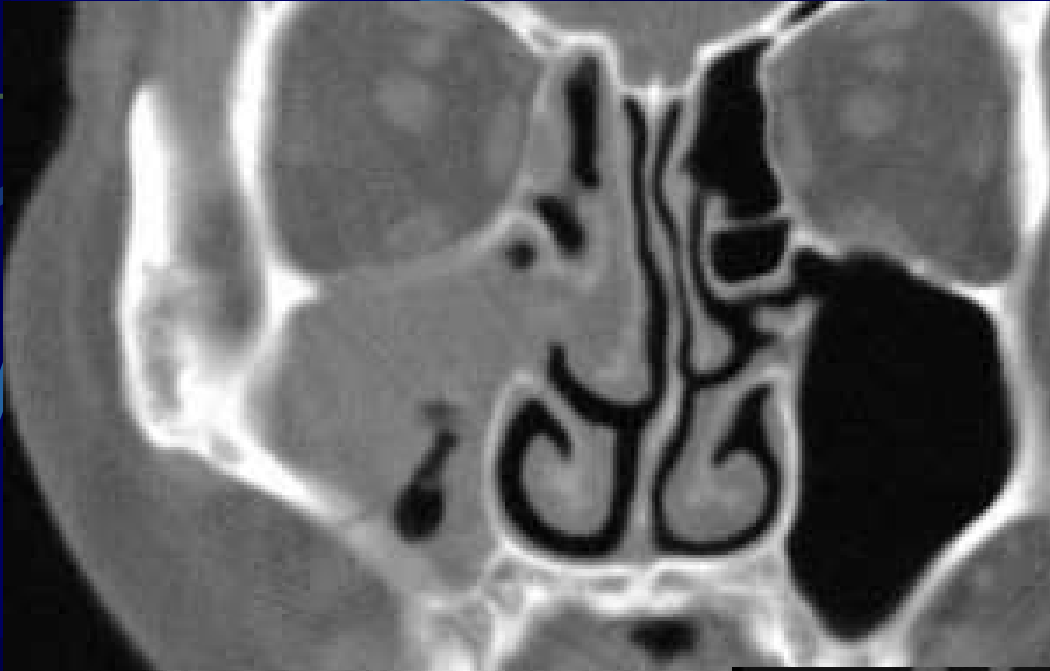Ankylozující artritida



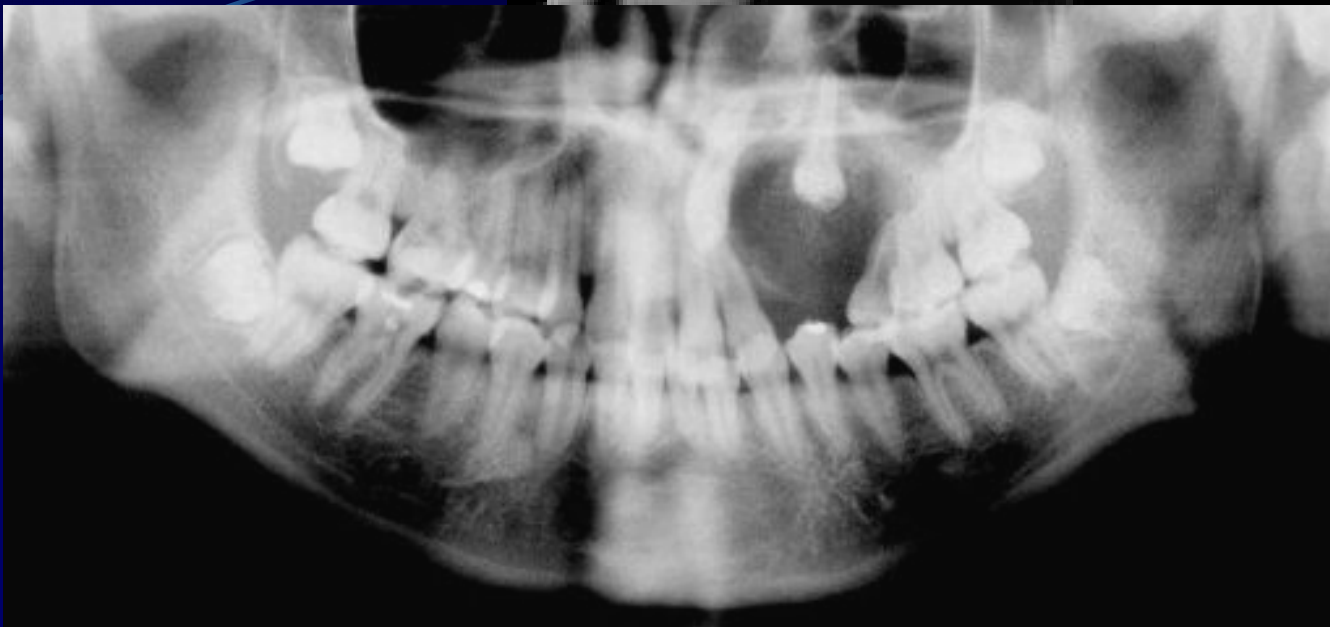
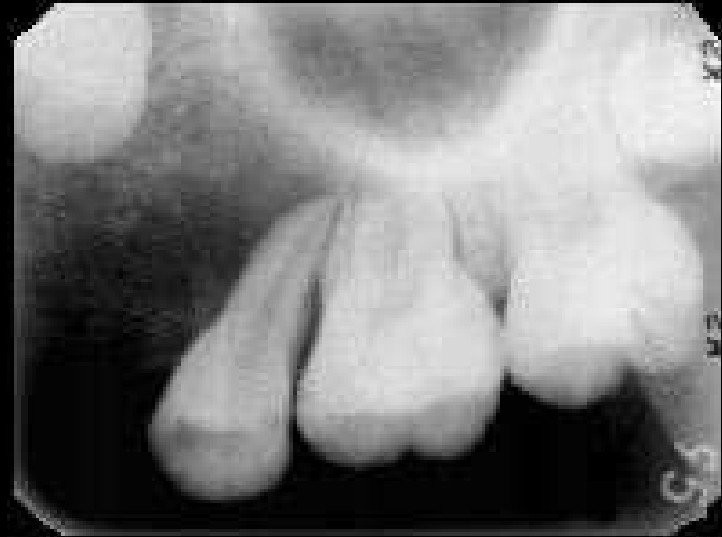
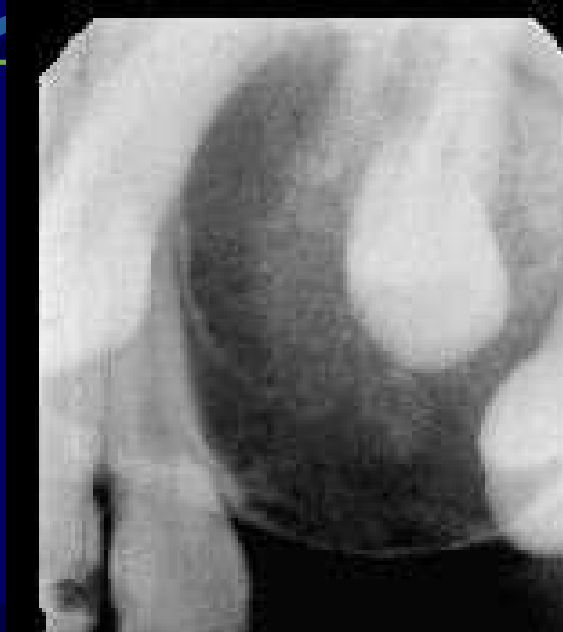Aspergilóza



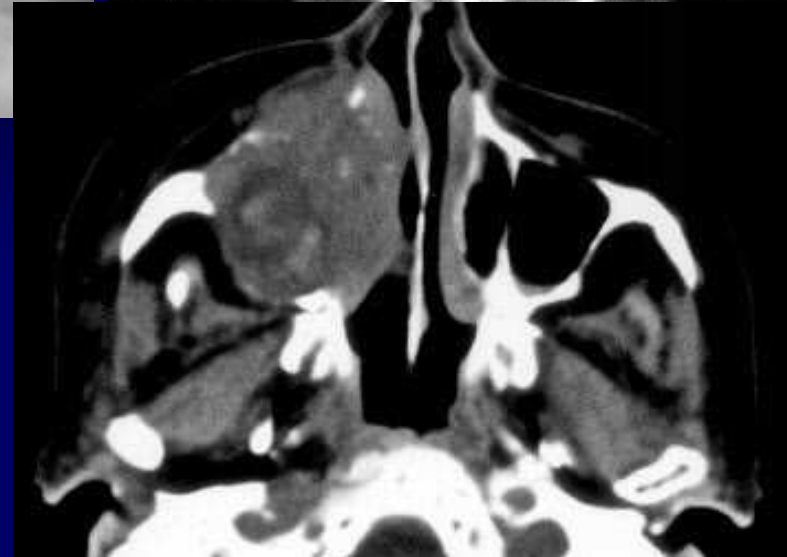
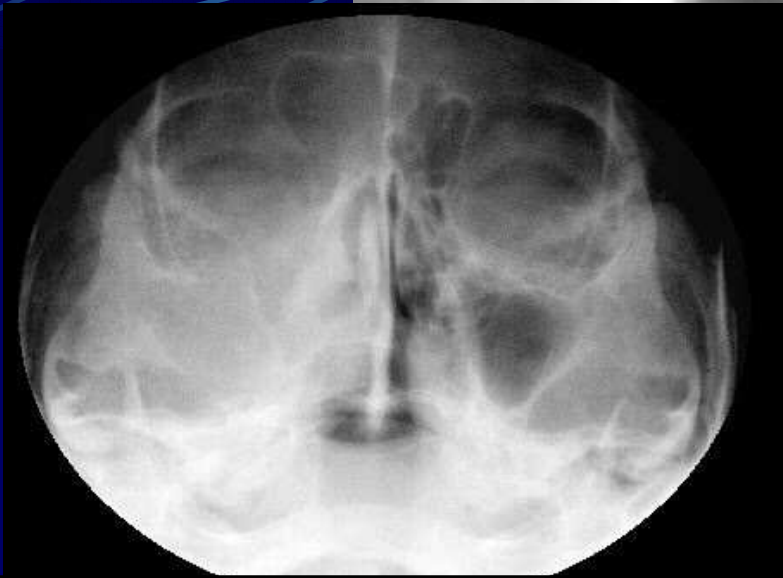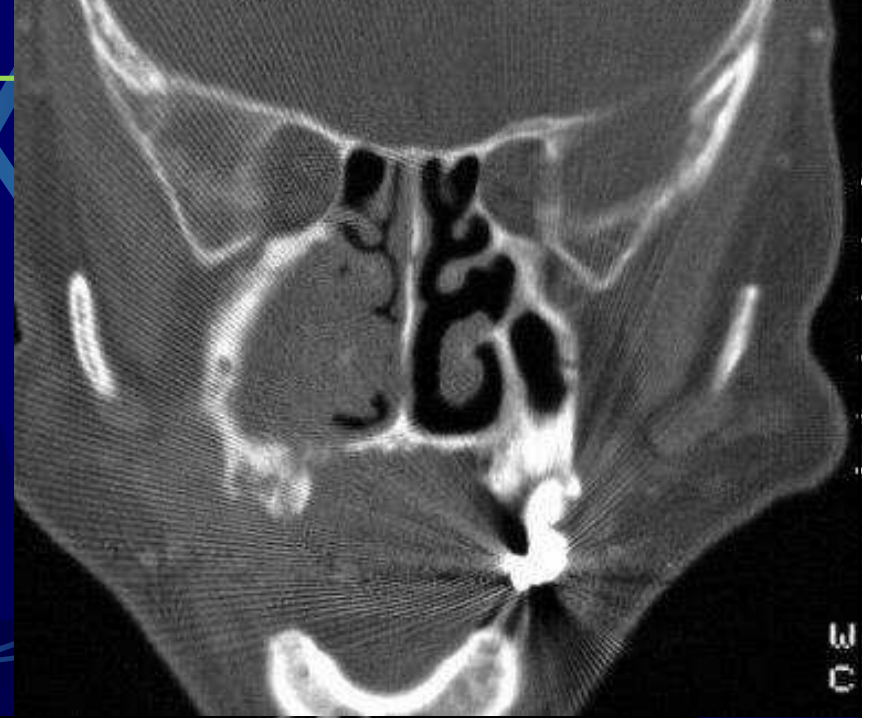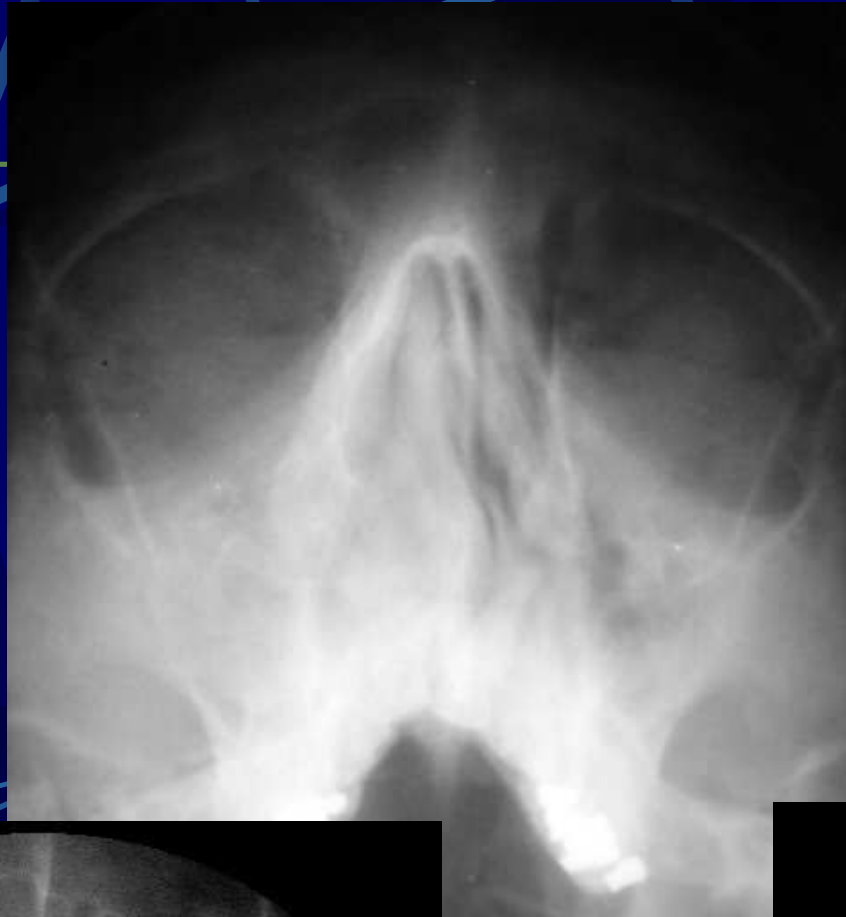



Ca – odontogenní tumor



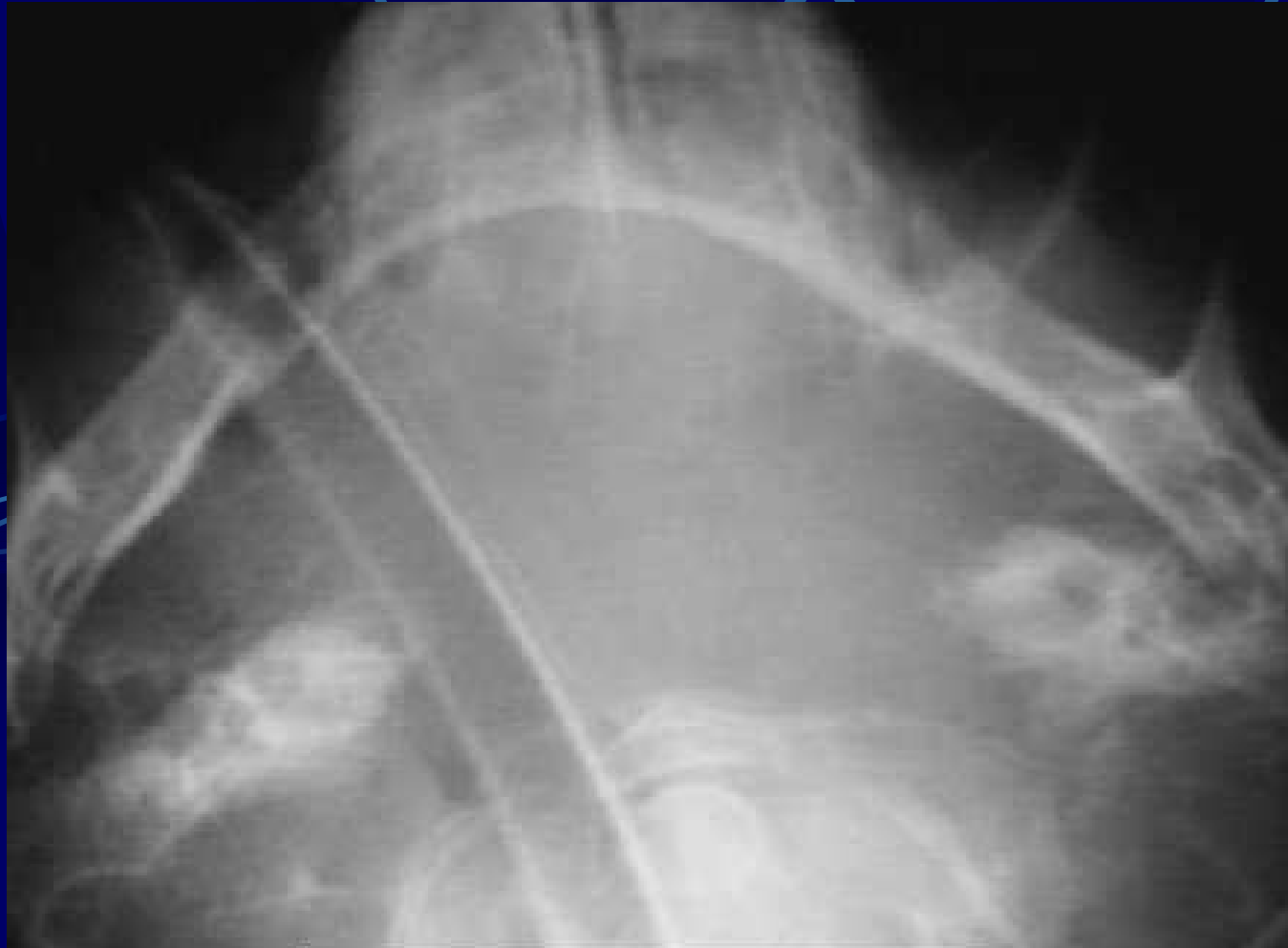

Ca maxilly



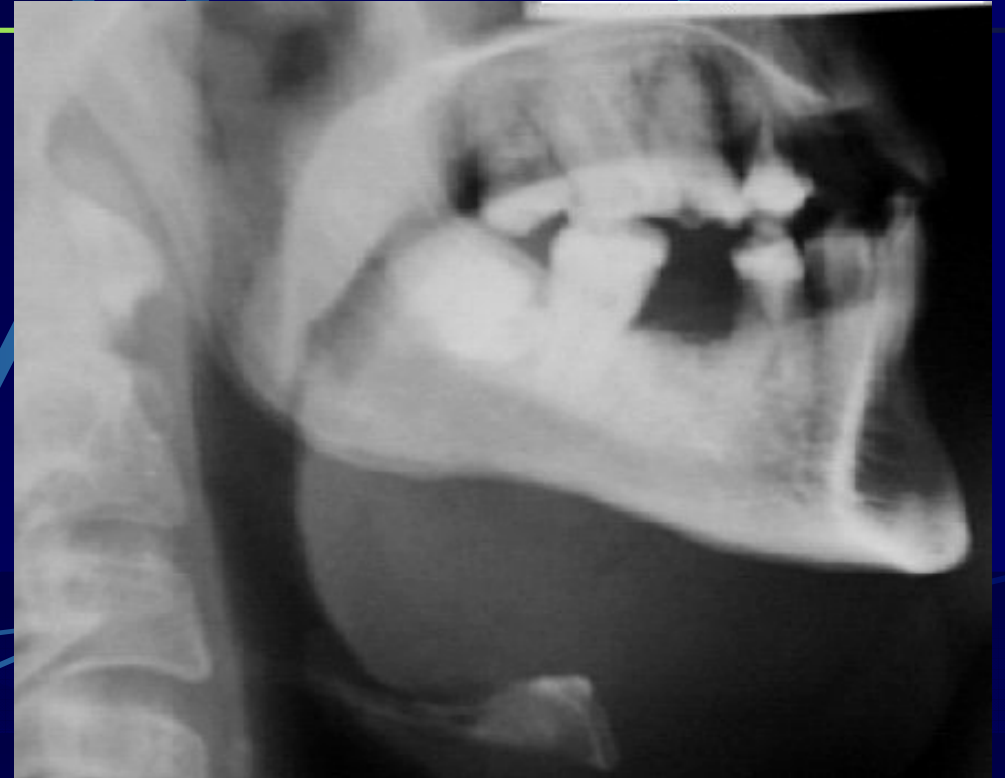
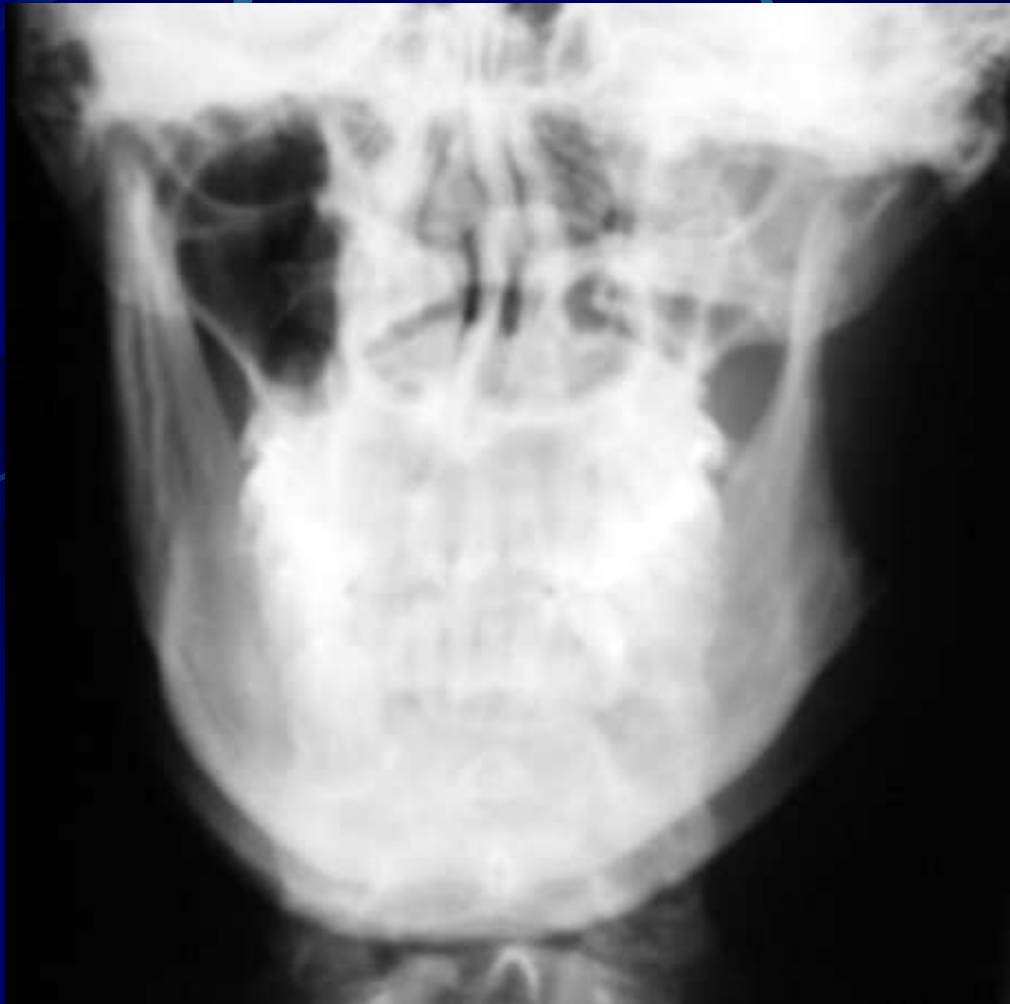
Ca nasopharyngu



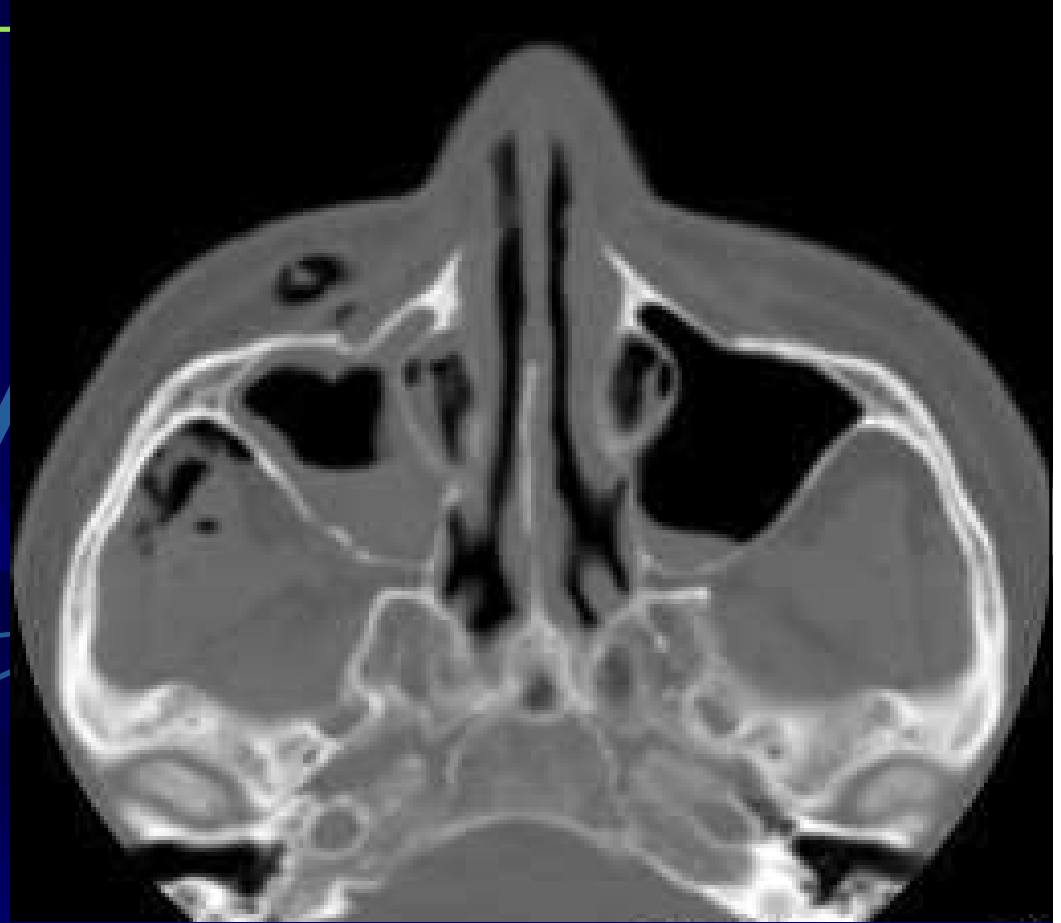
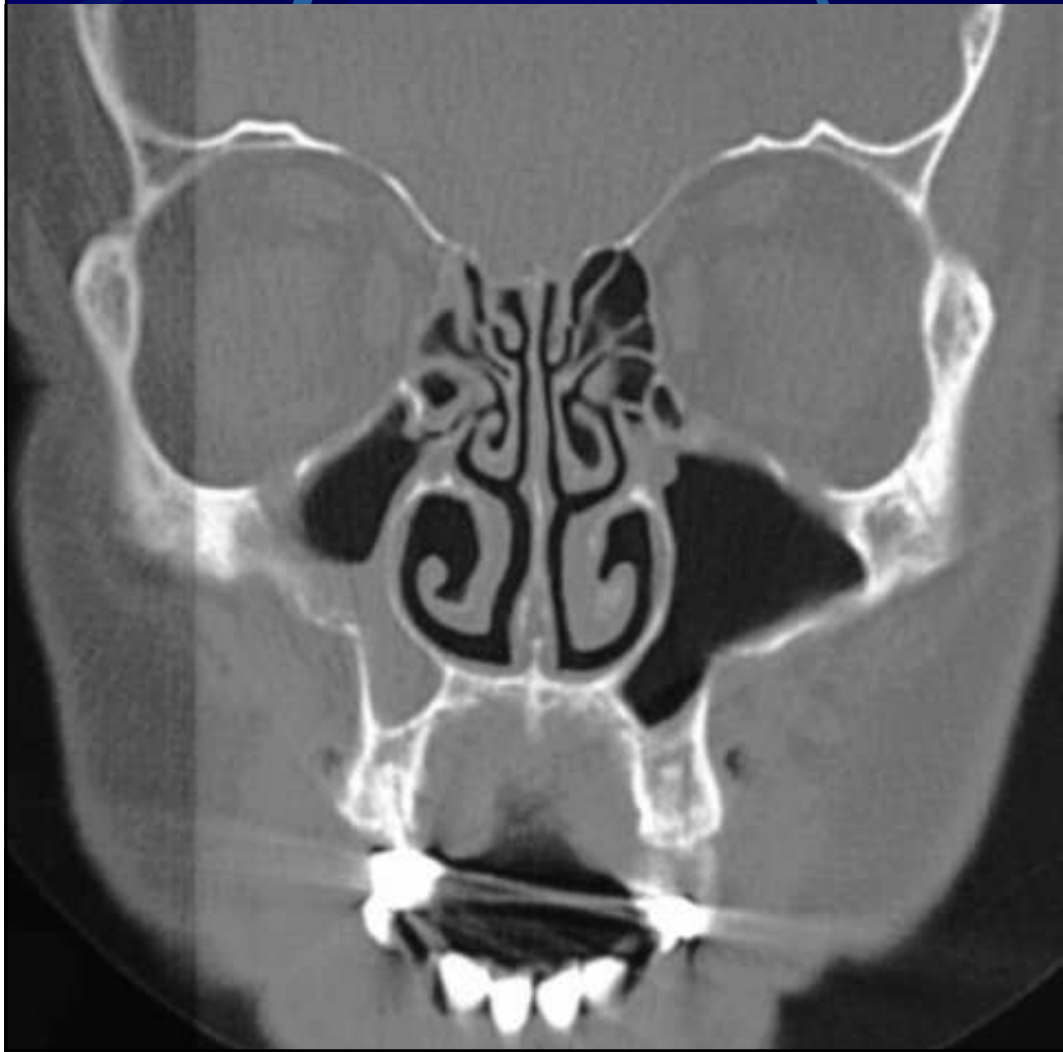

Sarcom mandibuly



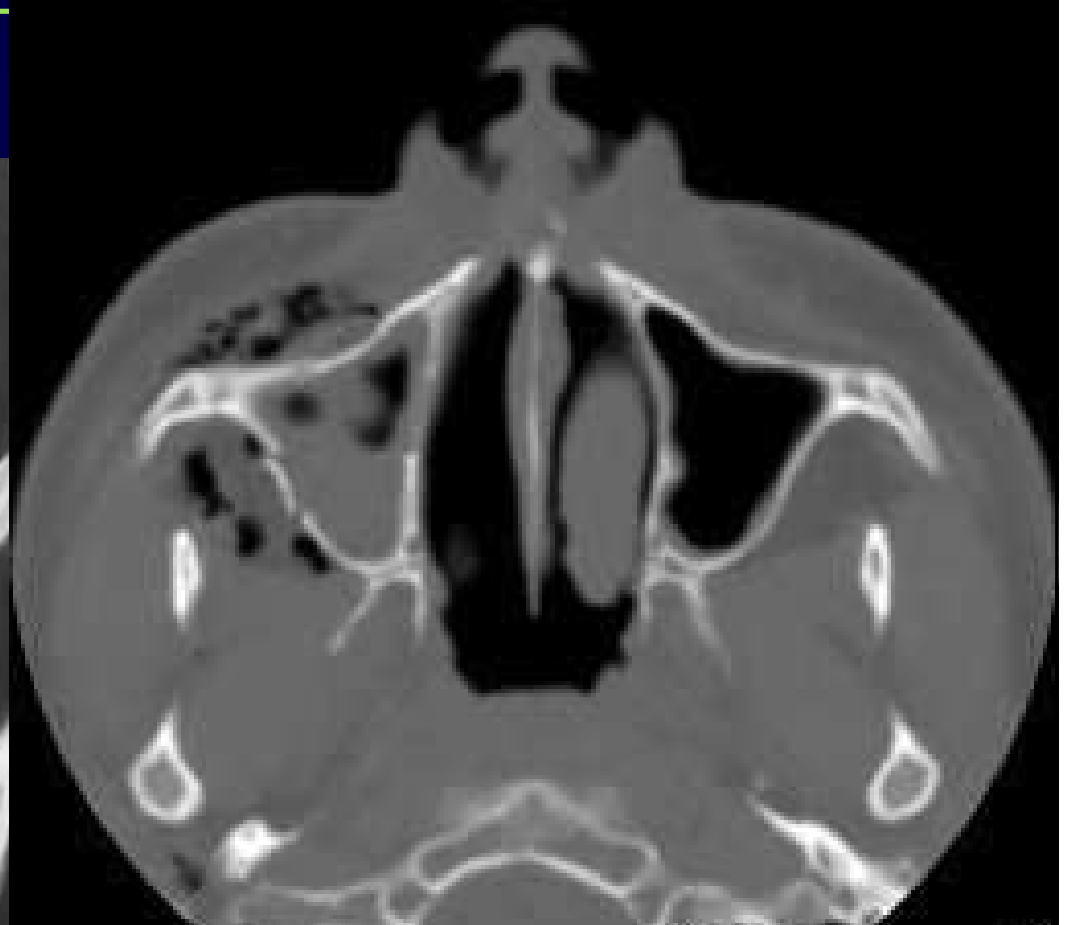
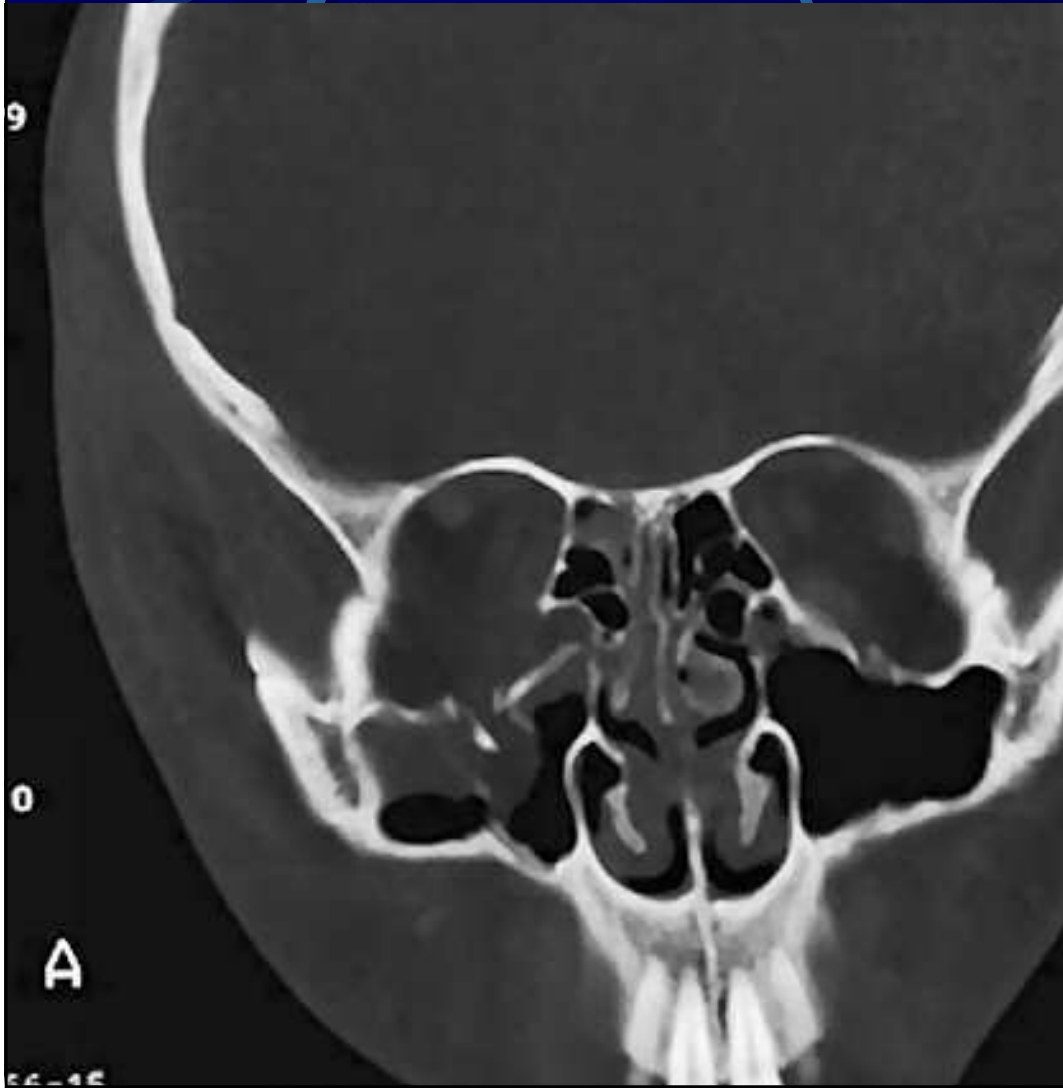

Fraktura



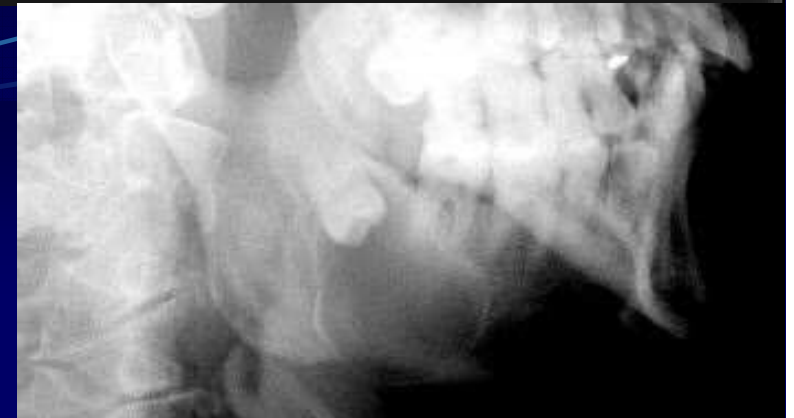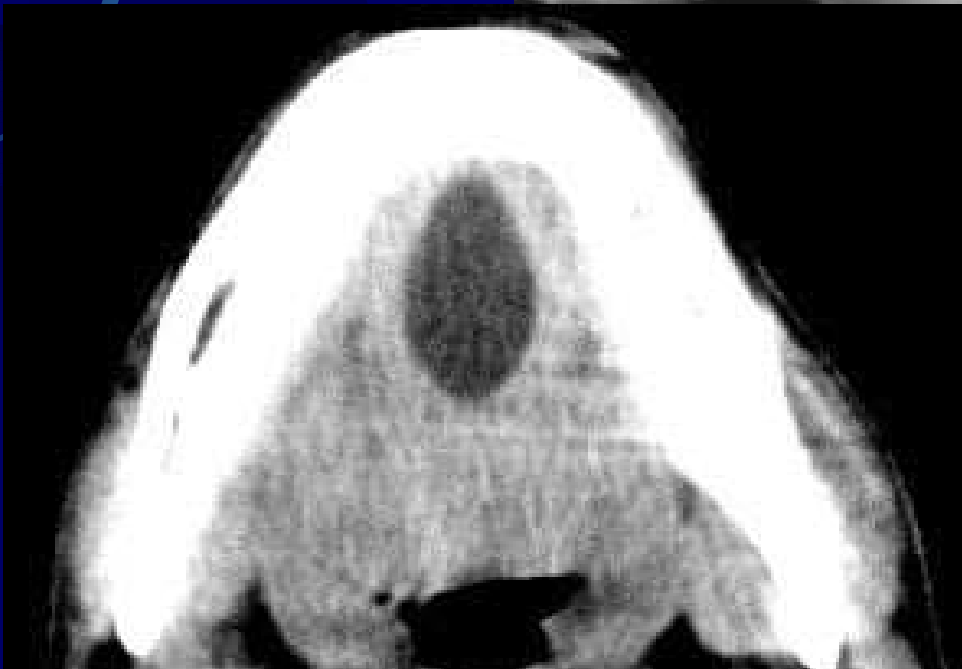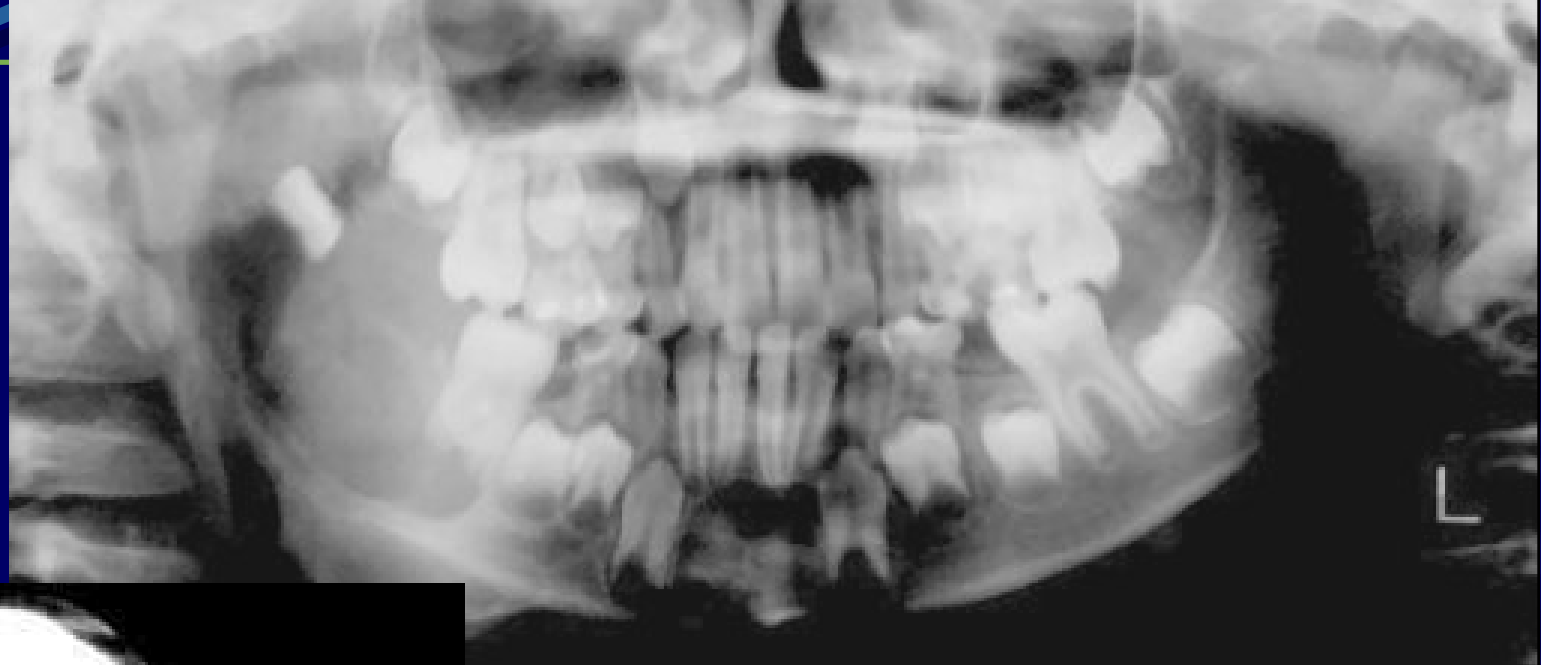



Fraktura



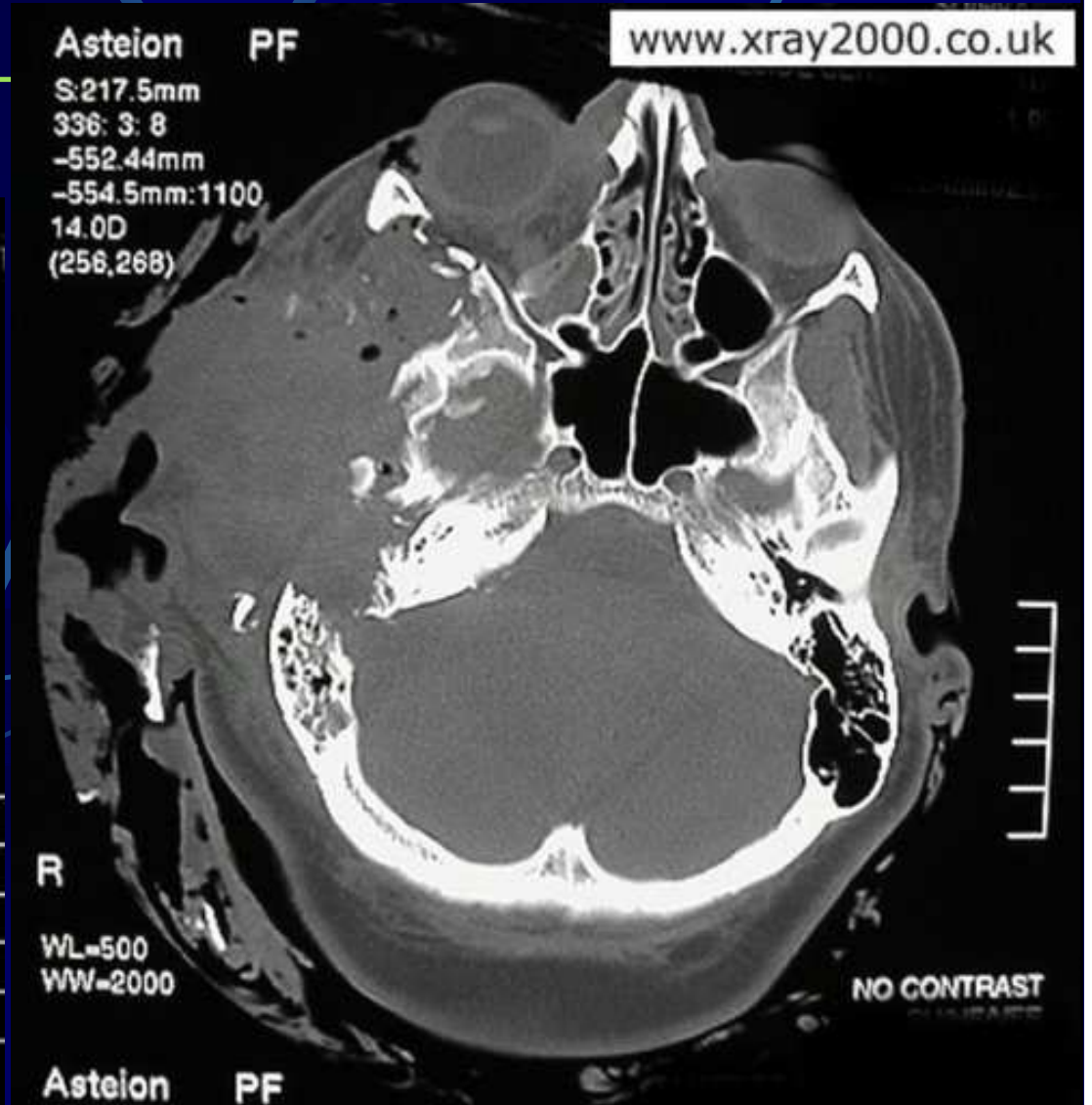
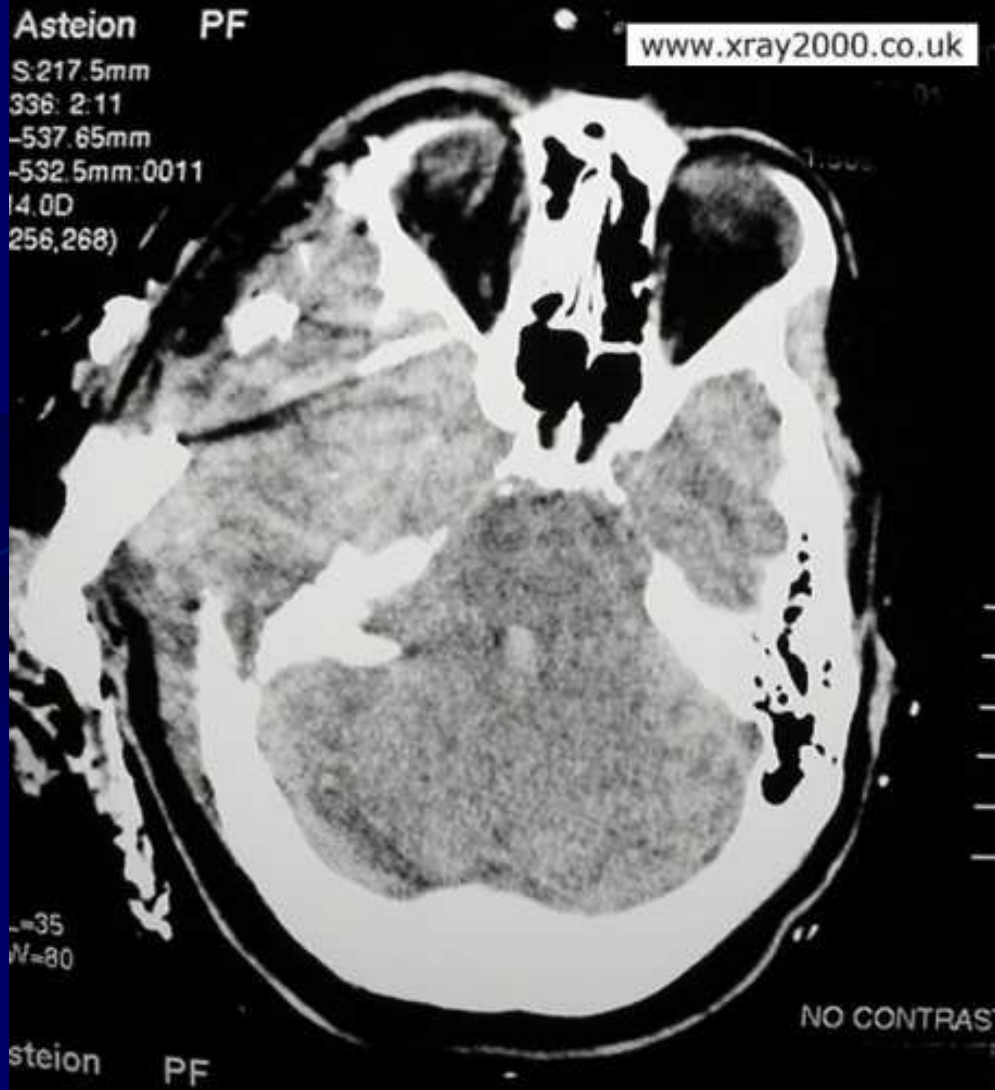


Cysta





Frantura

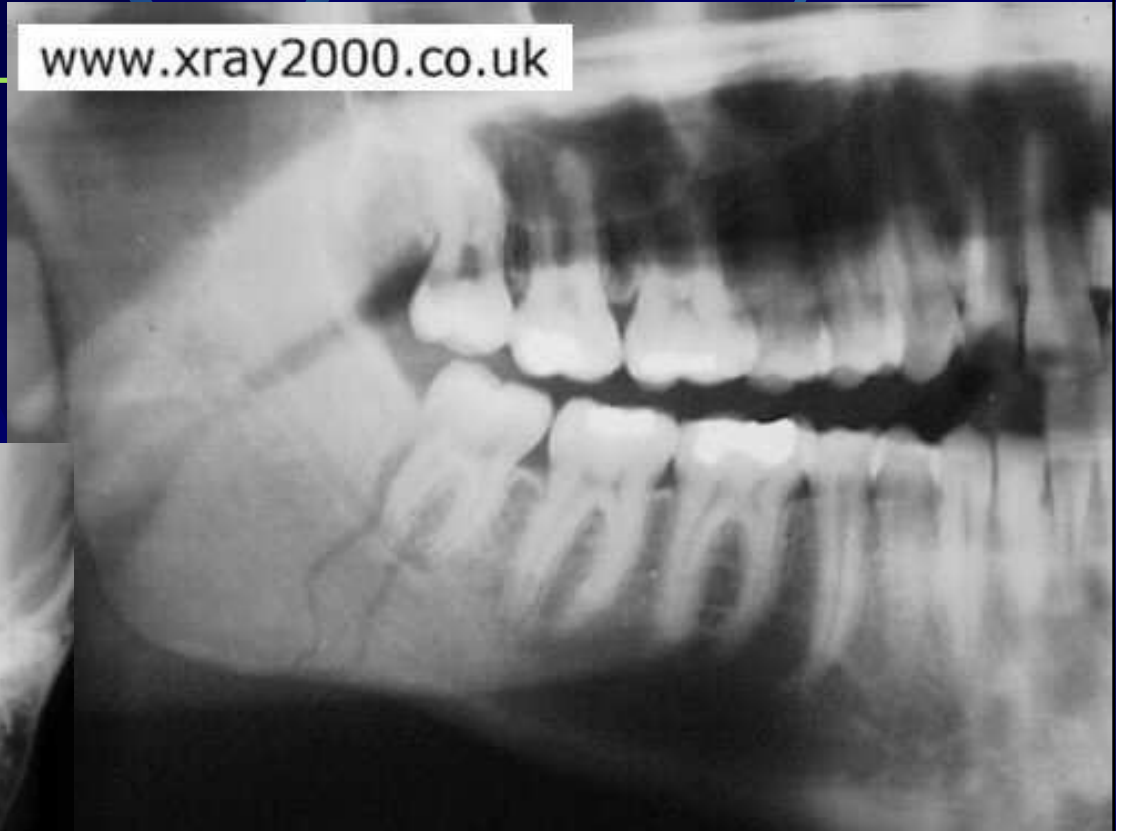



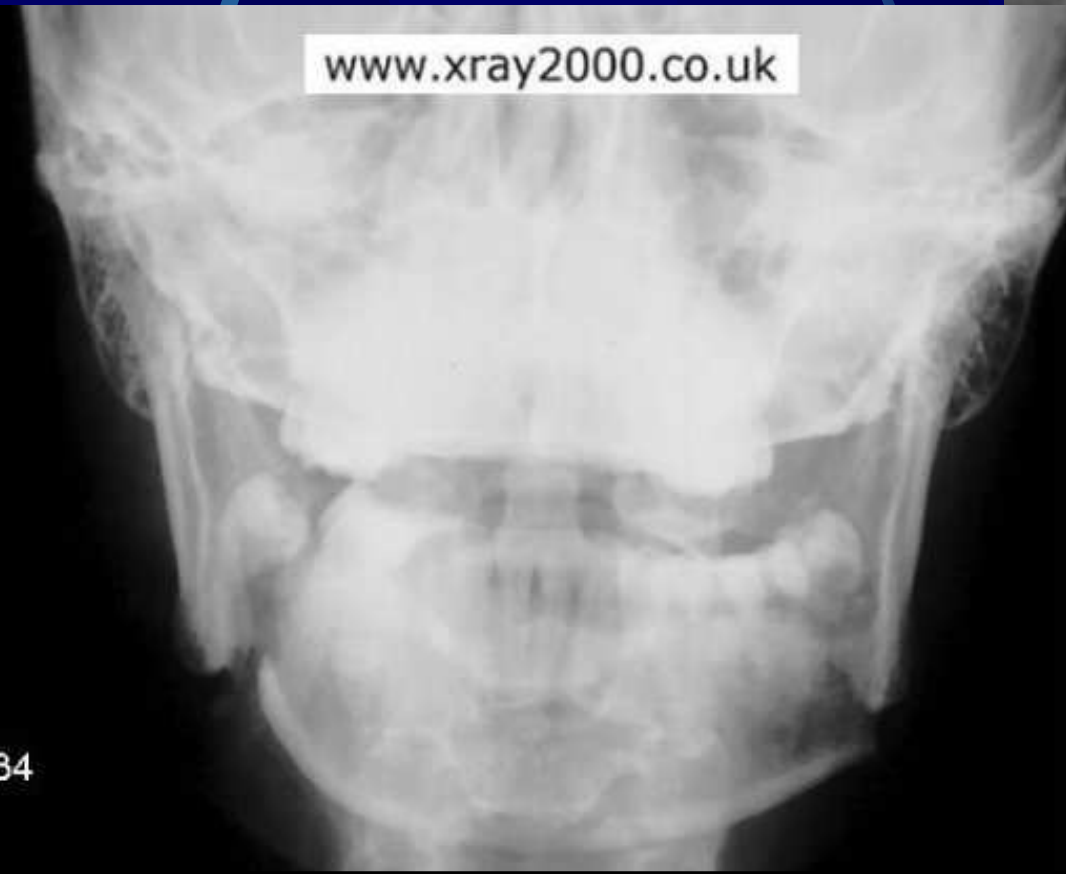Frantura



www.xray2000.co.uk



www.xray2000.co.uk

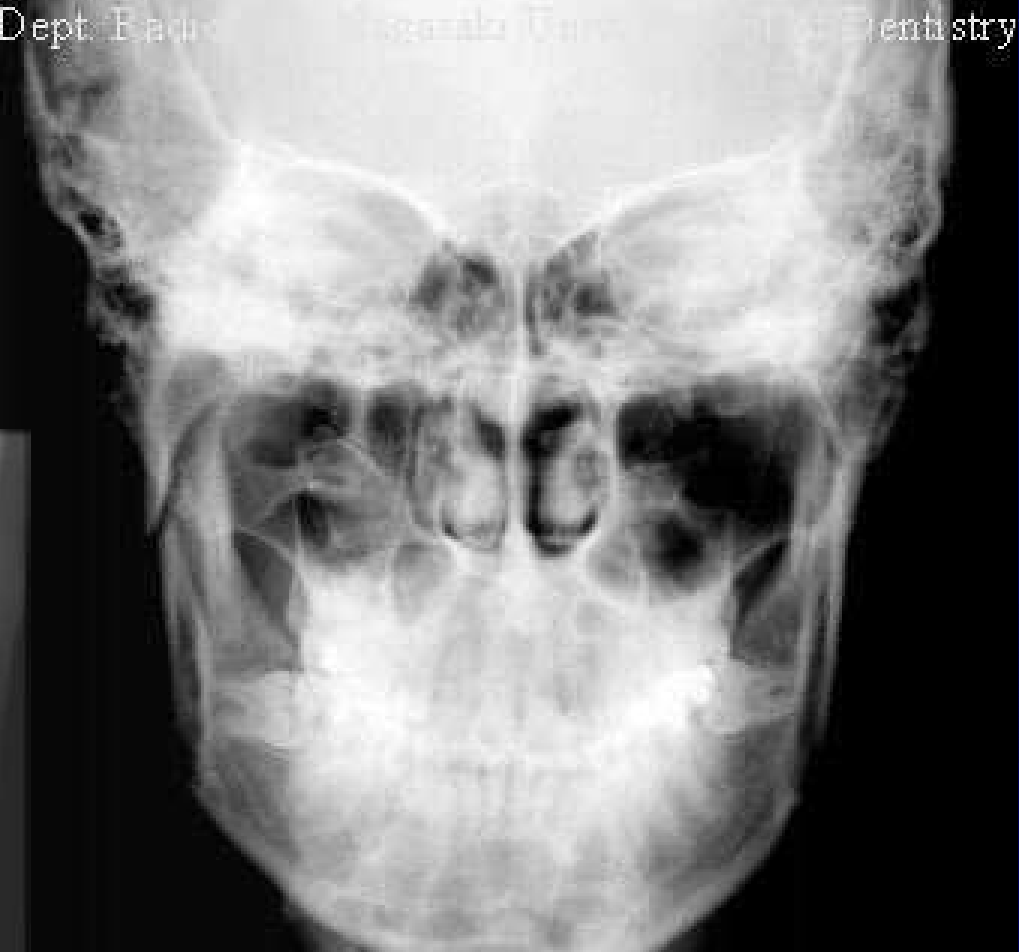




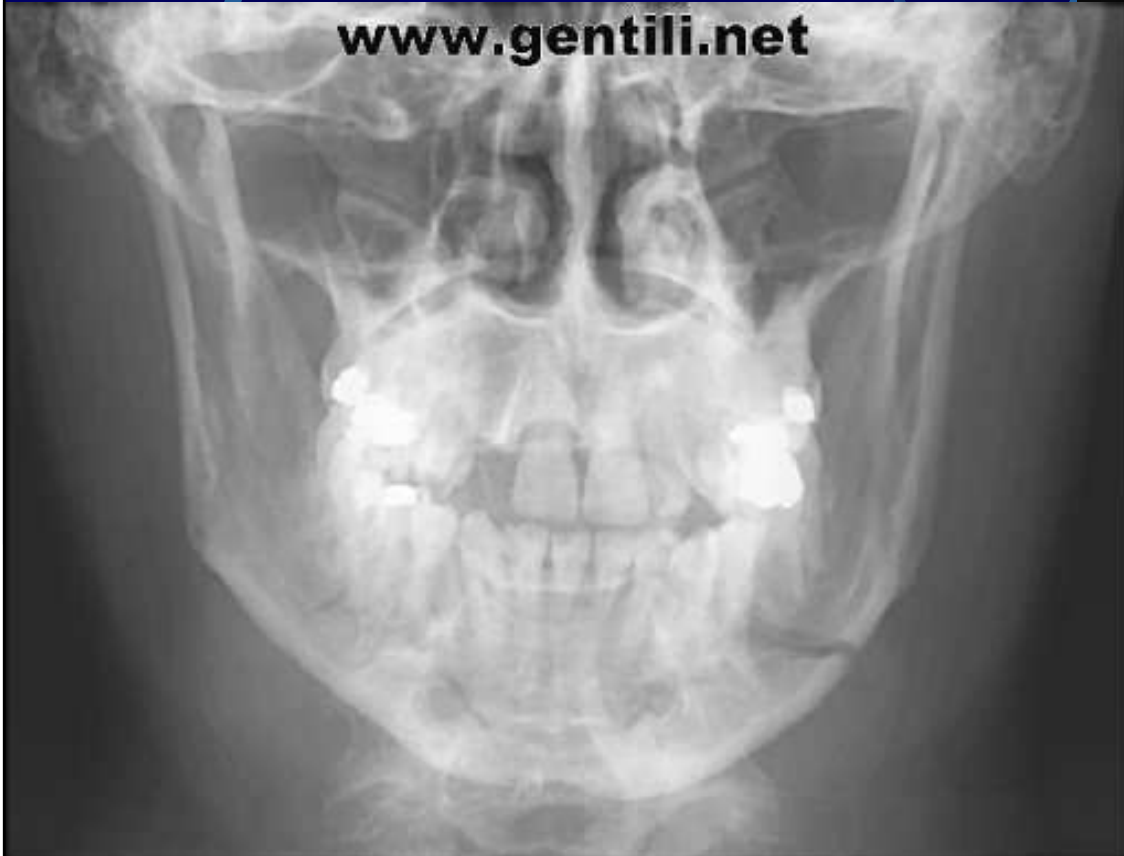Frantura



Dept. Radiology, Masaryk University Brno, Faculty of Medicine, Brno, Czech Republic



www.gentili.net

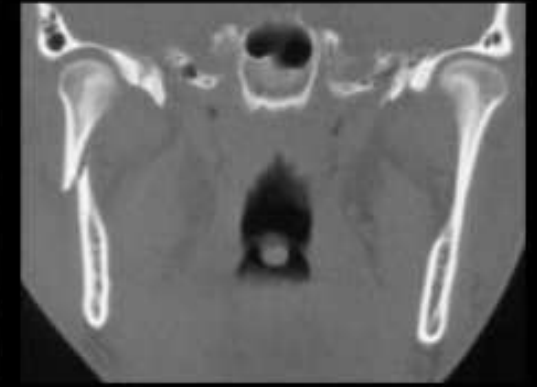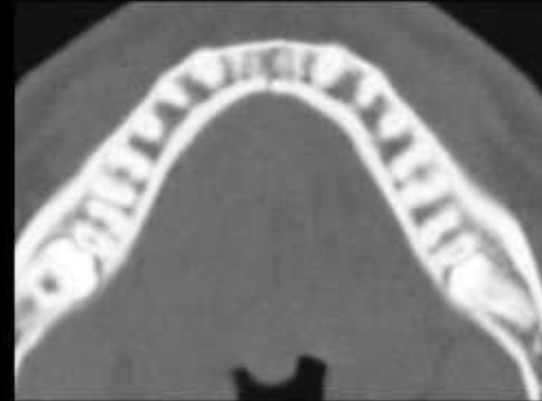

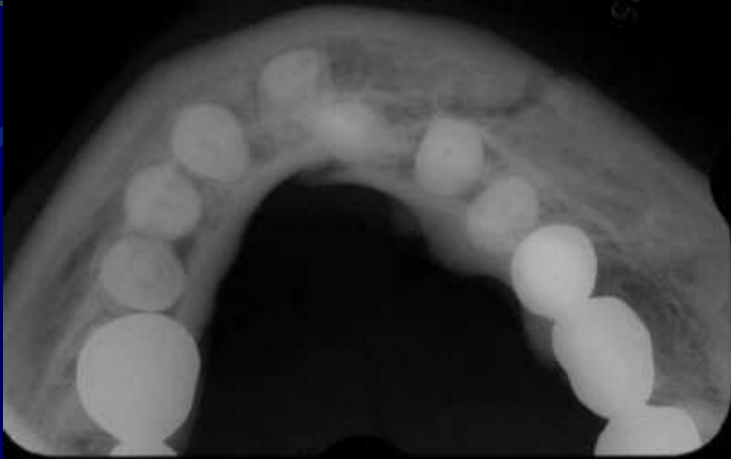


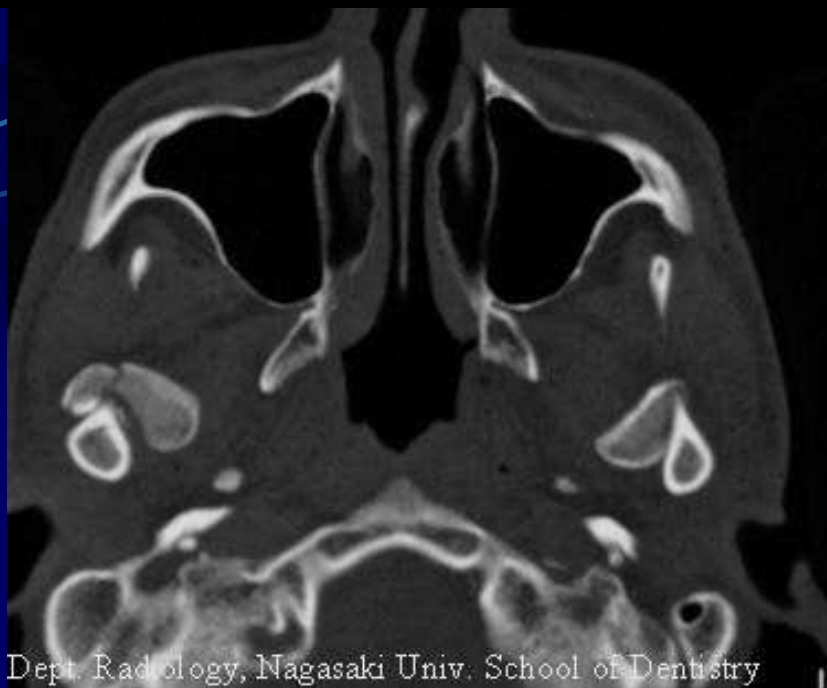
Frantura



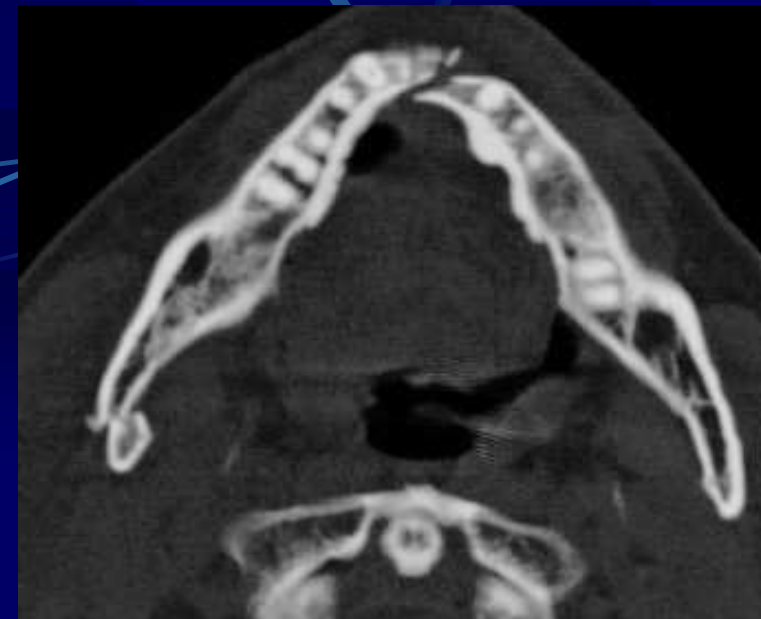
Dept. Radiology, Nagasaki Univ. School of Dentistry




Dept. Radiology, Nagasaki Univ. School of Dentistry



Dept. Radiology, Nagasaki Univ. School of Dentistry

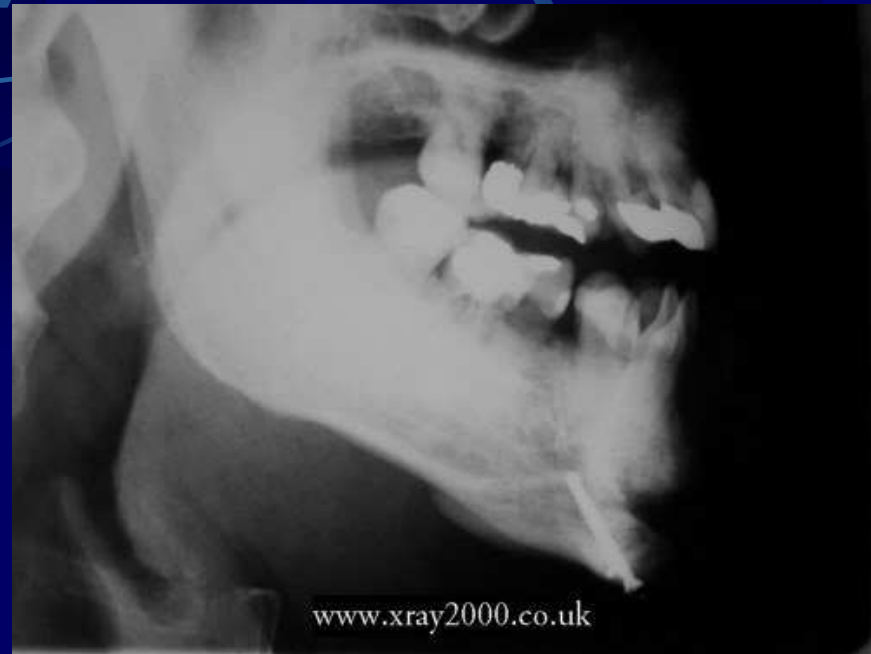
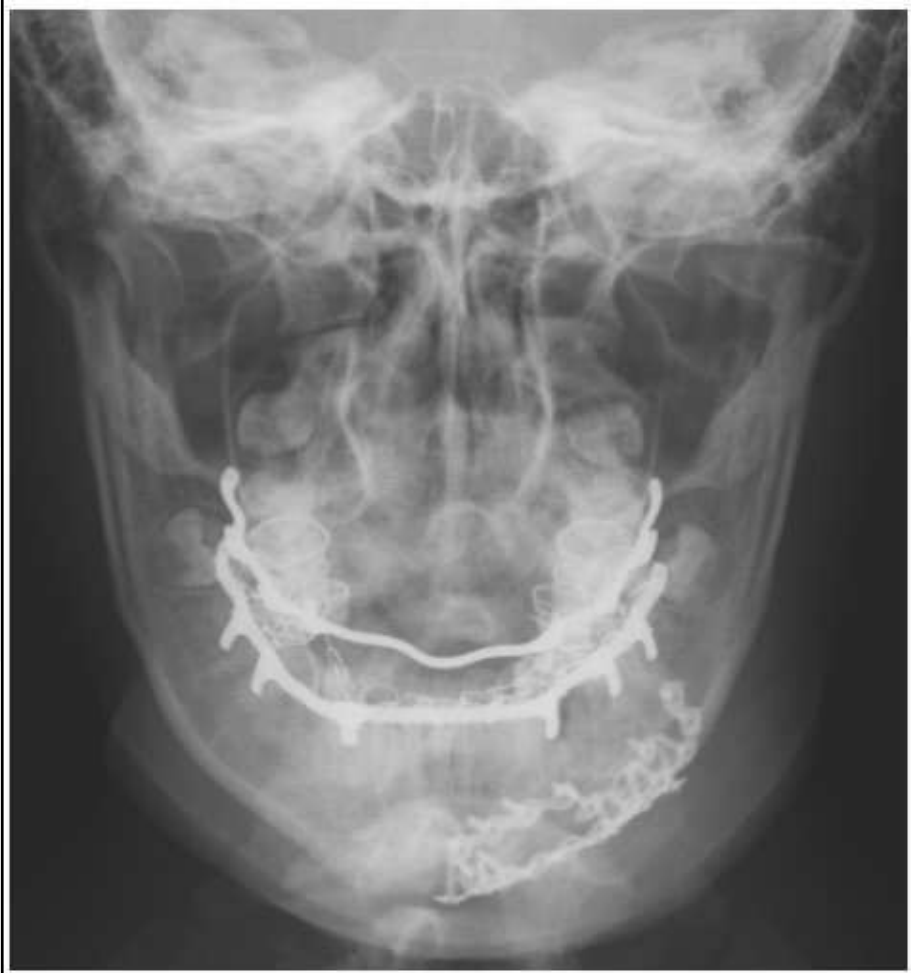
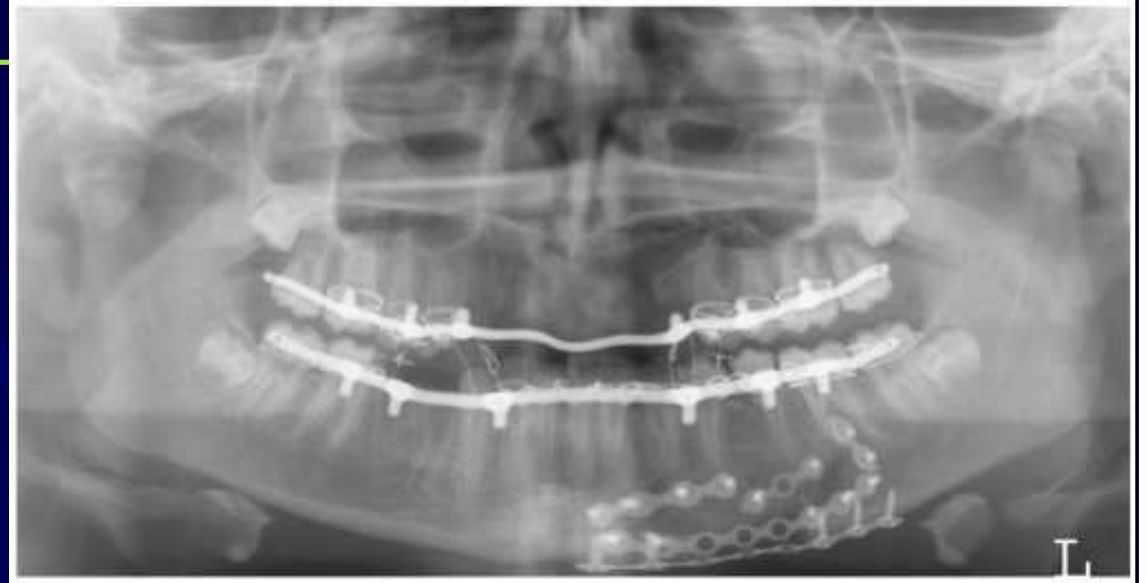Dept. Radiology, Nagasaki Univ. School of Dentistry





Frantura

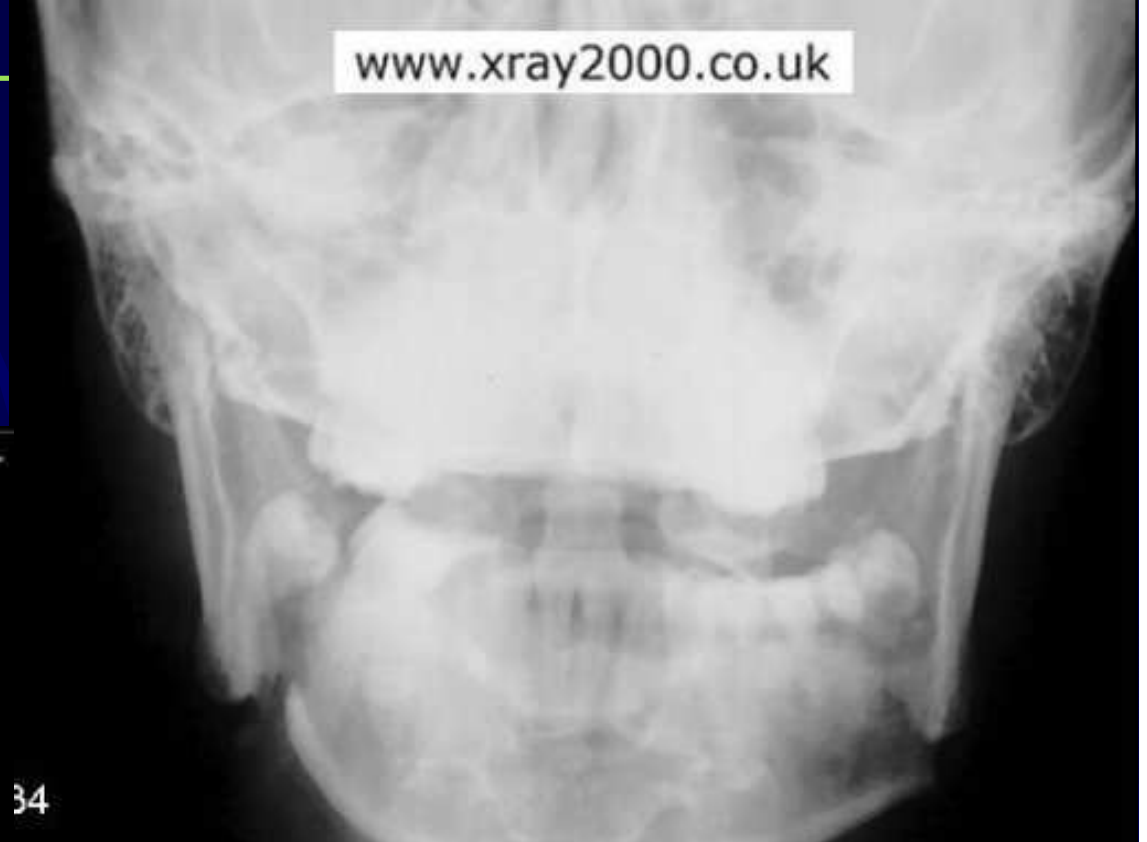



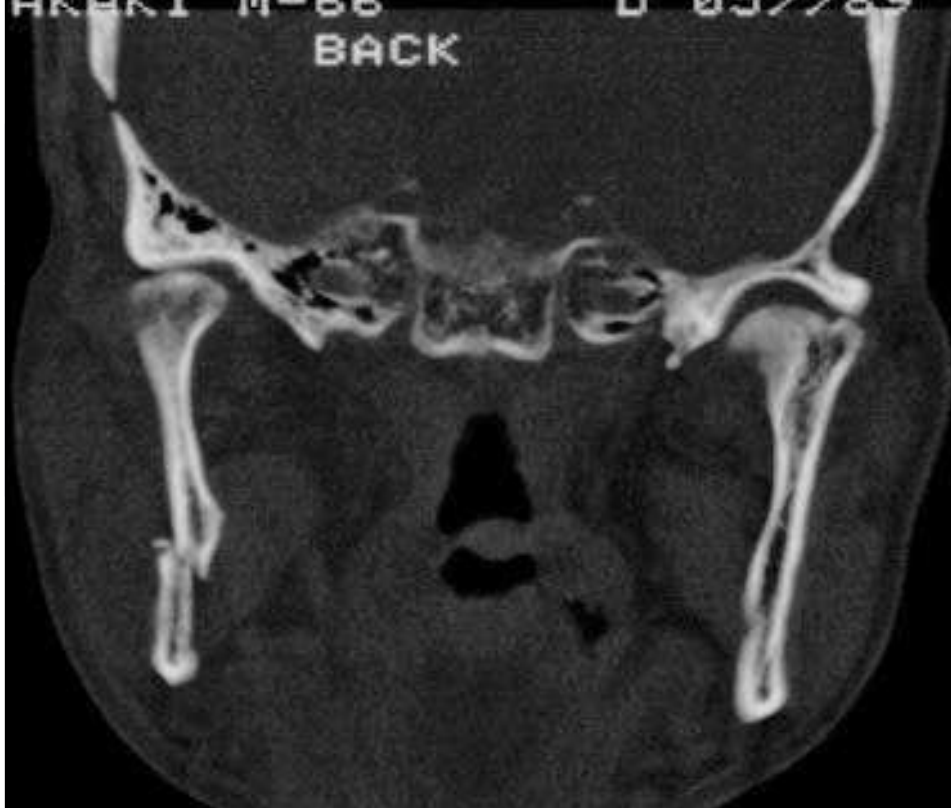Frantura



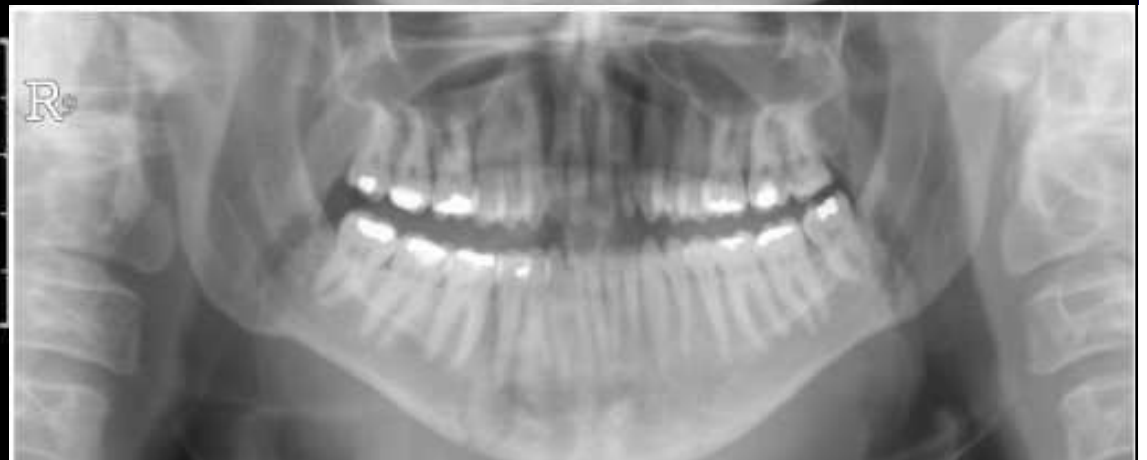www.xray2000.co.uk



R-H NAGASAKI UNIV. DENTAL
AKAKI M-66 D 057789
BACK

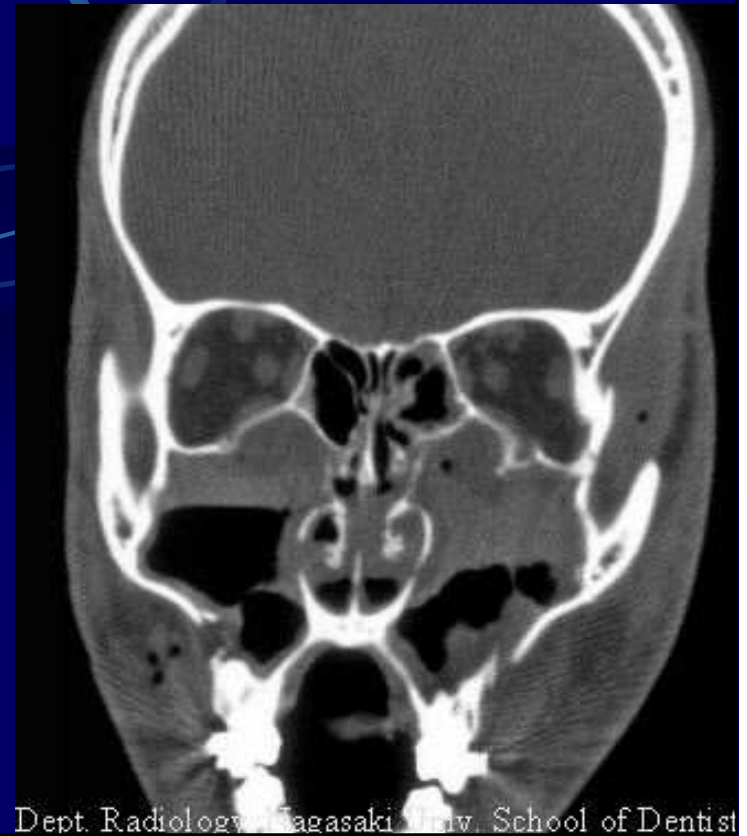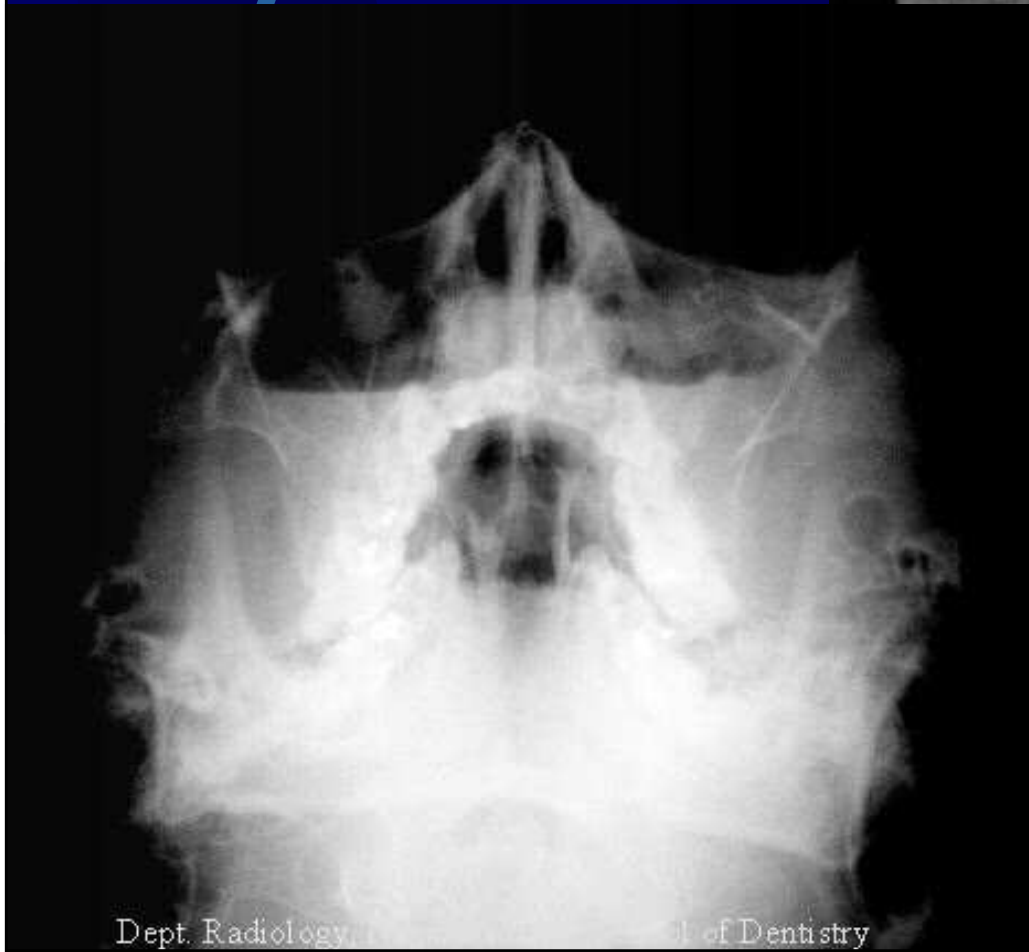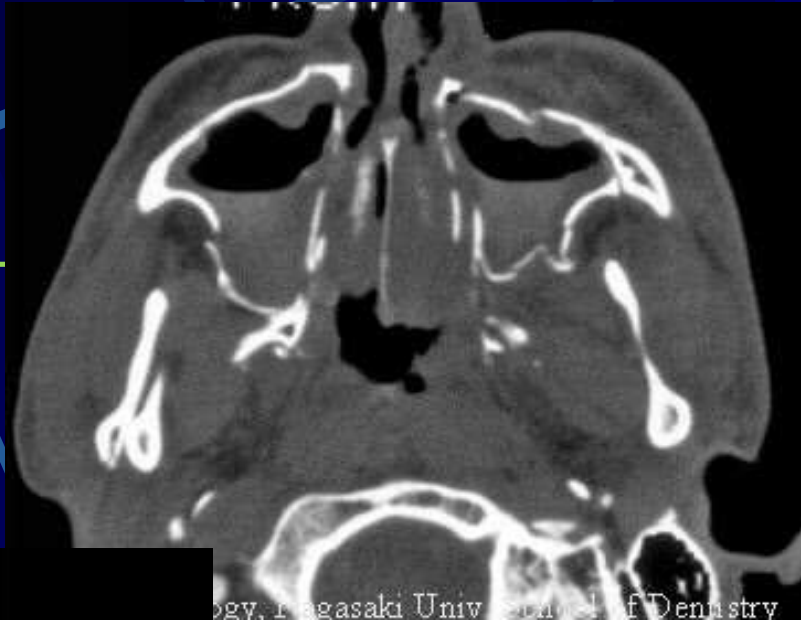


34



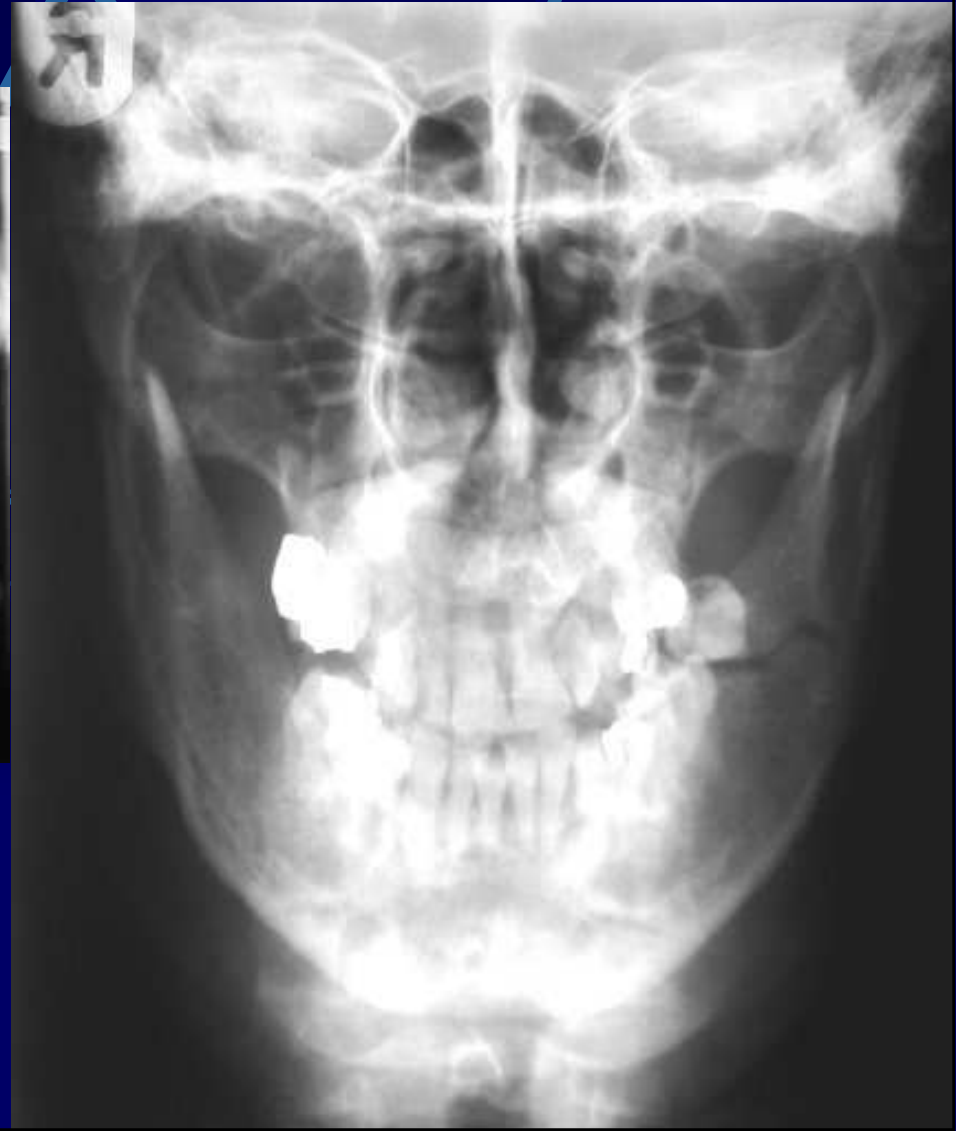
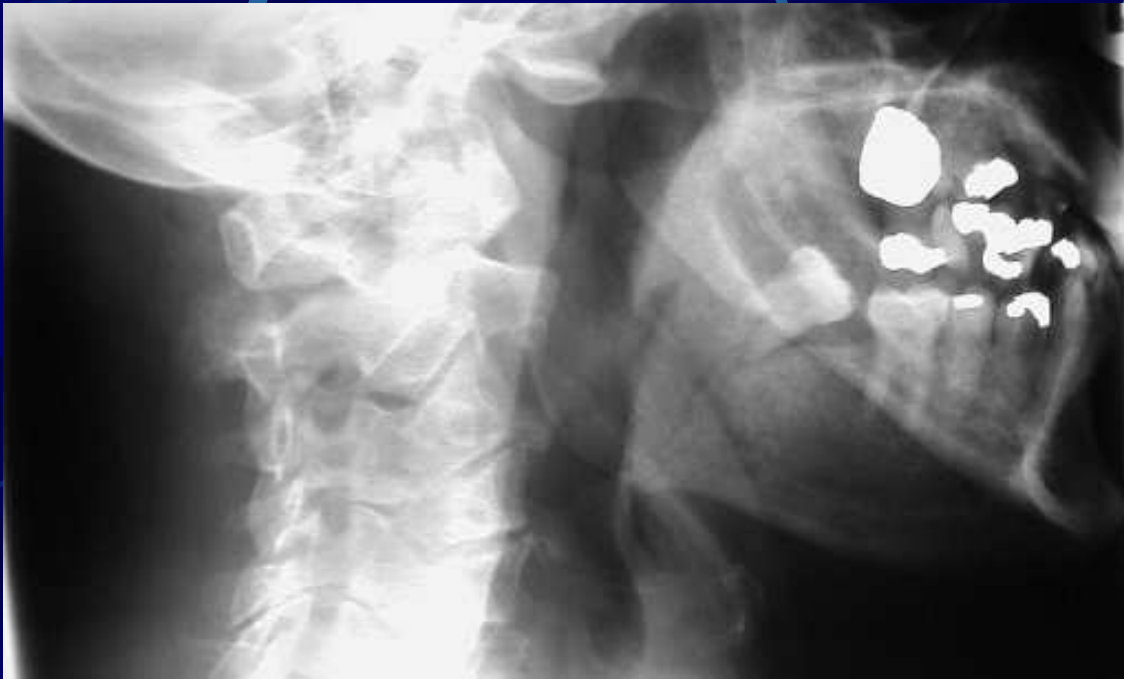

Frantura



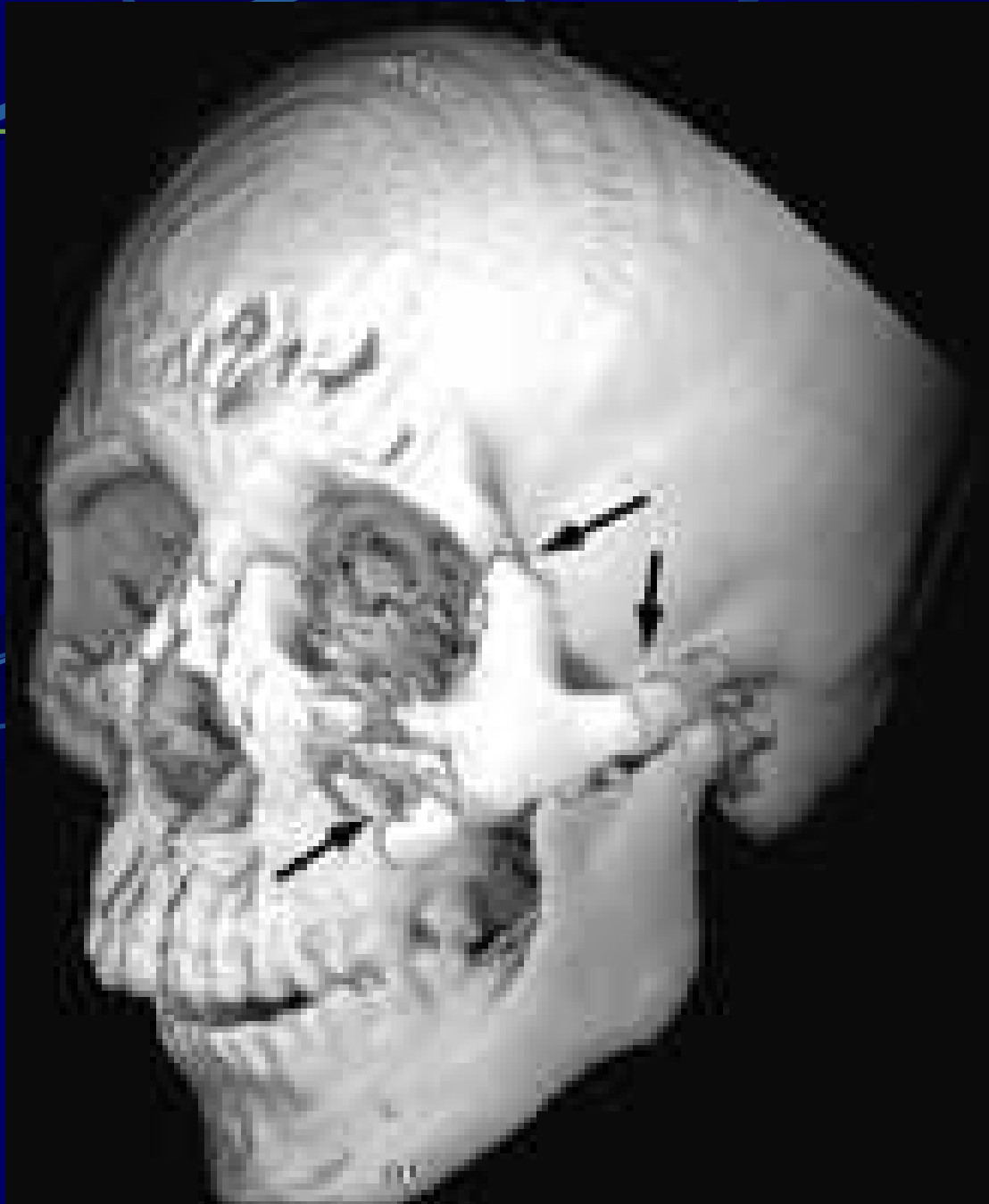


Frantura





Frantura





Zuby – náhrada

