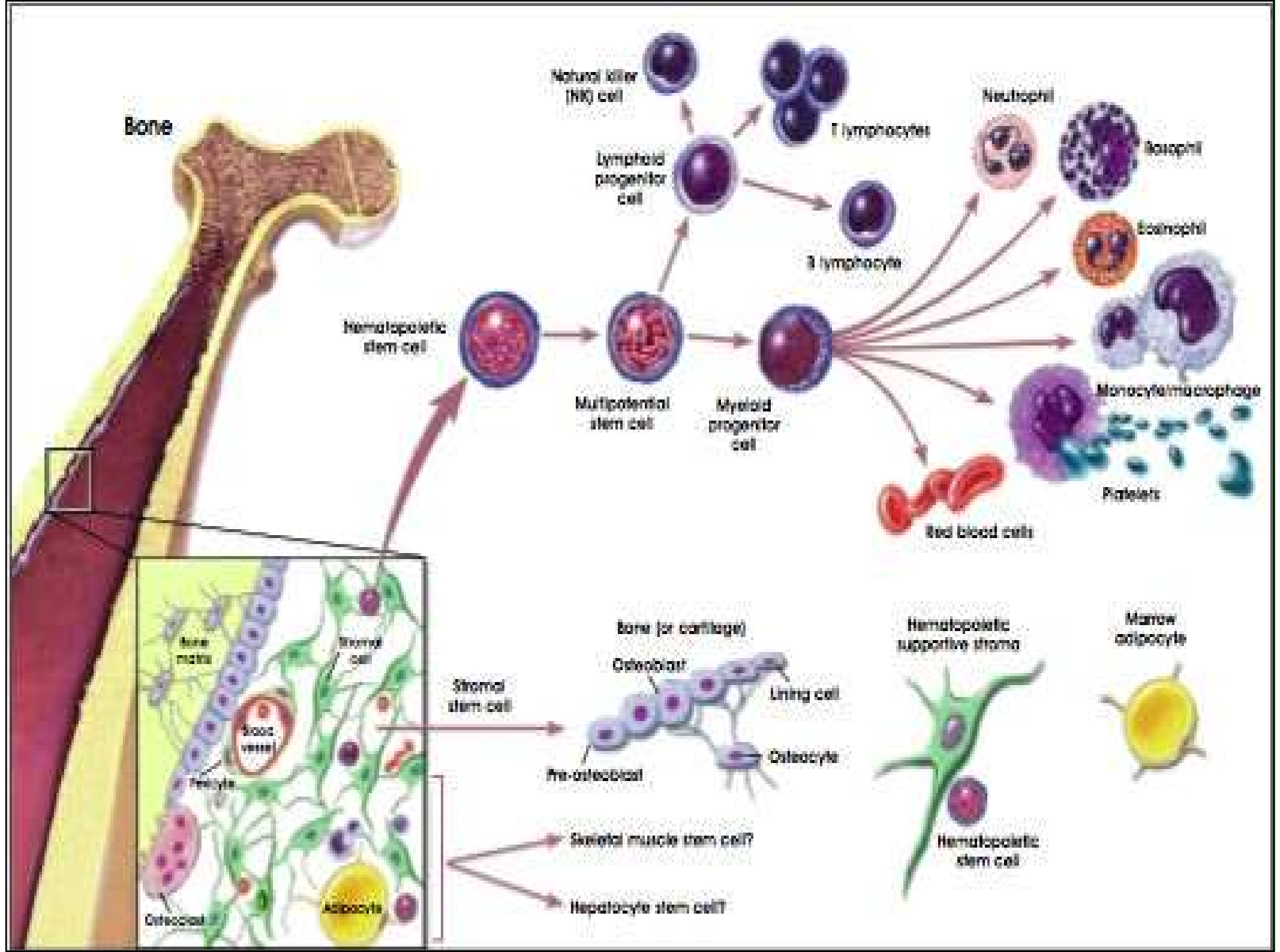
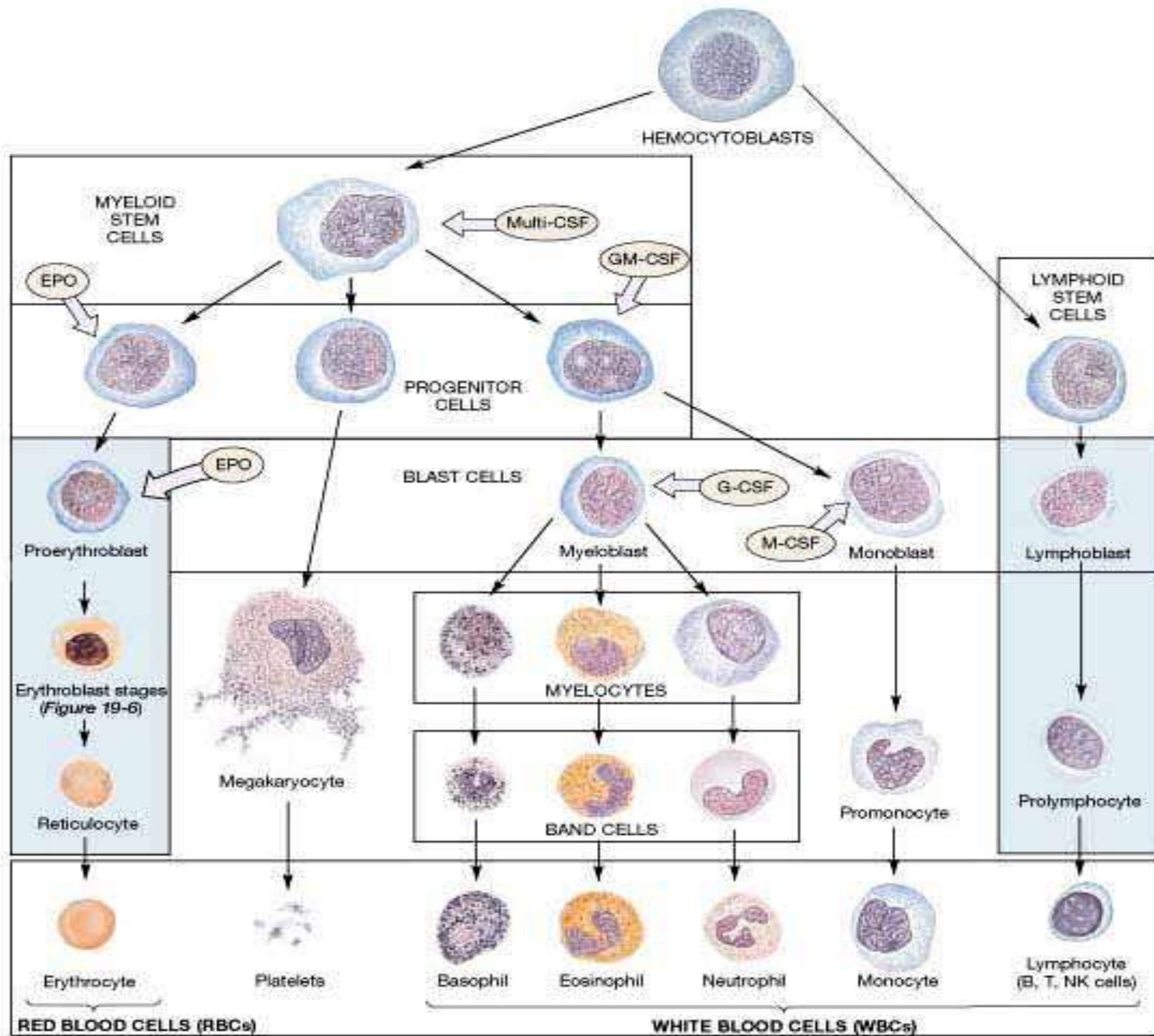


Hematopoéza

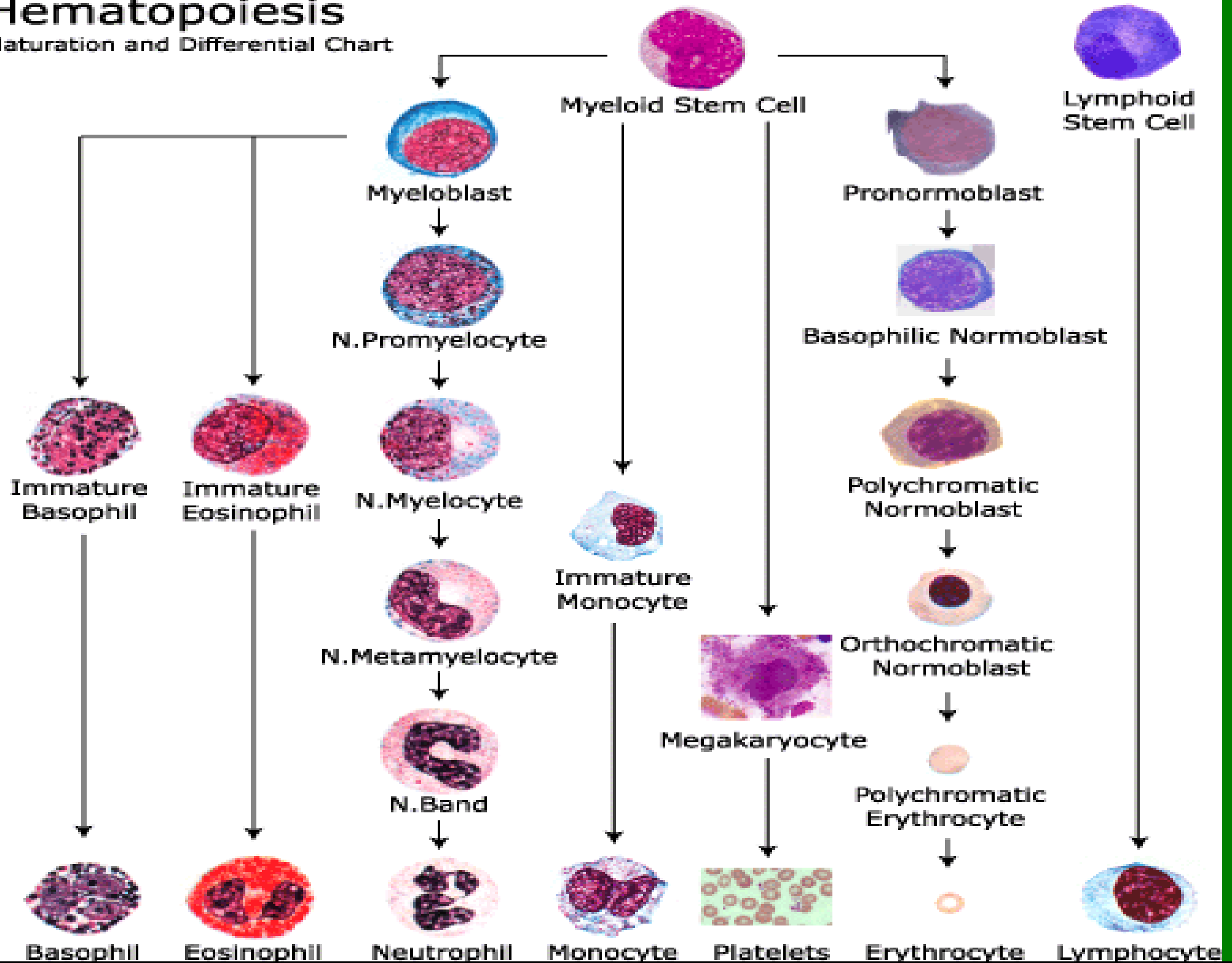
Bourková L., OKH FN Brno

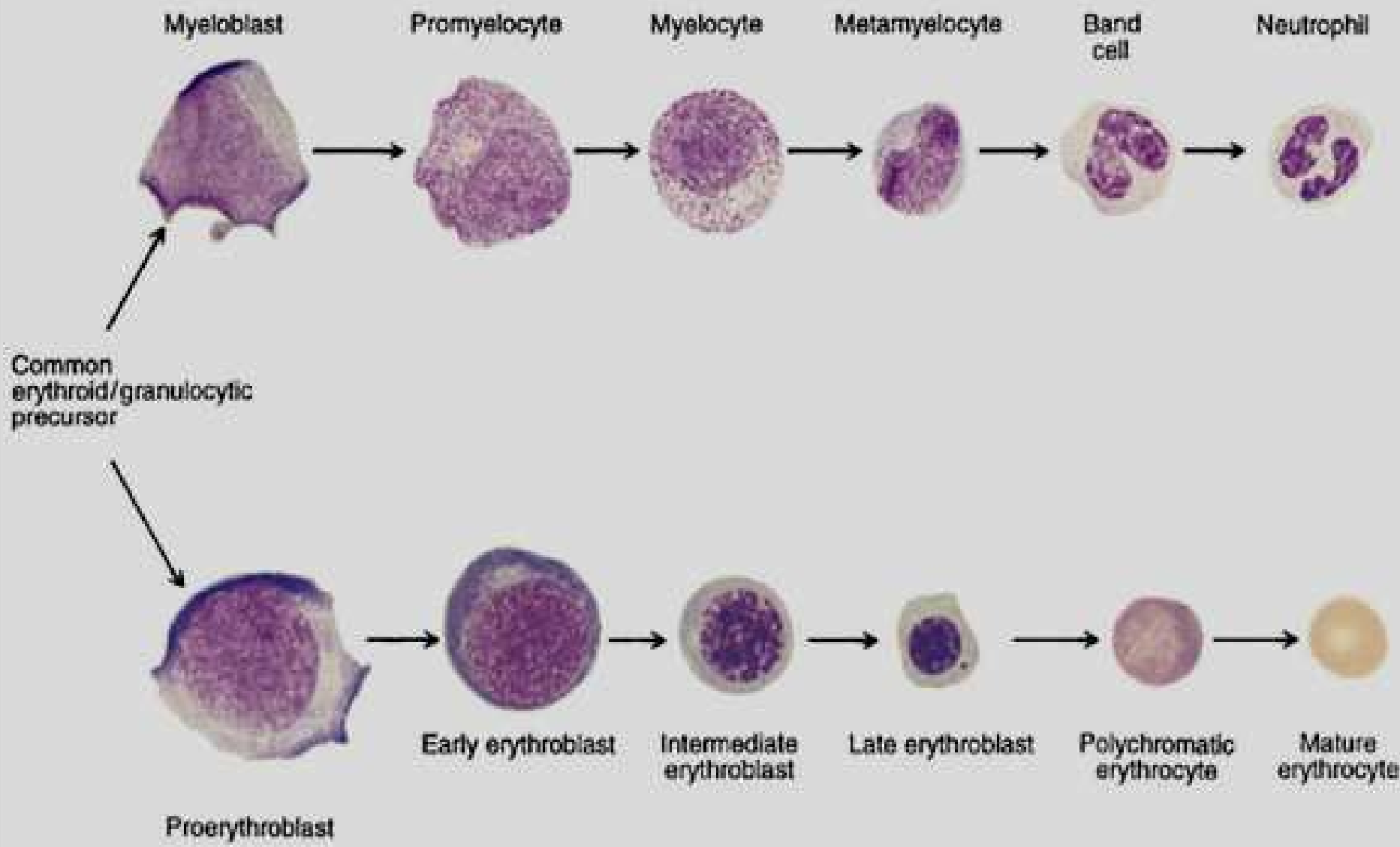




Hematopoiesis

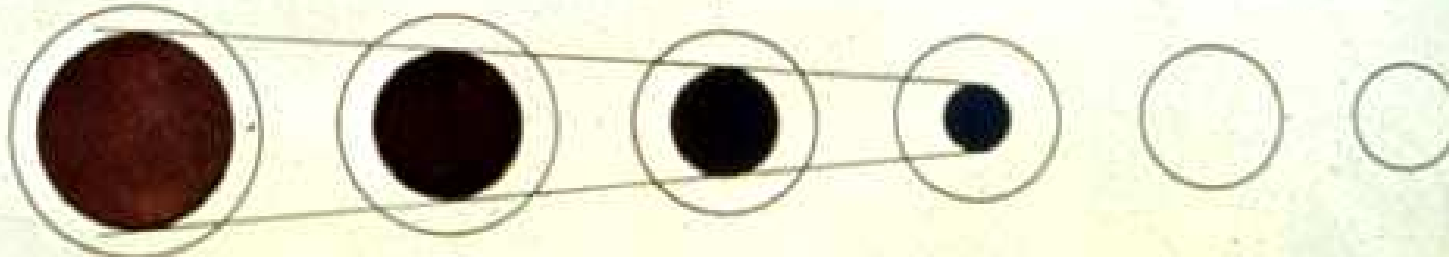
Maturation and Differential Chart







A. Cell size and cytoplasm color



B. Nuclear size and color



C. Nuclear chromatin structure



D. Composite (Left to right: Rubriblast, Proerythrocyte, Erythrocyte, Metarubricyte, Diffusely basophilic erythrocyte, Erythrocyte)

KOSTNÍ DŘEŇ

myeloblast

promyelocyt

proerythroblast

bazofilní normoblast

monoblastt

magakaryoblast

lymfoblast

neutrofilní myelocyt

eozinofilní myelocyt

bazofilní myelocyt

polychromní normoblast

promonocyt

promegakaryocyt

prolymfocyt

neutrofilní metamy

eozinofilní metamy

bazofilní metamy

oxyfilní normoblast

mono
makrofág

megakaryocyt

lymfo
plazmat. b.

KREV

neutrofilní tyč

eozinofilní tyč

bazofilní tyčí

retikulocyt

monocyt

trombocyty

lymfocyt

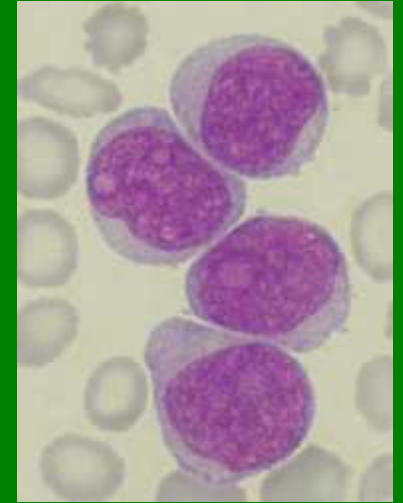
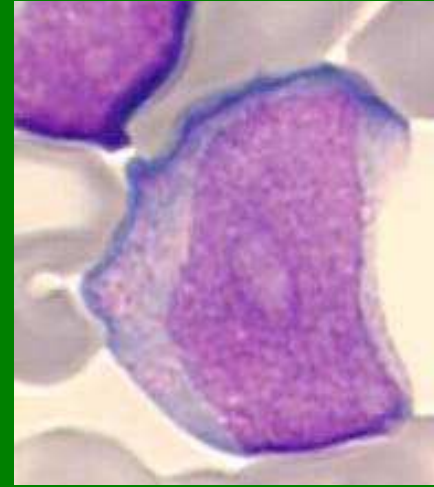
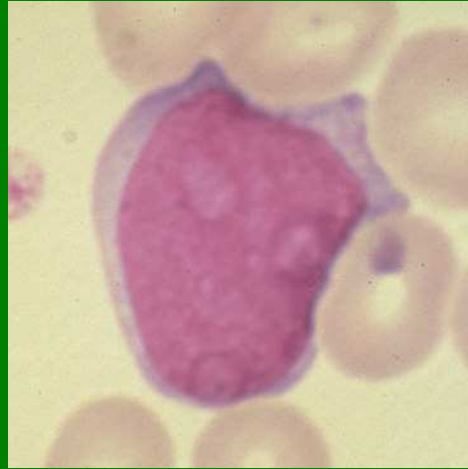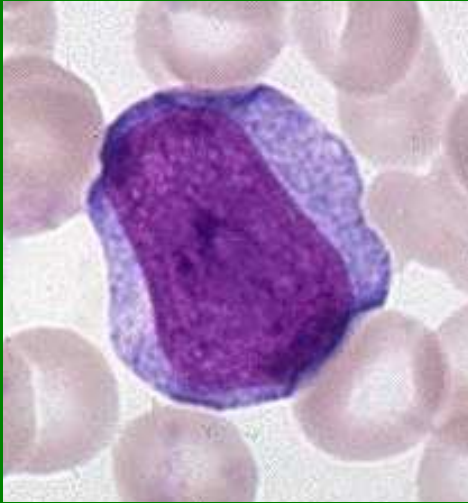
neutrofilní segment

eozinofilní segment

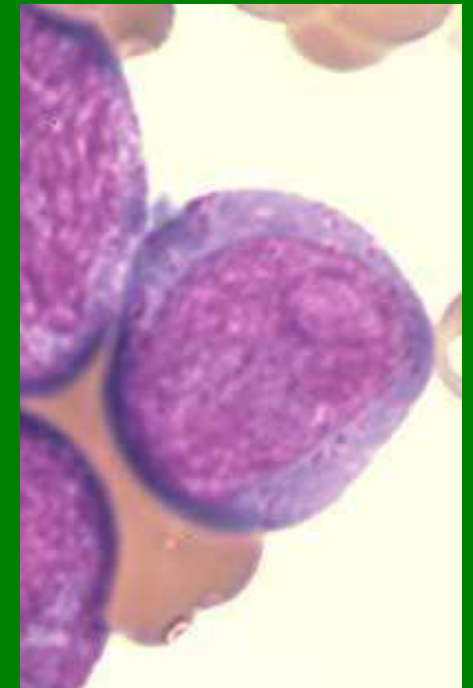
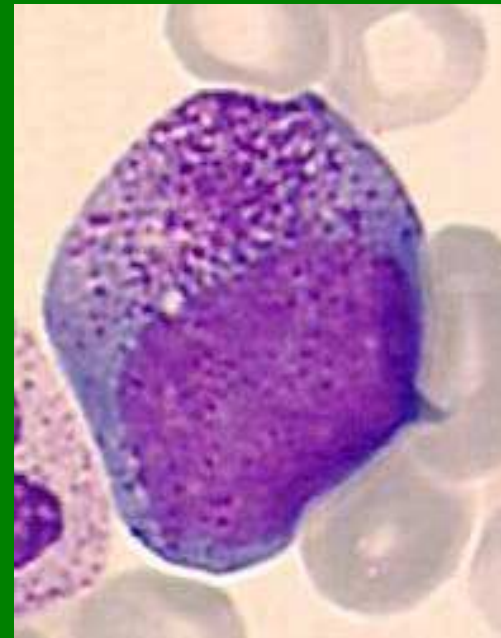
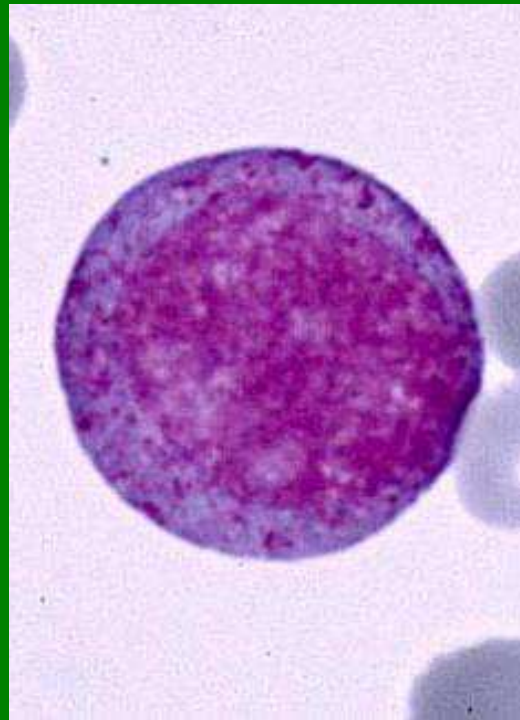
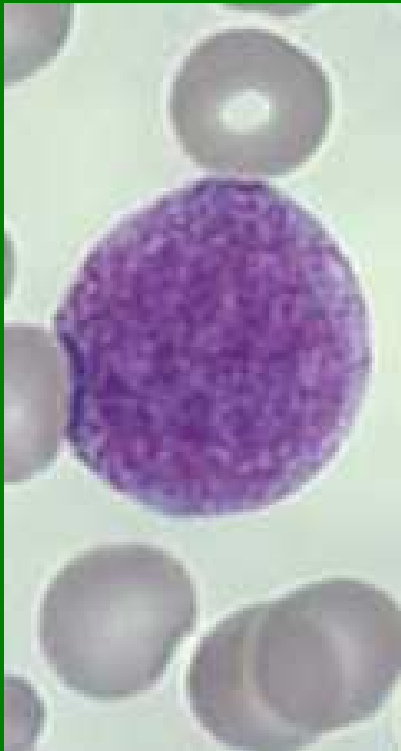bazofilní segment

erytrocyt

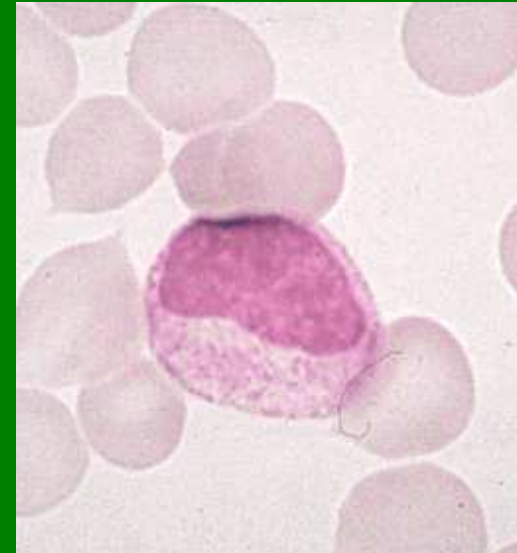
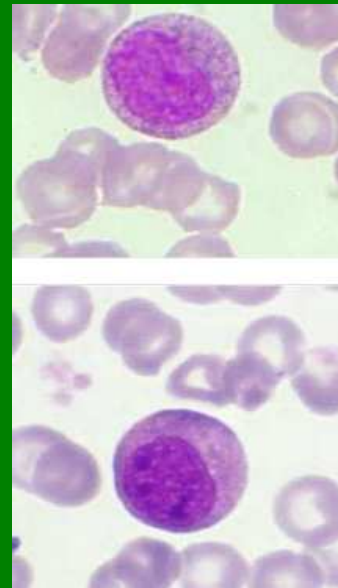
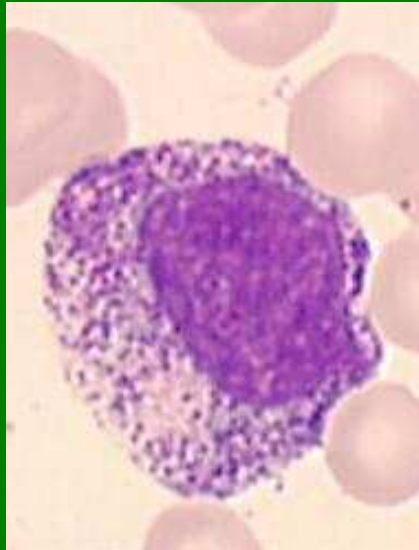
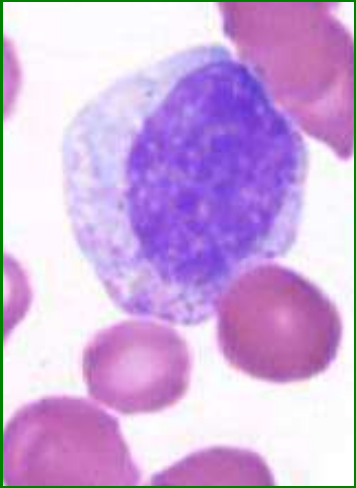
Myeloblasty



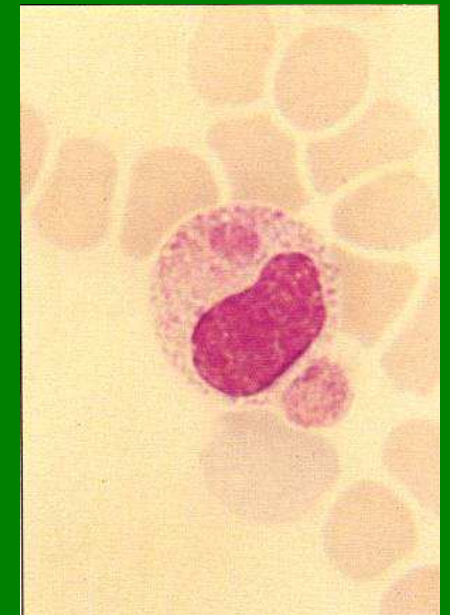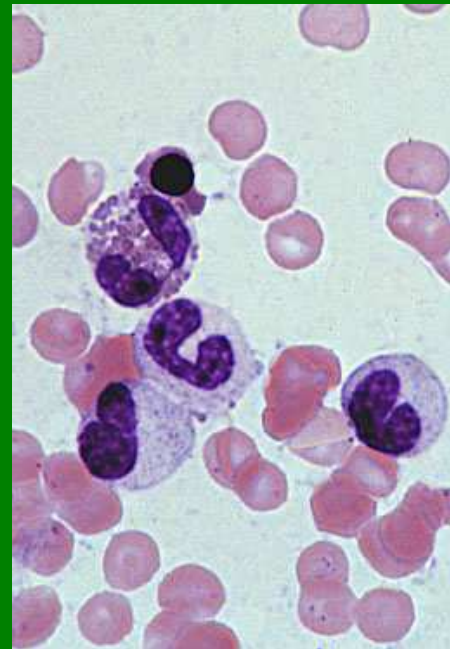
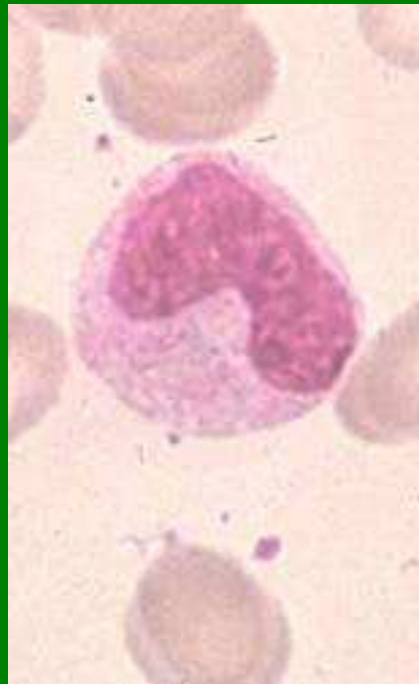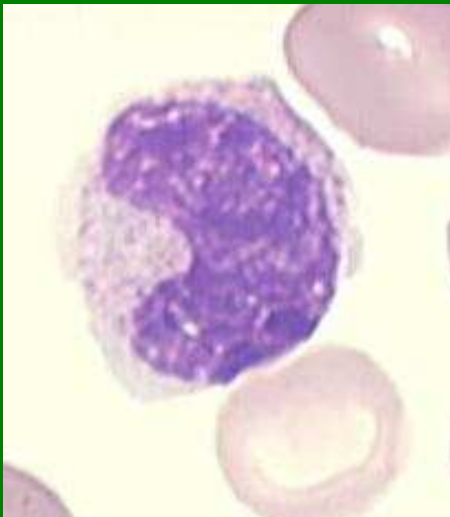Promyelocyty



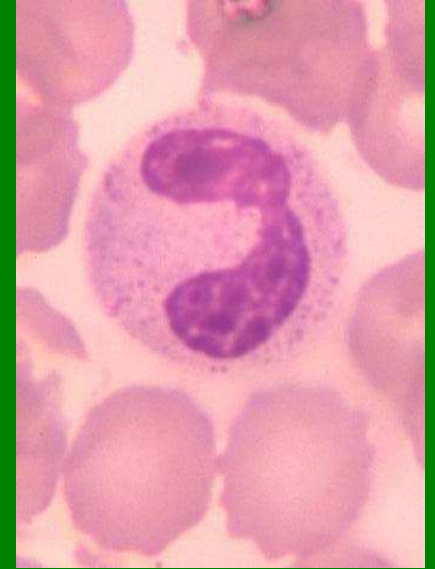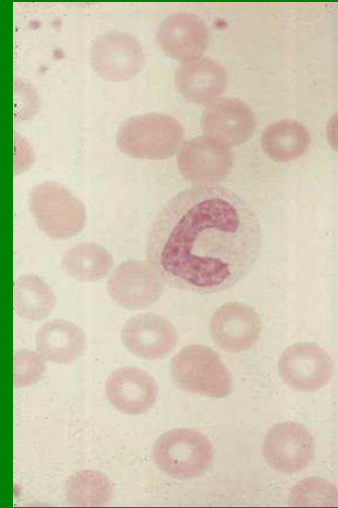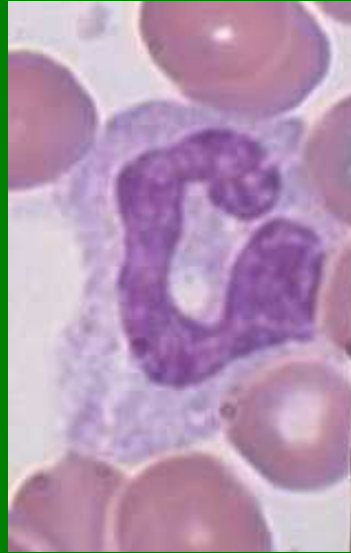
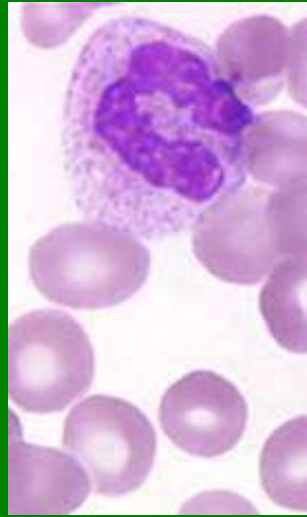
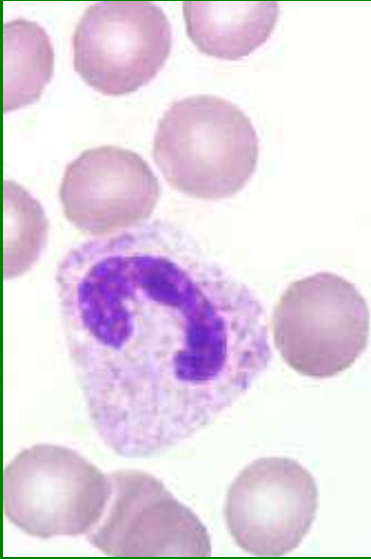Myelocyty - Ne



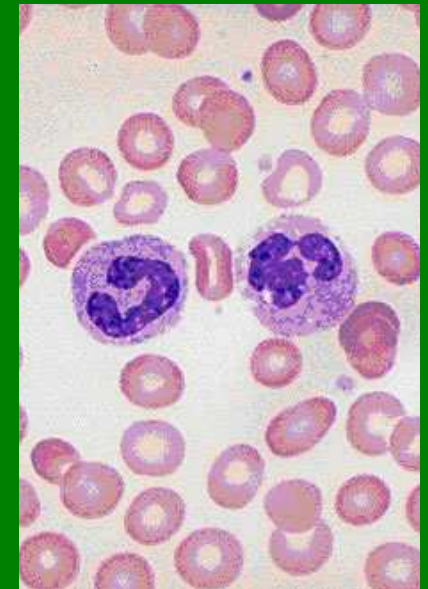
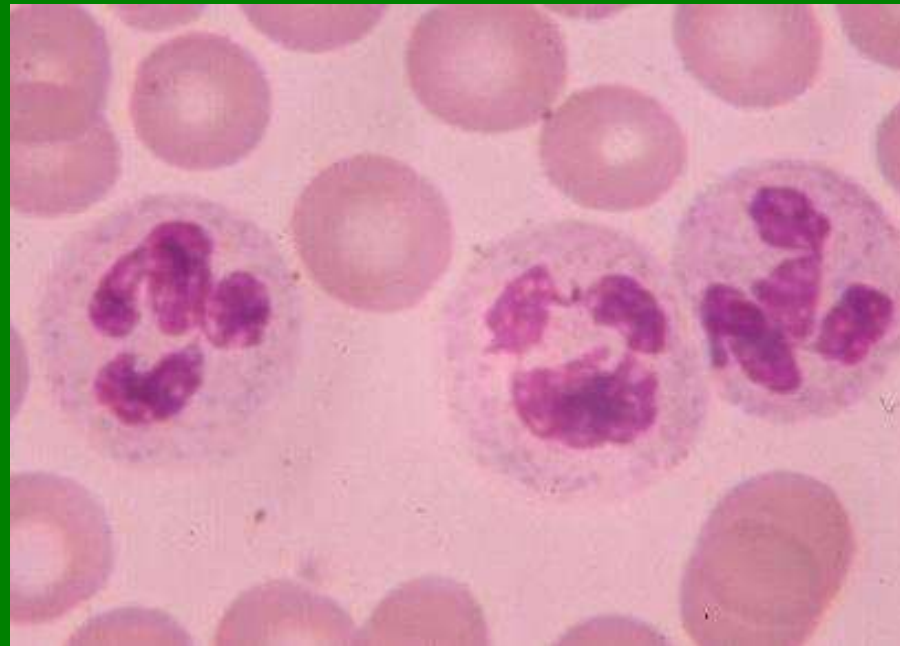
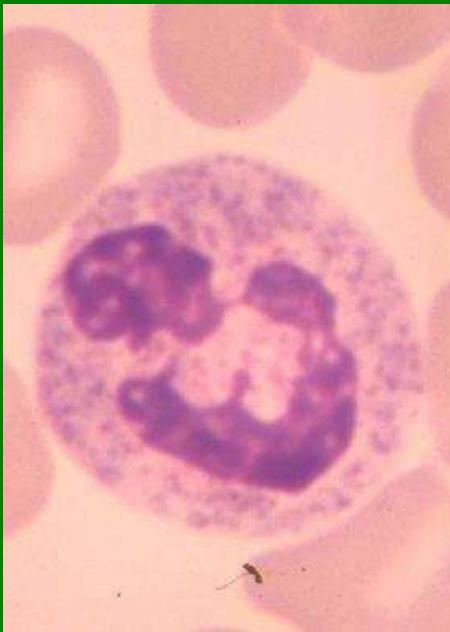
Metamyelocyty - Ne



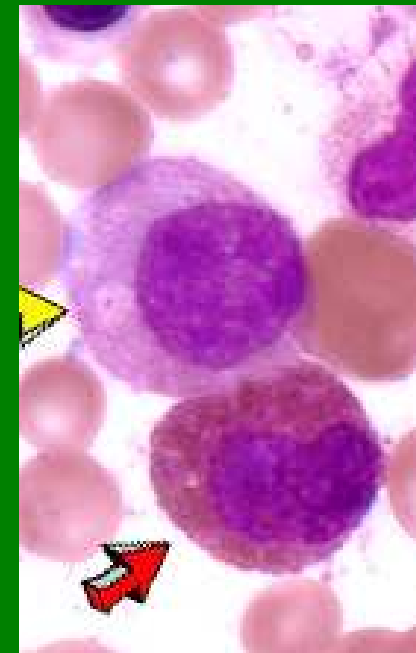
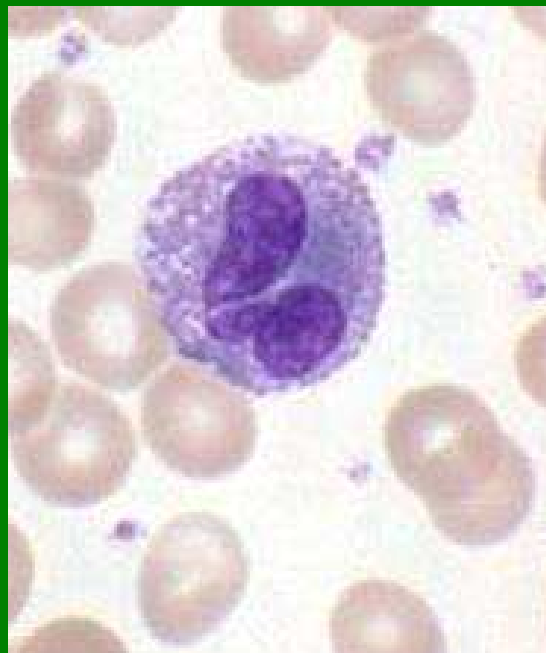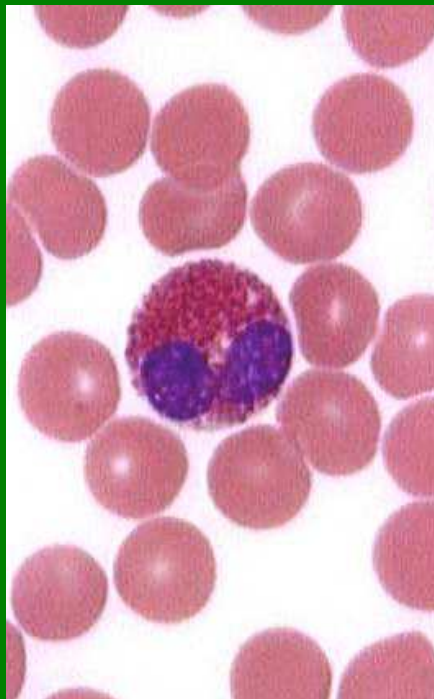
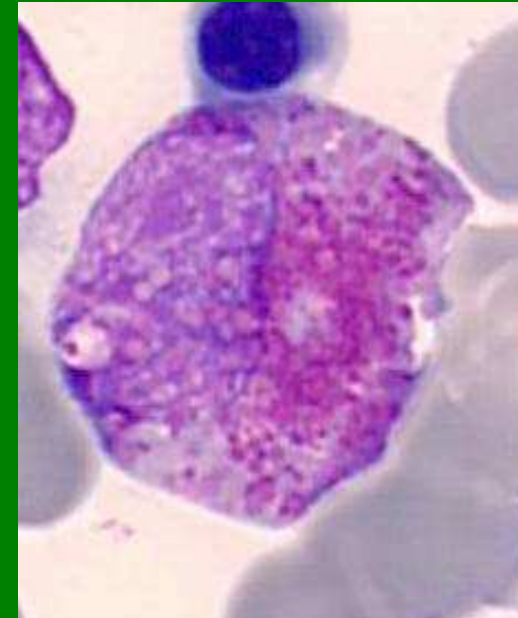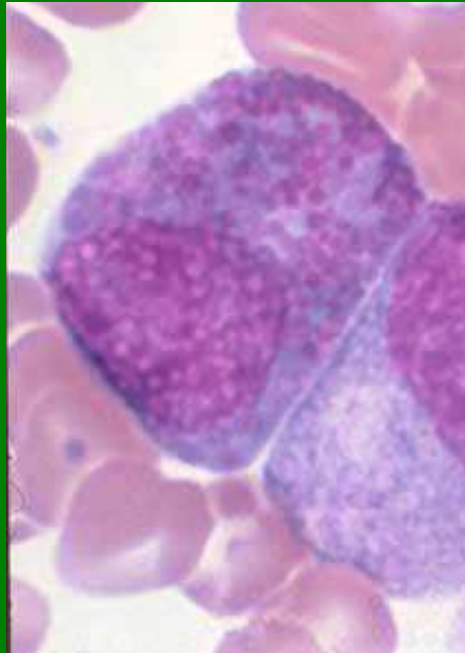
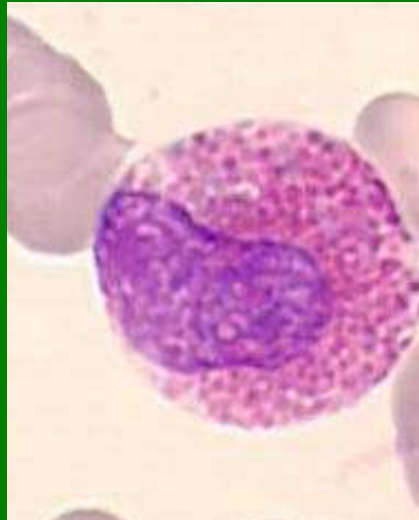
Tyč - Ne



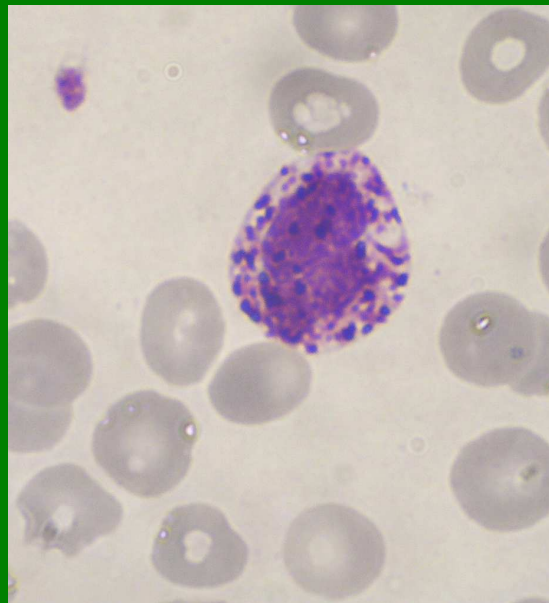
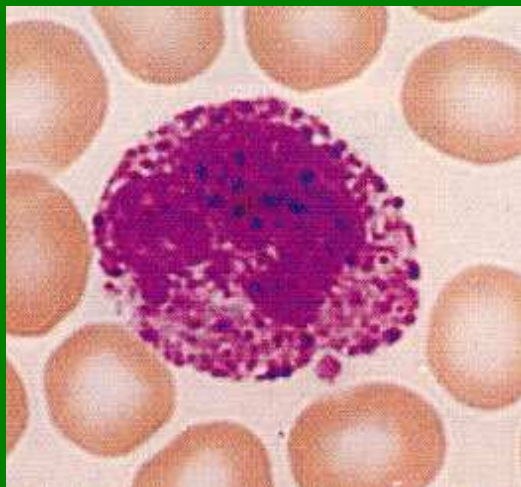
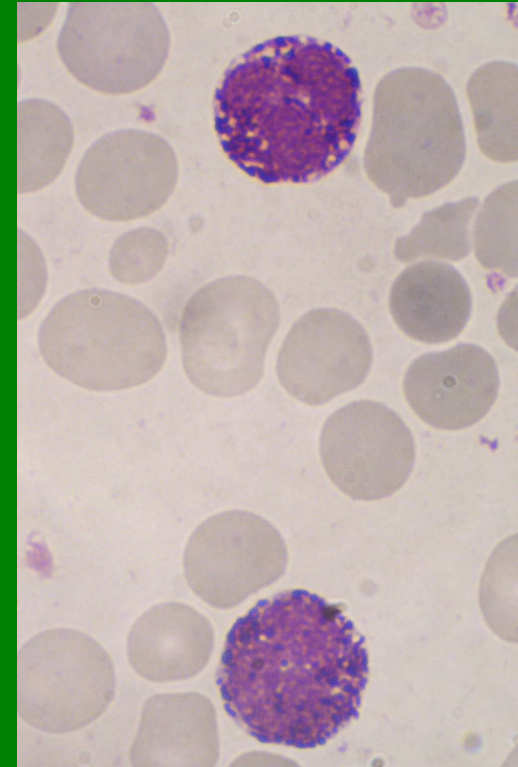
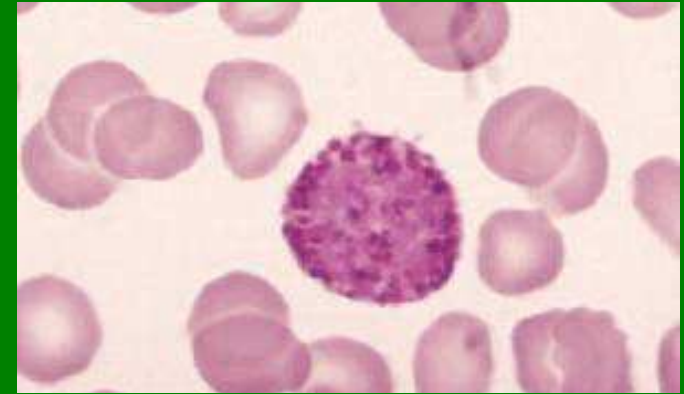
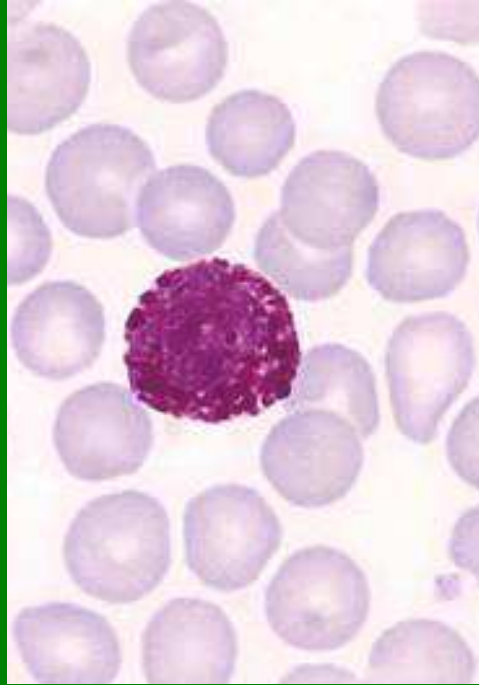
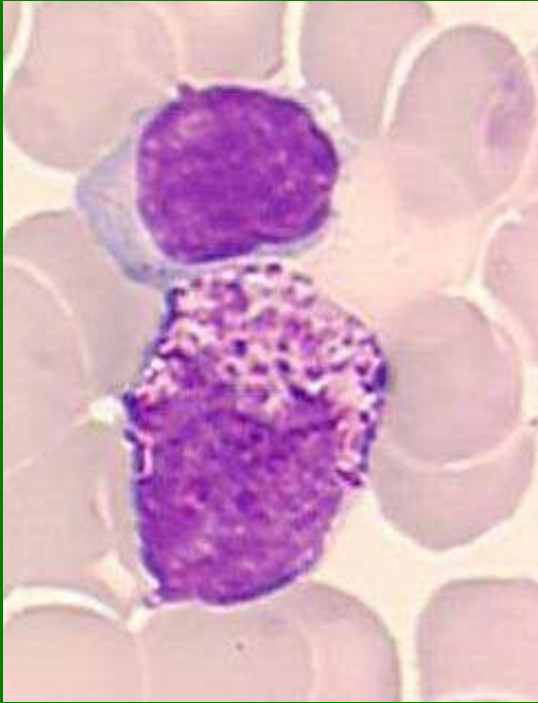
Segment - Ne



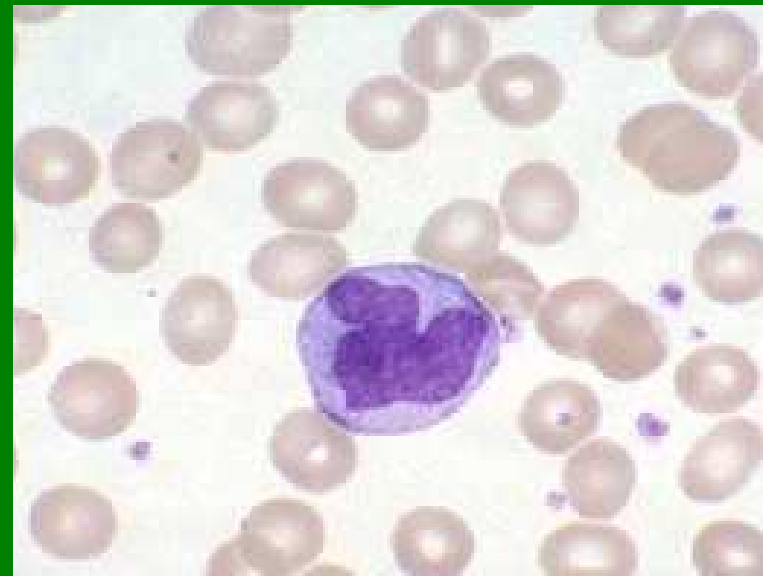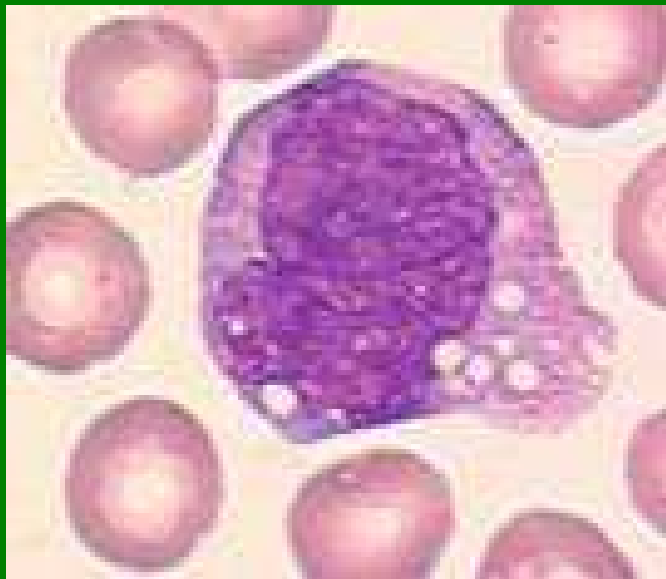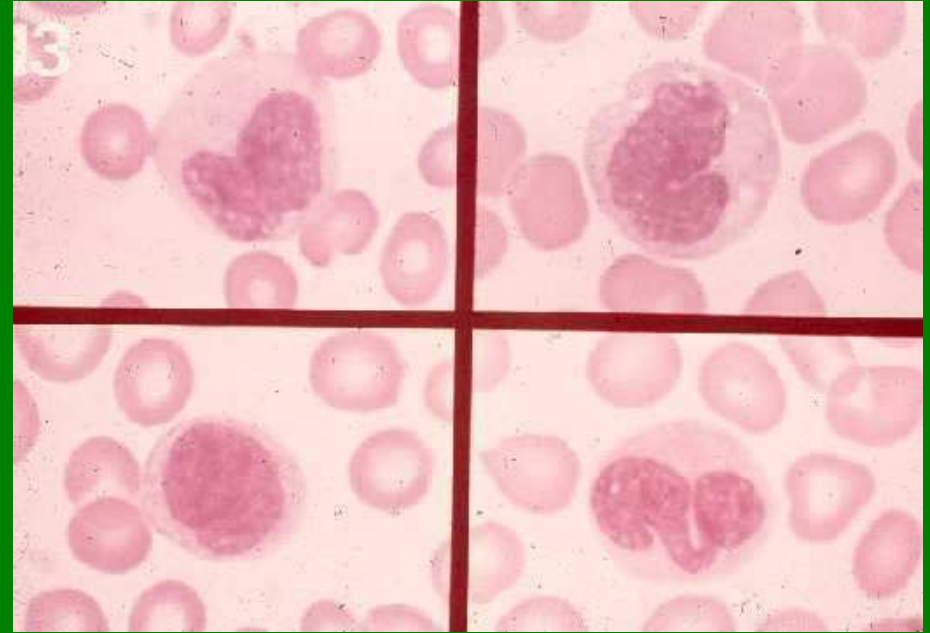
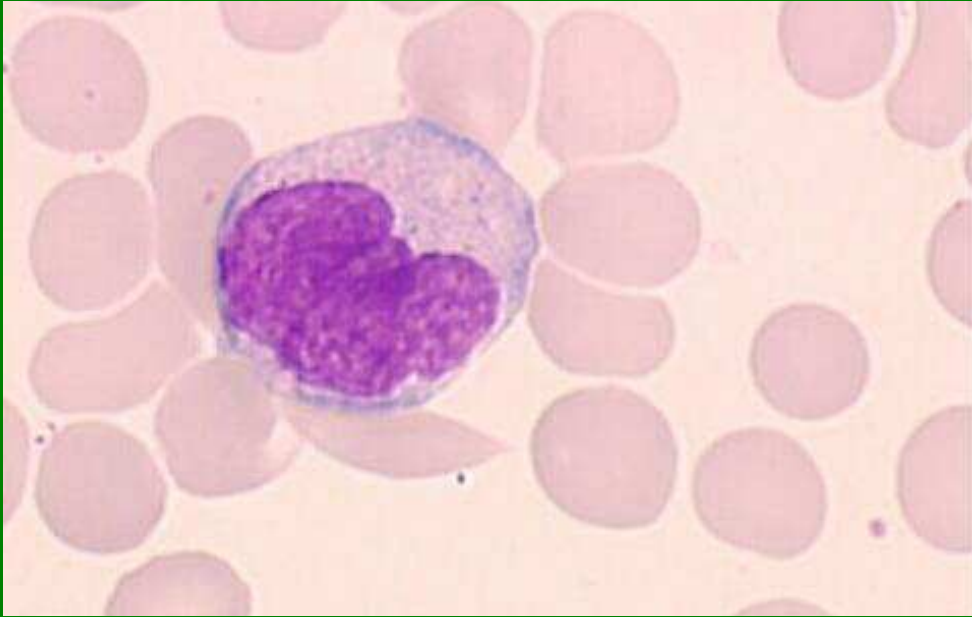
Eozinofily



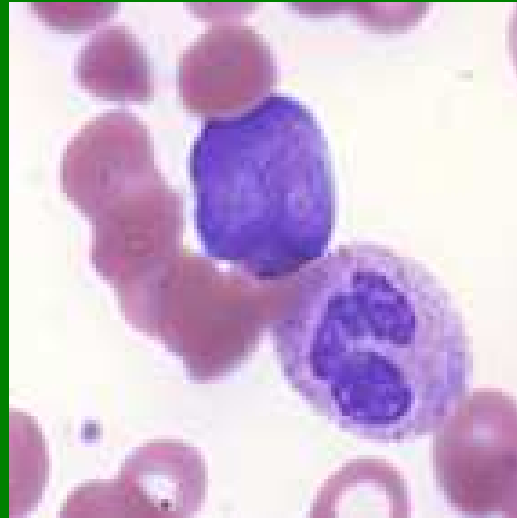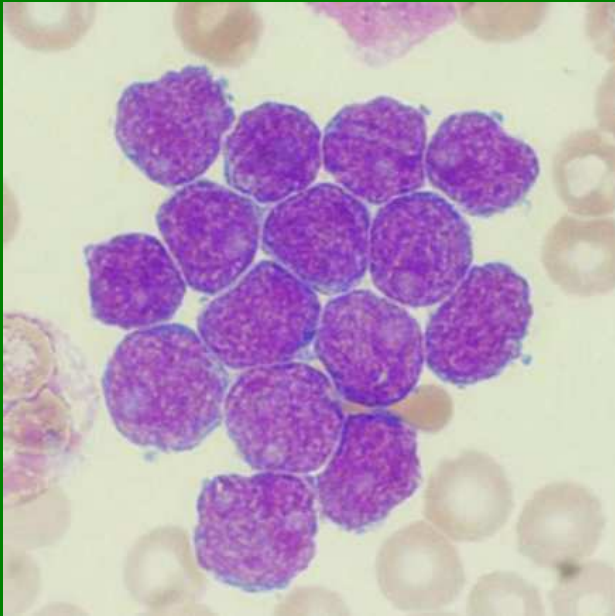
Bazofily



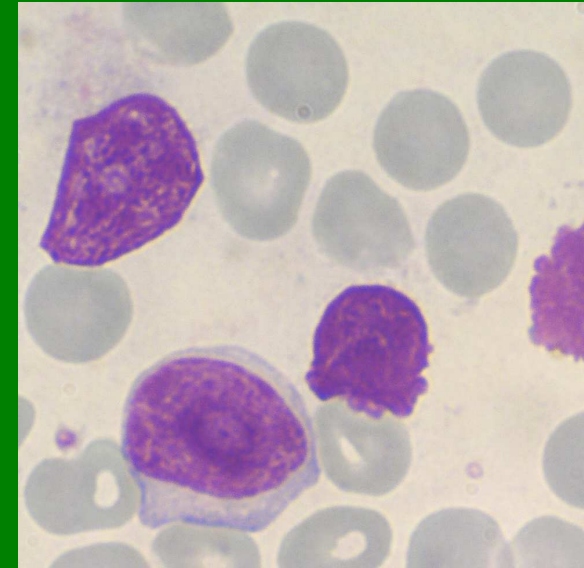
Monocyty



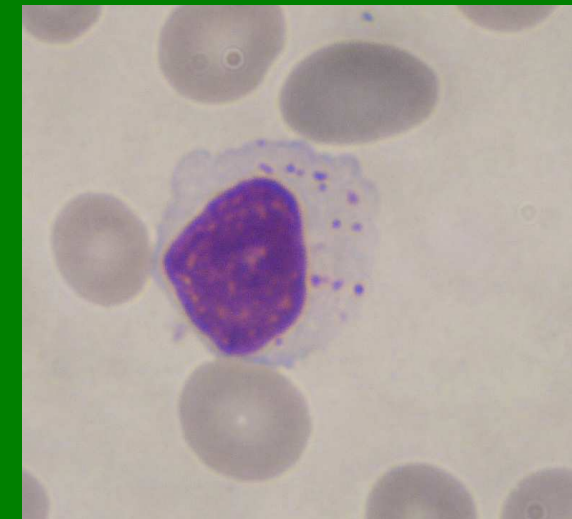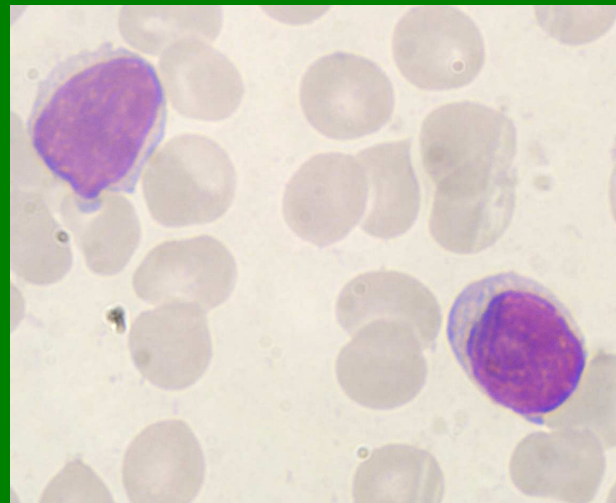
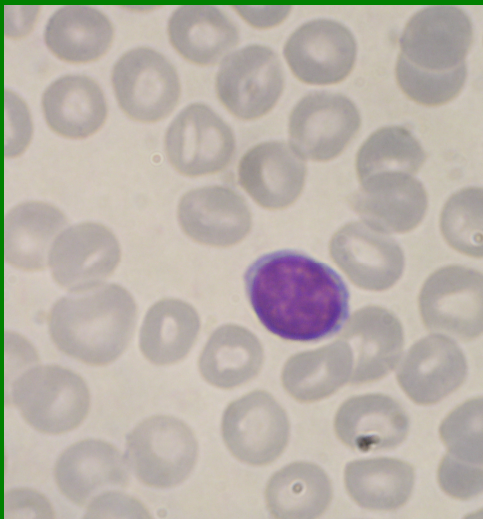
Lymfoblasty



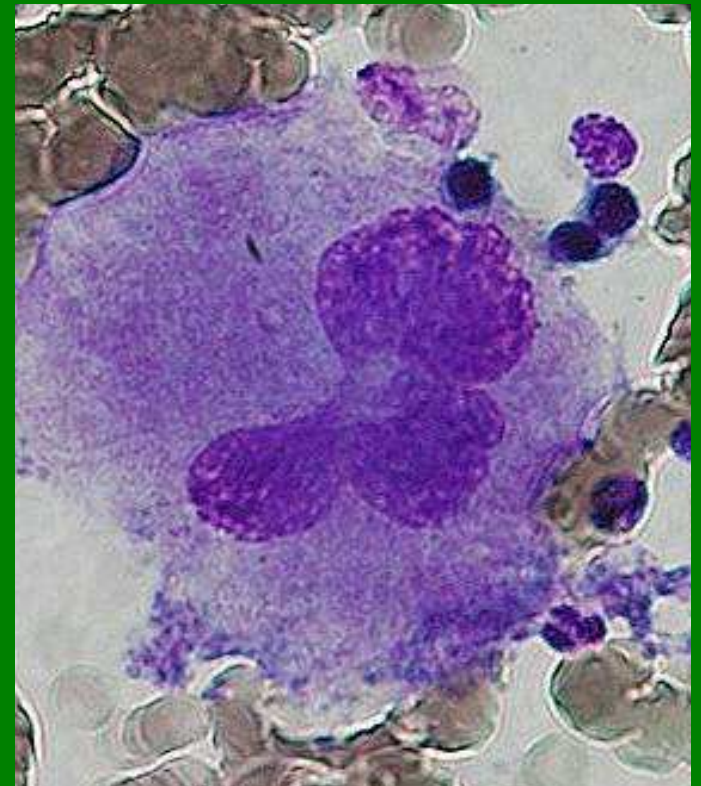
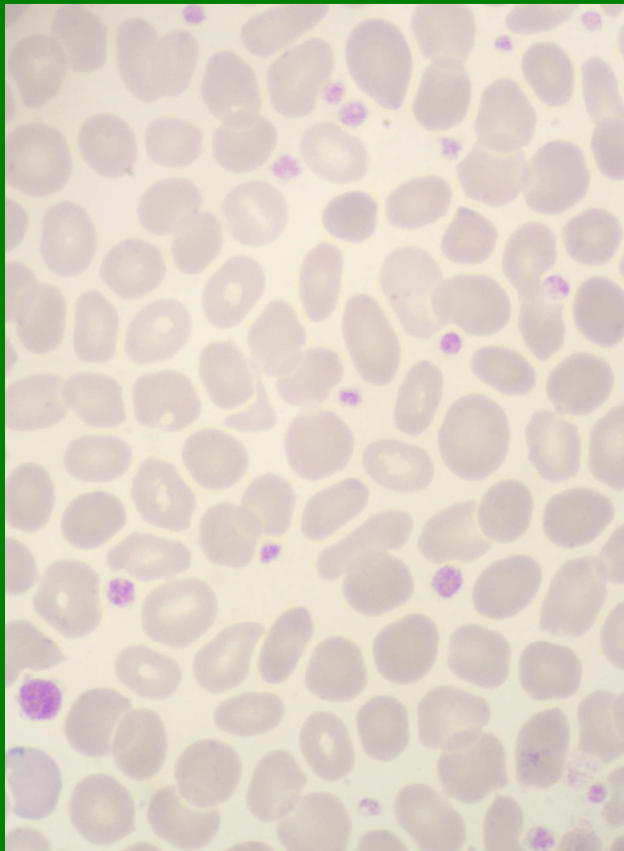
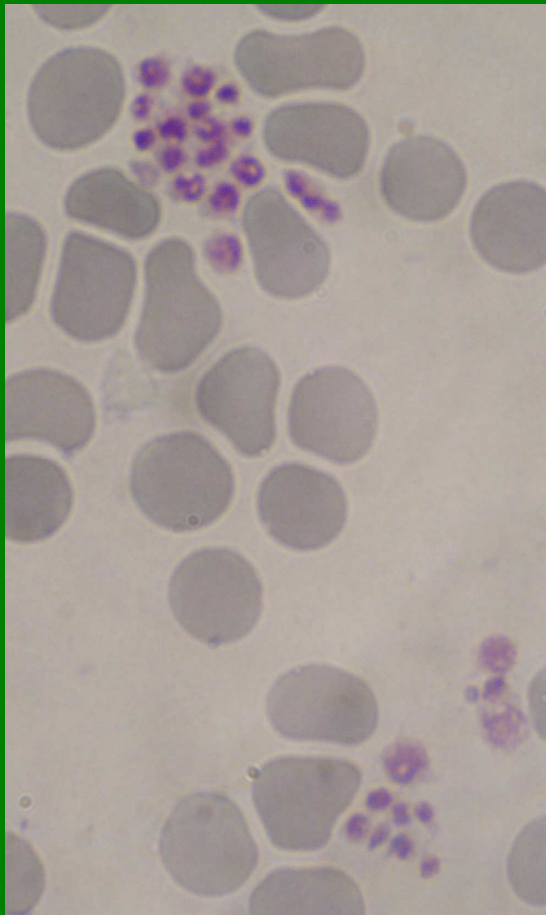
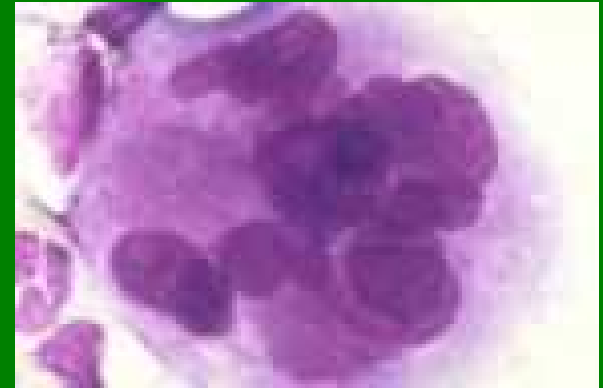
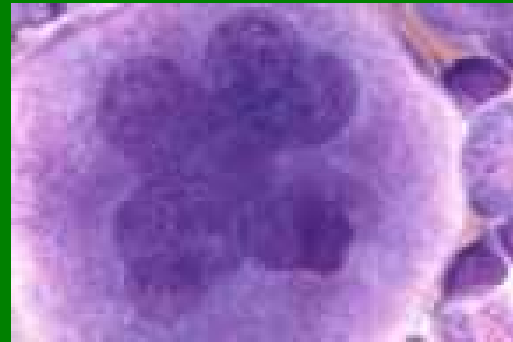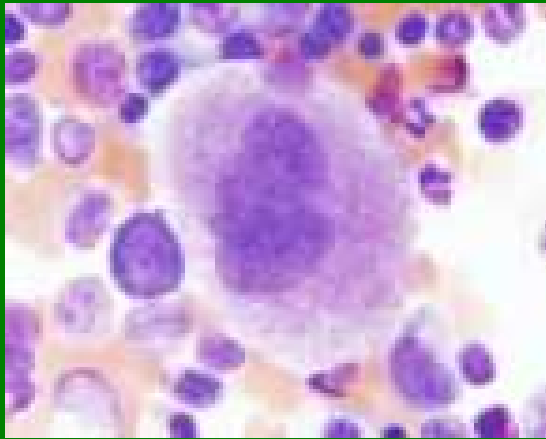
Prolymfocyt



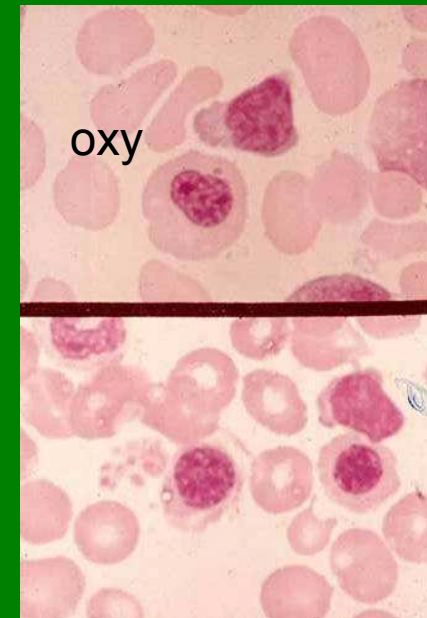
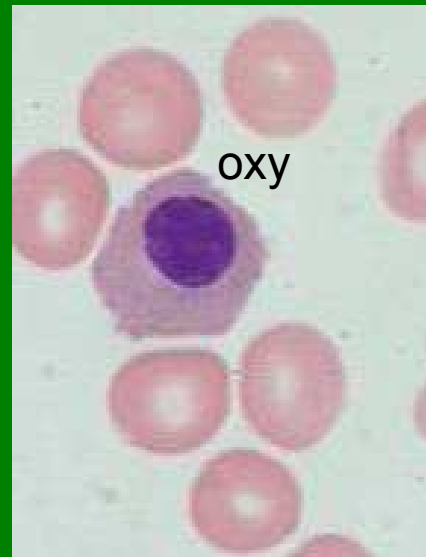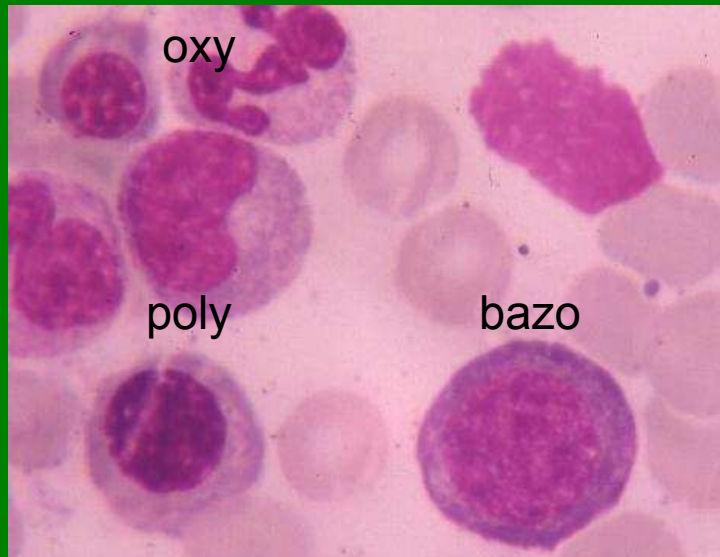
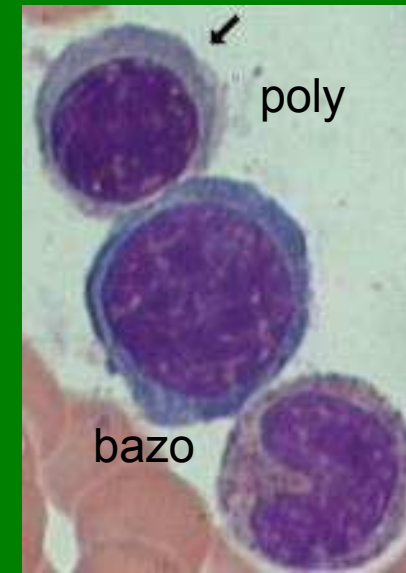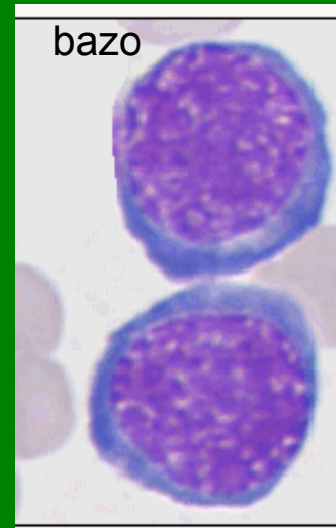
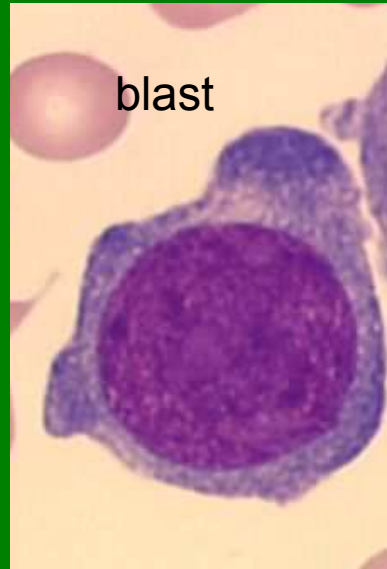
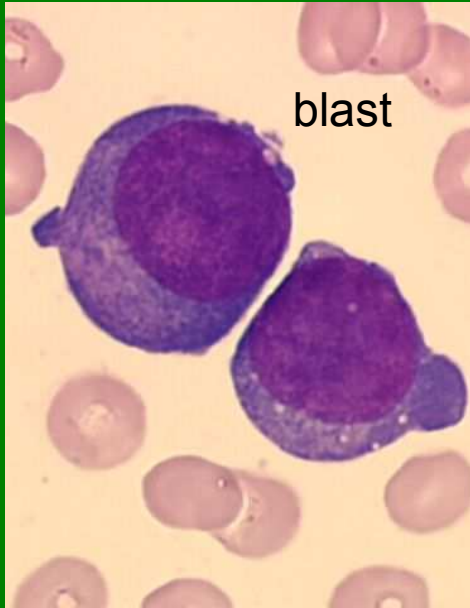Lymfocyty



Megakaryocyty, PLT

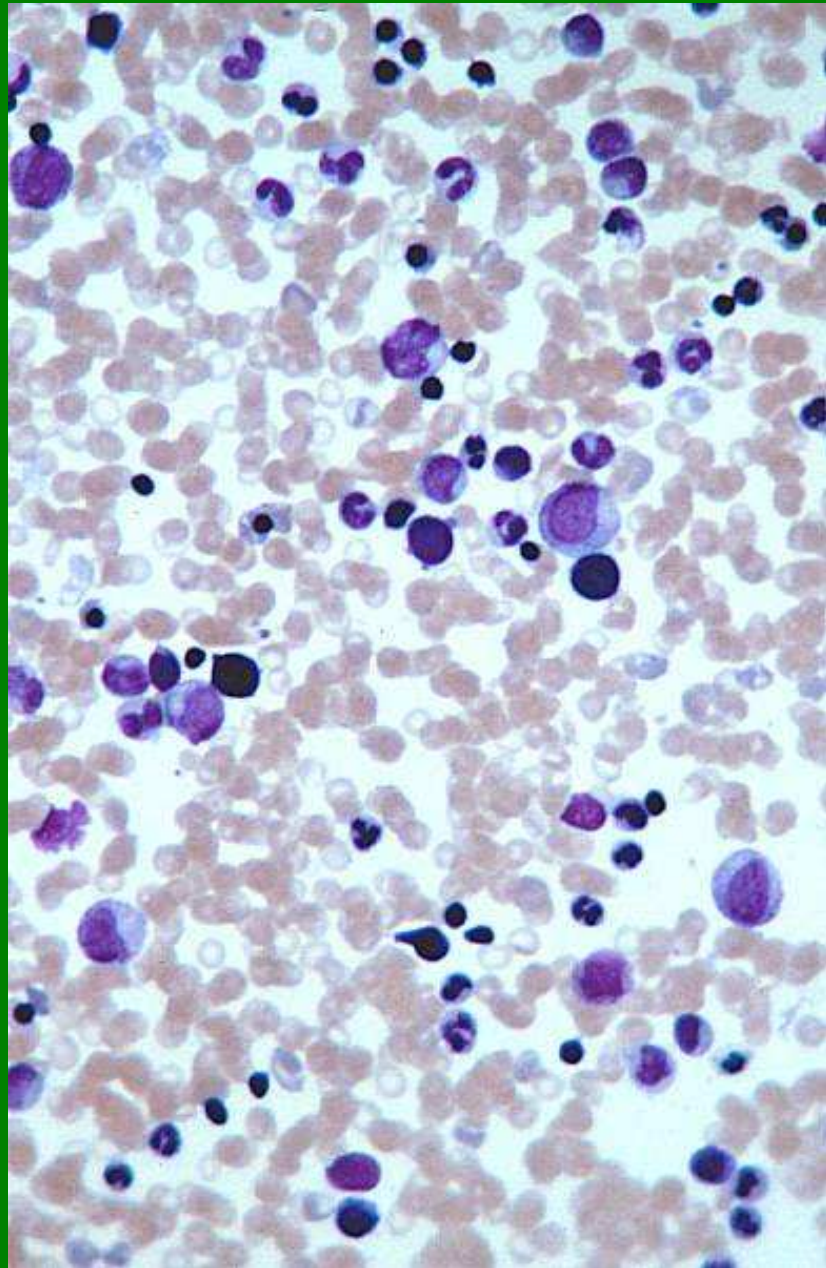


NRBC



Kostní dřeň - buněčnost

normální



vyšoká

