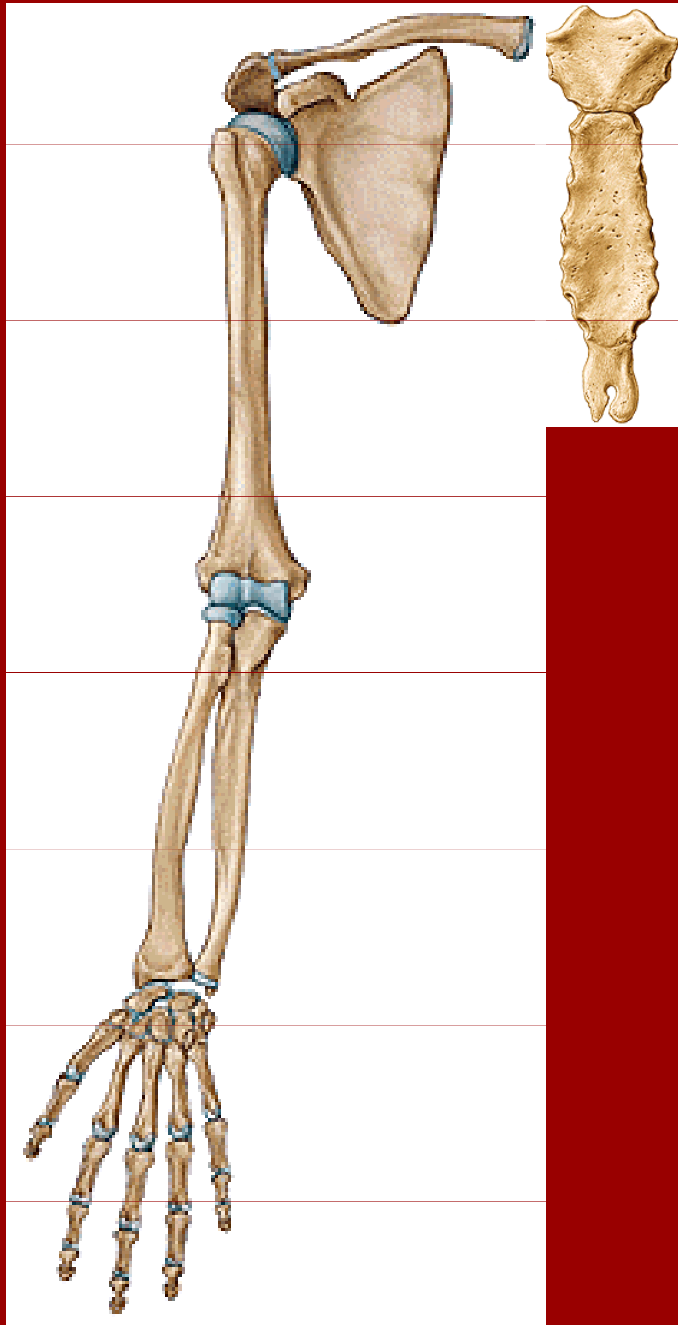


Spoje horní končetiny

Spoje horní končetiny - přehled

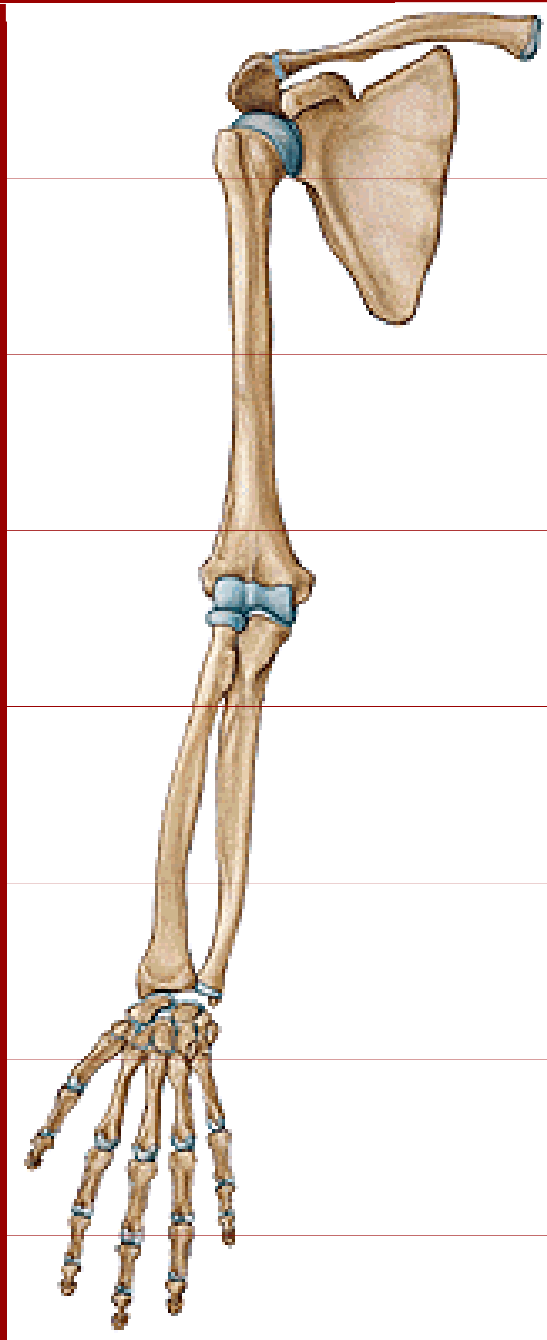


I. Spoje kostí pletence

art. sternoclavicularis

art. acromioclavicularis

Spoje horní končetiny - přehled



II. Spoje kostí volné končetiny

art. humeri

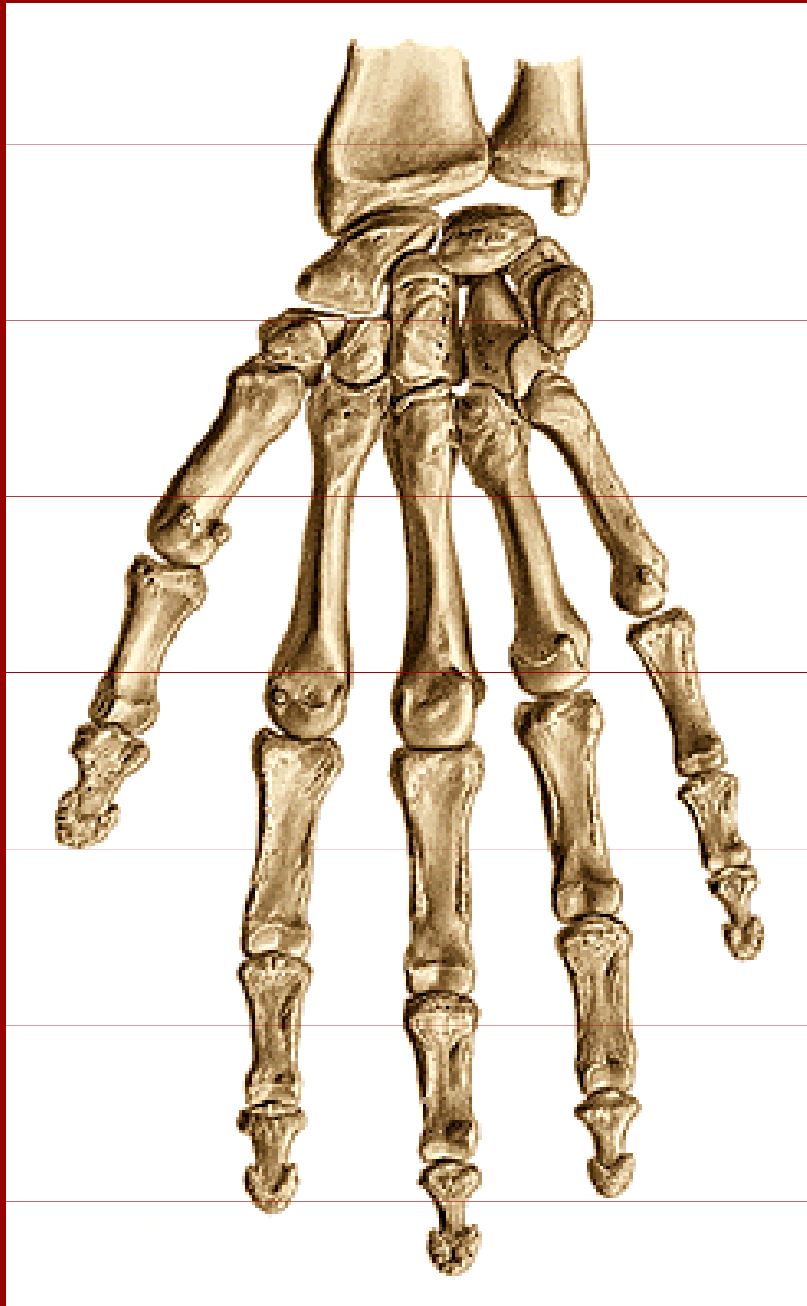
art. cubiti

membrana interossea

antebrachii

art. radioulnaris distalis

Spoje horní končetiny - přehled



II. Spoje kostí volné končetiny klouby ruky

art. radiocarpea

art. mediocarpea

artt. carpometacarpeae

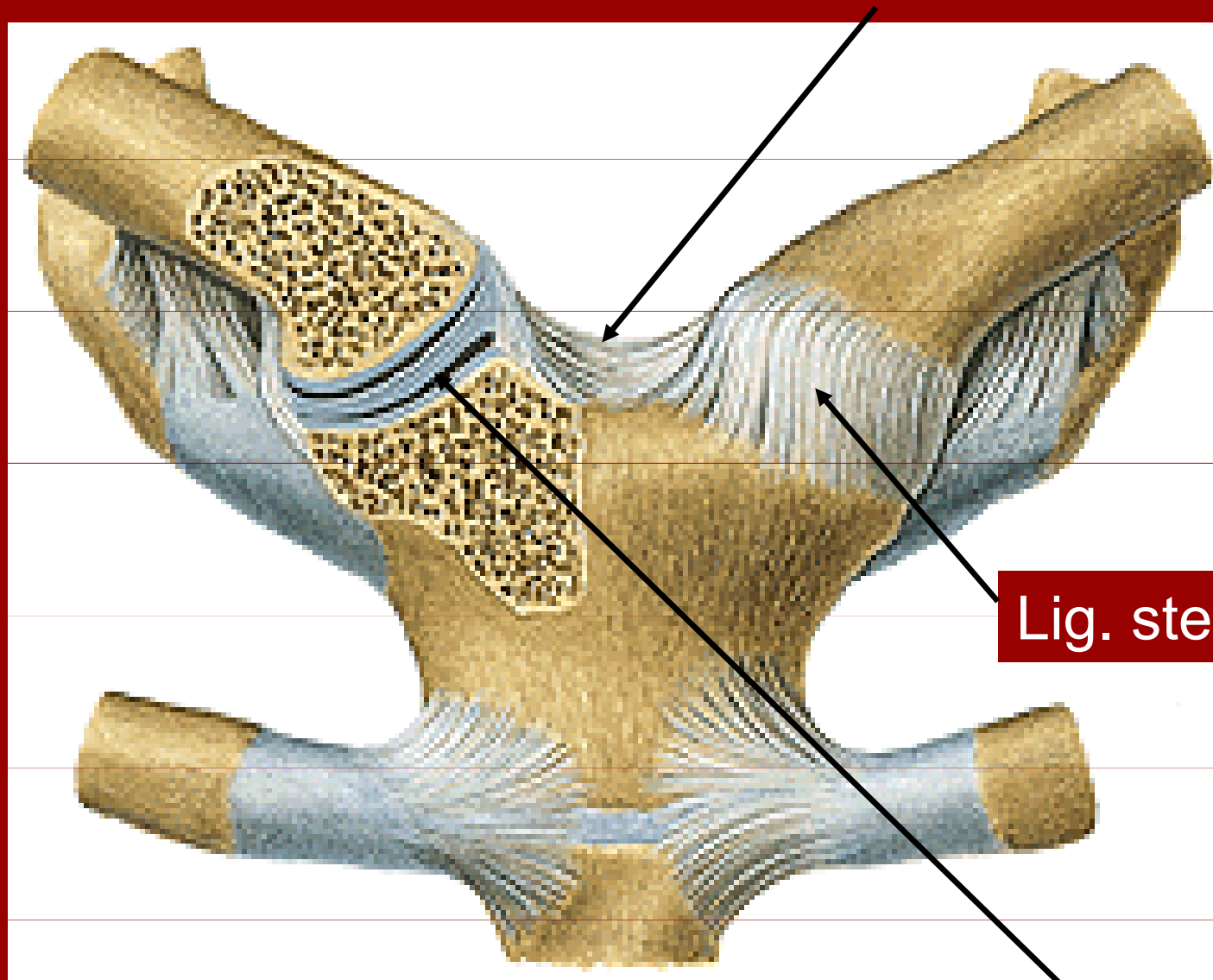
artt. metacarpophalangeae

artt. interphalangeae manus

Spoje kostí pletence

Art. sternoclavicularis

Lig. interclavicularia

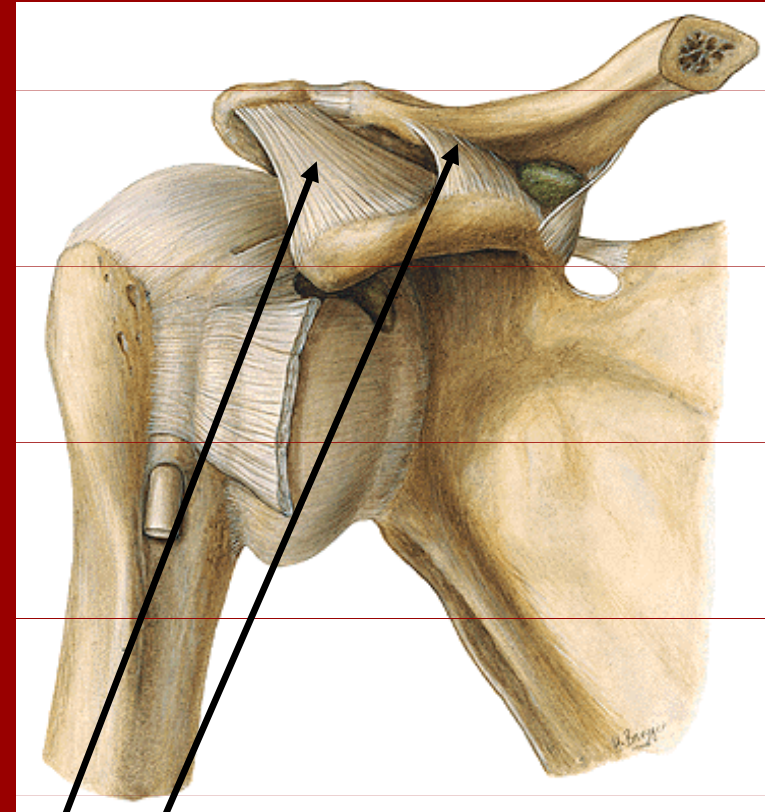
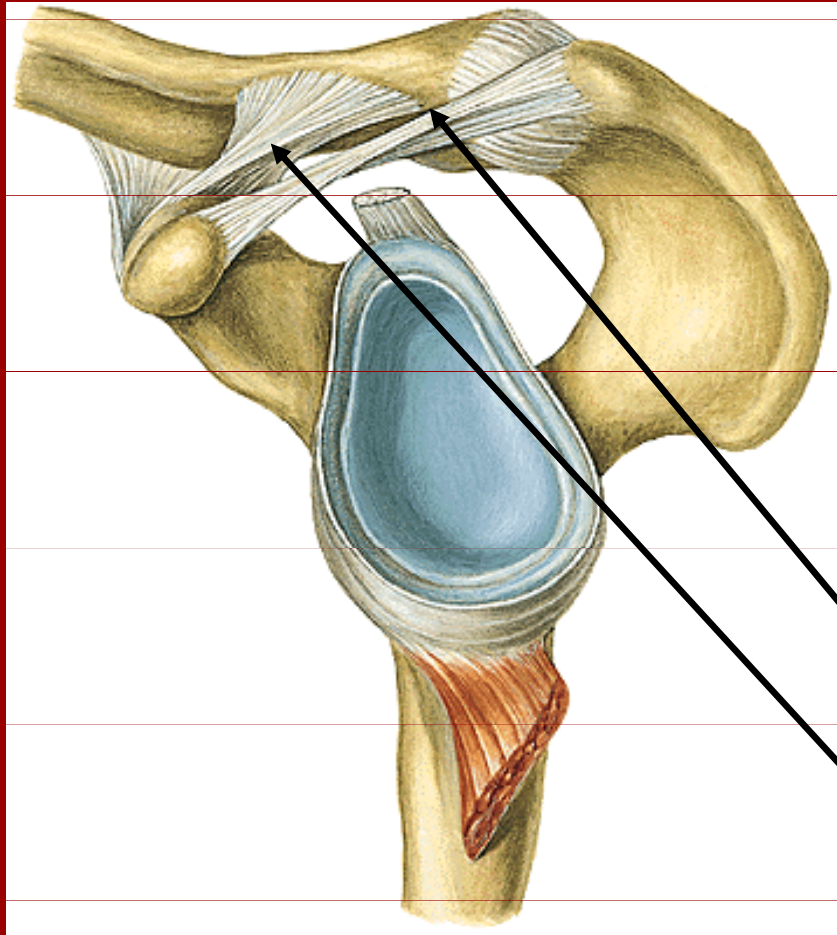


Lig. sternoclaviculare ant.

Discus articularis

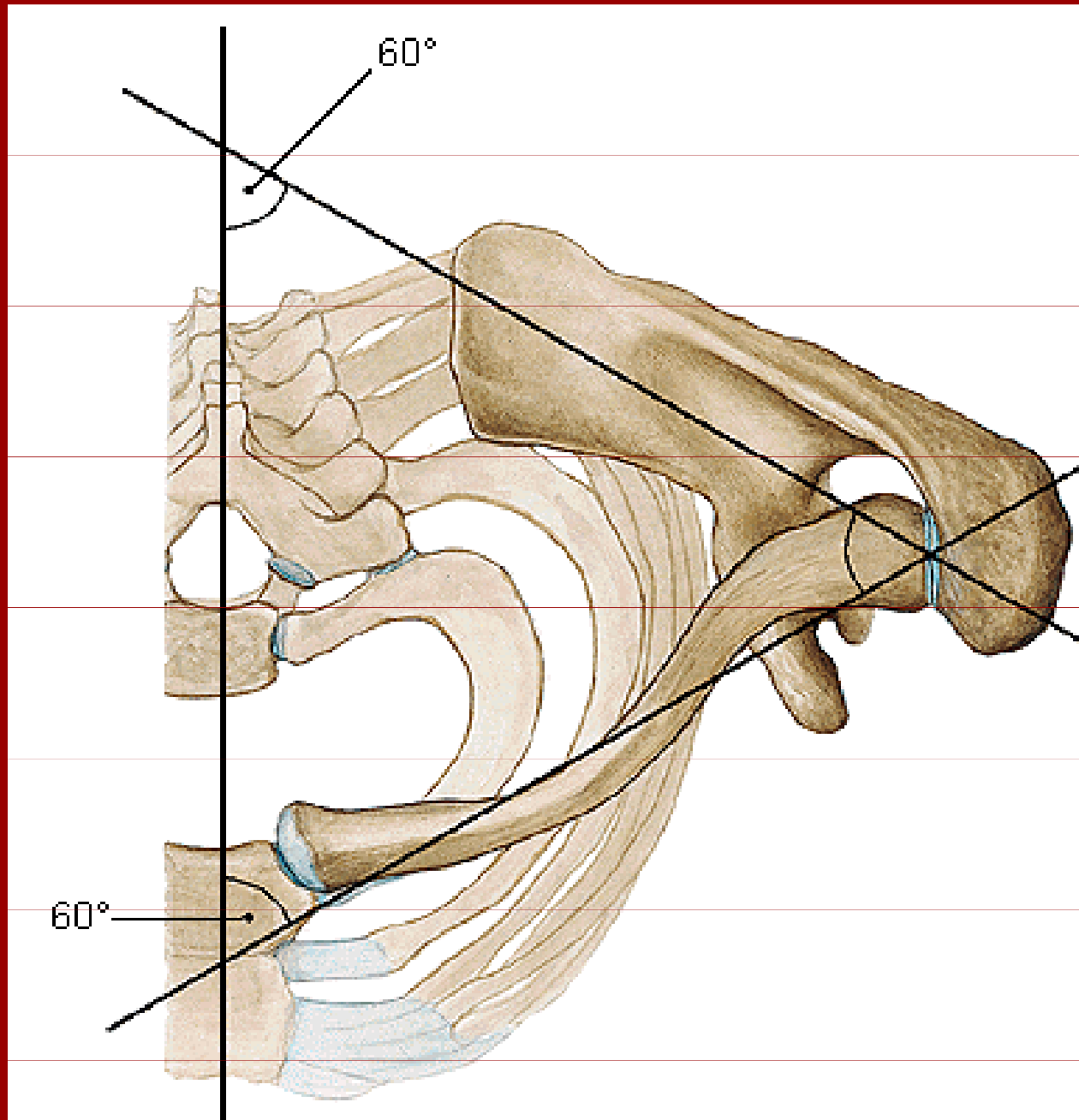
Spoje kostí pletence

Art. acromioclavicularis



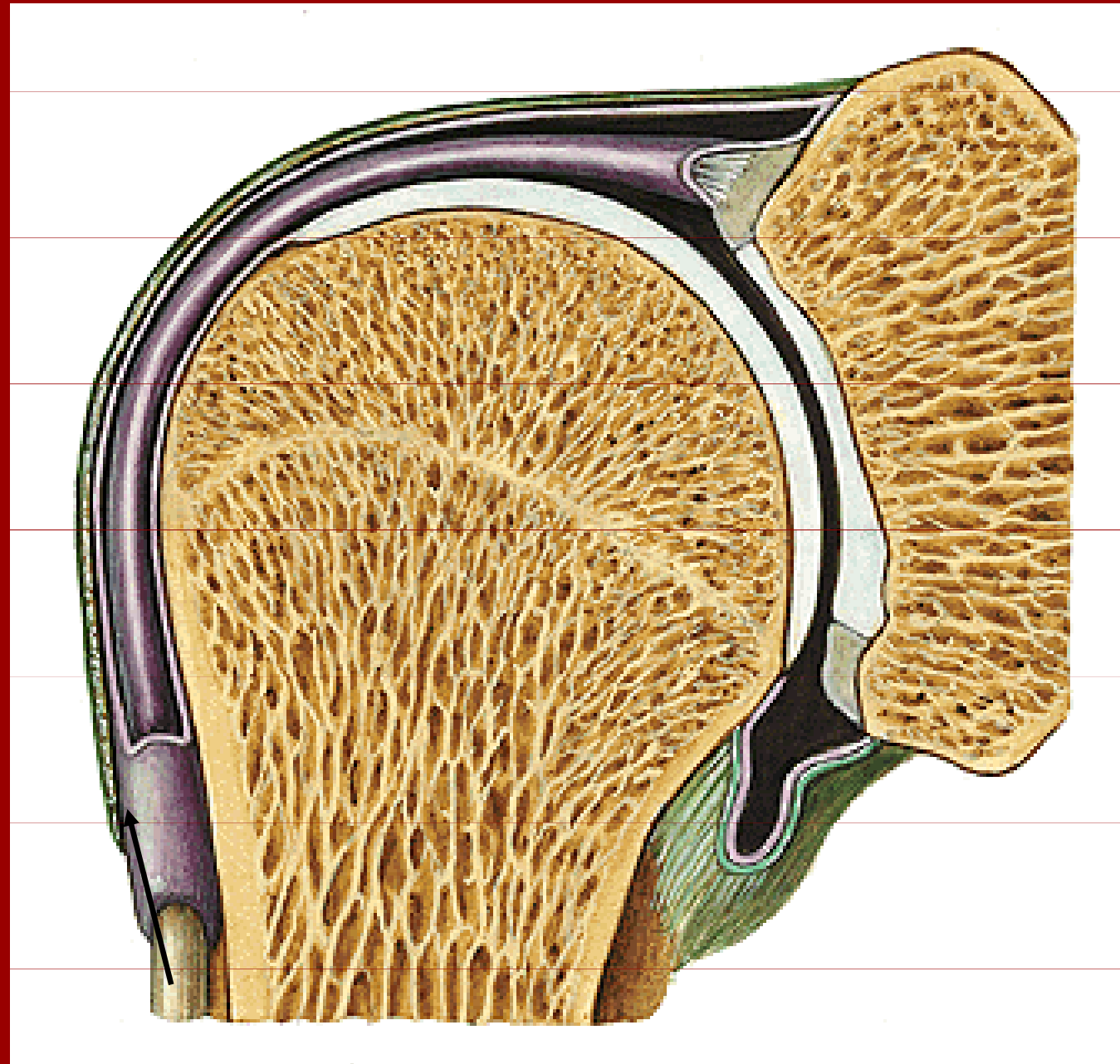
Lig. coracoacromiale

Lig. coracoclaviculare



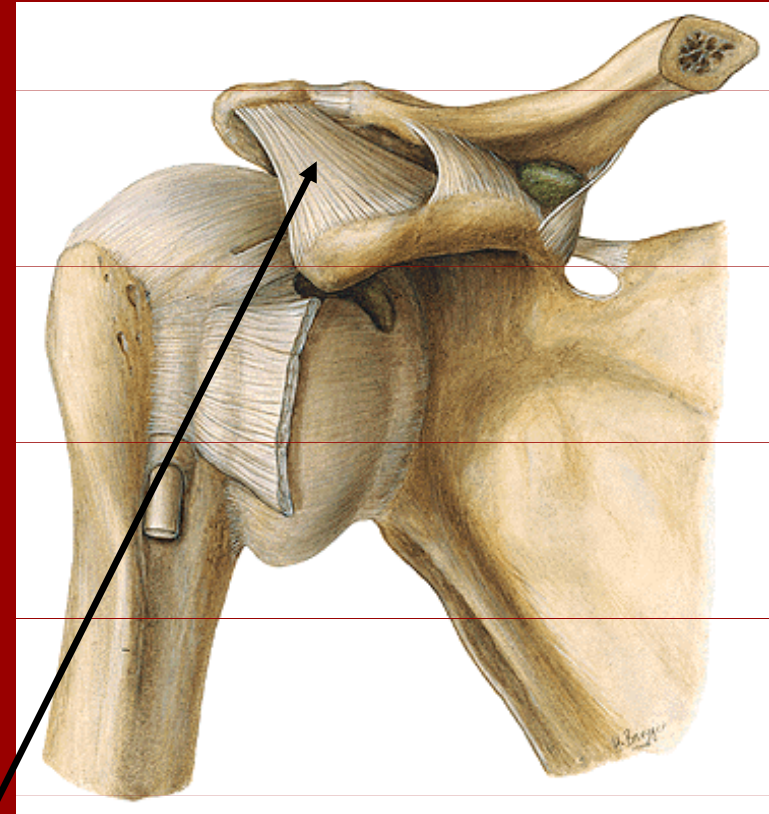
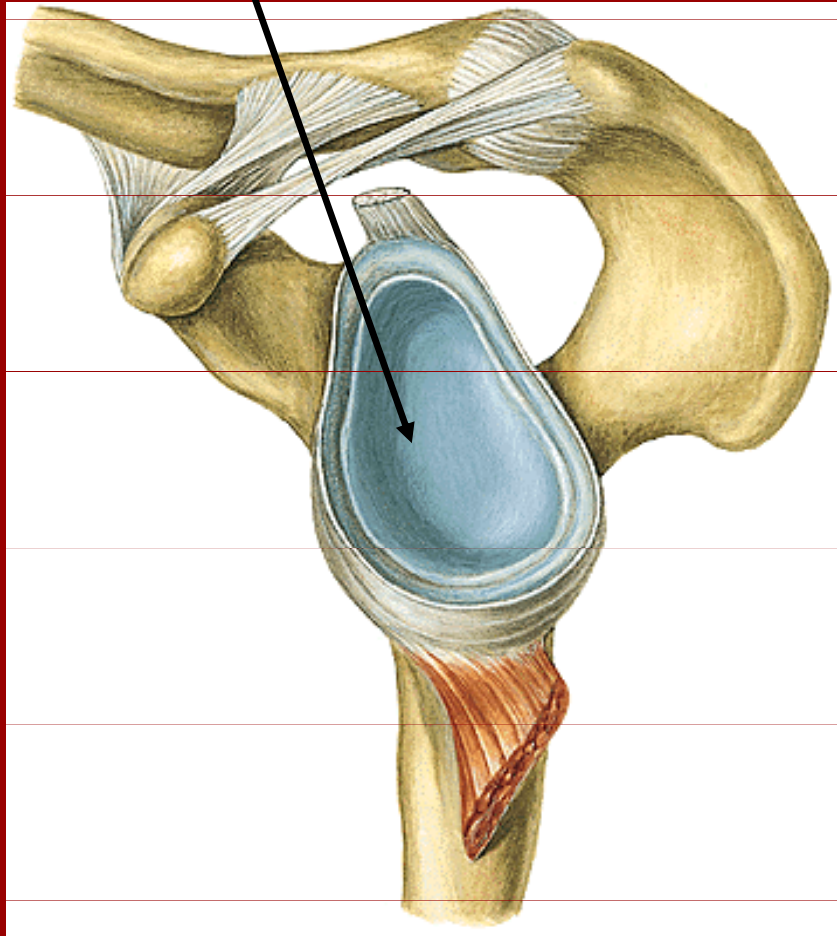
Spoje kostí volné končetiny

Art. humeri



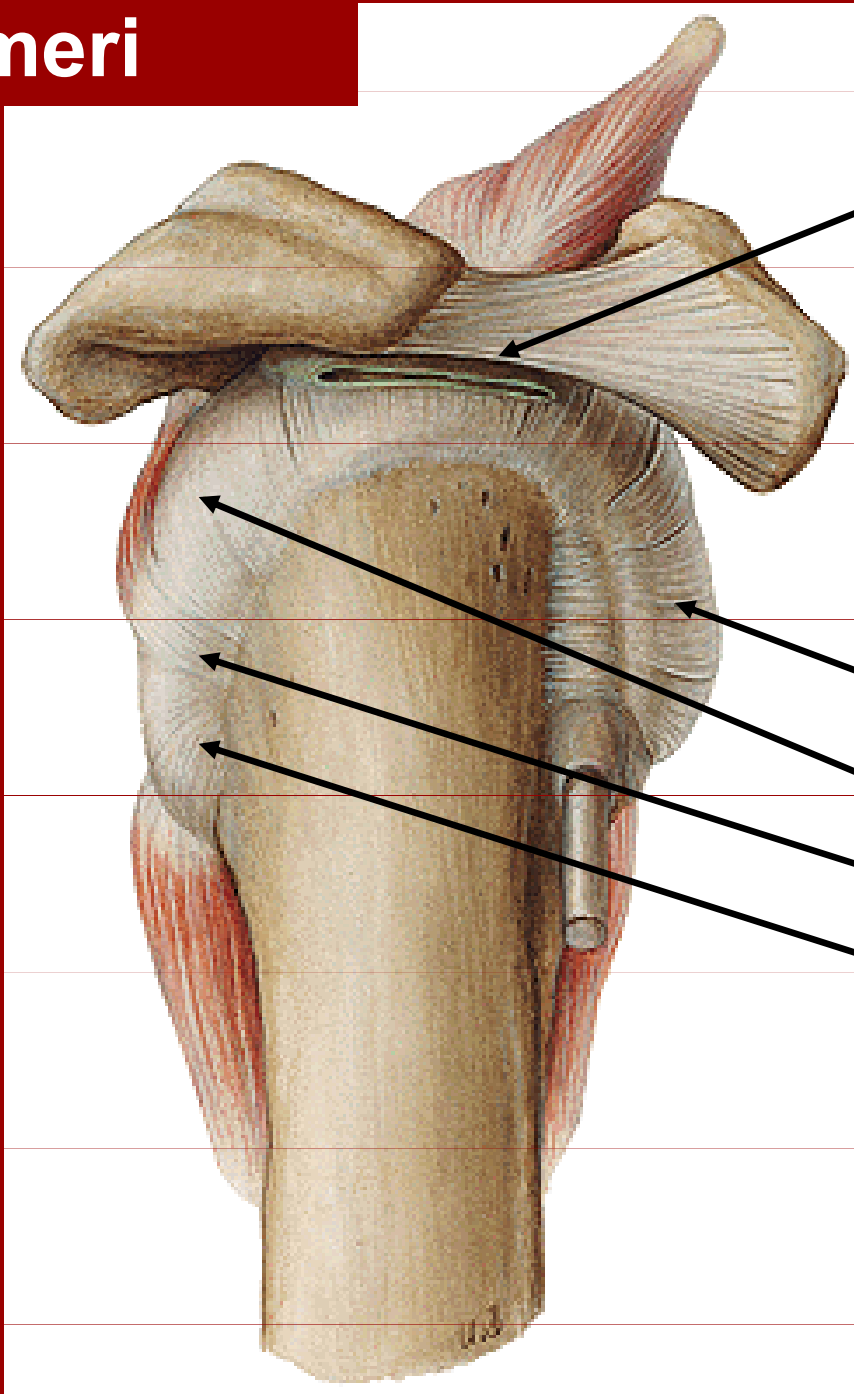
Spoje kostí pletence

Cavitas glenoidalis



Fornix humeri

Art.humeri



bursa
subacromialis

Svaly tvořící tzv.
rotátorovou
manžetu:

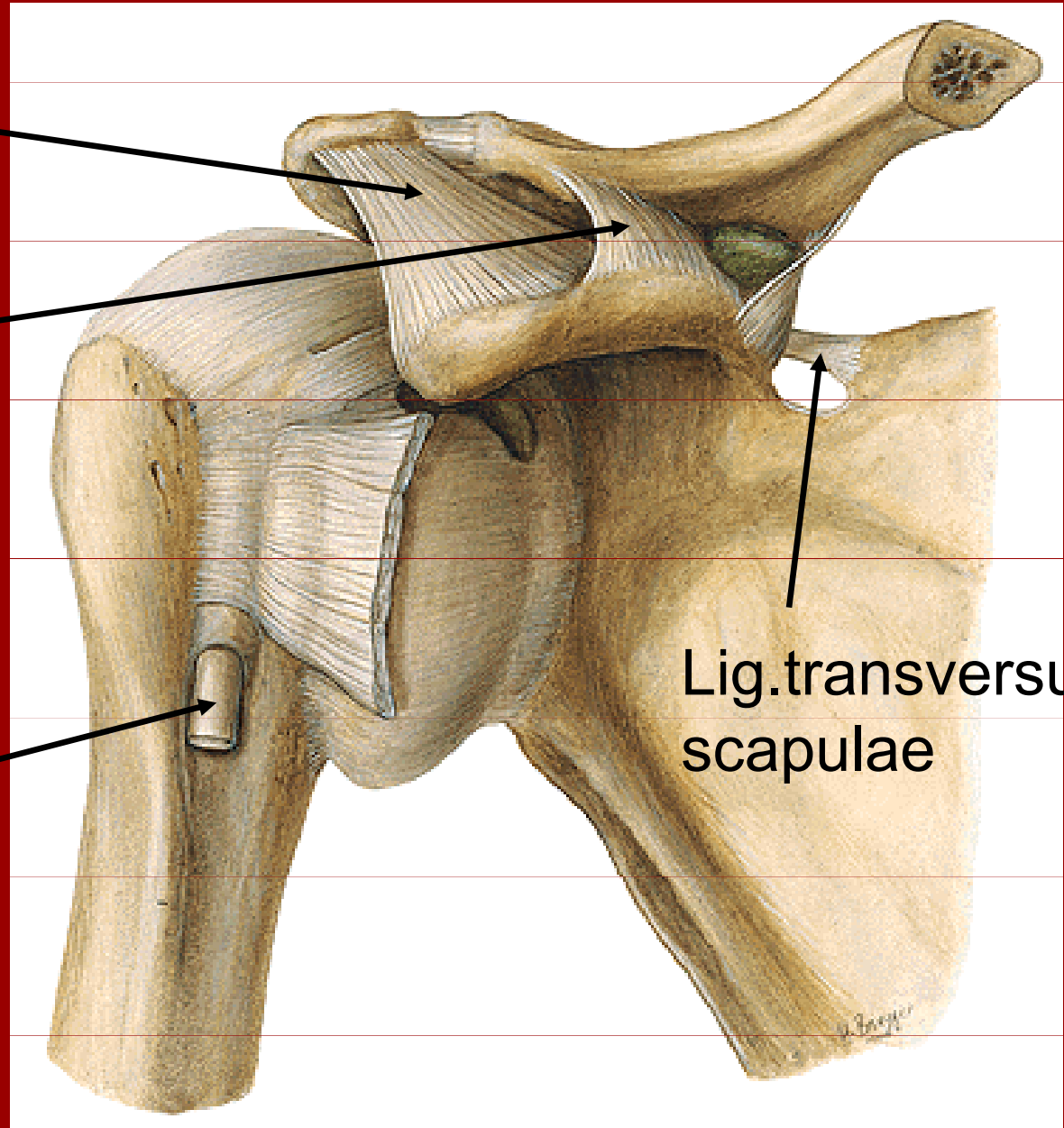
m.subscapularis
m.infraspinatus
m.teres minor
m.teres major,

Art.humeri a art.acromioclavicularis

Fornix humeri

Lig.coracoclaviculare

Caput longum
bicipsu

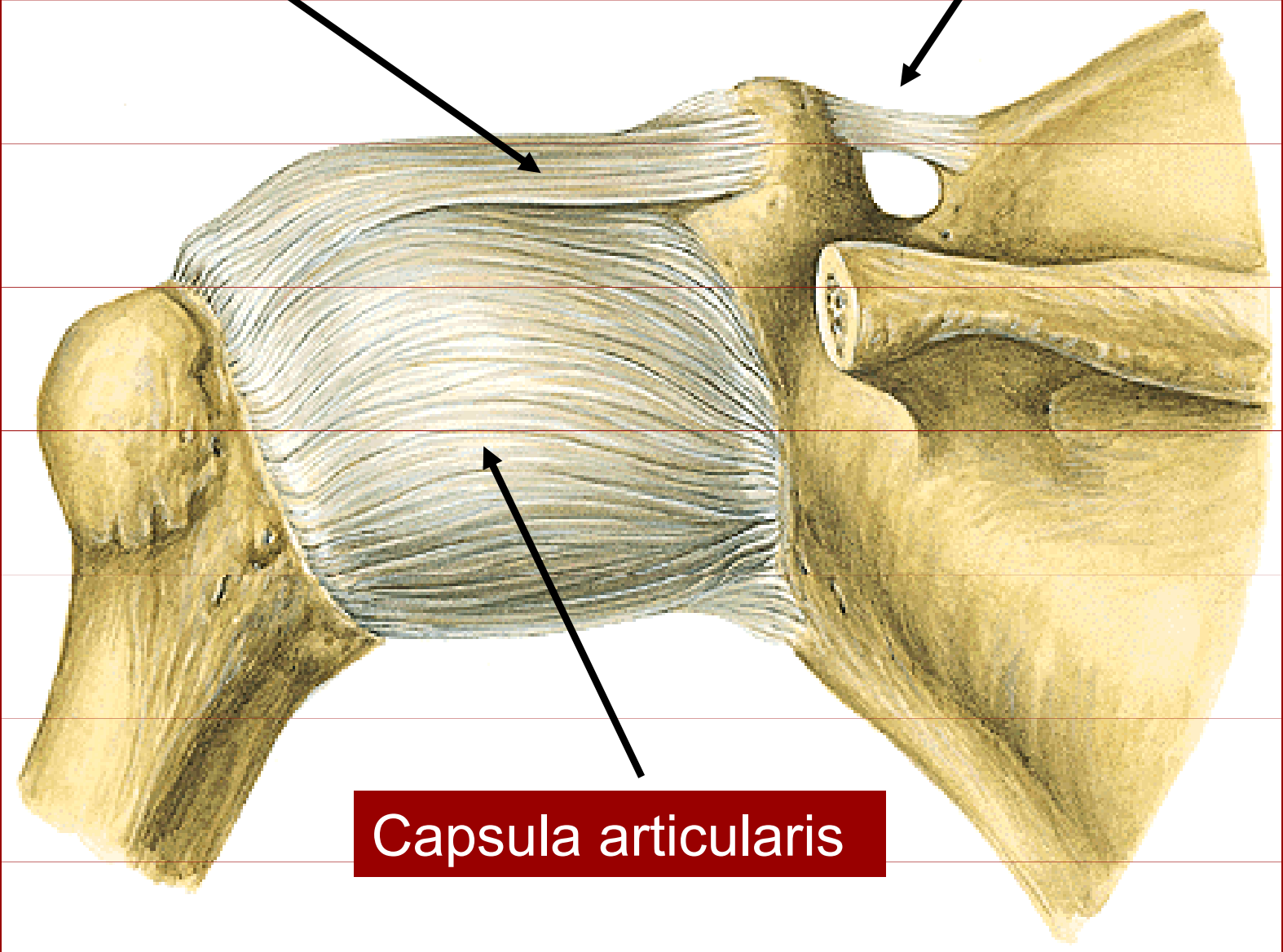


Lig.transversum
scapulae

Art.humeri

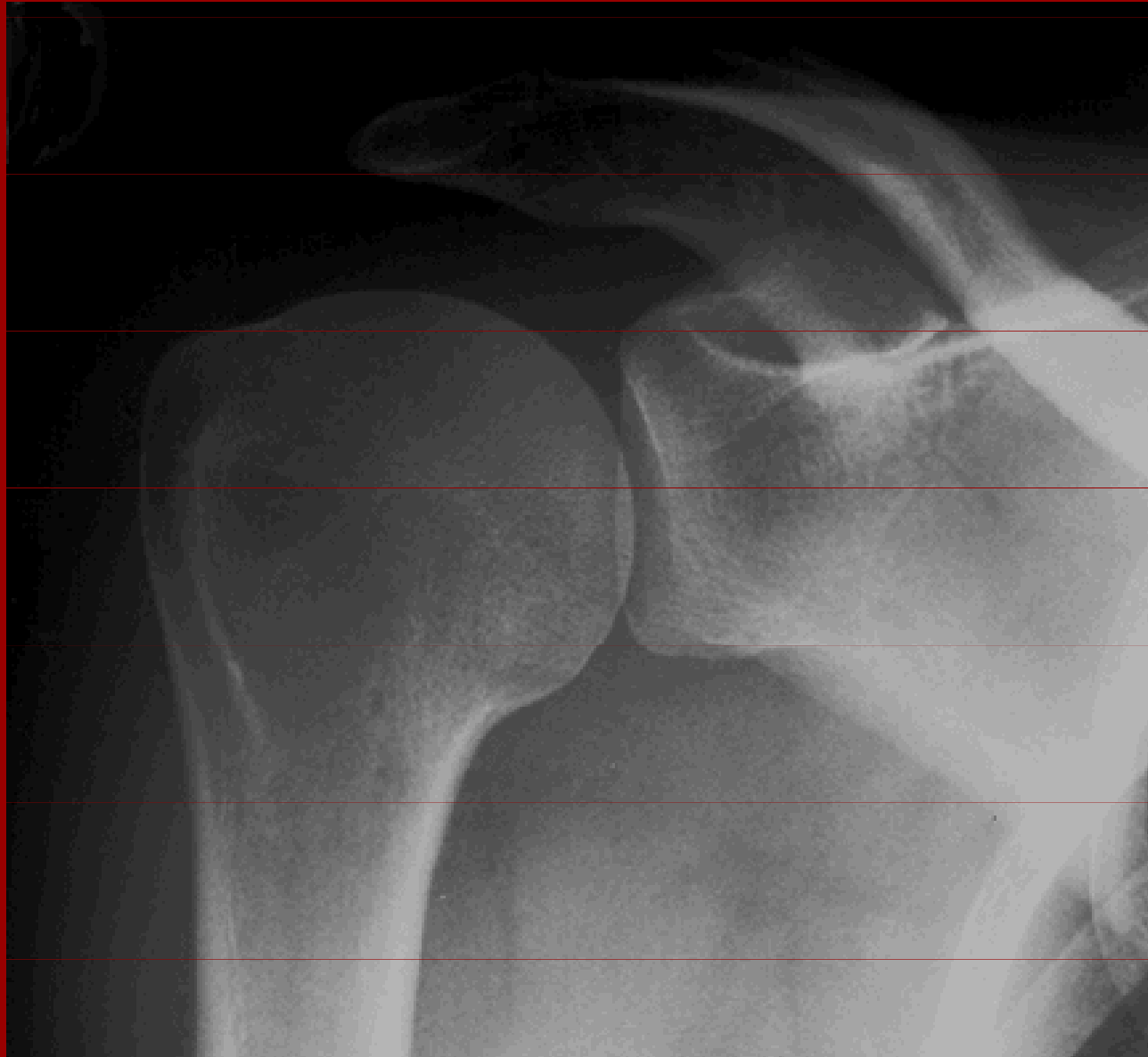Lig.coracohumerale

Lig.transversum scapulae



Capsula articularis

Rtg ramenního kloubu



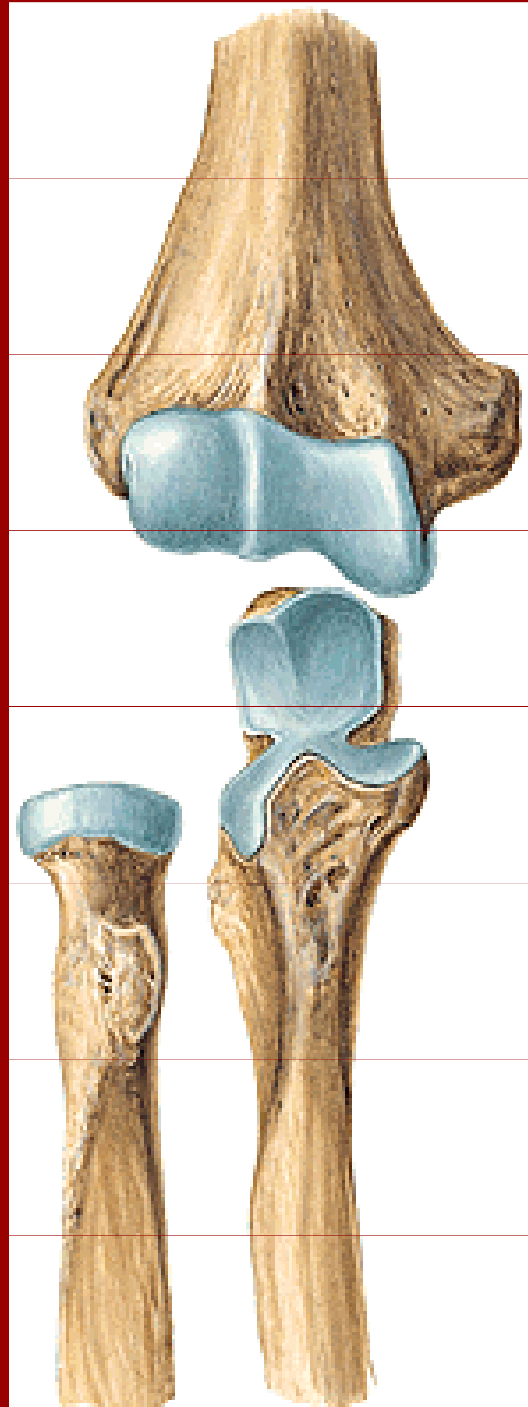
caput humeri

cavitas
glenoidalis

acromion

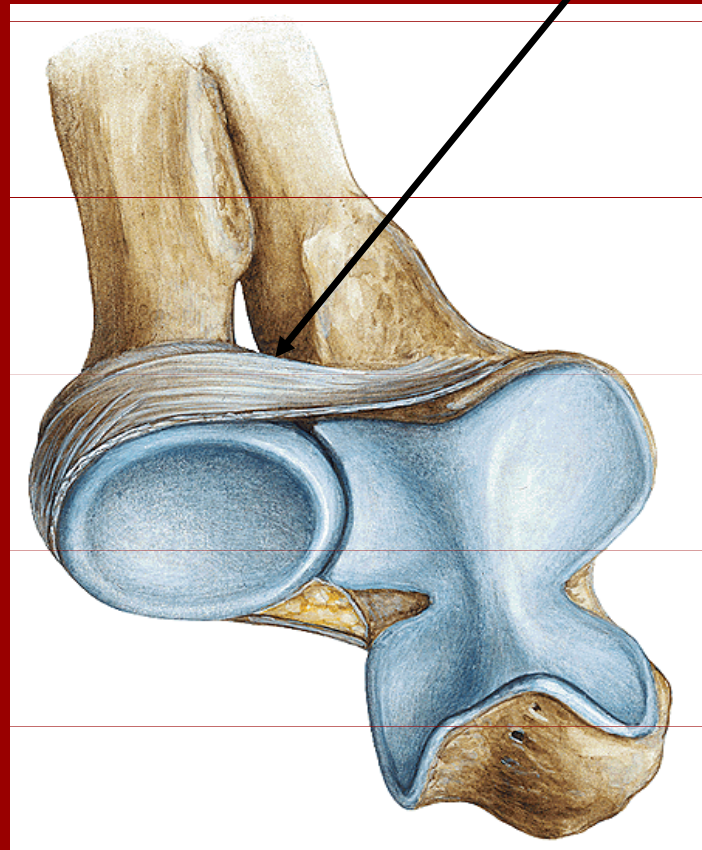
clavicula

Spoje kostí volné končetiny



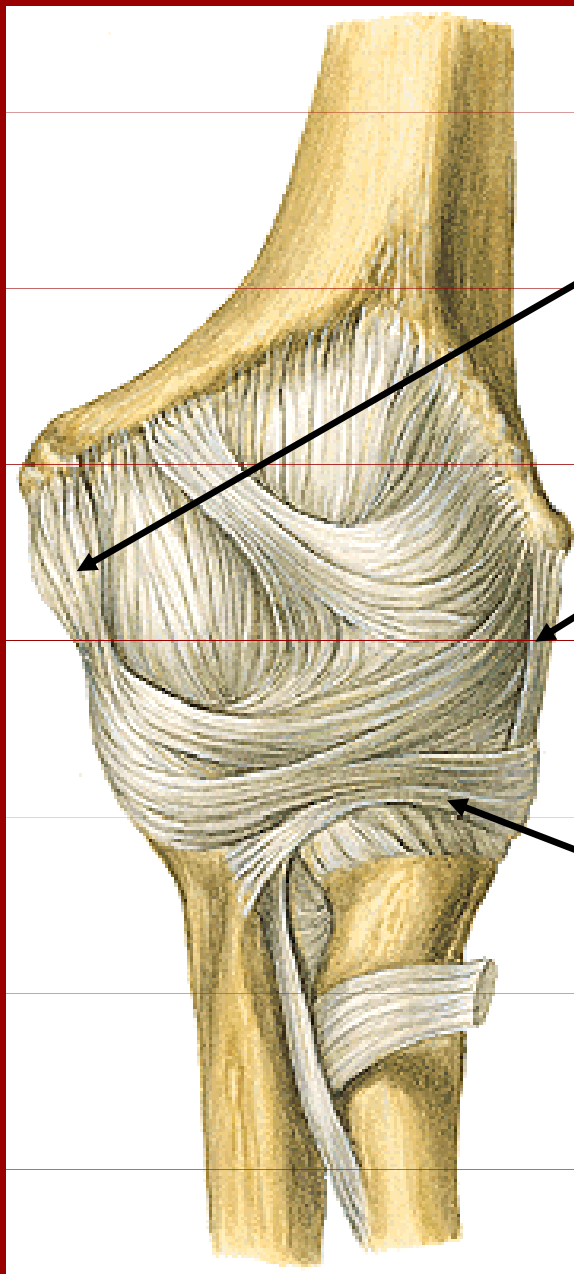
Art. cubiti

Lig.anulare radii



Spoje kostí volné končetiny

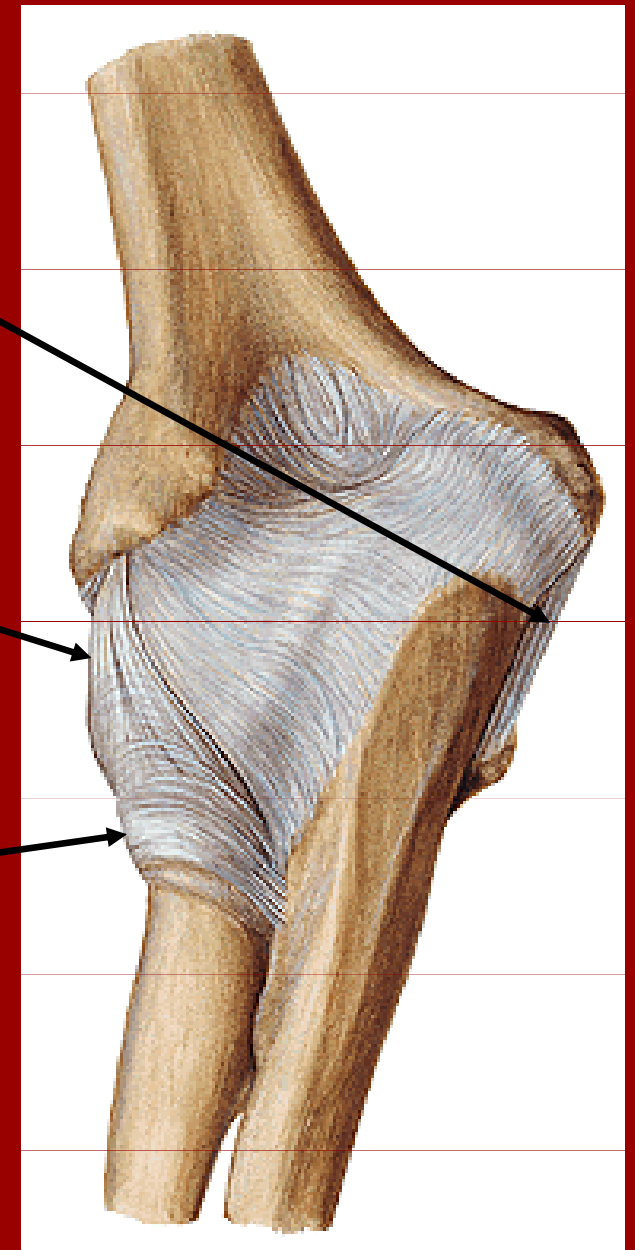
Art. cubiti



lig. coláterale
ulnare

lig. colaterale
radiale

lig. anulare radii

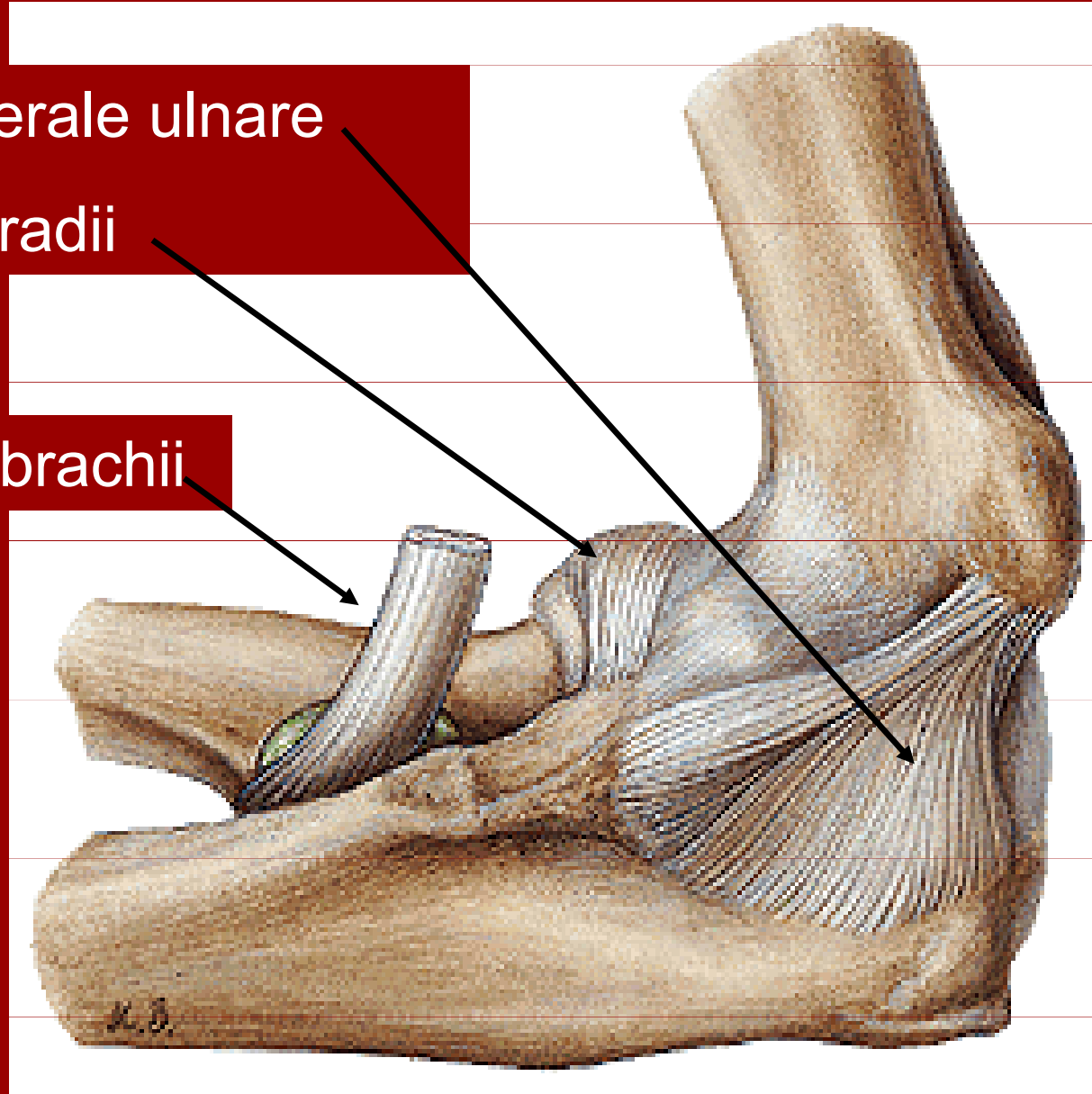


Art.cubiti

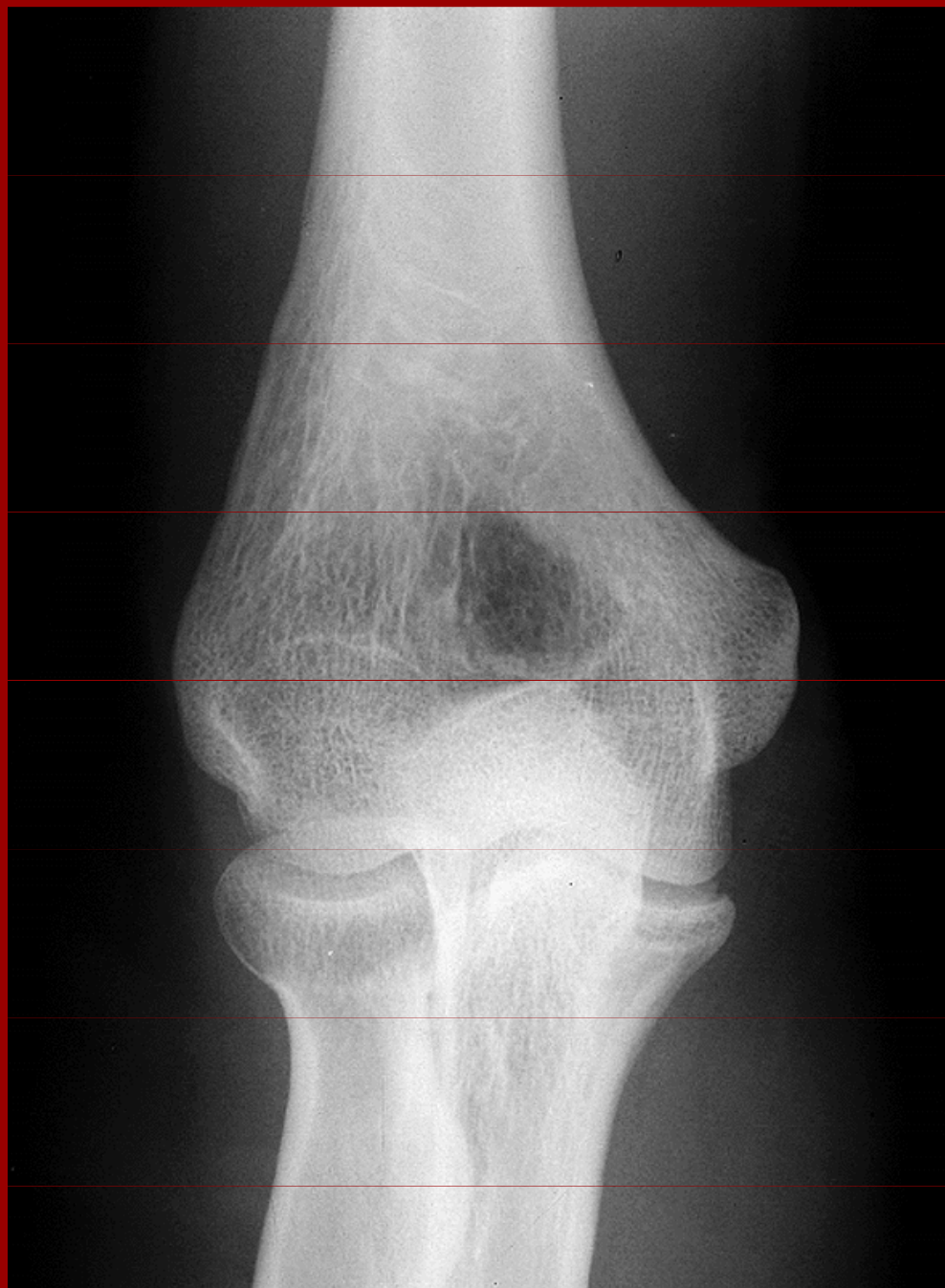
Lig. colaterale ulnare

Lig. anulare radii

Tendo m.biceps brachii



Rtg loketního kloubu



epicondylus med.

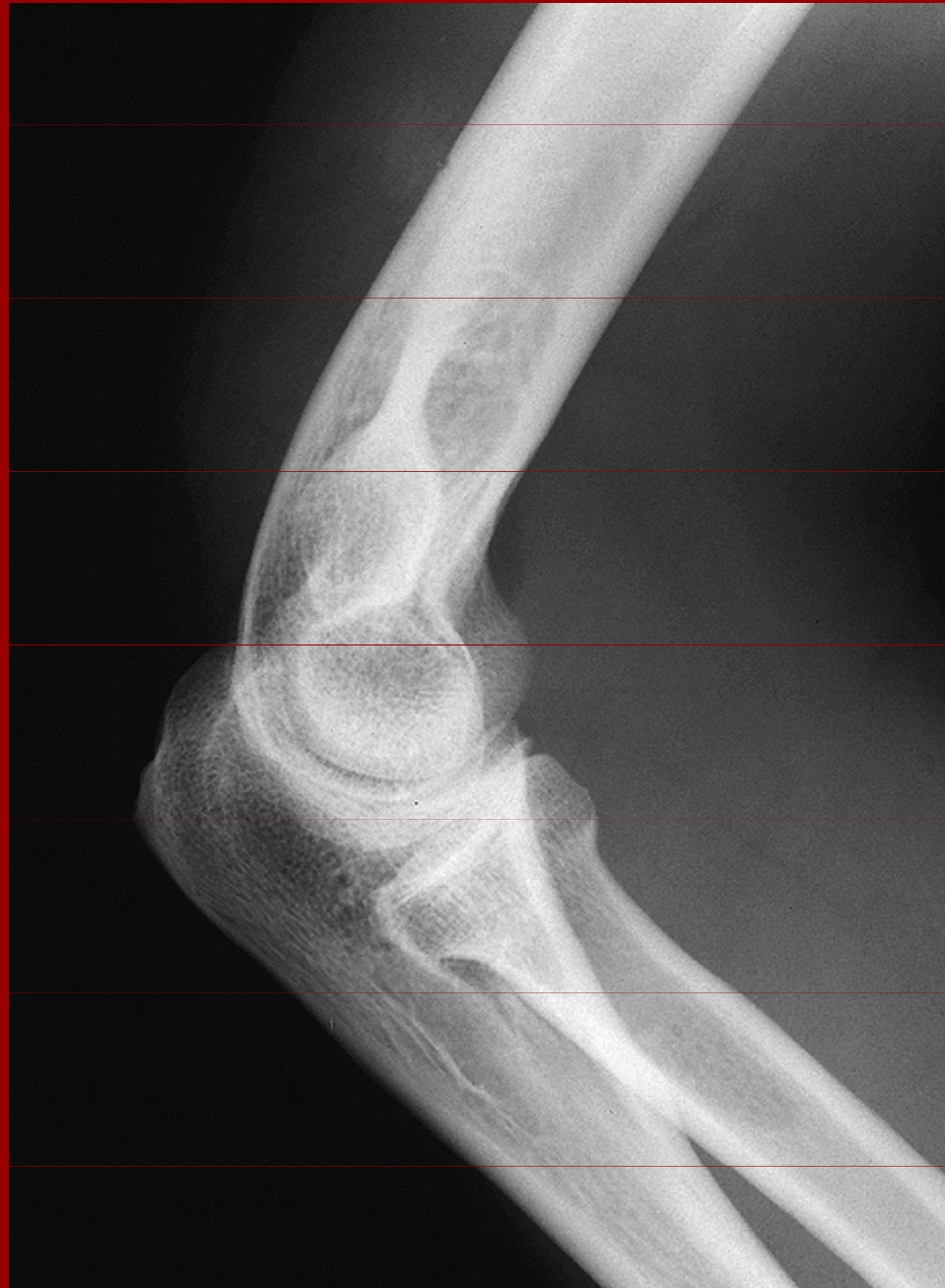epicondylus lat.

fossa olecrani

olecranon ulnae

caput radii

Rtg loketního kloubu



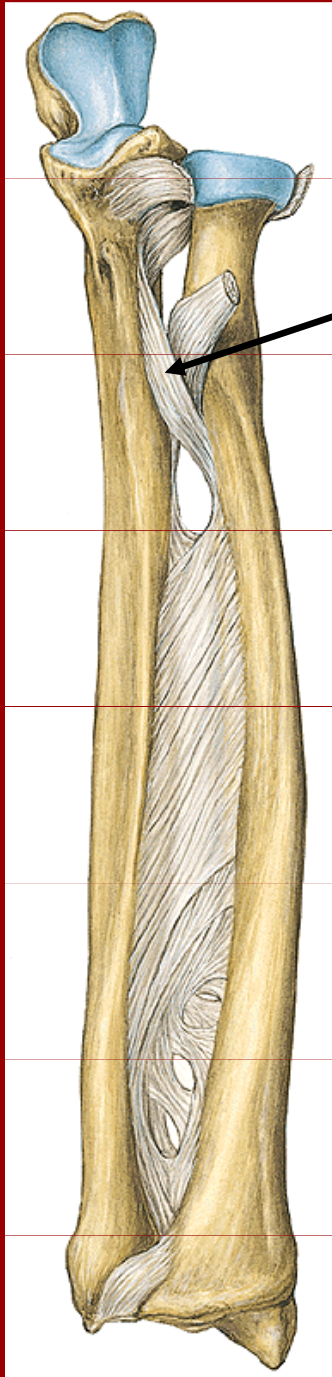
incisura ulnae

olecranon ulnae

caput radii

collum radii

Spoje kostí volné končetiny



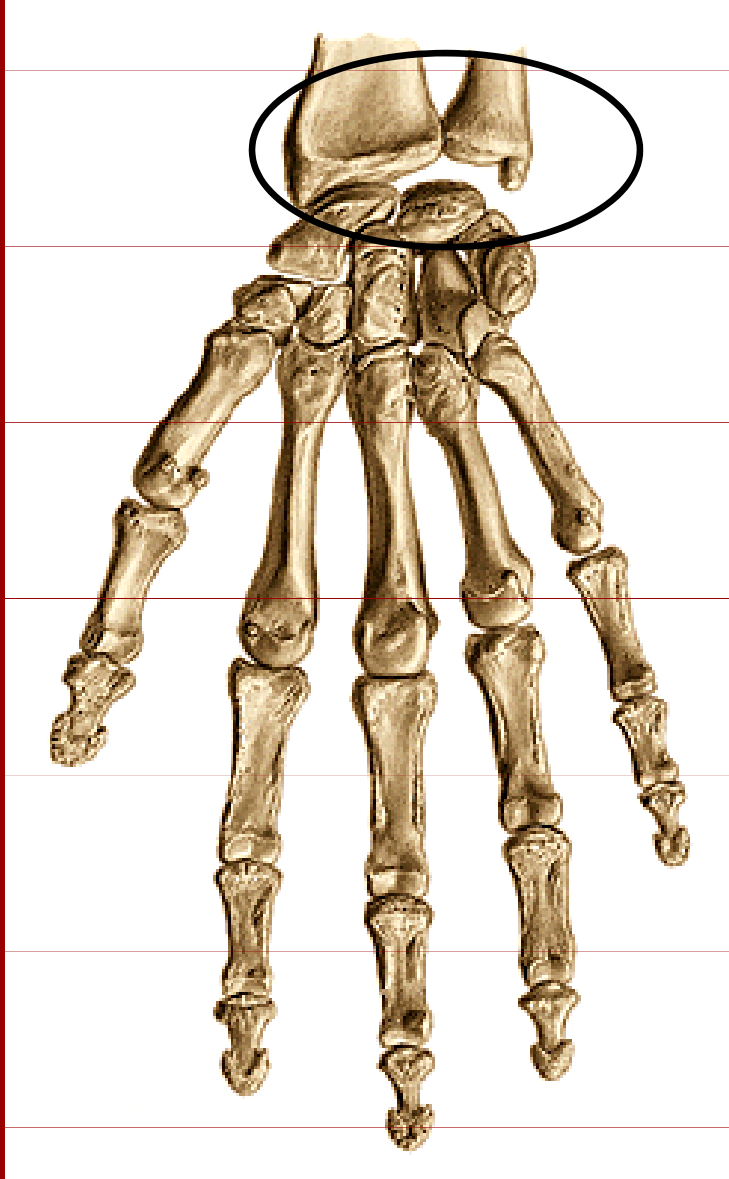
Chorda obliqua

Membrana interossea antebrachii

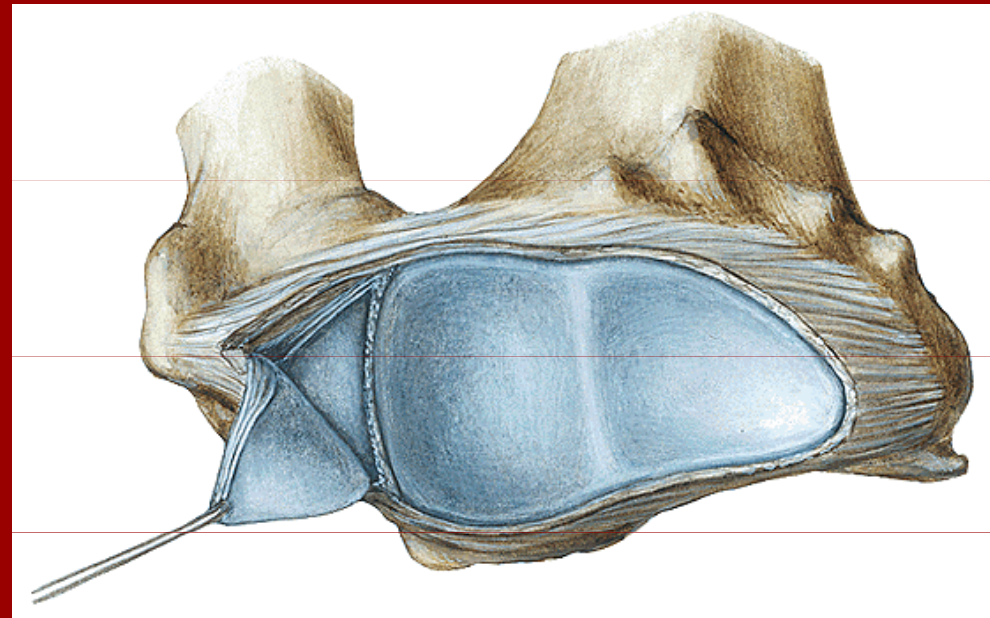
Articulatio radioulnaris distalis

Spoje kostí volné končetiny

Klouby ruky

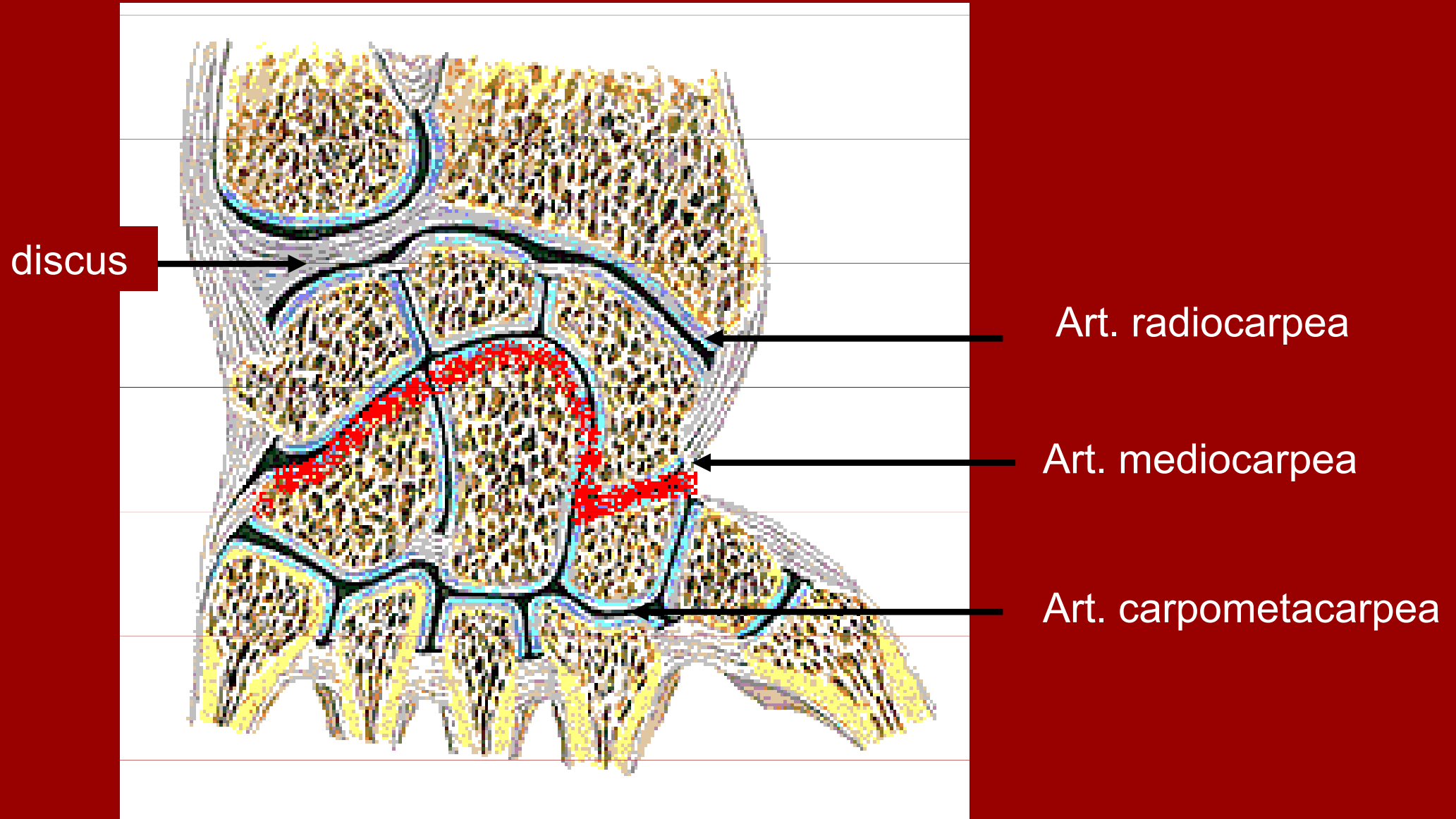


Art. radiocarpea

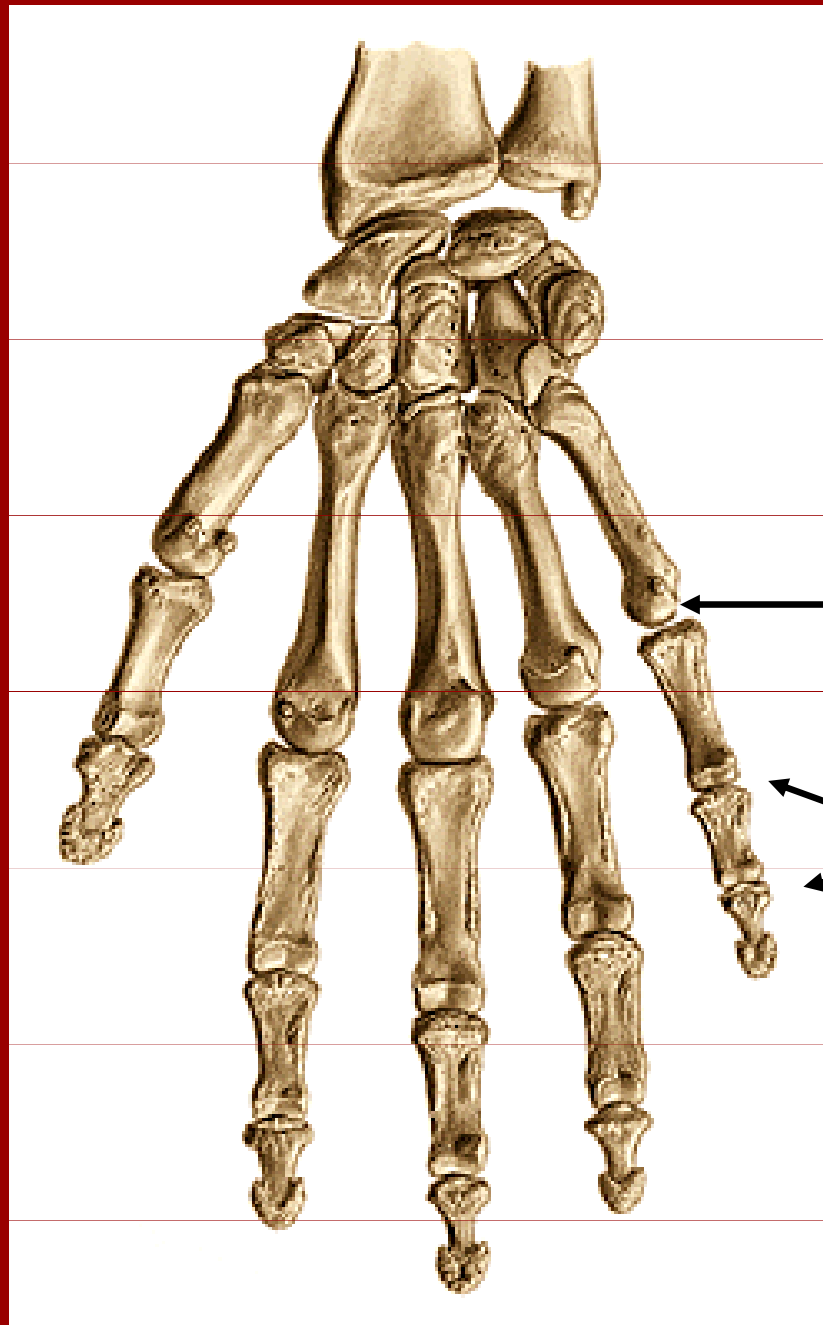


Spoje kostí volné končetiny

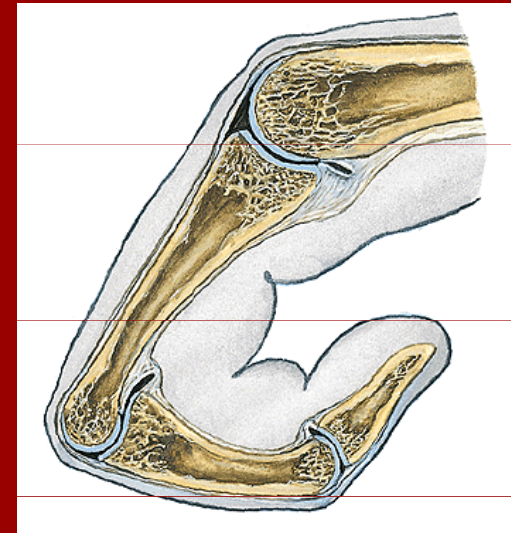
Klouby ruky



Spoje kostí volné končetiny



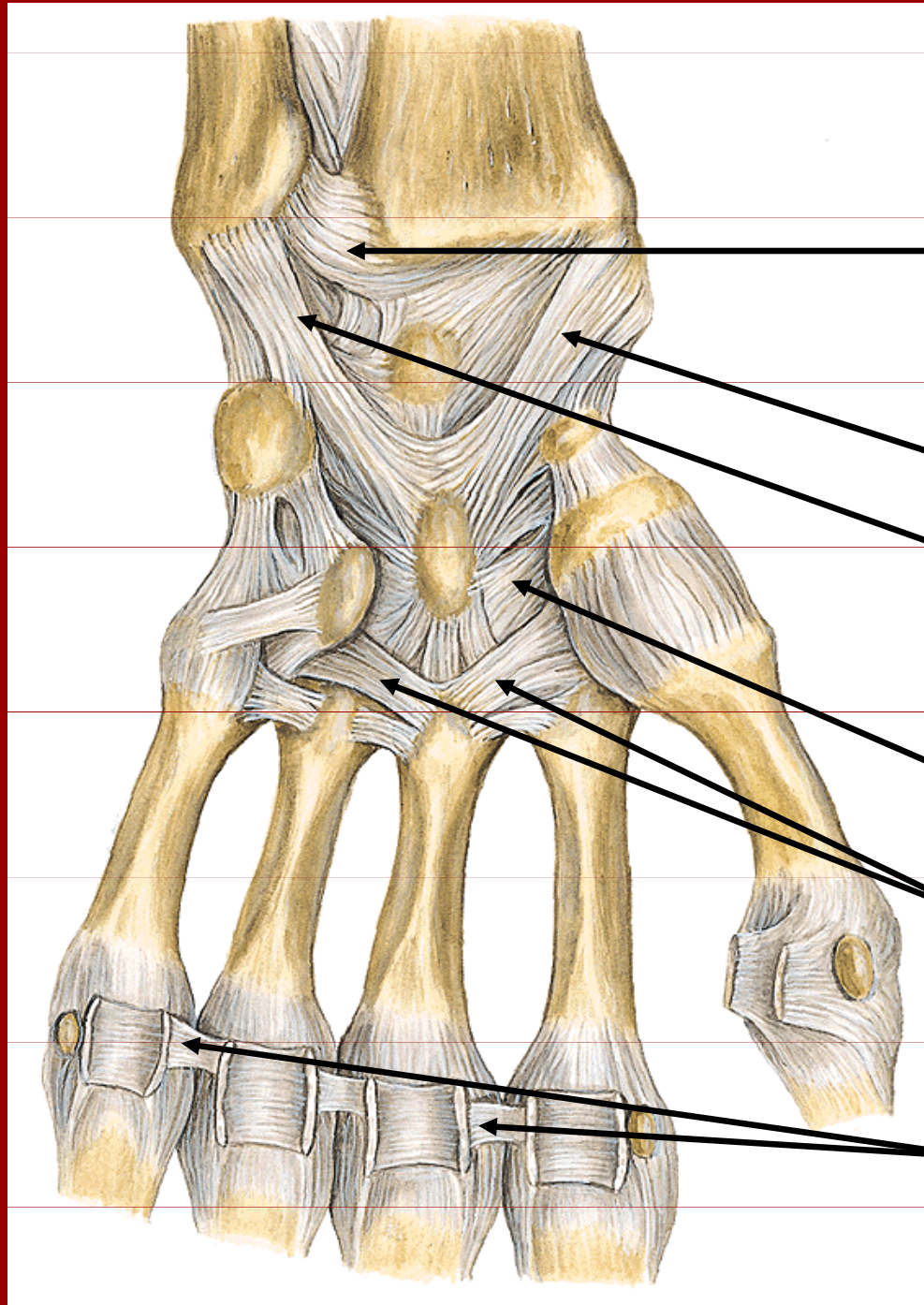
Klouby ruky



Artt. metacarpophalangeae

Artt. interphalangeae manus

Klouby ruky



Art.radioulnaris dist.

Lig.radiocarpale palmare

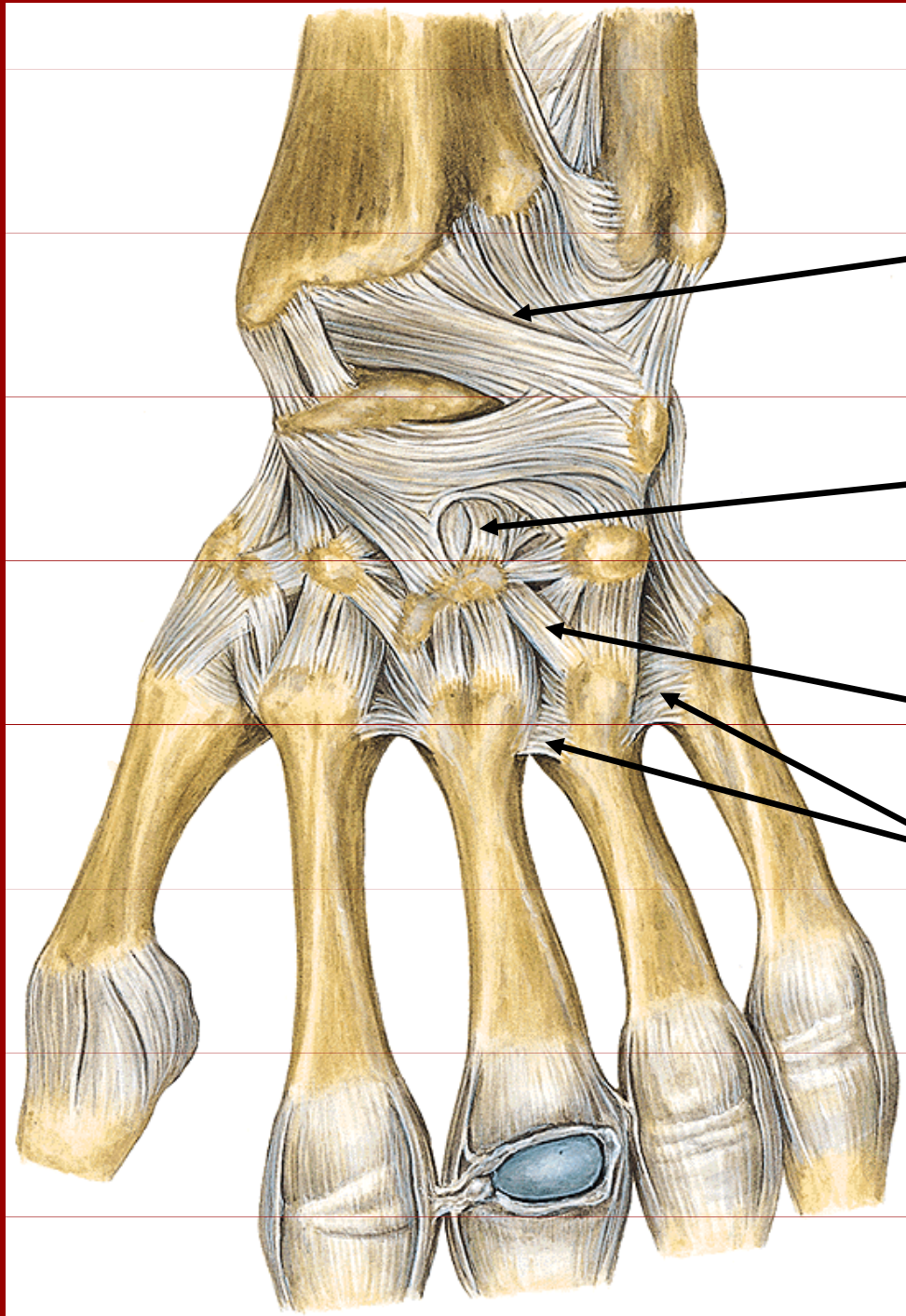
Lig.ulnocarpale palmare

Lig.carpi radiatum

Lig.metacarpalia
palmaria

Lig.metacarpale
transversum profundum

Klouby ruky



Lig.radiocarpale dors.

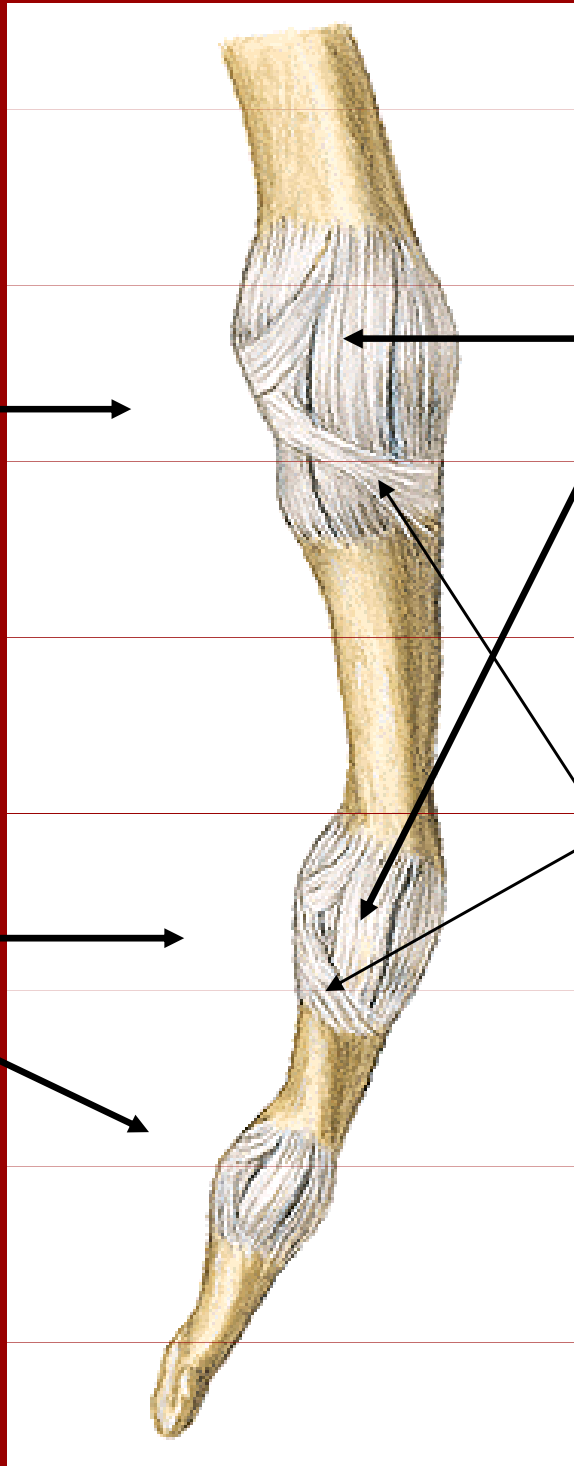
Lig.intercarpalia dors.

Lig.carpometacarpalia dors.

Lig.metacarpalia dors.

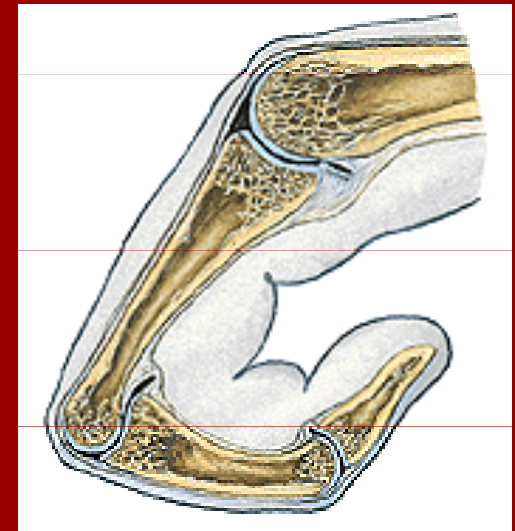
Articulatio
metacarpo-
phalangeales

Articulatio
interphalangeales

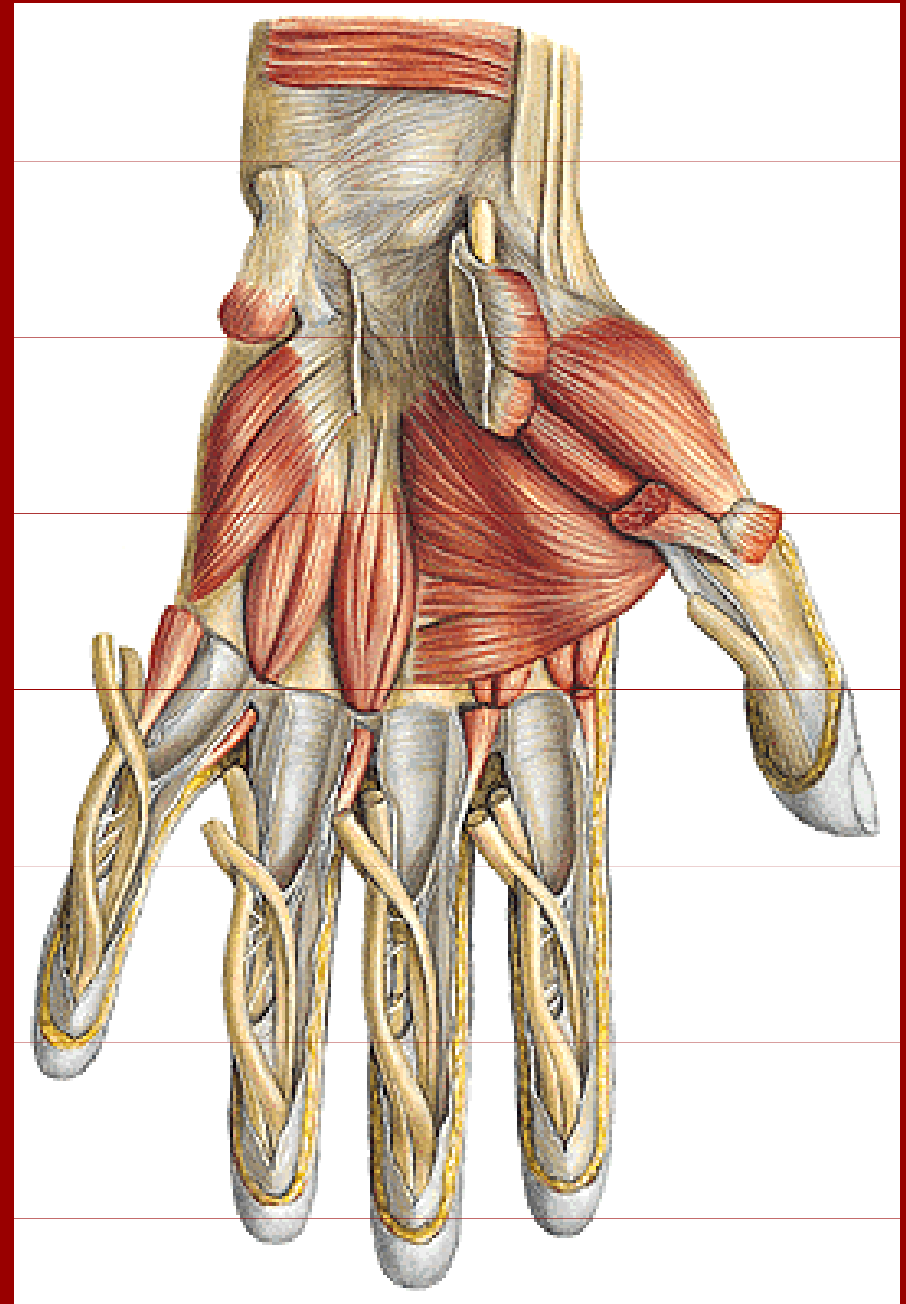
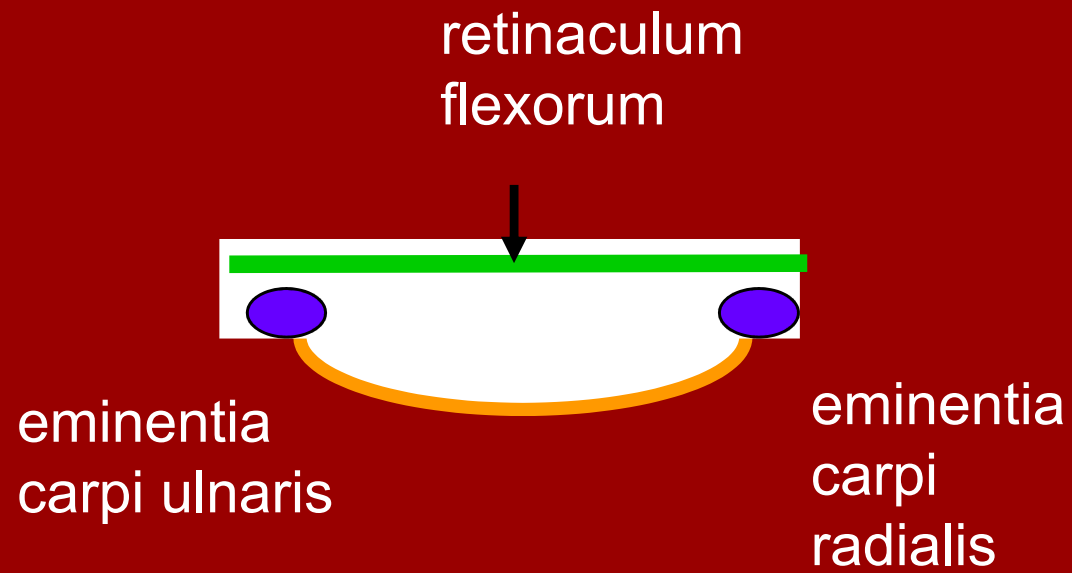


lig.collateralia

lig.palmaria

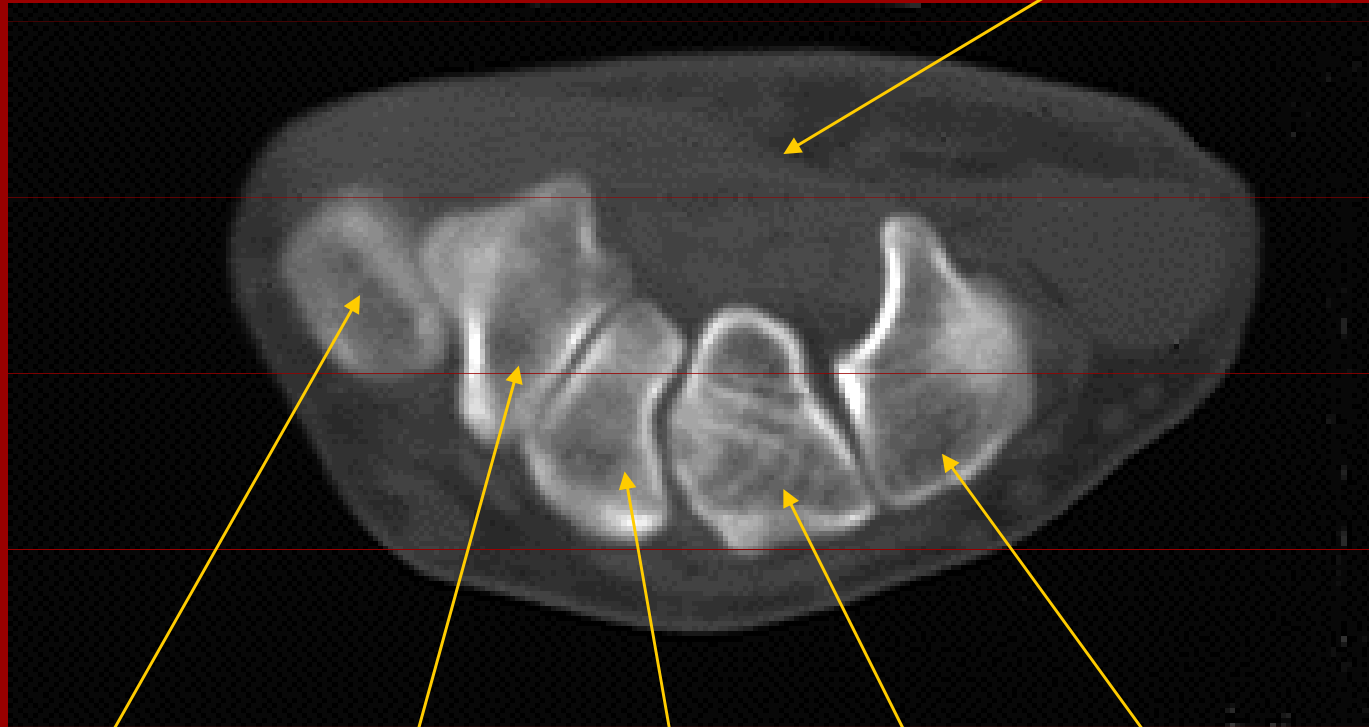


Sulcus et canalis carpi

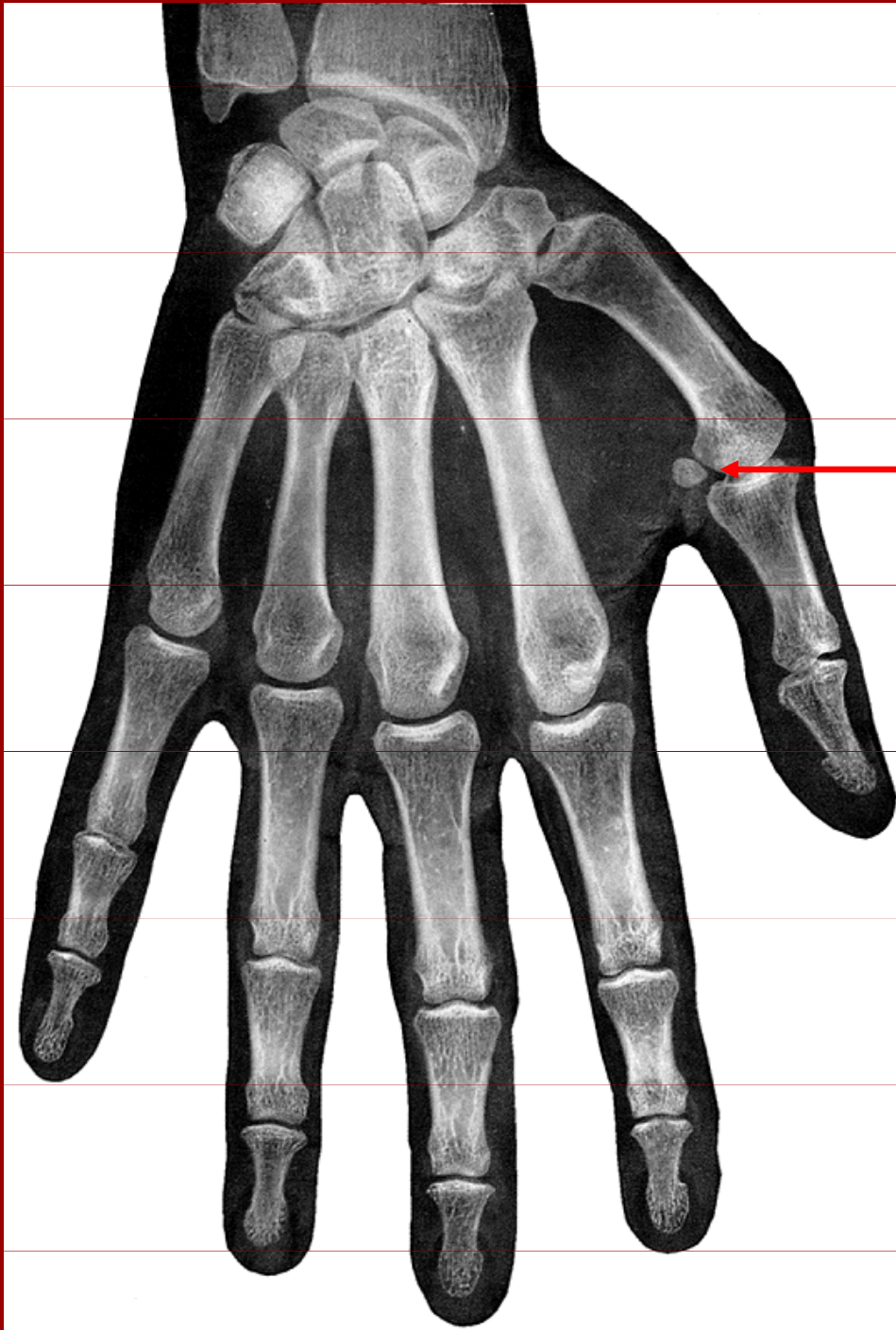

Canalis carpi (CT)

retinaculum flexorum

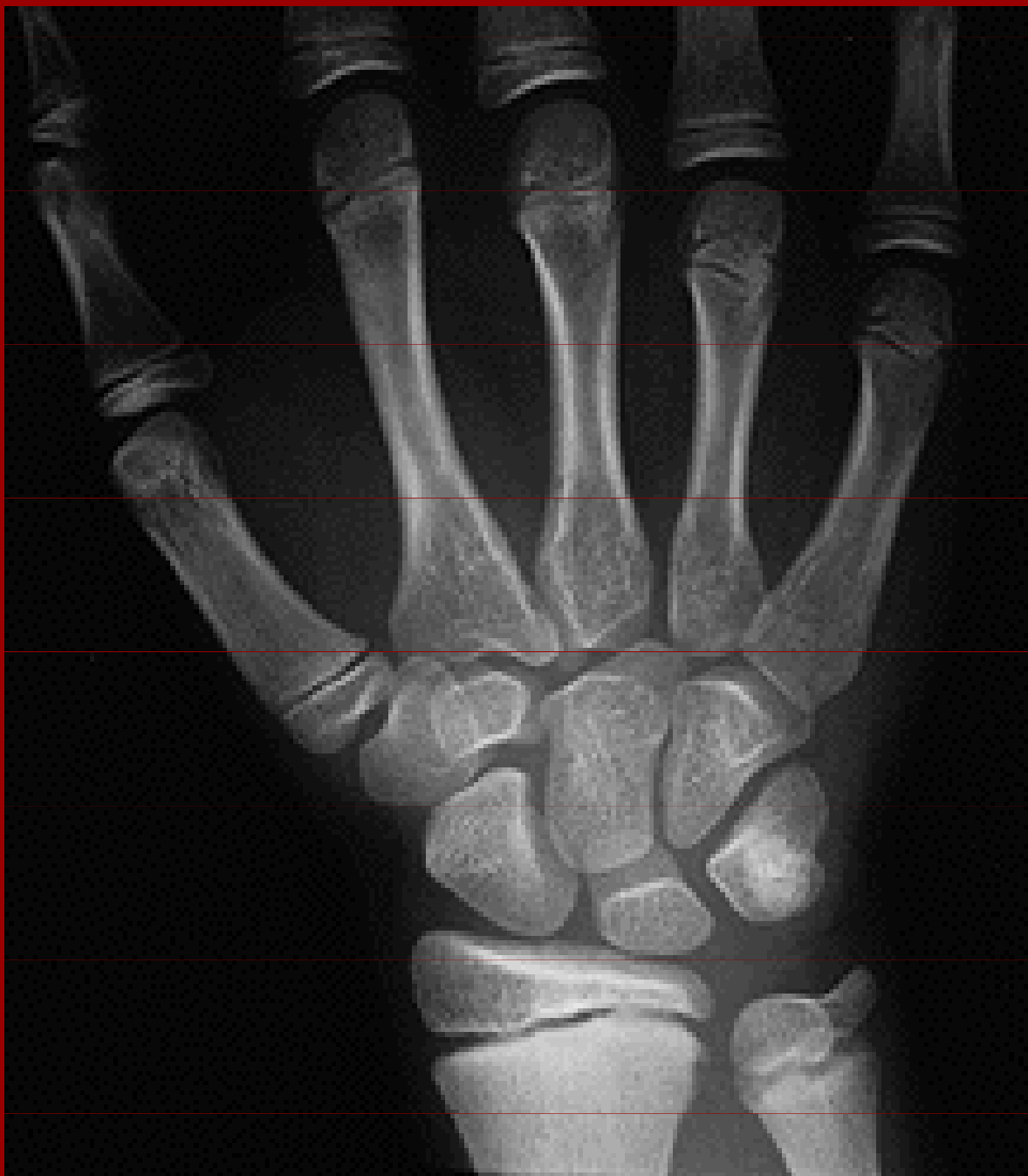

base V. metacarpu, os trapezium, trapezoideum, capitatum, hamatum



Rtg kloubů ruky

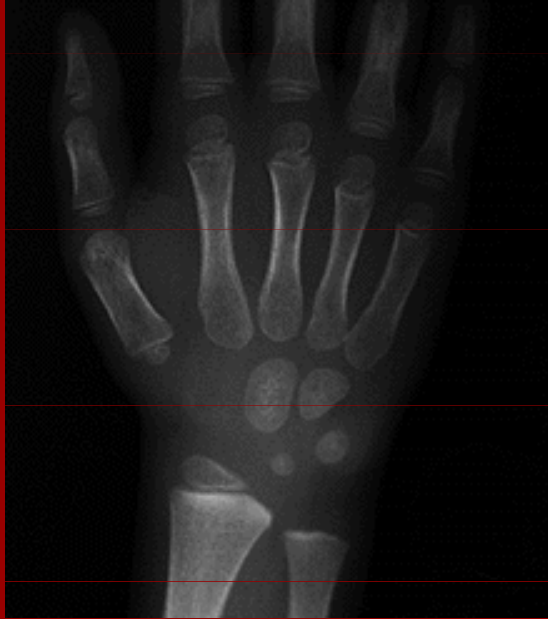sezamské
kůstky
v kloubu palce



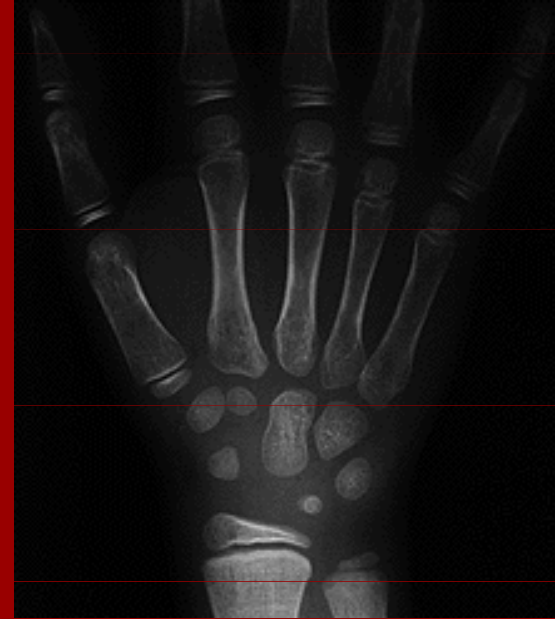Rtg zápěstí u dítěte
ve věku 11 let

růstová chrupavka

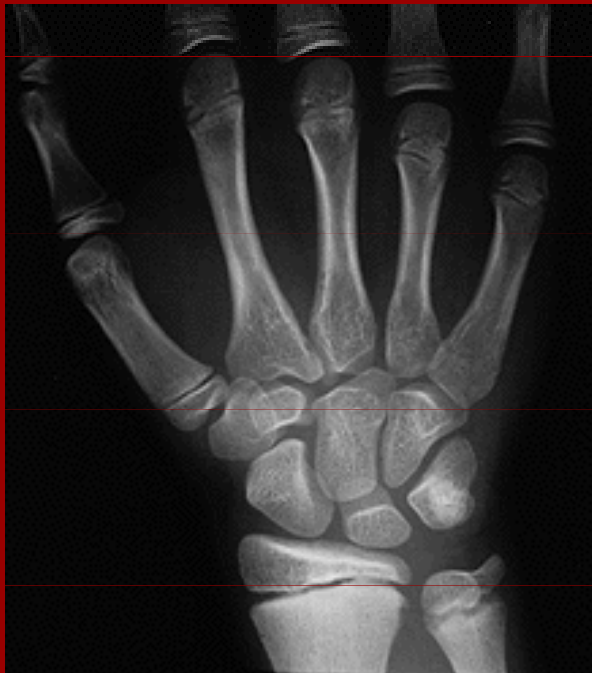Kostní věk



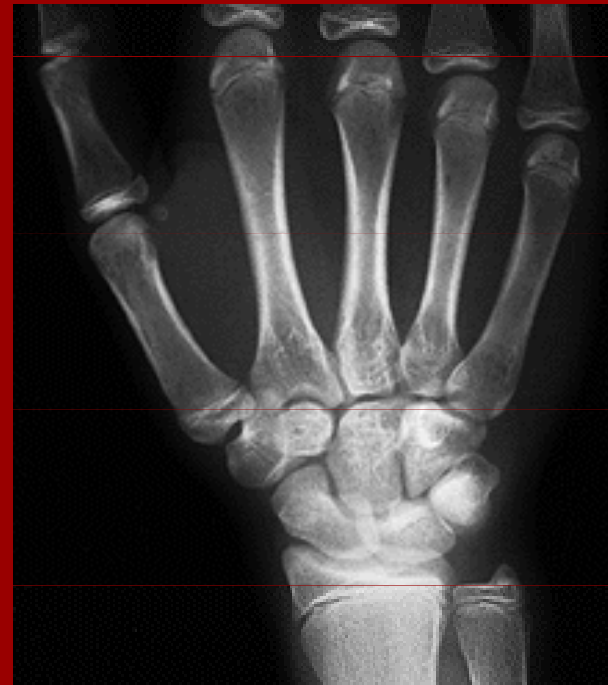4,5



7



11



13