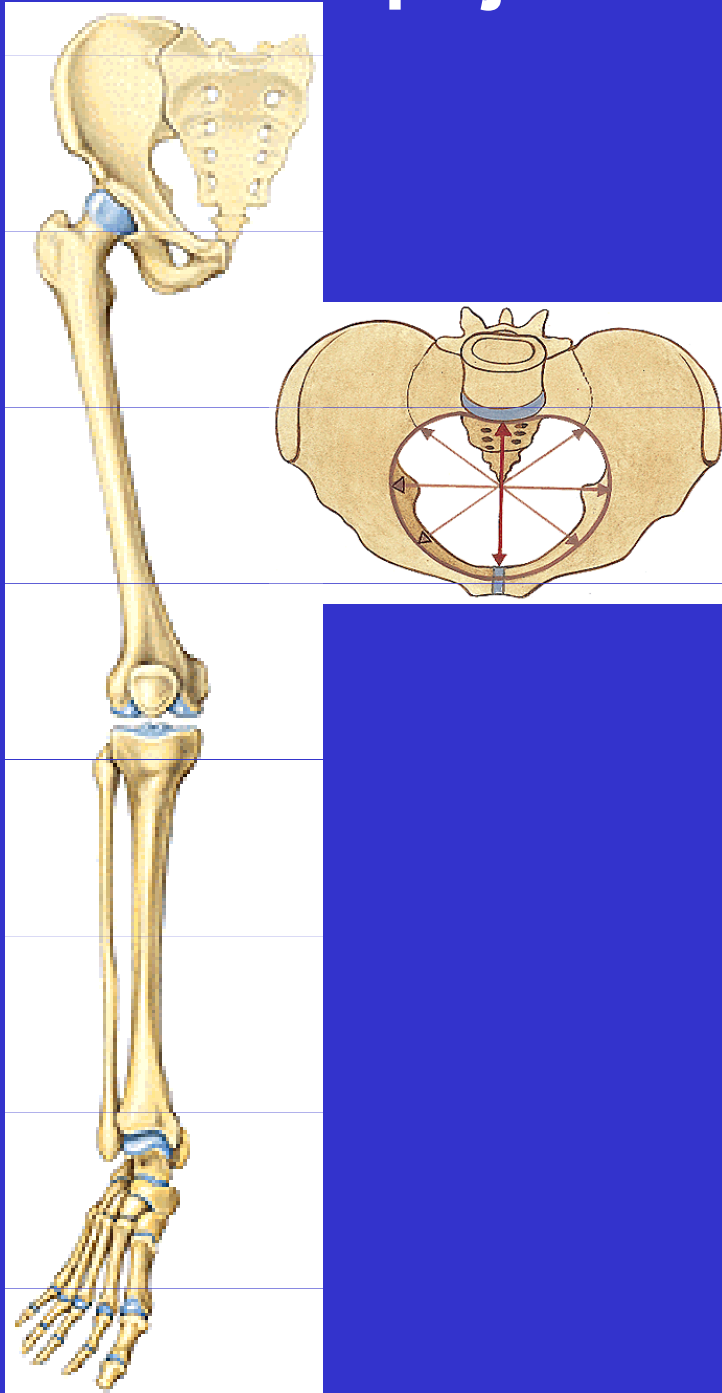


Spoje dolní končetiny

Spoje dolní končetiny - přehled



I. Spoje kostí pletence

art. sacroiliaca

symphysis pubica

membrana obturatoria

os sacrum + os coxae =
pelvis

Spoje dolní končetiny - přehled

II. Spoje kostí volné končetiny

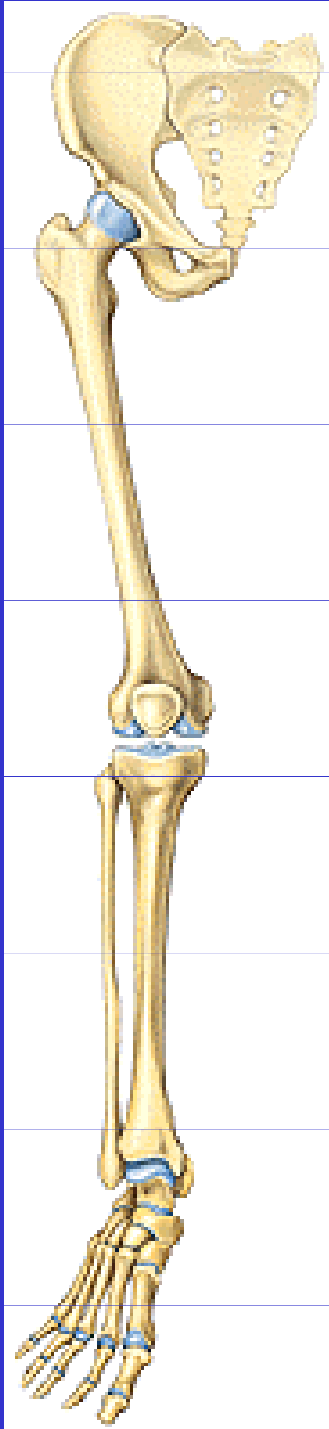
art. coxae

art. genus

art. tibiofibularis

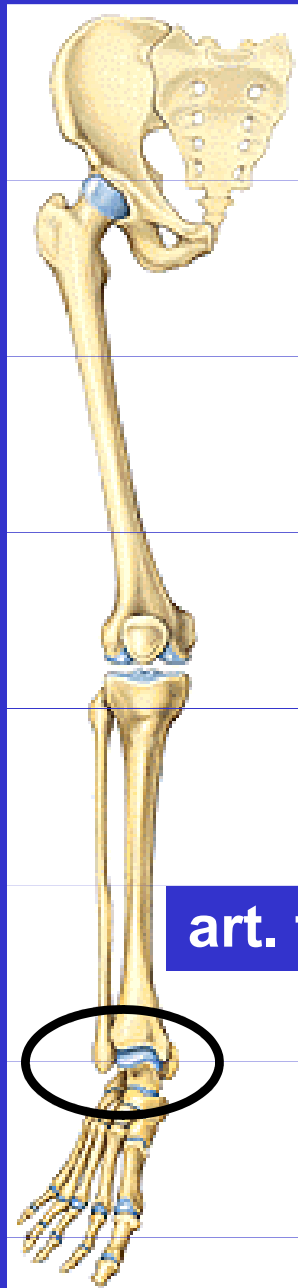
membrana interossea cruris

syndesmosis tibiofibularis

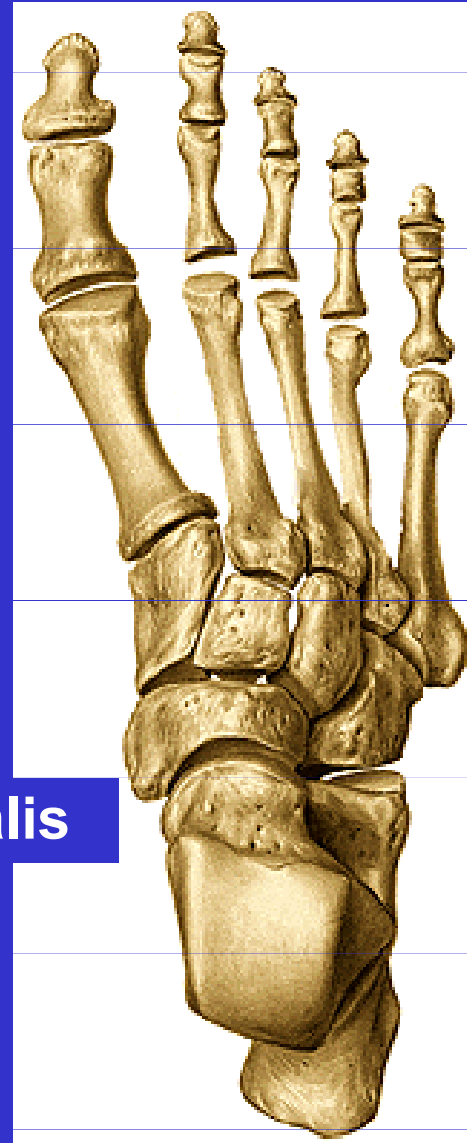


Spoje dolní končetiny - přehled

Klouby nohy



art. talocruralis



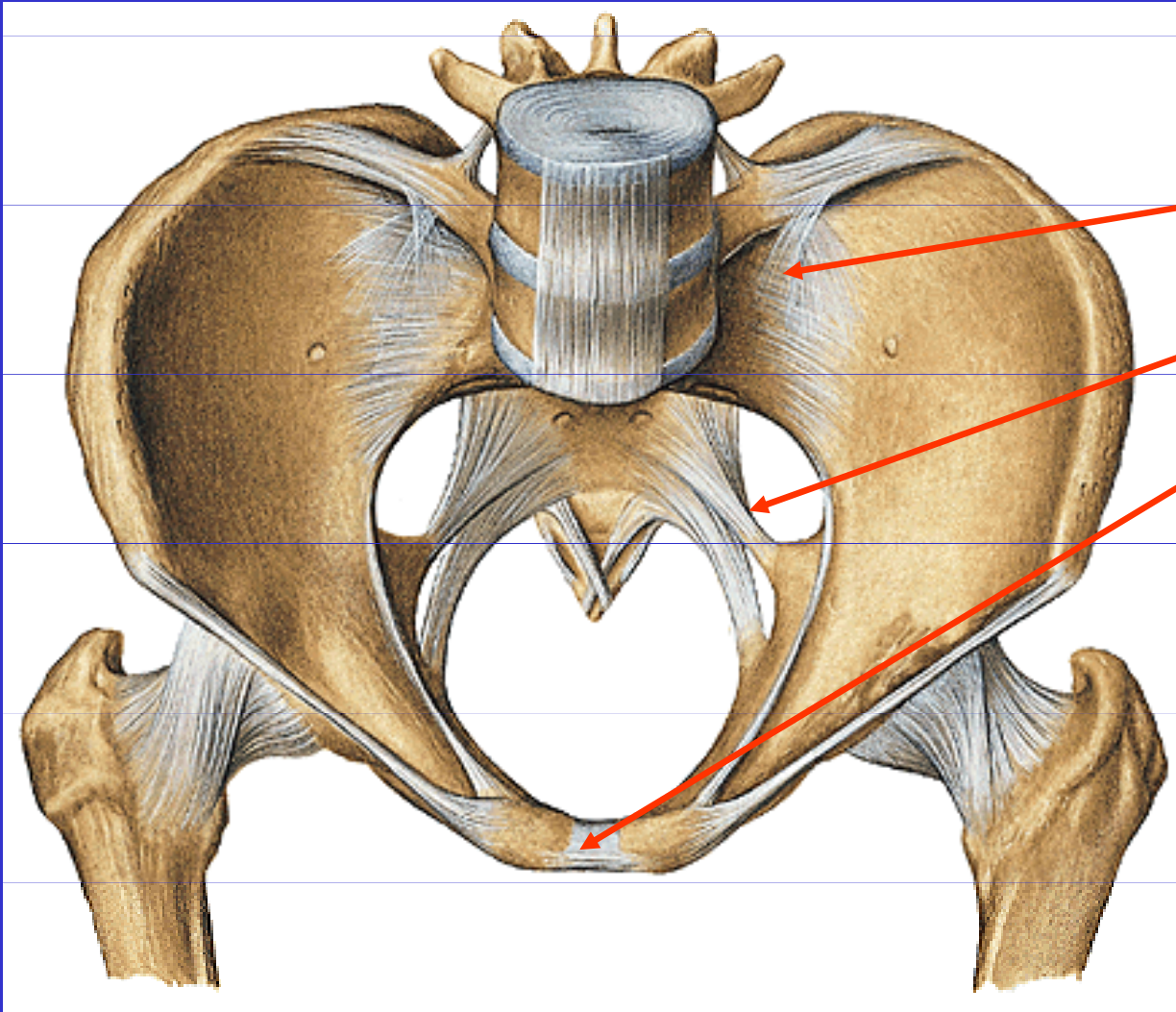
art. interphalangeae
pedis

art.
metatarsophalangeae

art. tarsometatarsae

art. intertarsae

I. Spoje kostí pletence



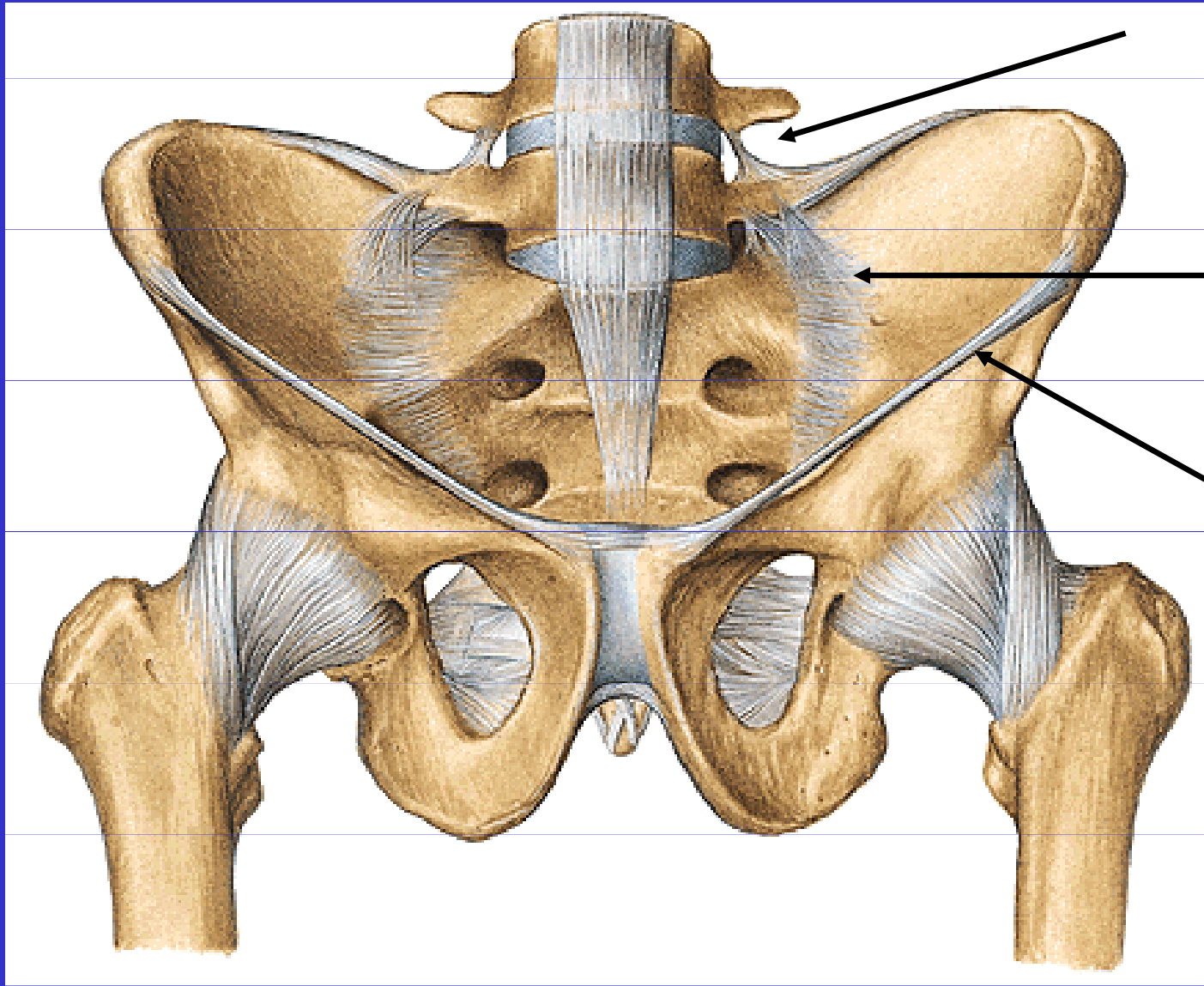
art. sacroiliaca

vazy pánve

symphysis pubica

membrana obturatoria

Articulatio sacroiliaca



Lig. iliolumbale

Lig. sacroiliaca
ventralia

Lig. inguinale

Amfiartróza

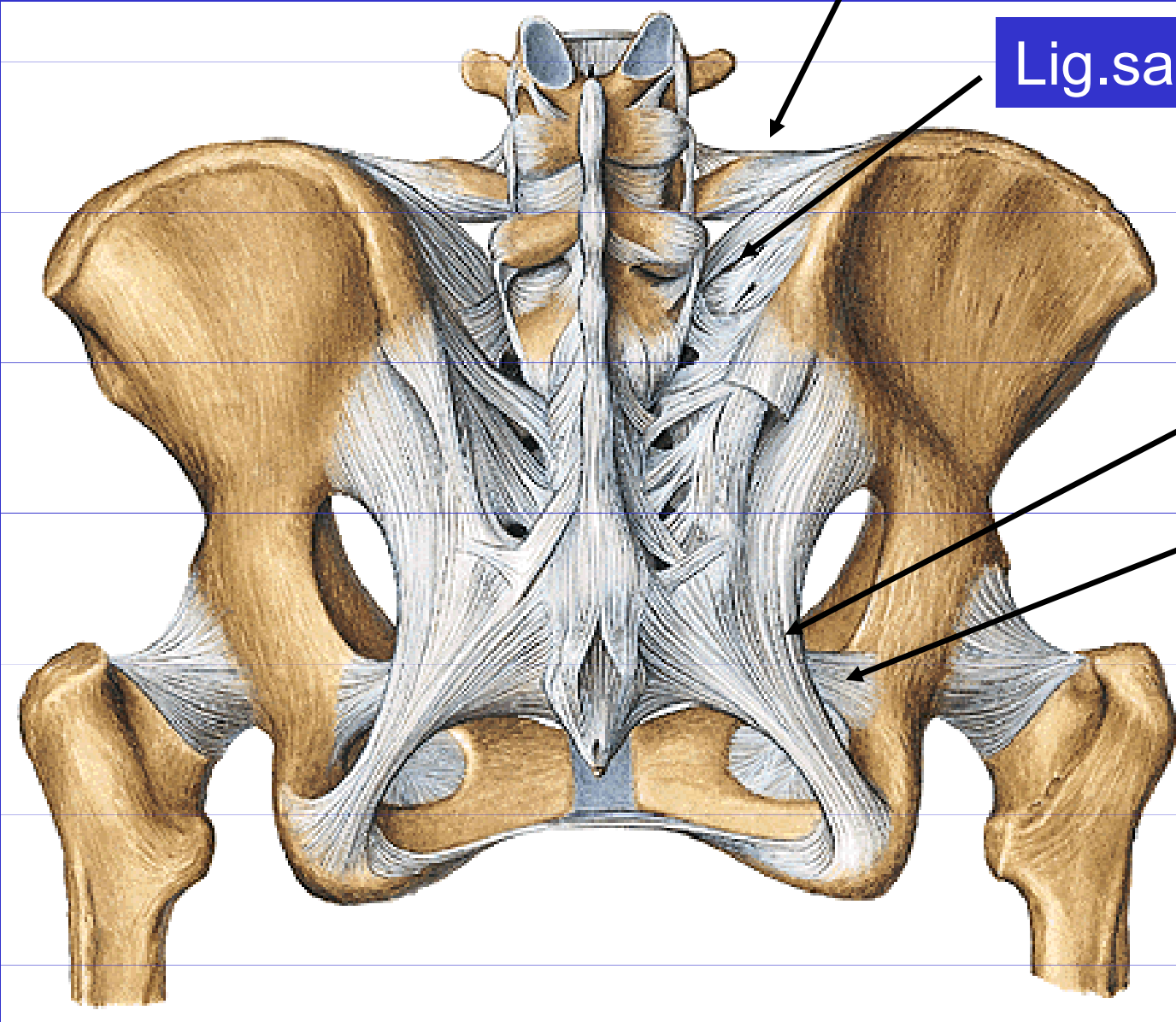
Articulatio sacroiliaca

Lig. iliolumbale

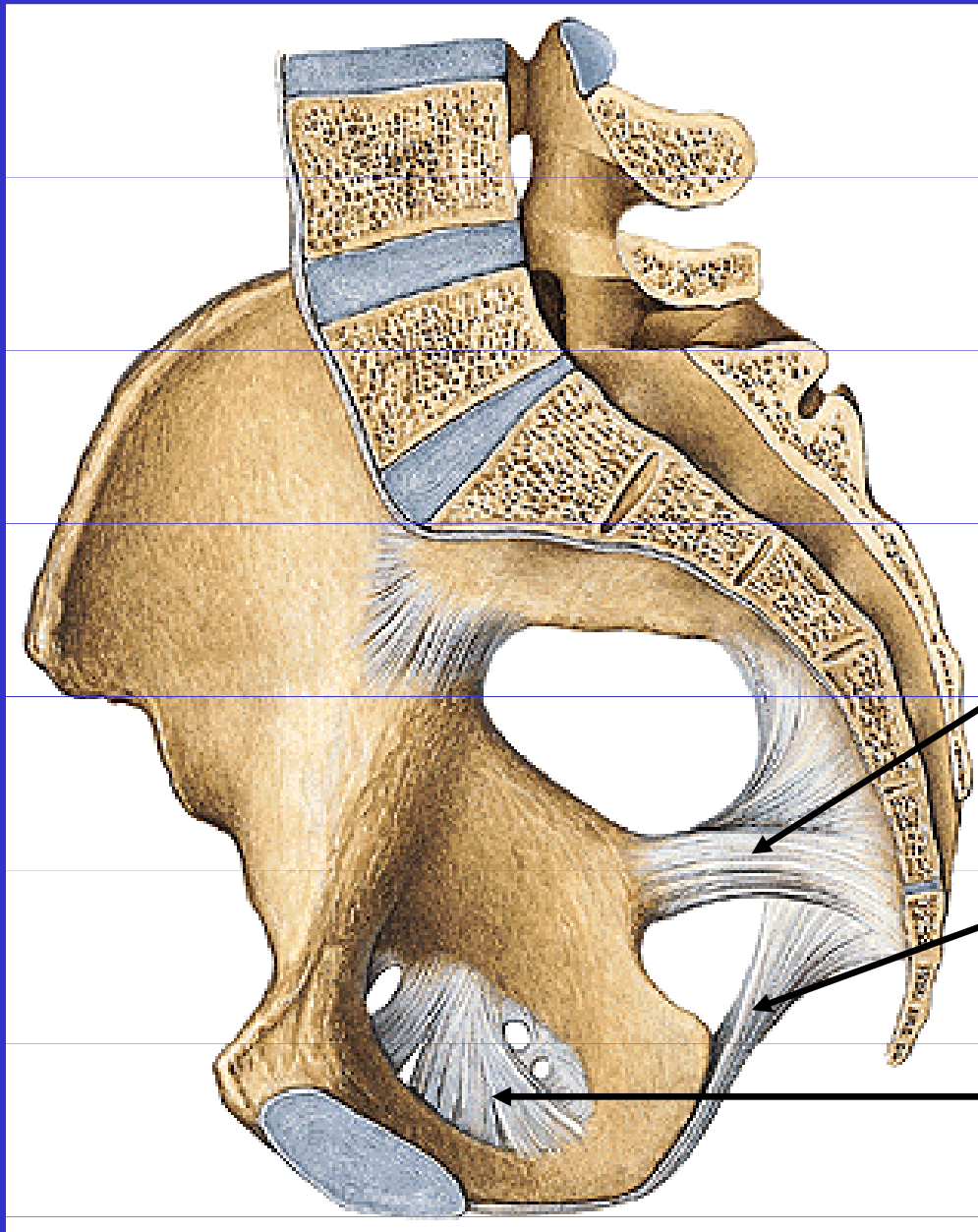
Lig. sacroiliaca dorsalia

Lig. sacrotuberale

Lig. sacrospinale



Vazy pánve



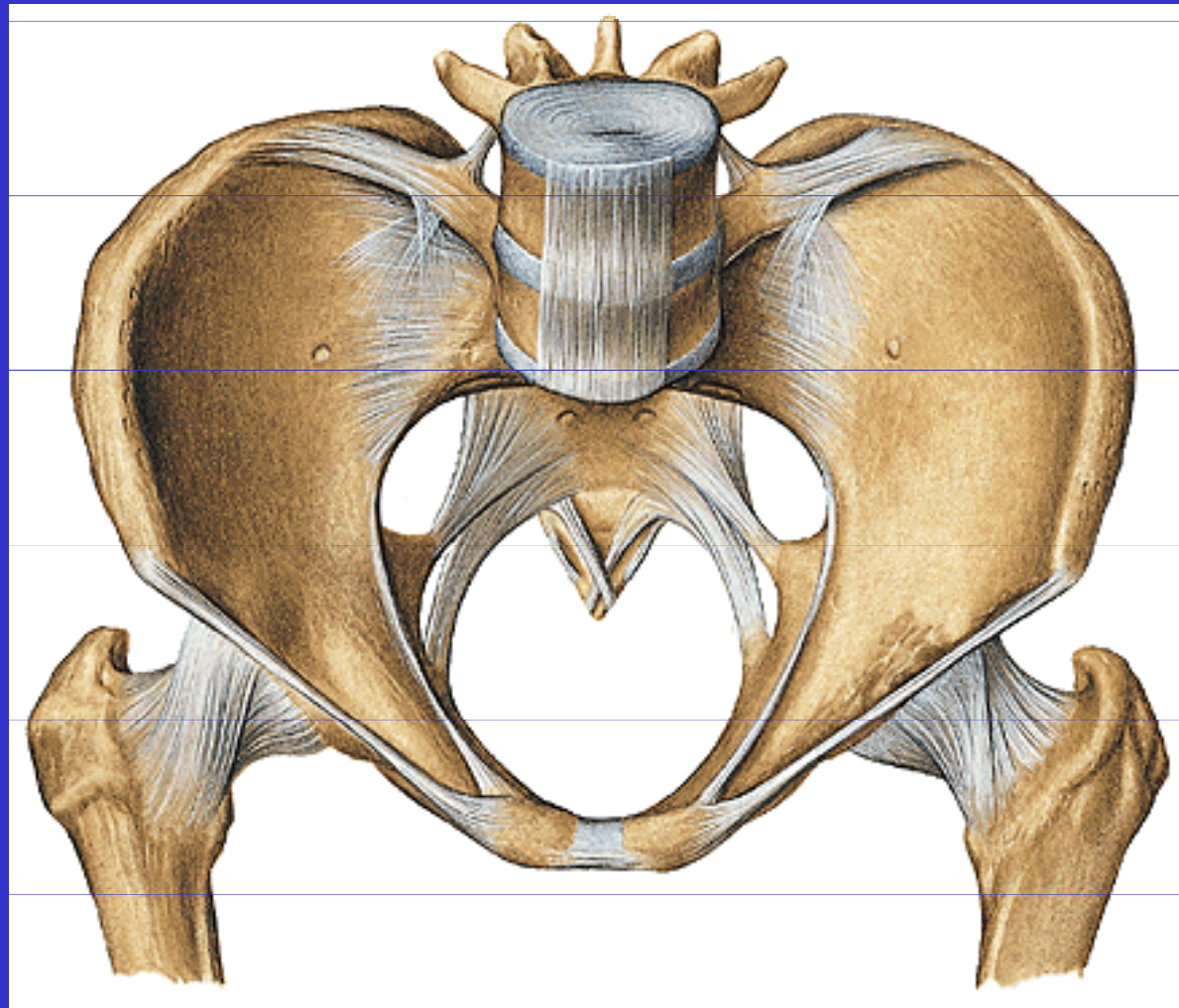
Lig.sacrospinale

Lig.sacrotuberale

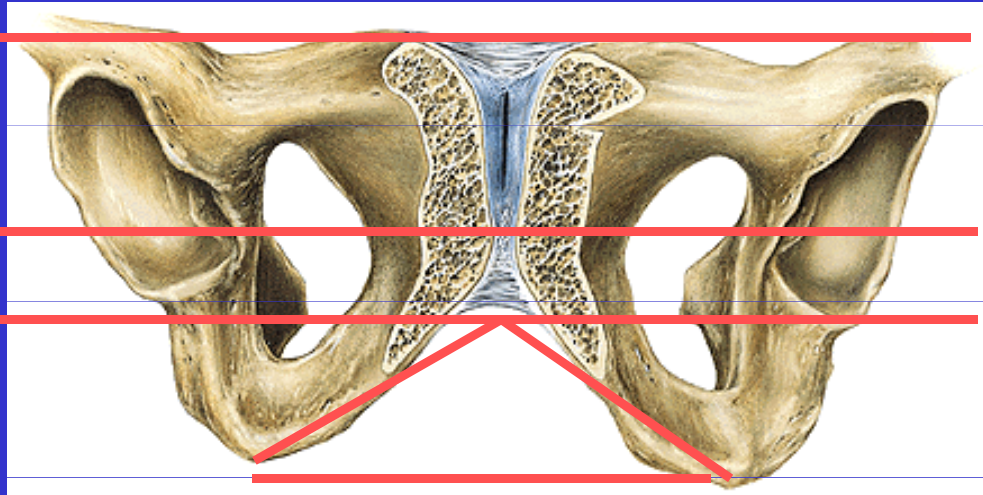
Membrana obturatoria

Pánev – pelvis

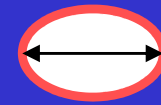
pelvis major et minor



Roviny pánevní




vchodu



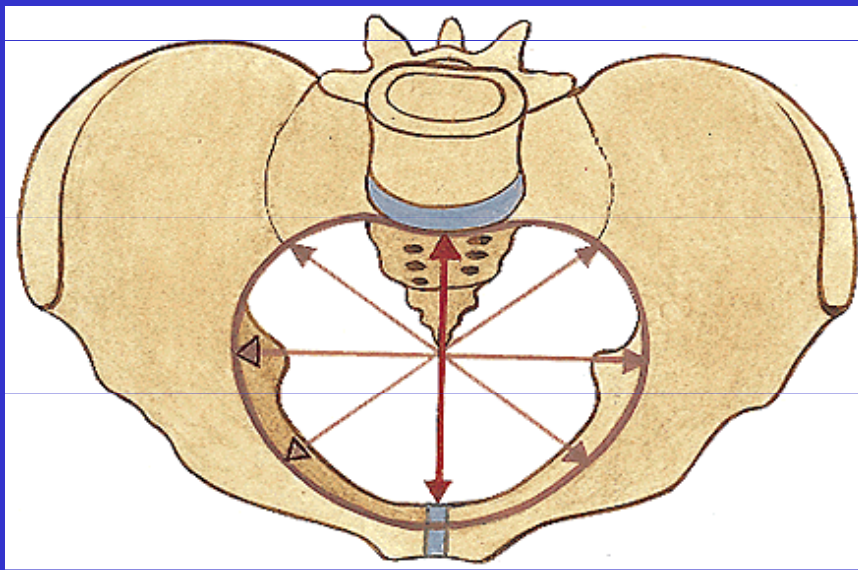
šíře



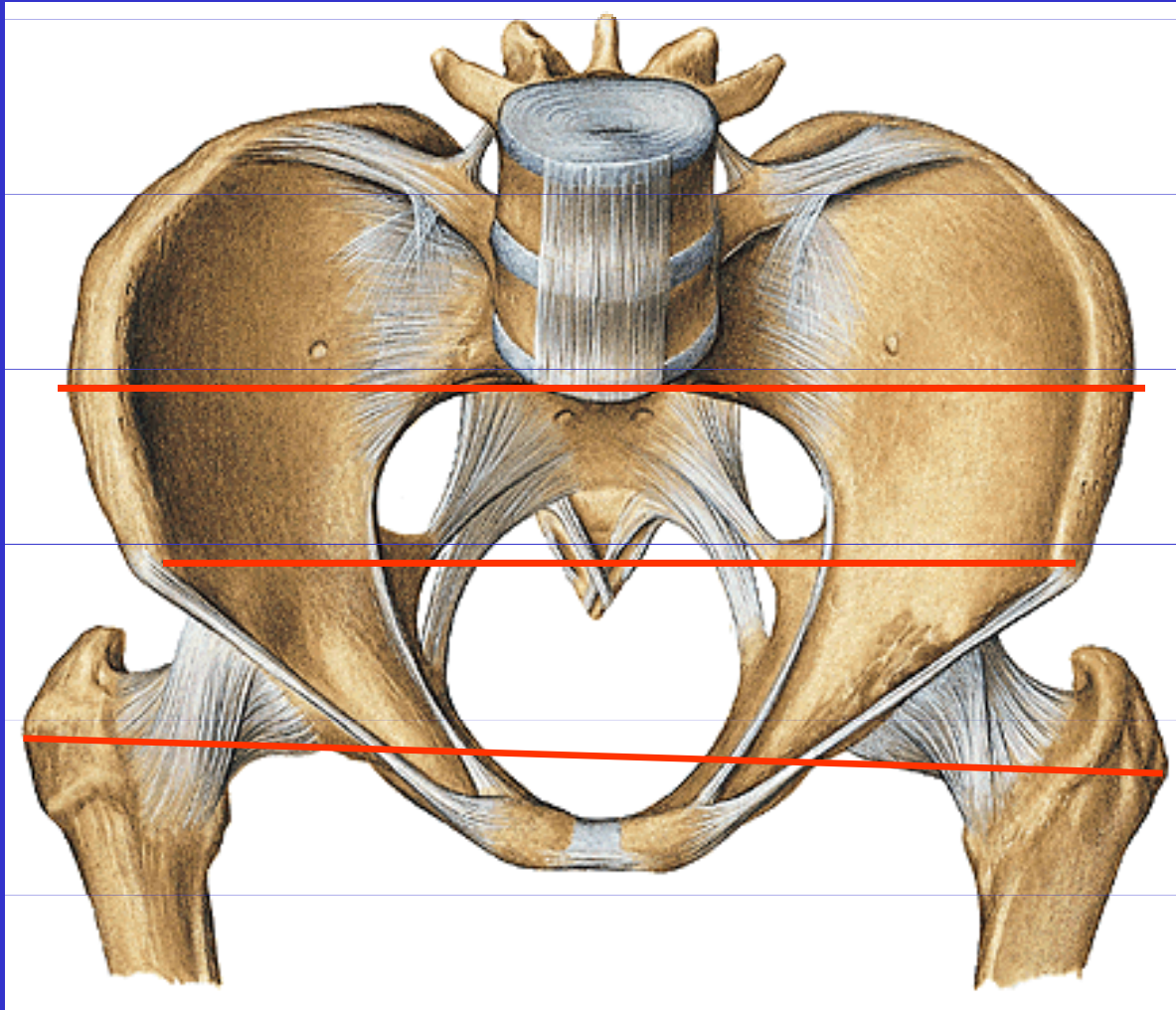
úžiny



východu



Zevní rozměry pánevní



distantia bispinalis

24 – 26 cm

distantia bicristalis

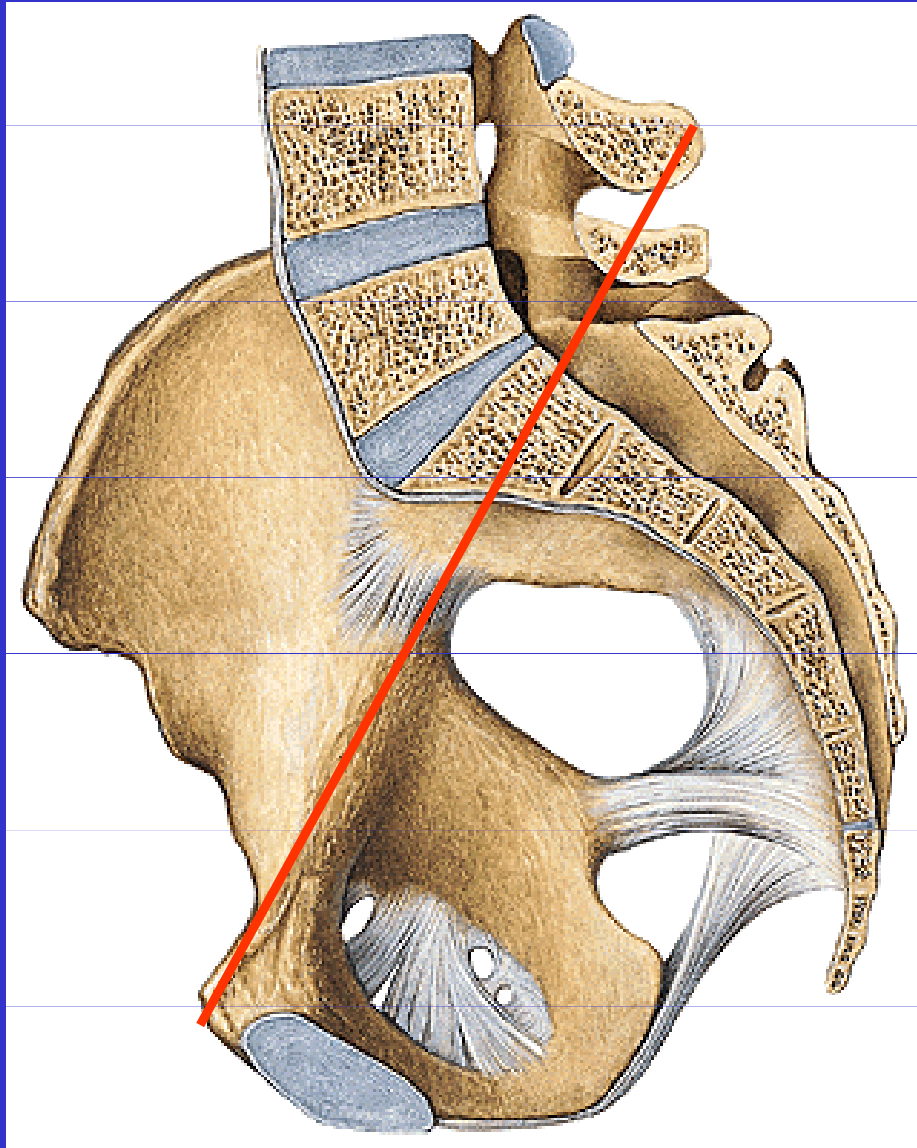
26 – 30 cm

distantia
bitrochanterica

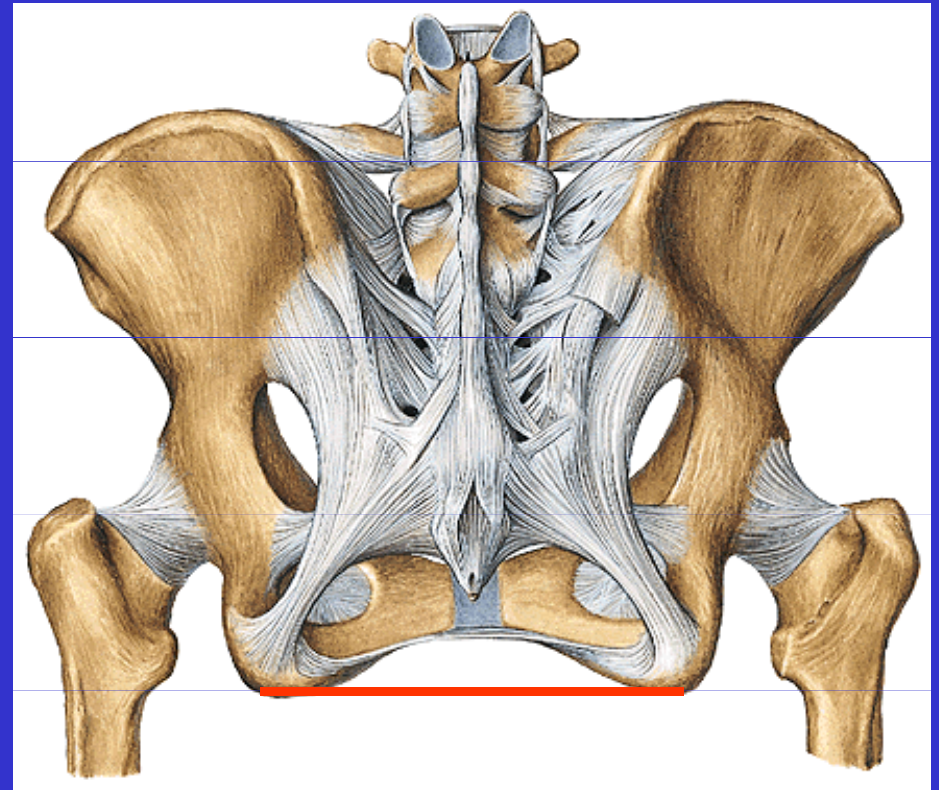
30 – 32cm

(distantia bituberalis)

Zevní rozměry pánevní



Conjugata externa (18 -20 cm)



Distantia bituberalis (8 – 10cm)

Pohlavní rozdíly na pánvi

Postavení lopat
kyčelní kosti

Výška symfýzy, úhel
pod symfýzou

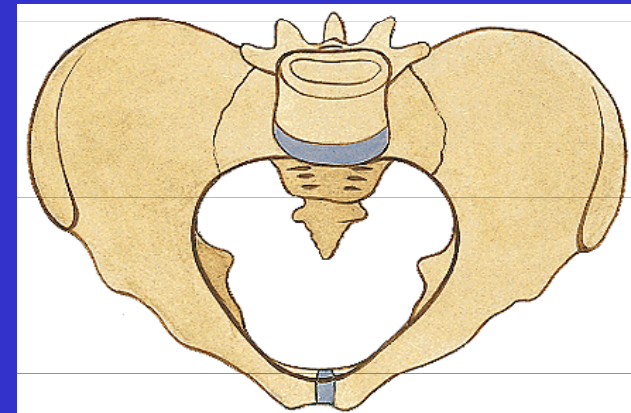
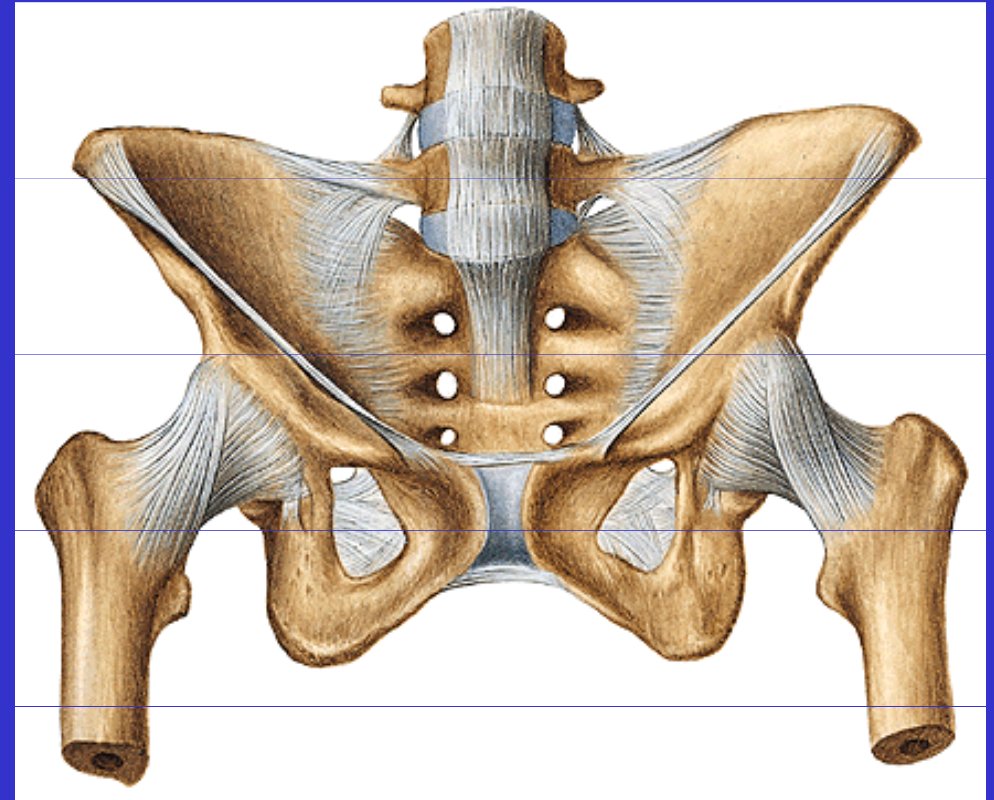
Promontorium

Vzdálenost tubera
ischiadica

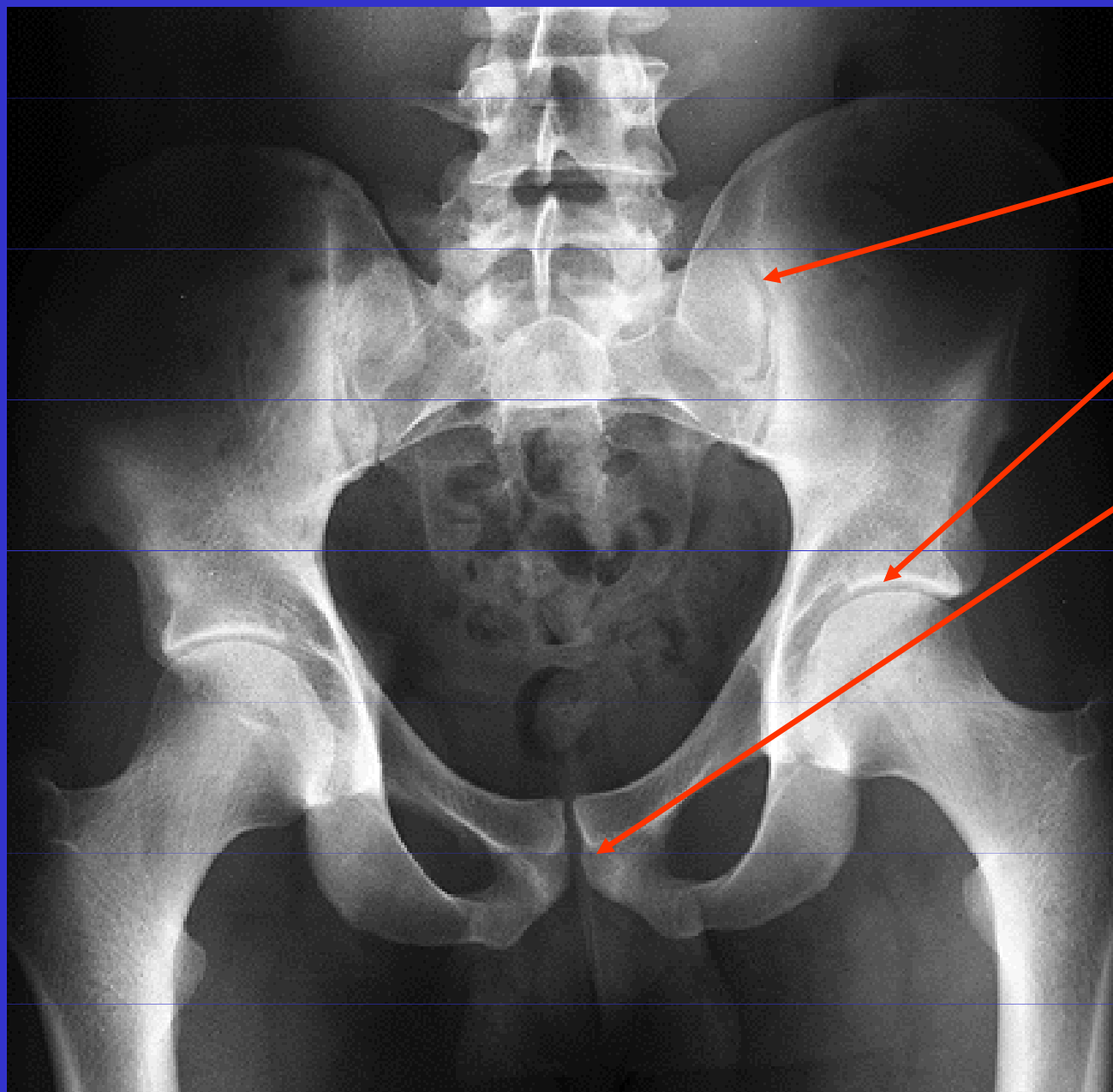
Tvar roviny vchodu

Délka ramus ossis
pubis

Tvar foramen
obturatum



Rtg pánve



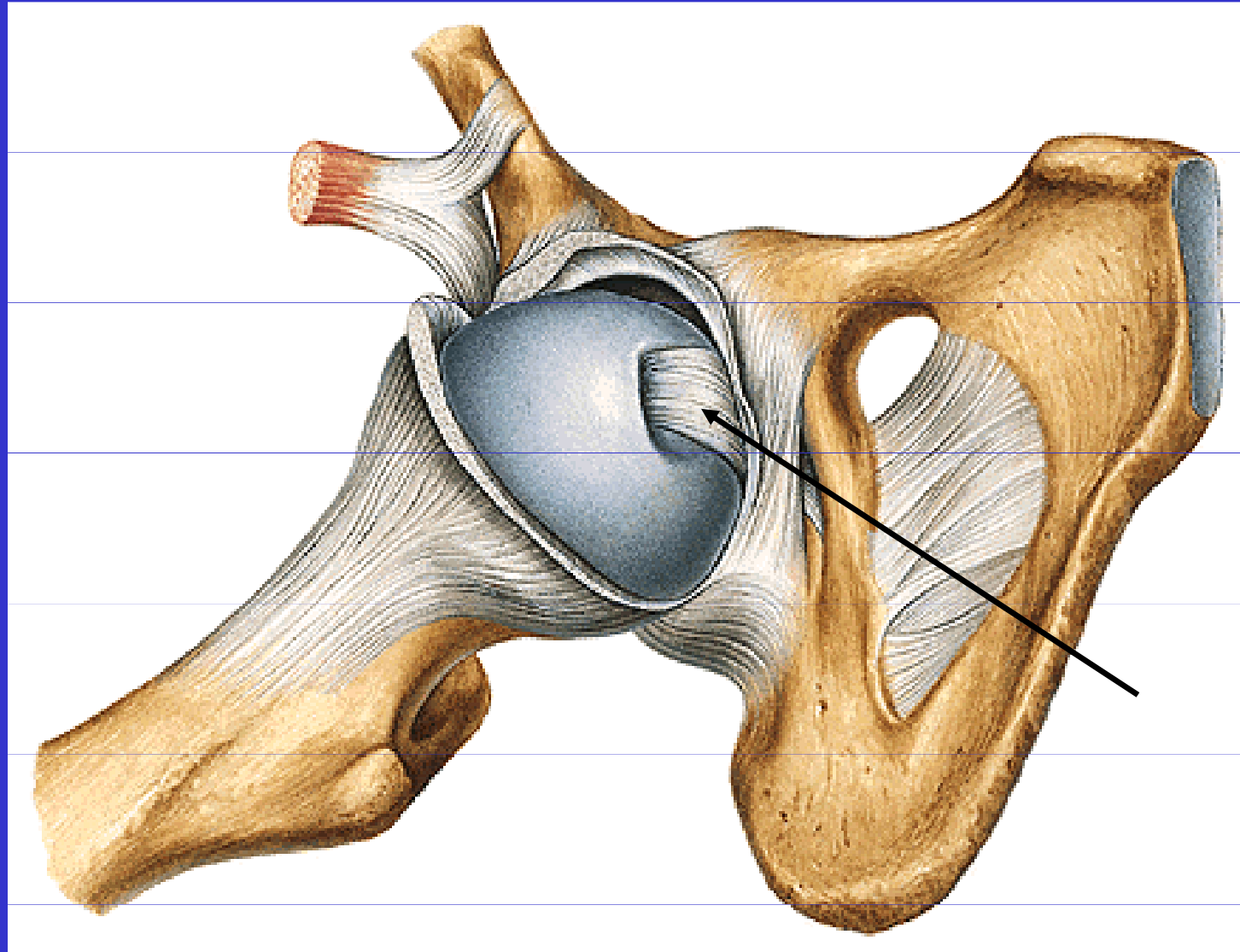
Art.sacroiliaca

Art.coxae

Symfýza

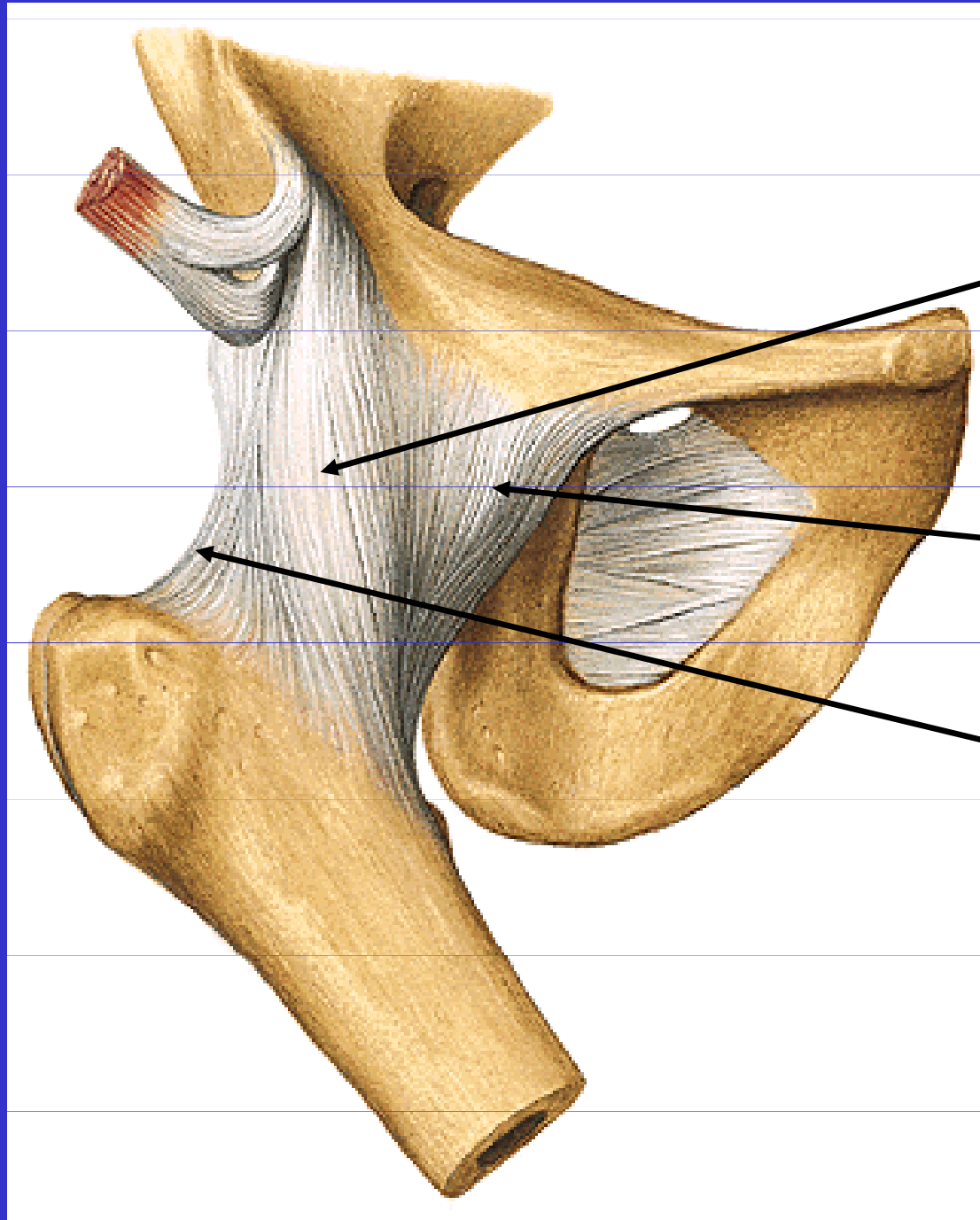
II. Spoje kostí volné končetiny

Art. coxae



Lig. capitis
femoris

Art.coxae

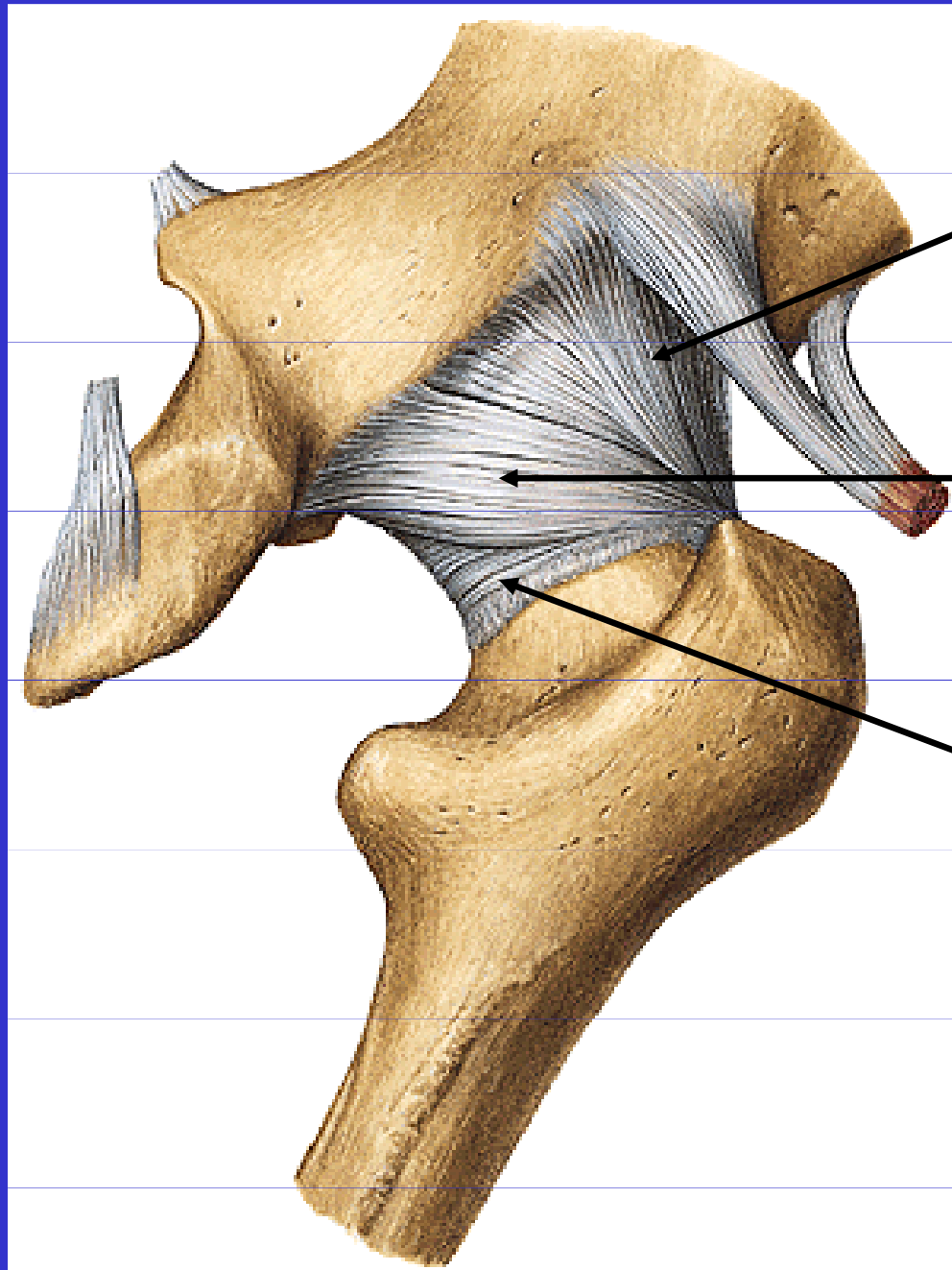


Lig. iliofemorale

Lig. pubofemorale

Lig. ischiofemorale

Art.coxae



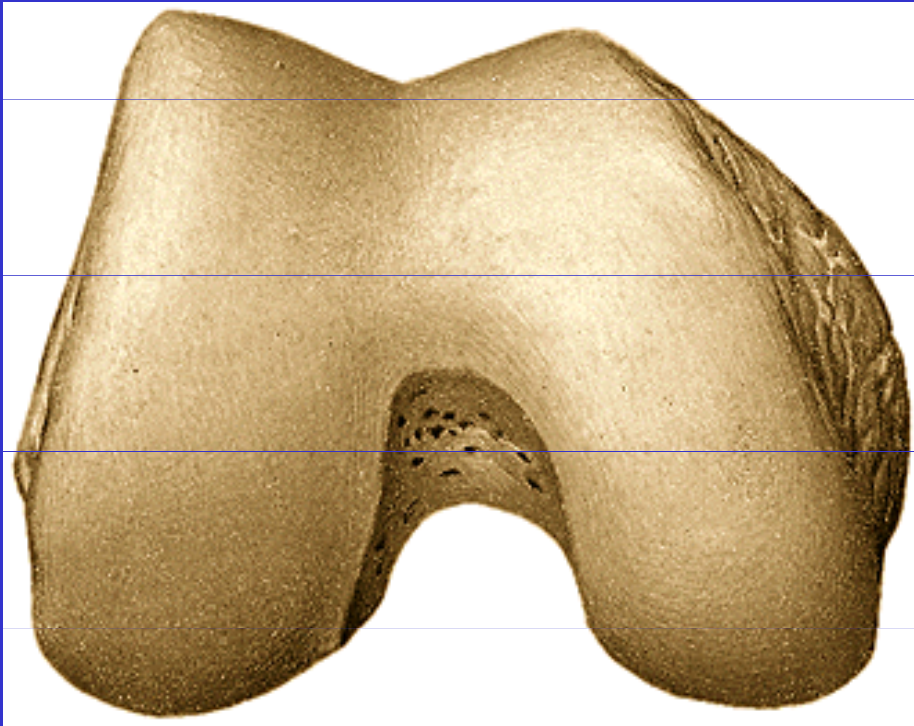
Lig.iliofemorale

Lig.ischiofemorale

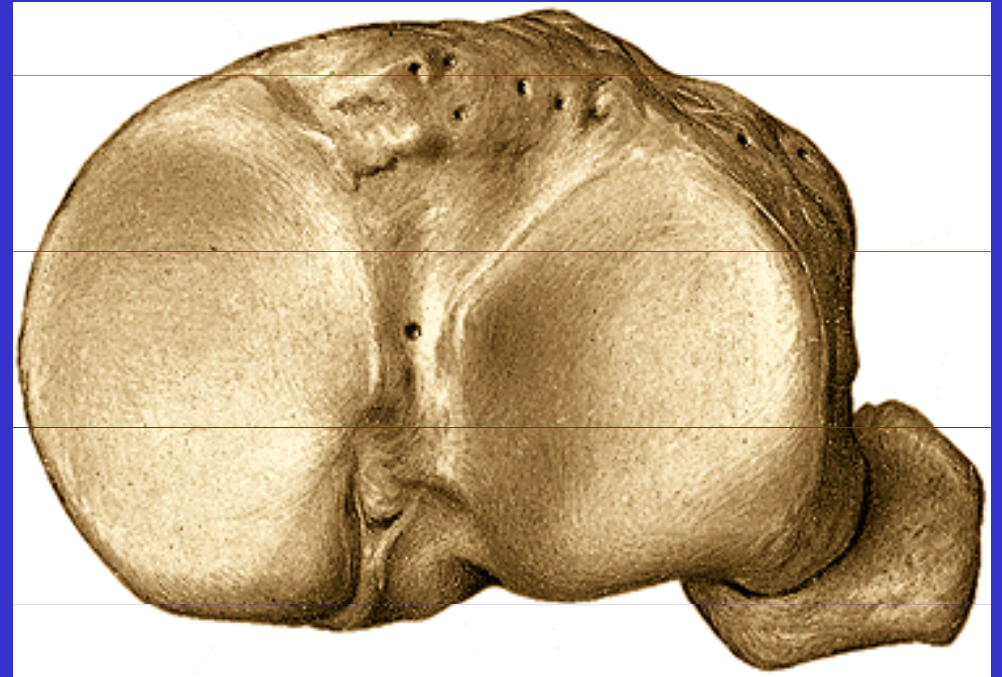
Zona orbicularis

II. Spoje kostí volné končetiny

Art.genus

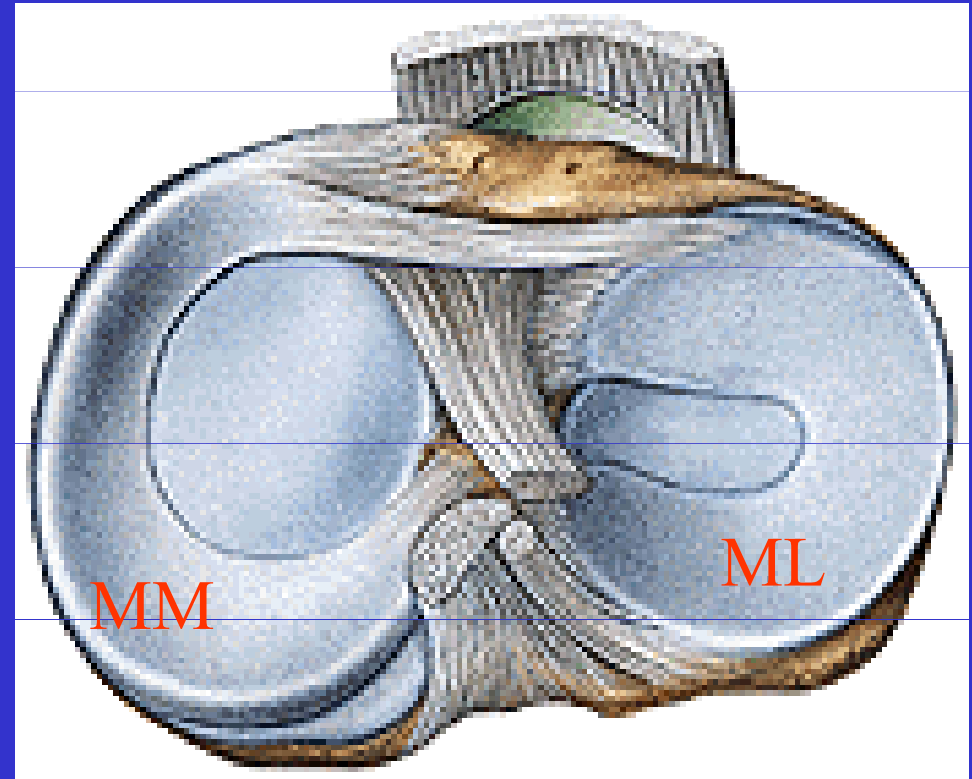
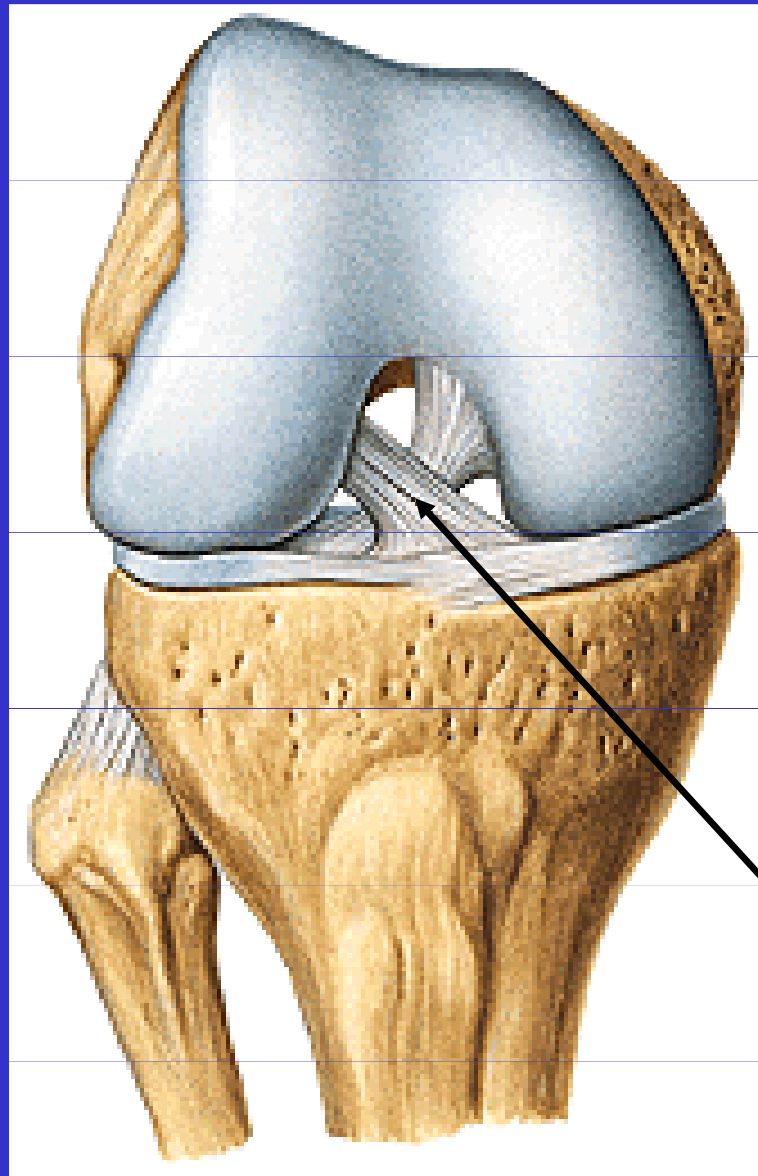


Kondyly femuru



Kondyly tibie

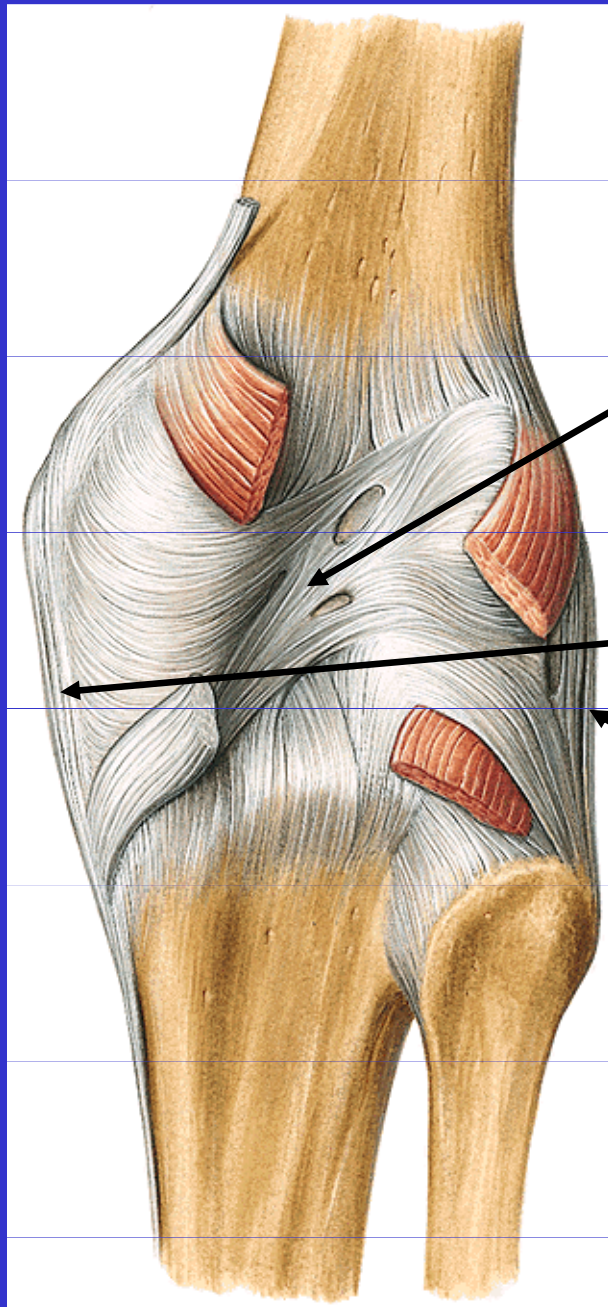
Art.genus



Menisky

Zkřížené vazy
kolenního kloubu

Art.genus

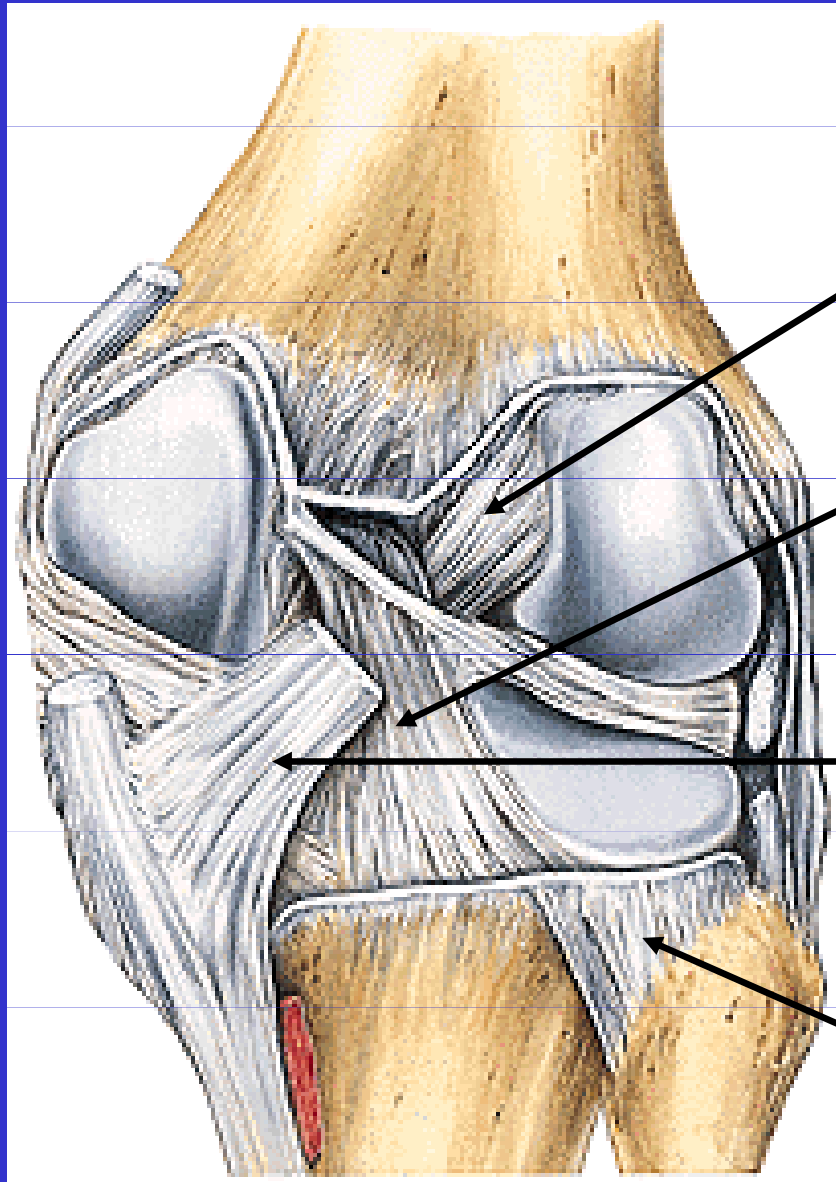


Ligamentum
popliteum obliquum

Ligamentum
collaterale mediale

Ligamentum
collaterale laterale

Art.genus



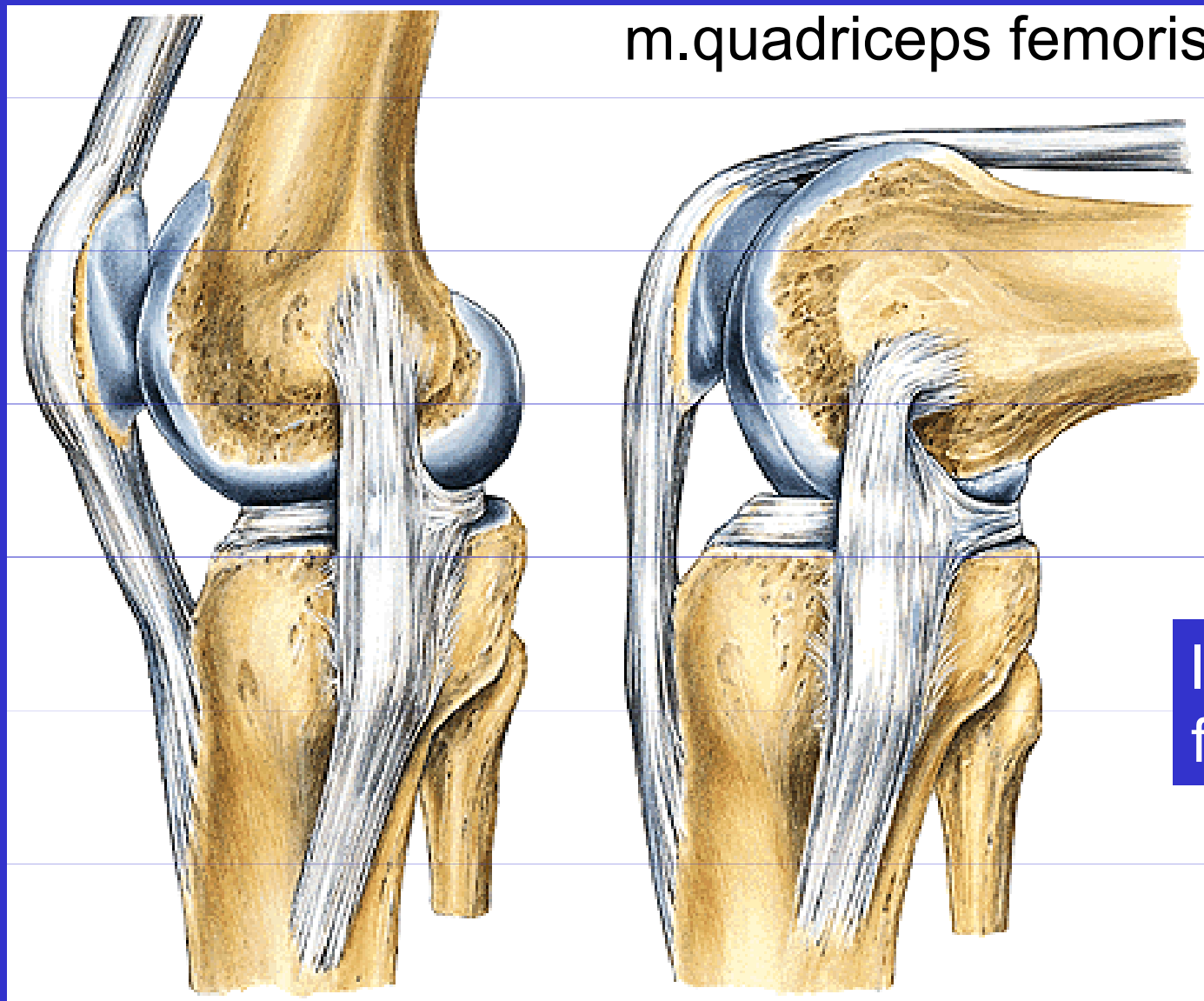
Lig. cruciatum ant.

Lig. cruciatum post.

Lig. popliteum obliquum

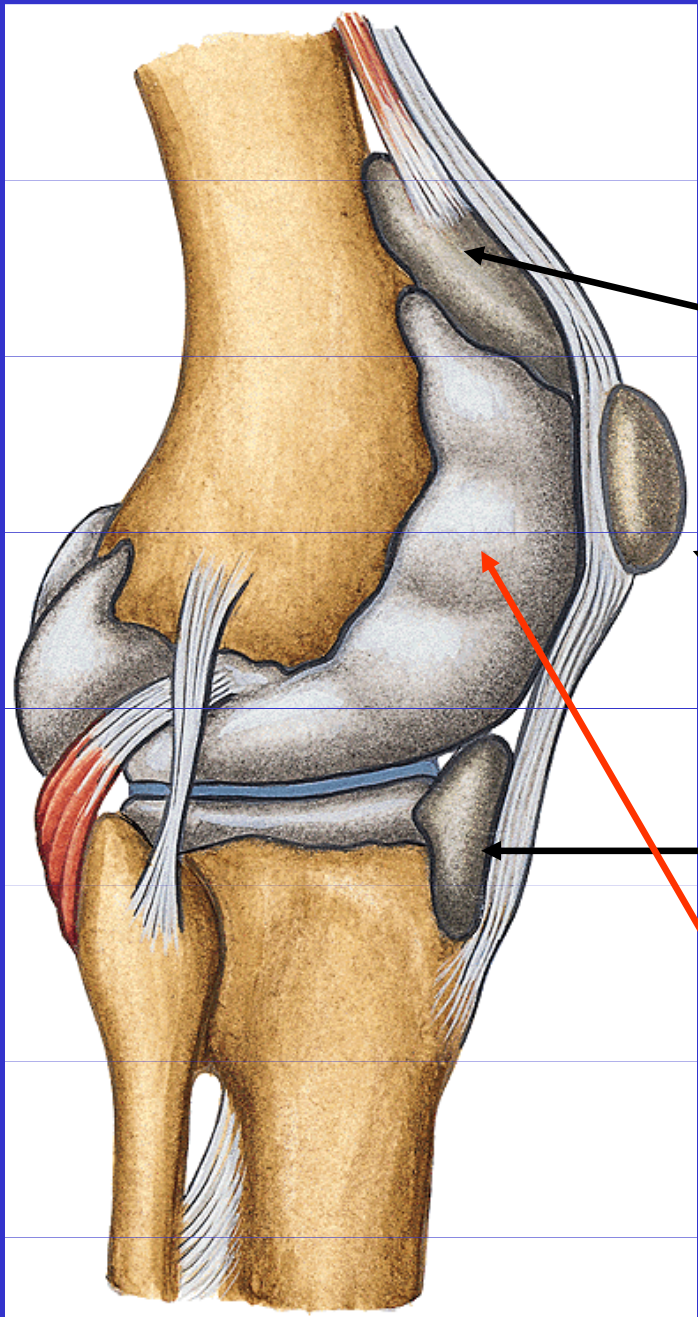
Lig. capitis fibulae post.

Art.genus



Postavení kloubních ploch při pohybu v kolenním kloubu

Bursy v kolenním kloubu



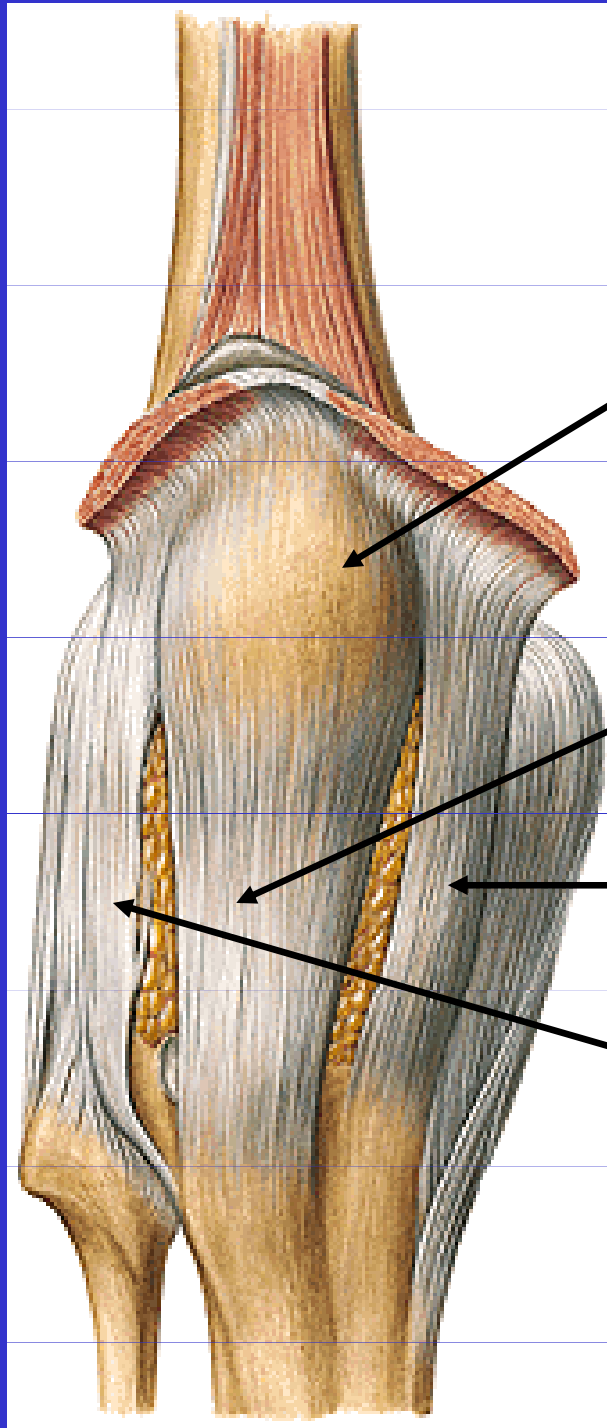
Bursa subpatellaris

Bursa praepatellaris

Bursa infrapatellaris

Cavitas articularis

Vazy kolenního kloubu



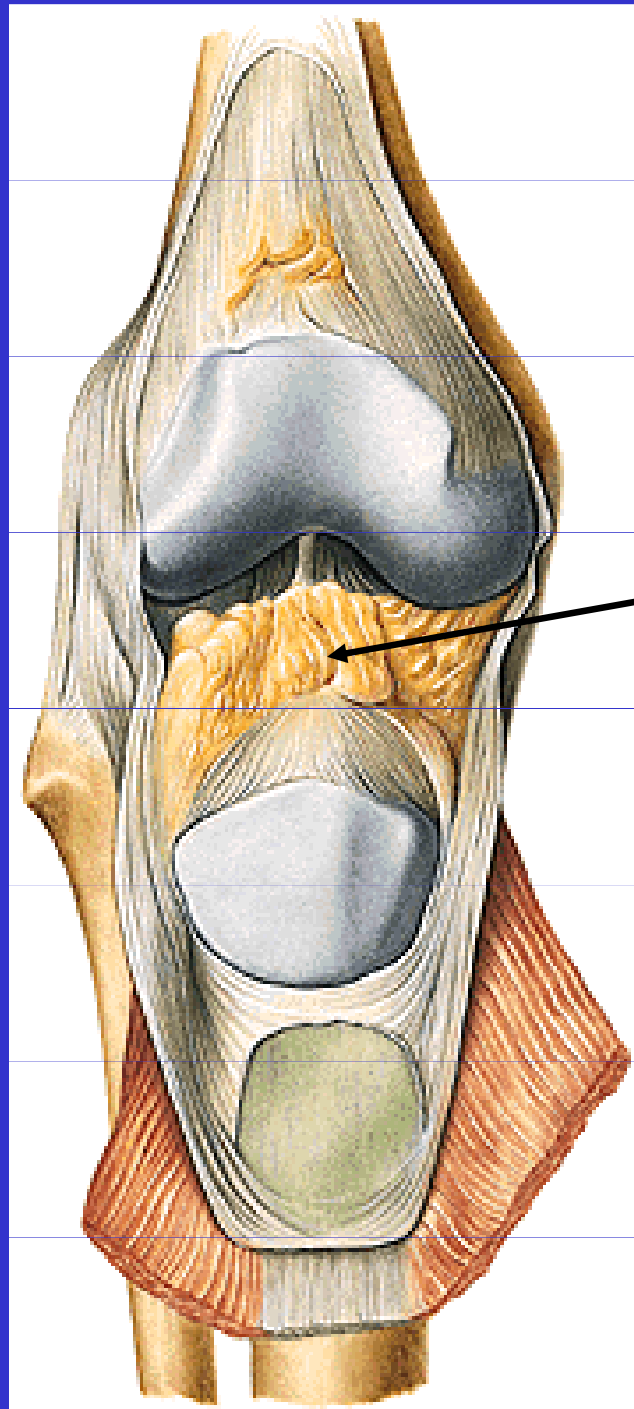
patella

Ligamentum
patellae

Retinaculum
patellae mediale

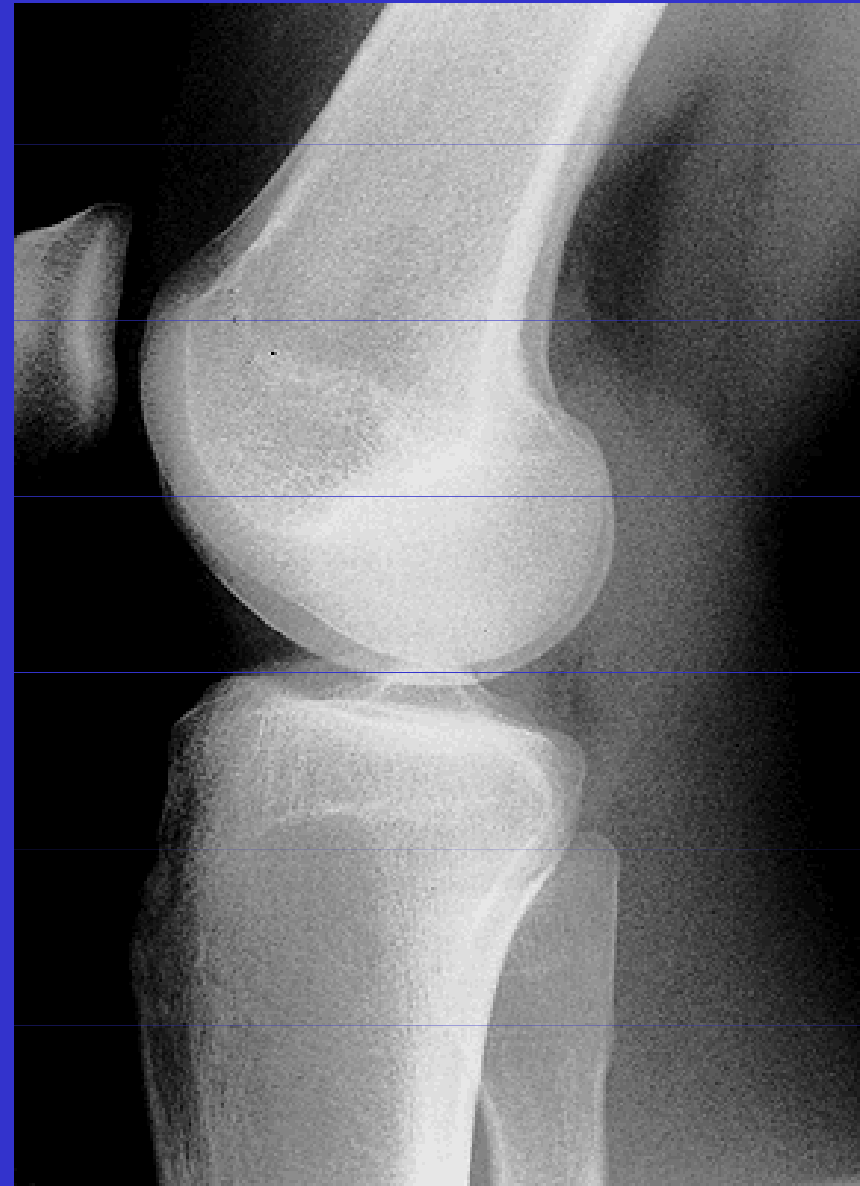
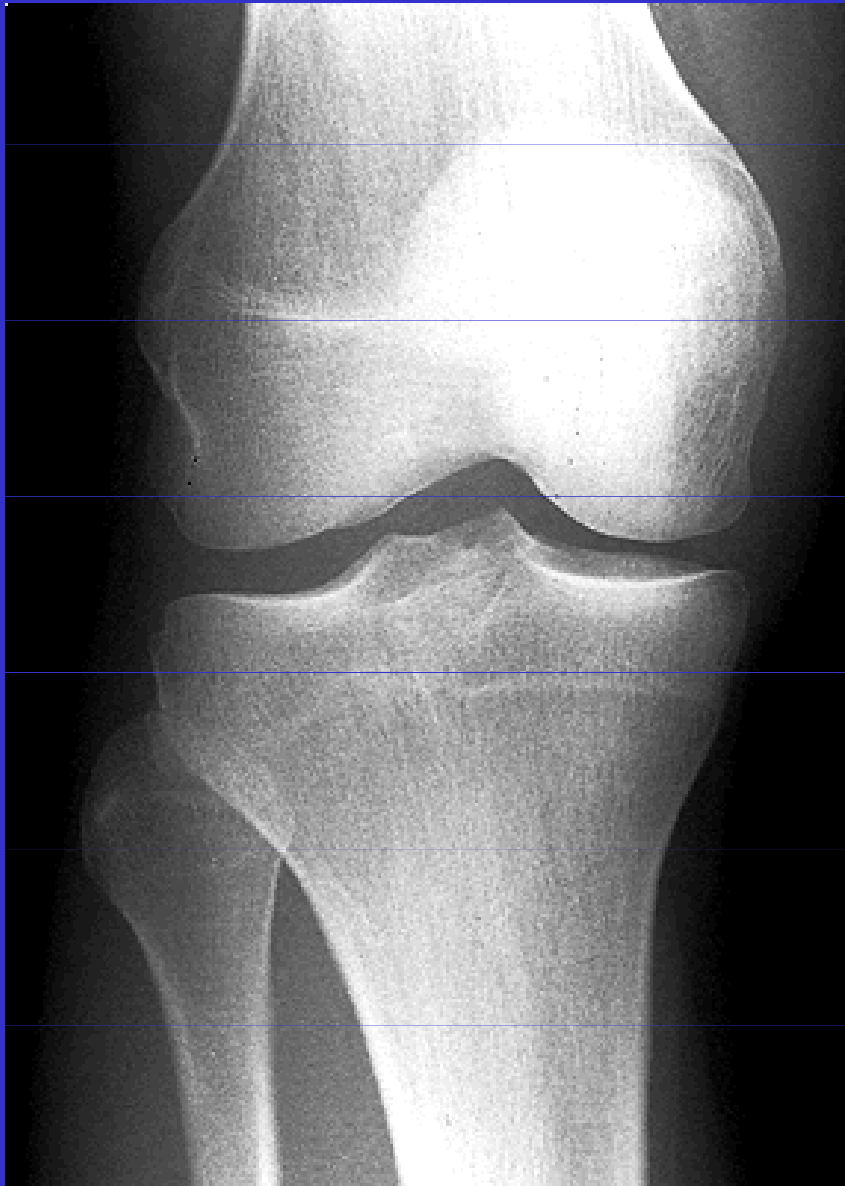Retinaculum
patellae laterale

Synoviální řasy v kolenním kloubu

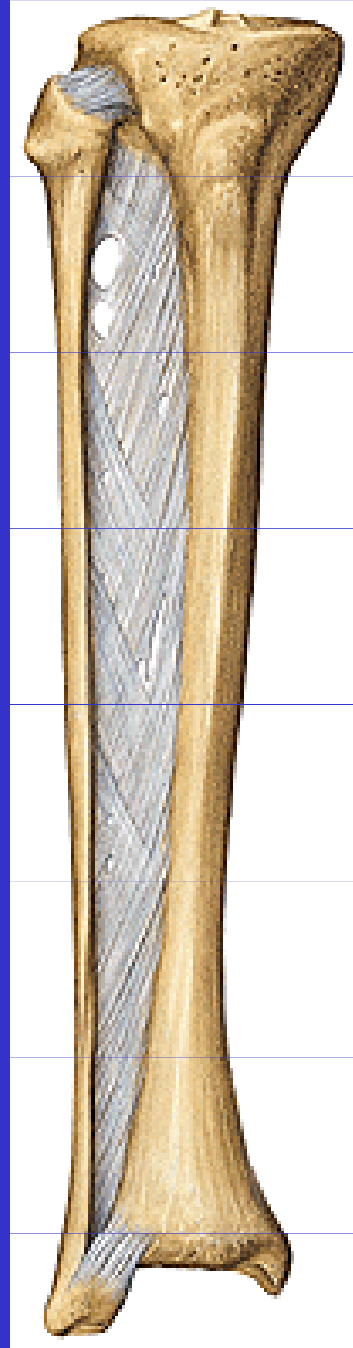


Plicae alares

Rtg kolenního kloubu



II. Spoje kostí volné končetiny



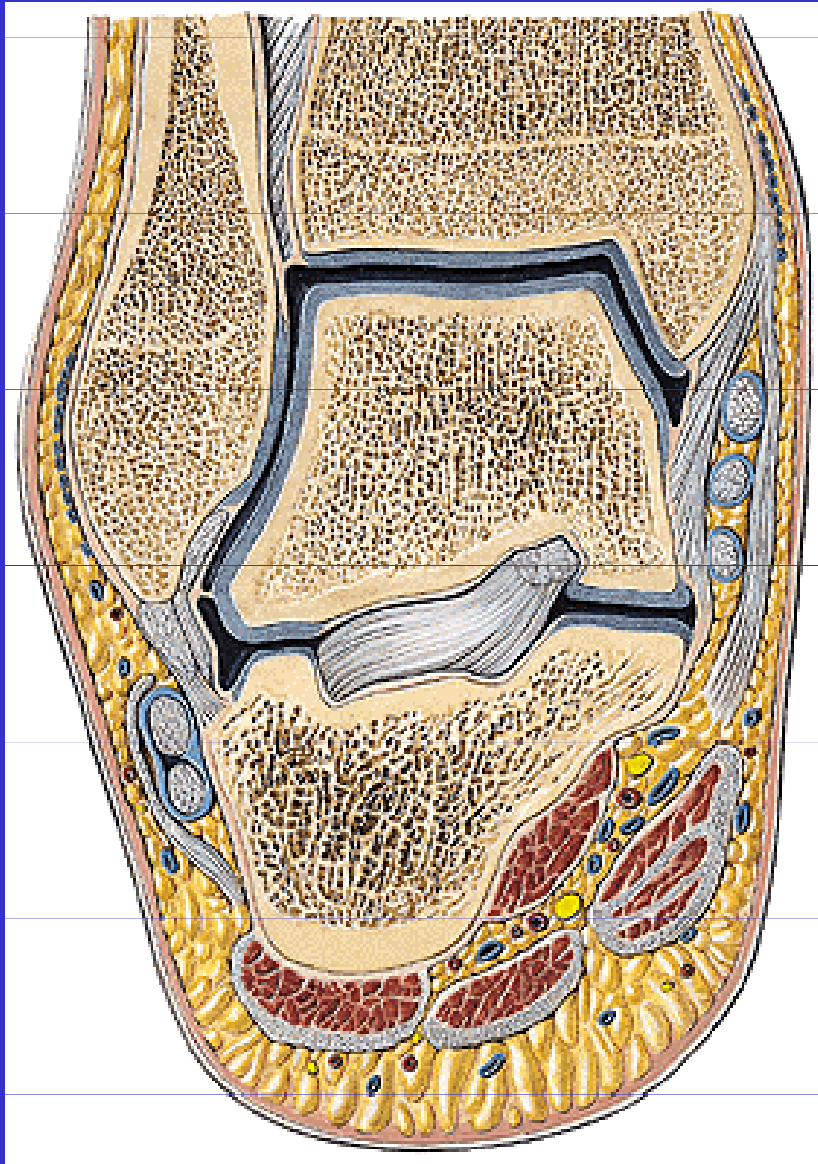
Juncturae tibiofibulares

Art.tibiofibularis

membrana interossea cruris

syndesmosis tibiofibularis

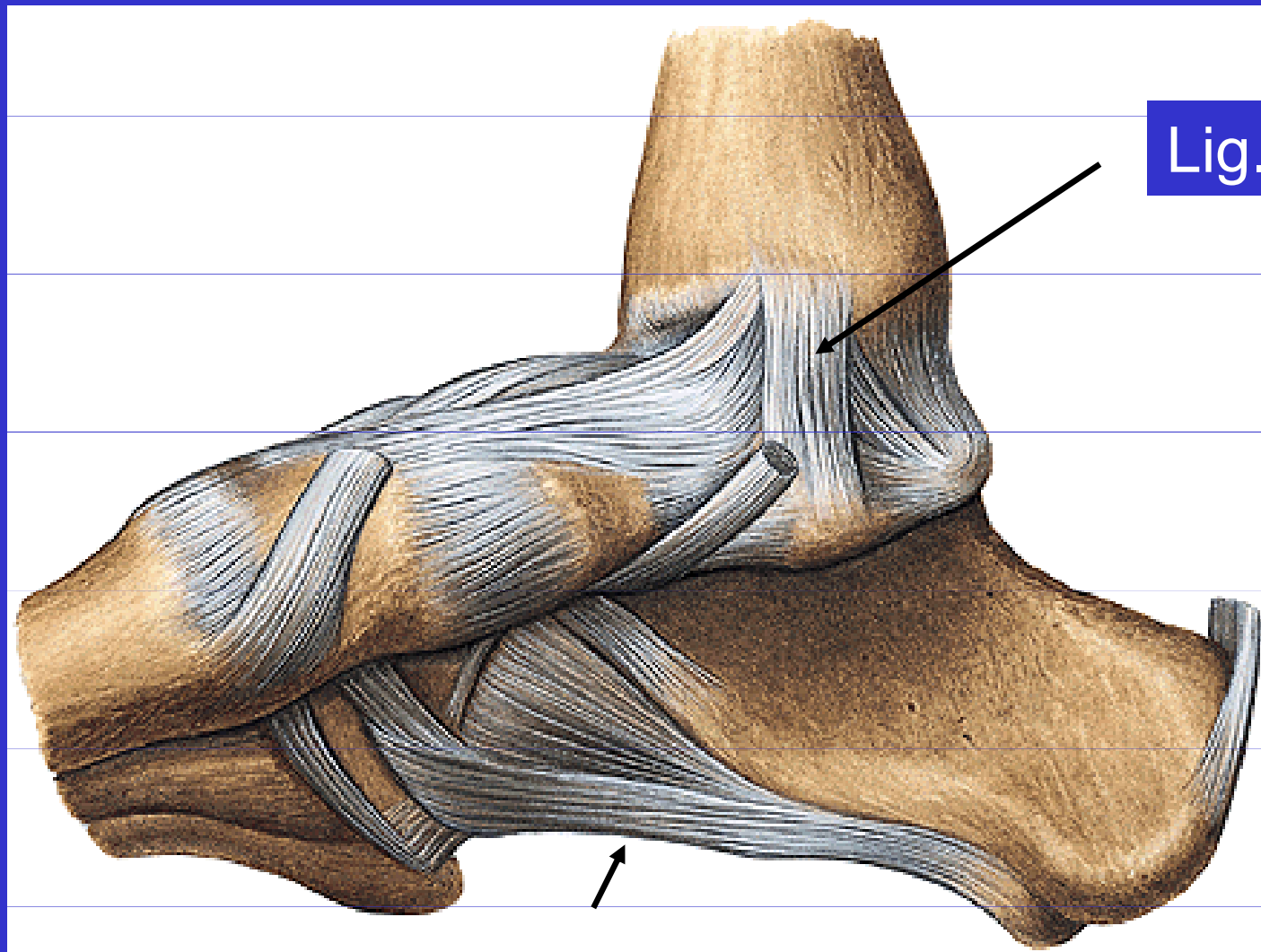
II. Spoje kostí volné končetiny



Klouby nohy

art. talocruralis (*horní nártní kloub*)

Klouby nohy

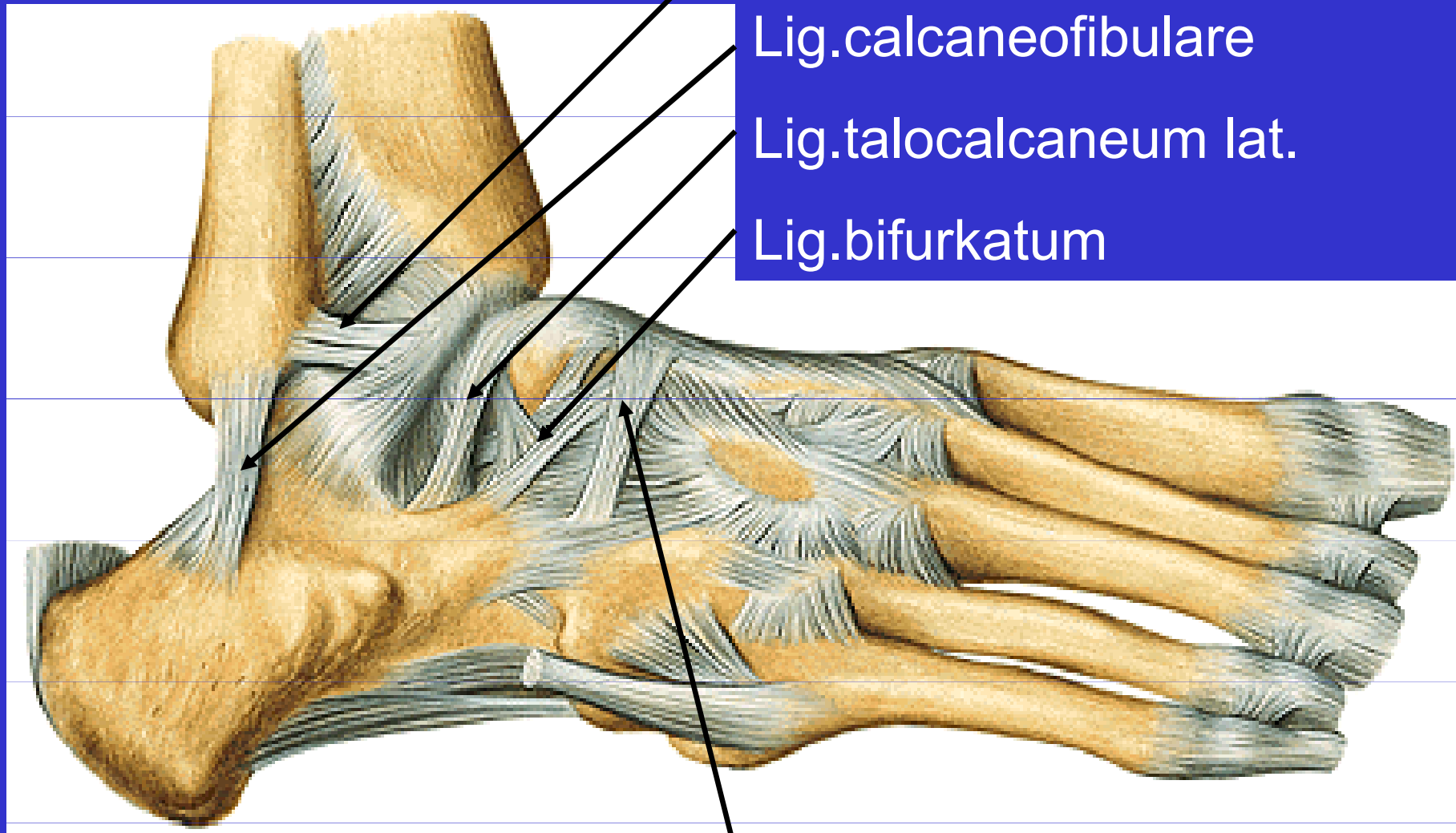


Lig.deltoideum

Tendo calcaneus

Lig.plantare longum

Klouby nohy



Lig.talofibulare ant.

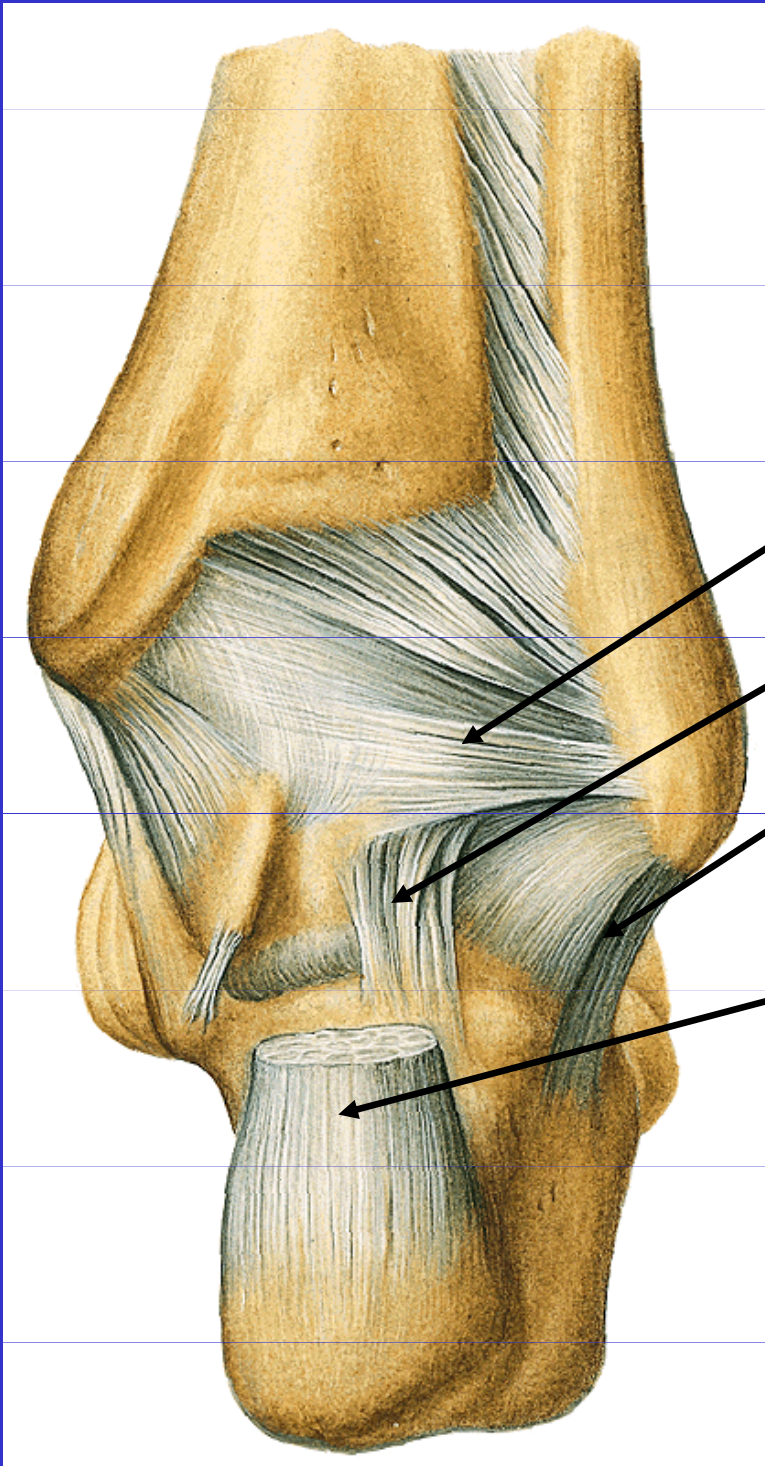
Lig.calcaneofibulare

Lig.talocalcaneum lat.

Lig.bifurkatum

Lig.cuboideonaviculare dorsale

Vazy nohy



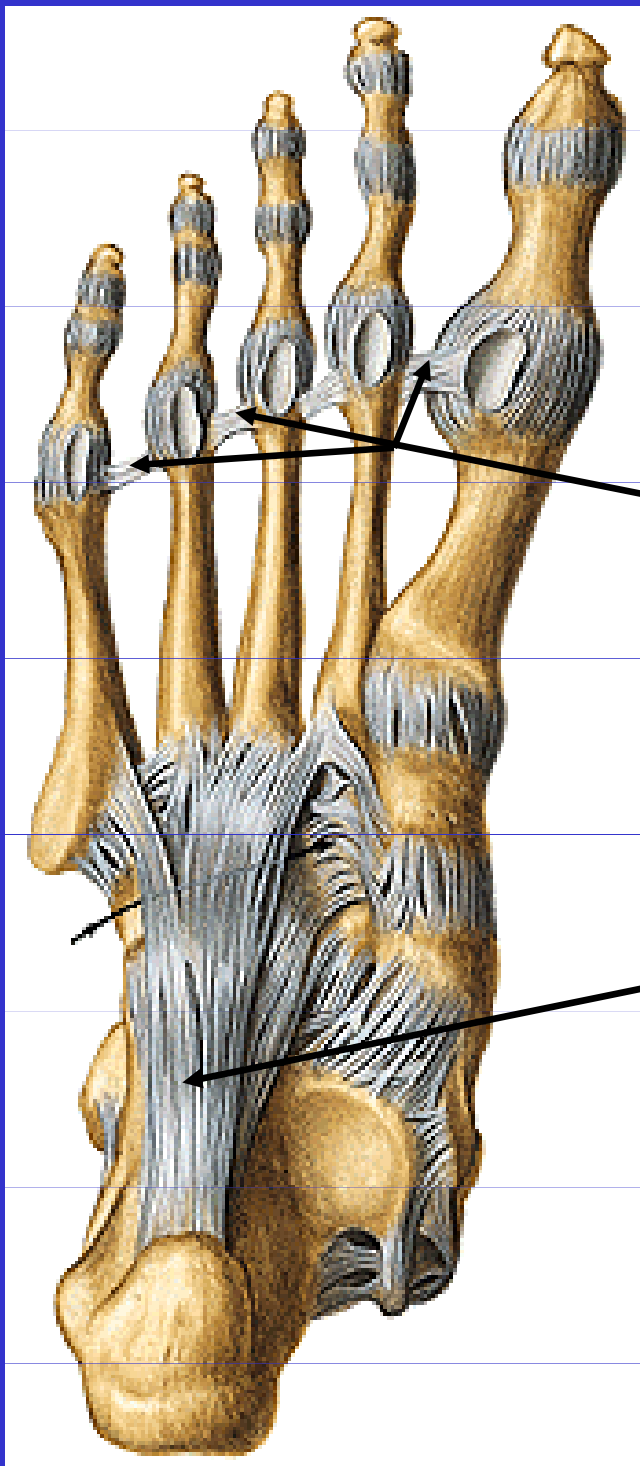
Lig.talofibulare post.

Lig.talocalcaneum lat.

Lig.calcaneofibulare

Tendo calcaneus

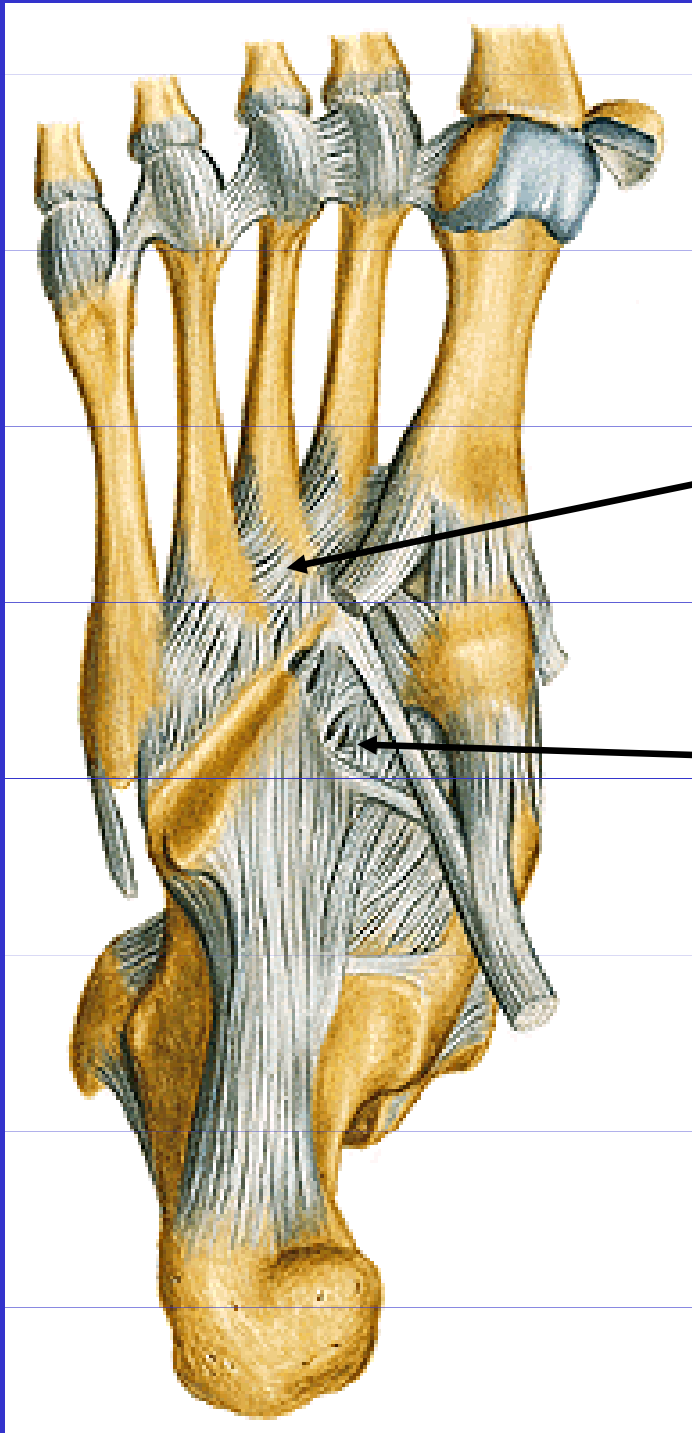
Vazy nohy



Lig. metatarsale
transversum
profundum

Lig. plantare longum

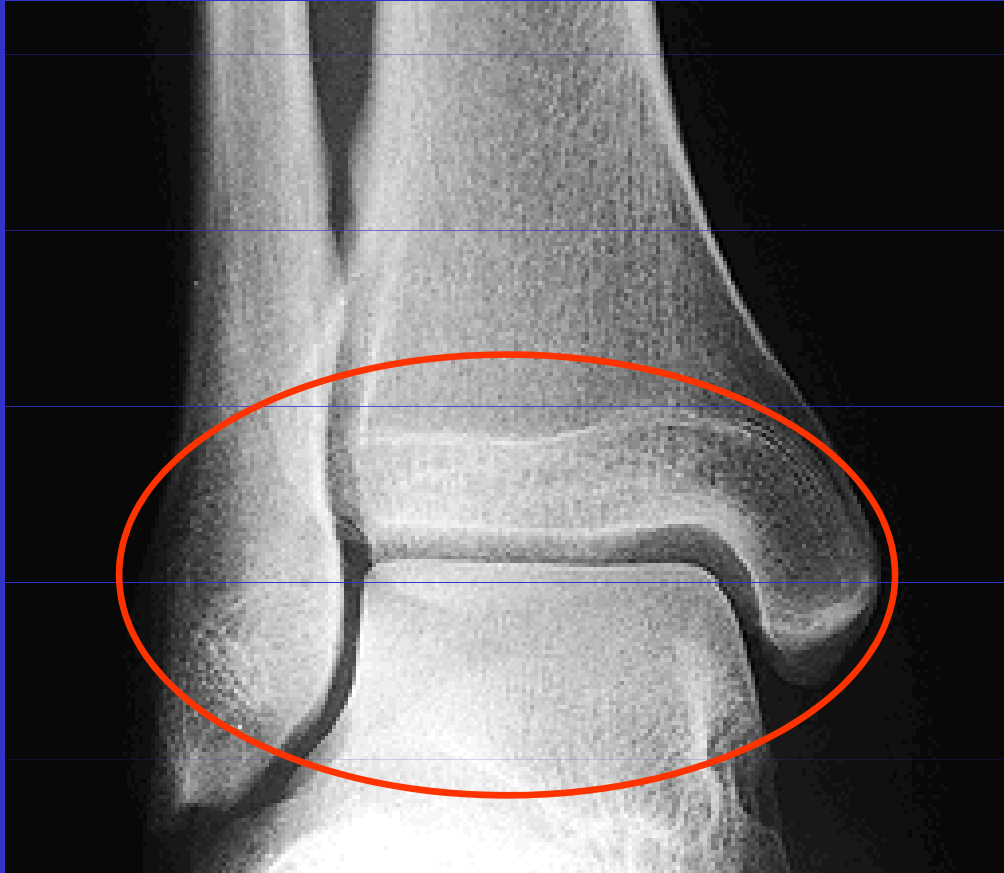Vazy nohy



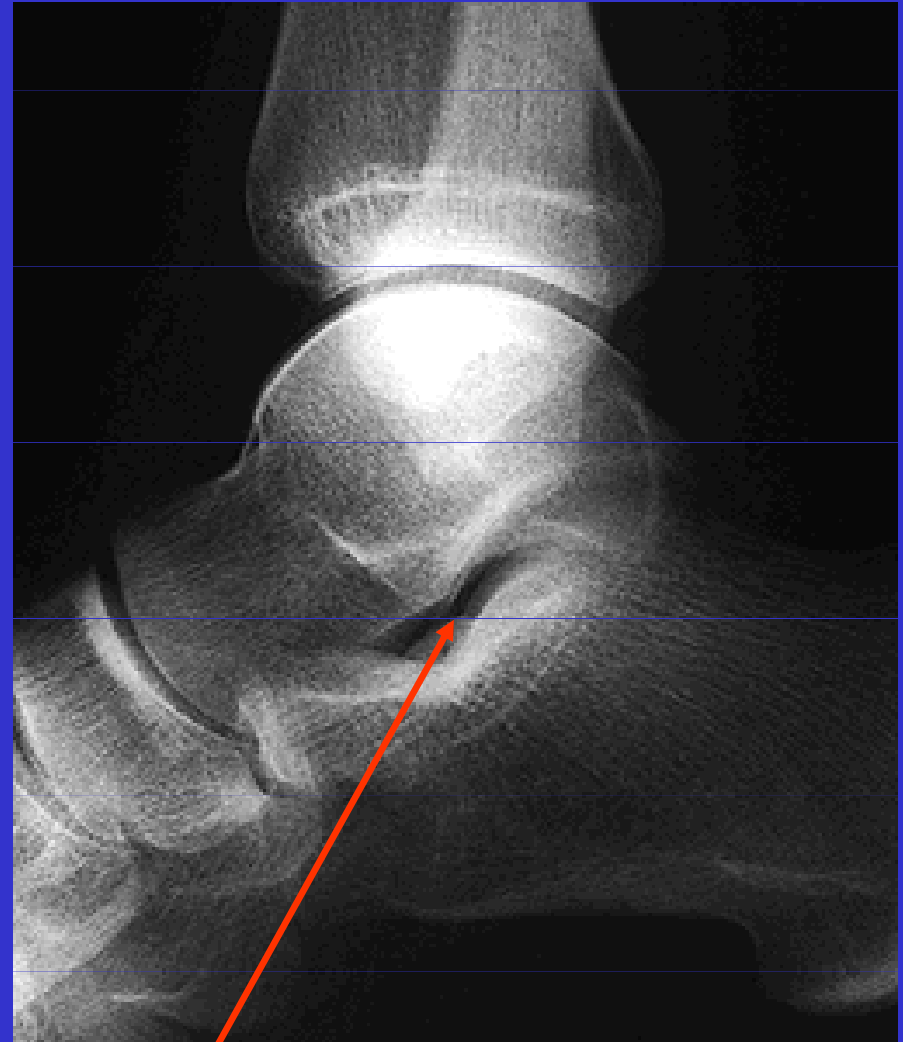
Lig. metatarsalia
plantaria

Lig. tarsi plantaria

Rtg nohy



Art.talocruralis



Sinus tarsi

II. Spoje kostí volné končetiny

Klouby nohy

Artt. intertarseae:

Dolní kloub nártní

I. zadní oddíl: art. subtalaris

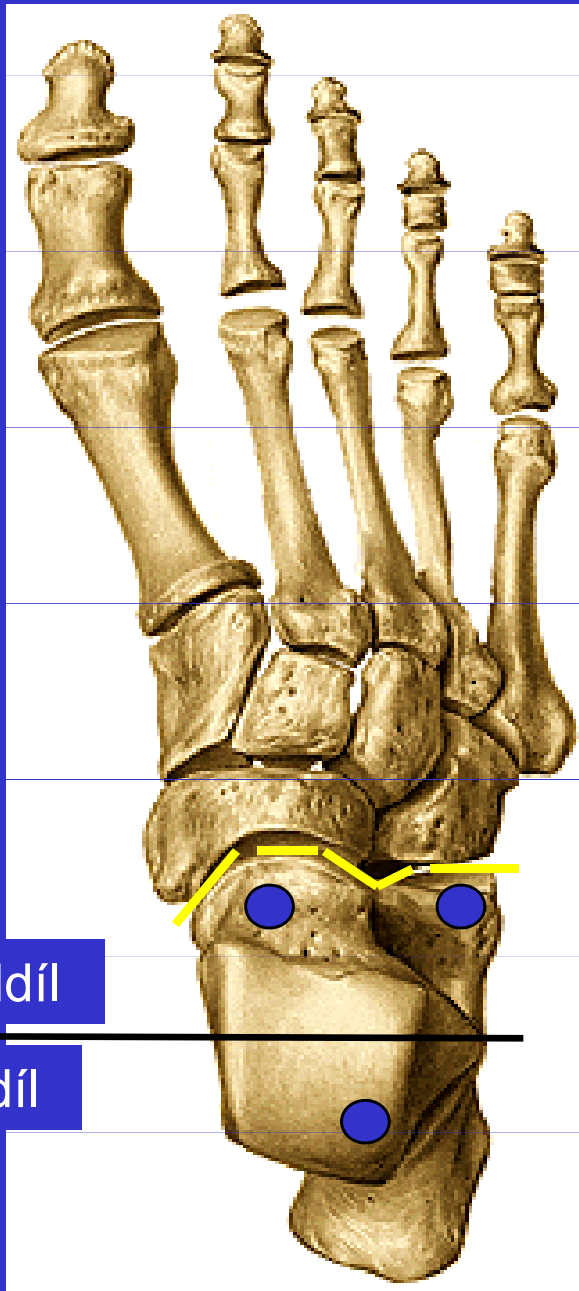
II. přední oddíl: art. talocalcaneonavicularis

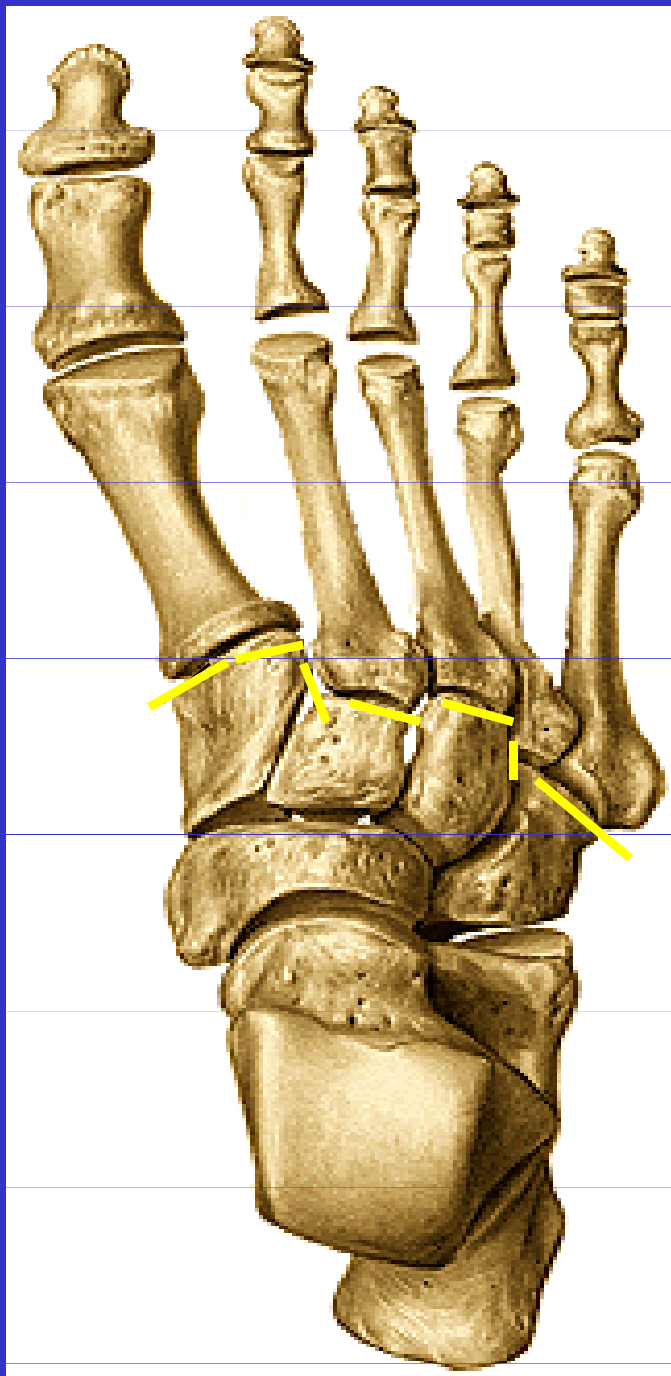
art. calcaneocuboidea

Chopartův kloub **(art. tarsi transversa)**

přední oddíl

zadní oddíl





II. Spoje kostí volné končetiny

Klouby nohy

artt. interphalangeae pedis

artt. metatarsophalangeae

artt. tarsometatarseae

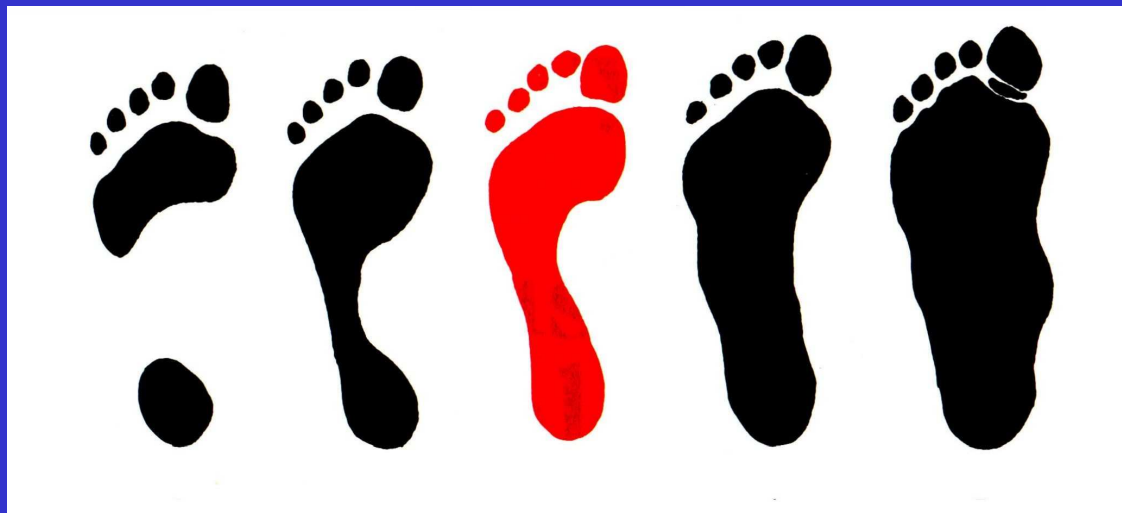Lisfrancův kloub

Artt. intertarseae:

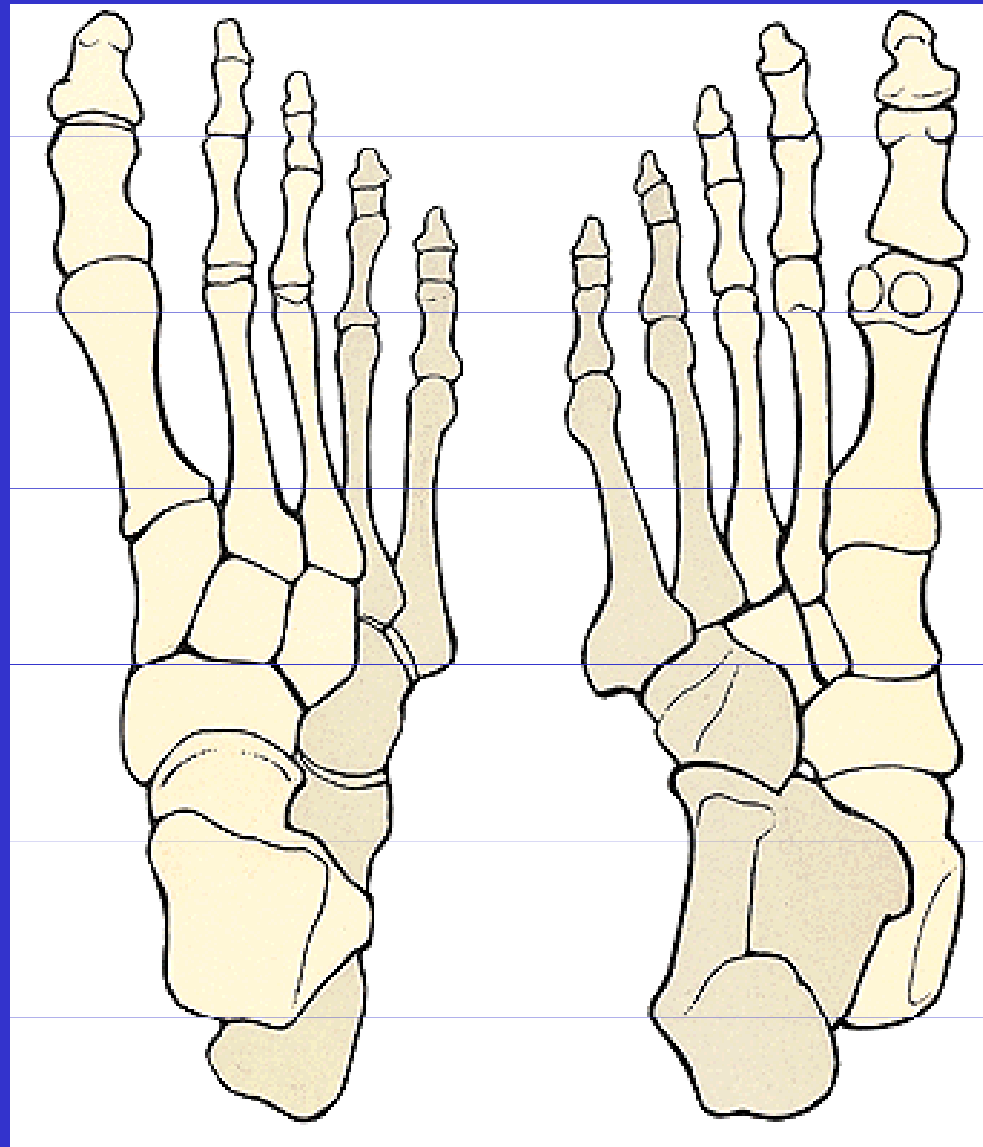
art. cuneocuboidea

art. cuneonavicularis

KLENBA NOHY

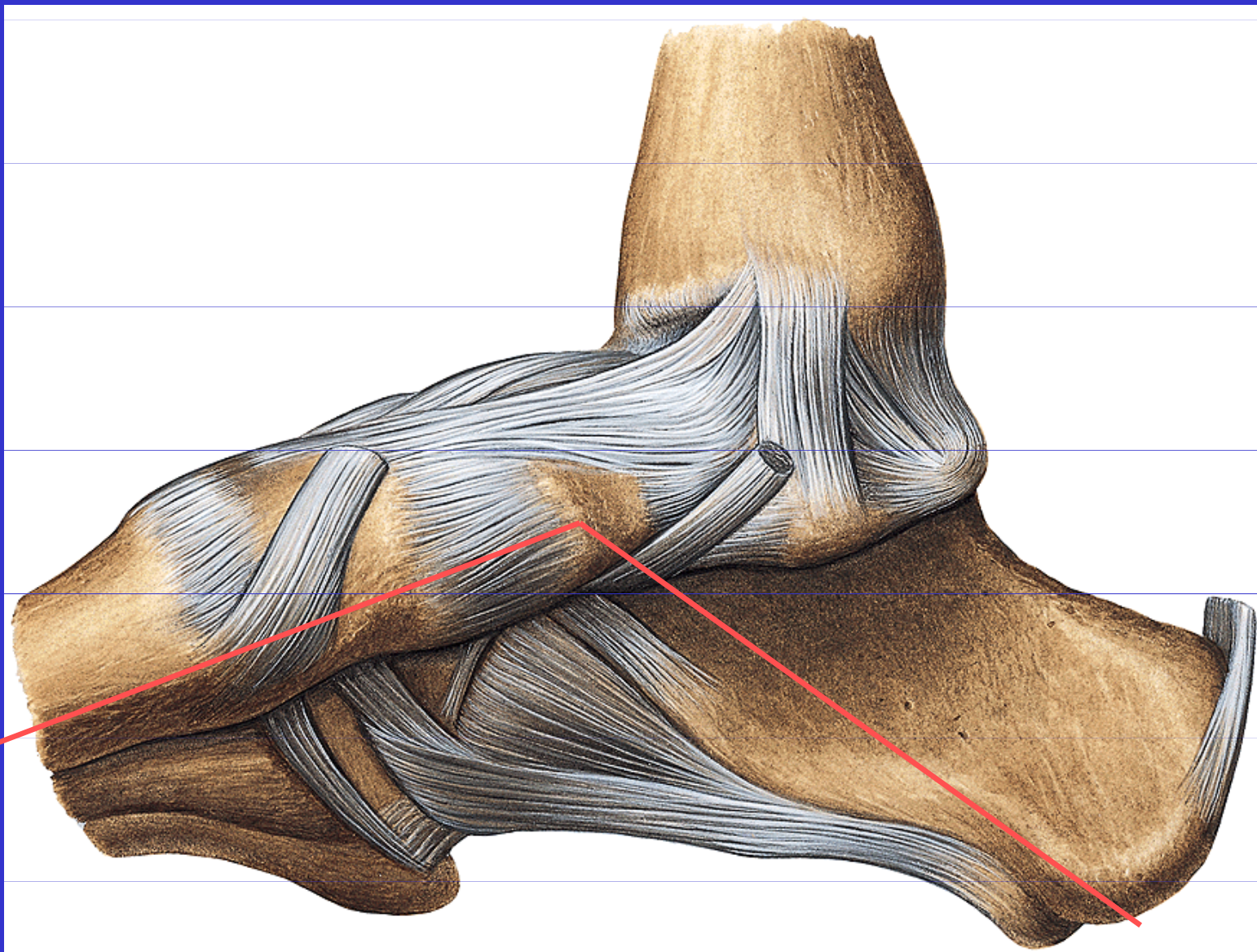


KLENBA NOHY

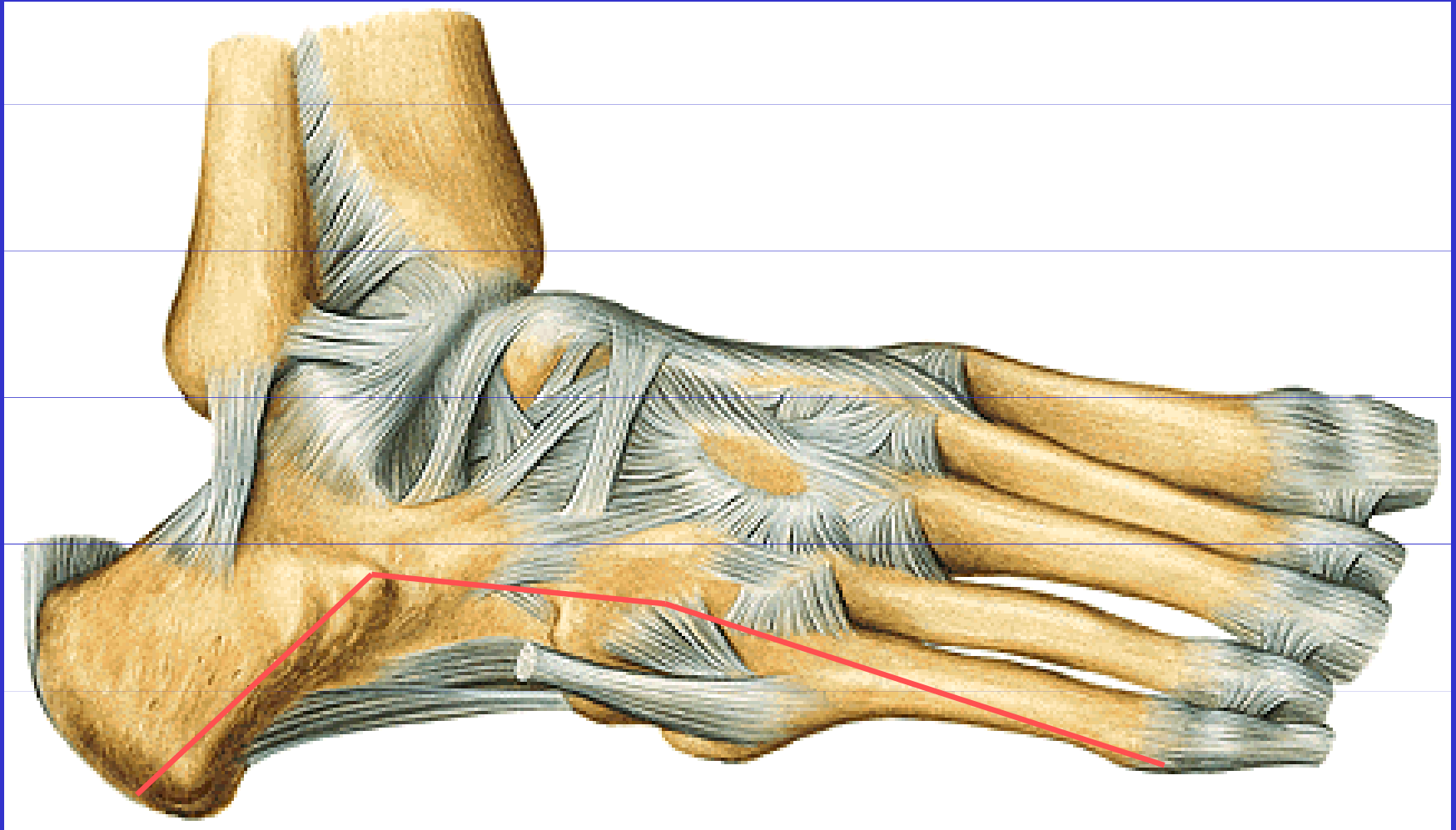


pohled shora

pohled zdola

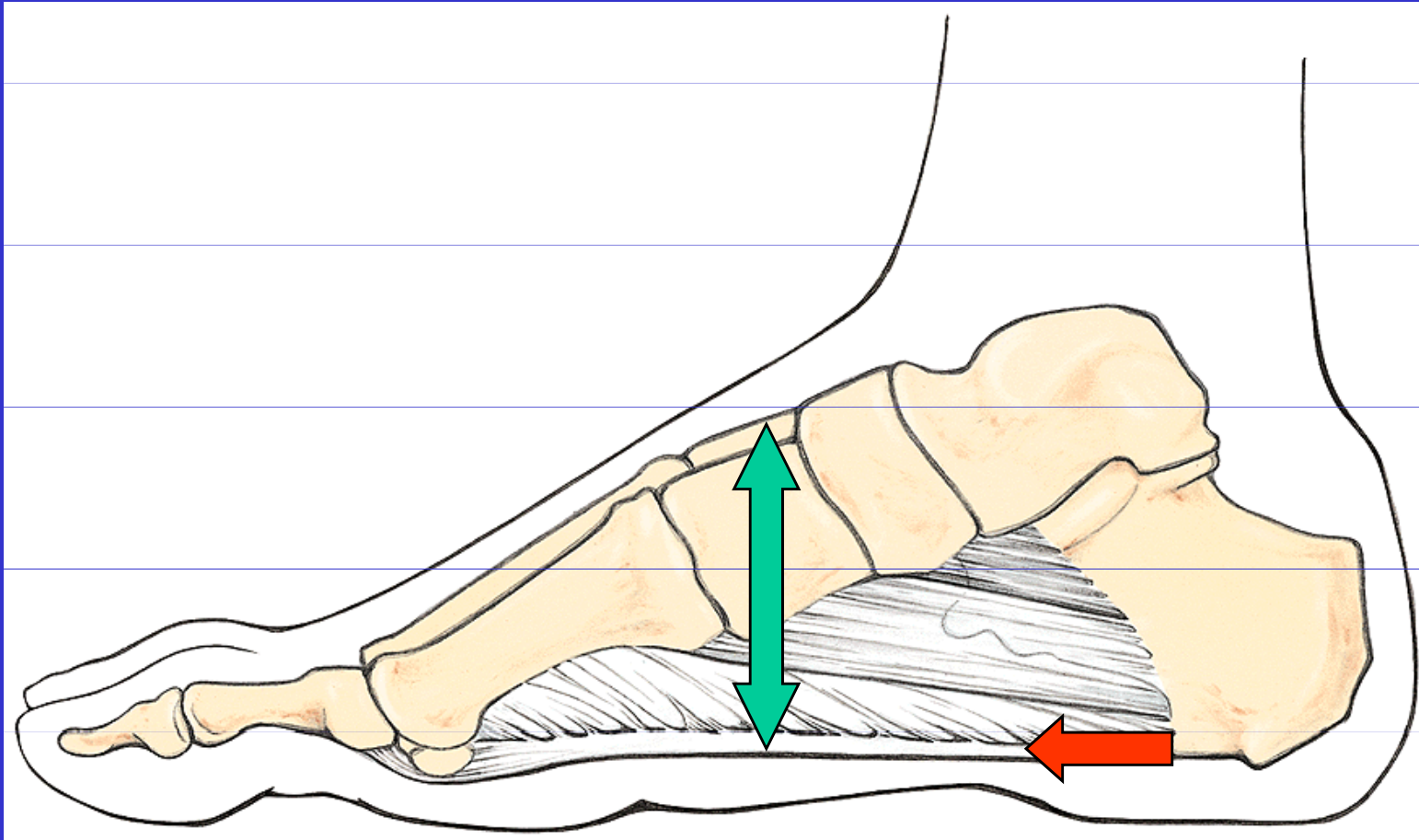


Paprsek tibiální

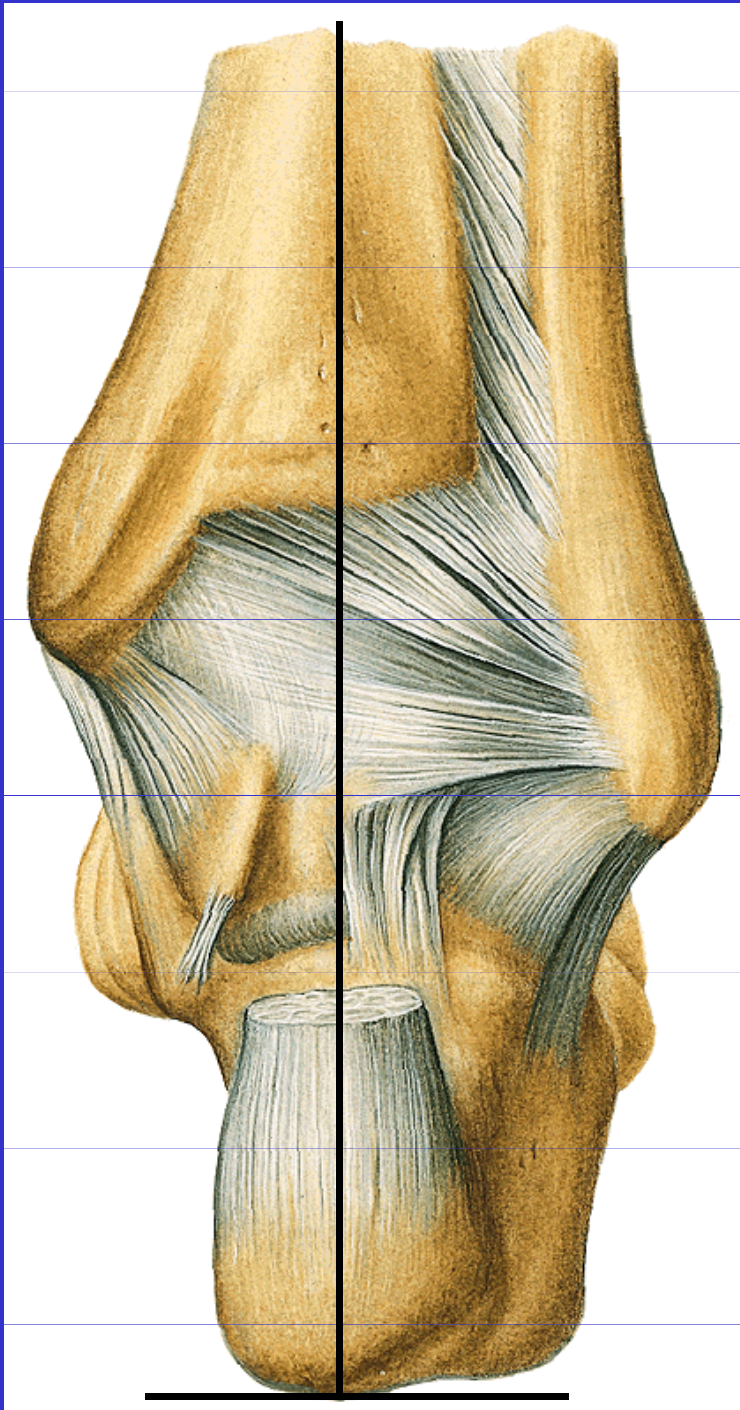


Paprsek fibulární

KLENBA NOHY

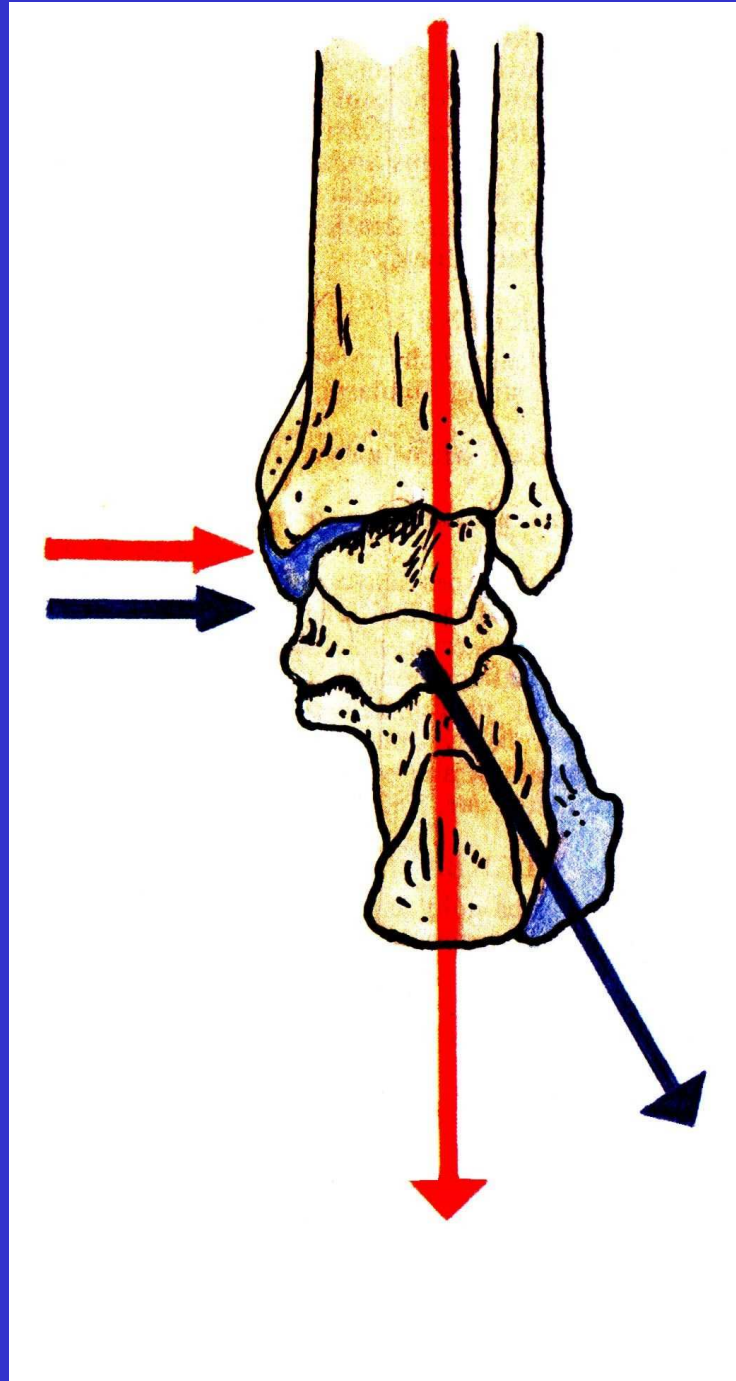


Ligamentum plantare longum, vznik ostruhy



Postavení patní kosti
(správné)

KLENBA NOHY



Postavení kosti patní u **zdravé nohy**

při **výrazně ploché noze:**

osa kosti patní se vychyluje zevně a vnitřní kotník, který je normálně vyš než zevní se snižuje, kolena jsou do X, sešlapává se vnitřní okraj podpatku

Postavení nohou do O je pro klenbu nožní prospěšnější