

Oral and maxillofacial surgery I., II. completed with control questions

Dental speciality that deals with diagnosis and surgical treatment of diseases, injuries and deformities of the face and jaws.

Surgical procedures

Routine extractions

Multiple routine extractions

Surgical extractions

Third molar extractions

Exposure of impacted cuspid

Frenectomy

Gingivectomy, osteoplastic

Biopsy

Anaesthesia

- Dentist is responsible for providing the patient with comfortable dental treatment !

Pain

Sensory and emotional experience associated with actual or potential tissue damage.

Pain and anaesthesia

Pain occurs when pain receptors or nerve endings transmit impulses to the central nervous system.

Anaesthesia eliminates the pain experience by interrupting the transmitted impulse.

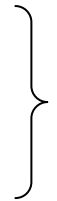Anaesthesia

- Absence of normal sensation, esp sensitivity to pain.

Anaesthesia

Topical: an application of substance to the tissues that creates loss of feeling on the surface.

Local: placement of a substance by injection at a site that creates a loss of sensation to one part of the body



Anaesthesia

Conscious sedation: an anaesthetic agent used to produce a sedative effect while patient remains conscious. (Sometimes inhalation)

General anaesthesia: an anaesthetic agent creates a state of unconsciousness with absence of sensation of entire body.

Local anaesthesia

The drug is delivered

- Locally (on the surface of oral mucosa) – topical anaesthesia.
- By injection

Local anaesthesia

Topical

Liquid or spray

Lidocain, Xylocain.

Local anaesthesia

By injection

- Infiltration
- Nerve block
- Periodontal ligament injection

Infiltration anaesthesia

Depositing anaesthesia into tissues. The solution is absorbed by many terminal nerve endings.

Single tooth extraction or other tissue surgery.

Nerve block anaesthesia

Depositing anaesthesia near the
nerv.

Mandibular arch (n. alveolais inferior)

Foramen infraorbitale

Foramen incisivum

Foramen palatinum majus

Tuber maxillae

Local anaesthesia

By injection

- Infiltration
- Nerve block
- Periodontal ligament injection

Instrumentarium

Syringes

Needels

Extracting teeth (exodontia)

Reasons:

- Caries
- Trauma
- Periodontitis
- Endodontic reasons
- Retention, semiretention if it causes
- Inflammation and pain

Principles of extraction

Interruption, rupture of periodontal
Ligaments and extraction - the tooth
is pulled out.

Anaesthesia

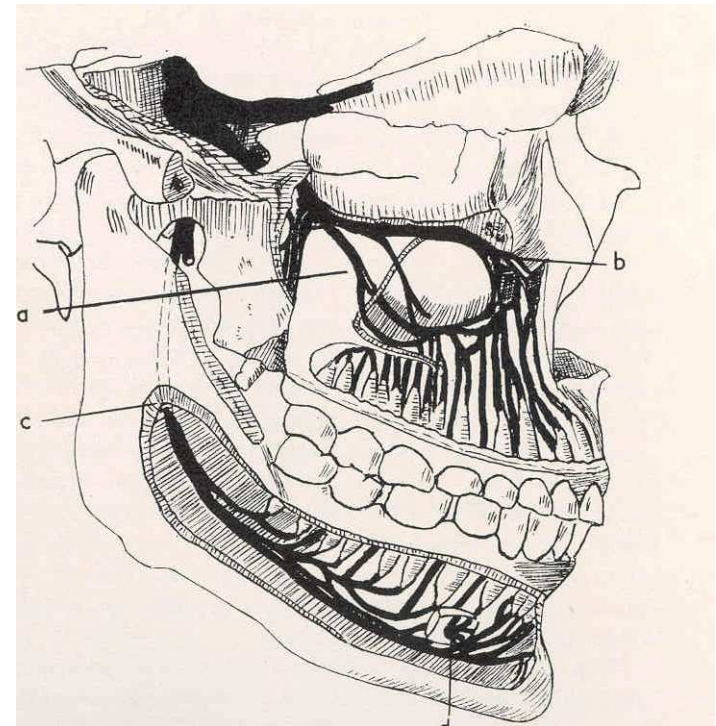
Topical

By injection

- Infiltration
- Nerve block

Nerve block anaesthesia


- Foramen mandibulare
- Foramen mentale
- Foramen palatinum majus
- Foramen incisivum
- Foramen infraorbitale



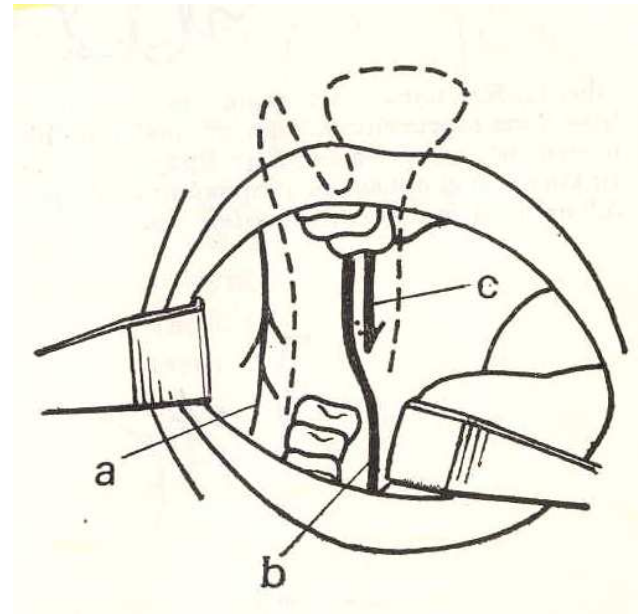
Nerve block anaesthesia

N. alveolaris inferior

Foramen mandibulare



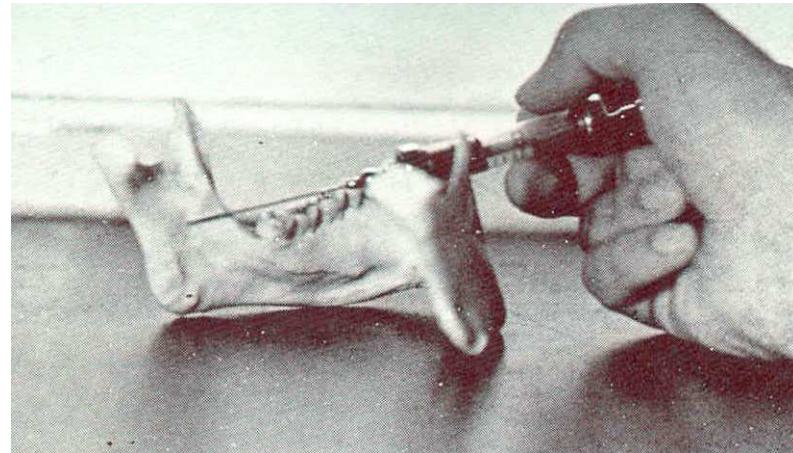
N. Alveolaris inferior
N. lingualis



Nerve block anaesthesia

Nervus alveolaris inferior

In sulcus colli mandibulae

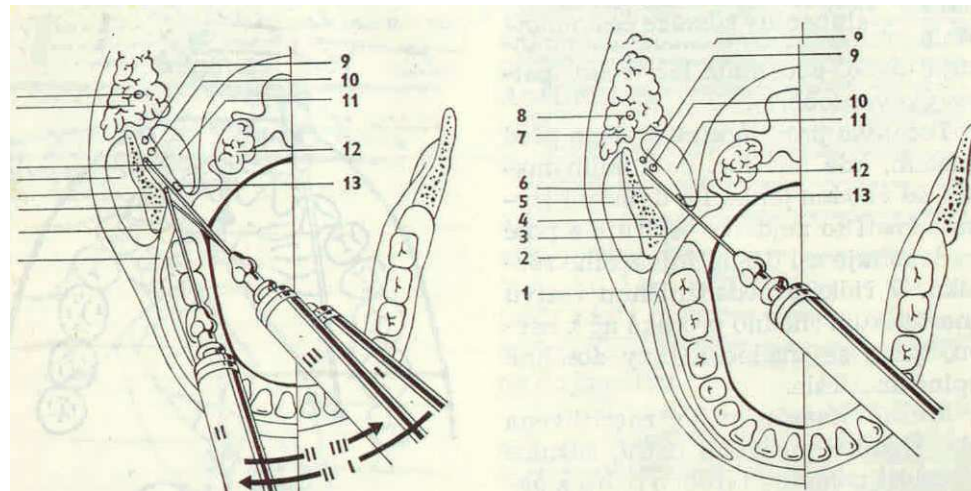


Nerve block anaesthesia

N. alveolaris inferior

Indirect

Direct



Nerve block anaesthesia

N. alveolaris inferior

Indirect

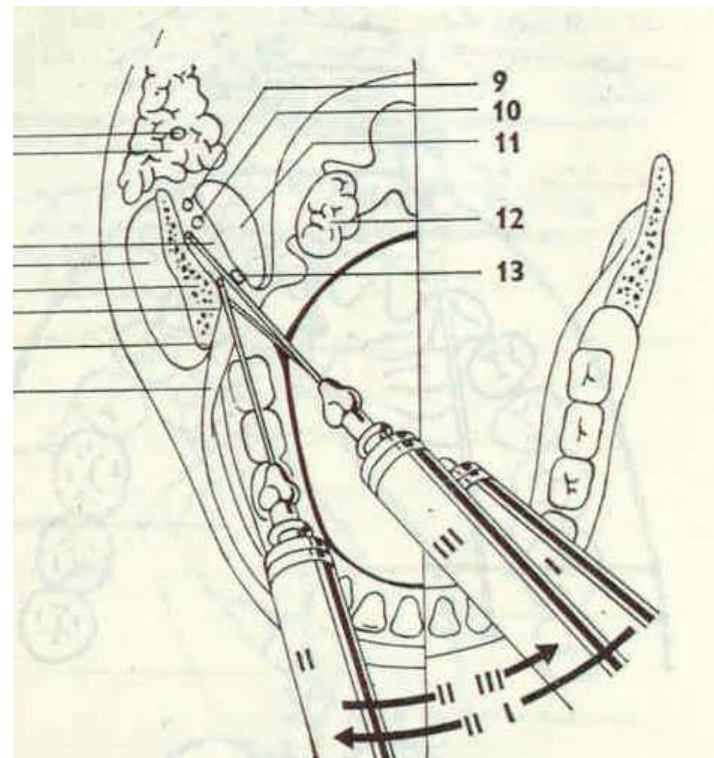
Put the forefinger

on the occlusal surface

Rotate inside (nail inside)

1 cm up occlusal surface

the puncture is situated

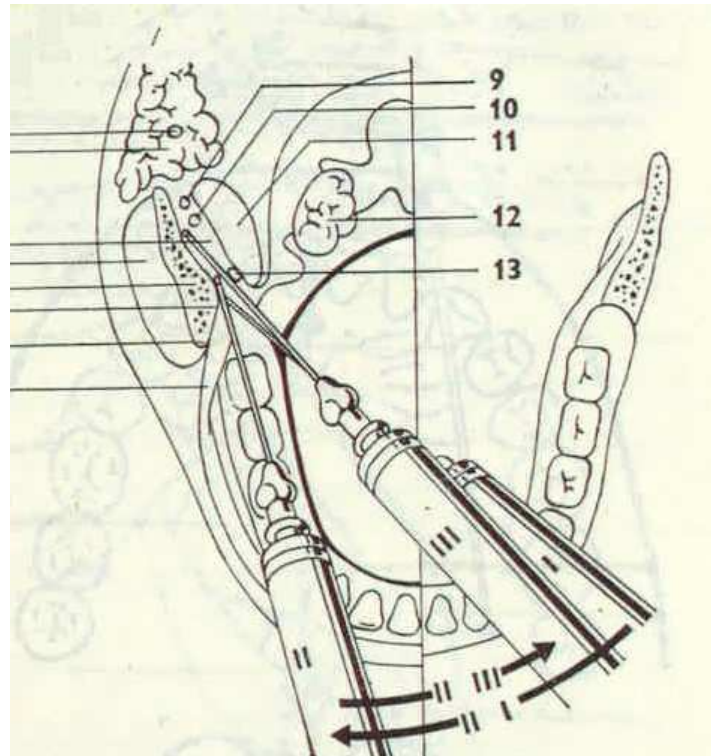


Nerve block anaesthesia

N. alveolaris inferior

Indirect

1. The needle goes behind the crista temporalis, the syringe on the opposite canine

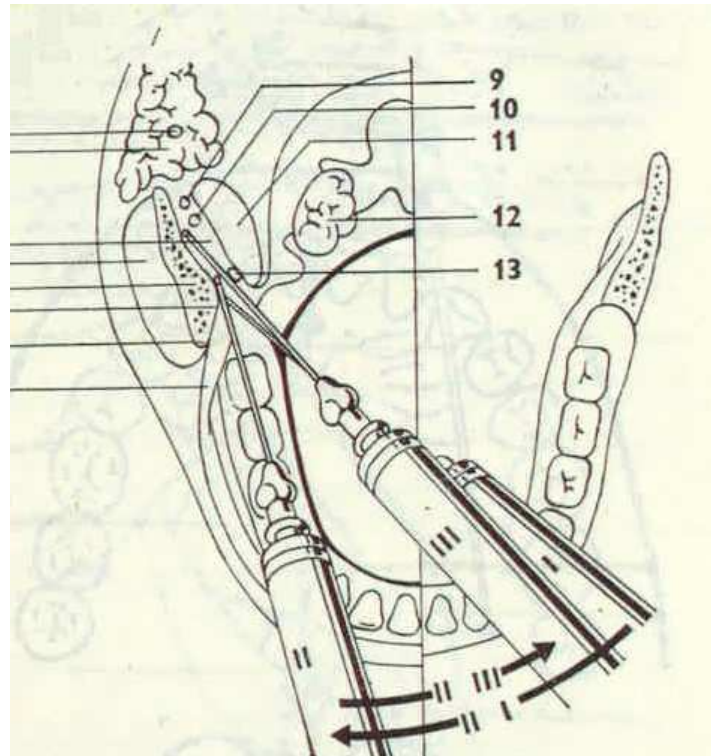


Nerve block anaesthesia

N. alveolaris inferior

Indirect

- 2. The needle goes deeper in the contact with the bone
- The syringe goes mesial

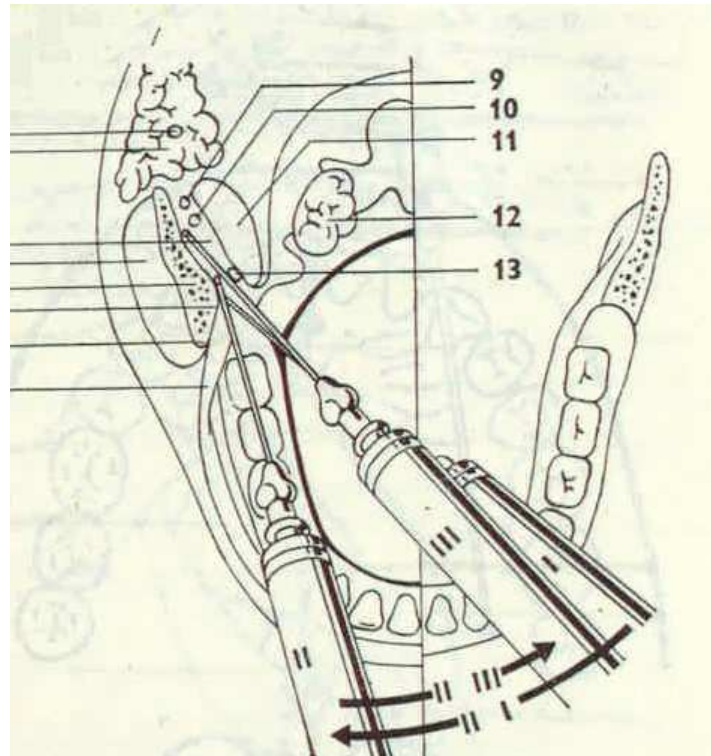


Nerve block anaesthesia

N. alveolaris inferior

Indirect

- 3. The contact with bone
Is lost, the syringe goes back



Nerve block anaesthesia

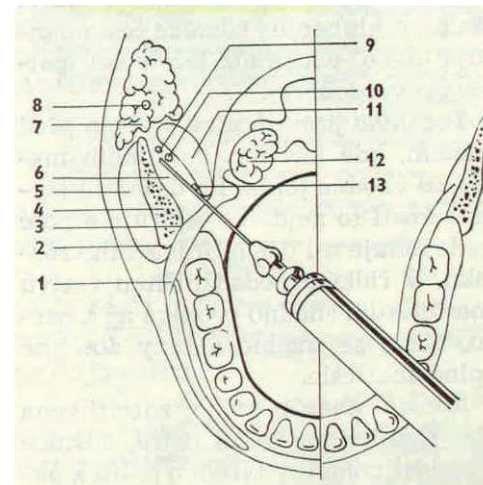
N. alveolaris inferior

Direct

Put the forefinger

on the occlusal surface

Rotate inside (nail inside)



1,5 cm deep

Nerve block anaesthesia

N. alveolaris inferior

Area:

Molars

Premolars

Tongue

Nerve block anaesthesia

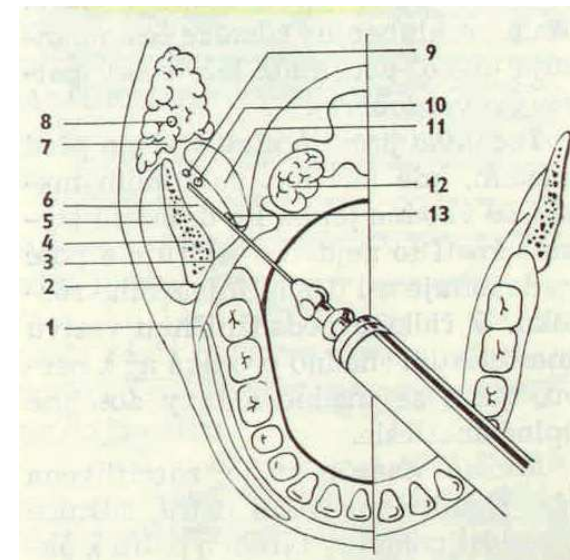
N. alveolaris inferior

Direct

- The puncture at the same place
- The syringe on opposite premolars
- The puncture goes into the small pink depression medial from crista temporalis and lateral from plica prerygomandibularis

1,5 cm deep

Molars, premolars, mucosa, skin, bone



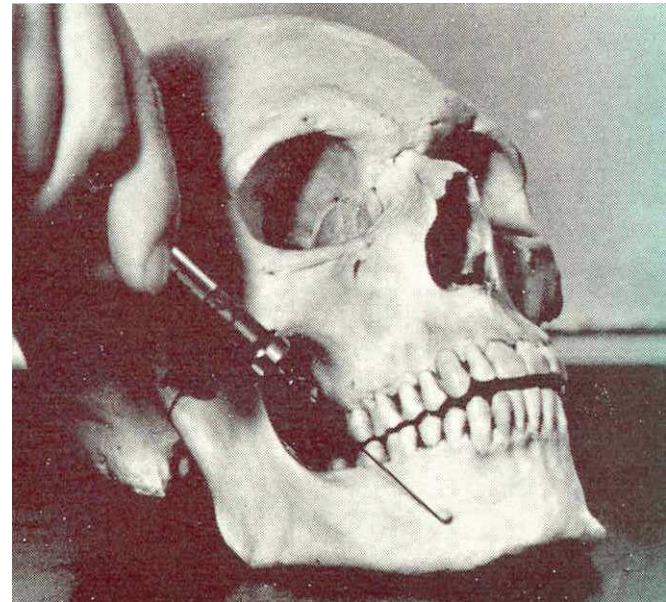Nerve block anaesthesia

N. mentalis

F. mentale

The puncture is situated behind the distal surface of 2nd premolar

The needle goes between roots of premolars



Nerve block anaesthesia

N. mentalis

F. mentale

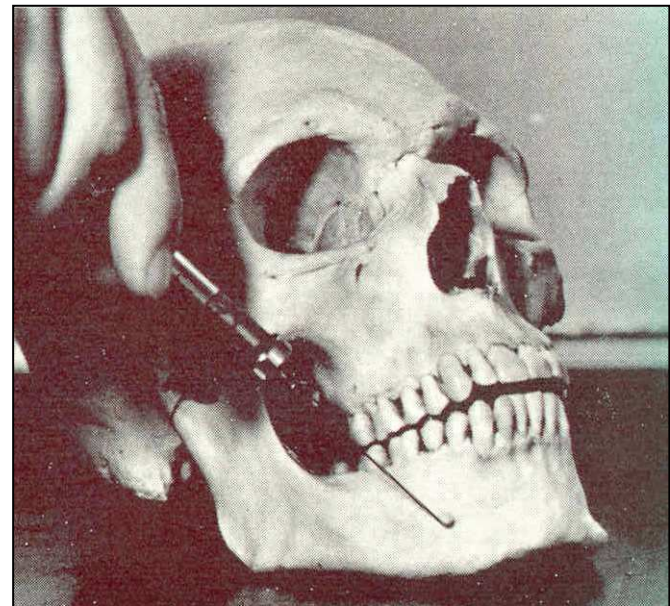The puncture is situated behind
the distal surface of 2nd premolar

The needle goes between
roots of premolars,

From up to down

Forward and mesial

Premolars and canine, mucosa, skin.



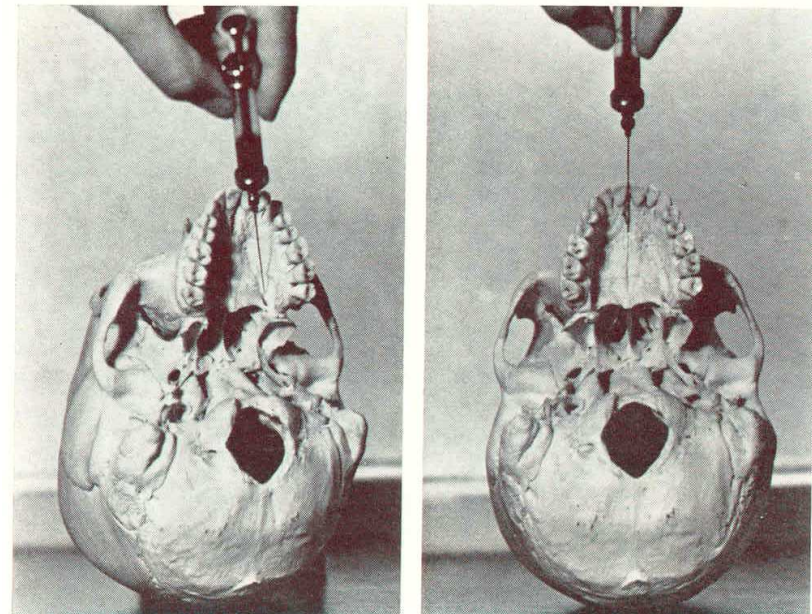
Nerve block anaesthesia

Foramen palatinum majus

Distal surface of 1st molar

The puncture is
0,5 – 1 cm before
from behind forward

Half of palate



Nerve block anaesthesia

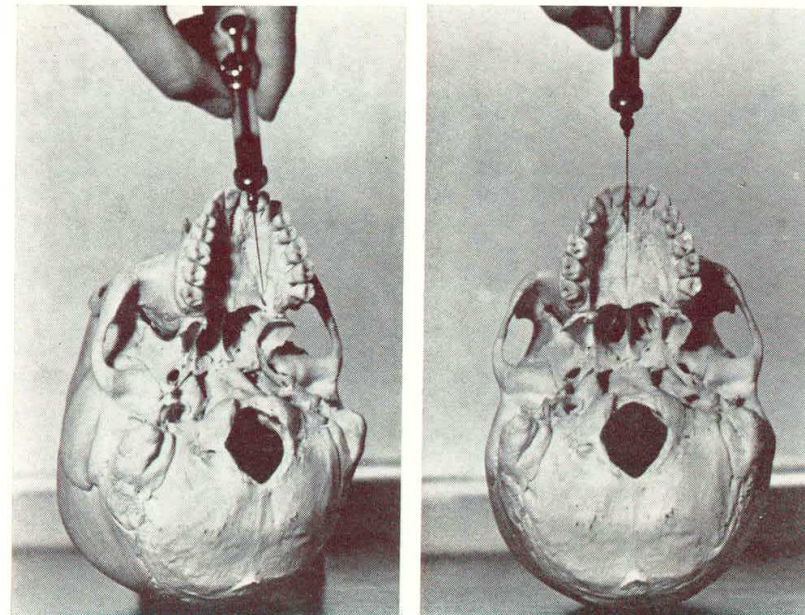

Foramen incisivum

Nervus incisivus

Papilla incisiva

Next to papilla,
mesial direction

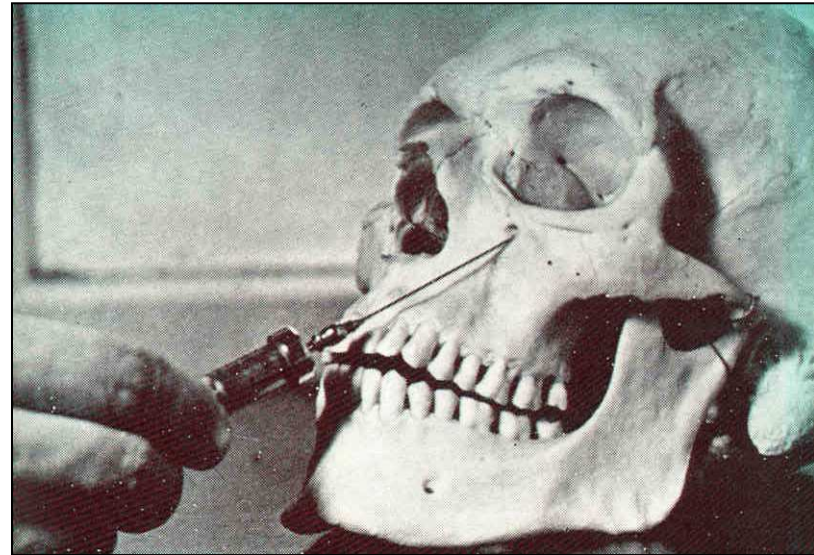
*Triangular area
behind incisors*



Nerve block anaesthesia

Raise the lip, the
index finger on
f. Infraorbitale
(1cm below the
border of the orbit)

The needle from down tu up



Suture

Suture material

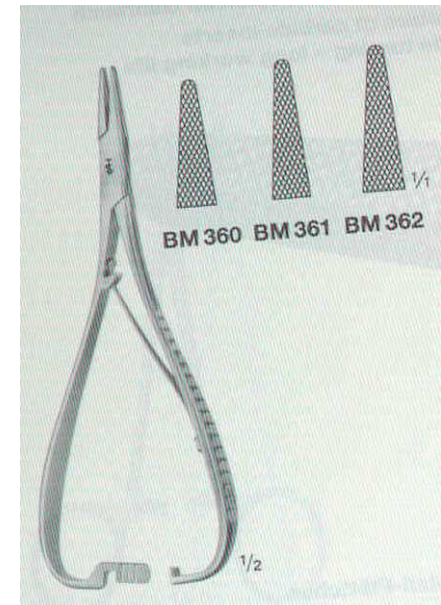
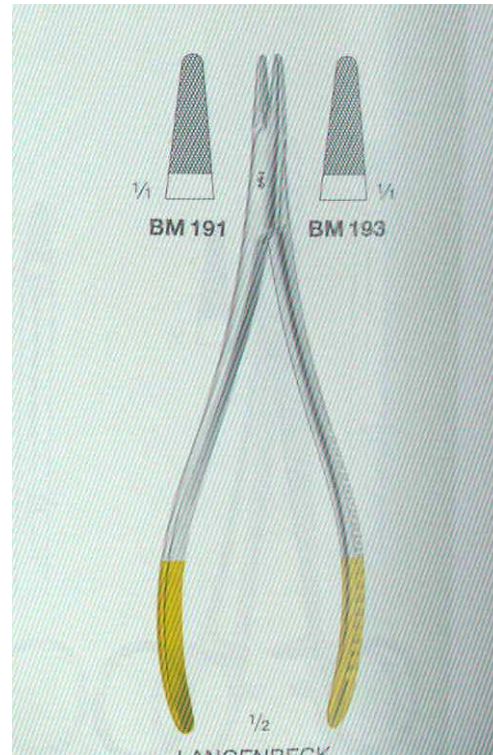
Silk, nylon

Needles

- bent, rounded
- straight

Needle holders

- autofix
- without fixation



Suture

Suture material

Silk, nylon

Needles


- bent, rounded

- straight

Needle holders

- autofix

-without fixation



Suture

Suture material

Silk, nylon

Needles


- bent, rounded
- straight

Needle holders

- autofix
- without fixation

Tweezers – tissue forceps

- anatomical
- surgical



Control questions

- What is the principle of the local anaesthesia?
- What kinds of local anaesthesia do you know?
- Describe the principle of the nerve block anaesthesia, which kinds do you know?

Control questions

Describe the infiltration anaesthesia.

Describe all techniques used for the nerve block anaesthesia including the affected area.

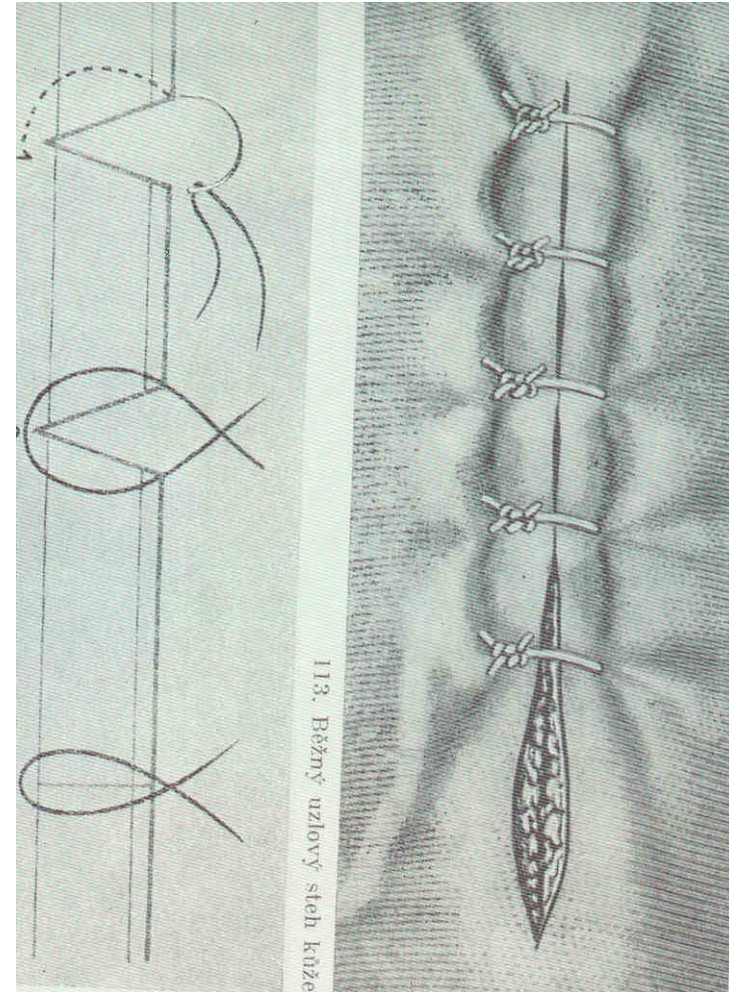
Which instruments and material are necessary for the suture?

Control questions

- Which kinds of the suture do you recognize?
- Practice them.

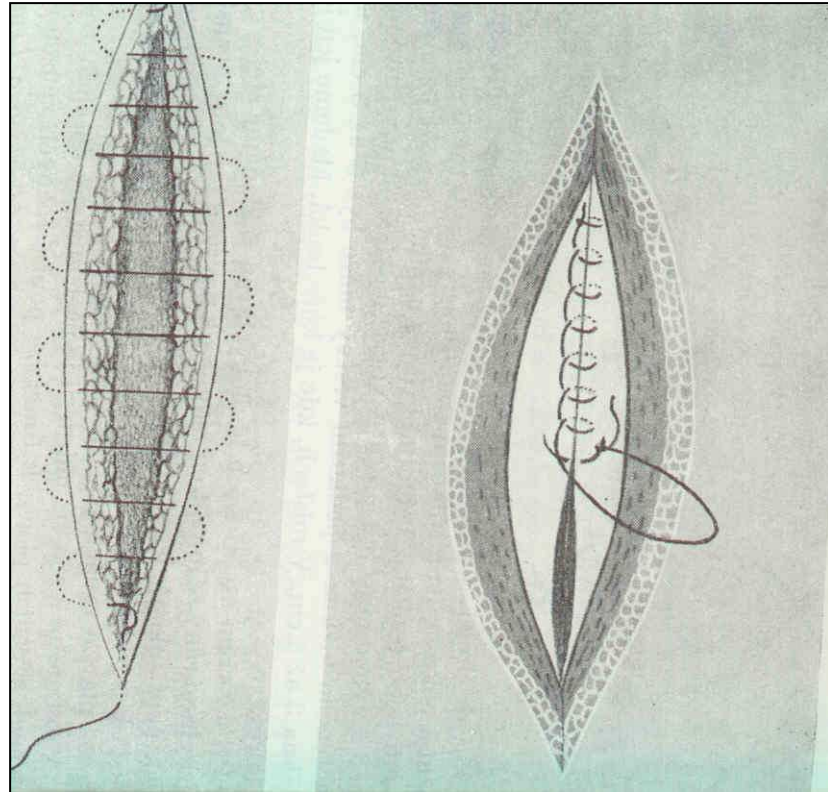
Sutura

Surgical knot – single suture



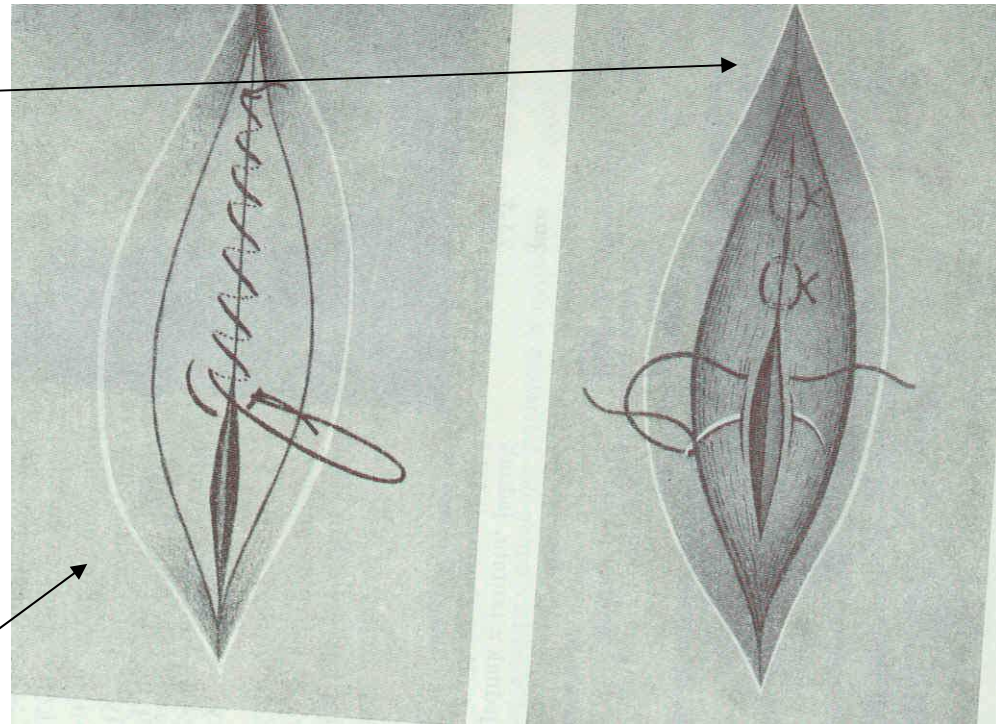
Suture

Continuus suture



Suture

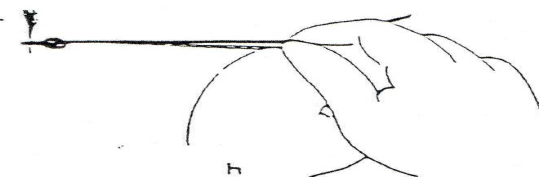
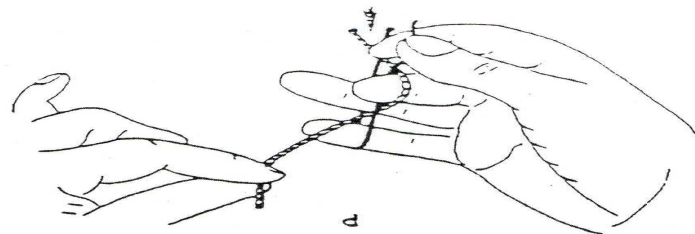
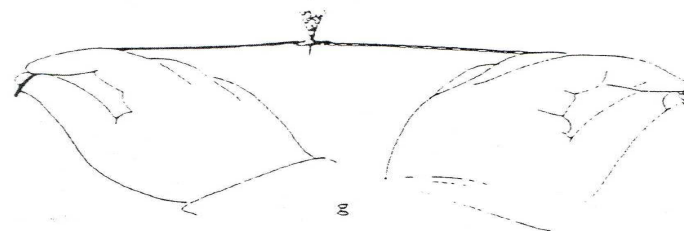
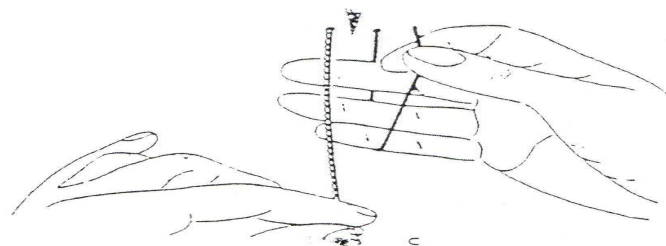
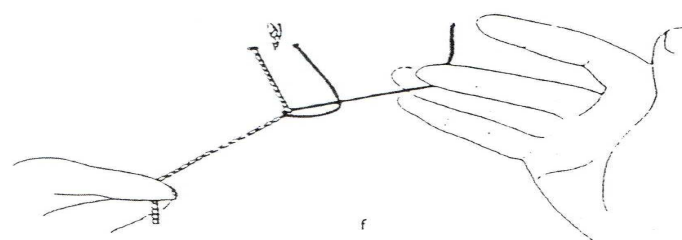
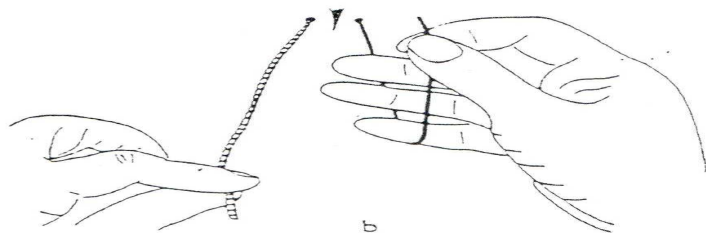
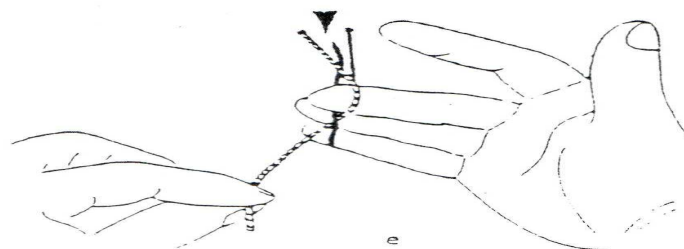
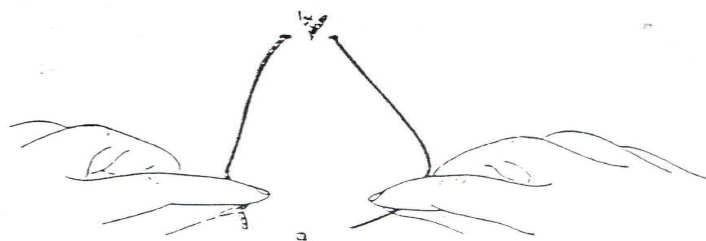
Matress suture



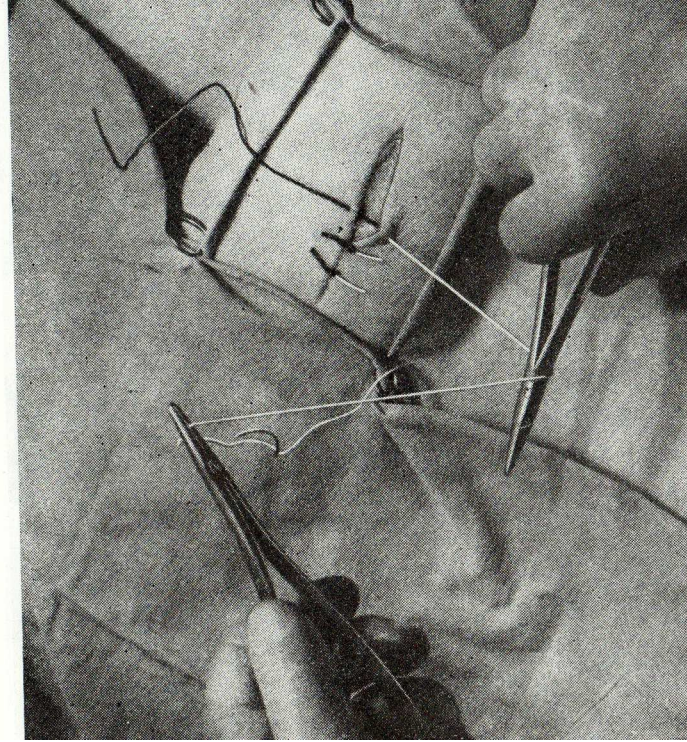
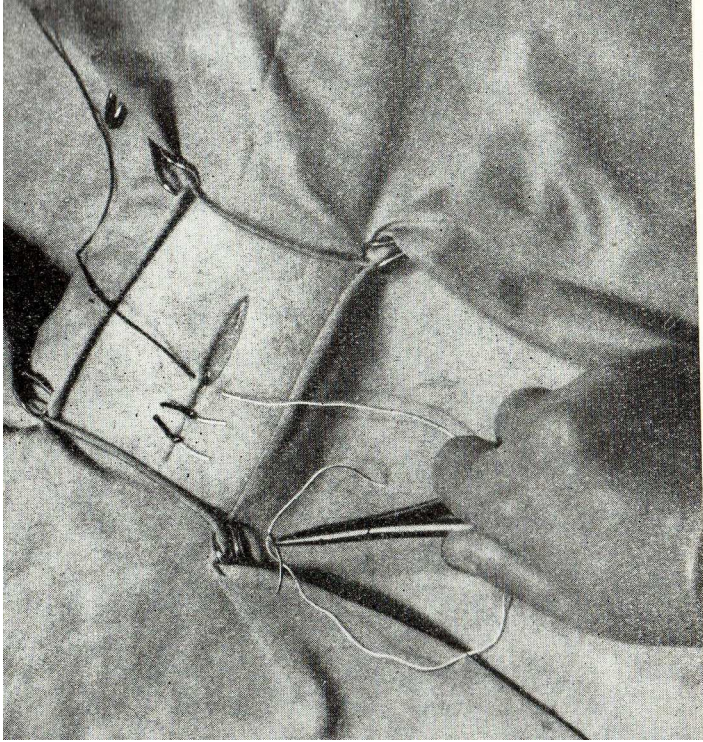
Continous suture

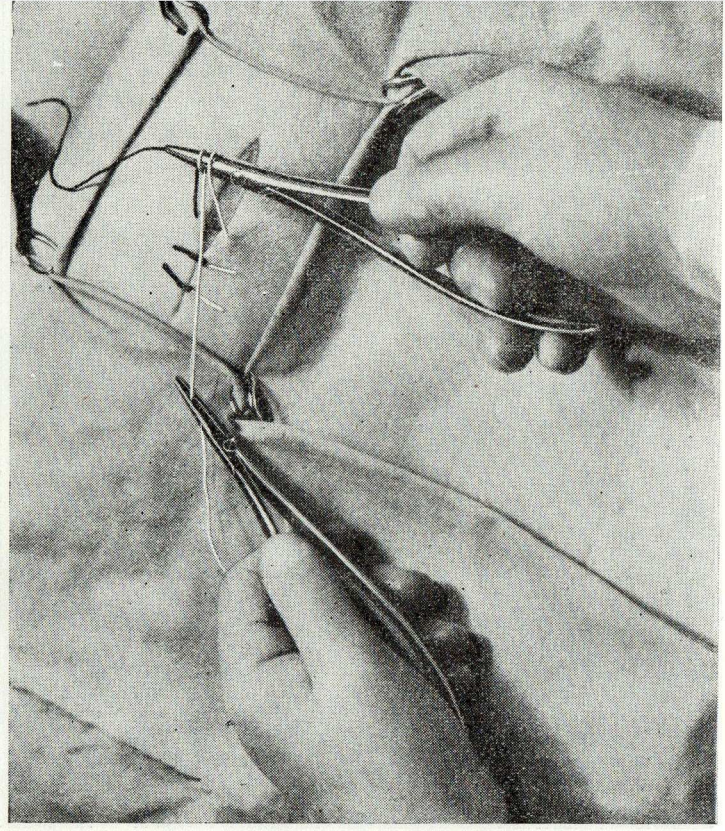
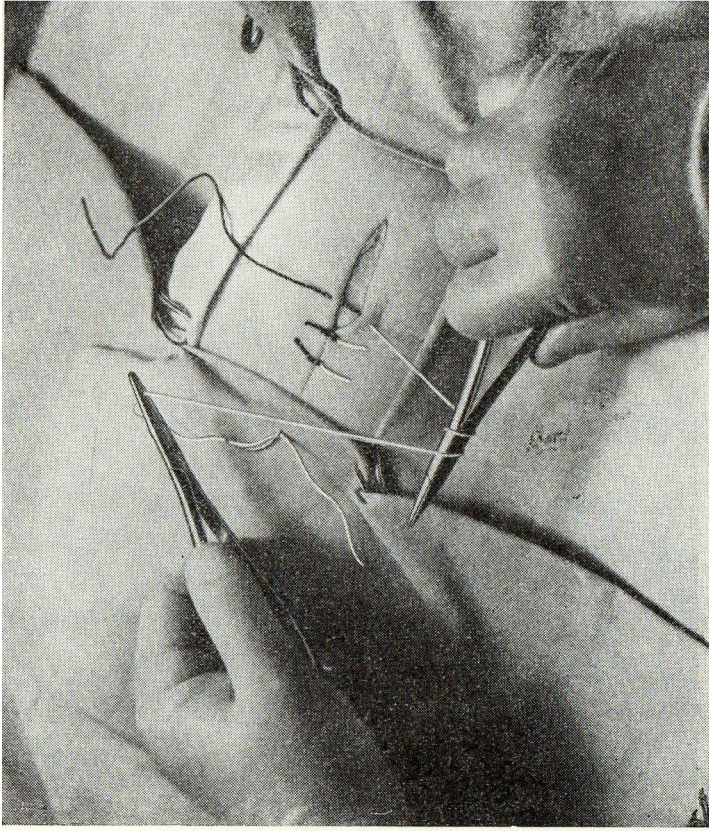
Suture

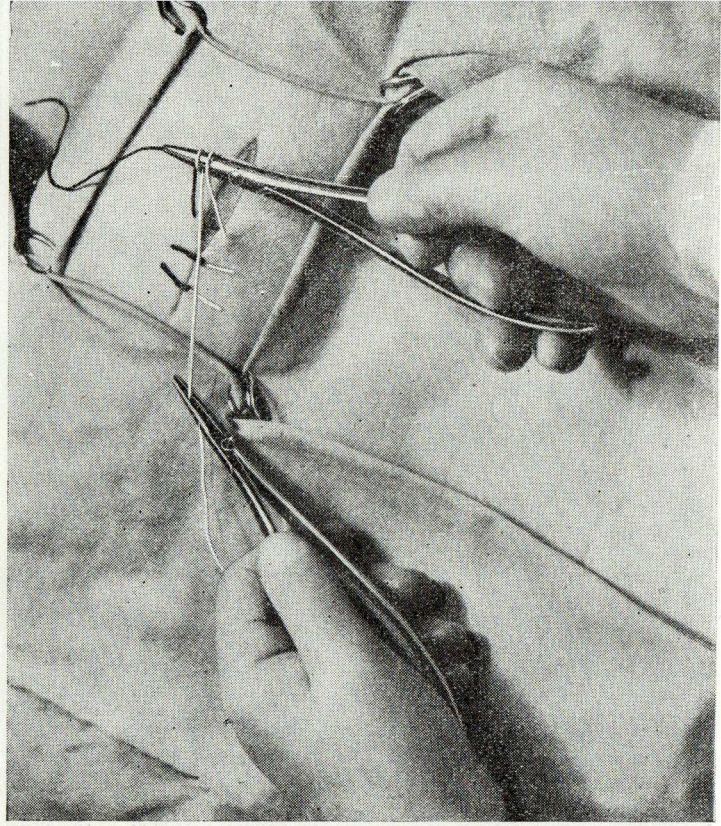
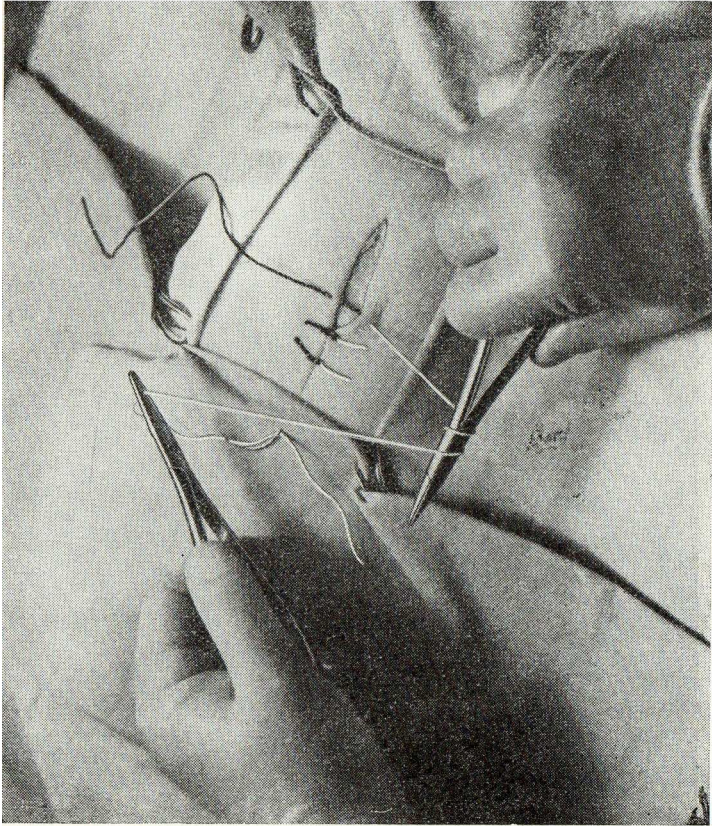
- Well adapted borders
- Without tension
- Needle goes perpendiculary

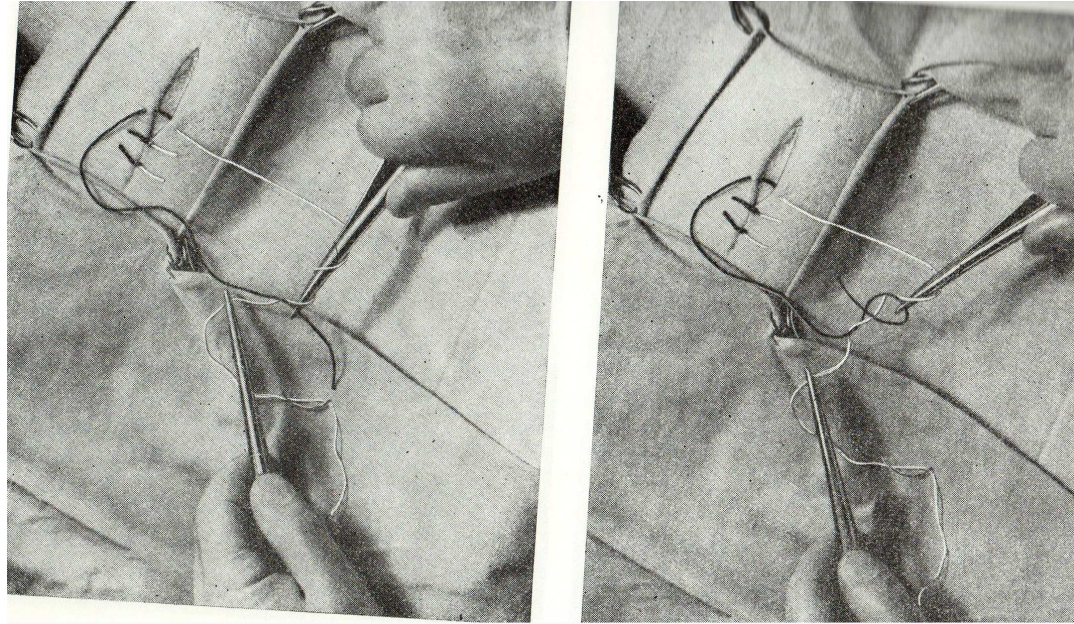


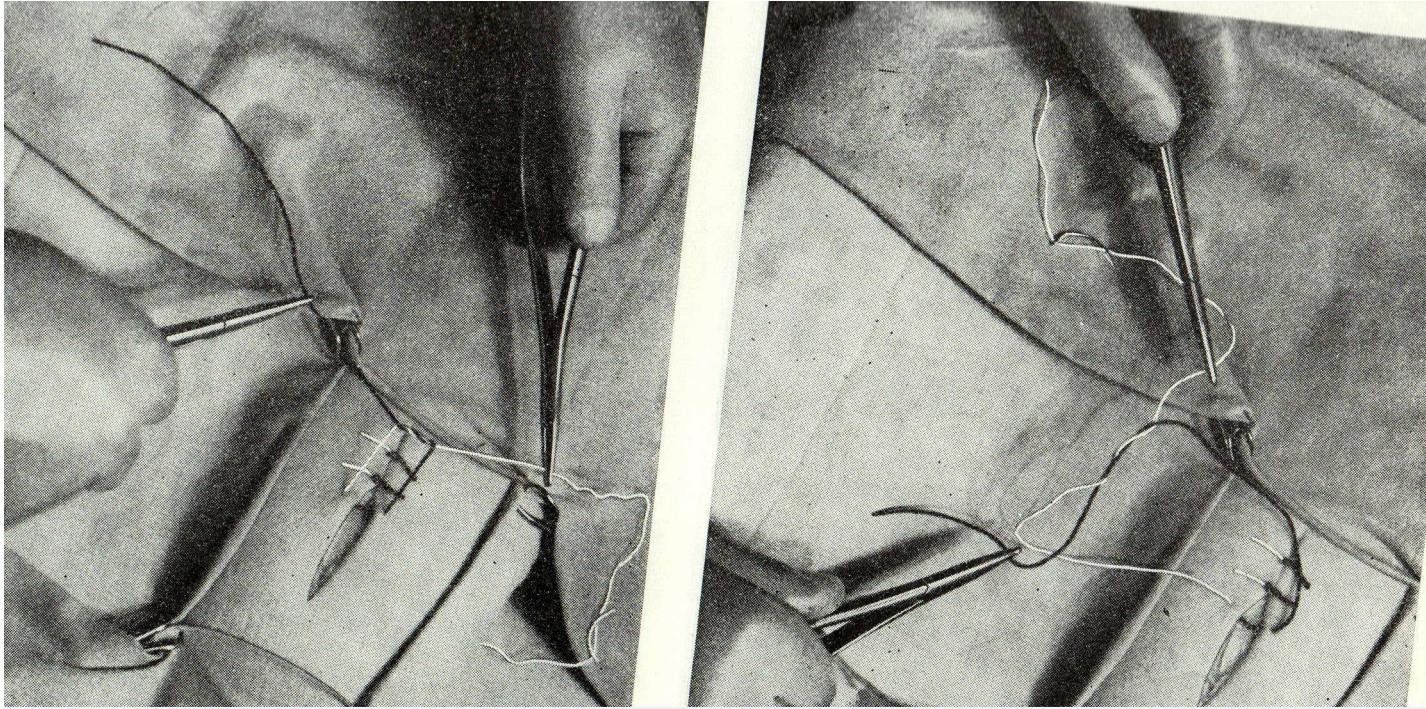
Obr. 211. Uzlení v ruce (a — h); popis v textu











Control questions

- What is the principle of the local anaesthesia?
- What kinds of local anaesthesia do you know?
- Describe the principle of the nerve block anaesthesia, which kinds do you know?

Control questions

Describe the infiltration anaesthesia.

Describe all techniques used for the nerve block anaesthesia including the affected area.

Which instruments and material are necessary for the suture?

Control questions

- Which kinds of the suture do you recognize?
- Practice them.