

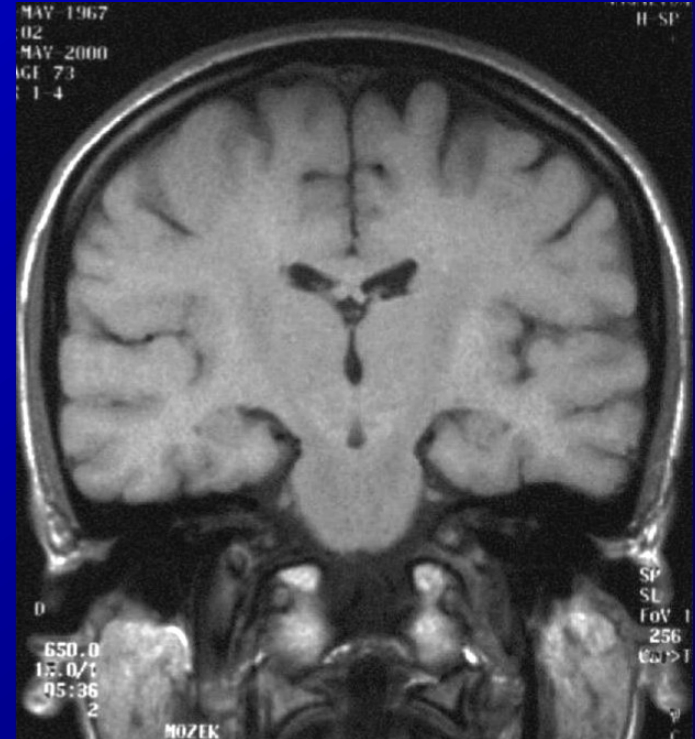Radiologická anatomie centrálního nervového systému

Marek Mechl, Miloš Keřkovský

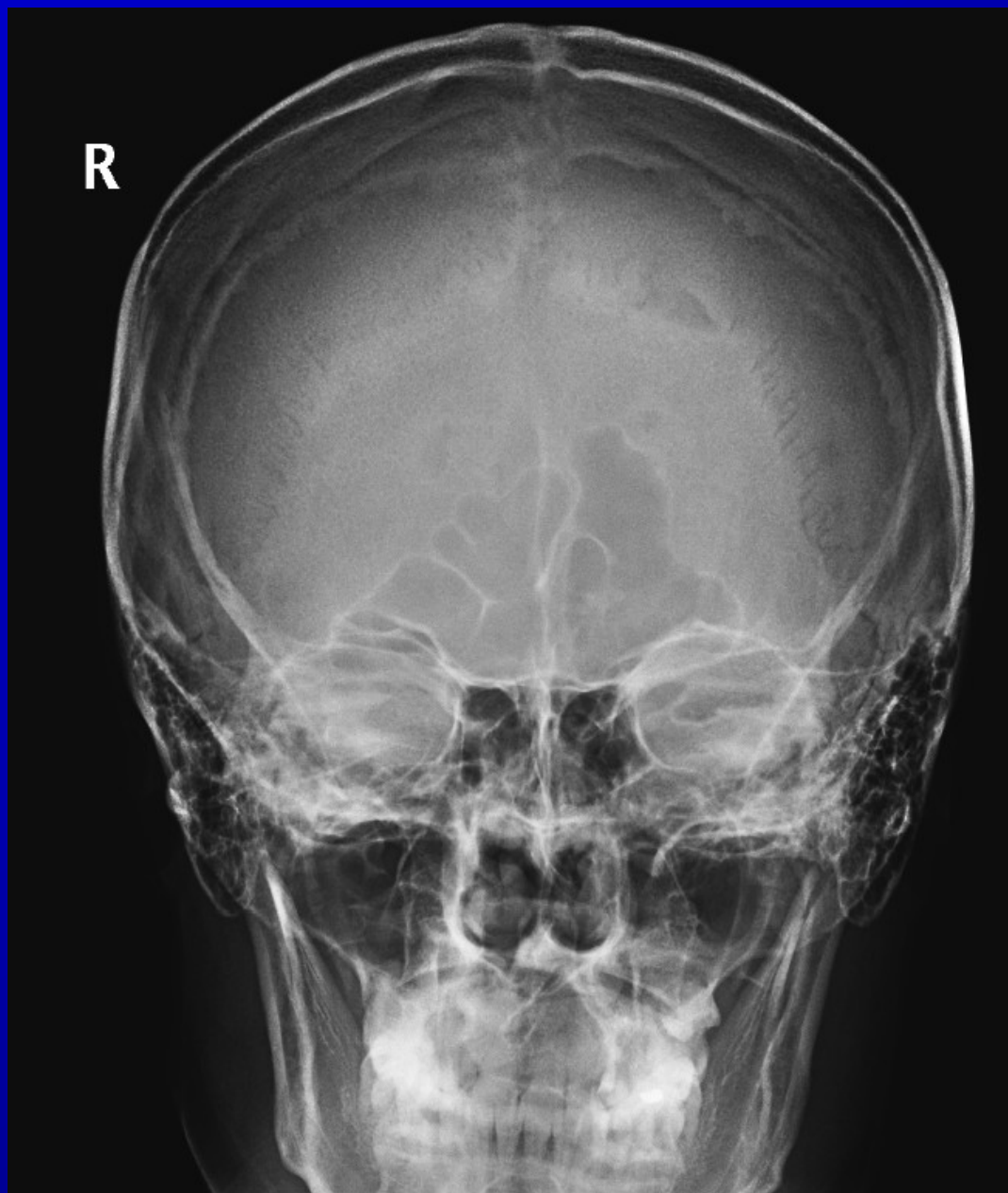*Radiologická klinika LF MU a FN
Brno - Bohunice*

Anatomie CT, MR - Mozek

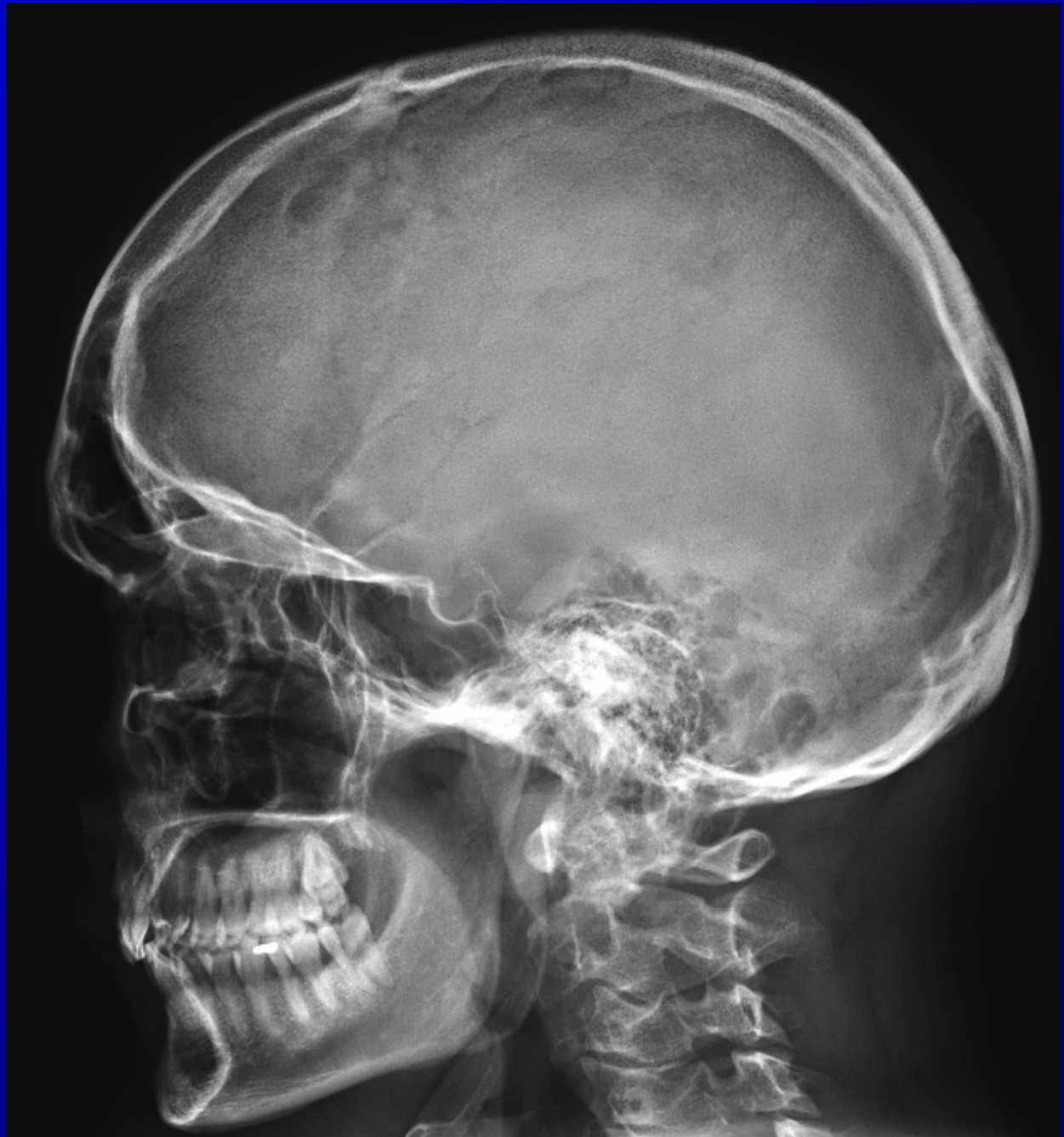- metodika vyšetření
- baze lební
- obaly mozku
- likvorové prostory
- mozková kůra
- bazální ganglia
- kmen, mozeček a hlavové nervy
- turecké sedlo



Skiografie – prostý rentgenový snímek (zadopřední projekce)



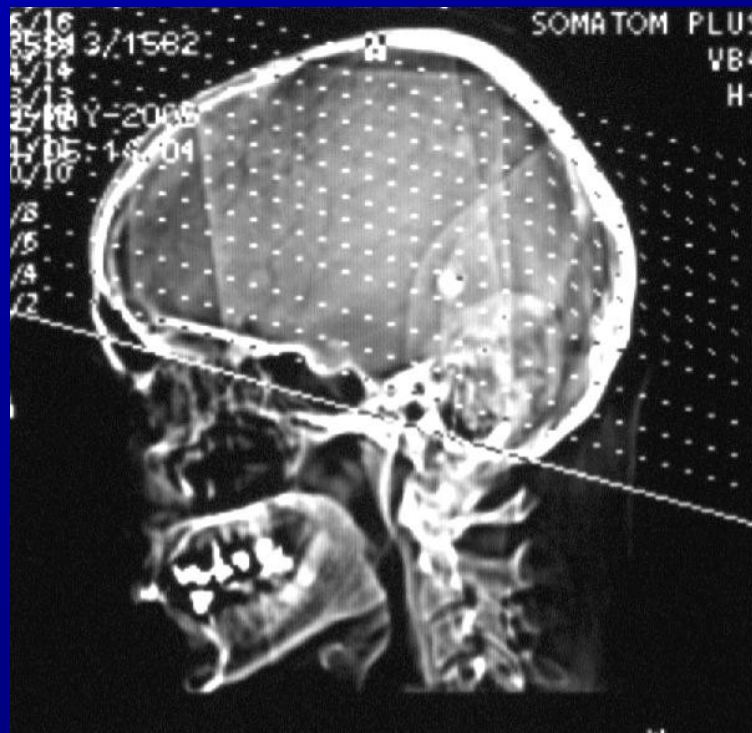
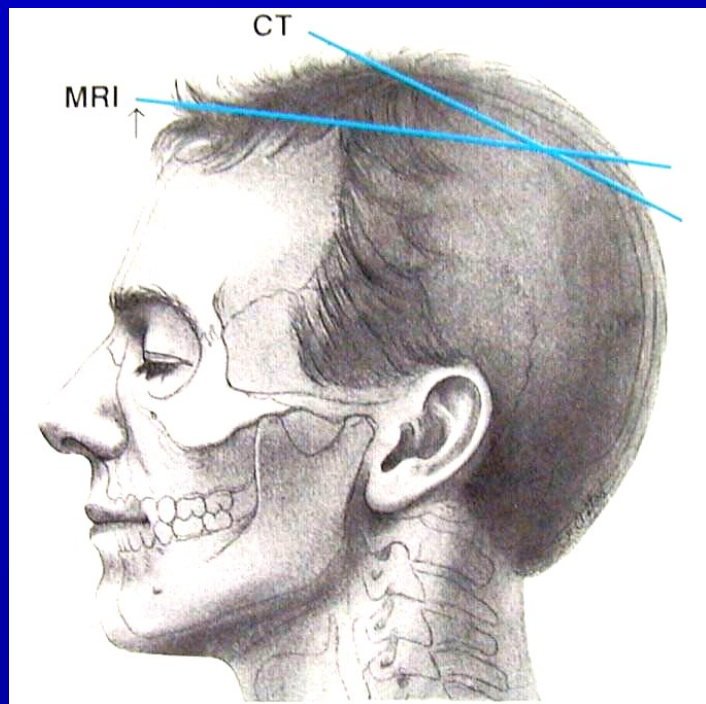
Skiagrafie – prostý rentgenový snímek (bočná projekce)

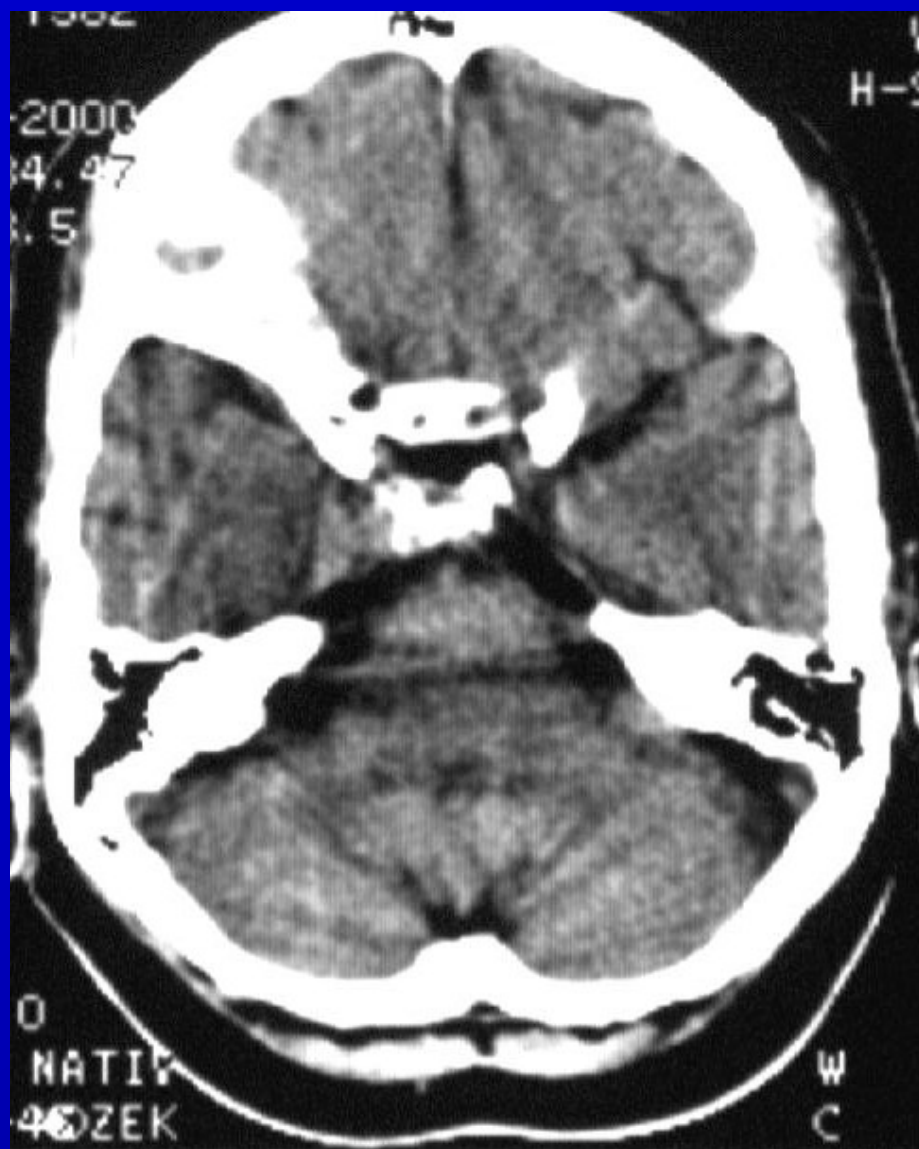


Metodika vyšetření

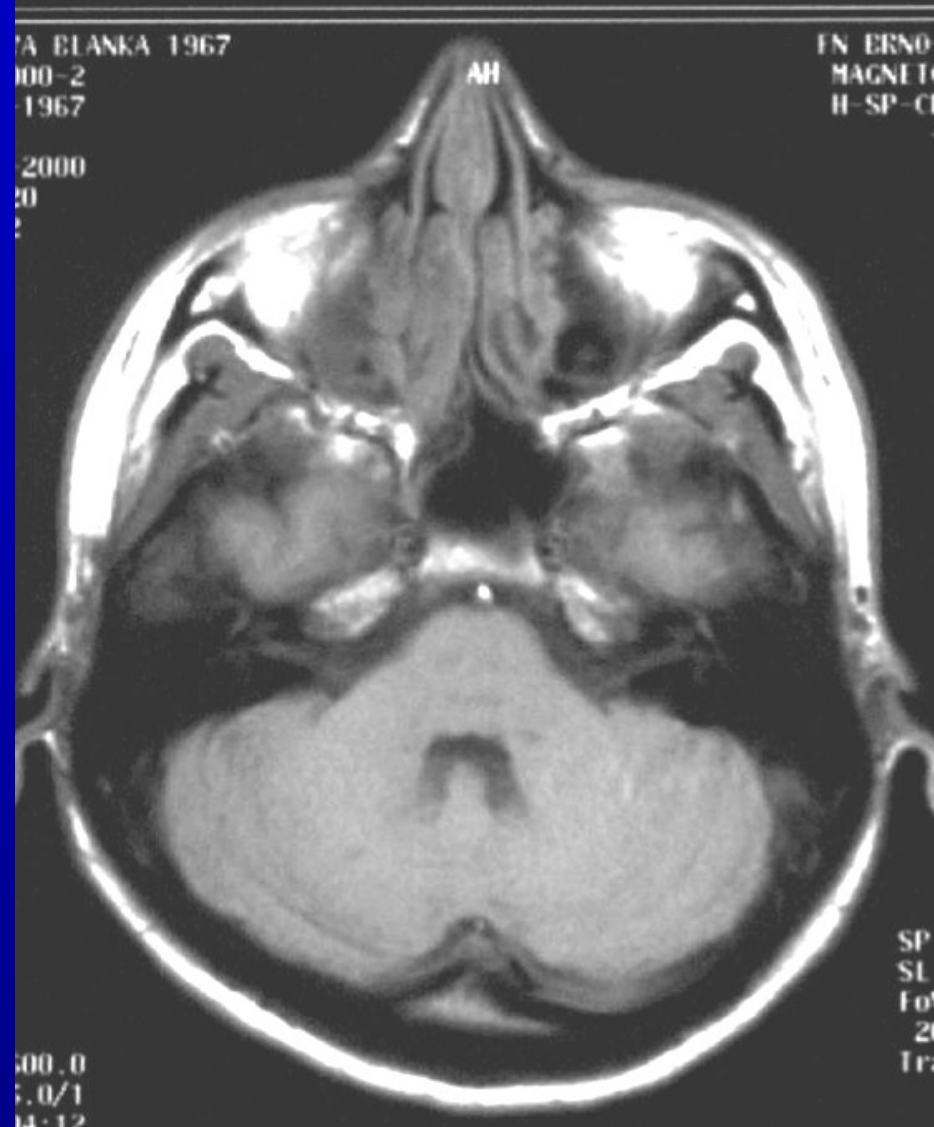
CT

- orbitomeatální linie, je-li možné, nelze u MDCT
- zadní jáma 5mm, dále 8mm
- HRCT, spirální, 3D, CTAG
- artefakty – zadní jáma, kov





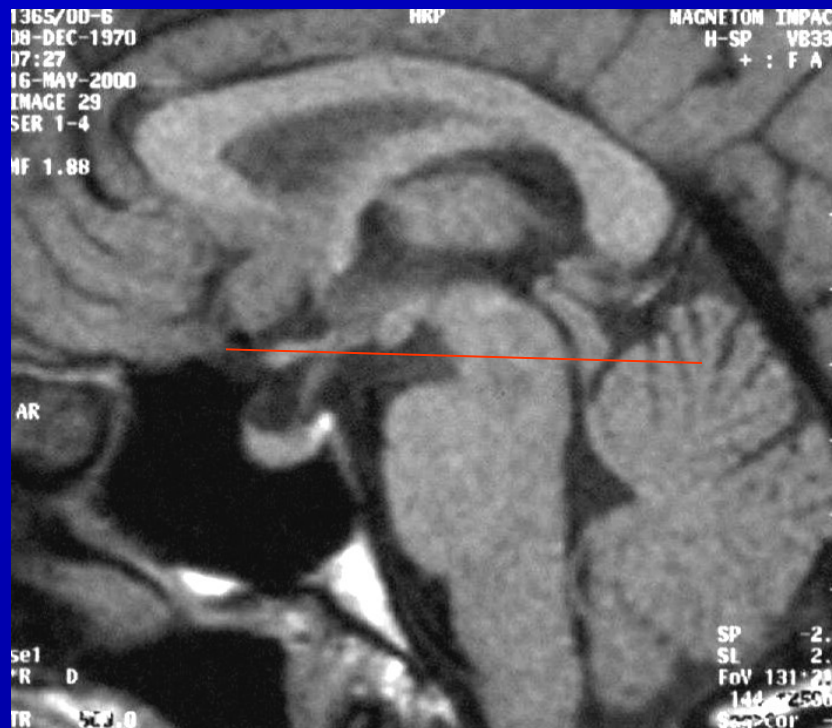
CT



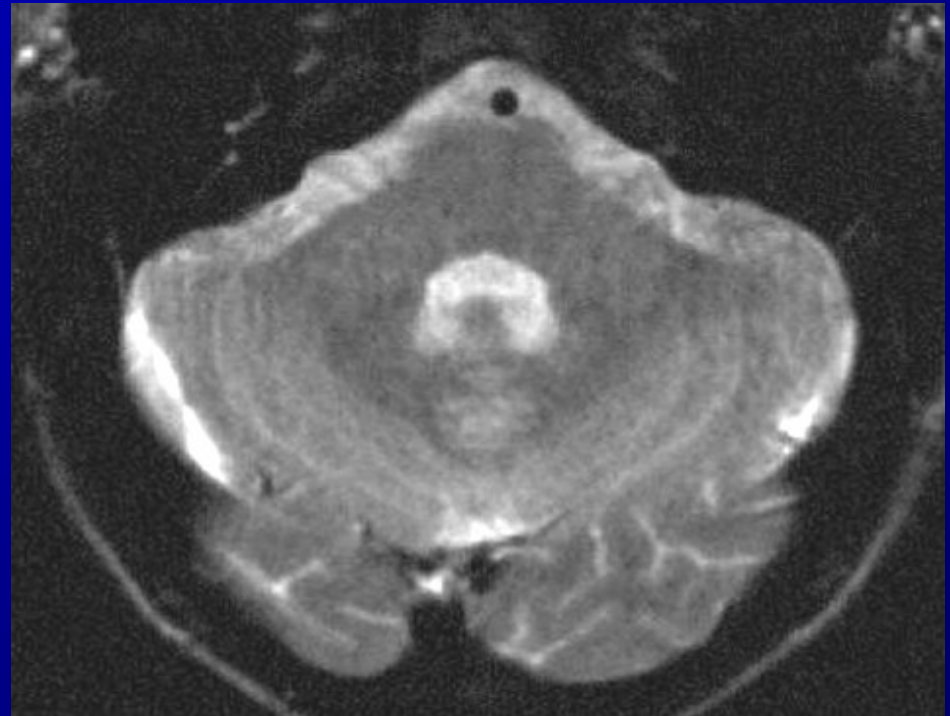
MR – T1 obraz

MR

- všechny tři základní roviny
- commisura ant.-post.
- různé typy sekvencí - AG,3D.....
- artefakty - pohyb - cévy, pacient (pohyb)
- kov



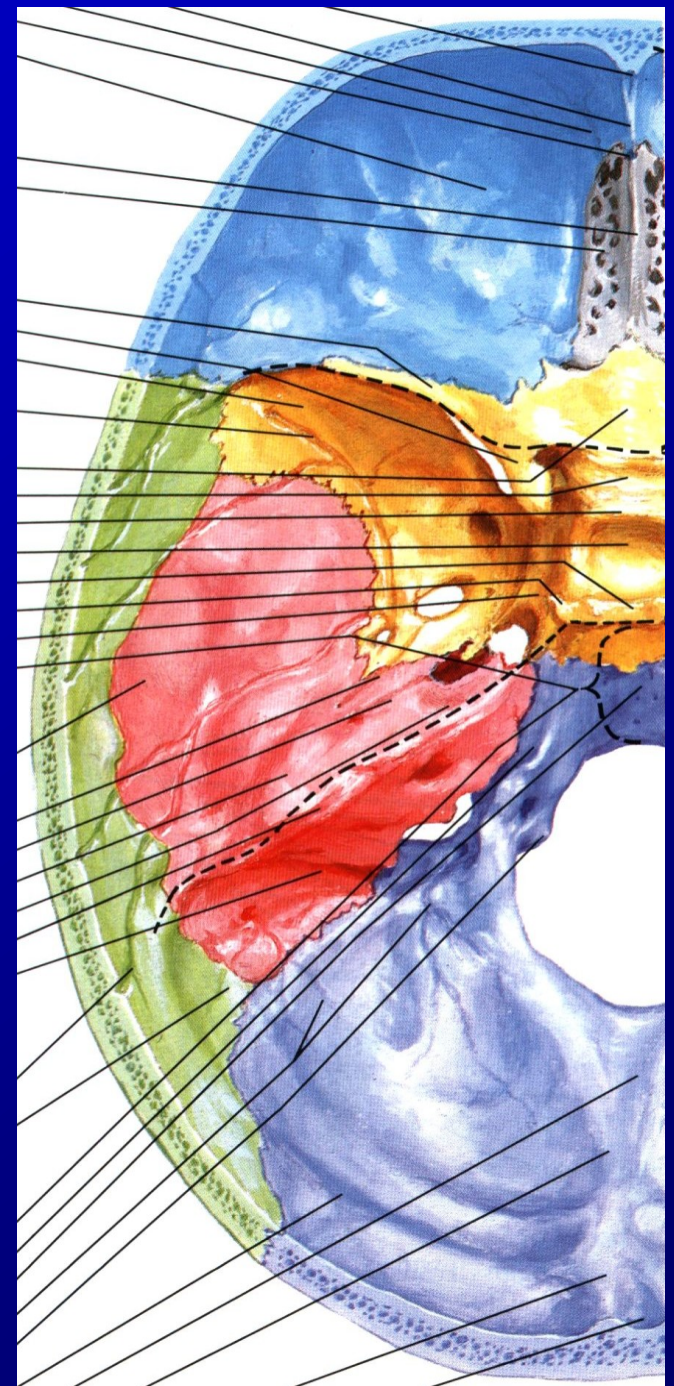
T1 obraz – commisura ant.-post.



T2 obraz – zadní jáma lební

Baze lebni

Skelet - os ethmoidale
os sphenoidale
os occipitale
os frontale
os temporale



Baze lební

Foramina a jejich obsah

Os ethmoidale

Lamina cribiformis - n.I

Os sphenoidale

f.ovale - n.V₃, vv.emm.

f.spinsum - a.mening.media

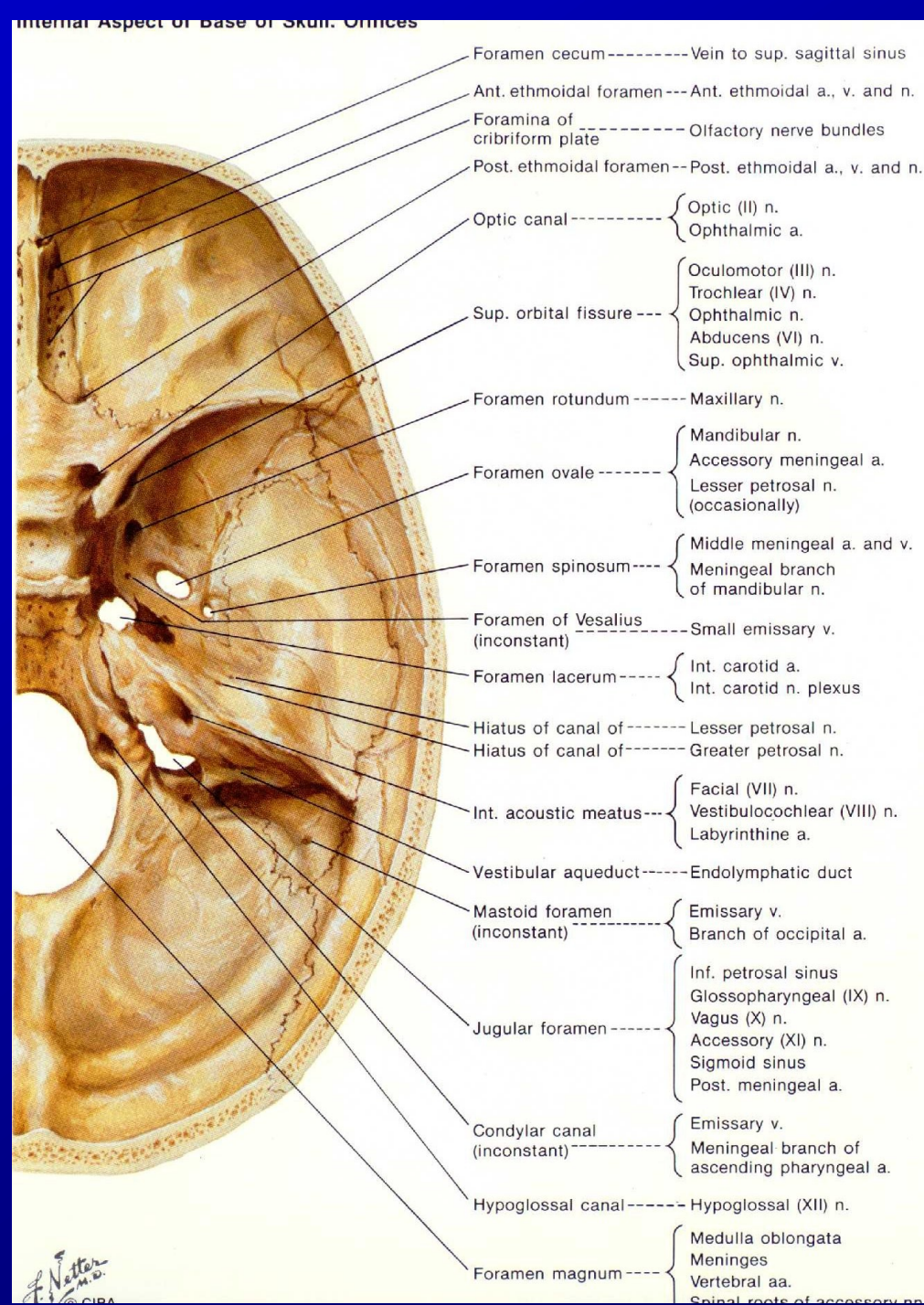
f.rotundum - n.V₂, vv.

optický kanál - n.II,AO,mok

fiss.orb.sup. - III.,IV.,V.,v.opht.

karotický kanál - ACI

f.lacerum - nic



Baze lebni

Os occipitale

f.magnum - XI., mícha, AV
can.hypogl. - XII.

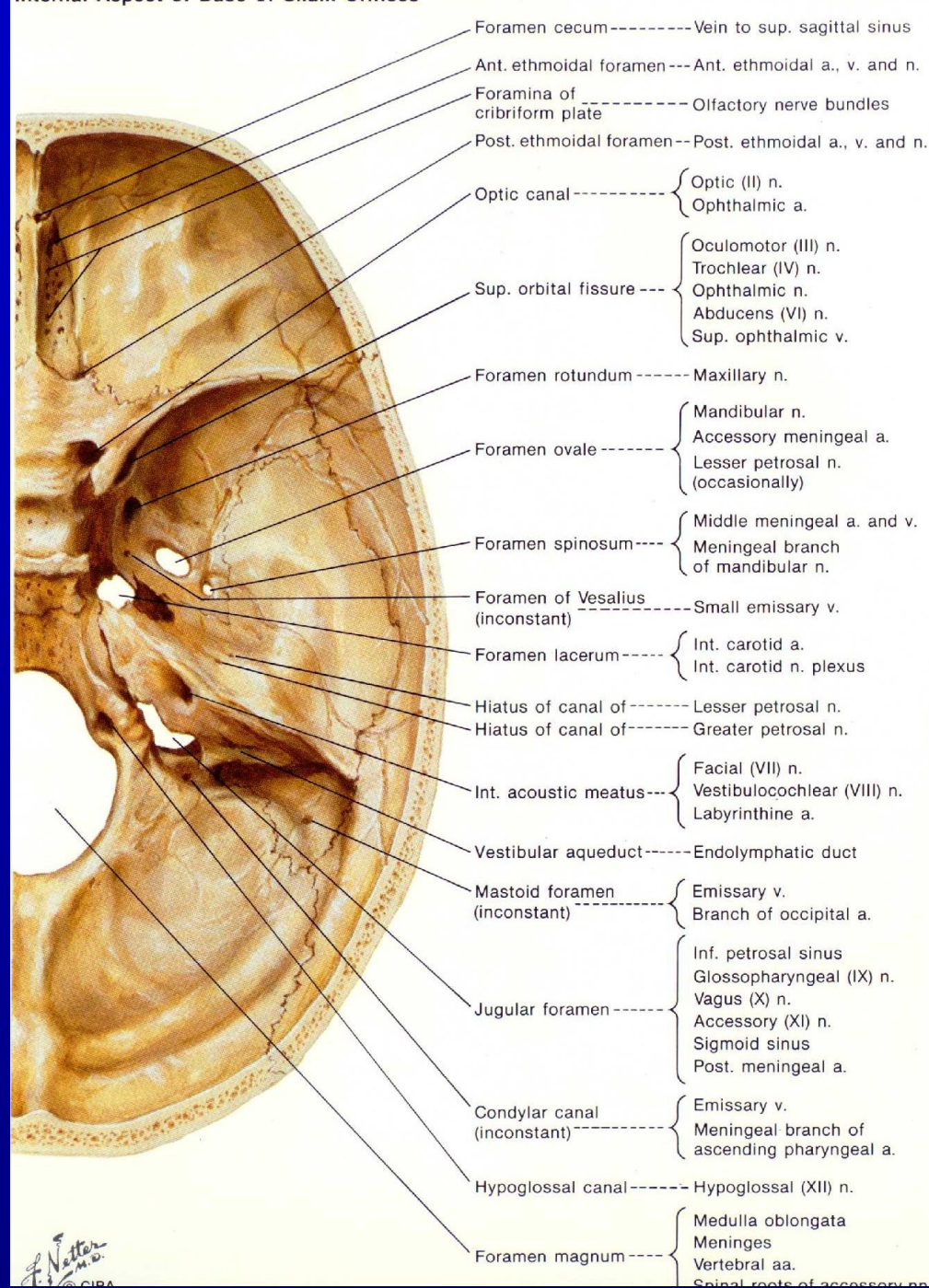
Os temporale

f.jugulare - IX,X.,XI,v.jug-
canalis n.VII.
can.ac.int. - VII.+VIII.

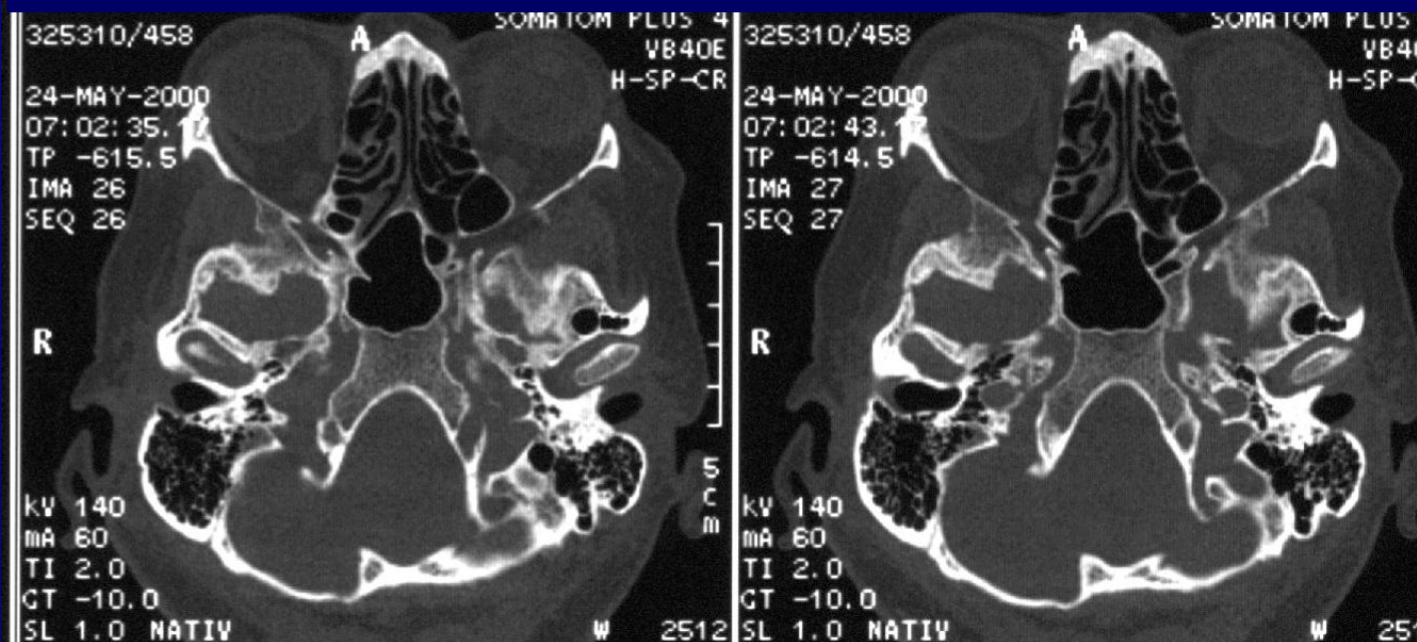
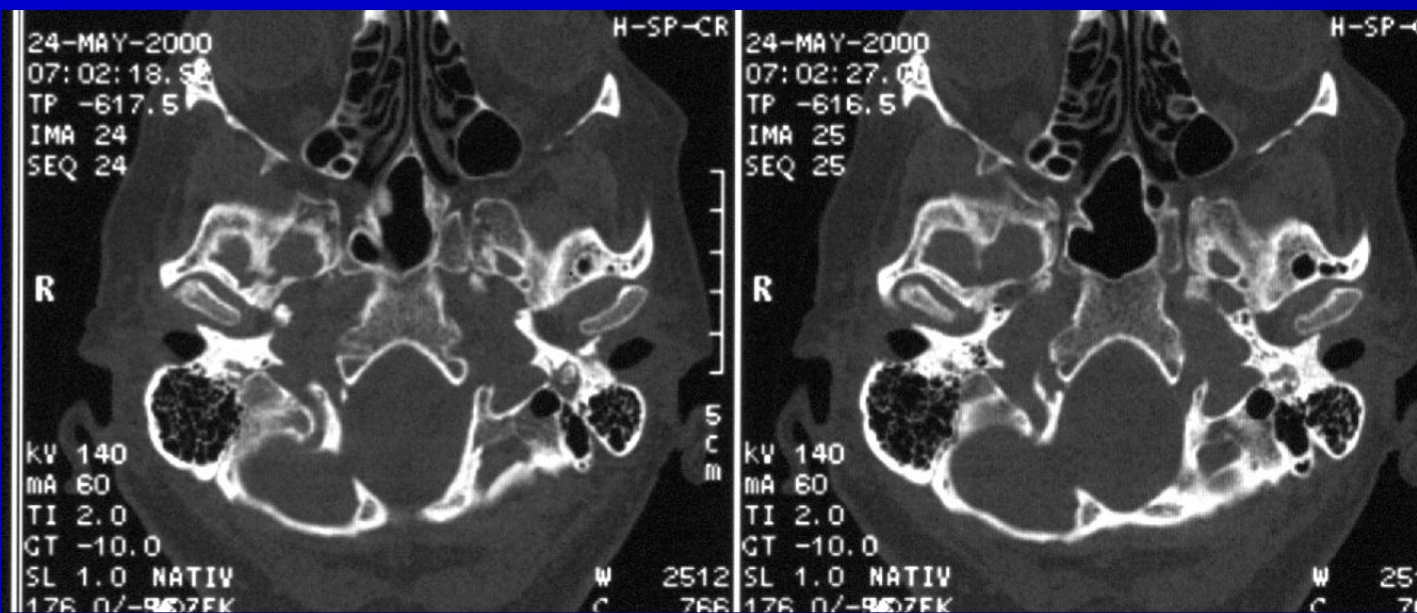
Varianty !!!

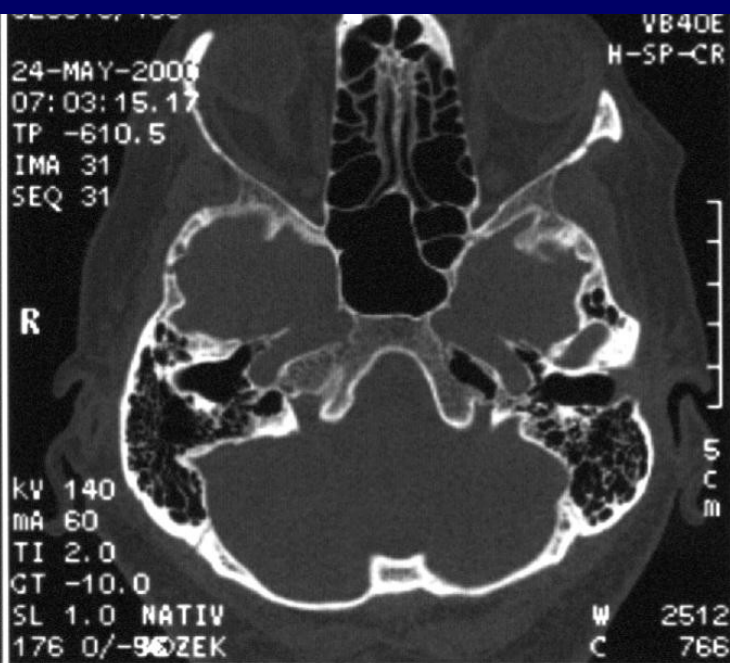
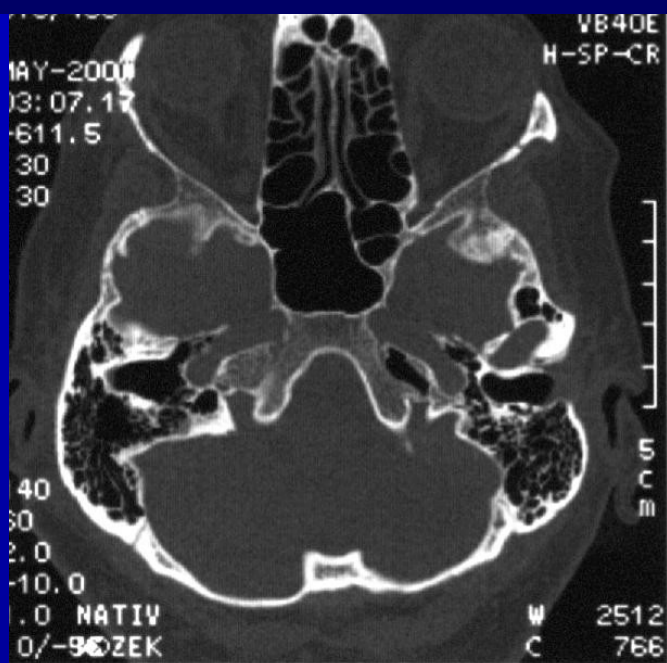
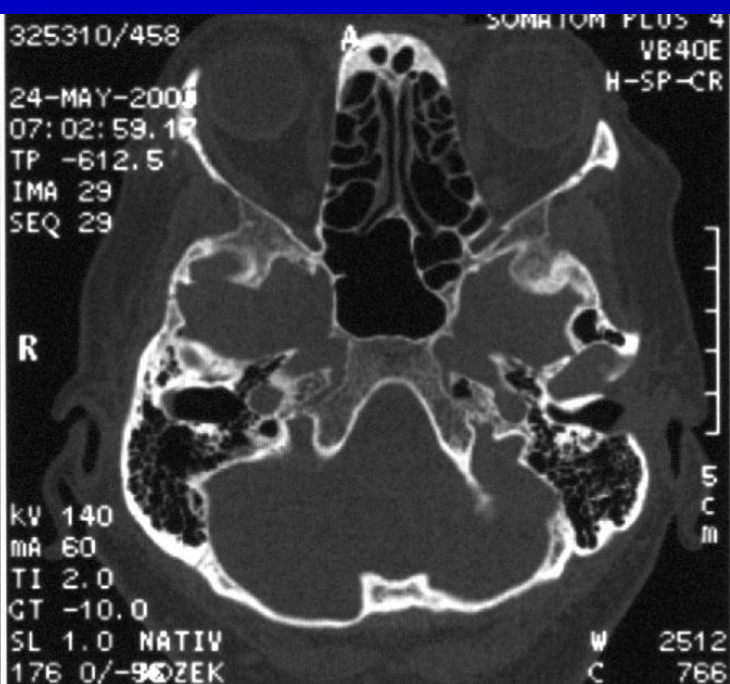
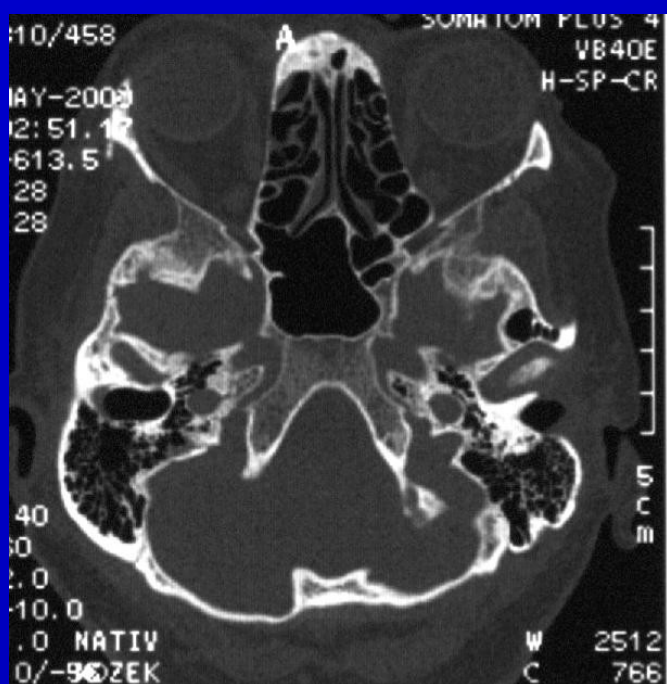
f.jugulare

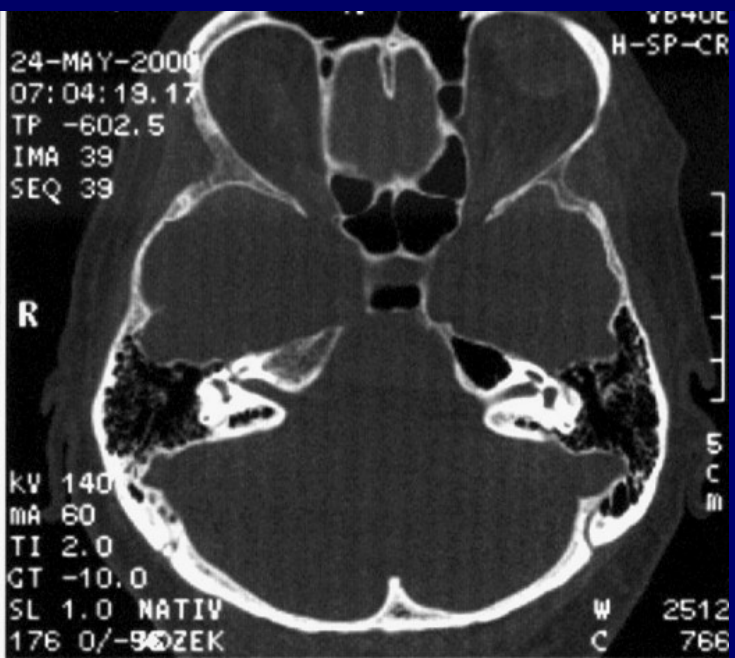
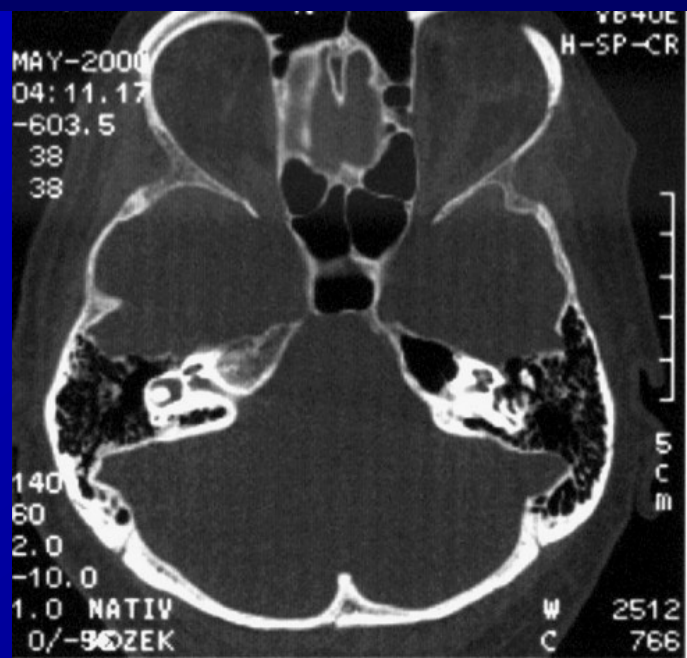
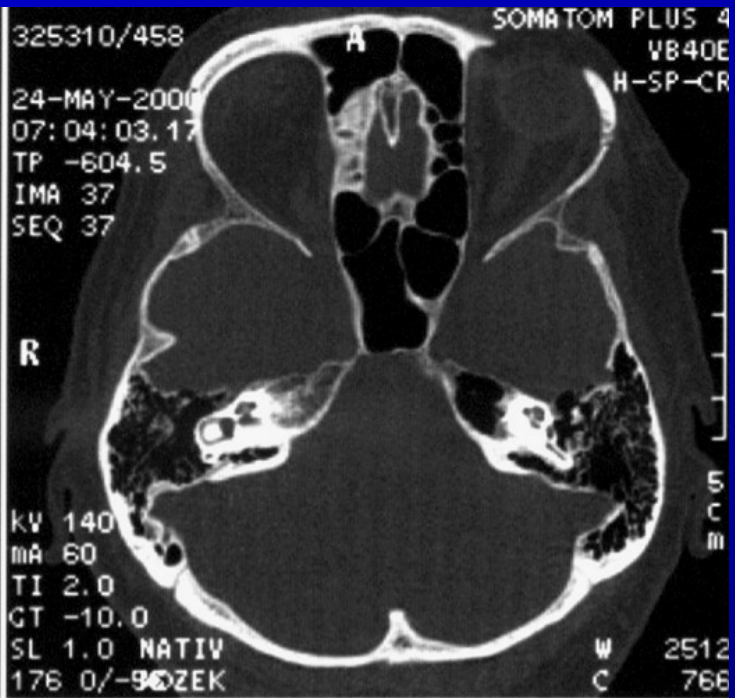
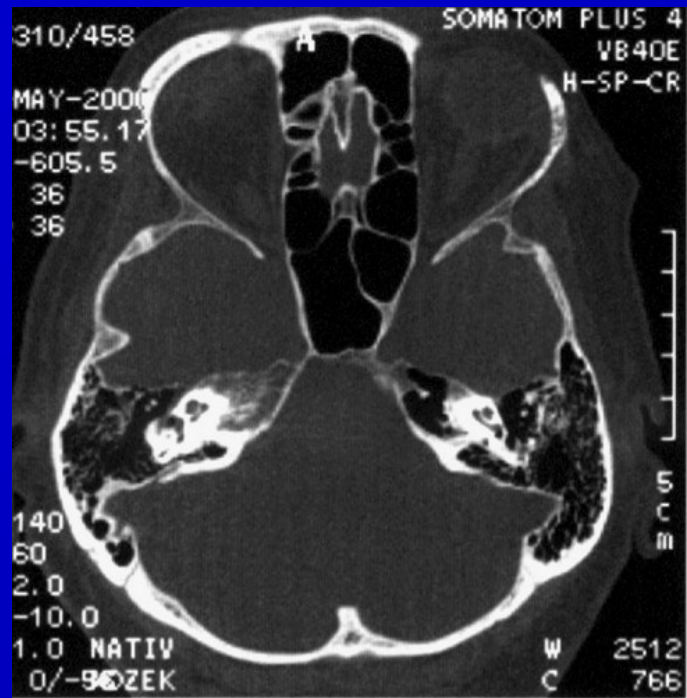
Internal Aspect of Base of Skull. Orifices



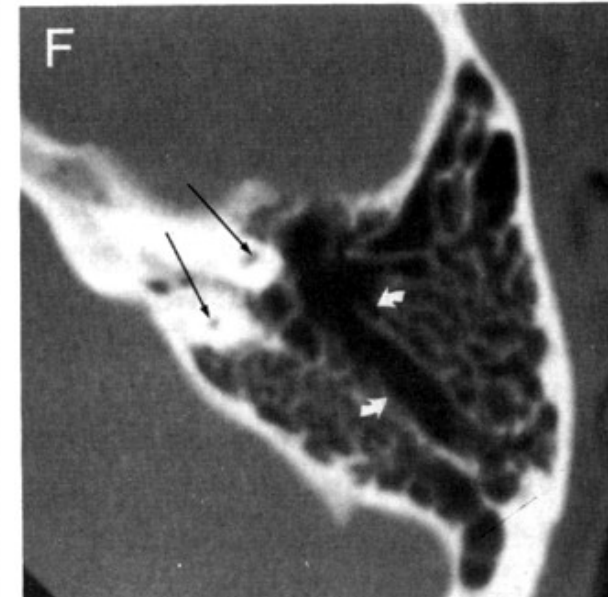
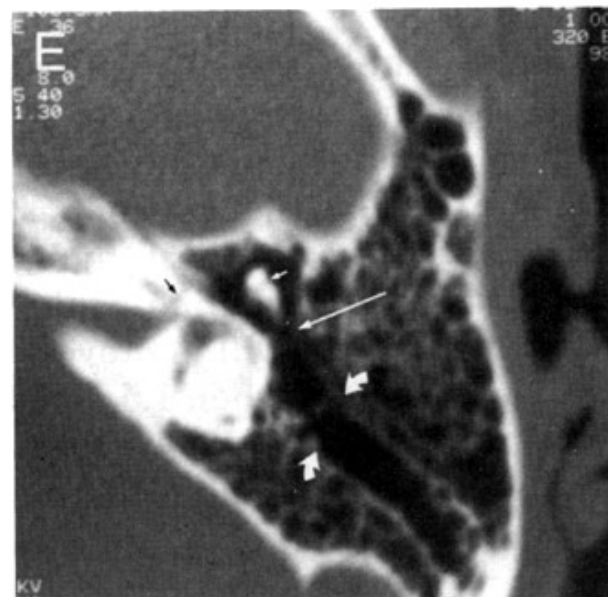
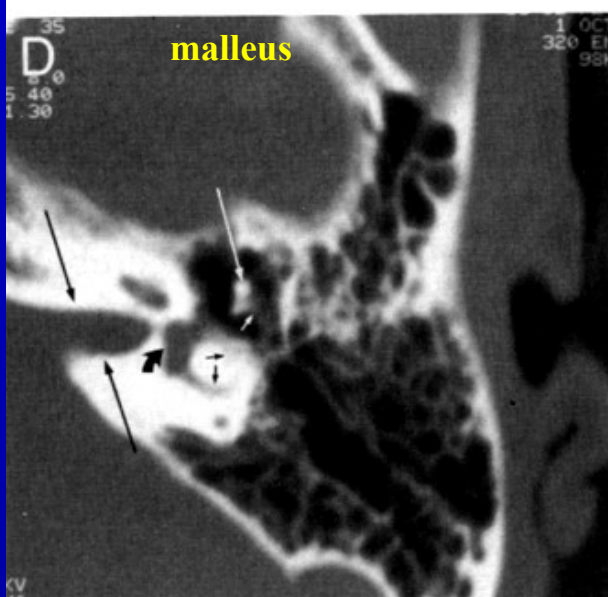
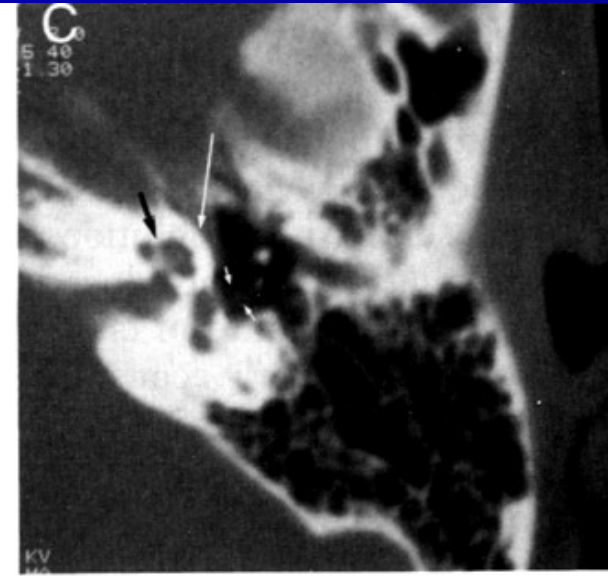
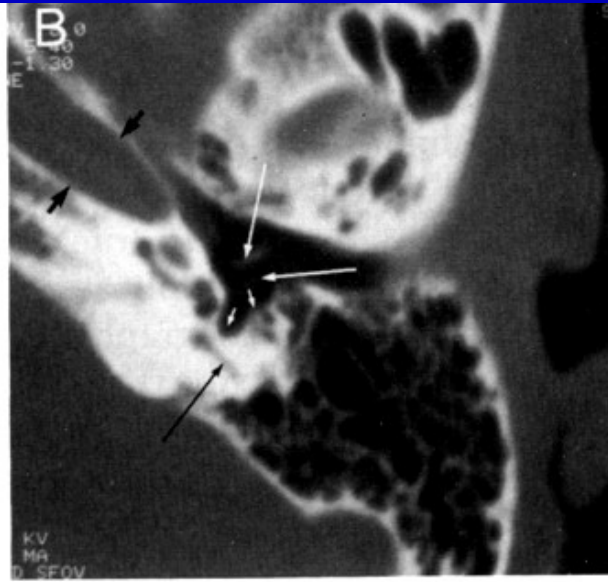
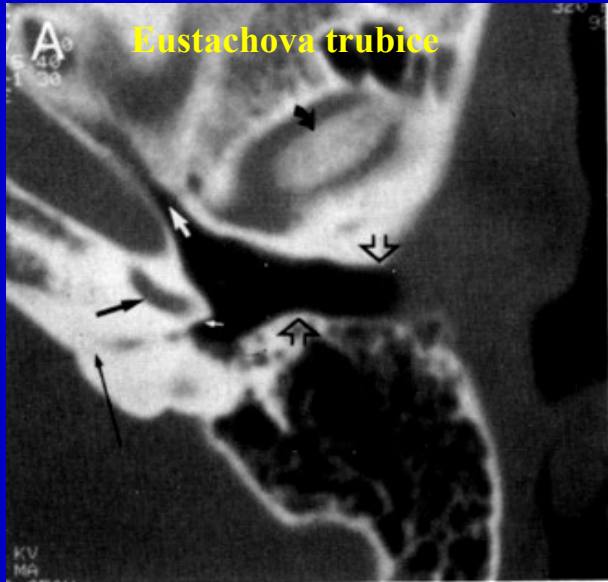CT baze lební, HR přepočet

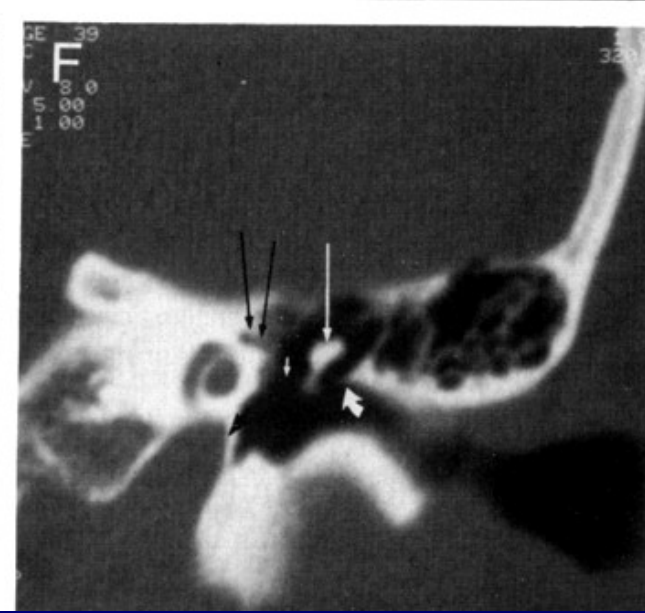
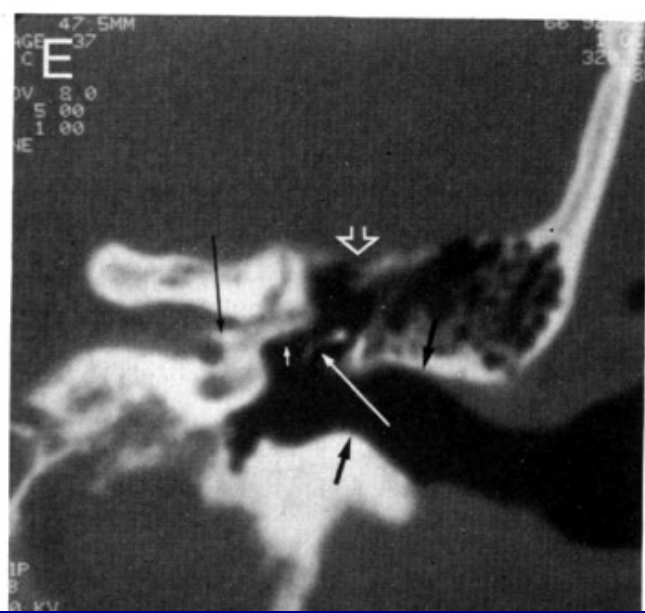
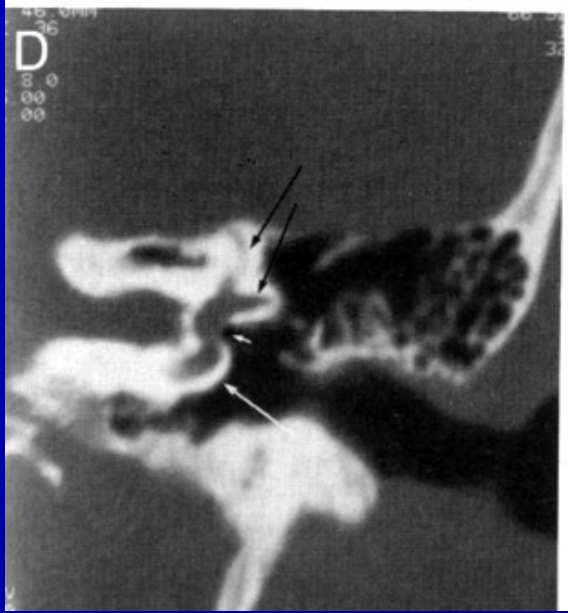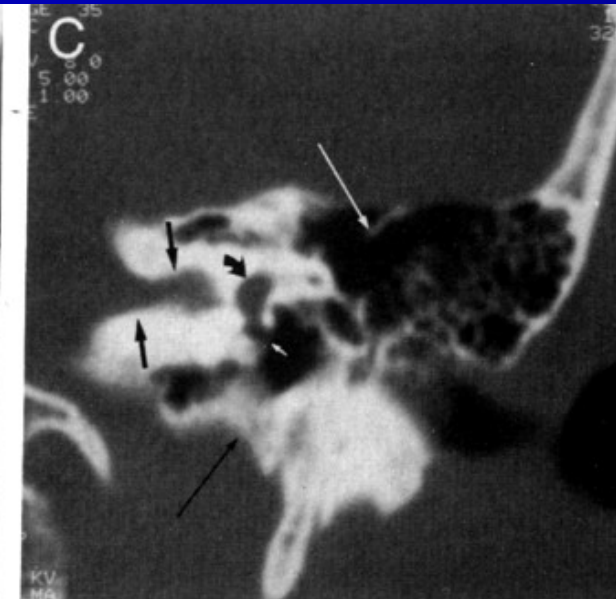
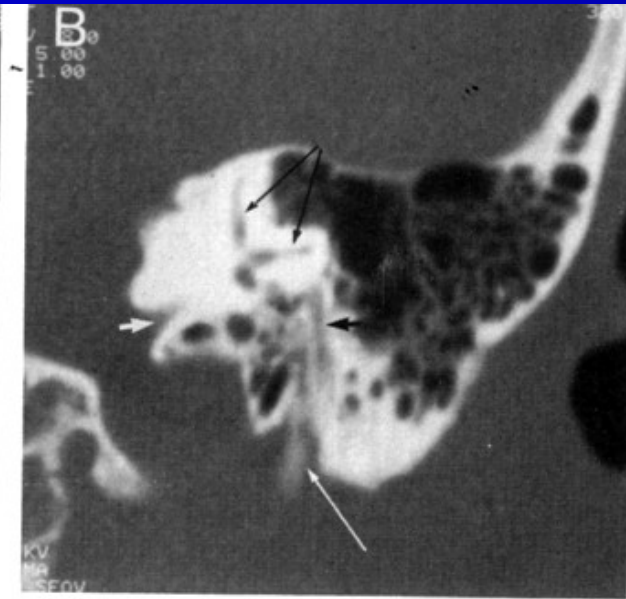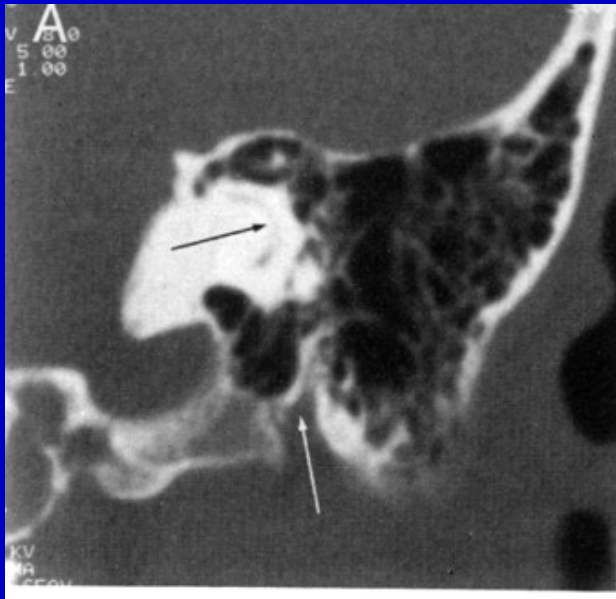


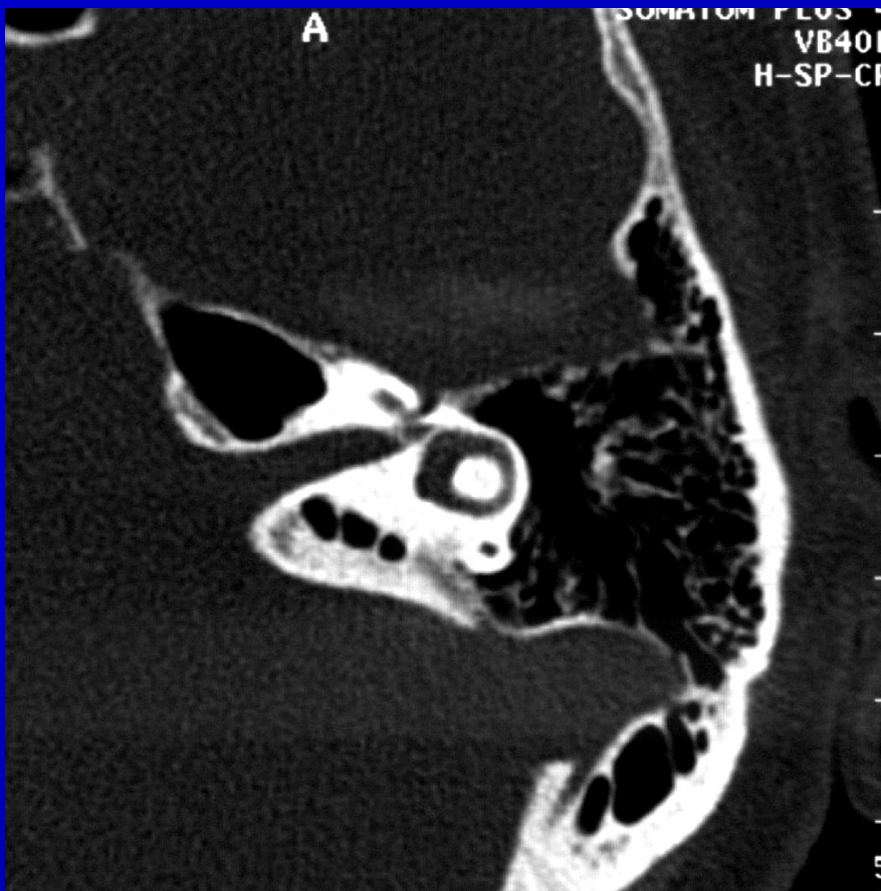




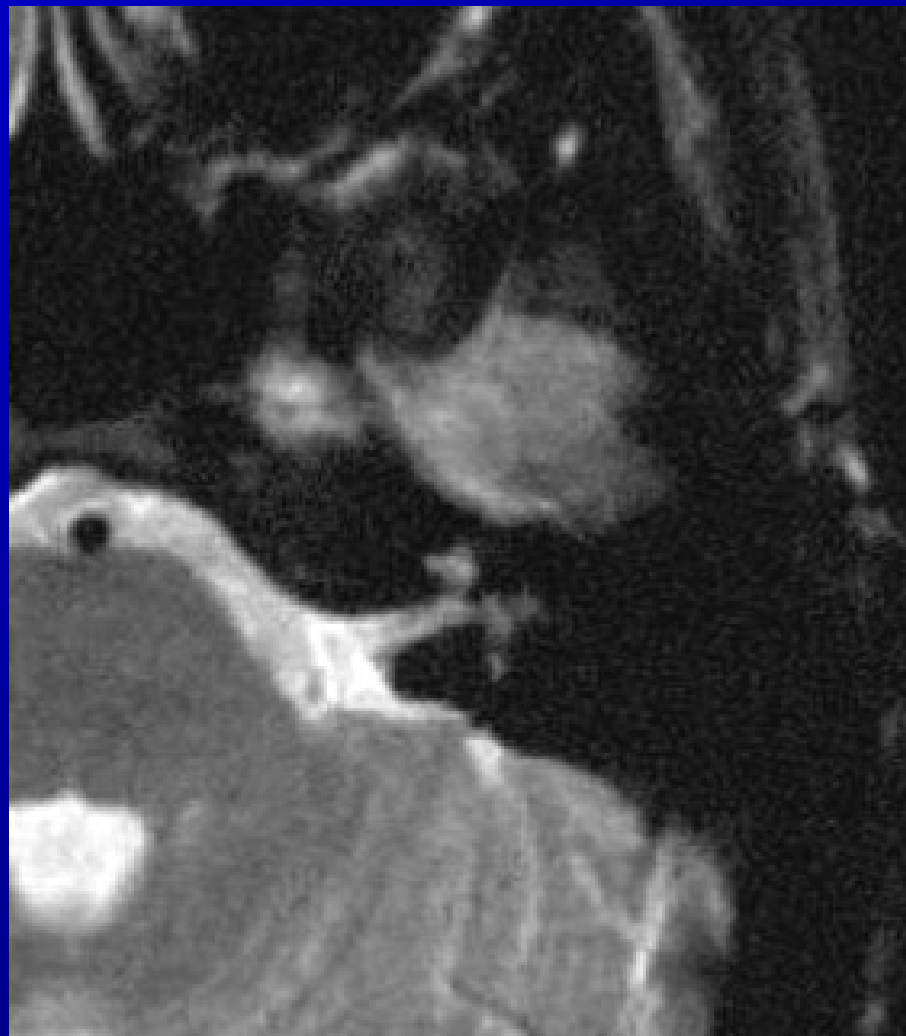
HRCT kosti spánkové







HRCT pyramidy



T2 obraz pyramidy

Likvorové prostory

Komory

Čtvrtá komora

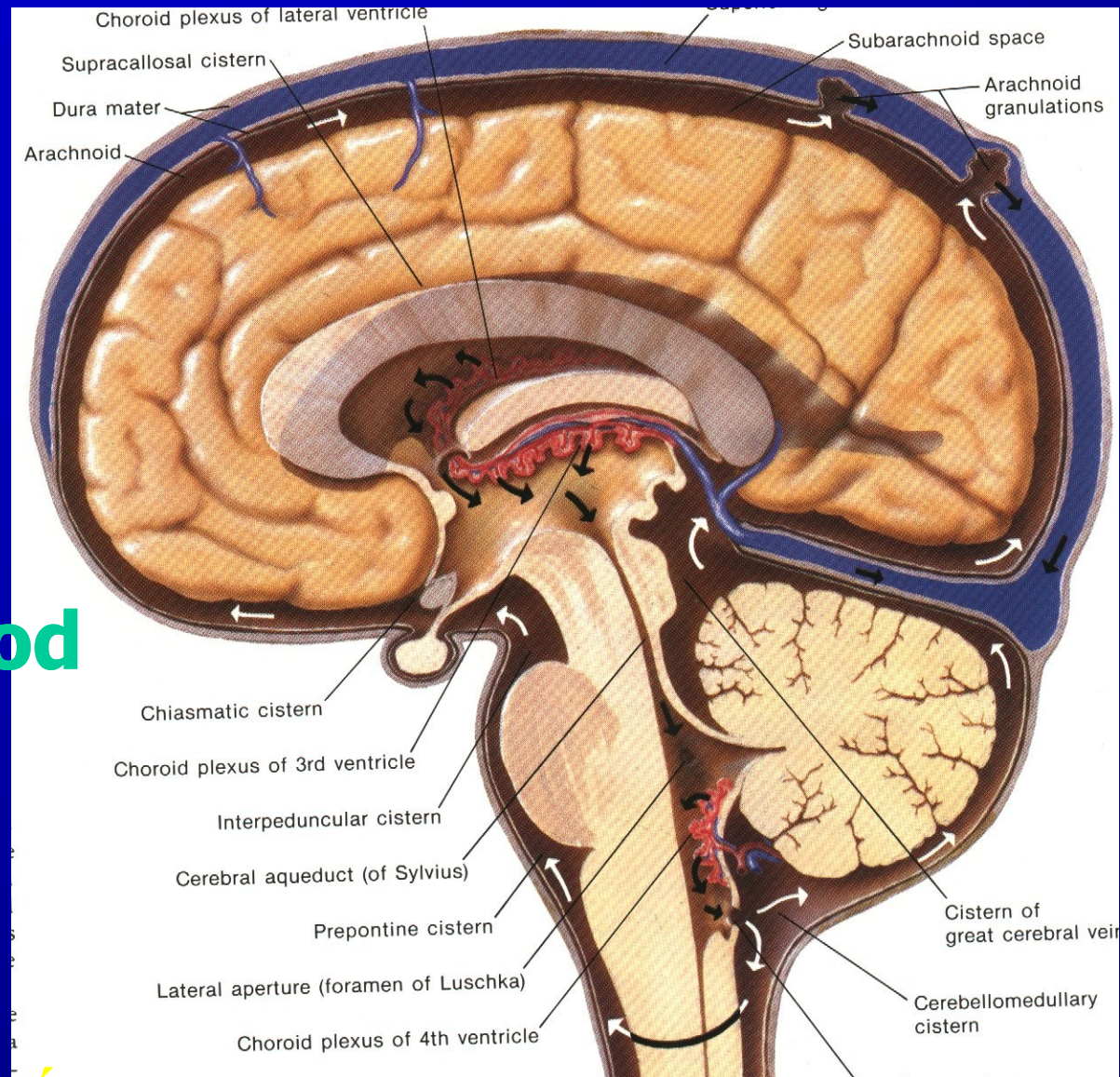
- ↑ mokovod
- ↓ obex a centr.can.
- f.Magendie - post-inf
- ff.Luschka - post.-lat

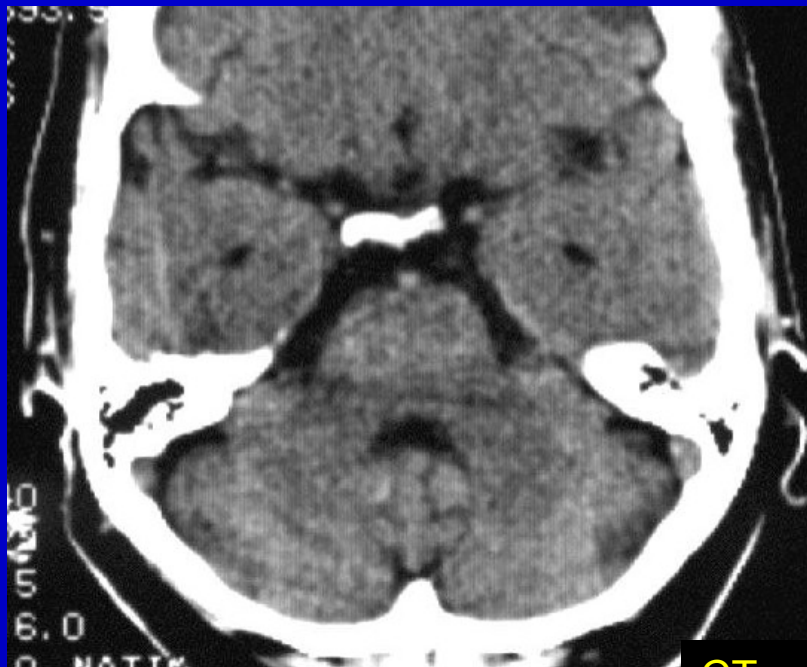
Sylviův mokovod

tegmentum/tektum

Třetí komora

- mezi thalamy
- recessy - optický
 - infundibulární
 - suprapineální

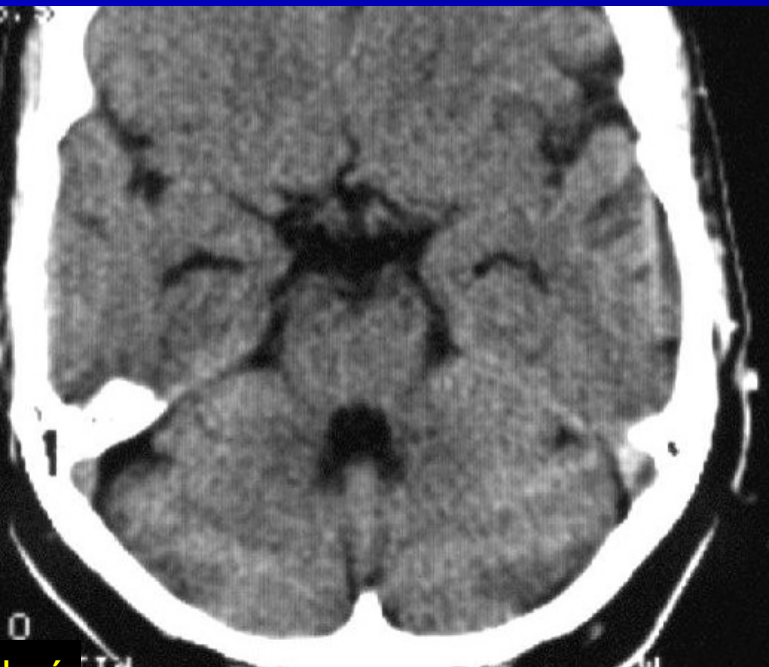



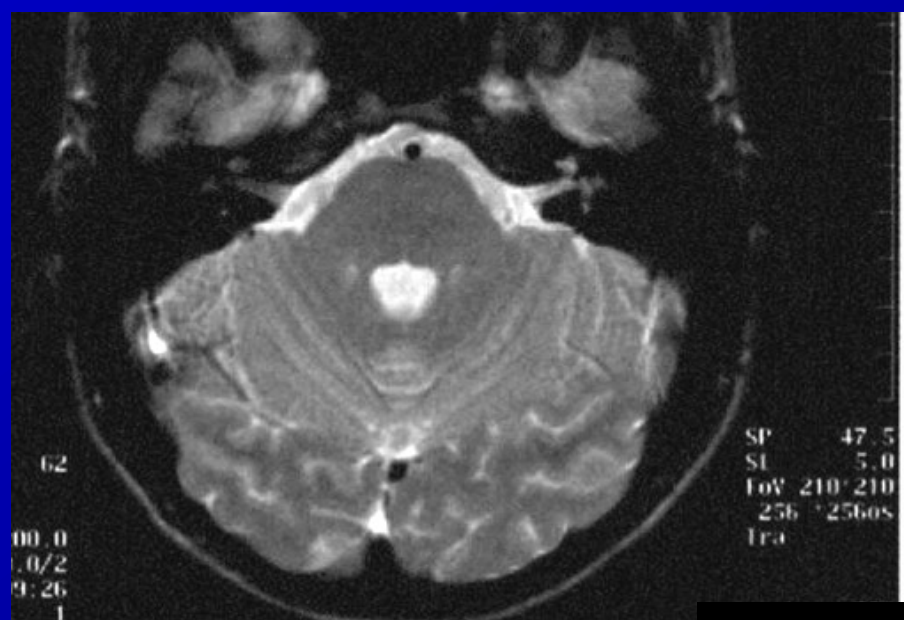
IP -588.5
IMA 7
SEQ 7

R

KV 140
MA 125
C TI 1.5
M CT -16.0



CT – zadní jáma lební

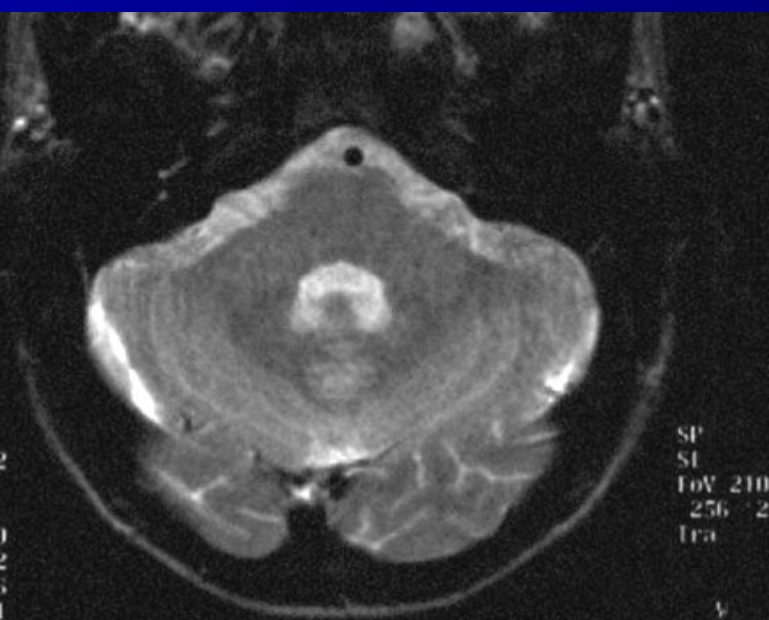


R

SP 47.5
SI 5.0
FoV 210:210
256:256os
Tra

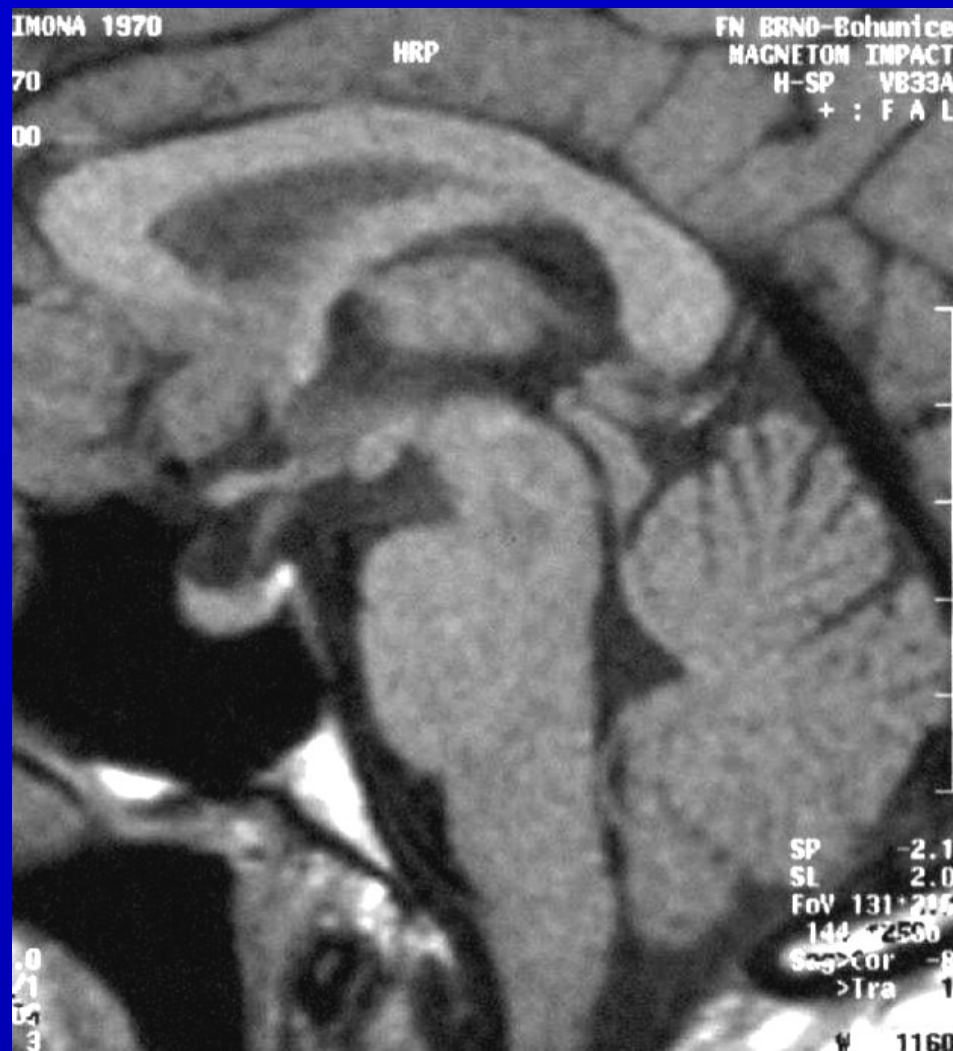
so2 62
R D

TR 2200.0
TI 80.0/2
TA 09:26

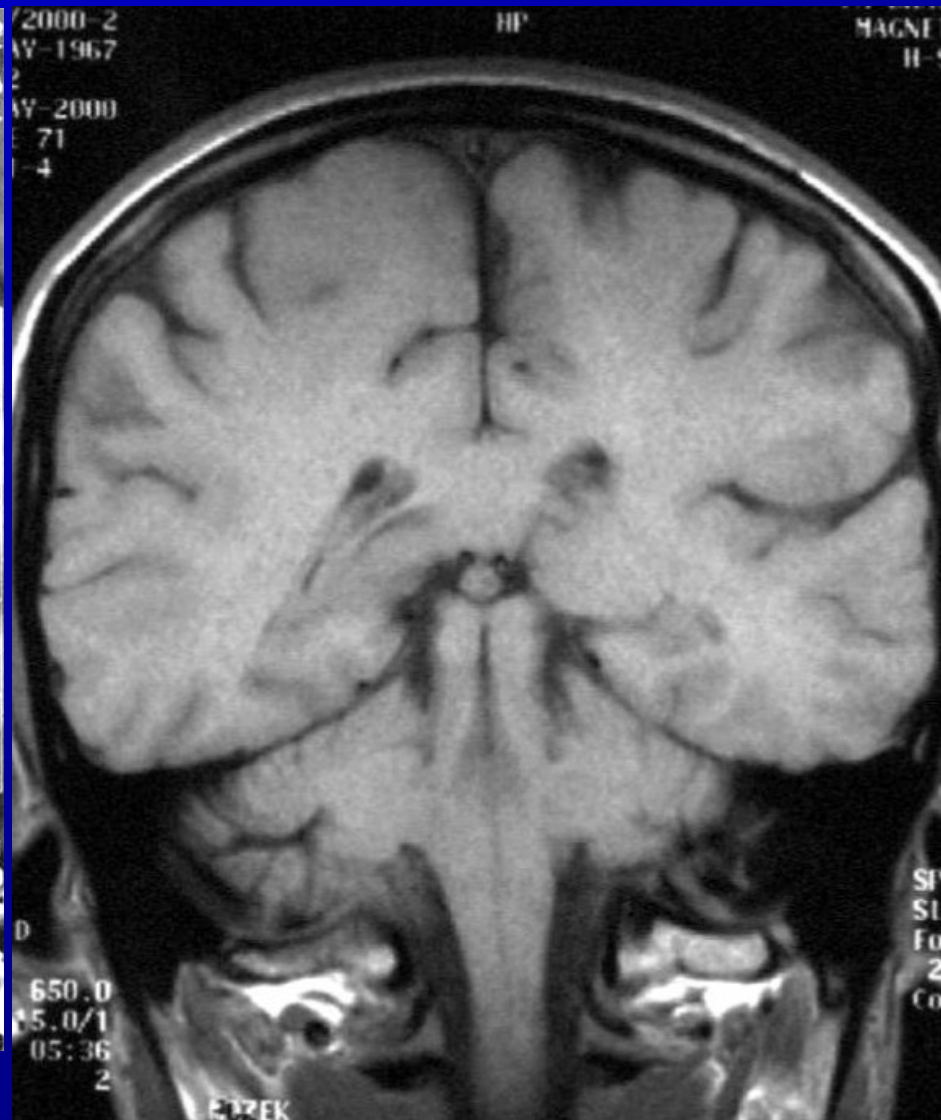


SP 47.5
SI 5.0
FoV 210
256:256
Tra

MR – T2 obrazy

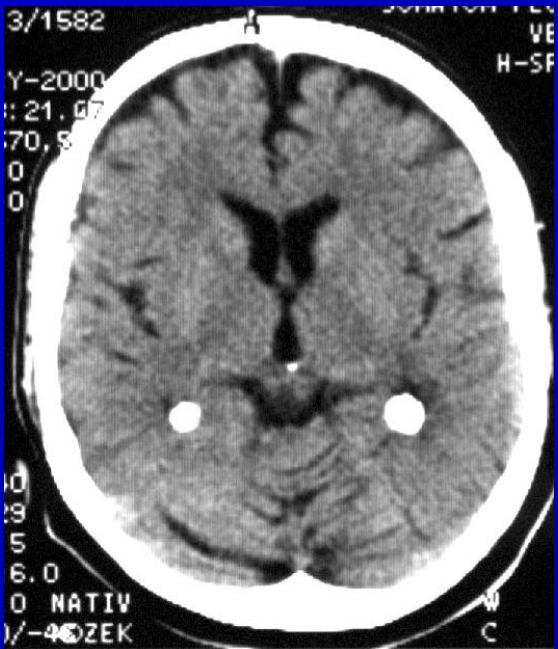
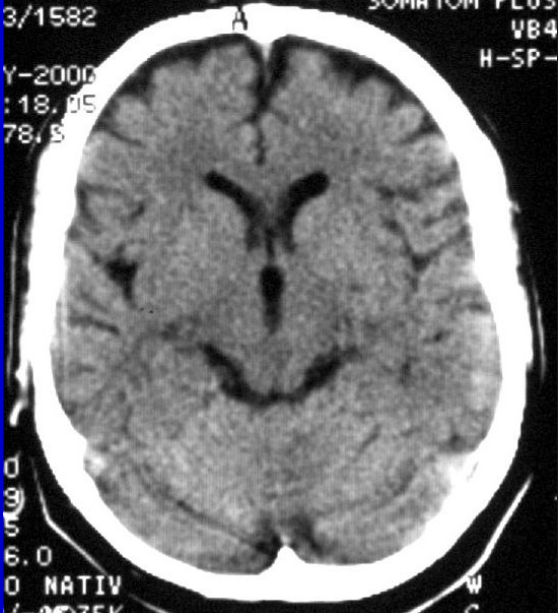

T1 obraz – sagitální rovina

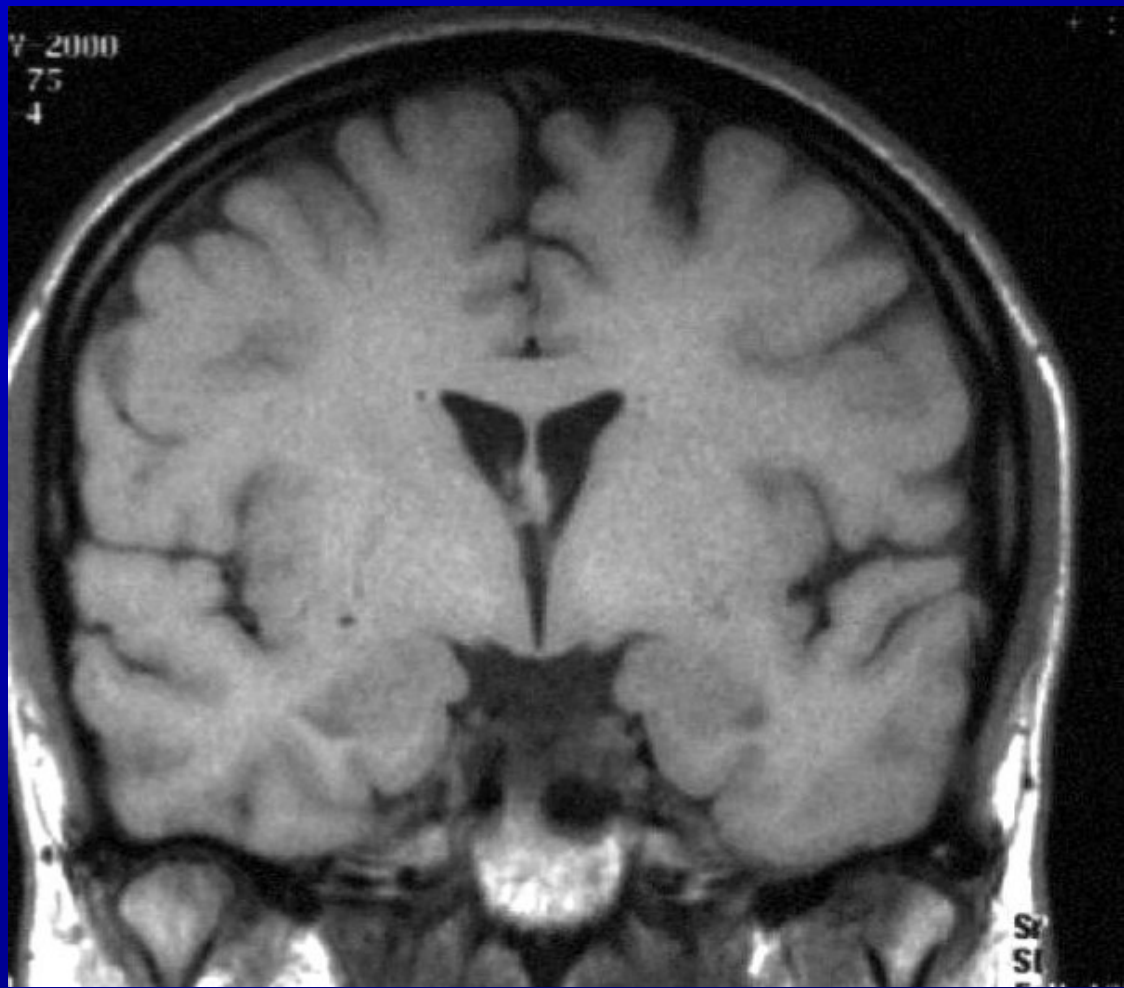


T1 obraz – koronární rovina

Třetí komora



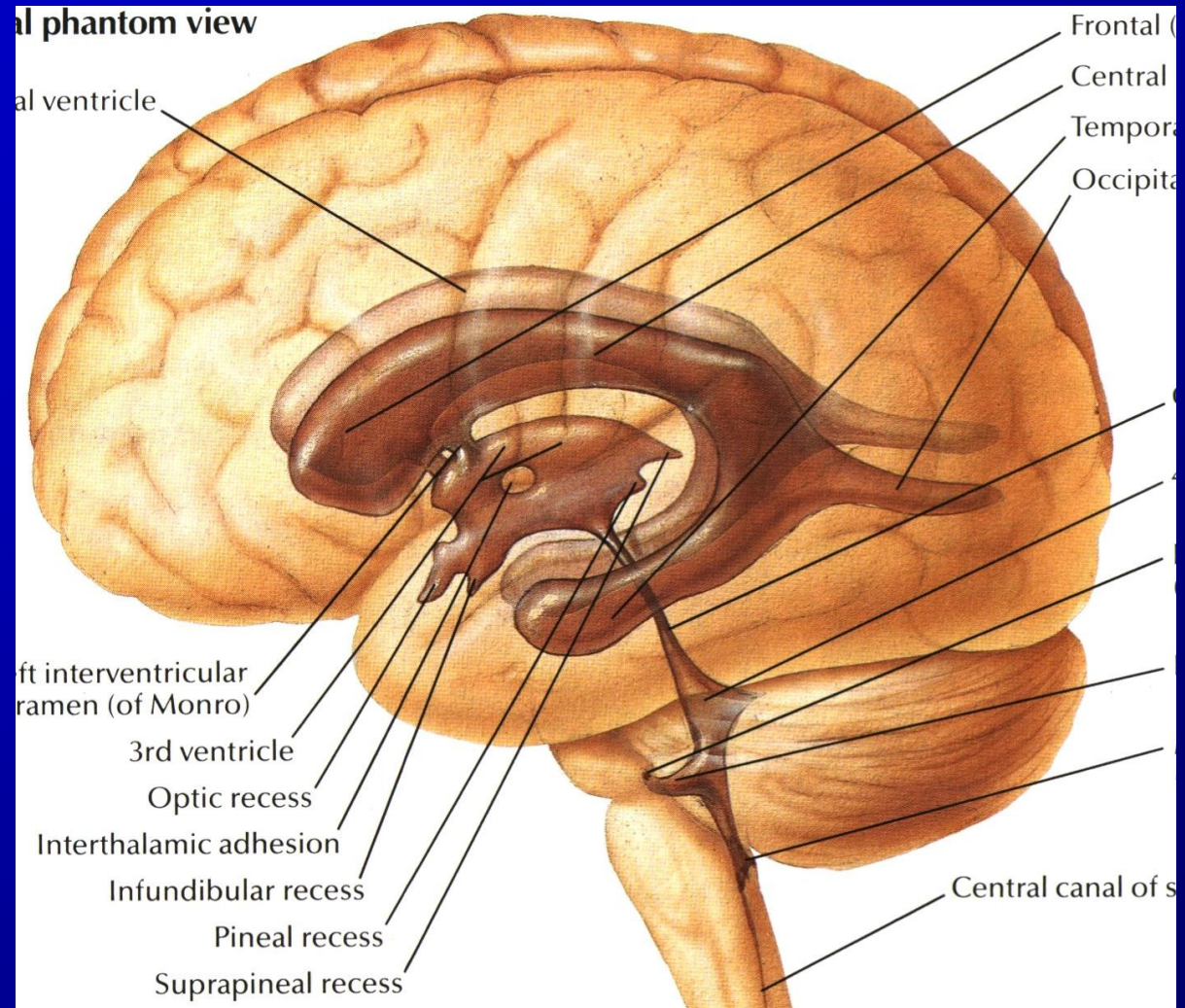
CT

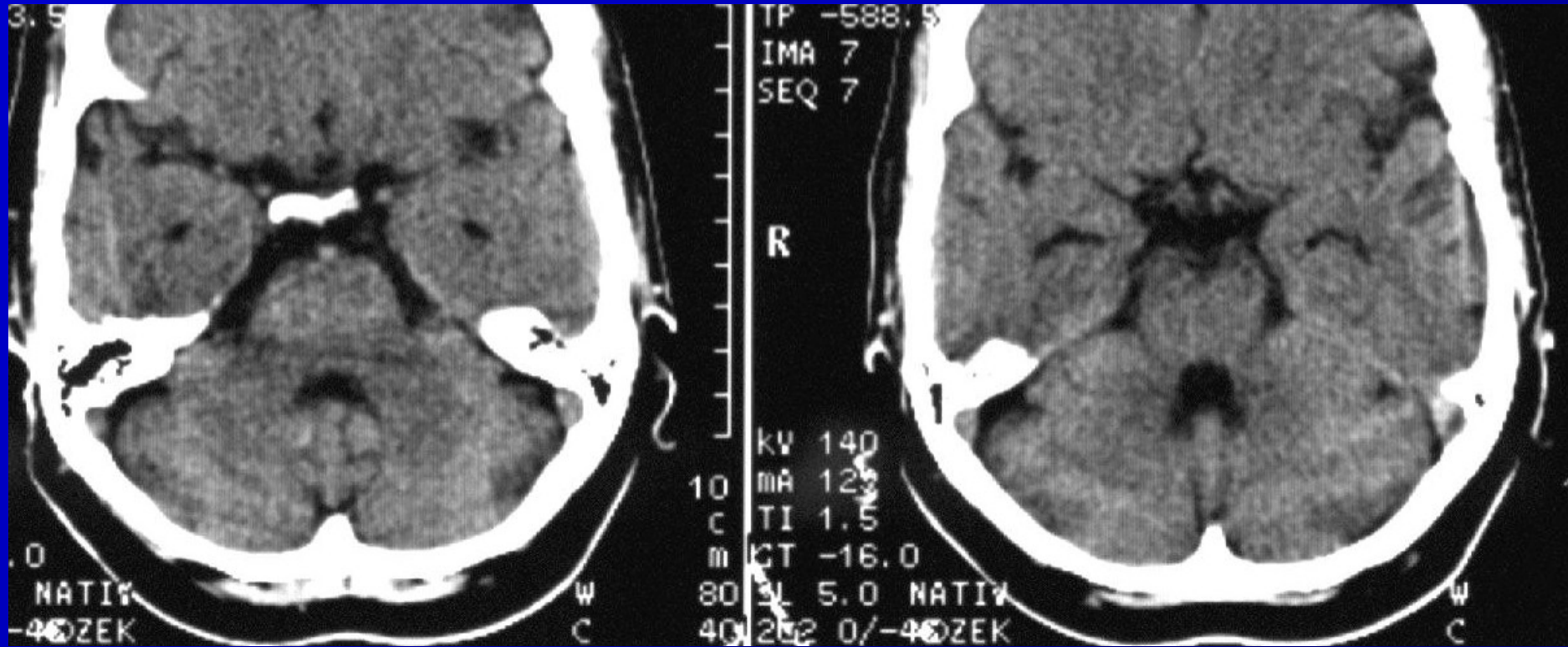


MR – T1 obraz

Postranní komory

- čelní roh, tělo, trigonum, occ.+temp.rohy
- f.Monroi tvar Y

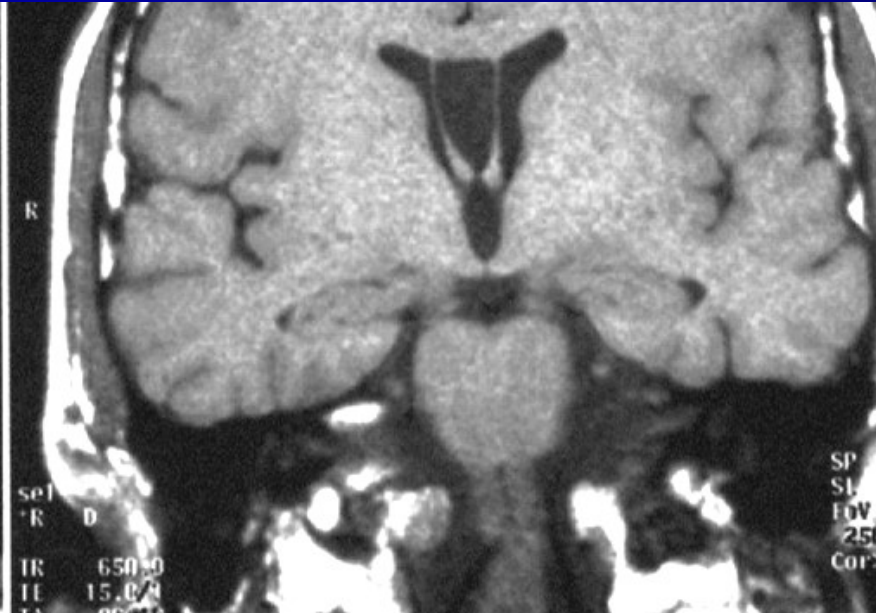
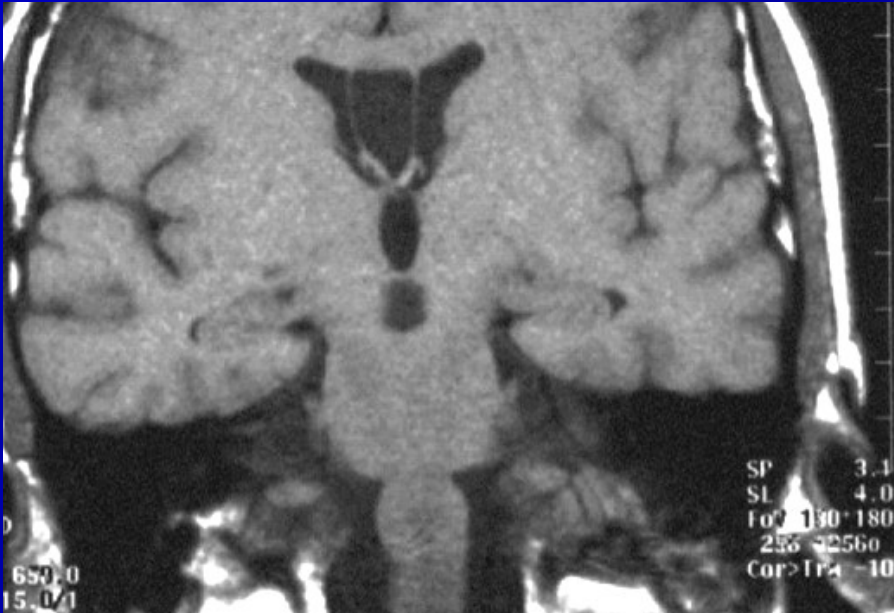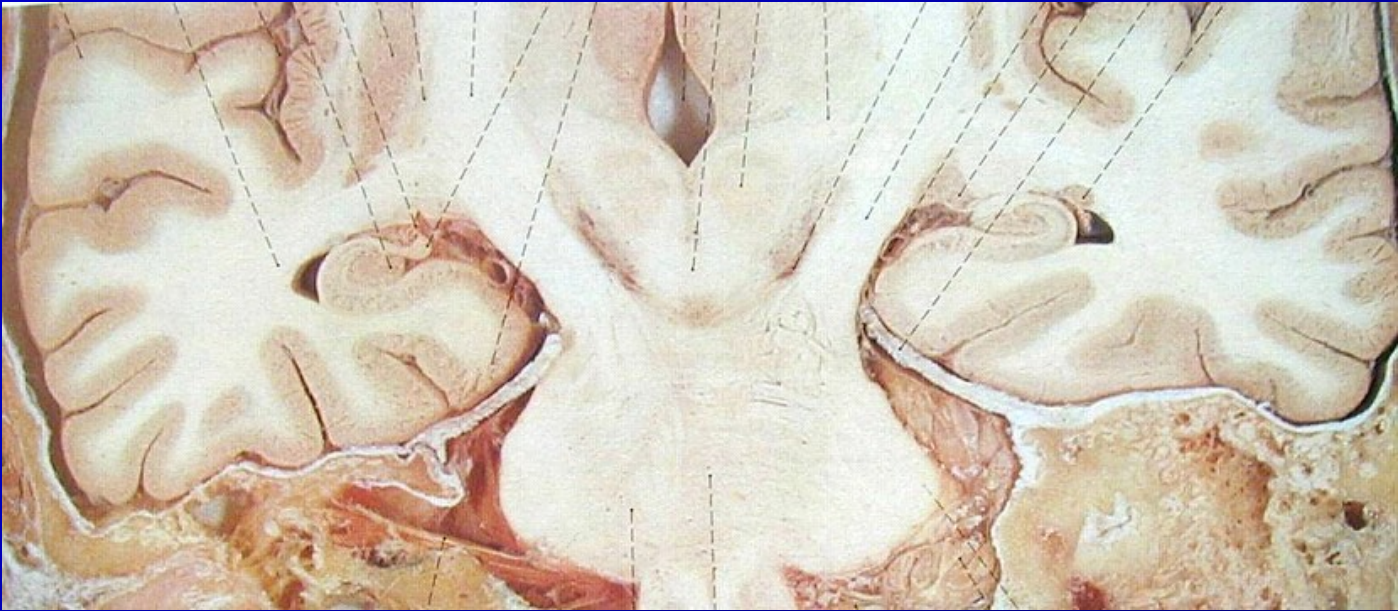




Temporální rohy postranních komor

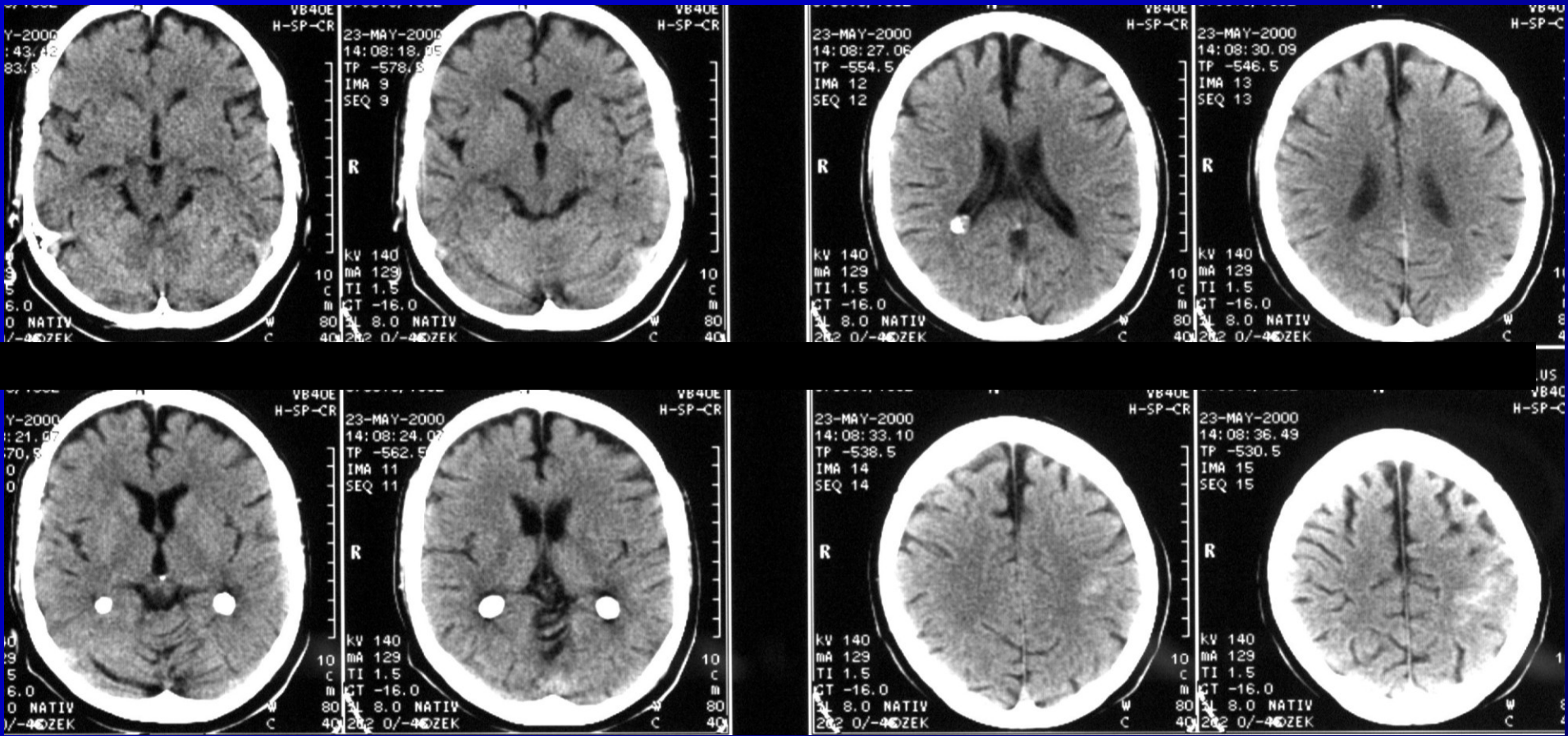
*Variabilita X degenerativní změny
(mesiální temporální skleróza)*

Temporální rohy postranních komor

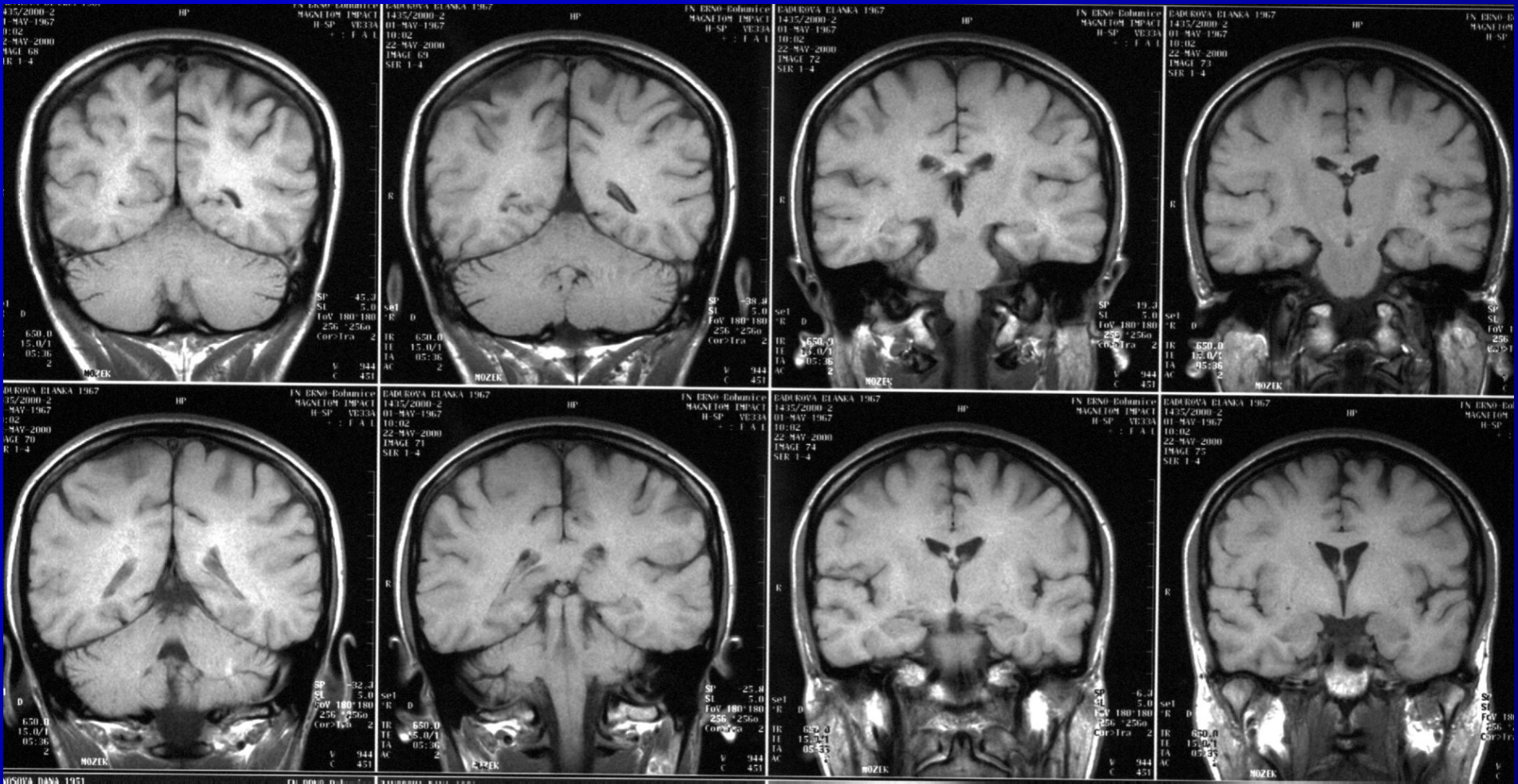

MR – T1 obrazy

Postranní komory - CT



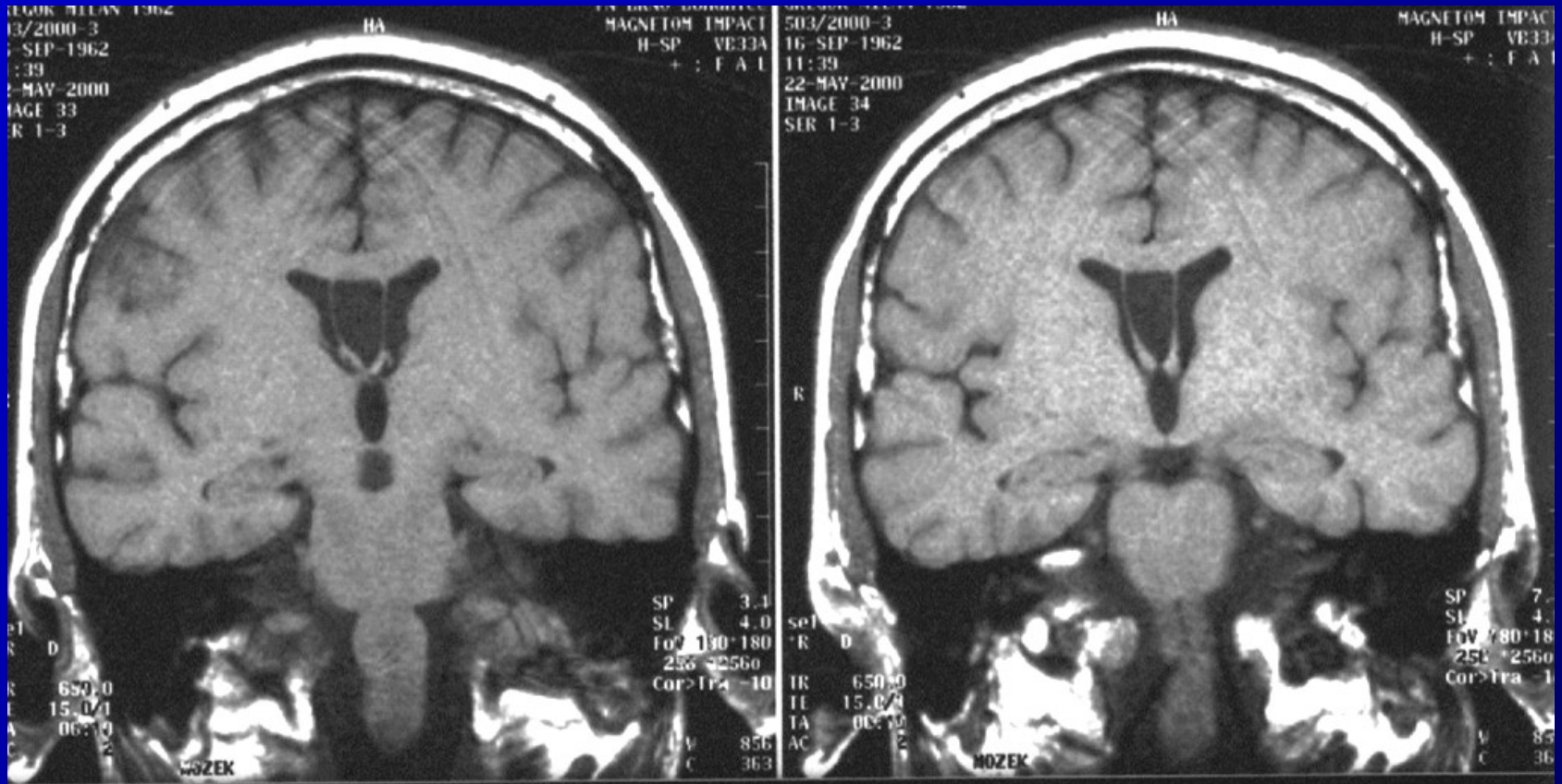
Postranní komory - MR



MR – T1 obrazy

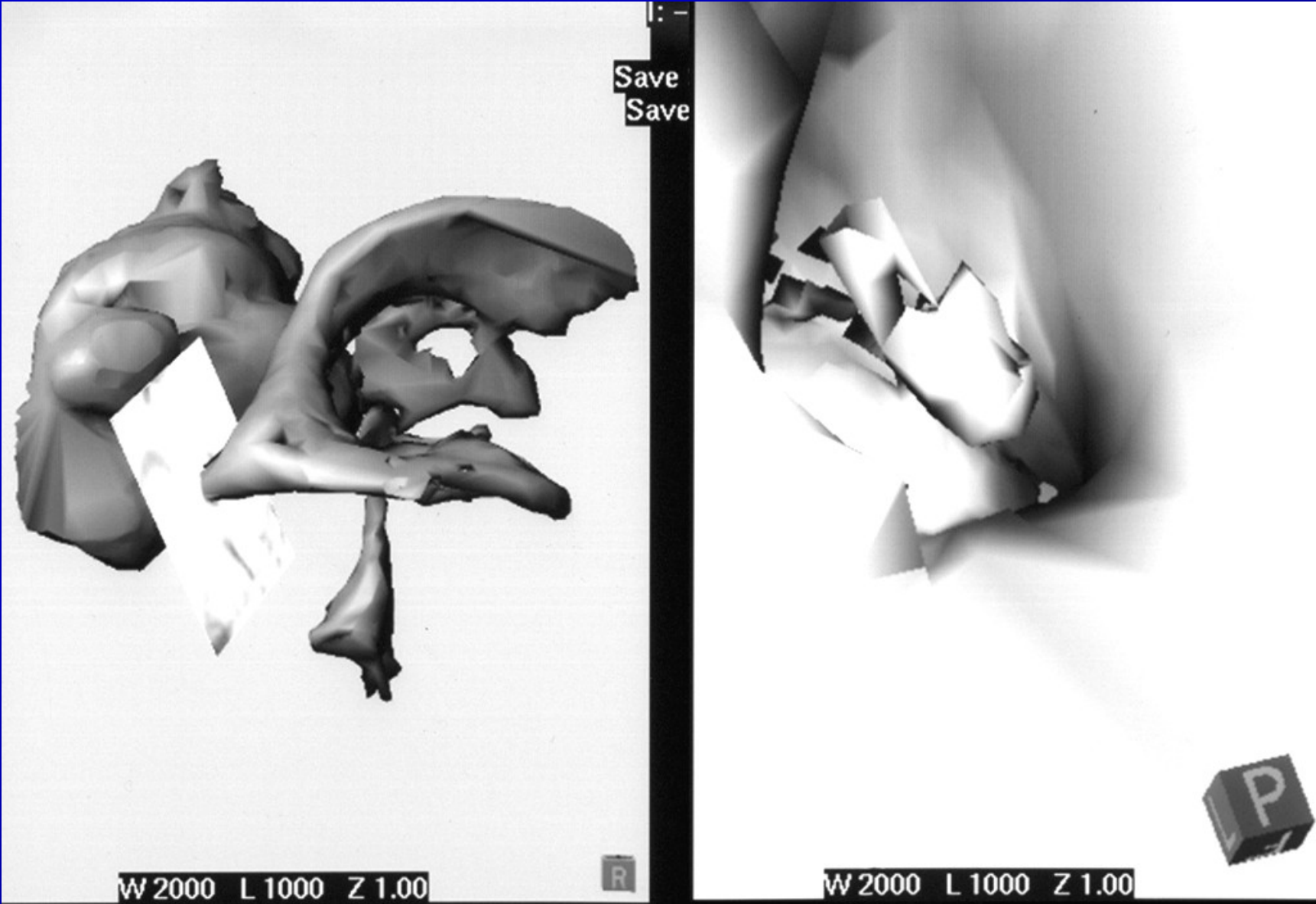
Varianty komorového systému

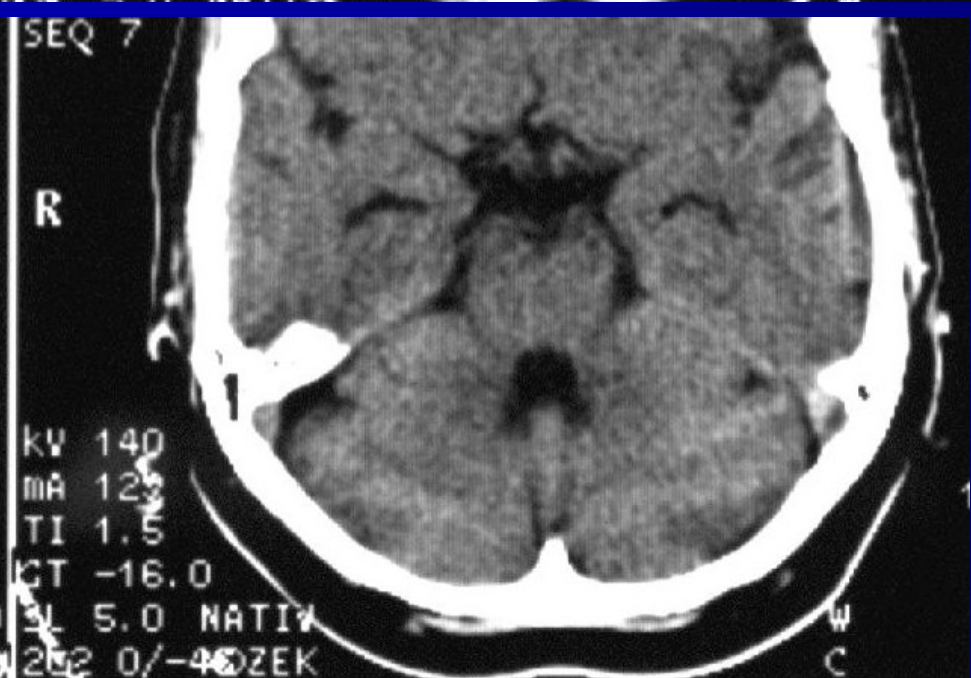
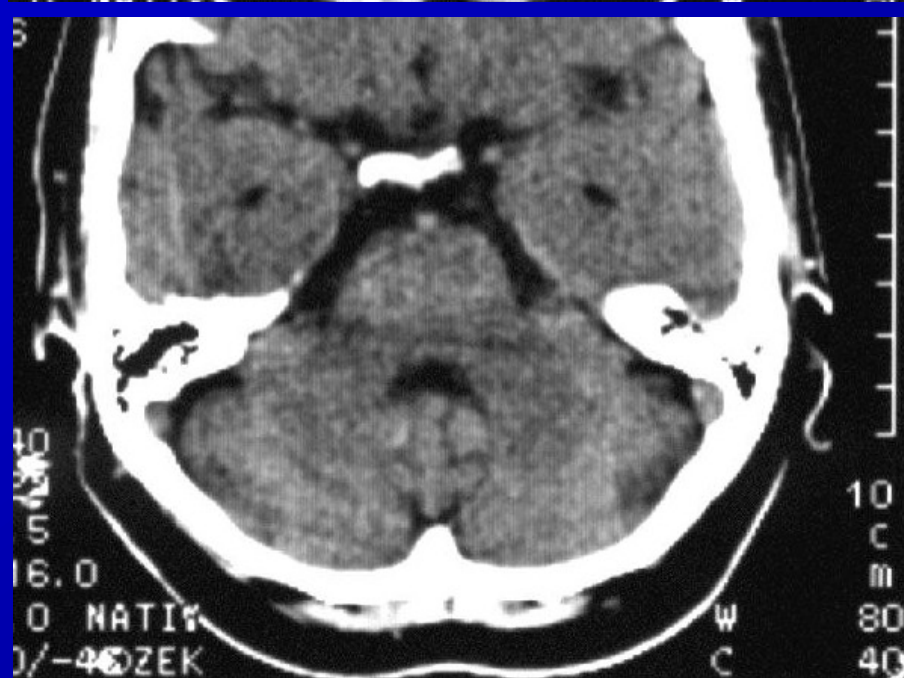
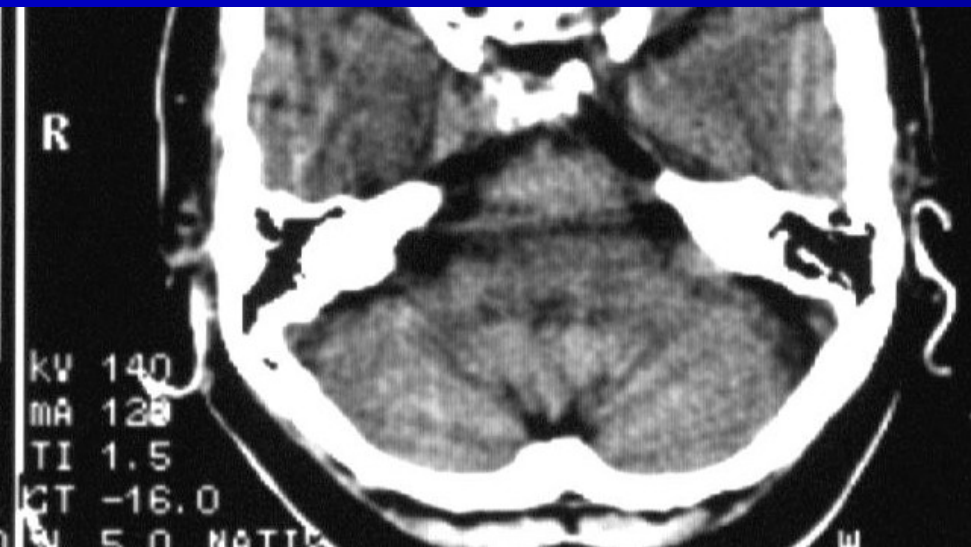
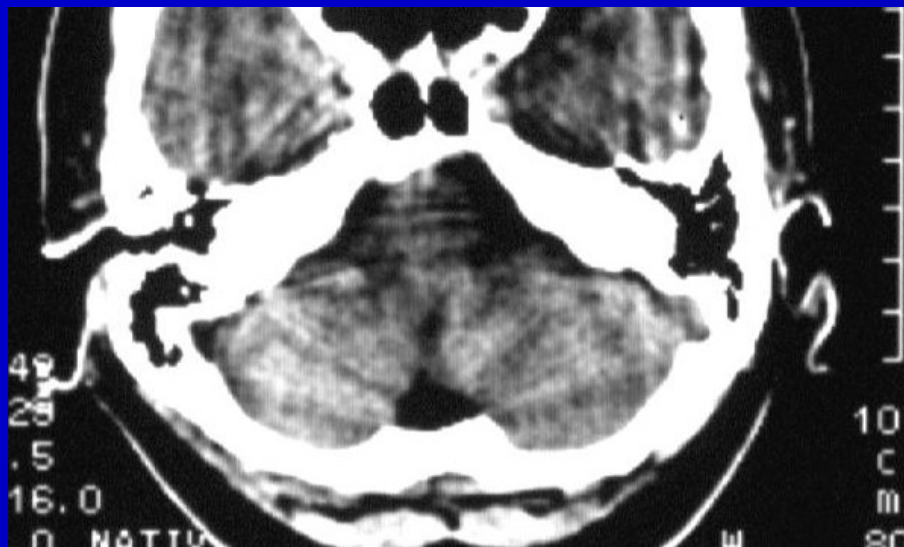
- asymetrie
- cavum - septi pellucidi, vergae, velum interpositum



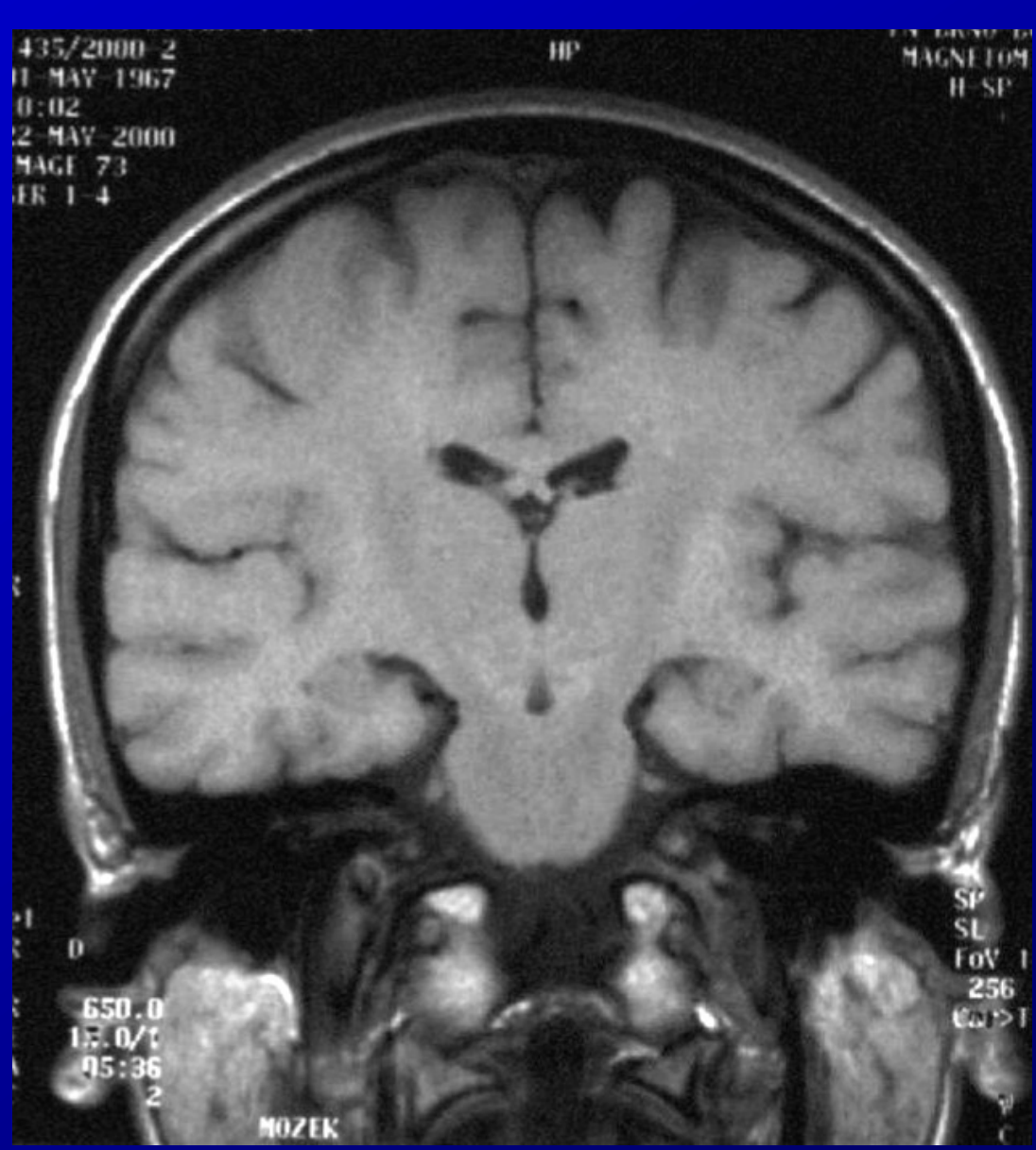
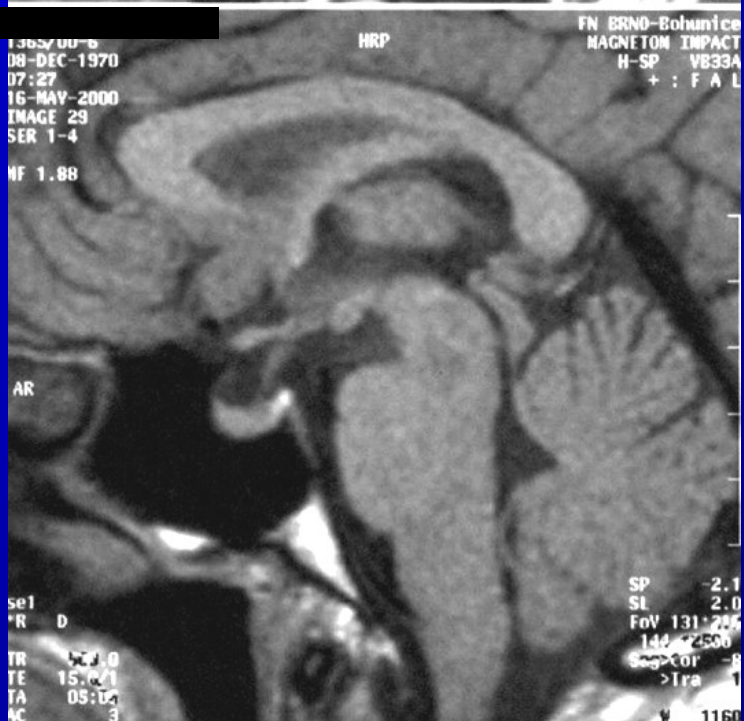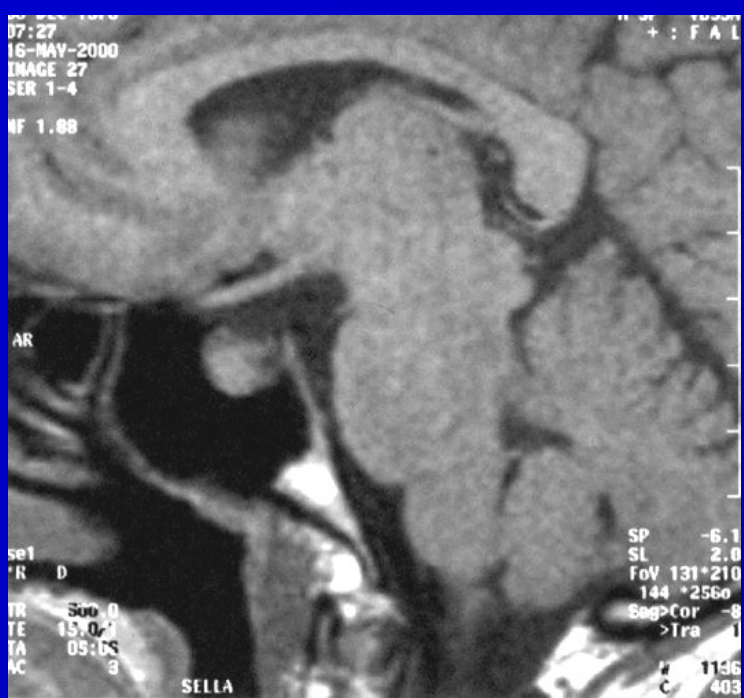
MR – T1 obrazy

Virtuální endoskopie komorového systému – zdroj dat MR





Cisterny - CT

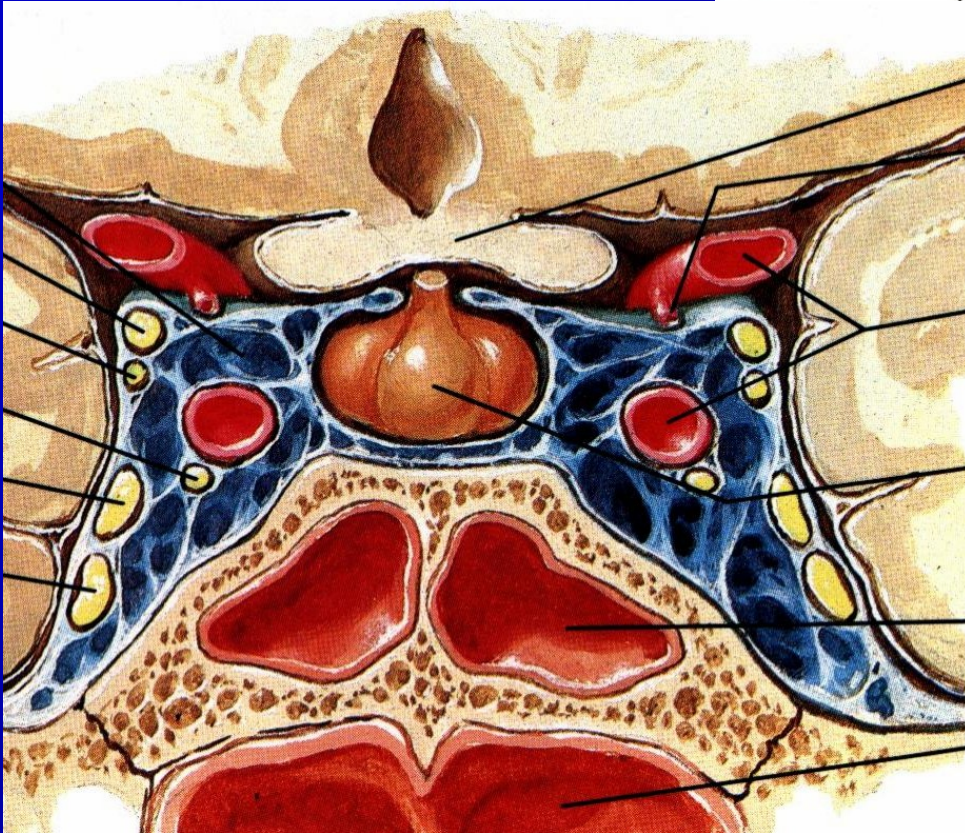
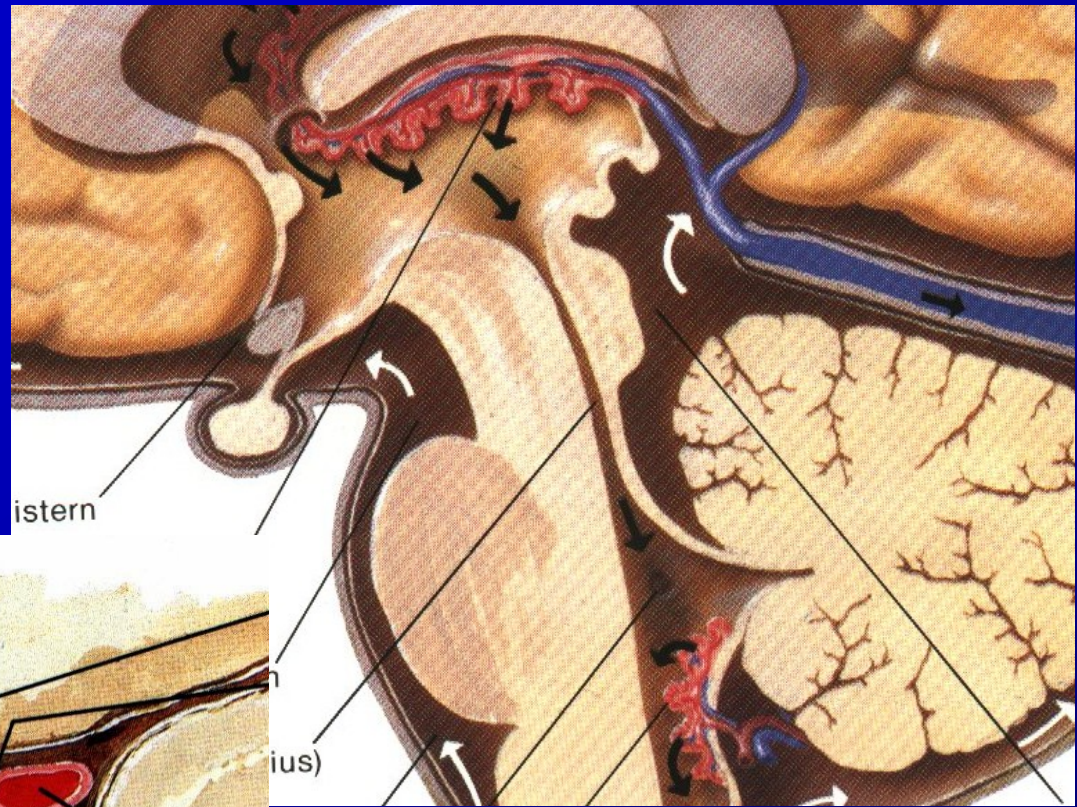


Cisterny: MR – T1 obrazy

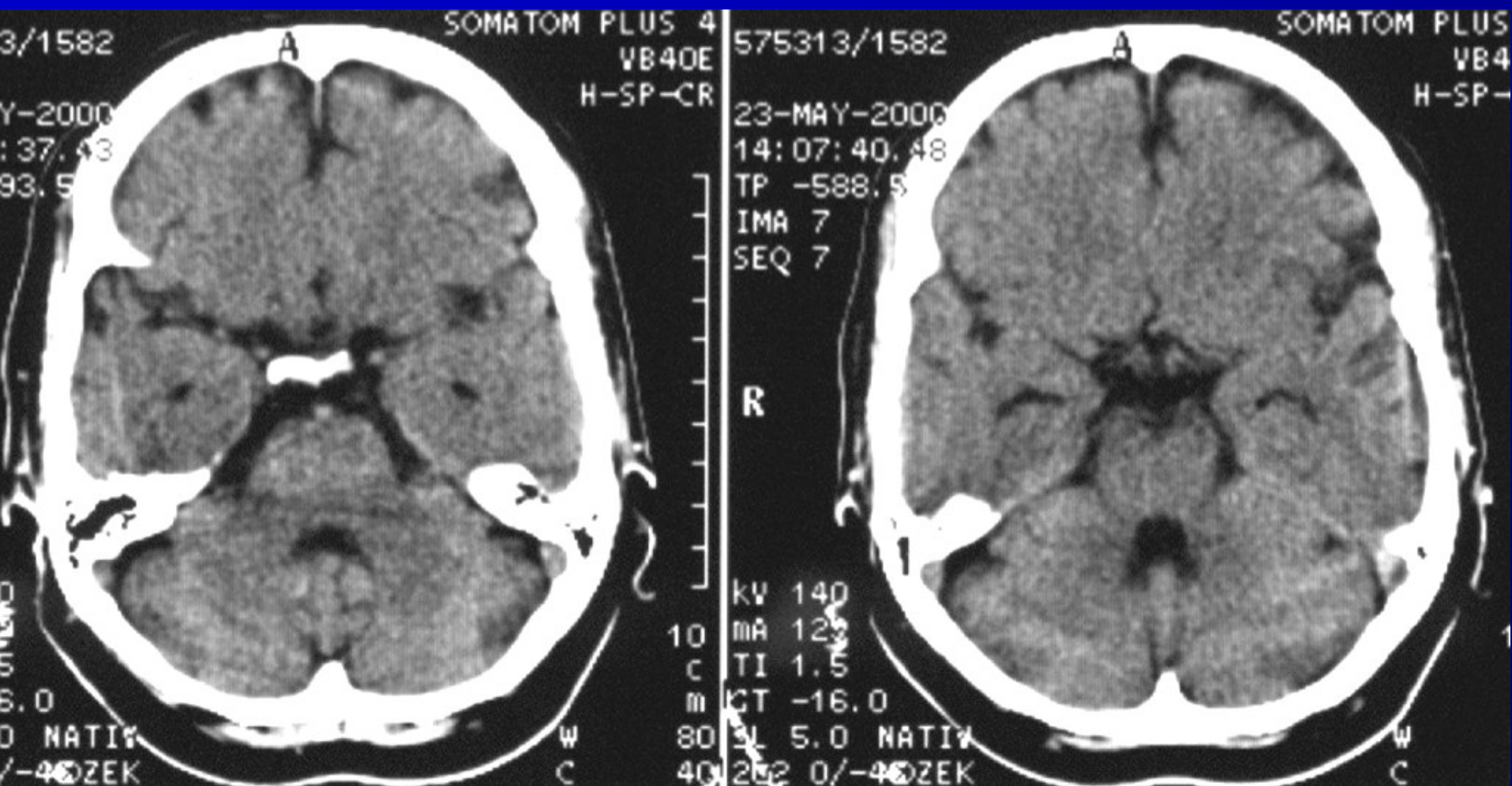
Cisterny

Bazální cisterny

- interpedunkulární
- supraselární



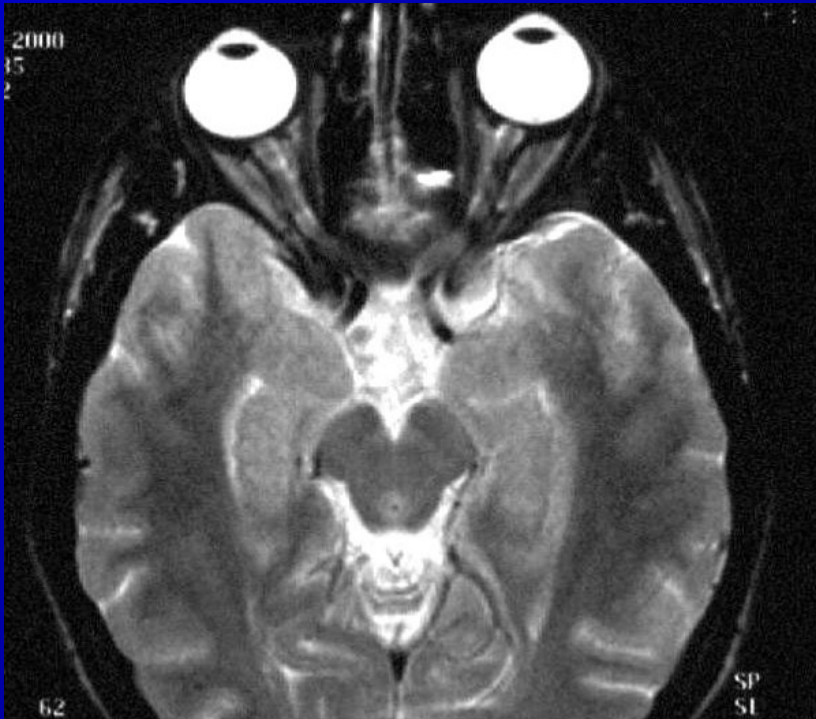Supraselární cisterna - CT



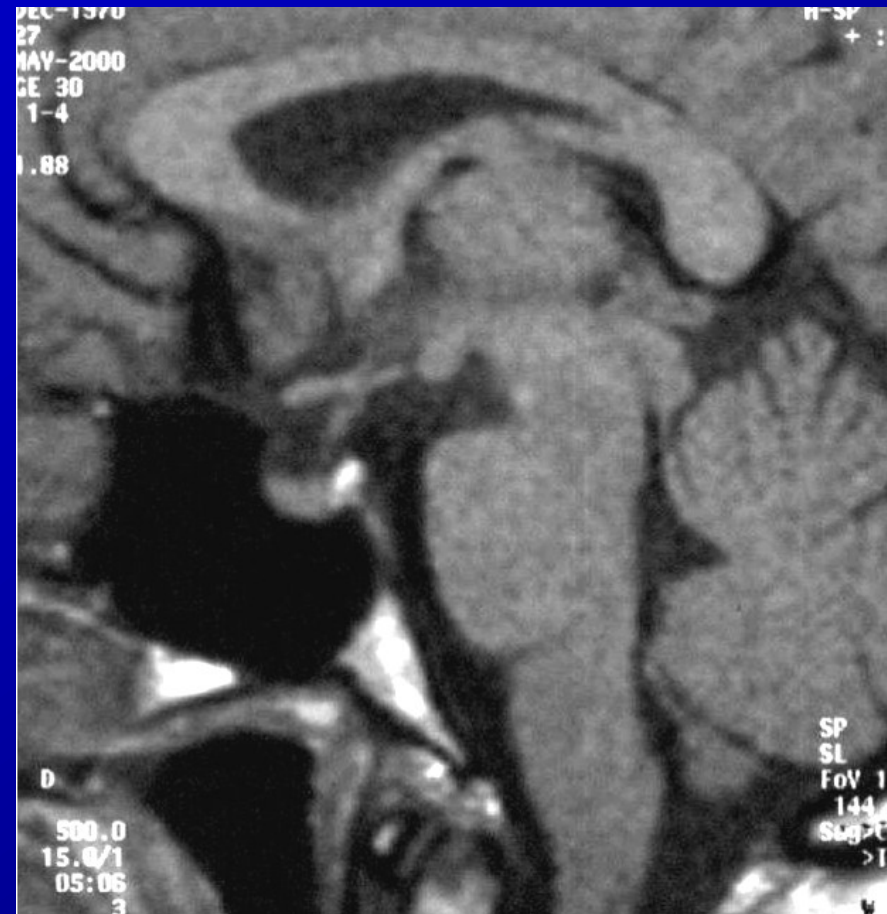
Cisterny

Kolem mesencephala

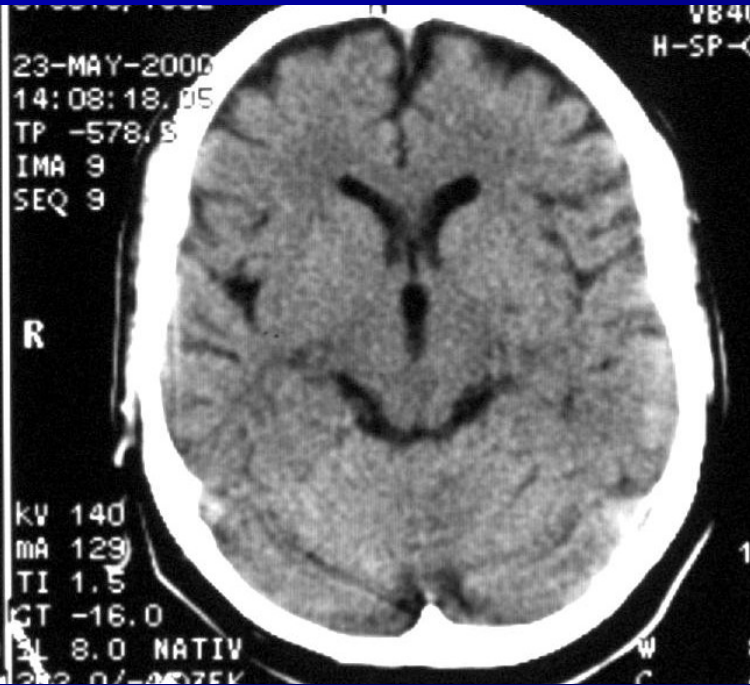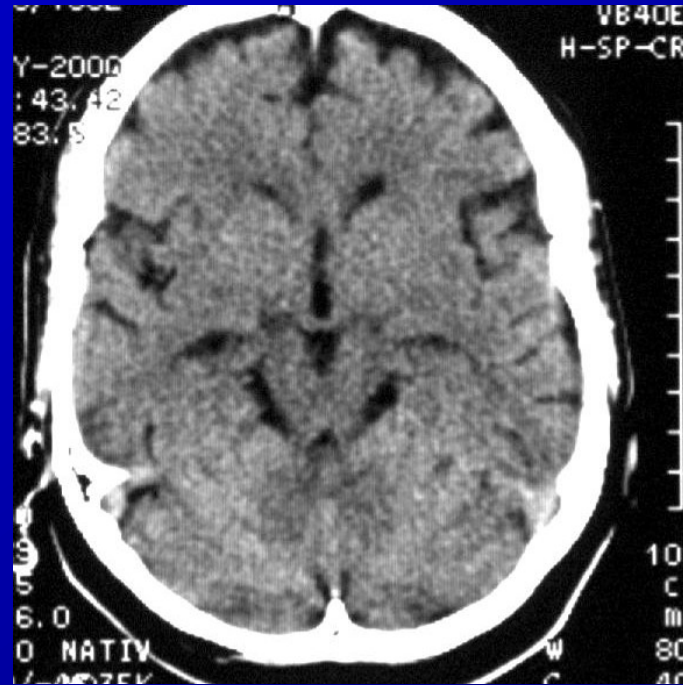
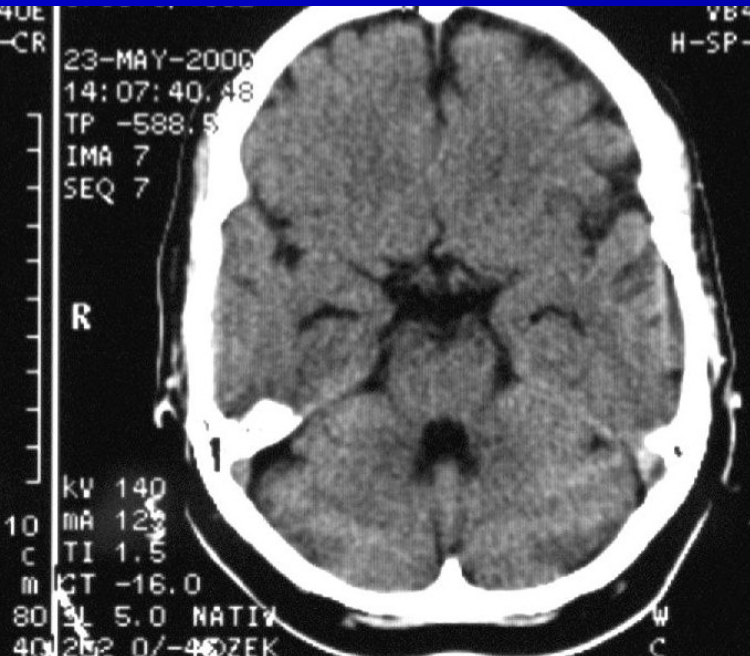
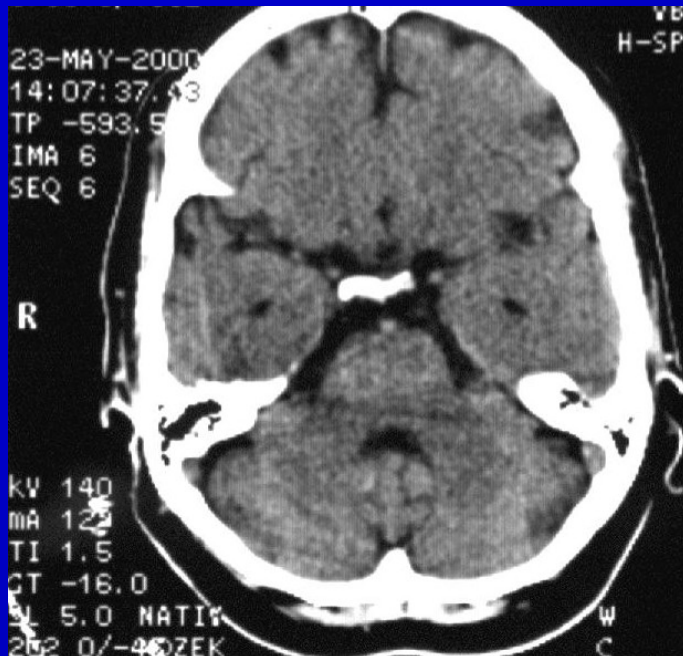
- ambientní
- quadrigeminální
- velum interpositum



MR – T2 obraz



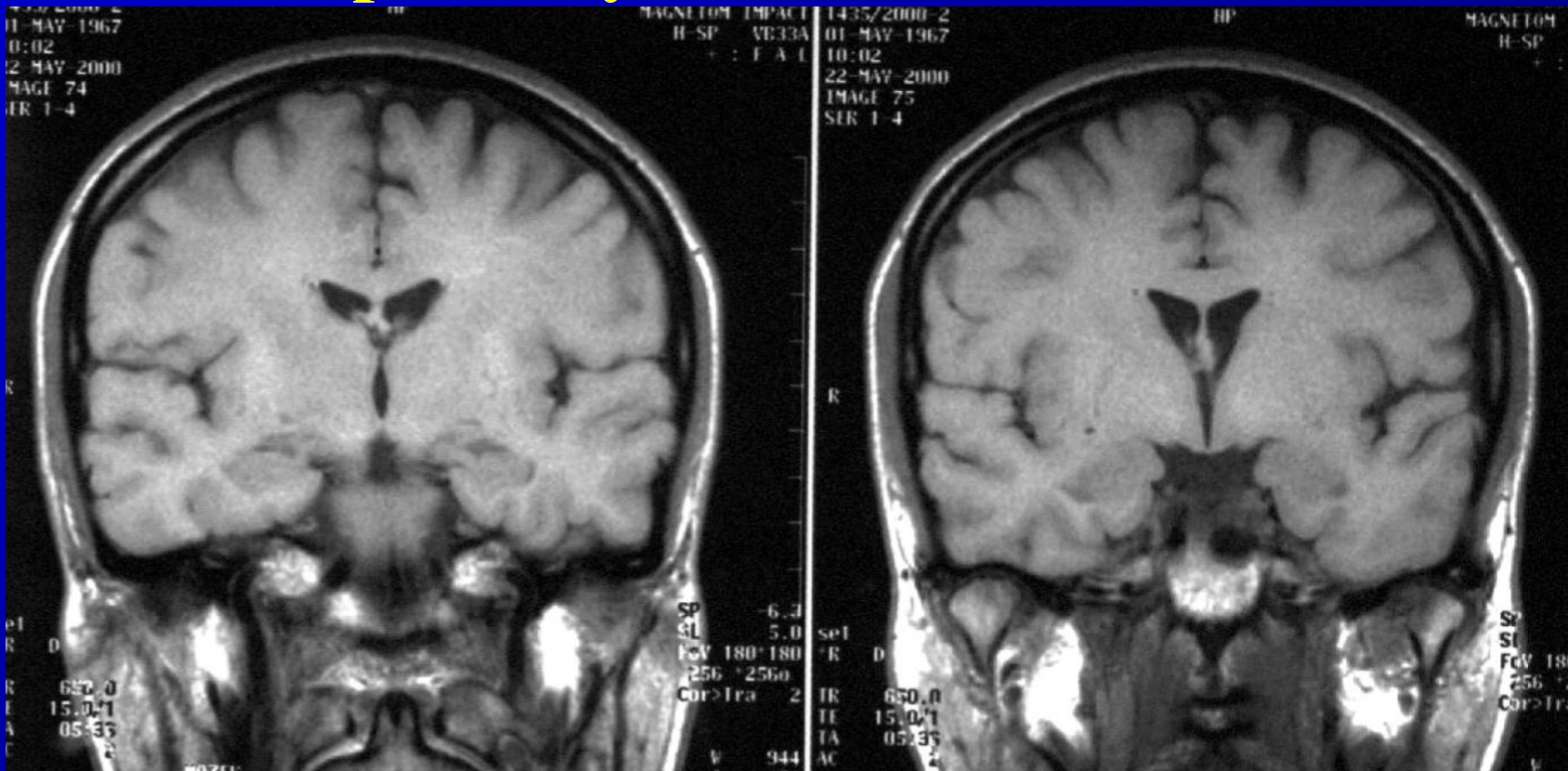
MR – T1 obraz



Bazální cisterny - CT

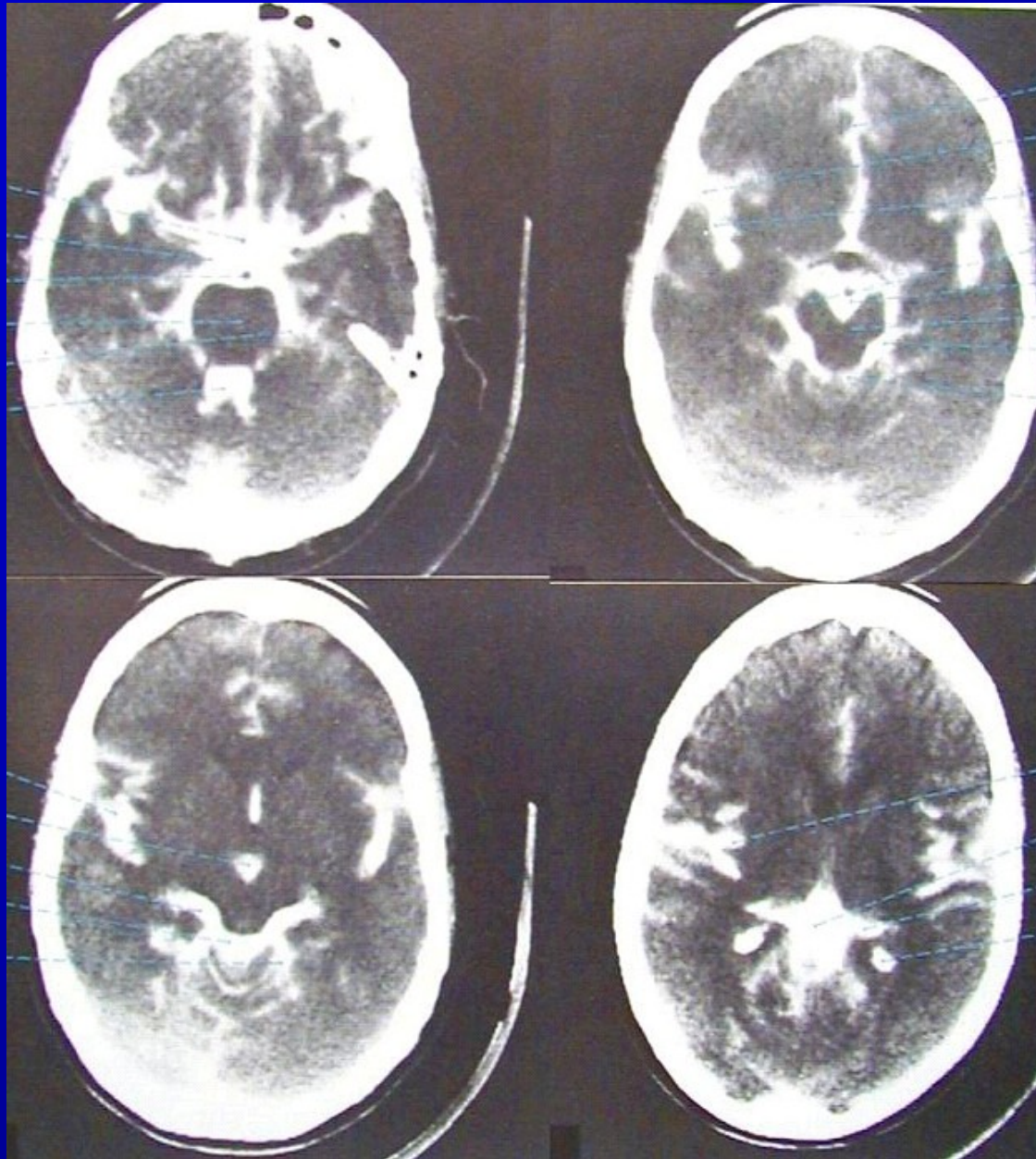
Zevní likvorové prostory kolem hemisfér

- Sylvická rýha
- subarach.prostory na konvexitách

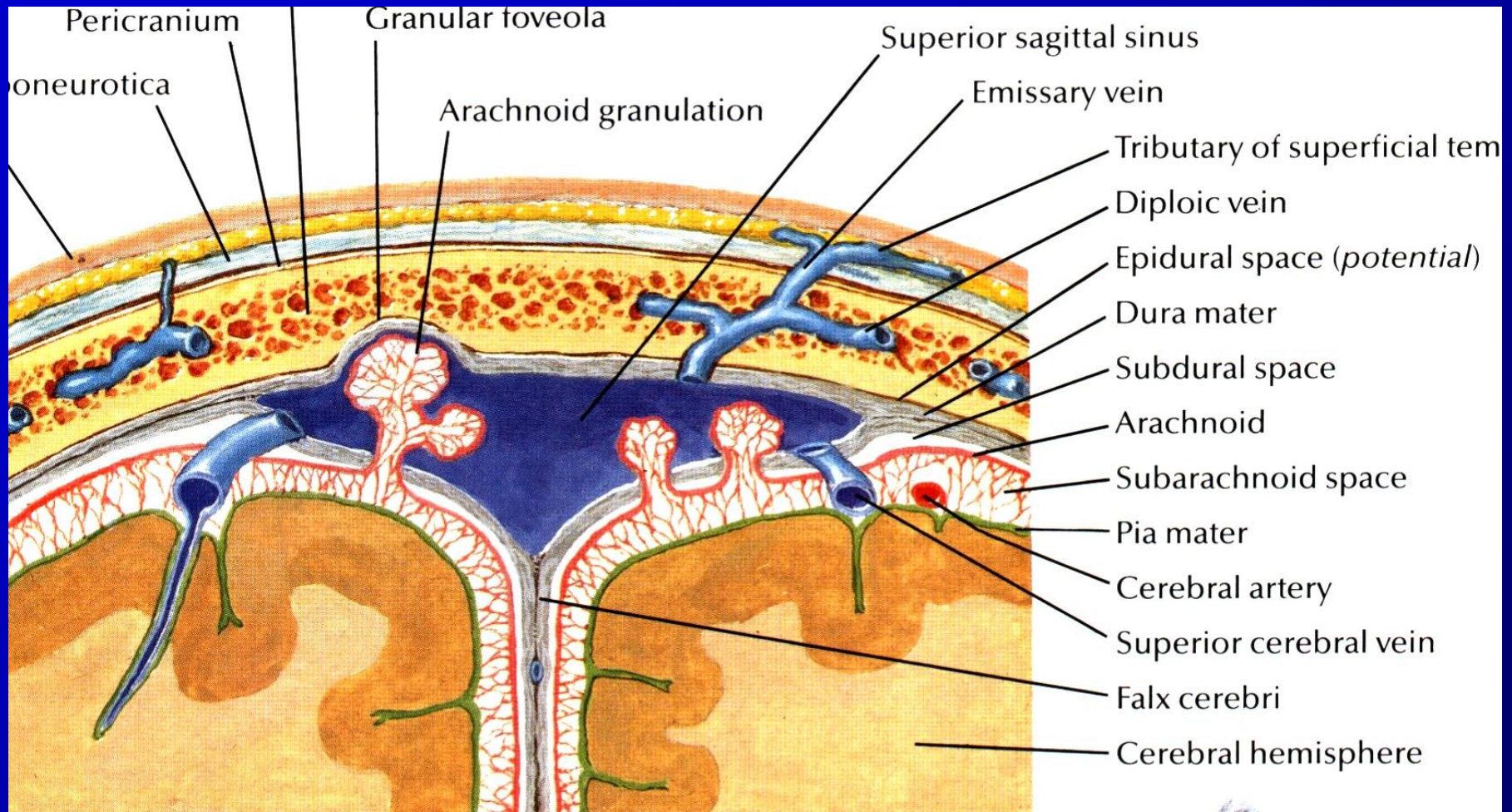


MR – T1 obrazy

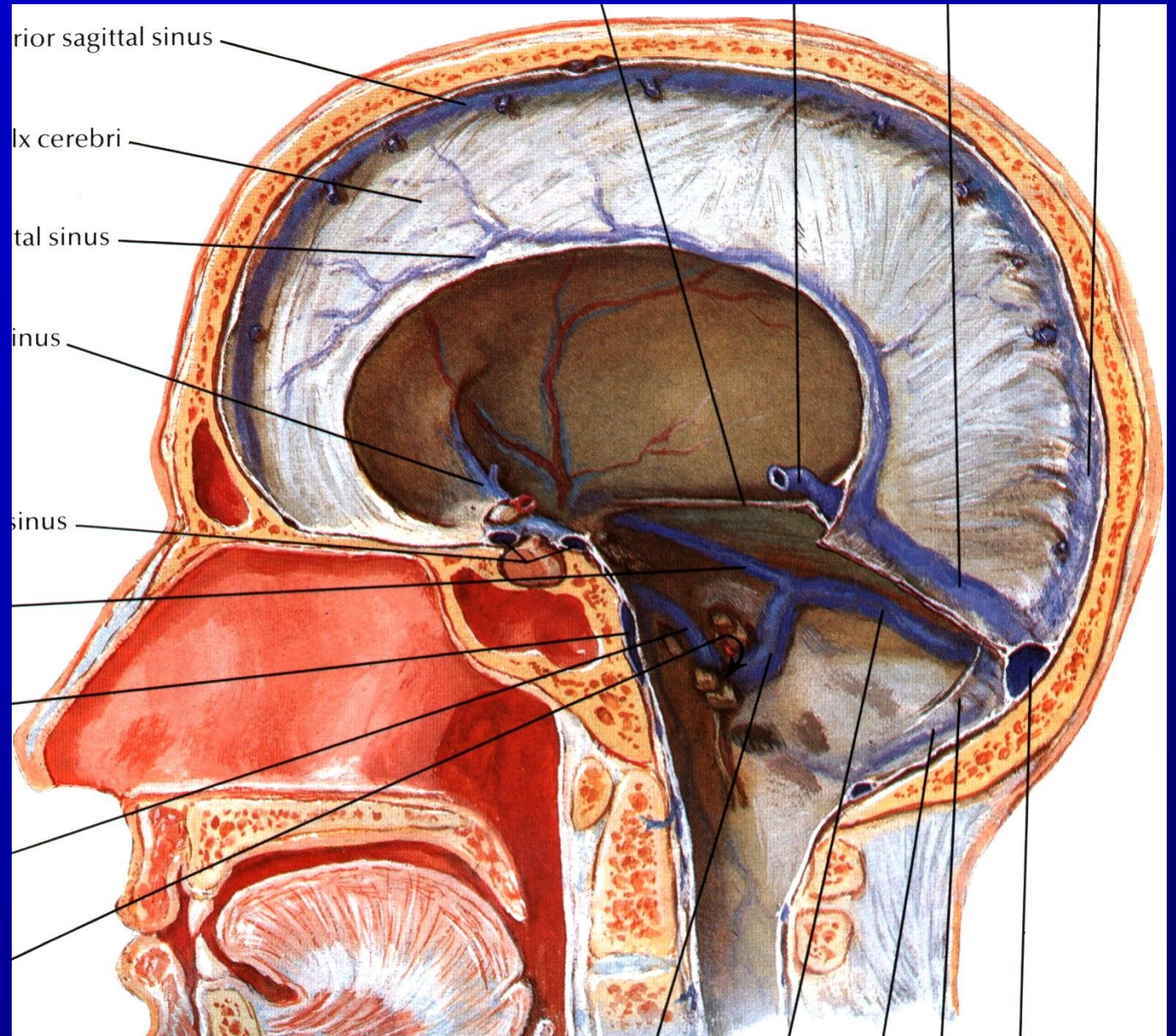
CT cisternografie



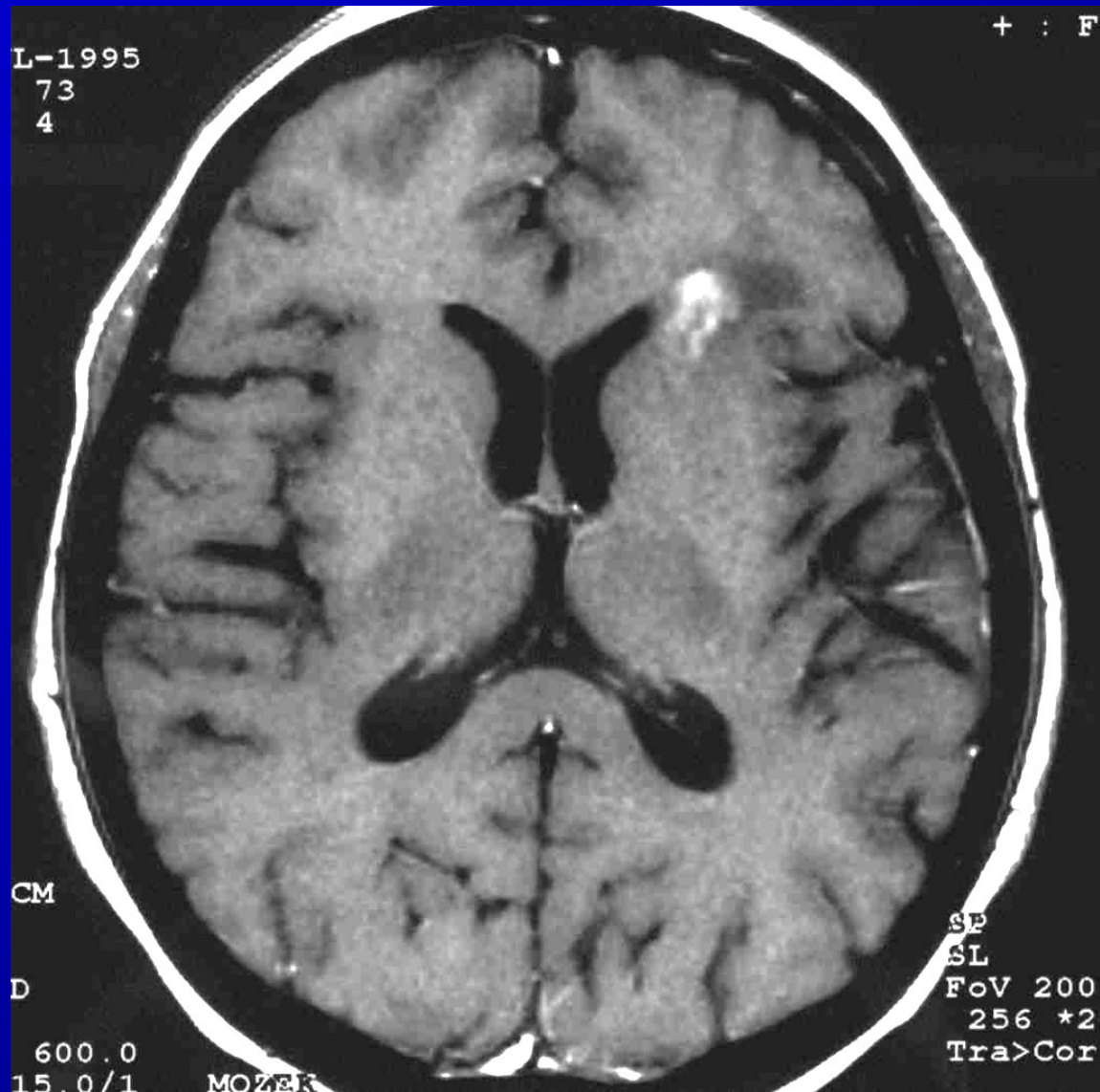
Mozkové obaly



Mozkové obaly



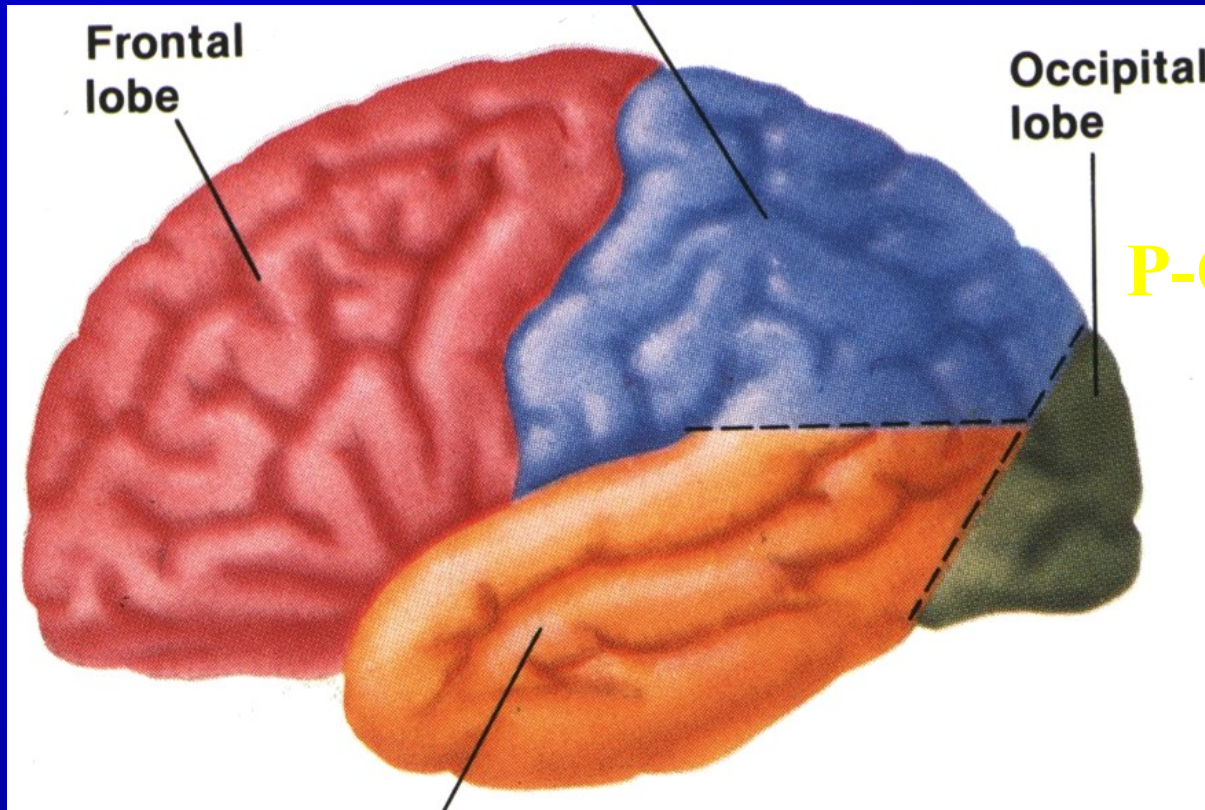
Mozkové obaly - MR



T1 obraz postkontrastně – obaly se jen stopově sytí – normální nález

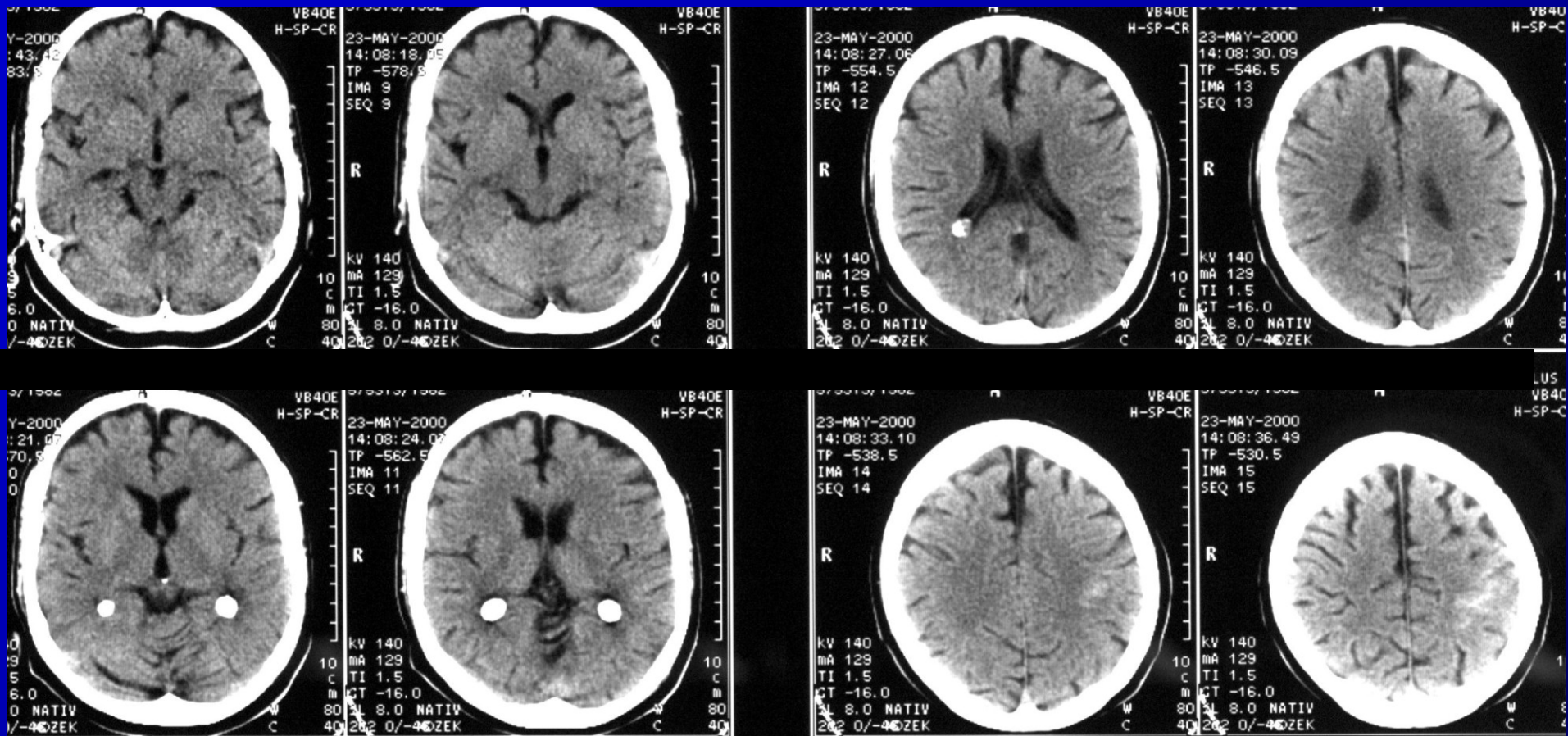
Mozkové laloky

Sulcus centralis - Rolandi

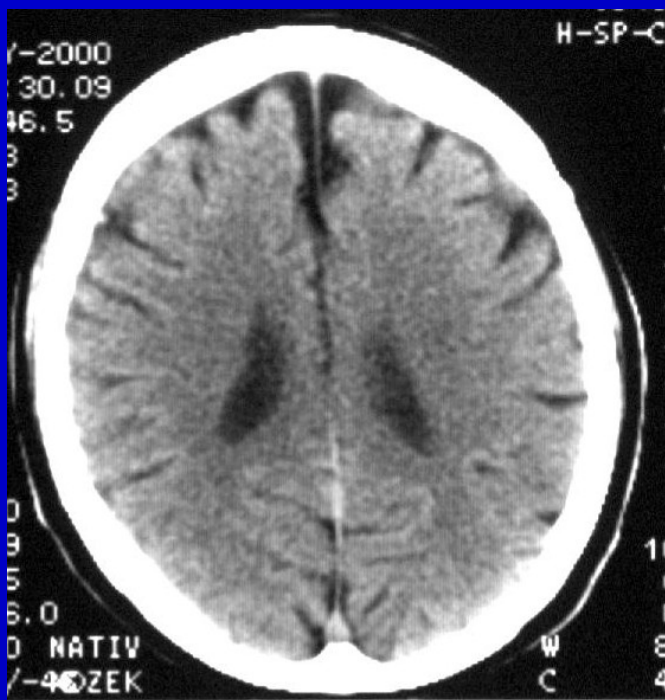


Sulcus lateralis - Sylvii

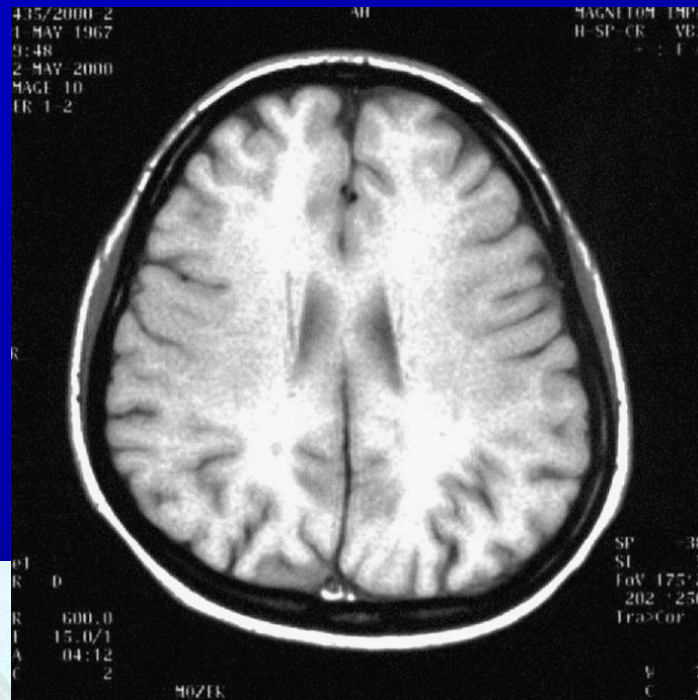
Mozkové laloky - CT



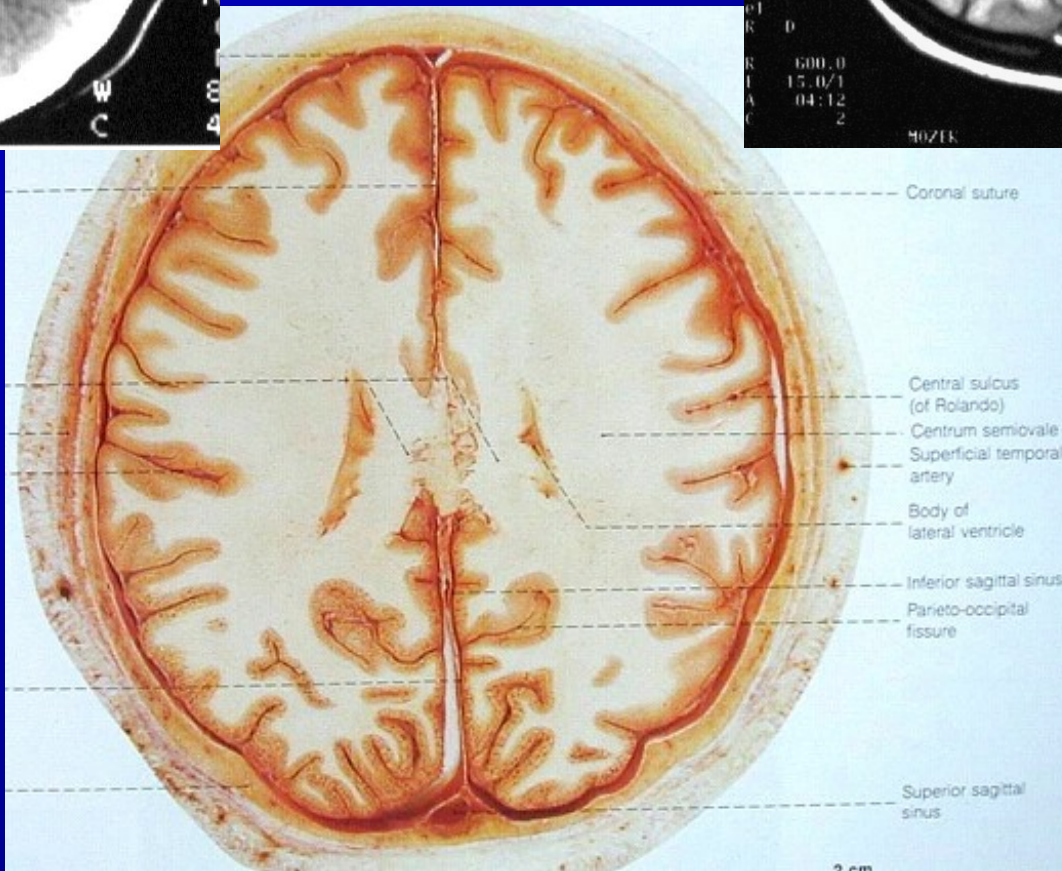Sulcus centralis



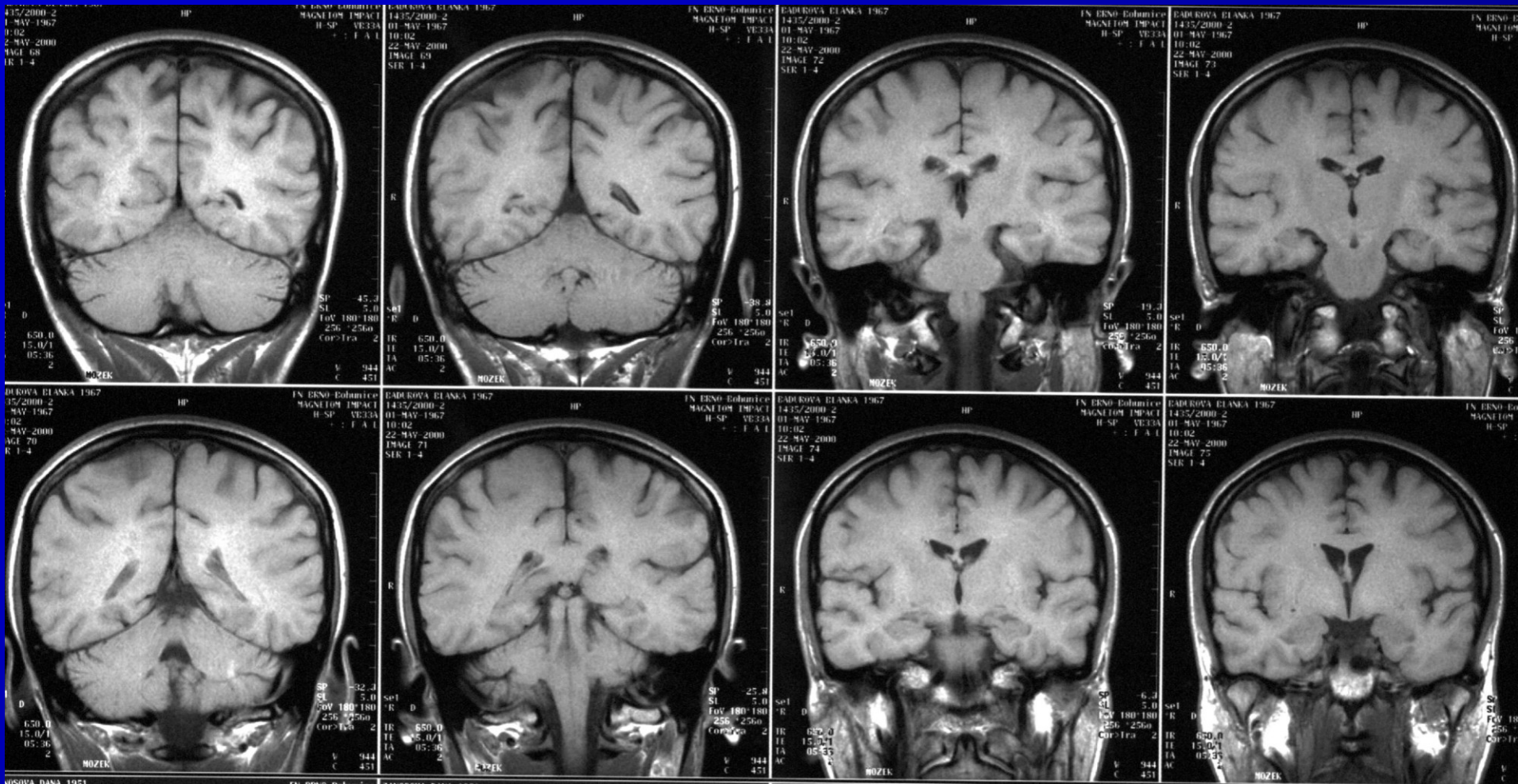CT



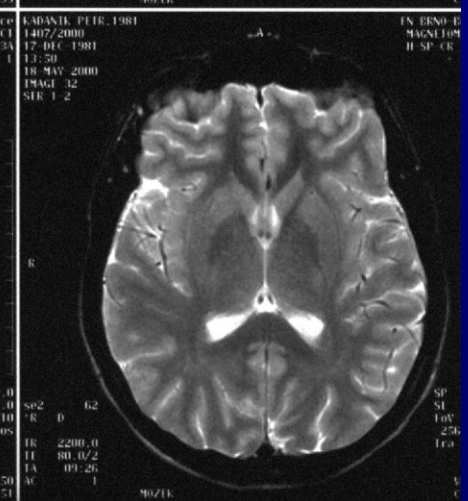
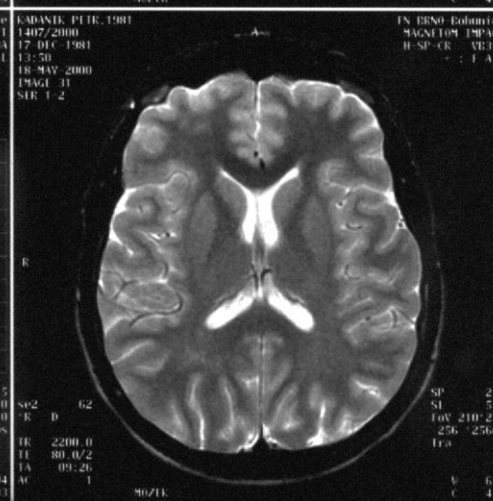
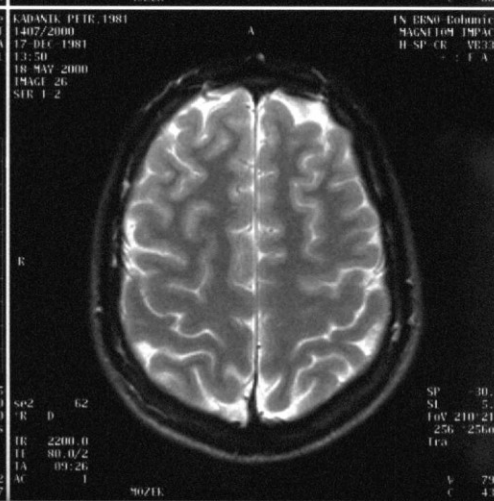
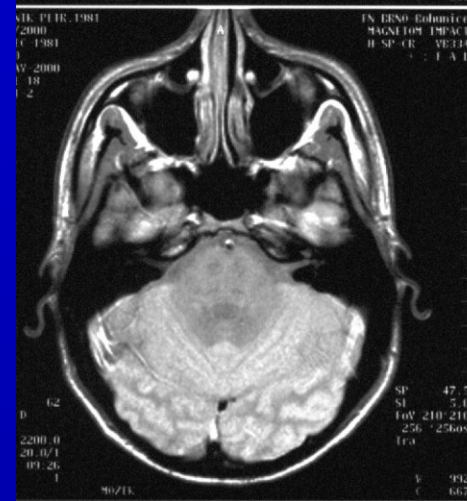
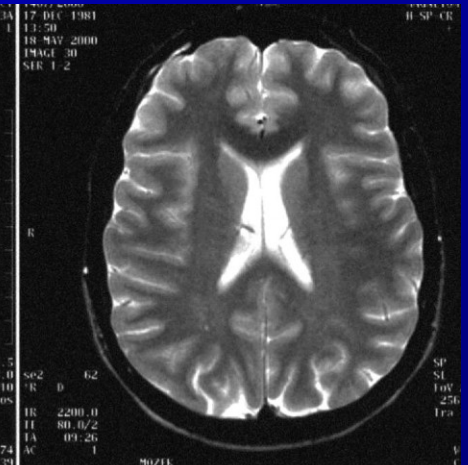
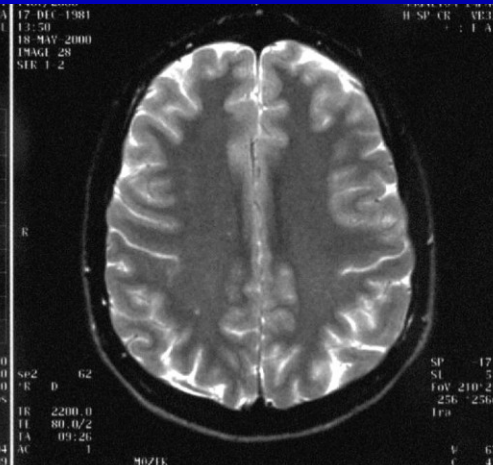
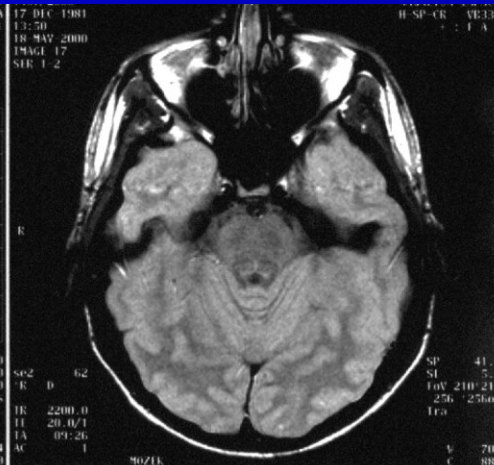
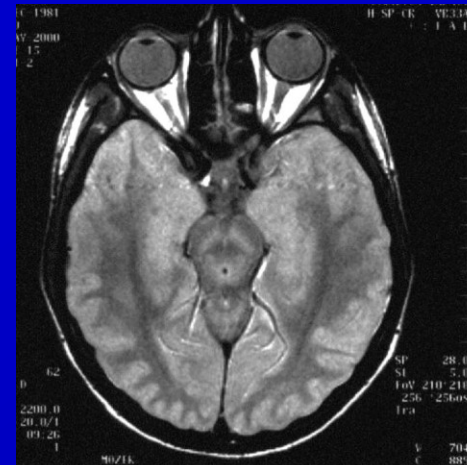MR – T1 obraz



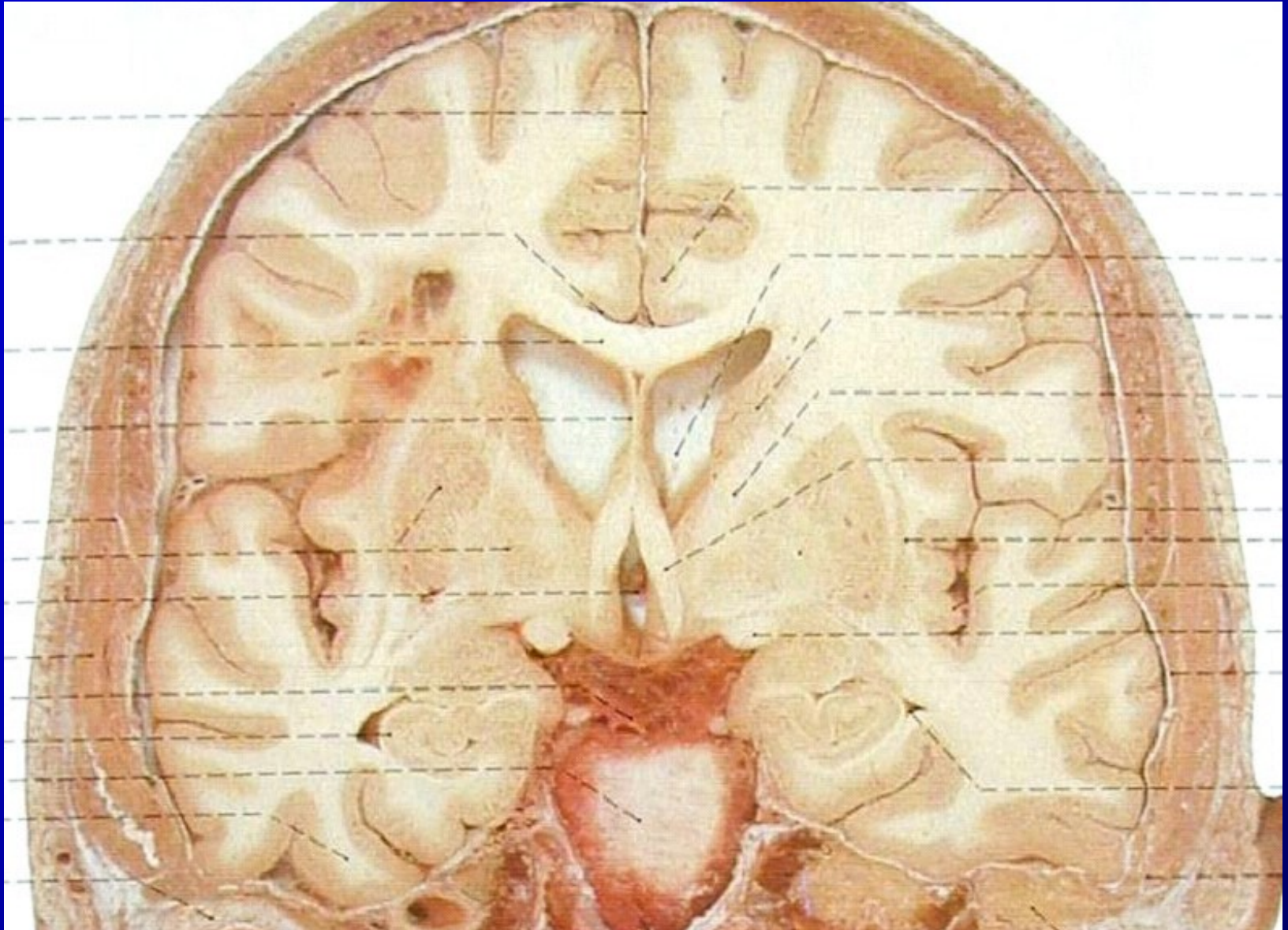Mozkové laloky – MR – T1



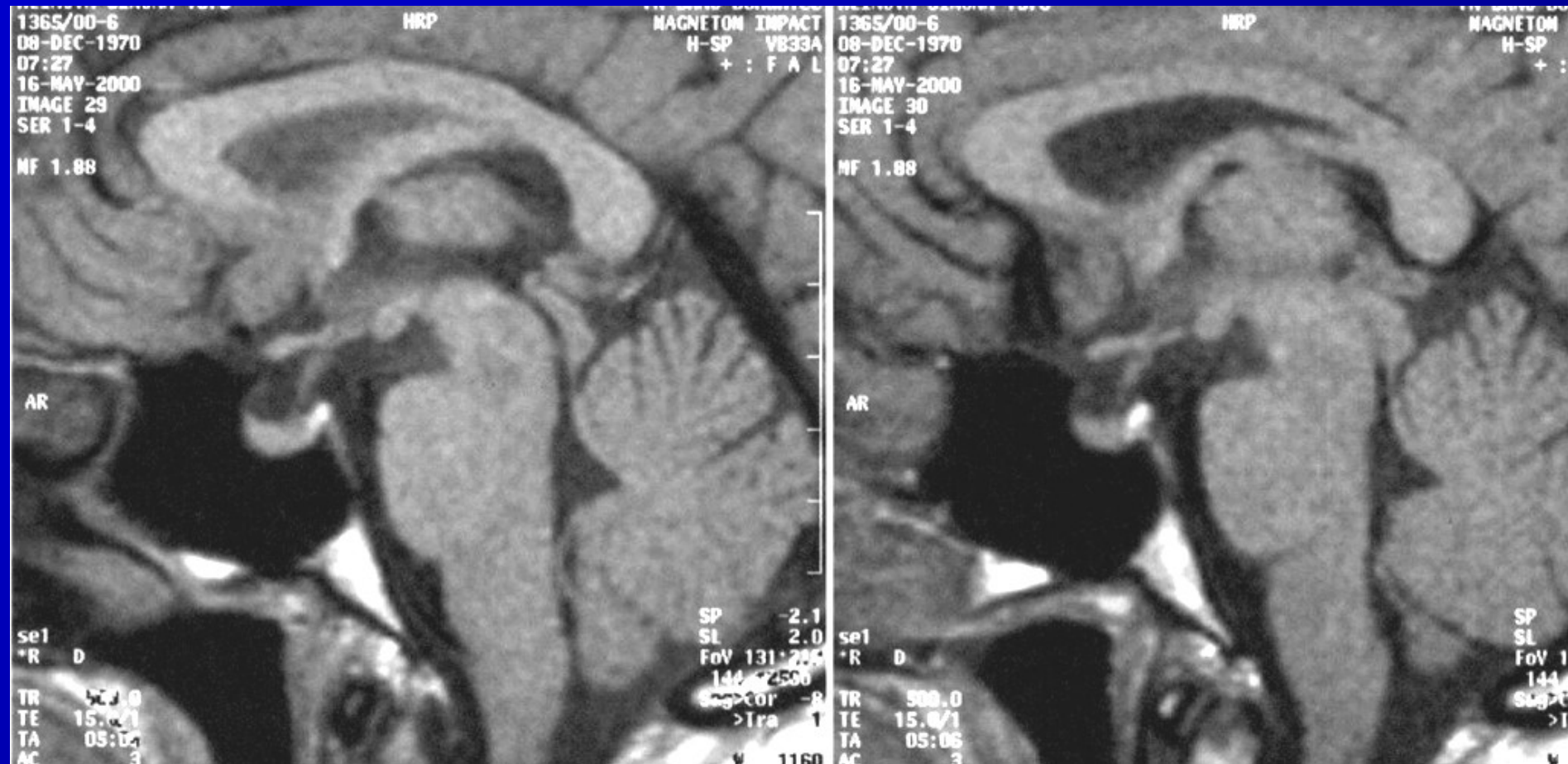
Mozkové laloky – MR – T2



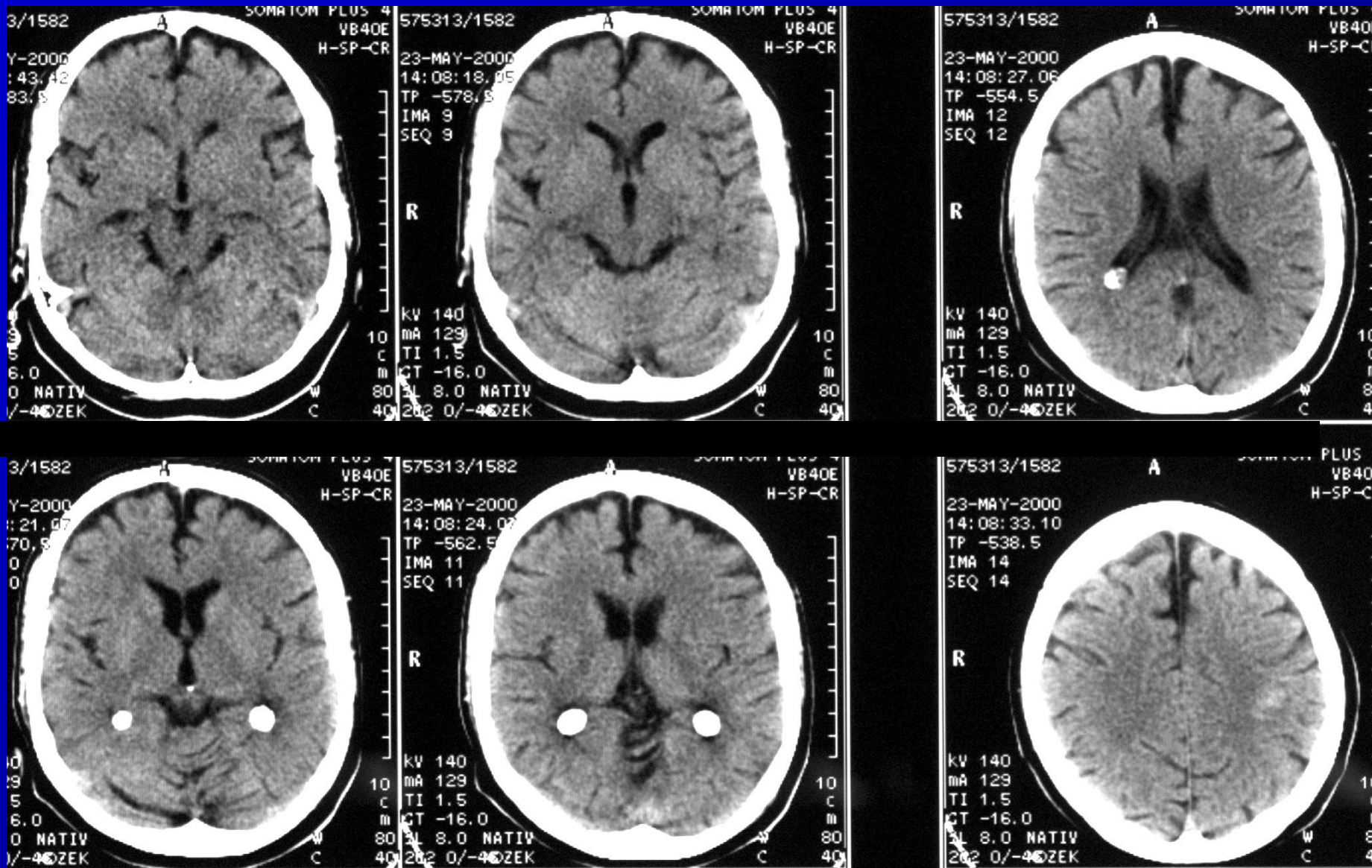
Corpus callosum



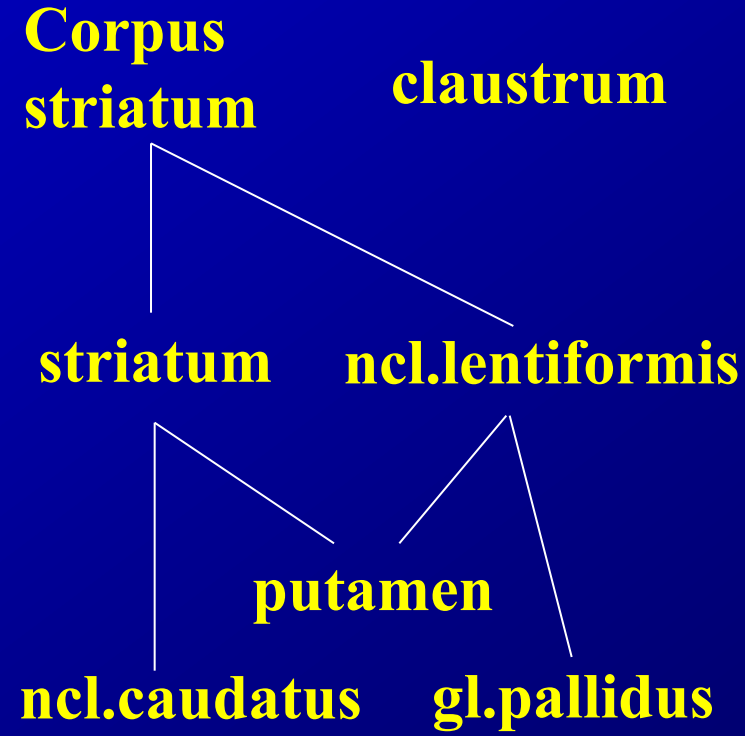
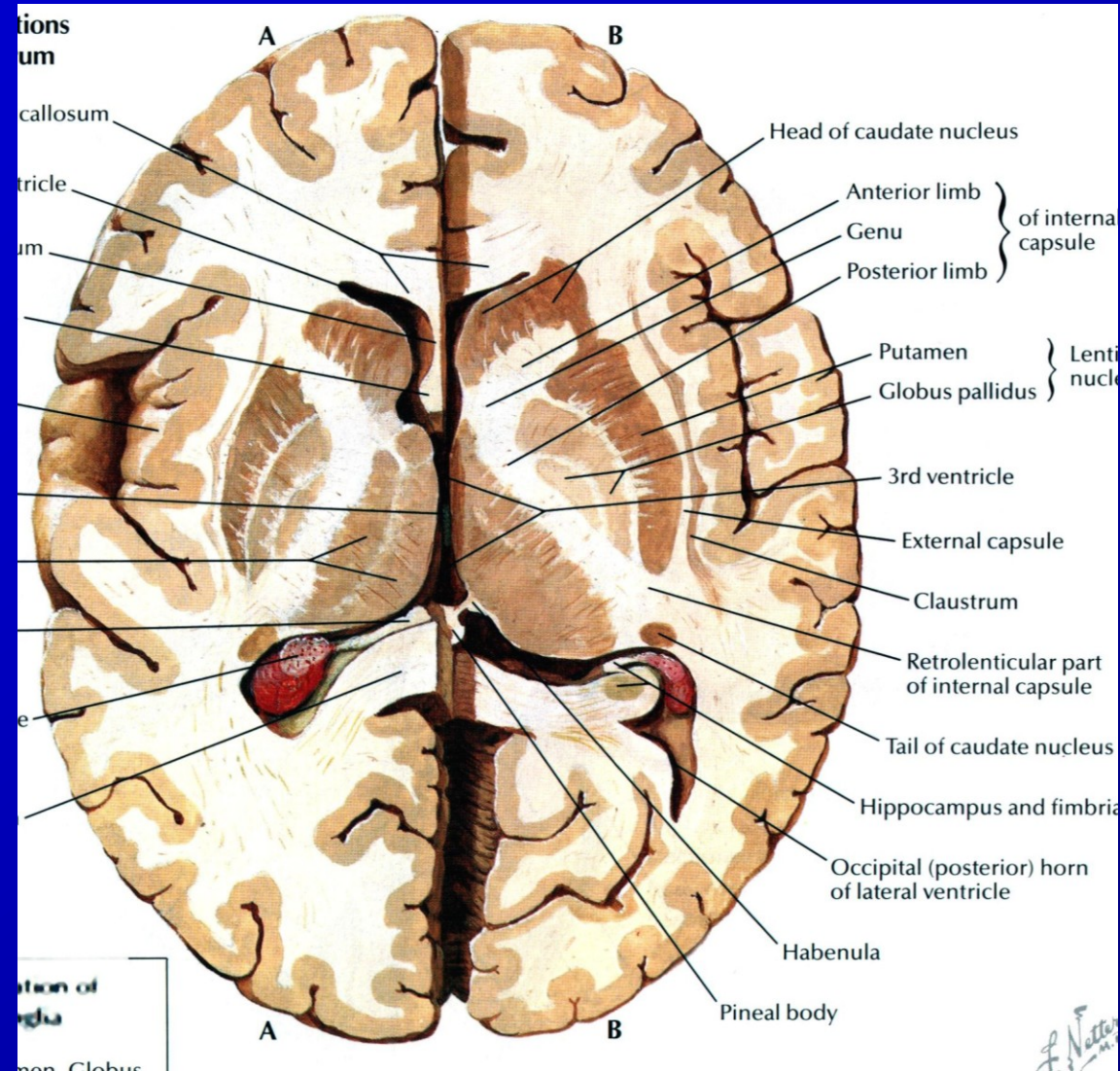
Corpus callosum – MR – sagitální rovina



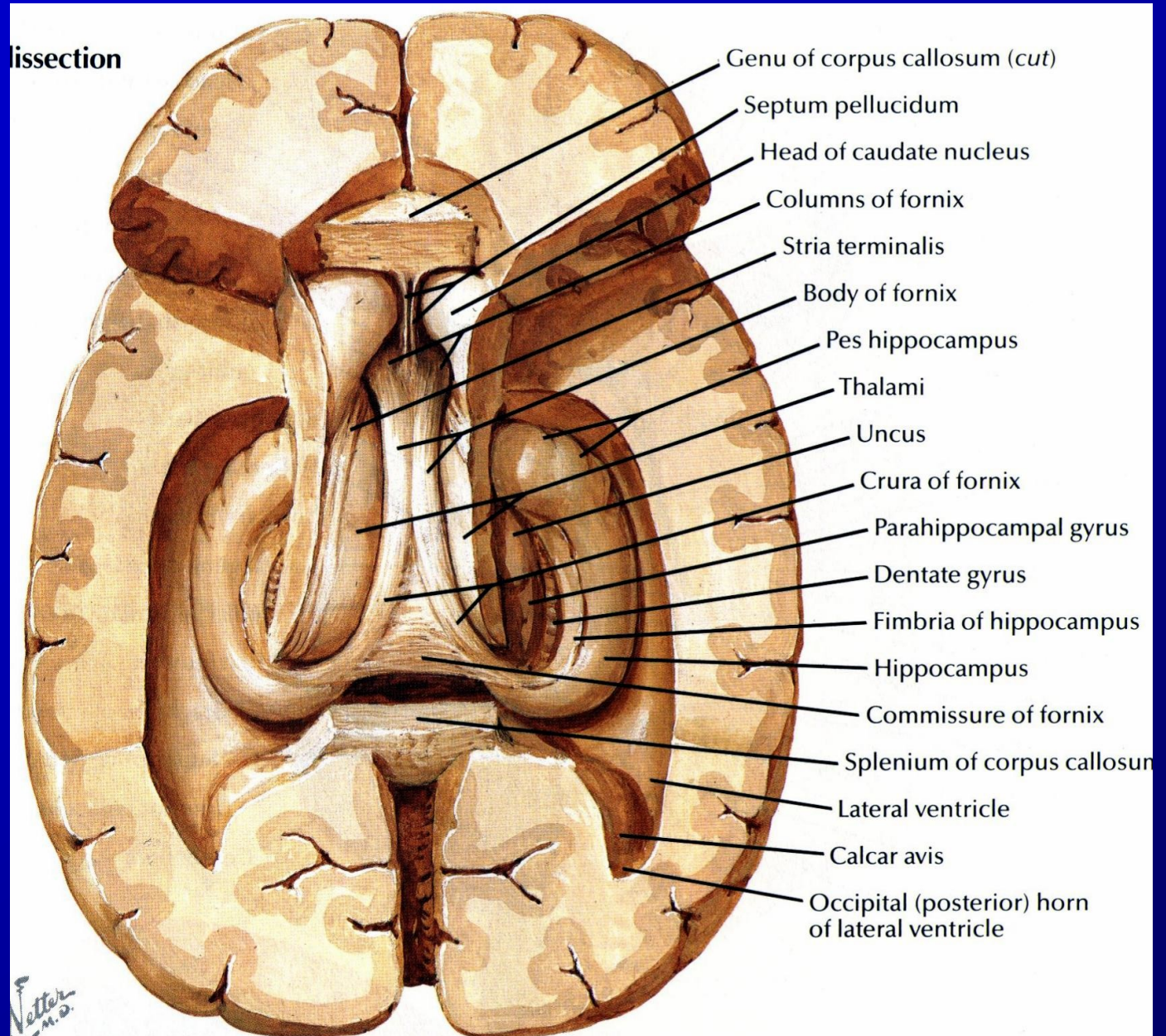
Corpus callosum - CT



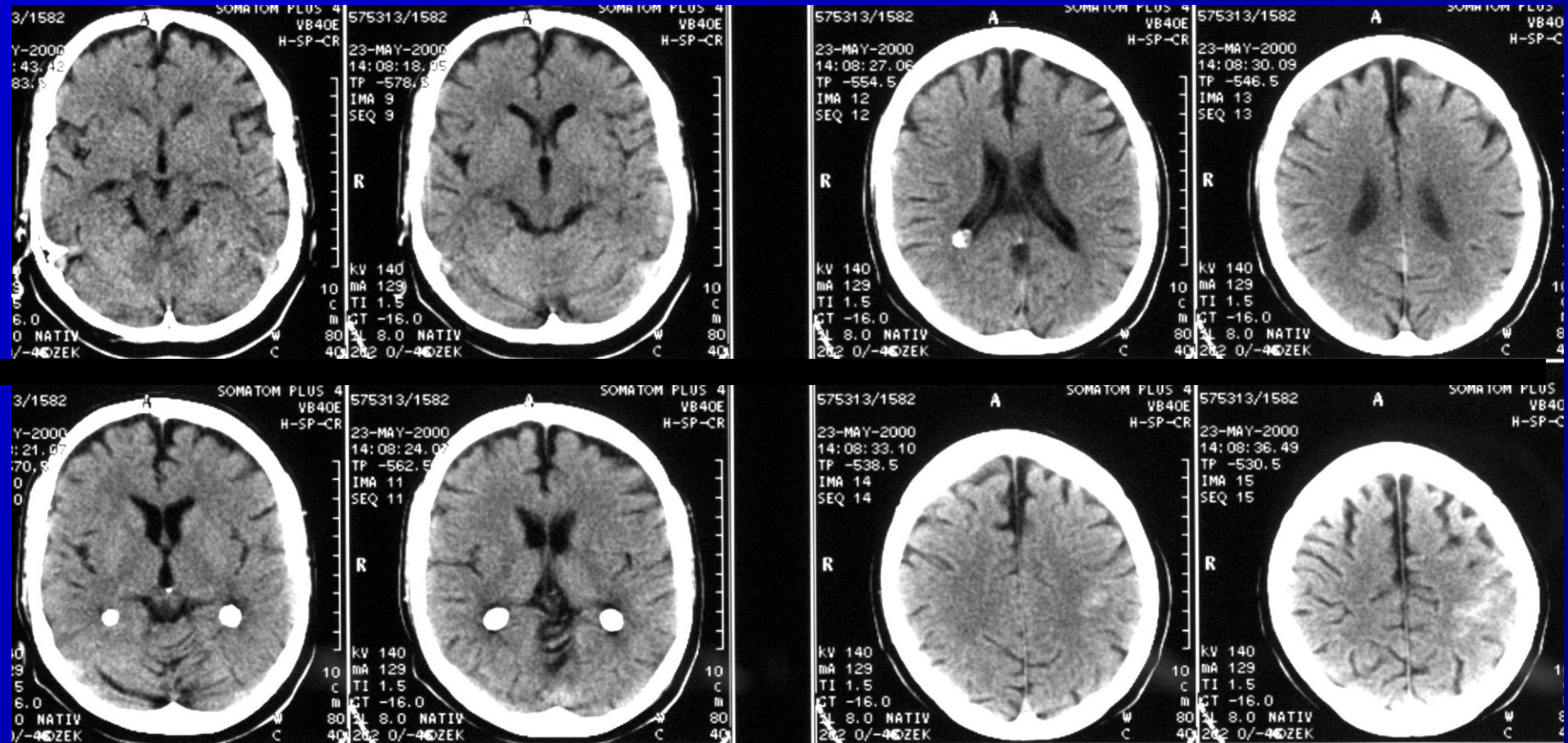
Bazální ganglia



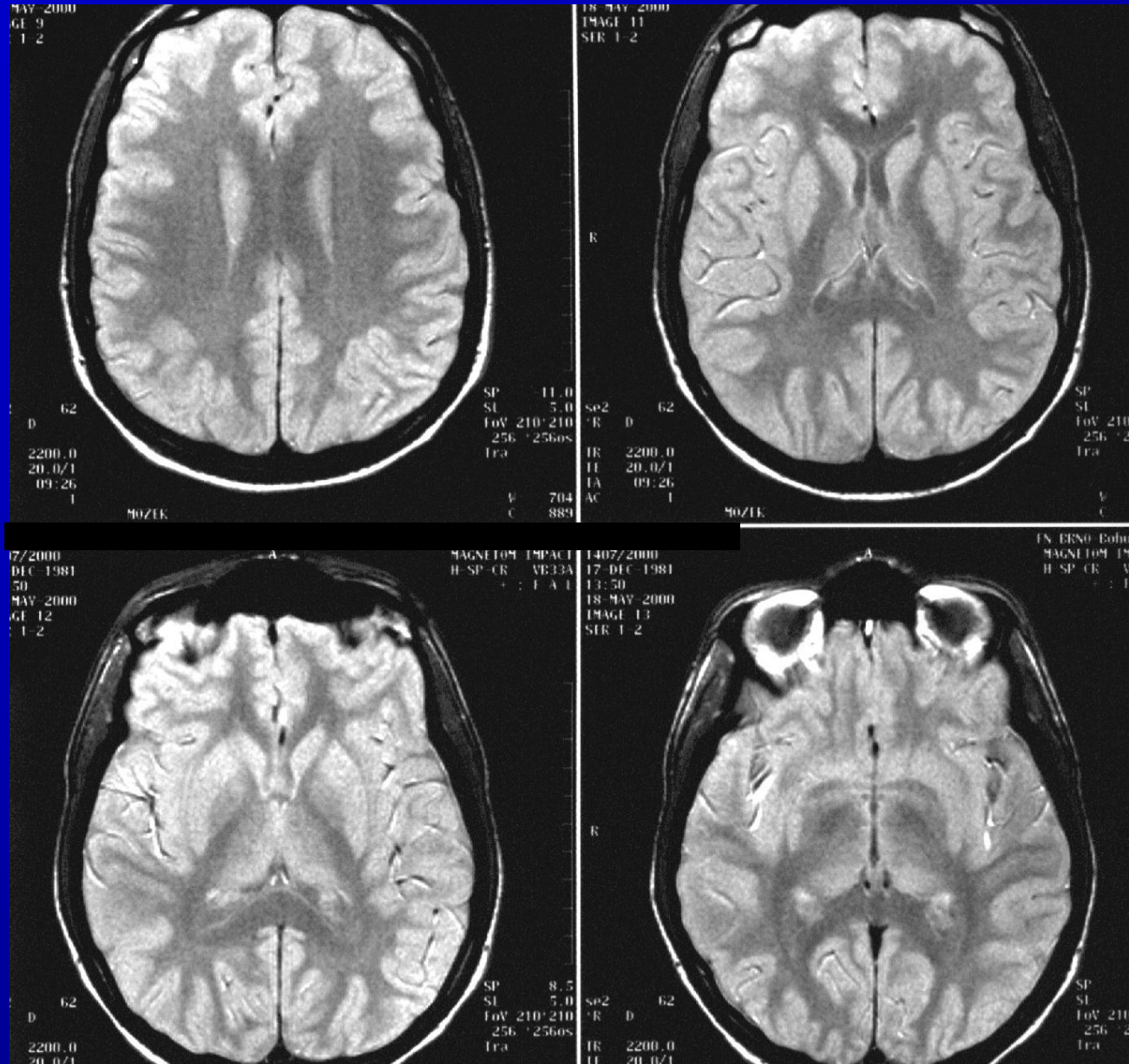
Bazální ganglia



Bazální ganglia - CT

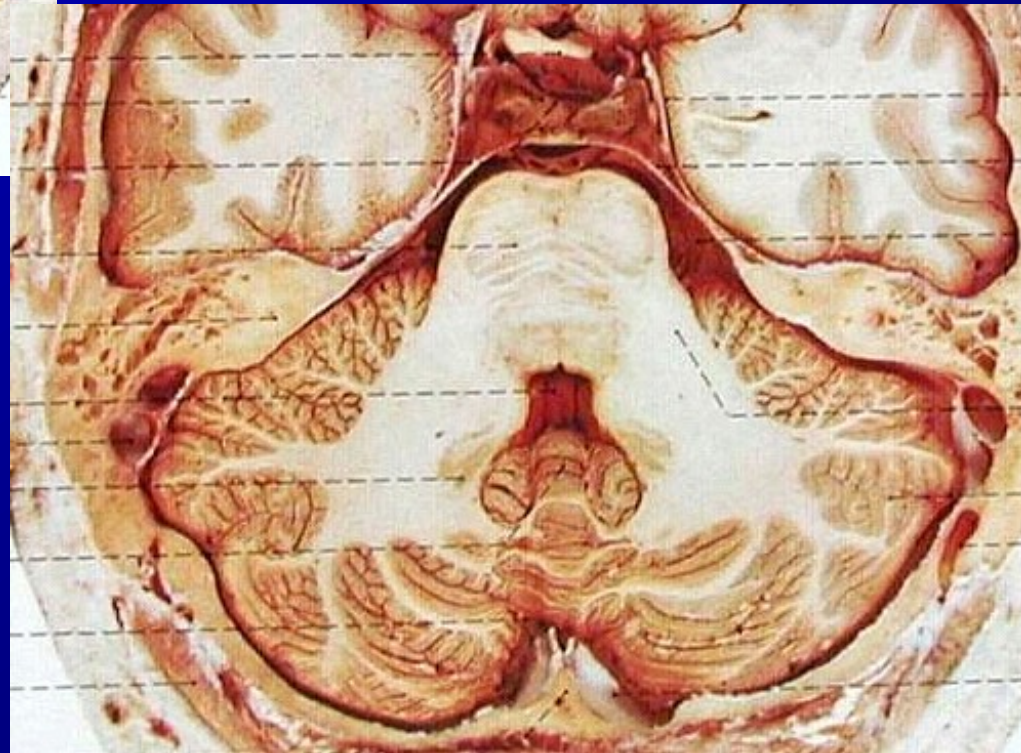
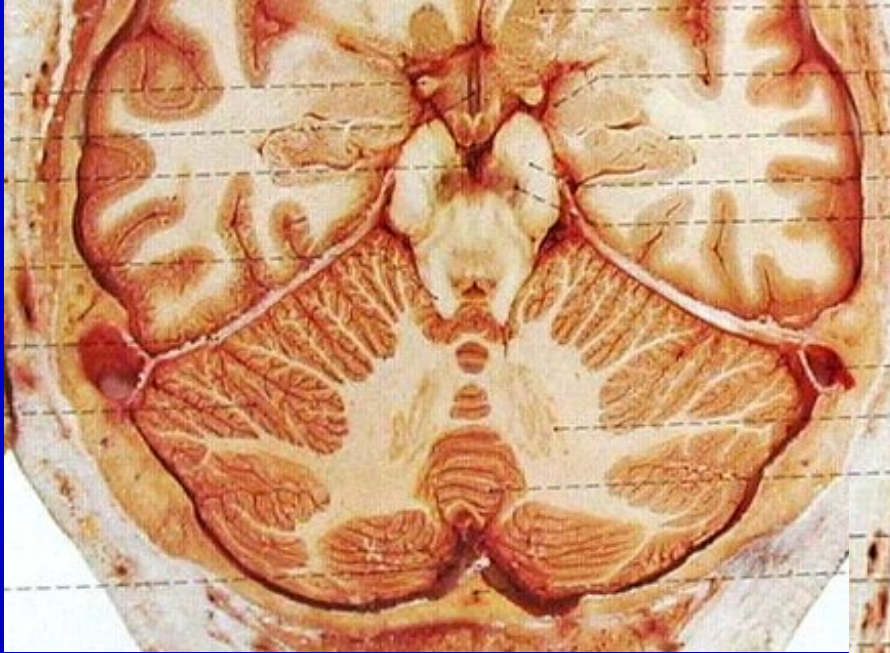


Bazální ganglia – MR (protonová denzita)

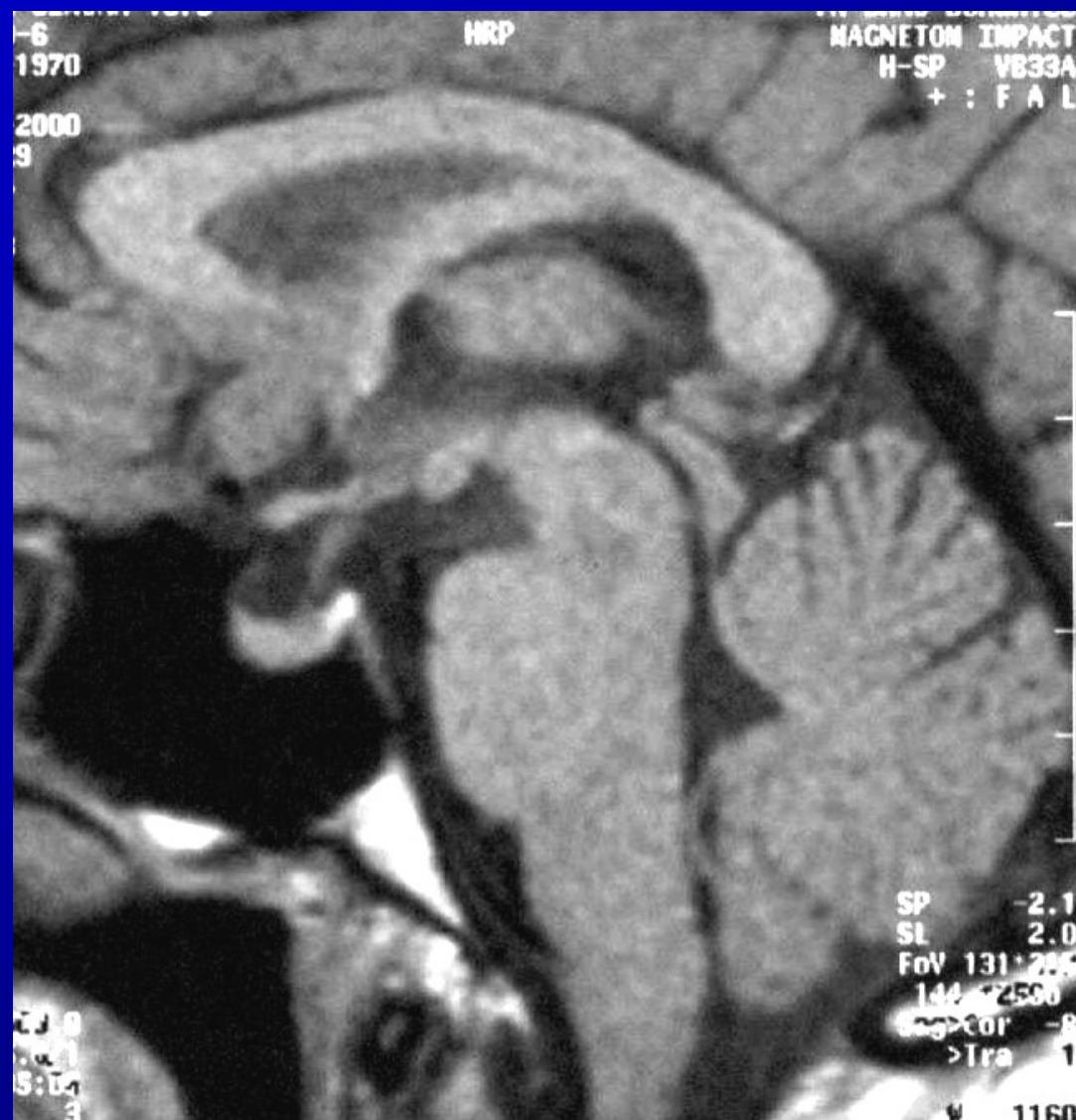
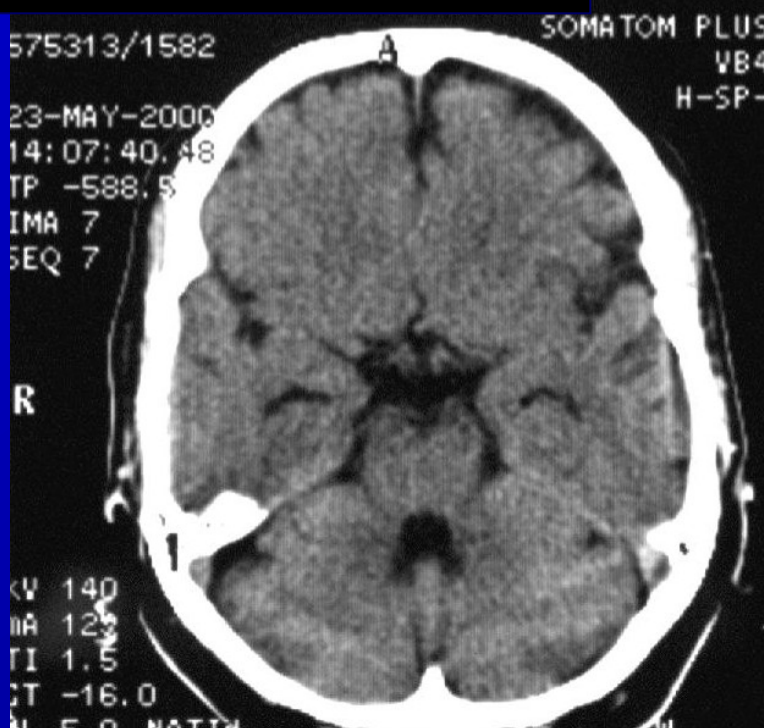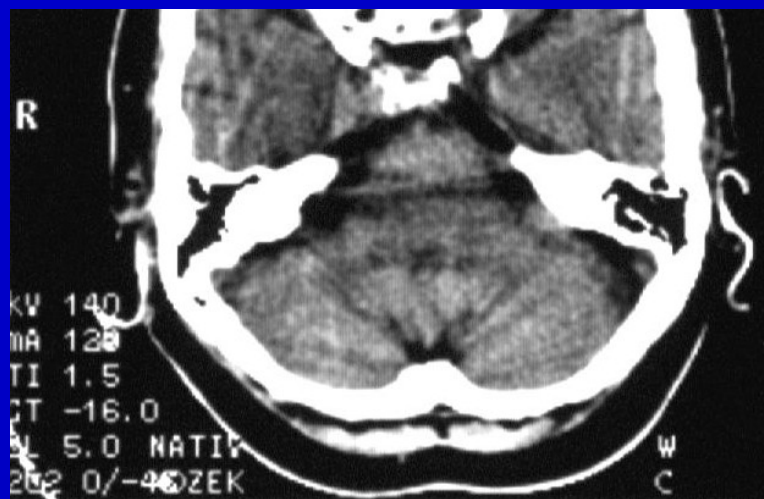


Výborný
kontrast šedé a
bílé hmoty v MR
obraze

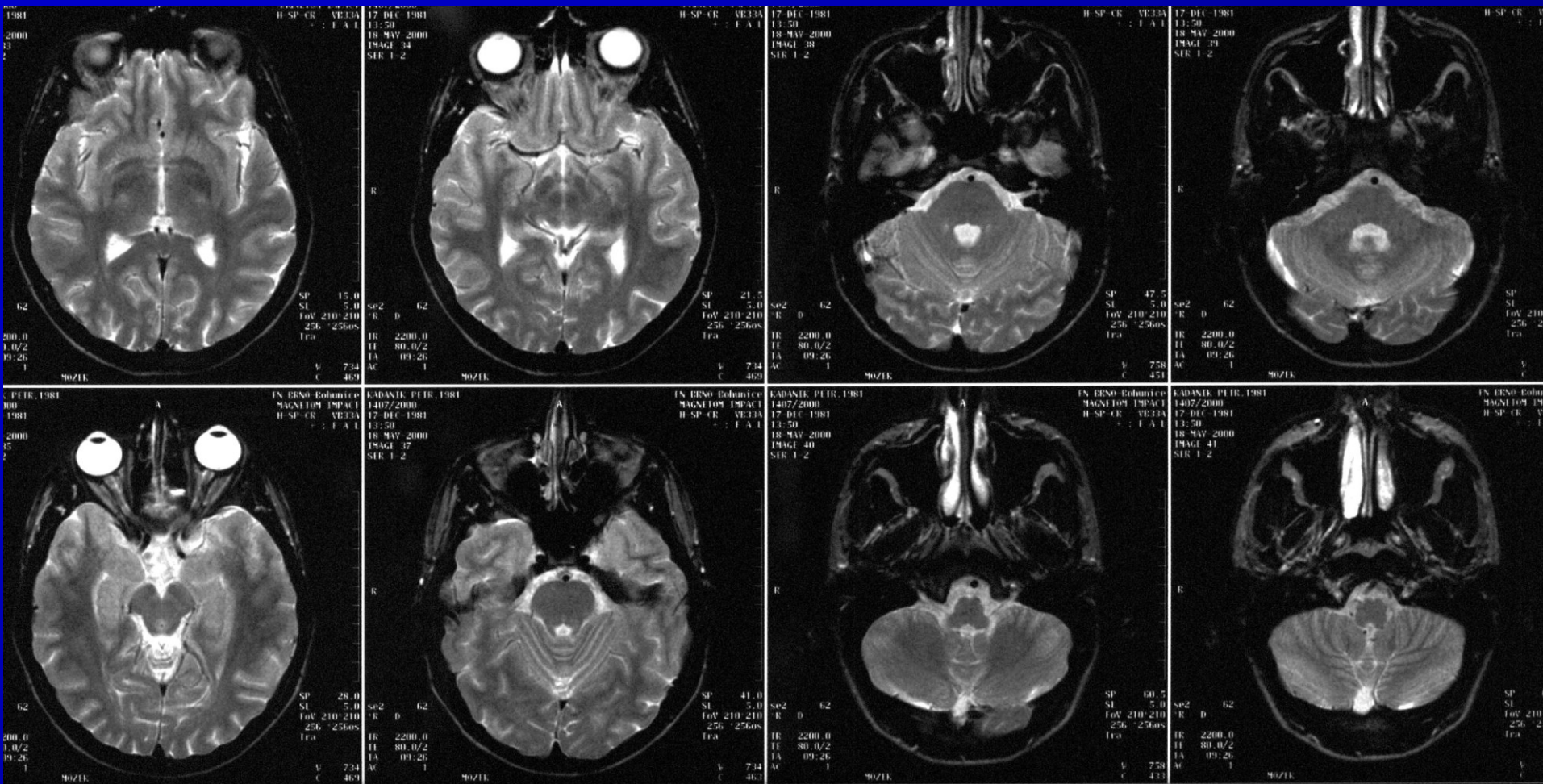
Kmen, mozeček, hl.nervy



Kmen, mozeček, hl.nervy



Kmen, mozeček, hl.nervy

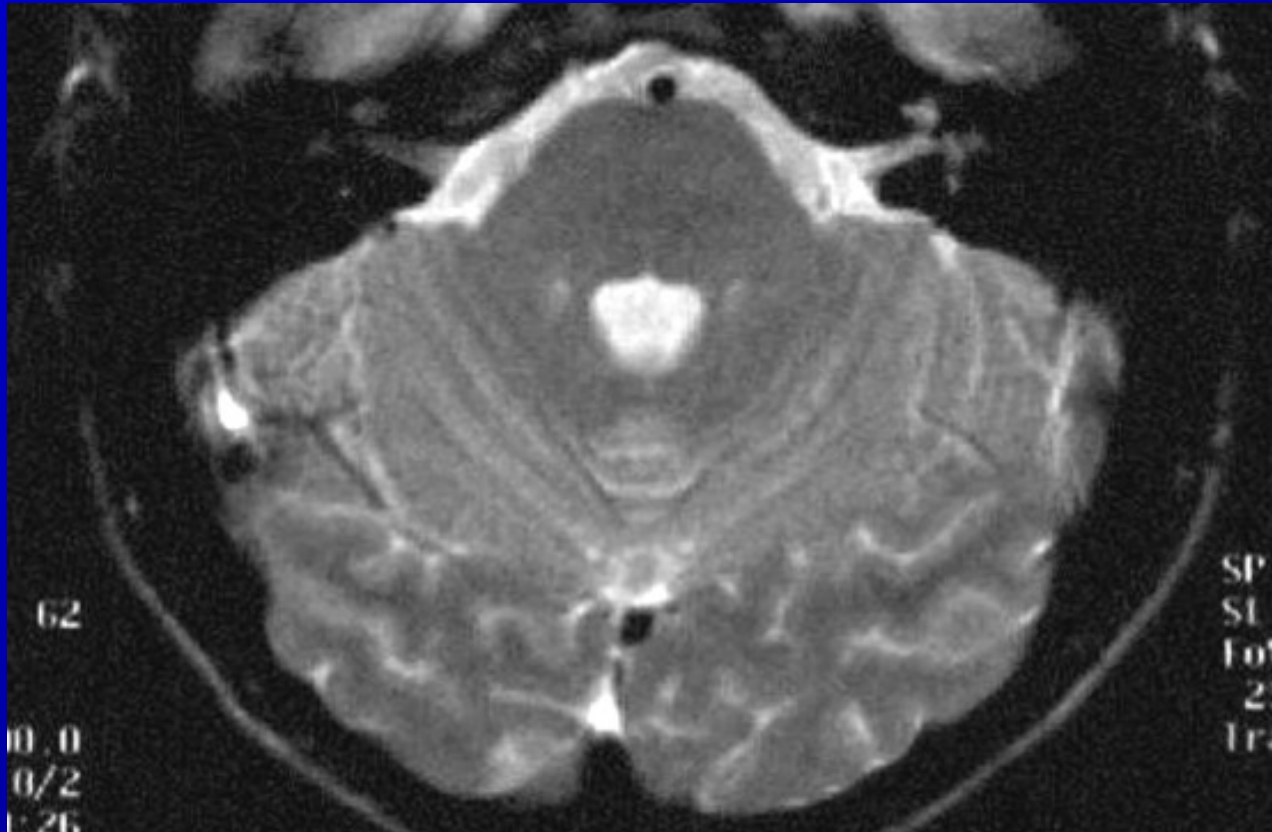


MR – T2 obrázky

Mostomozečkový kout

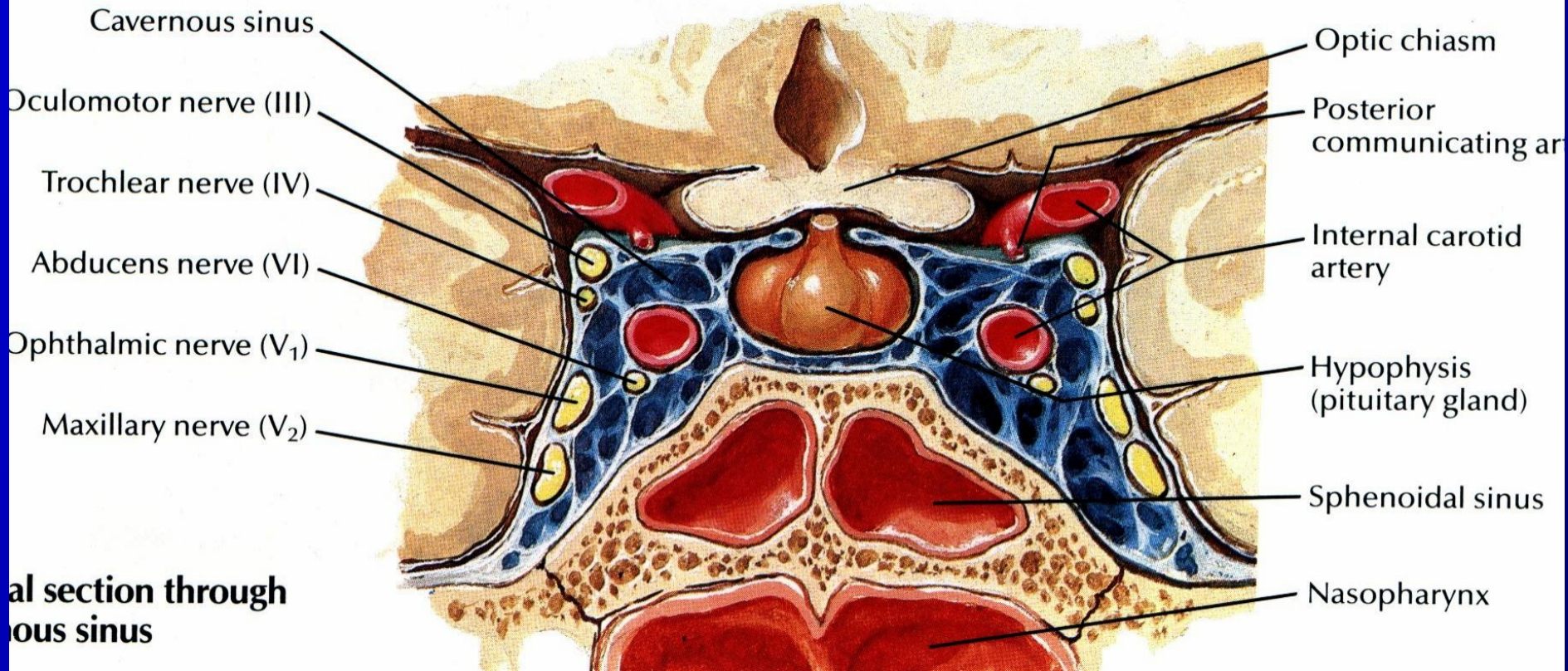
CT - skelet, HRCT

MR - likvorové prostory, k.l. !!

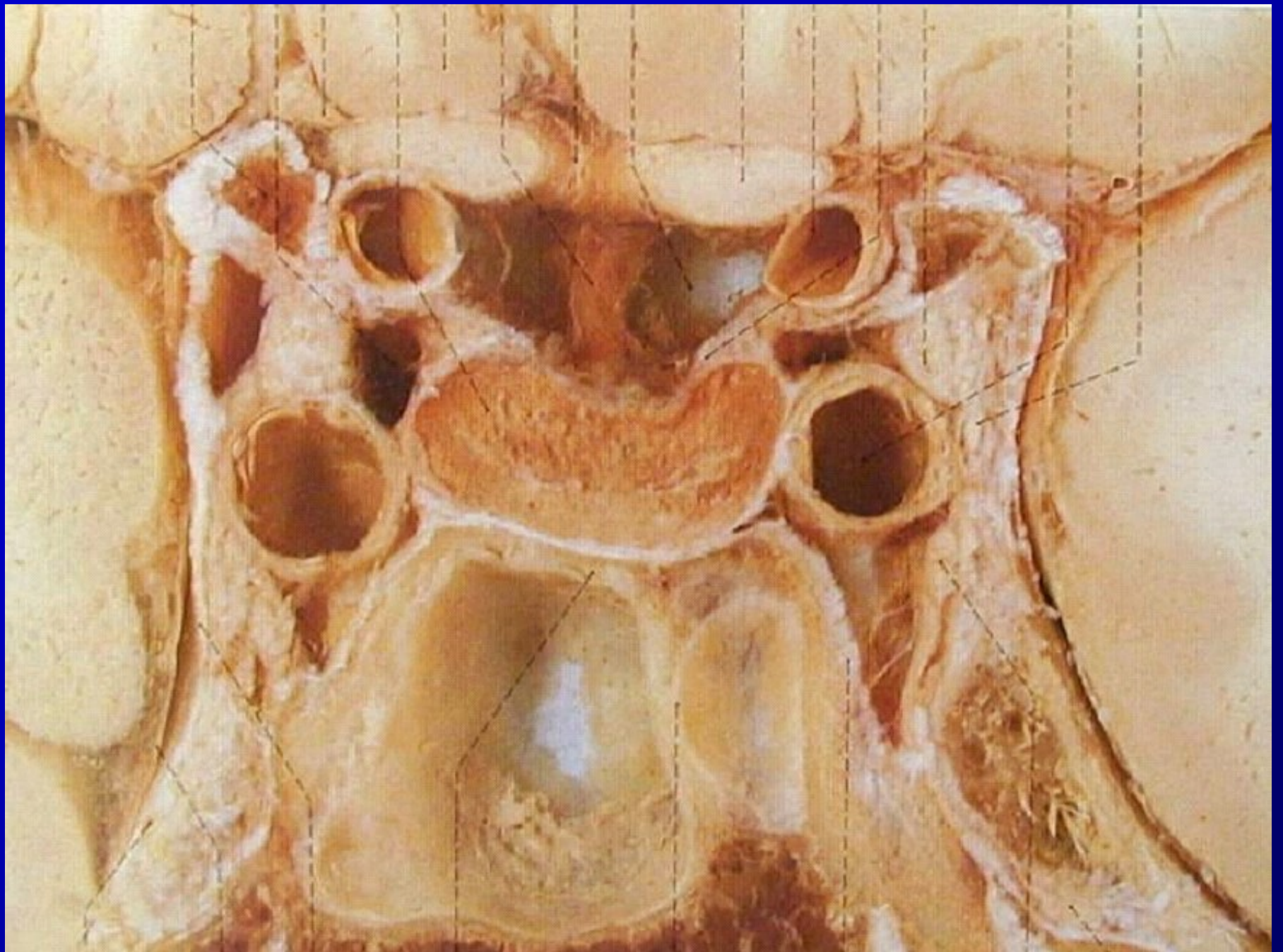


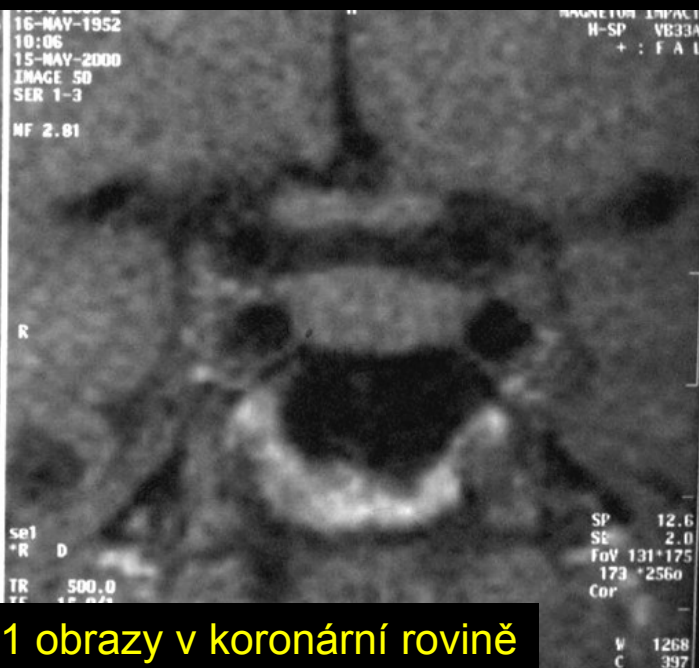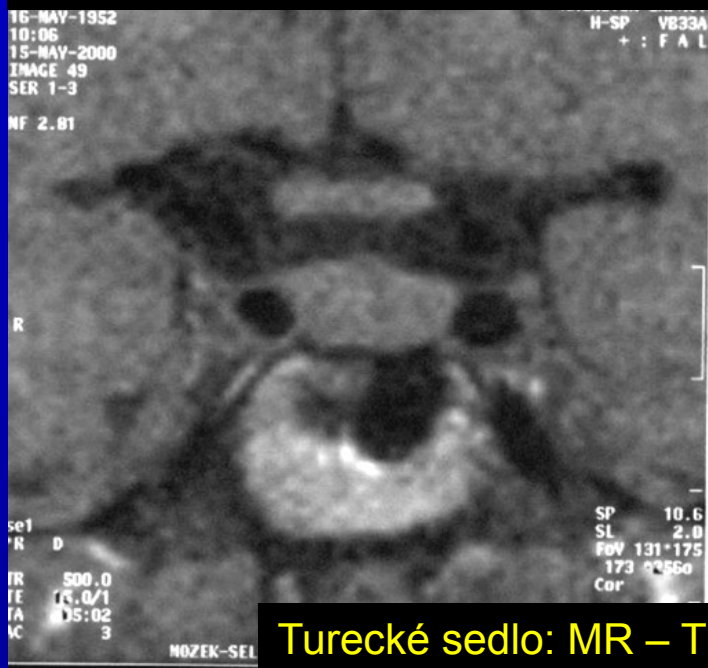
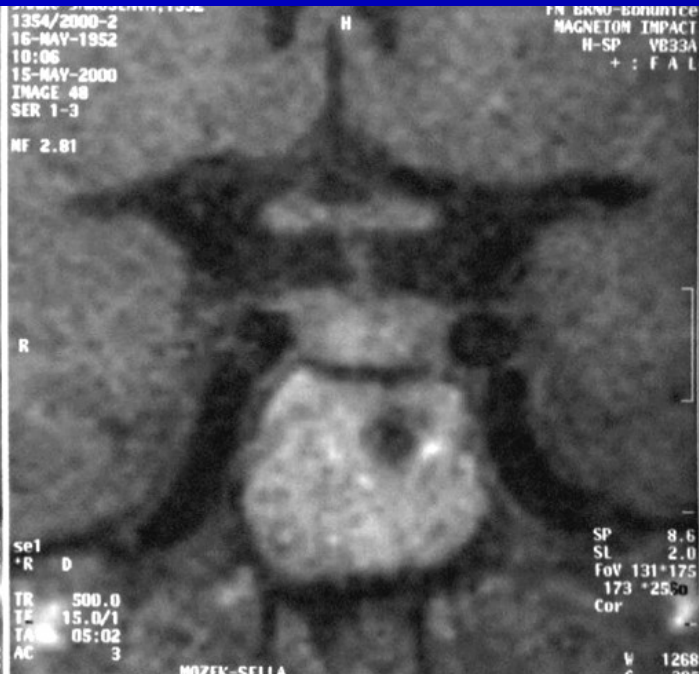
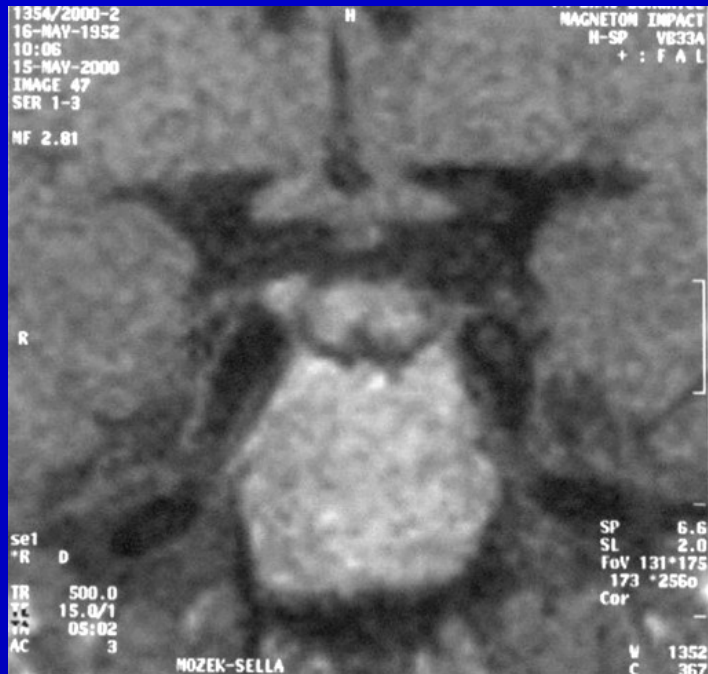
MR – T2 obraz

Turecké sedlo a okolí

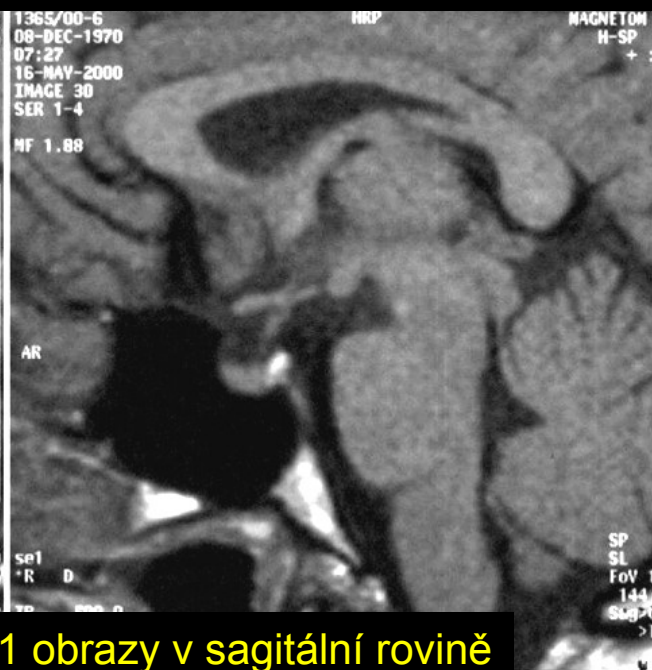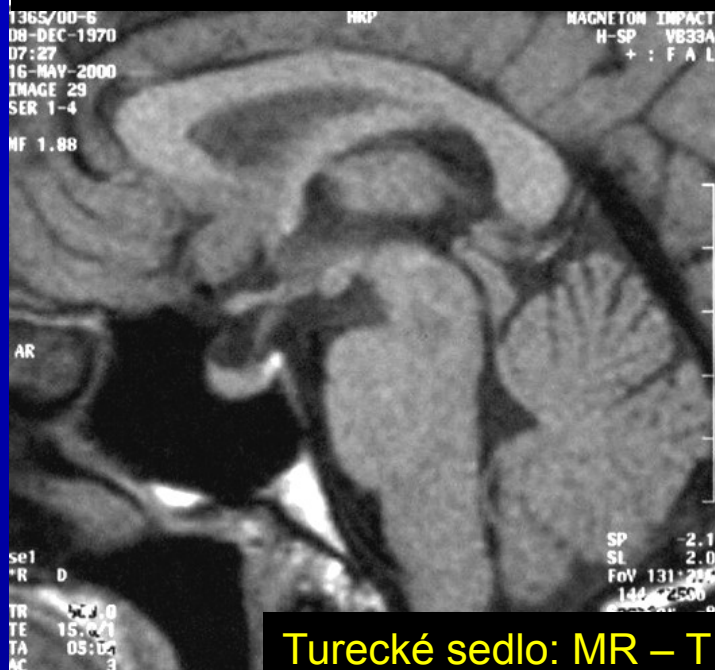
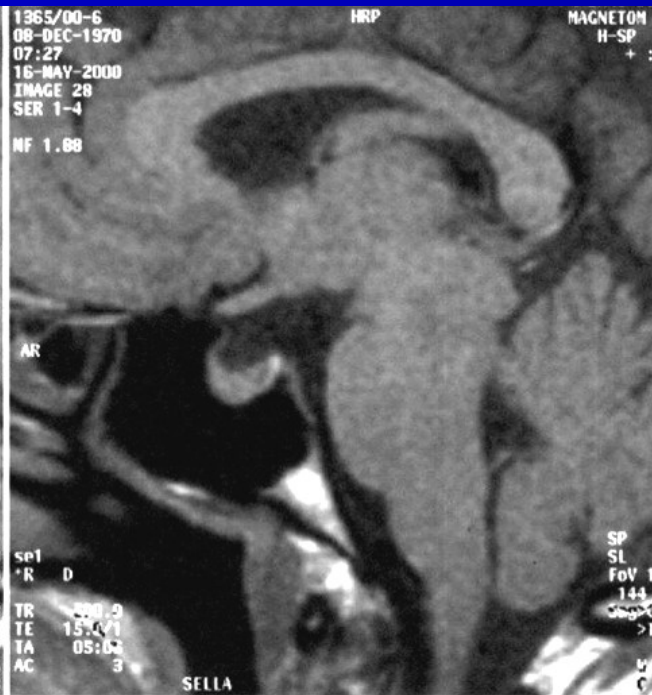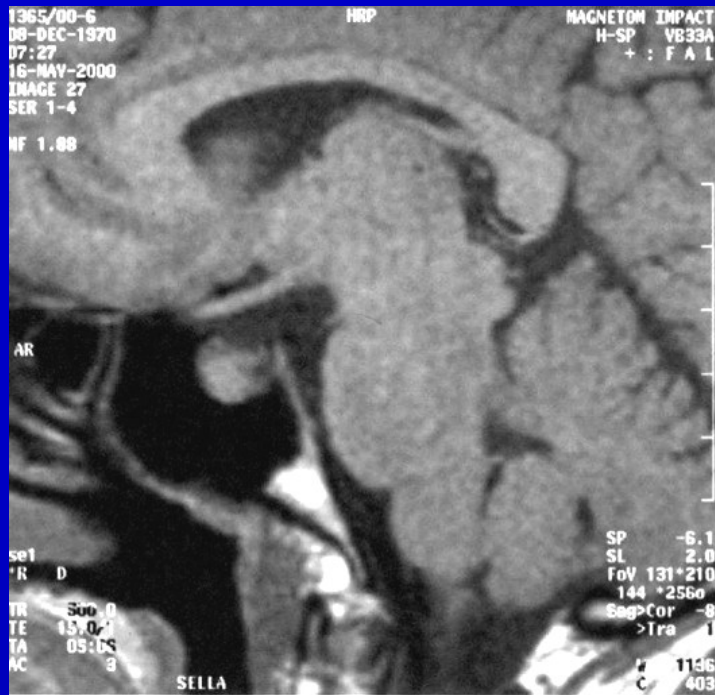


MR + k.I.
CT ??





Turecké sedlo: MR – T1 obrazy v koronární rovině



Turecké sedlo: MR – T1 obrazy v sagitální rovině

Anatomie orbity

* skelet

* měkké tkáně

- bulbus

- optický nerv (a obaly)

- oblast konu (intrakonální)

- oblast extrakonální

B

UPPER LID

SUPERIOR OBLIQUE

MEDIAL RECTUS

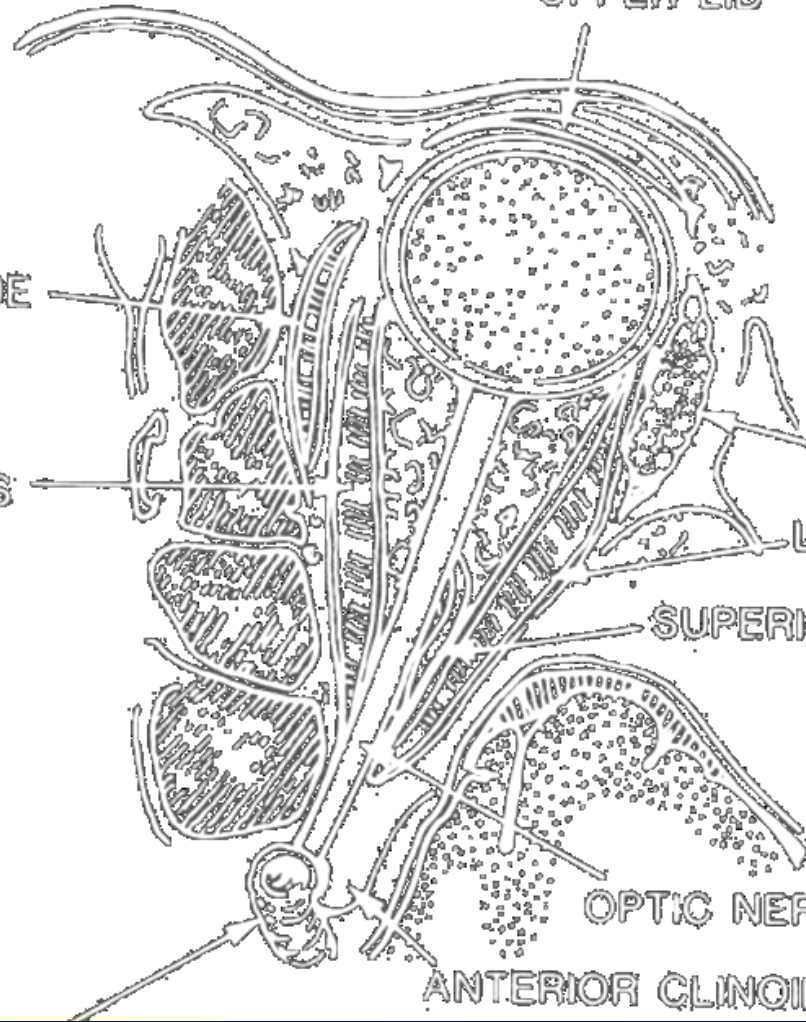
LACRIMAL GLAND


LATERAL RECTUS

SUPERIOR OPHTHALMIC VEIN

OPTIC NERVE IN OPTIC CANAL

ANTERIOR CLINOID PROCESS





Anatomie orbity

Bulbus

- přední a zadní část (čočka)
- vrstvy stěny nevidíme (UZ ano !)

Optický nerv

- orbitální, intrakan.a intrakran.
- 4,5 cm
- pochva - stejné obaly jako mozek

Anatomie orbity

Intrakonální prostor

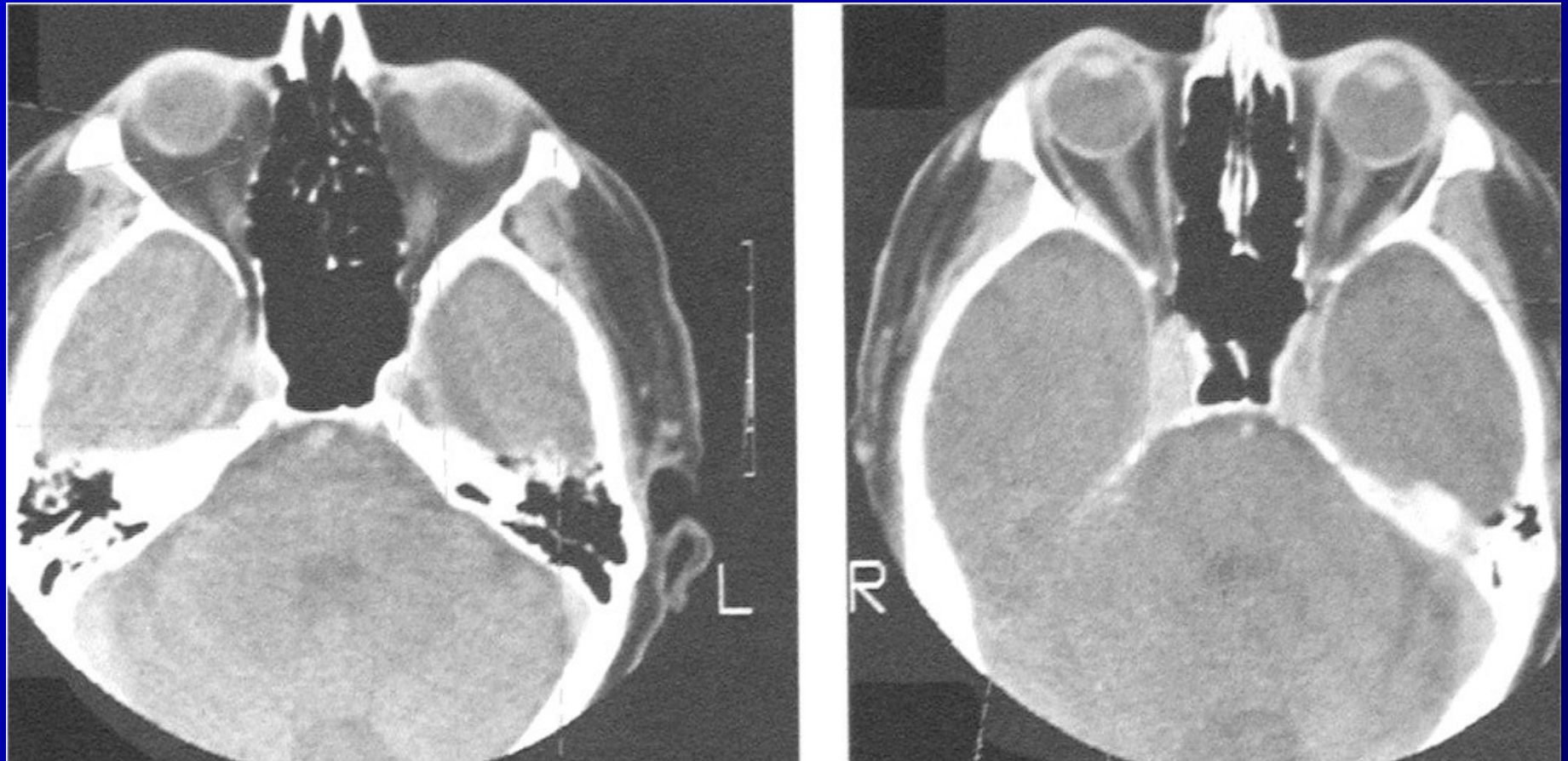
- svaly tvoří konus (7)
- obsahuje tuk, cévy (a.+v.opht.), nervy (větve III,IV,VI,V) a n.II

Extrakonální prostor

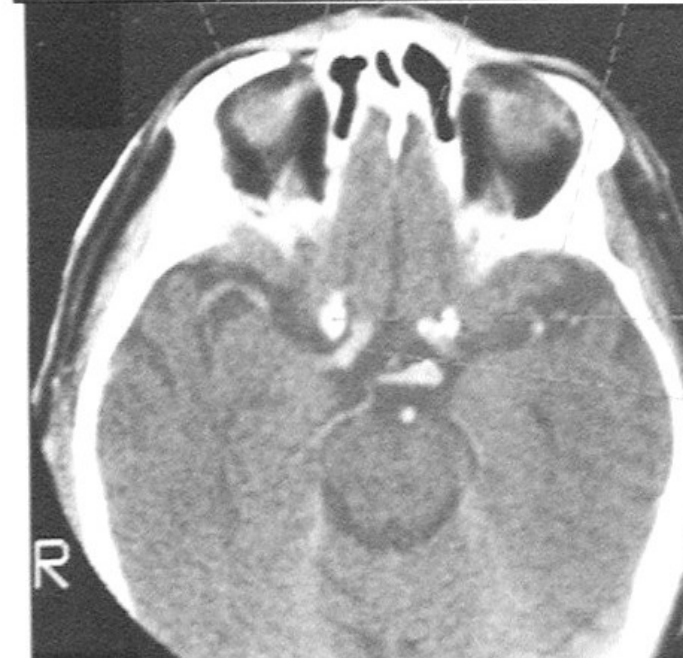
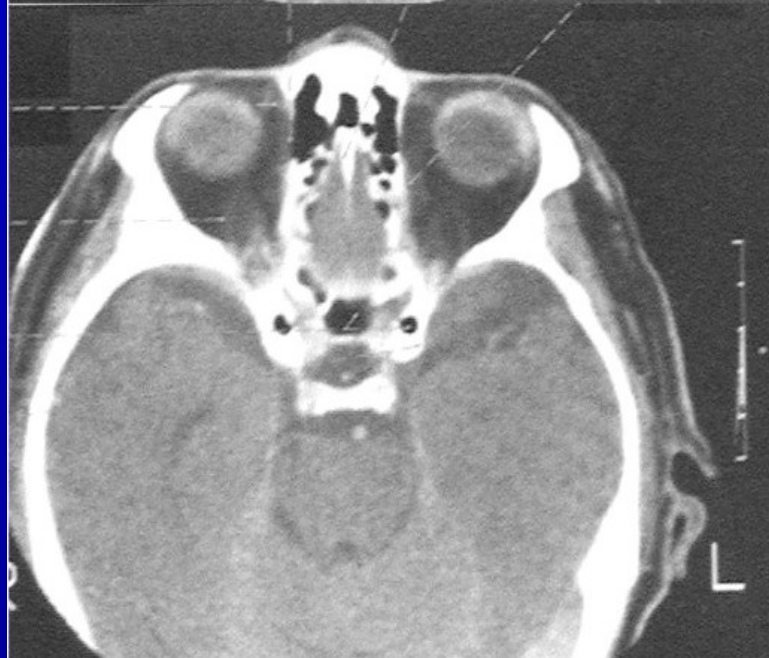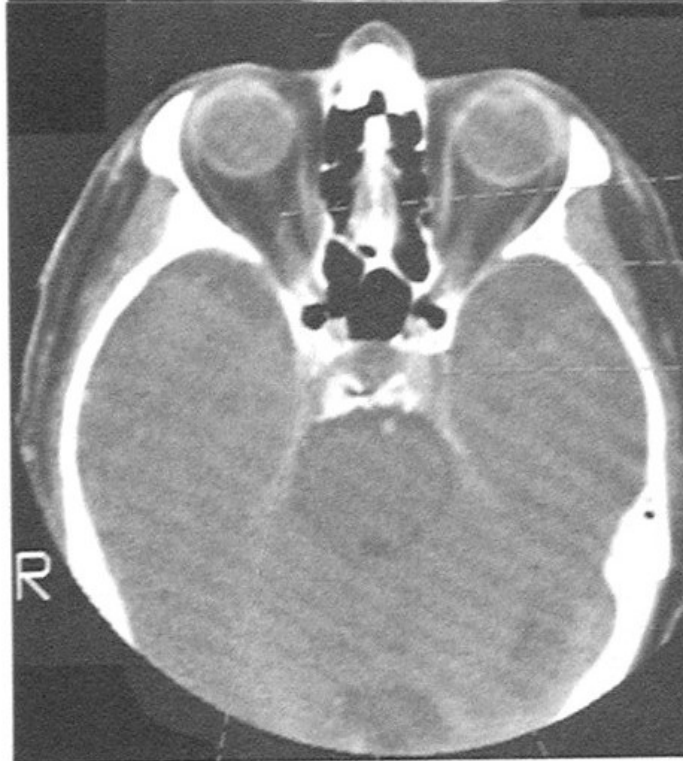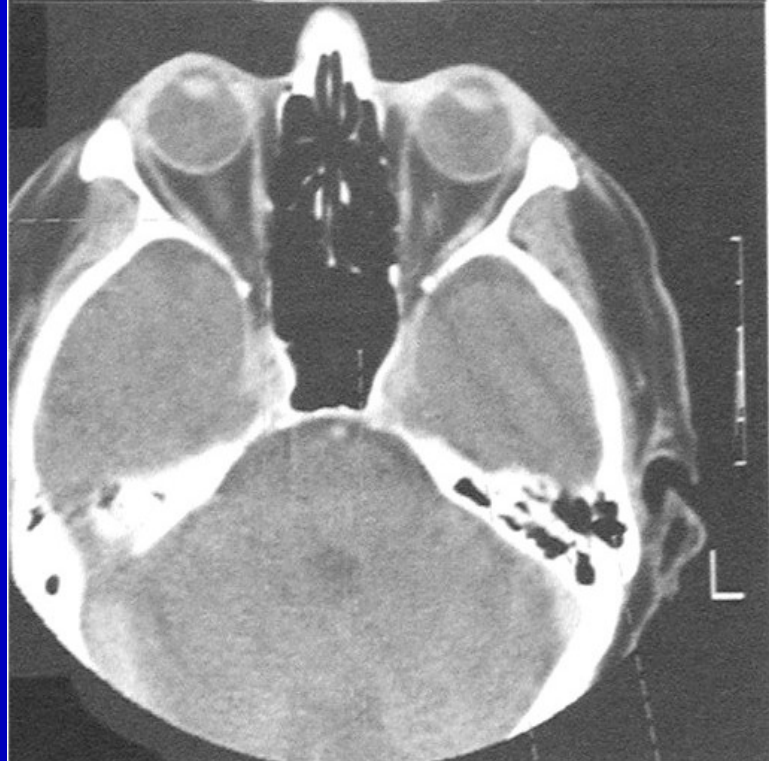
- prostor mezi svaly a skeletem
- obsahuje tuk a slznou žlázu

Anatomie orbity - CT

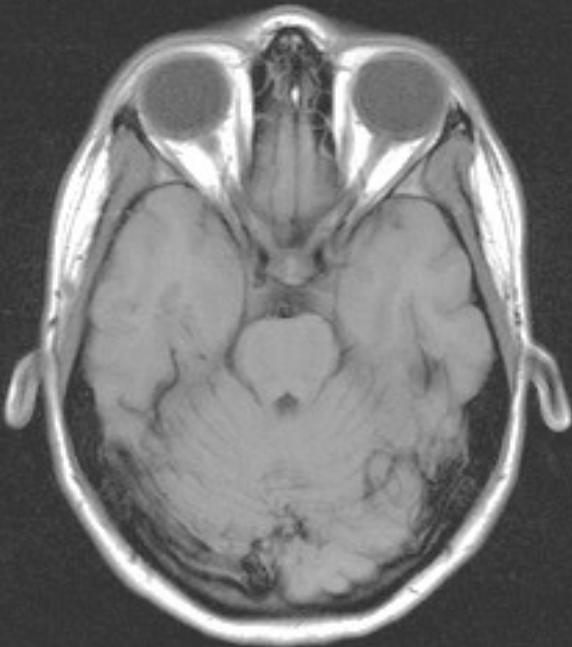
- transverzální a koronární obrazy



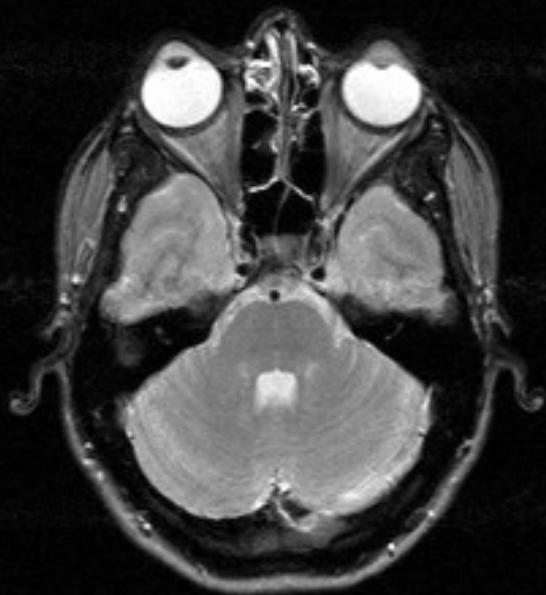
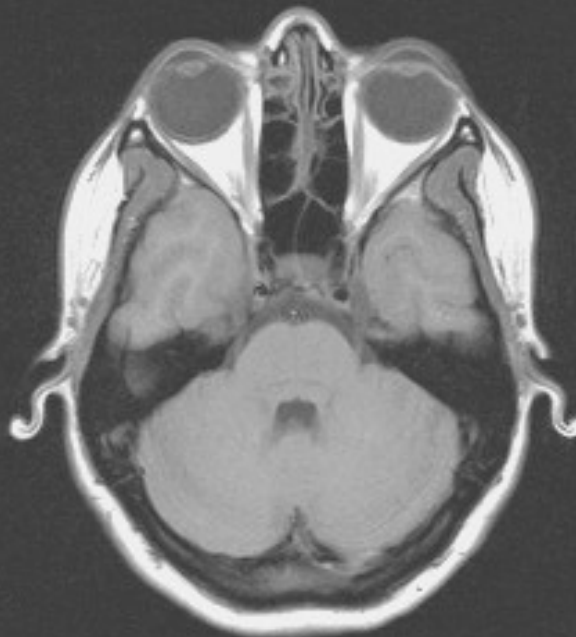
CT



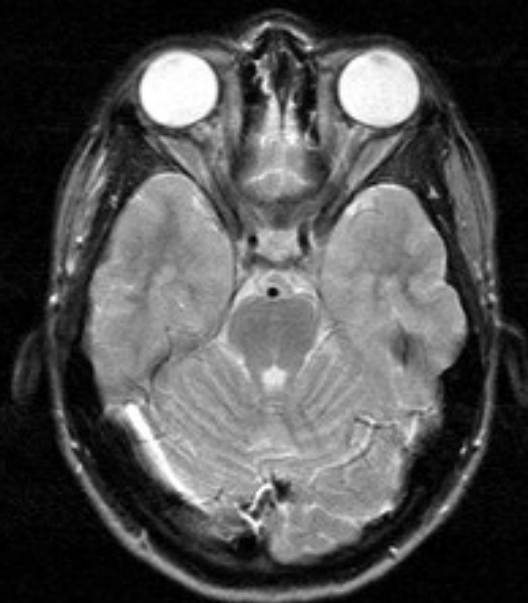MR



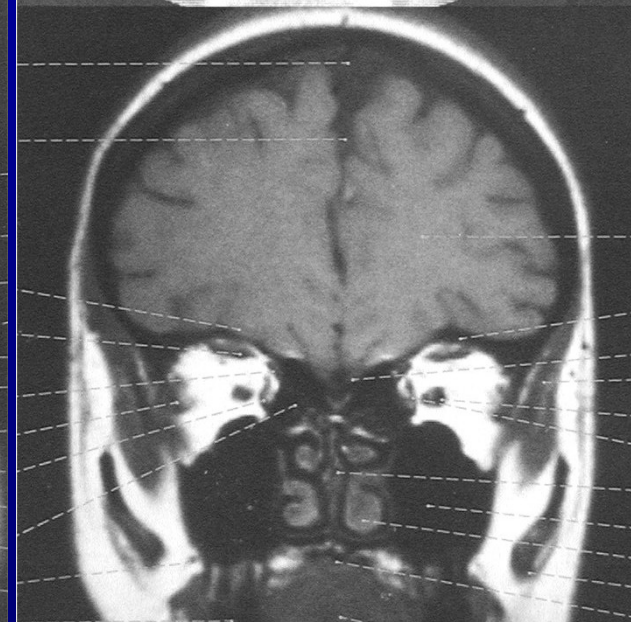
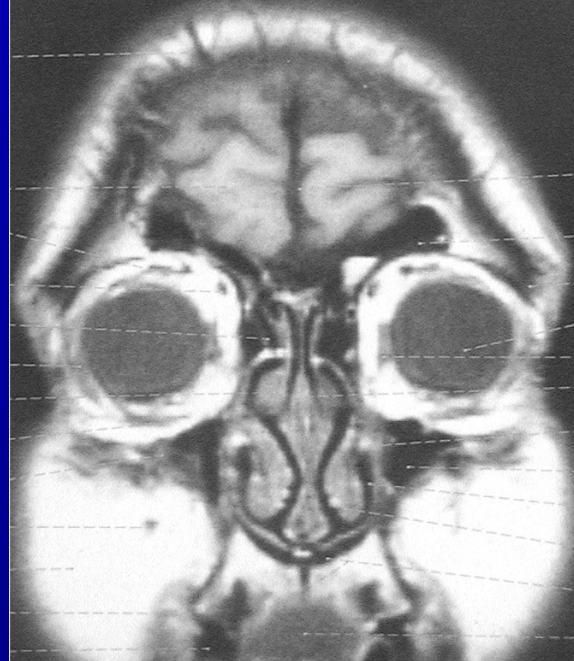
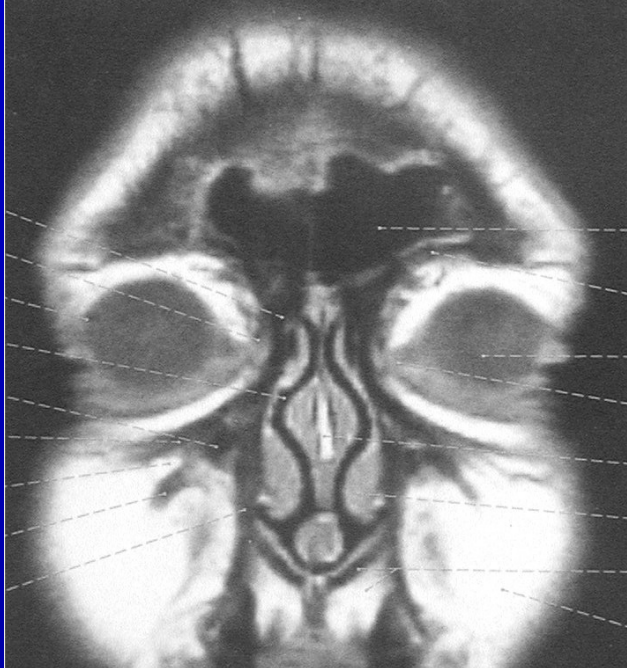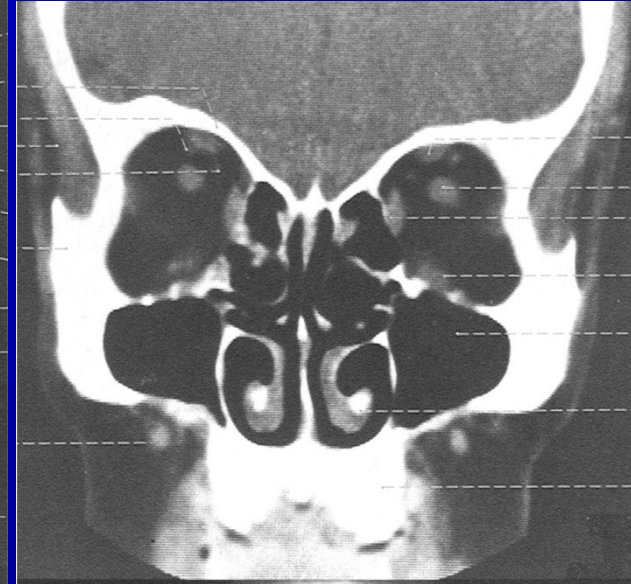
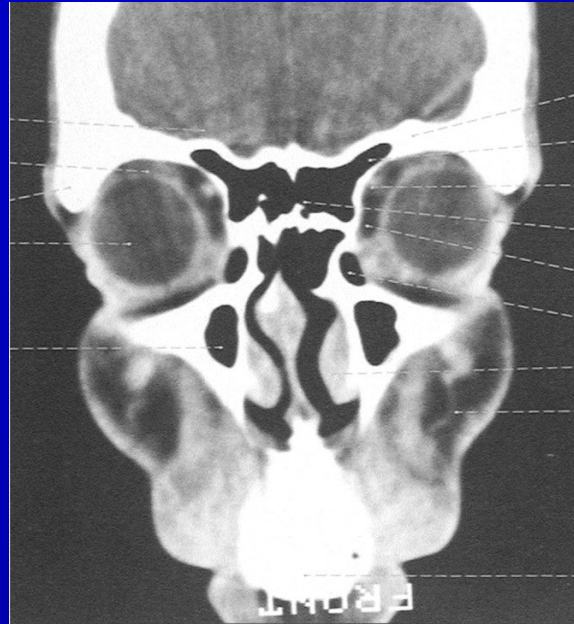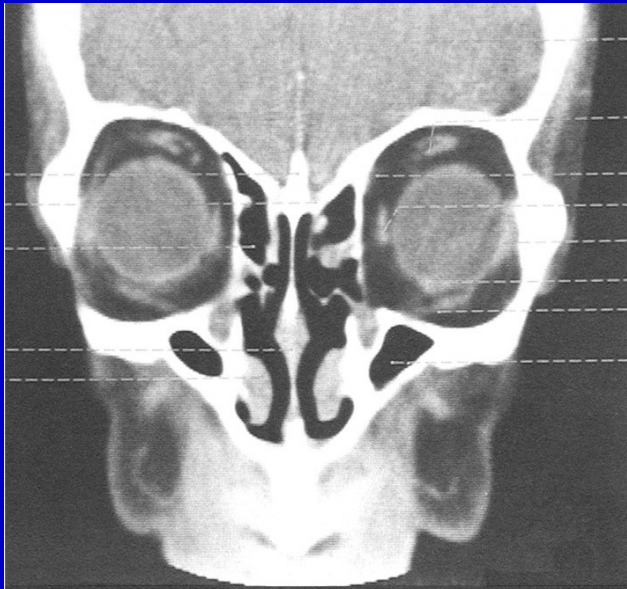
T1 obraz



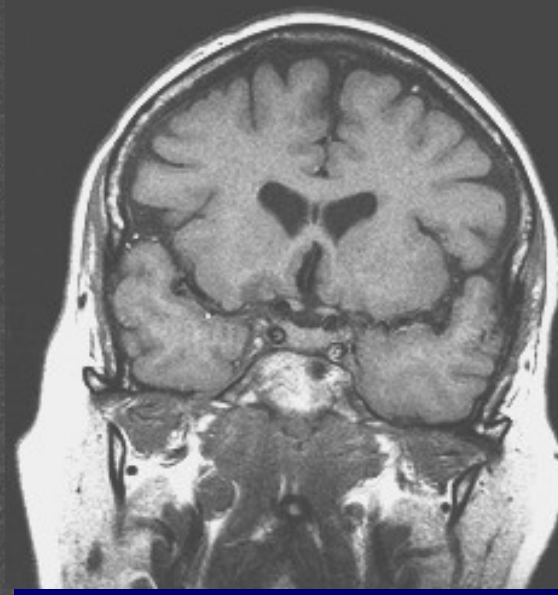
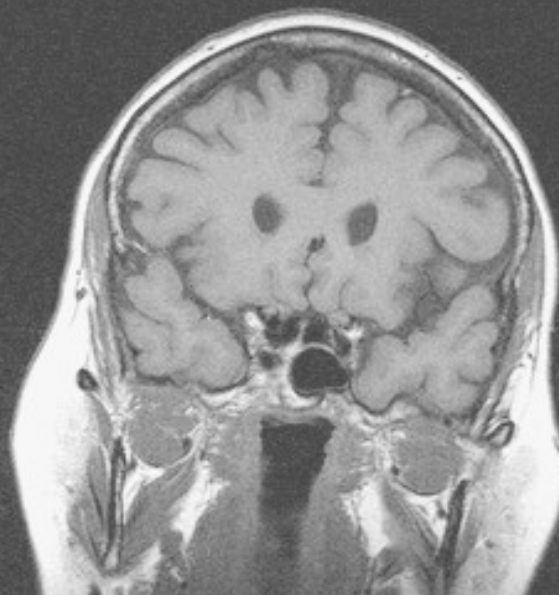
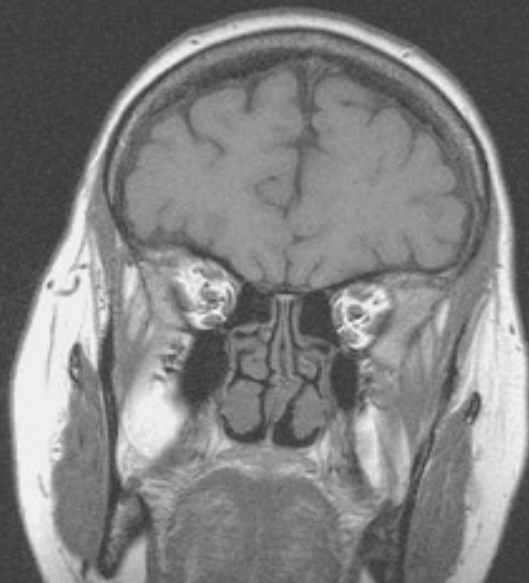
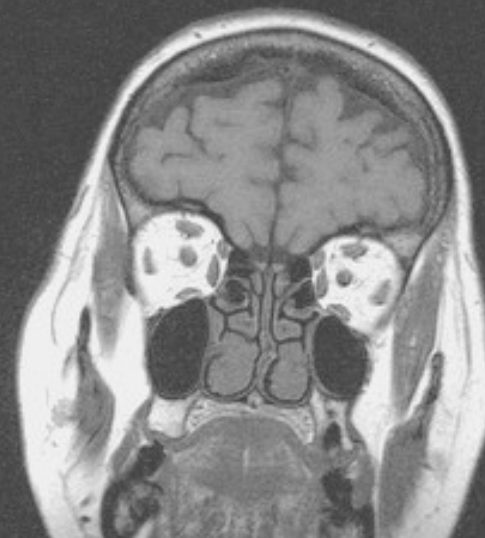
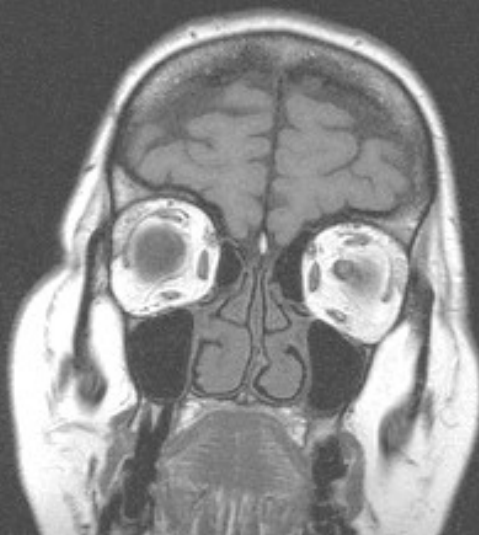
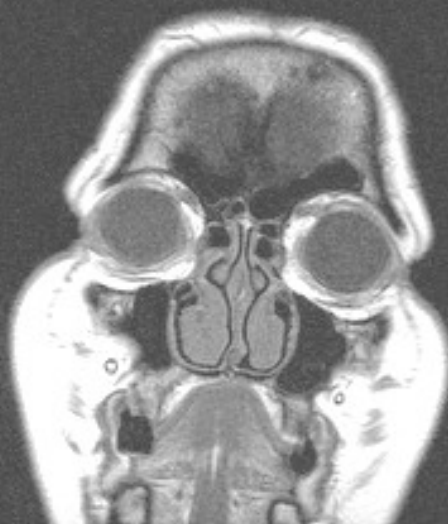T2 obraz



CT, koronární rekonstrukce



MR T1 obraz, koronární rovina

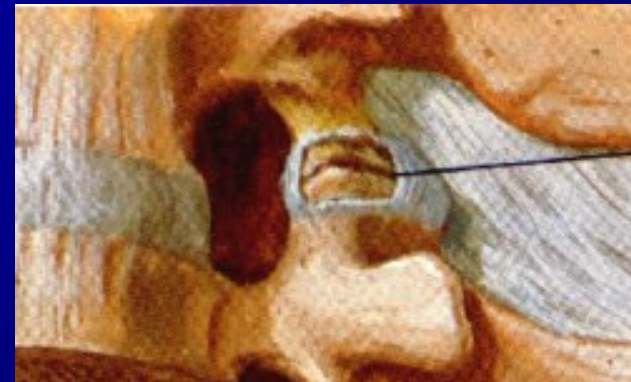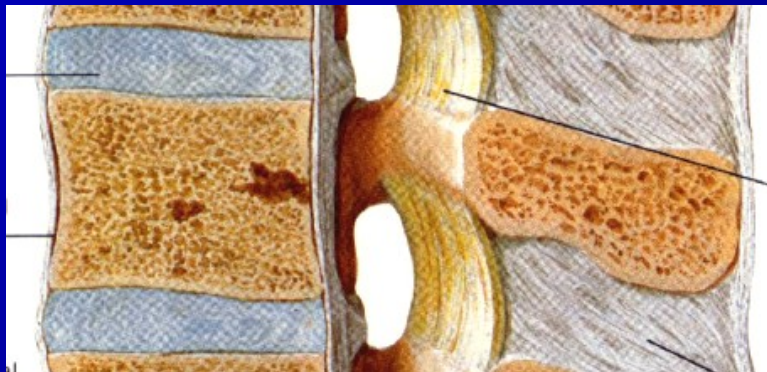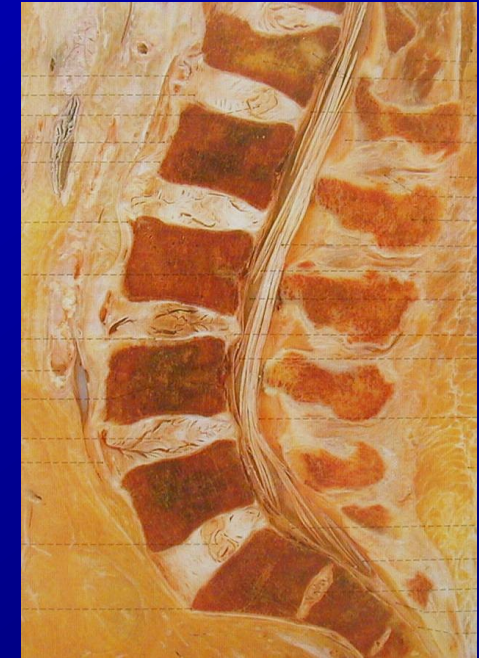
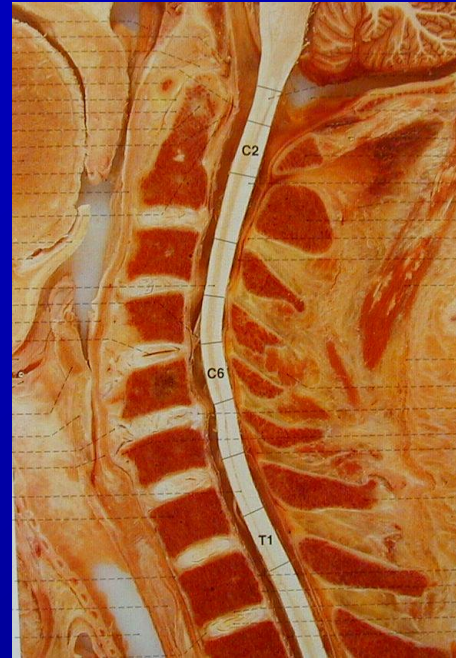


Orbity: MR T1 obraz, koronární rovina

CT a MR anatomie páteře a páteřního kanálu

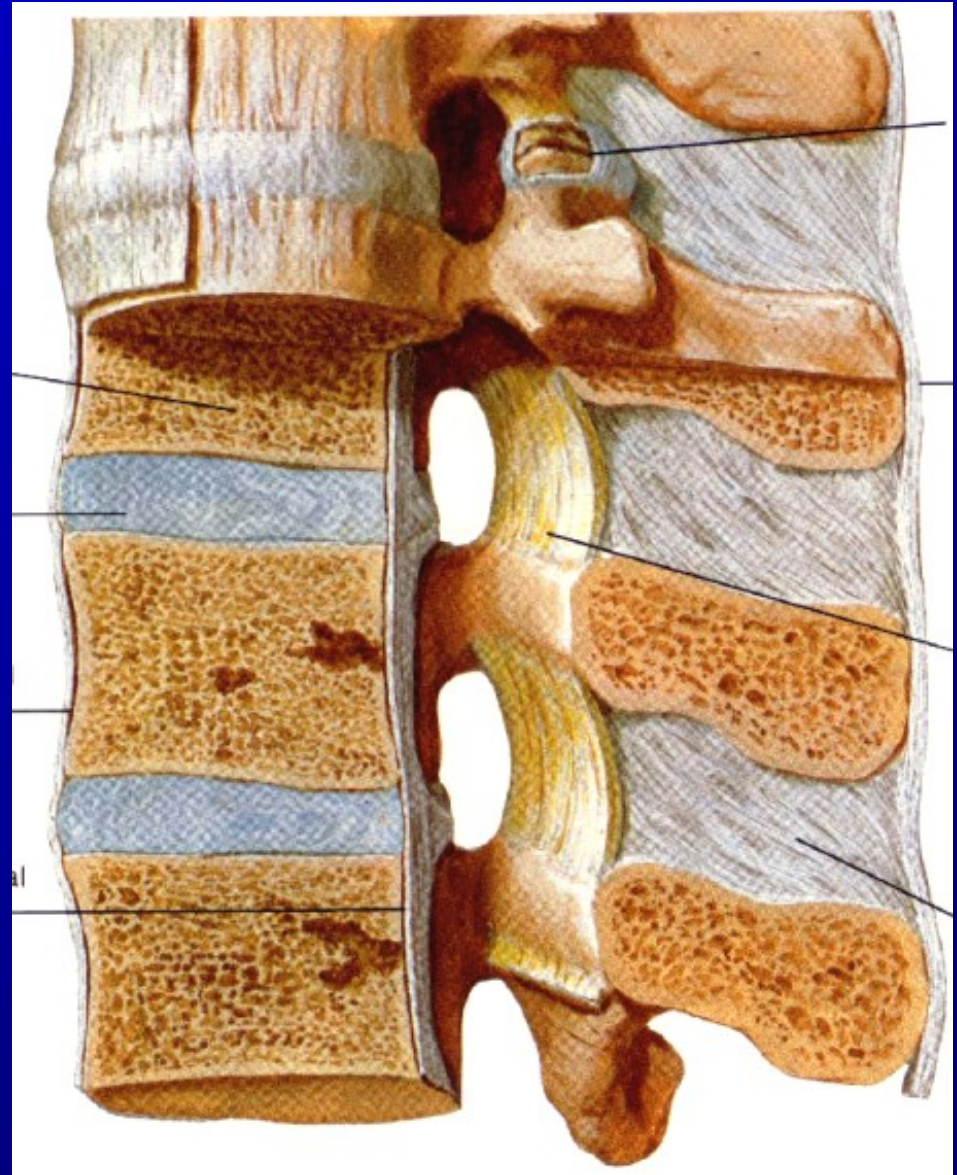
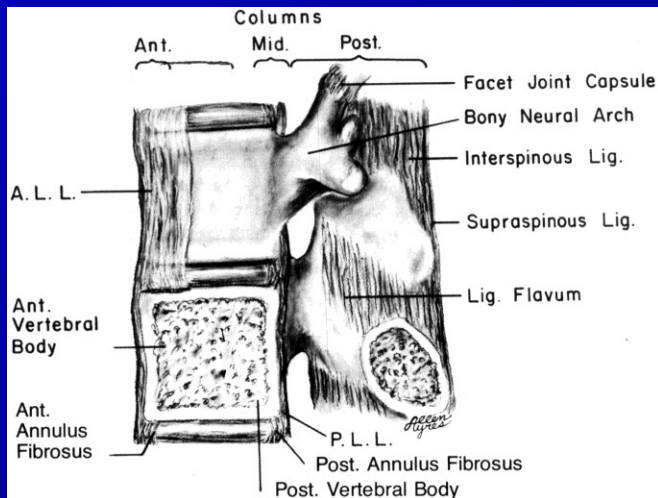
Anatomie - obratle

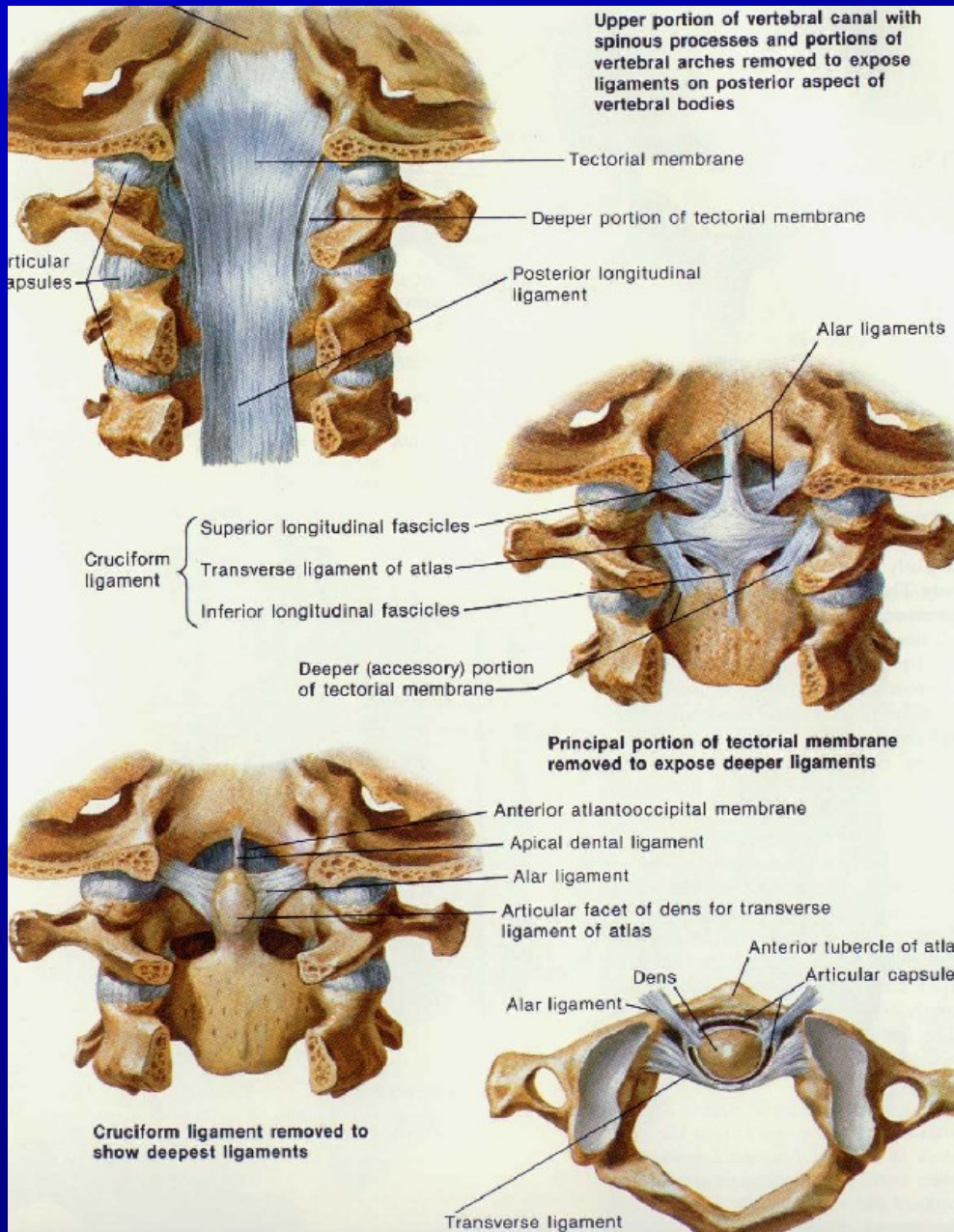
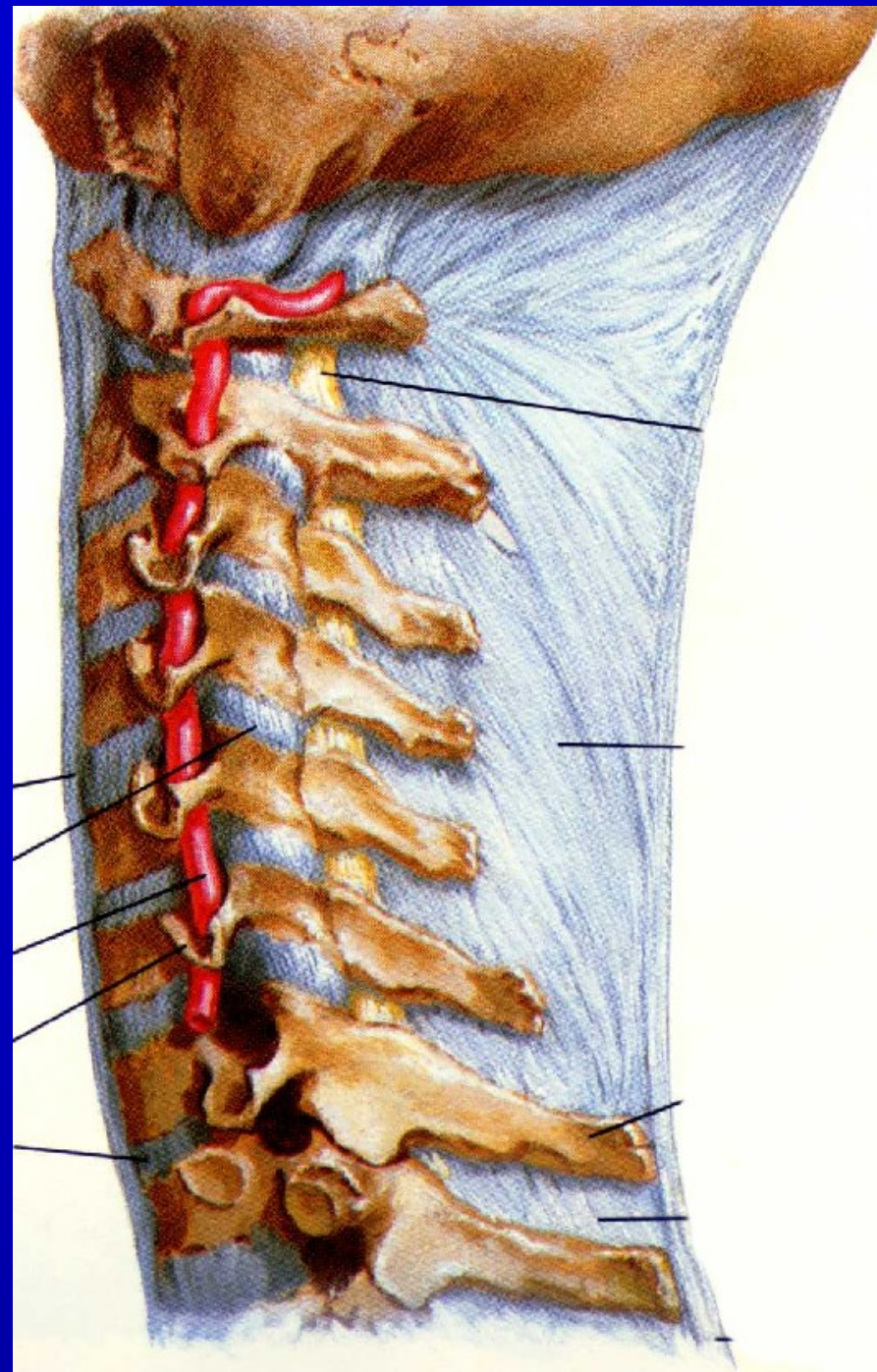
- 33 ks
- tělo a oblouk
 - 2 pedikly
 - 2 laminy
 - 4 kloubní výběžky
 - 2 příčné výběžky
 - 1 spinózní
- foramina - ohraničení



Anatomie - ploténky a vazy

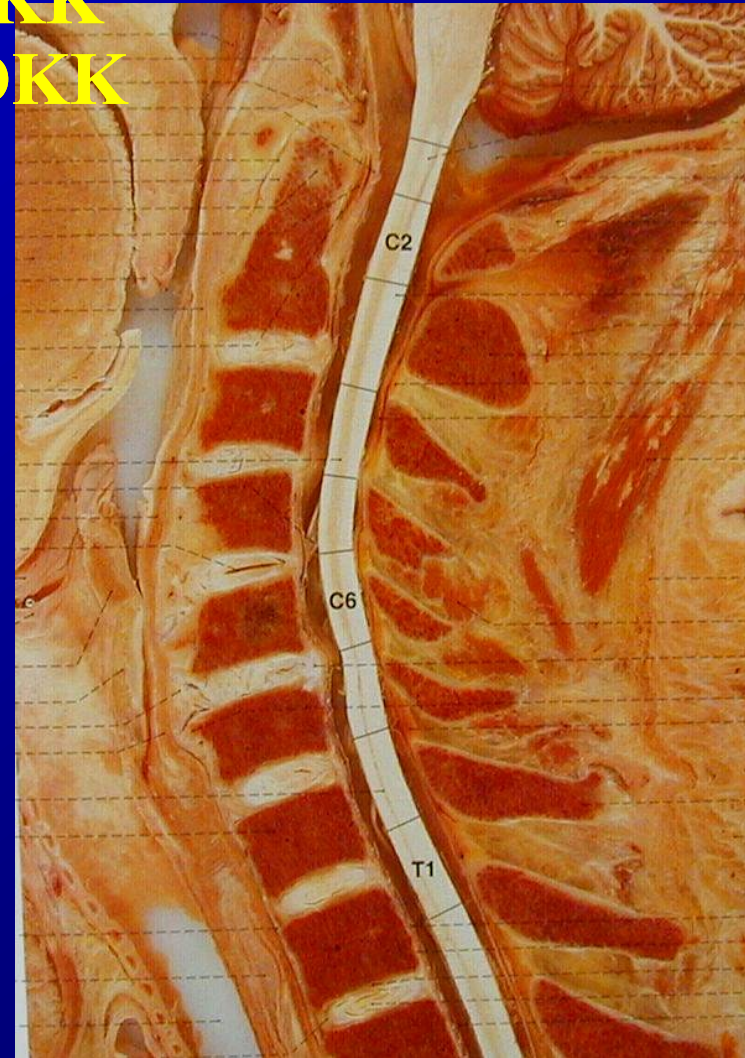
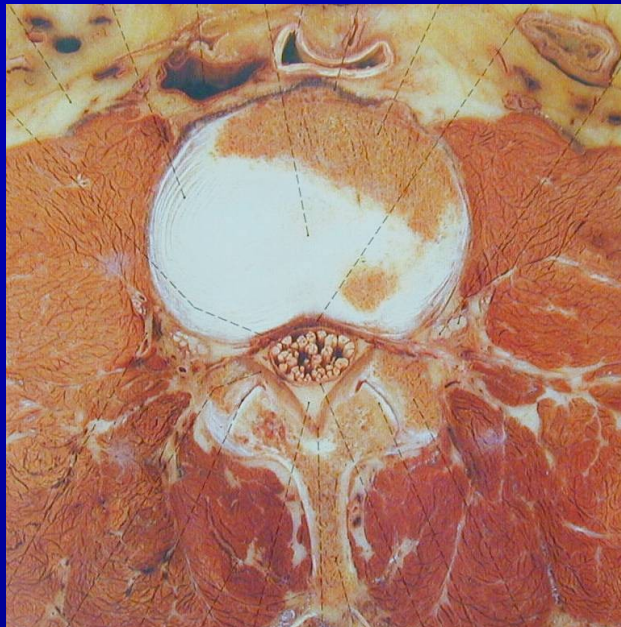- **disk - ncl.pulposus + annulus fibrosus**
- **přední a zadní podélný vaz**
- **lig. flava - spojují laminy**
- **interspinální ligamentum**
- **lig.supraspinosum - nuchae**
- **lig. intertransversarium**





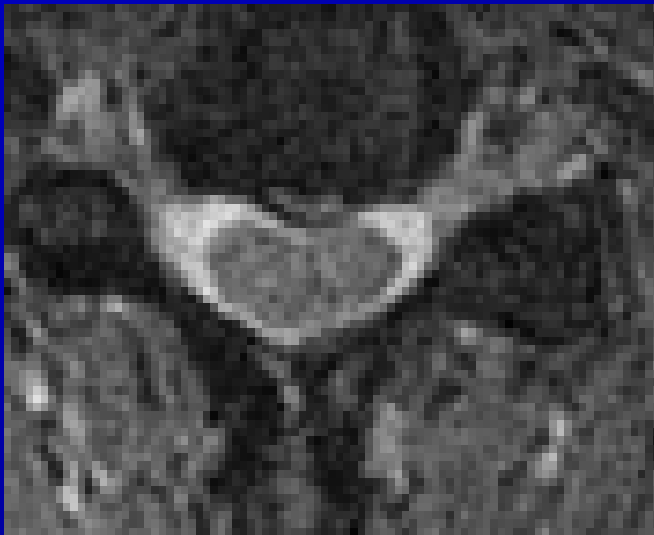
Mícha a kořeny

- mícha - rozšíření - C2-Th2 - HKK
- Th10-L1 - DKK
- konus - Th12-L2(3)
- filum terminale
- nervy - 8C, 12Th, 5L, 5S, 1Co

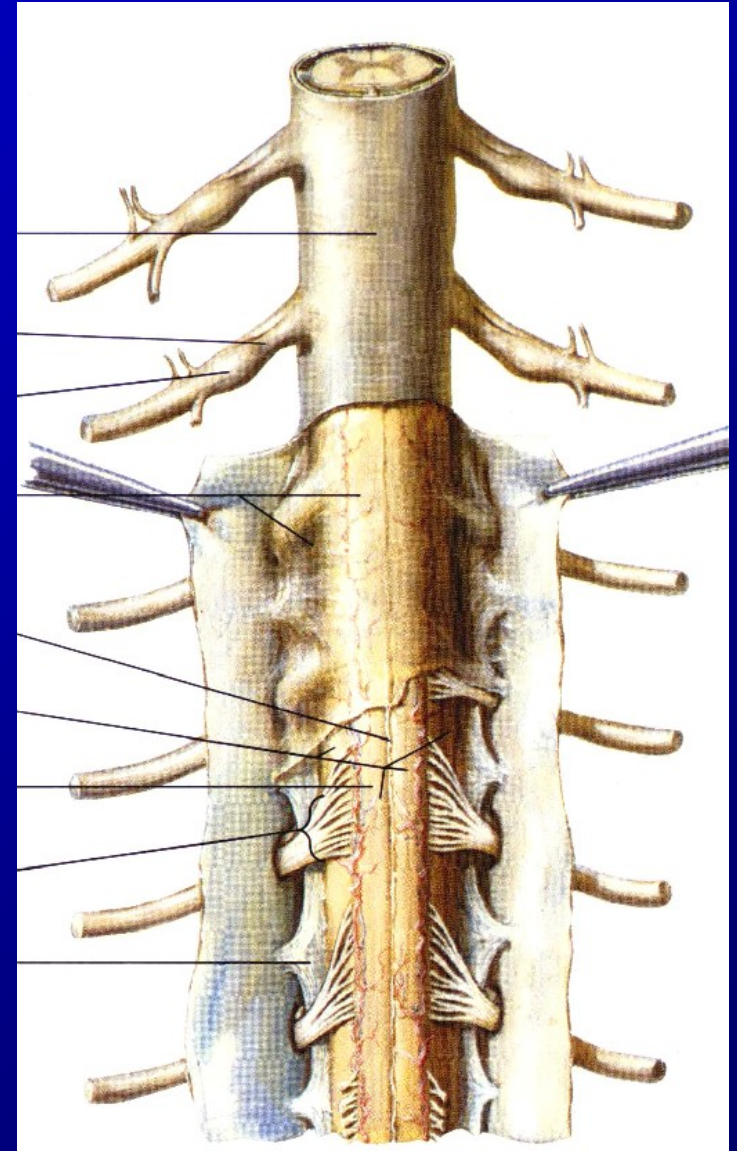


- **meningy**

- **dura mater - epidur.prostor**
- **pia mater - subarach.=mok**
- **lig.dentatum - přední a zadní subarach.pr.**
- **dorzální subarachnoideální septum**



MR – T2 obraz, axiální rovina



Anatomie - cévy míchy

**A.vertebralis - a.spinalis ant. + post.
radikulární arterie - AV**

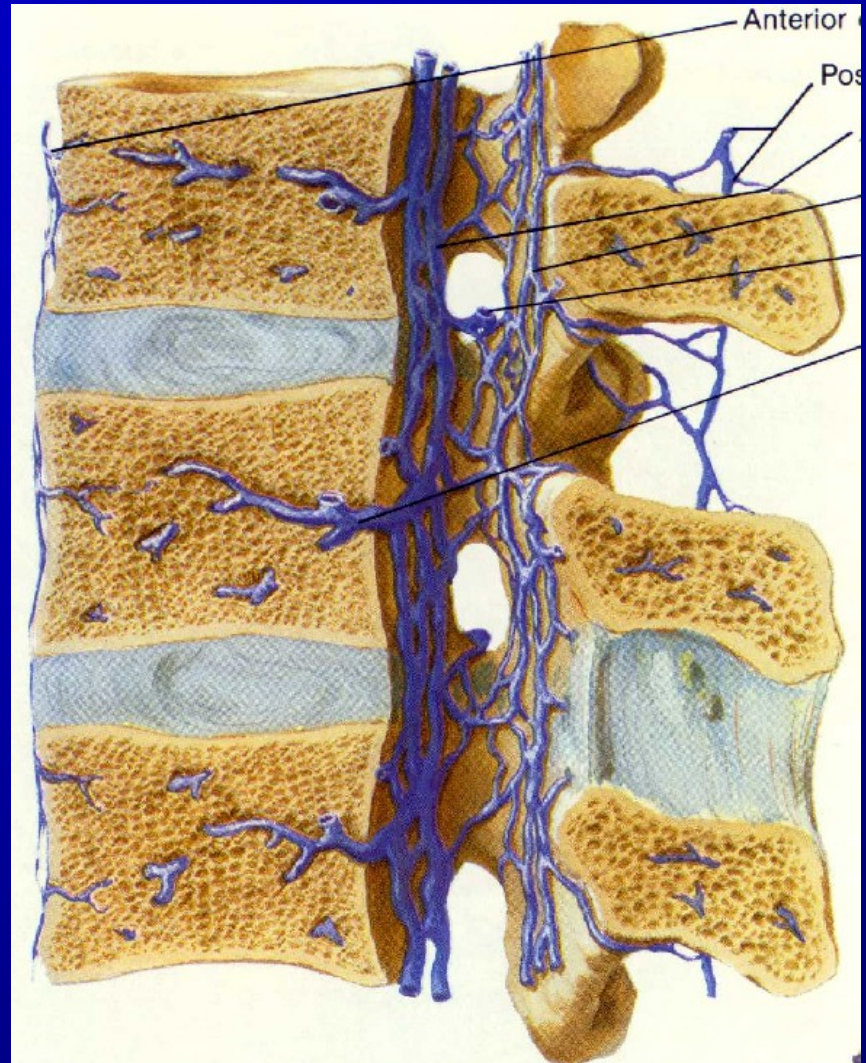
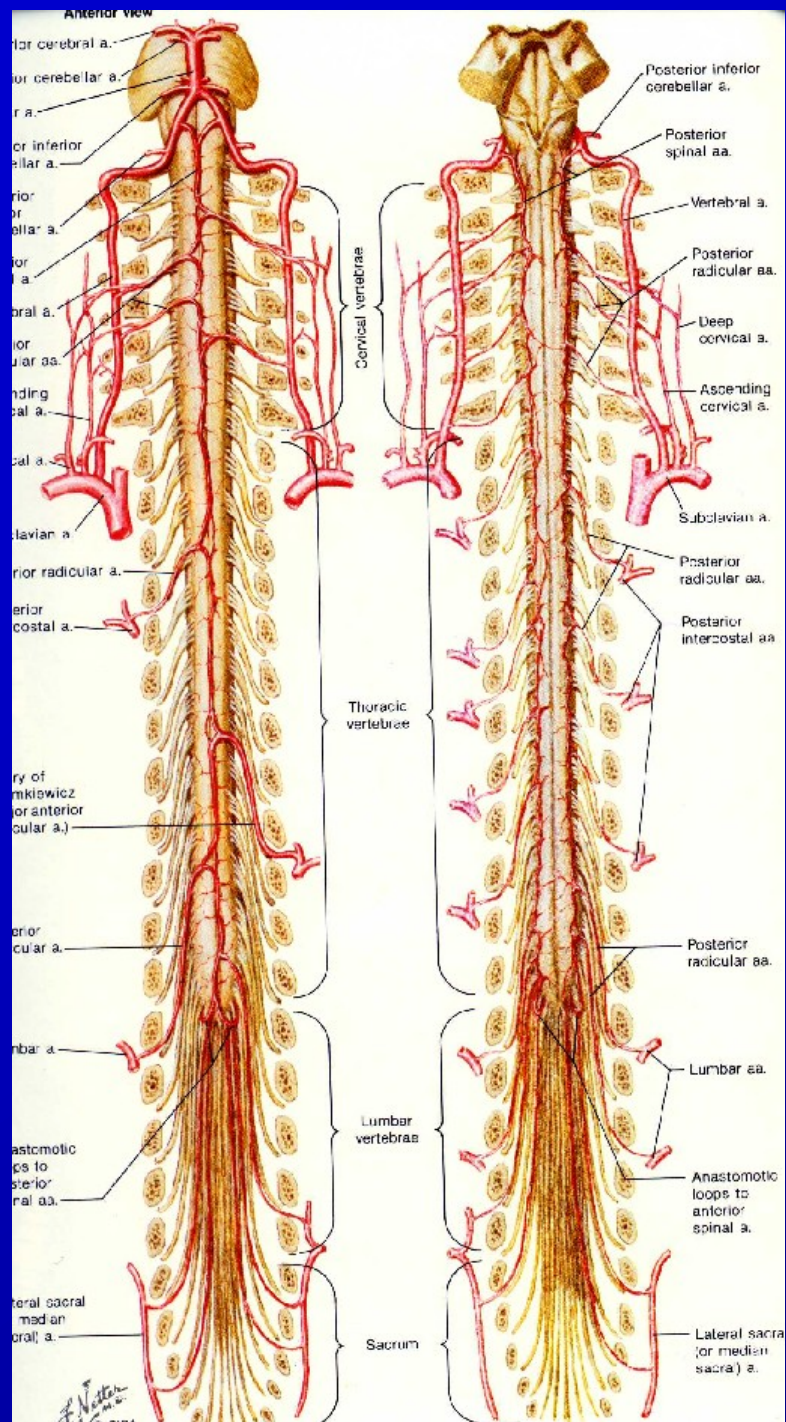
- a.subcalvia (thyr.)
- intercostální
- lumbální

Tři teritoria : 1) C-Th - do Th2

2) Střední Th - 3-7

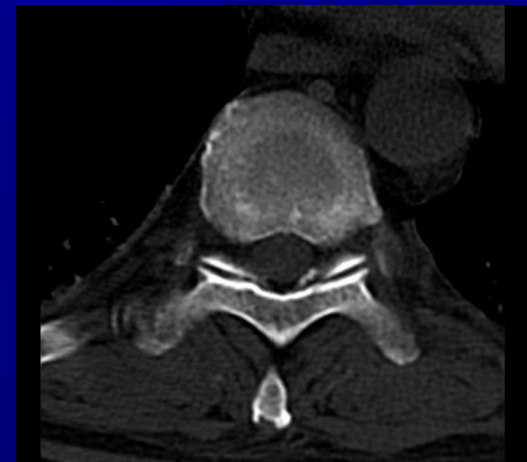
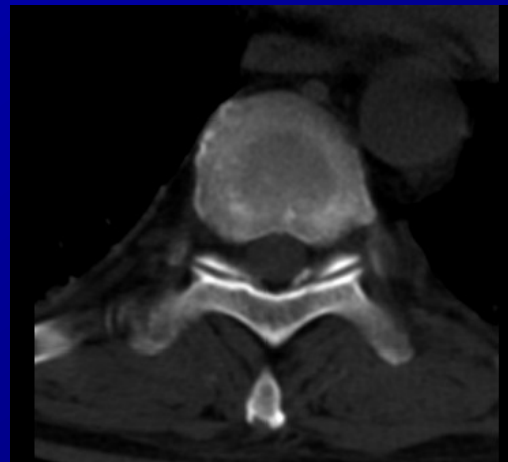
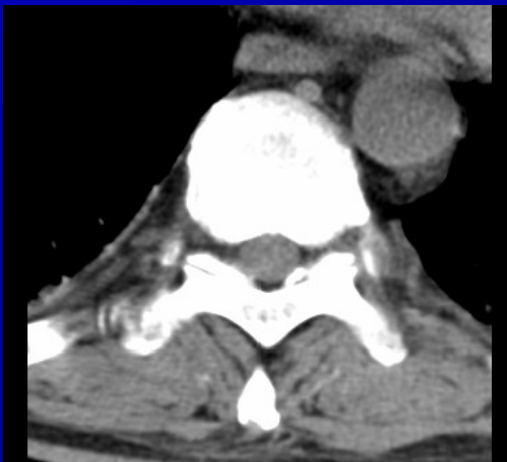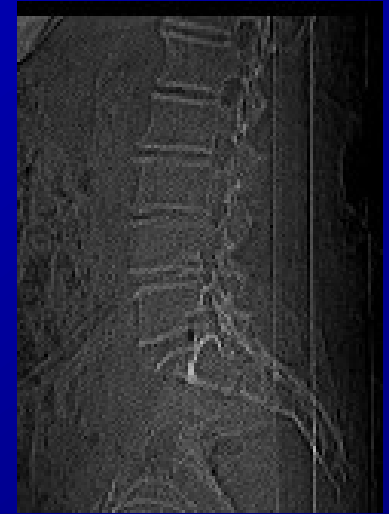
3) Th-L

a.radicularis magna (Adamkiewicz)

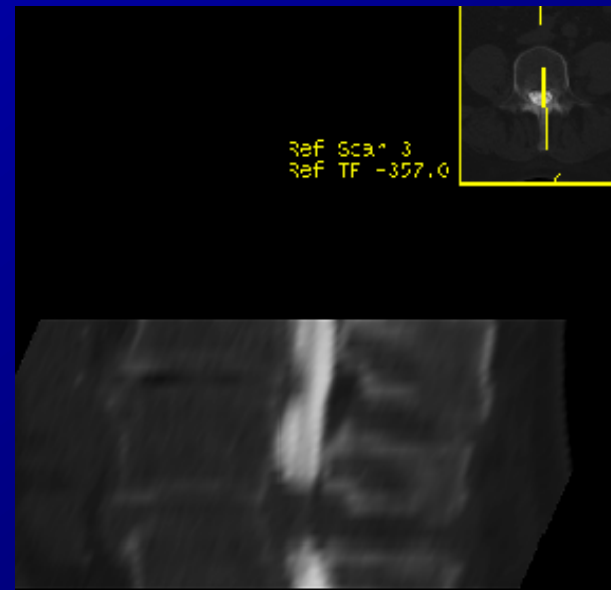
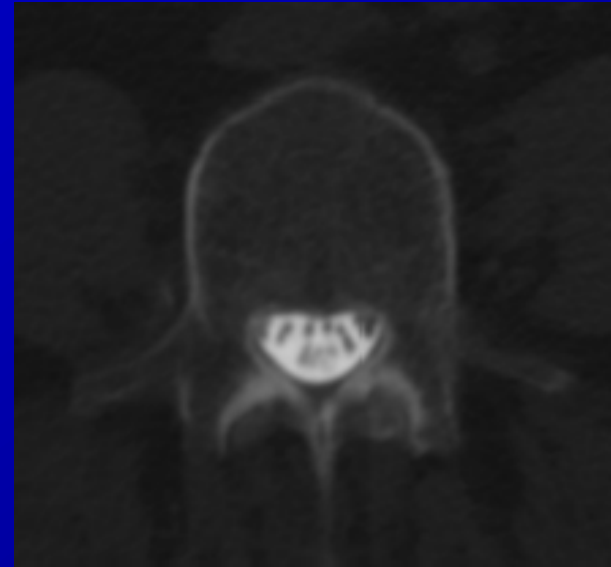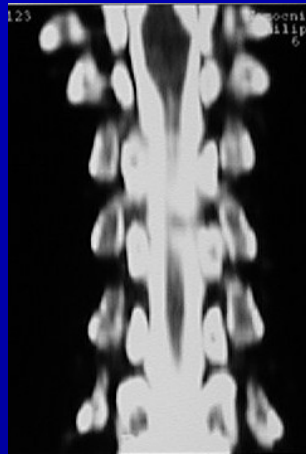
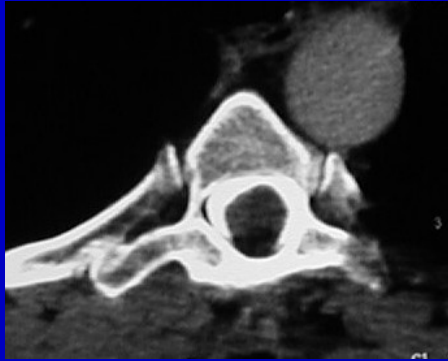


CT paterě

- **metodika vyšetření** - (*sekvenční*), **spirální**
standardní X polytrauma (*radiační zátěž !*)
kostní HR mod
- **rekonstrukce**
- **dokumentace - hodnocení**
měkkotkáňové i kostní okno !



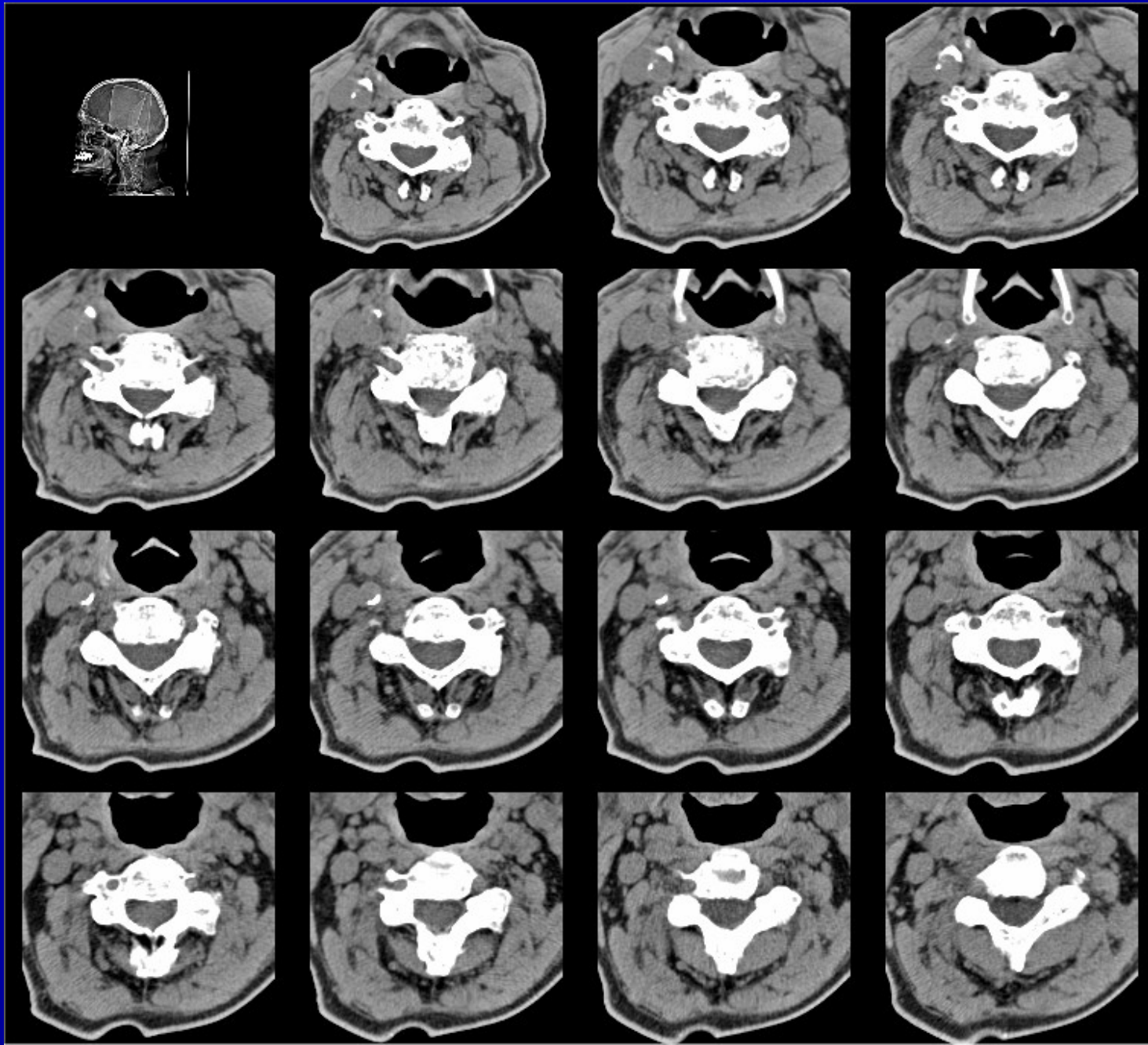
CT myelografie



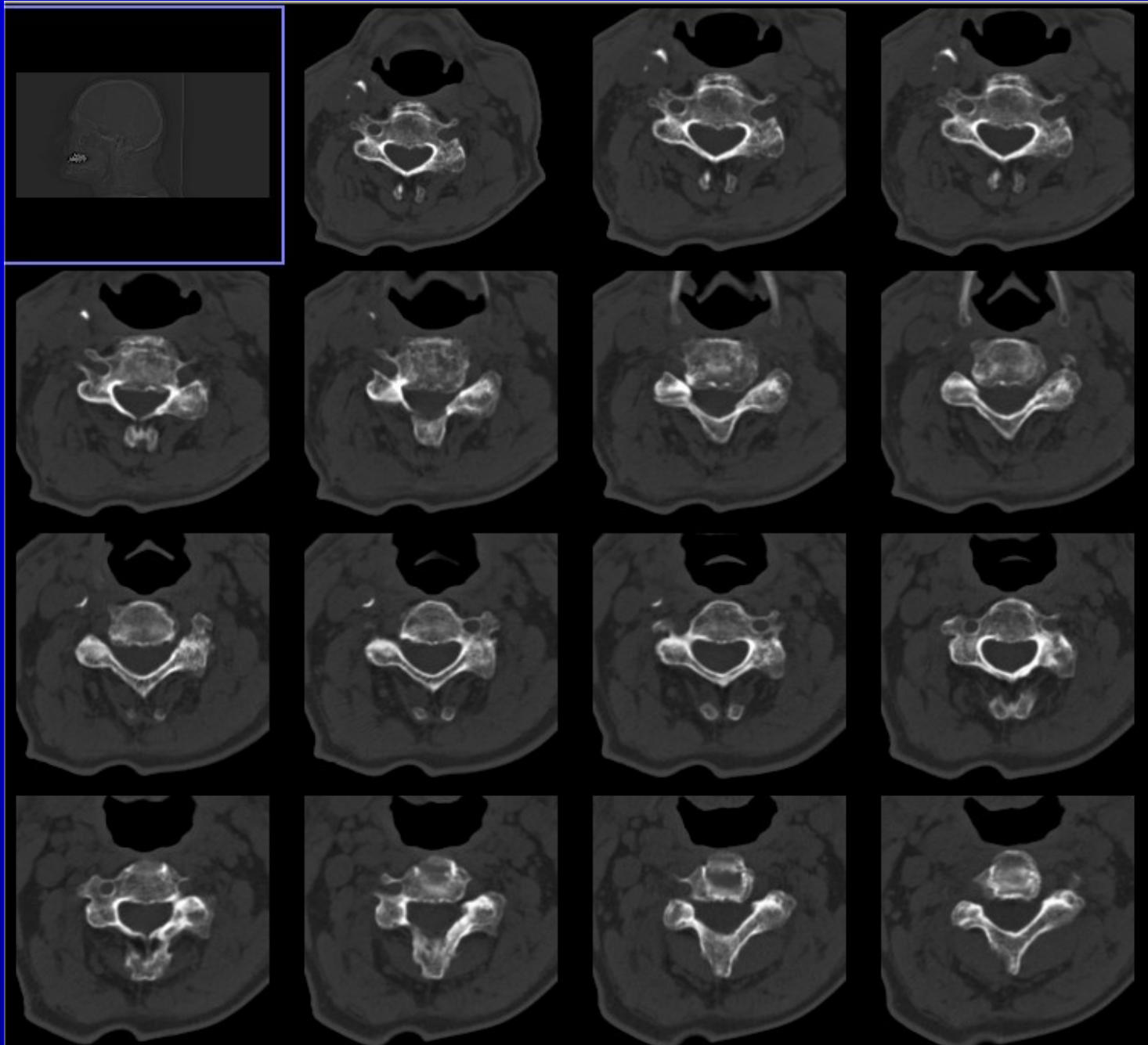
Intramedulární expanse – patol. rozšíření Th míchy.
Mícha působí „defekt“ náplně kontrastní látky v
likvorových prostorách

Útlak durálního
vaku herní
ploténky L páteře

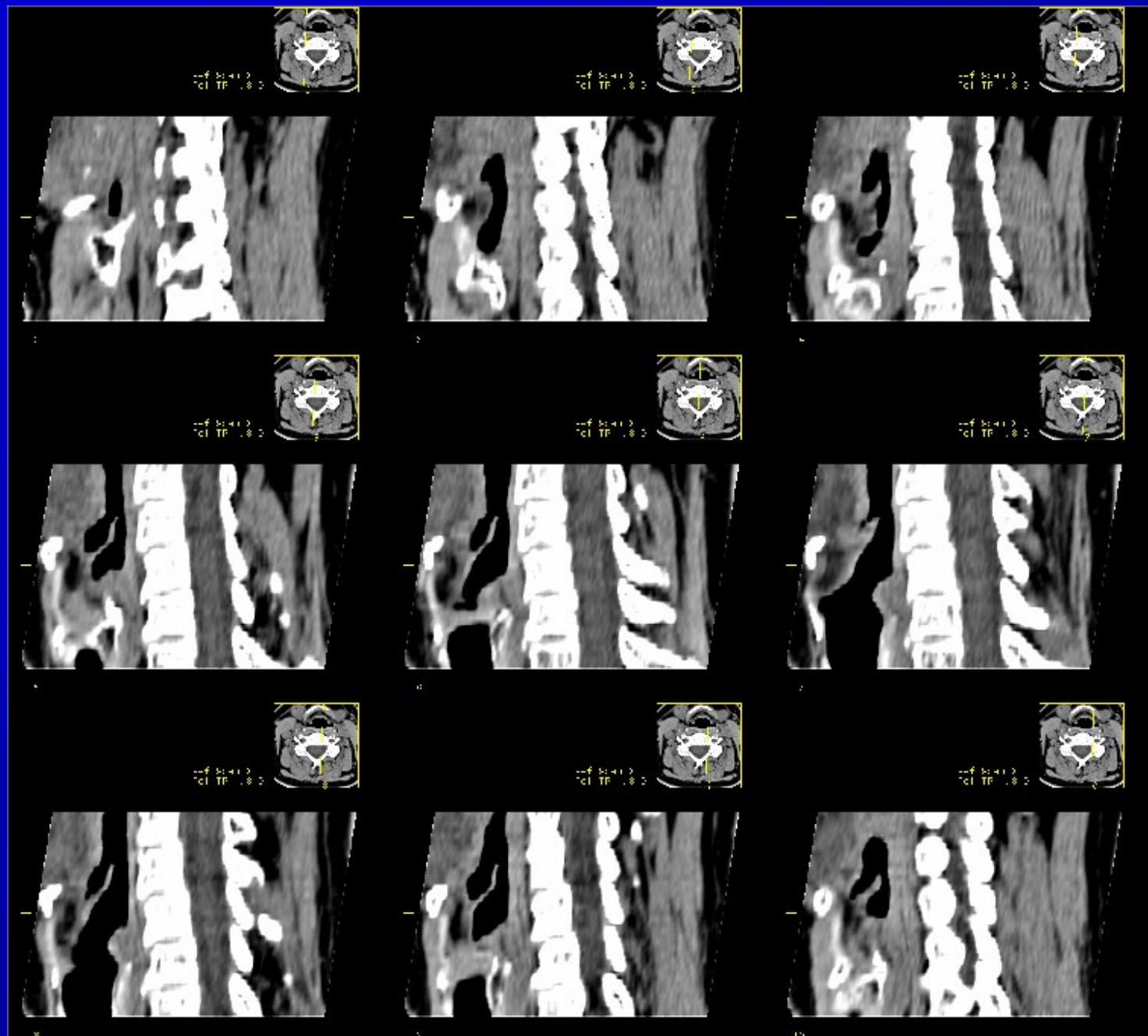
CT krční páteře, měkkotkáňové okno



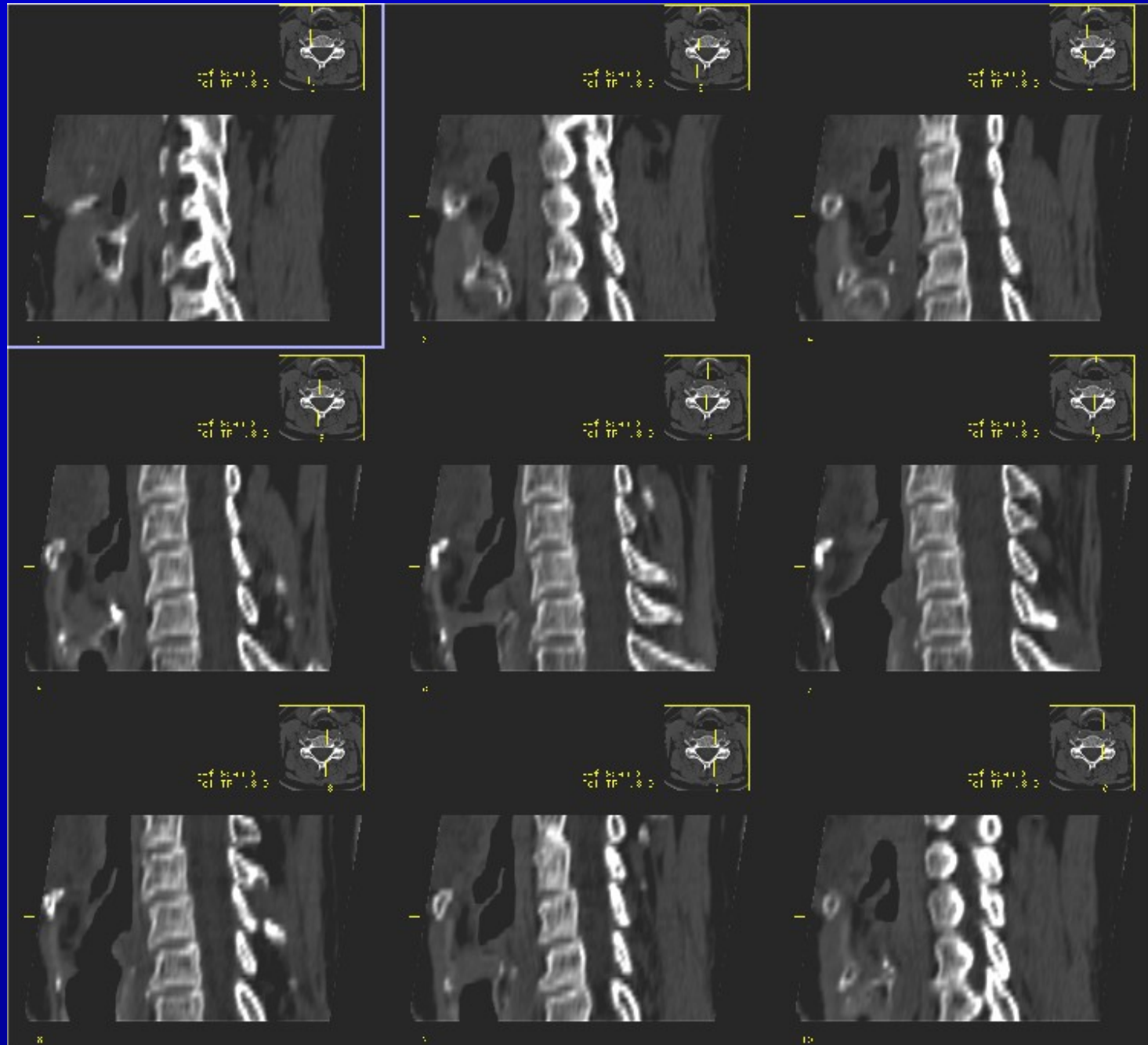
CT krční páteře, kostní okno



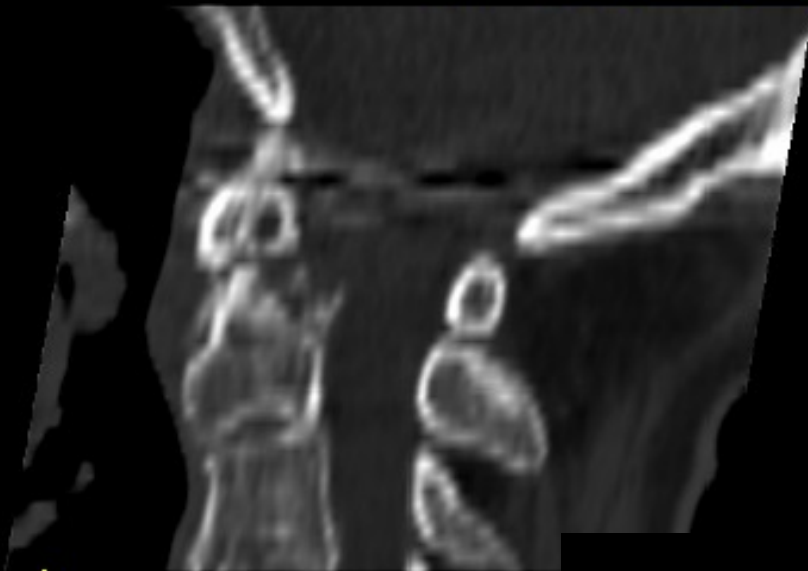
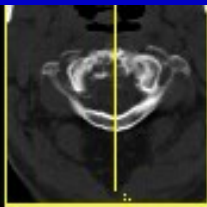
CT krční páteře – sagitální rekonstrukce, měkkotkáňové okno



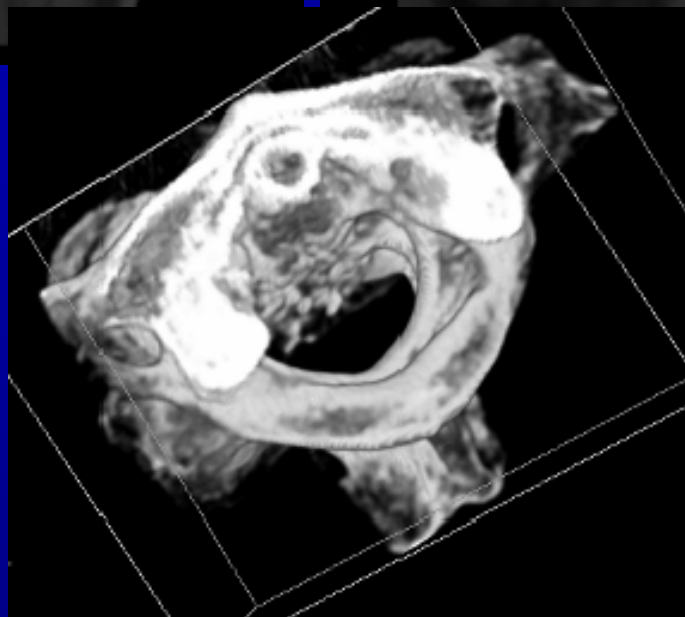
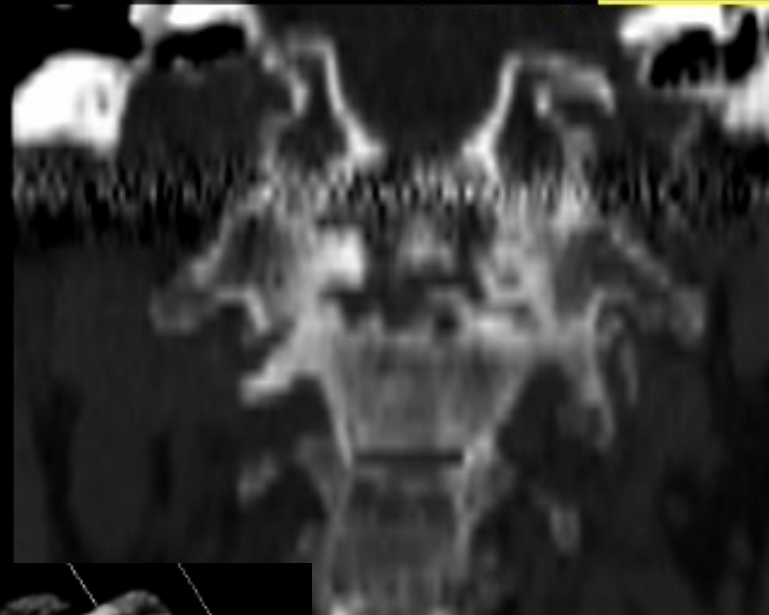
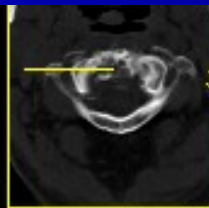
CT krční páteře – sagitální rekonstrukce, kostní okno



Ref Scan 22
Ref TF -025.0

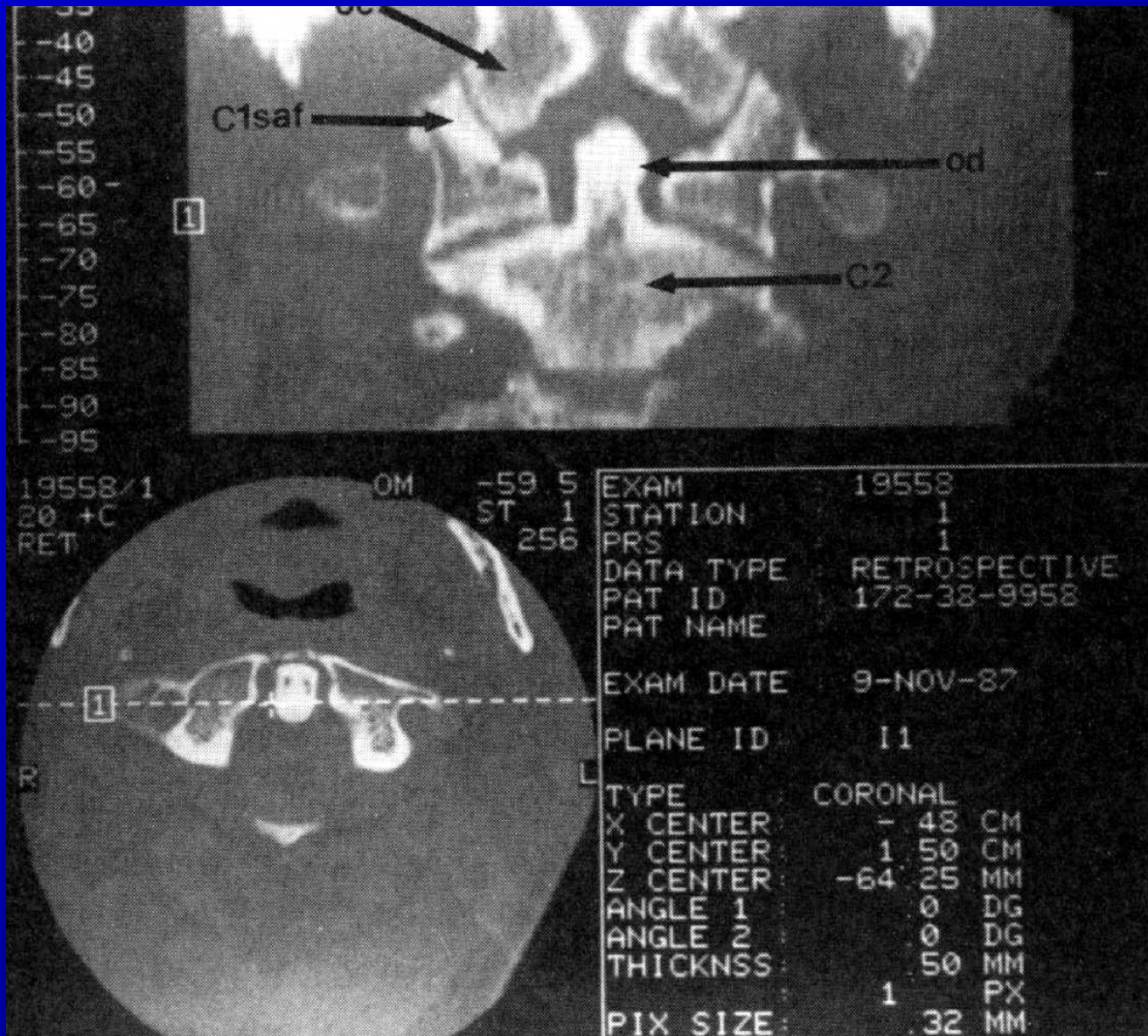

Ref Scan 22
Ref TF -025.0

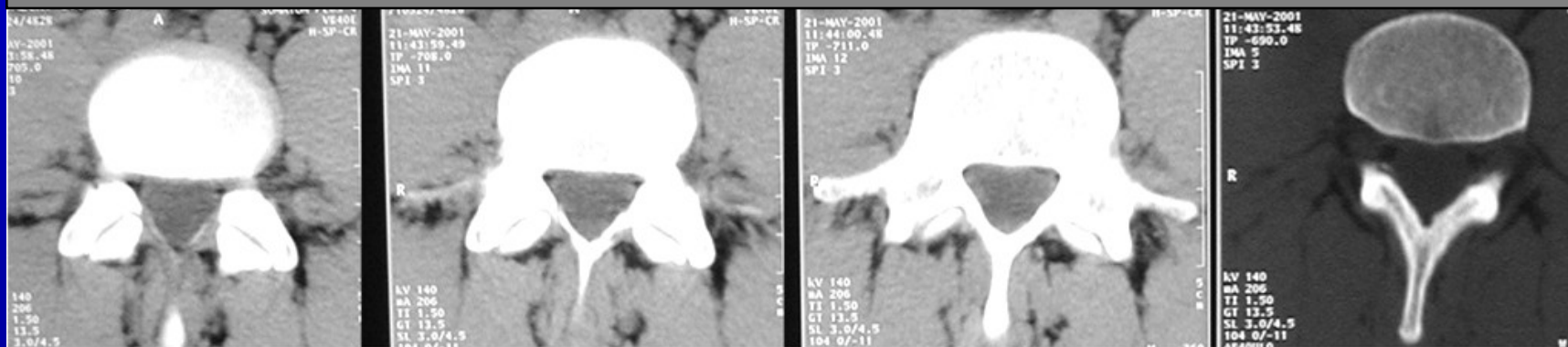
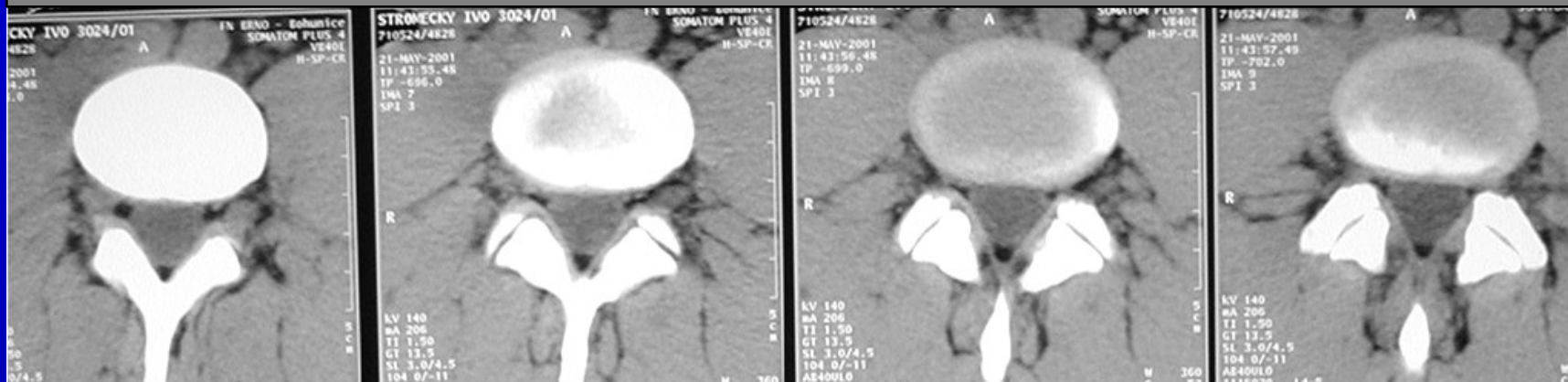
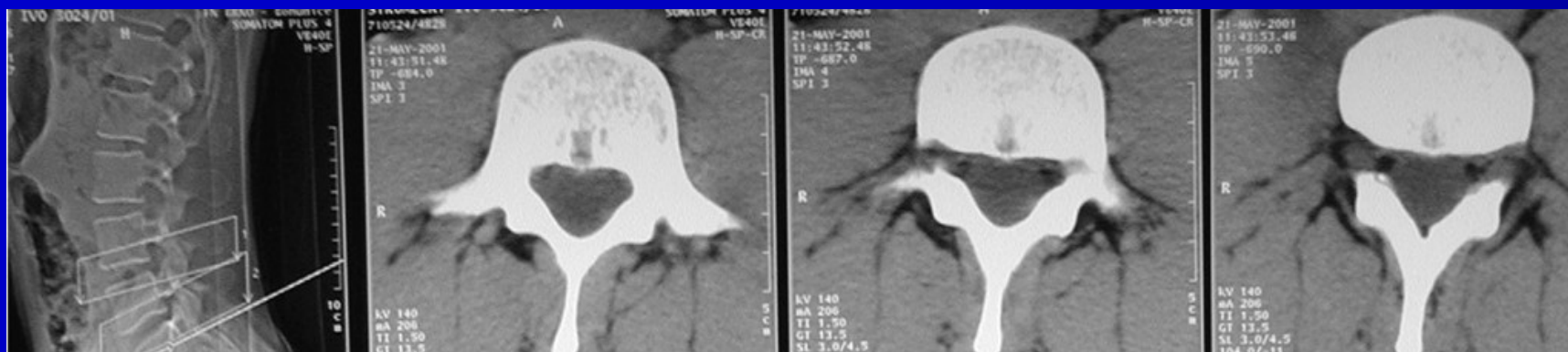


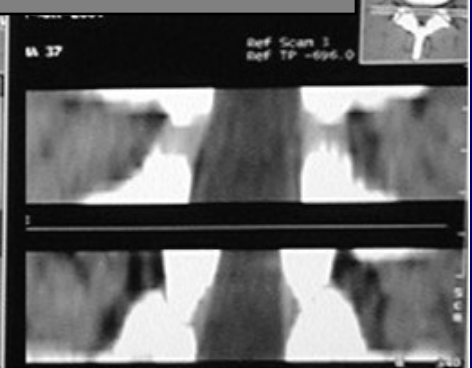
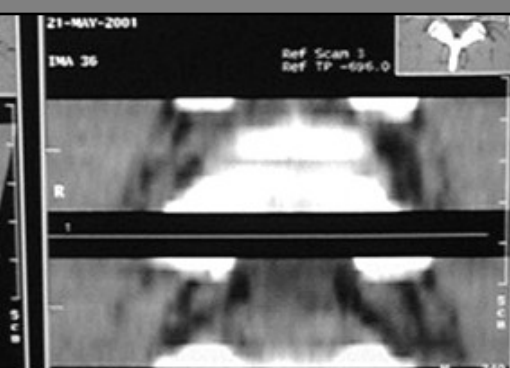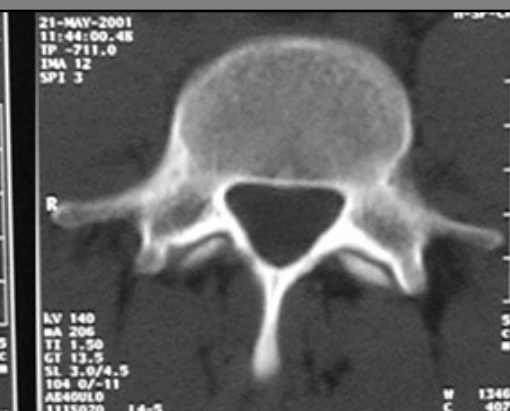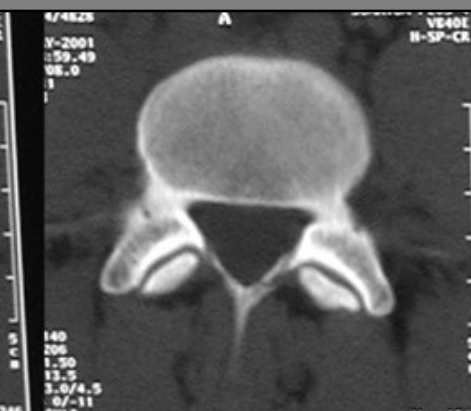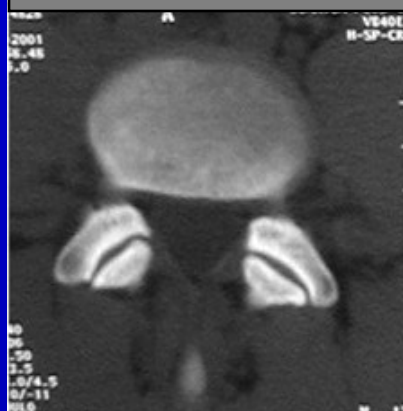
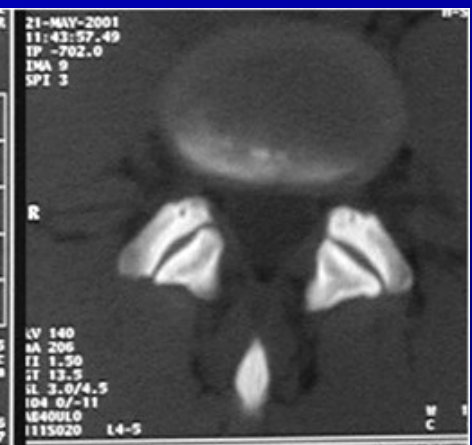
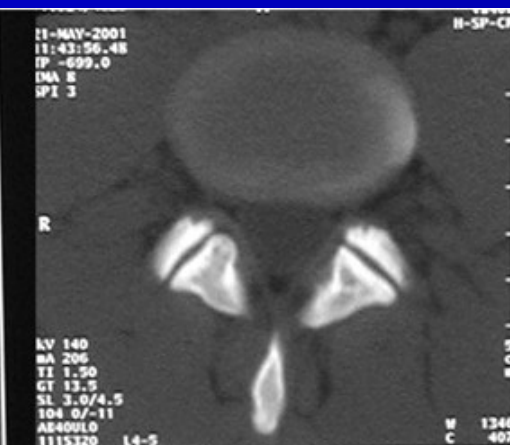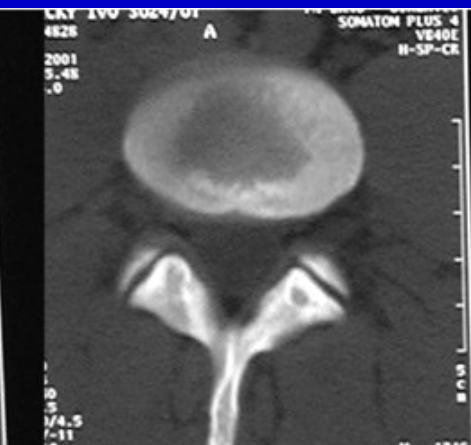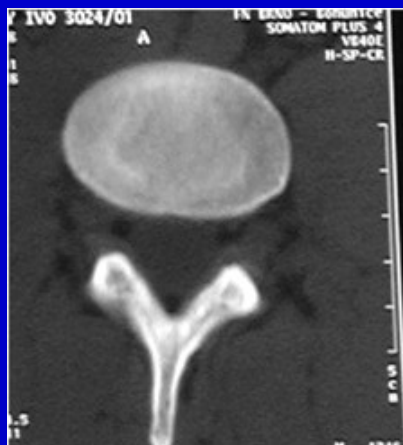Osteolýza dens axis:
CT 2D a 3D rekonstrukce

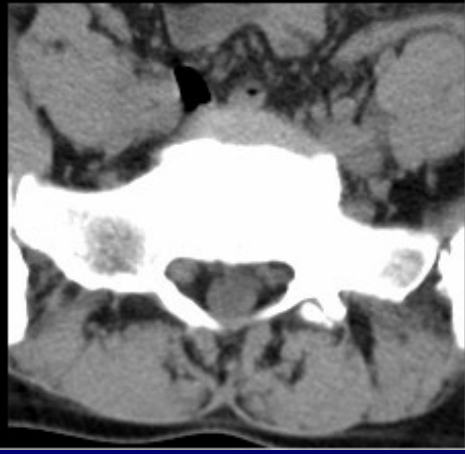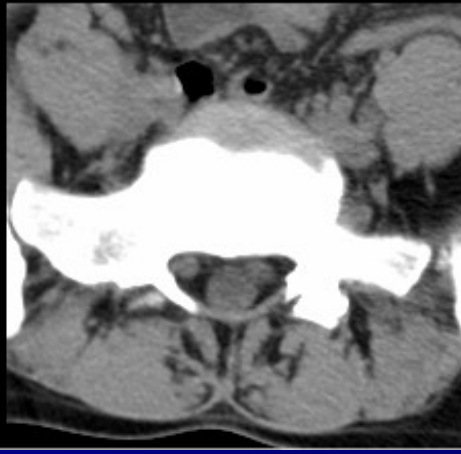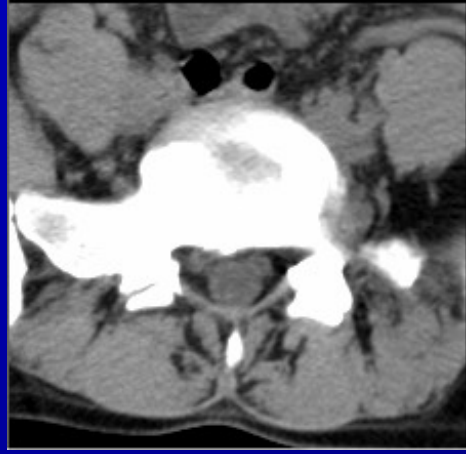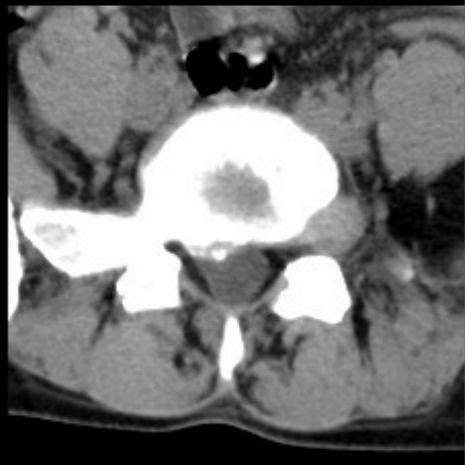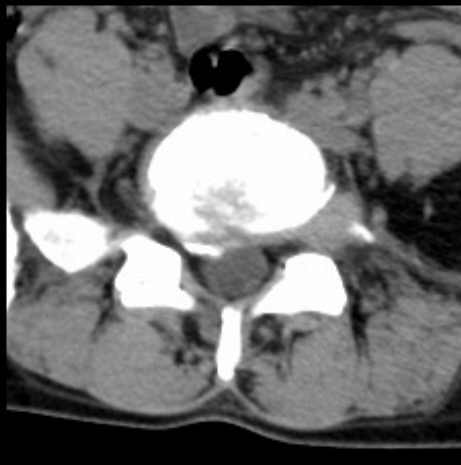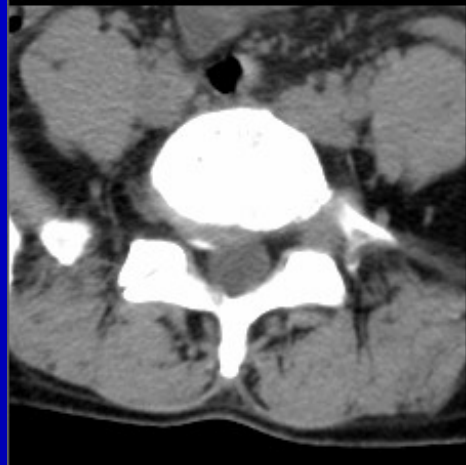
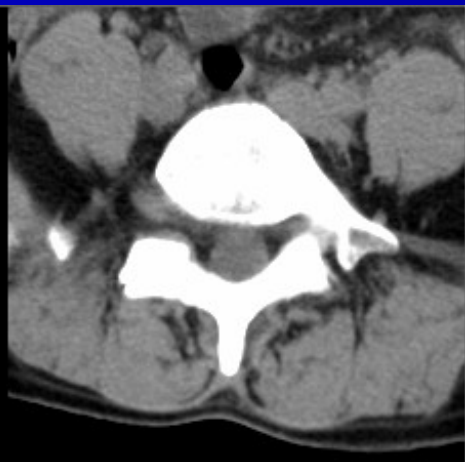
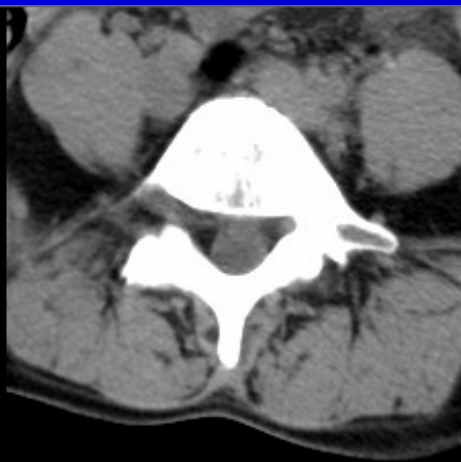
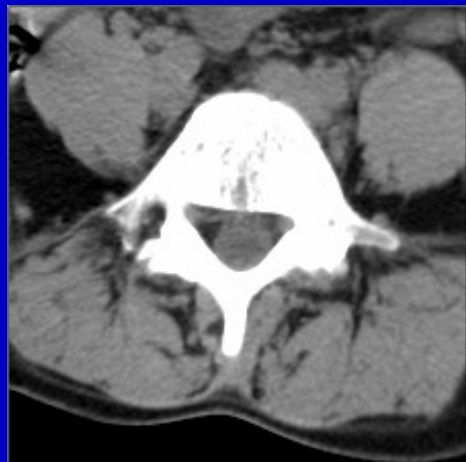
CT rekonstrukce: atlanto-okcipitální přechod – koronární rovina!



CT bederní páteře

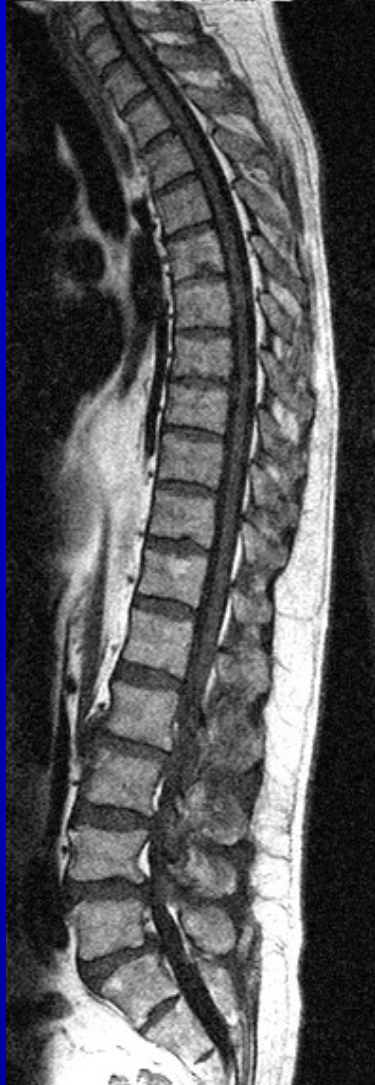




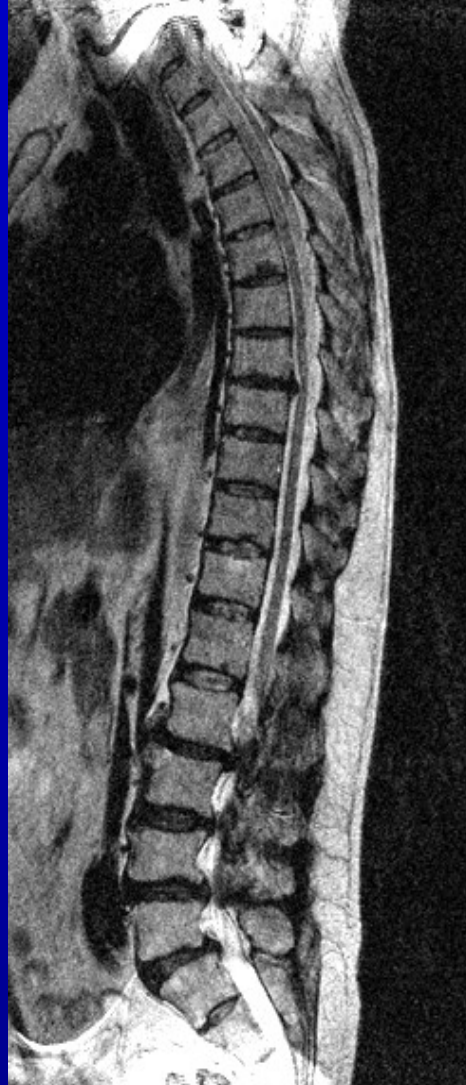
Technika MR vyšetření páteře

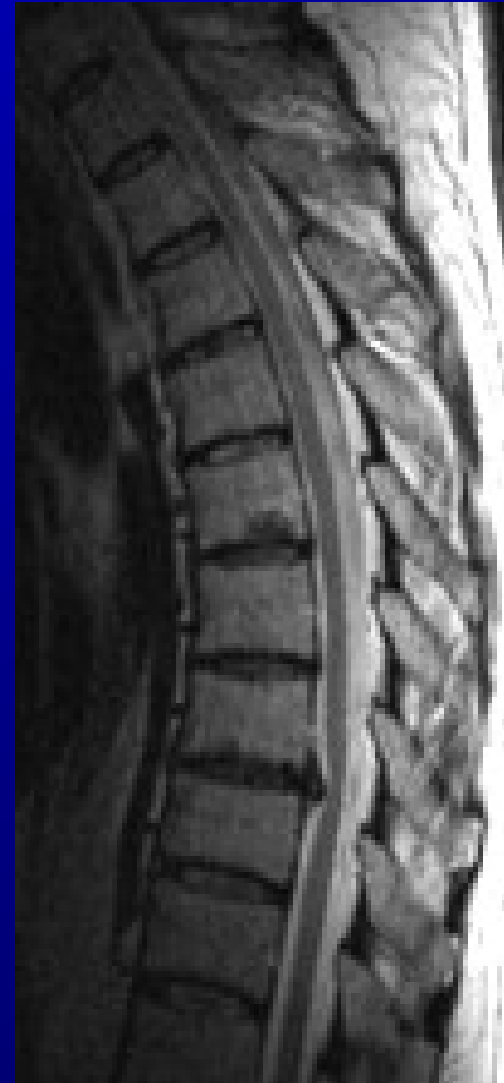Volba cívkky - celotělová X povrchová



T1

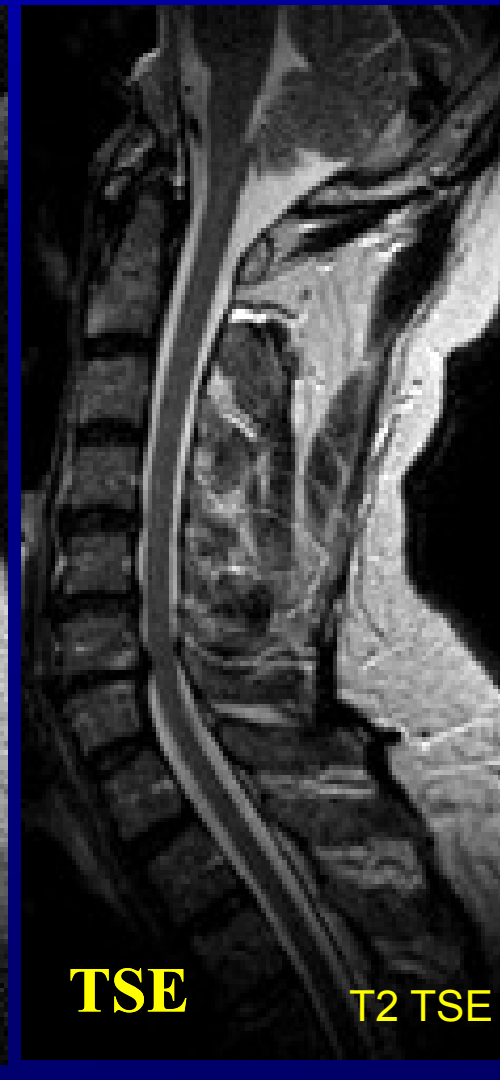
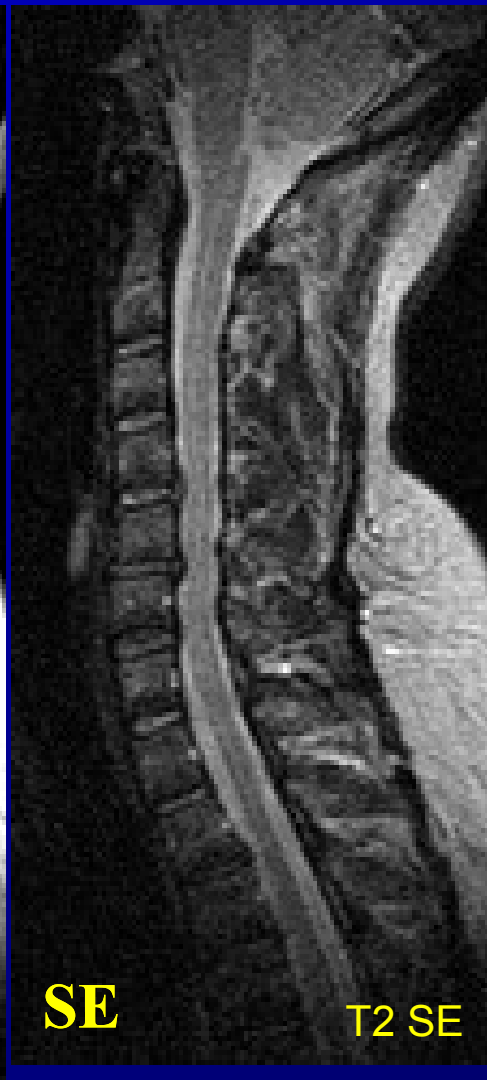
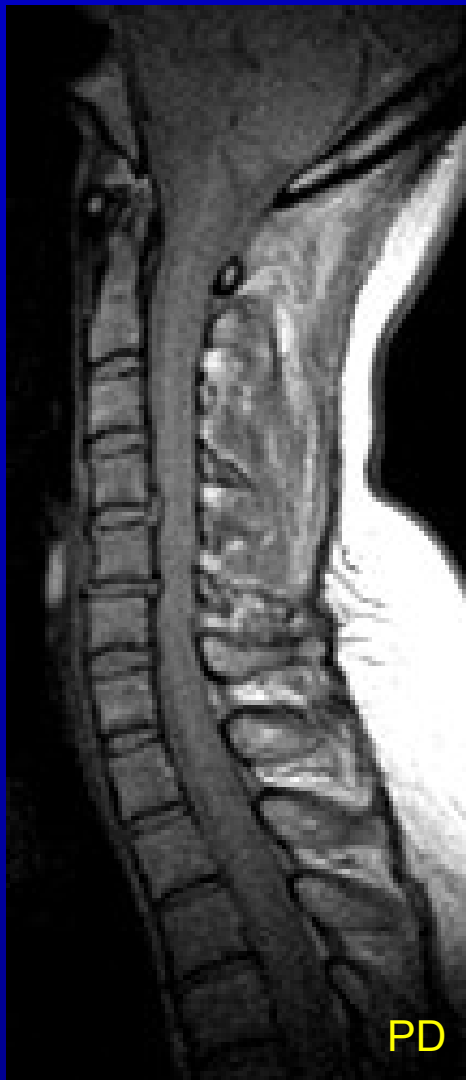
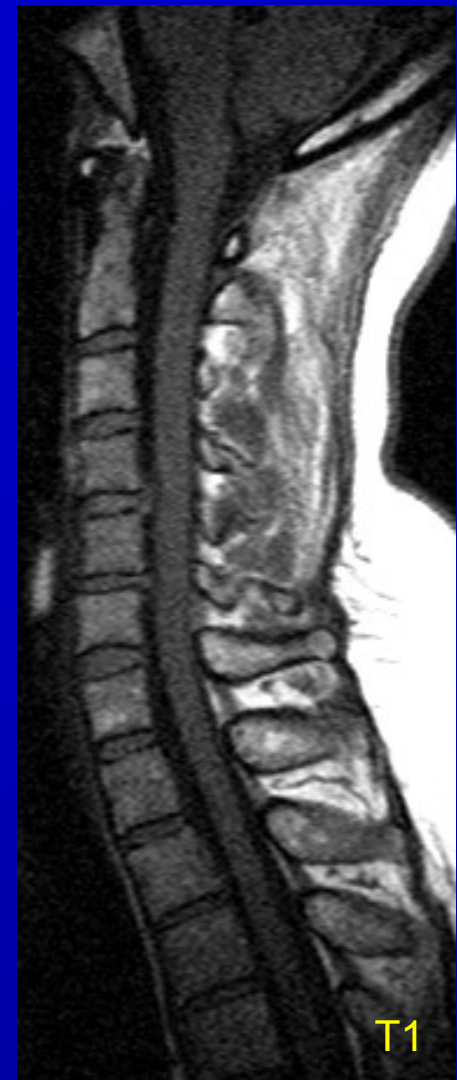T2



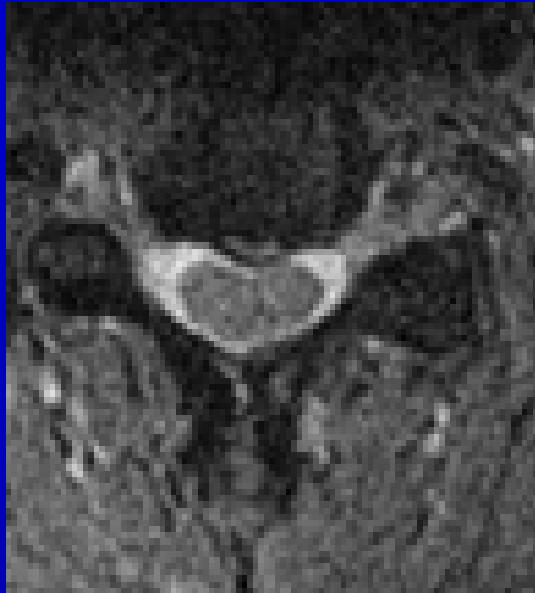
Technika MR vyšetření páteře

Volba sekvence - Sagitální rovina T1, PD a T2 vážení

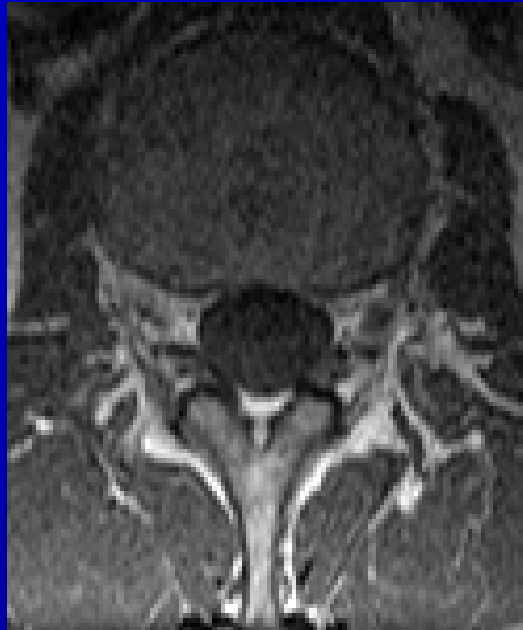

Technika MR vyšetření páteře

Transverzální rovina T1 a T2 vážení

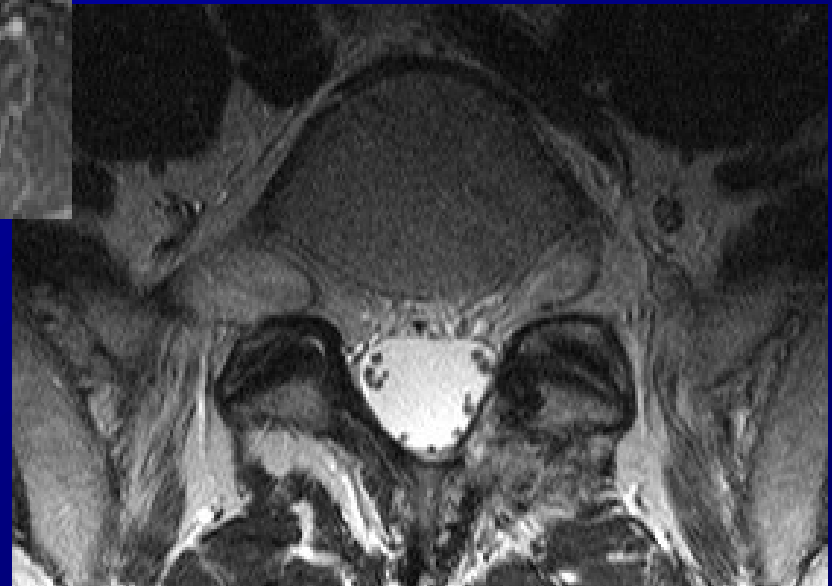


T2, axiální rovina, C páteř



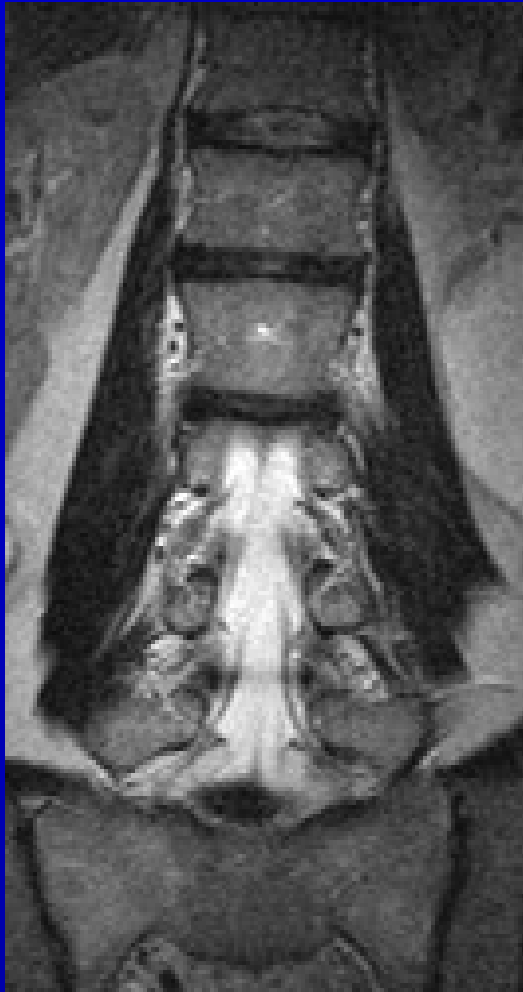
T1, axiální rovina, L páteř

T2, axiální rovina, L páteř

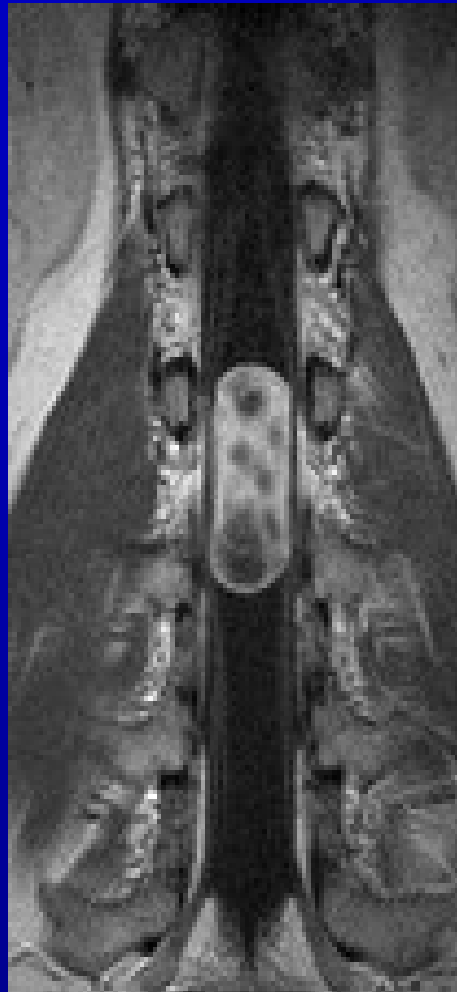


Technika MR vyšetření páteře

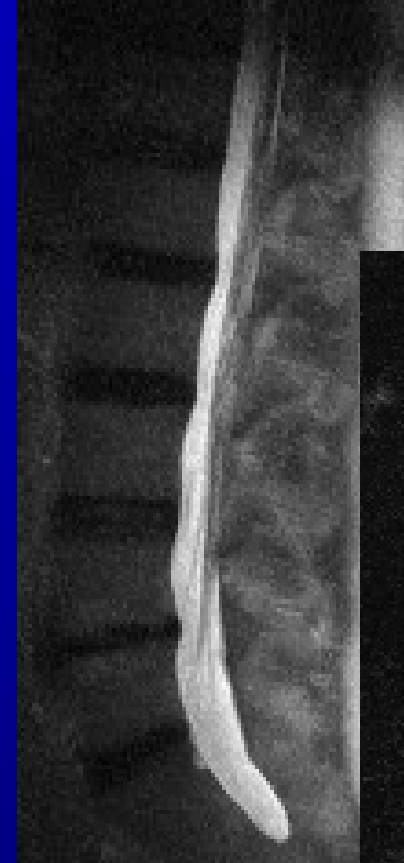
Koronární rovina, myelografie



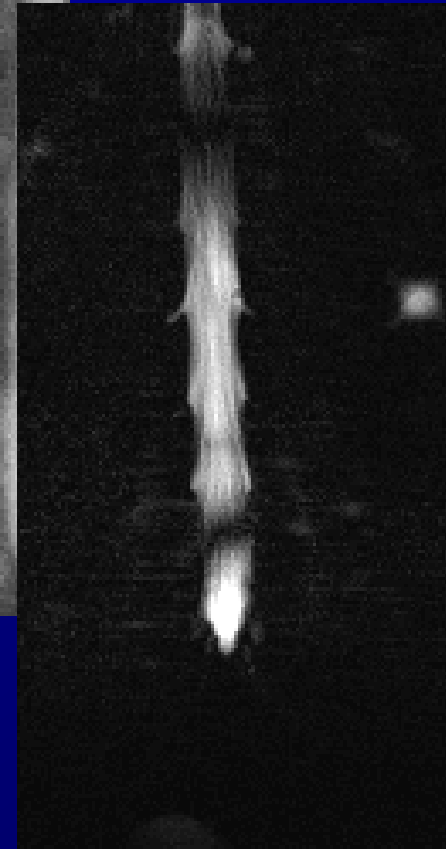
T2 koronárně, L páteř



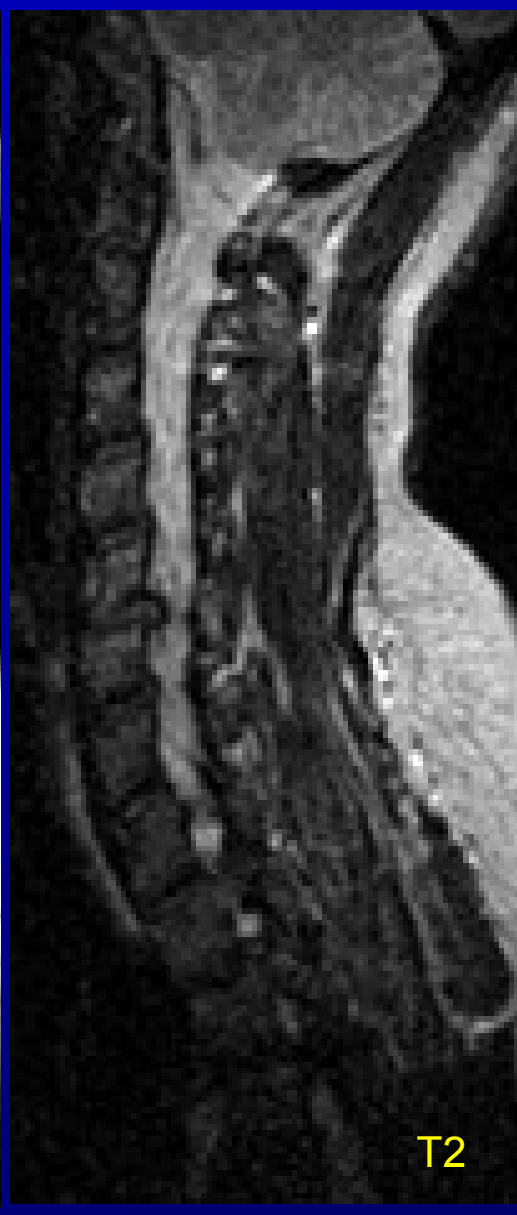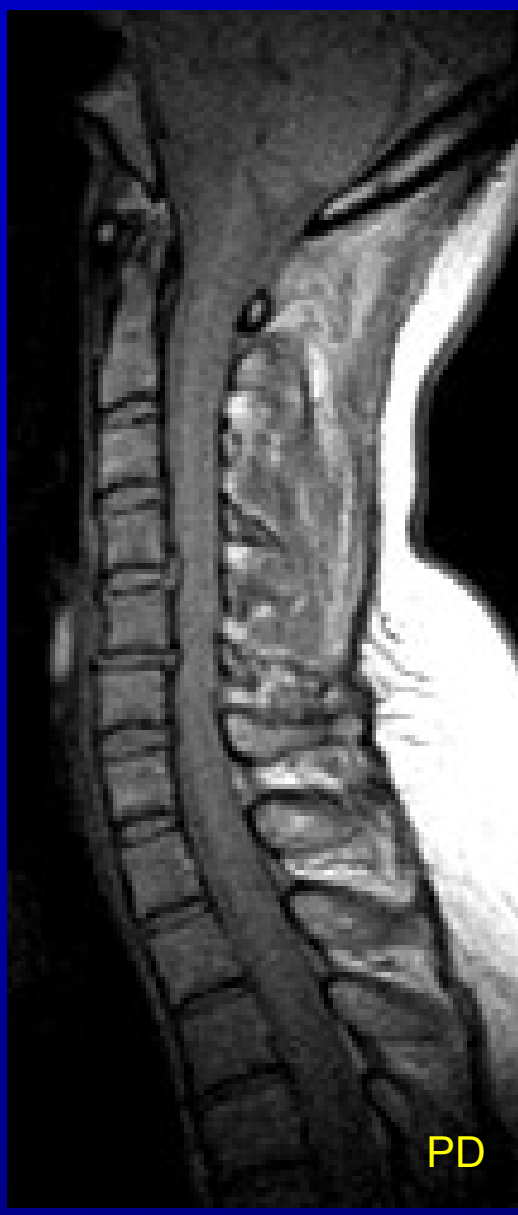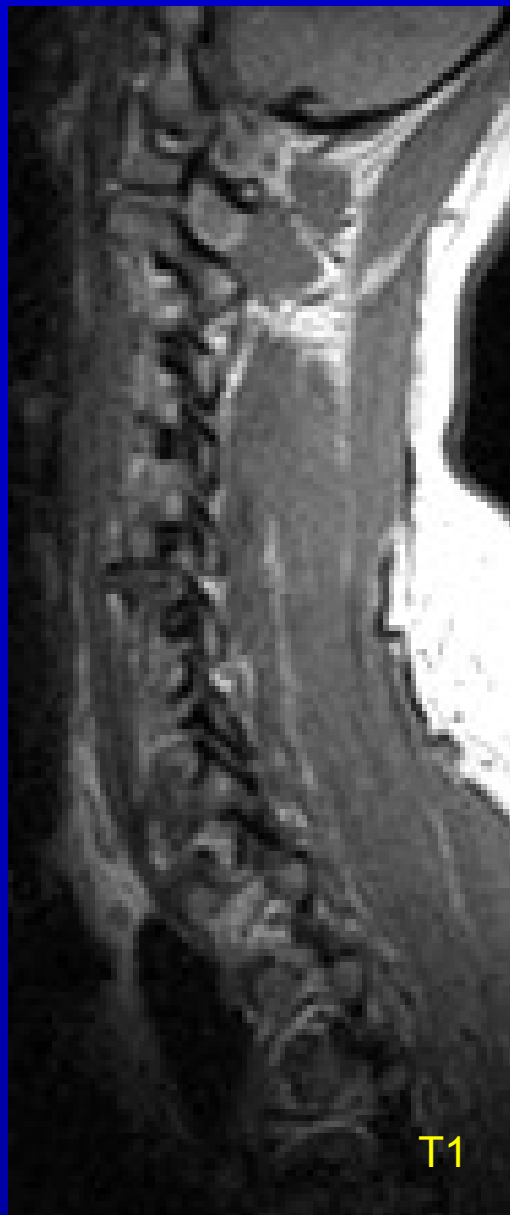T1 Gd koronárně, L páteř:
Intradurální tumor



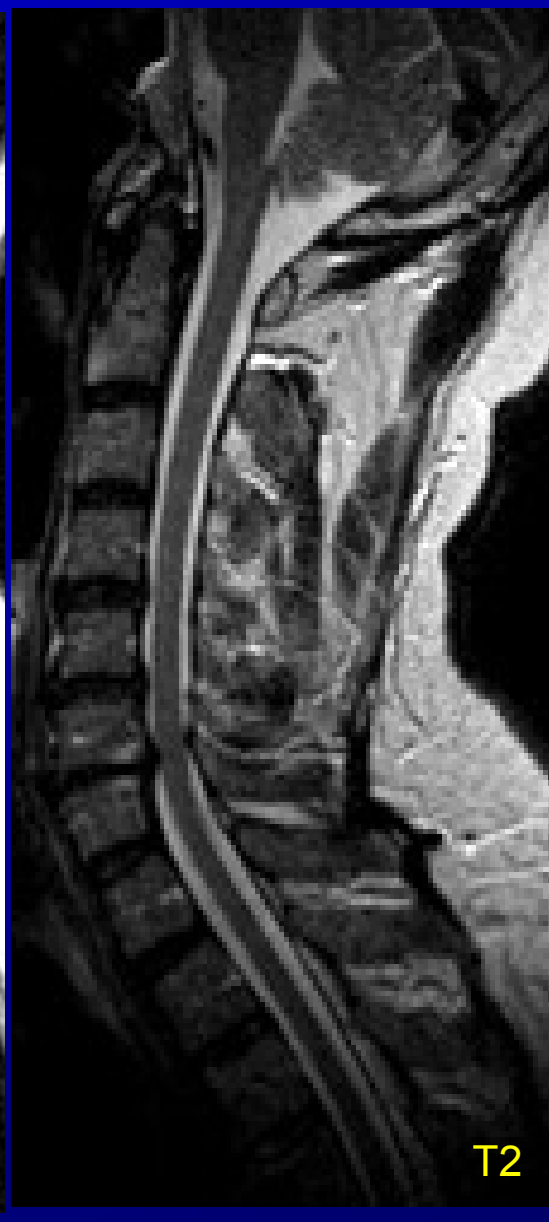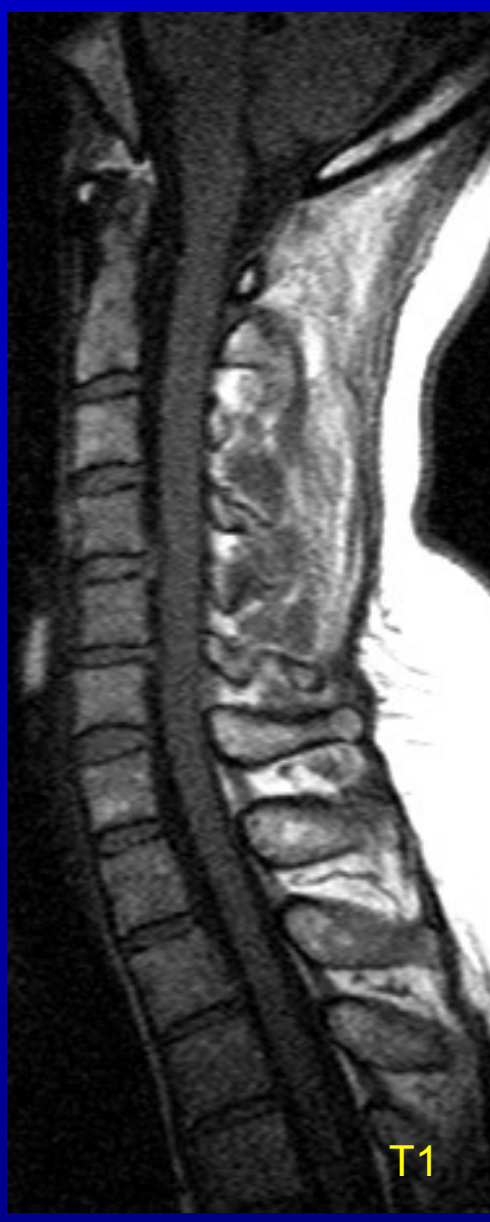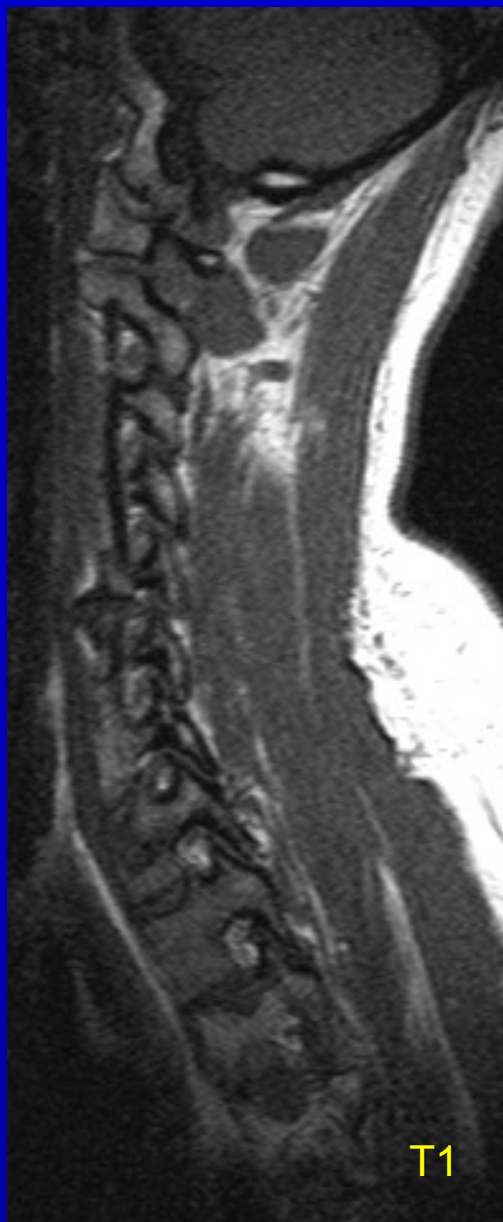
MR myelografie



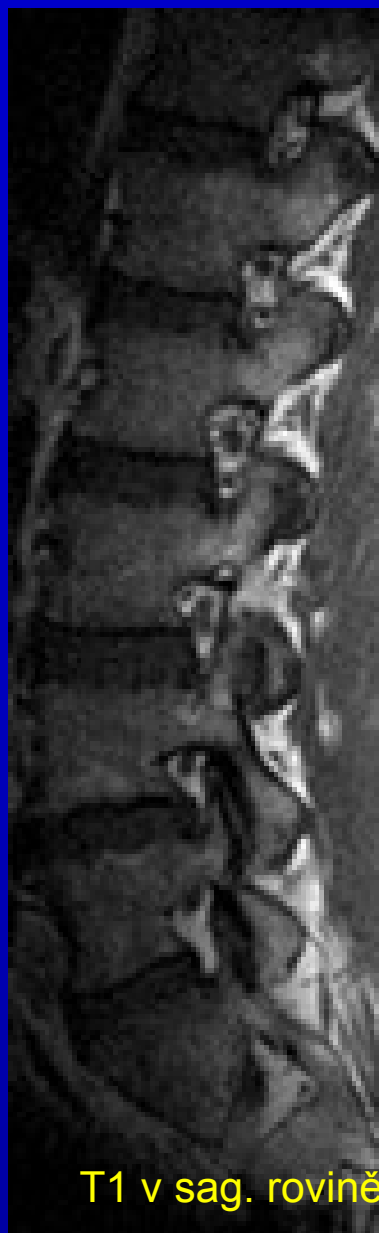Hodnocení MR vyšetření - C



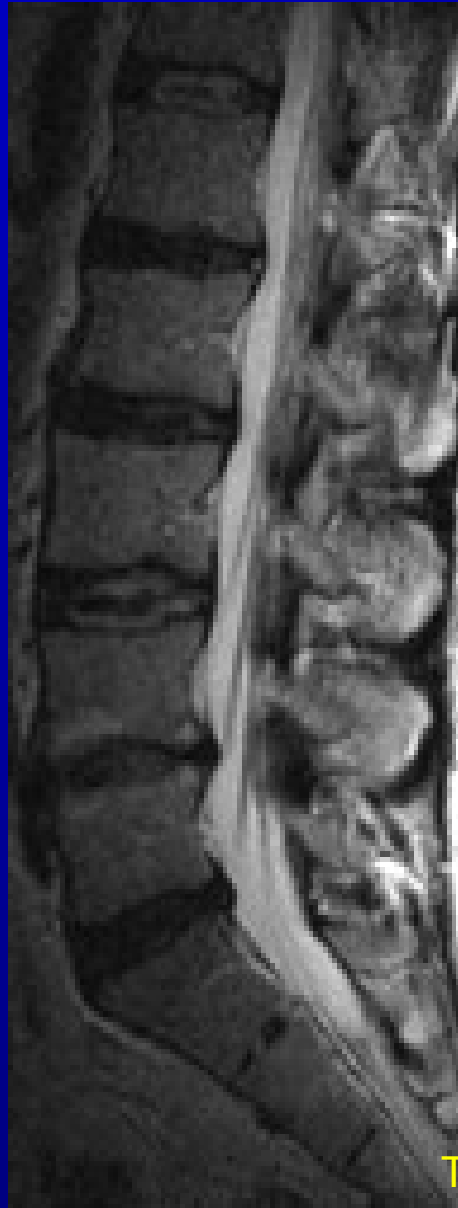
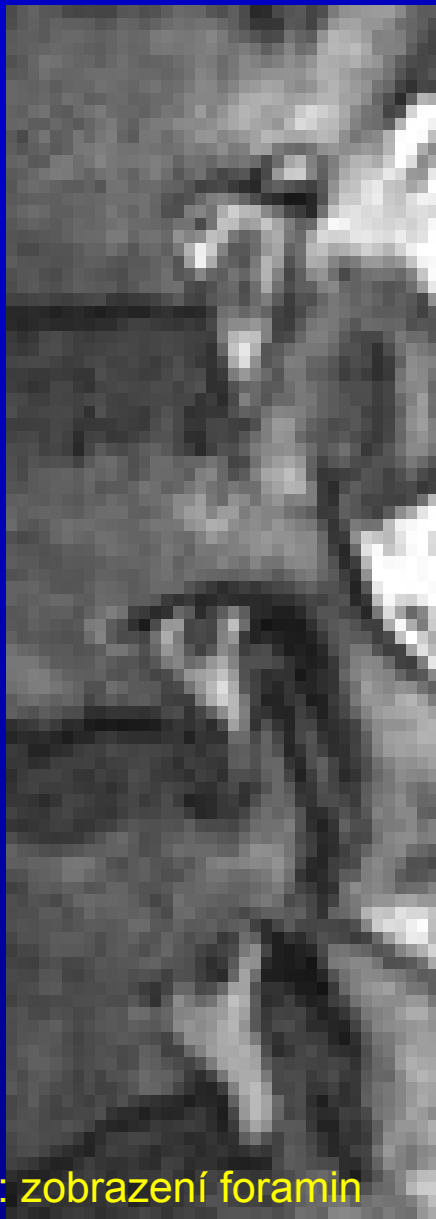
Hodnocení MR vyšetření - C



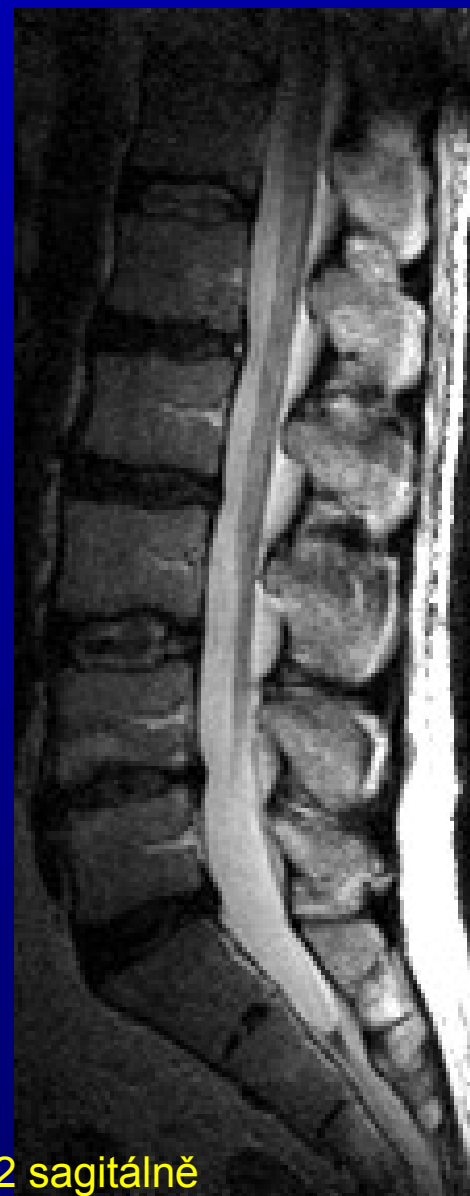Hodnocení MR vyšetření - Th,L



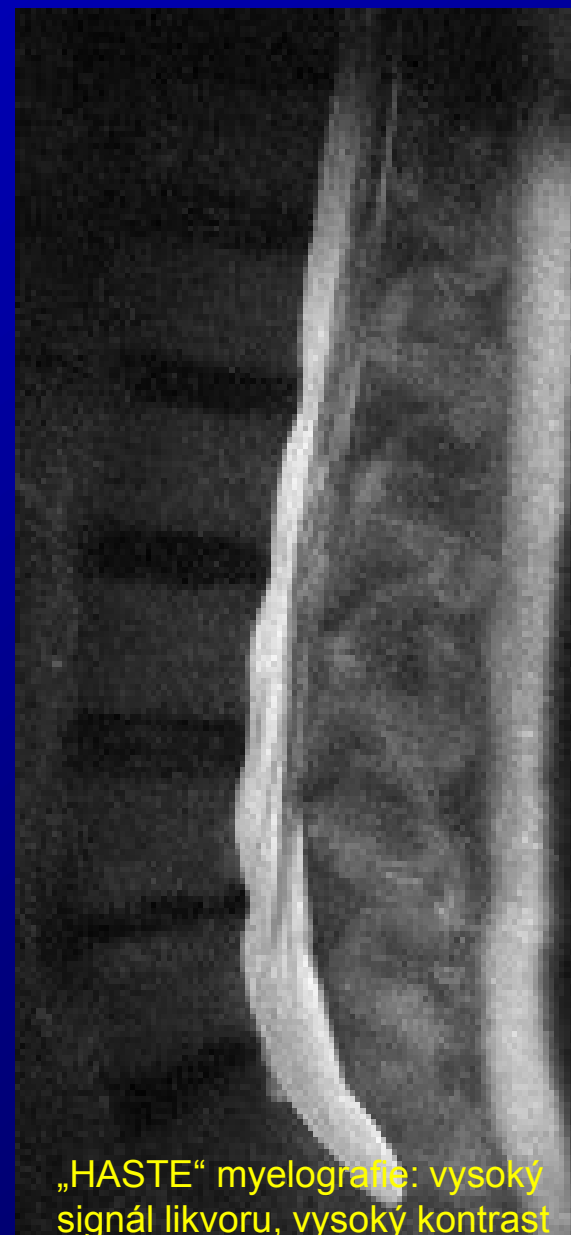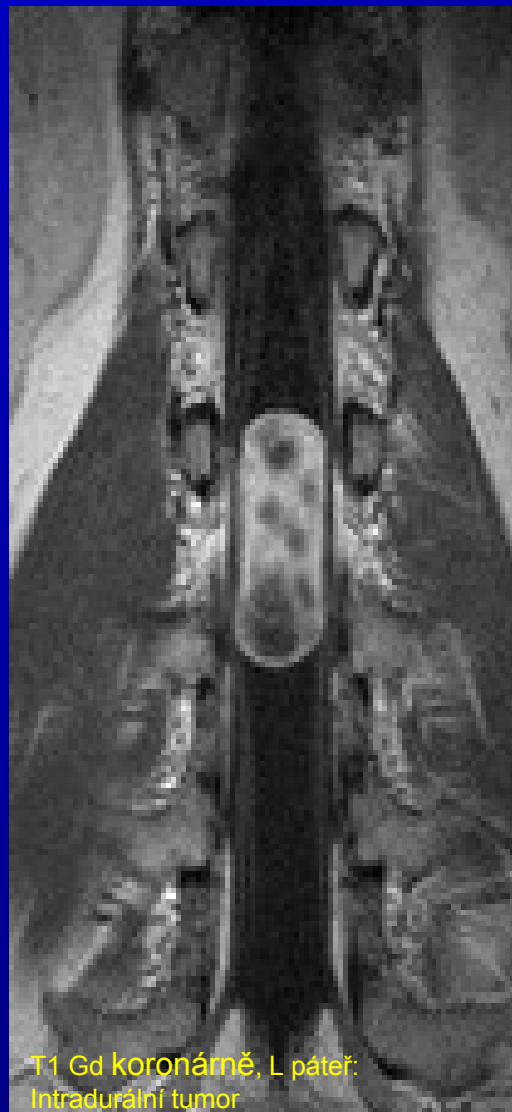
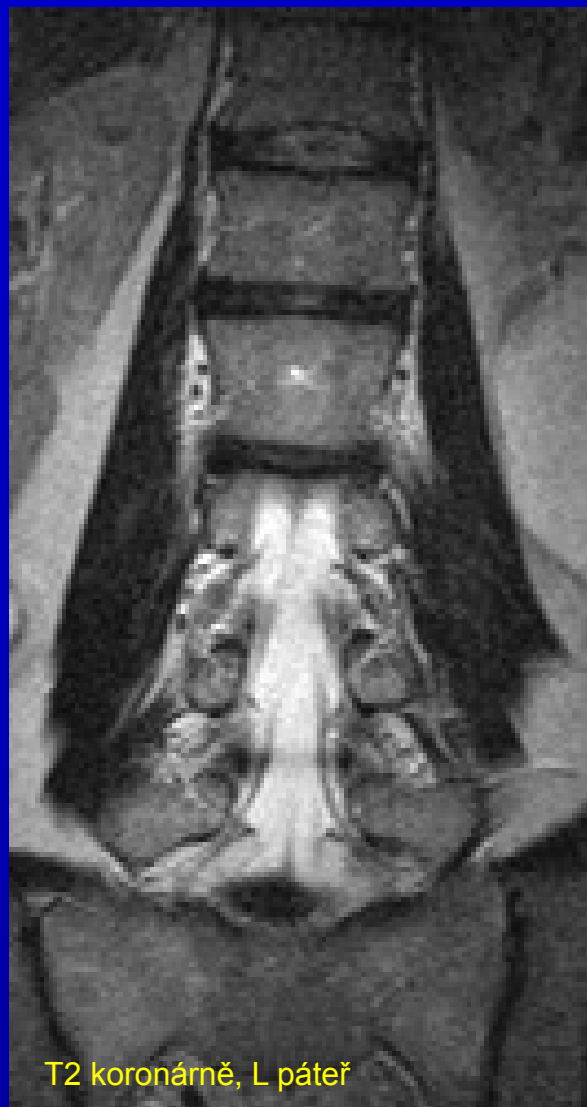
T1 v sag. rovině: zobrazení foramin



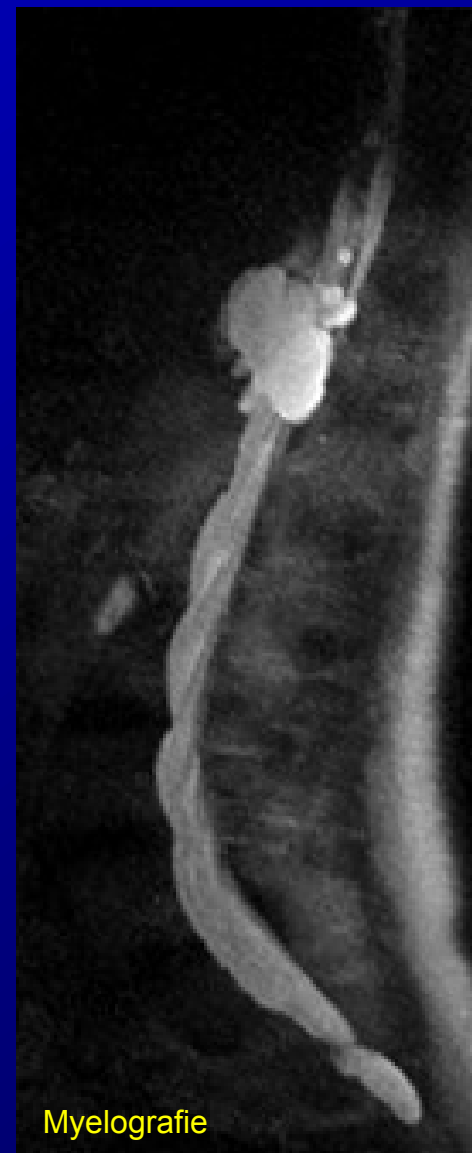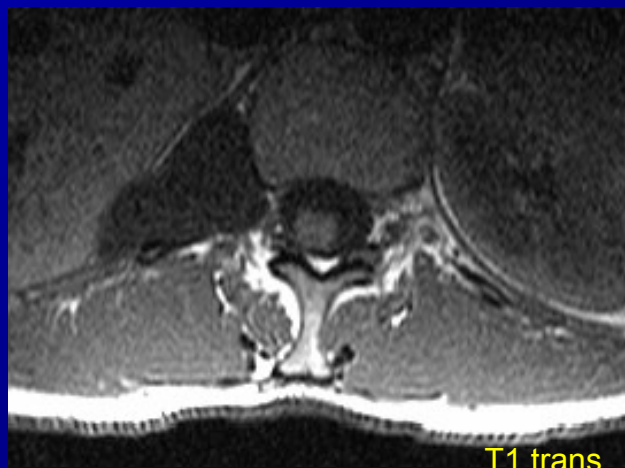
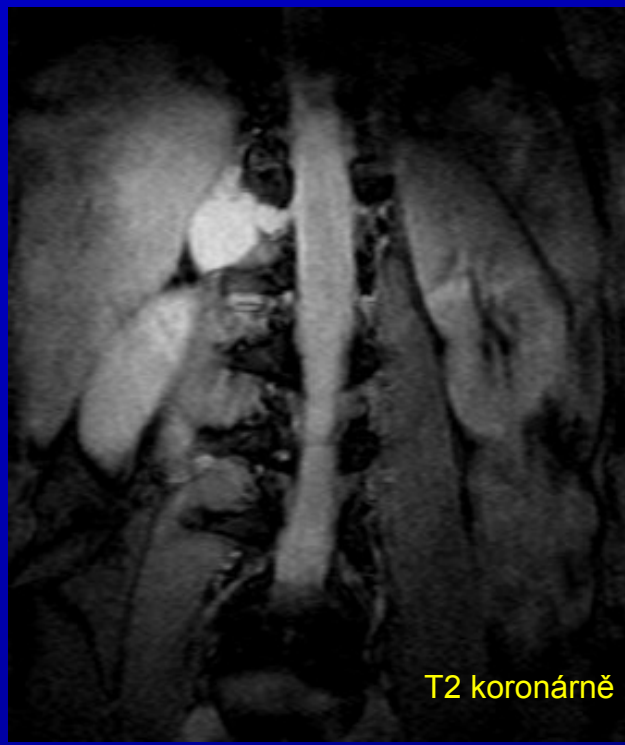
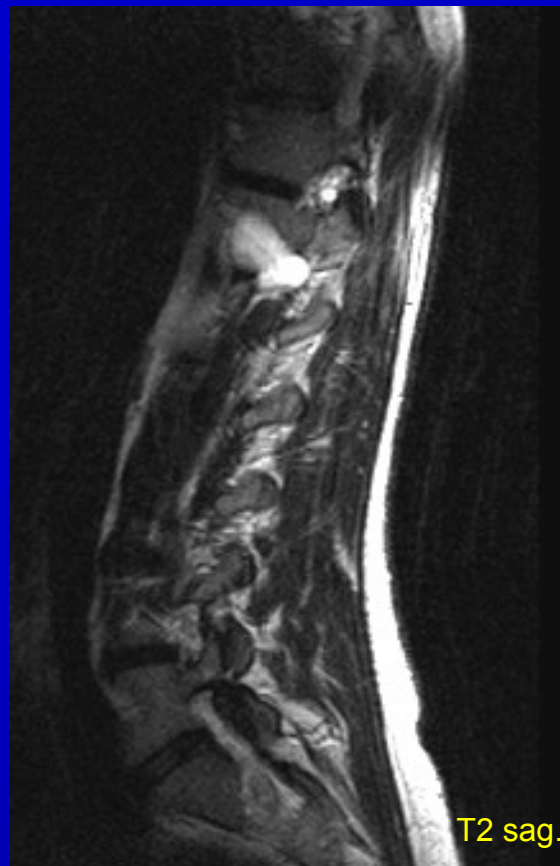
T2 sagitálně



Hodnocení MR vyšetření - Th,L



Hodnocení MR vyšetření - Th,L



MR zobrazení tekutiny:
kořenová cysta