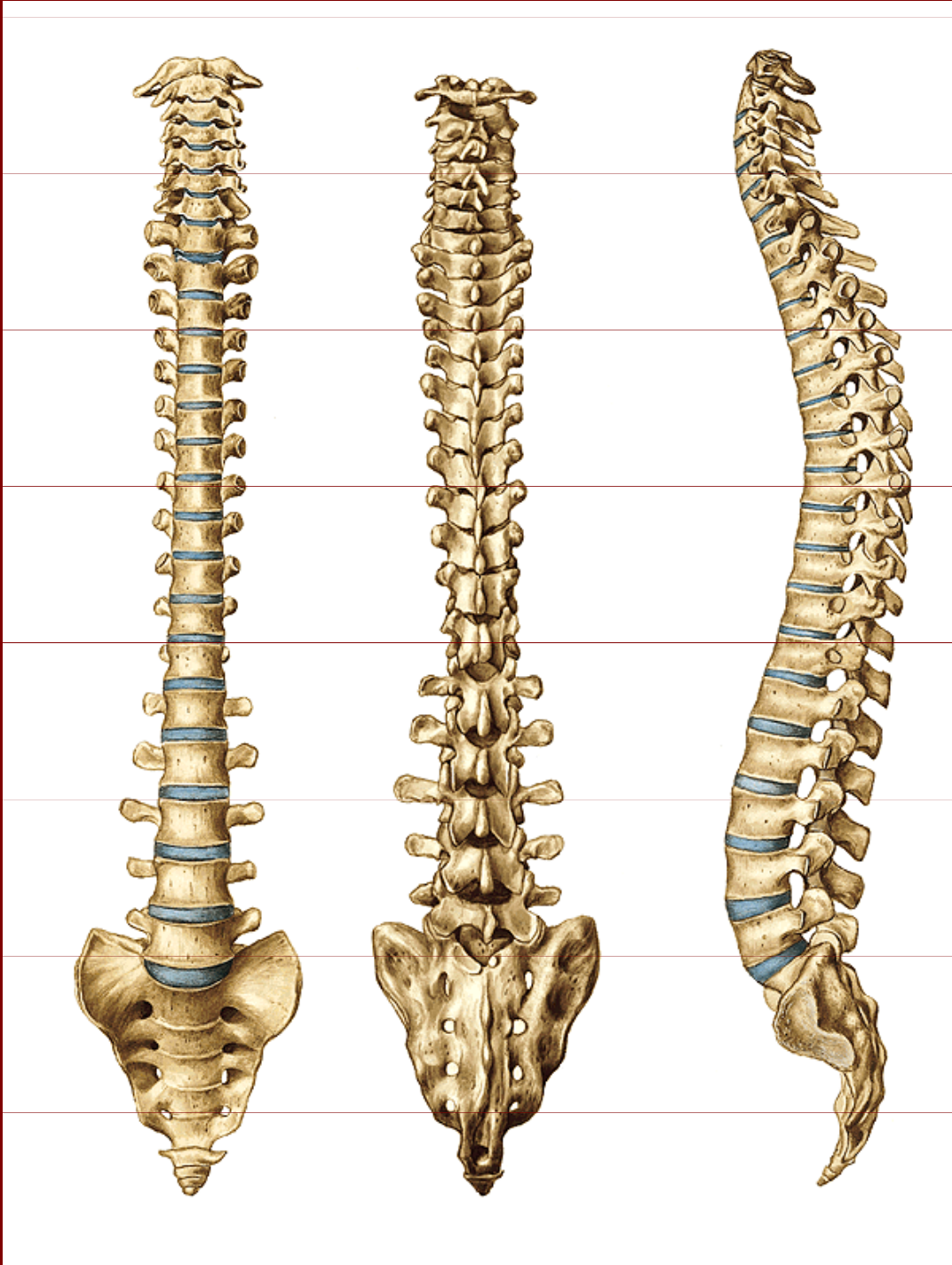


Kostra páteře, hrudníku, horní a dolní končetiny

ZL I (2) / podzim

Kostra páteře



Vertebrae cervicales 7

Vertebrae thoracicae 12

Vertebrae lumbales 5

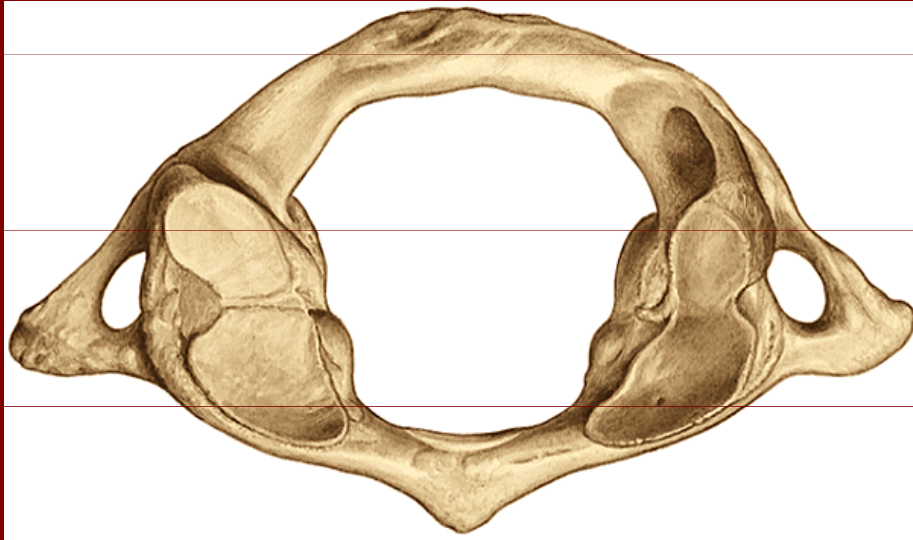
Vertebrae sacrales 5

(os sacrum)

Vertebrae coccygeae 3-5

(os coccygis)

Atlas = nosič



Arcus anterior

Arcus posterior

Massae laterales

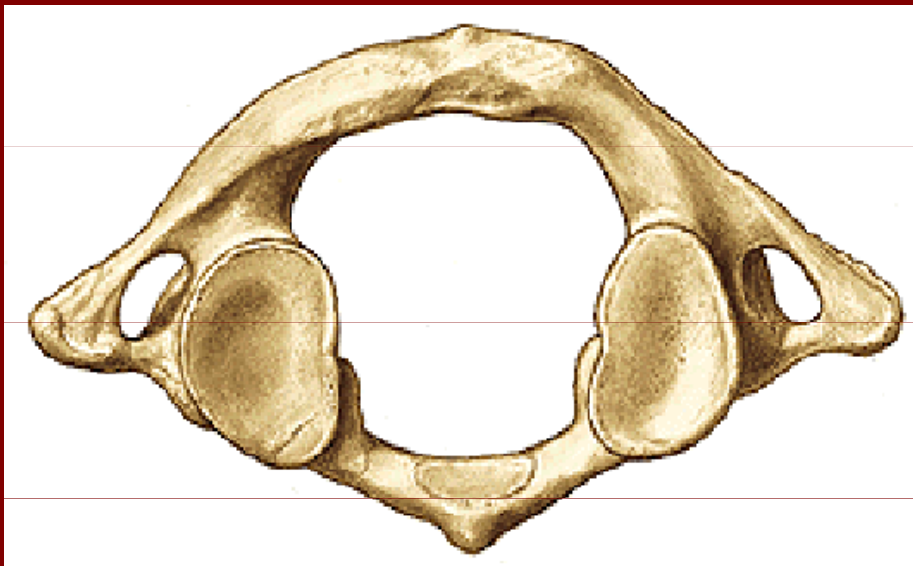Fovea dentis

Tuberculum posterius
atlantis

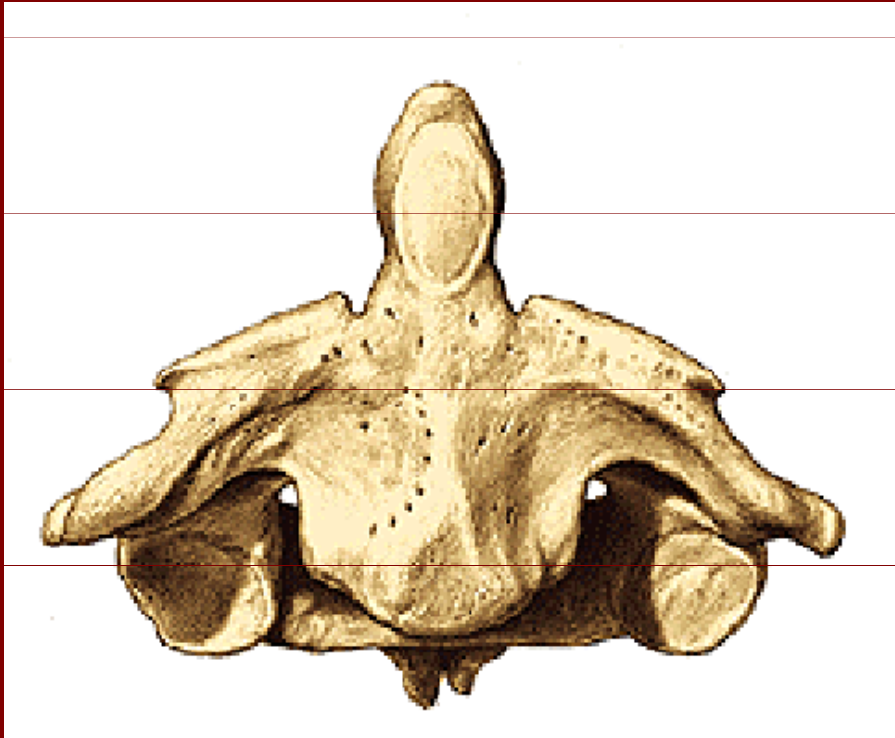
Foveae articulares sup.

Foveae artticulares inf.

Foramen processus
transversi



Axis = čepovec



Facies articulares superiores

Facies articulares inferiores

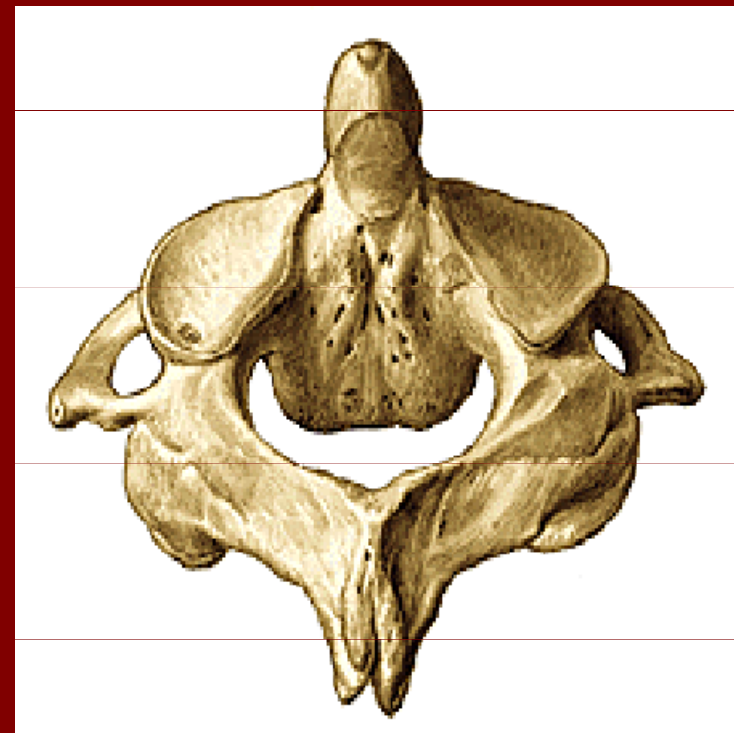Processus transversarius

Processus spinosus

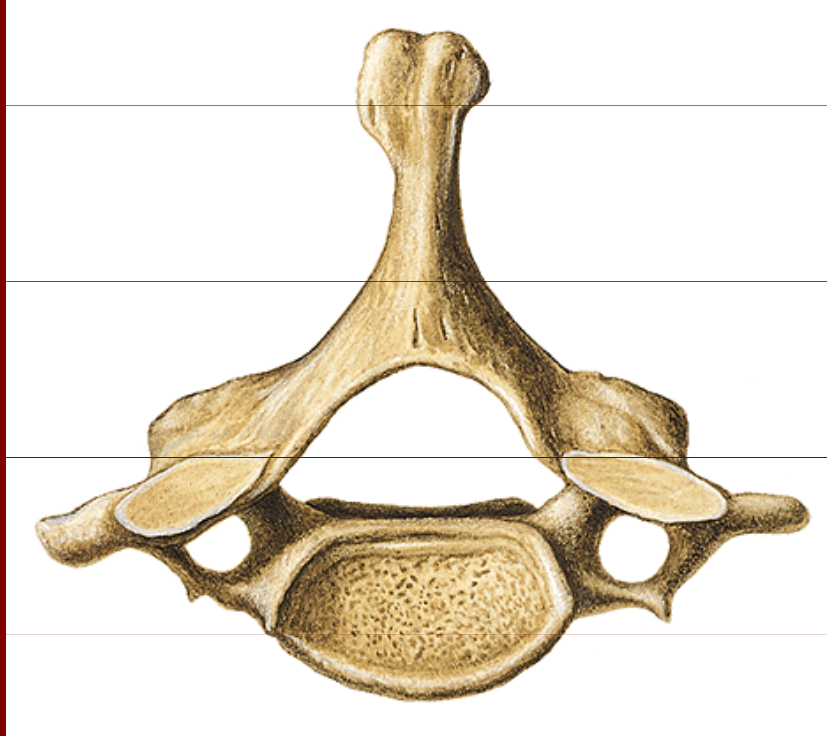
Dens axis

Facies articularis anterior

Facies articularis posterior



Vertebra cervicalis



Corpus vertebrae

Arcus vertebrae

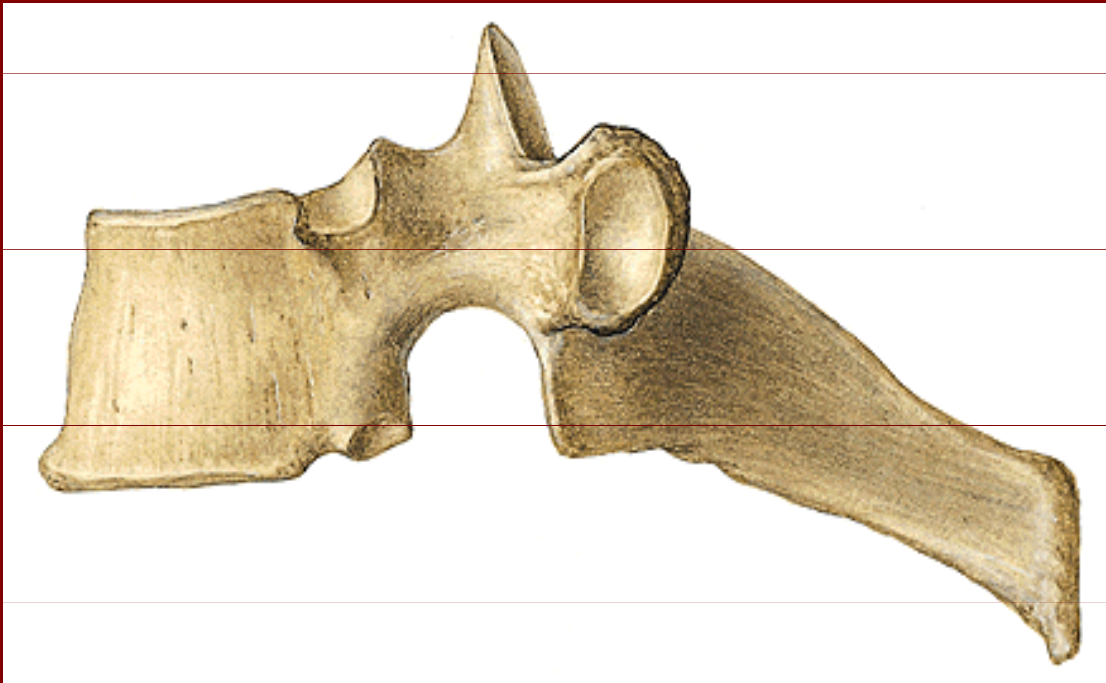
Processus spinosus

Processus transversi

Foramen processus transversi

Sulcus nervi spinalis

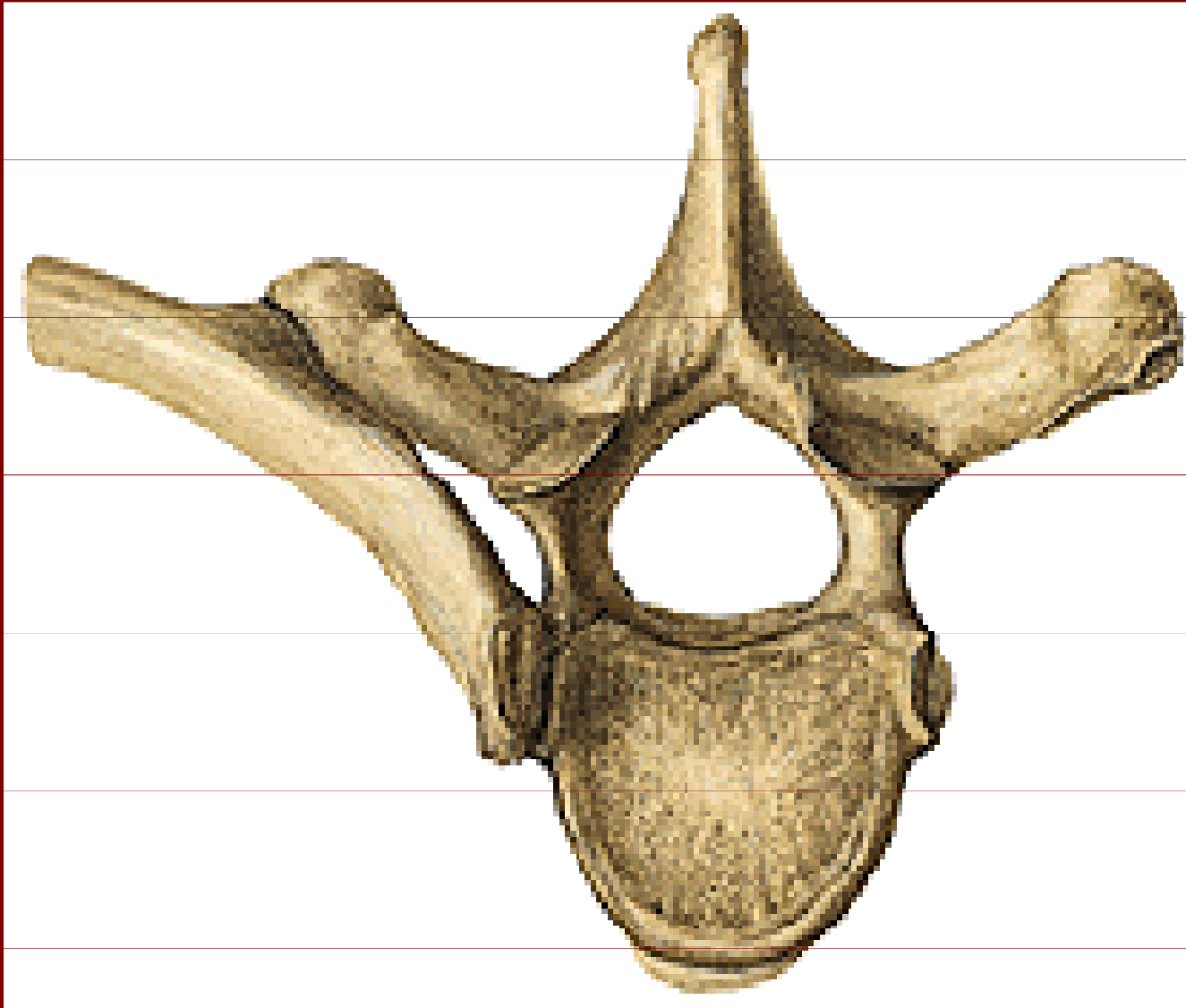
Vertebra thoracica



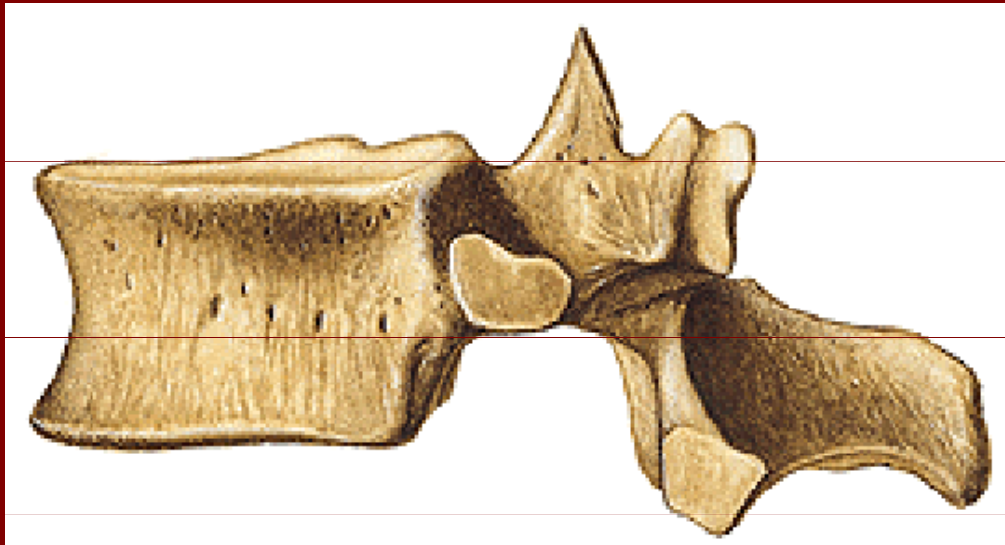
Foveae costales

Facies costales
transversales

Připojení žebra na hrudní obratel



Vertebra lumbalis



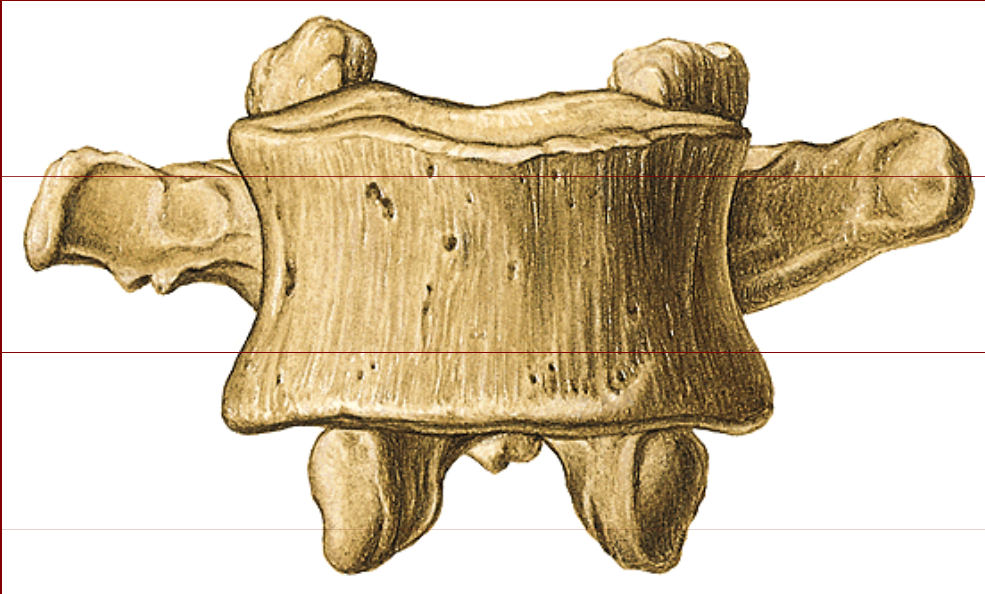Corpus vertebrae

Processus articulares

Processus spinosus

Processus mammillaris

Vertebra lumbalis



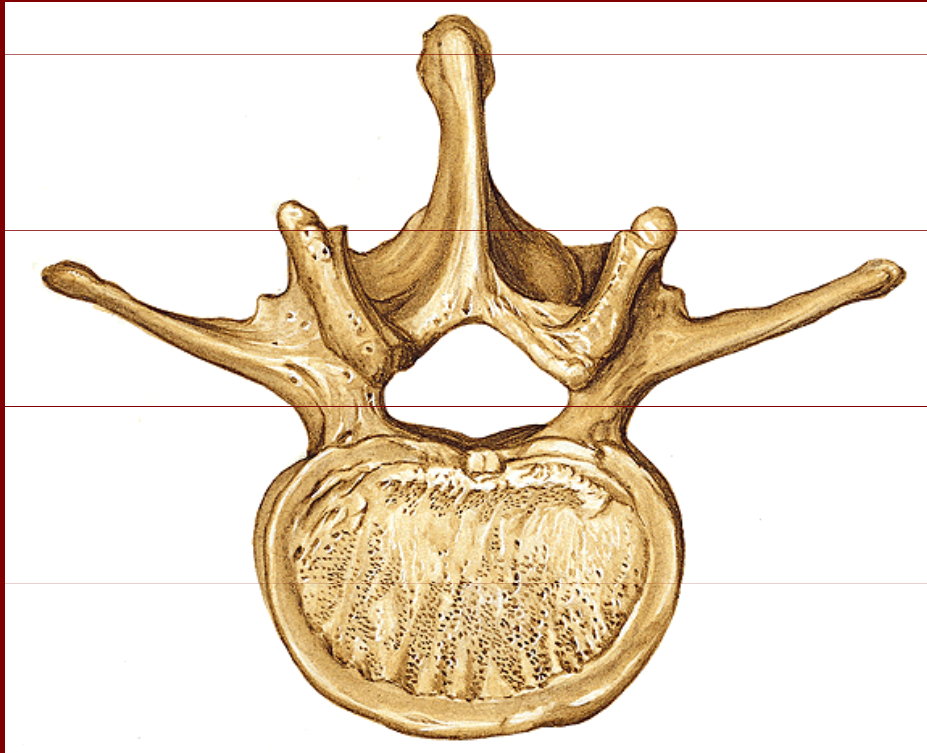
Corpus vertebrae

Processus costarius

Processus articulares

superiores a inferiores

Vertebra lumbalis



Corpus vertebrae

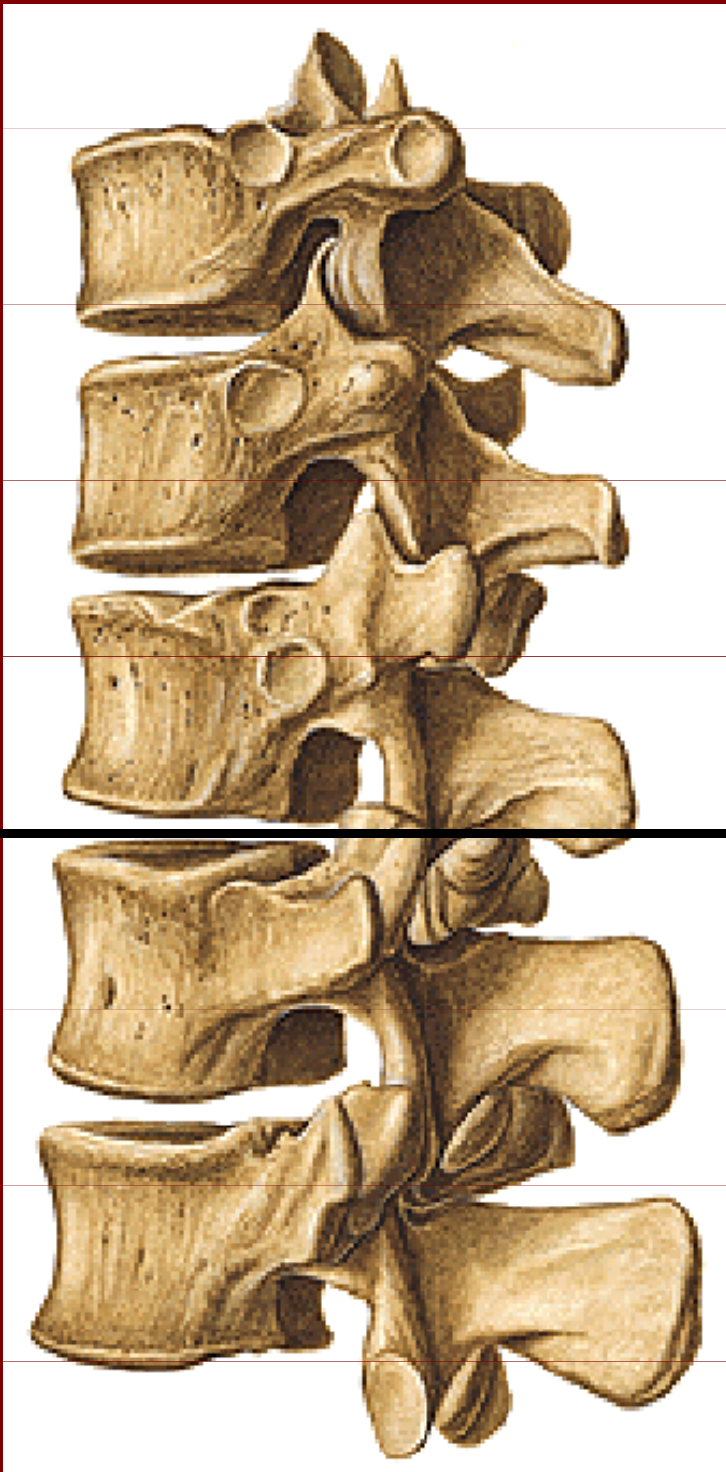
Foramen vertebrae

Processus costarius

Processus spinosus

Processus mammillaris

Processus accessorius

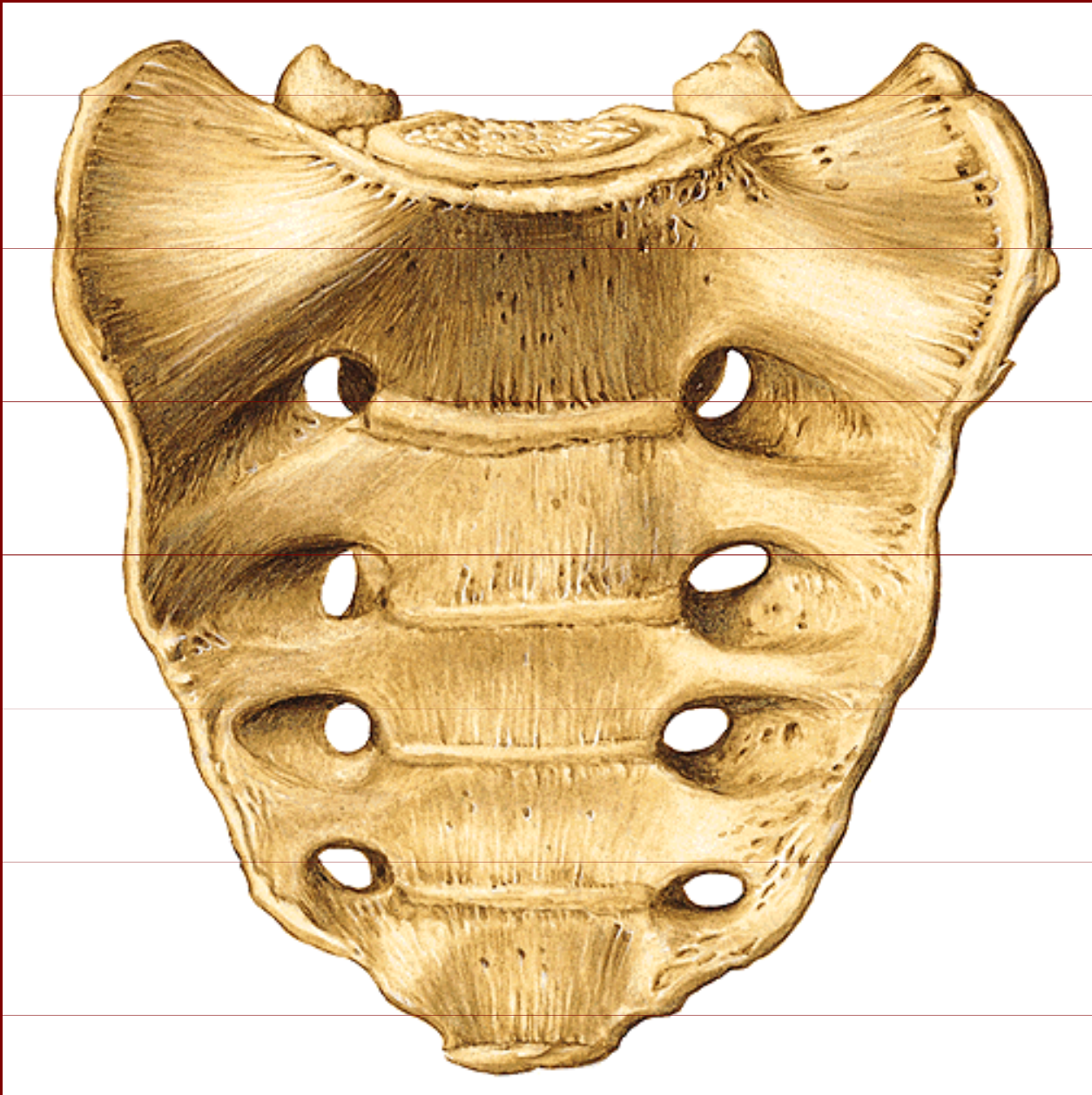


Columna vertebralis

Hrudní oddíl

Bederní oddíl

Os sacrum



Basis ossis sacri

Promontorium

Facies pelvina

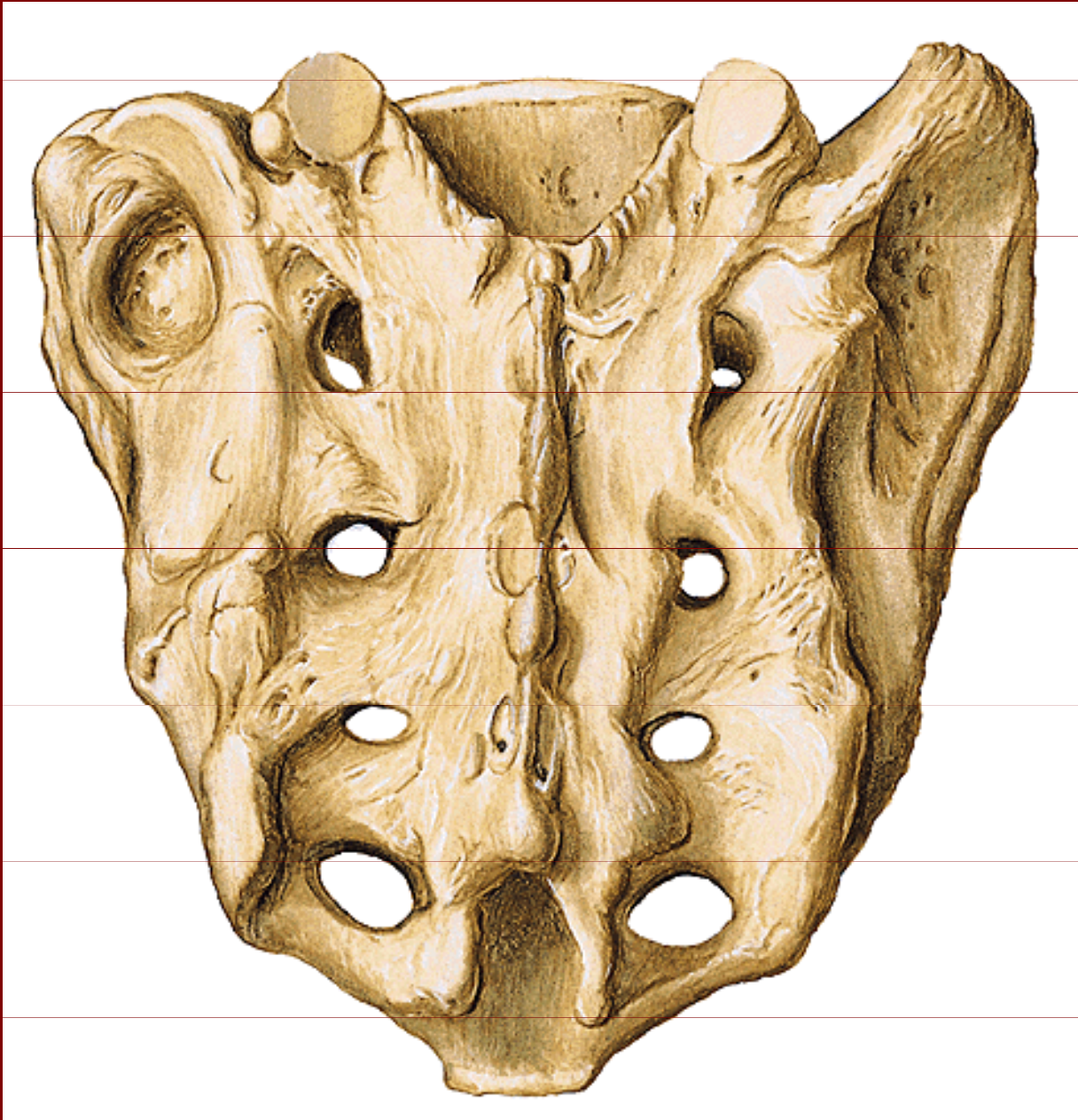
Lineae transversae

Foramina sacralia
pelvina

Apex ossis sacri

(konkávní plocha)

Os sacrum



Facies dorsalis

Crista sacralis
mediana

Cristae sacrales
laterales

Cristae sacrales
intermediae

Foramina sacralia
dorsalia

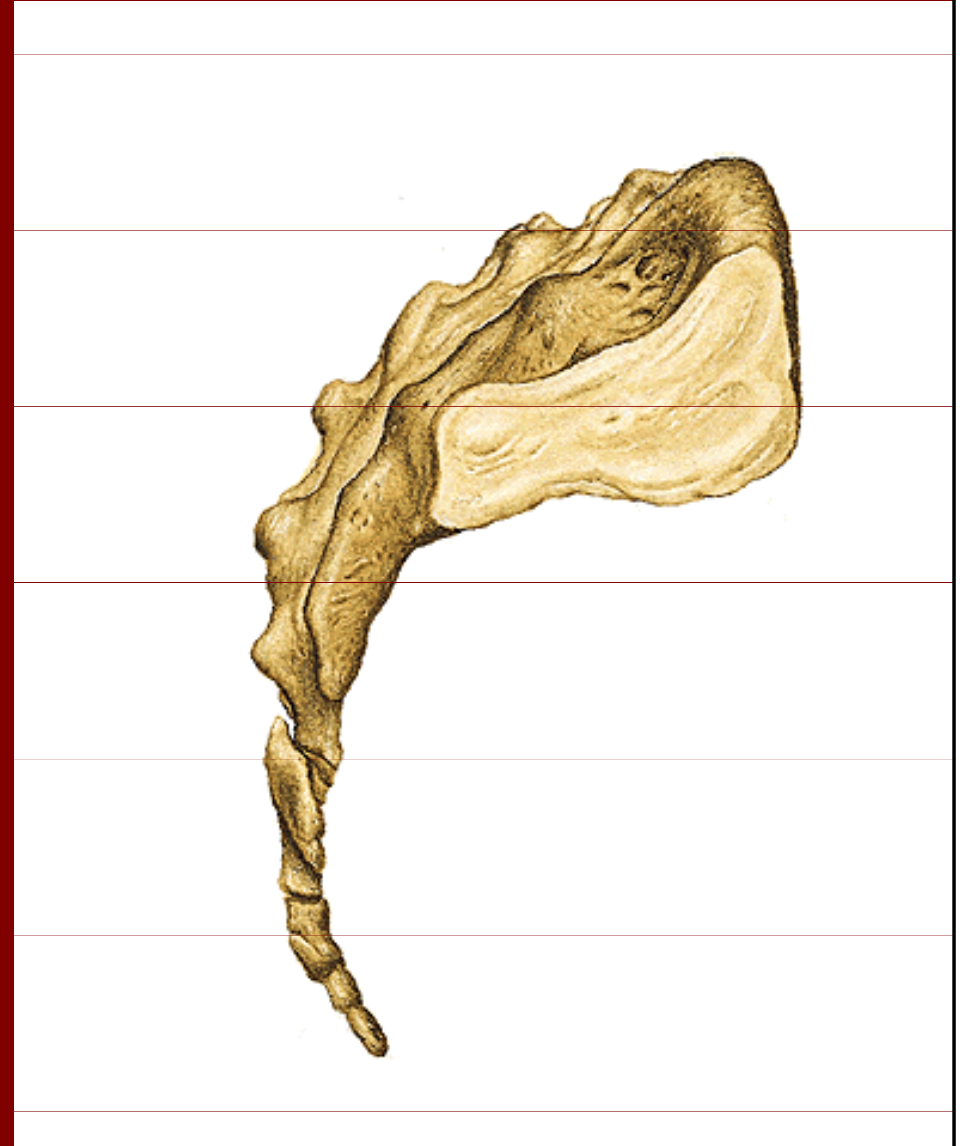
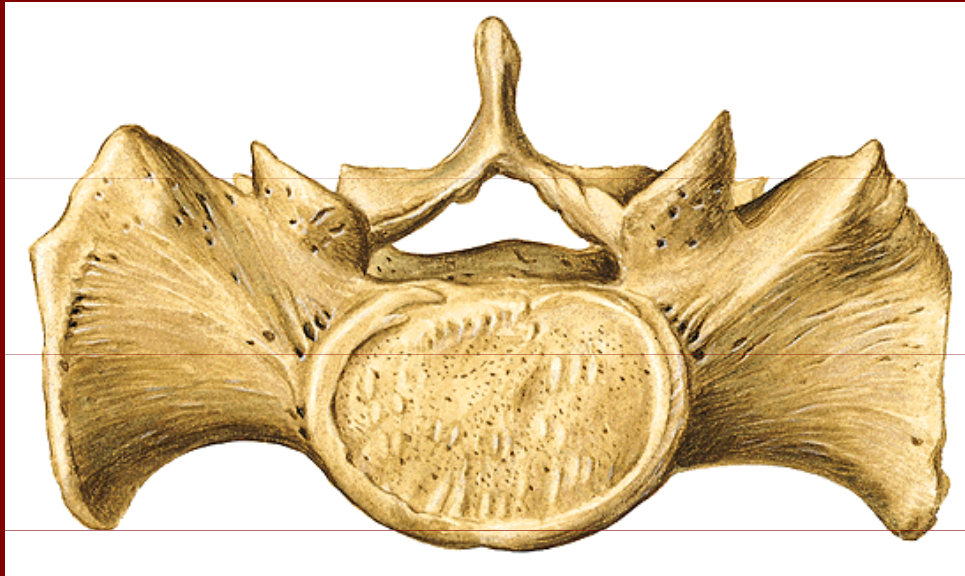
Cornua ossis sacri
(konvexní plocha)

Os sacrum

Facies auricularis

Canalis sacralis

Hiatus sacralis



Os coccygis = kostrč

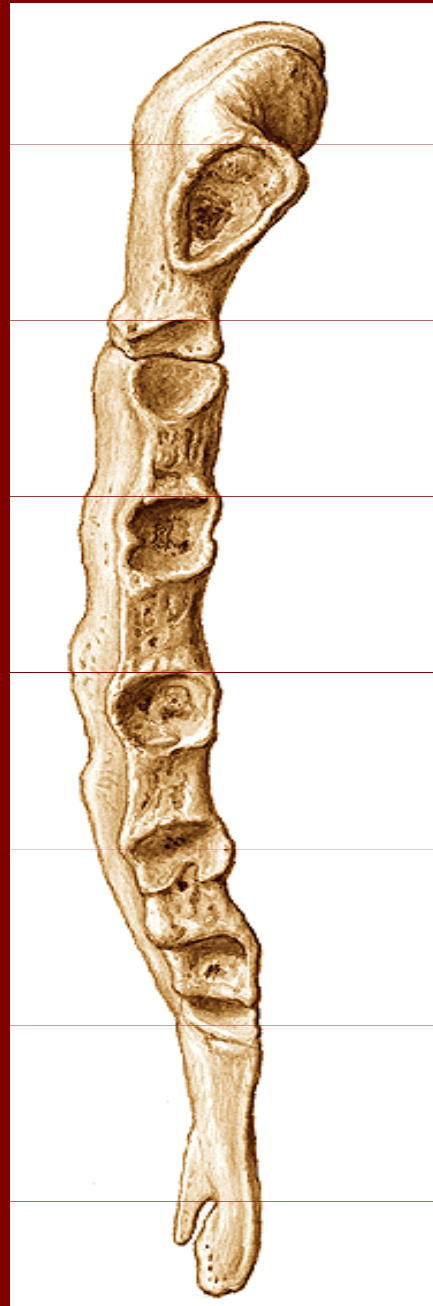
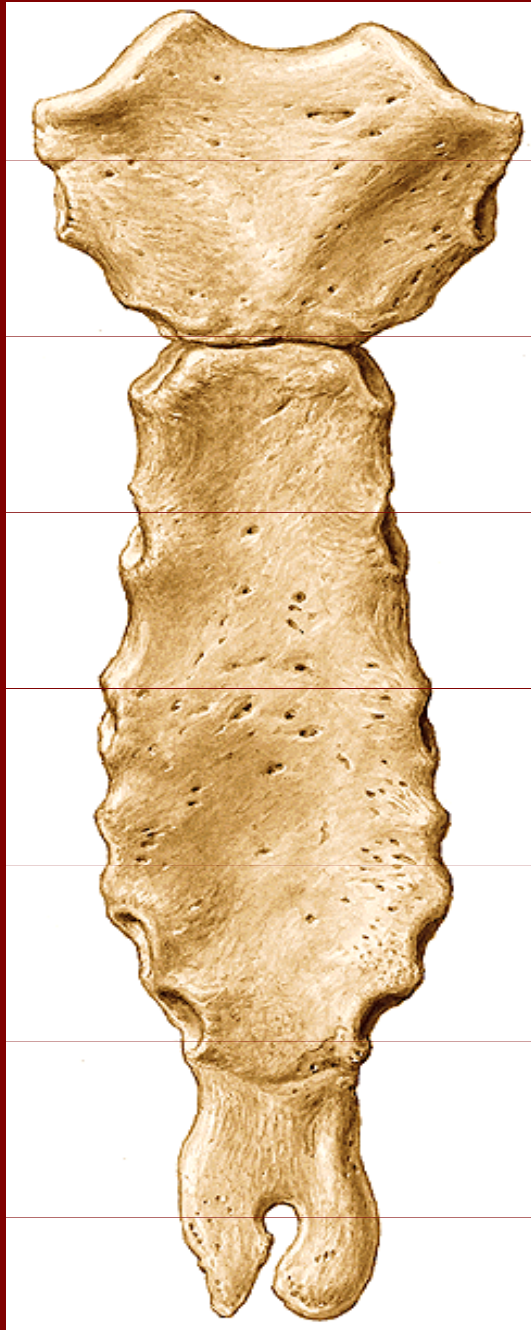
Facies terminalis sacralis

Cornua ossis coccygis

Apex coccygis

Sternum = kost hrudní



Manubrium

Angulus sterni

Corpus

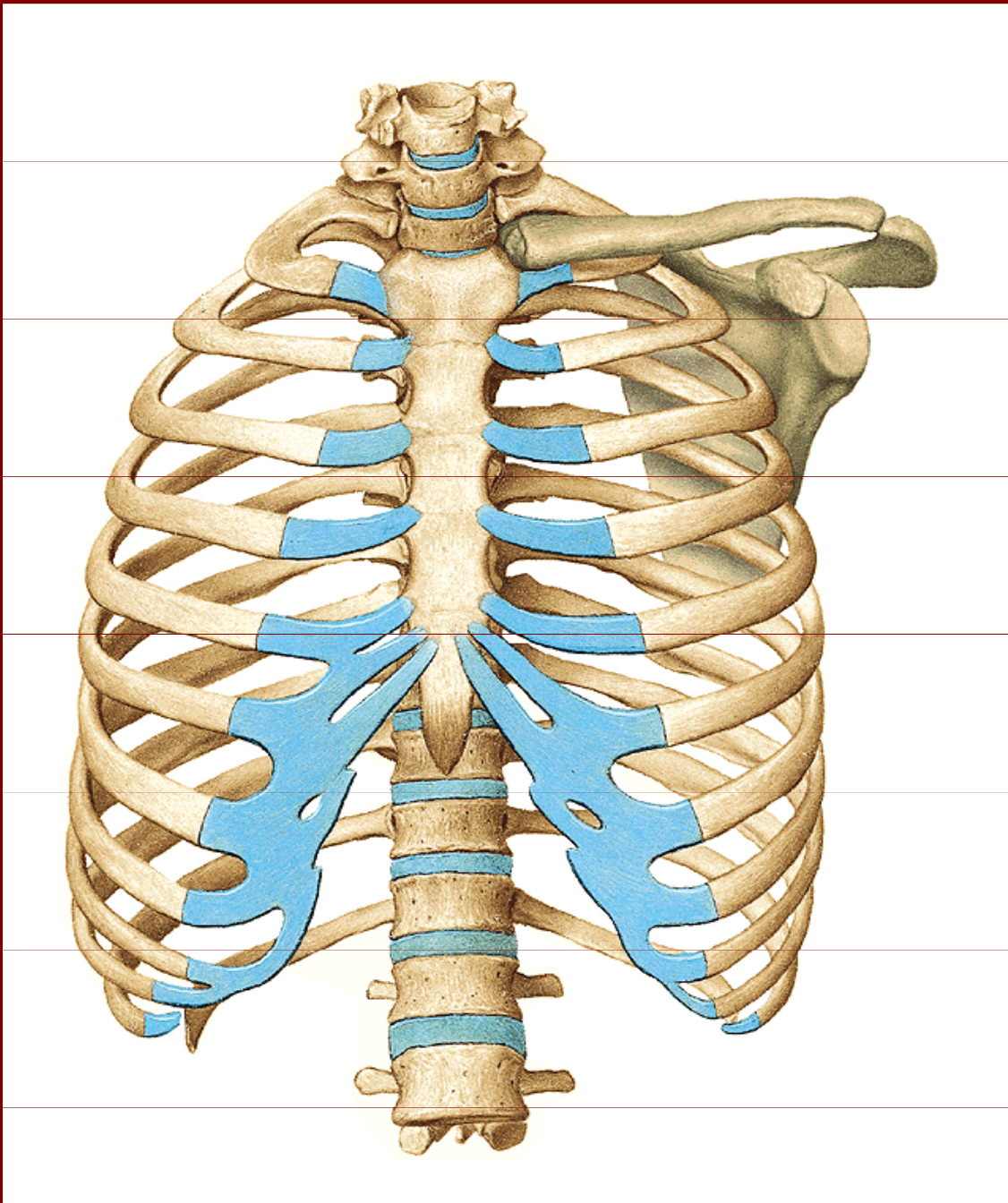
Processus xiphoideus

Incisura jugularis

Incisura clavicularis

Incisurae costales

Spojení na hrudníku

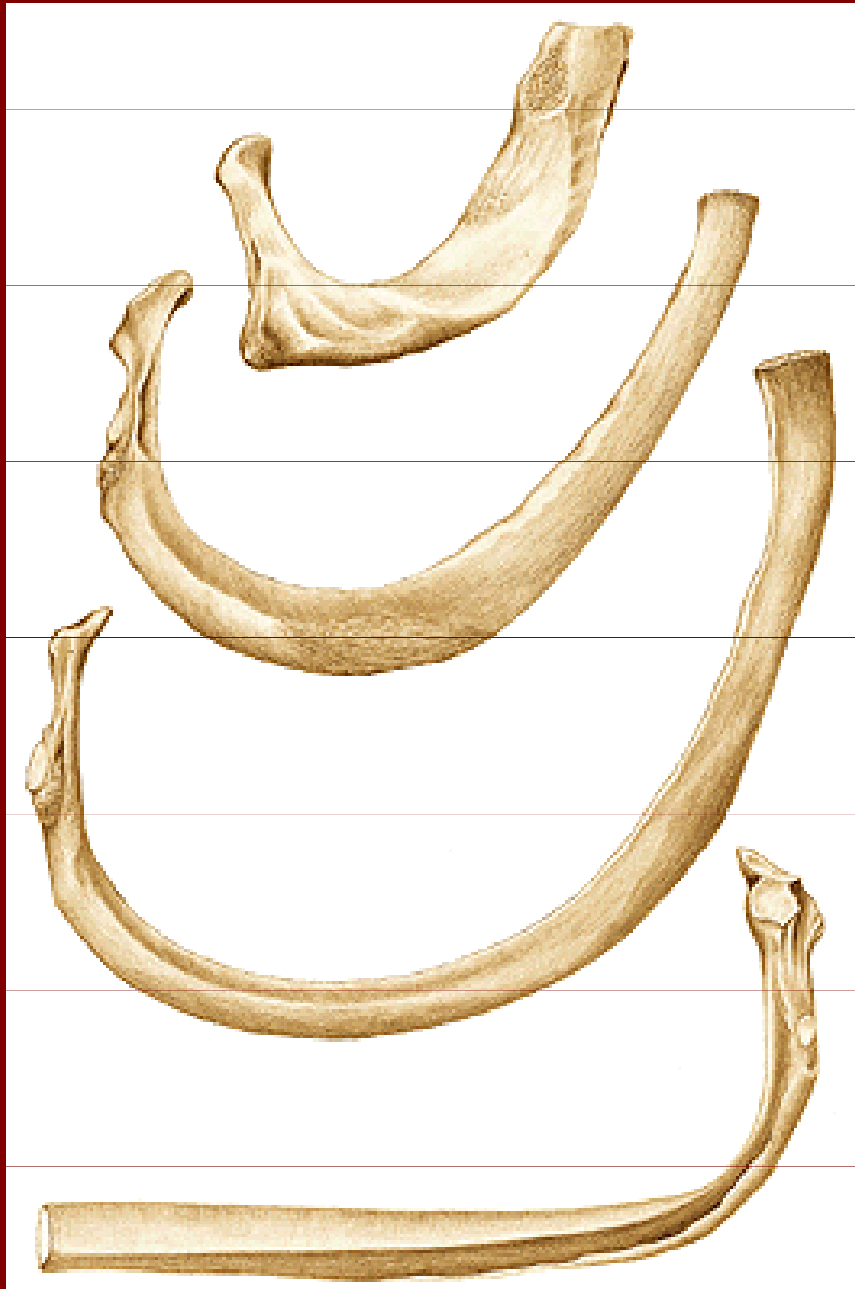

Costae verae (7)

Costae spuriae (3)

Costae fluctuantes (2)

Costae = žebra



Caput

Collum

Corpus

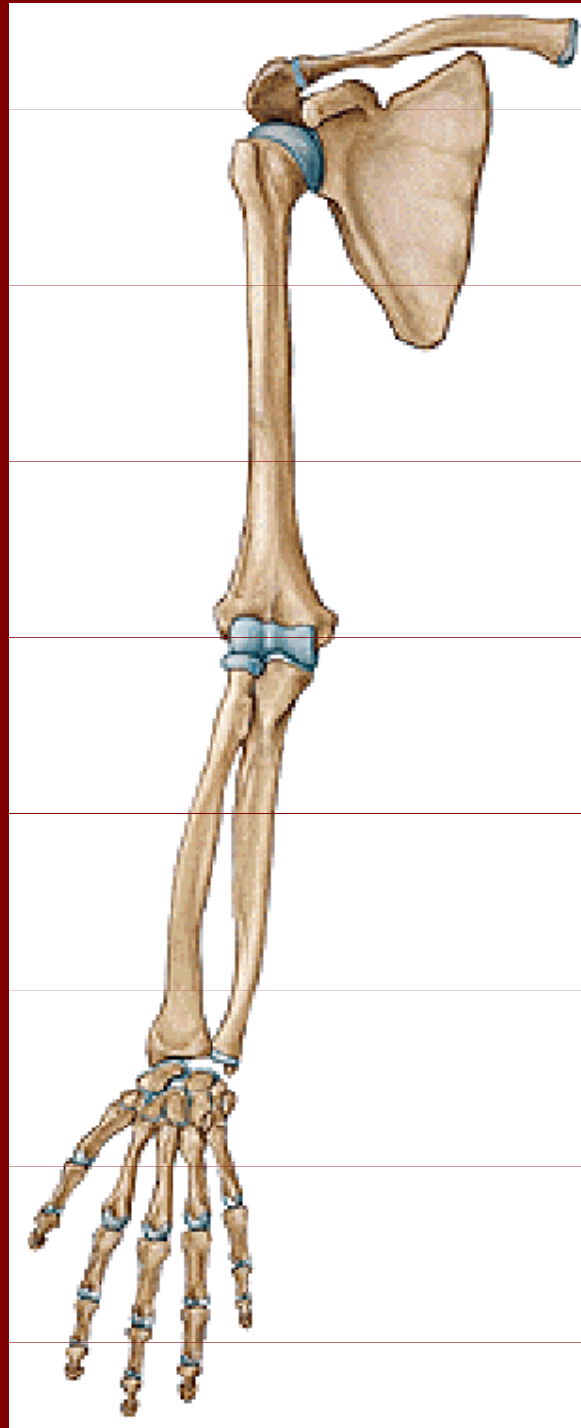
Tuberculum costae

Angulus costae

Sulcus costae

Crista costae

Kostra HK



Scapula

Clavicula

Humerus

Radius

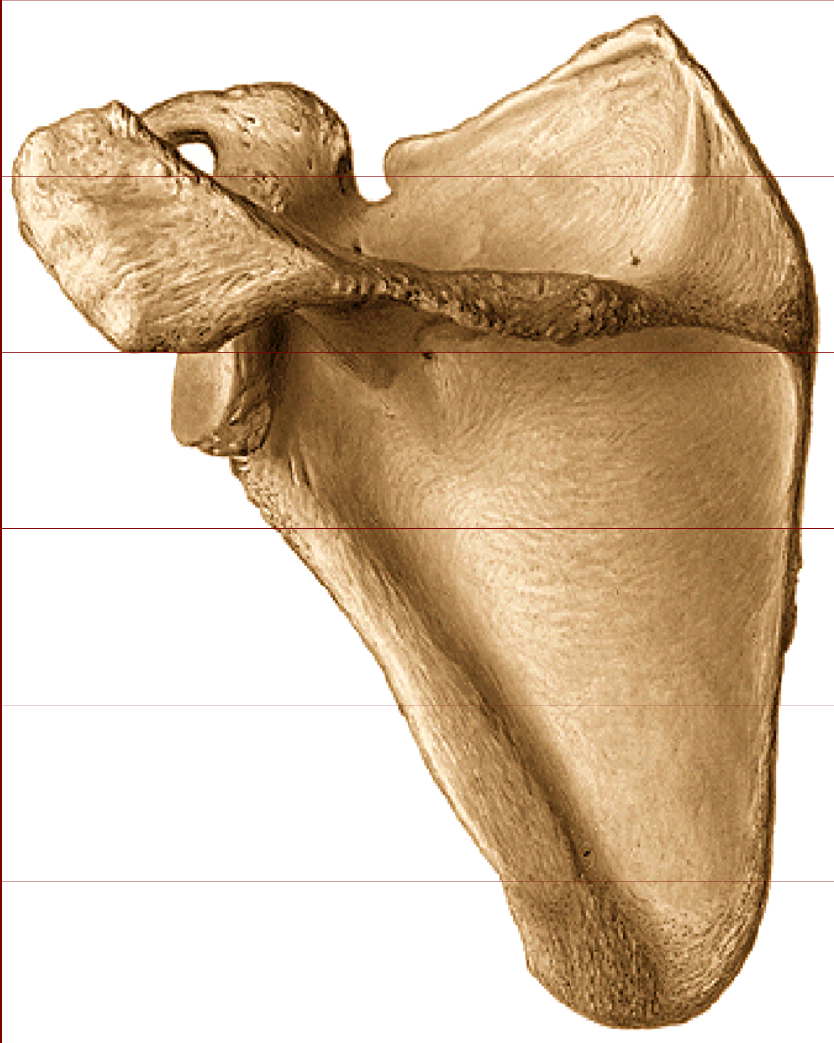Ulna

Ossa carpi

Ossa metacarpi

Phalanges digitorum

Scapula = lopatka



Margo superior, medialis, lateralis

Angulus superior, inferior, lateralis

Spina scapulae

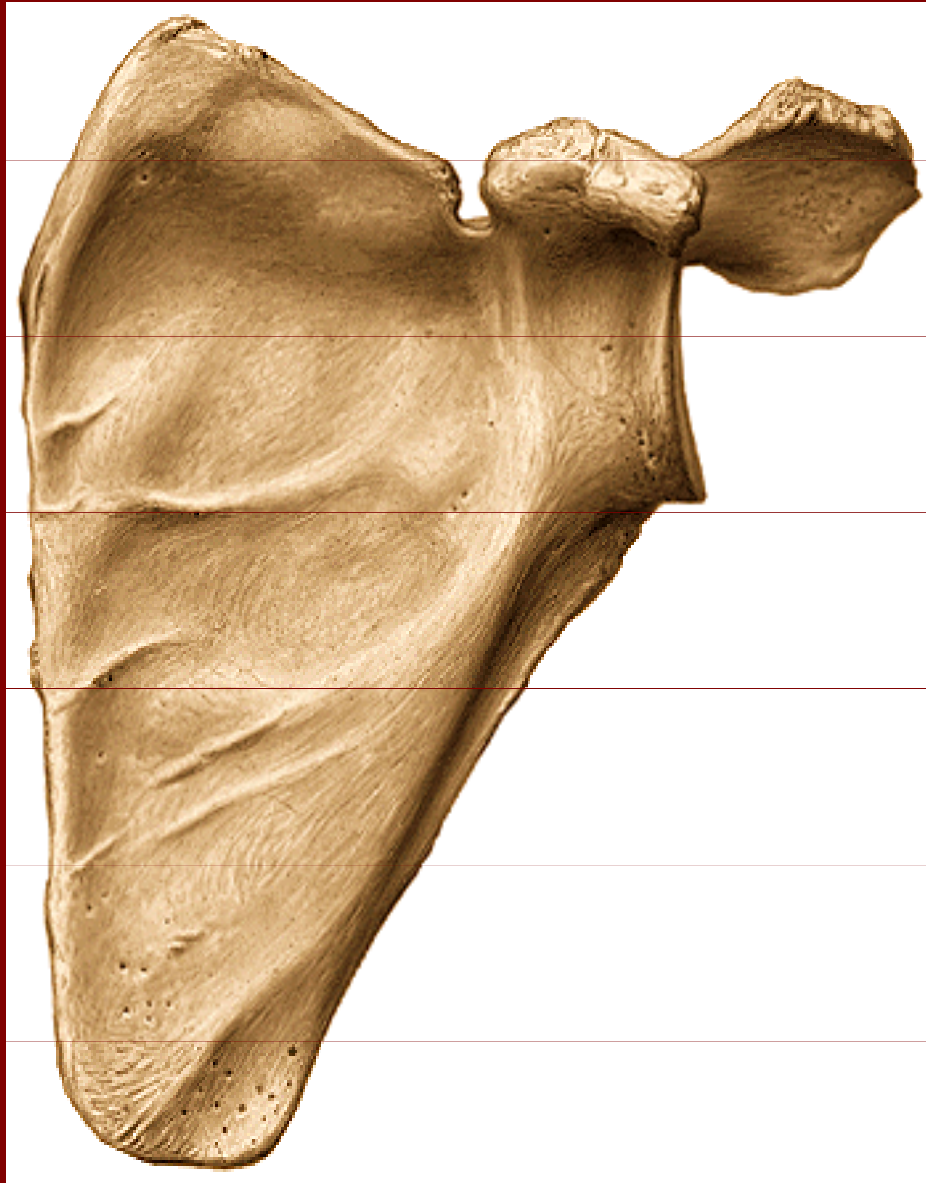
Acromion

Fossa supraspinata

Fossa infraspinata

Facies dorsalis

Scapula = lopatka



Lineae musculares

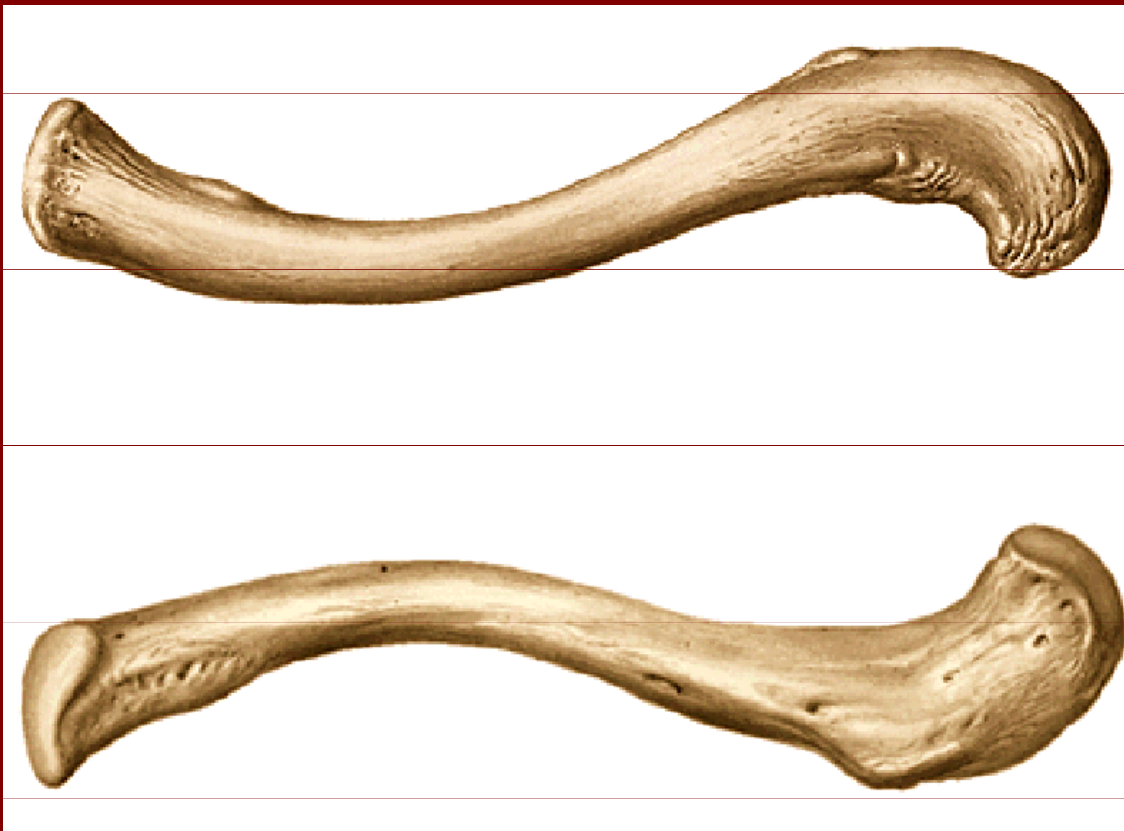
Incisura scapulae

Processus
coracoideus

Cavitas glenoidalis

Facie costalis

Clavicula = klíčnicí kost



Extremitas acromialis

Extremitas sternalis

Facies articularis sternalis

Facies articularis acromialis

Tuberositas coracoidea

Humerus



Caput humeri

Collum anatomicum

Tuberculum majus

Tuberculum minus

Sulcus intertubercularis

Tuberossitas deltoidea

Sulcus nervi radialis

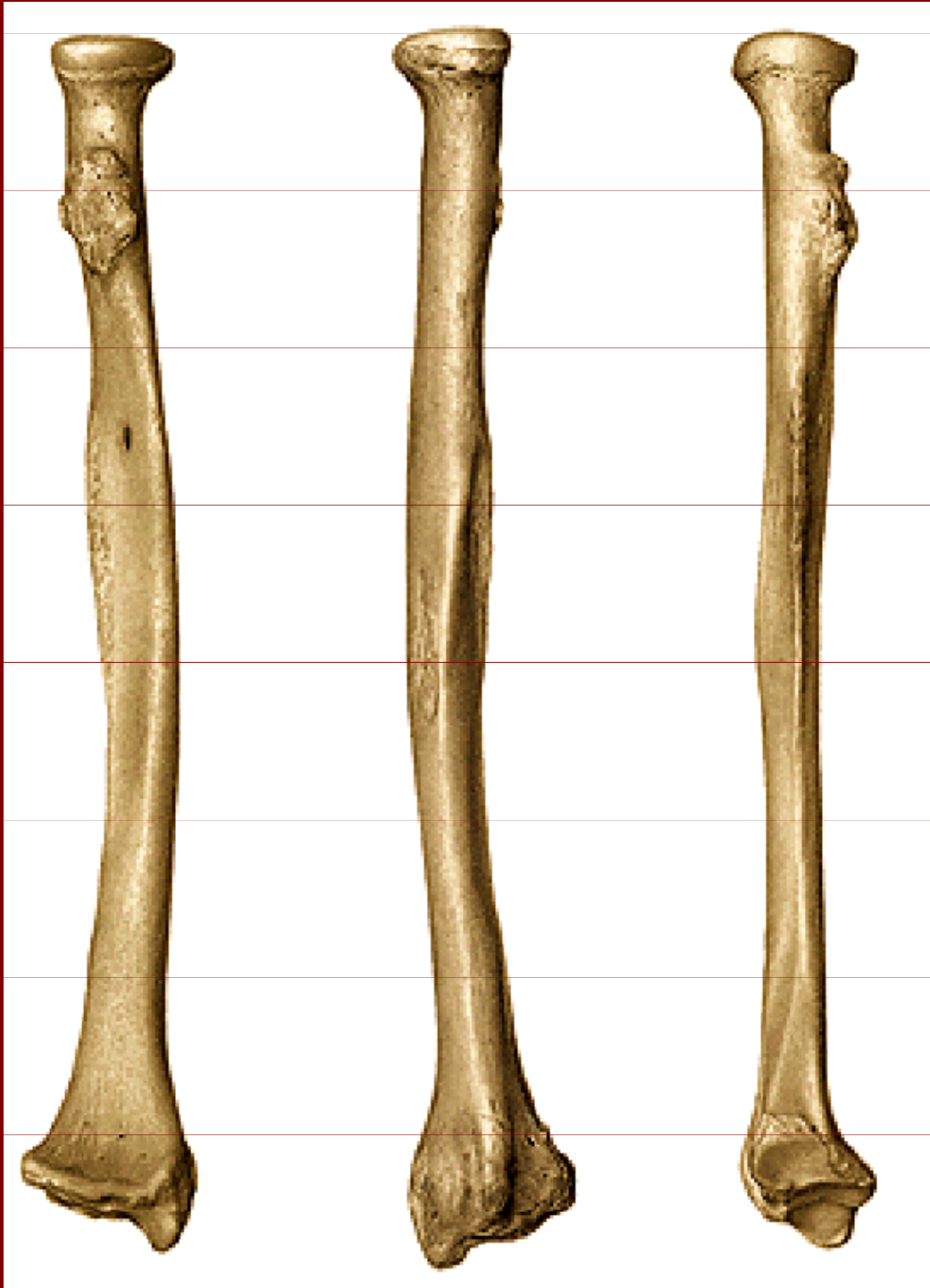Epicondylus med., lat.

Trochlea humeri

Capitulum humeri

Fossa olecranii, radialis,
coronoidea

Radius



Caput radii

Circumferentia capitis radii

Collum radii

Tuberositas radii

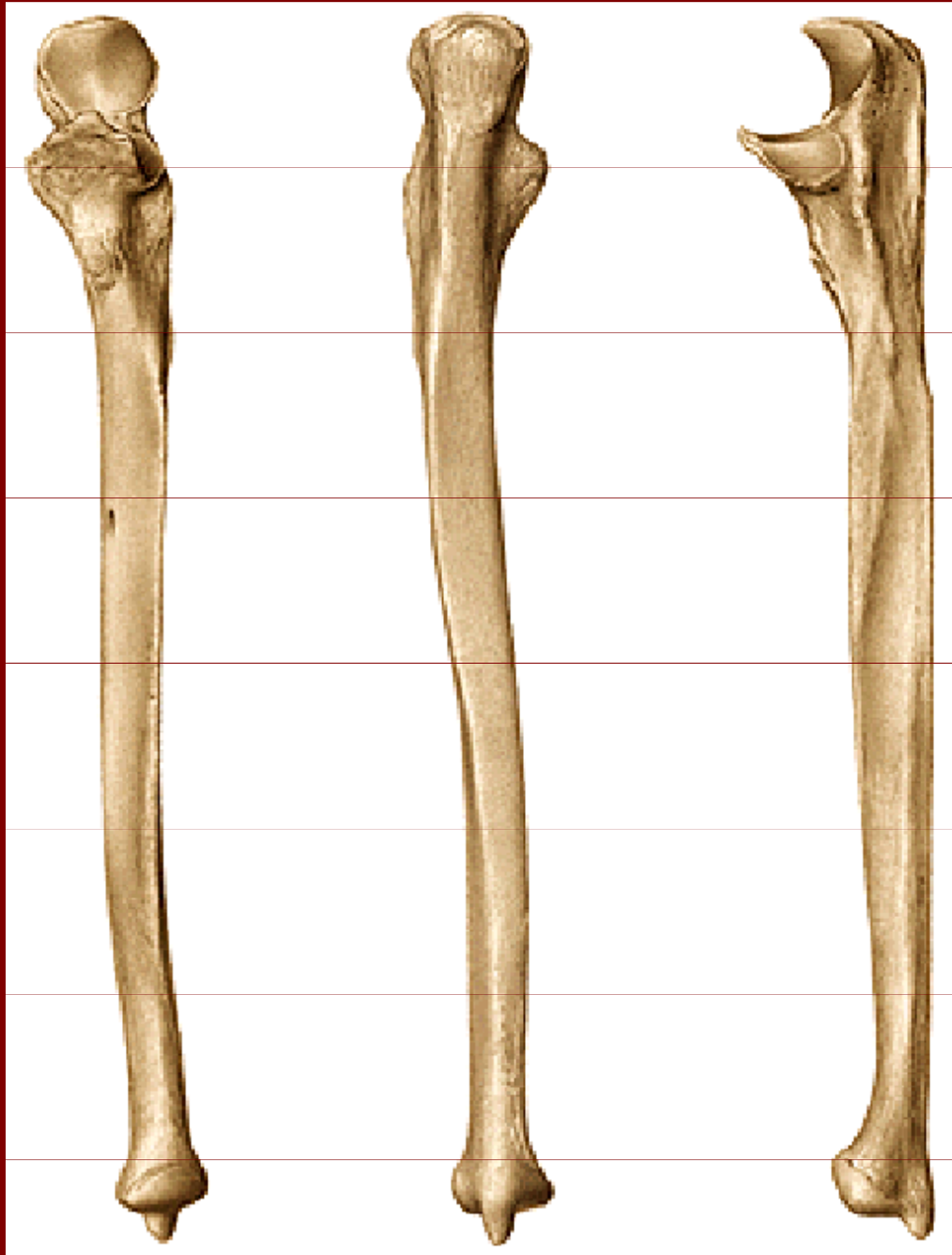
Margo interosseus

Processus styloideus

Incisura ulnaris

Facies articularis distalis

Ulna



Olecranon ulnae

Incisura trochlearis

Crista musculi supinatorii

Processus coronoideus

Tuberositas ulnae

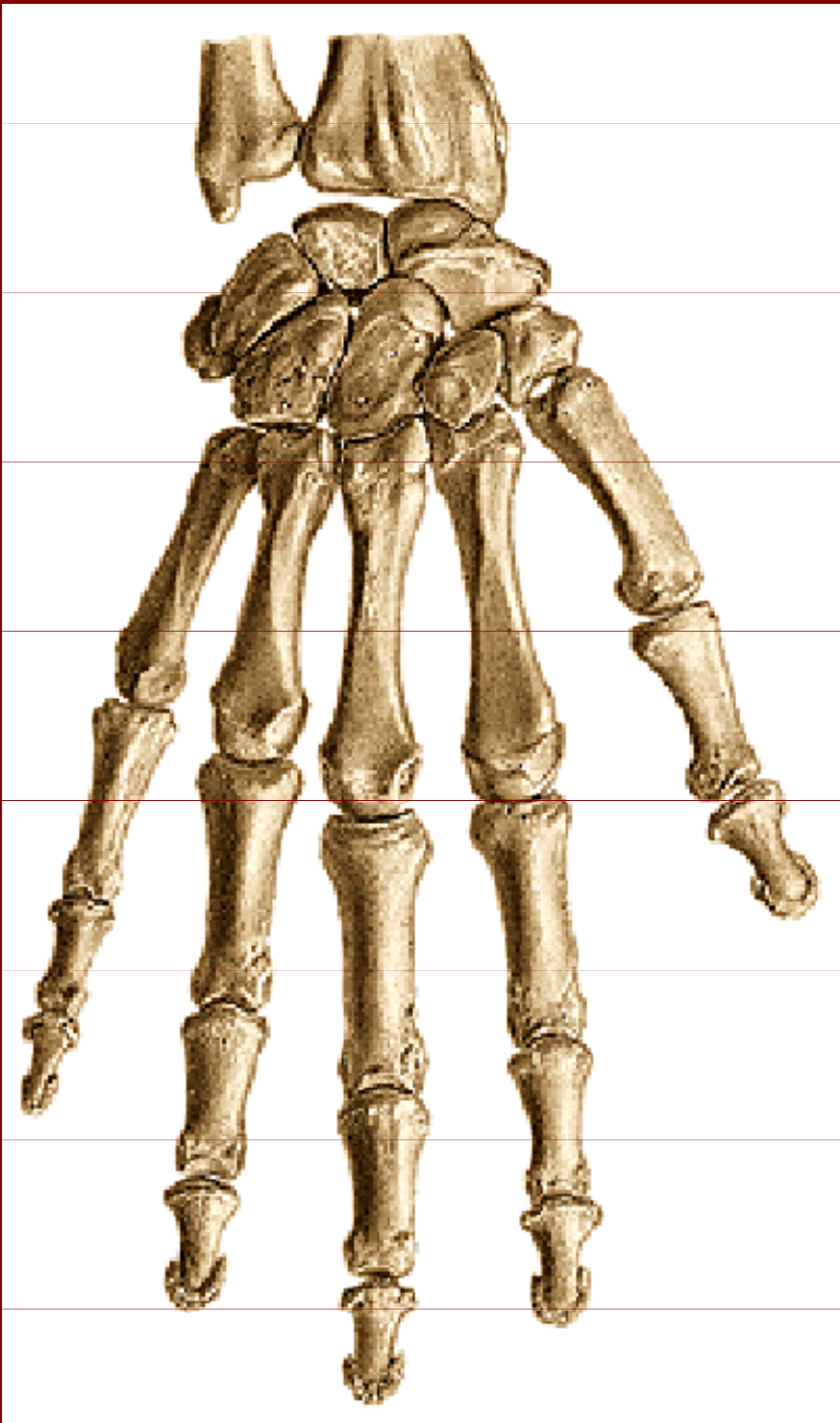
Margo interosseus

Caput ulnae

Processus styloideus

Circumferentia articularis

Ossa manus



Ossa carpi:

Os scaphoideum, os lunatum,
os triquetrum, os pisiforme,
os trapezium, os trapezoideum,
os capitatum, os hamatum

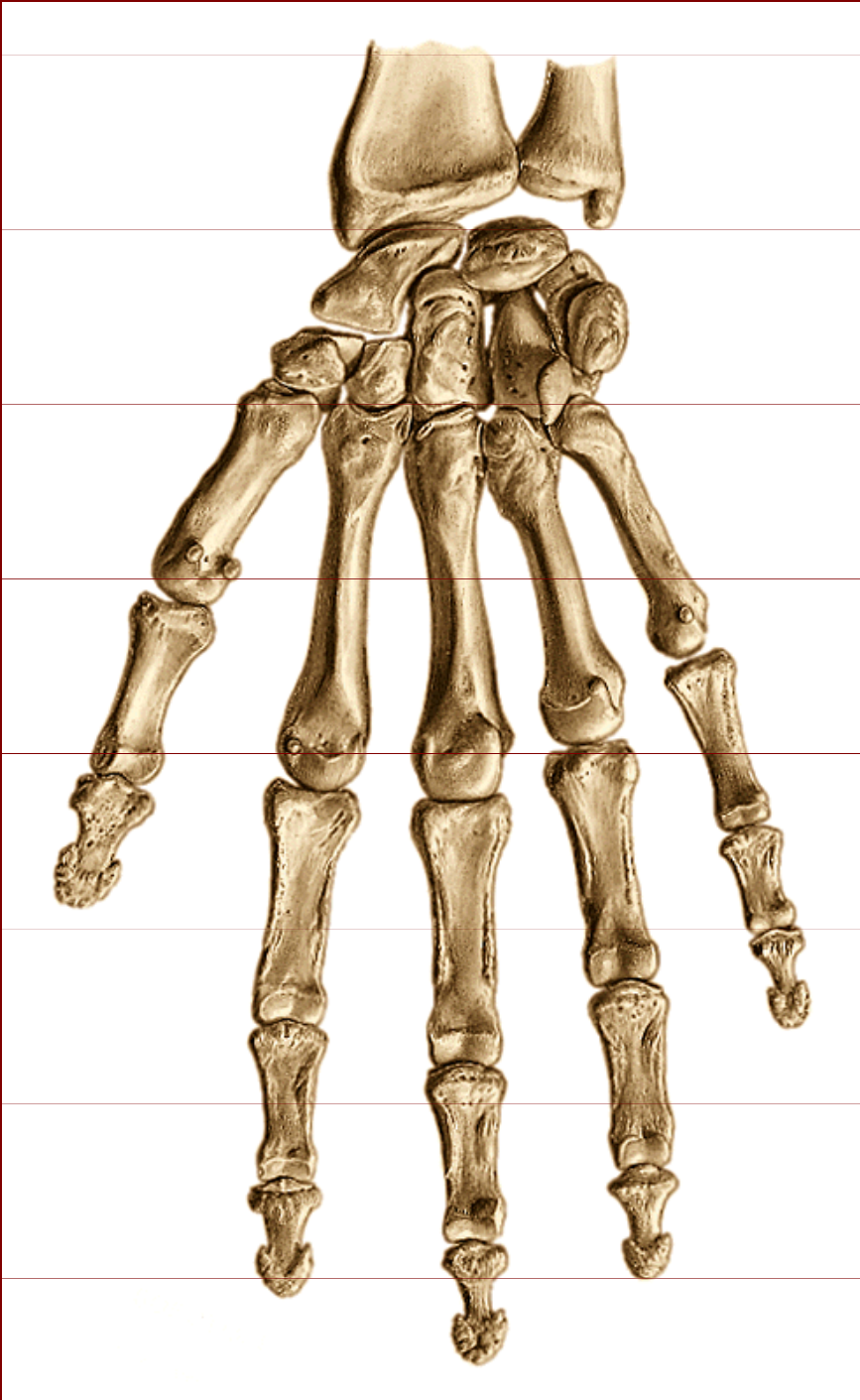
Ossa metacarpi I až V:

Basis, corpus, caput

Ossa digitorum manus:

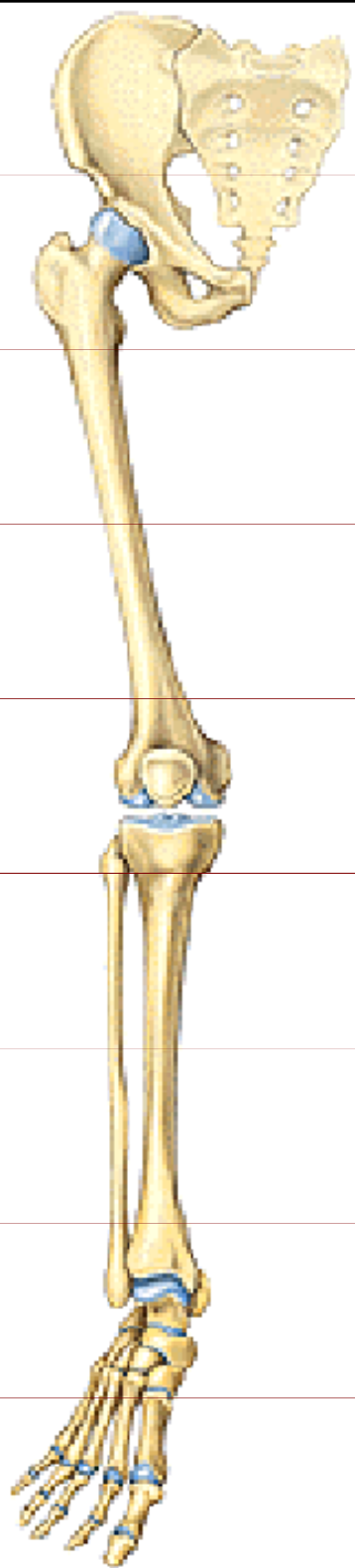
Phalanges :

proximalis, medius, distalis



Ossa manus

Facies palmaris



Kostra dolní končetiny

Os coxae

Femur

Tibia

Fibula

Patella

Ossa tarsi:

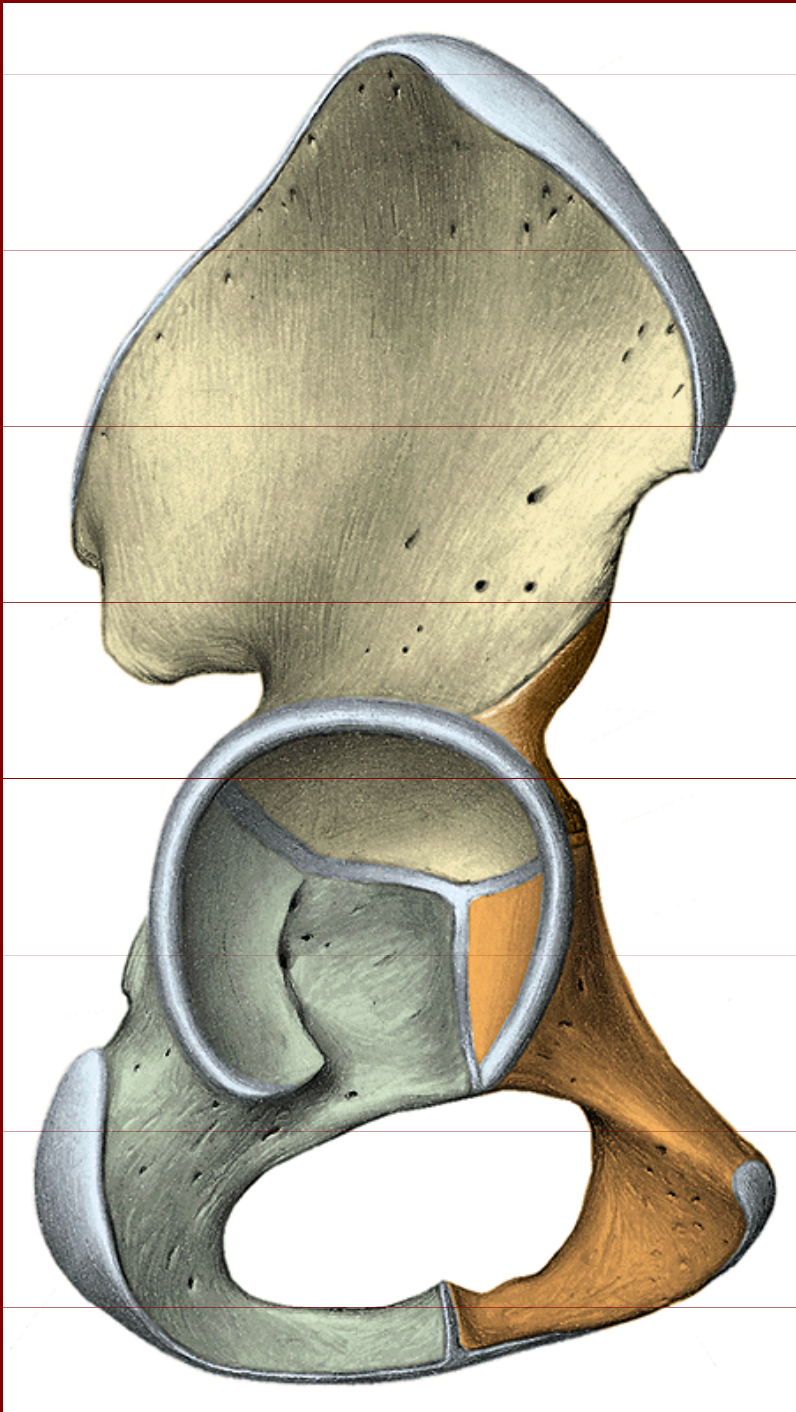
calcaneus, talus, os naviculare,

os cuboideum, ossa cuneiformia

Ossa metatarsi

Ossa digitorum pedis

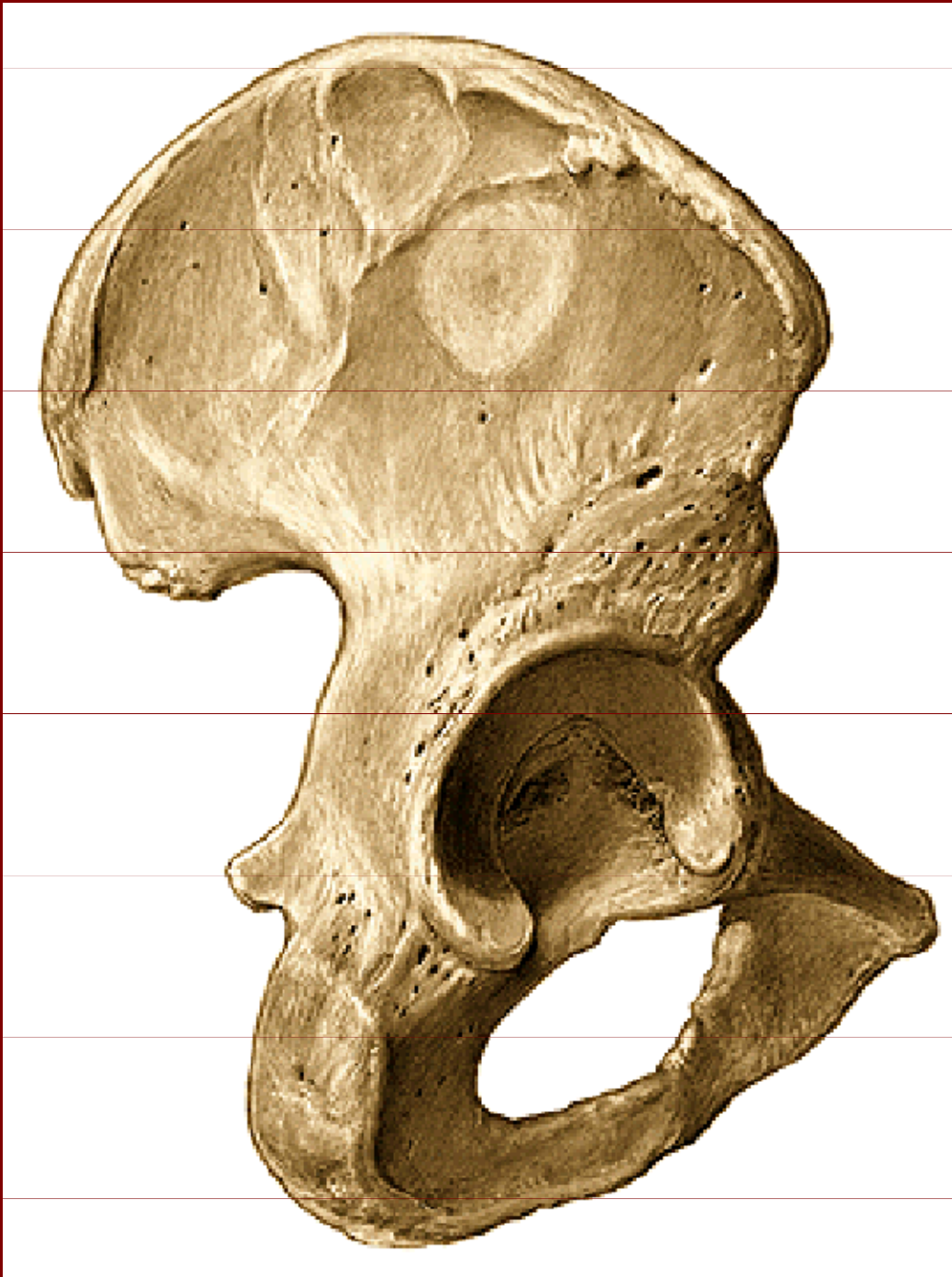Os coxae



Os illium

Os ischii

Os pubis



Os coxae

– facies lateralis

Corpus ossis illi, pubis , ischii

Acetabulum

Ala ossis ilii

Linea glutea anterior, inferior, posterior

Crista iliaca

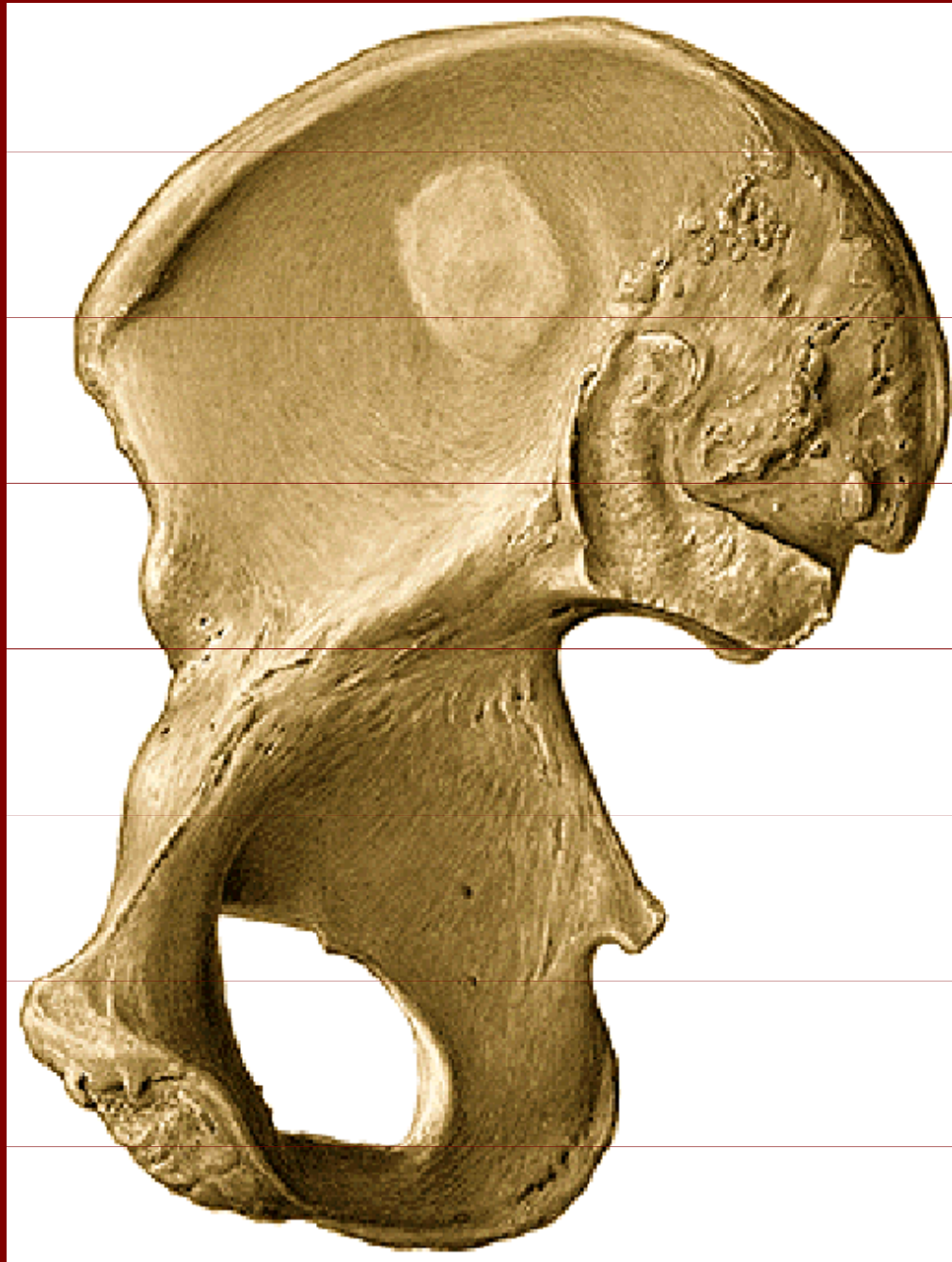Spina iliaca ant.sup., inf.

Spina iliaca post.sup.,inf.

Incisura ischiadica major

Spina ischiadica

Incisura ischiadica minor



Os coxae

- facies medialis

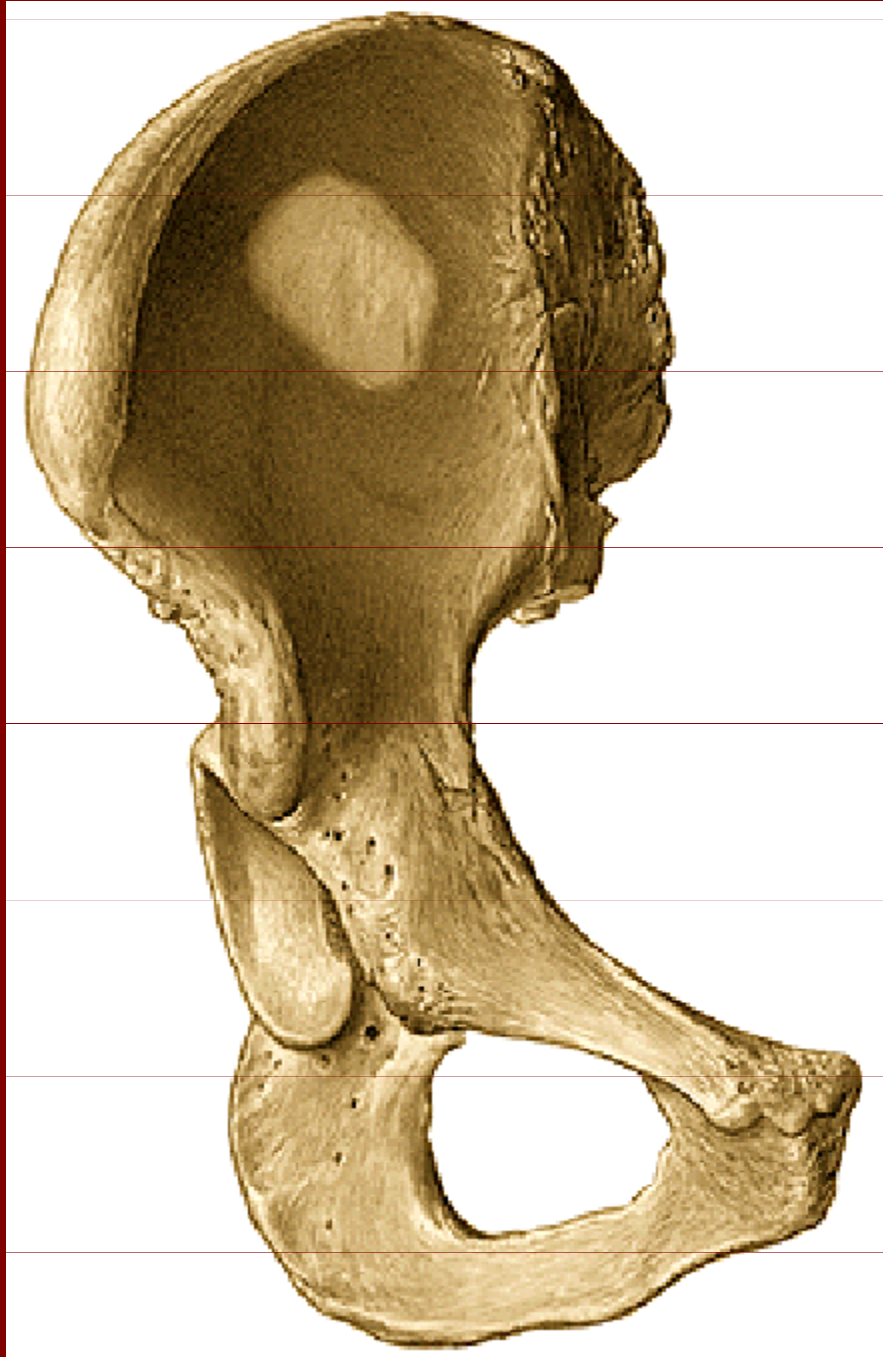
Fossa iliaca

Eminentia arcuata

Pecten ossis pubis

Tuberculum pubicum

Facies symphysealis



Os coxae

Crista iliaca

Labium laterale

Labium mediale

Crista intermedia

Facies auricularis

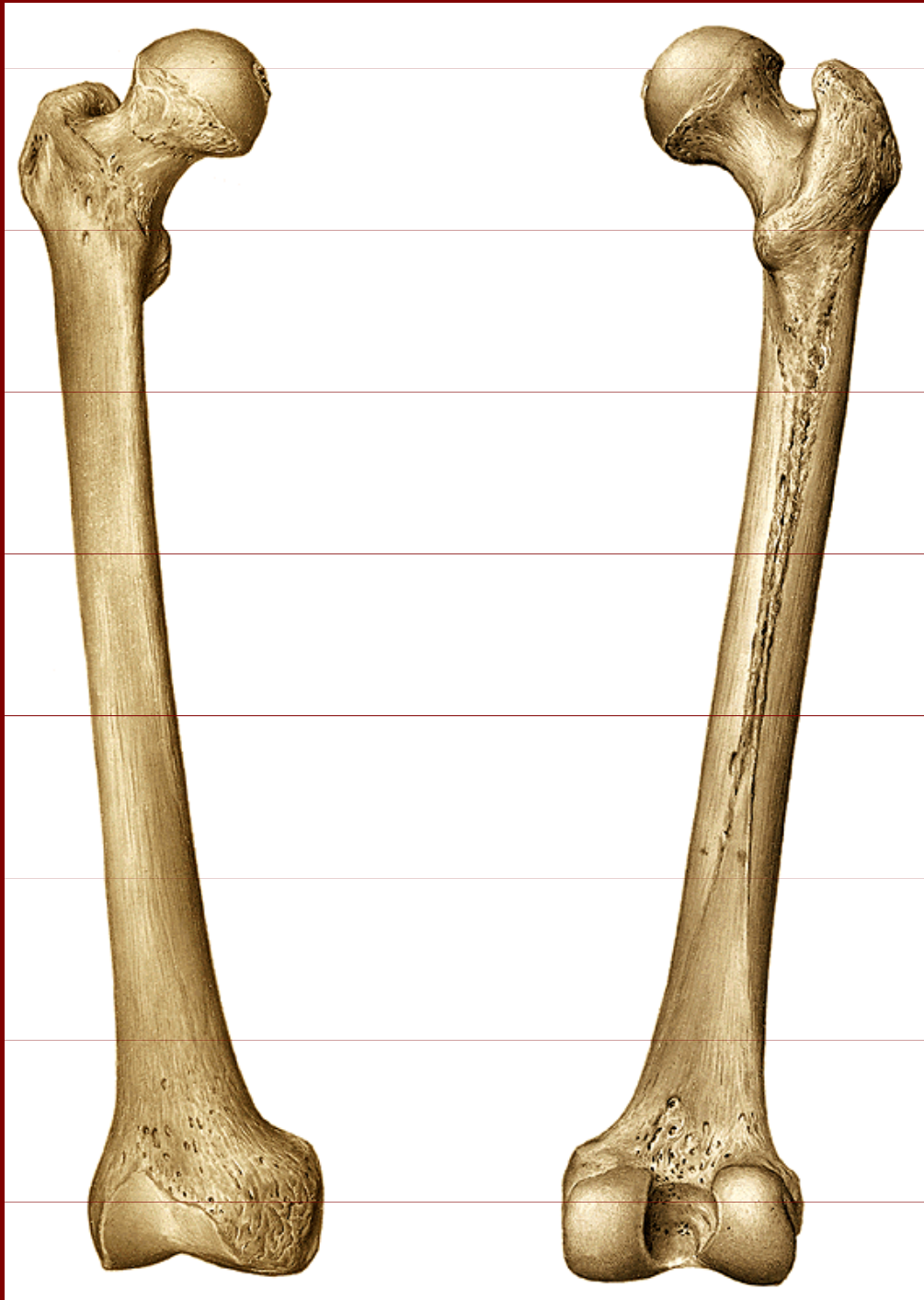
Foramen obturatum

Facies lunata

Ramus superior ossis pubis

Ramus inferior ossis pubis

Tuber ischiadicum



Femur – kost stehenní

Caput femoris

Collum femoris

Trochanter major, minor

Crista intertrochanterica

Linea intertrochanterica

Fossa trochanterica

Linea aspera:

labium mediale, laterale

Planum popliteum

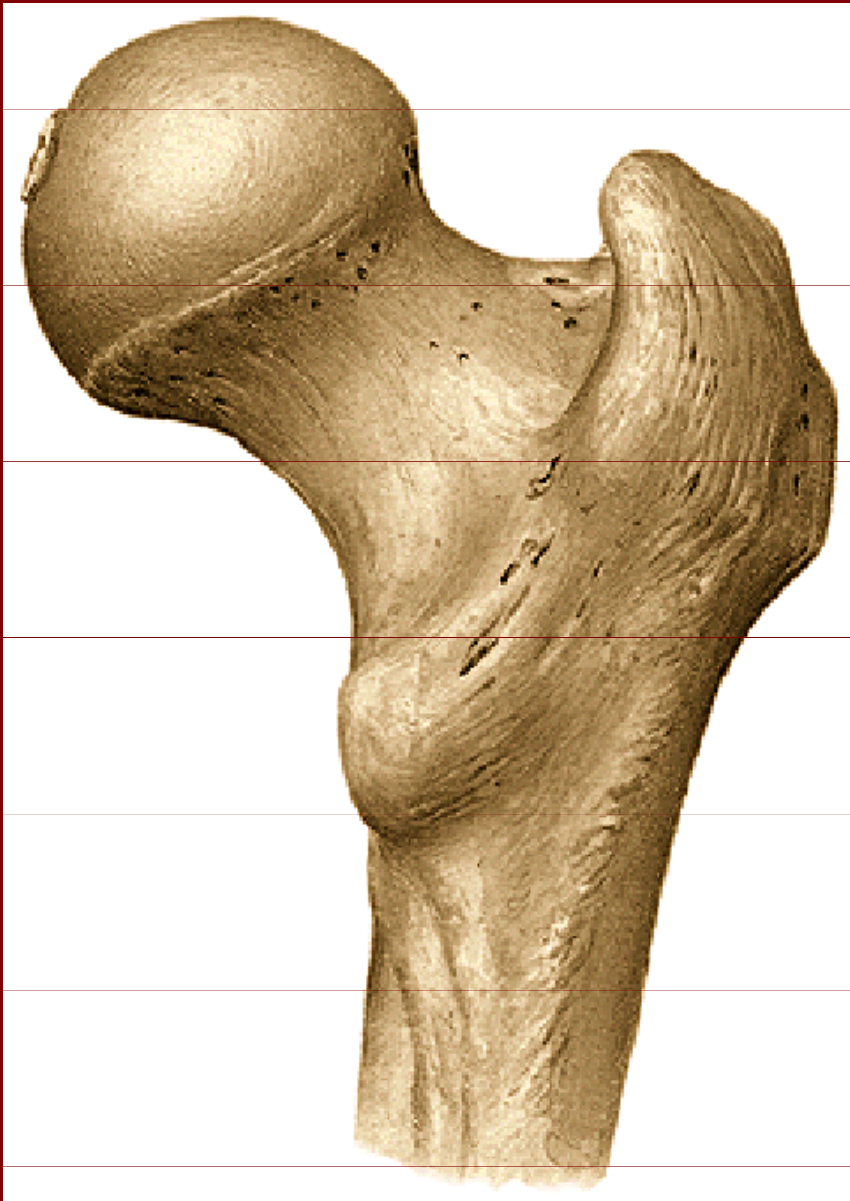Tuberositas glutea

Condylus medialis, lateralis

Fossa intercondylaris

Facies patellaris

Proximální epifýza femuru



Caput femoris

Collum femoris

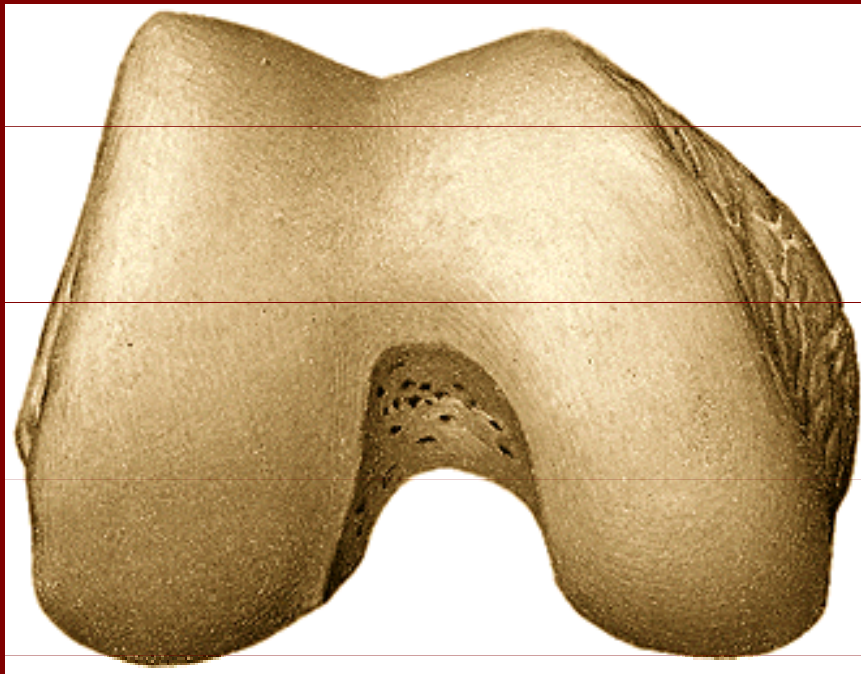
Trochanter major, minor

Crista intertrochanterica

Linea intertrochanterica

Fossa trochanterica

Distální epifýza femuru



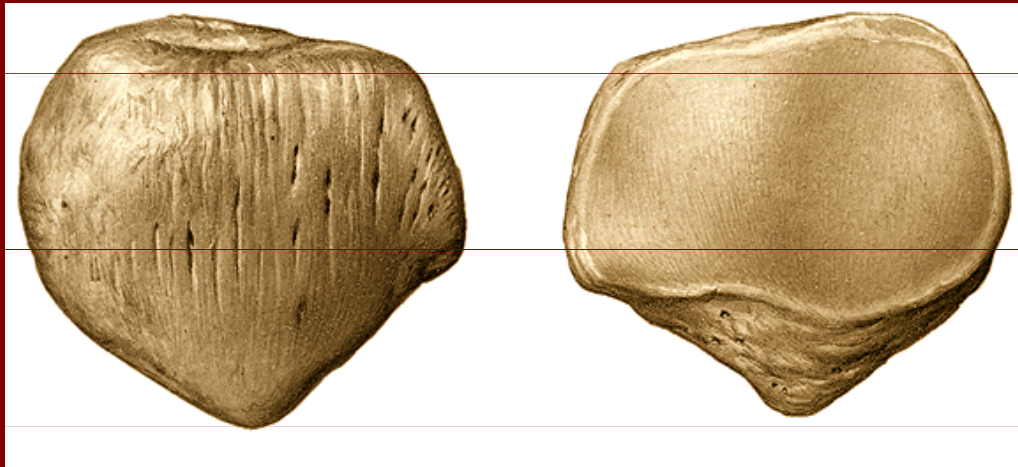
Condylus medialis, lateralis

Fossa intercondylaris

Epicondylus medialis, lateralis

Facies patellaris

Patella - čéška



Basis patellae

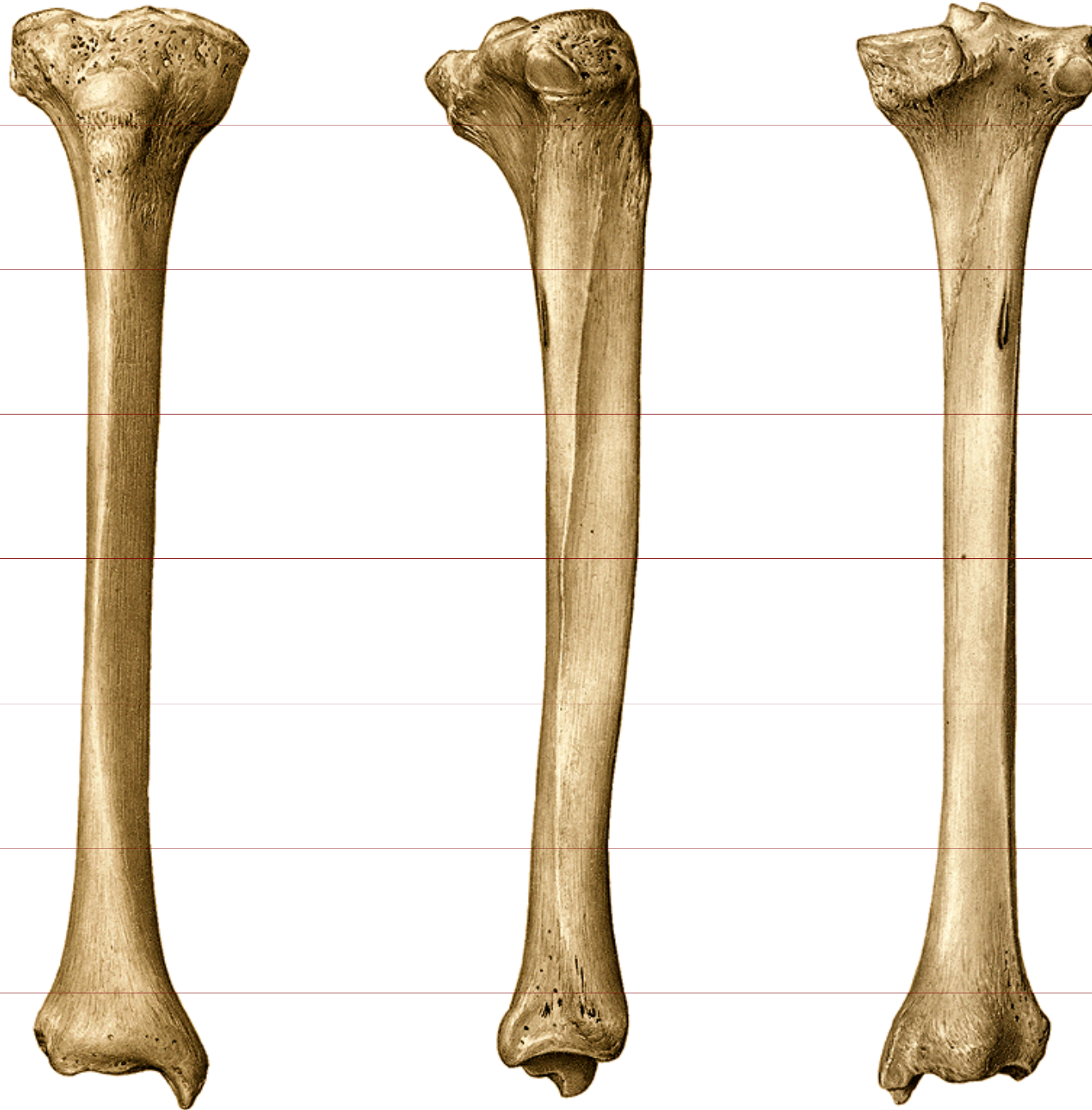
Apex patellae

Facies articularis patellae:

- medialis

- lateralis (širší)

Tibie – kost holenní



Proximální epifýza:

Condylus medialis

Condylus lateralis

Tuberositas tibiae

Facies art.fibularis

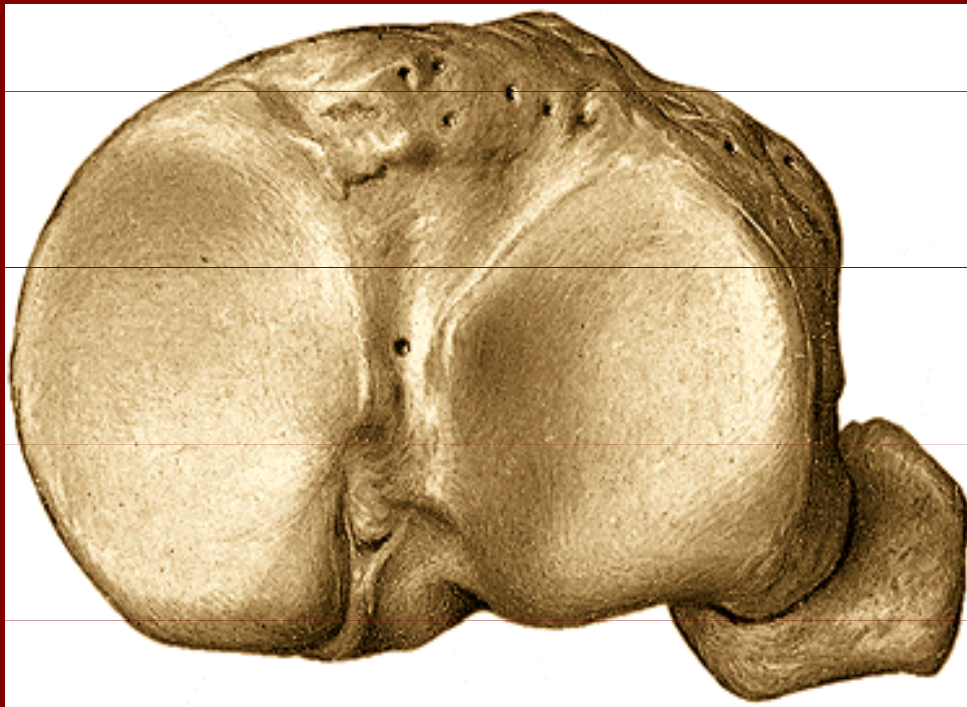
Corpus:

Distální epifýza:

Malleolus tibialis

Facies art.distalis

Proximální epifýza tibiae



Condylus medialis

Condylus lateralis

Eminentia intercondylaris

Tuberculum
intercondylare med., lat.

Tuberositas tibiae

Caput fibulae



Fibula – kost lýtková

Caput fibulae

Facies art.capitis fibulae

Apex capitis fibulae

Corpus fibulae

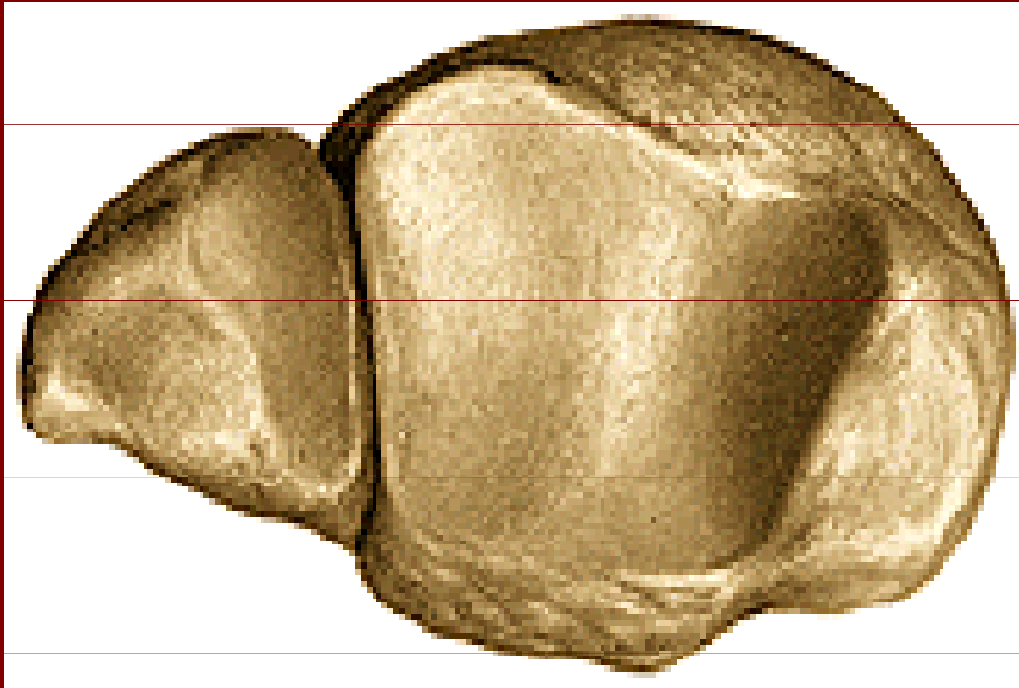
Malleolus lateralis

Sulcus malleoli lateralis

Facies art.malleoli lateralis

Fossa malleoli lateralis

Distální konec tibie a fibuly

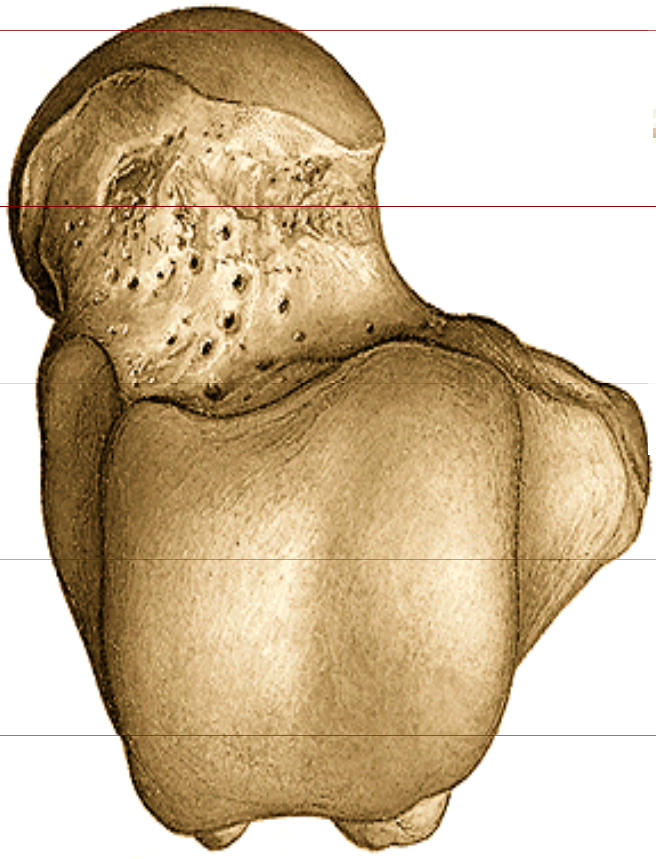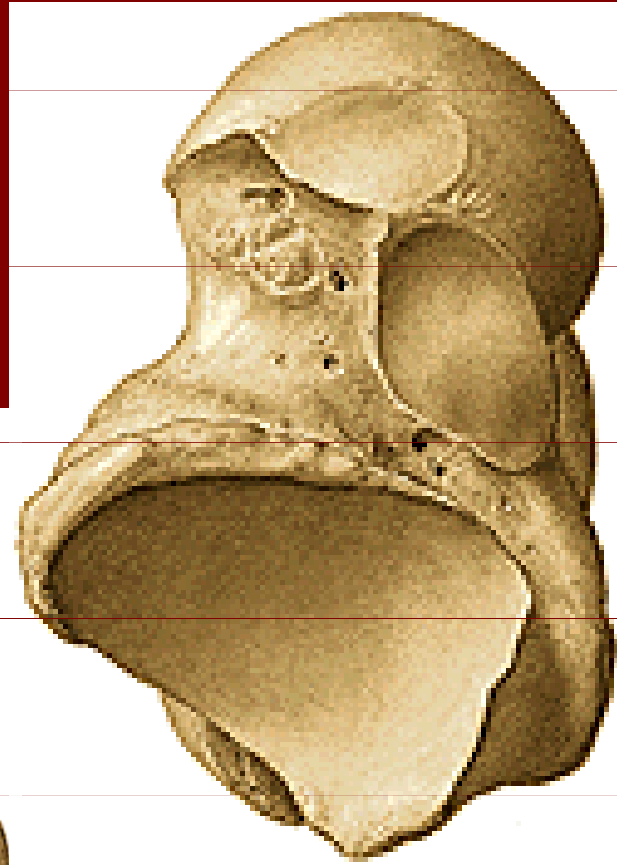


Malleolus medialis

Malleolus lateralis

Facies art.distalis

Talus – kost hlezenná



Corpus tali

Caput tali

Collum tali

Trochlea tali

Facies malleolaris med.

Facies malleolaris lat.

Facies articularis calcanea
post., med., ant.

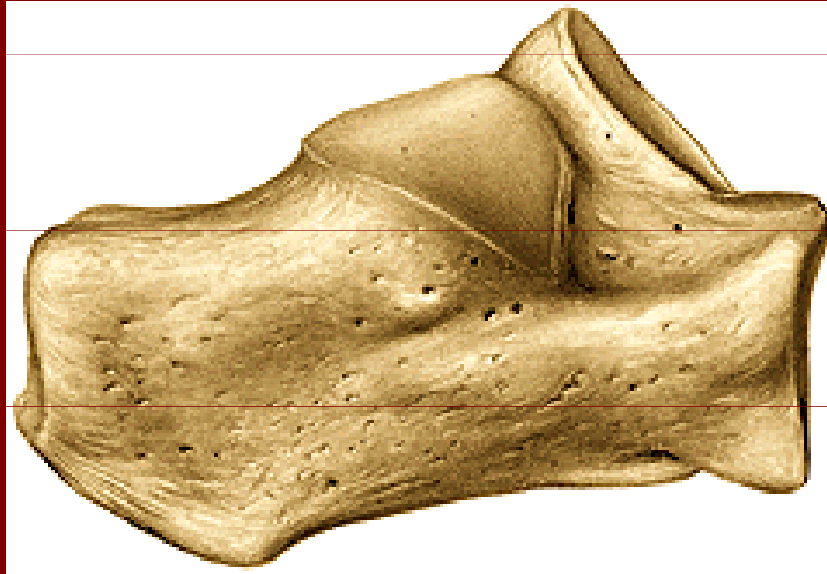
Processus posterior

Sulcus tendinis m. flexoris
hallucis longi

Processus lateralis

Facies articularis navicularis

Calcaneus – kost patní



Tuber calcanei

Processus med., lat. tuberis calcanei

Facies art. cuboidea

Facies talaris post., med., ant.

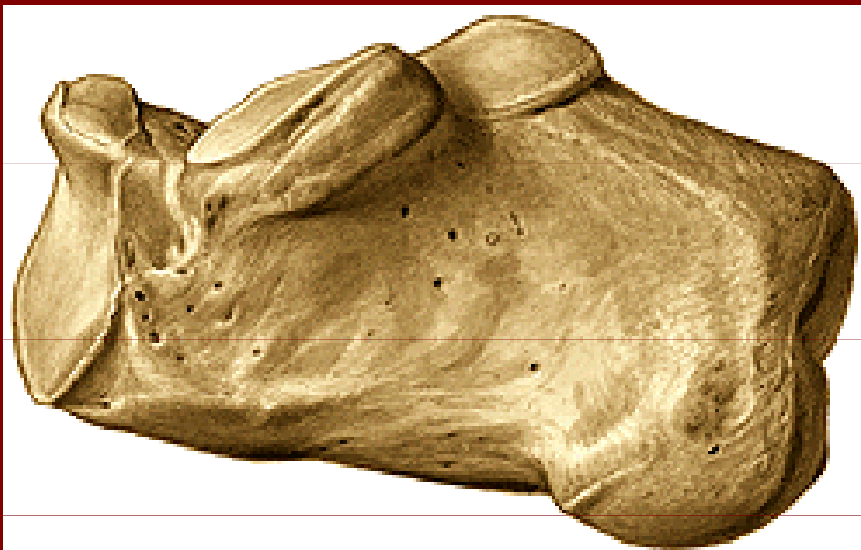Sulcus calcanei

Sustentaculum tali

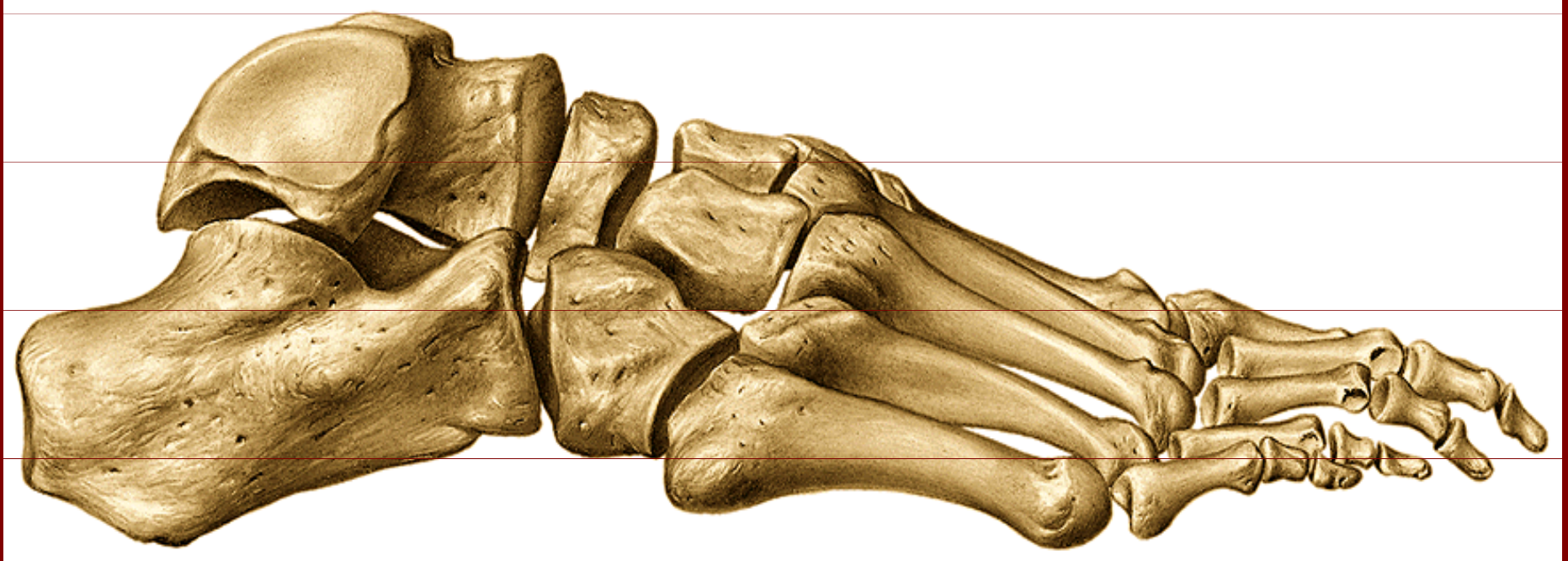Sulcus tendinis m. flexoris hallucis longi

Trochlea peronealis

Sulcus tendinis m. peronei longi



Ossa pedis



Calcaneus, talus, os naviculare, os cuboideum,
ossa cuneiformia, ossa metatarsalia, phalanges

Poděkování

Pro tuto přednášku byly použity obrázky
z Atlas of Human Anatomy od Sobotty