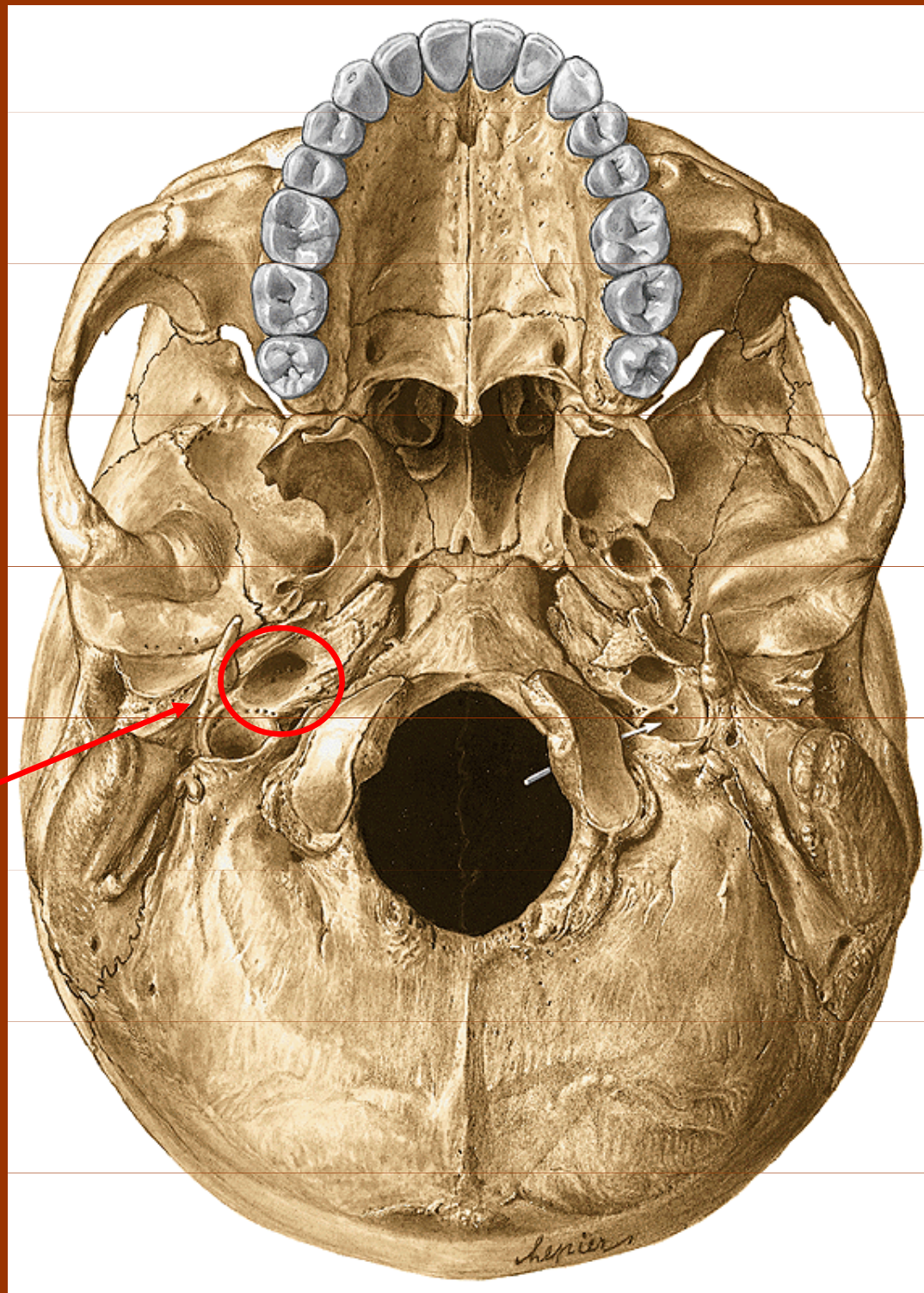


# **Kanáalky v os temporale**

# Kanáčky v os temporale

1. Canalis caroticus
2. Canaliculi caroticotympanici
3. Canalis nervi facialis
4. Canaliculus chordae tympani
5. Canaliculus mastoideus
6. Canaliculus tympanicus
7. Canalis musculotubarius
8. Canaliculus cochleae
9. Canaliculus vestibuli

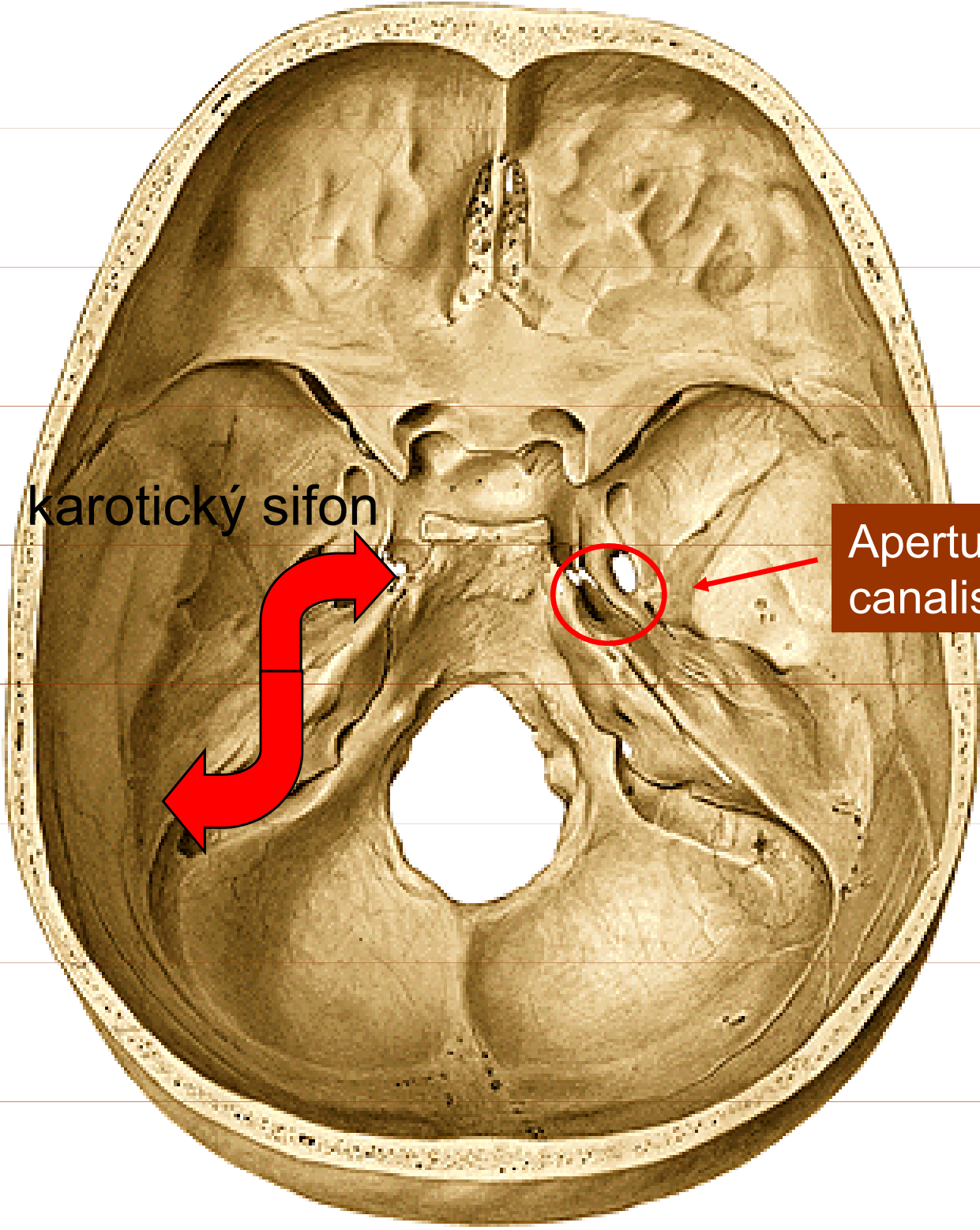
1., 2.



Apertura externa  
canalis carotici

+ canaliculi  
caroticotympanici  
(2 až 3, vedou do  
CT)

1.



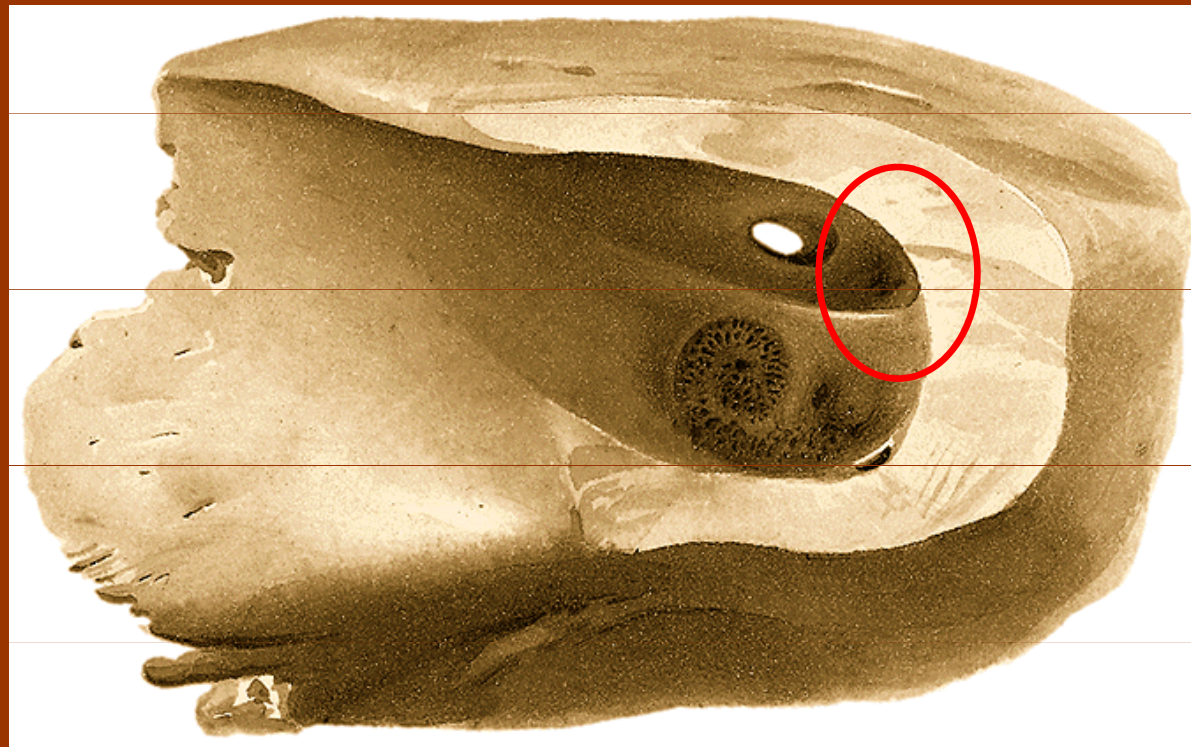
karotický sifon

Apertura interna  
canalis carotici



3.

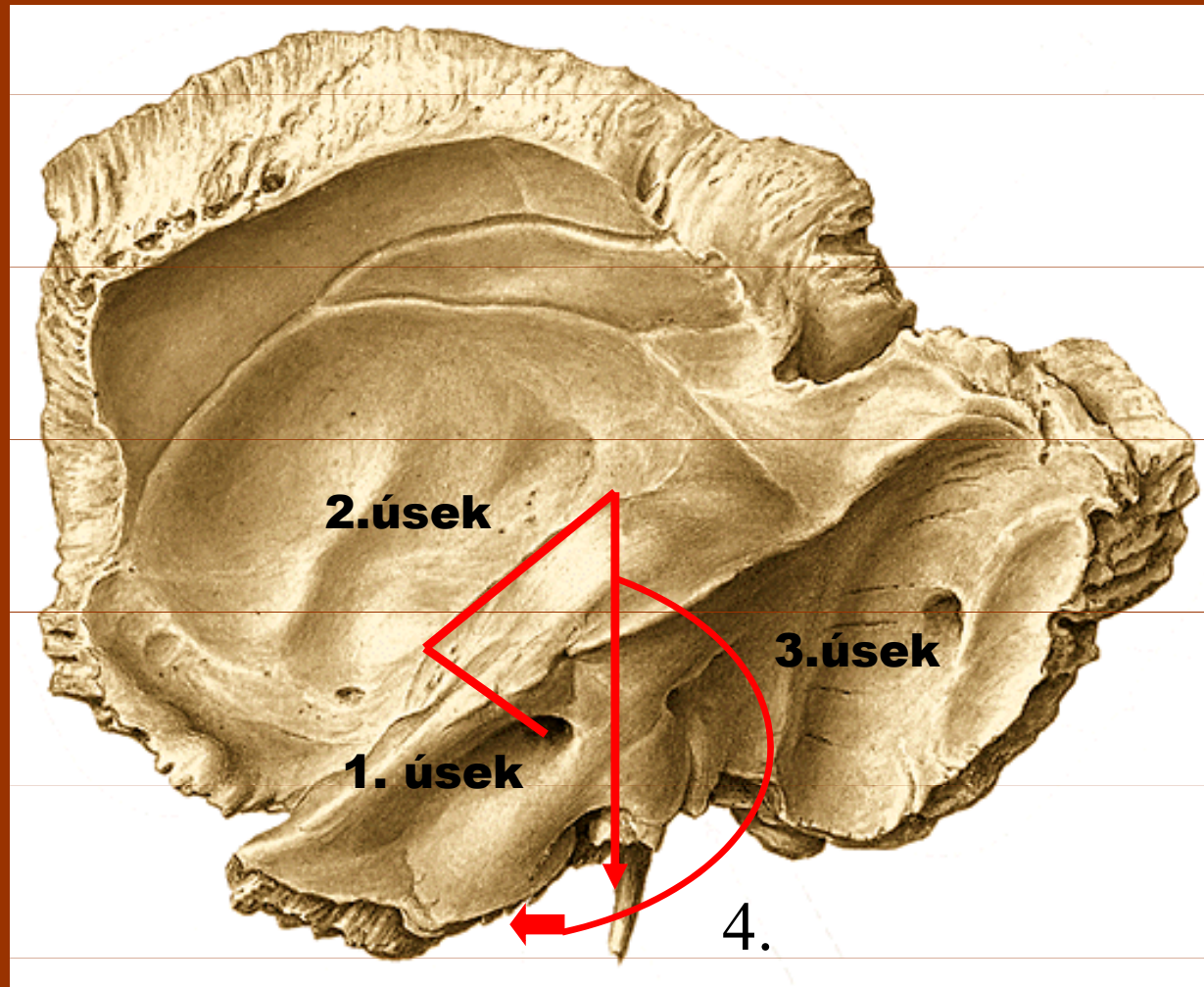
## Porus acusticus internus



Area nervi facialis (vstup)

**3.**

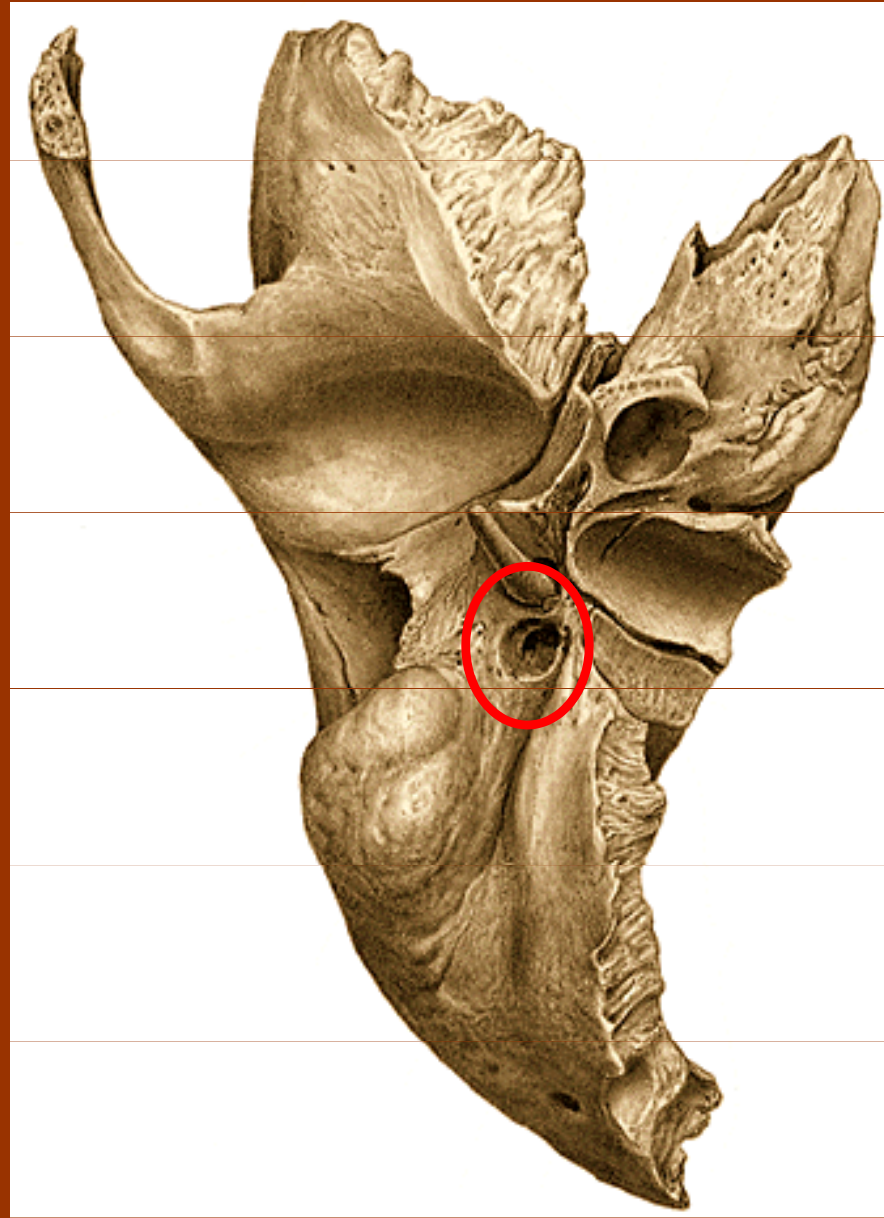
## Canalis nervi facialis



+ 4. Canaliculus chordae tympani ze 3.úseku N.VII. do CT

a pak do jazyka...

**3.**



**Foramen  
stylomastoideum**

# 3.

## 1.úsek :

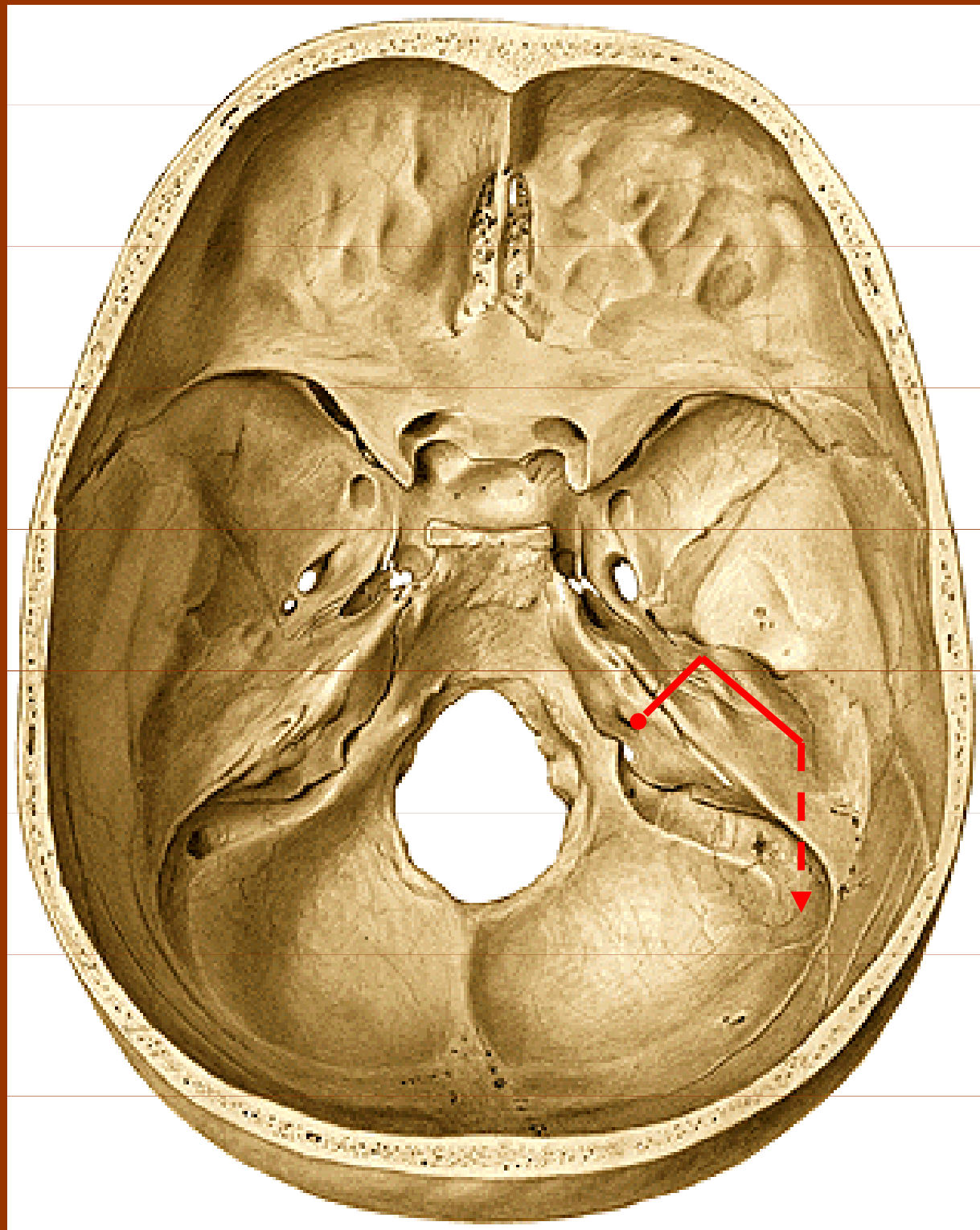
Ventrokraniální kvadrant fundus meatus acusticus internus až k hiatus nervi petrosi majoris

## 2.úsek:

Hiatus nervi petrosi majoris až tegmen tympani

## 3.úsek

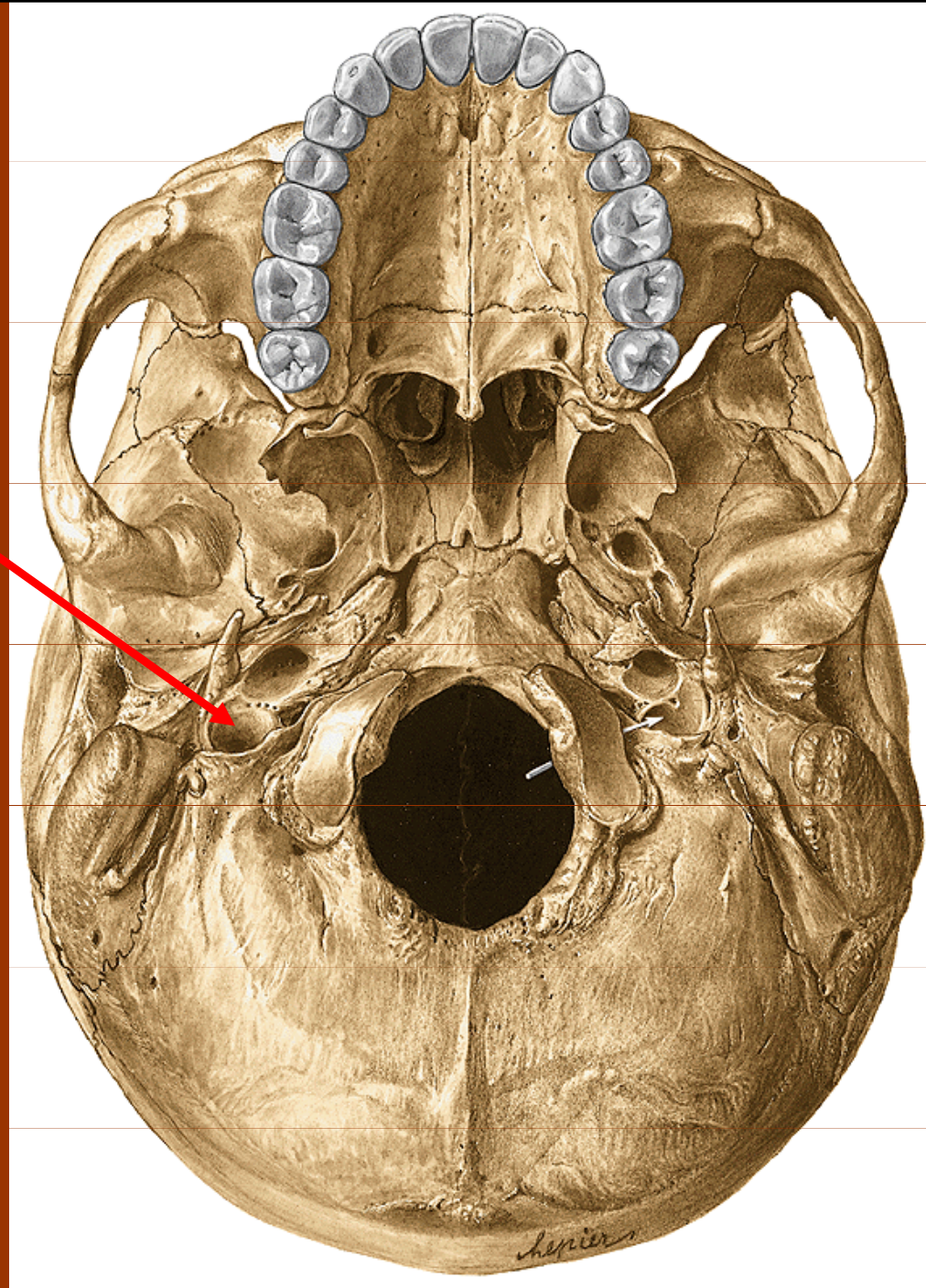
Tegmen tympani až k foramen stylomastoideum





5.

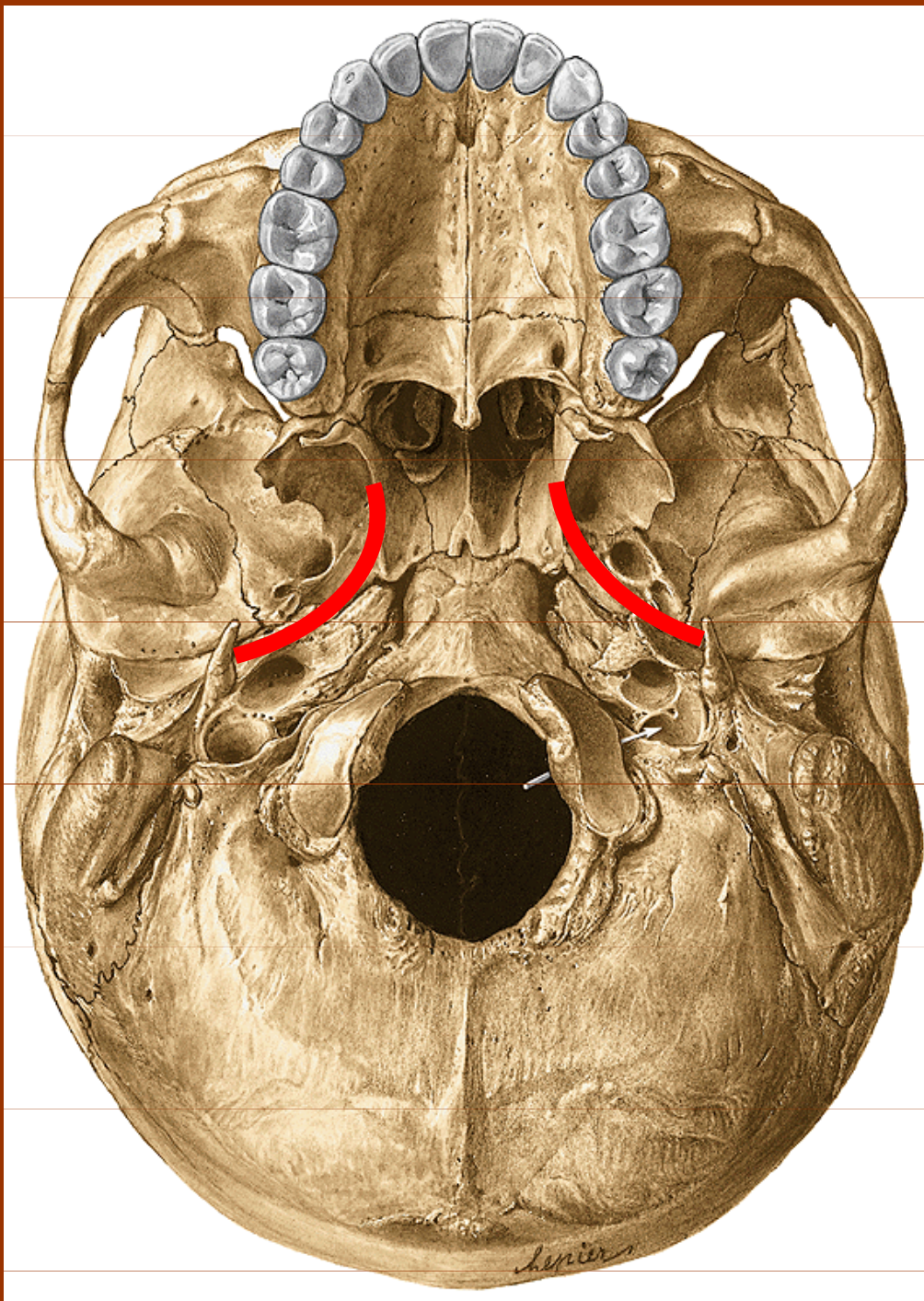
Fossa  
jugularis  
(n. IX., X., XI).



Canaliculus mastoideus – r. auricularis nervi vagi



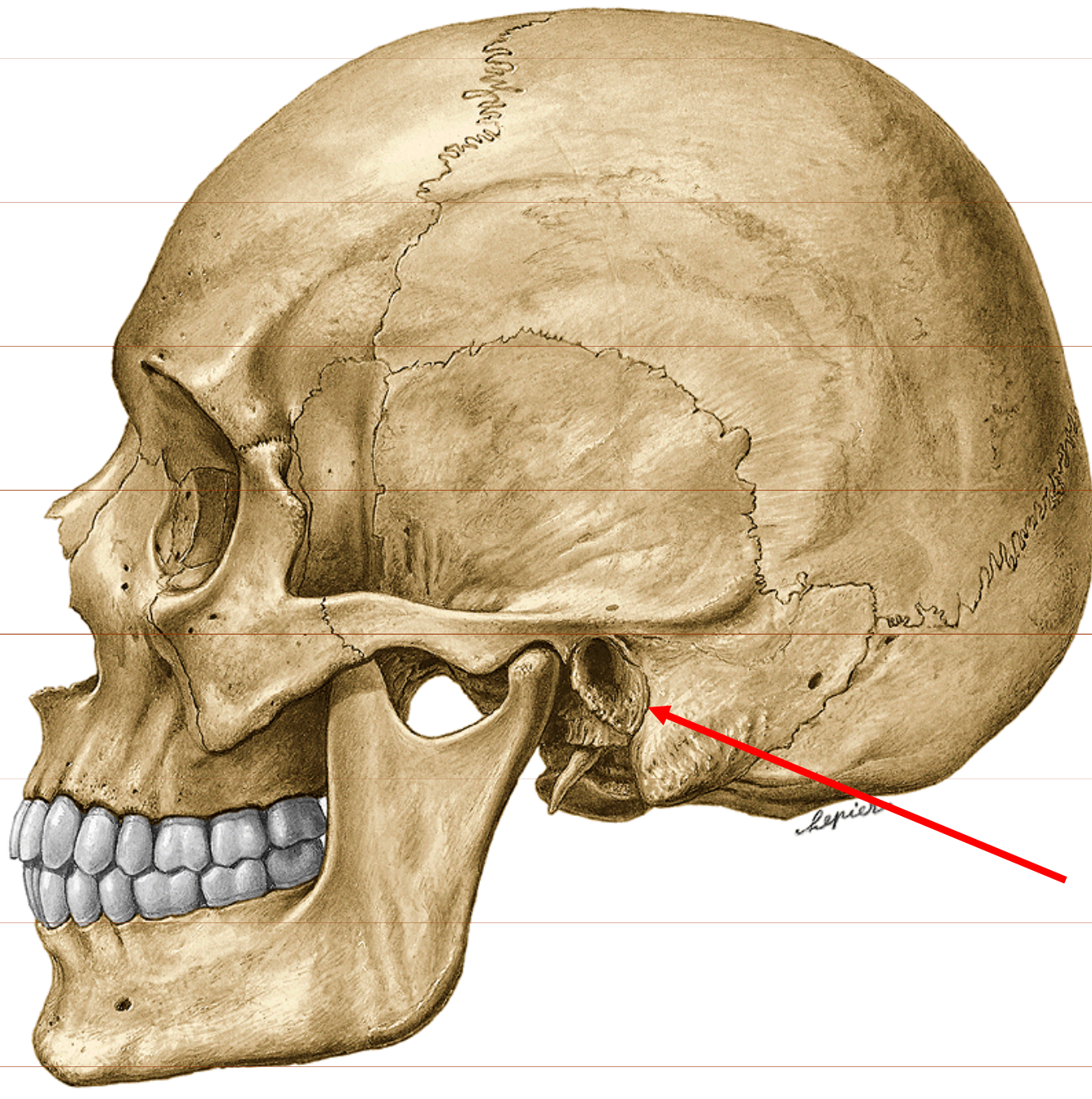
7.



Canalis musculotubarius (m.tensor tympani + tuba auditiva)



**5.**



Fissura  
tympanomastoidea



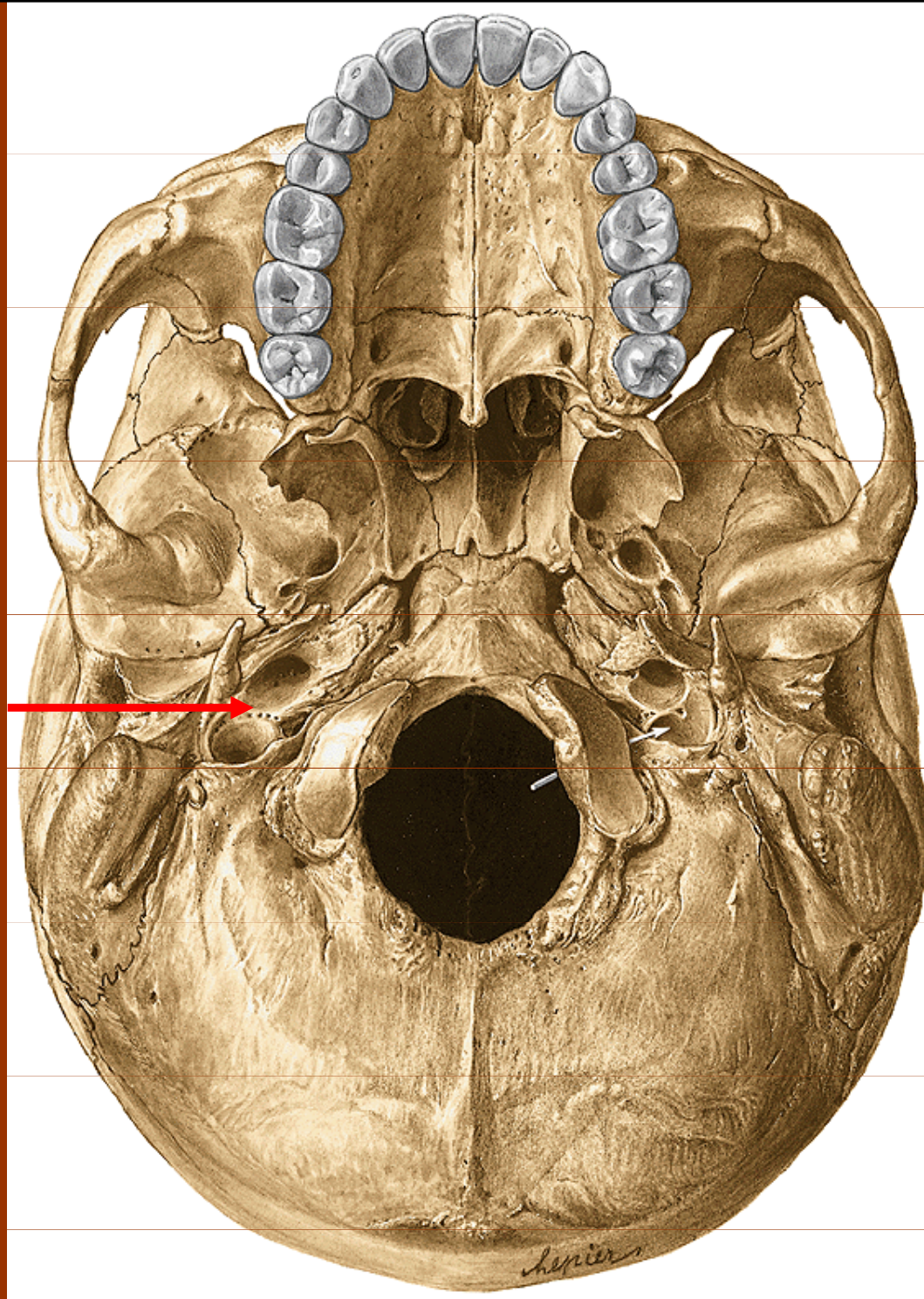
**6.**

**Canalis  
caroticus**

**Foramen  
jugulare**

**Fossula petrosa**

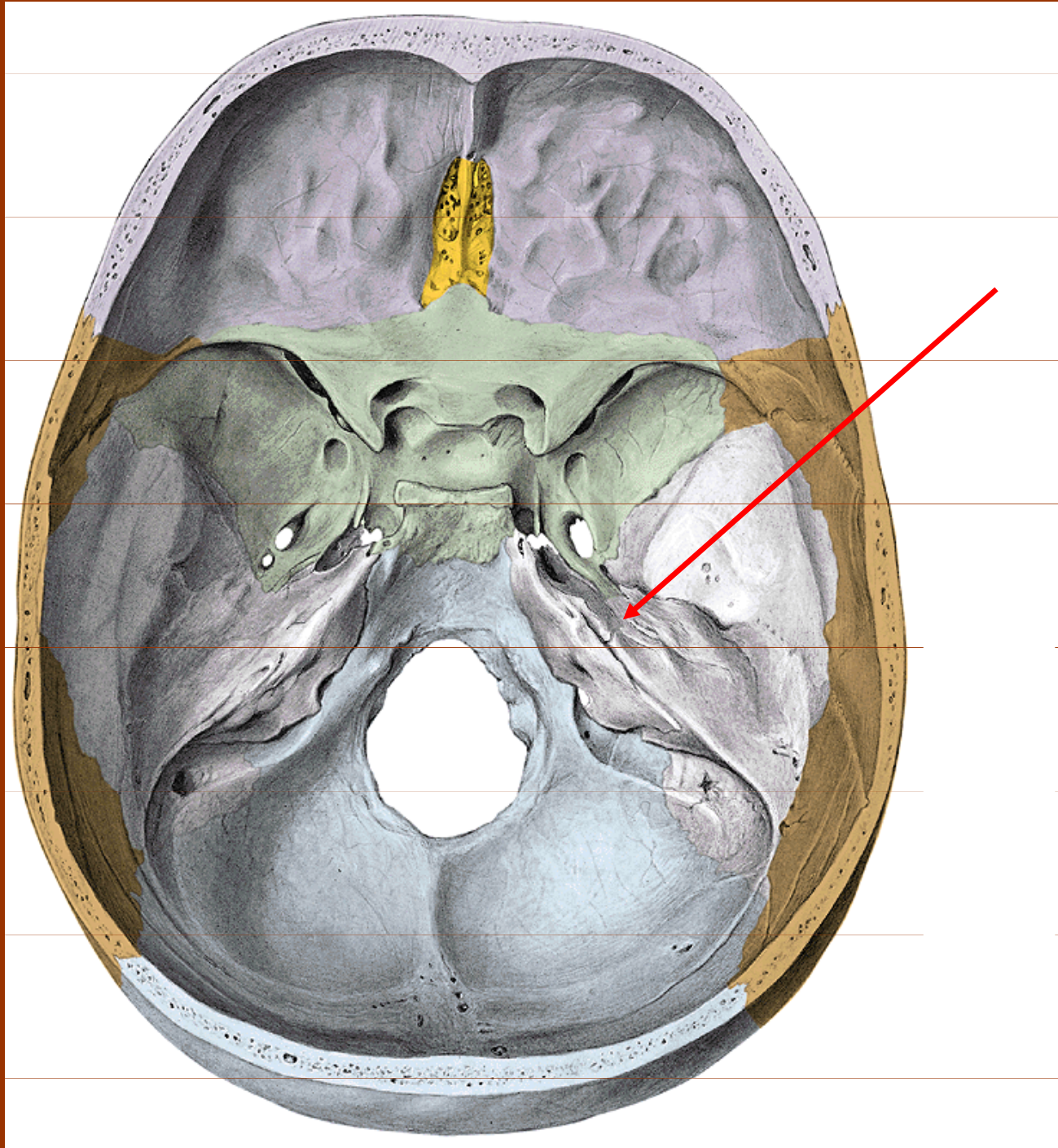
**apertura  
ext.canaliculi  
tympanici**



**Canaliculus tympanicus – nervus tympanicus**



6.



Hiatus  
nervi  
petrosi  
minoris

apertura  
interna  
canalis  
tympanici



**8. + 9.**

Apertura externa  
canaliculi cochleae

Apertura externa  
aquaeductus vestibuli

