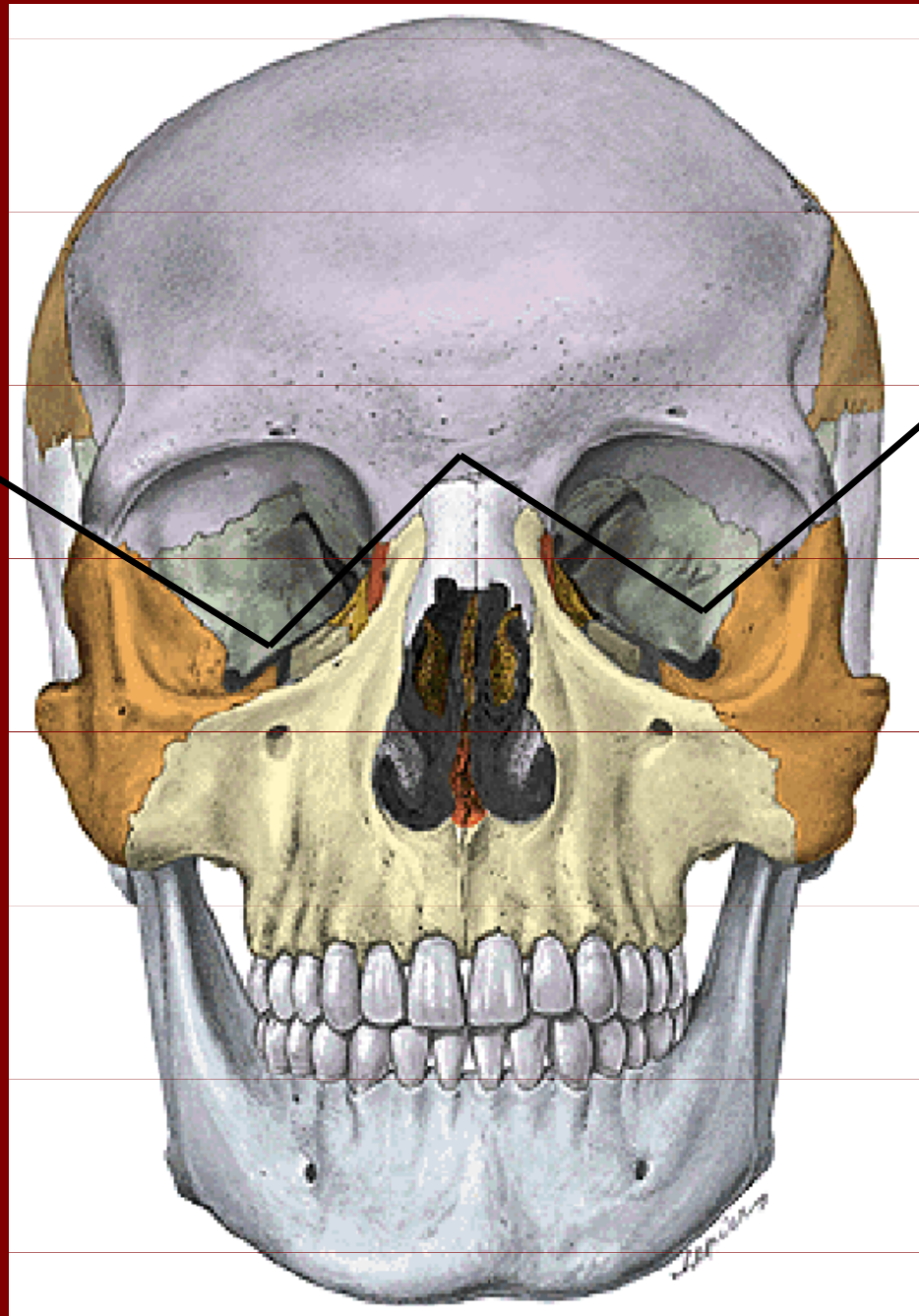
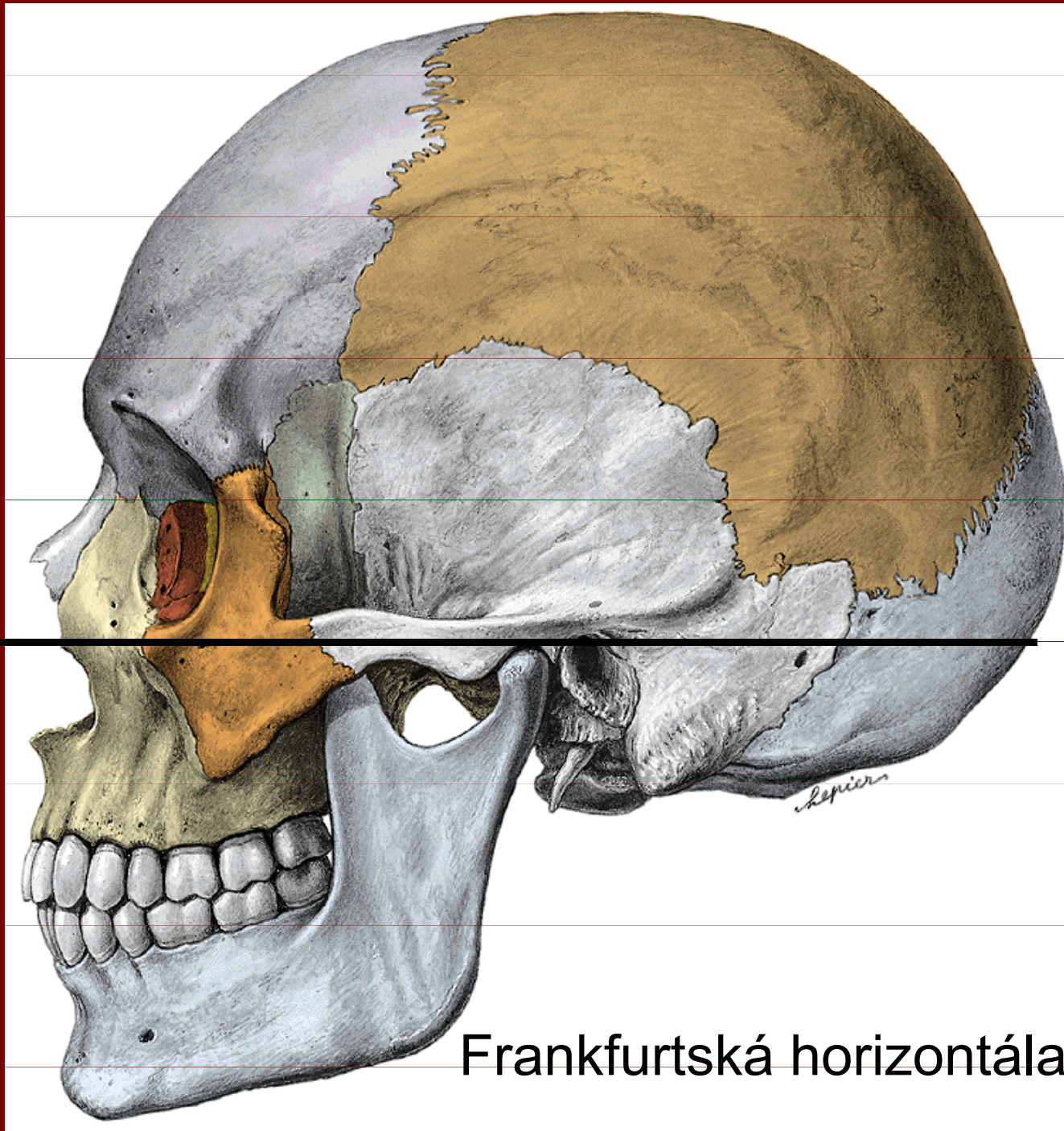


# **ANATOMIE**

Kosti splanchnokrania

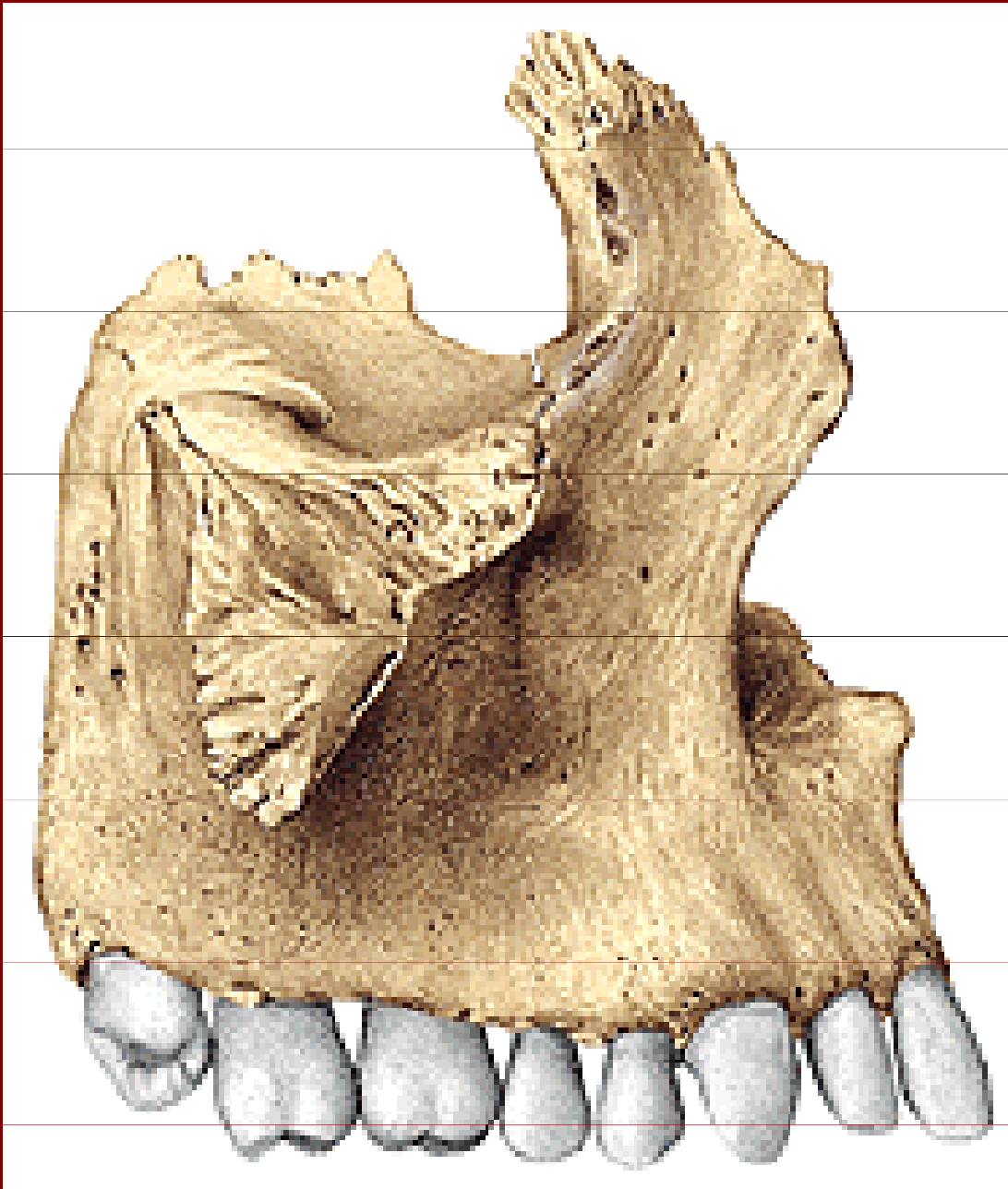
# Kosti splanchnocrania





Frankfurtská horizontála

# Maxilla



## Corpus

## Facies:

anterior, nasalis,  
orbitalis, infratemporalis  
(tuber maxillae)

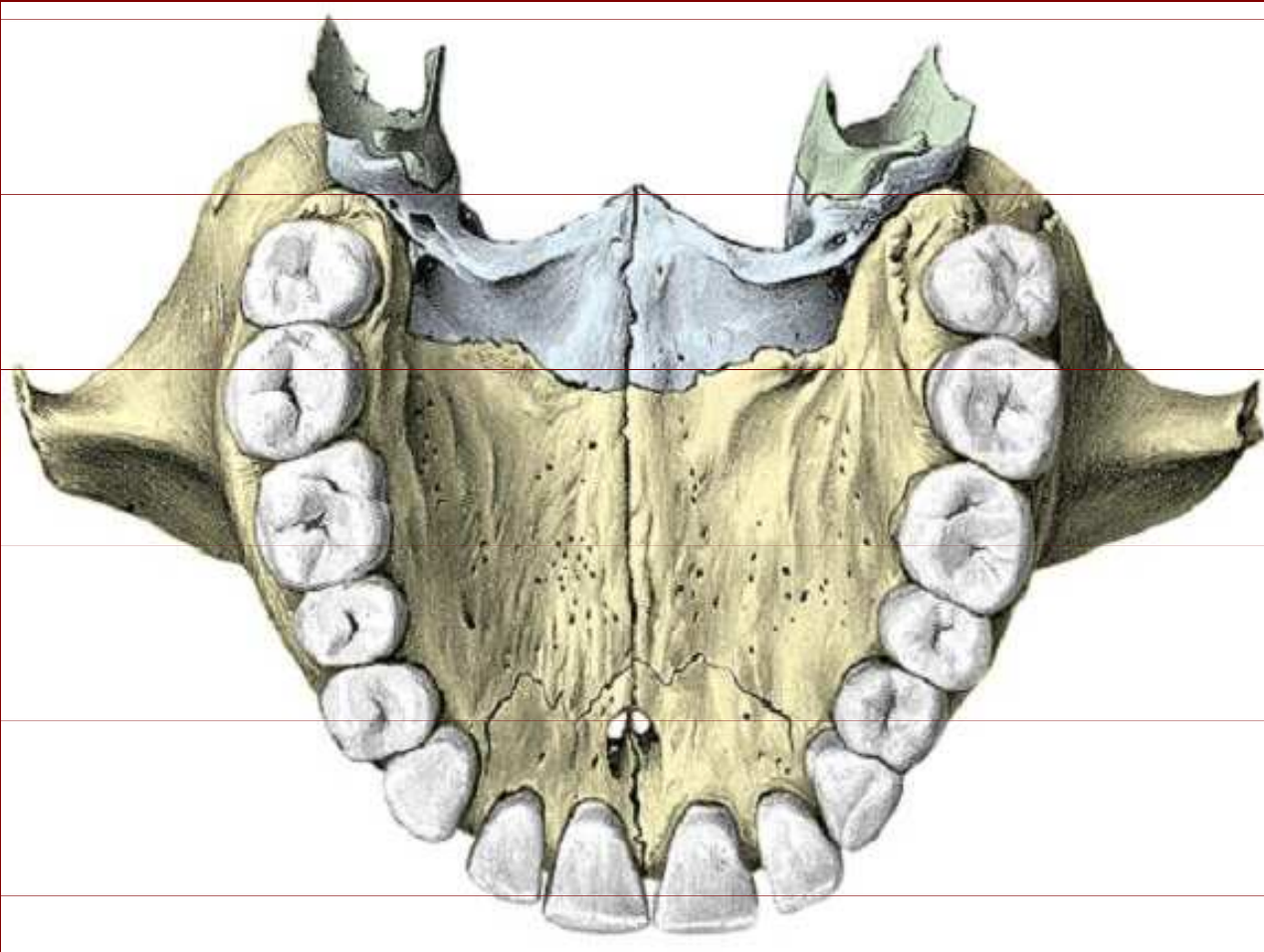
## Processus:

frontalis, zygomaticus,  
alveolaris, palatinus

## Praemaxilla



# Maxilla



Processus palatinus:

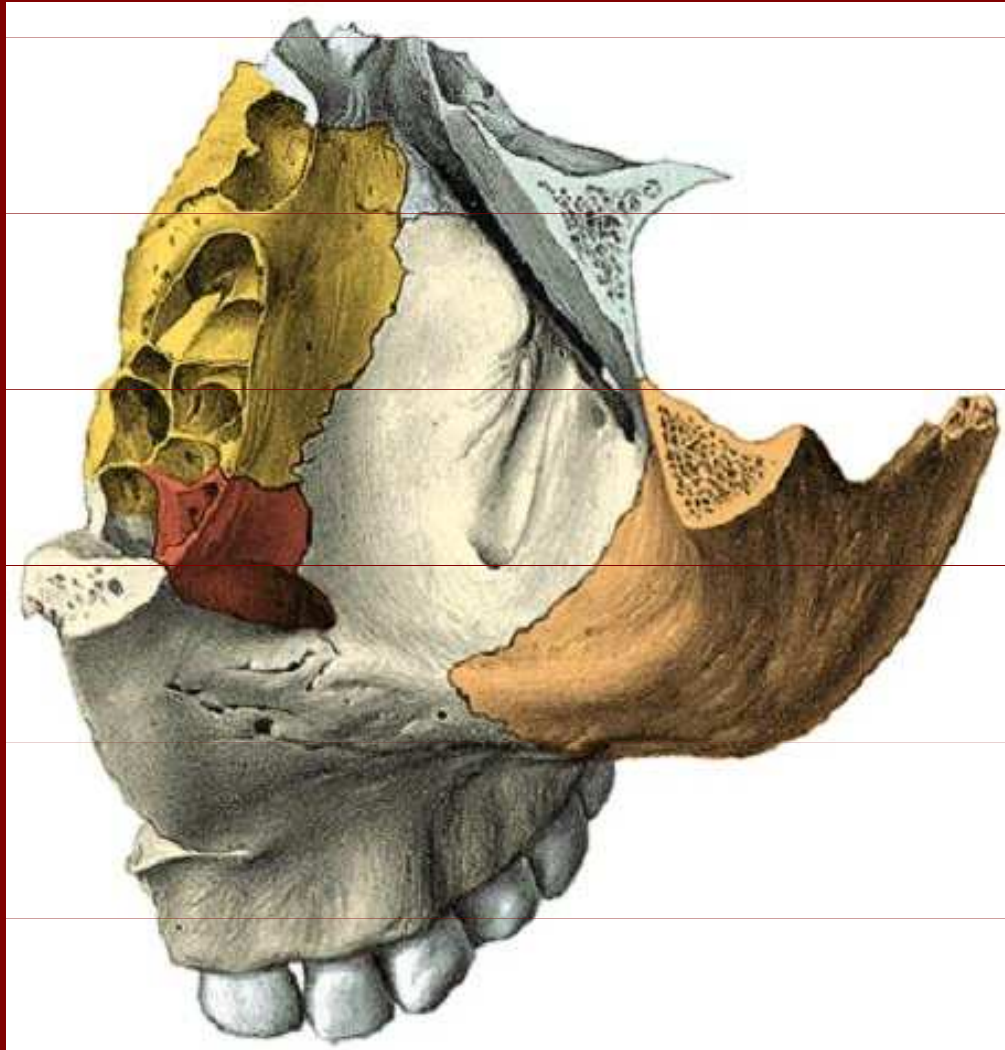
Processus  
zygomaticus

Processus alveolaris

Praemaxilla

Foramen incisivum

# Maxilla



Facies orbitalis:

Sulcus infraorbitalis

Canalis infraorbitalis

Os lacrimale

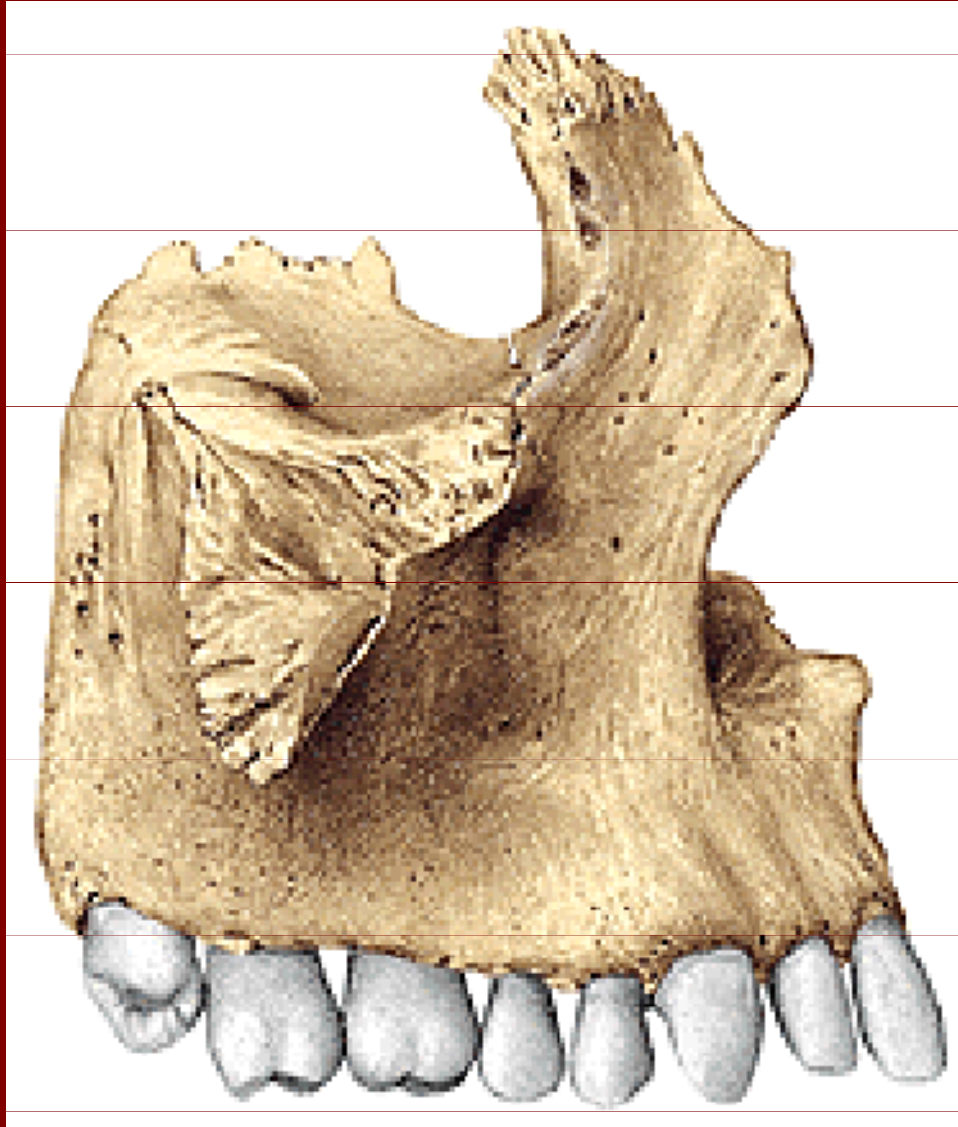
Celulae ethmoidales

Facies anterior =  
fossa canina

Juga alveolaria

Incisura nasalis

# Maxilla



Facies anterior:

Processus frontalis

Incisura nasalis

Processus alveolaris

Juga alveolaria

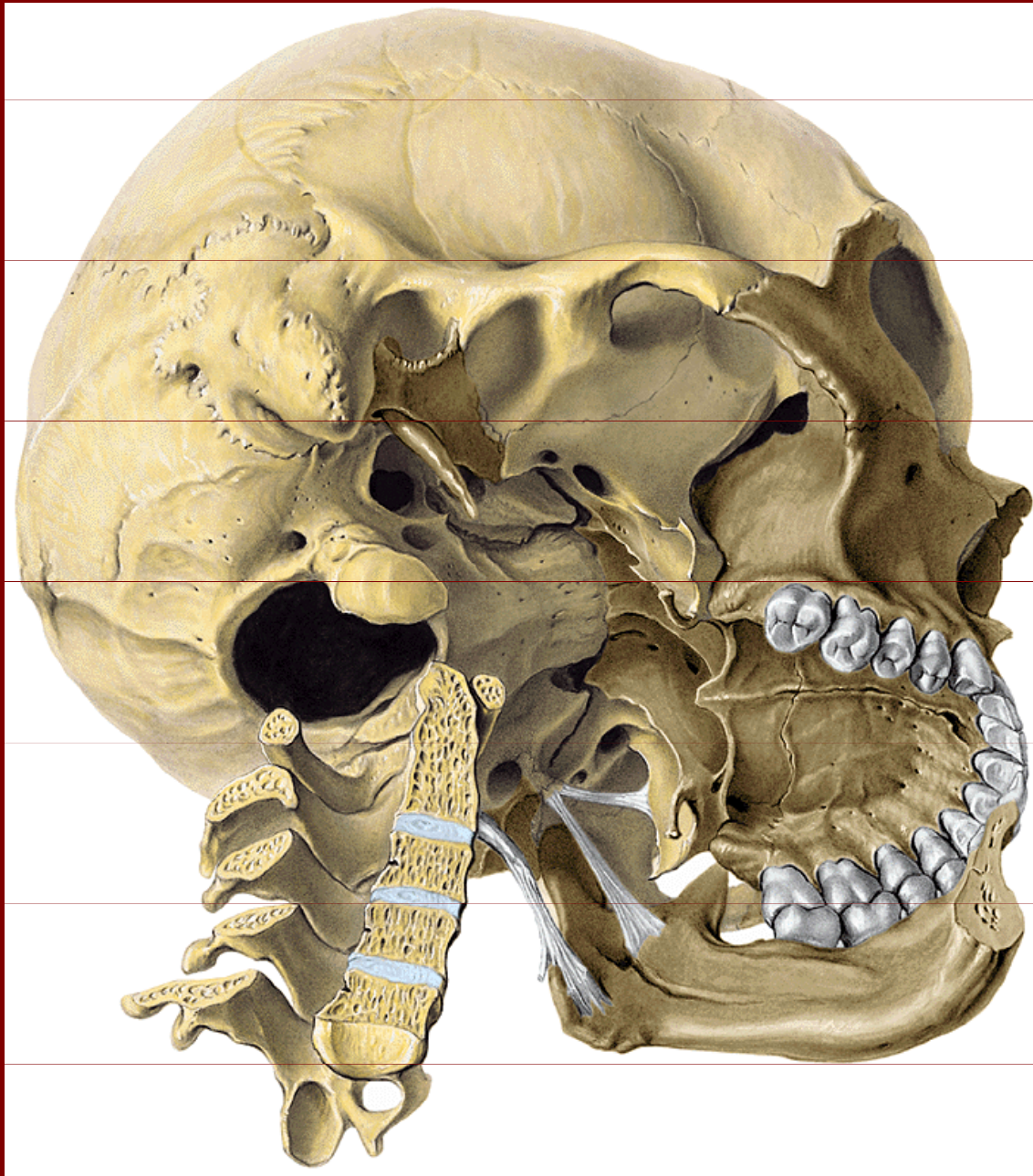
Alveoli dentales

Fossa canina

Processus zygomaticus



# Maxilla



Facies infratemporalis  
(tuber maxillae):

Foramina alveolaria  
posteriora superiora

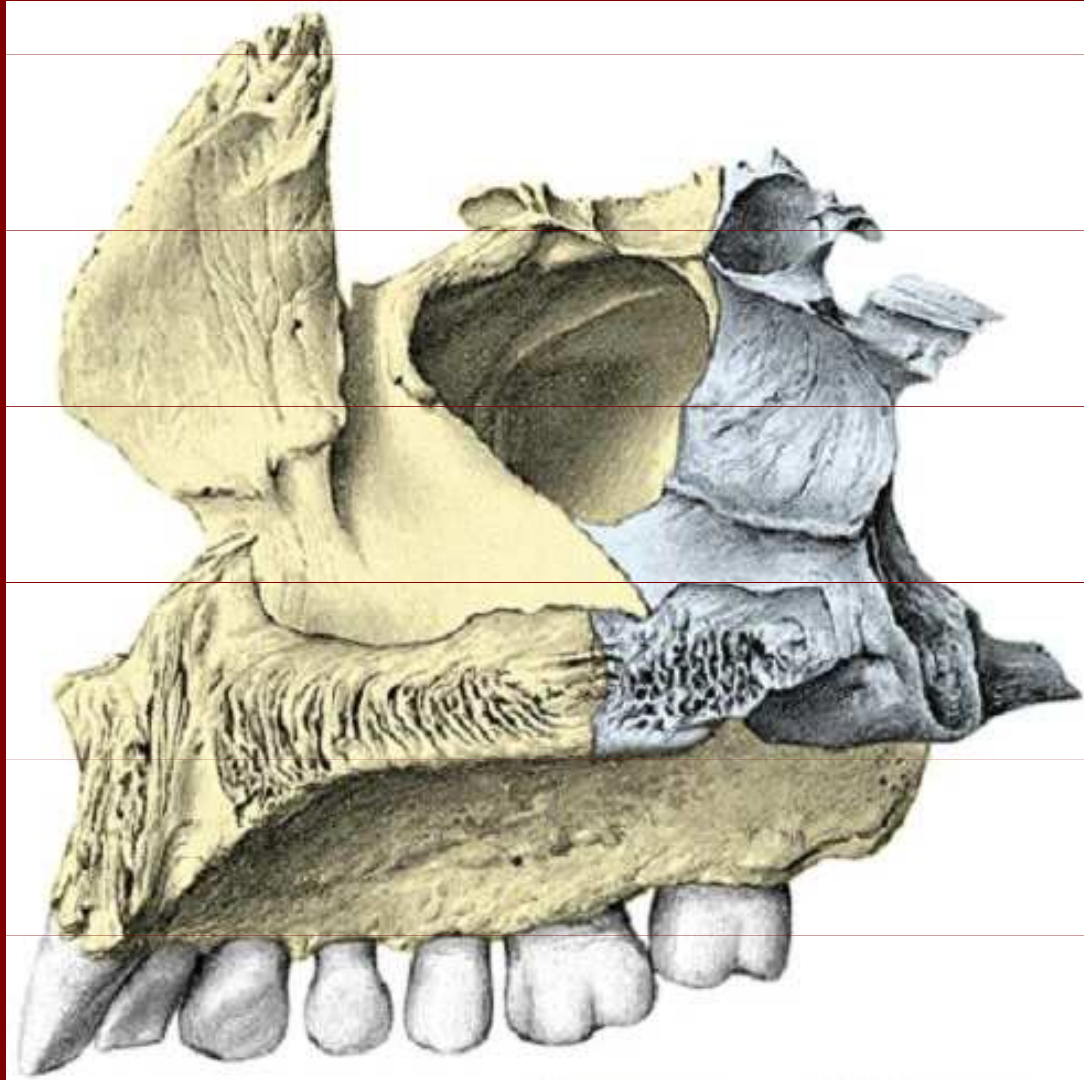
Crista infrazygomica

Fossa canina

Foramen infraorbitale



# Maxilla



Facies nasalis:

Antrum Highmori

Processus frontalis

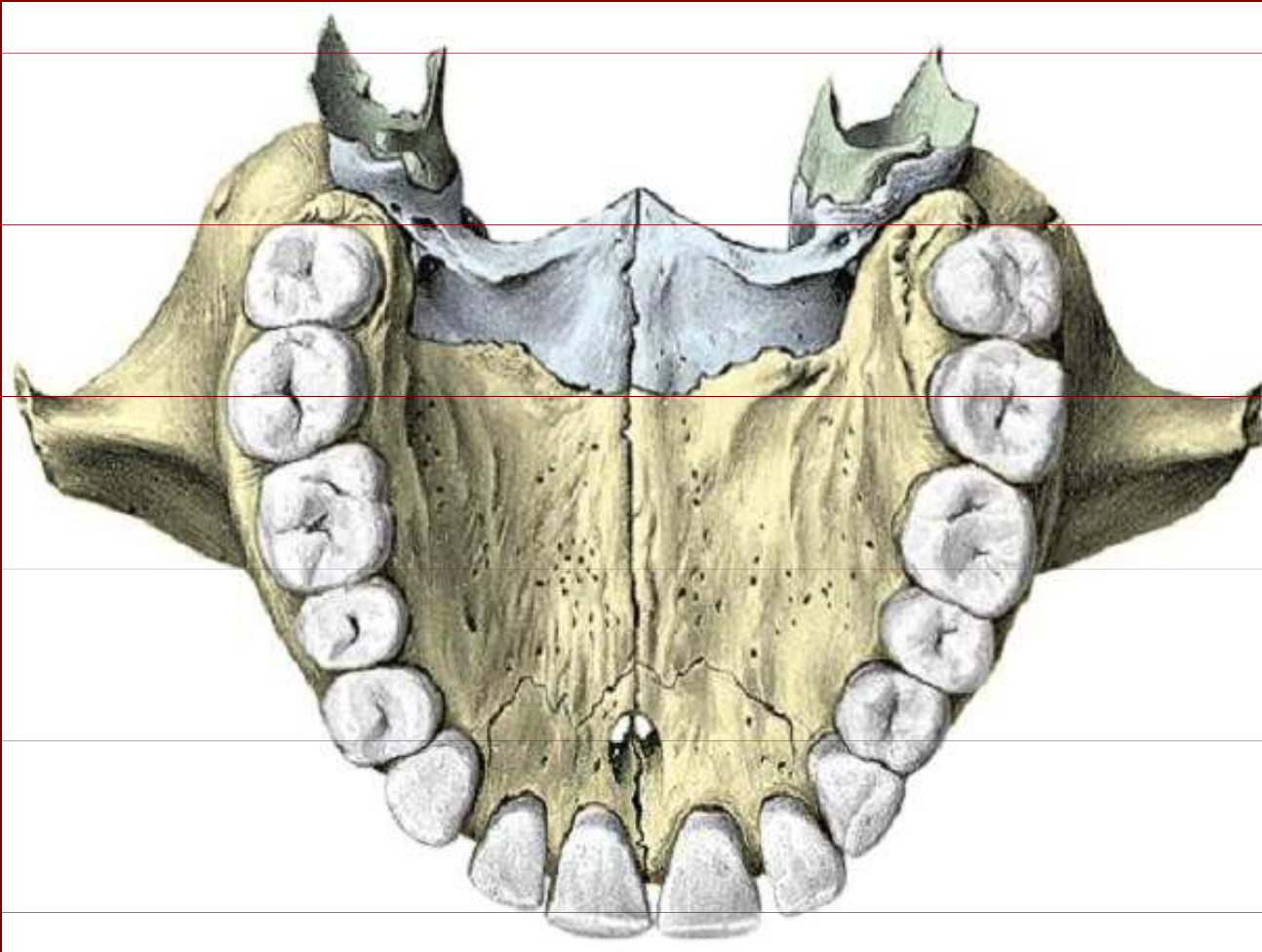
Crista ethmoidalis

Crista conchalis

Spina nasalis anterior

Processus alveolaris

# Maxilla: palatum durum



Tuber maxillae

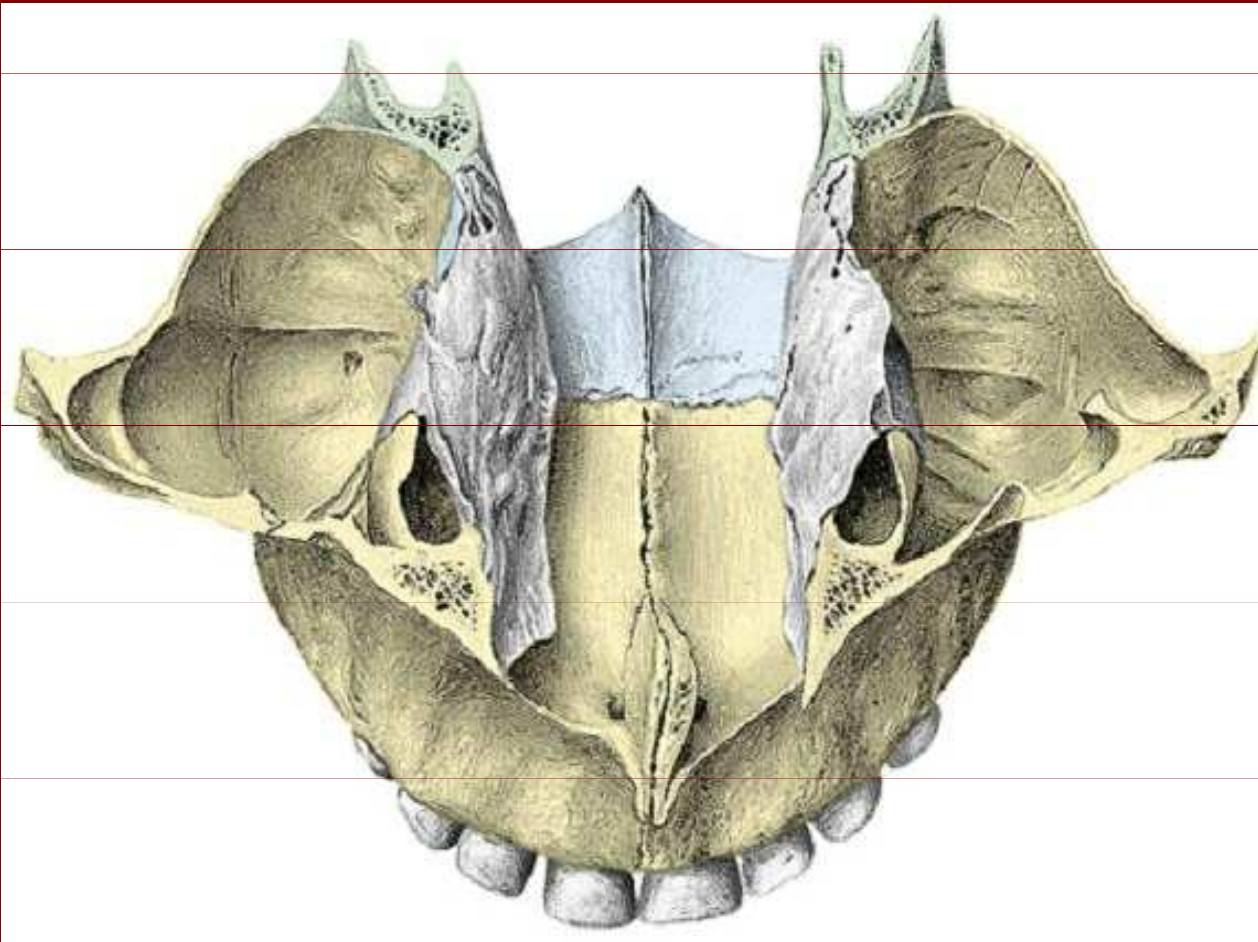
Processus palatinus

Processus  
zygomaticus

Praemaxilla  
(foramen incisivum)

Sutura palatina  
mediana

# Maxilla



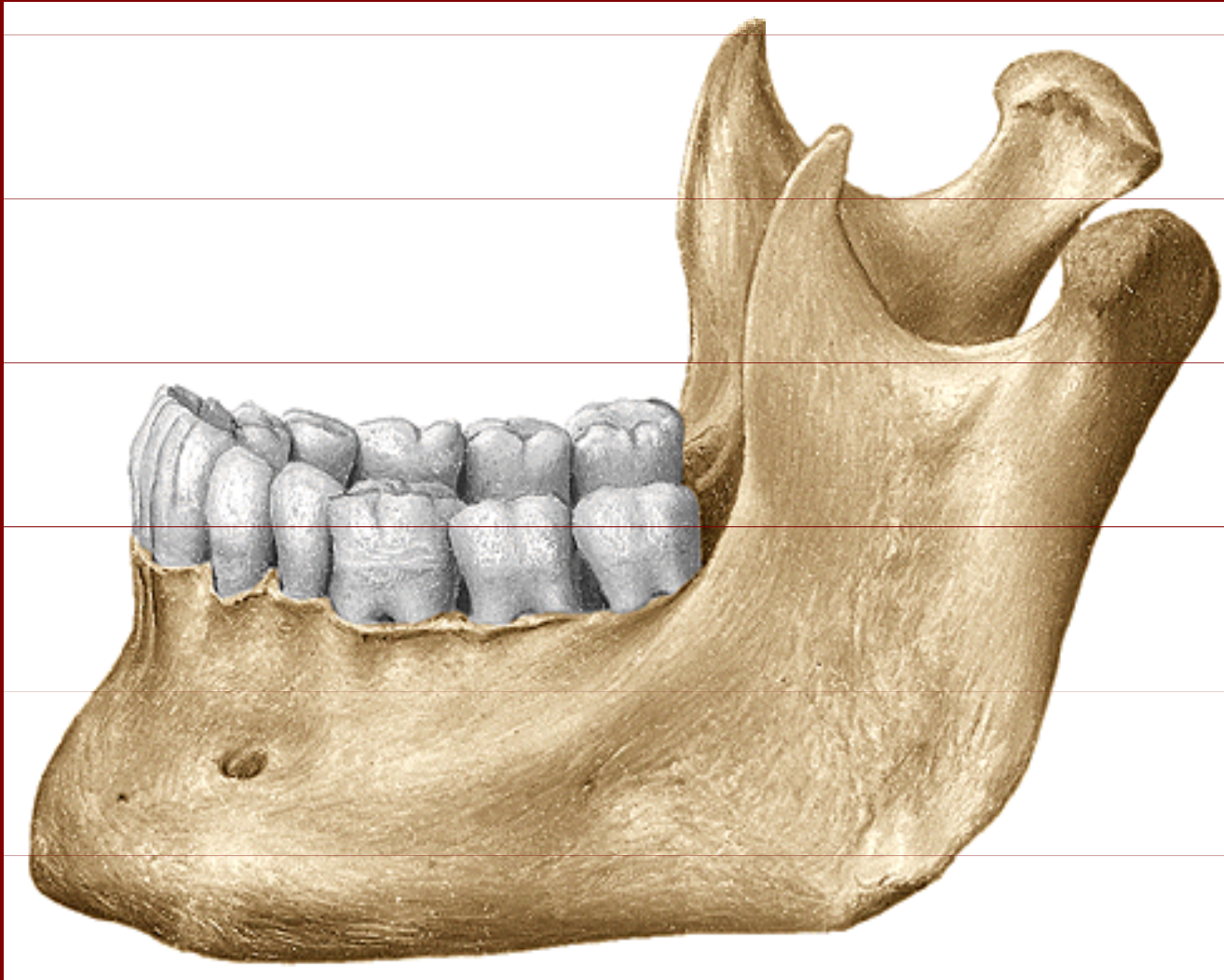
Antrum Highmori

Sutura palatina  
transversa

Sutura palatina  
mediana



# Mandibula



Processus condylaris

Processus  
coronoideus

Ramus mandibulae

Angulus mandibulae

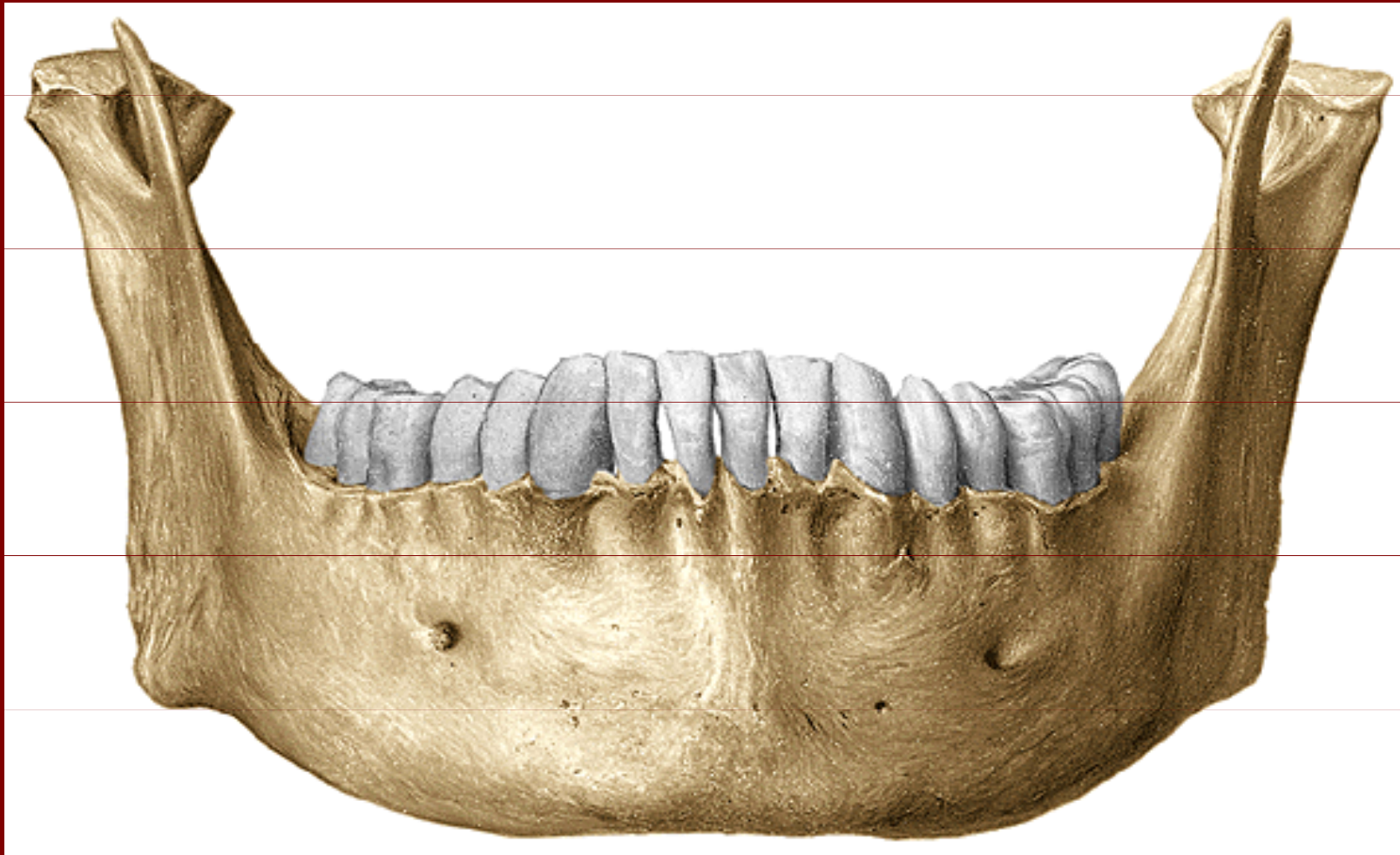
Corpus mandibulae

Foramen mentale

Processus alveolaris



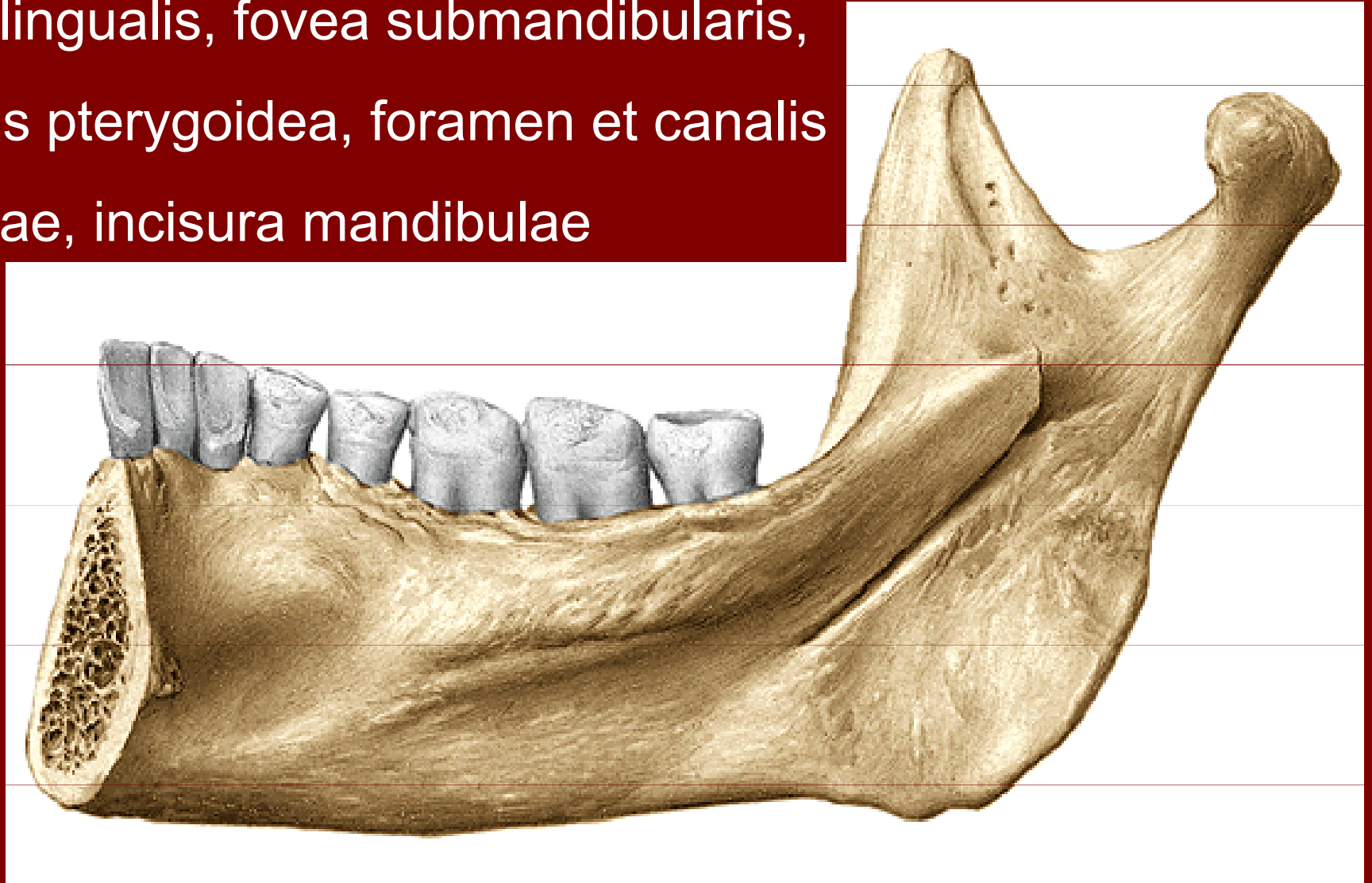
# Mandibula



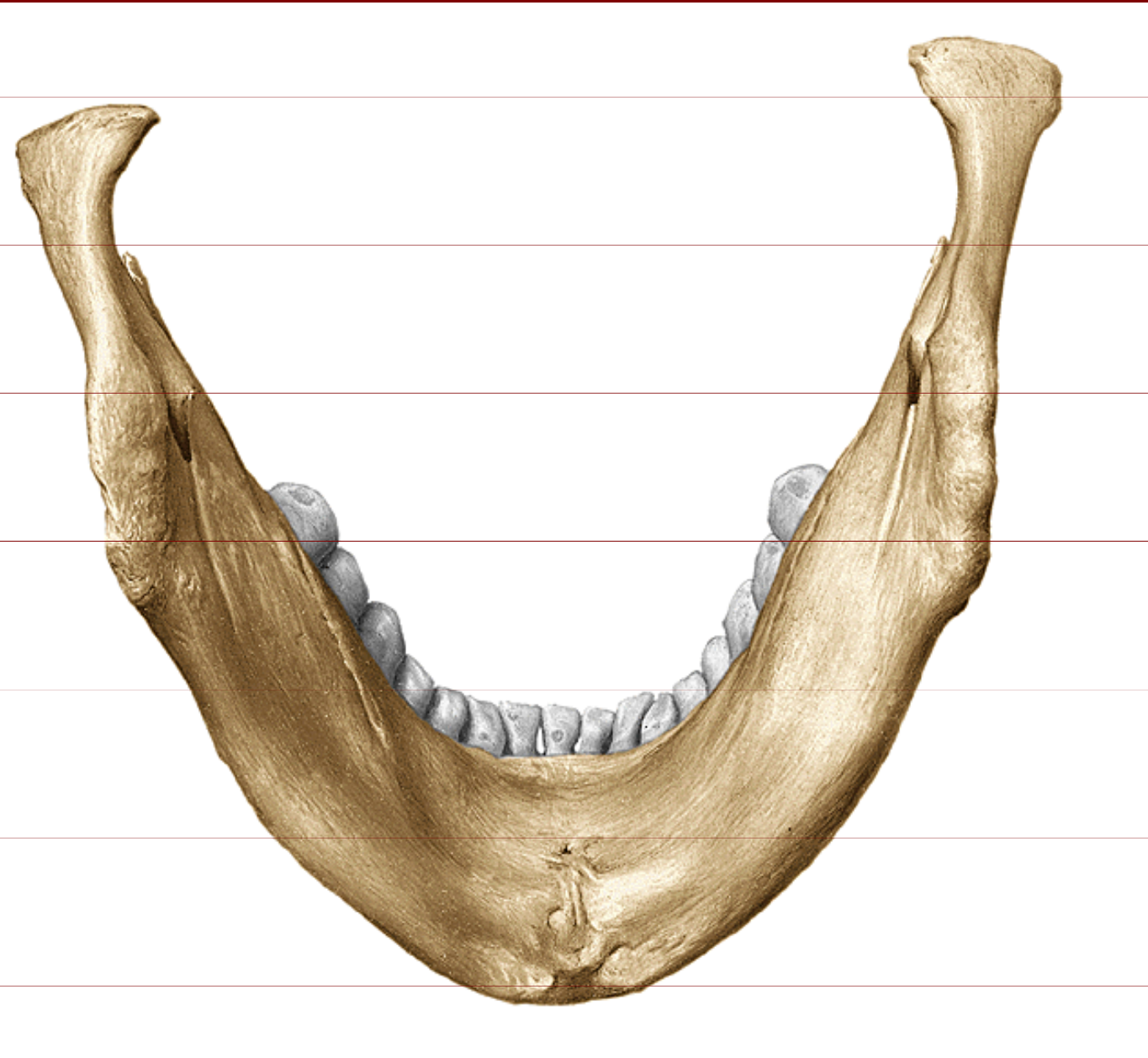
Corpus mandibulae, Ramus mandibulae,  
Foramen mentale, Protuberantia mentalis

# Mandibula

spina mentalis, linea mylohyoidea,  
fovea sublingualis, fovea submandibularis,  
tuberositas pterygoidea, foramen et canalis  
mandibulae, incisura mandibulae

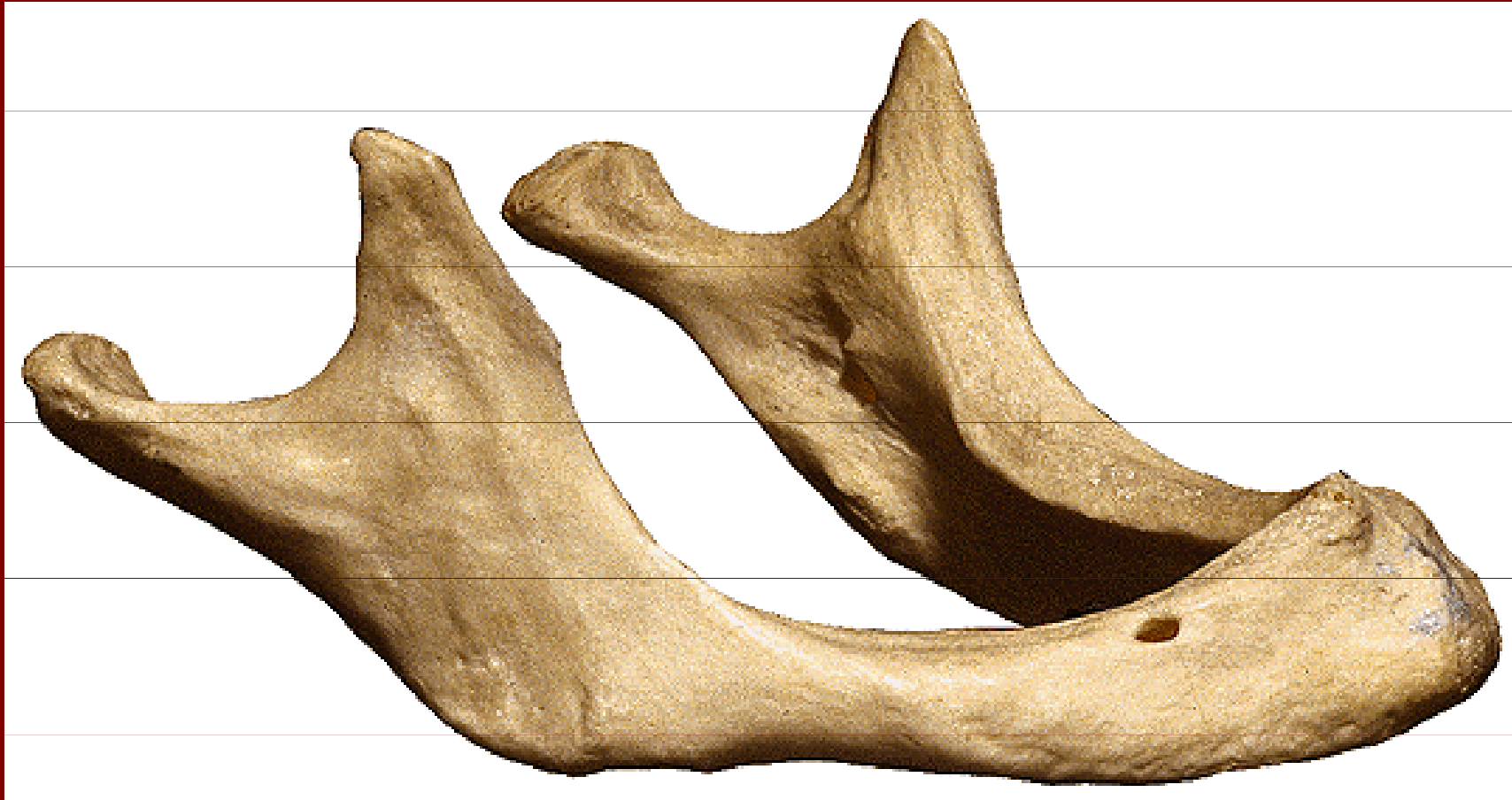

# Mandibula



- Spina mentalis
- Linea mylohyoidea
- Fovea sublingualis
- Fovea submandibularis
- Fossa digastrica
- Processus condylaris
- Tuberositas pterygoidea

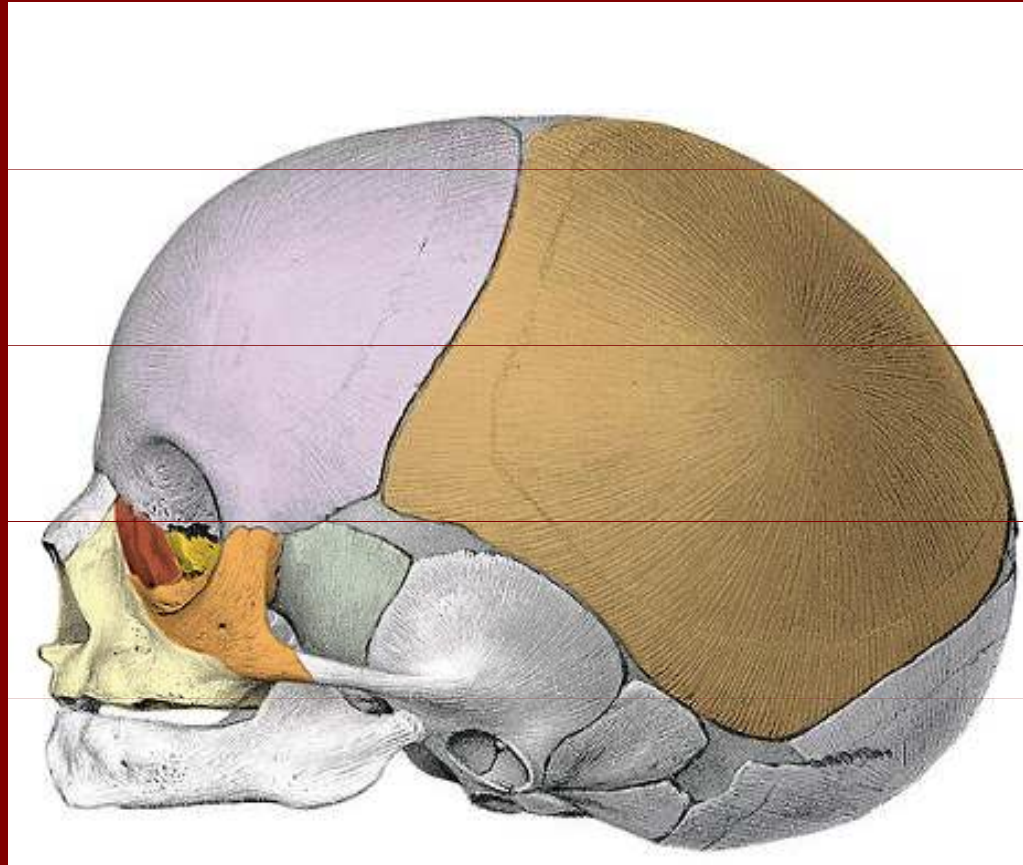
# Mandibula



Mandibula ve stáří, po ztrátě zubů  
zvětšení úhlu až na 150°

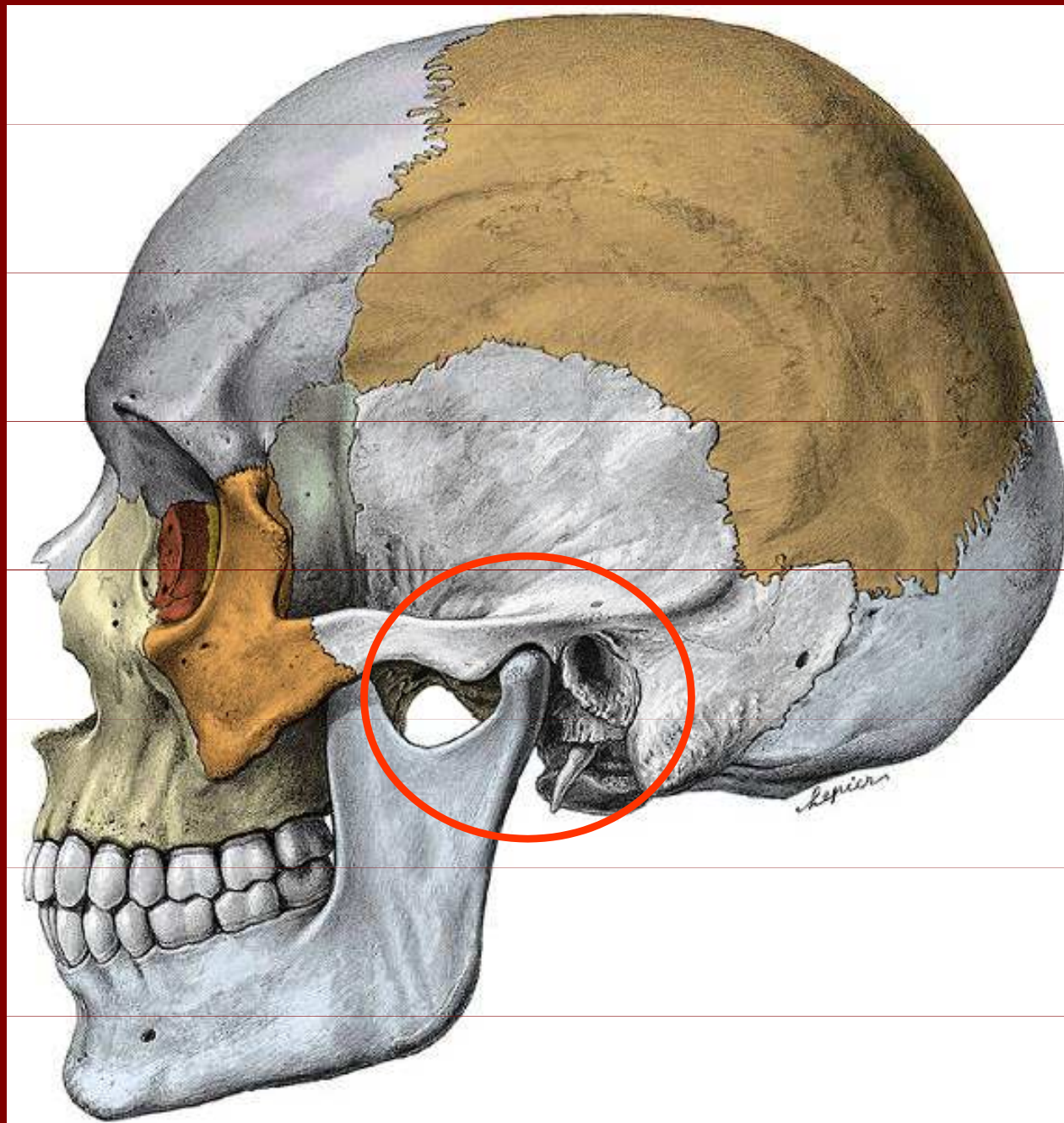


# Lebka novorozenca

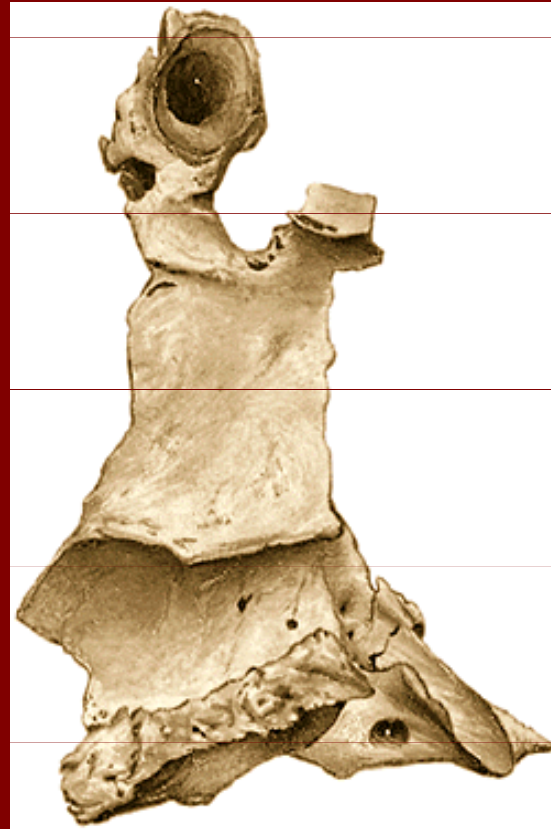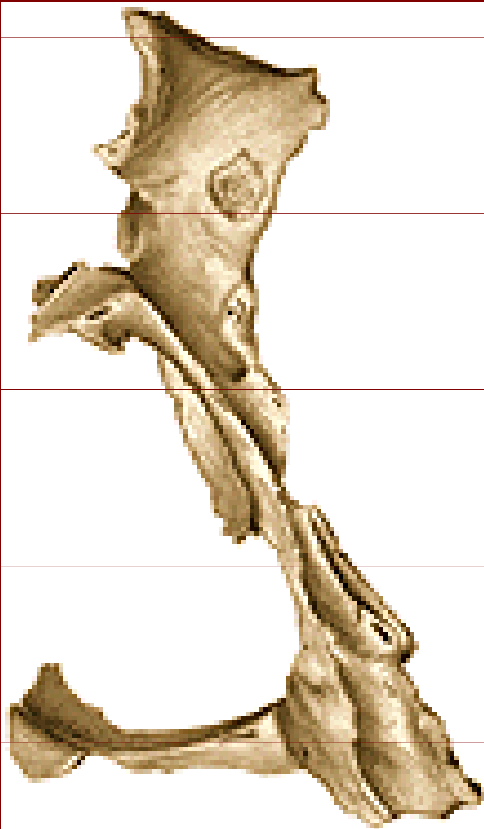


Mandibula novorozenca

# Spojení čelisti s lebkou



# Os palatinum



Lamina horizontalis

Lamina perpendicularis

Processus sphenoidalis

Processus orbitalis

Incisura sphenopalatina

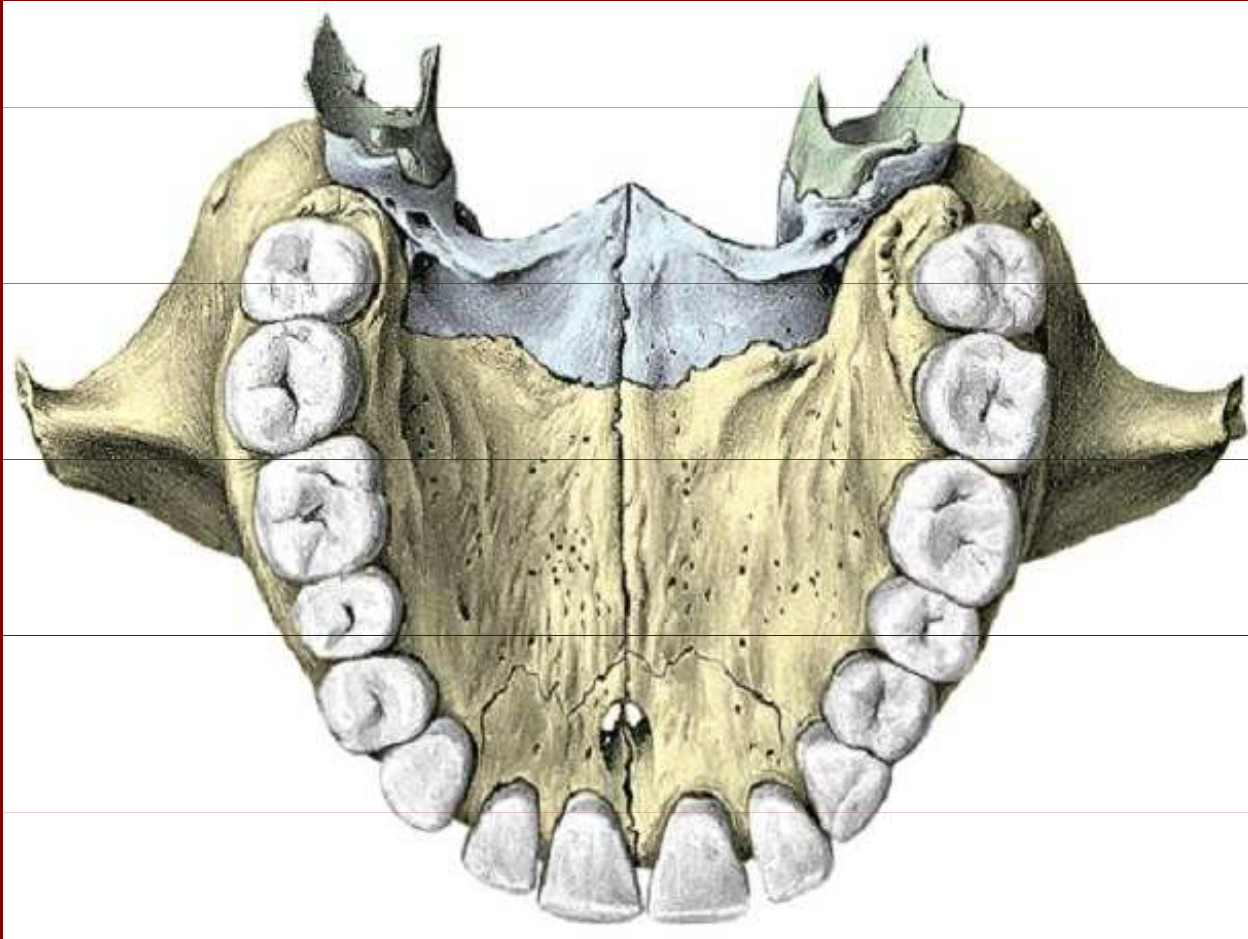
Crista nasalis

Crista conchalis

Crista ethmoidalis

Processus pyramidalis

# Palatum durum



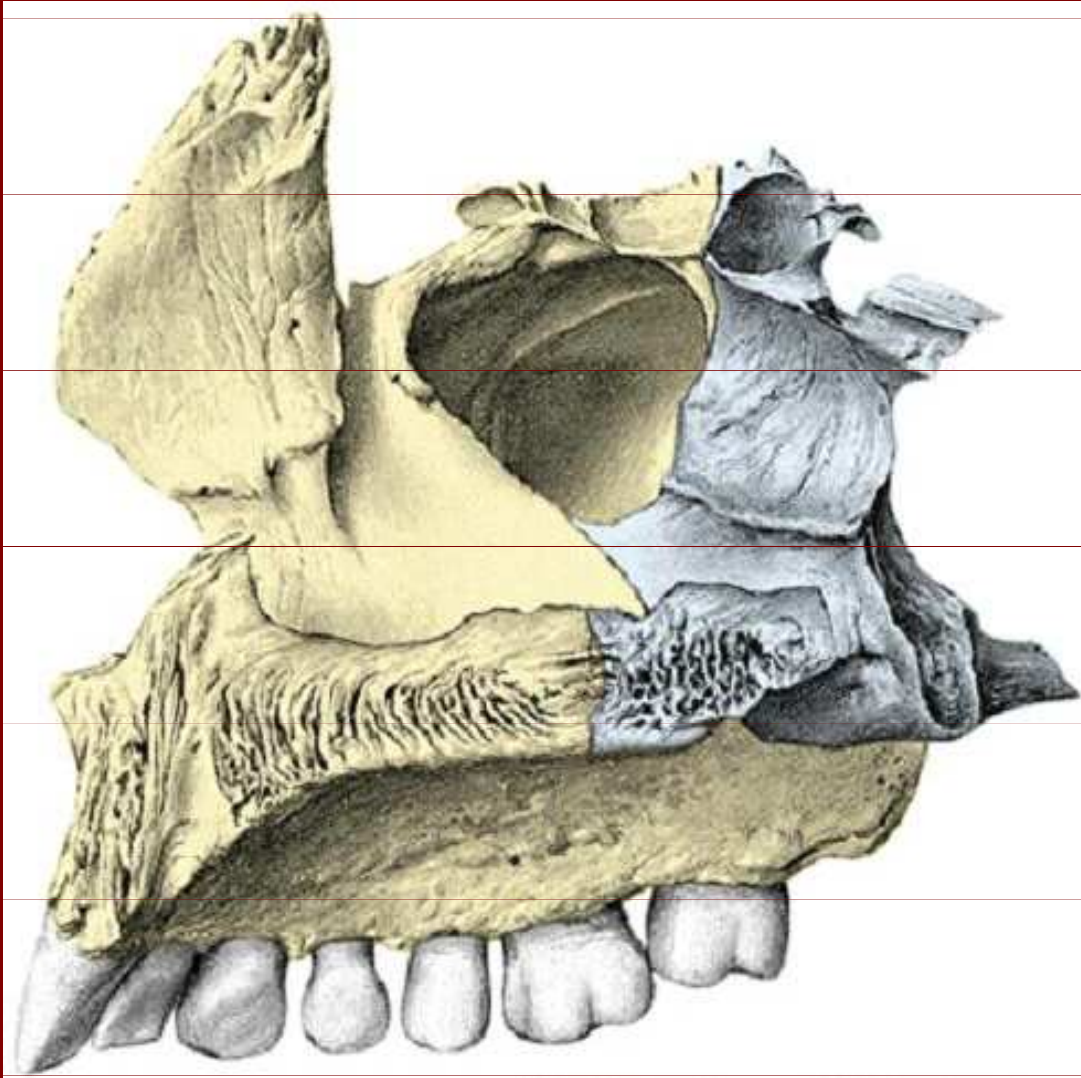
Lamina horizontalis ossis palatini

Spina nasalis posterior

Processus pyramidalis



# Os palatinum



Processus orbitalis

Incisura sphenopalatina

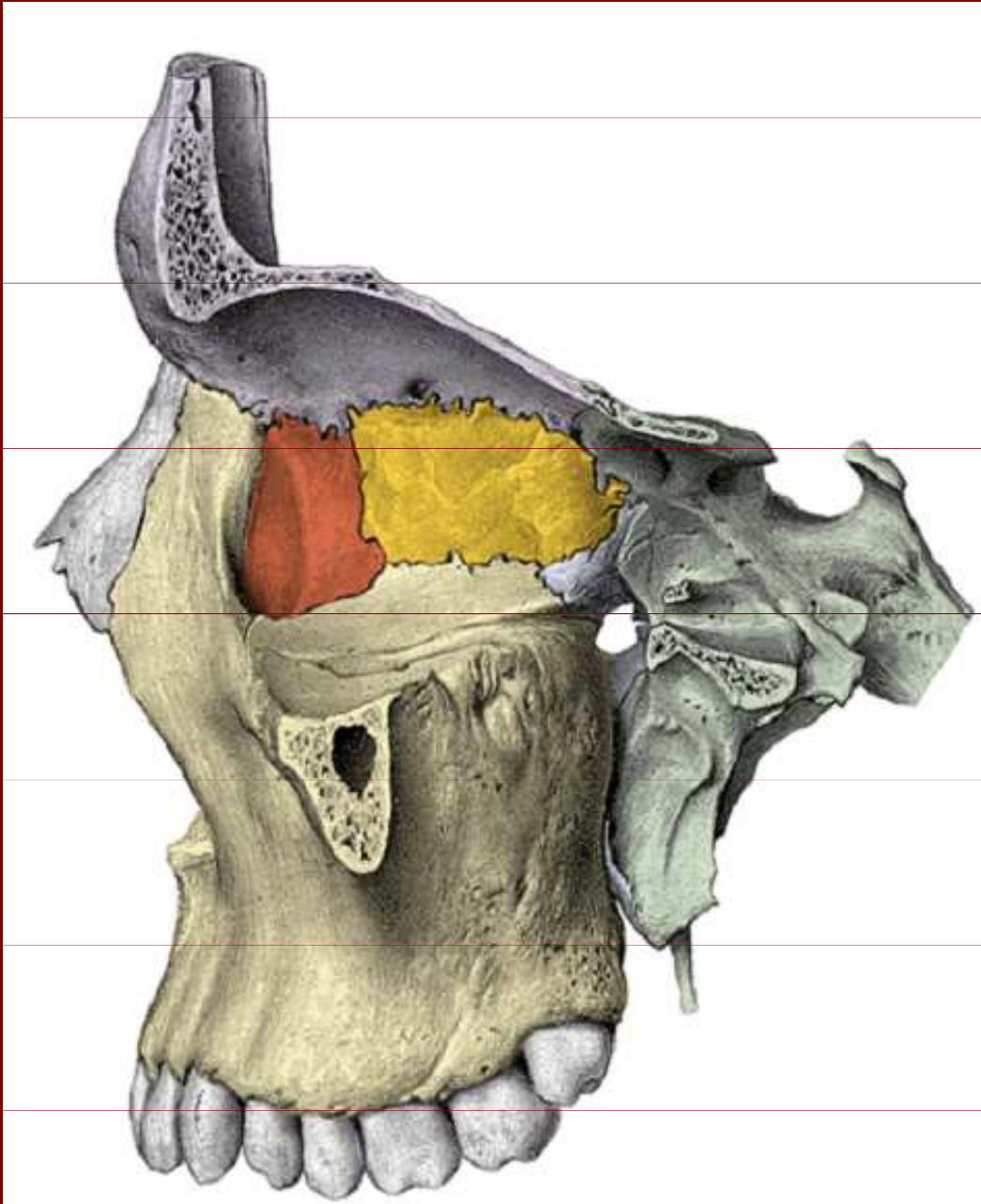
Processus sphenoidalis

Crista conchalis

Processus pyramidalis

Lamina horizontalis

# Pohled na mediální plochu očnice



Processus orbitalis

Foramen  
sphenopalatinum

Processus sphenoidalis

Lamina papyracea ossis  
ethmoidalis

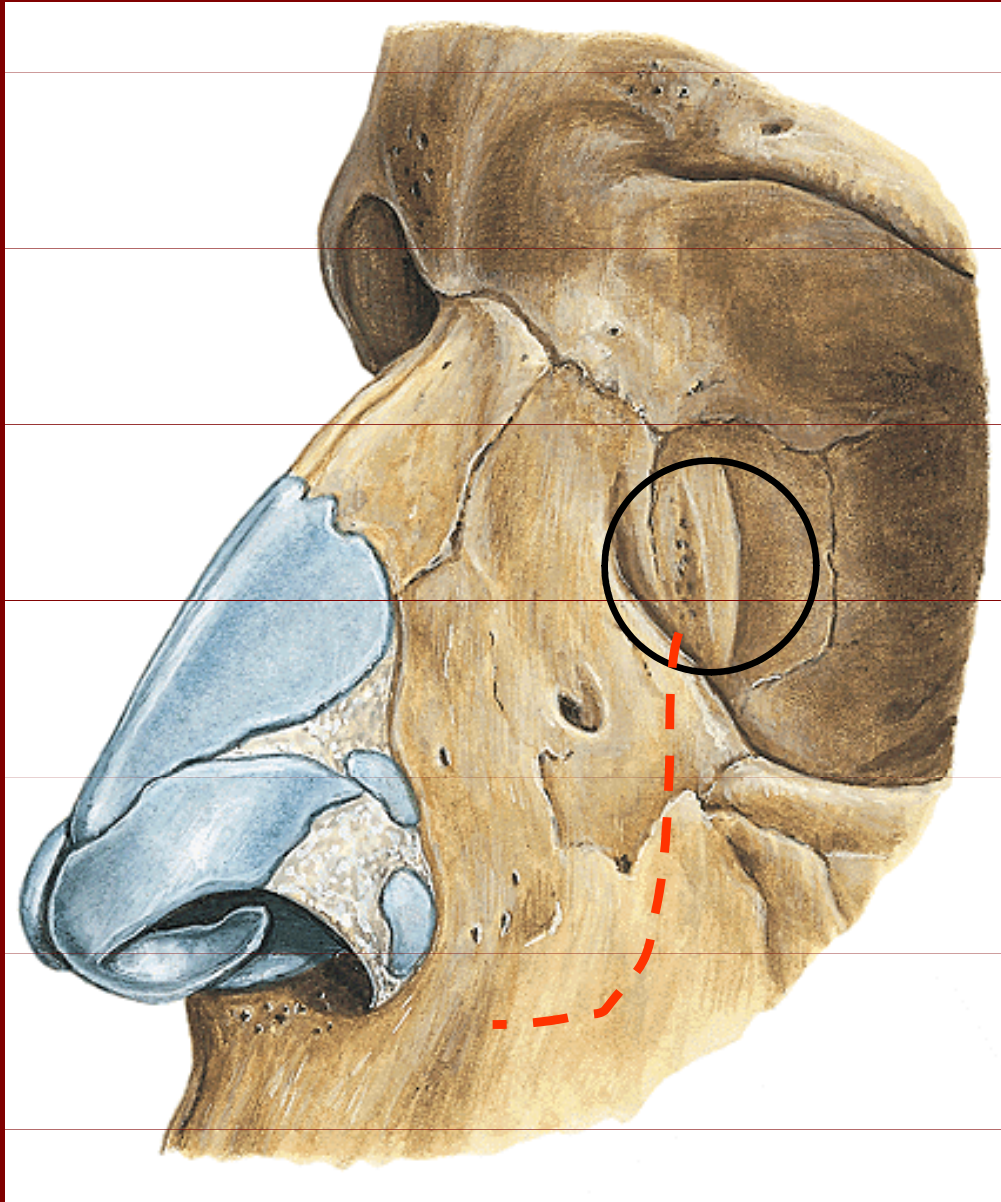
Os lacrimale

Fossa sacci lacrimalis

Processus frontalis

Facies orbitalis

# Os lacrimale



Crista lacrimalis  
posterior

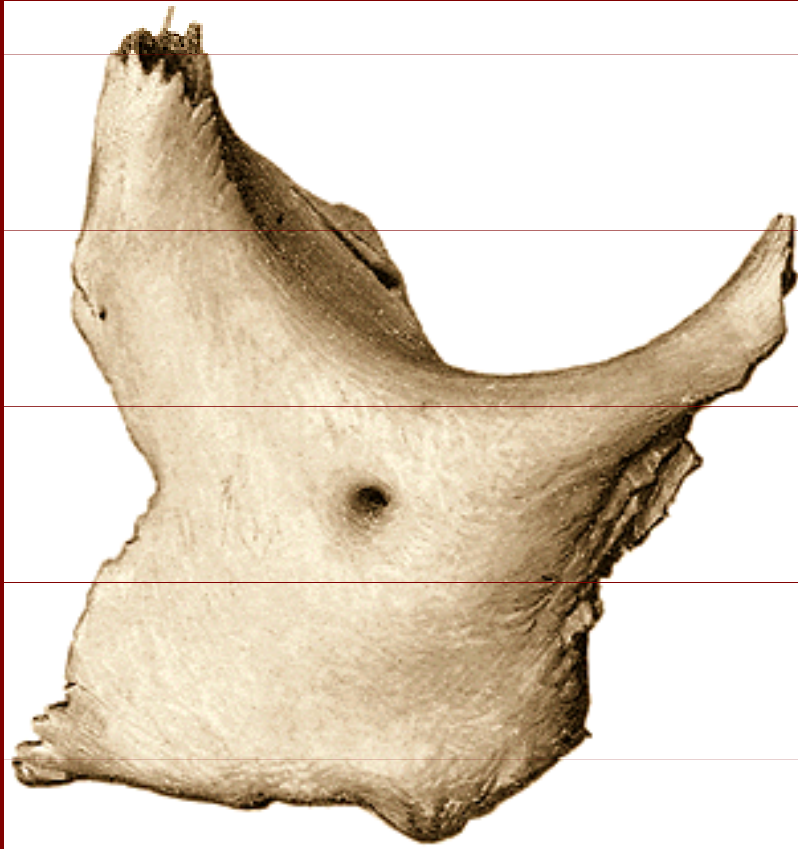
Sulcus lacrimalis

Fossa sacci lacrimalis

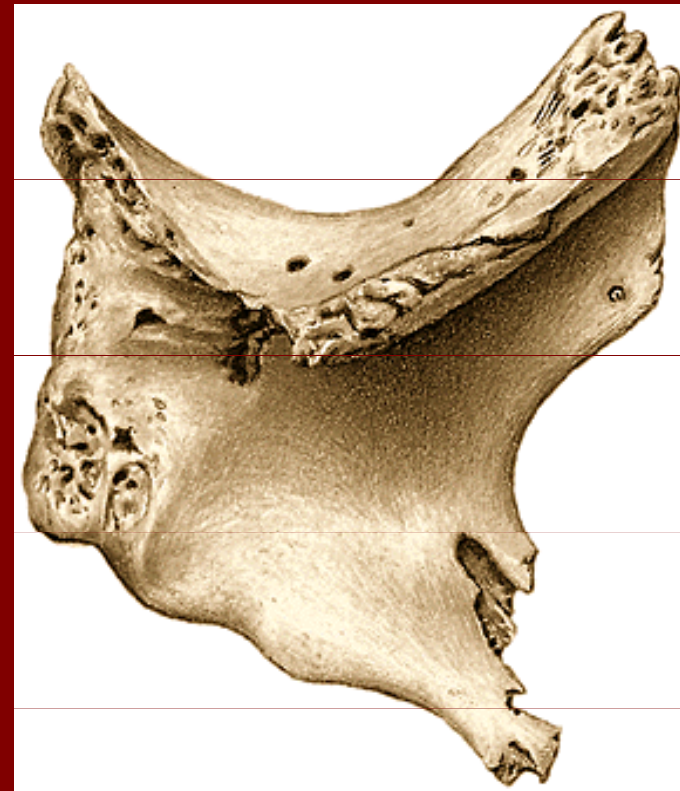Canalis nasolacrimalis



# Os zygomaticum



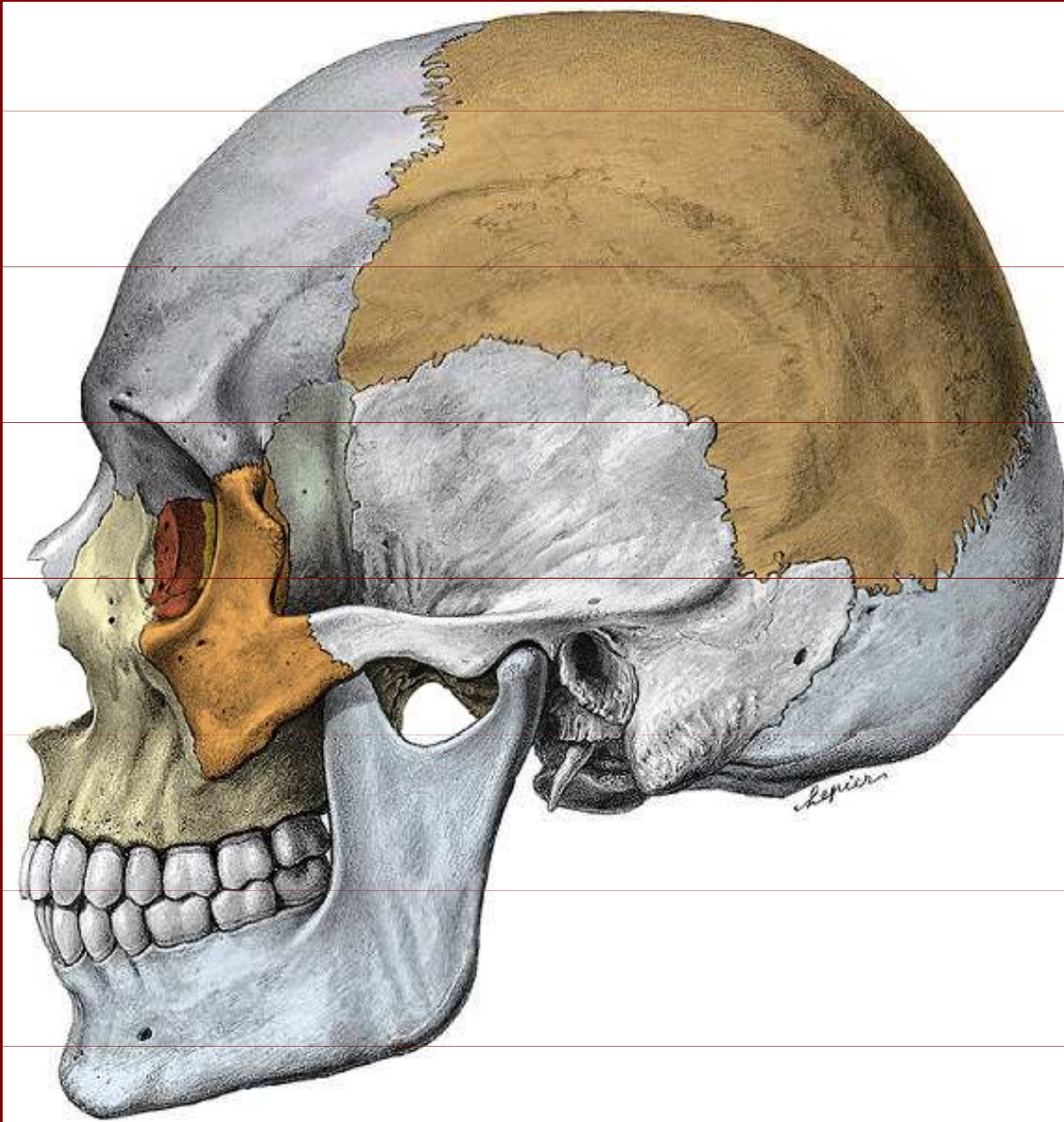
Facies lateralis



Facies temporalis



# Os zygomaticum



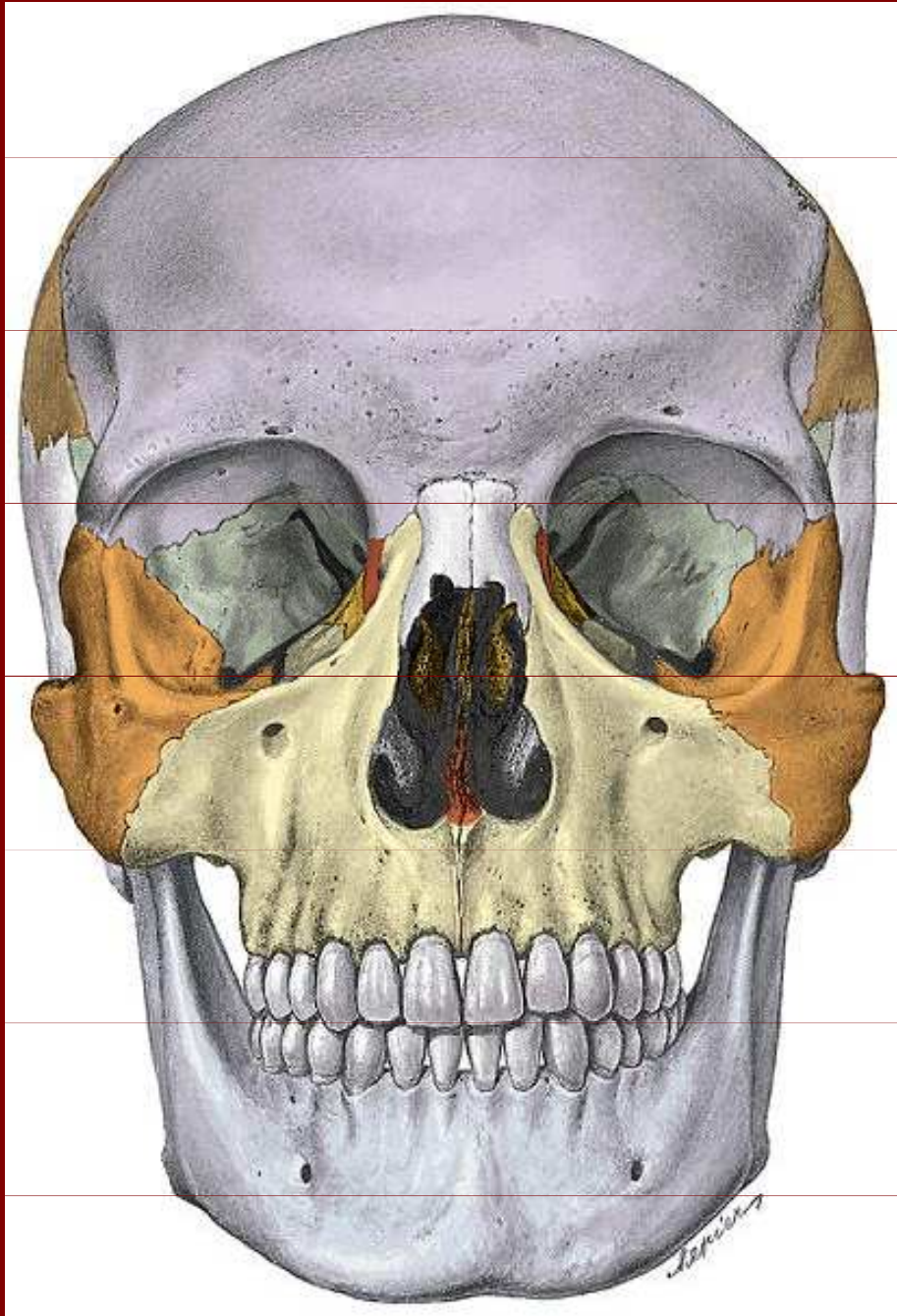
Processus frontalis

Processus temporalis

Foramen  
zygomaticofaciale

Processus maxillaris

# Os zygomaticum



Facies lateralis

Facies orbitalis

Processus frontalis

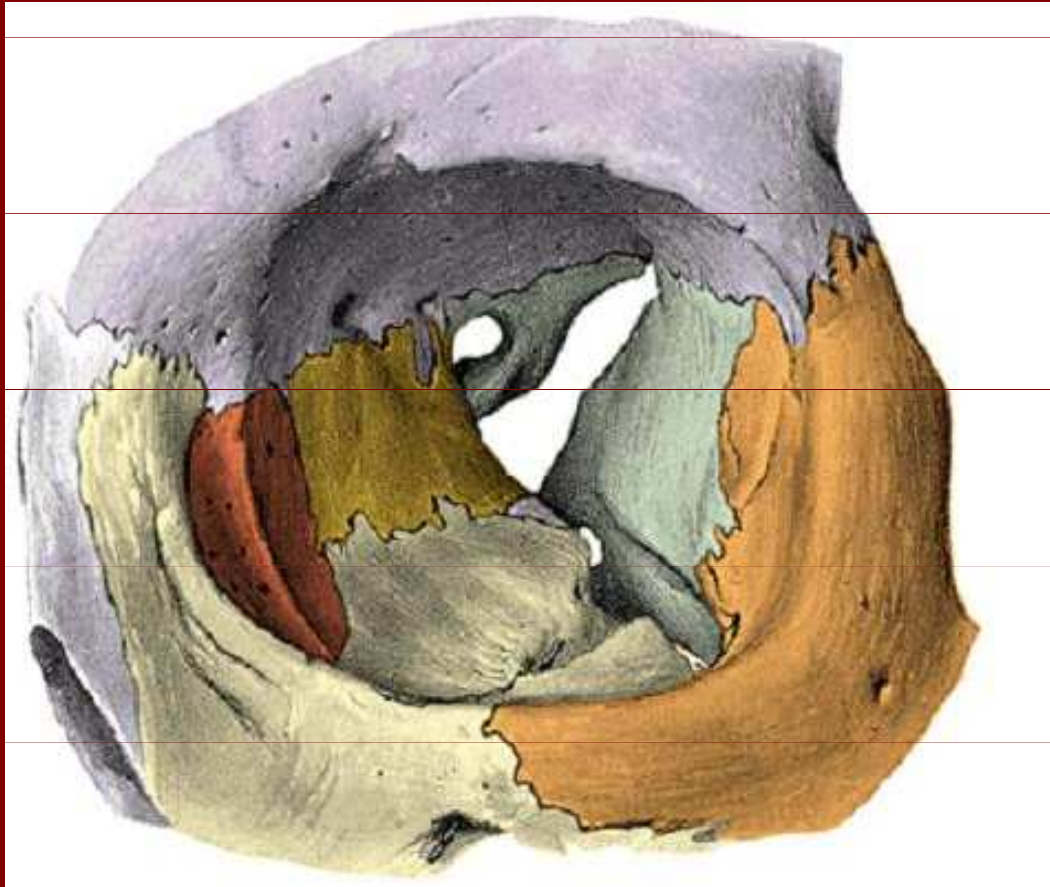
Processus maxillaris

Foramen zygomaticoorbitale

Foramen zygomaticofaciale



# Orbita



Os zygomaticum

Processus maxilaris

Processus frontalis

Foramen zygomaticofaciale

Lamina papyracea ossis  
ethmoidalis

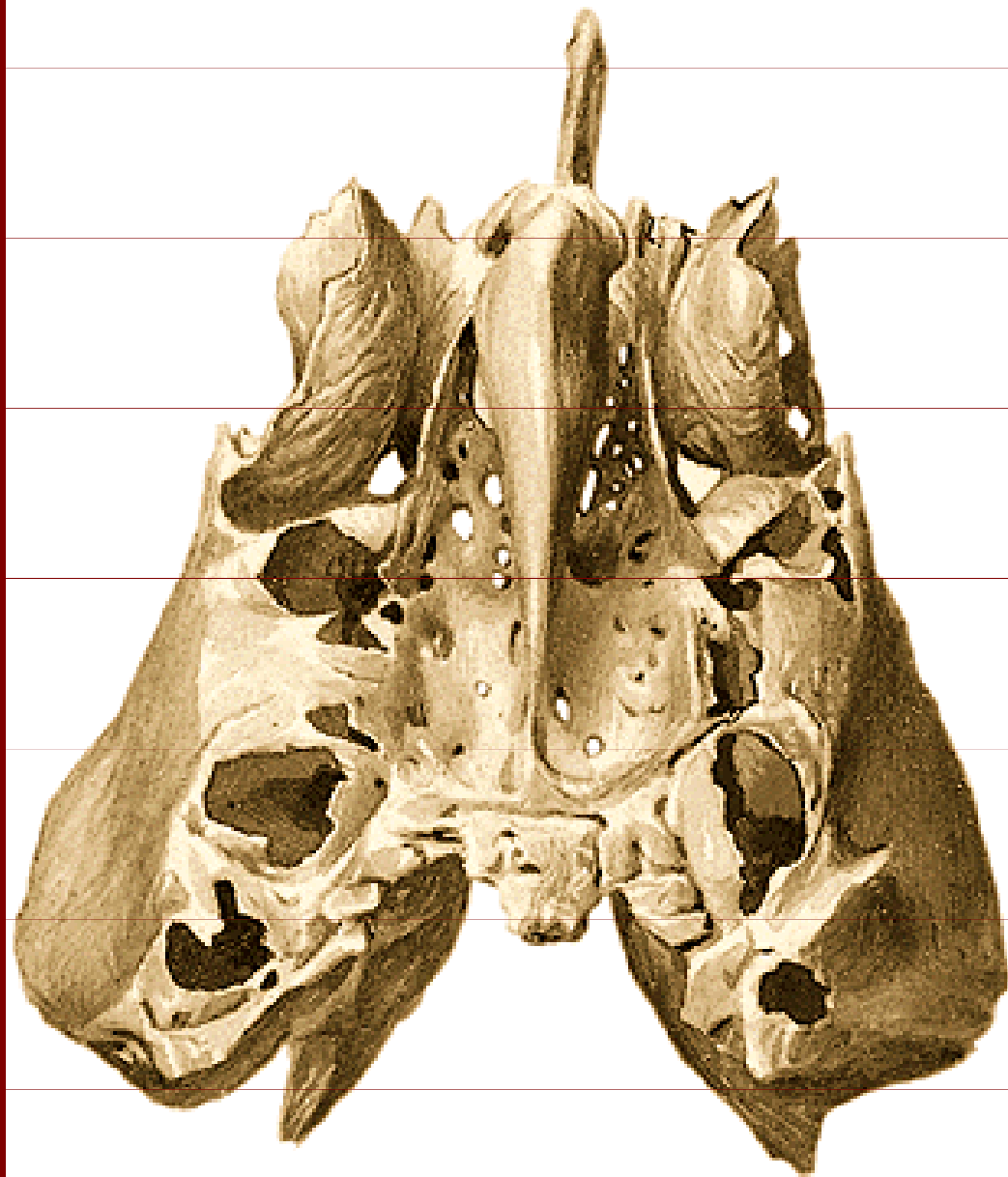
Os lacrimale

Facies orbitalis maxillae

Ala minor s canalis opticus

Fissura orbitalis superior

# Os ethmoidale



Crista galli

Lamina cribrosa

Cellulae ethmoidale

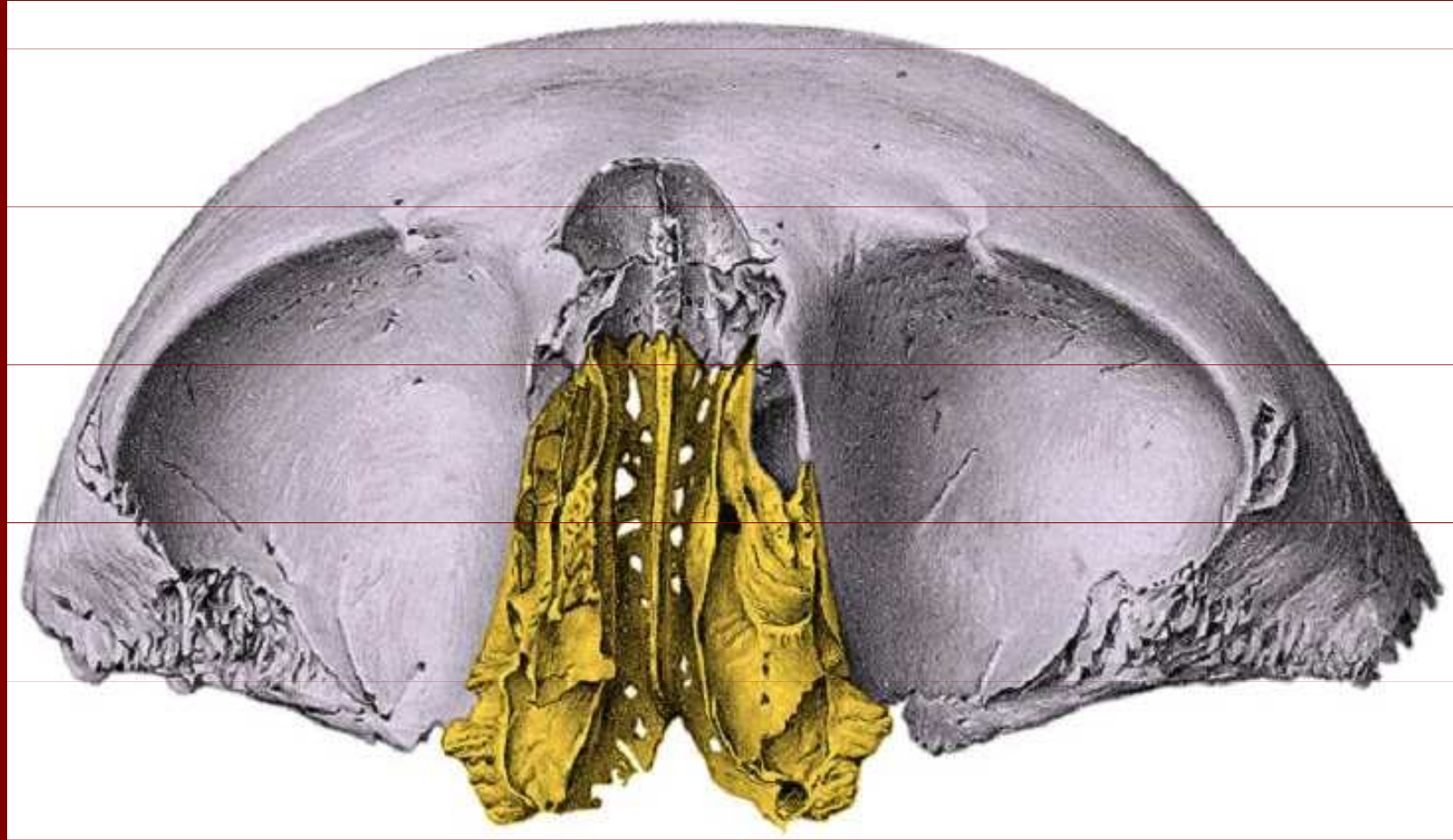
Lamina papyracea

Concha nasalis  
media

Bulla ethmoidalis

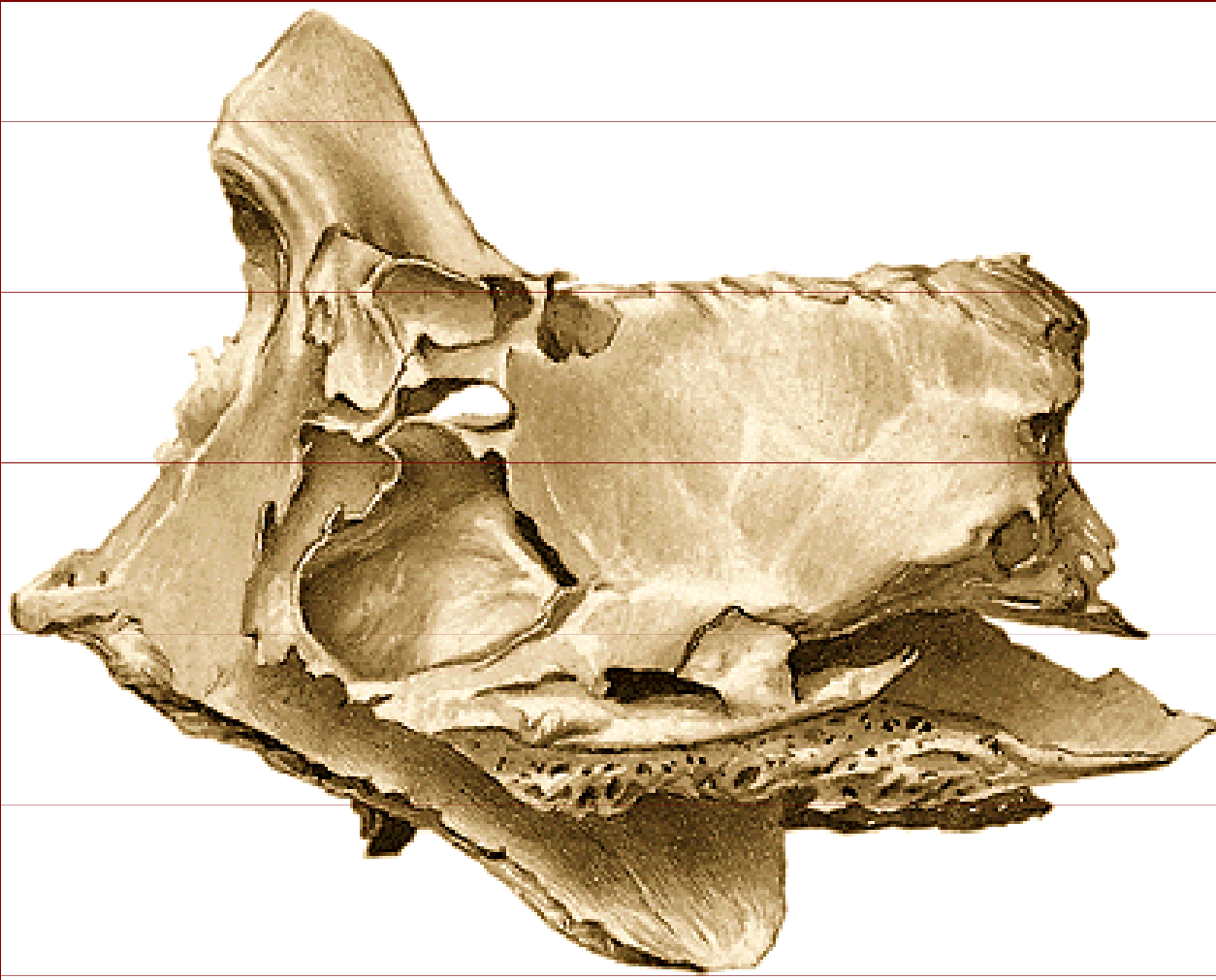


# Os ethmoidale



processus uncinatus, lamina perpendicularis, lamina cribrosa

# Os ethmoidale



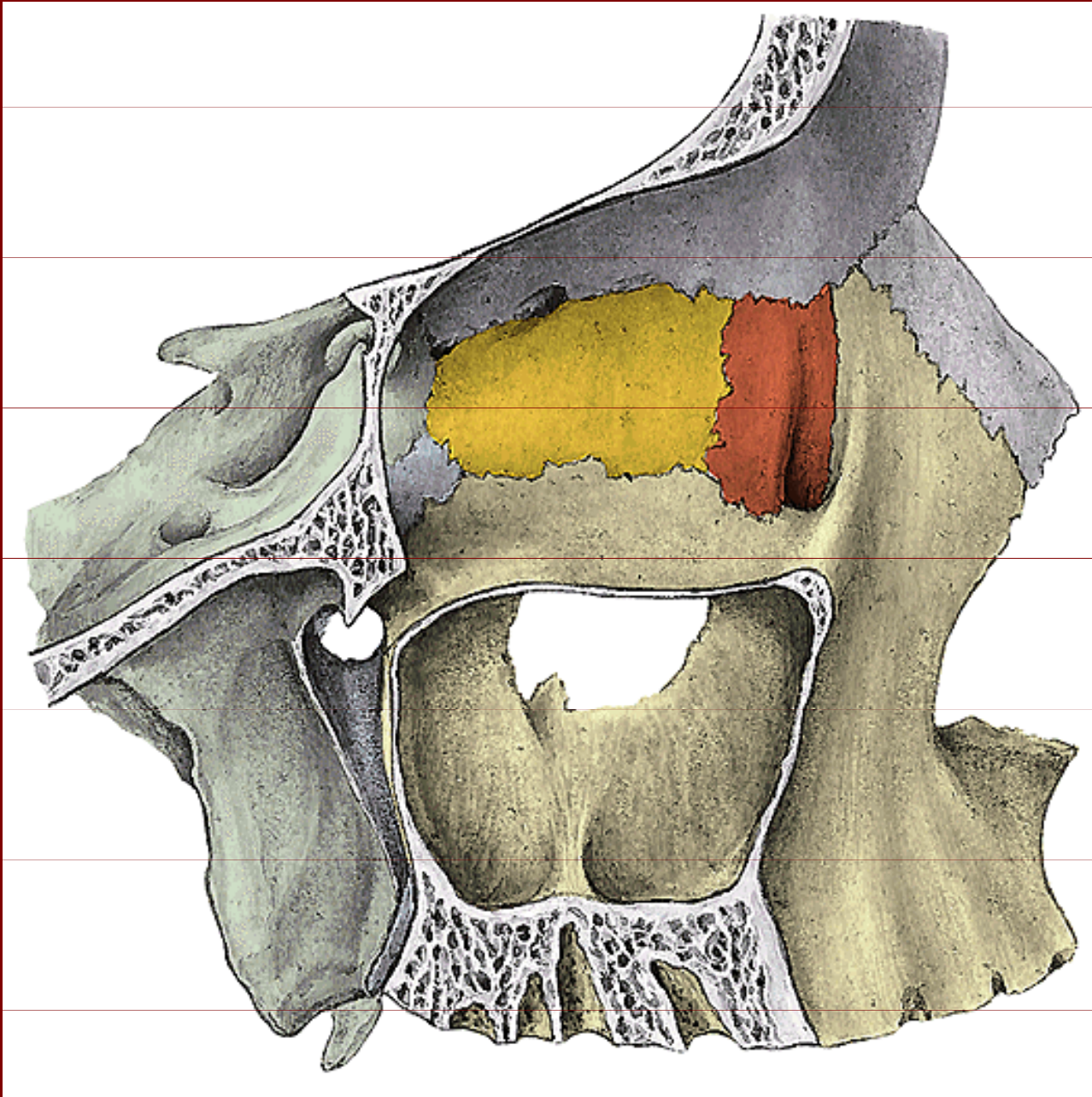
Labyrinthus ethmoidalis

Concha nasalis media

Lamina perpendicularis

Crista galli

# Mediální stěna očnice



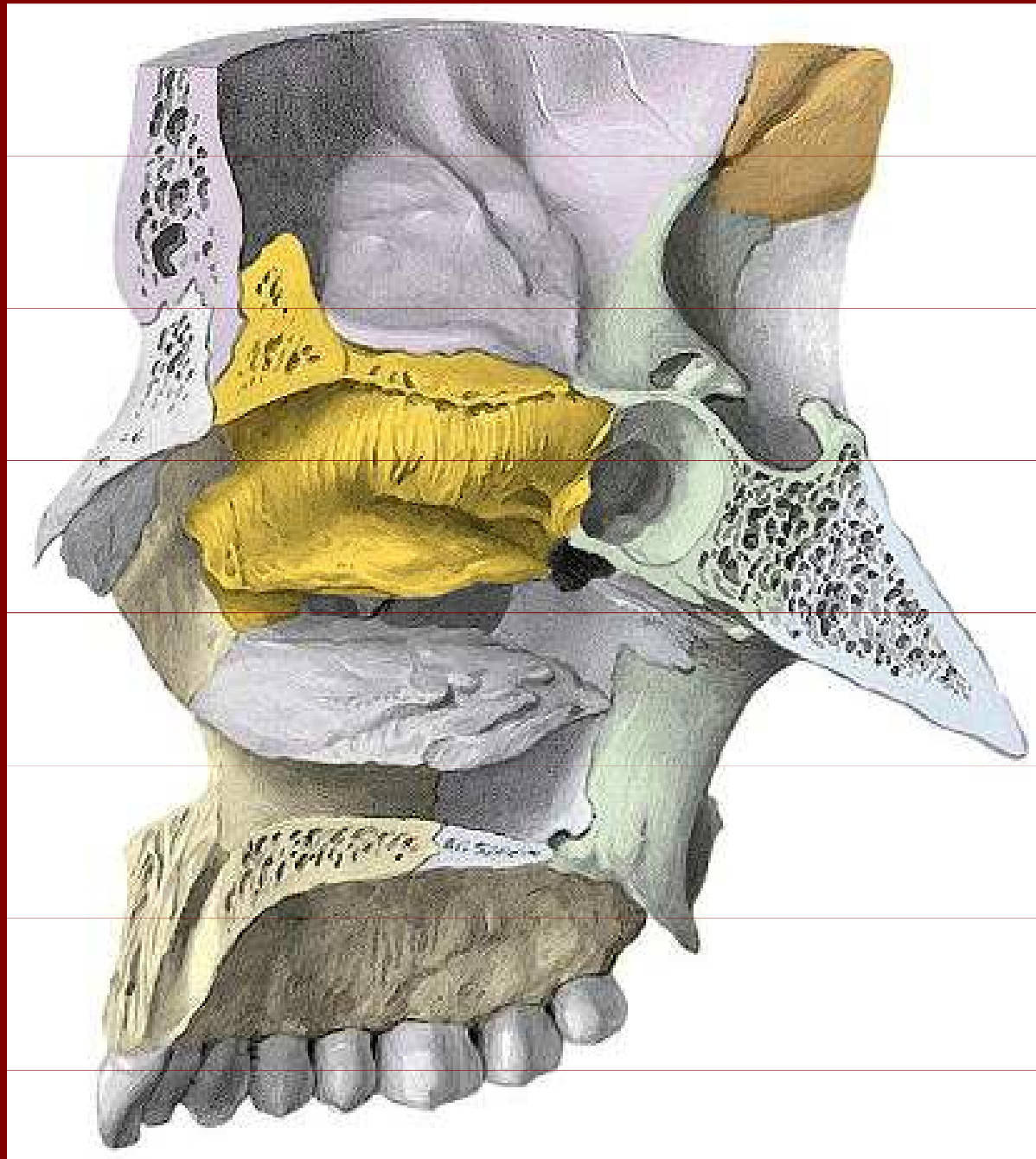
Lamina orbitalis  
ossis ethmoidalis  
= lamina papyracea

Processus orbitalis  
ossis palatini

Os lacrimale

Sinus maxillaris

# Laterální stěna nosní



Os ethmoidale

Crista galli

Lamina cribrosa

Concha nasalis media

Concha nasalis superior

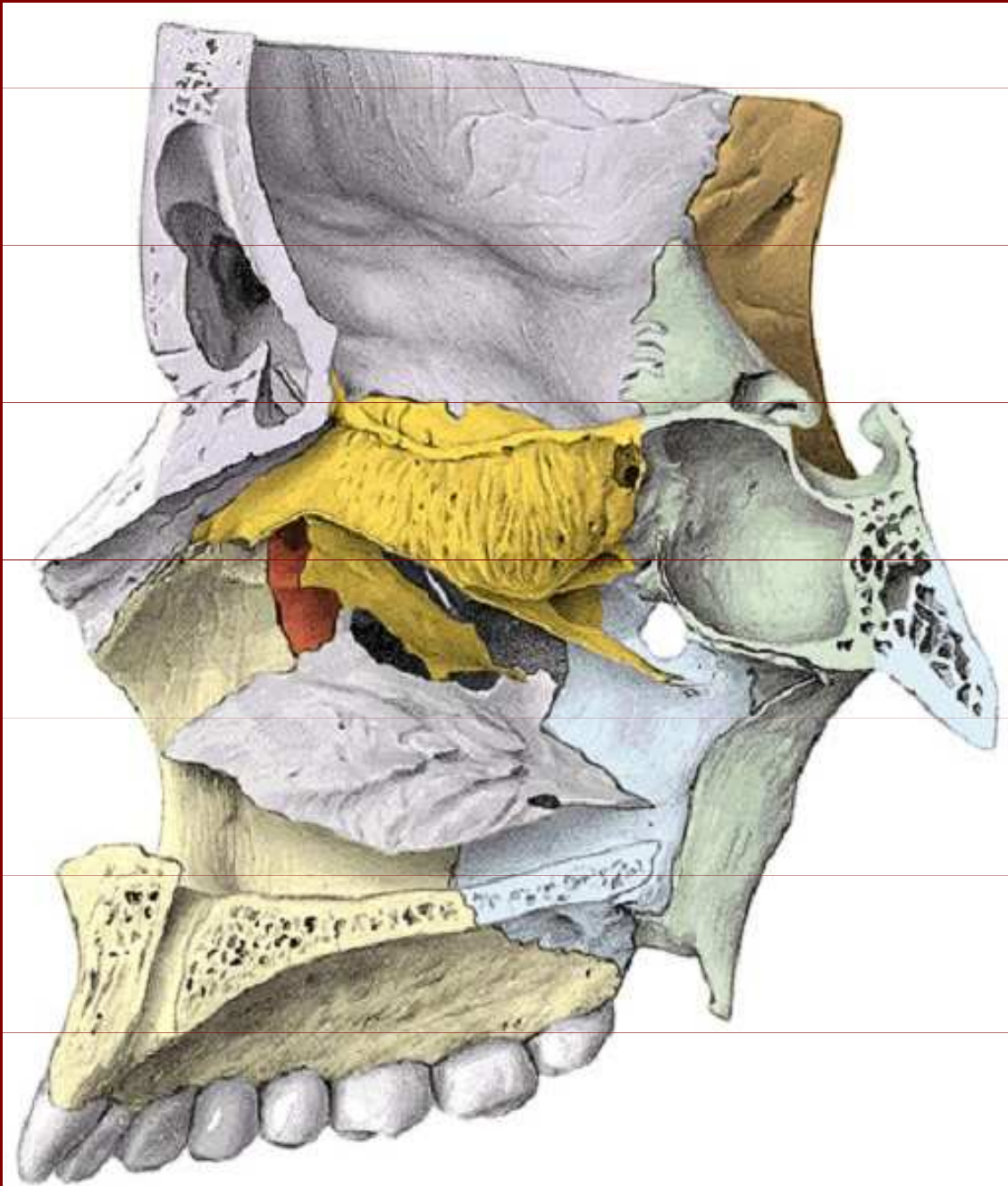
Sinus sphenoidalis

Lamina perpendicularis ossis palatini

Processus pterygoideus medialis



# Laterální plocha dutiny nosní

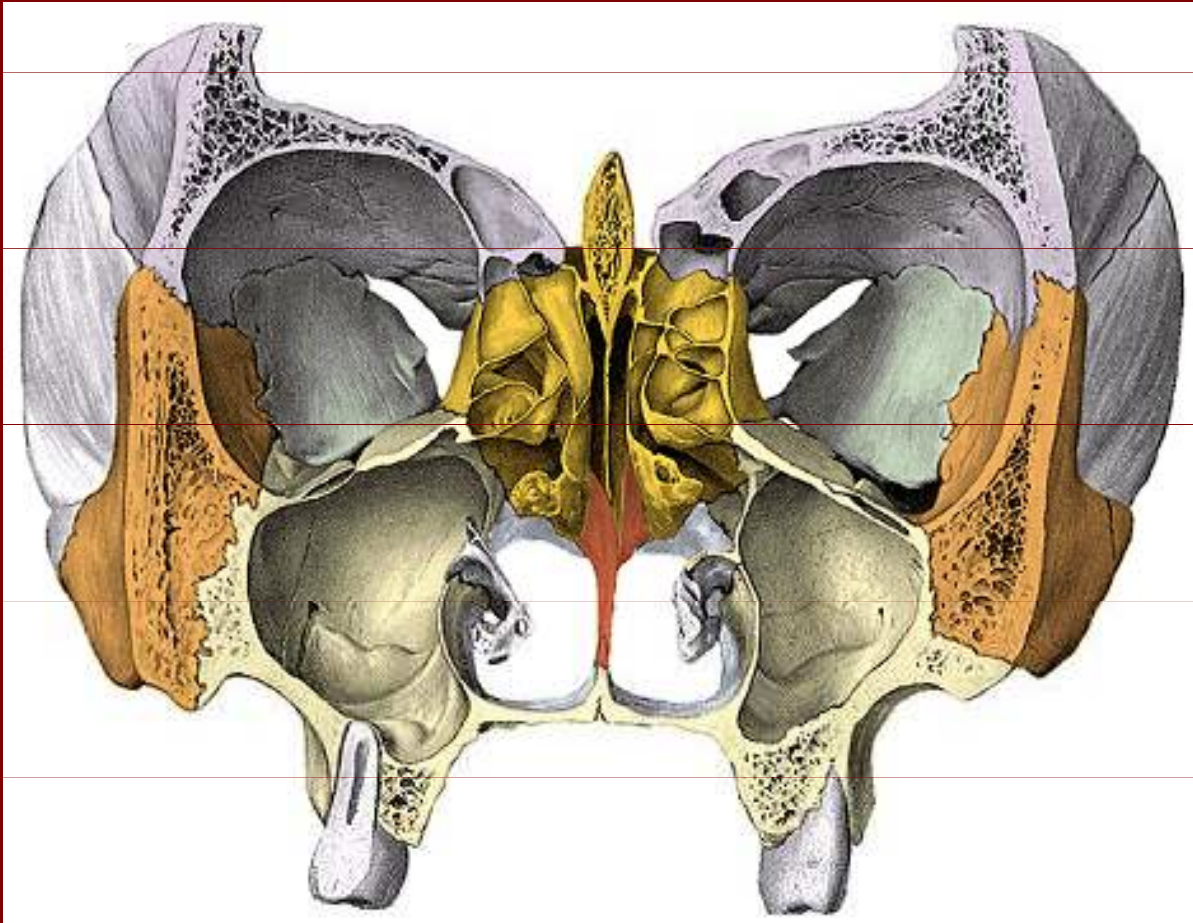


Concha nasalis  
inferior

Hiatus semilunaris

Processus uncinatus

# Frontální řez lebkou



Crista galli

Lamina perpendicularis  
ossis ethmoidalis

Celulae ethmoidales

Concha nasalis media

Pars nasalis ossi frontalis

Vomer

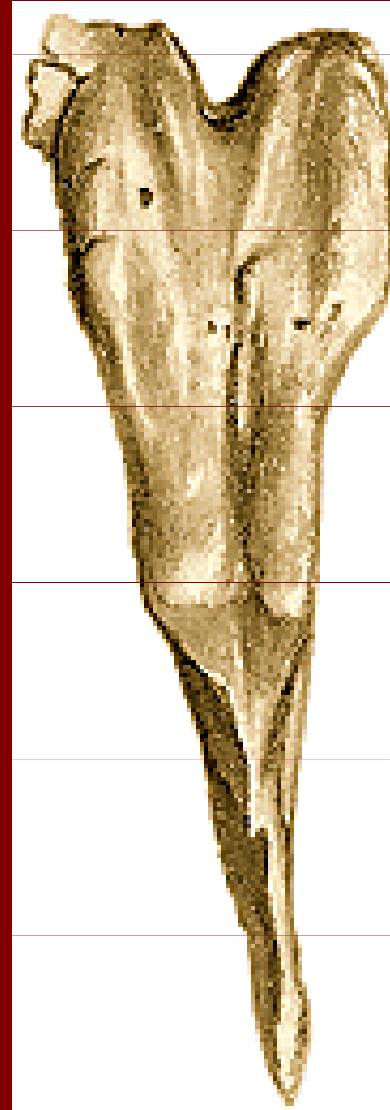
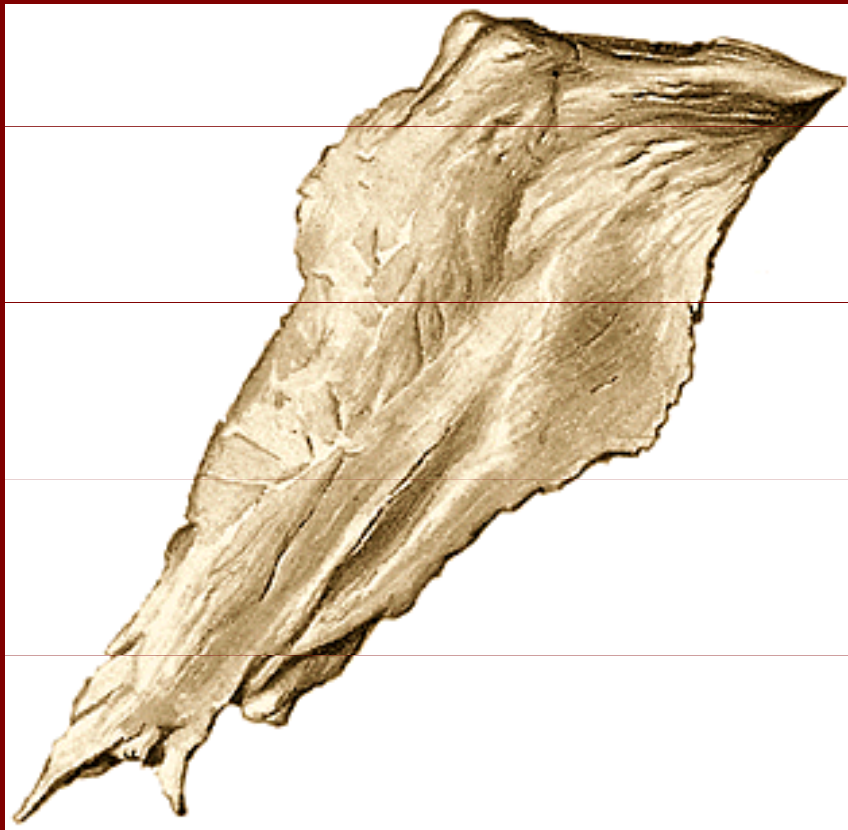
Concha nasalis inferior

Sinus maxillaris

Fissura orbitalis superior

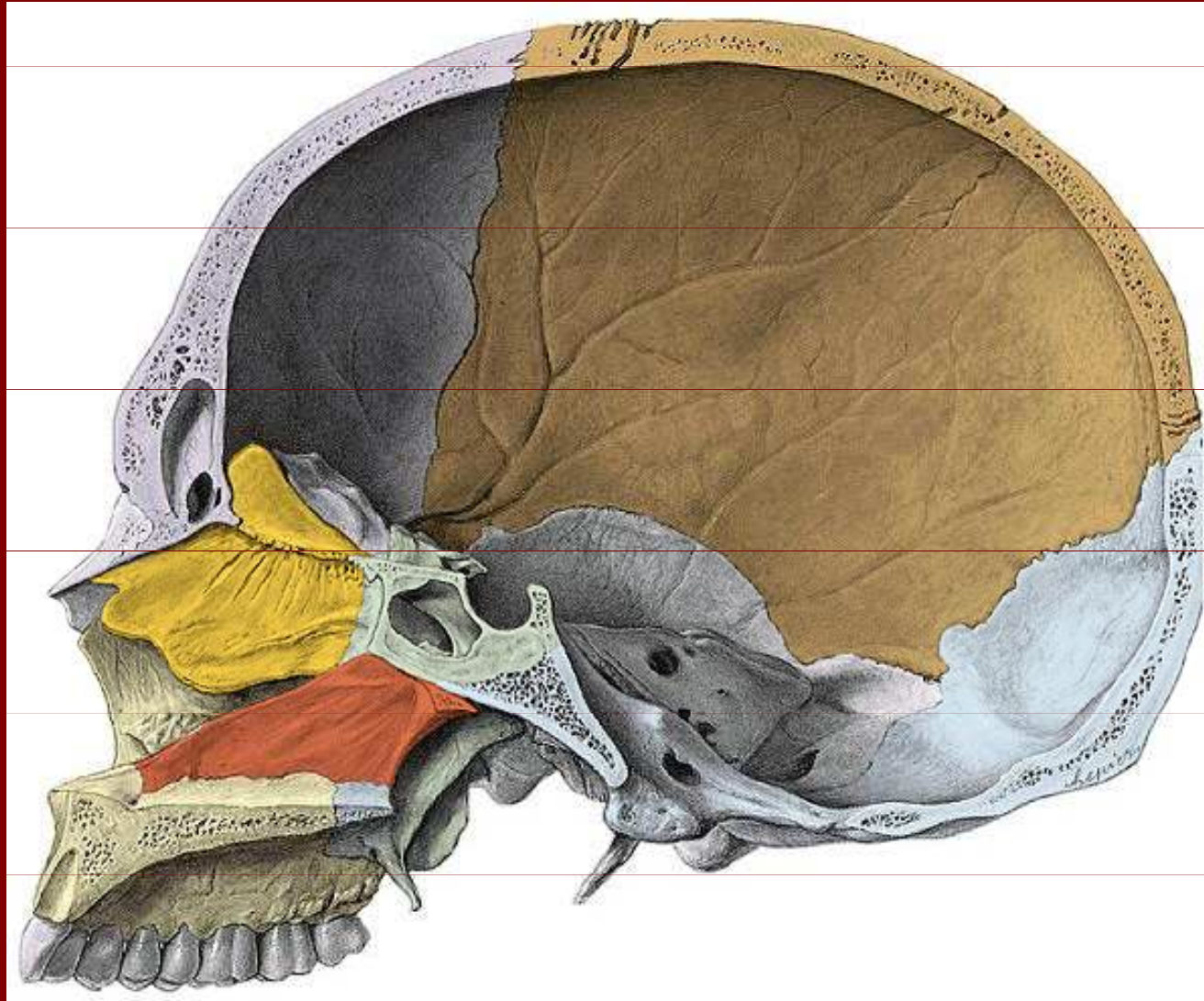
# Vomer

alae vomeris





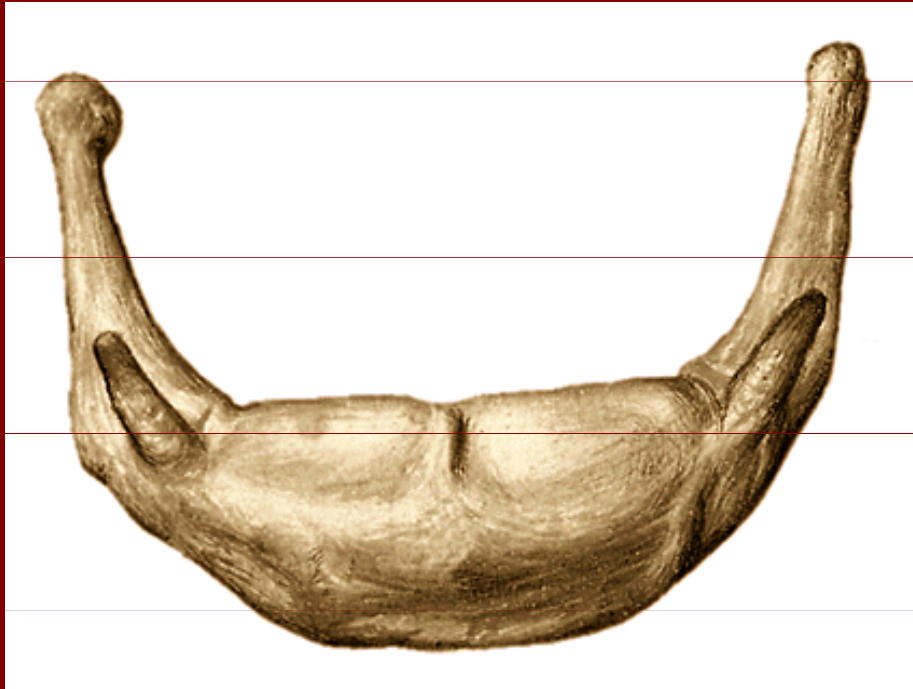# Sagitální řez lebkou



Vomer a lamina perpendicularis ossis ethmoidalis



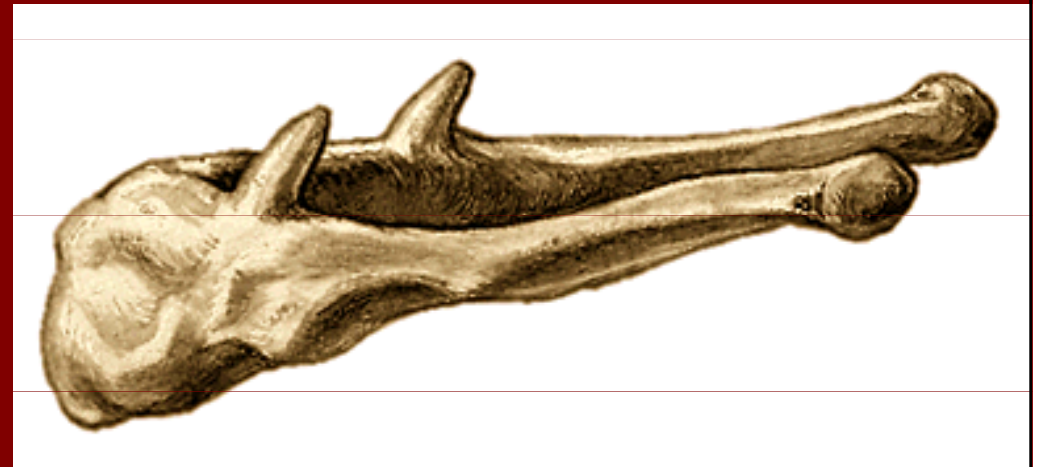# Os hyoideum



Corpus

Cornu majus

Cornu minus



# Poděkování

Pro tuto přednášku byly použity obrázky z  
**Atlas of Human Anatomy od Sobotty**