

REGIONAL ANATOMY OF THE THORAX

- **Regions**
- **Lines**
- **Thoracic wall**

**Regio infraclavicularis
(trig. deltopectorale)**

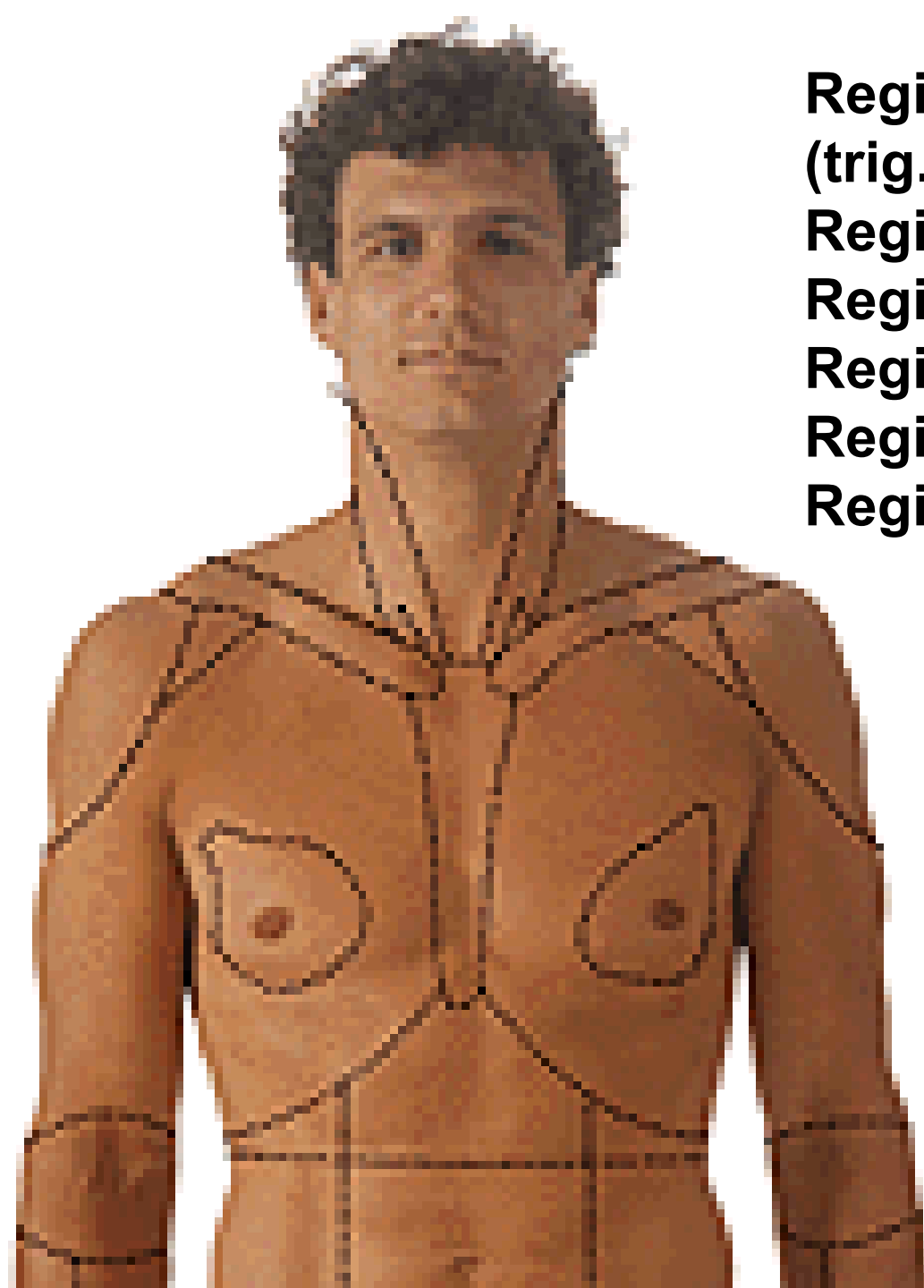
Regio pectoralis

Regio axillaris

Regio mammaria

Regio sternalis

Regio hypochondriaca dx. et sin.





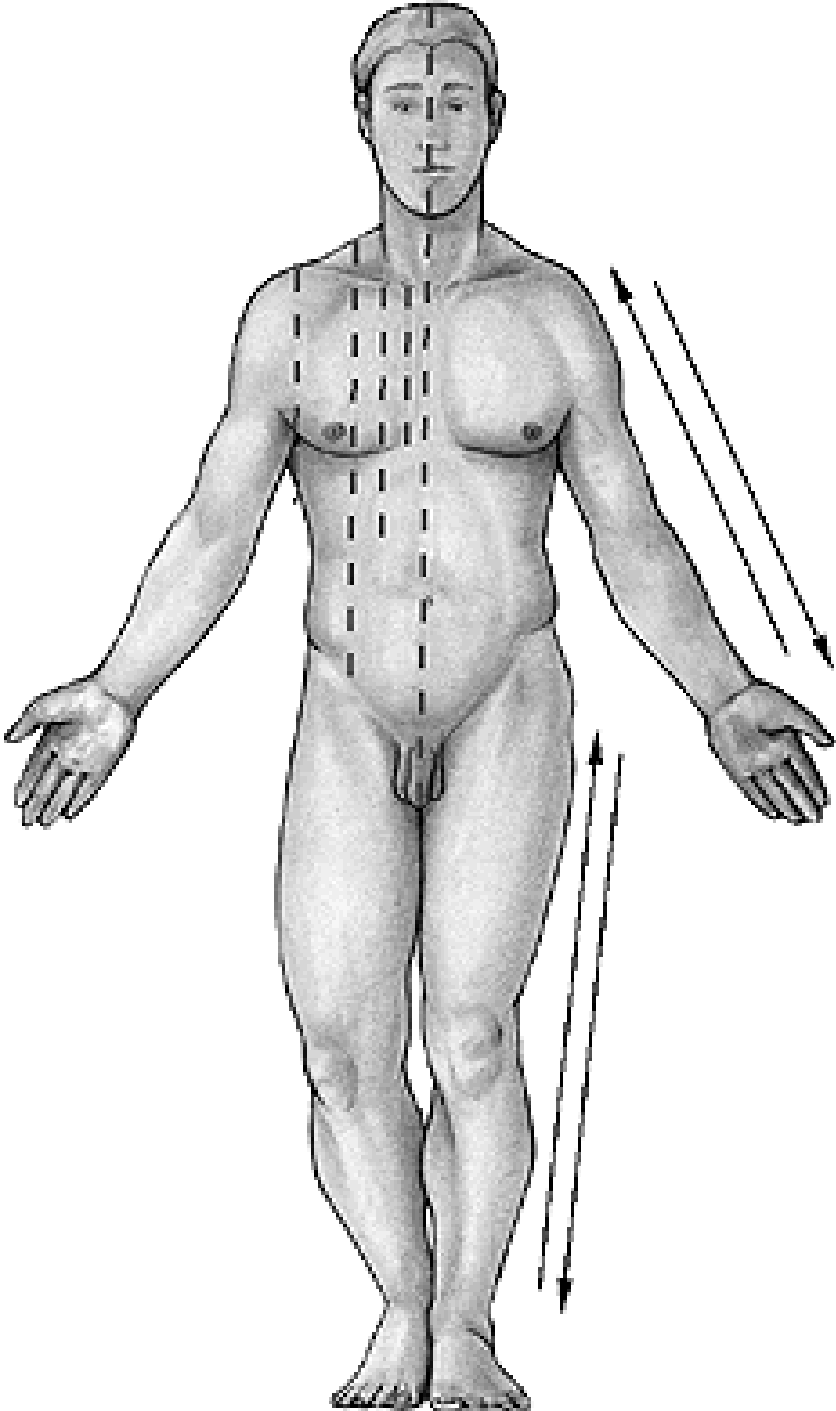
Regio vertebralis

Regio suprascapularis

Regio scapularis

Regio infrascapularis

Regio axillaris



Linea mediana anterior

Linea sternalis

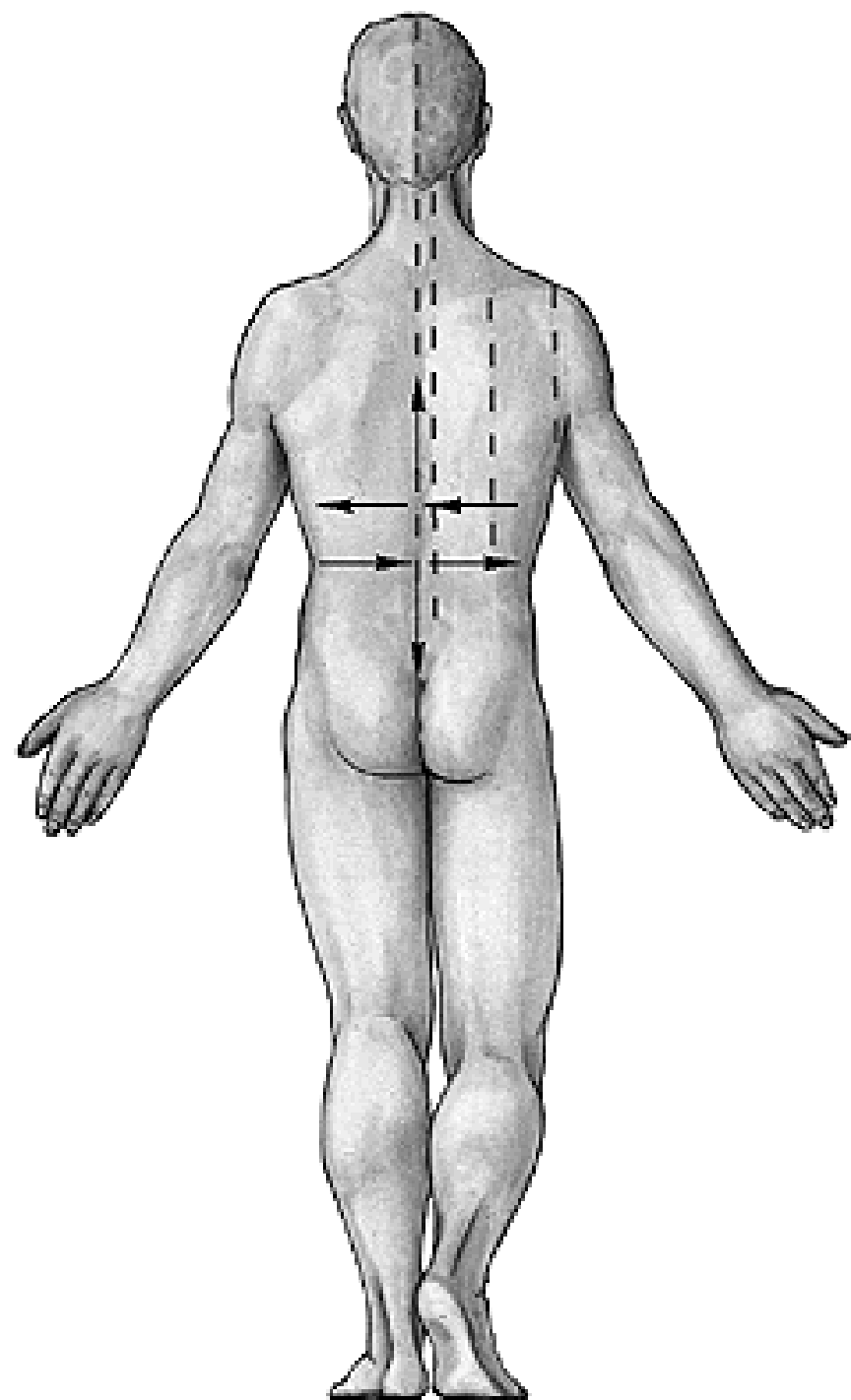
Linea parasternalis

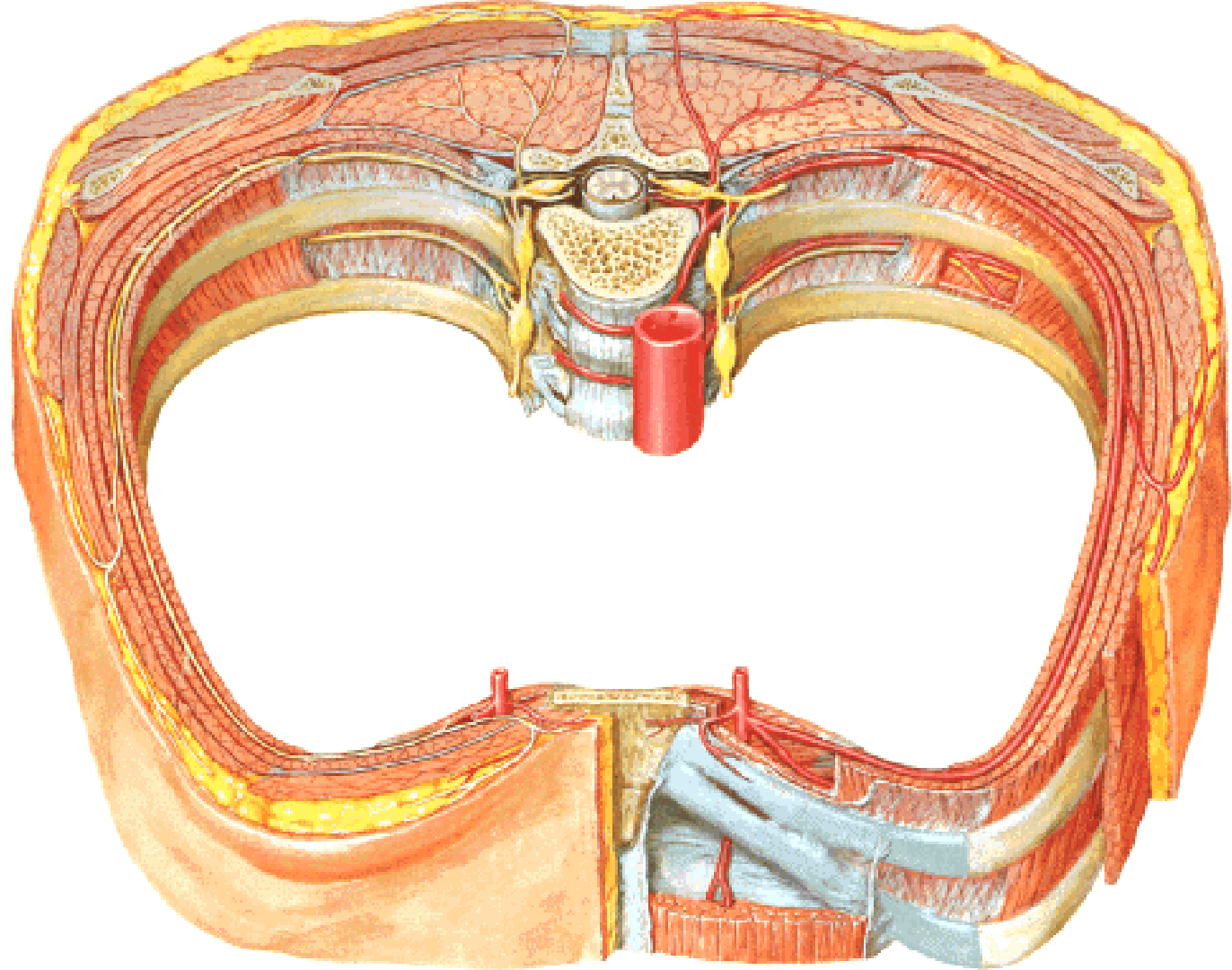
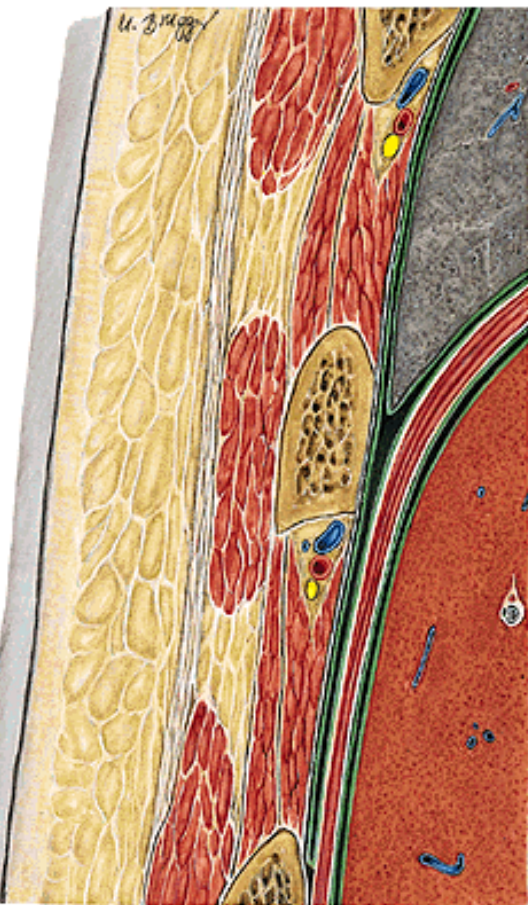
Linea medioclavicularis

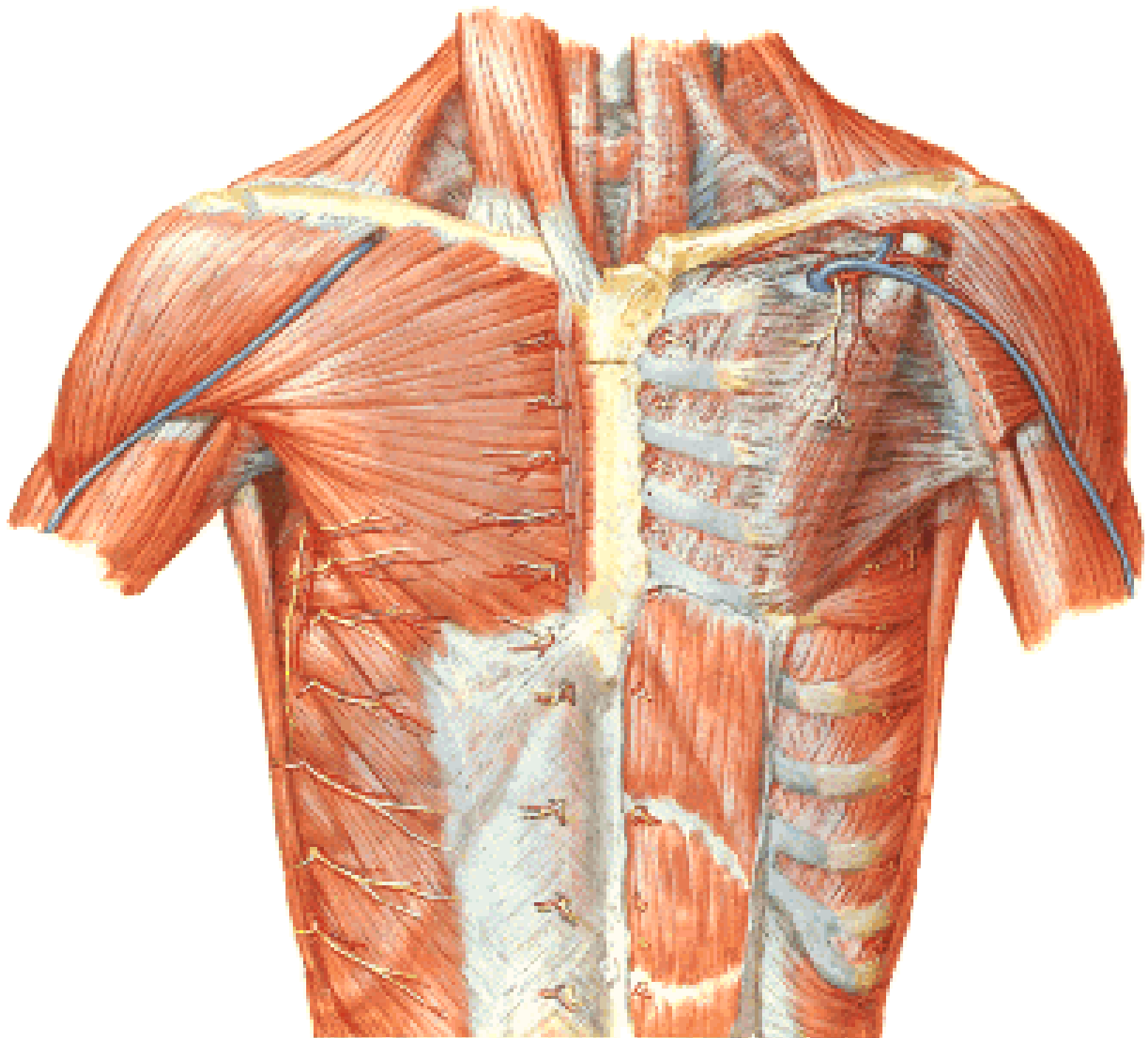
Linea axillaris ant.

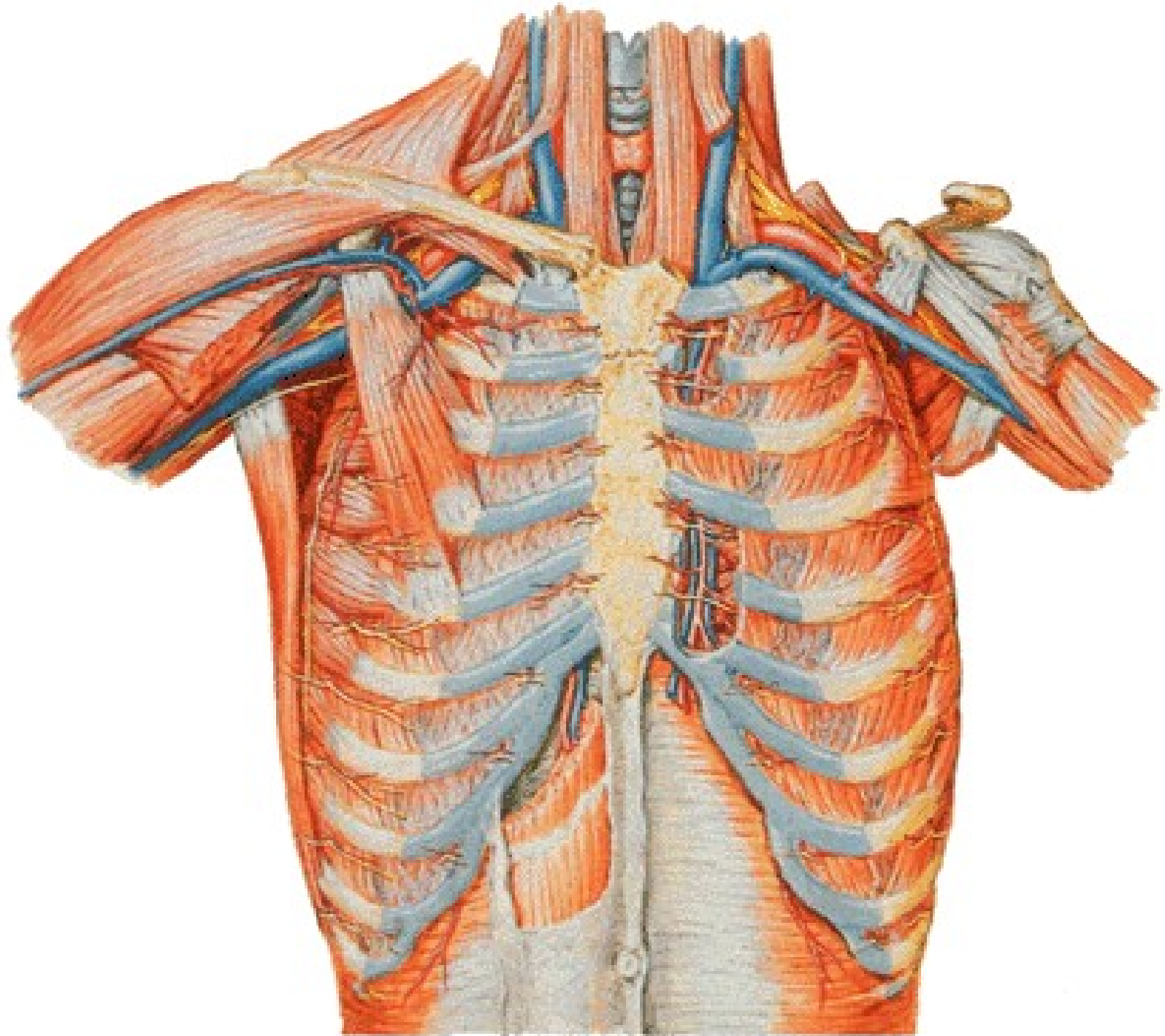
Linea axillaris media

Linea axillaris post.
Linea scapularis
Linea paravertebralis
Linea mediana post.

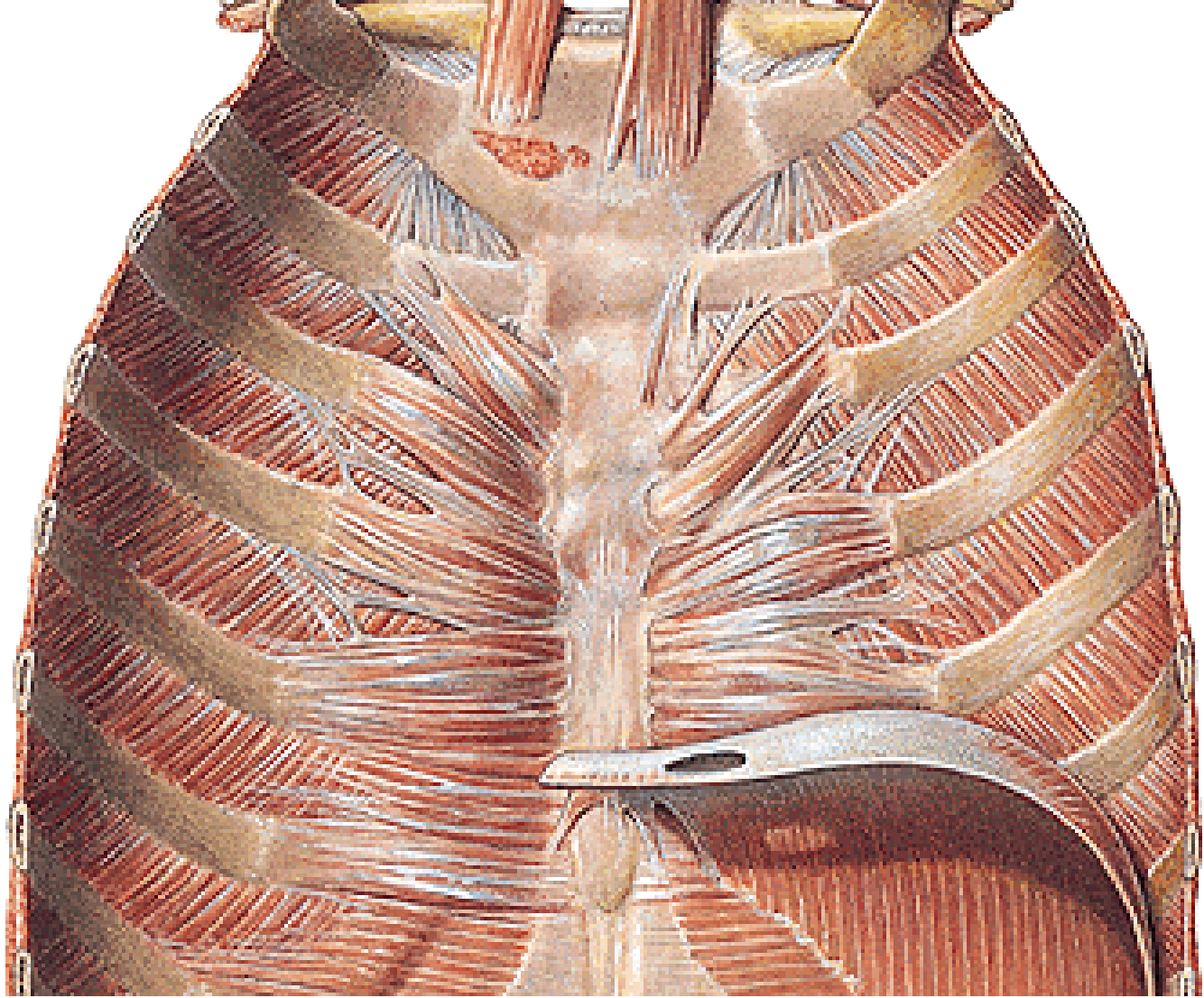
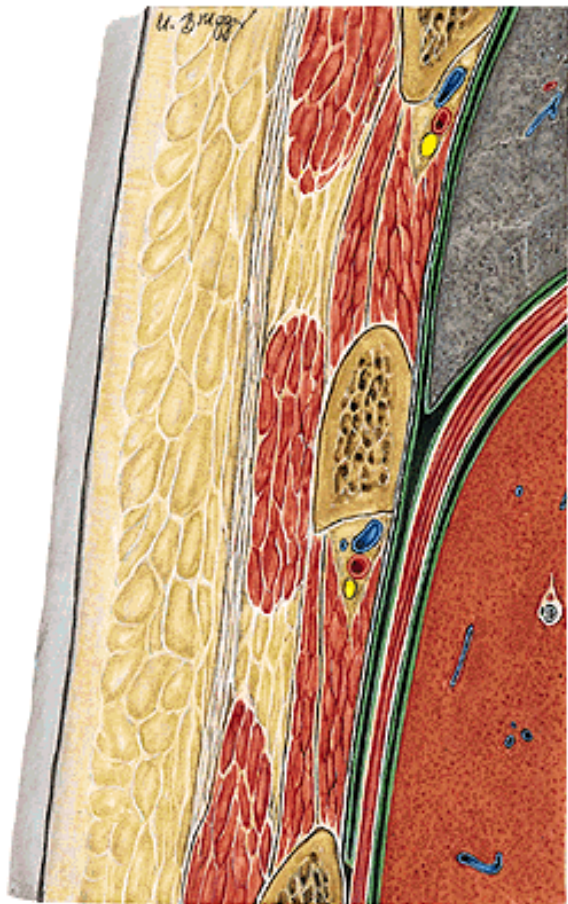



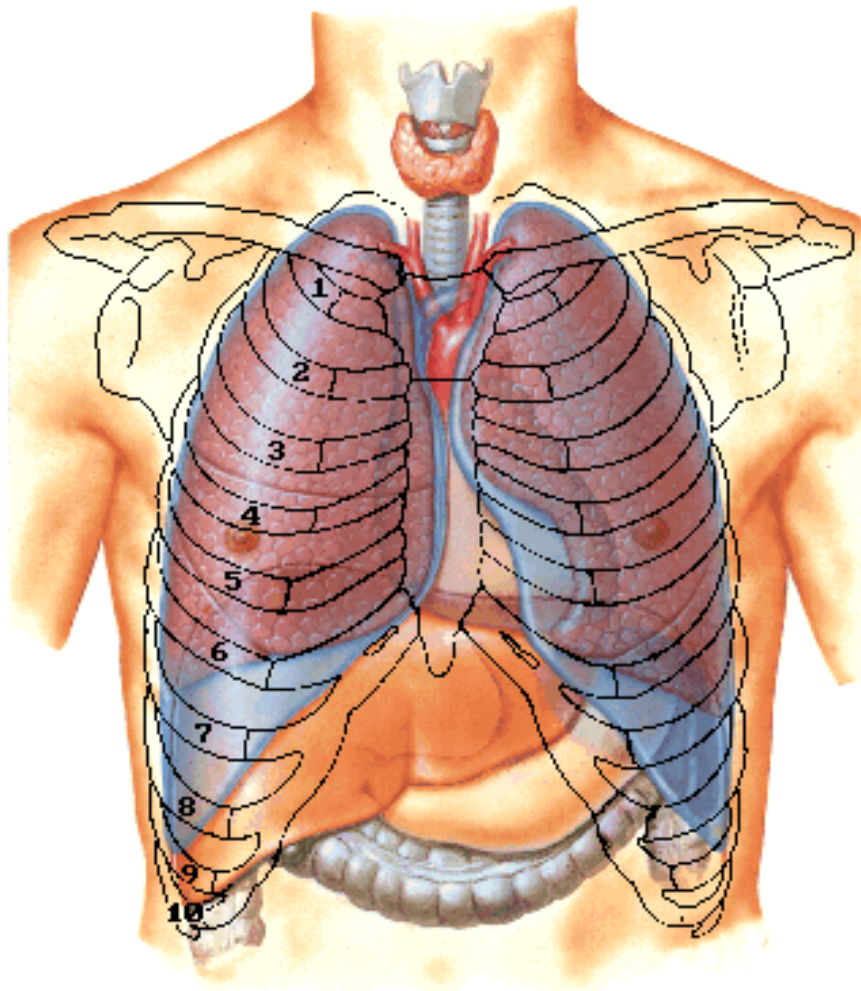




VAN



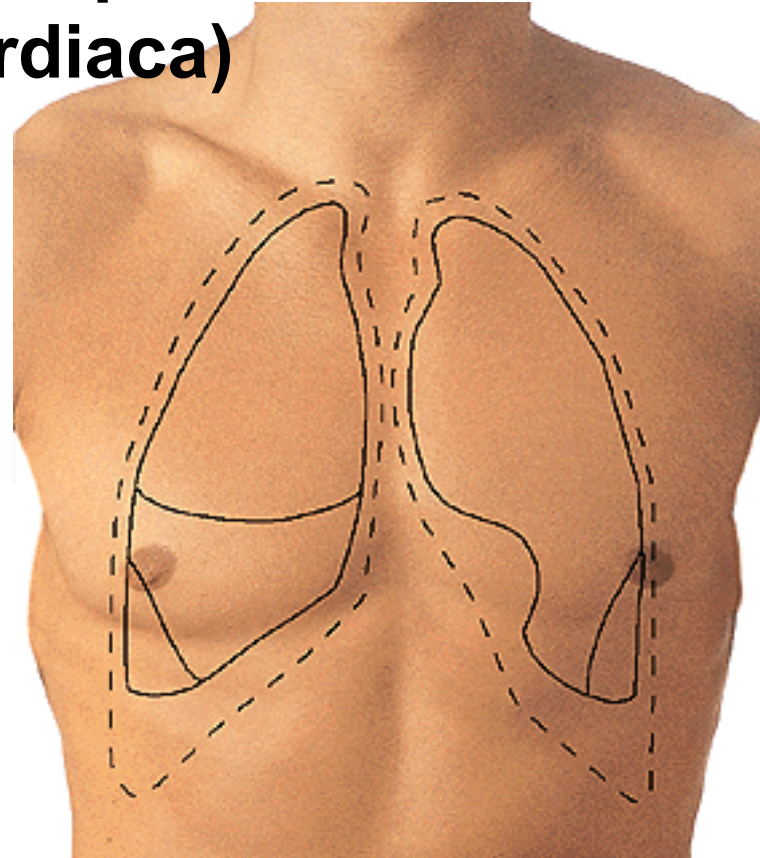
**PROJECTION OF ORGANS
ONTO THE THORACIC WALL**

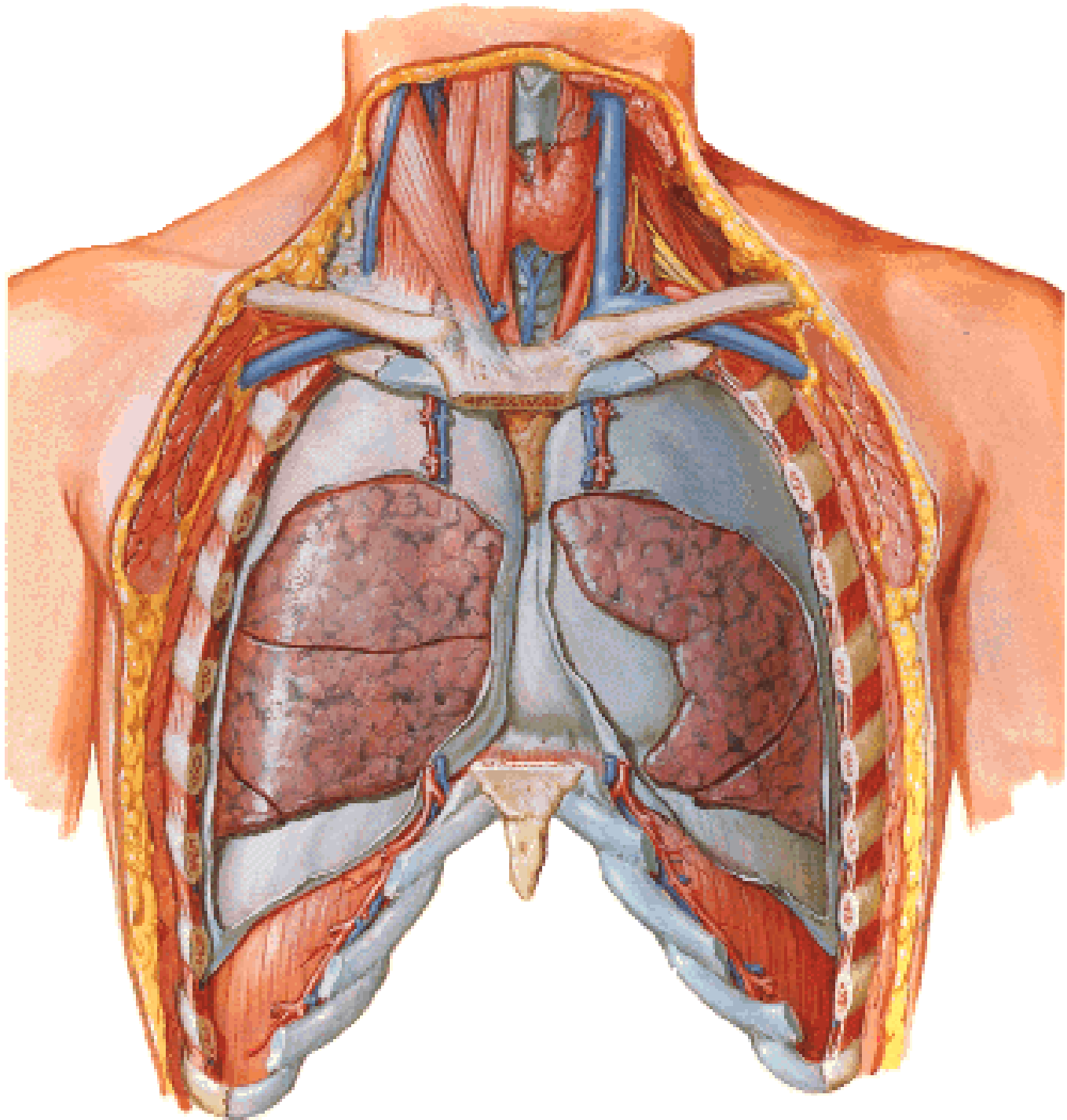


**Cupula pleurae
= Apex pulmonis**

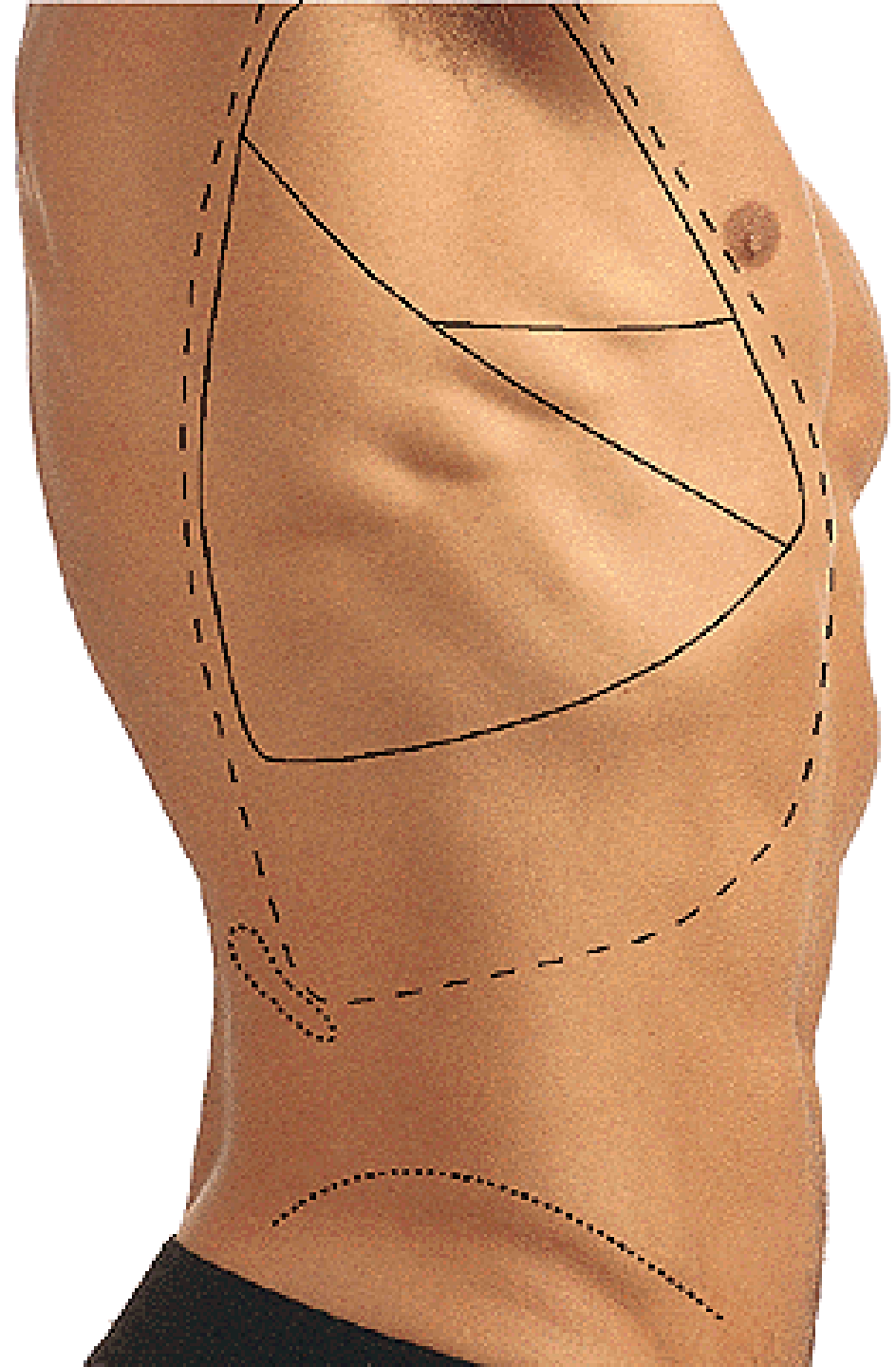
**Area interpleuralis sup.
(thymica)**

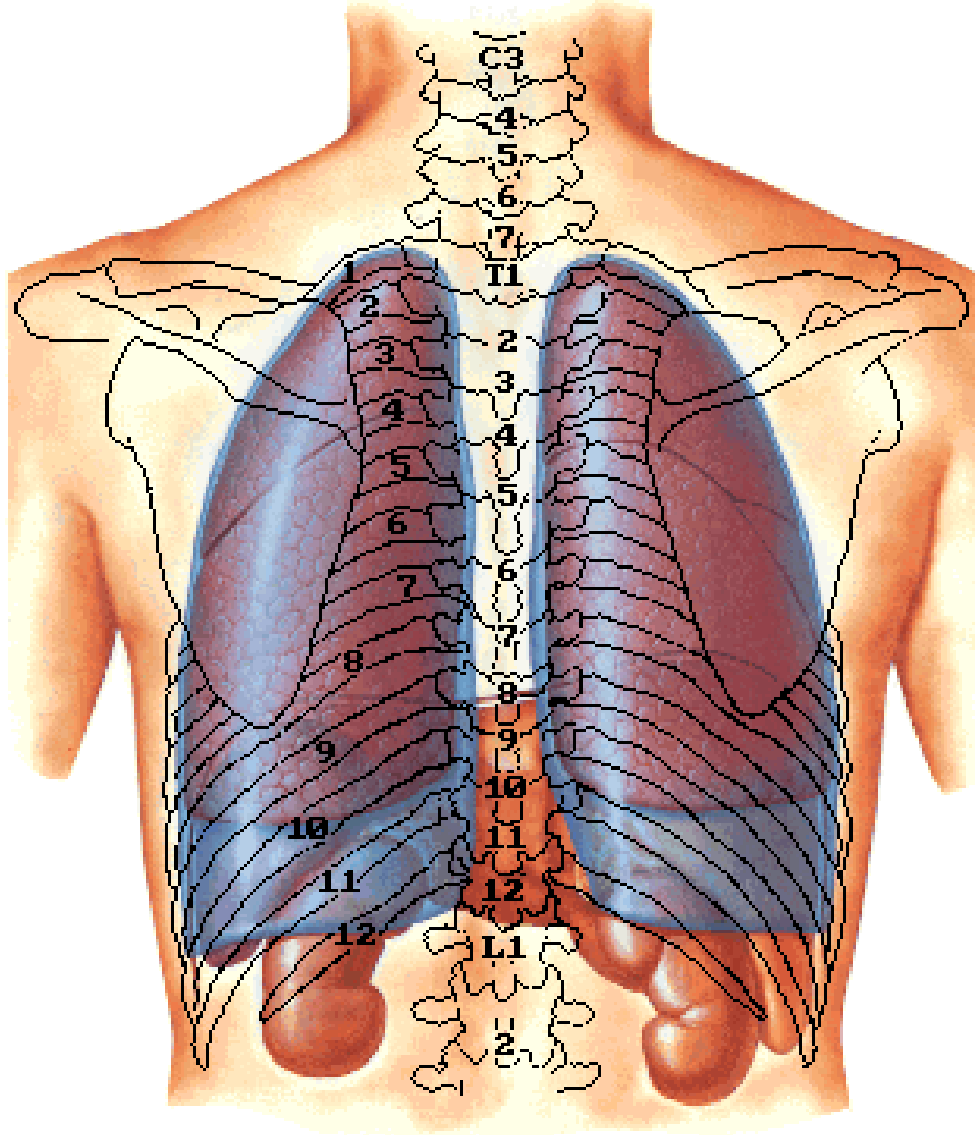
**Area interpleuralis inf.
(pericardiaca)**

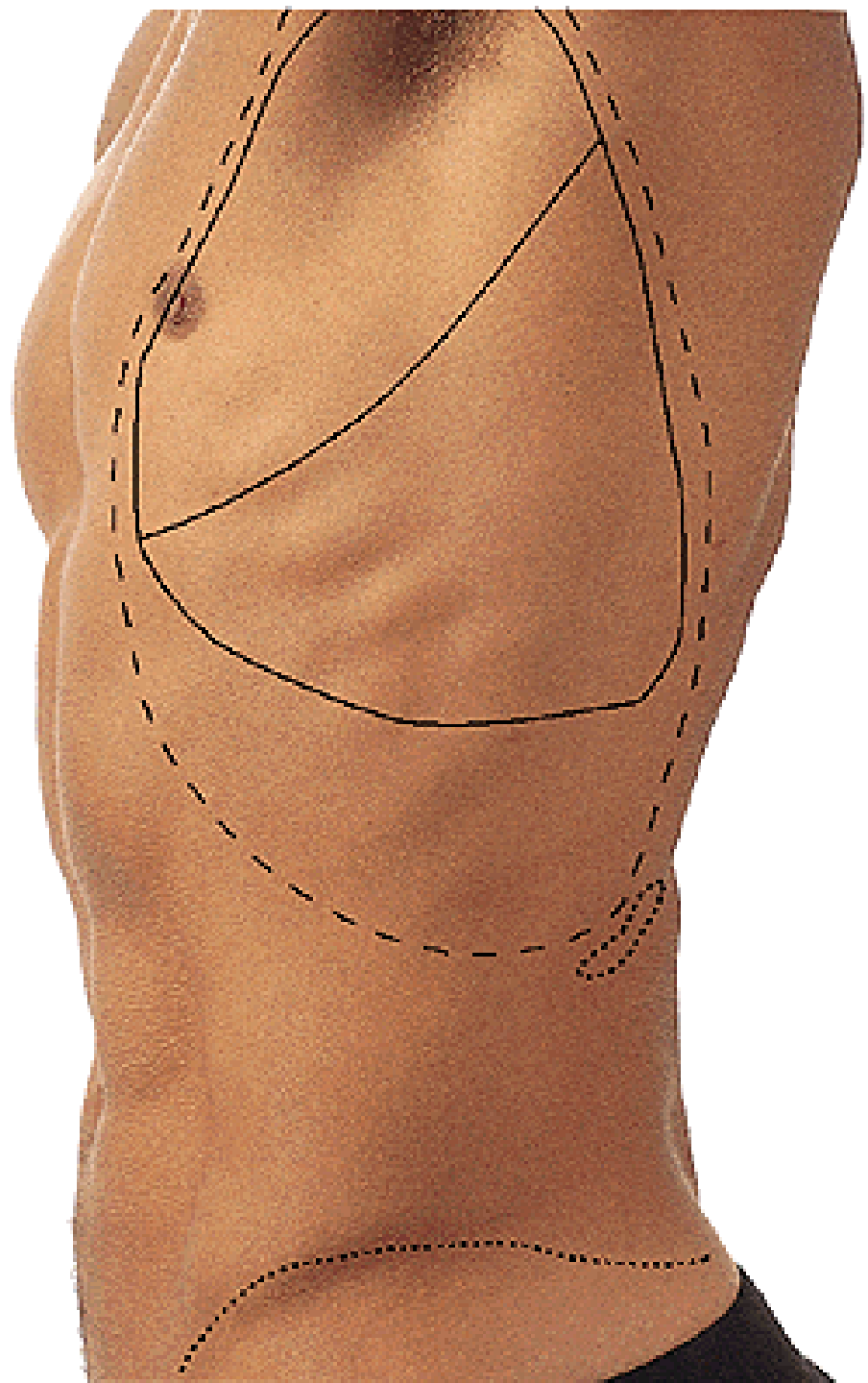


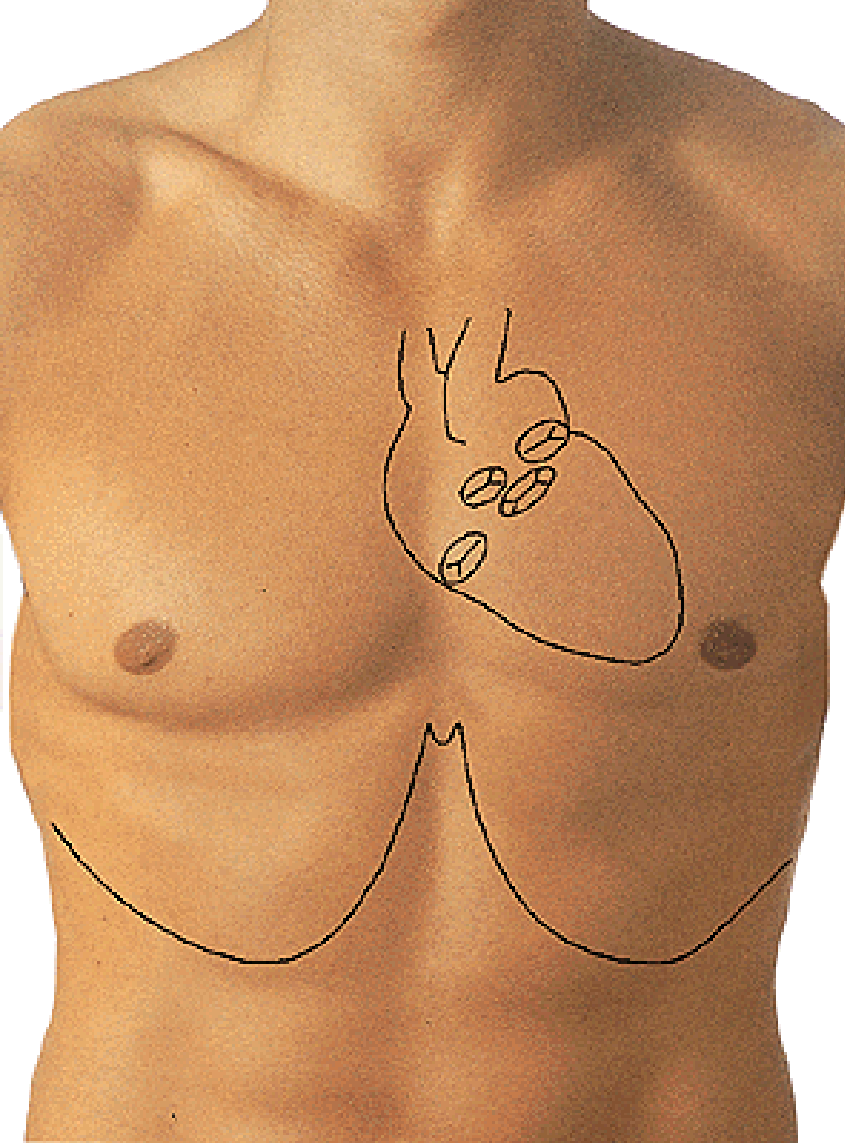


Fissura obliqua
Fissura horizontalis







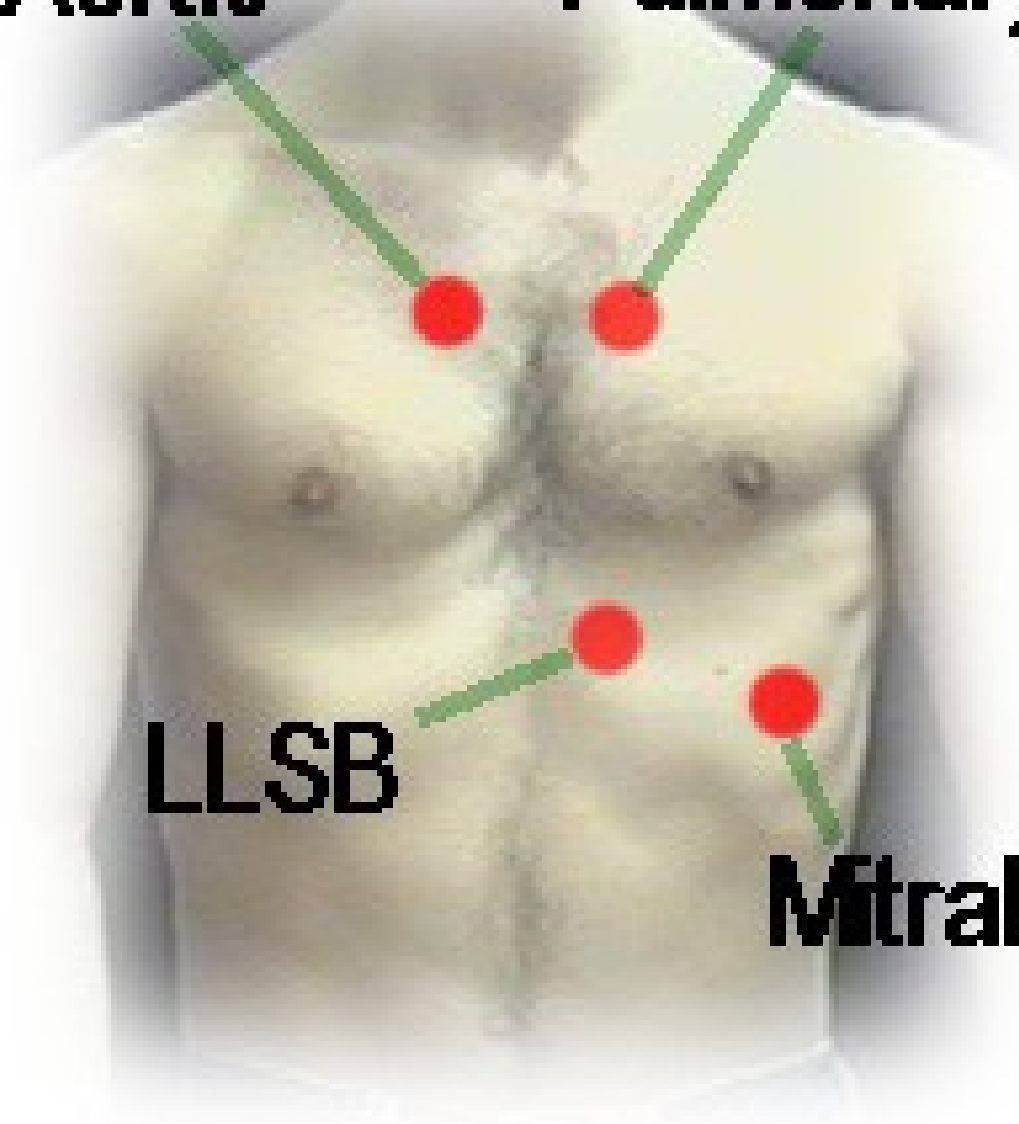


Aortic

Pulmonary

LLSB

Mitral



MEDIASTINUM

Sternal angle

