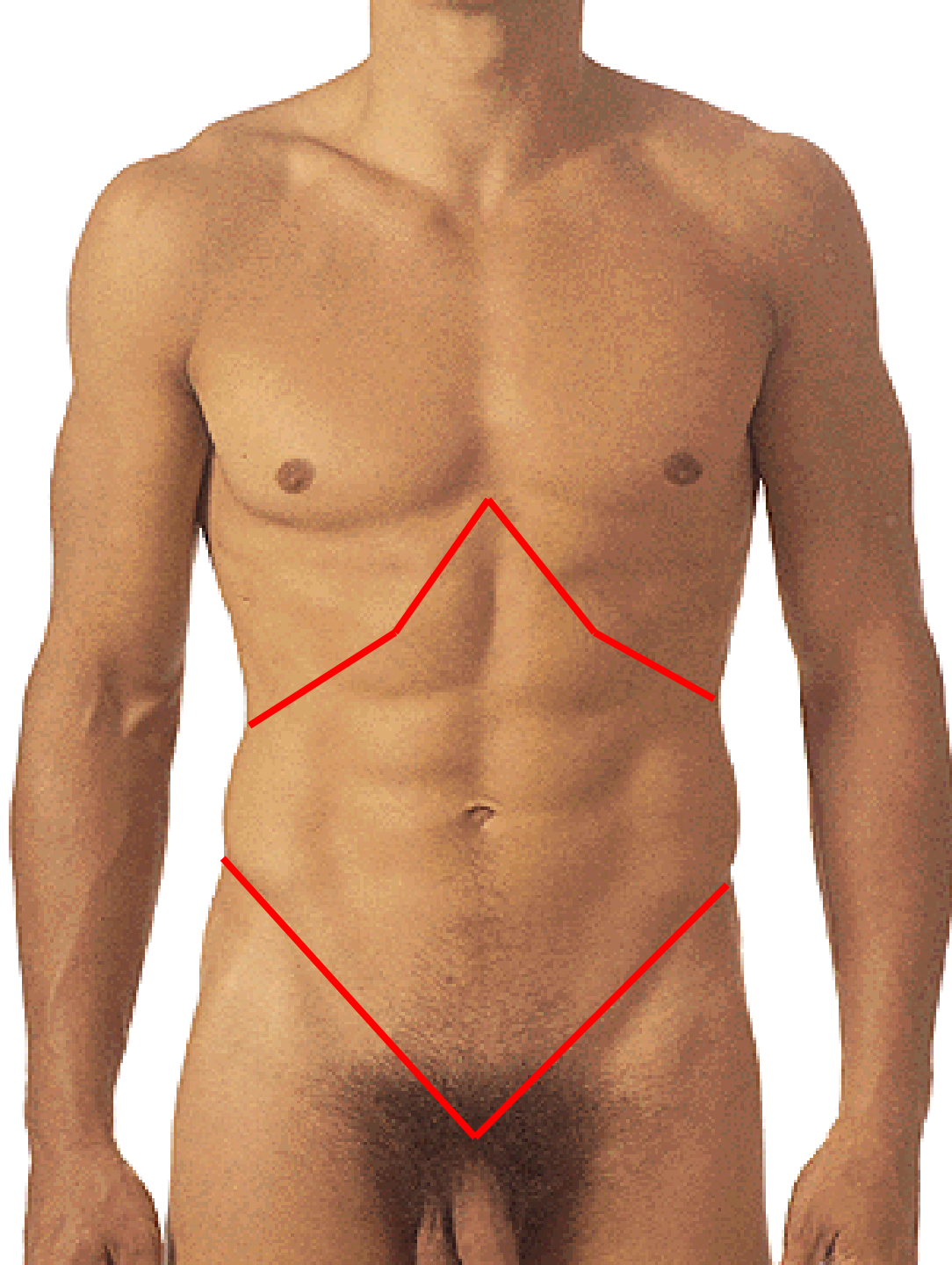
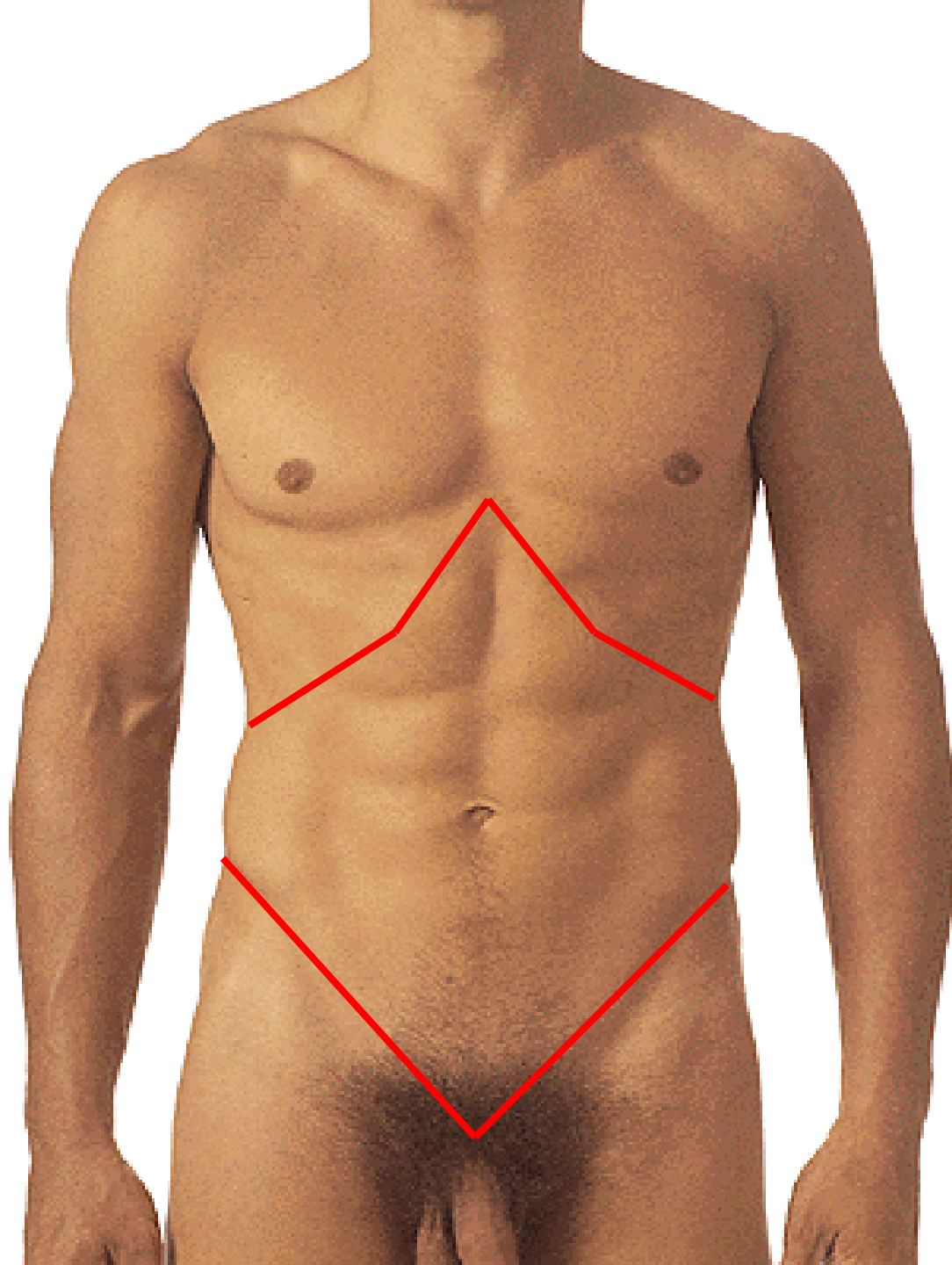
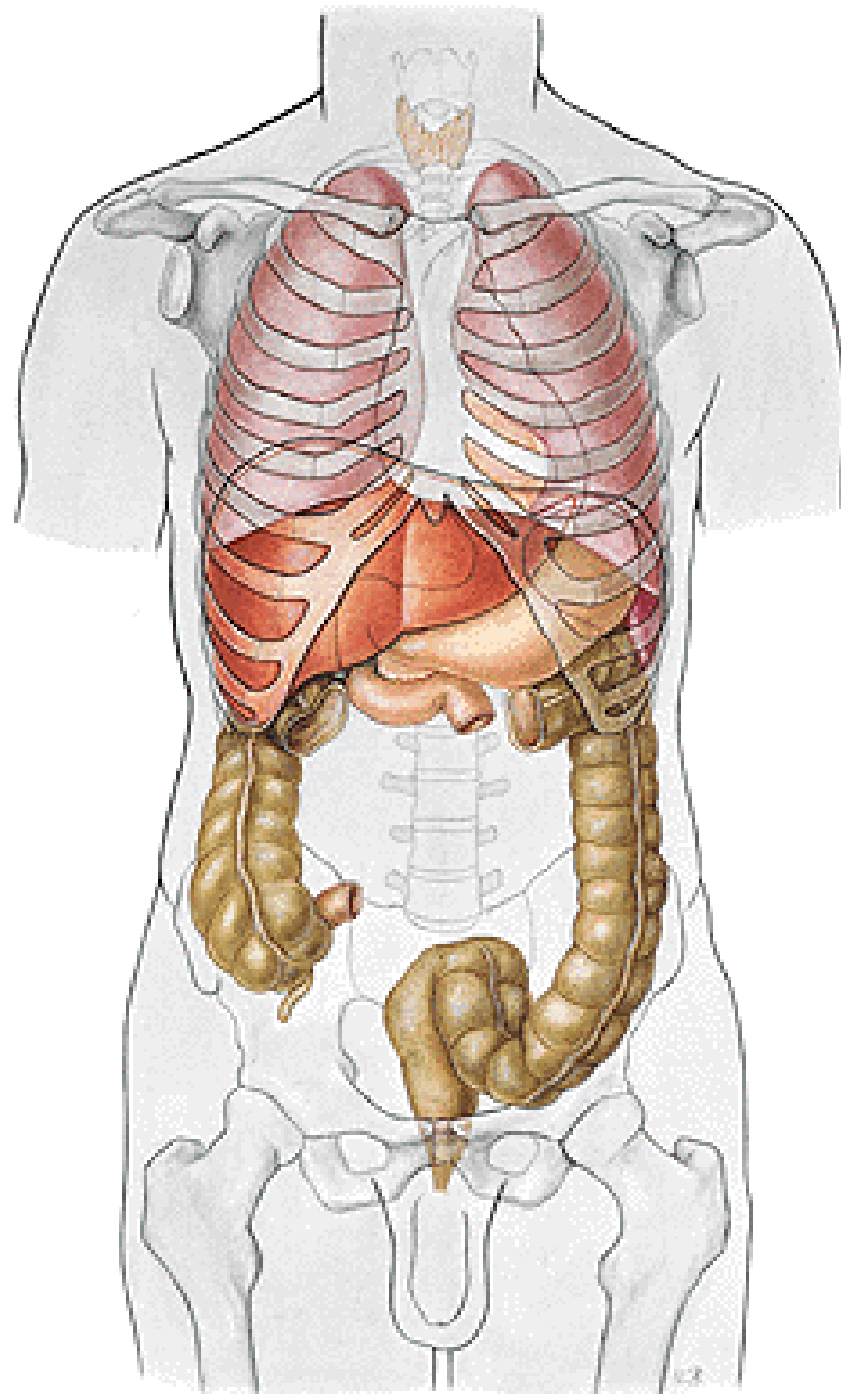


# **REGIONAL ANATOMY OF THE ABDOMEN**

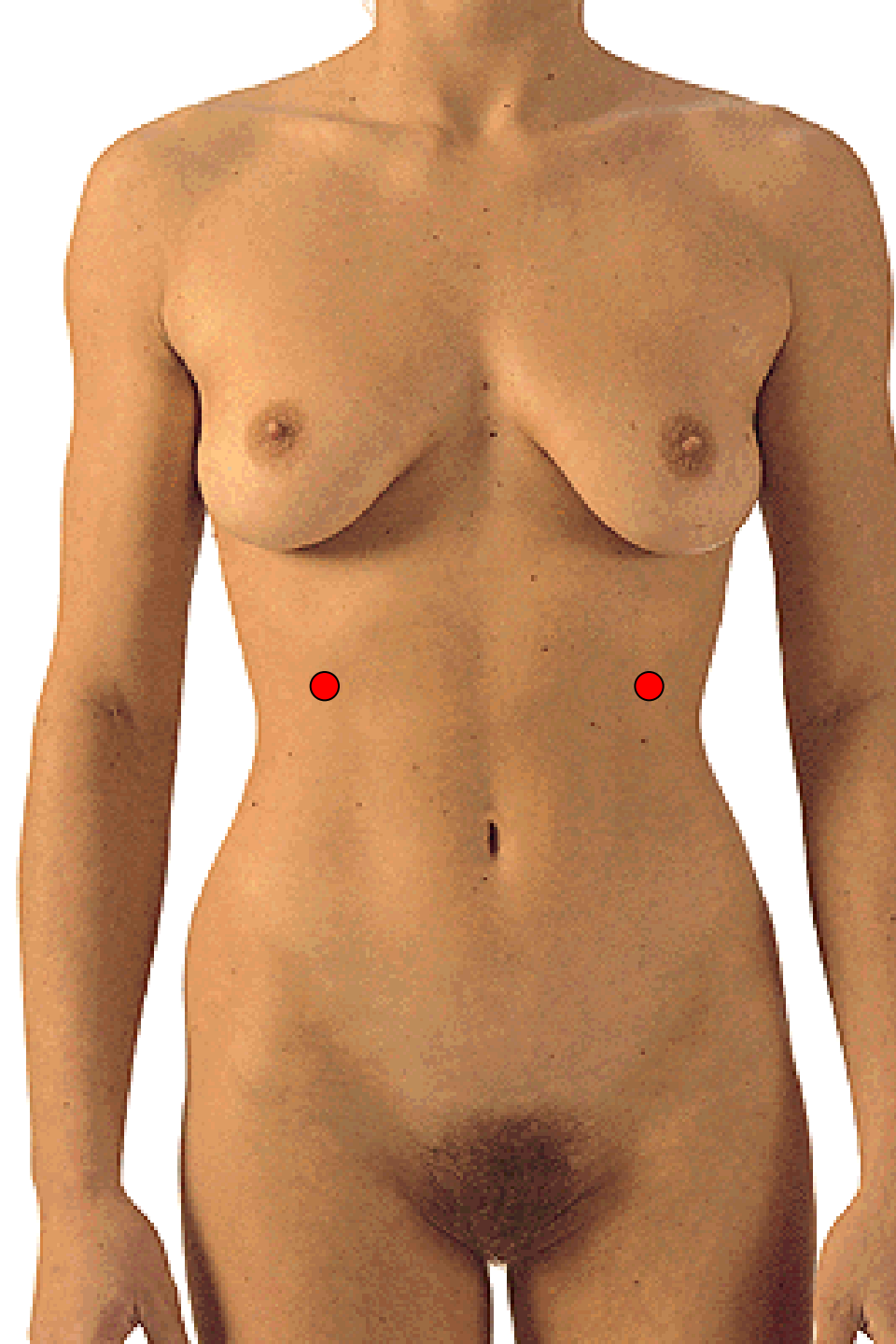
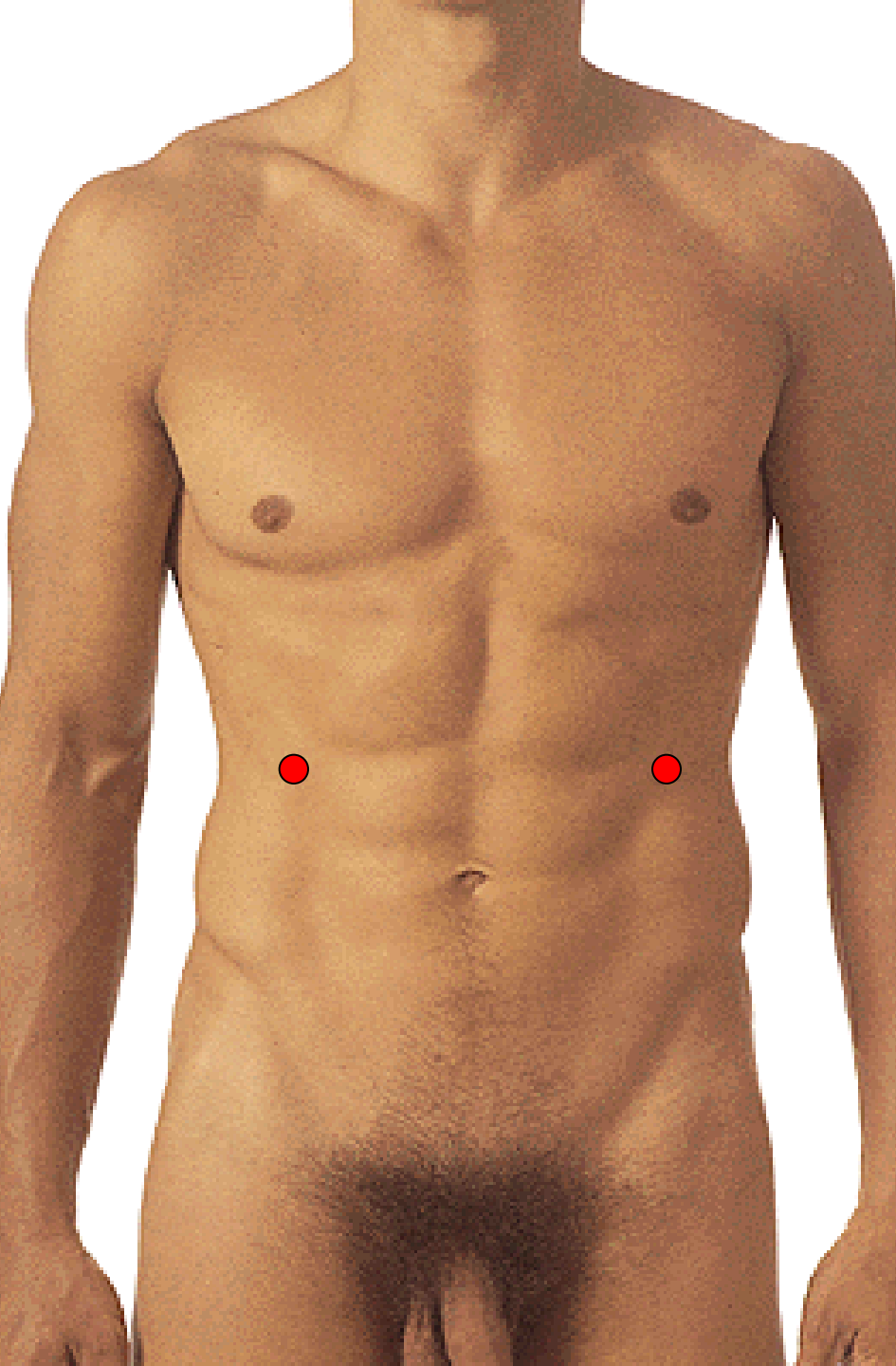
- Regions**
- Lines**
- Projection of organs**

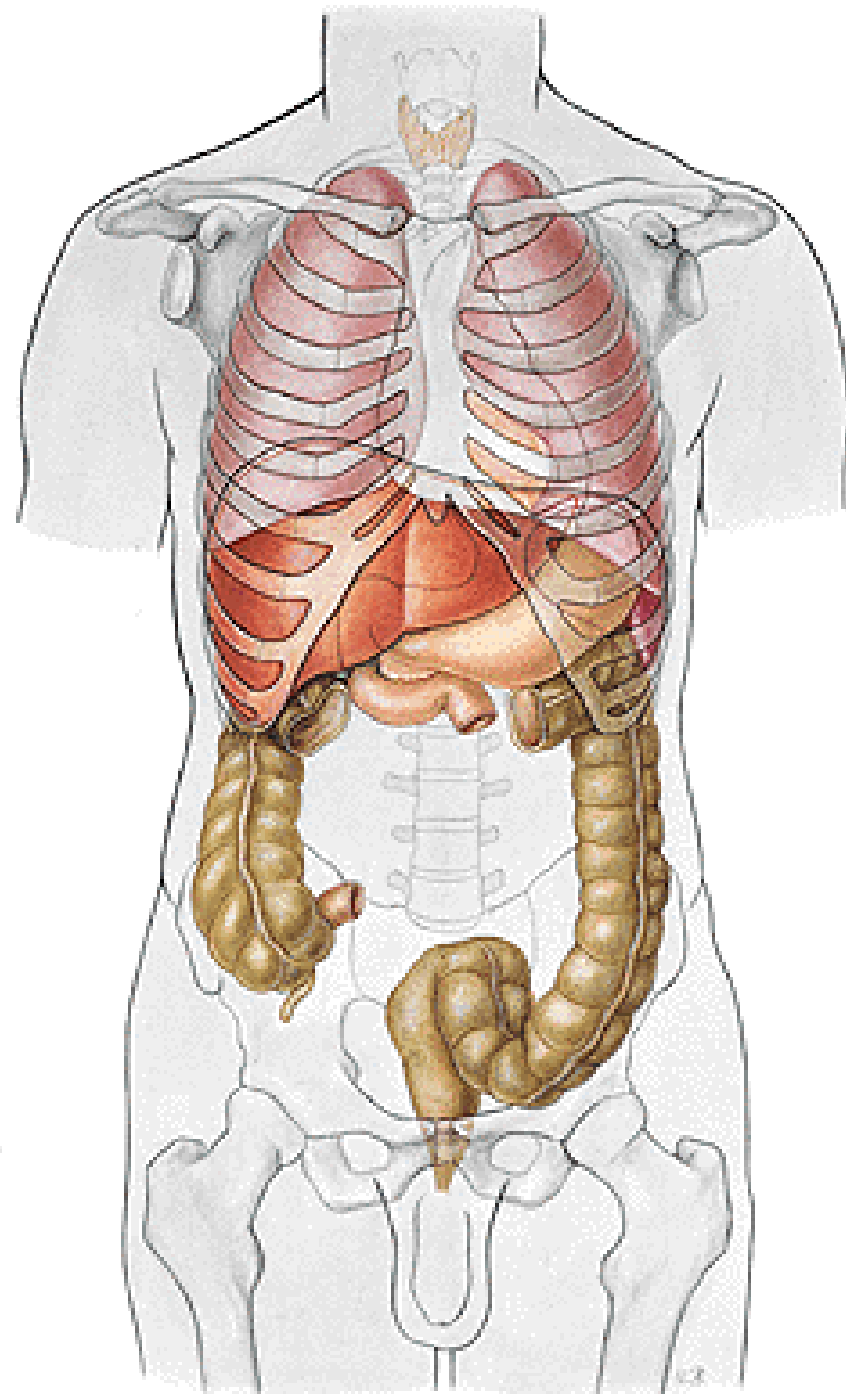


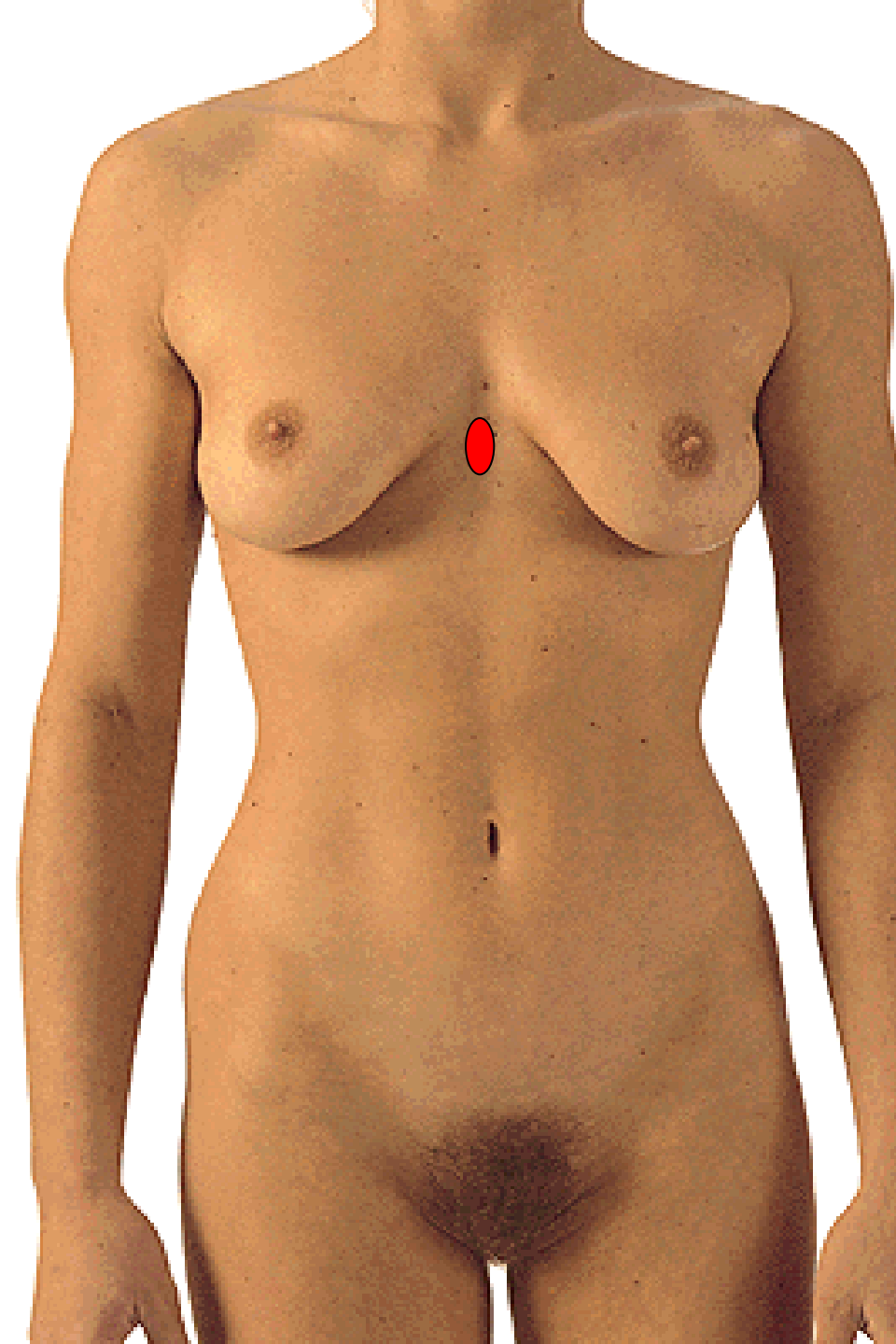
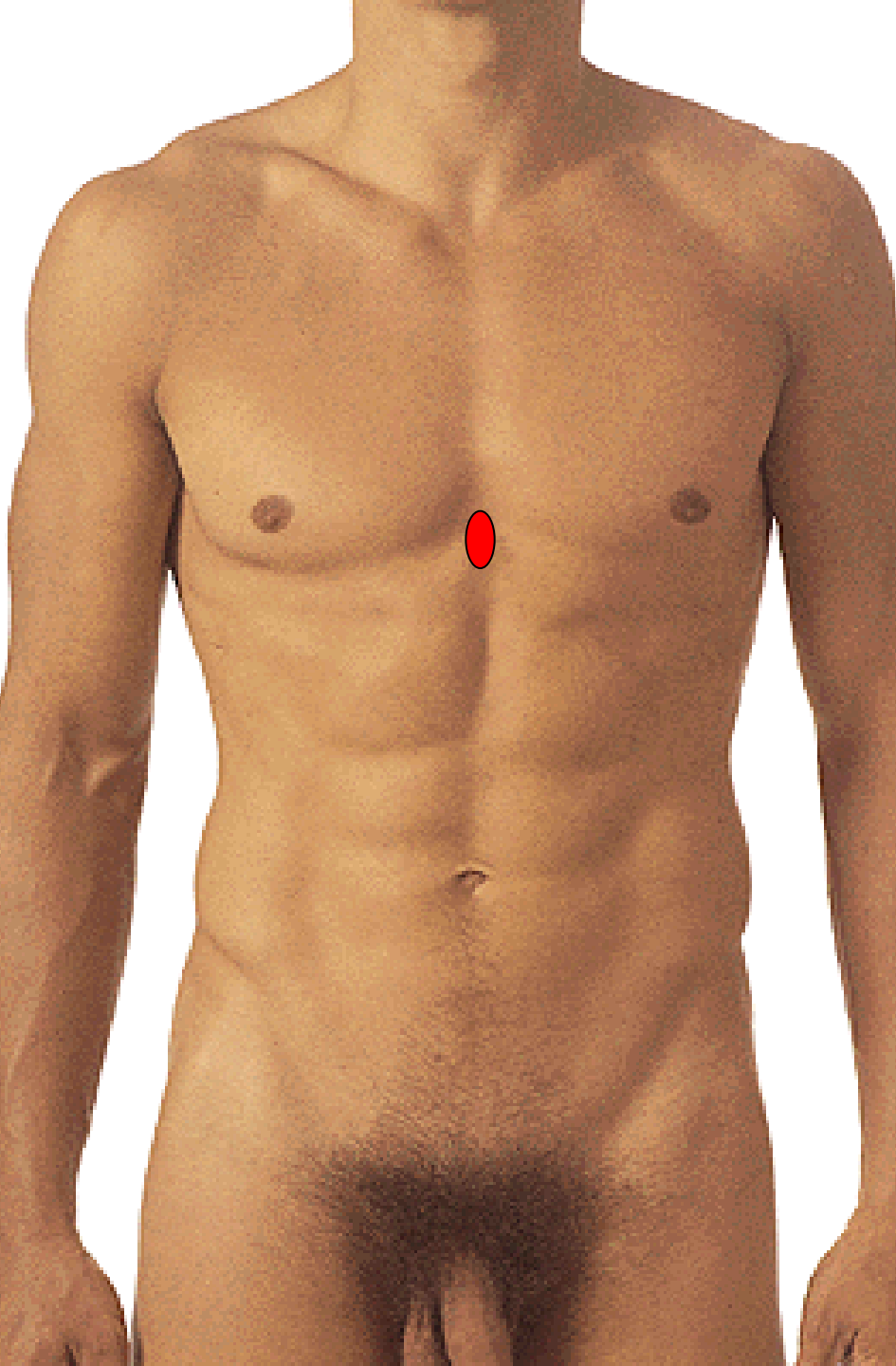




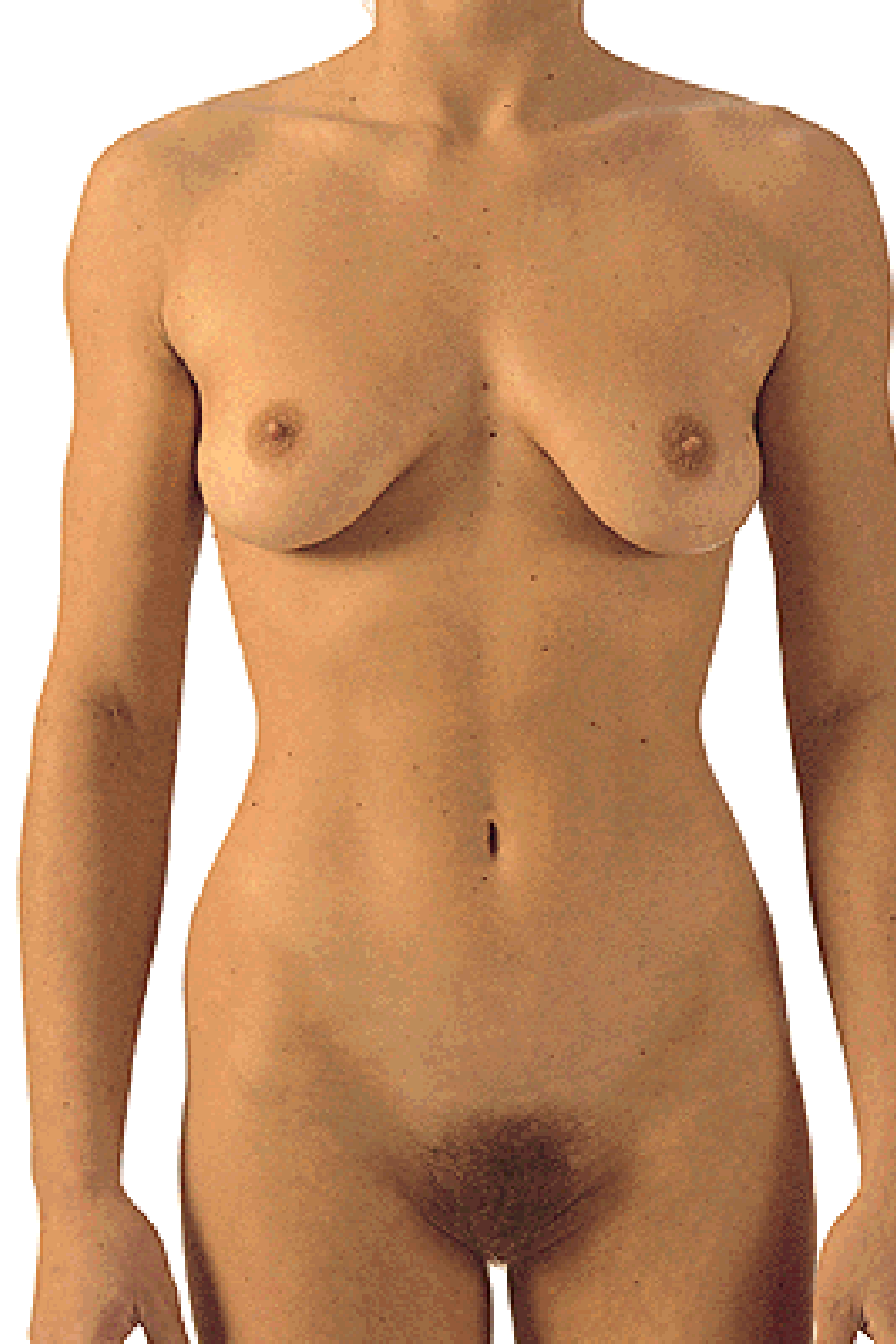
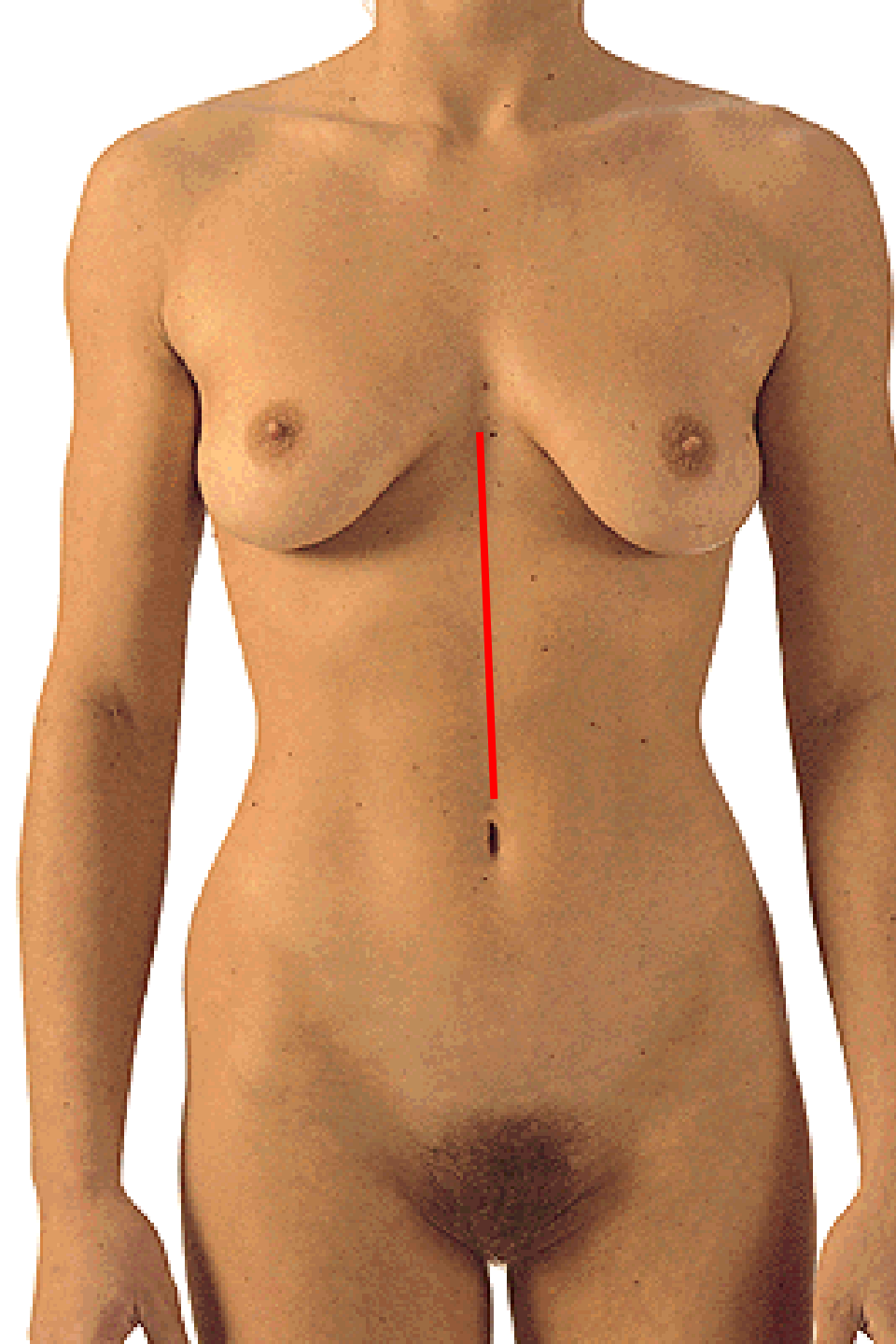
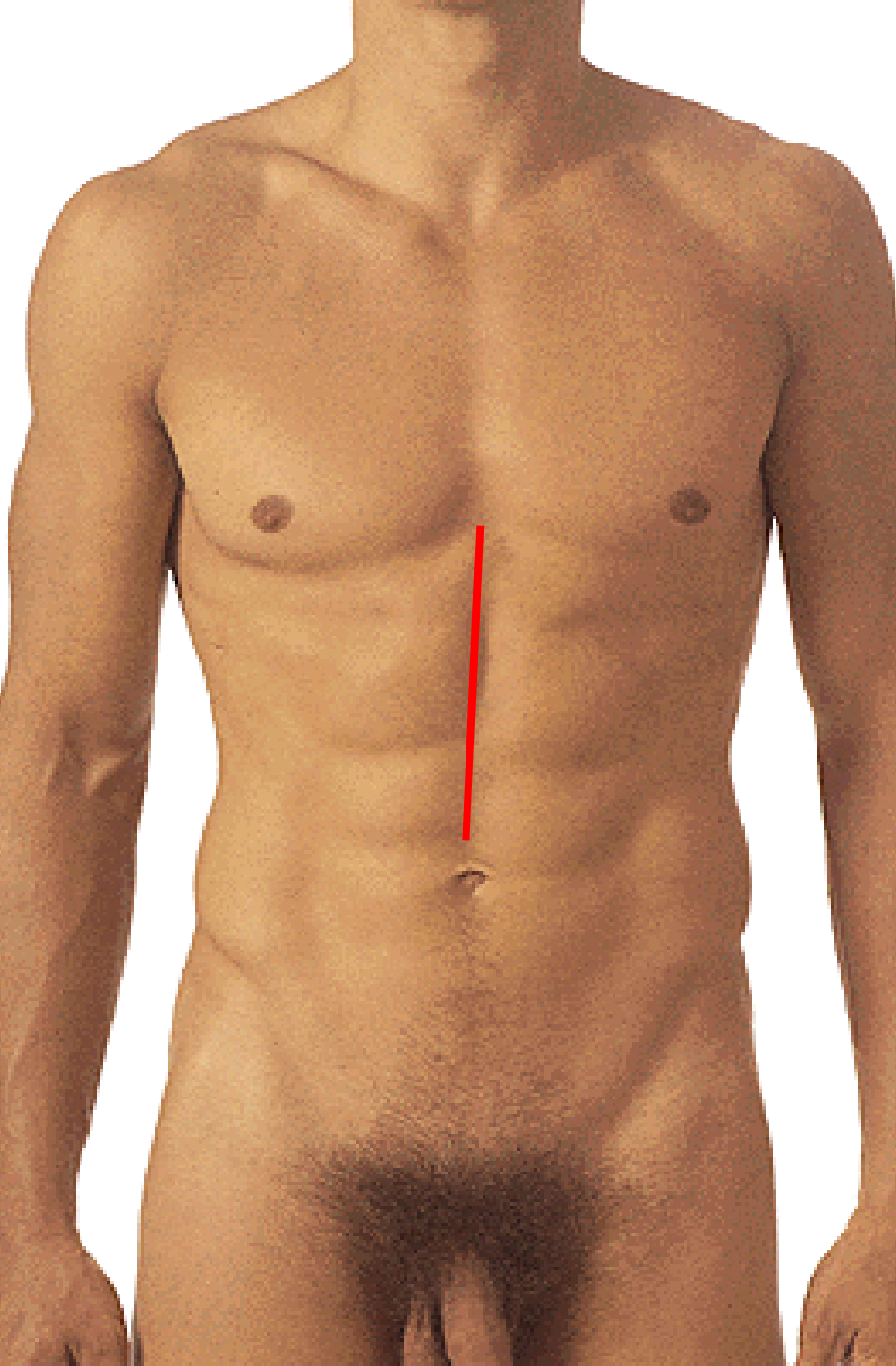


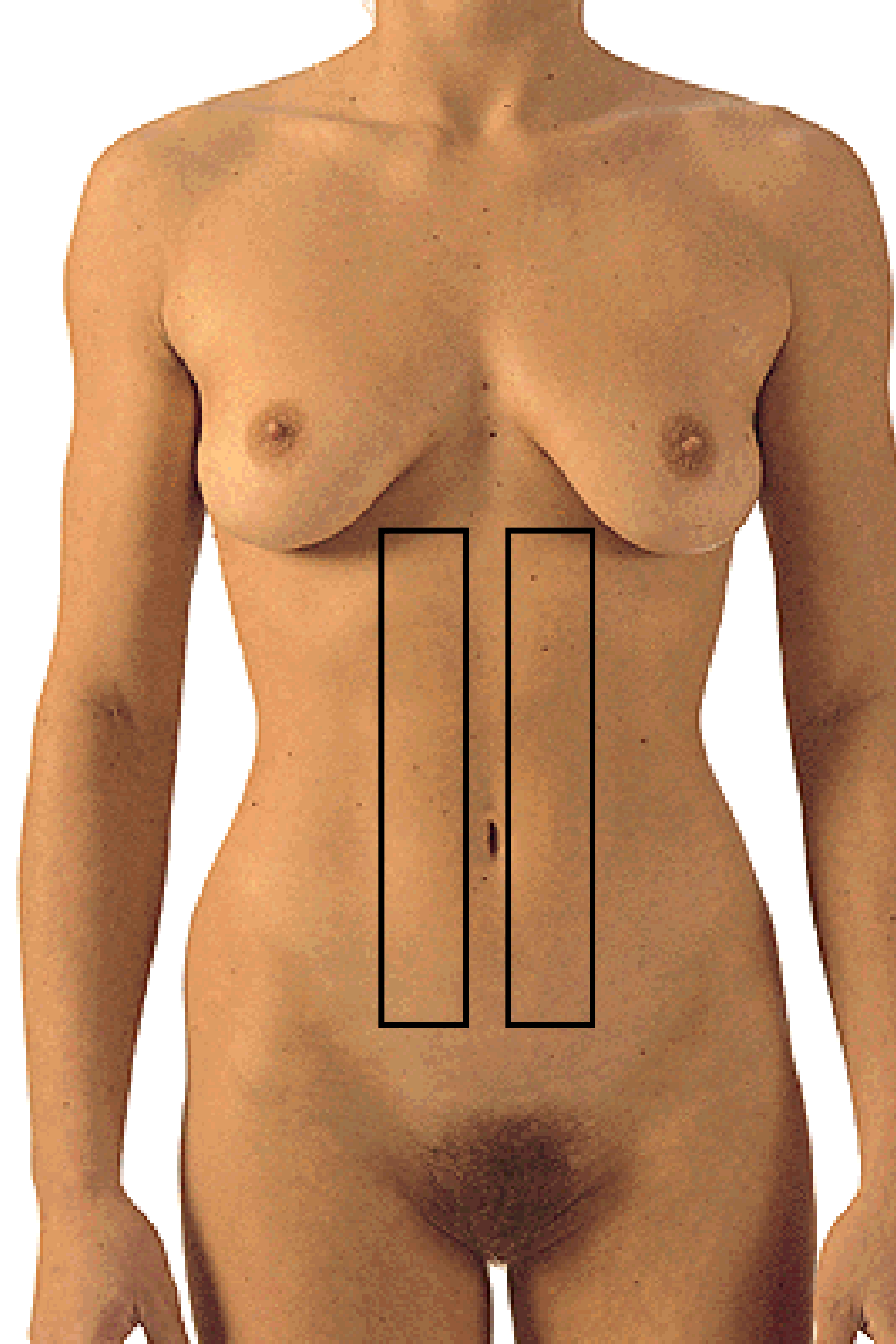
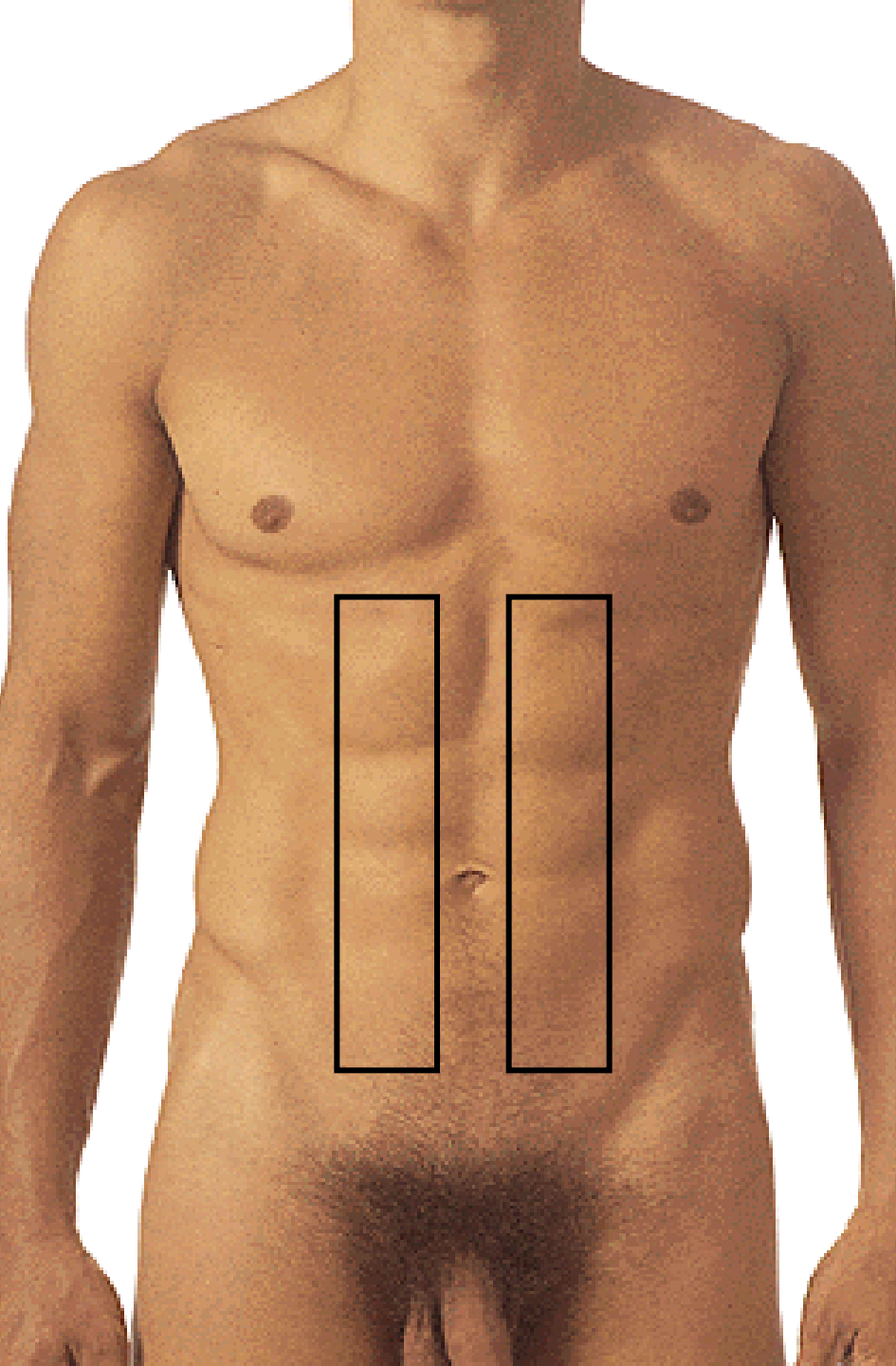


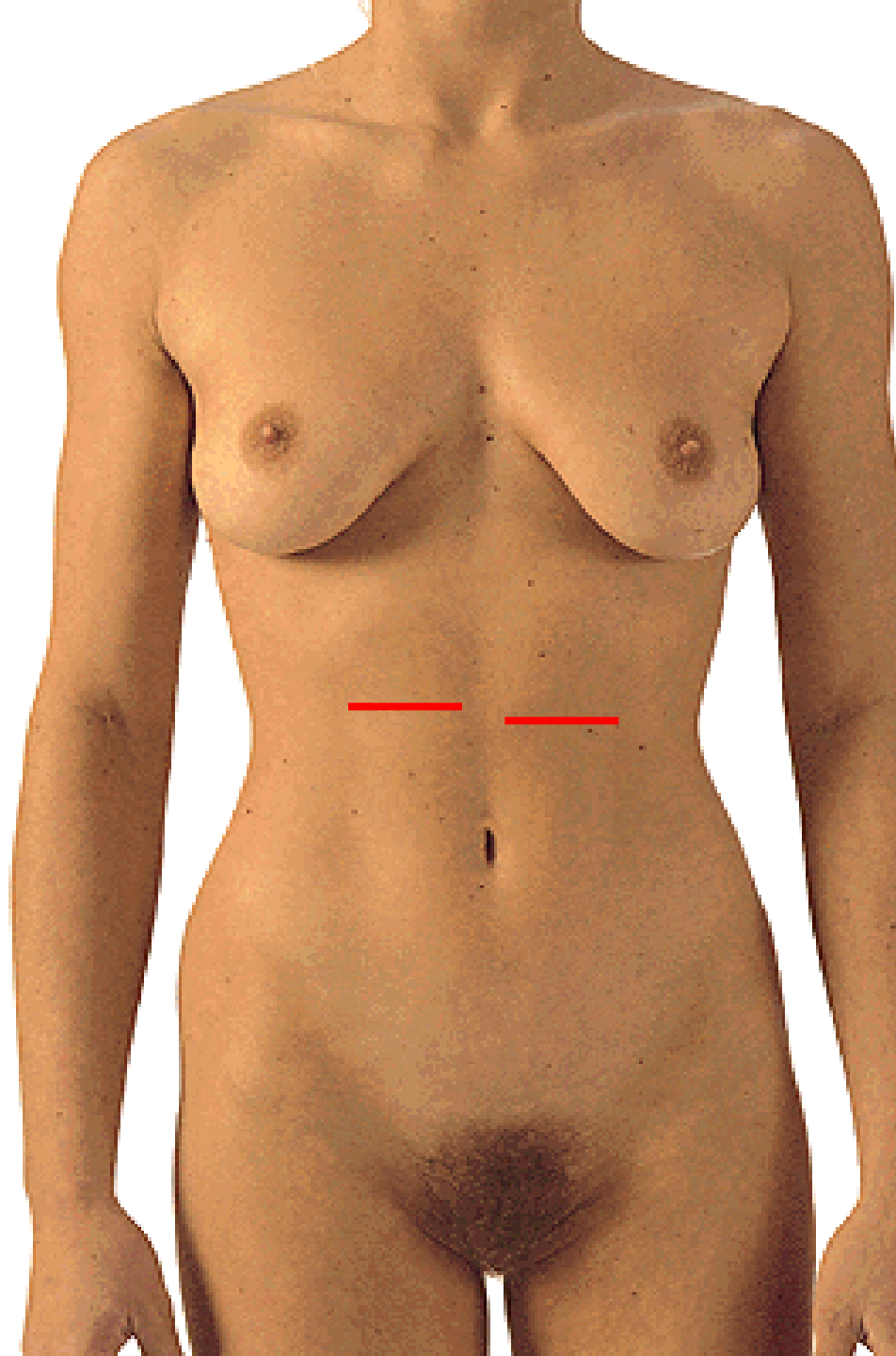
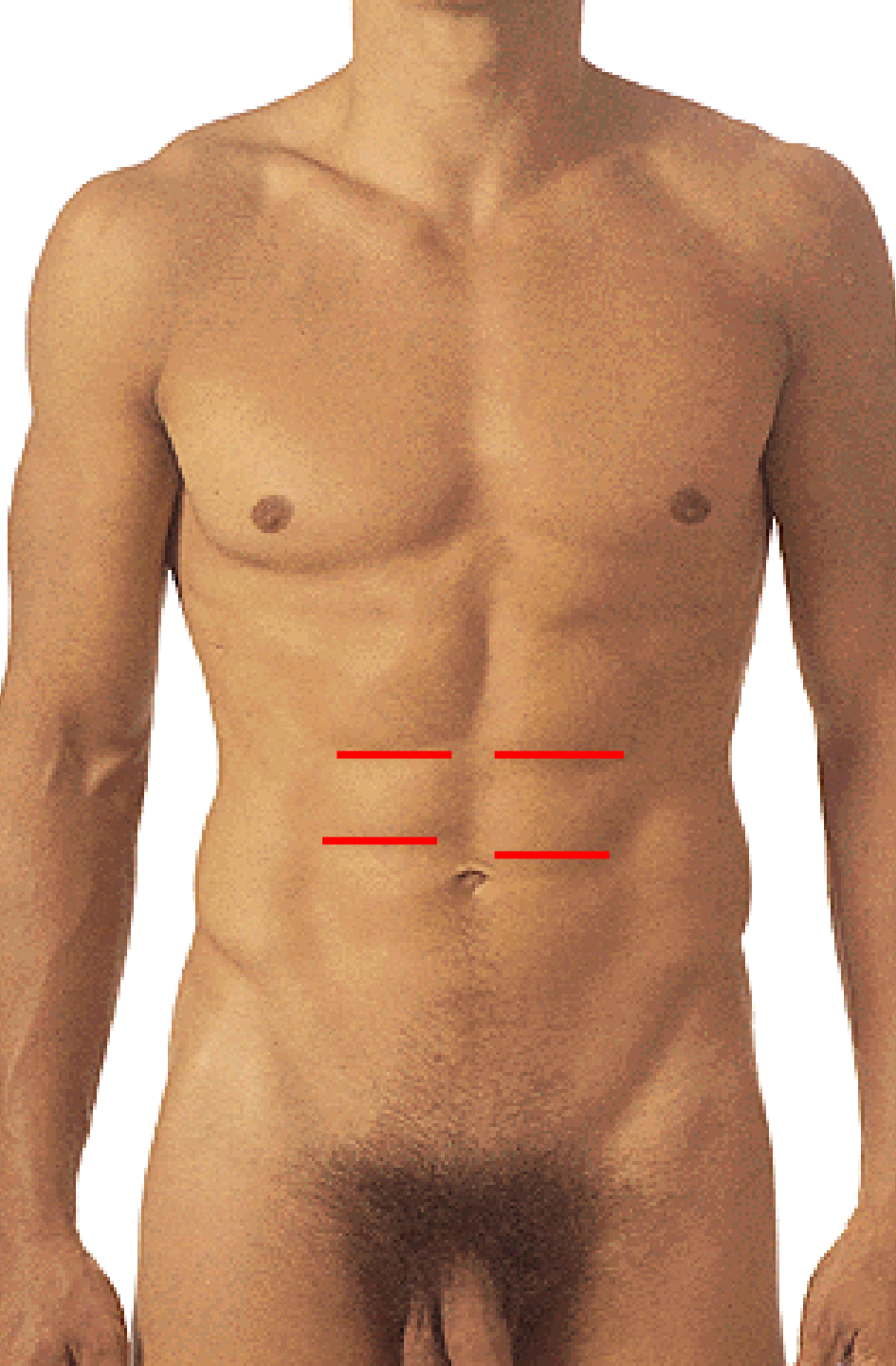


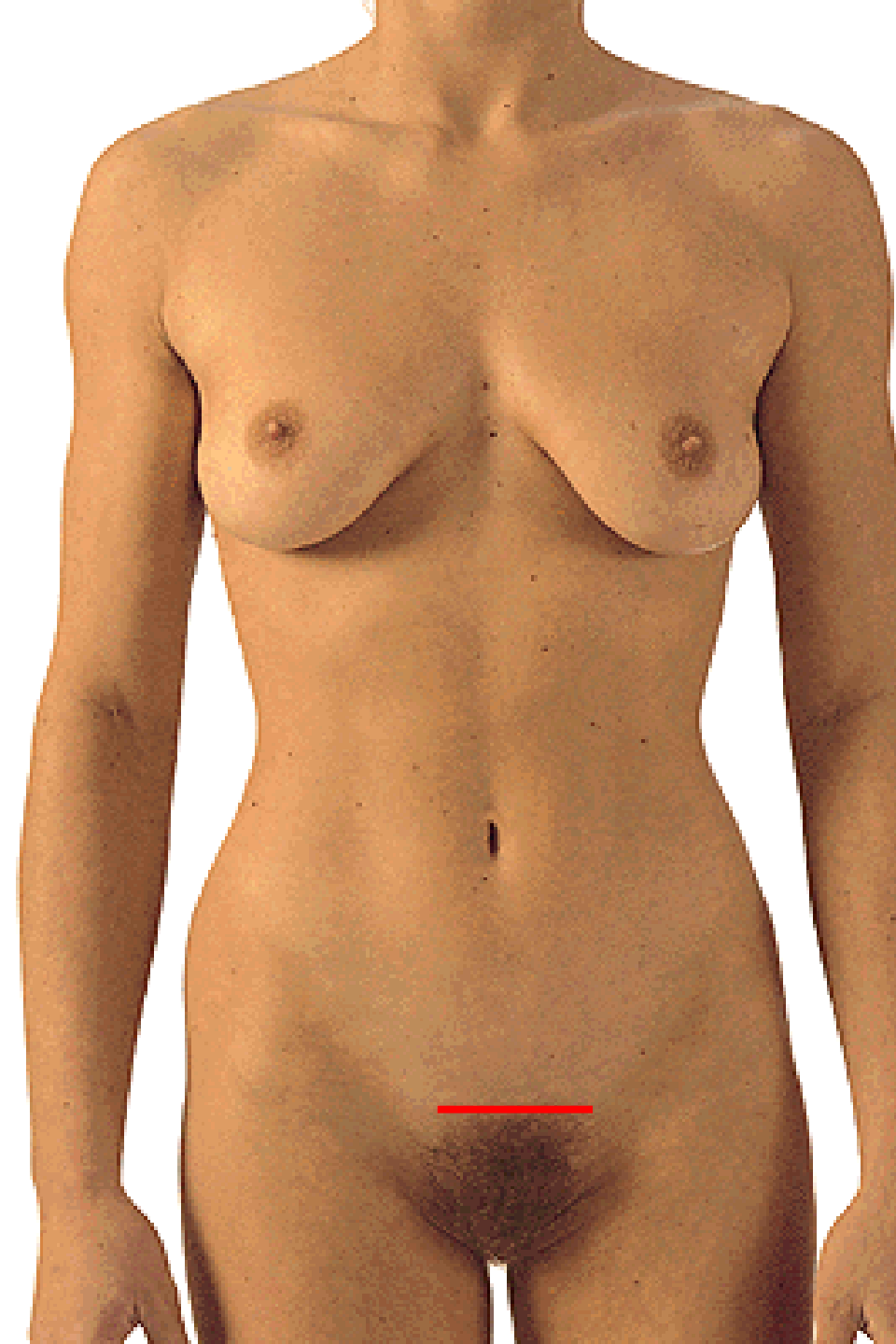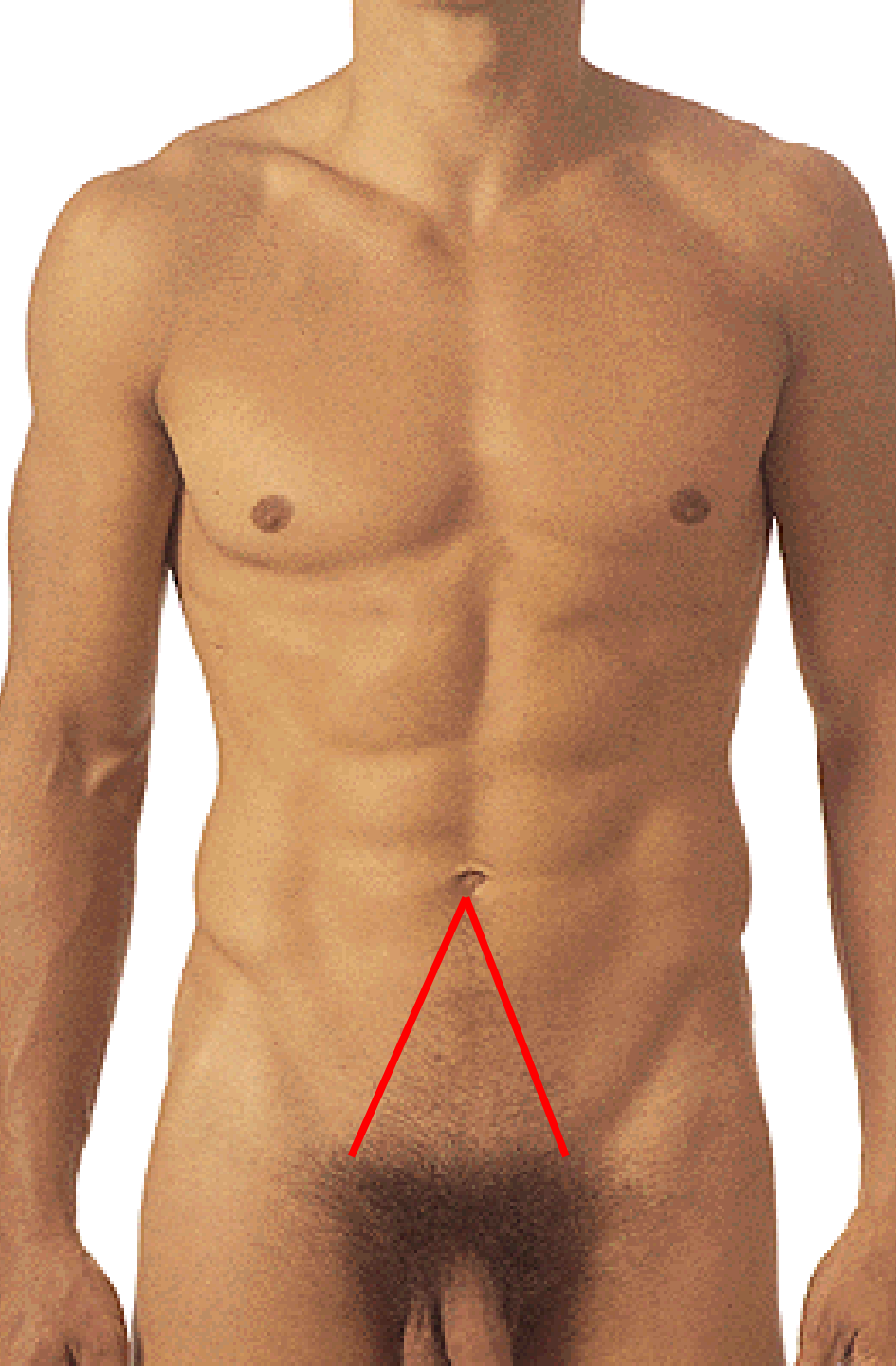




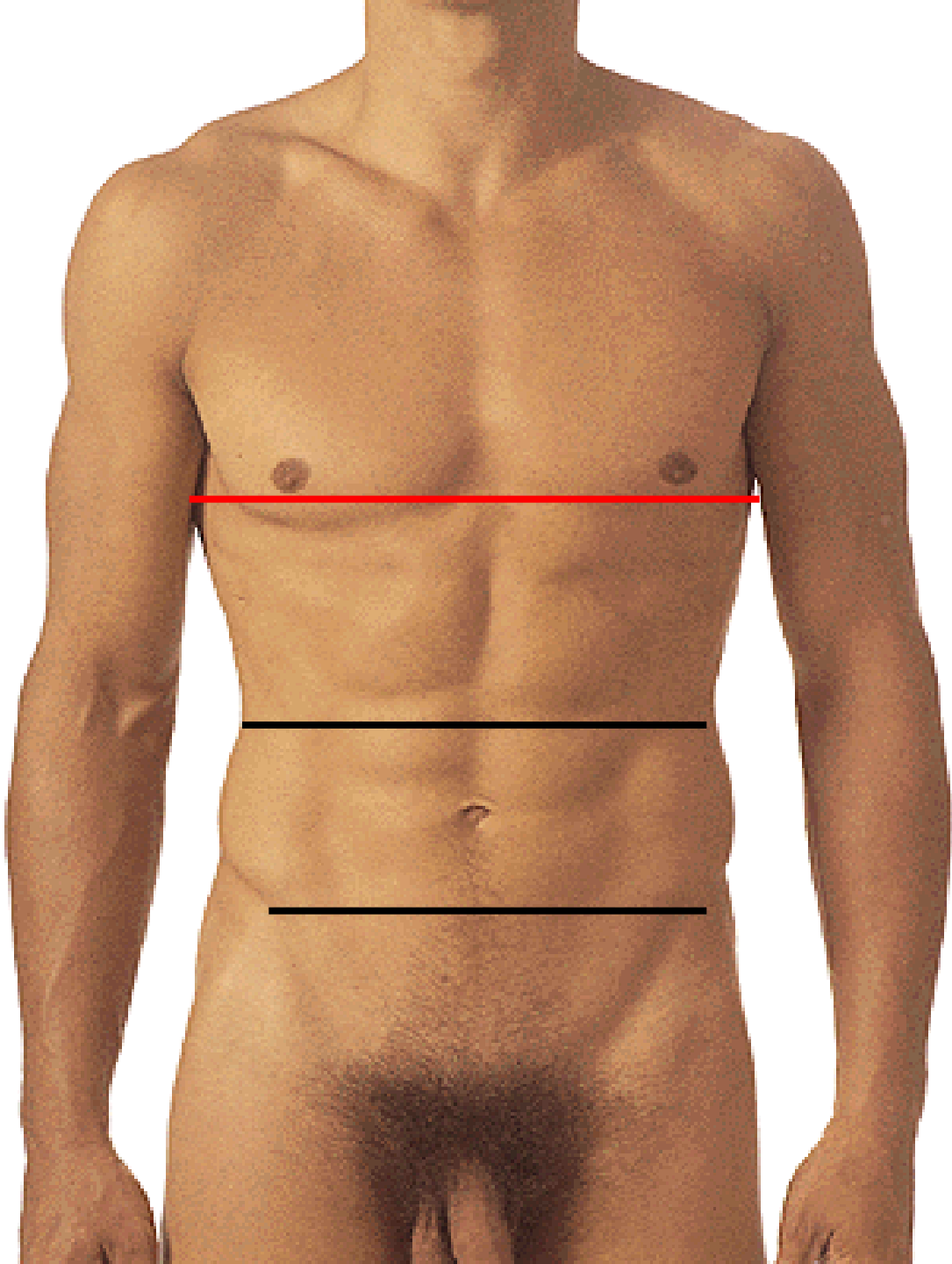




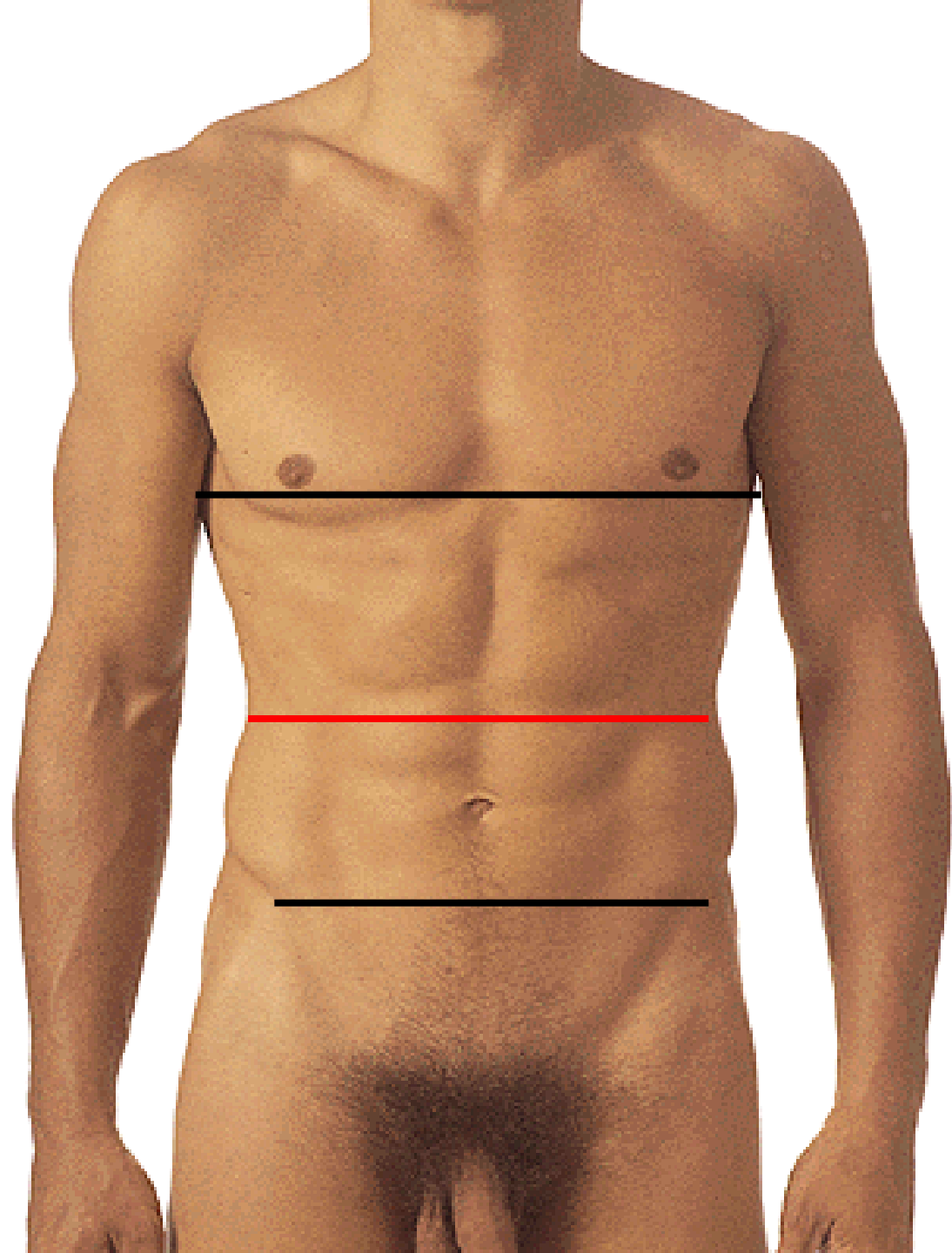




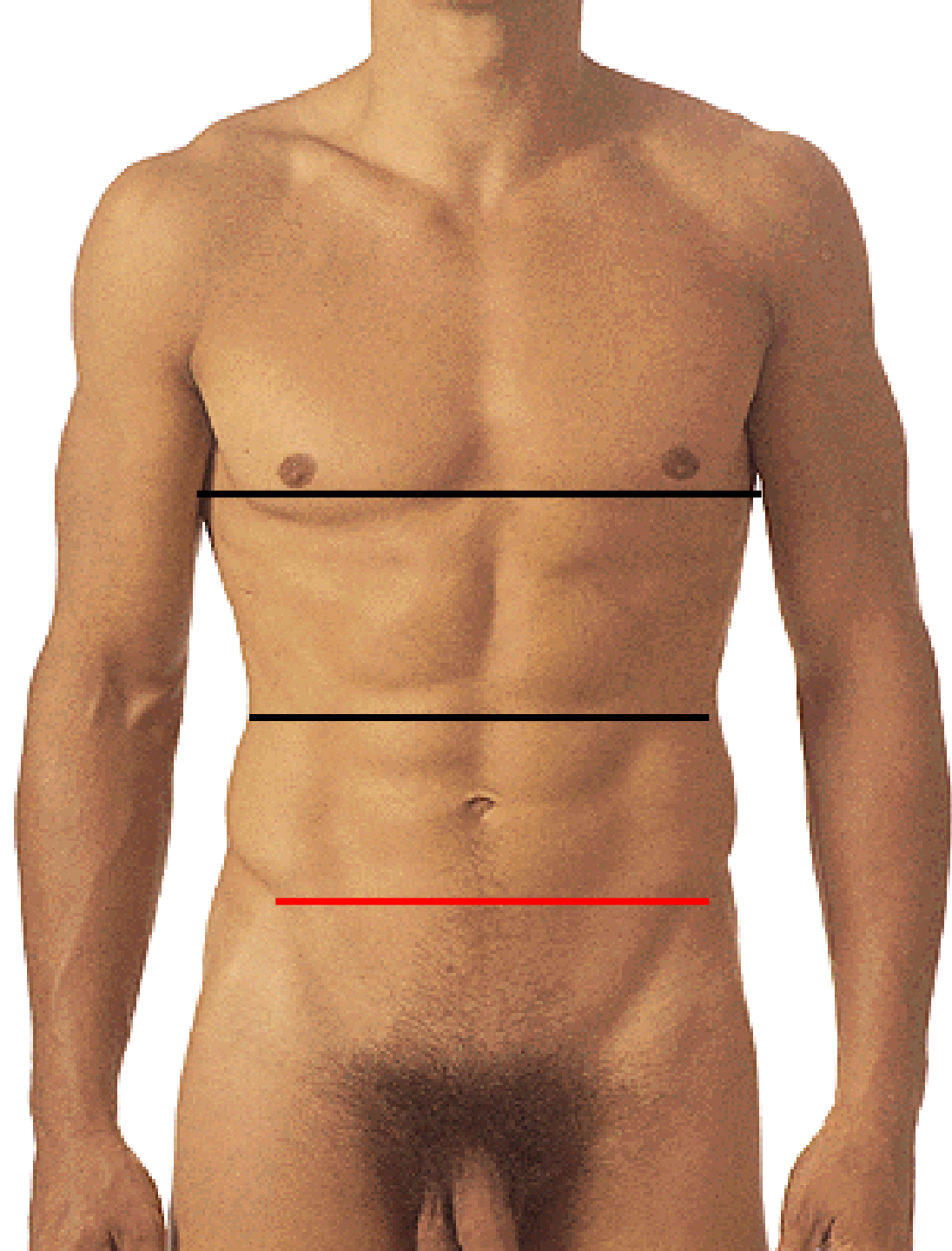
**LINEA XIPHISTERNALIS**



# LINEA SUBCOSTALIS

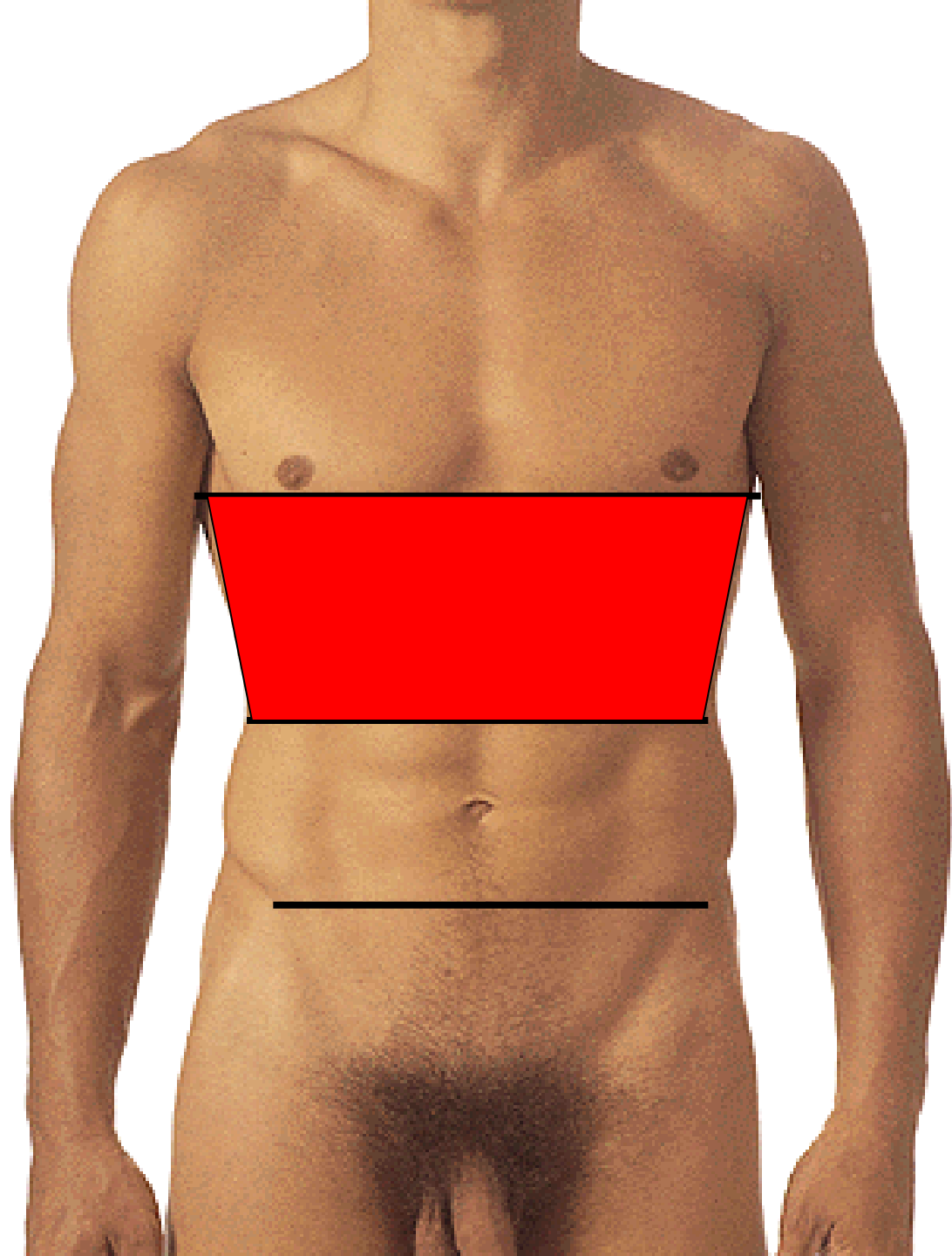


# LINEA BISPINALIS

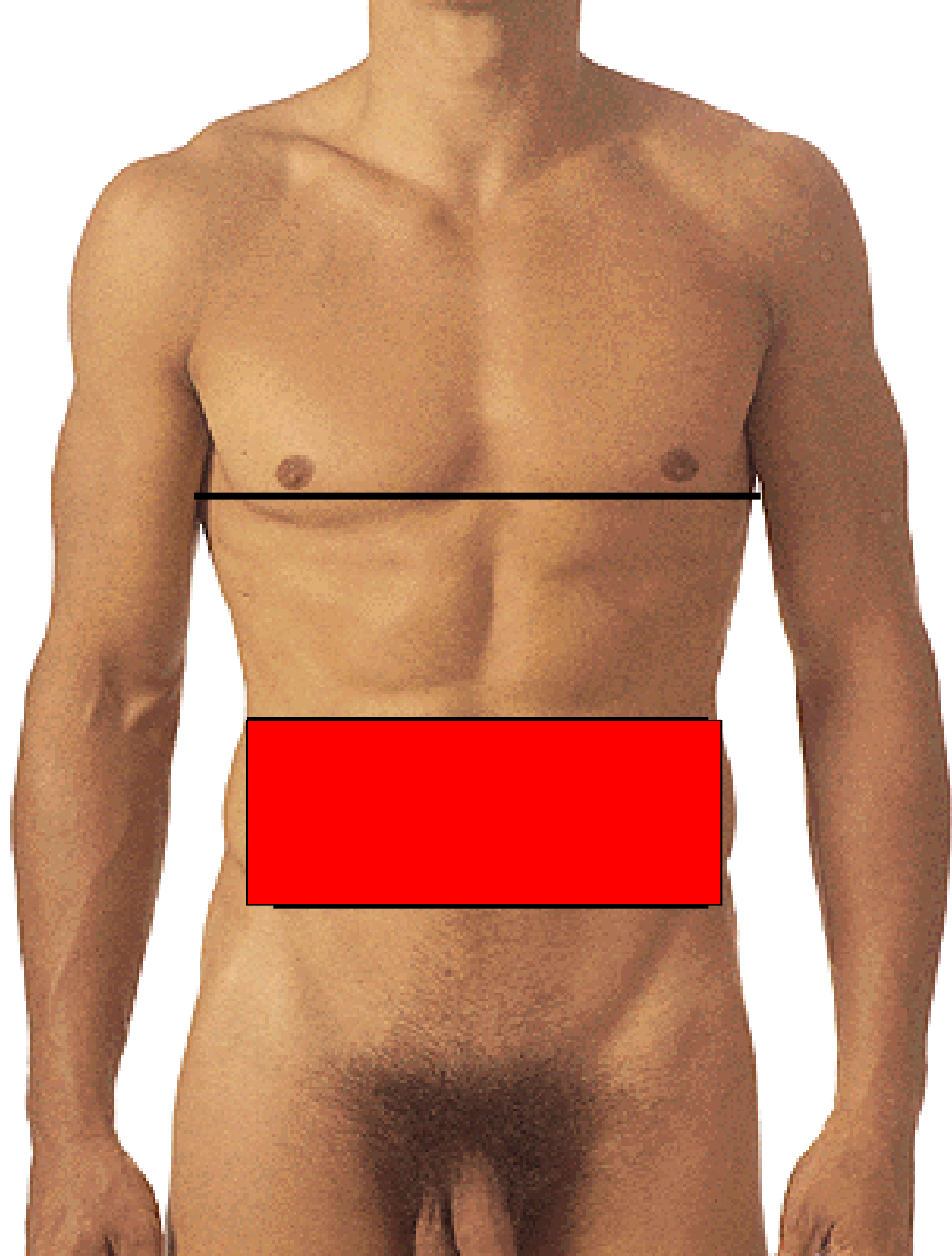




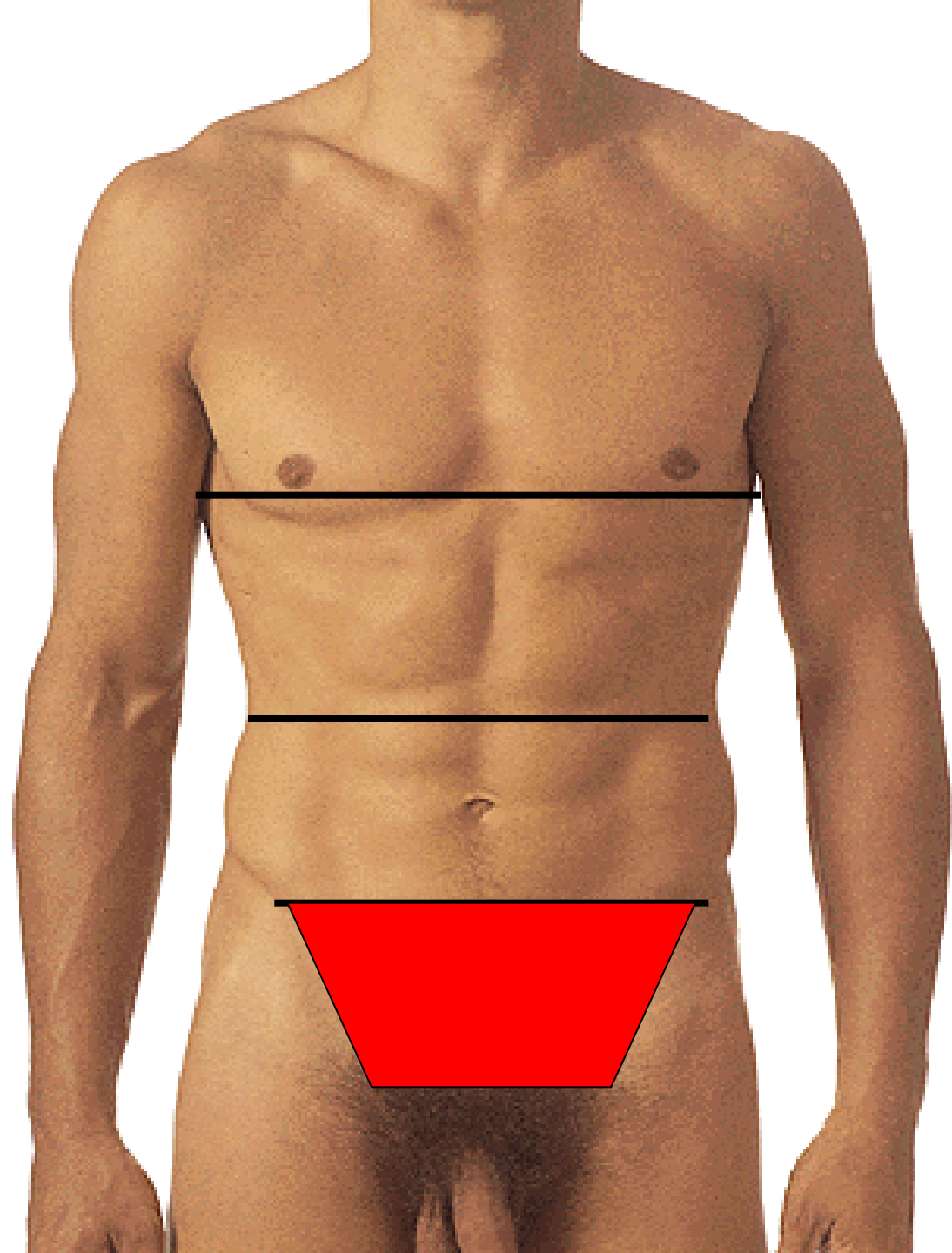
# EPIGASTRIUM

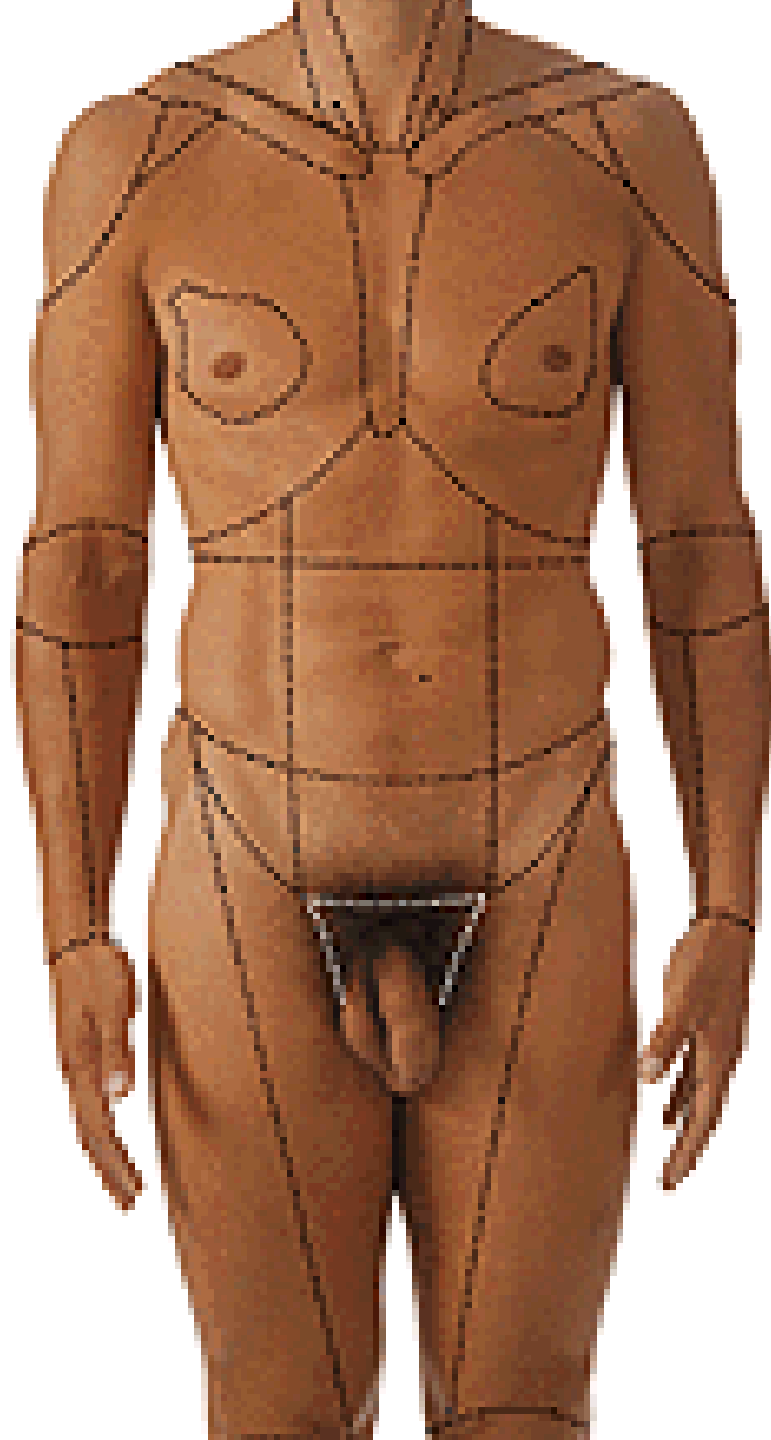


# MESOGASTRIUM

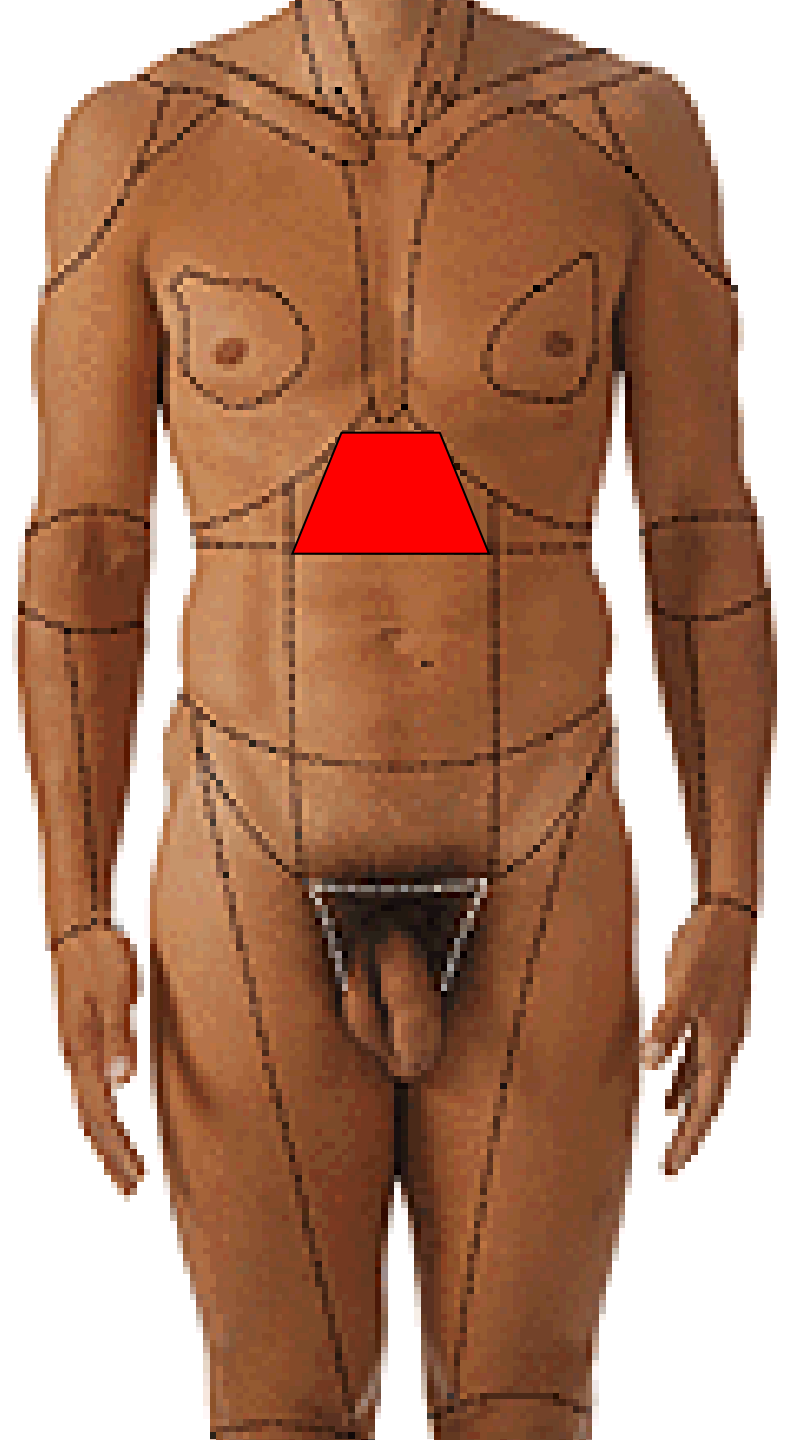


# HYPOGASTRIUM

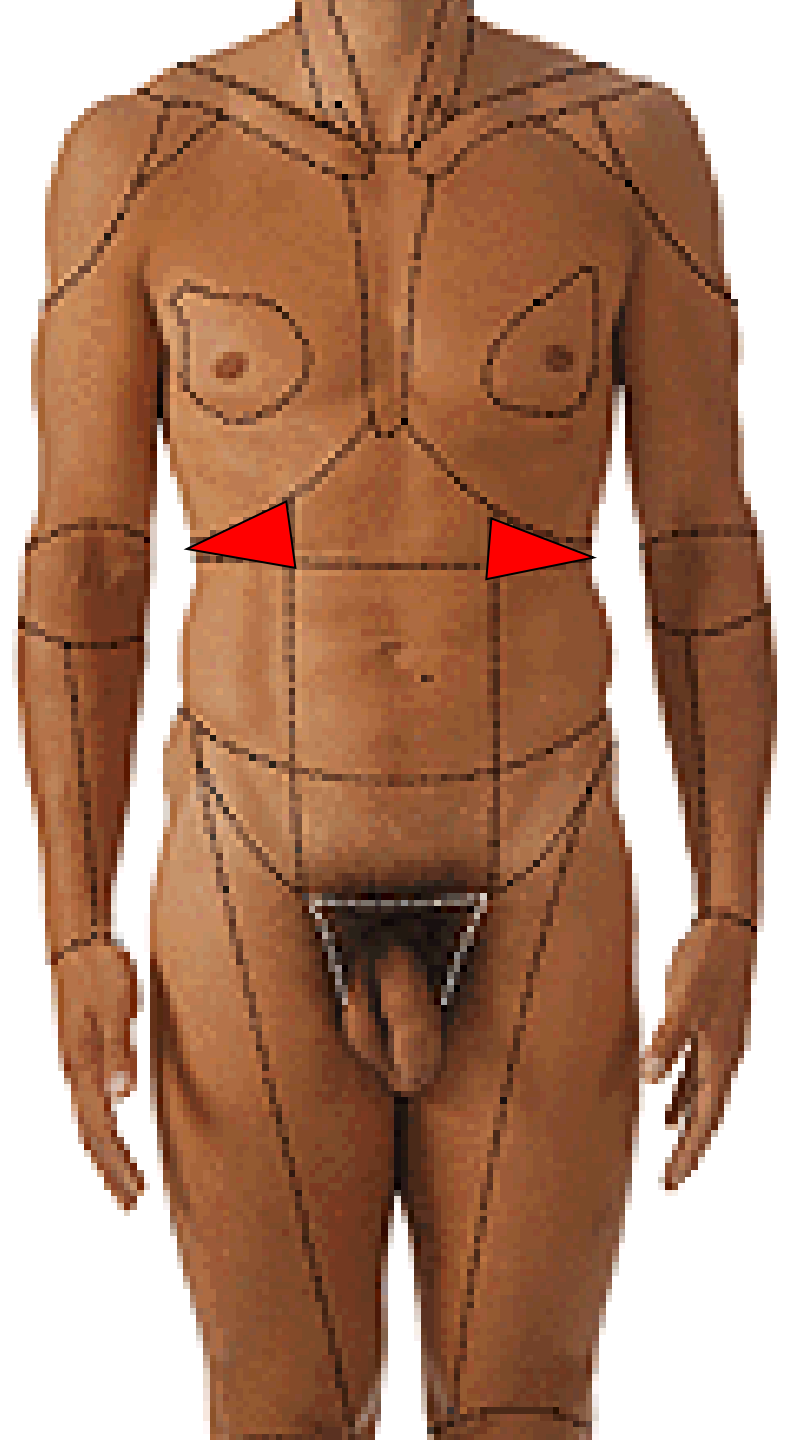




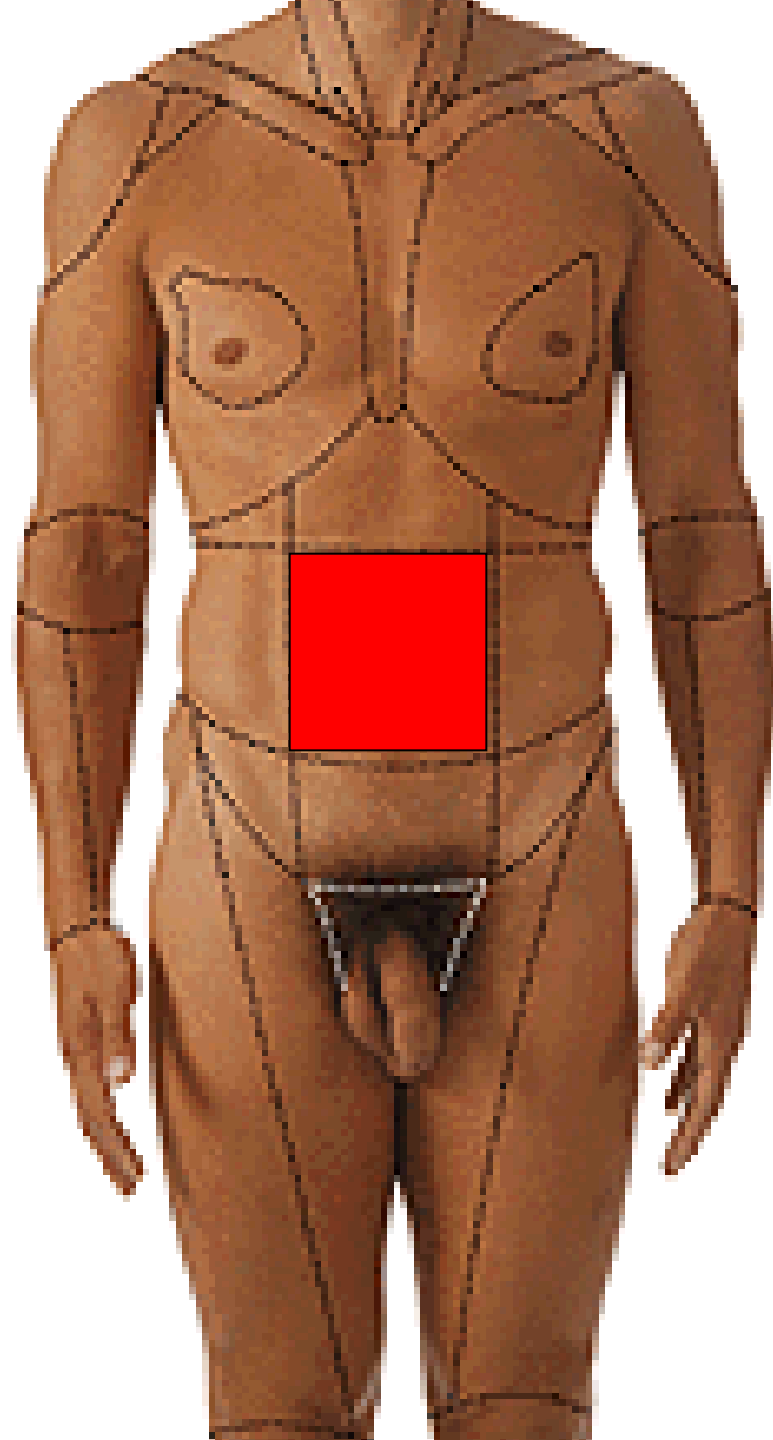
# REGIO EPIGASTRICA



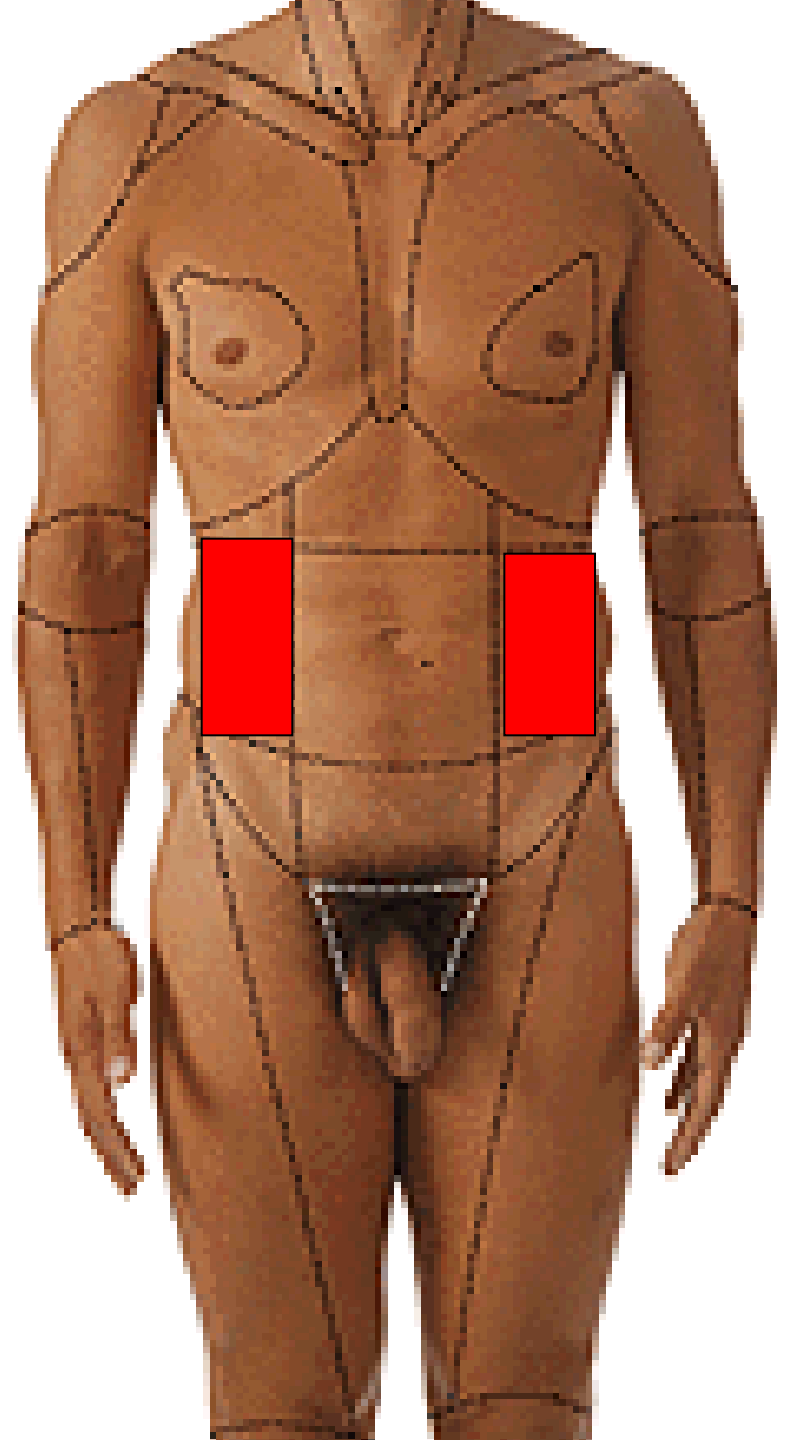
**REGIO HYPOCHONDRIACA  
DEXTRA ET SINISTRA**



# REGIO UMBILICALIS

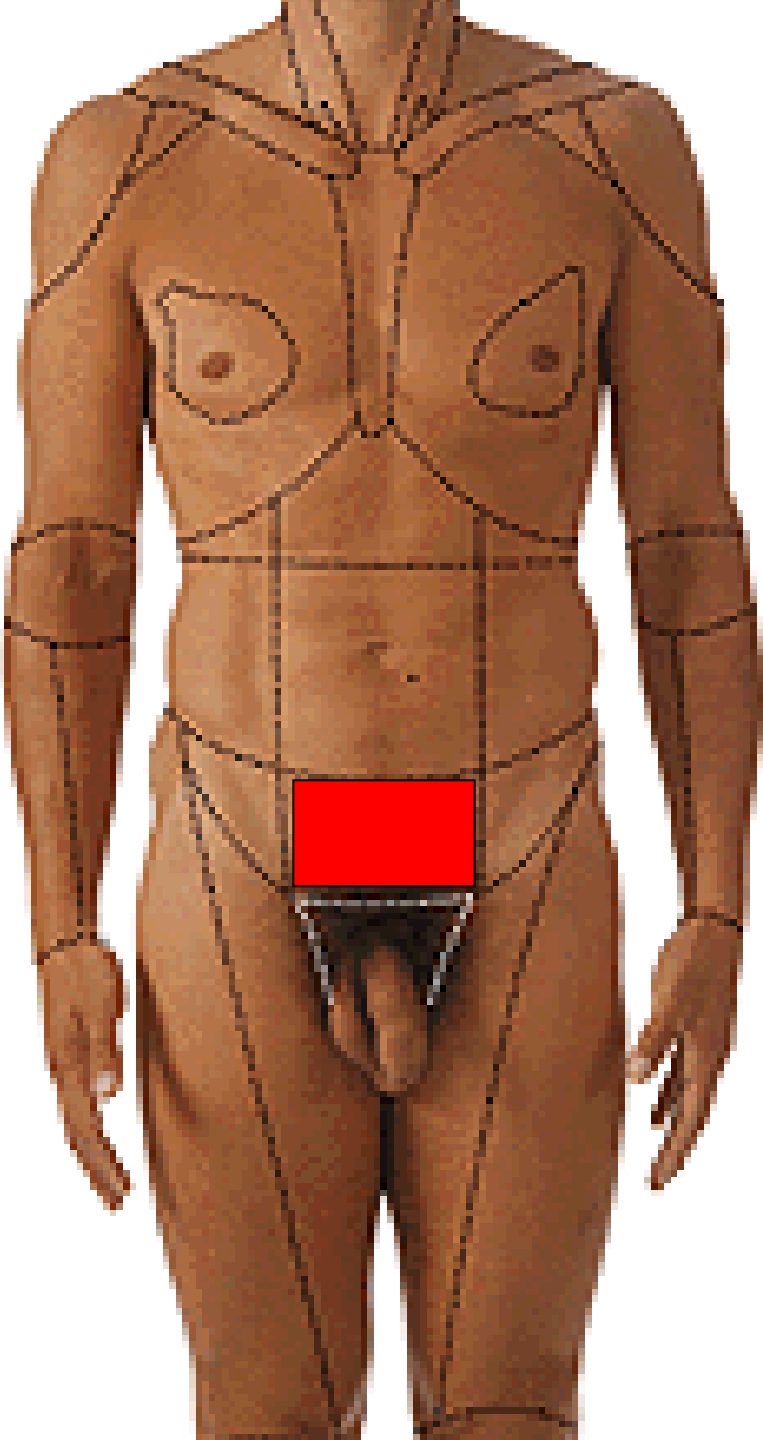


**REGIO LATERALIS  
DEXTRA ET SINISTRA**

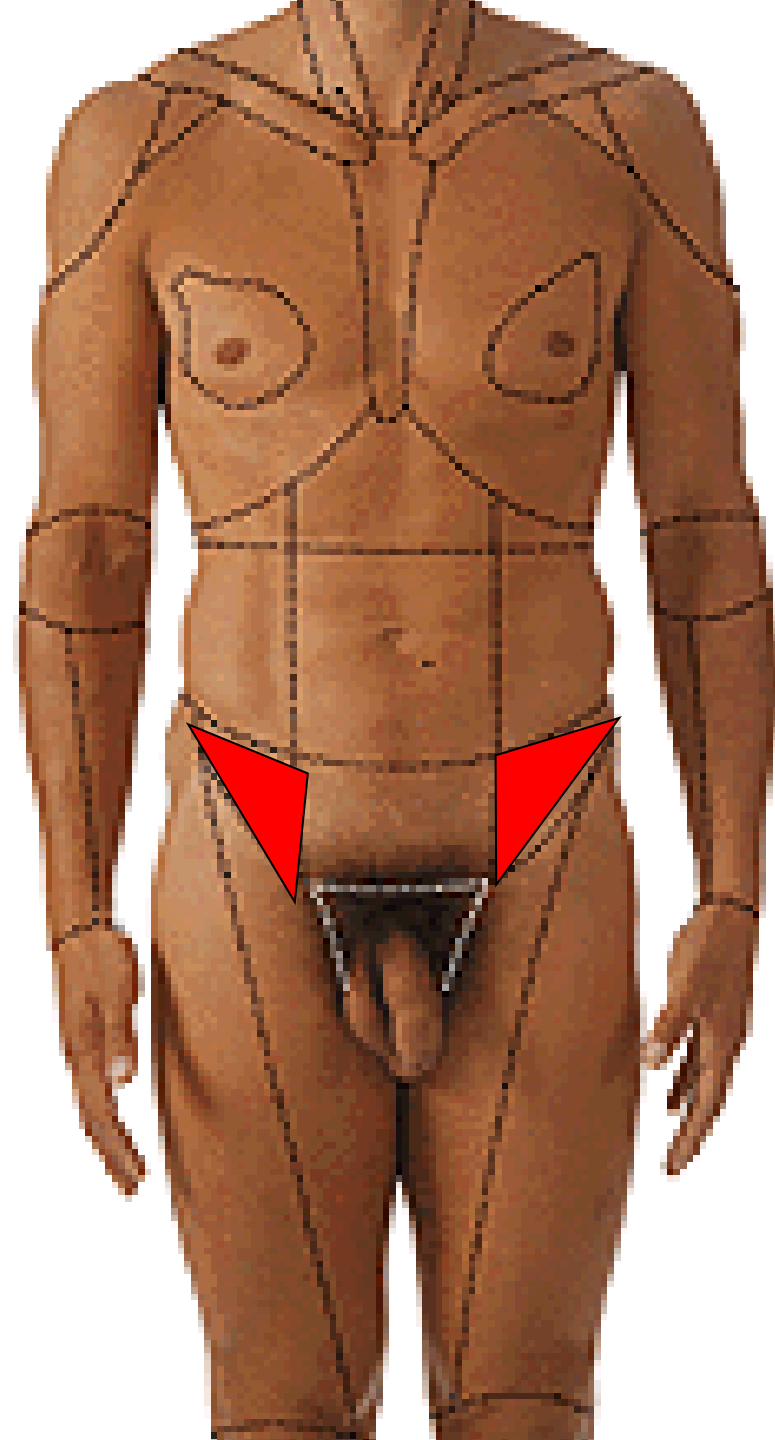




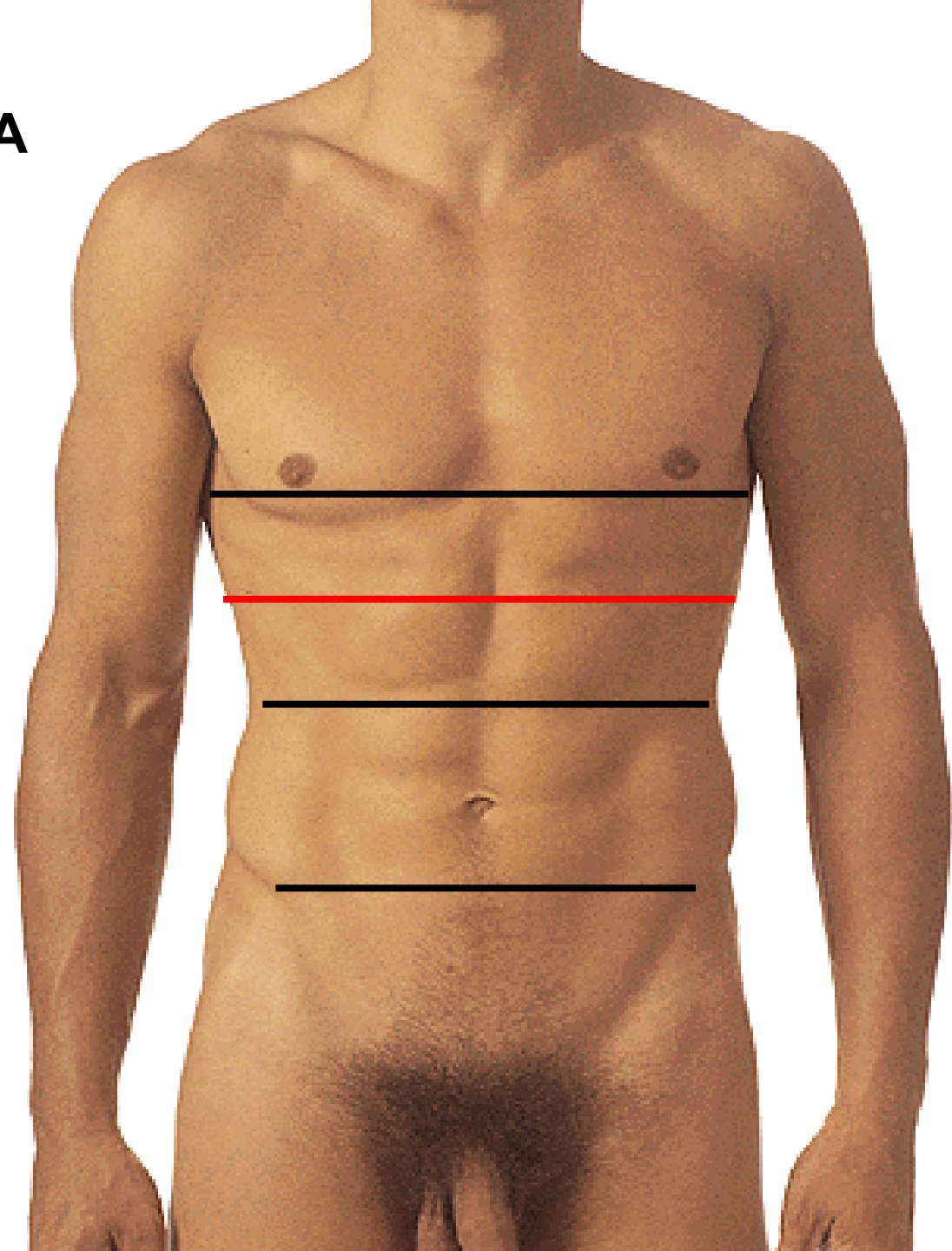
**REGIO PUBICA**



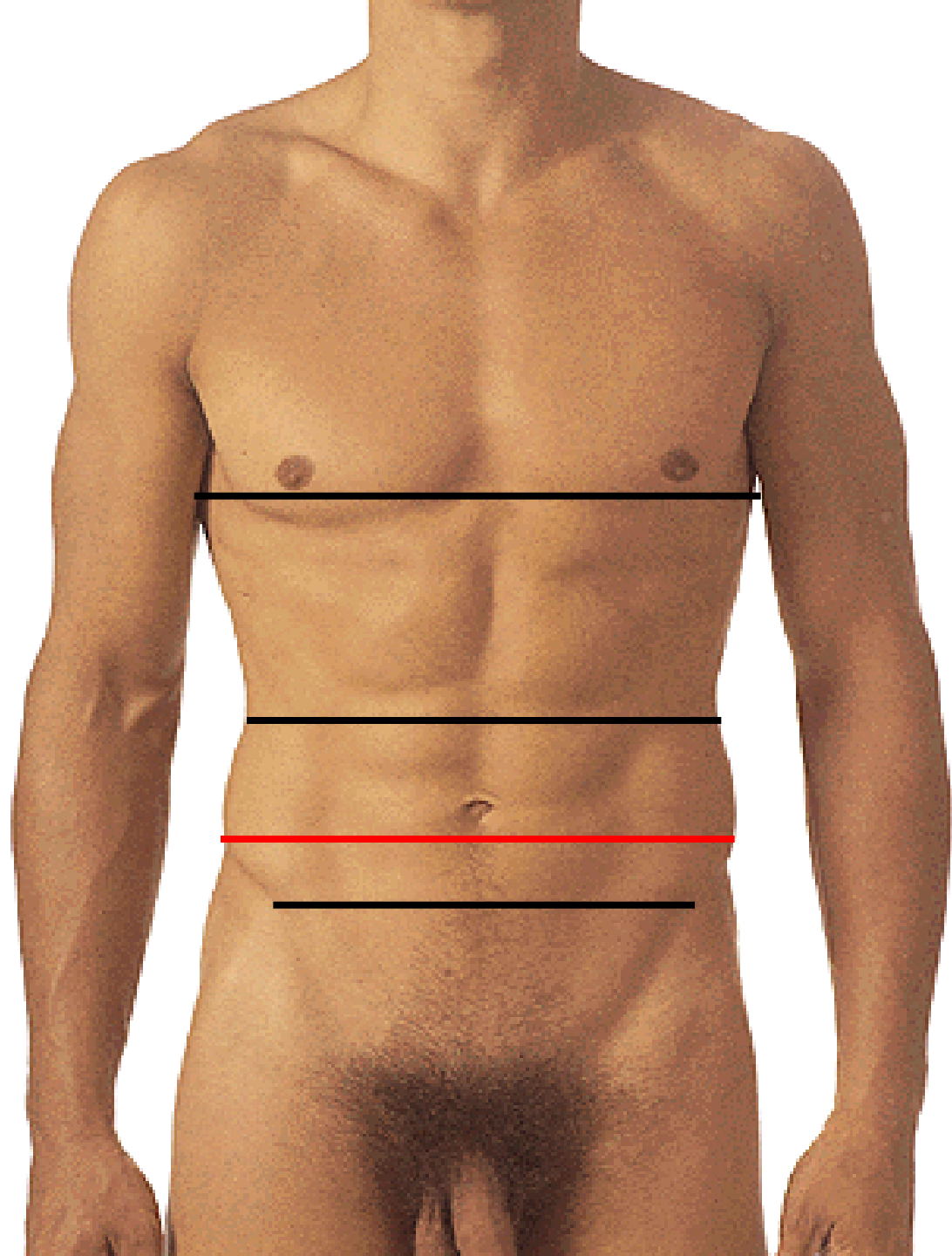
**REGIO INGUINALIS  
DEXTRA ET SINISTRA**



# LINEA TRANSPYLORICA

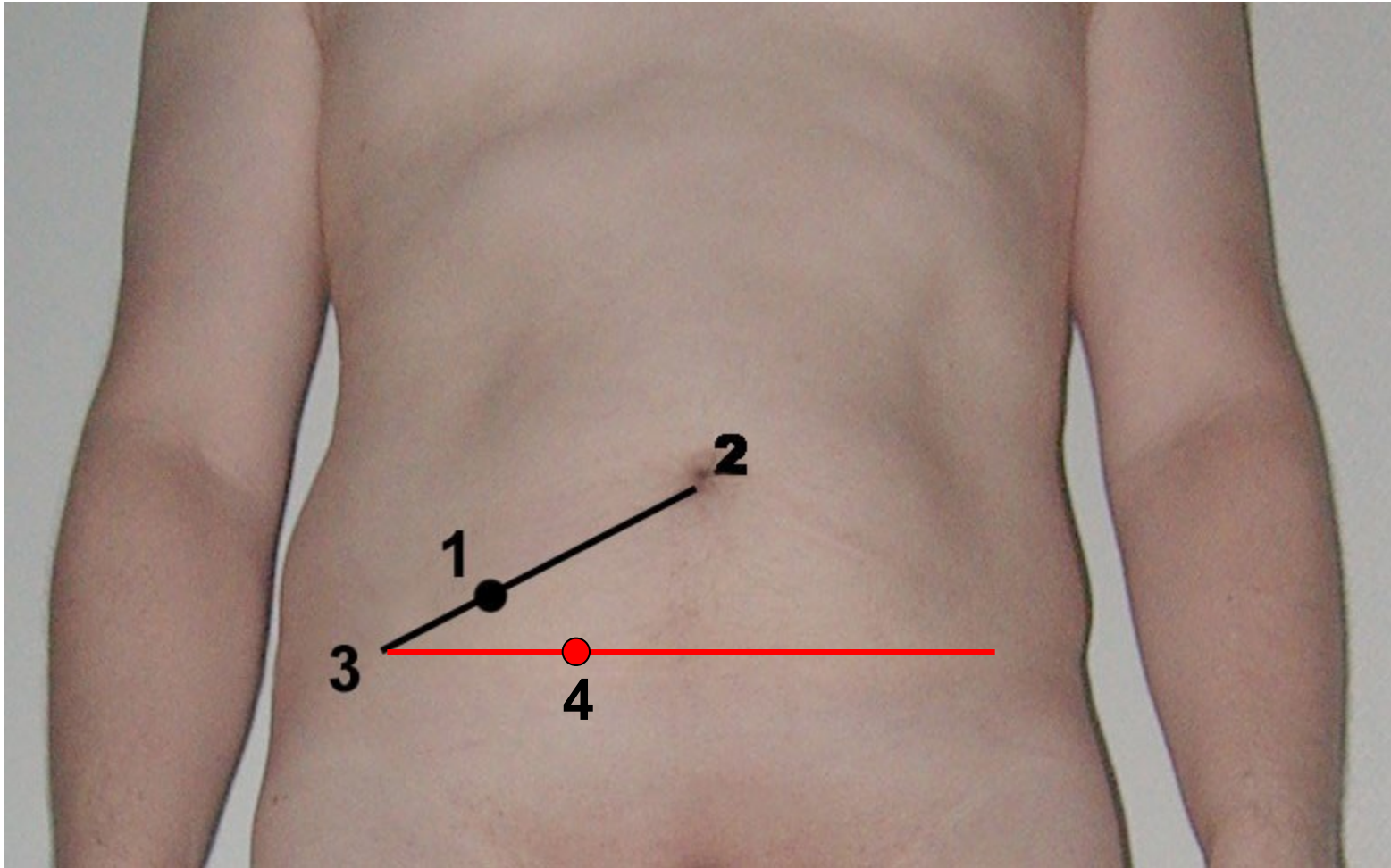


# LINEA BICRISTALIS



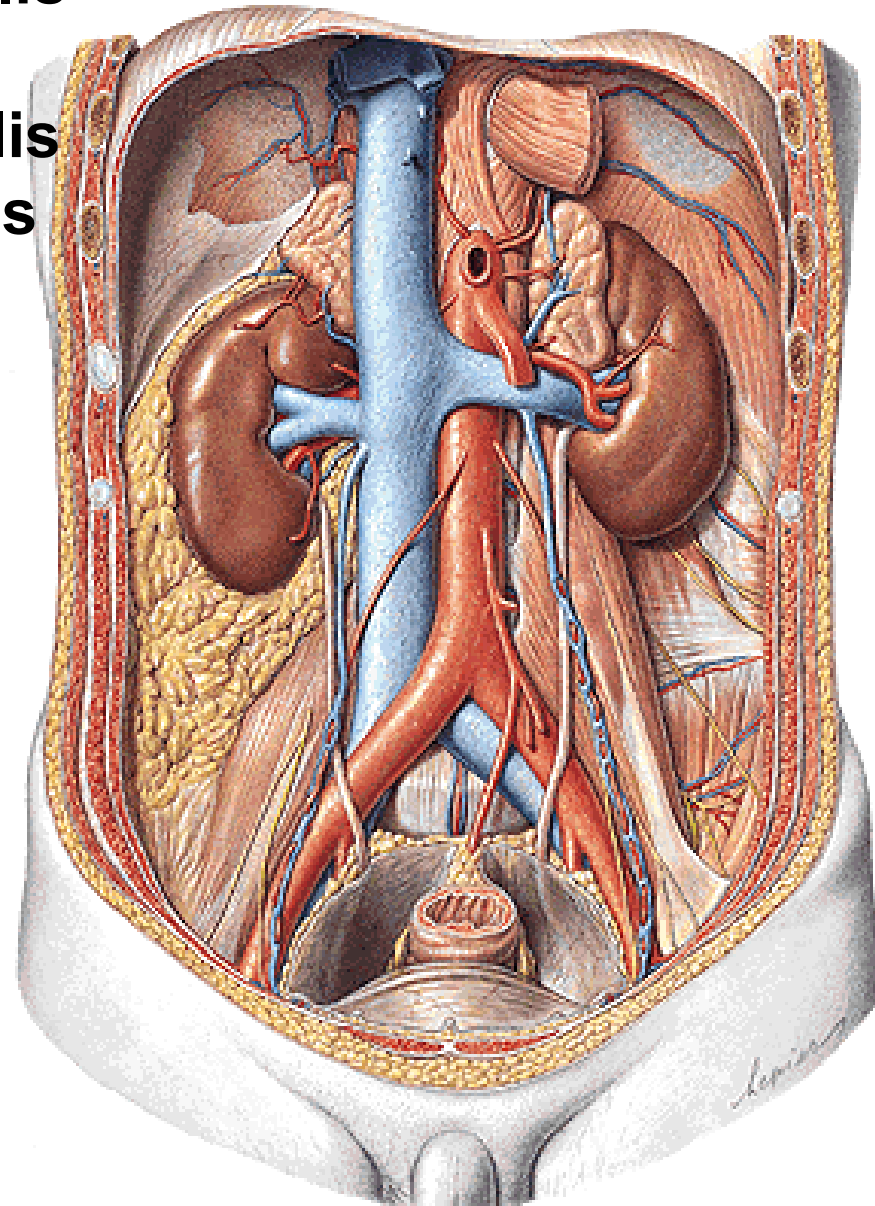
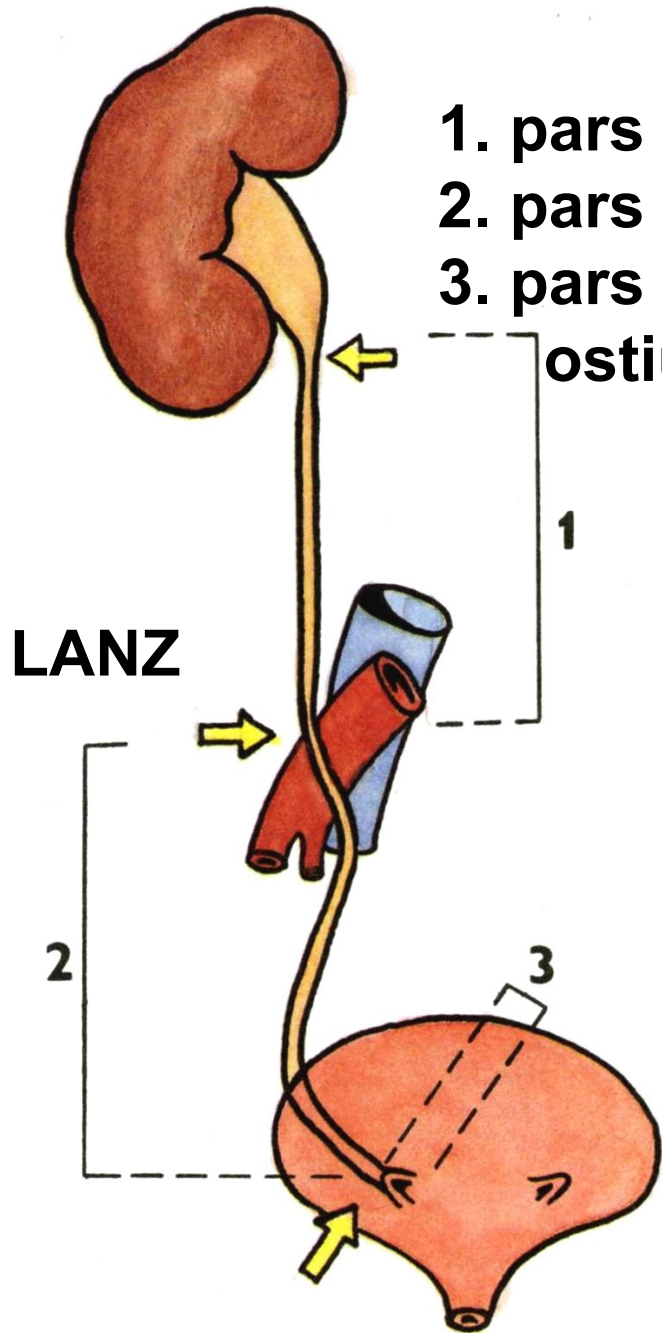
McBurney's point

Lanz's point

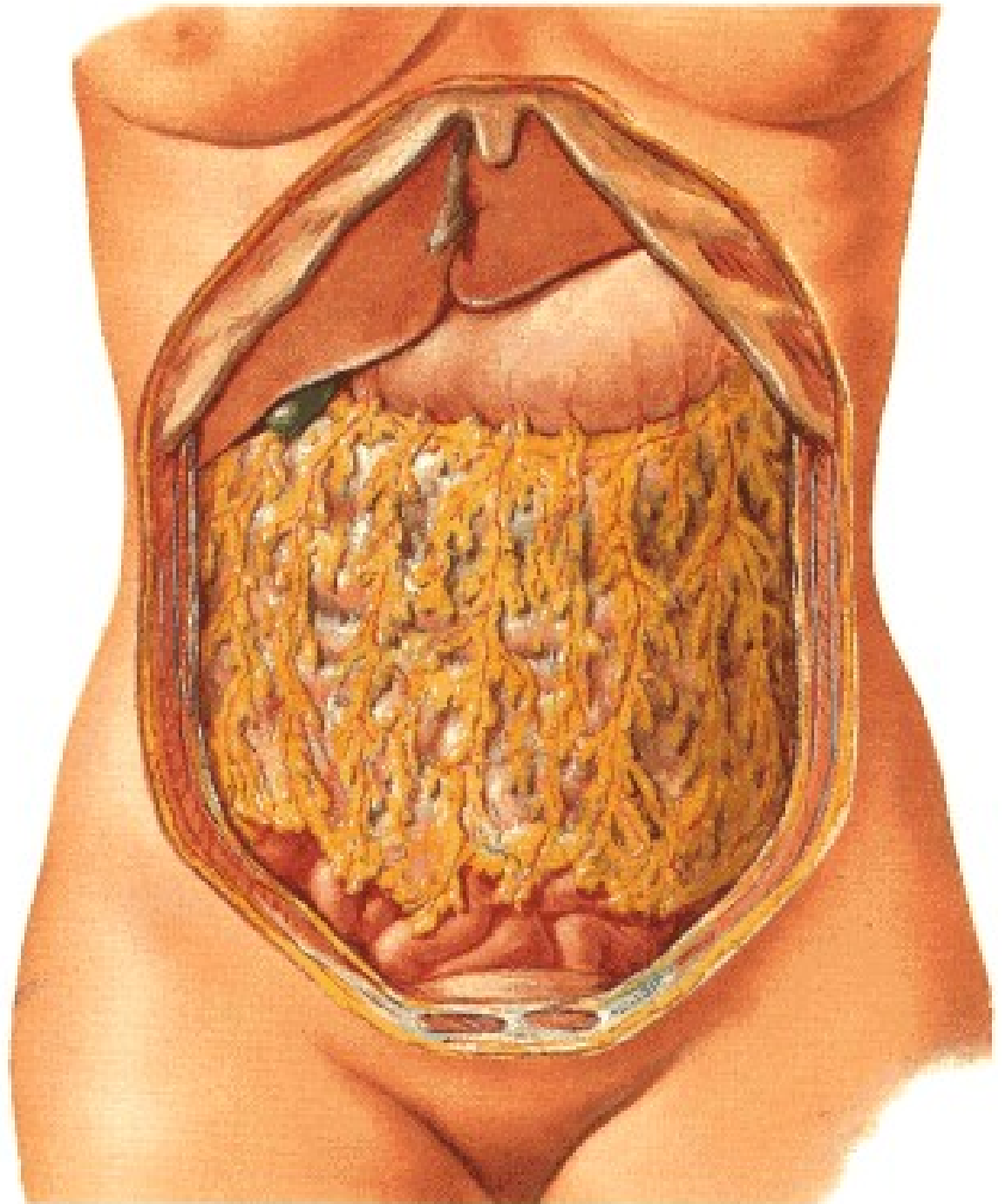


# URETER

1. pars abdominalis
2. pars pelvina
3. pars intramuralis  
ostium ureteris



# Labbe's triangle



# **ABDOMINAL WALL**





**PANNICULUS ADIPOSUS**

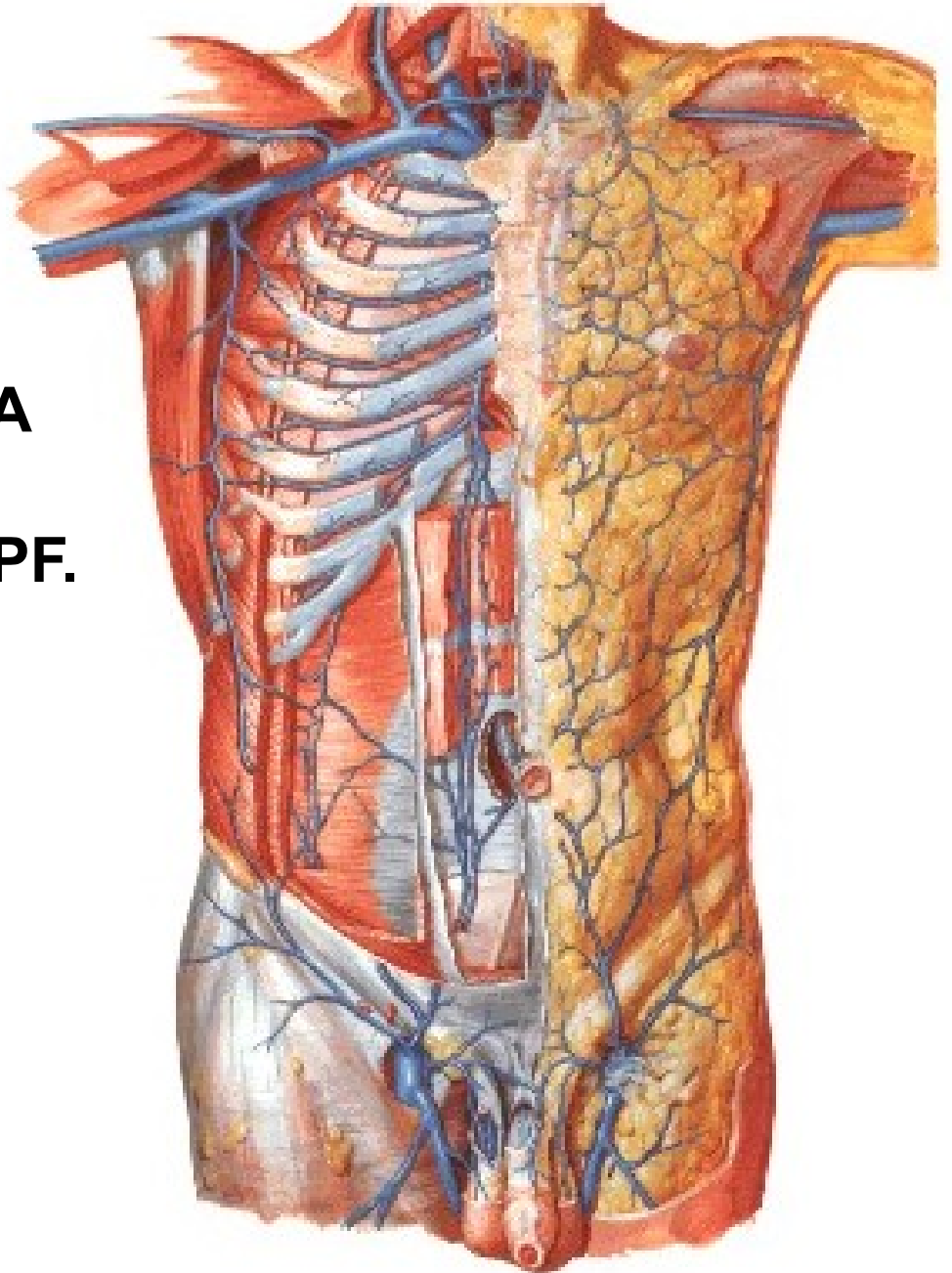
**VV. SUBCUTANEA ABD.**

**V. THORACOEPIGASTRICA**

**V. EPIGASTRICA SPF.**

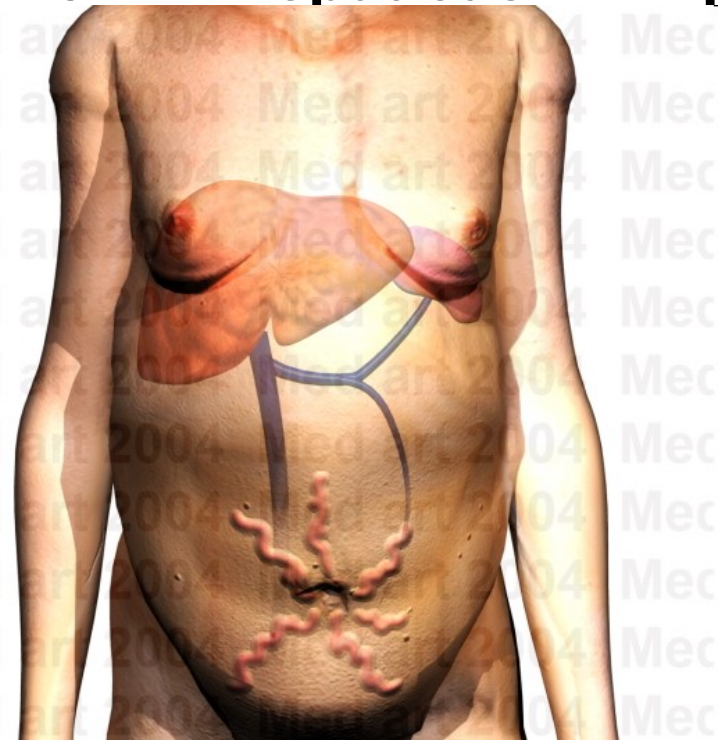
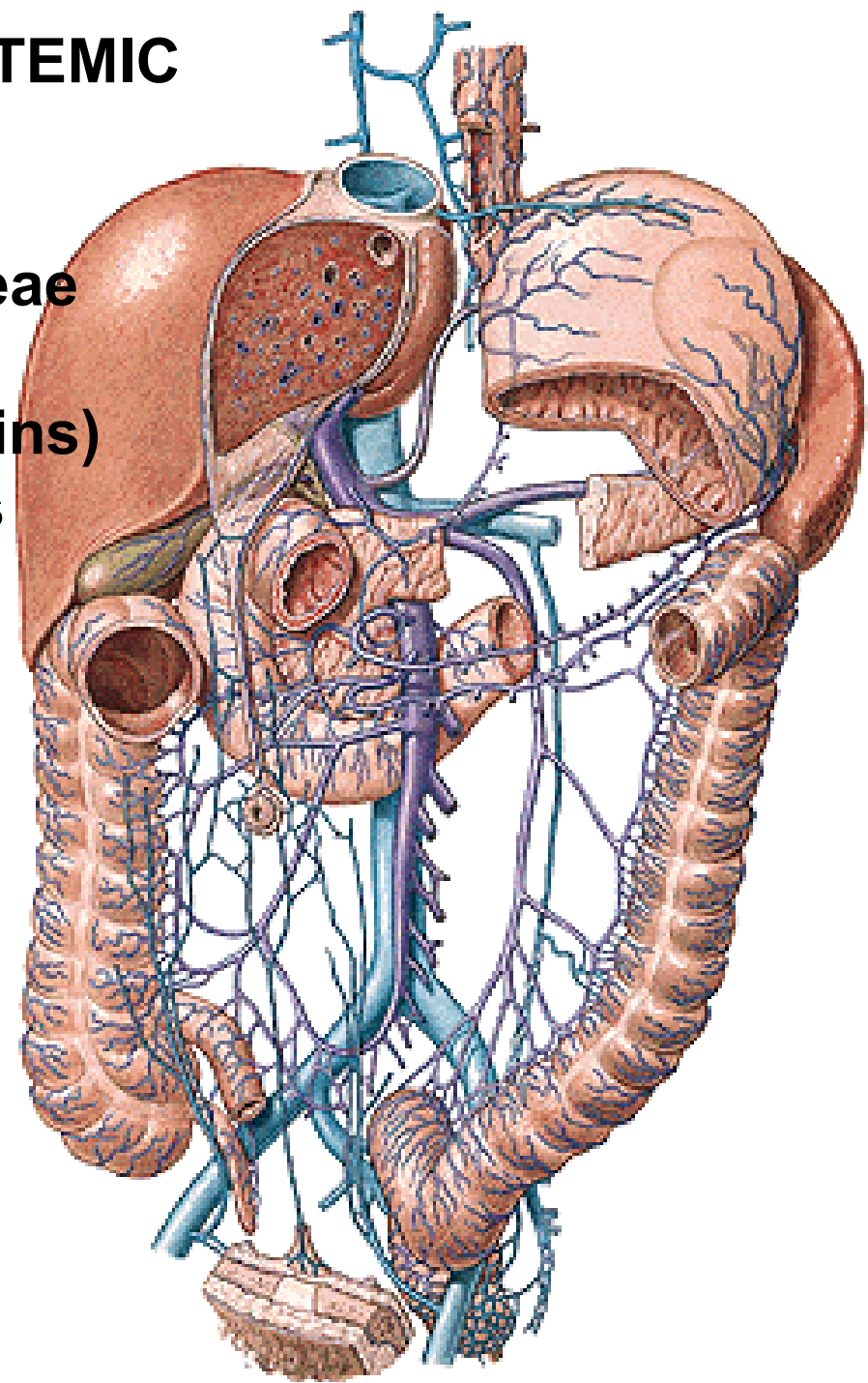
**V. CIRCUMFLEXA ILIUM SPF.**

**VV. PARAUMBILICALES**

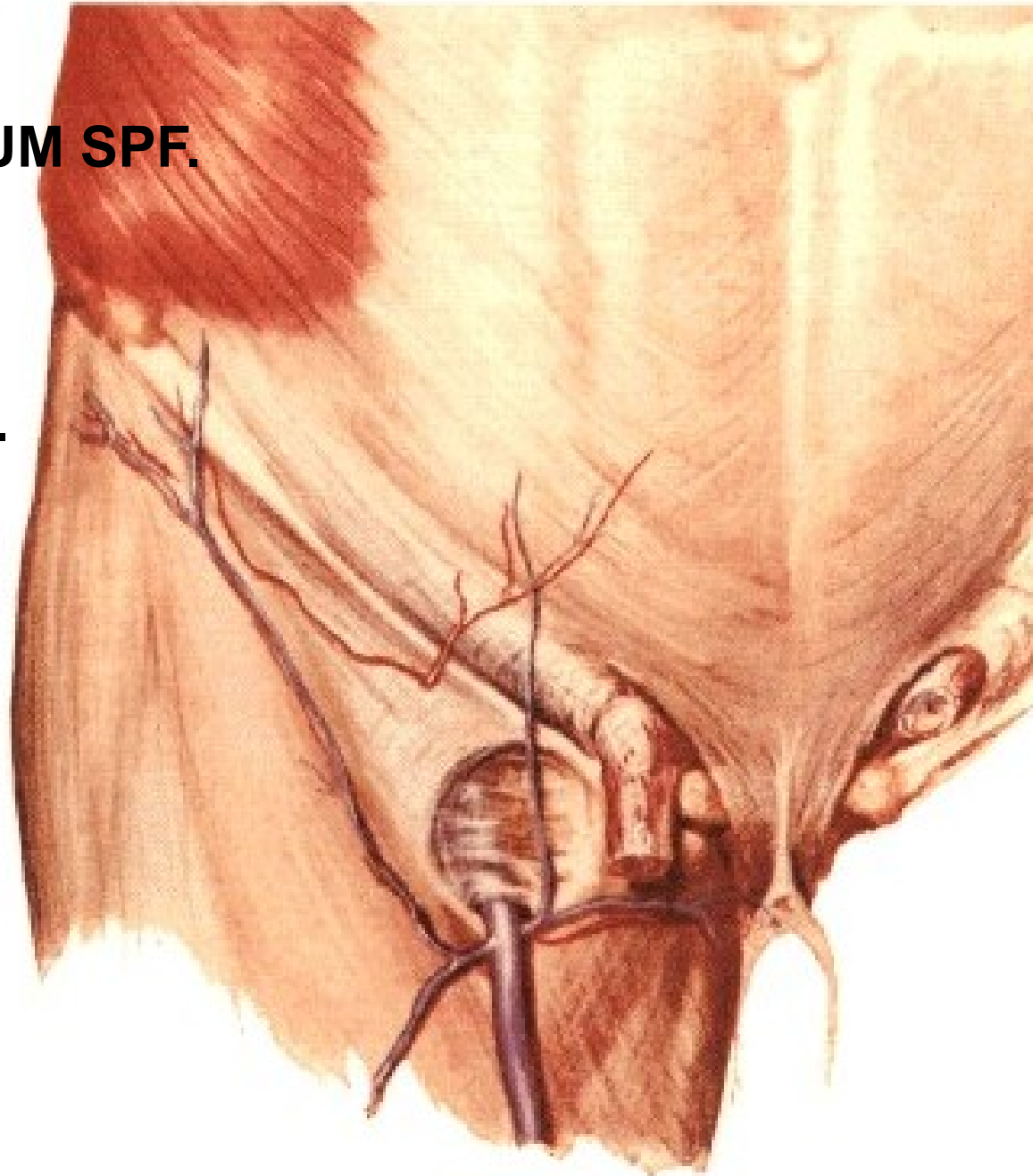


# PORTAL-CAVAL / PORTAL-SYSTEMIC ANASTOMOSES

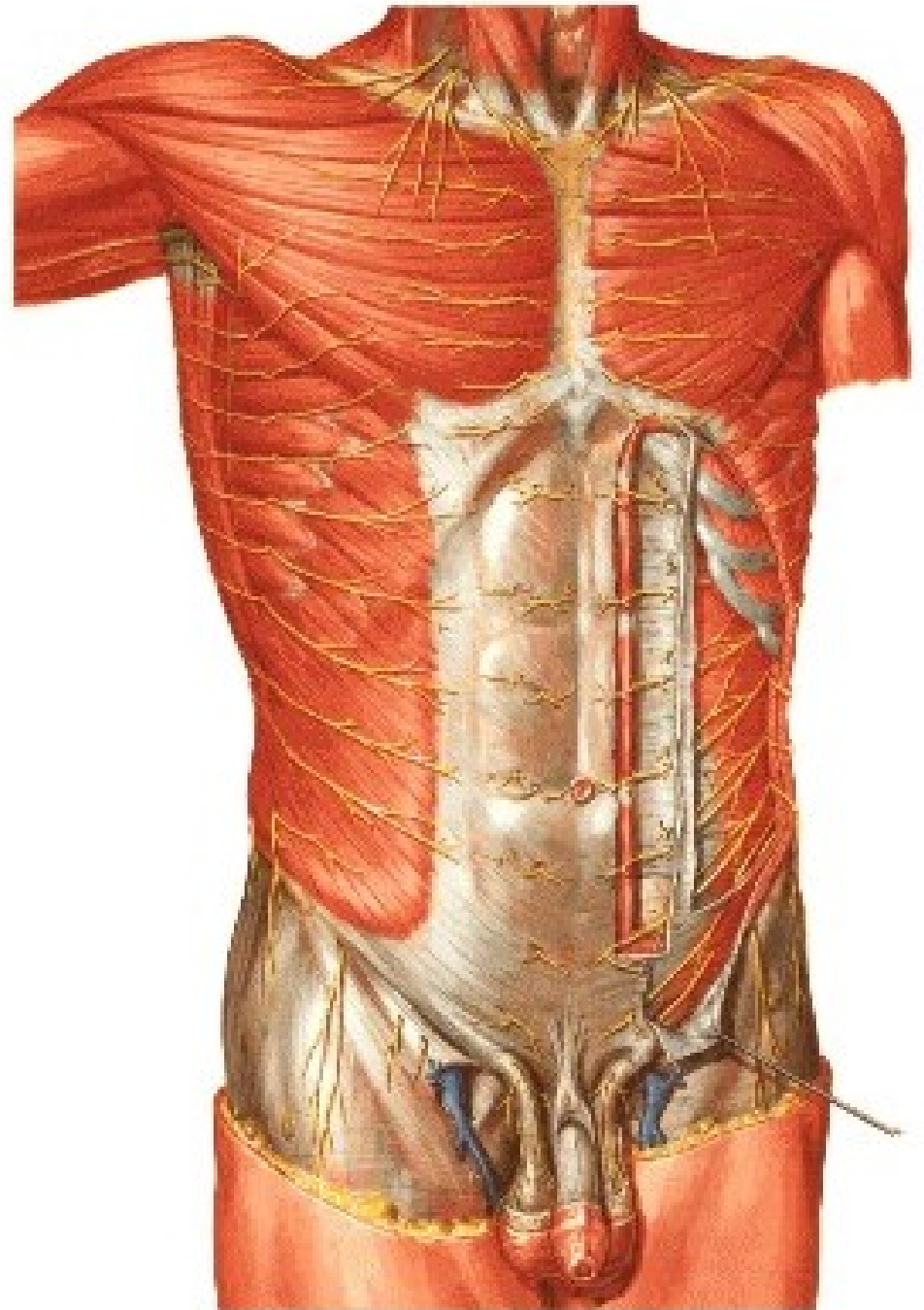
1. Vv. gastricae – vv. oesophageae
2. Vv. paraumbilicales  
(caput Medusae, Burrow's veins)
3. Plexus rectalis - hemorrhoids
4. Retzius' veins
5. Vv. hepaticae – vv. phrenicae



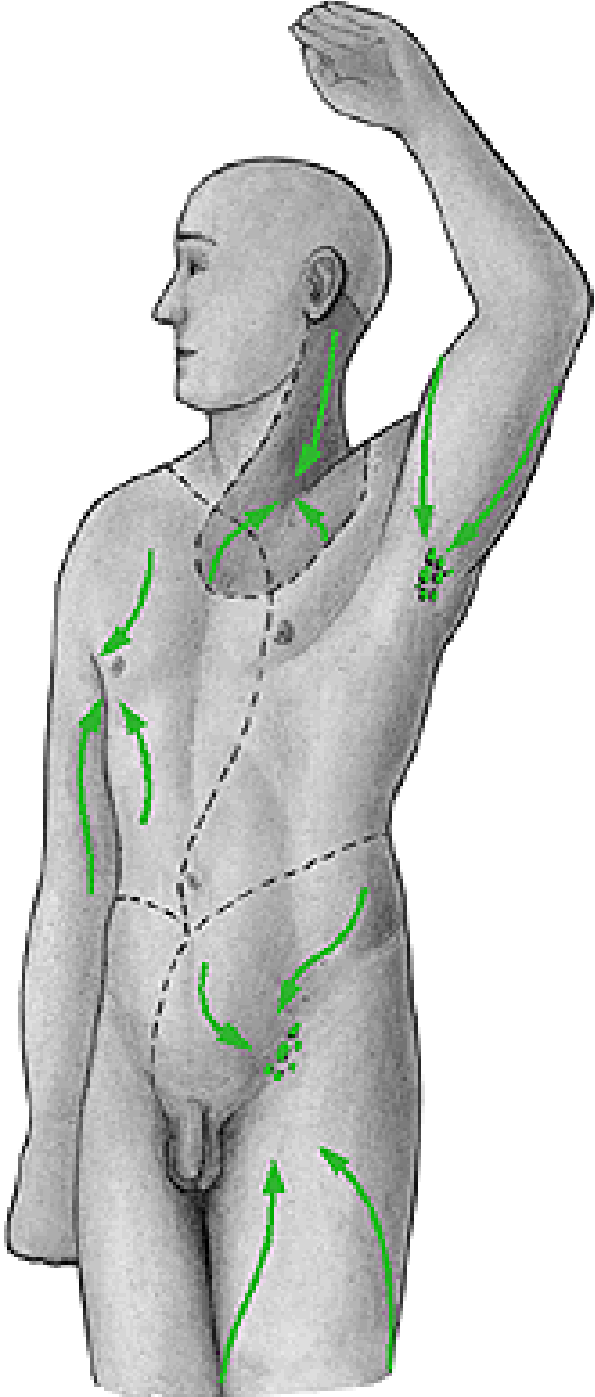
**A. EPIGASTRICA SPF.**  
**A. CIRCUMFLEXA ILIUM SPF.**  
**AA. INTERCOSTALES**  
**A. SUBCOSTALIS**  
**AA. LUMBALES**  
**A. EPIGASTRICA SUP.**

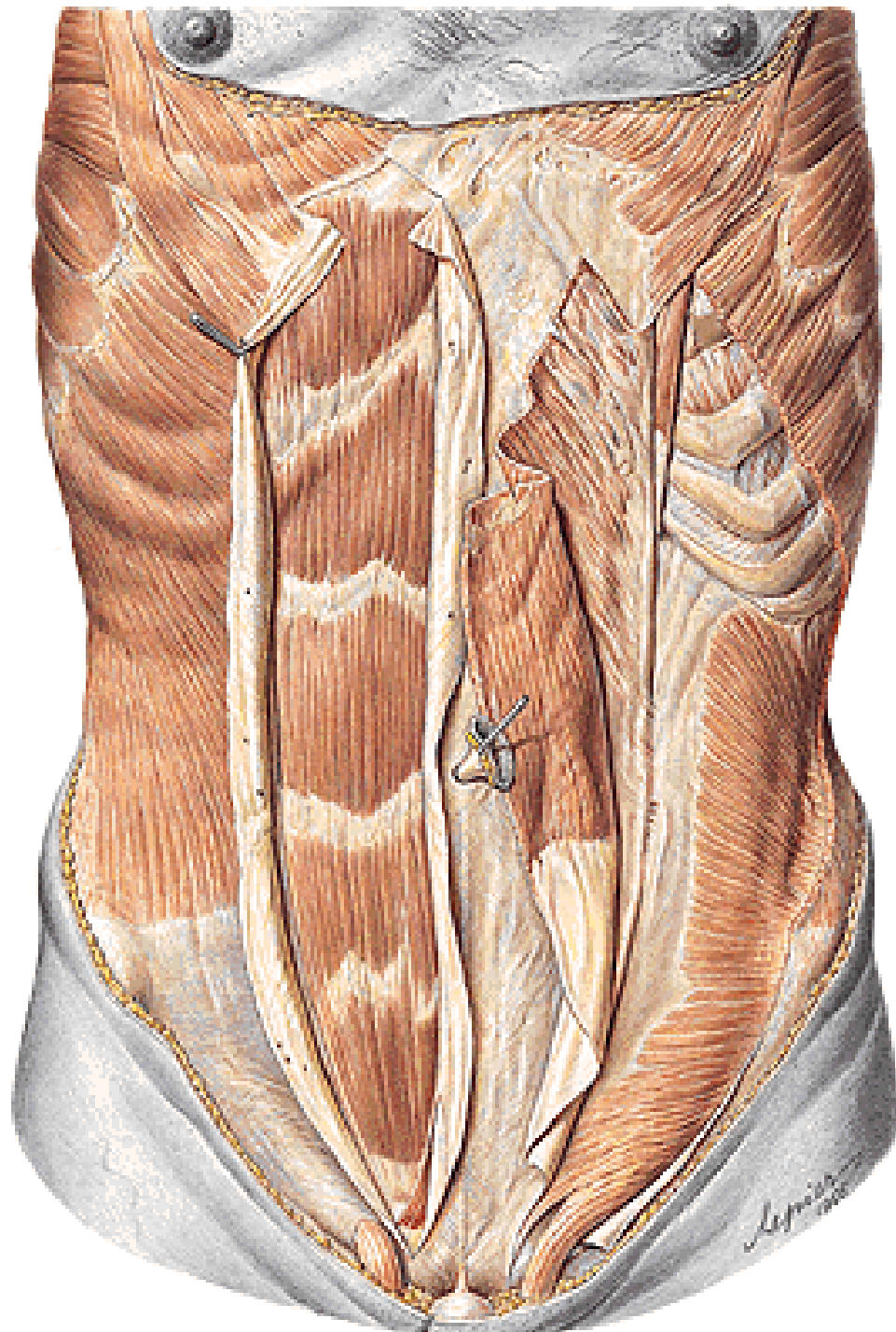


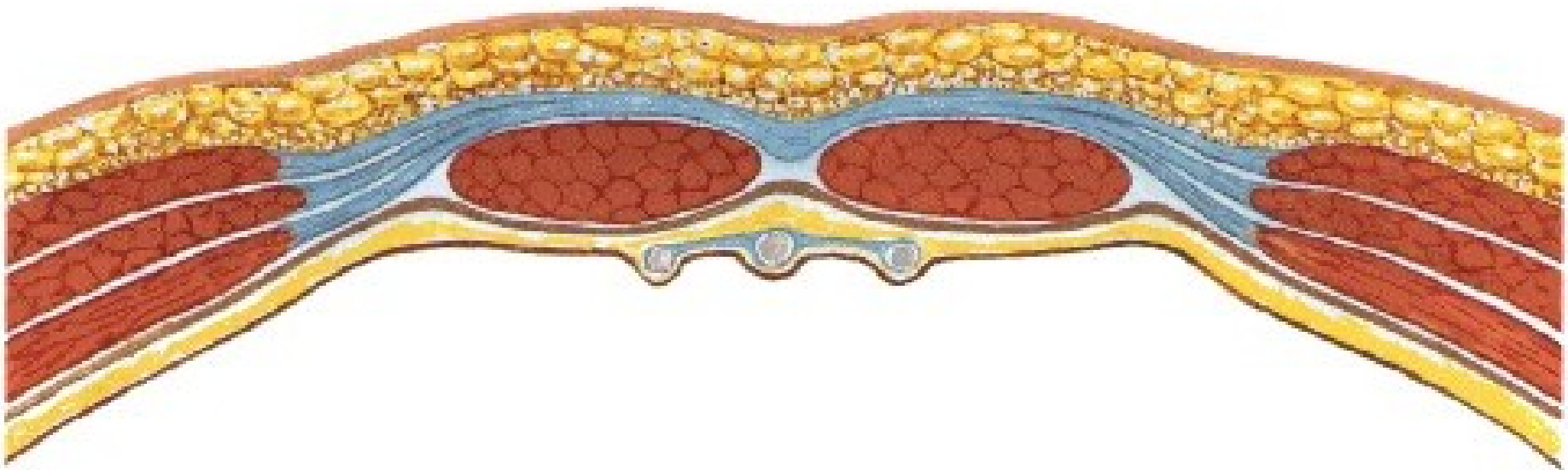
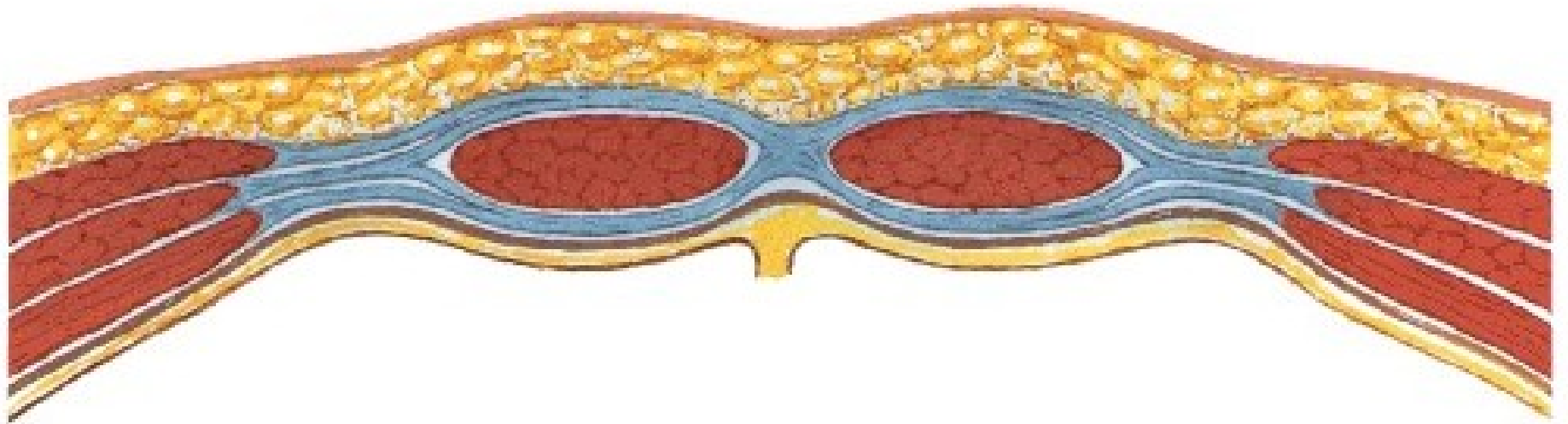
**NN. INTERCOSTALES**  
**N. SUBCOSTALIS**  
**N. ILIOHYPOGASTRICUS**  
**N. ILIOINGUINALIS**



**NODI LYMPHATICI AXILLARES**  
**NODI LYMPHATICI INGUINALES SPF.**

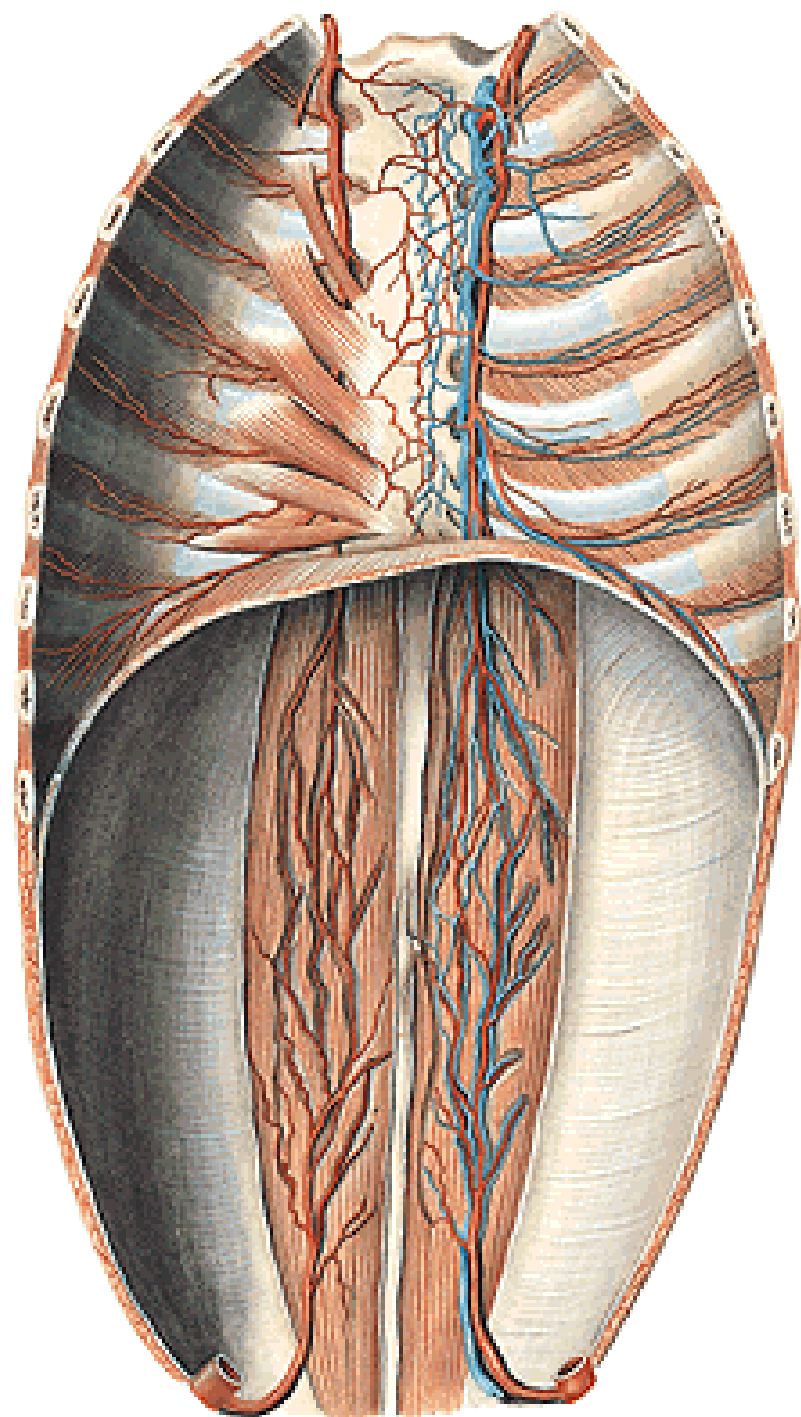




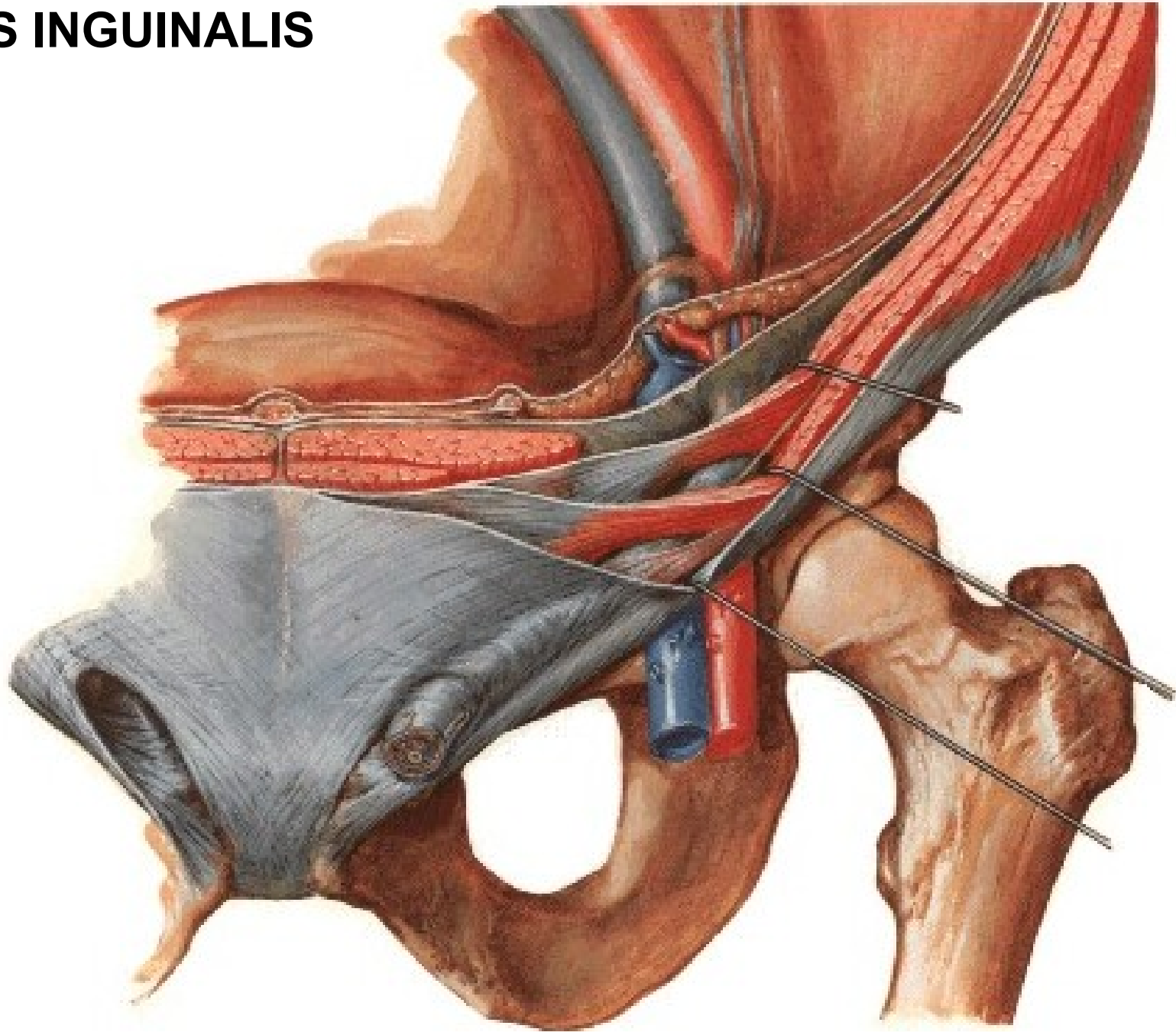




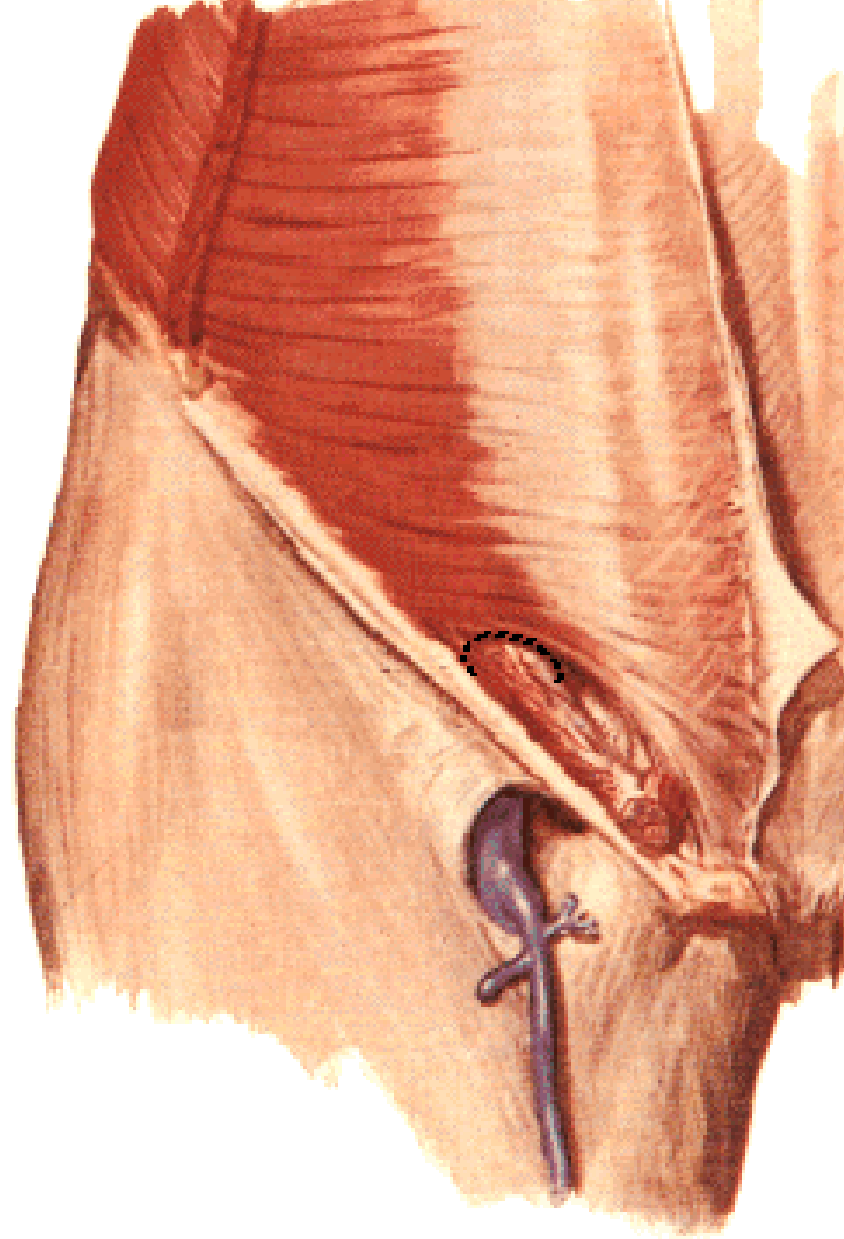
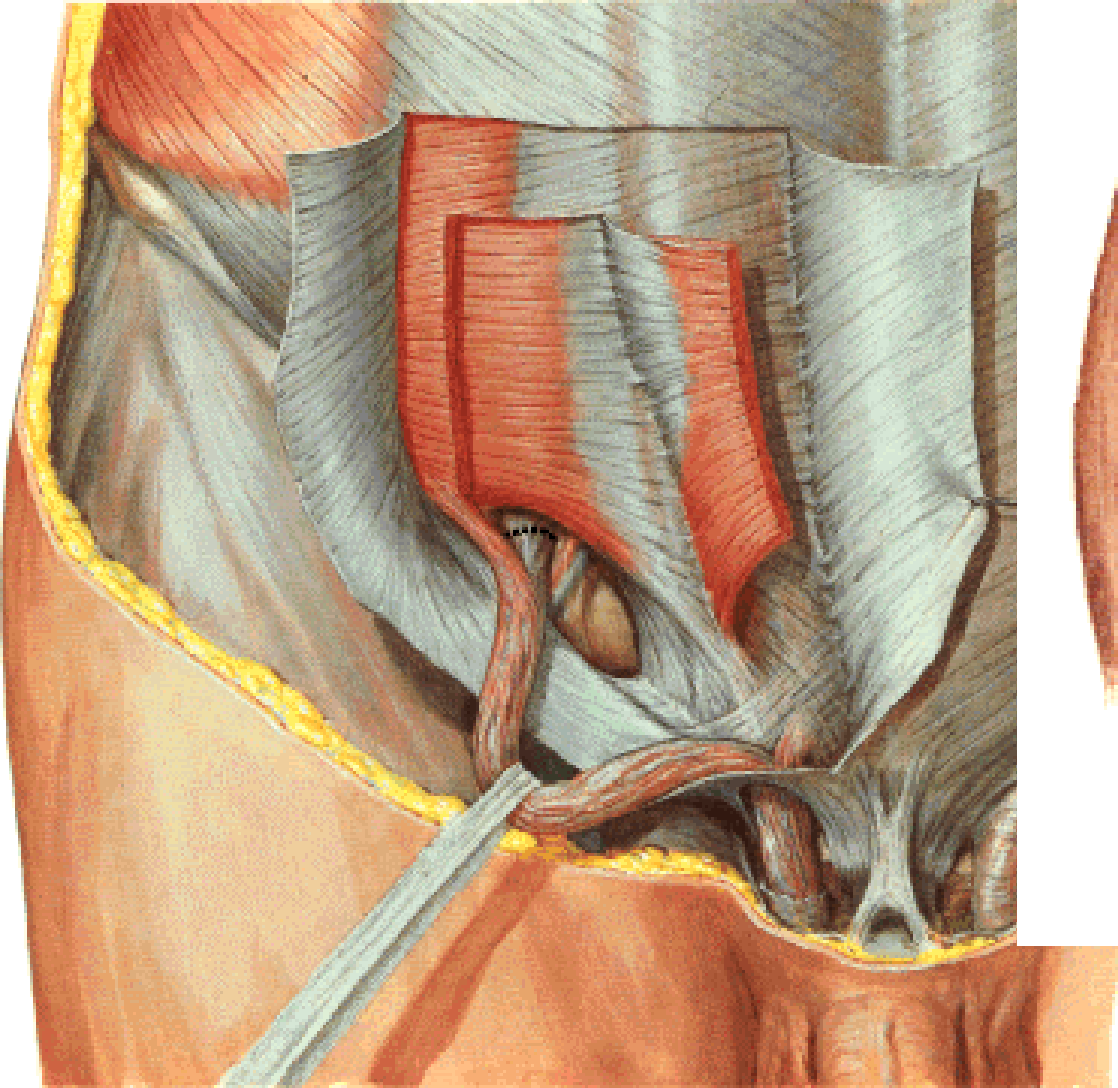
**A. EPIGASTRICA SUP.**  
**A. EPIGASTRICA INF.**  
**A. CIRCUMFLEXA ILIUM PROF.**  
**AA. INTERCOSTALES**  
**A. SUBCOSTALIS**  
**AA. LUMBALES**



# CANALIS INGUINALIS



# CANALIS INGUINALIS

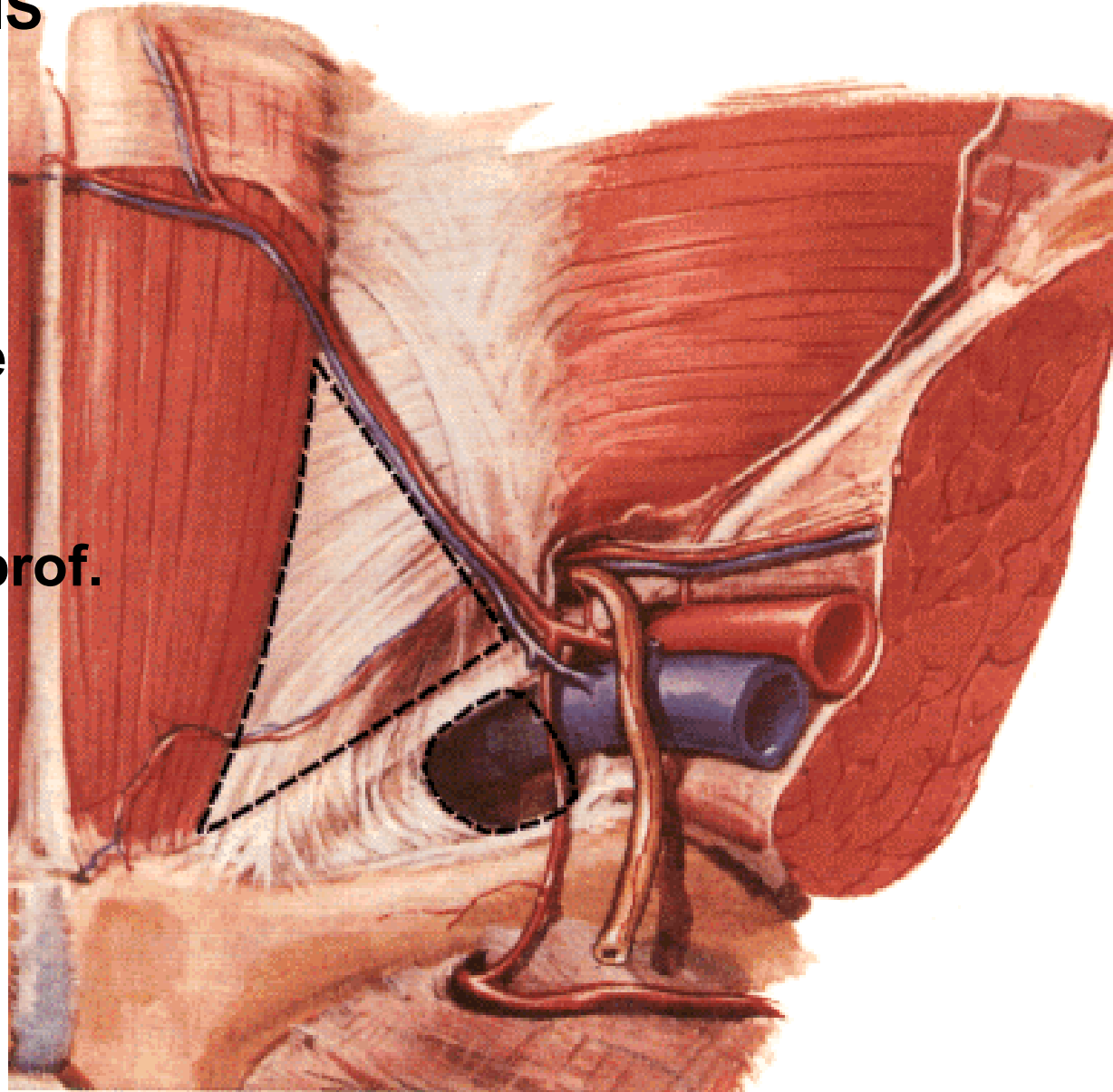


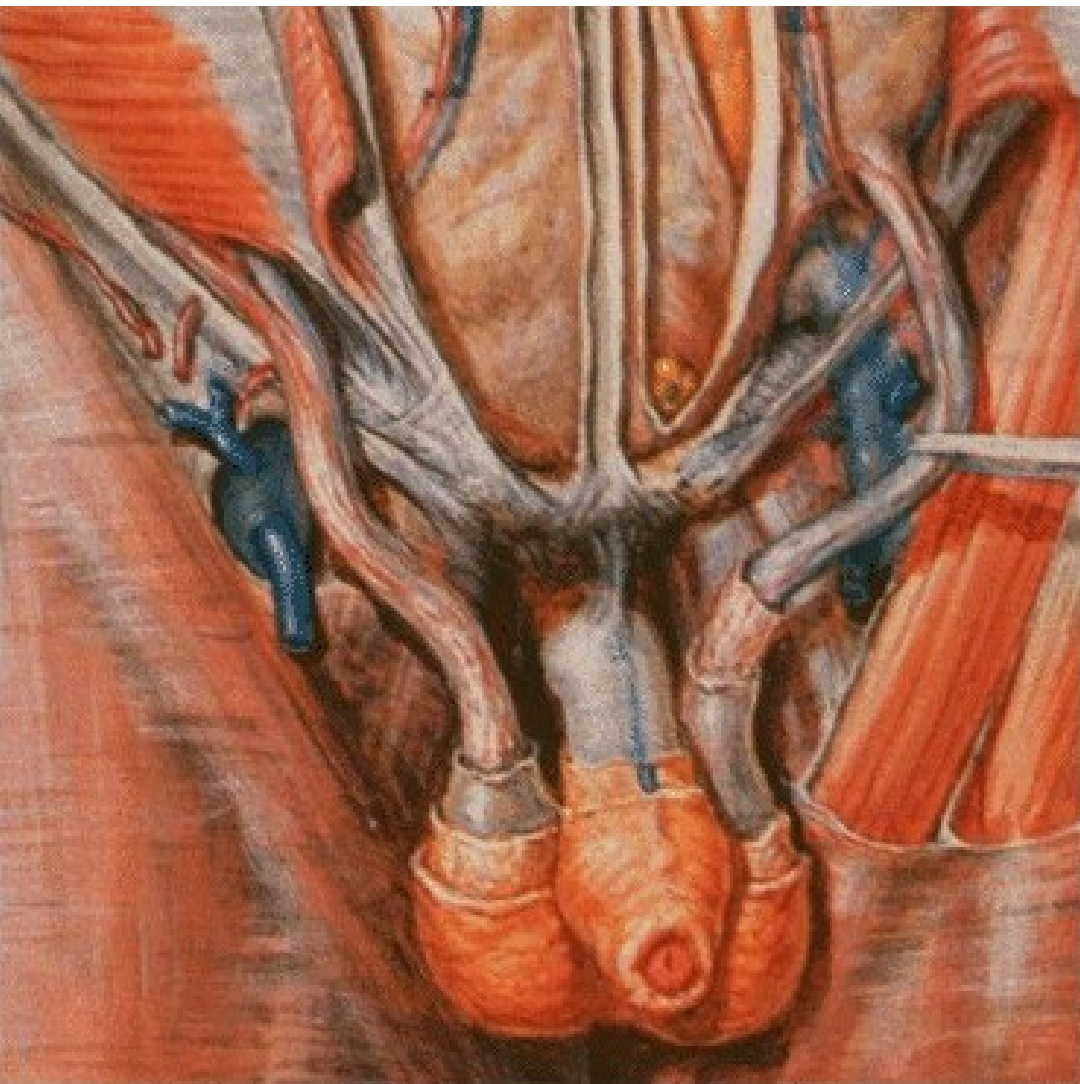
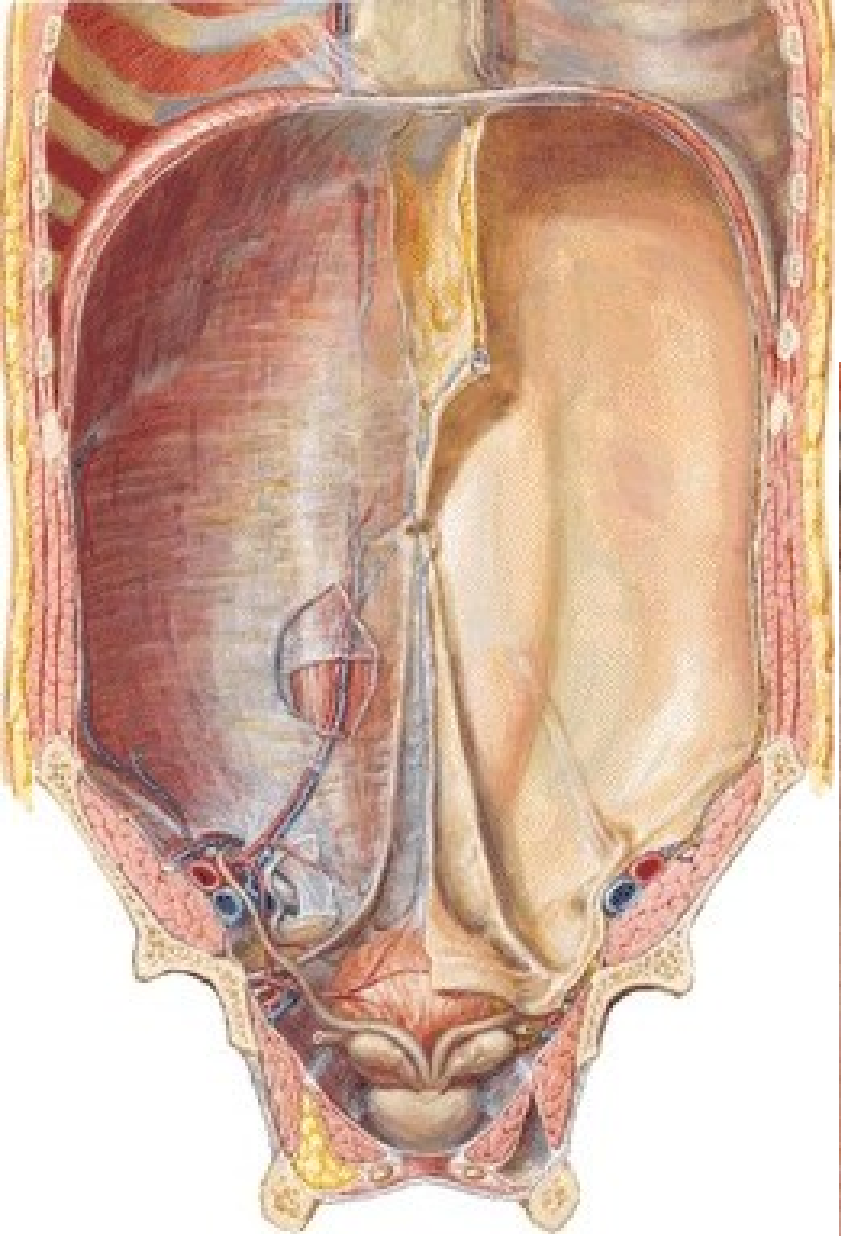
# CANALIS INGUINALIS

*Posterior wall:*

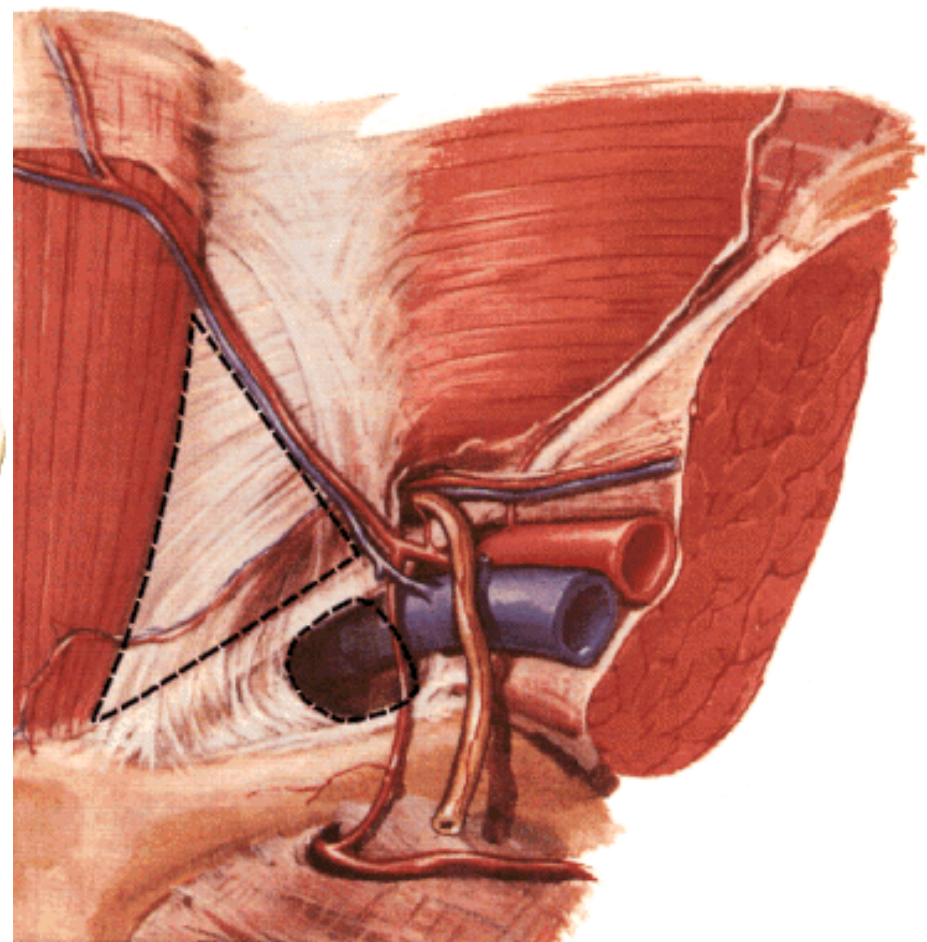
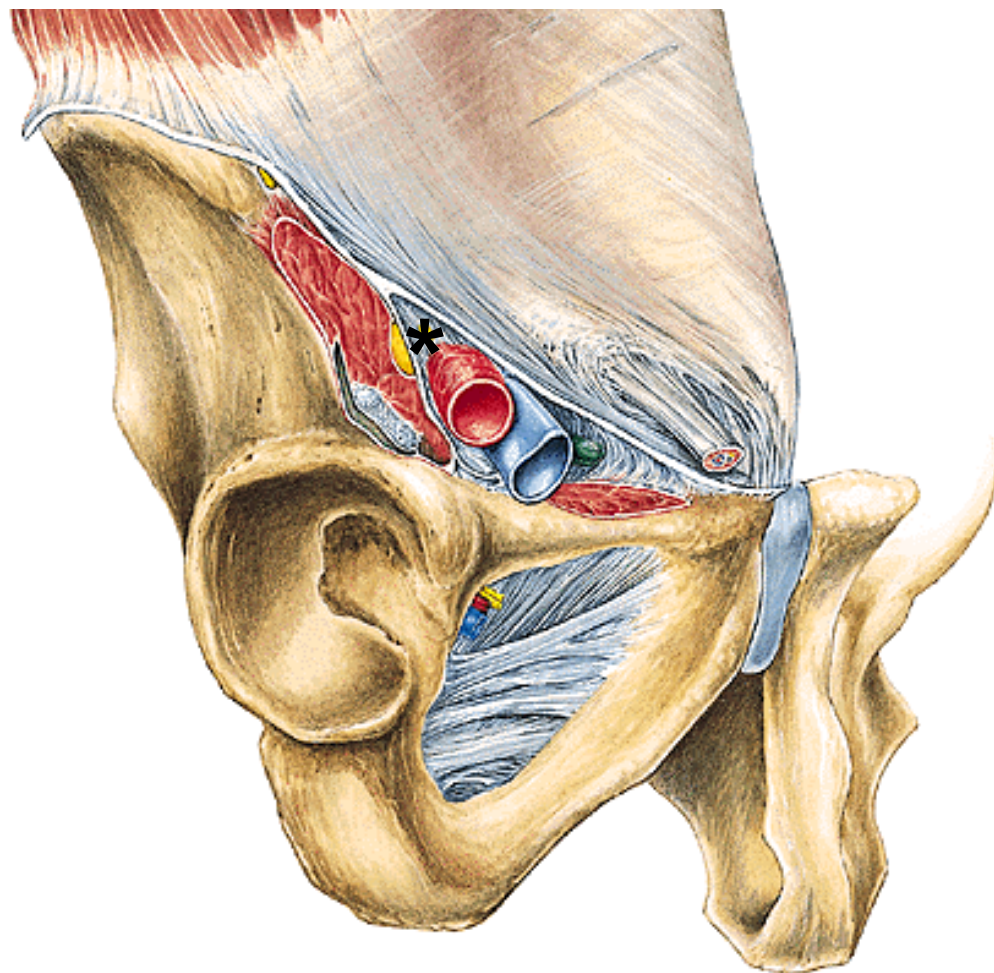
**Fascia transversalis**

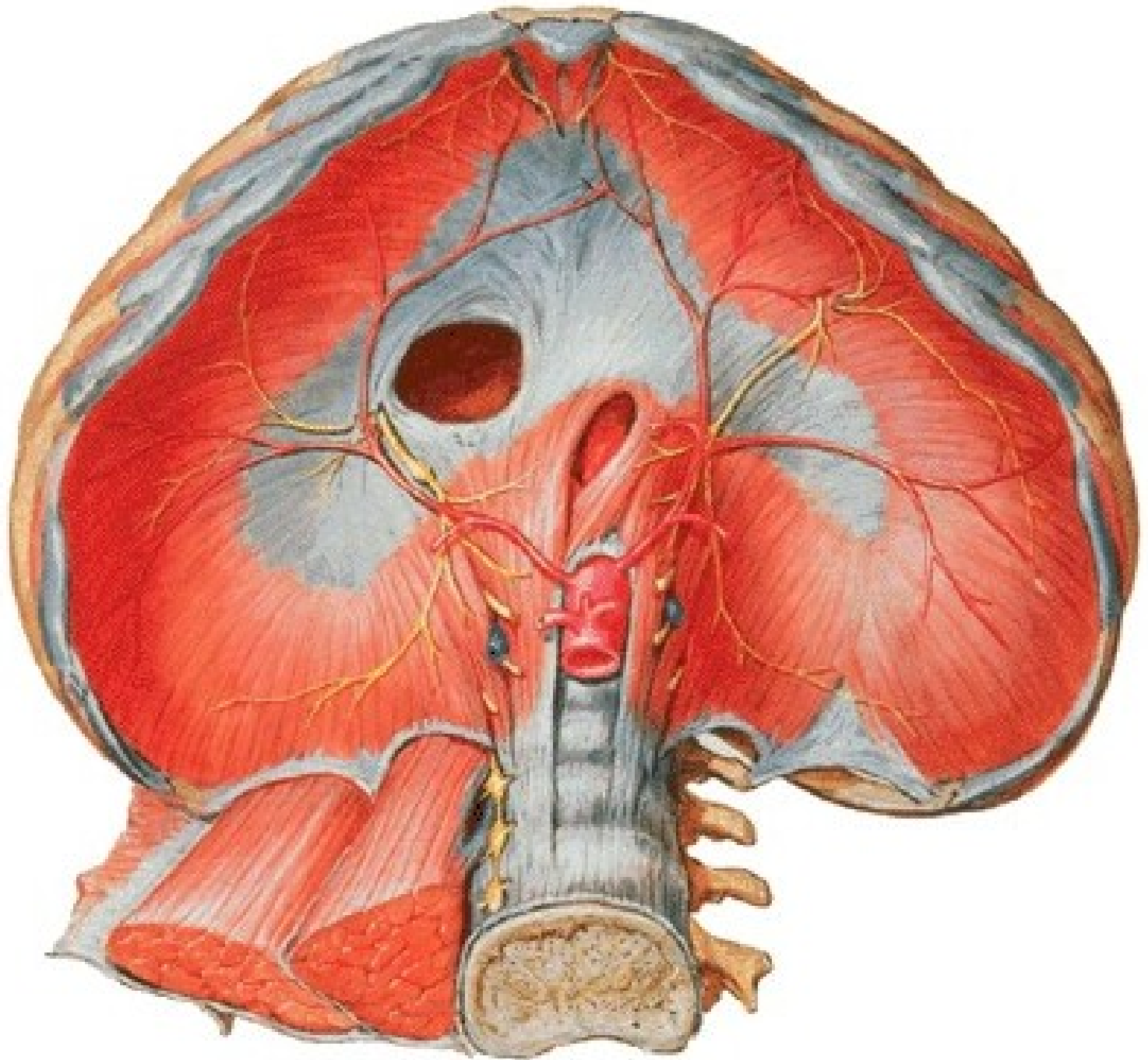
- falx inguinalis
- trigonum inguinale (Hesselbachi)
- lig. interfoveolare
- anulus inguinalis prof.





**\*Lacuna vasorum – anulus femoralis**  
**Lacuna musculorum**



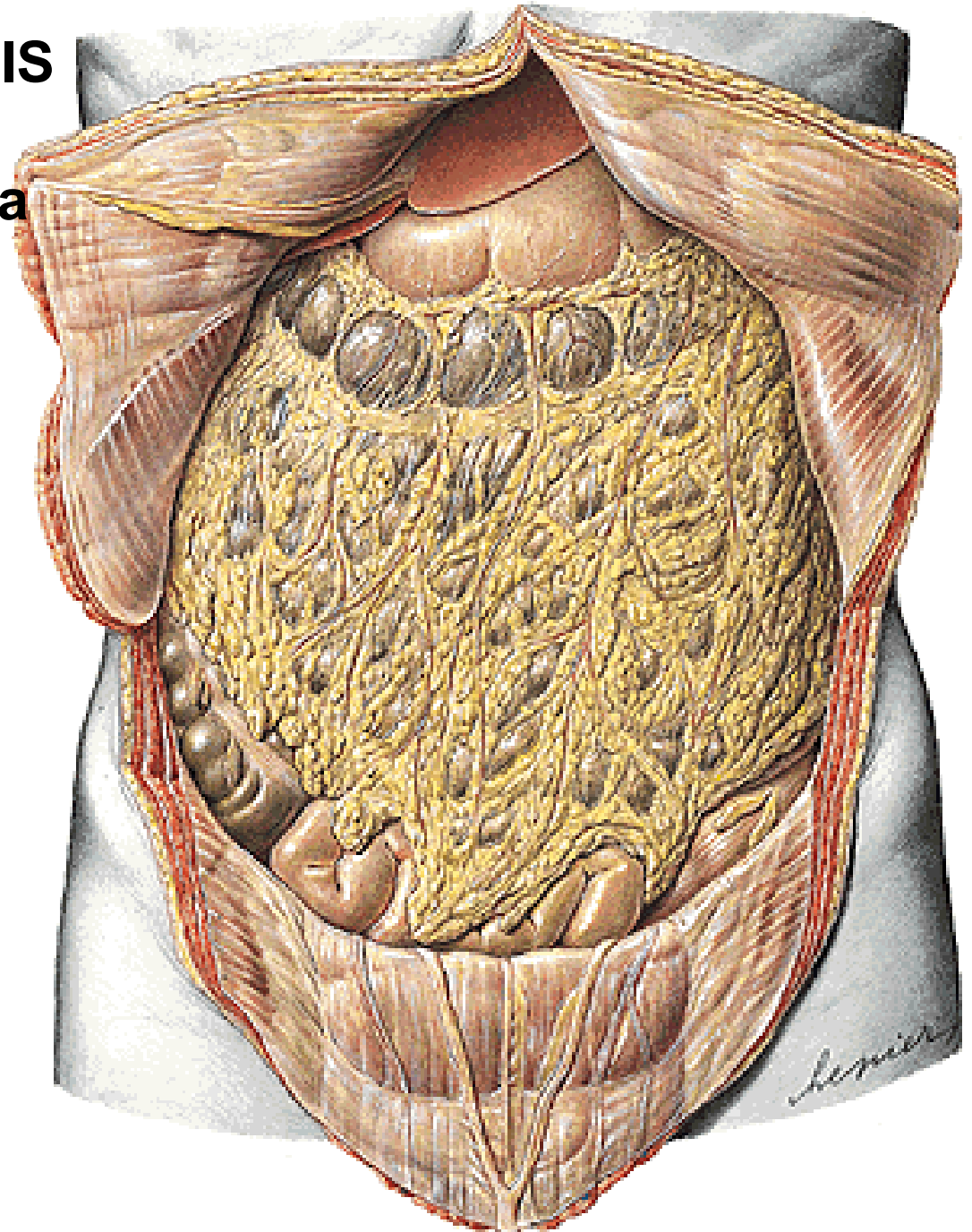


# **CAVITAS PERITONEALIS**

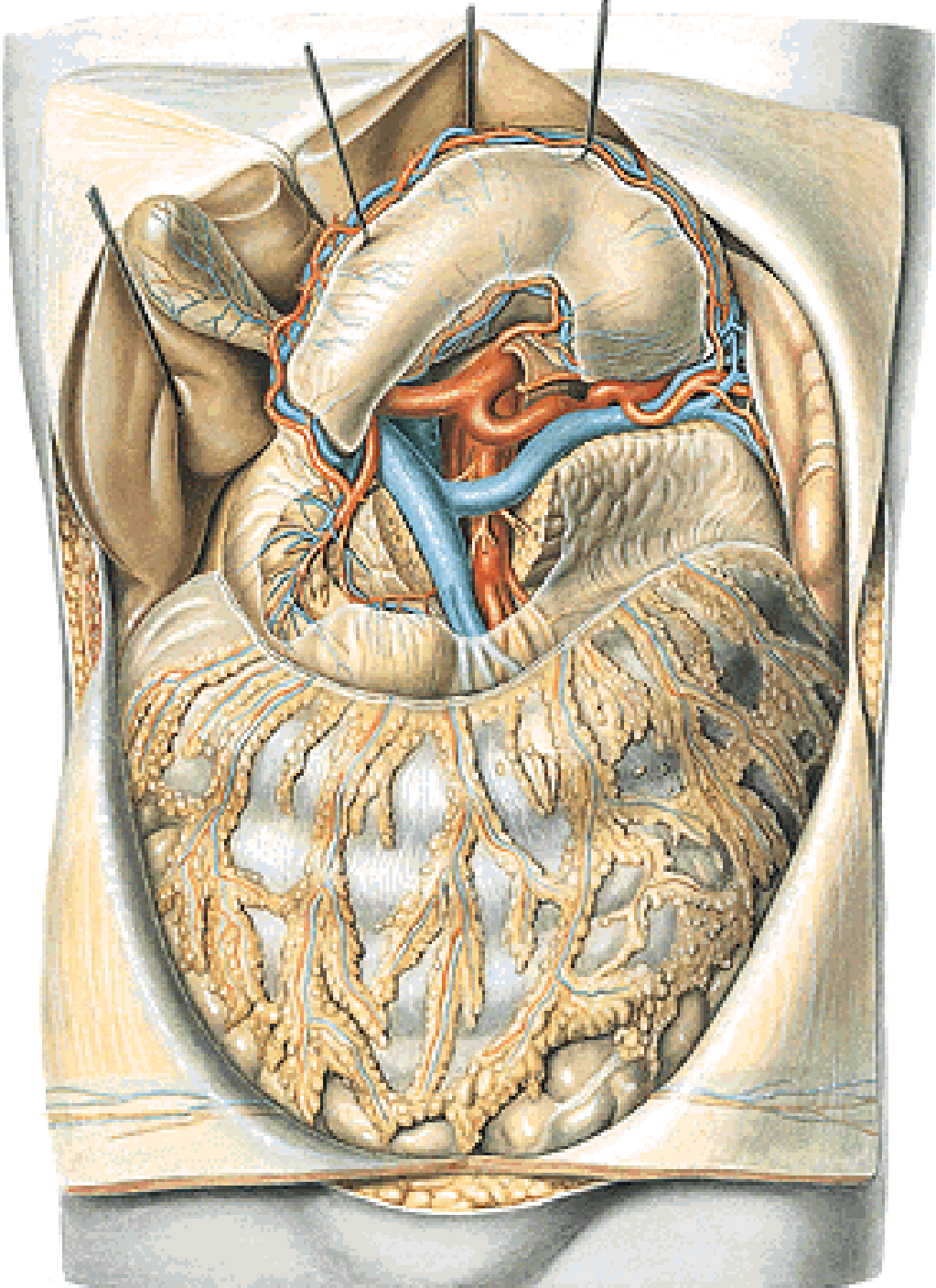


# CAVITAS PERITONEALIS

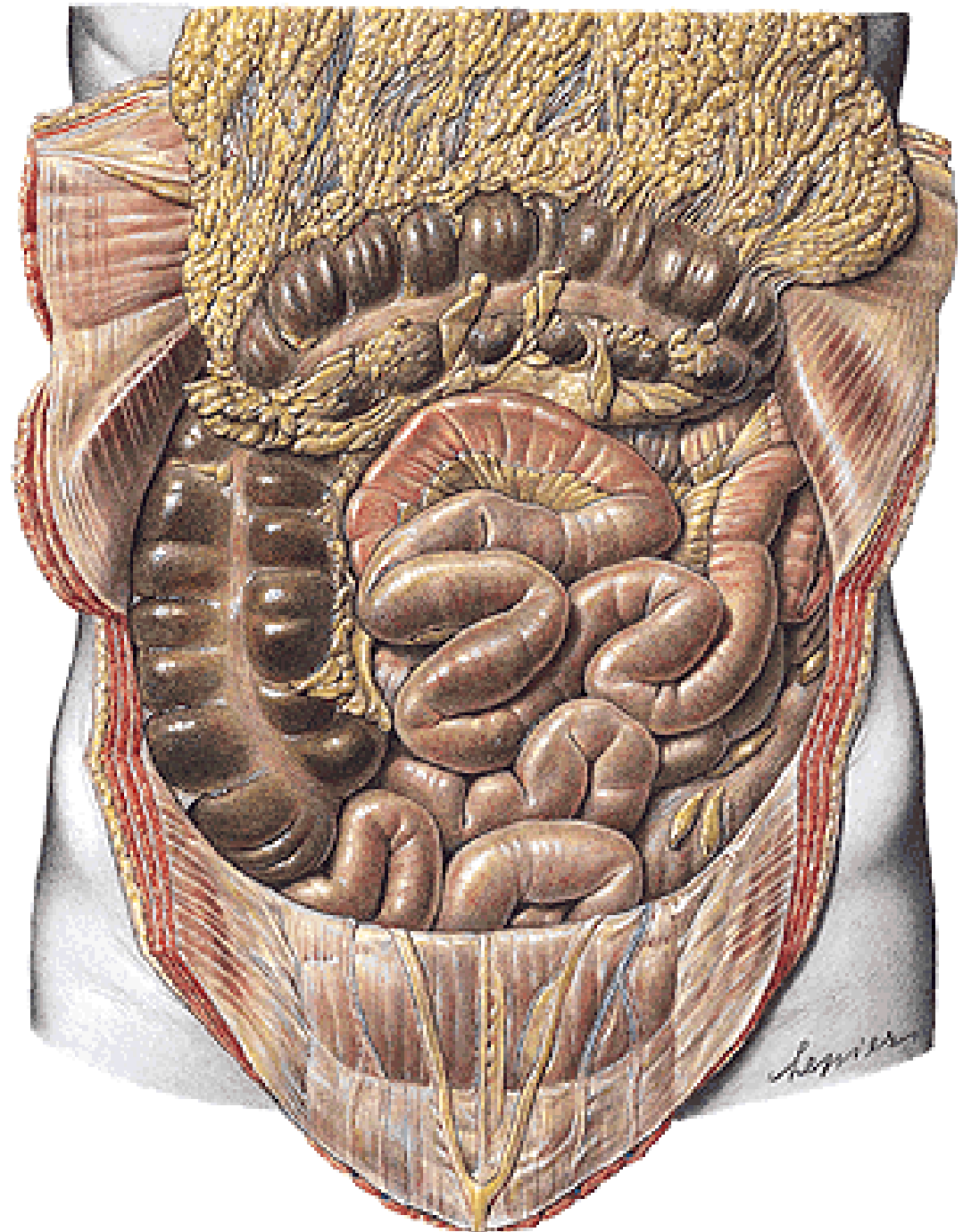
- pars supramesocolica
- pars inframesocolica

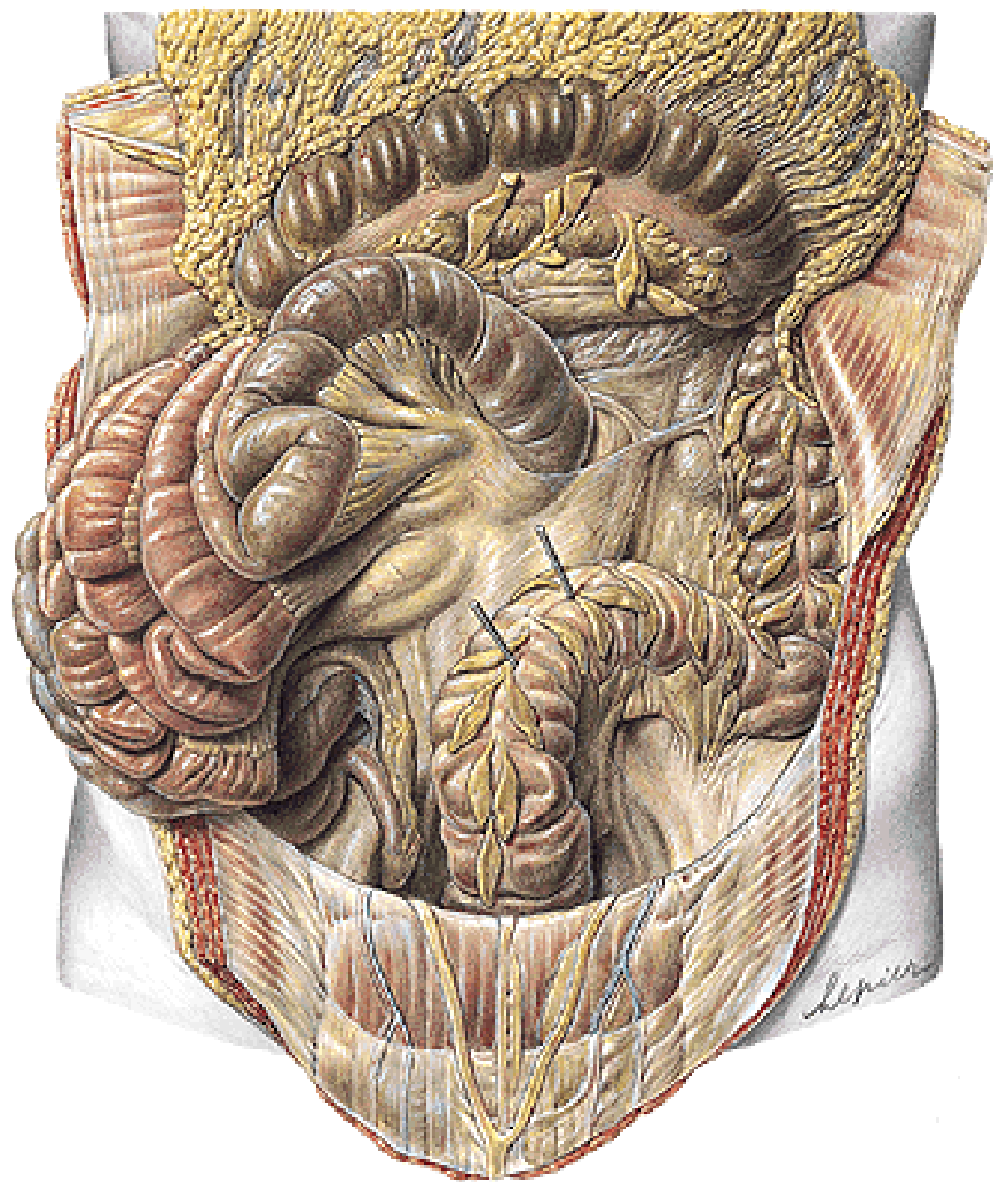


**Pars supramesocolica  
(truncus coeliacus)**

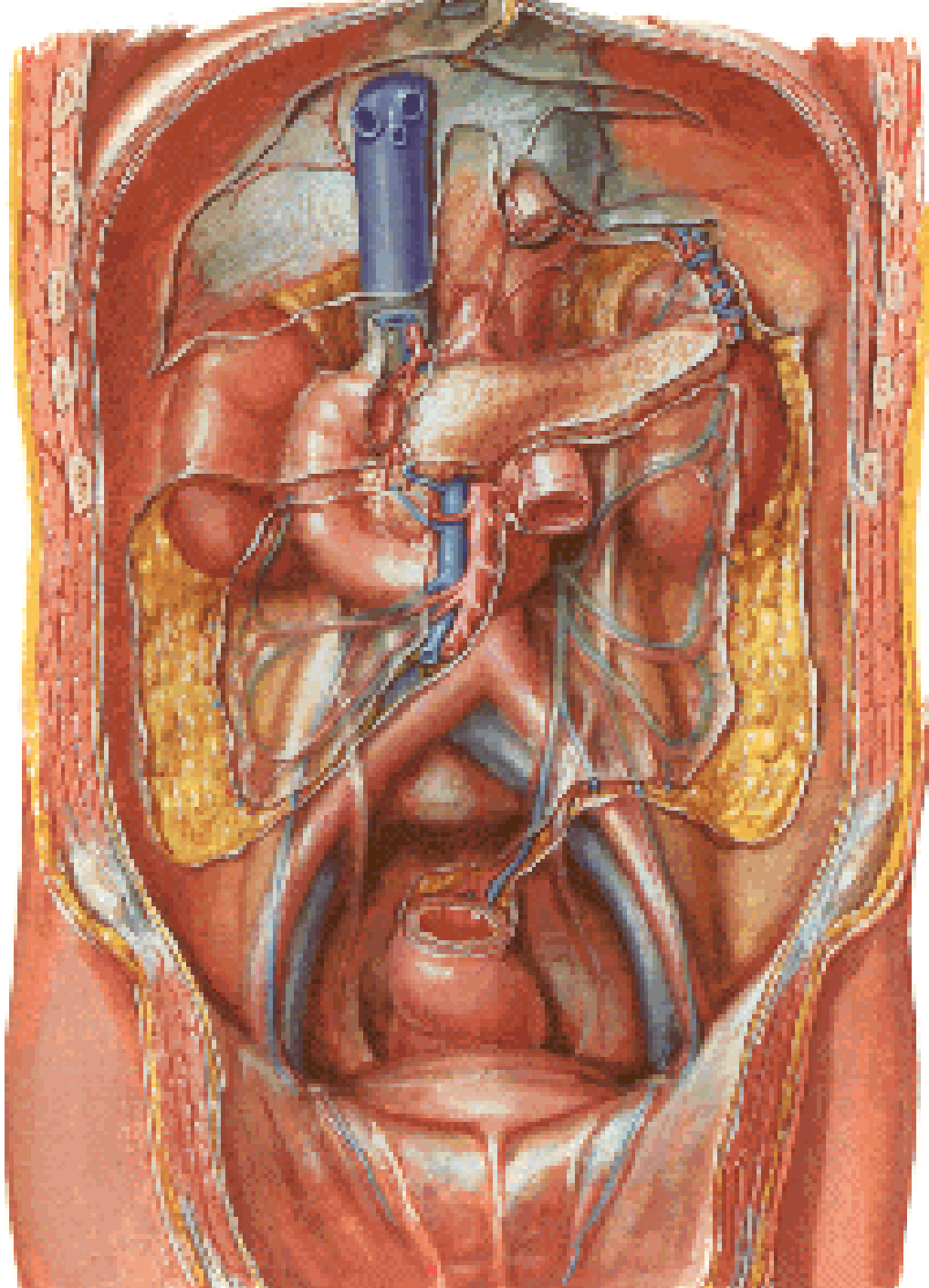


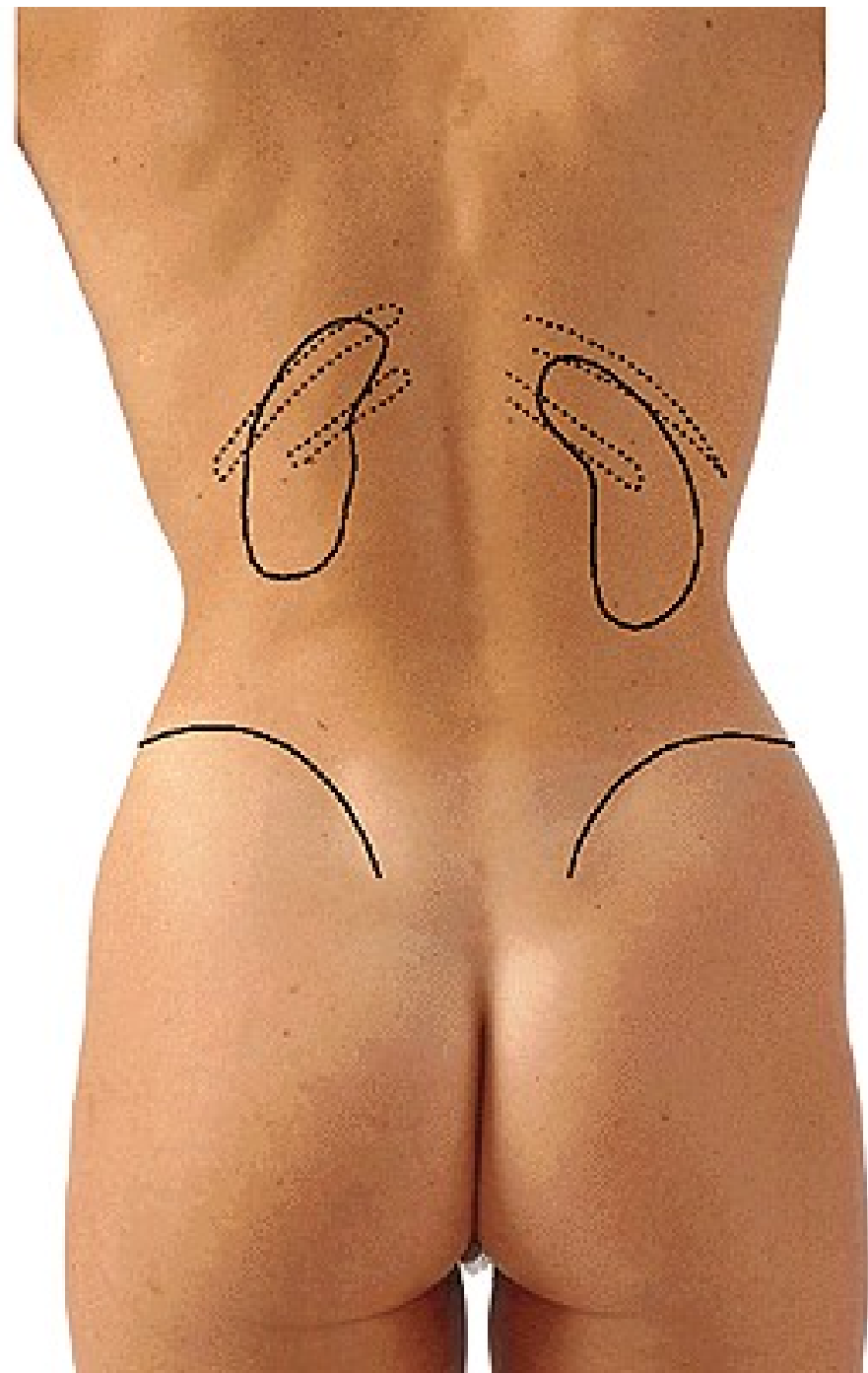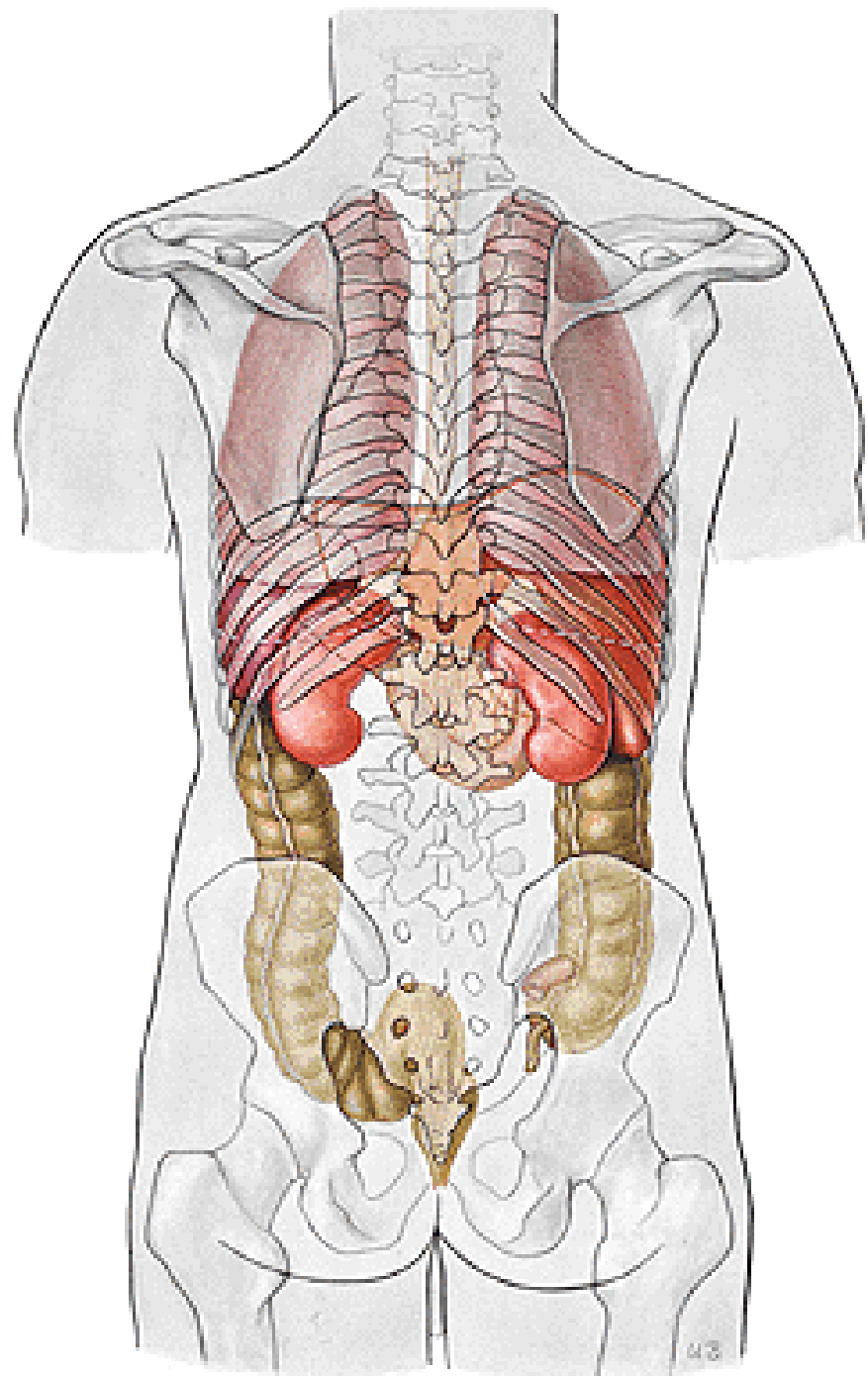
# Pars inframesocolica





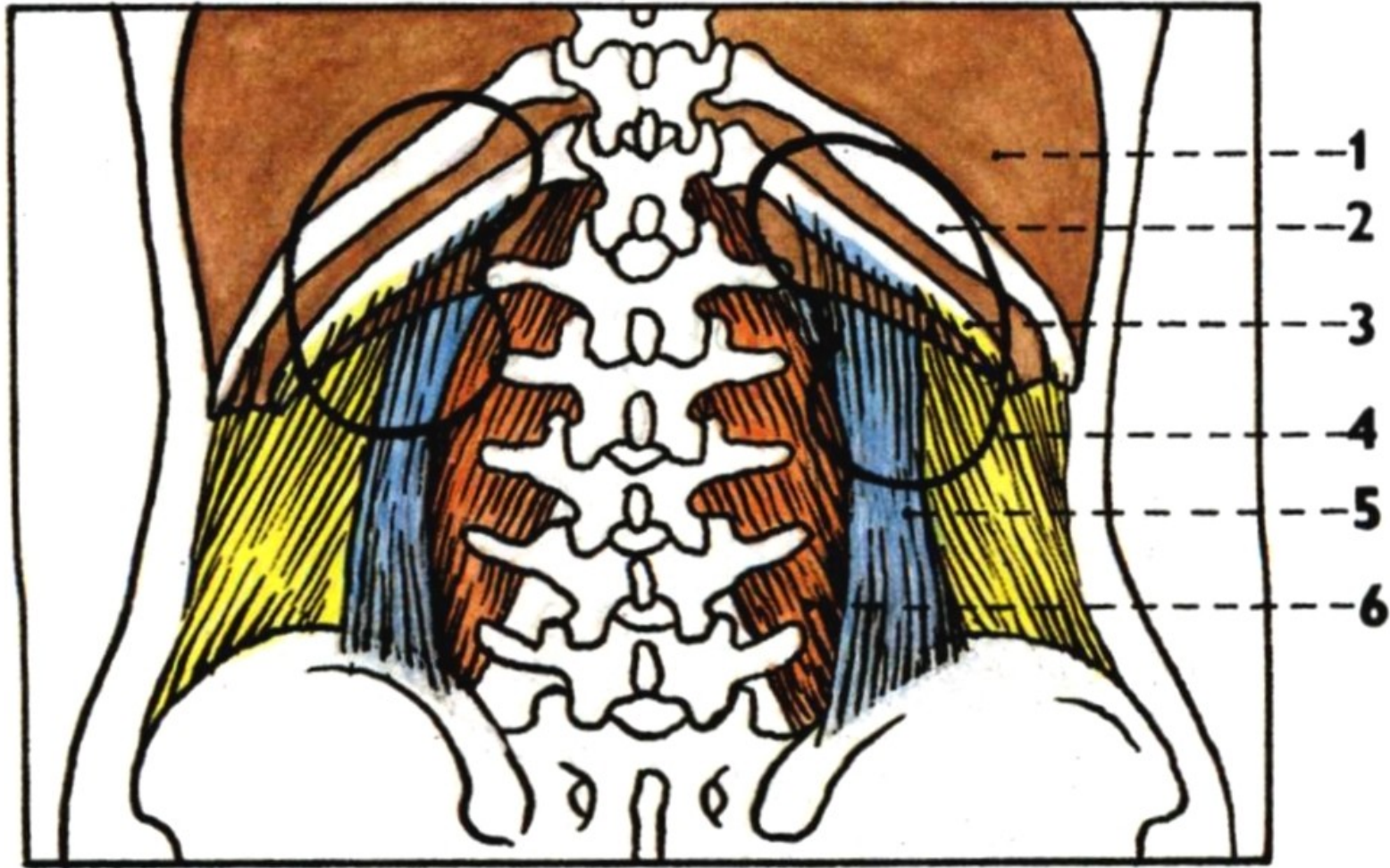
# **SPATIUM RETROPERITONEALE**





- 1. diaphragma
- 2. 11<sup>th</sup> rib
- 3. 12<sup>th</sup> rib

- 4. m. transversus abdominis
- 5. m. quadratus lumborum
- 6. m. psoas major

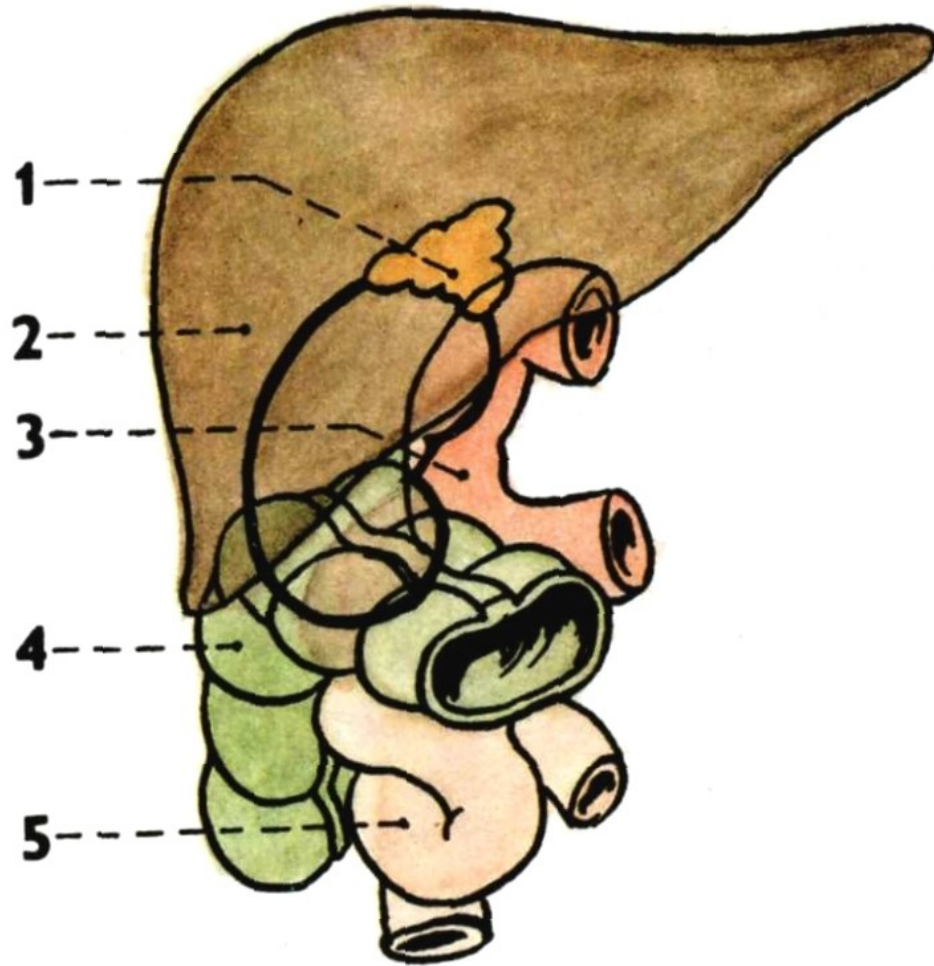


SIN.

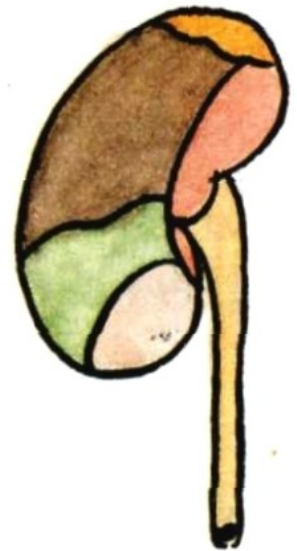
DX.



1. gl. suprarenalis dx.
2. liver
3. duodenum
4. flexura coli dx.
5. jejunum

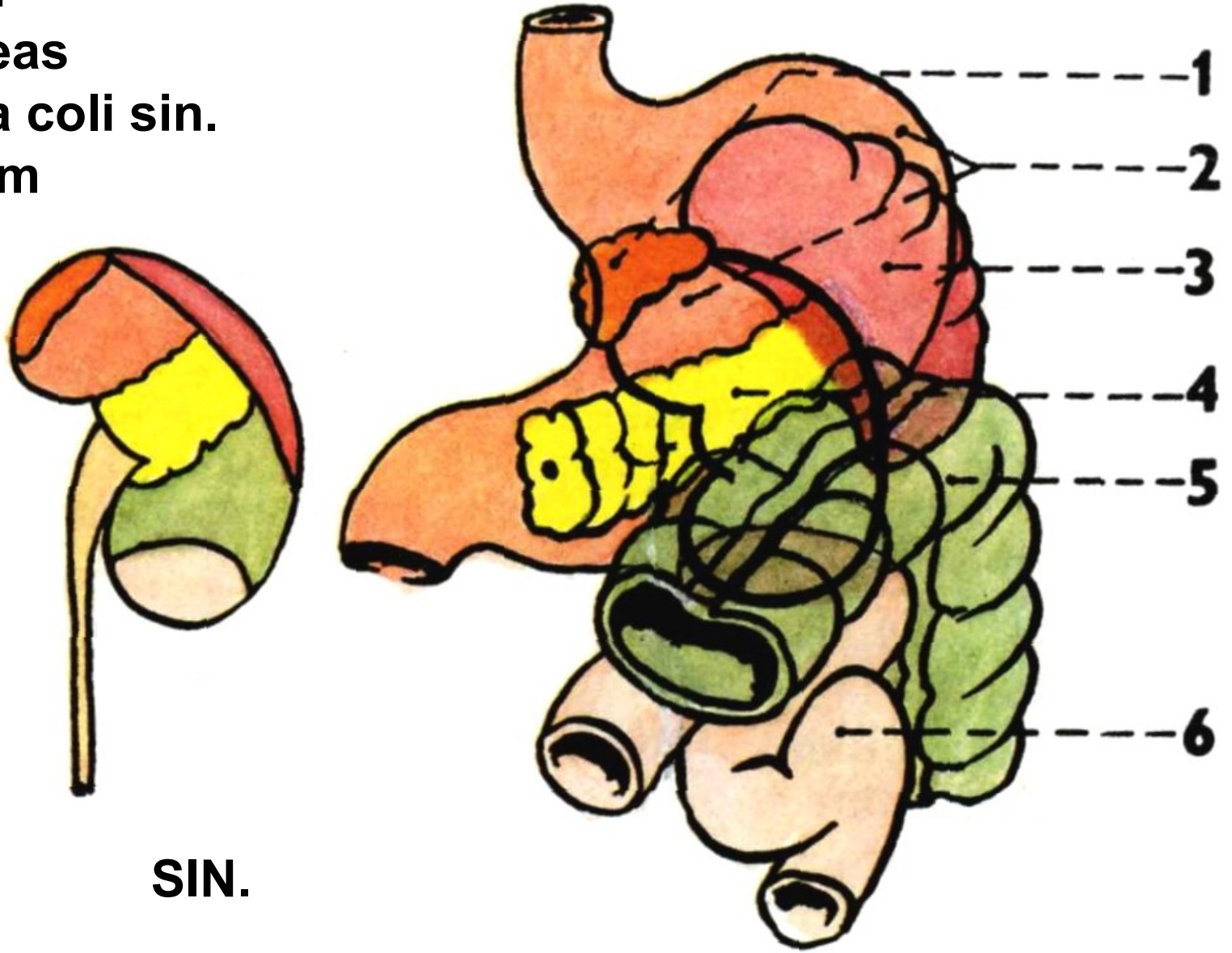


**DX.**



**DX.**

1. gl. suprarenalis sin.
2. stomach
3. spleen
4. pancreas
5. flexura coli sin.
6. jejunum



**SIN.**

1. fascia renalis
2. lamina praerenalis
3. lamina retrorenalis
4. capsula adiposa

5. corpus adiposum pararenale
6. peritoneum
7. fascia transversalis

