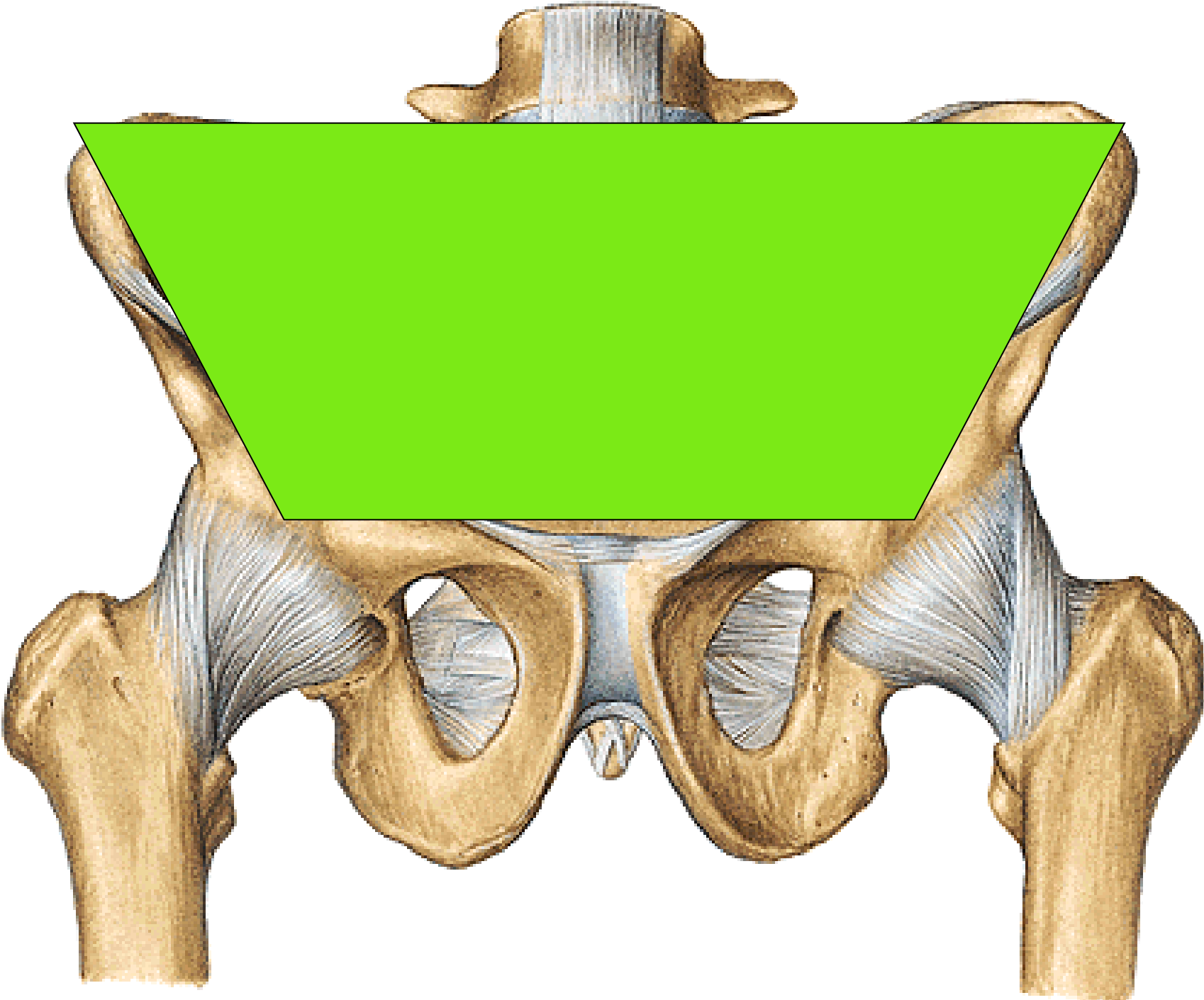
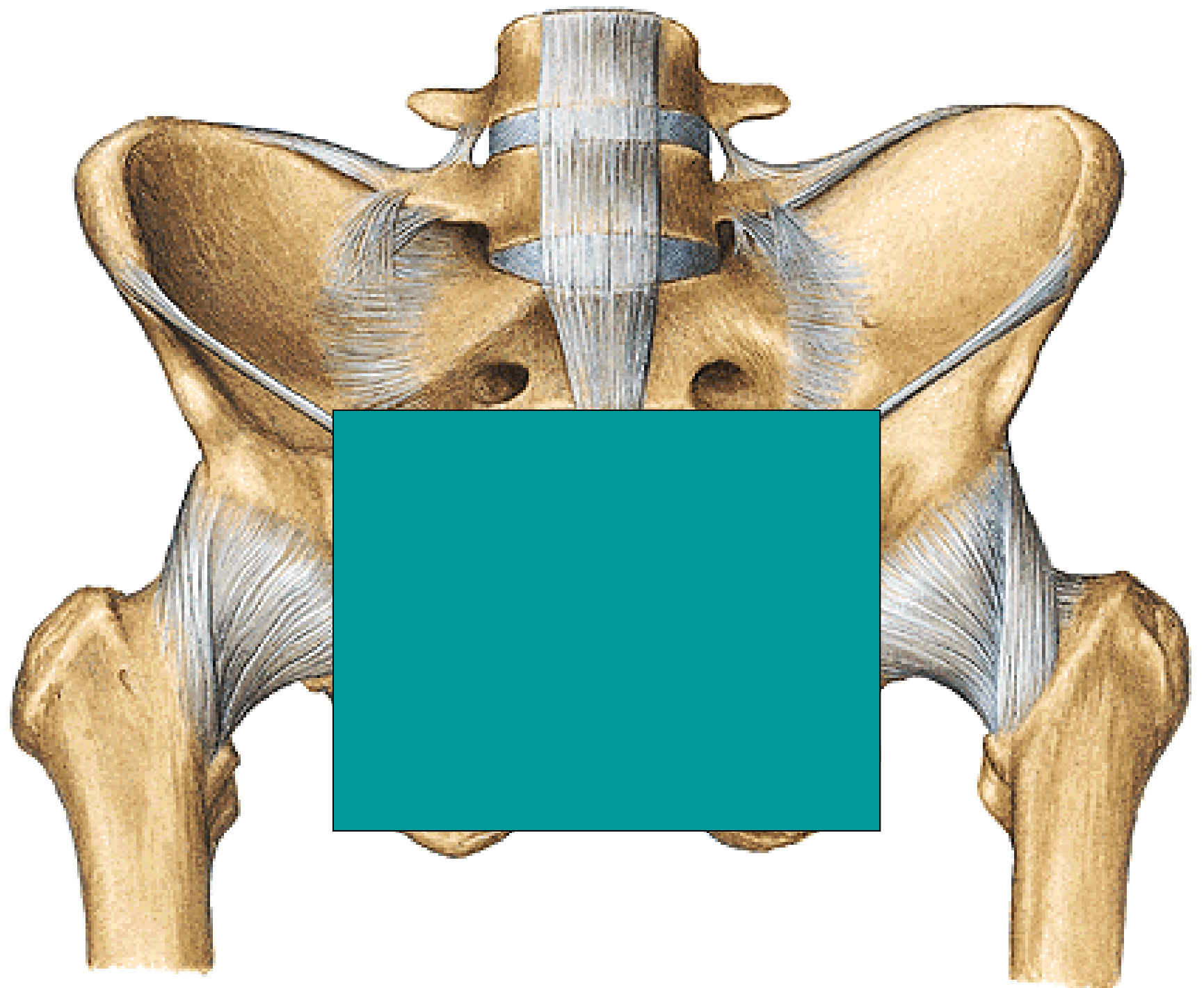
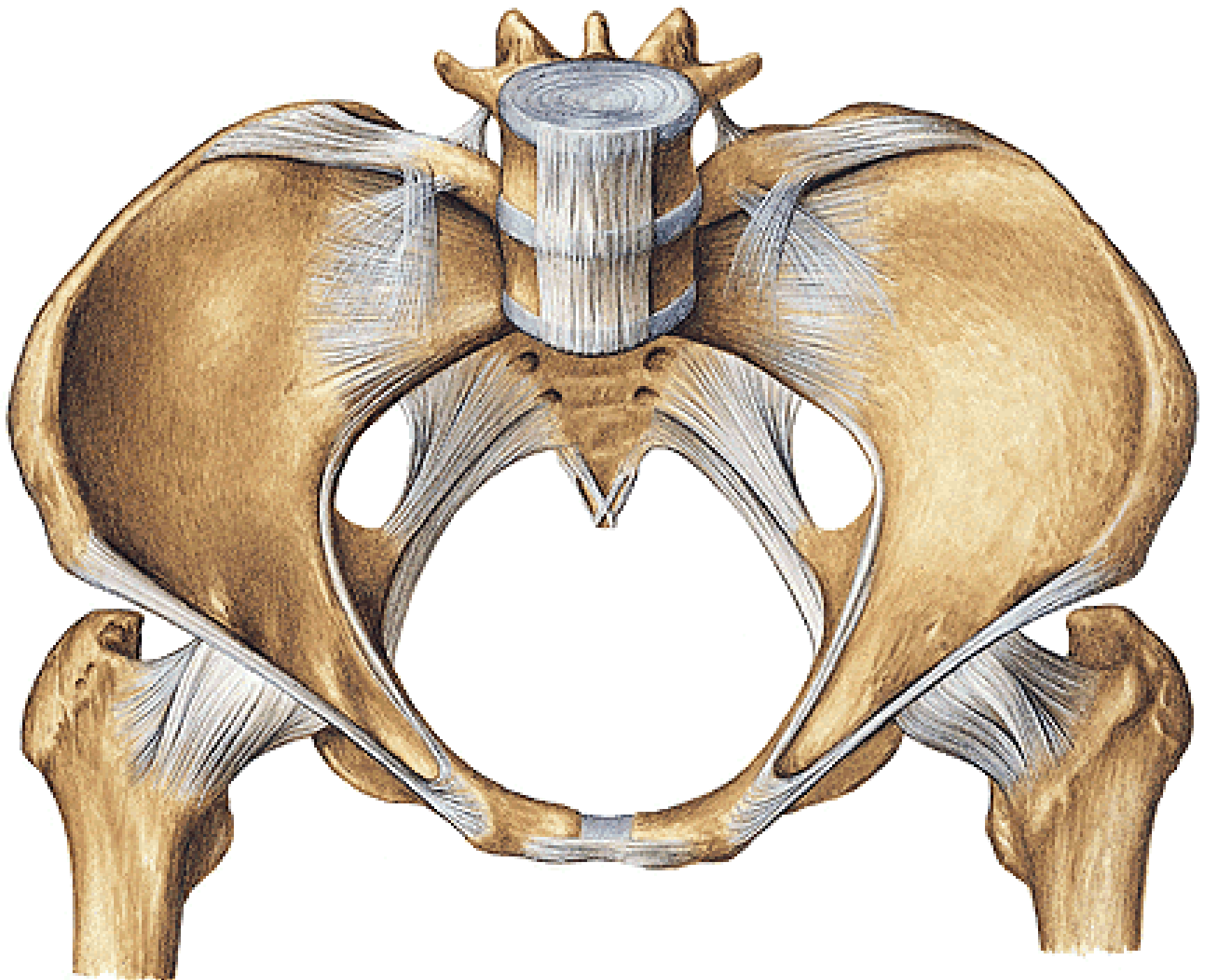


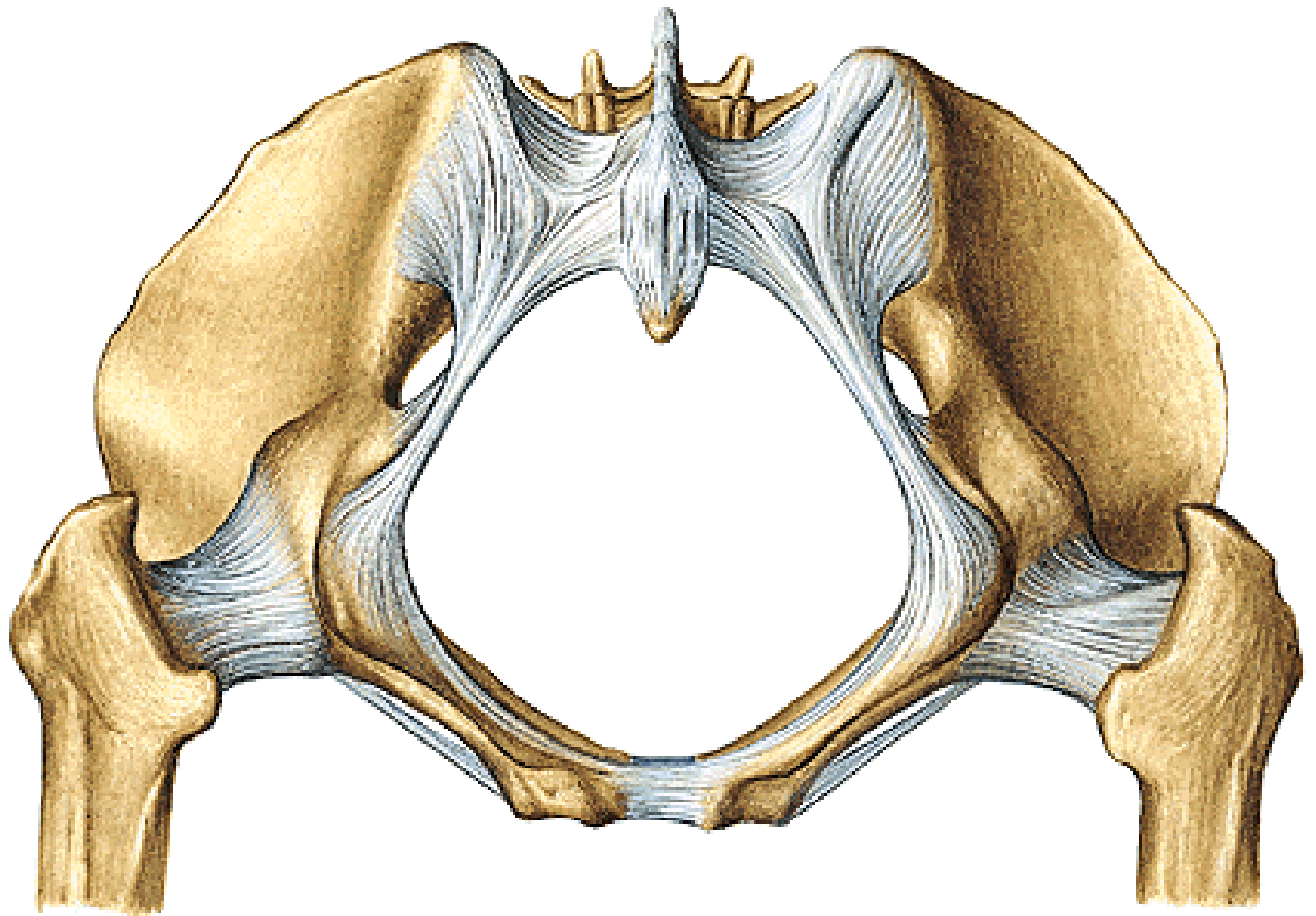
REGIONAL ANATOMY

OF THE PELVIS

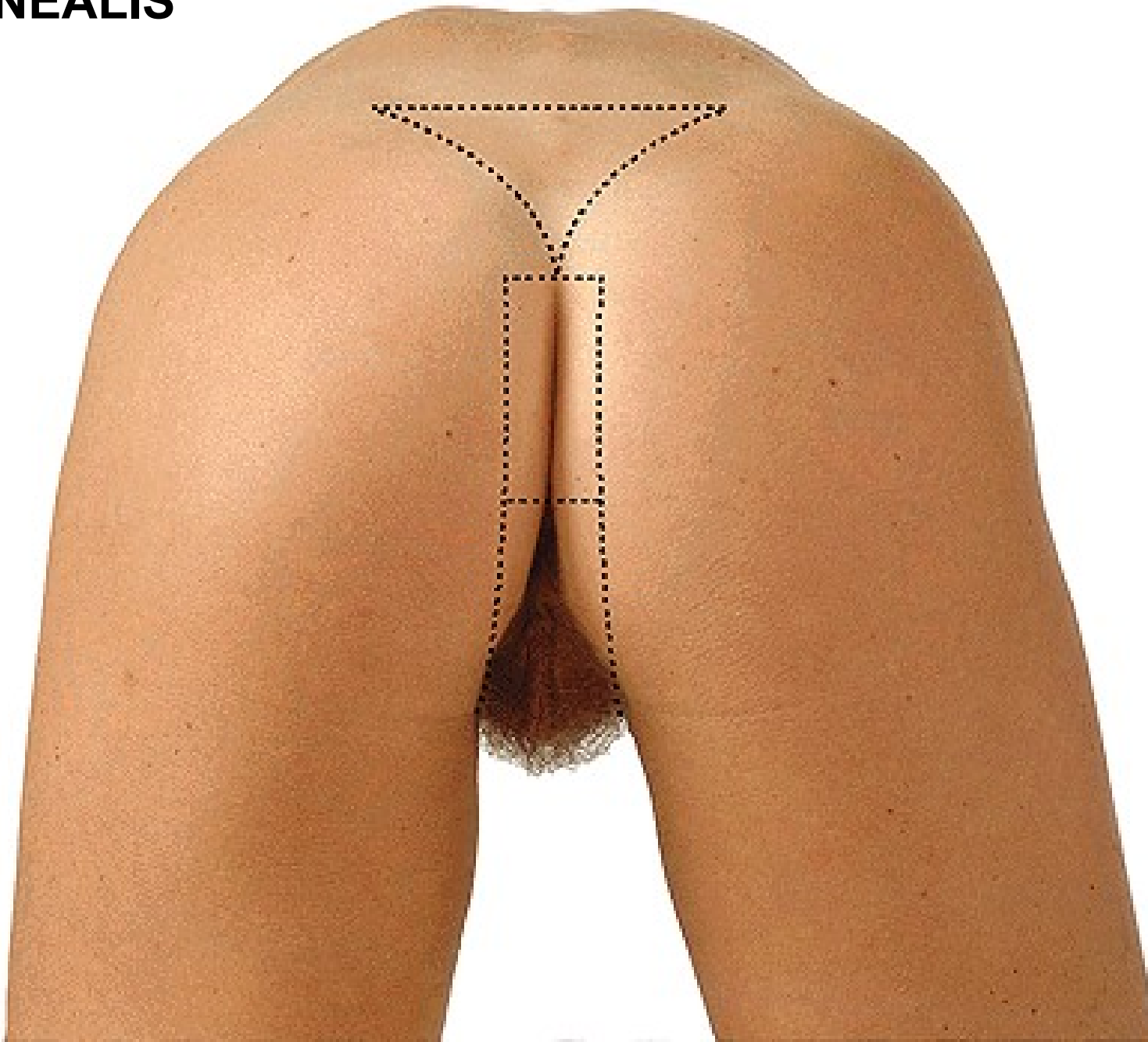








REGIO PERINEALIS

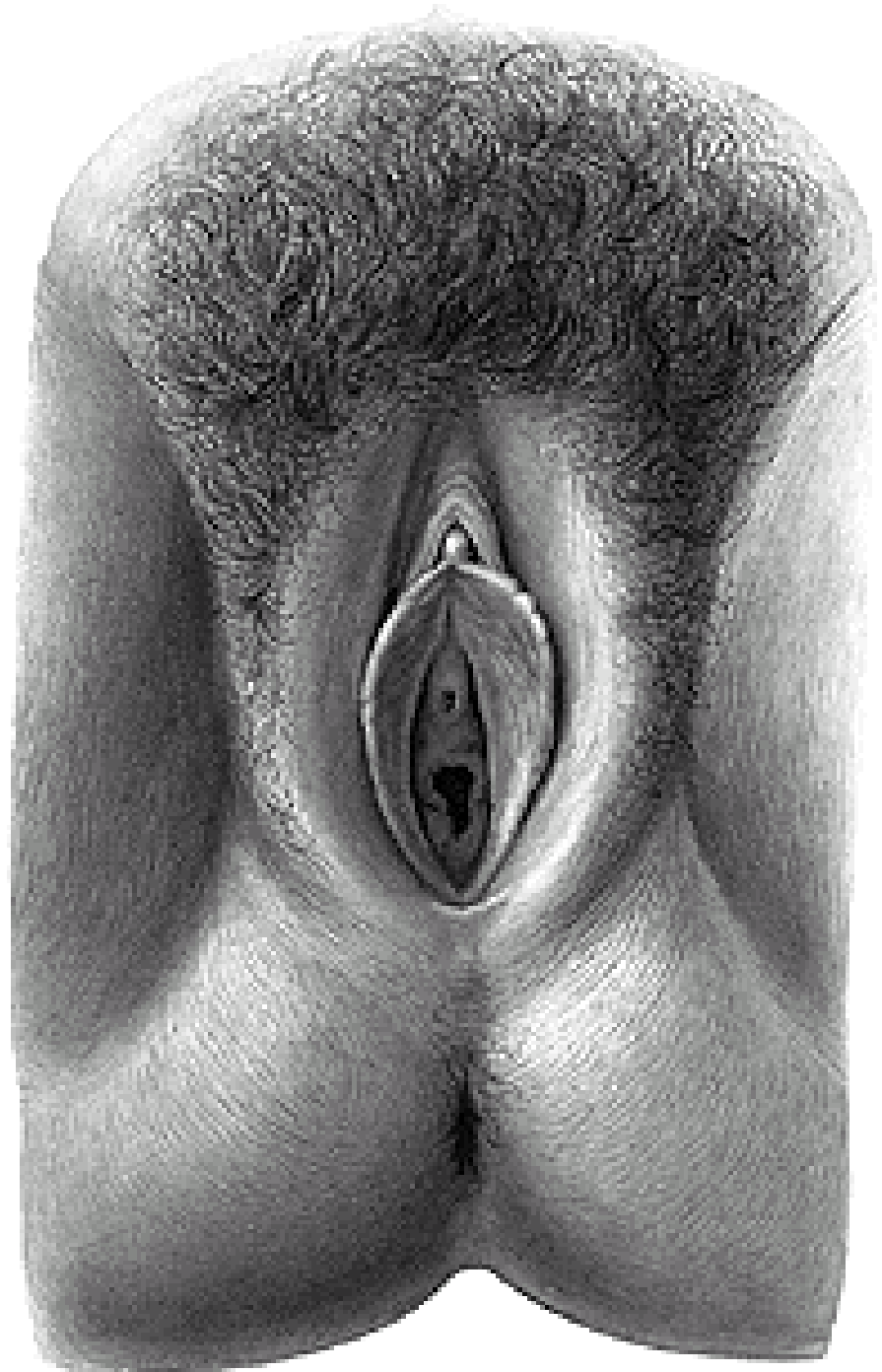

REGIO ANALIS

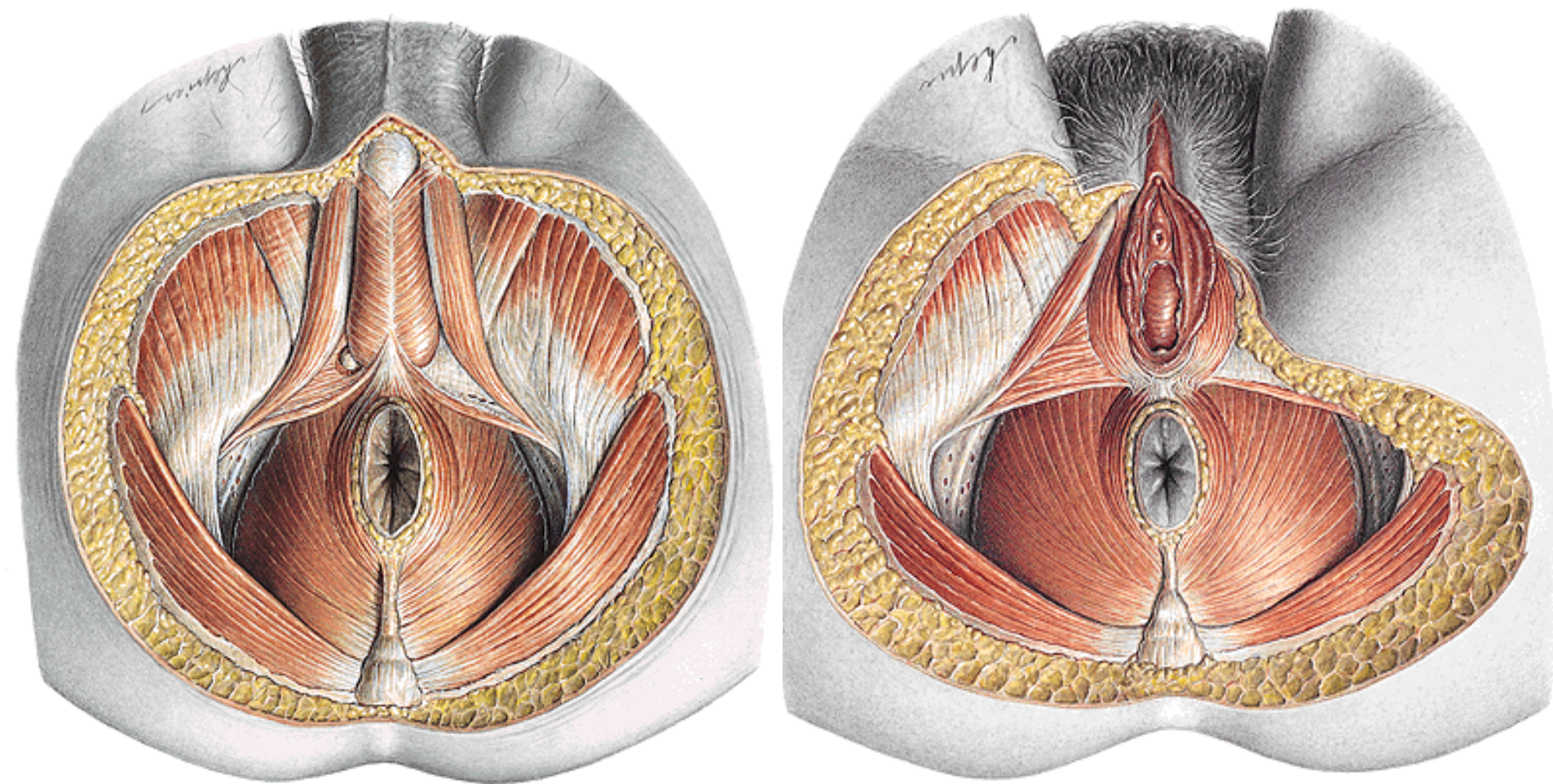
ANUS

RAPHE

GLANDULAE CIRCUMANNALES



**DIAPHRAGMA PELVIS
DIAPHRAGMA UROGENITALE
FOSSA ISCHIORECTALIS**

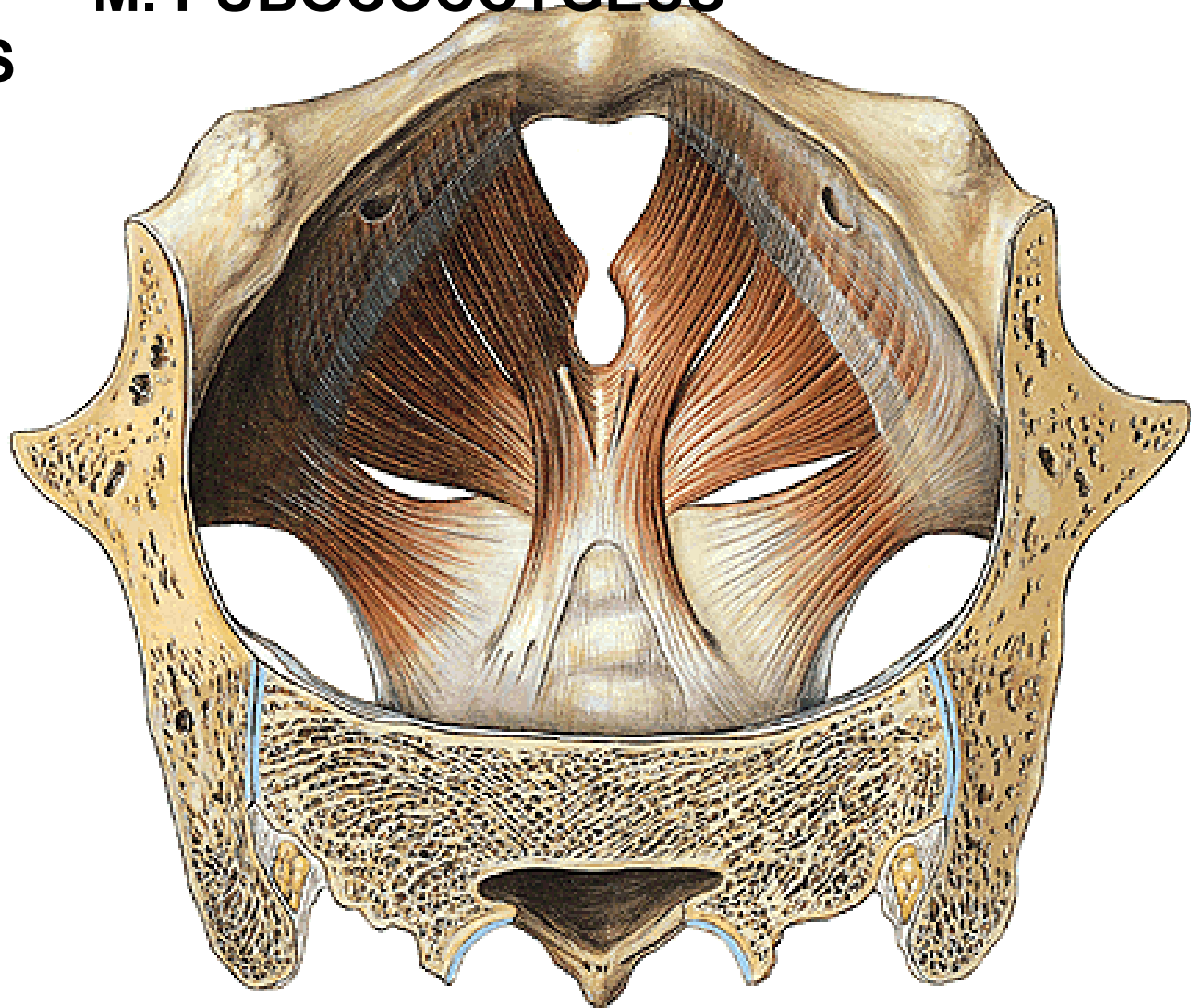


DIAPHRAGMA PELVIS

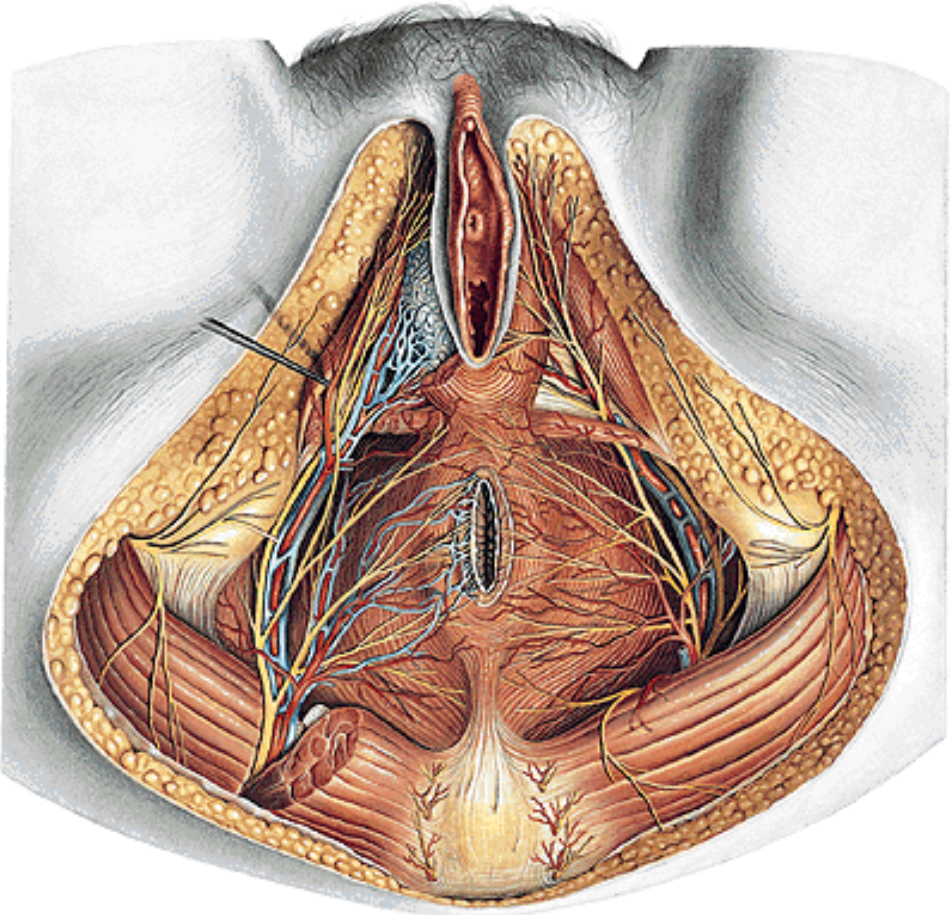
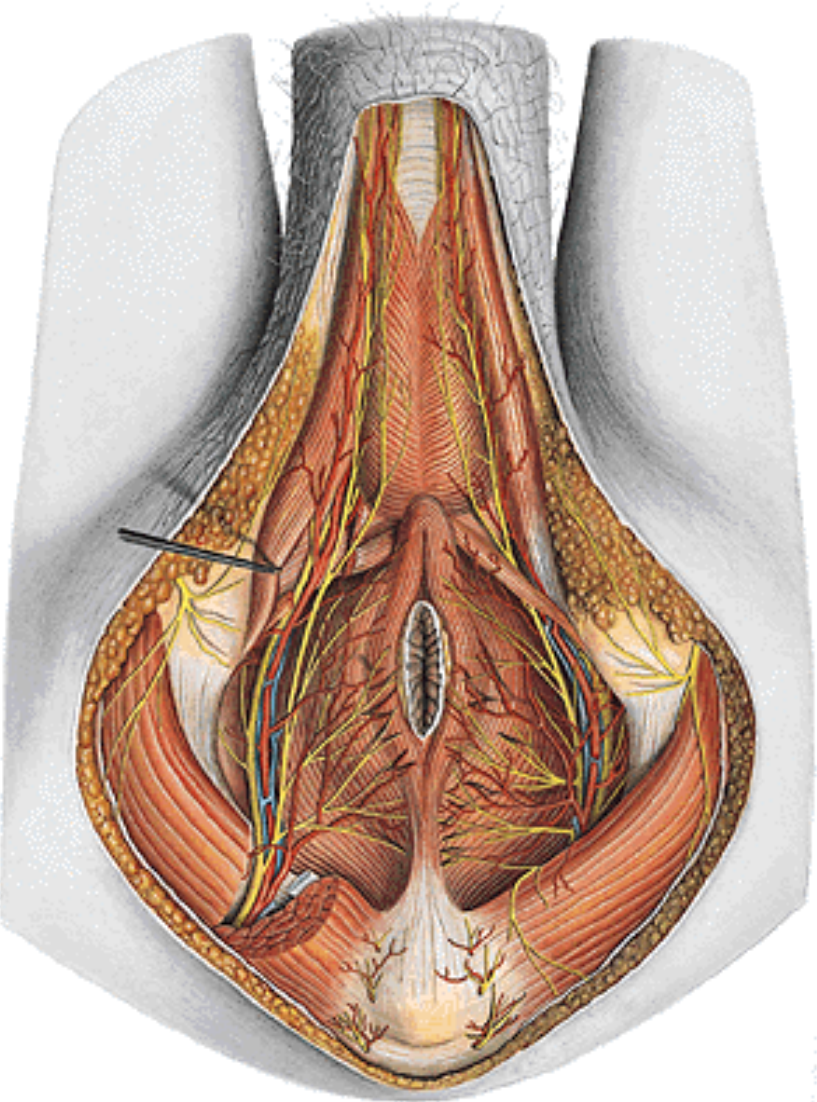
- M. LEVATOR ANI – M. ILIOCOCYGEUS
- M. PUBOCOCYGEUS
- M. COCCYGEUS

Arcus tendineus
m. levatoris ani

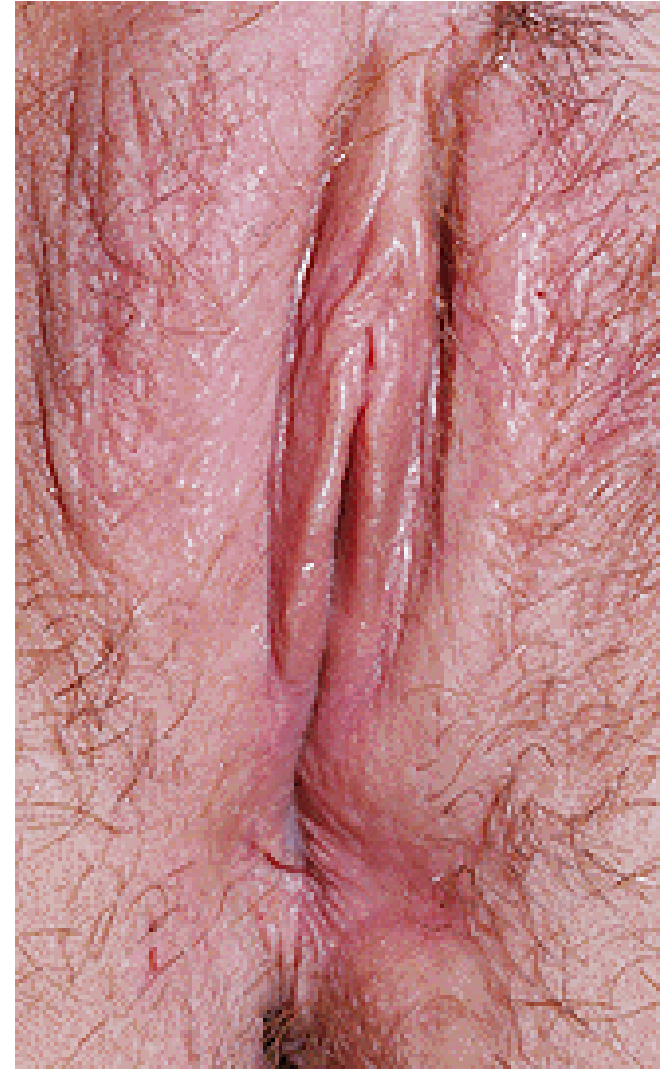Hiatus
urogenitalis

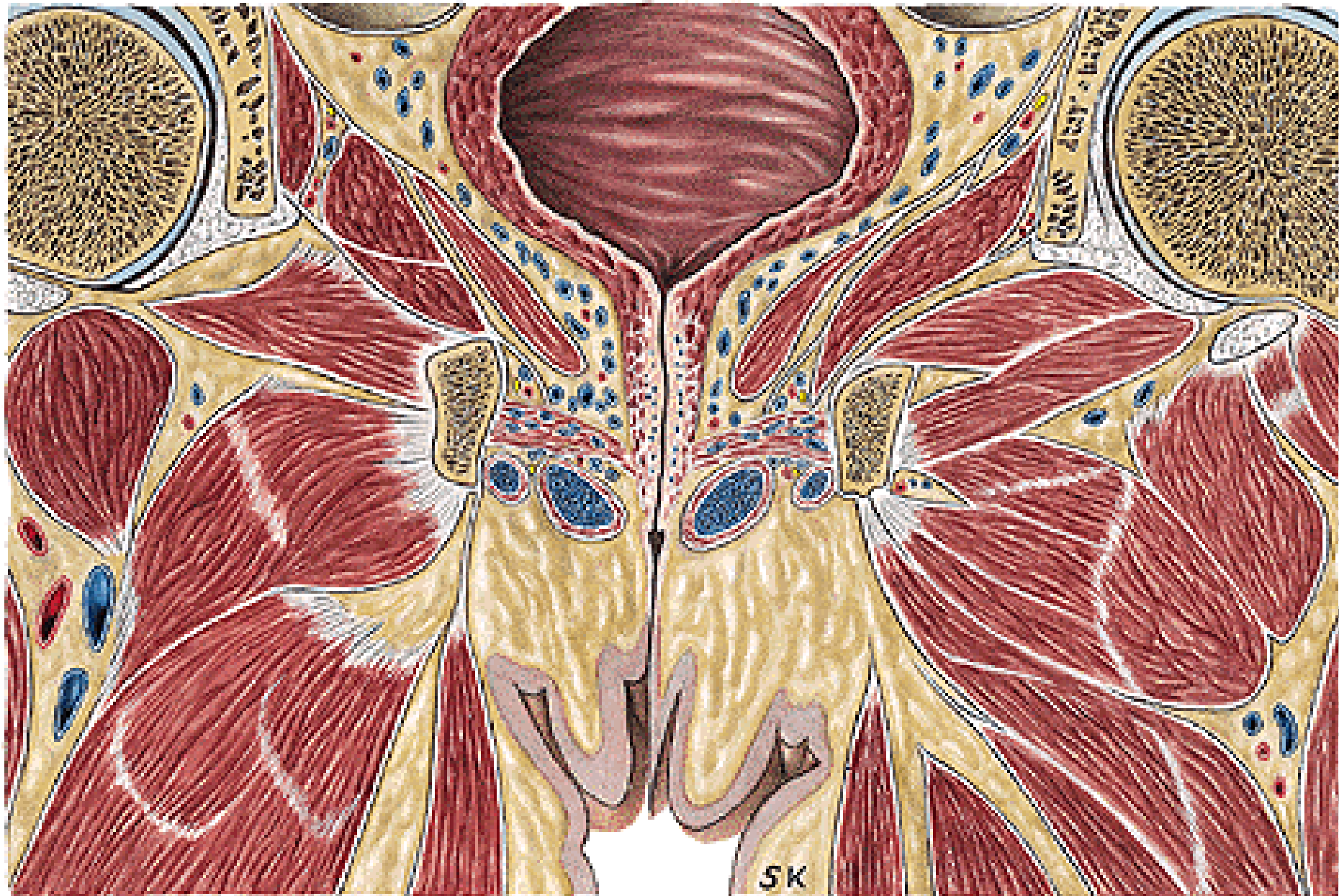

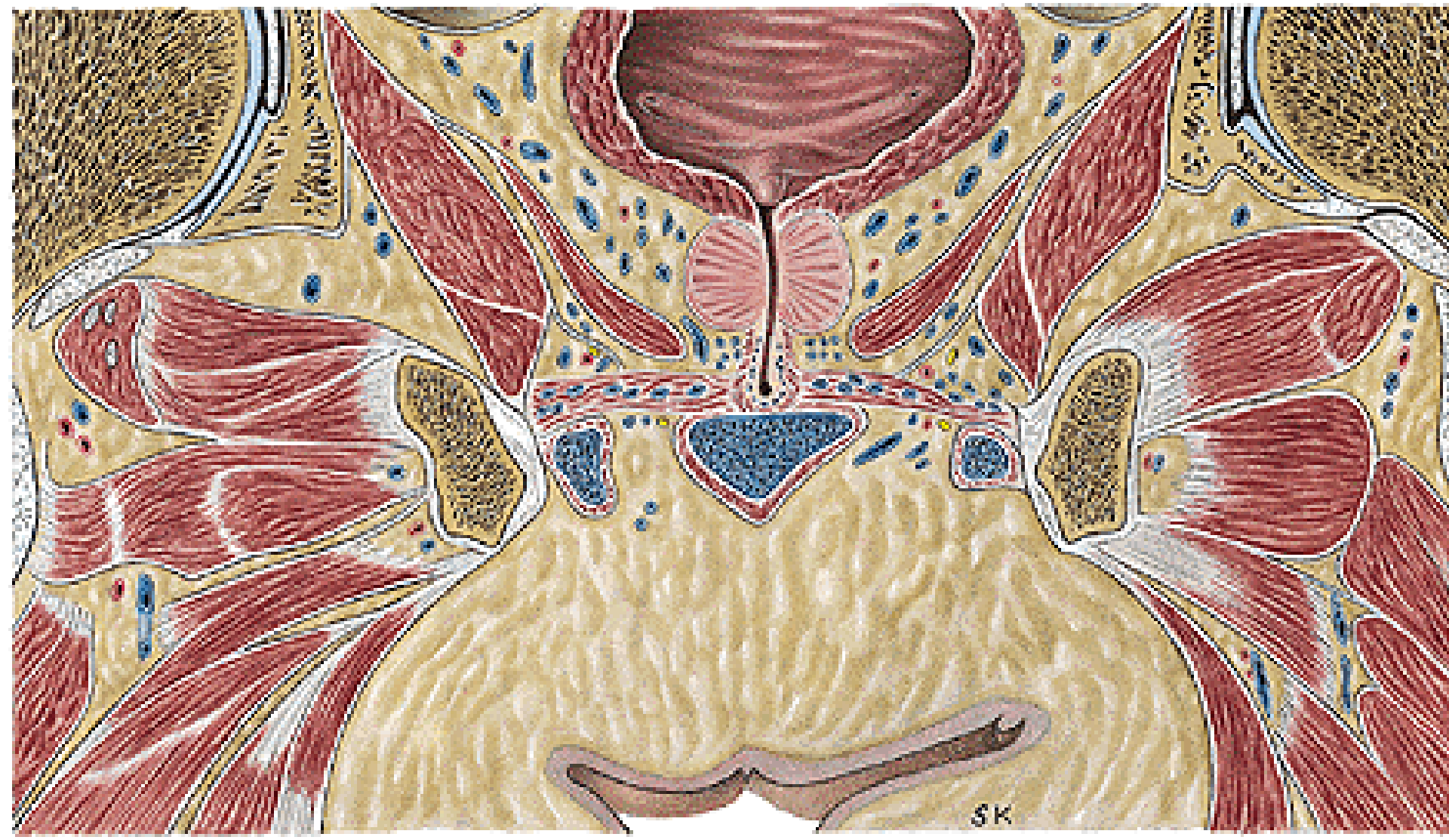CANALIS PUDENDALIS (ALCOCK)



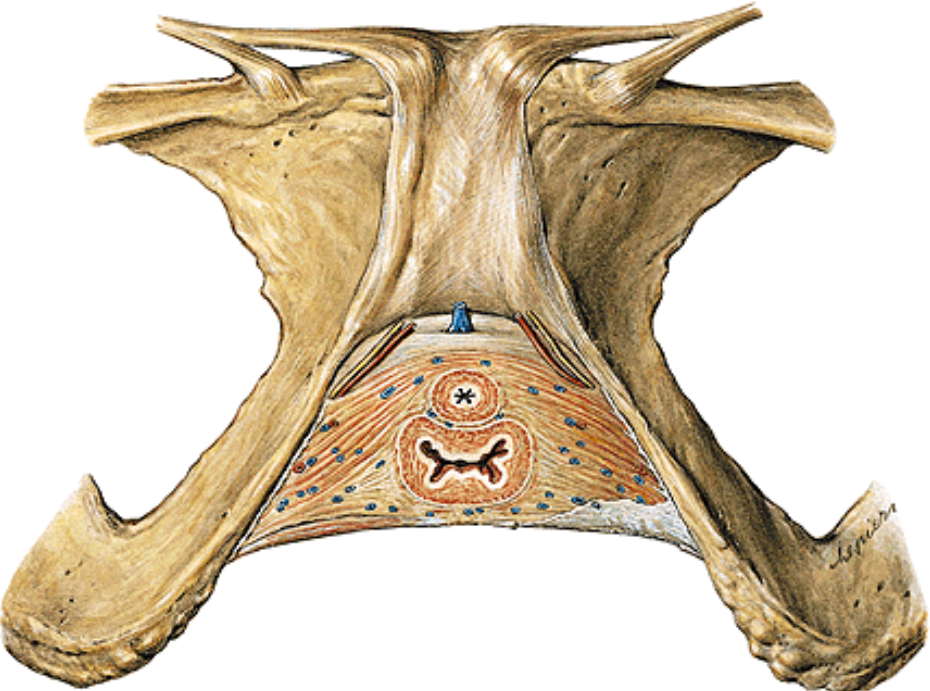
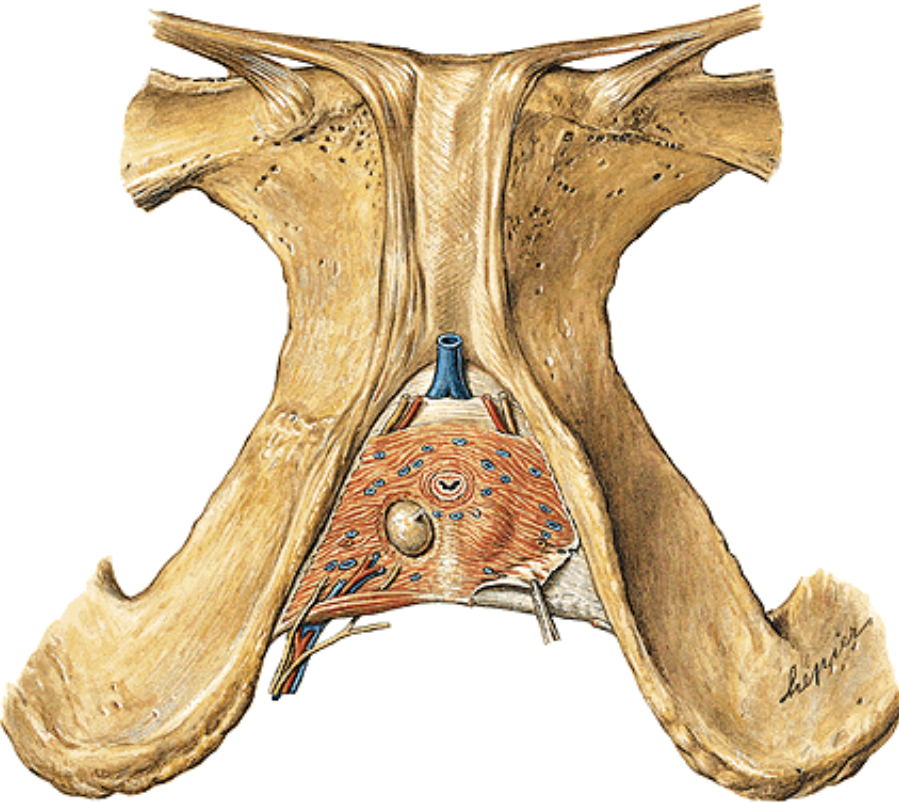
REGIO UROGENITALIS

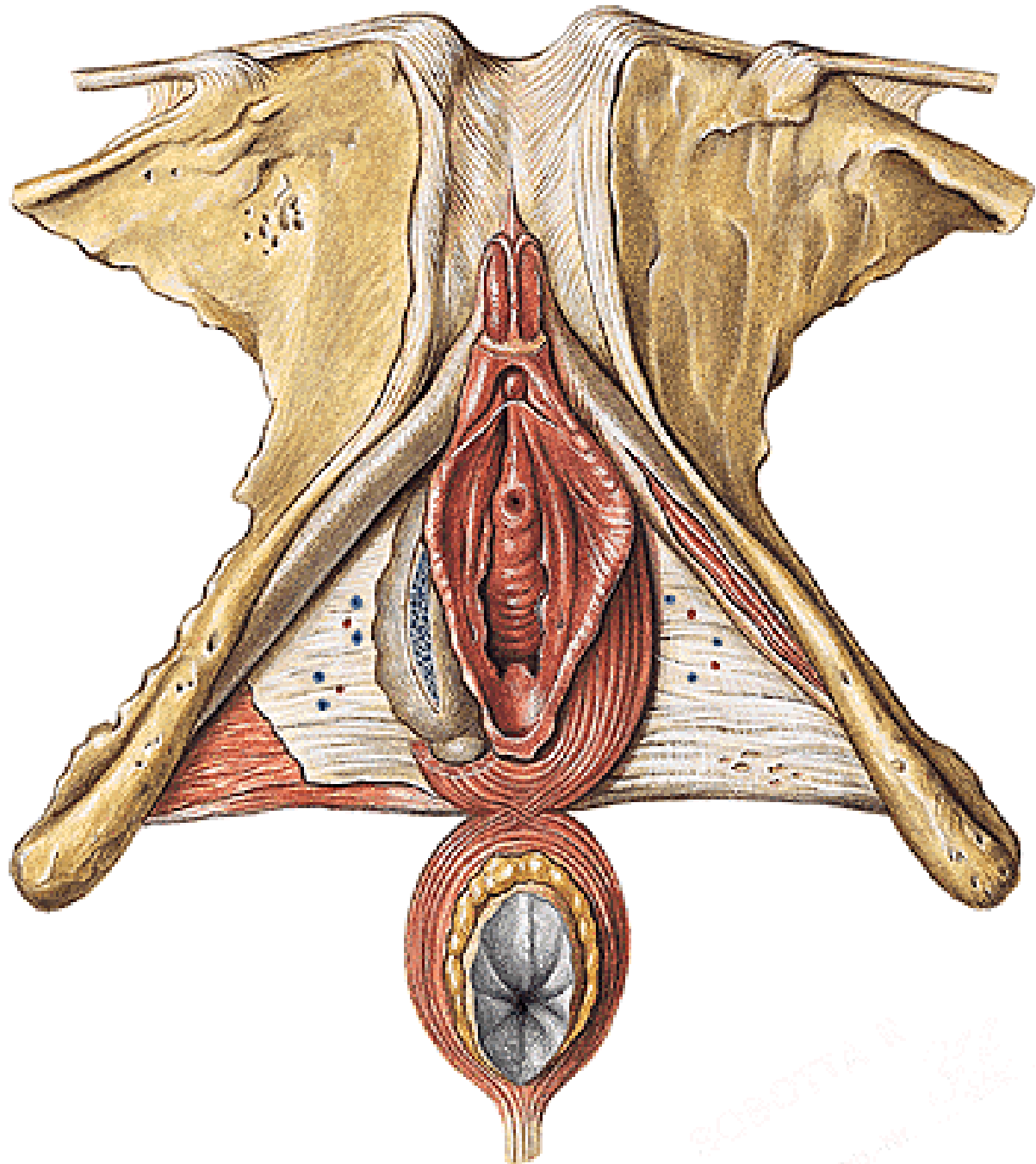






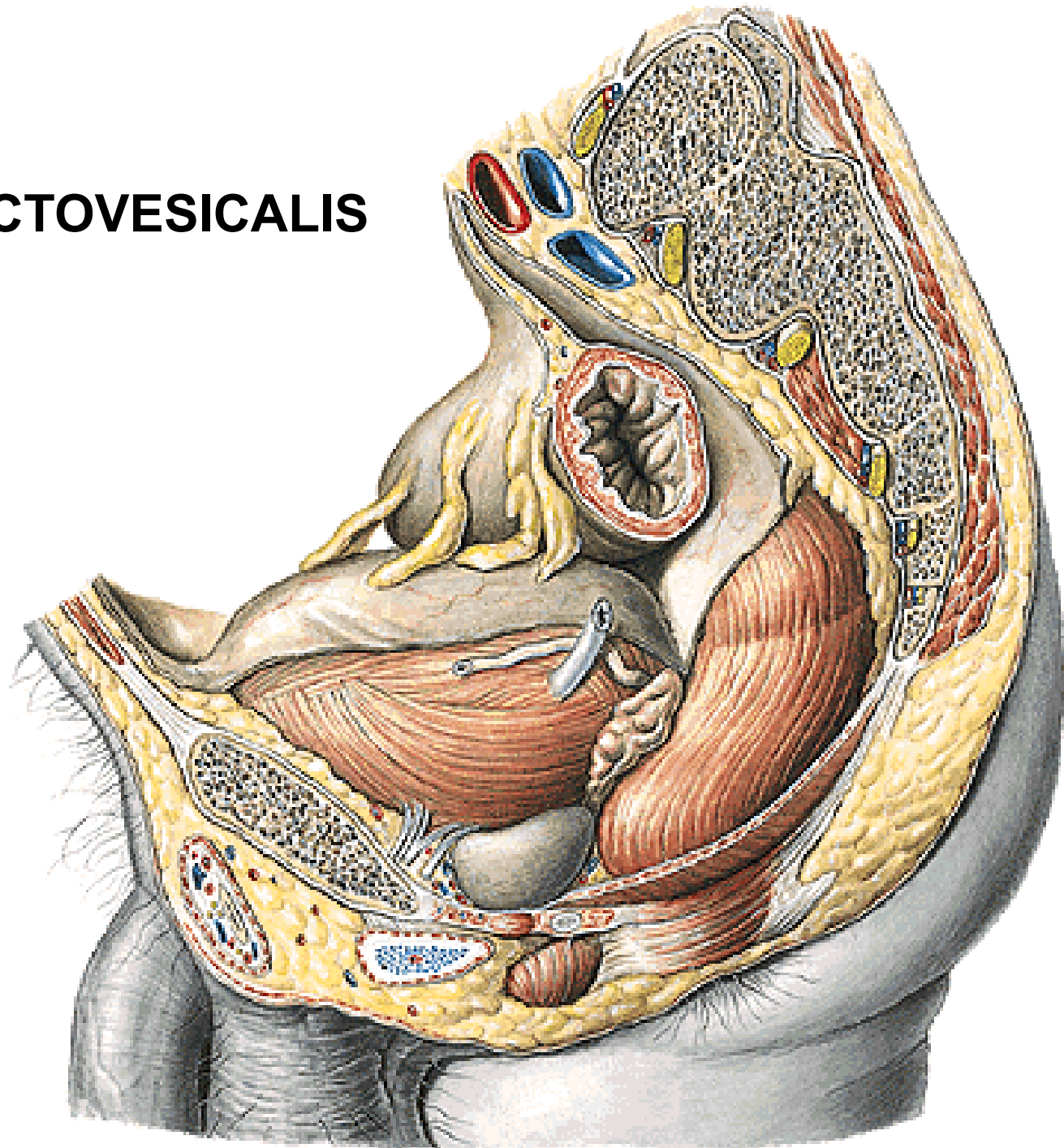
DIAPHRAGMA UROGENITALE



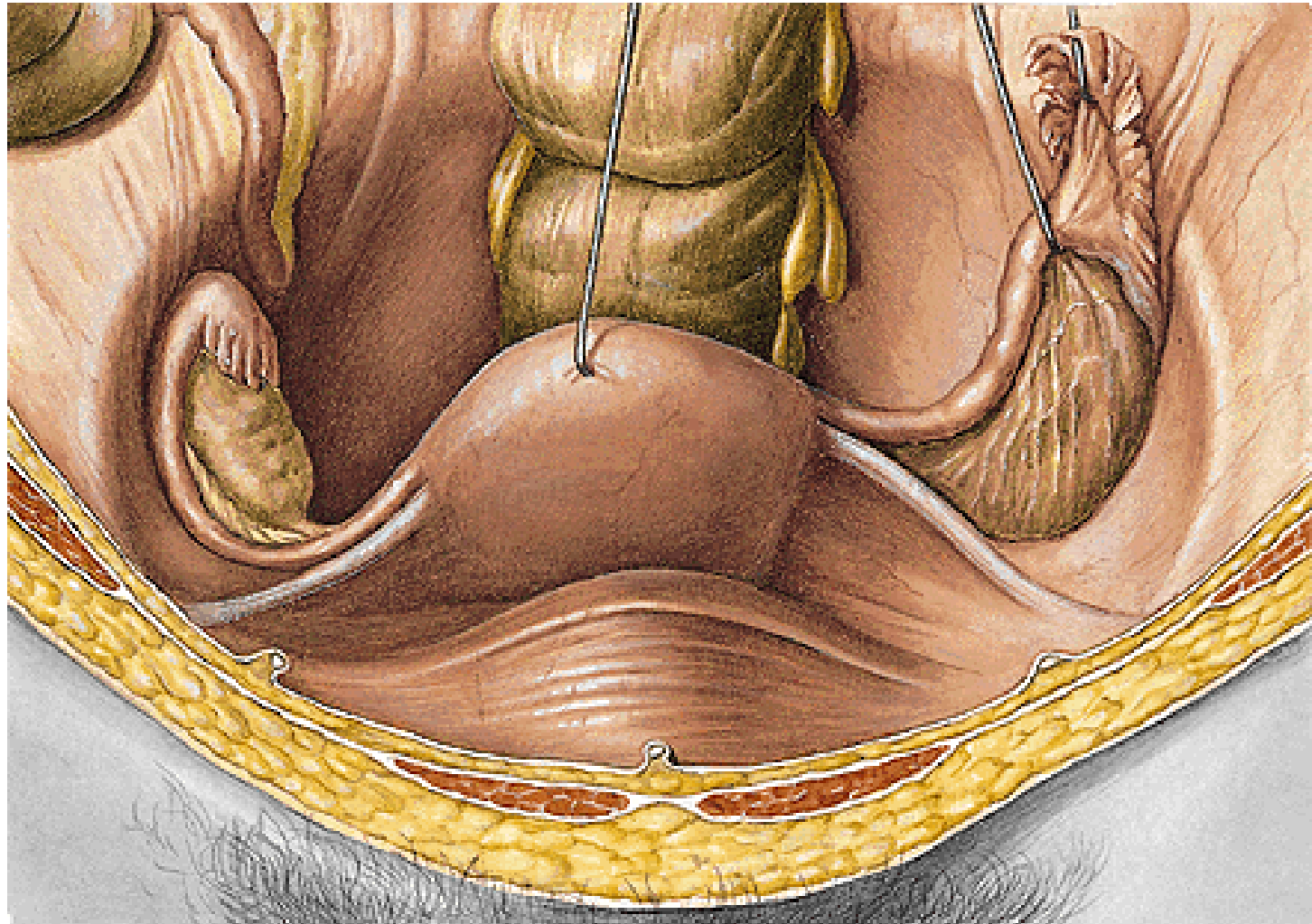


CAVUM PELVIS

EXCAVATIO RECTOVESICALIS

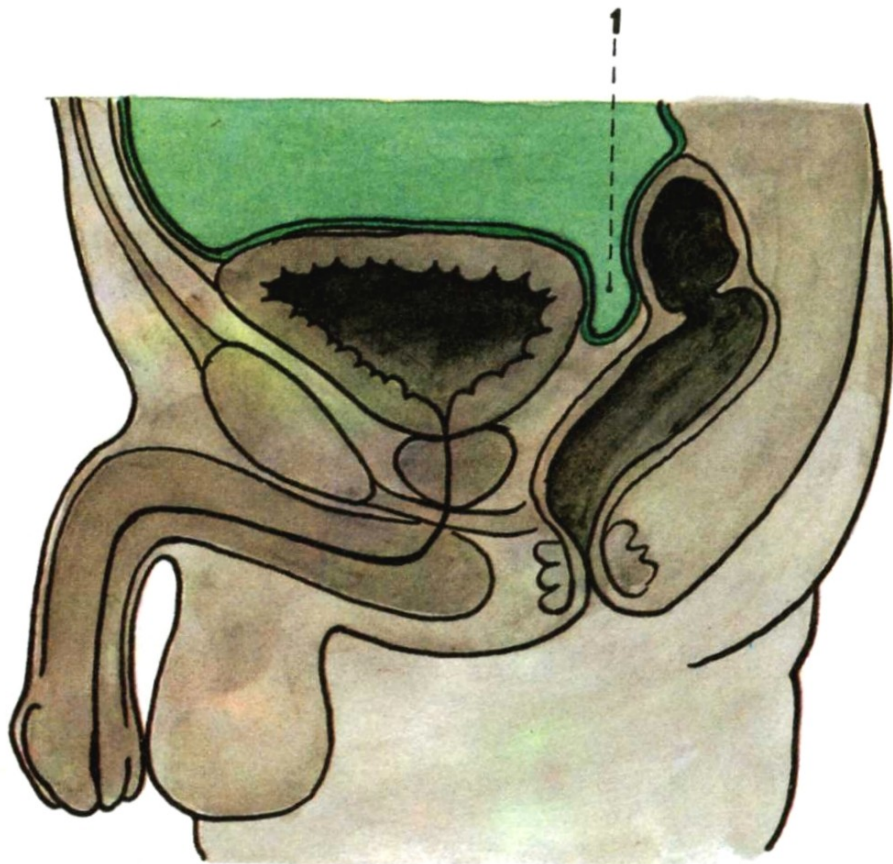


LIGAMENTUM LATUM UTERI
LIGAMENTUM OVARIUM PROPRIUM
LIGAMENTUM SUSPENSORIUM OVARIUM
LIGAMENTUM TERES UTERI



Median section through the male pelvis

1. excavatio rectovesicalis



Median section through the female pelvis

1. excavatio rectouterina (Douglas)
2. excavatio vesicouterina

