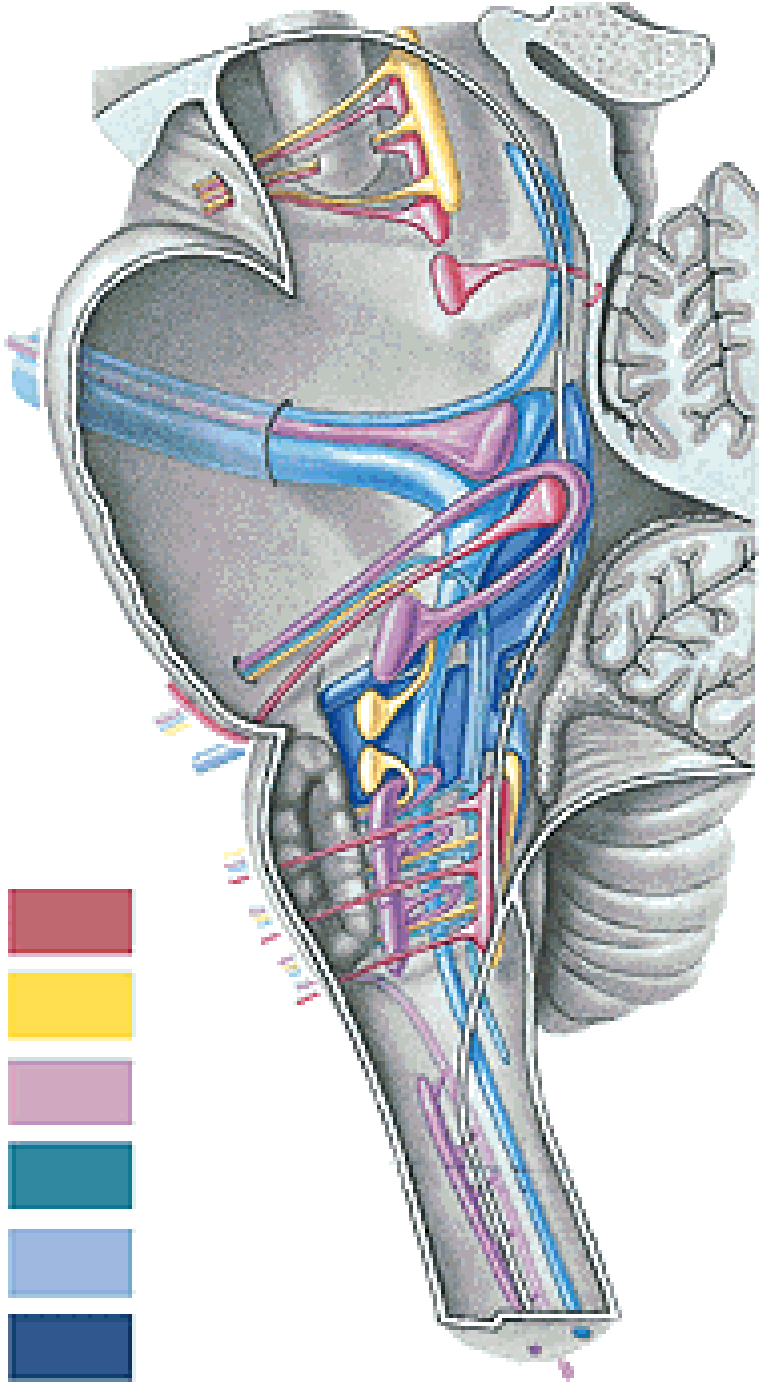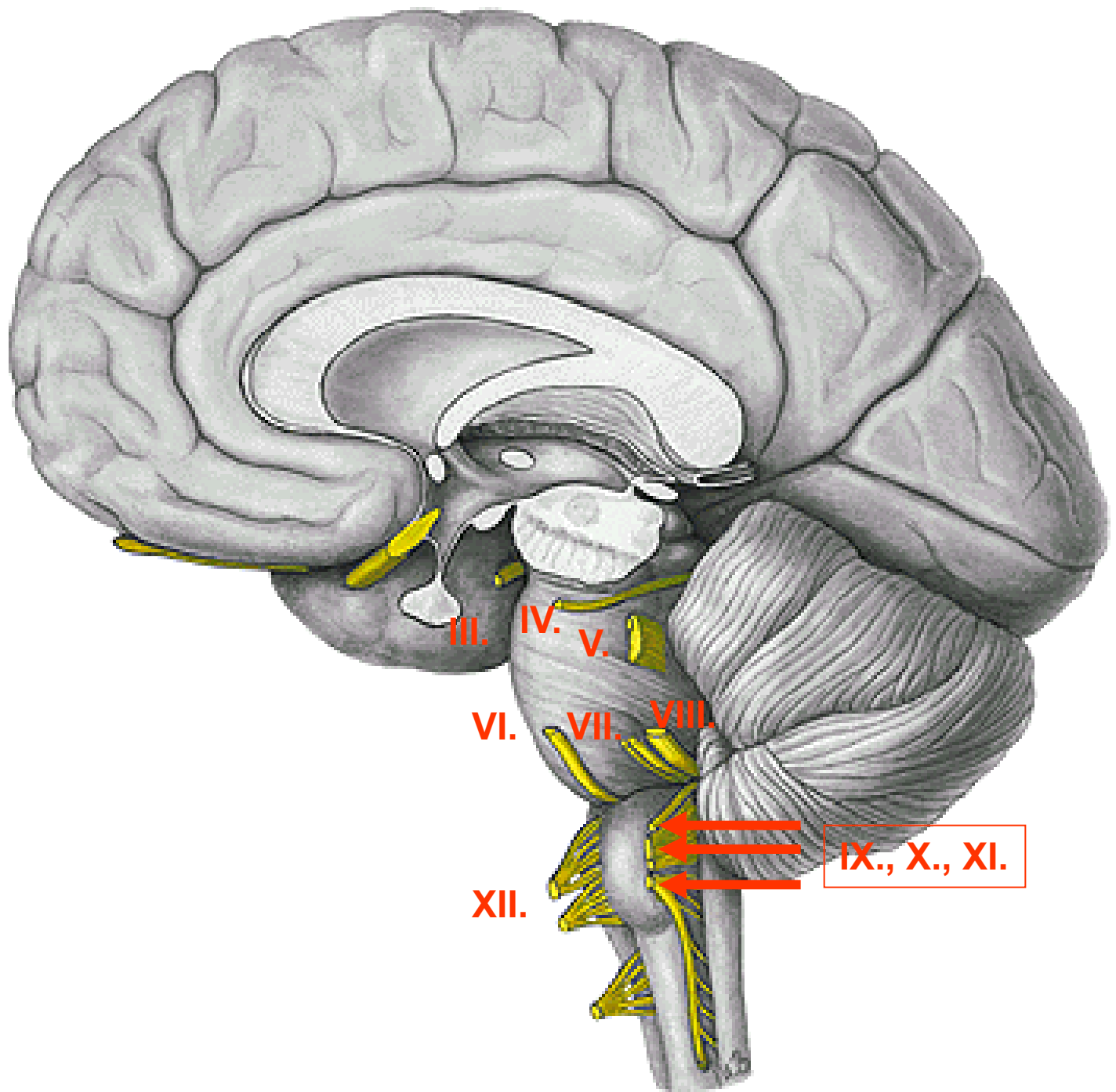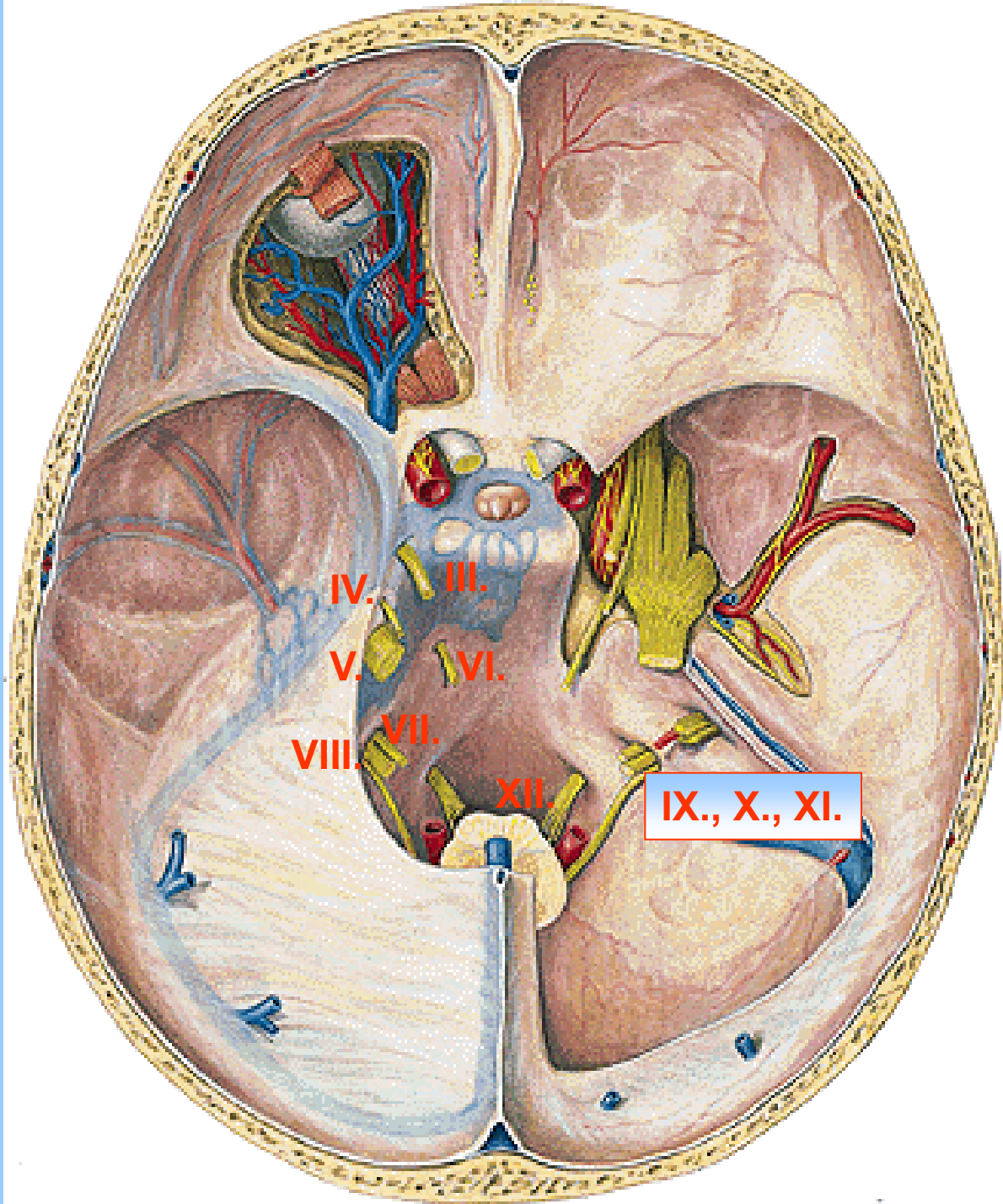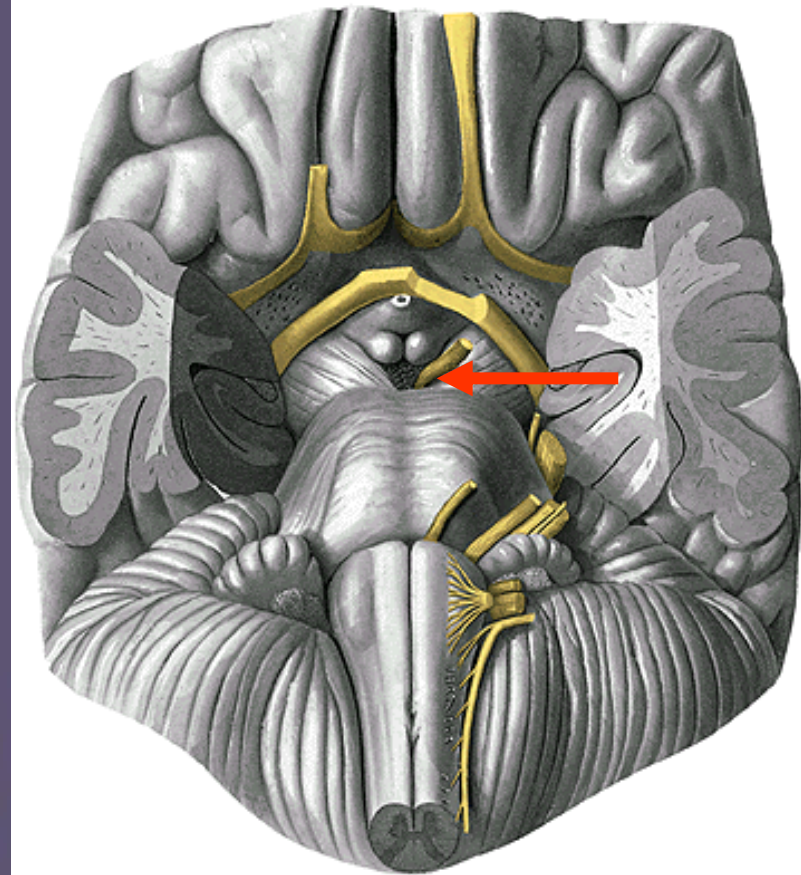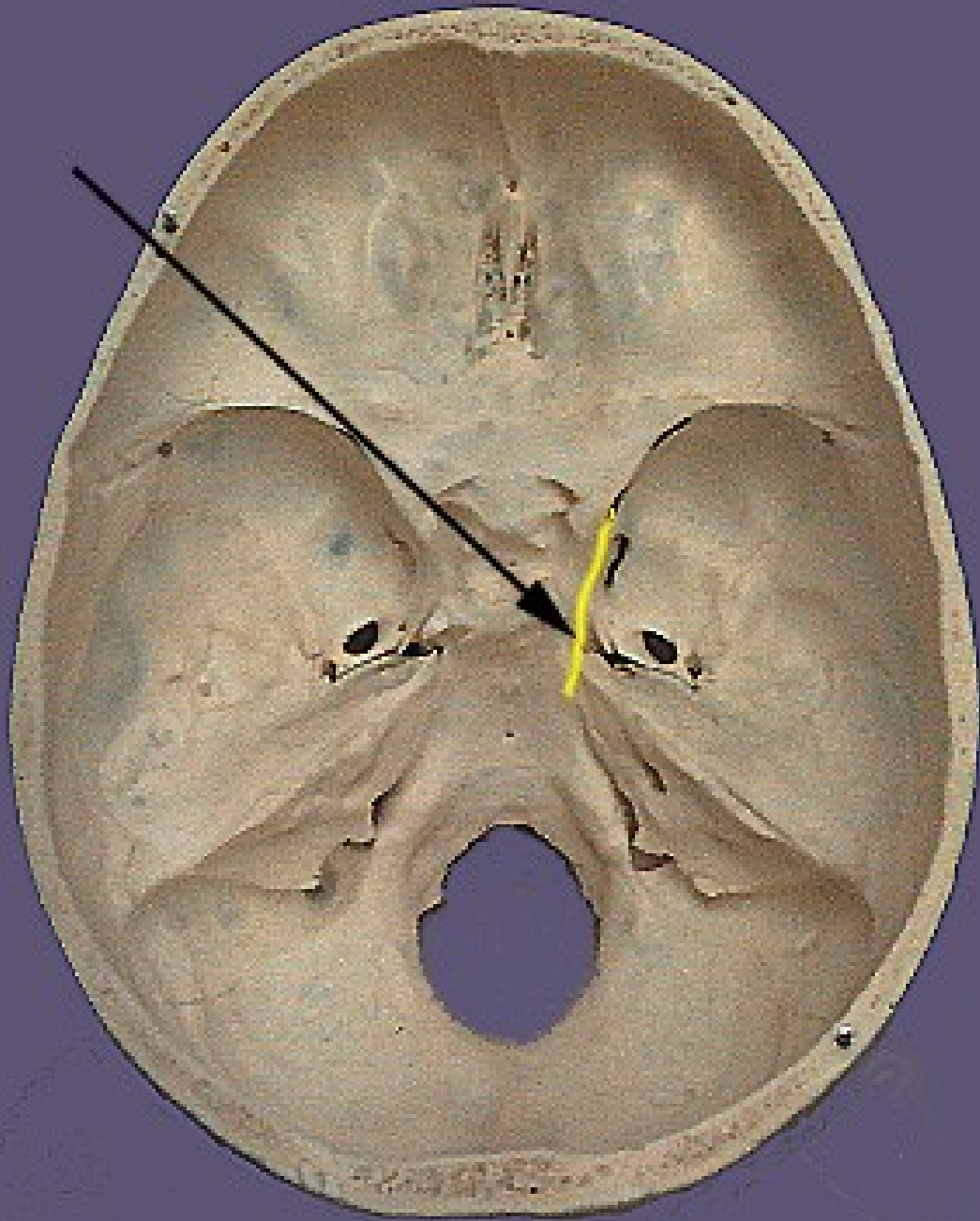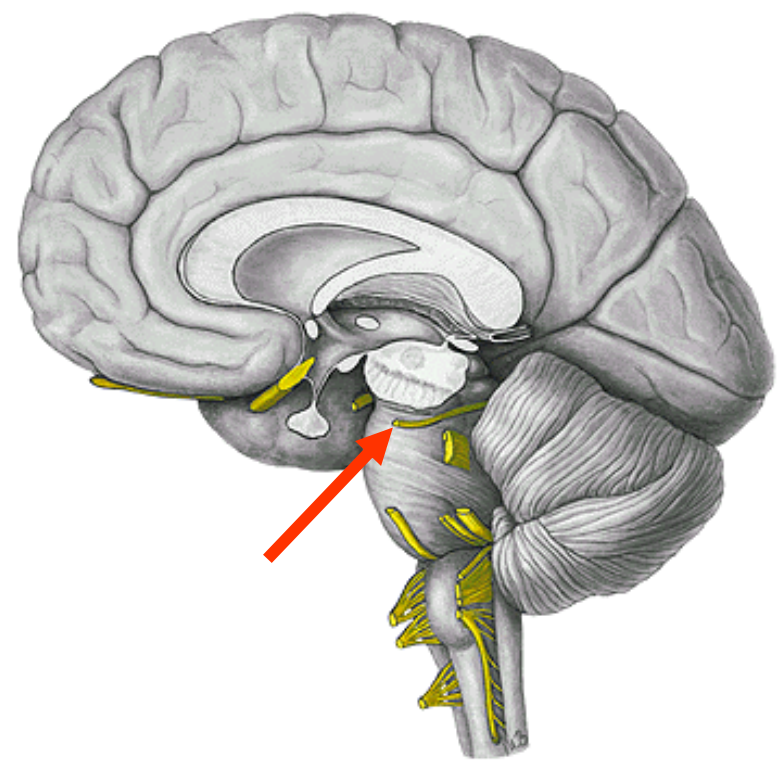
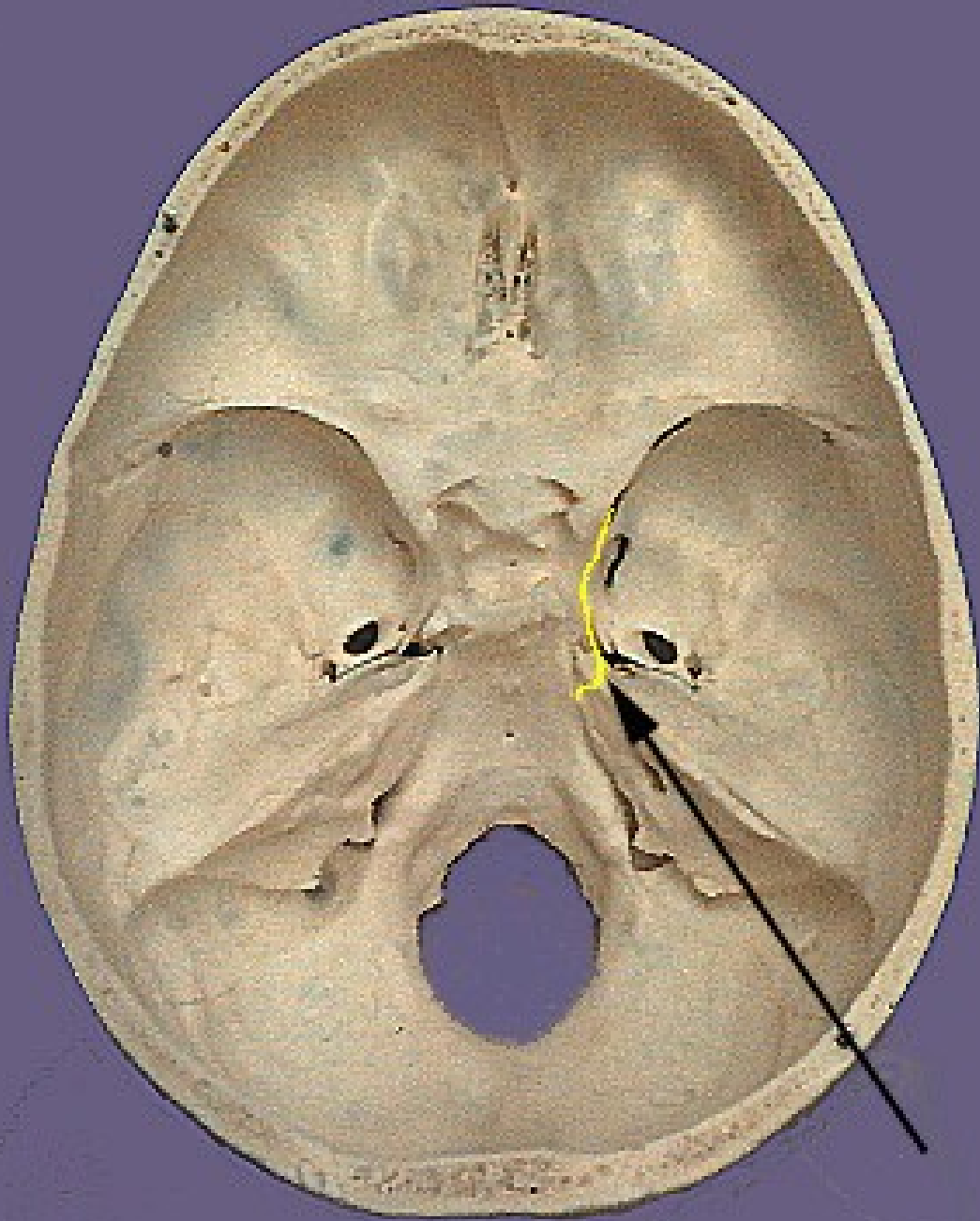
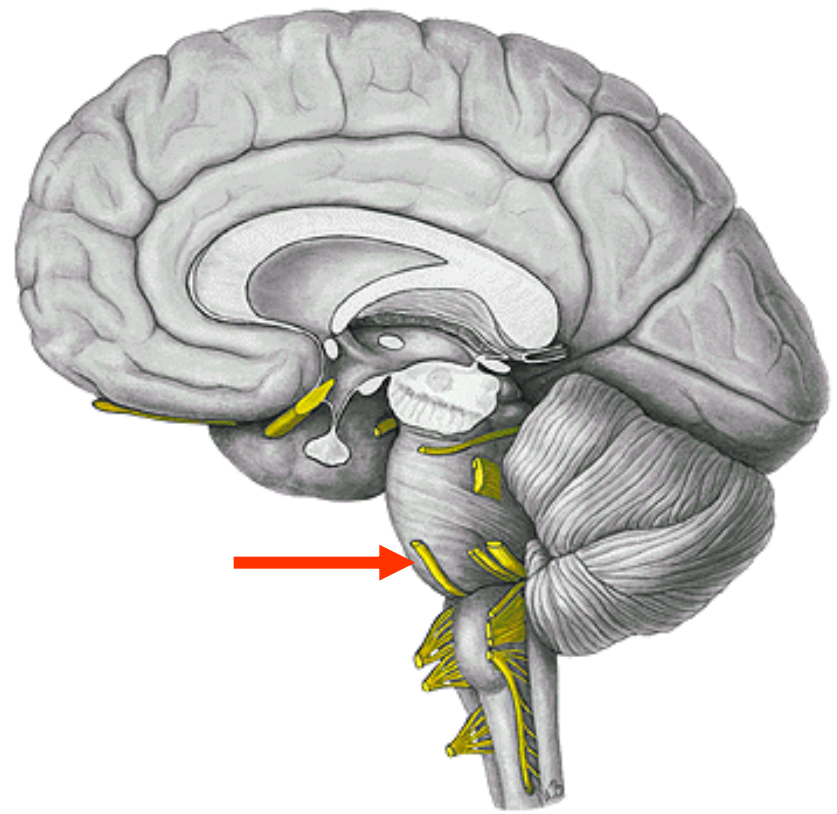
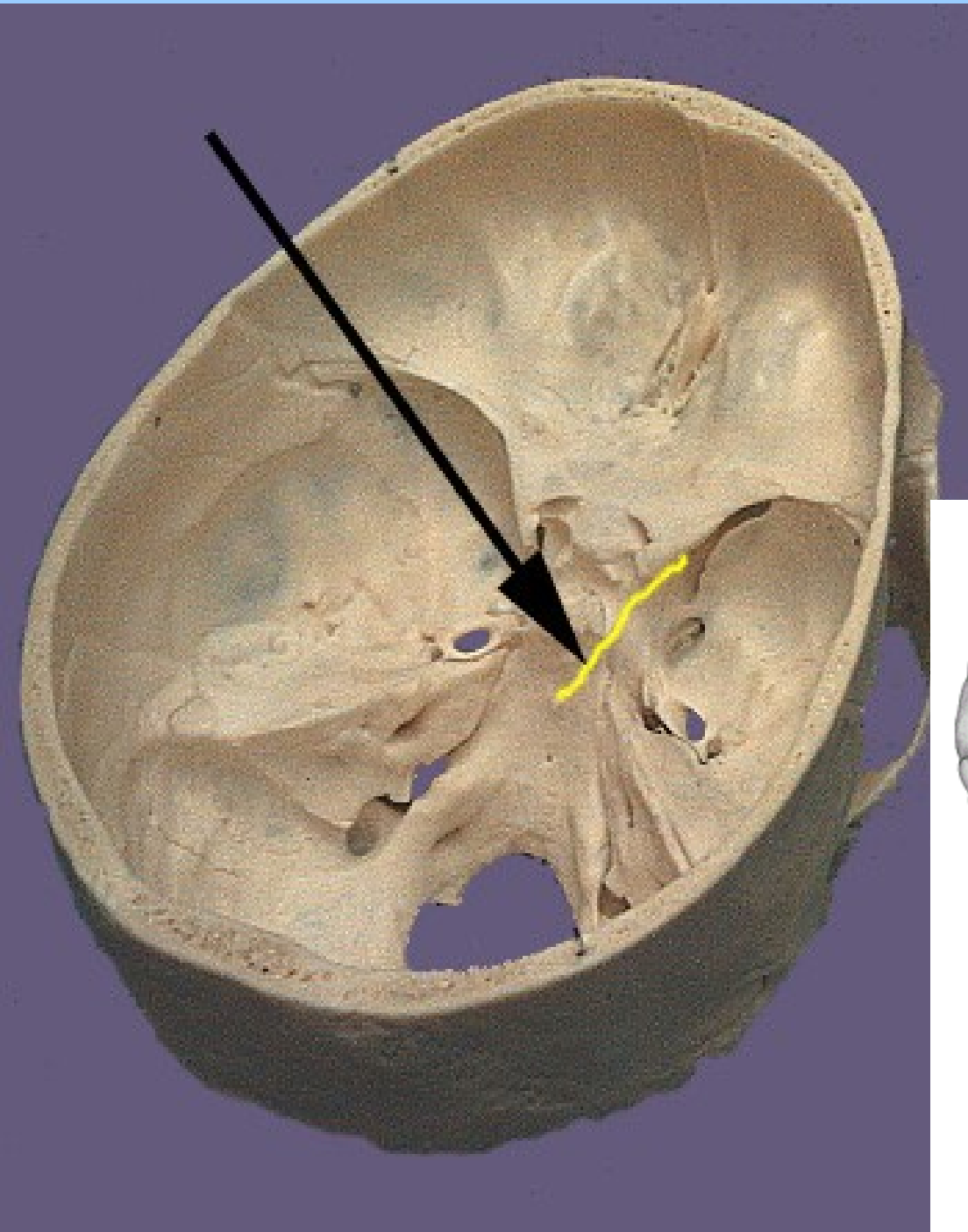


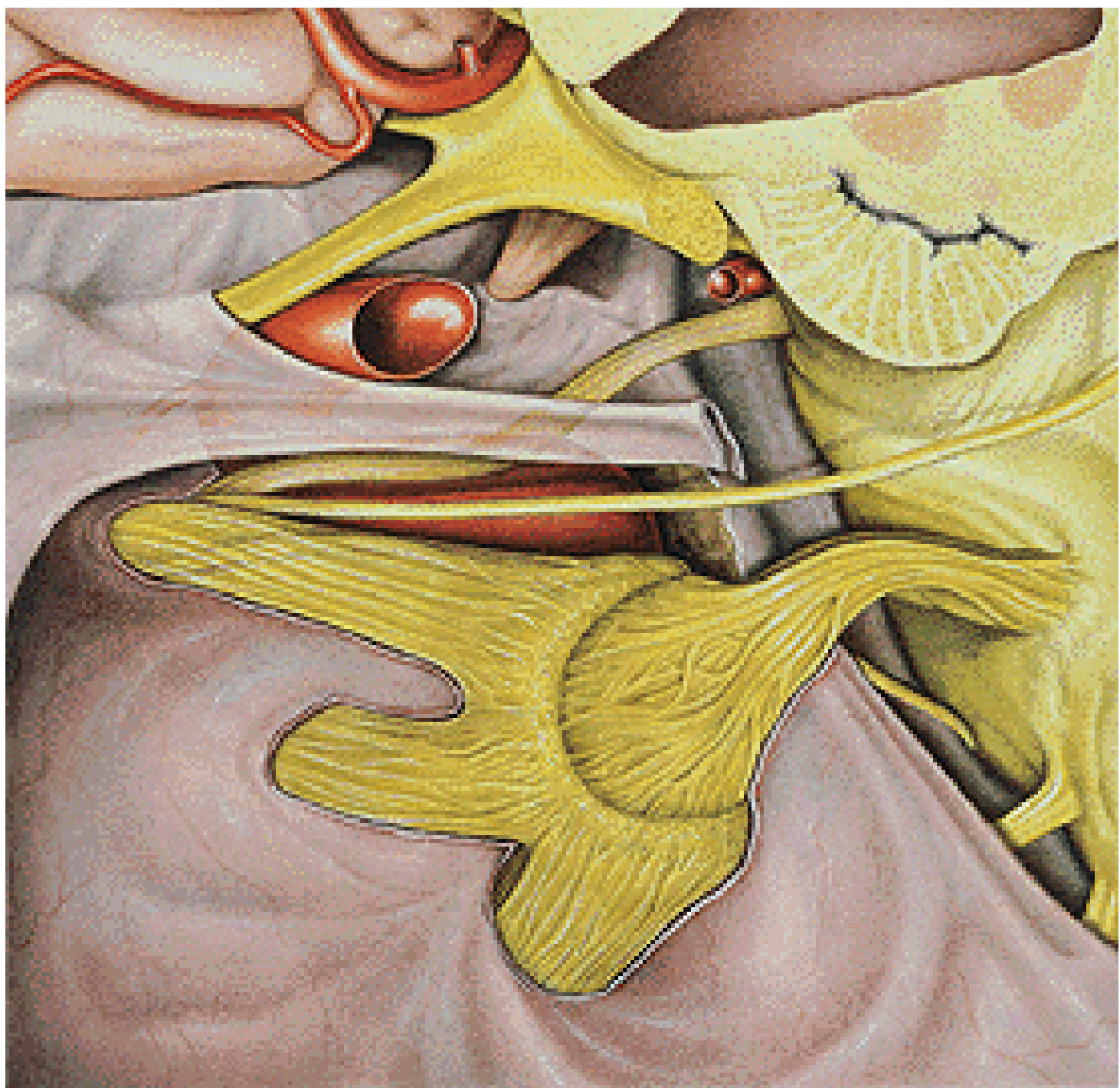
n.III.



n.IV.

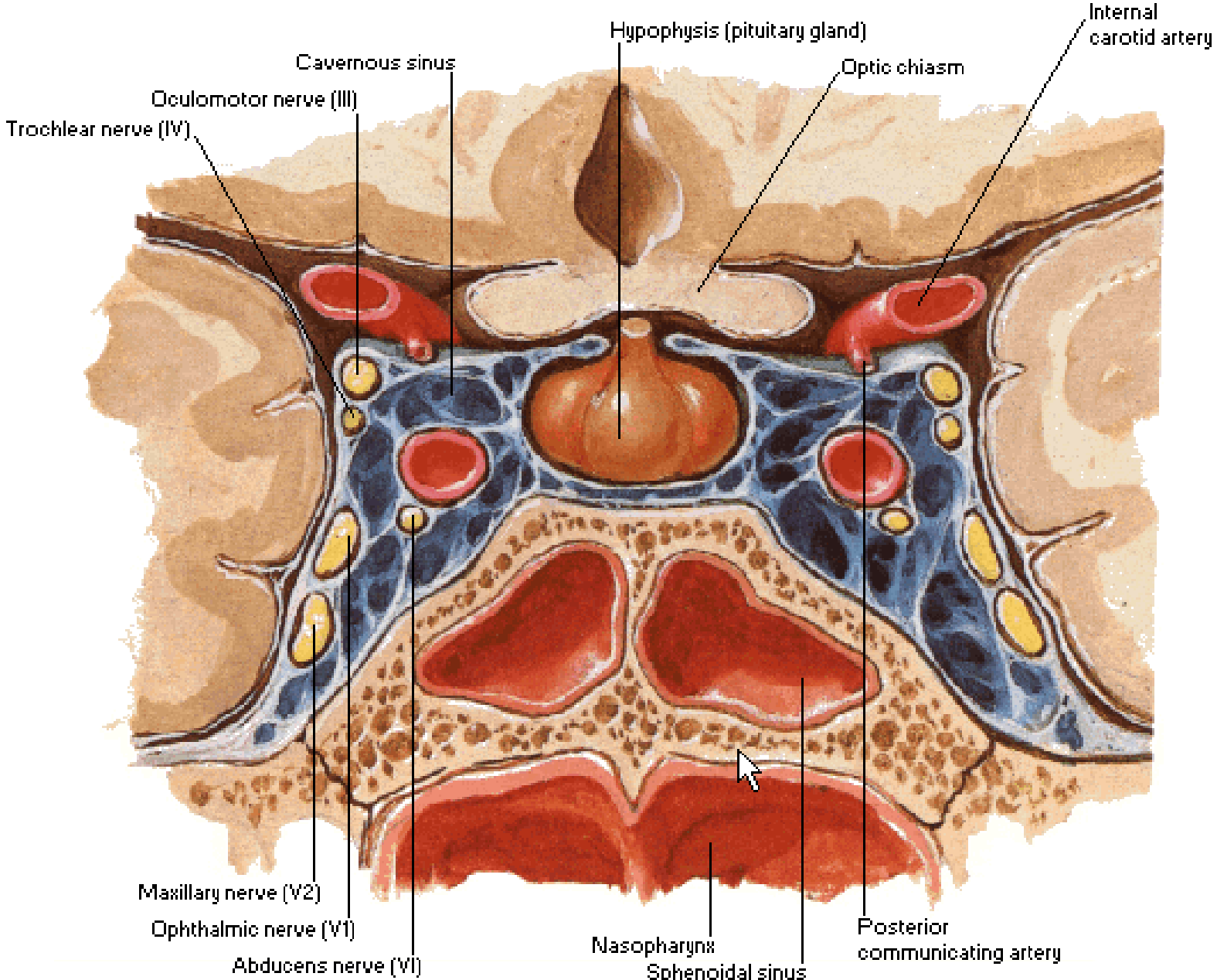
n.VI.

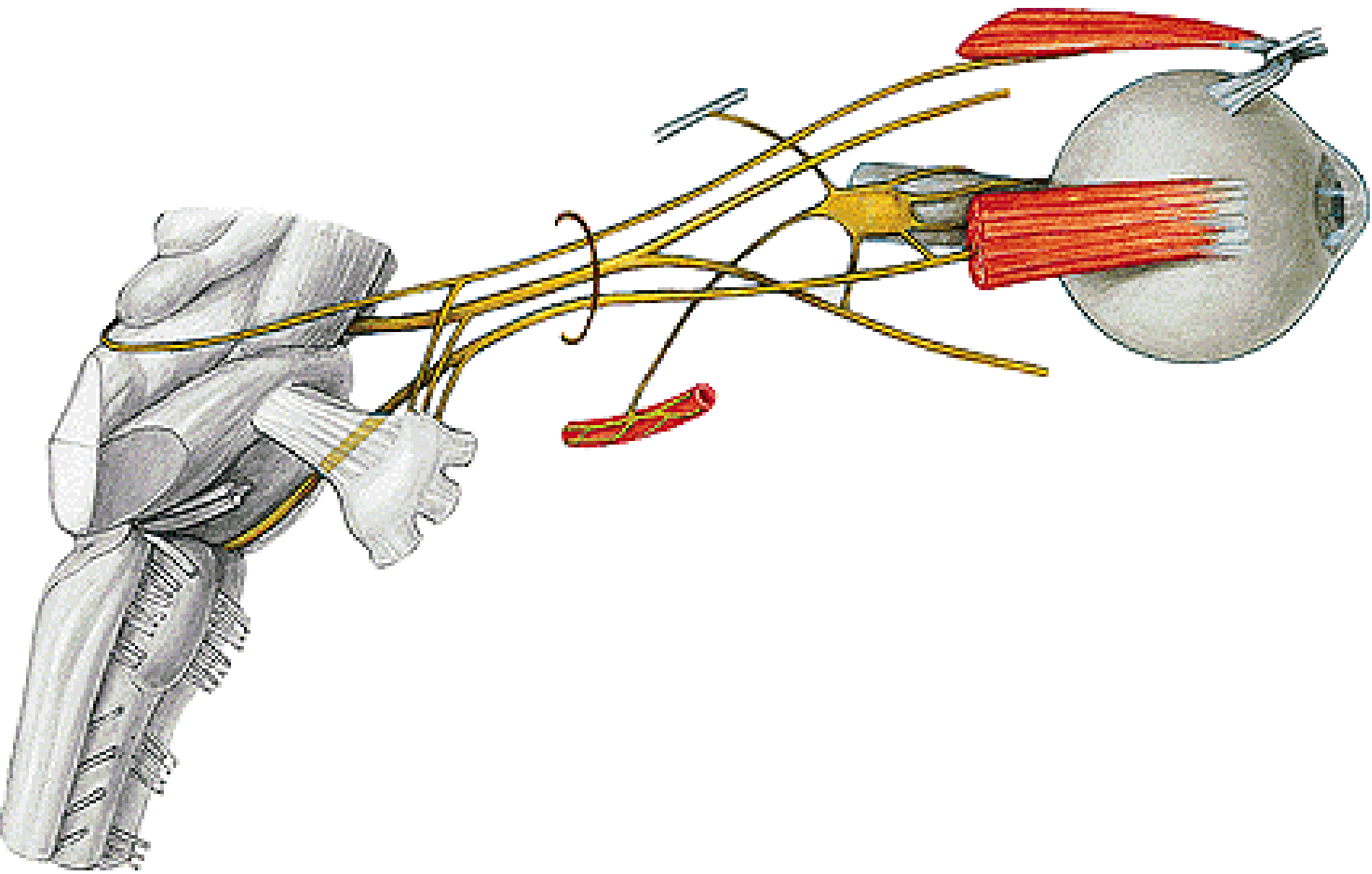


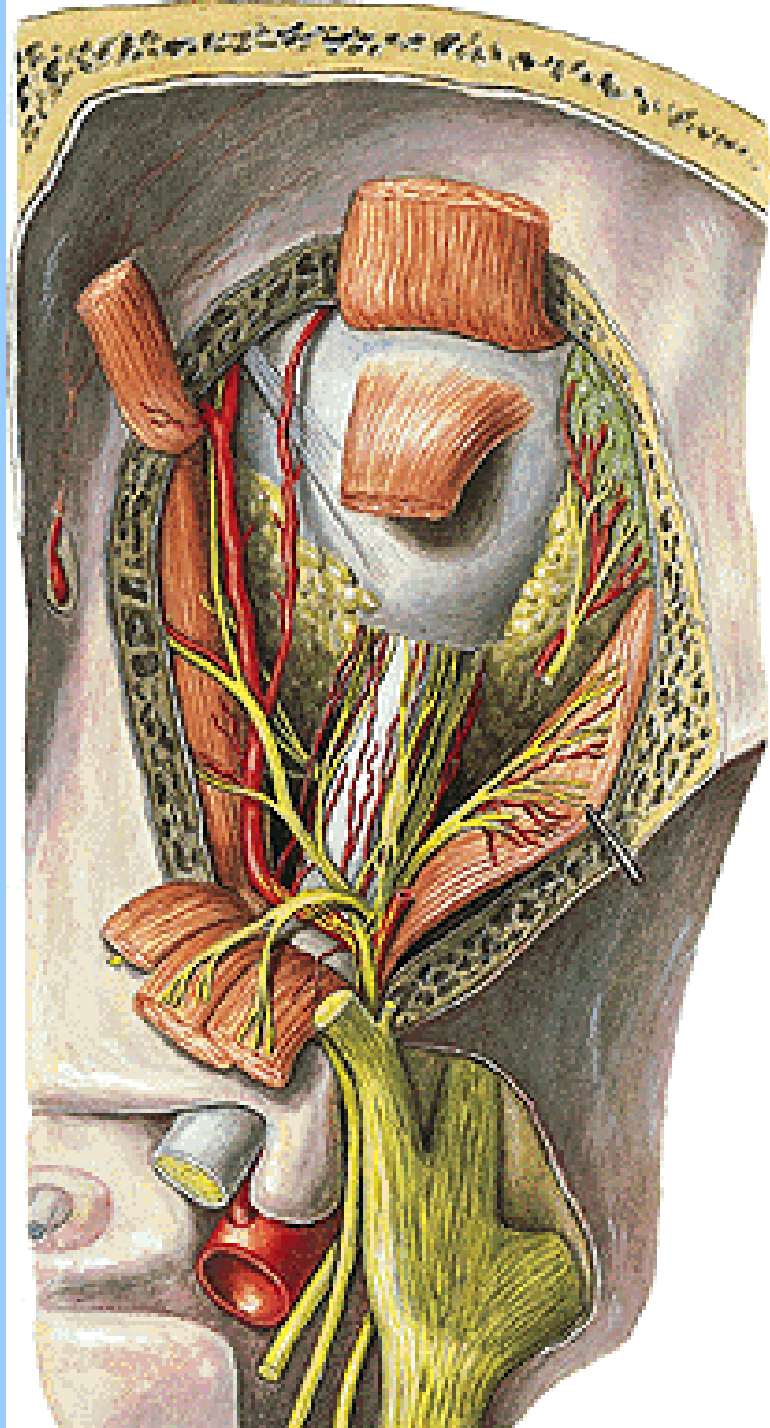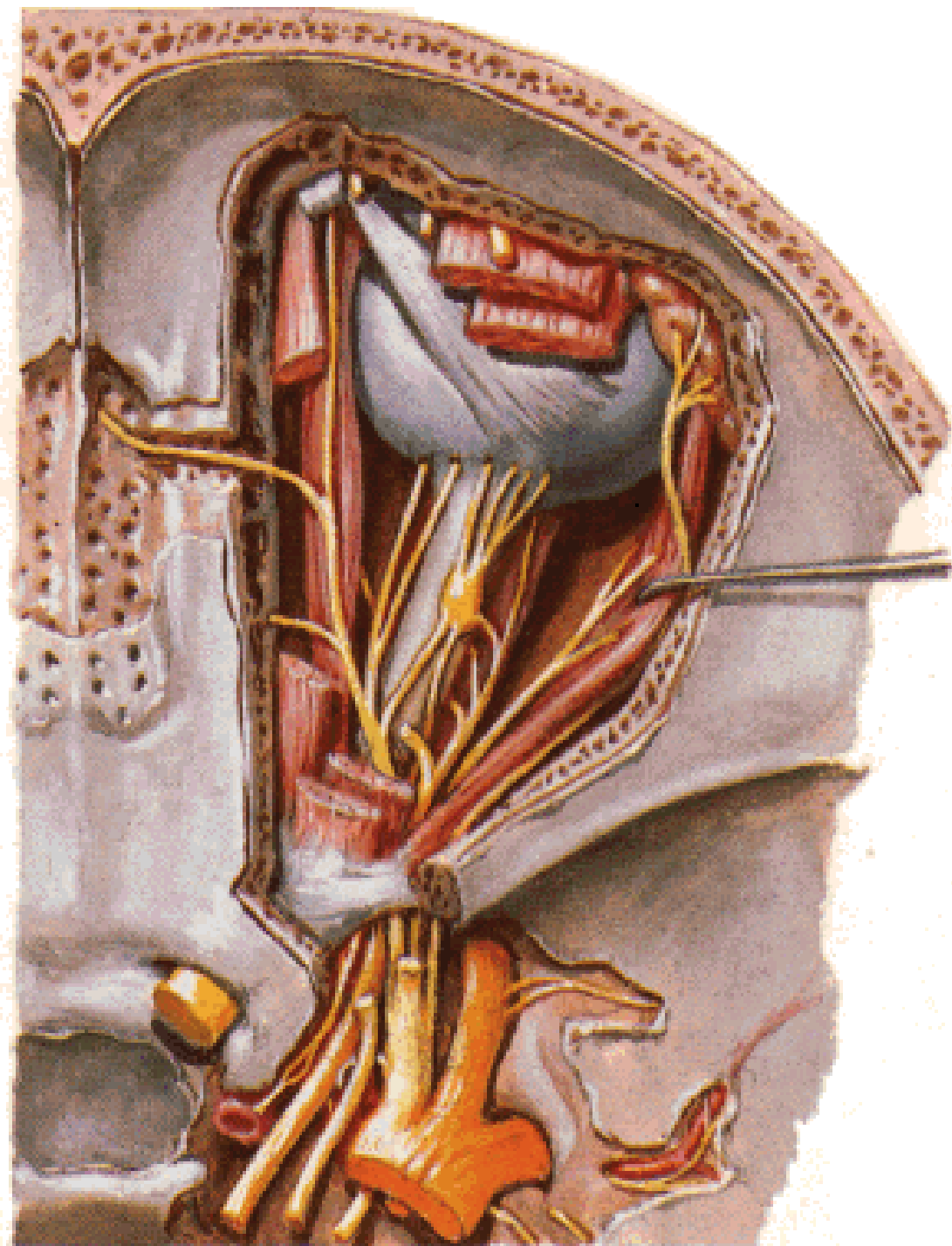


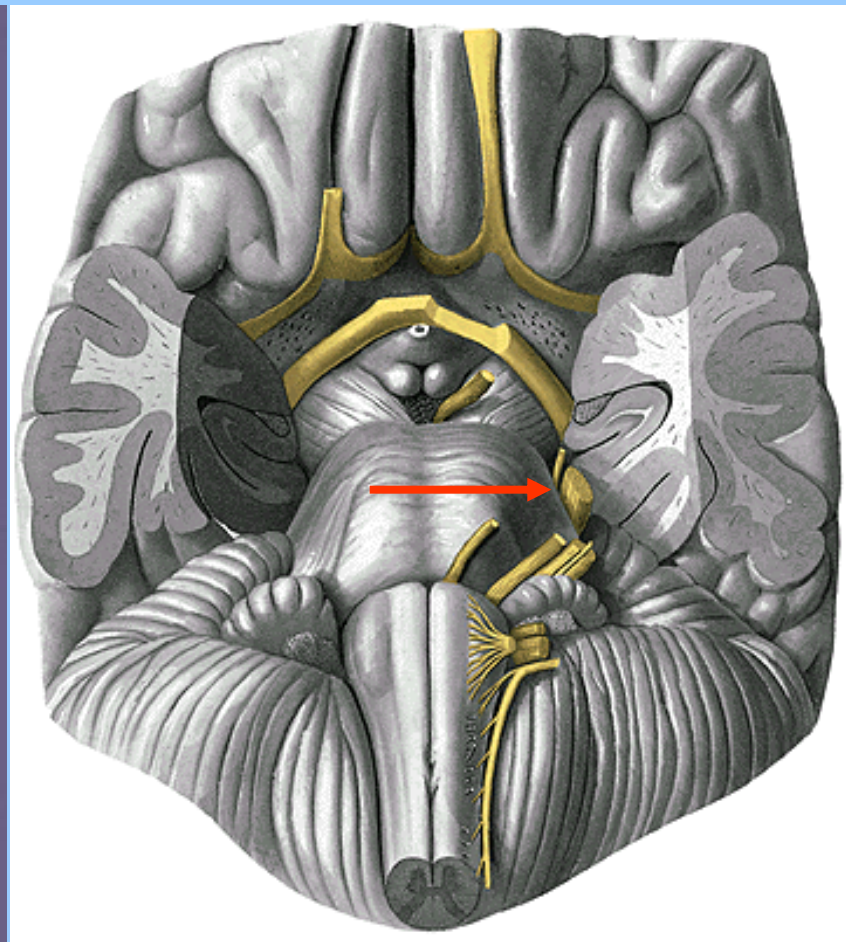
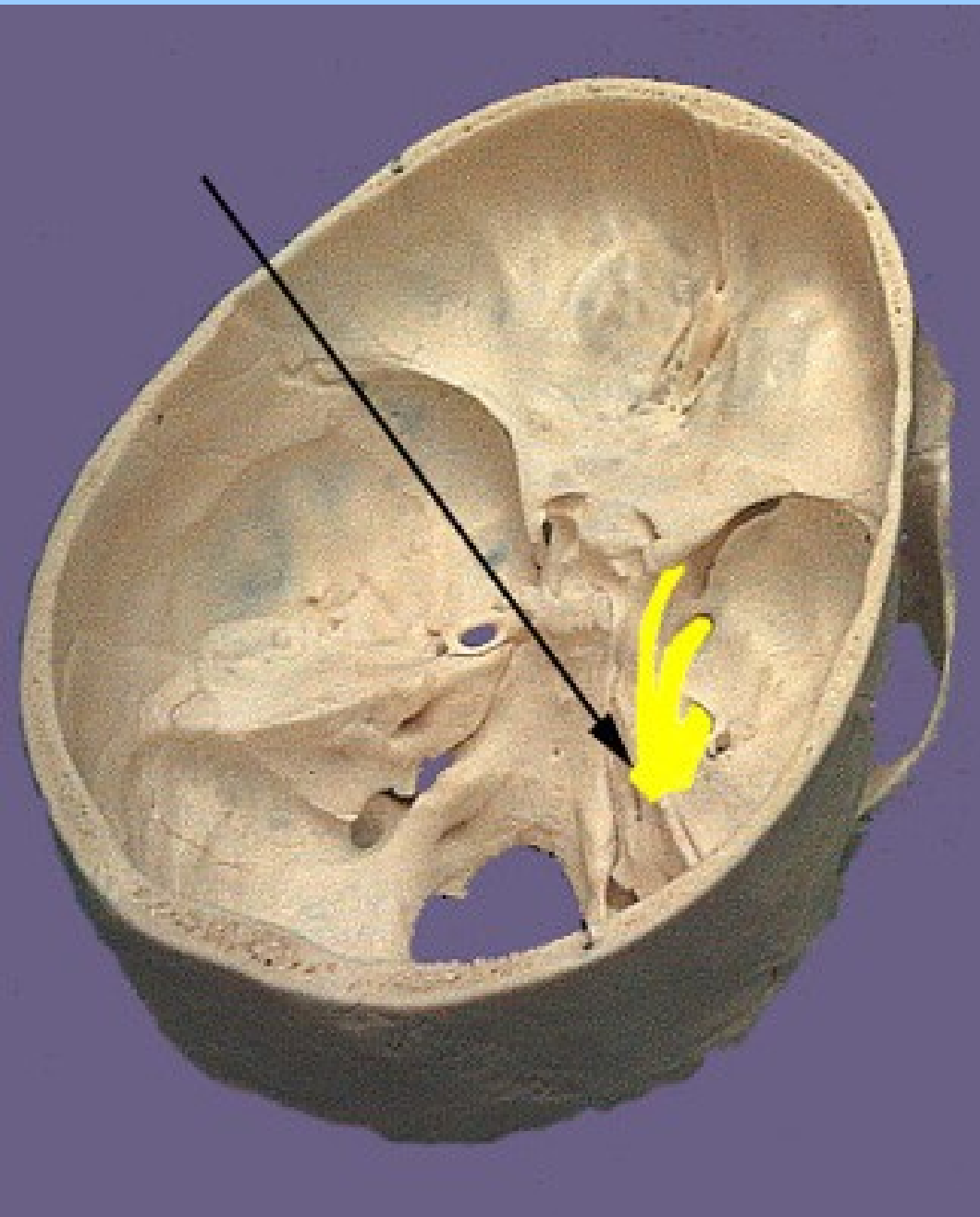
Cavernous Sinus

Coronal Section

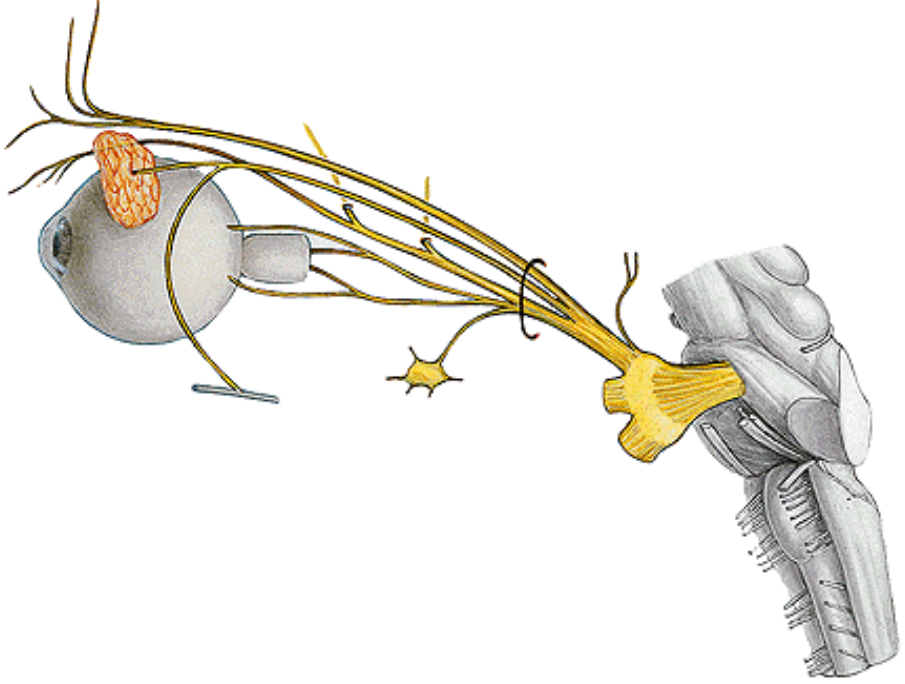




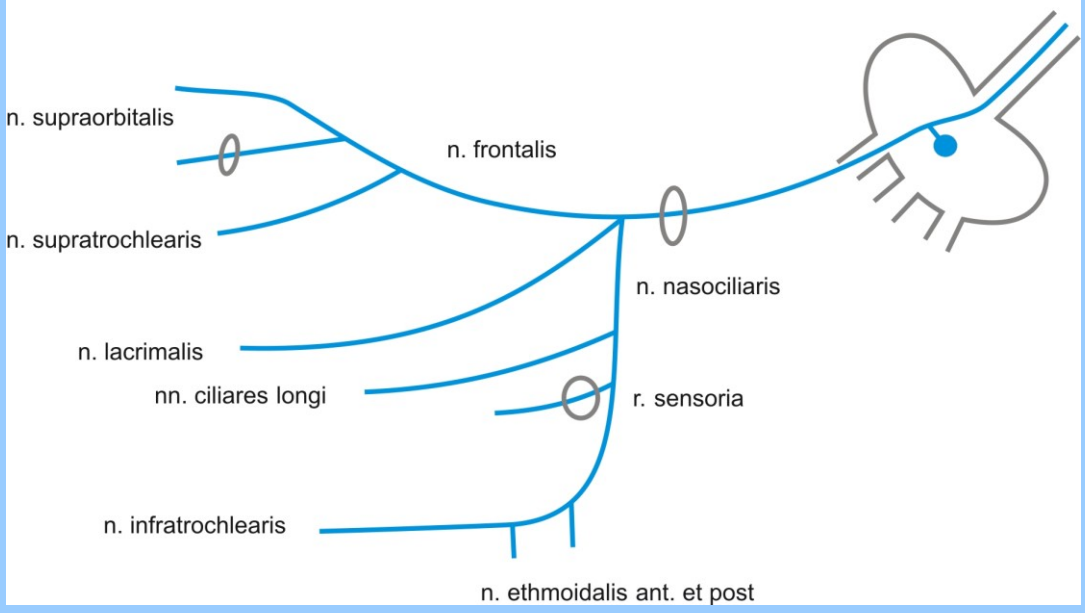




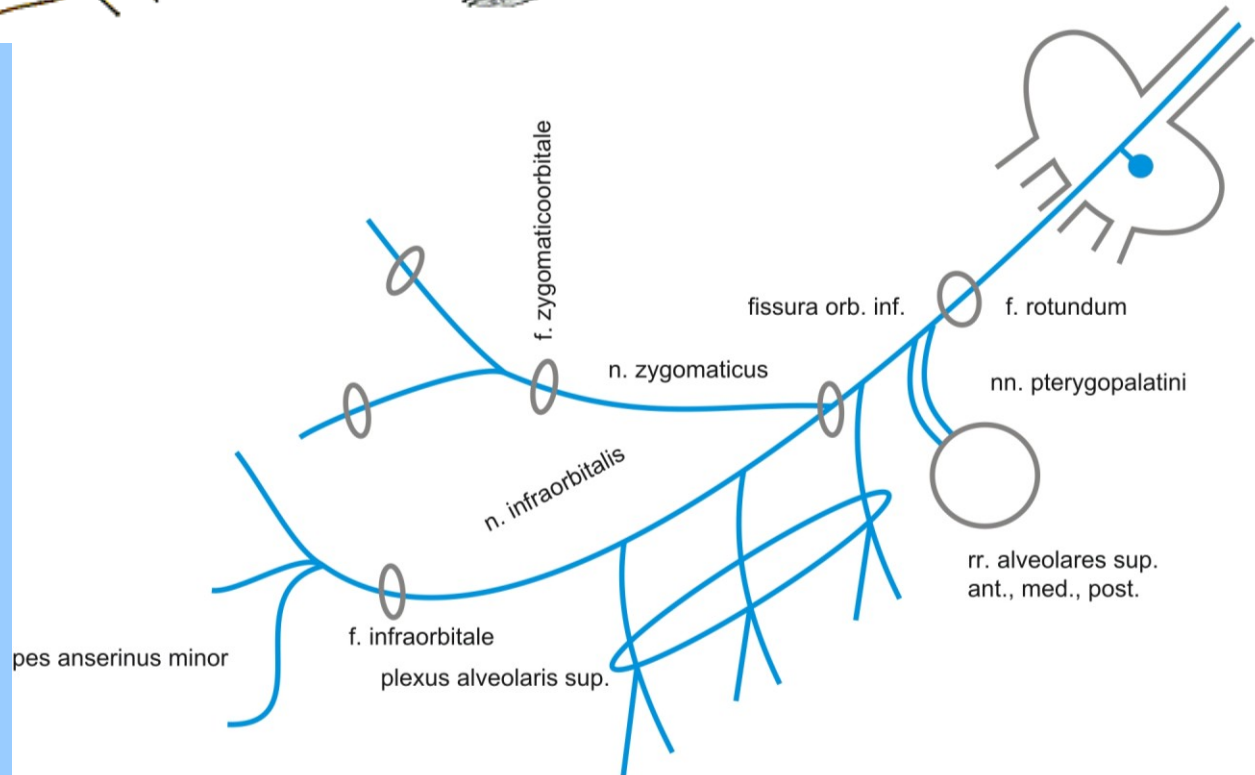
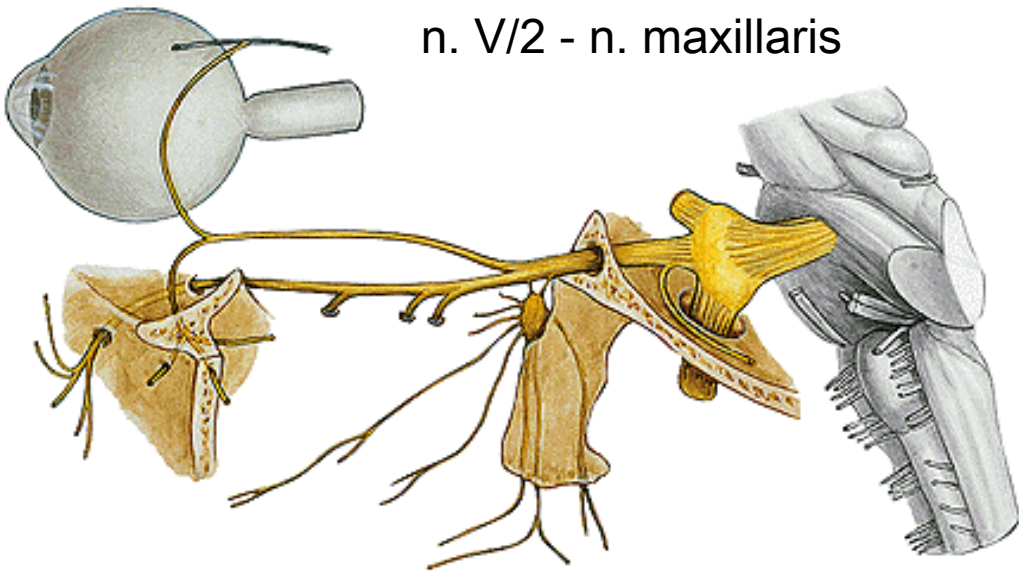
n.V.



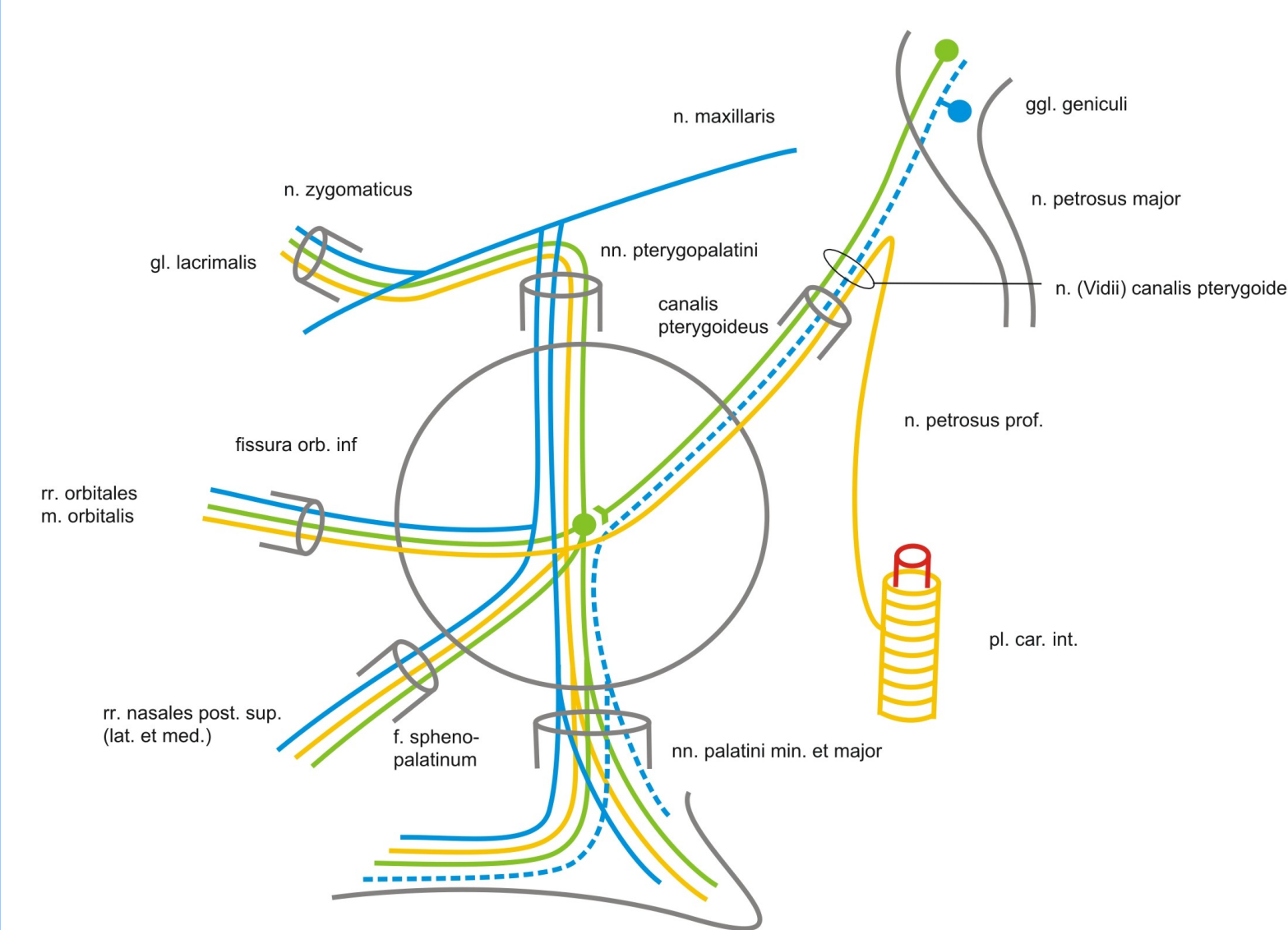
n. V/1 - n. ophthalmicus



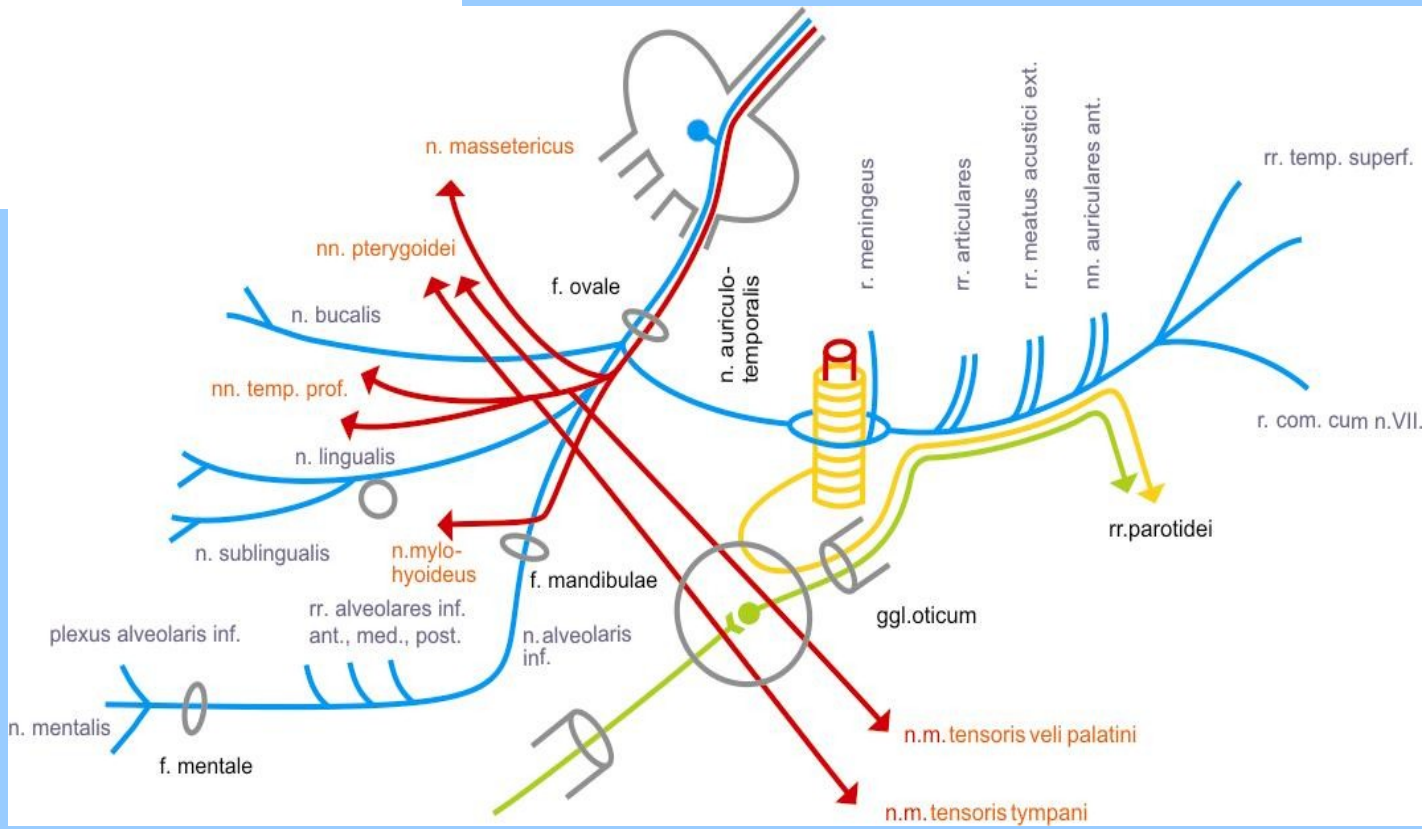
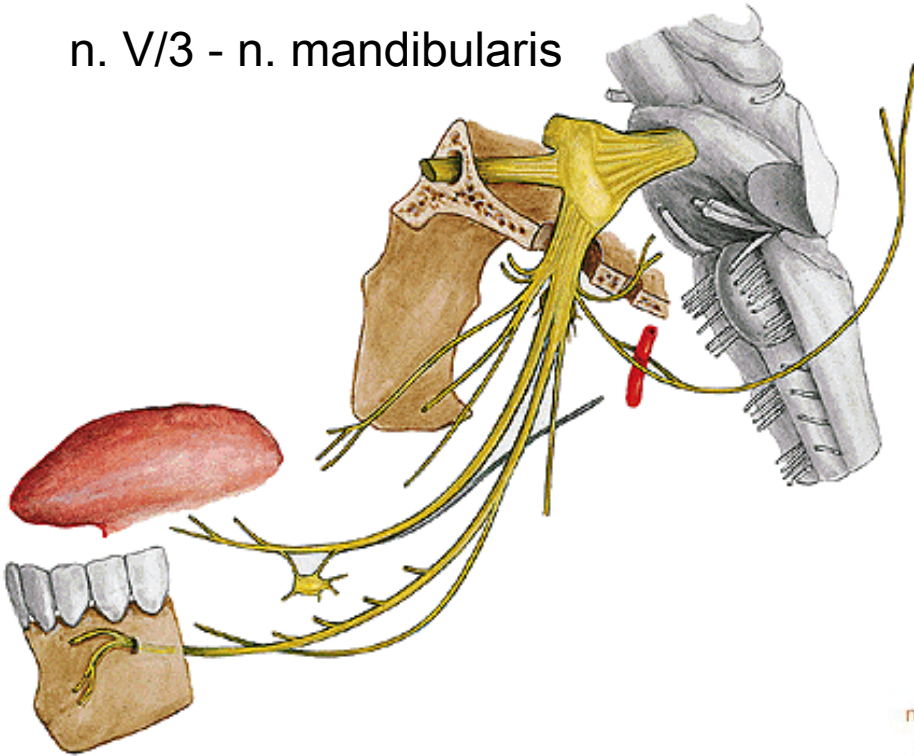
n. V/2 - n. maxillaris



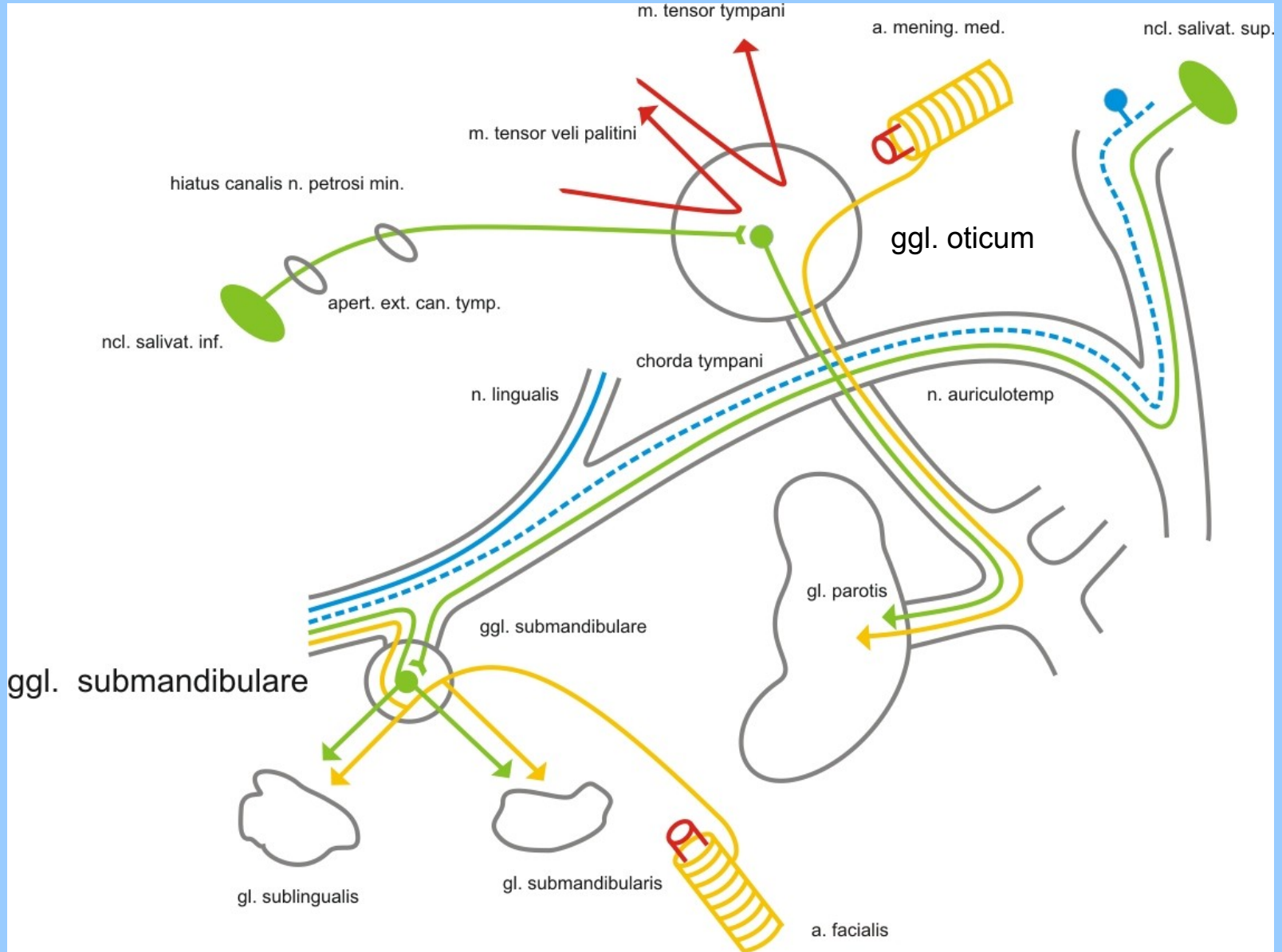
ggl. pterygopalatinum



n. V/3 - n. mandibularis

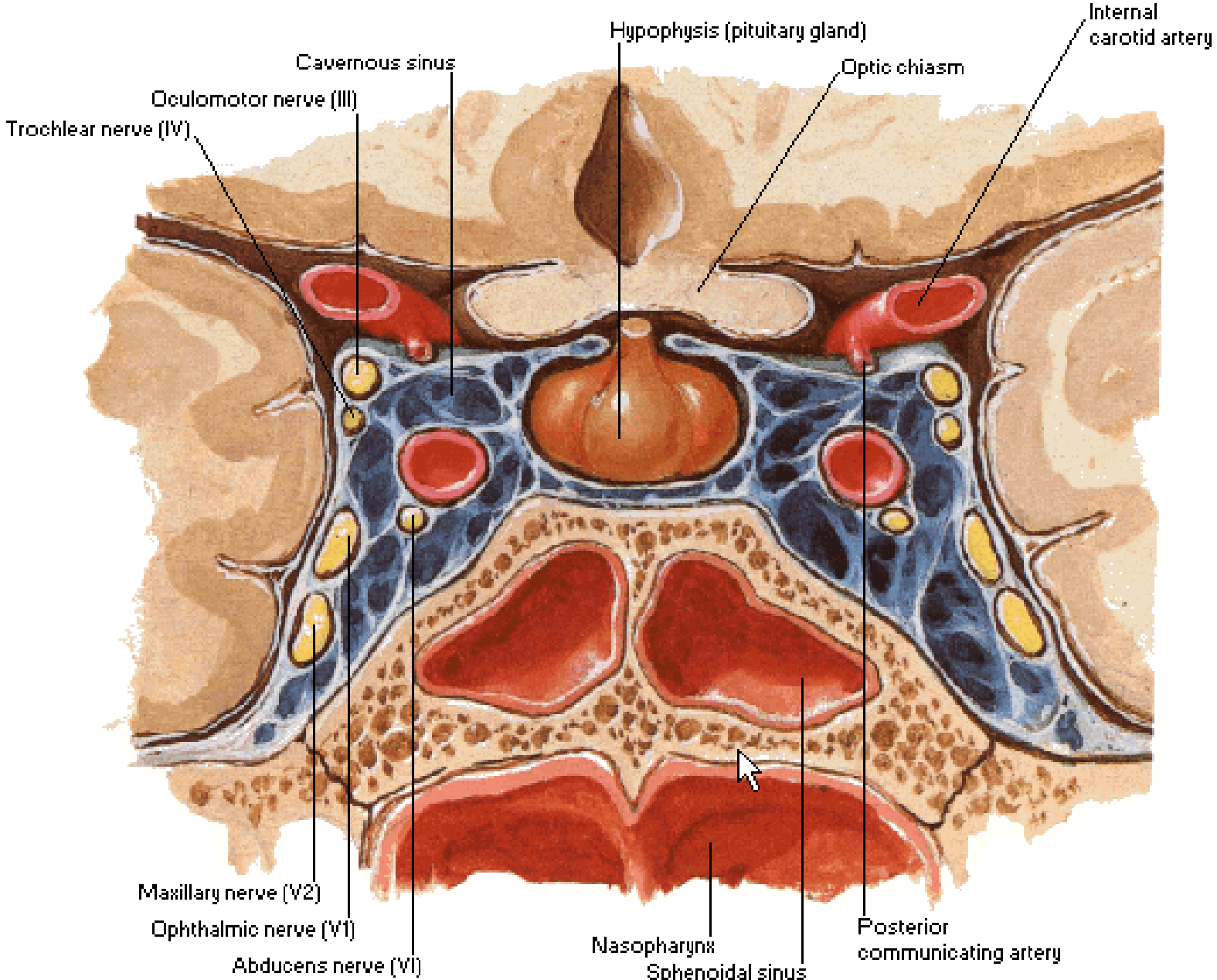


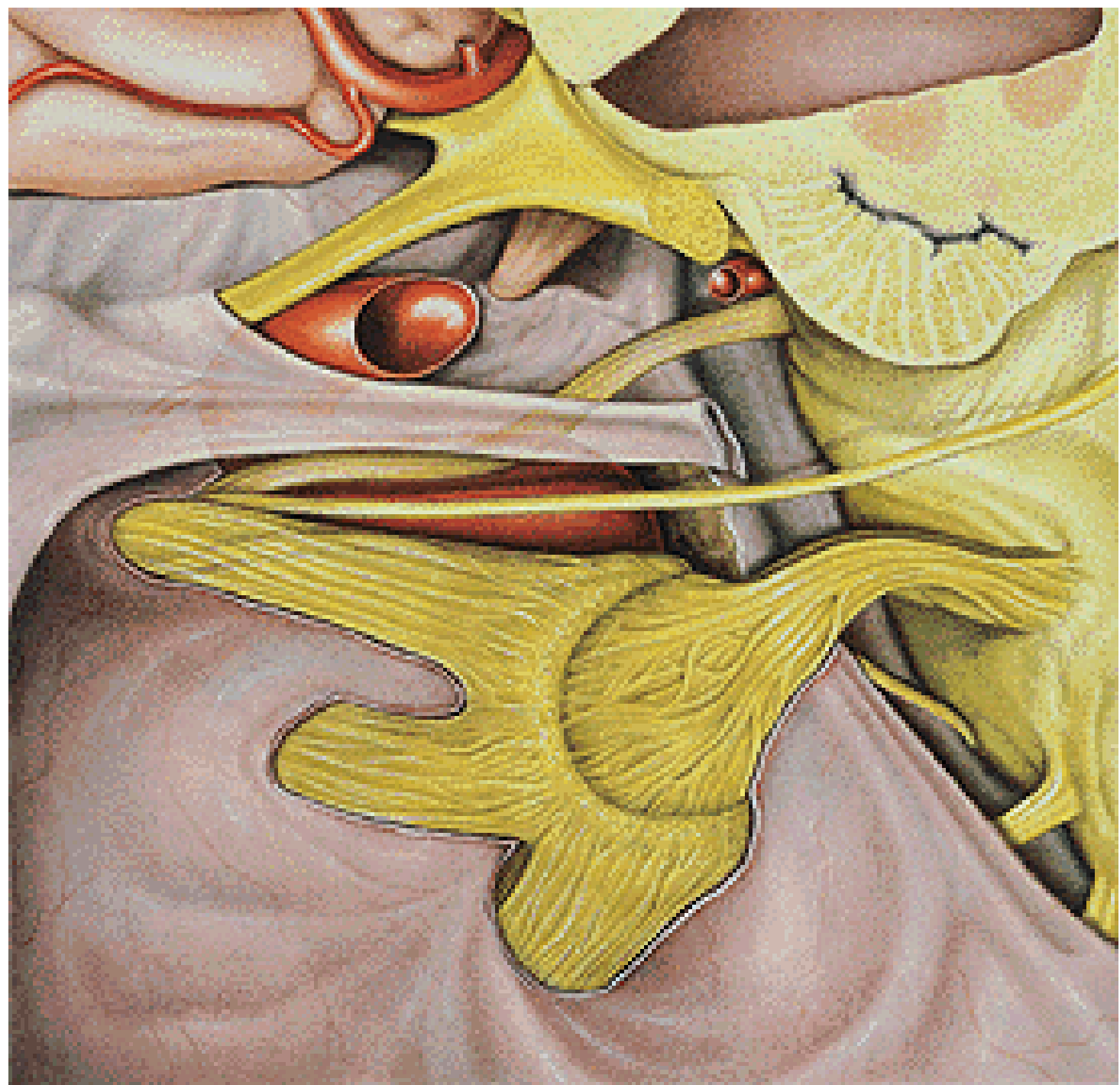
Ggl. oticum et submandibulare

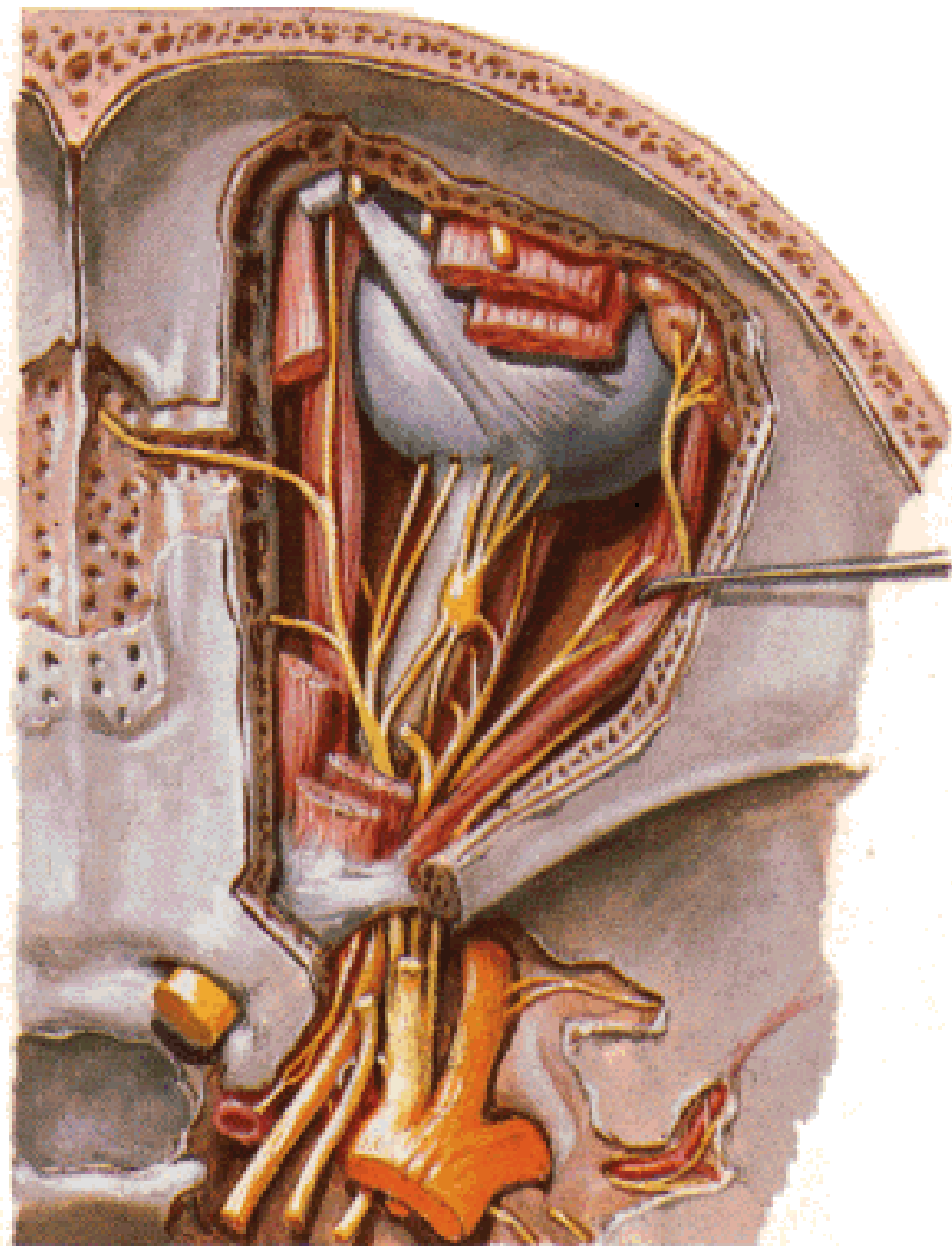


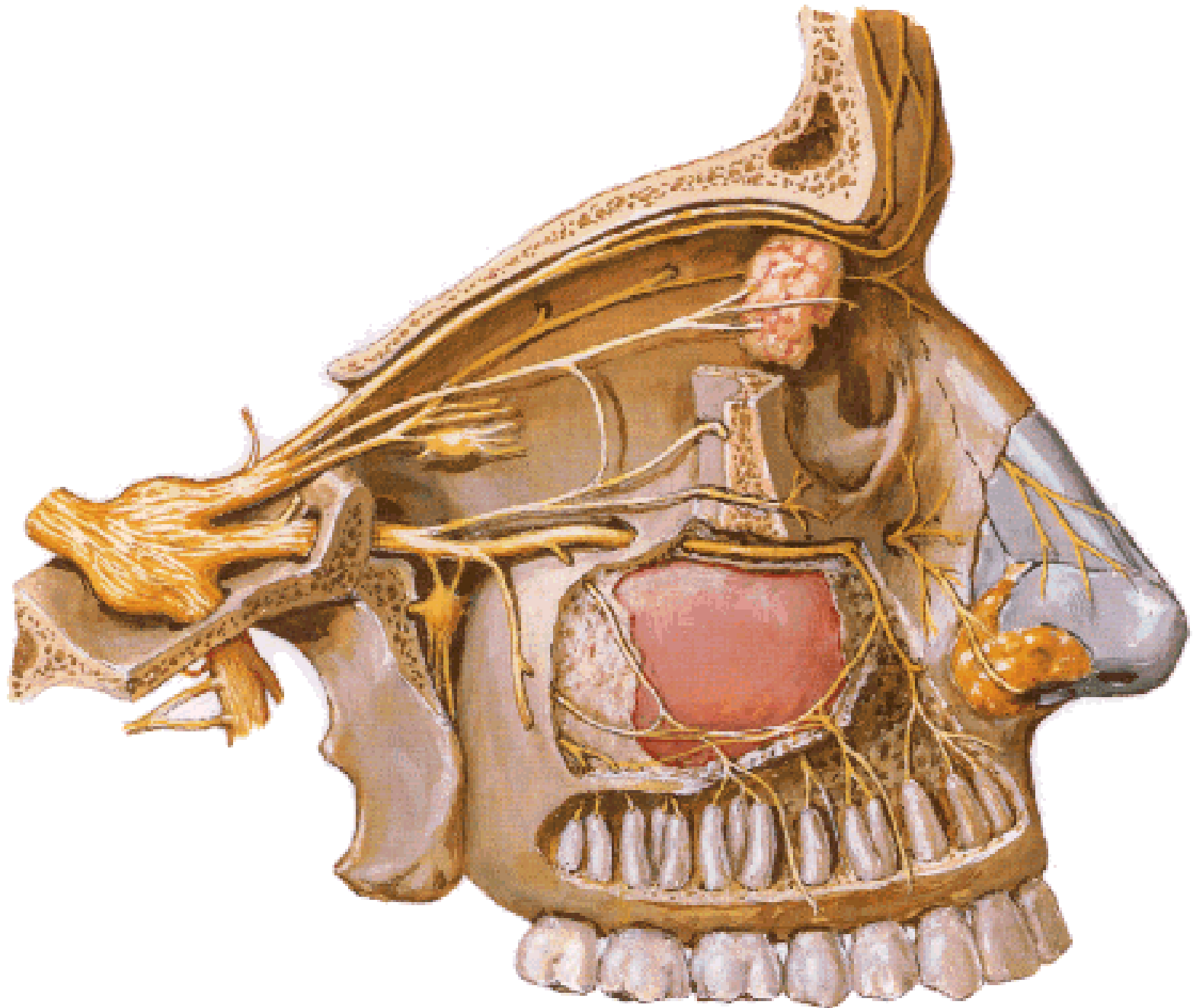
Cavernous Sinus

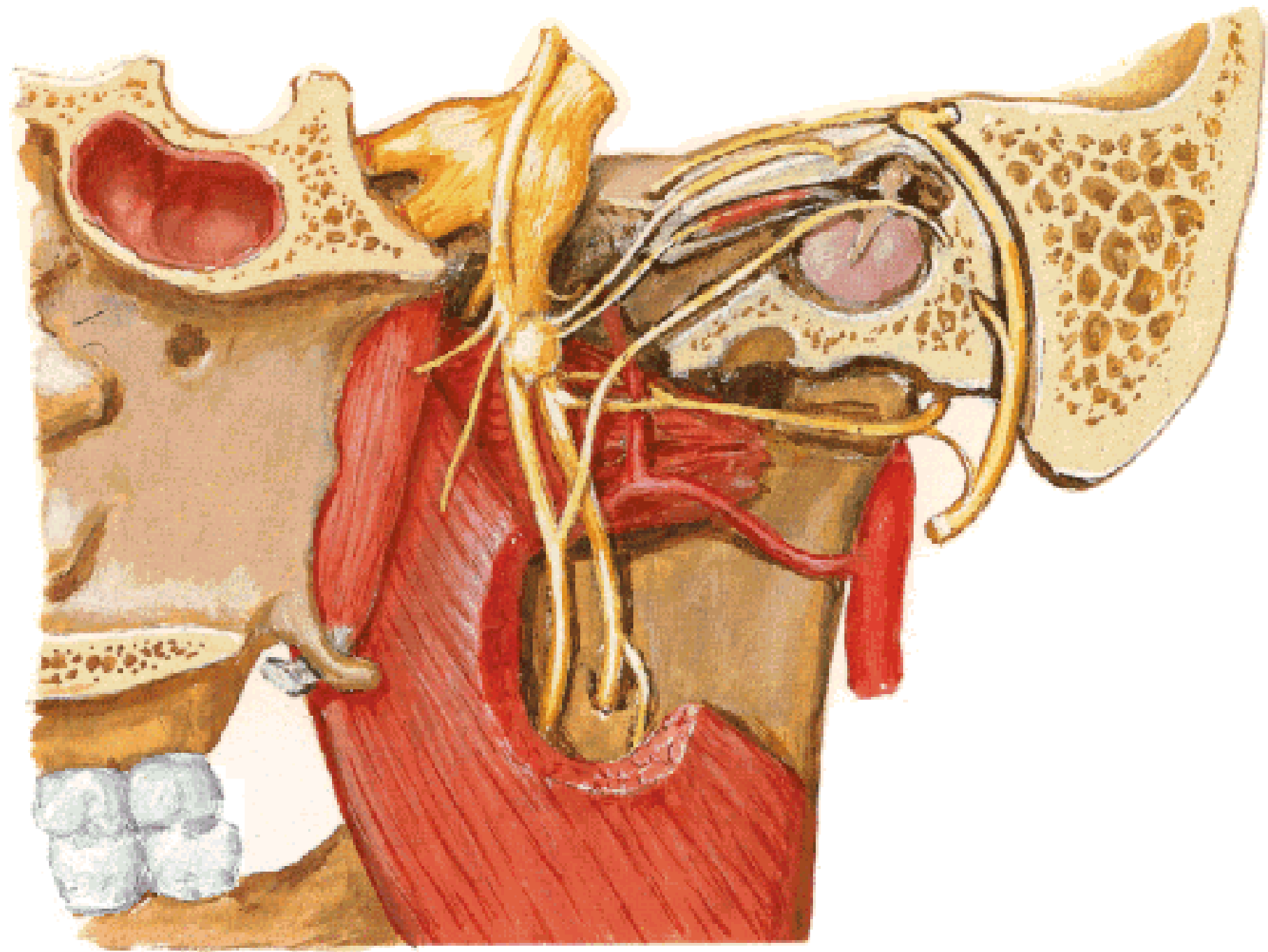
Coronal Section

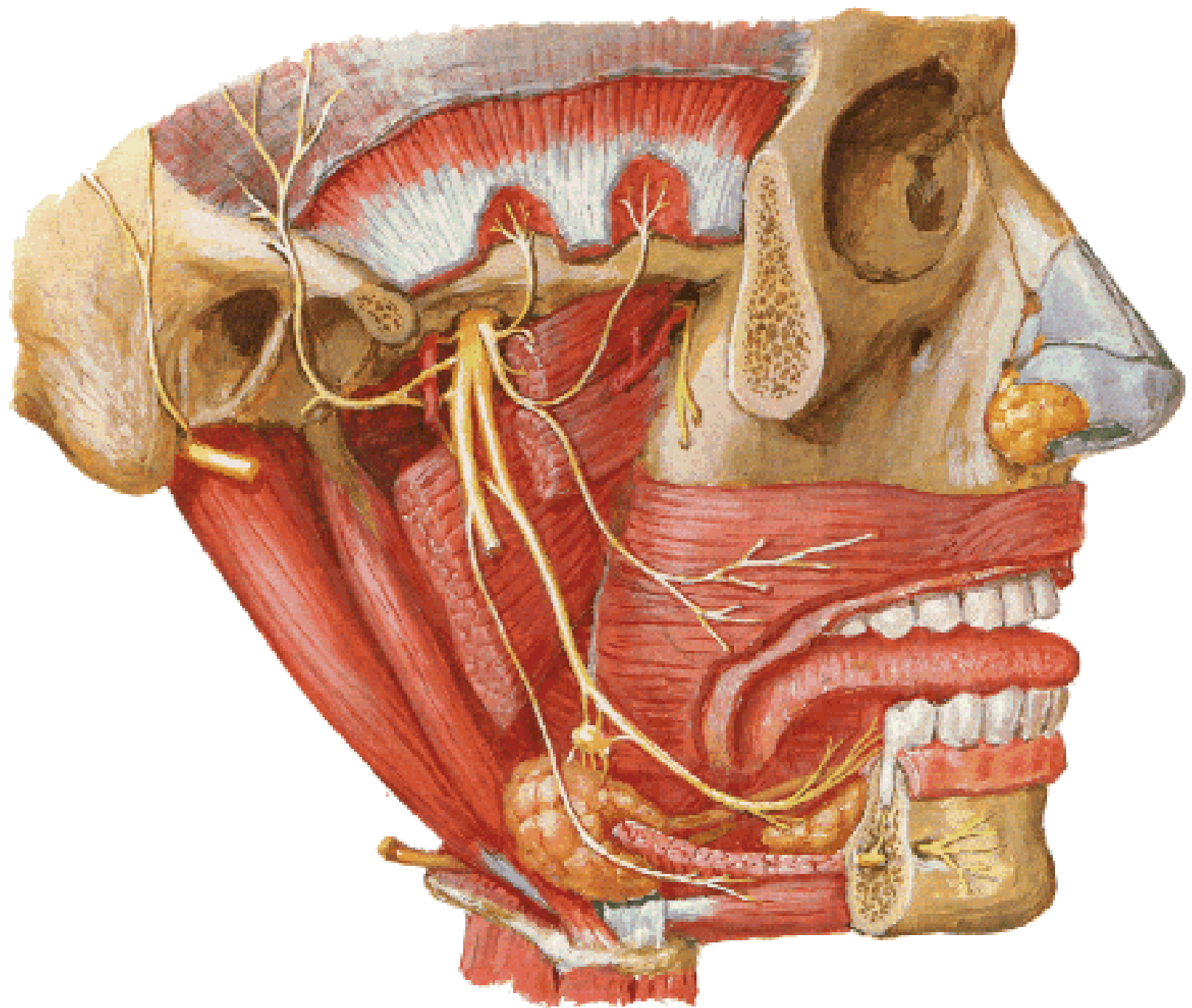


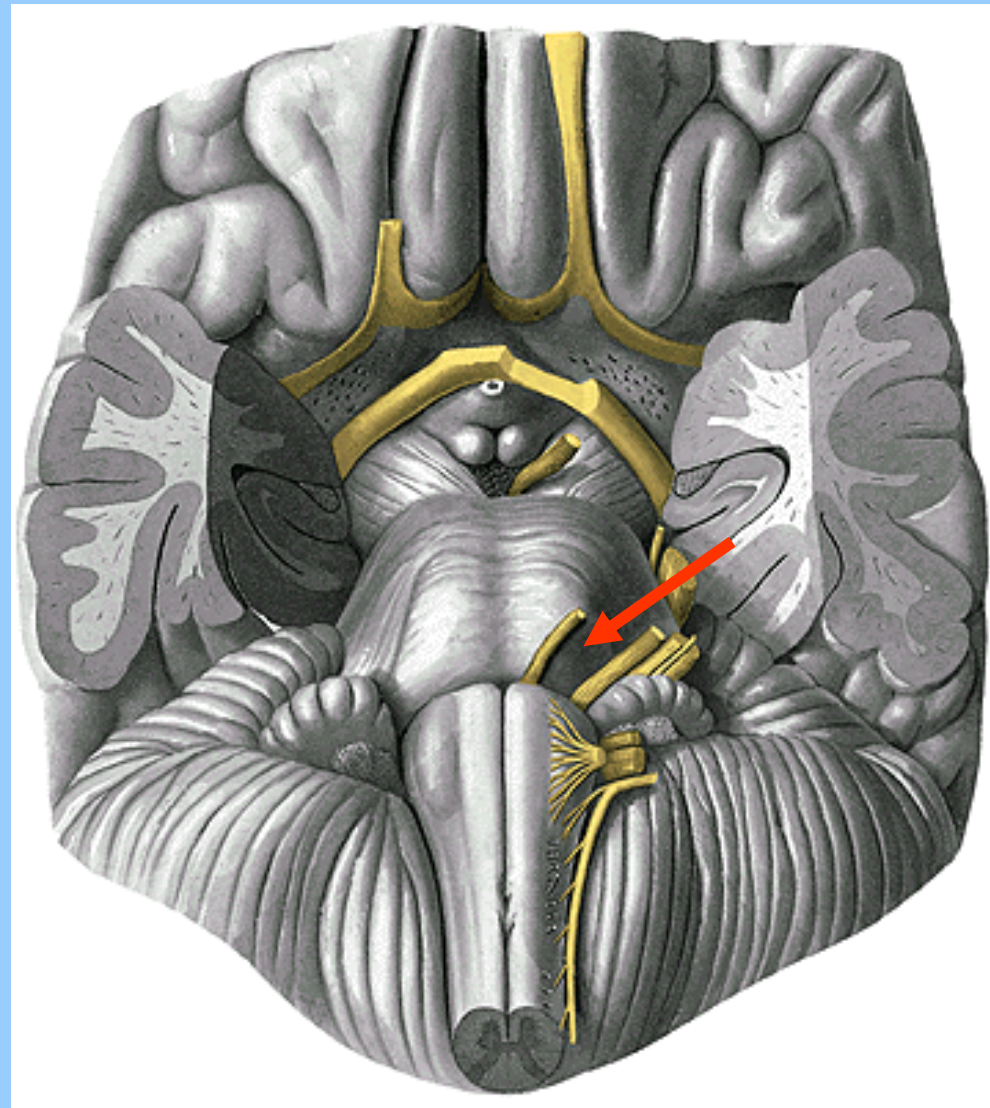
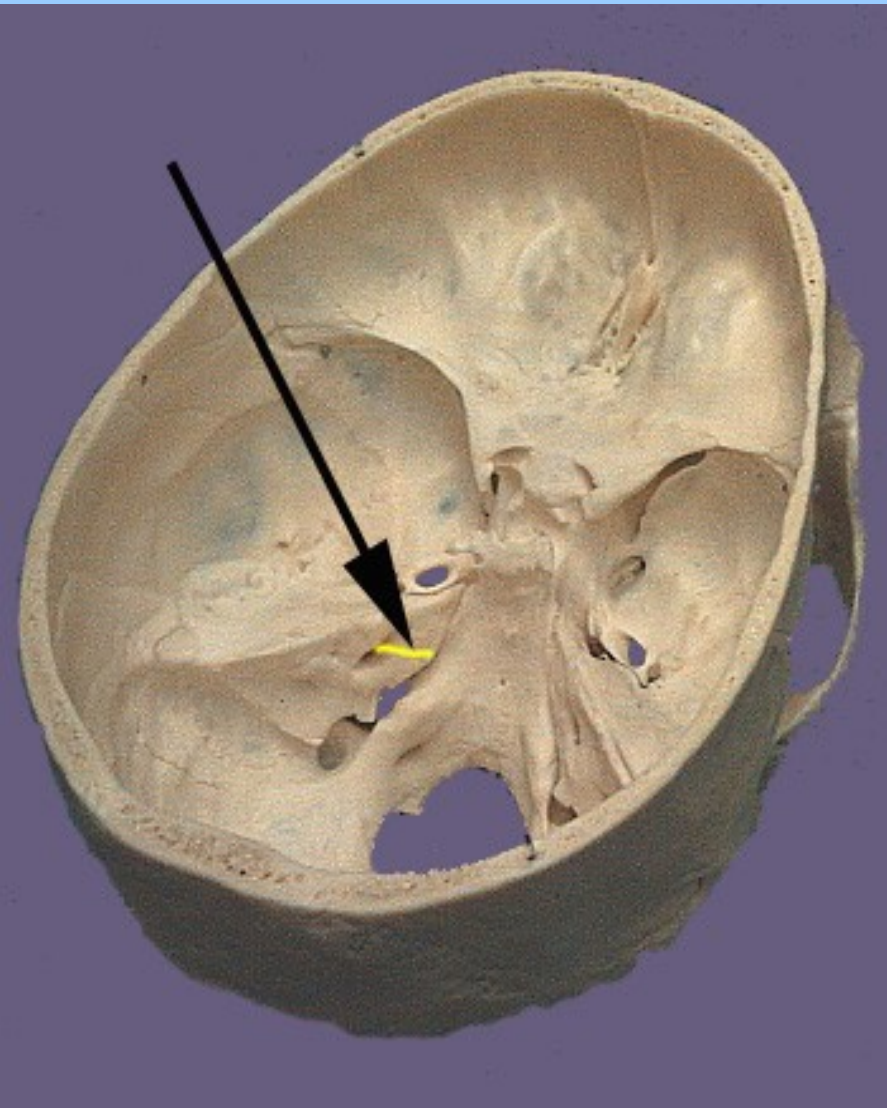




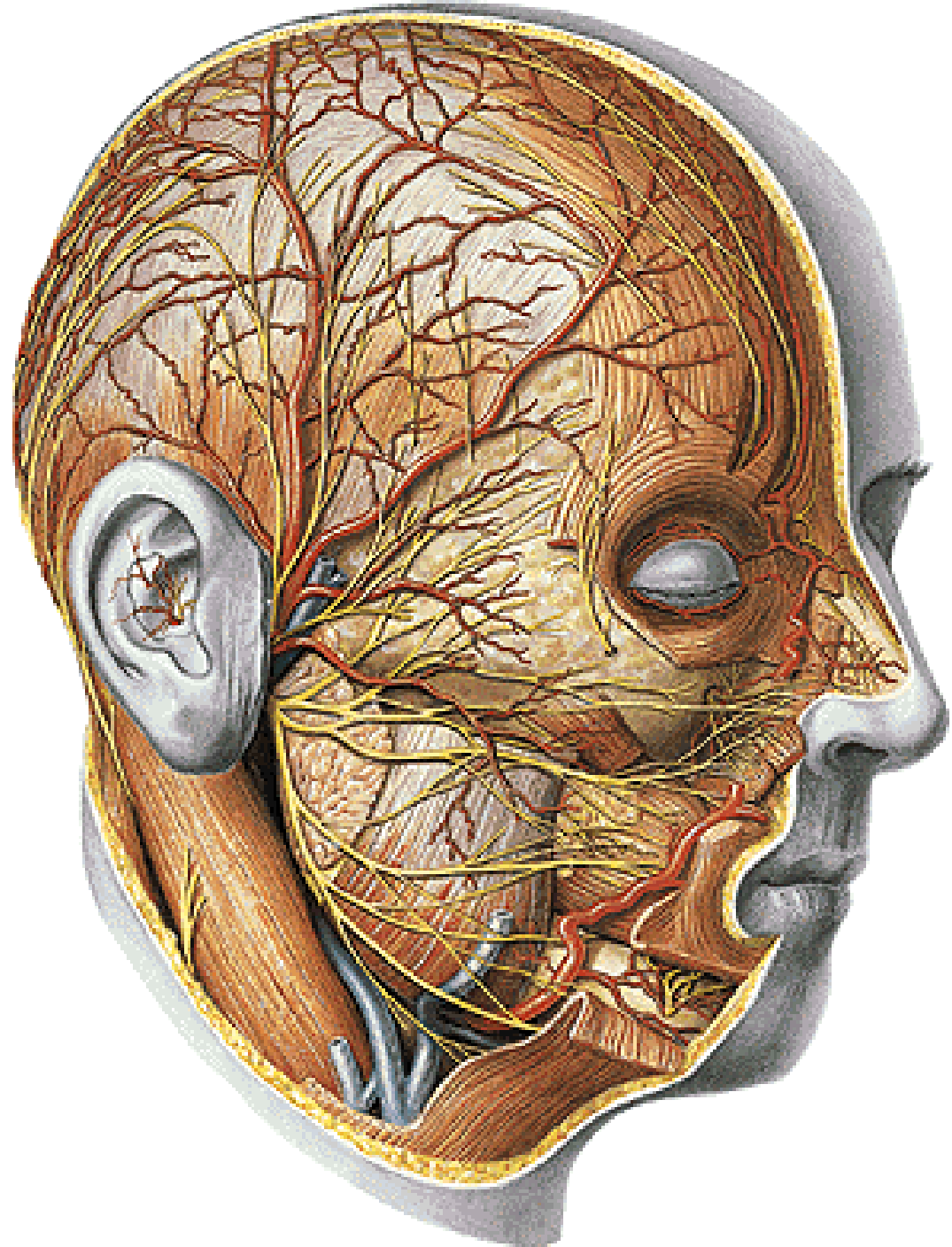


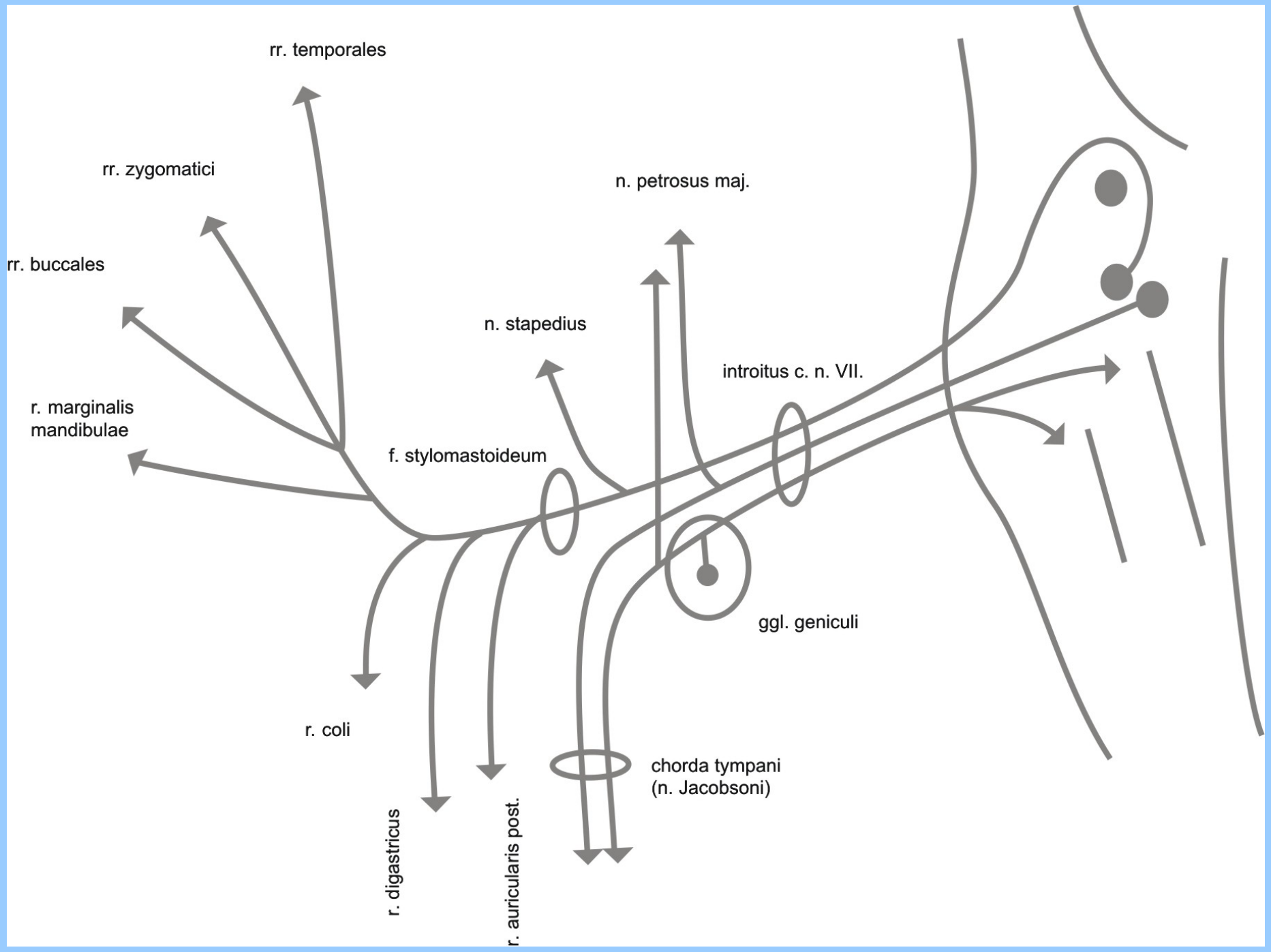






n. VII.





rr. temporales

rr. zygomatici

rr. buccales

r. marginalis mandibulae

n. petrosus maj.

n. stapedius

introitus c. n. VII.

f. stylomastoideum

ggl. geniculi

r. coli

chorda tympani (n. Jacobsoni)

r. digastricus

r. auricularis post.