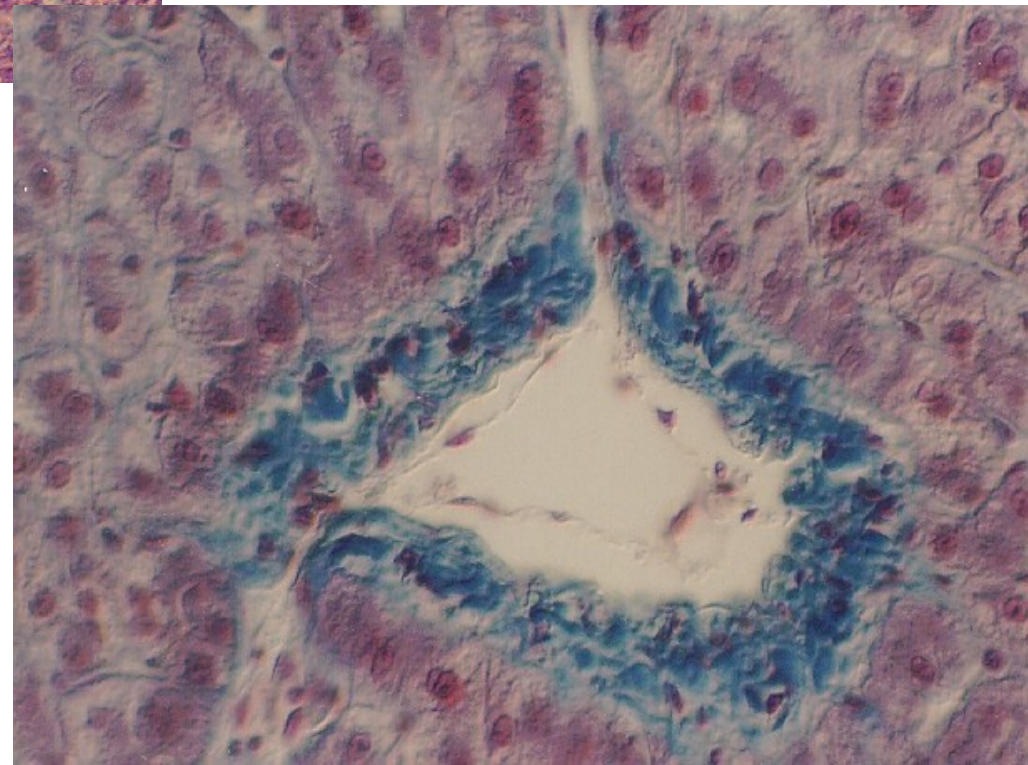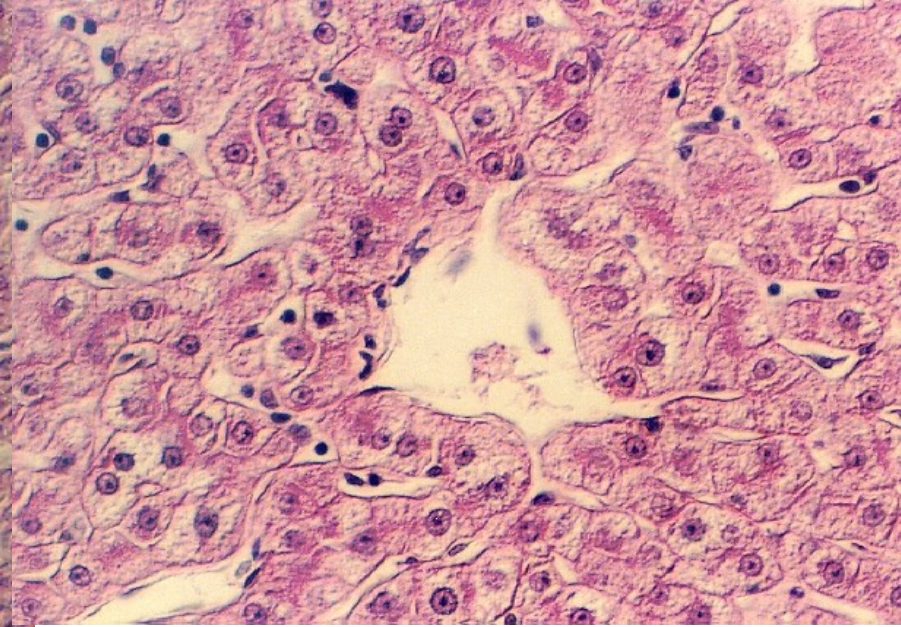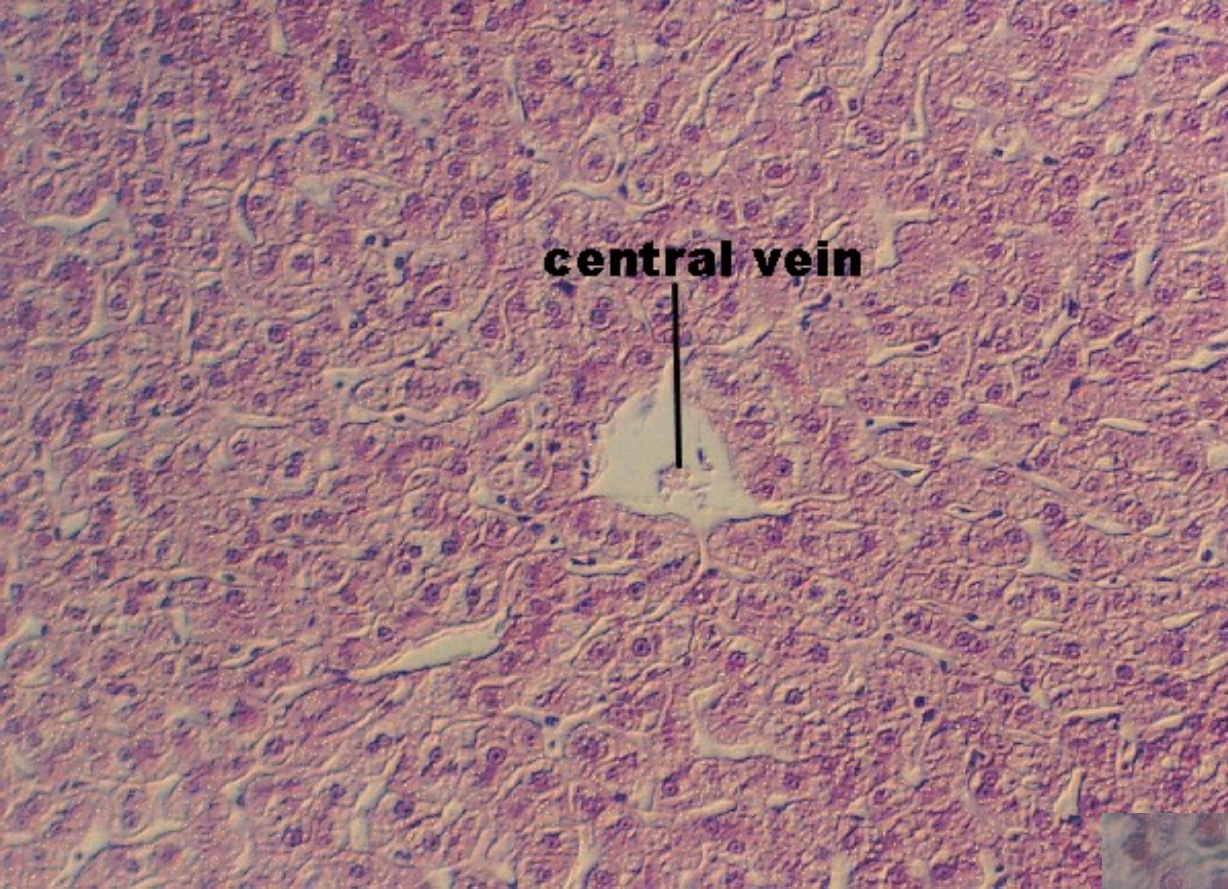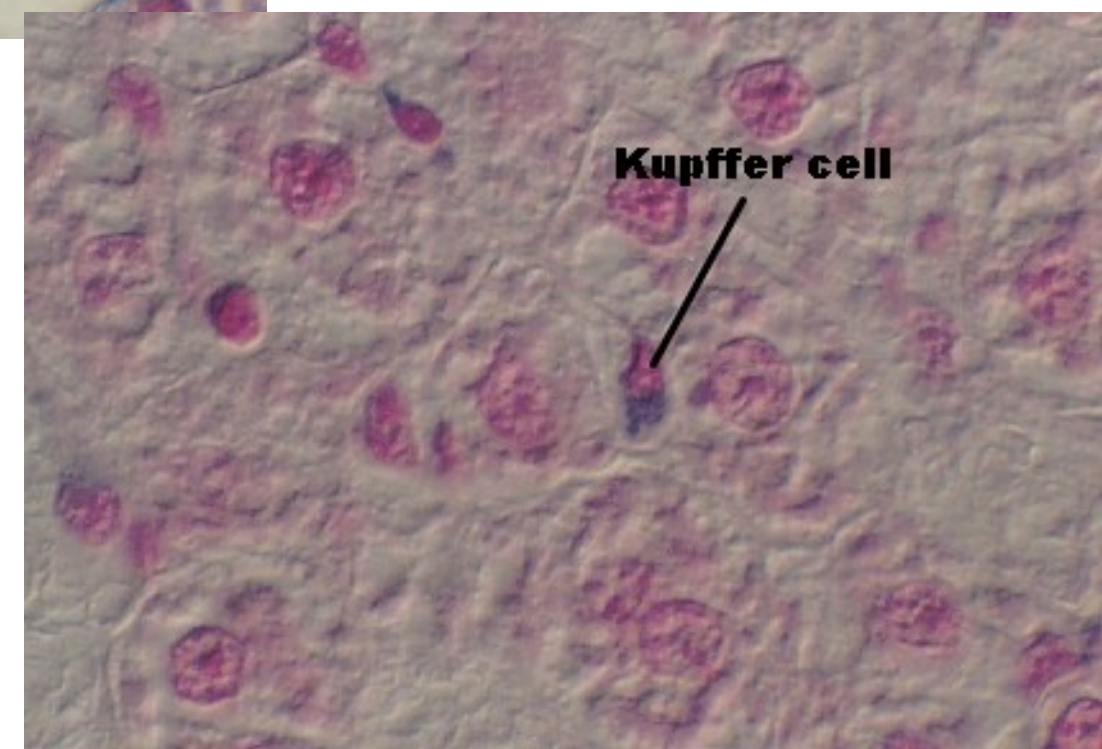
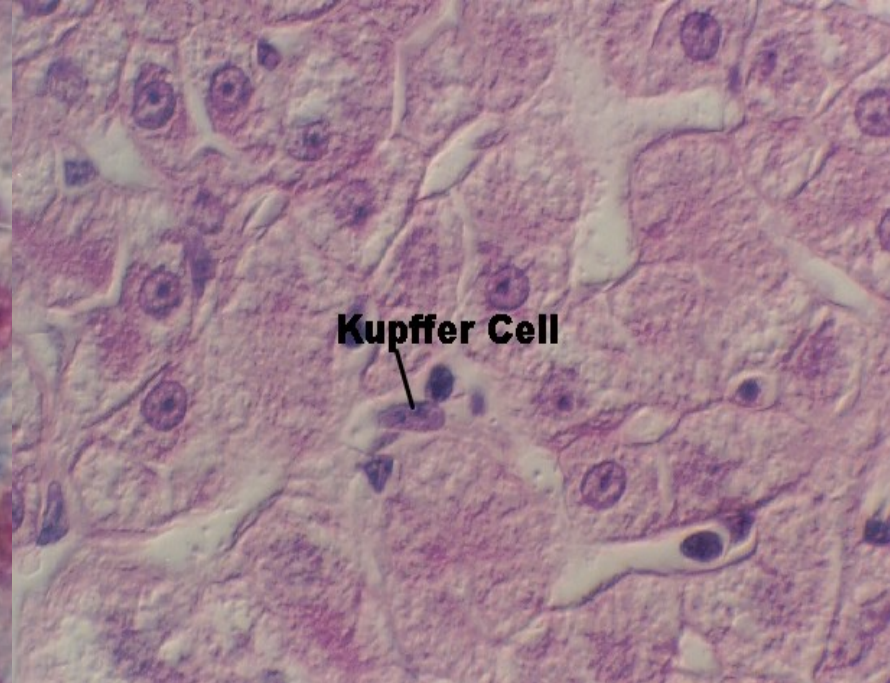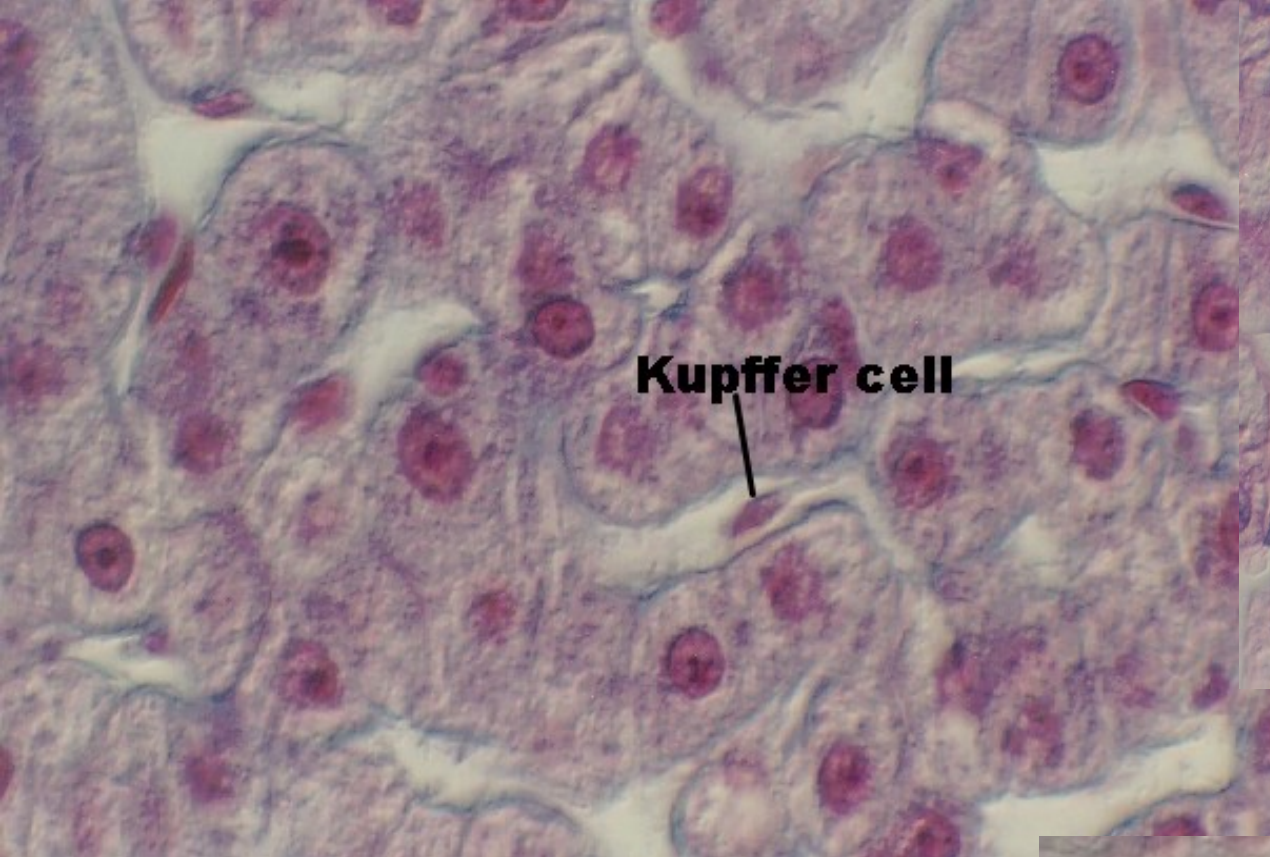
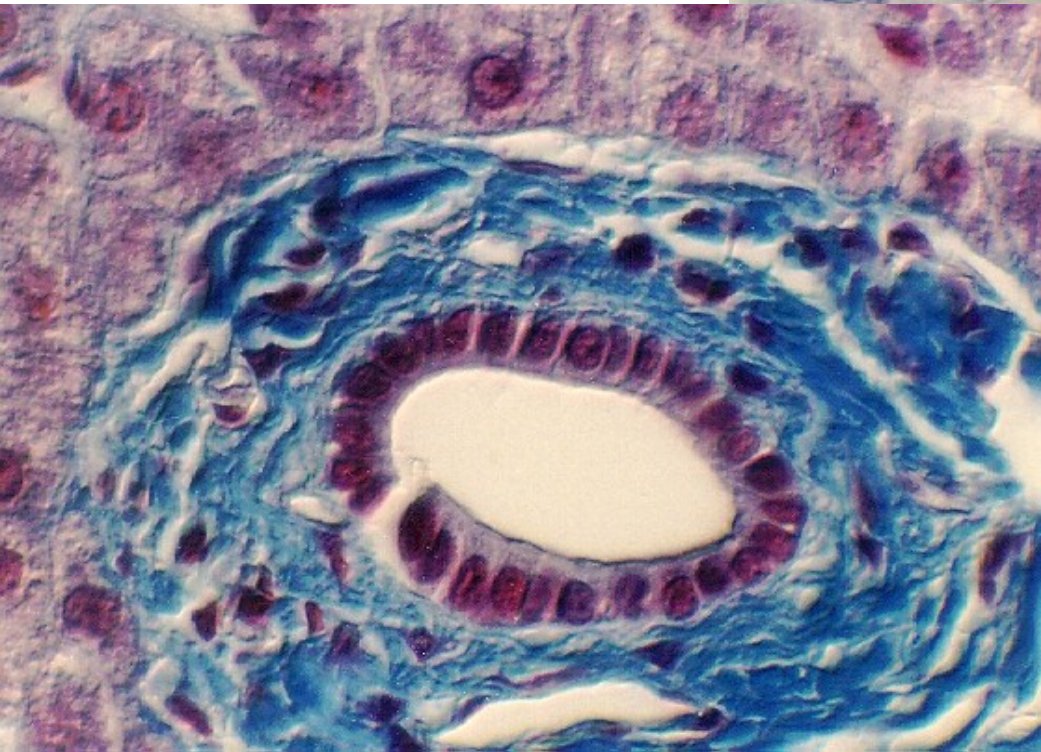
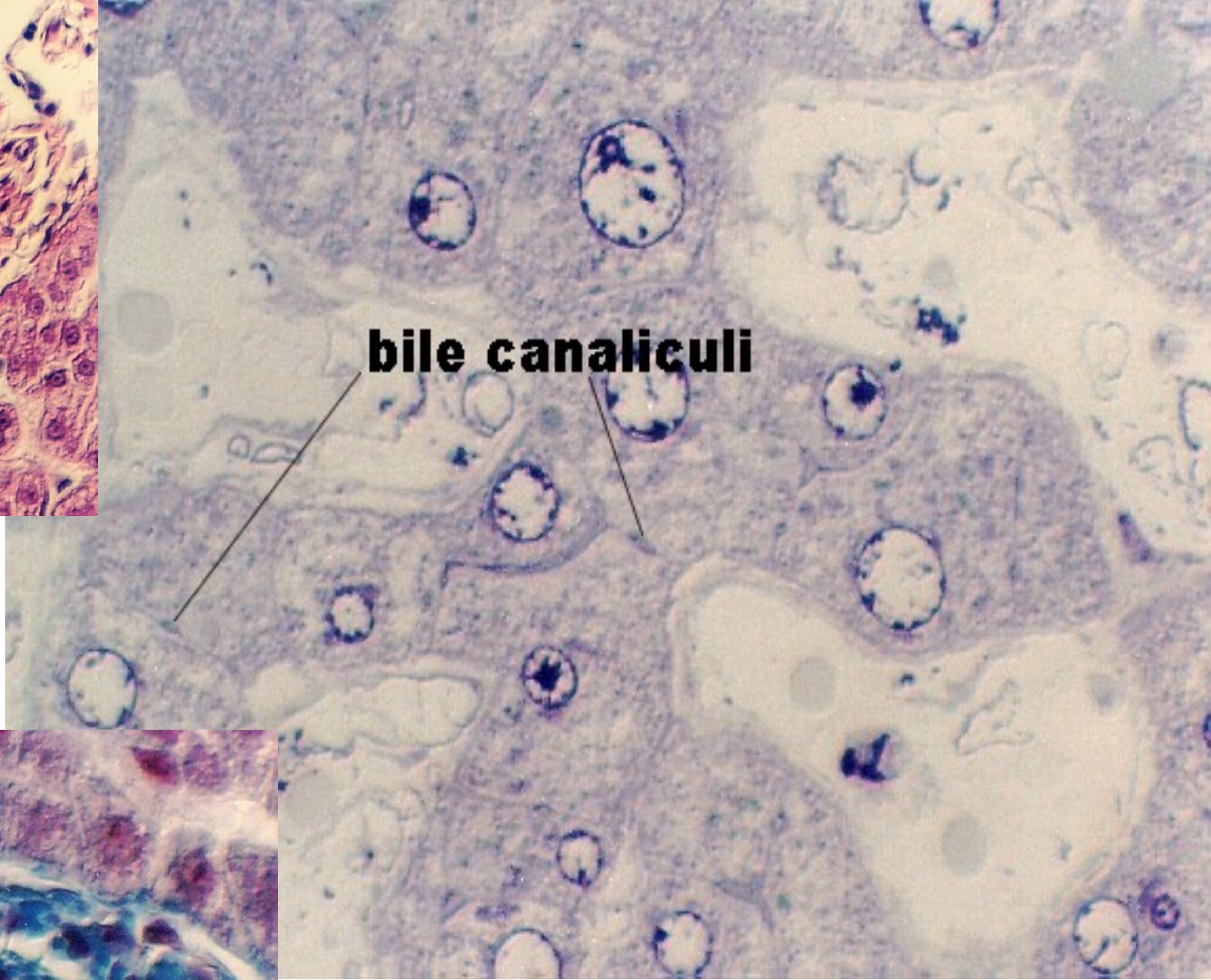
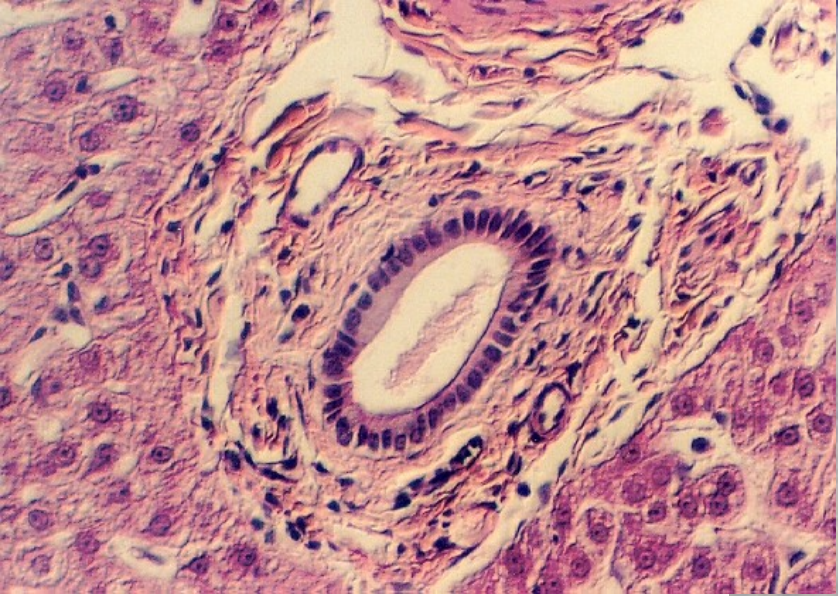
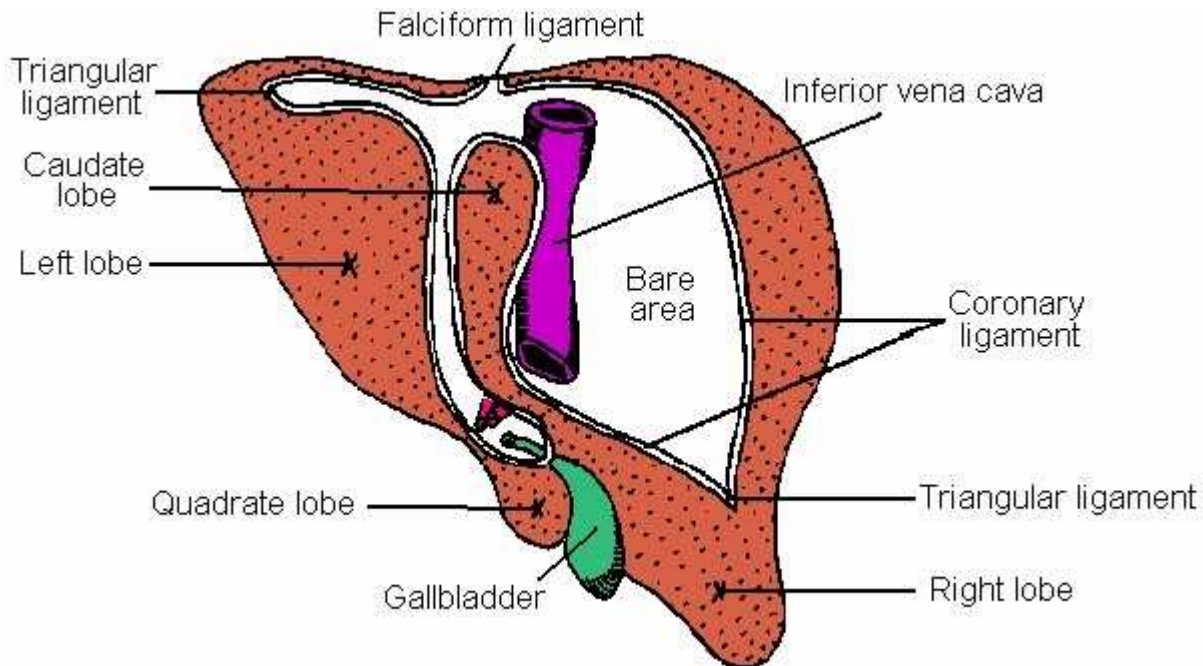
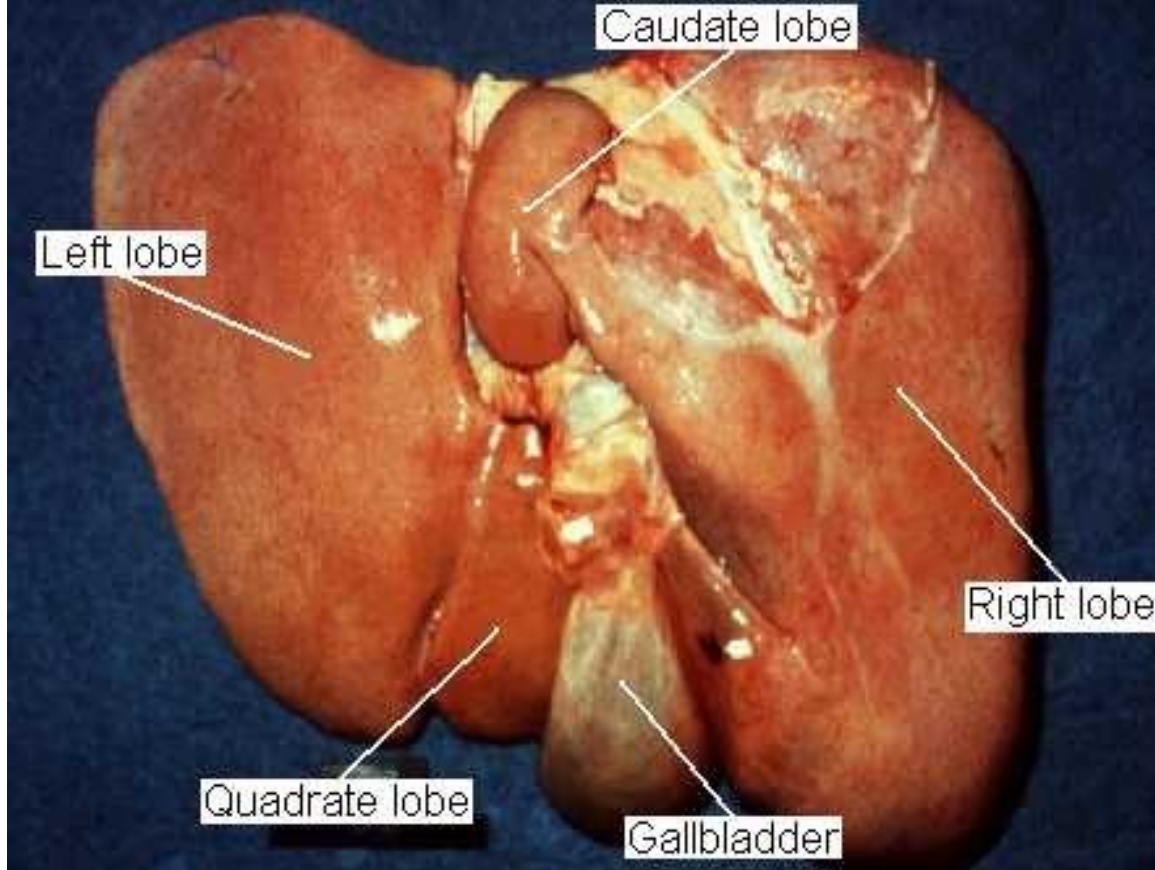


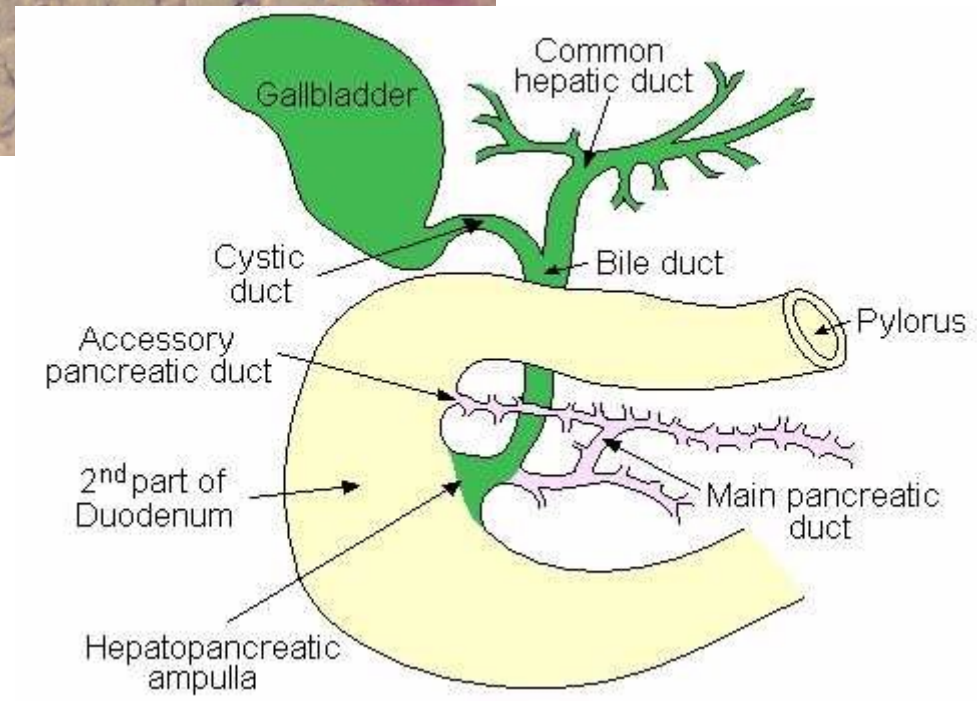
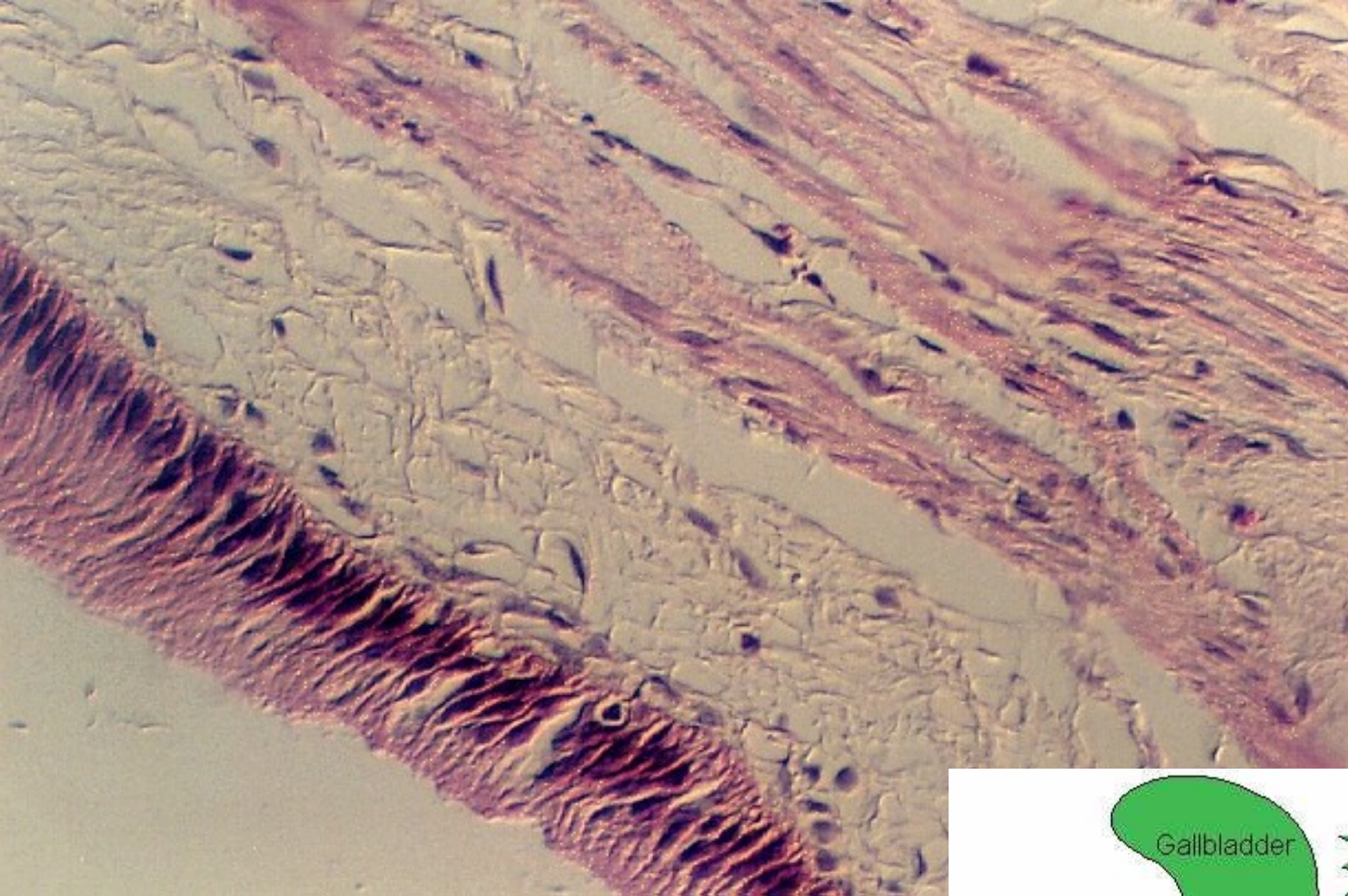
[http://cellbio.utmb.edu/microanatomy/Digestive/Liver\\_and\\_pancreas.htm](http://cellbio.utmb.edu/microanatomy/Digestive/Liver_and_pancreas.htm)  
(+ 2 následující slajdy)





<http://137.222.110.150/calnet/git/page3.htm>



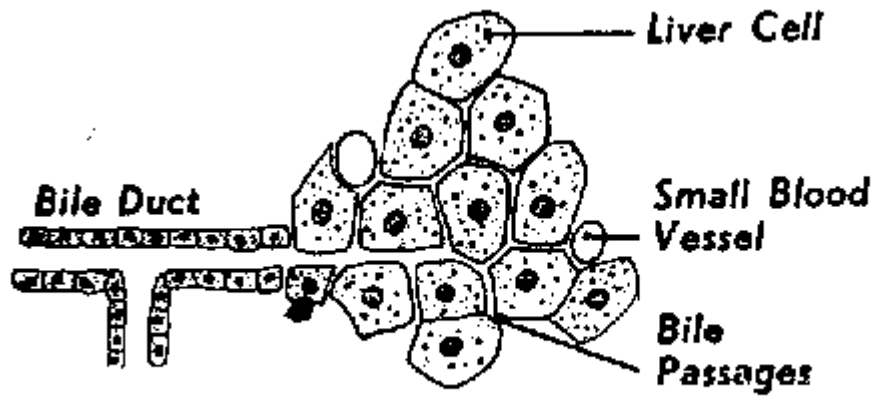


<http://cellbio.utmb.edu/microanatomy/>

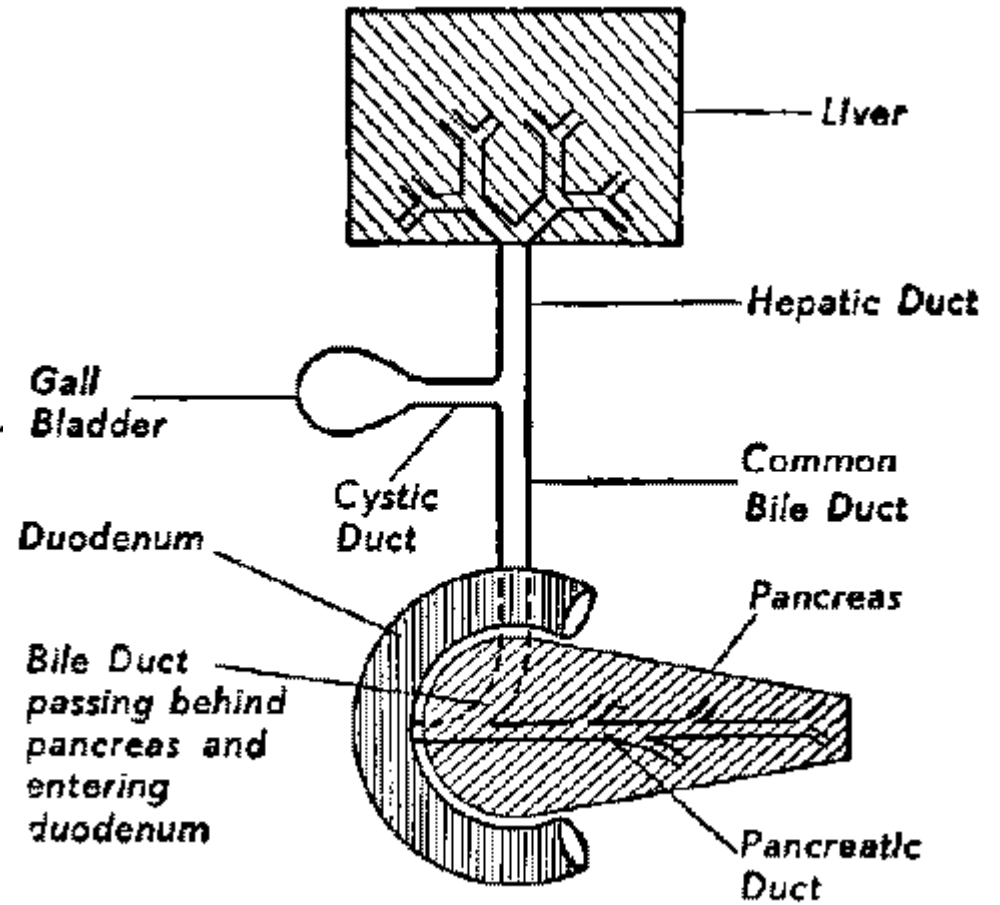
[Digestive/Liver\\_and\\_pancreas.htm](http://137.222.110.150/calnet/git/Digestive/Liver_and_pancreas.htm)

<http://137.222.110.150/calnet/git/>

[page3.htm#section4](http://137.222.110.150/calnet/git/page3.htm#section4)



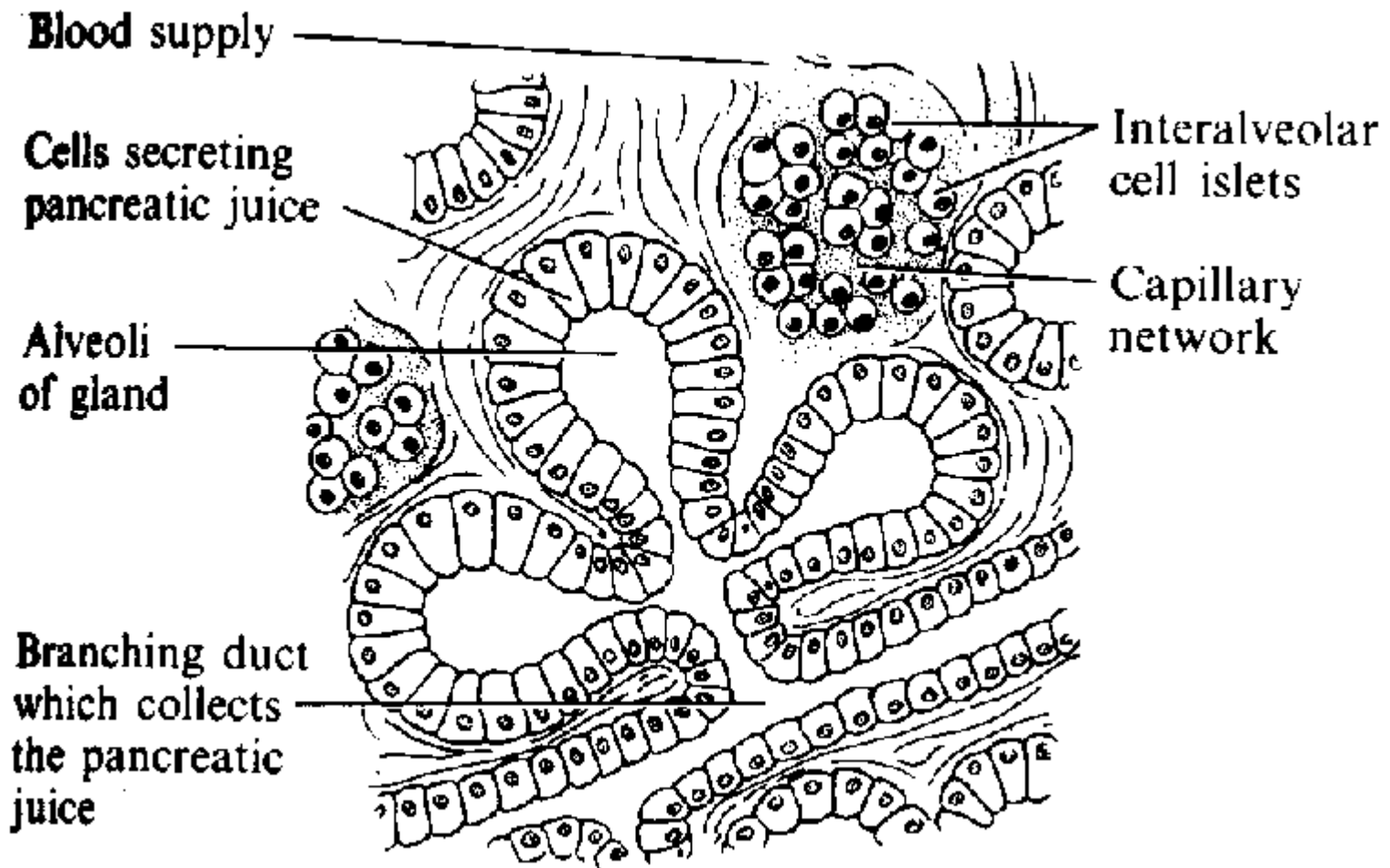
Termination of a Bile Duct at edge of L



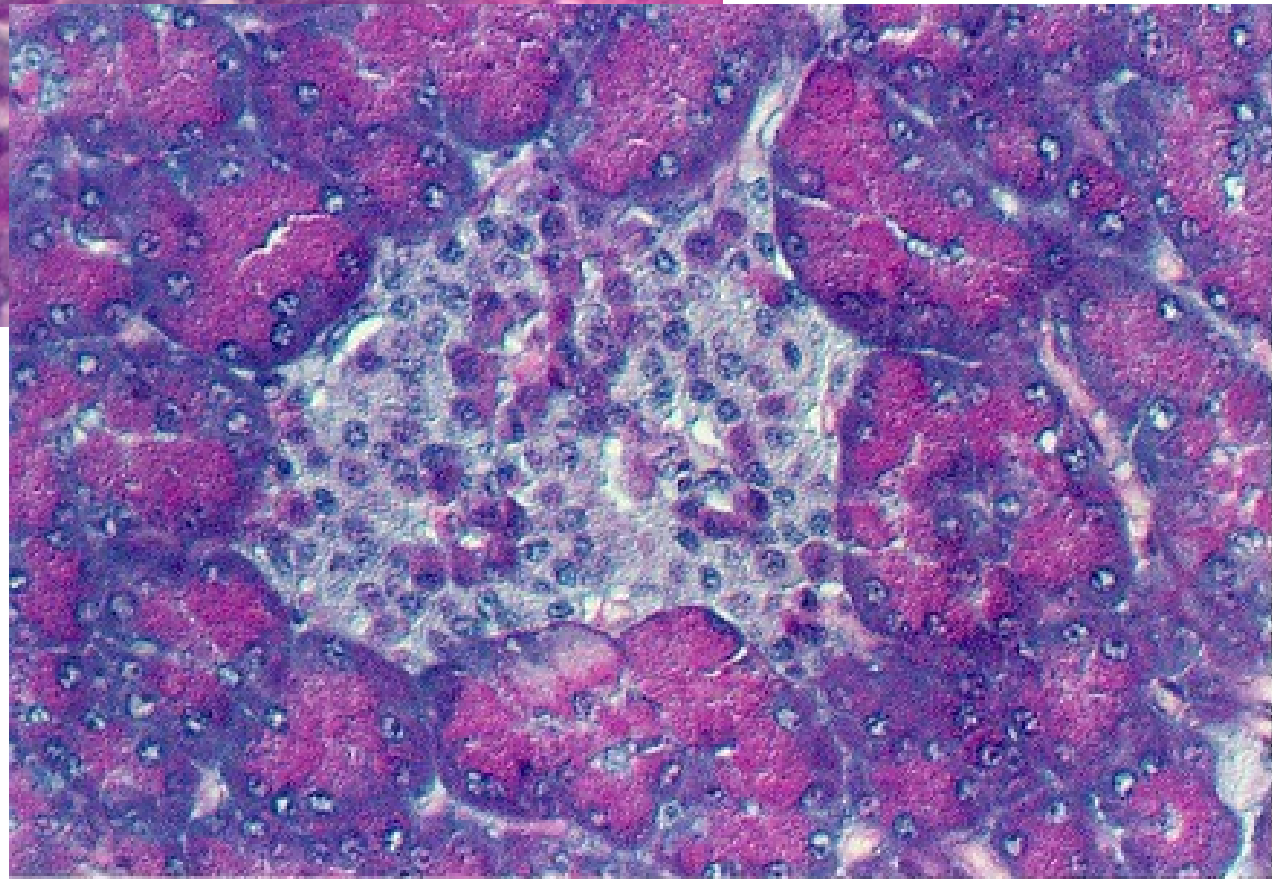
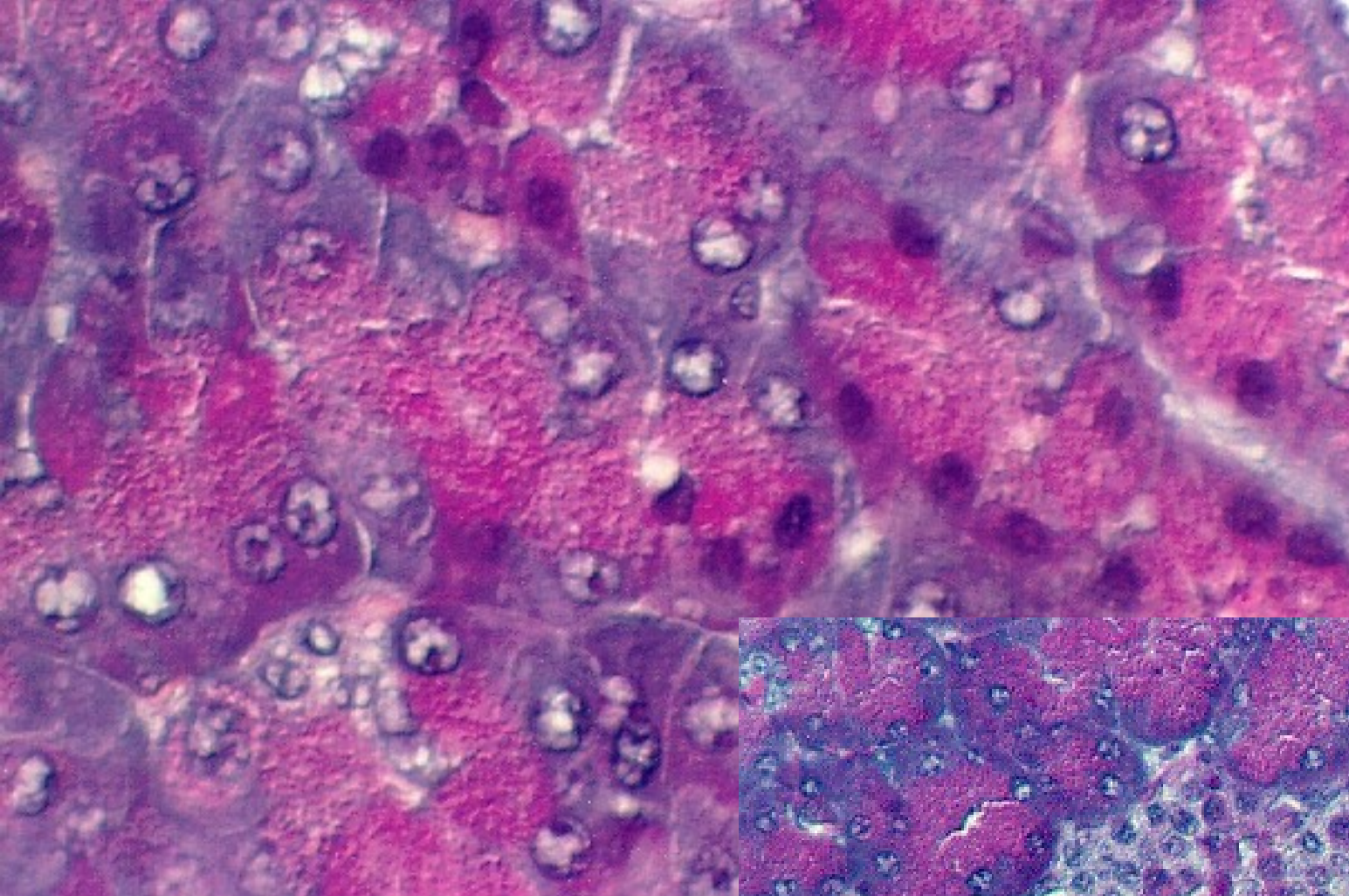
-Diagram illustrating the Biliary Apparatus.

<http://www.arthursclipart.com/medical/digesbw/bileduct.gif>

<http://www.arthursclipart.com/medical/digesbw/billiary.gif>



<http://www.arthursclipart.com/medical/digesbw/PANSREAS.gif>



[http://cellbio.utmb.edu/  
microanatomy/Digestive/  
Liver\\_and\\_pancreas.htm](http://cellbio.utmb.edu/microanatomy/Digestive/Liver_and_pancreas.htm)