

REGIONAL ANAESTHESIA

Katarina Zadrazilova FN

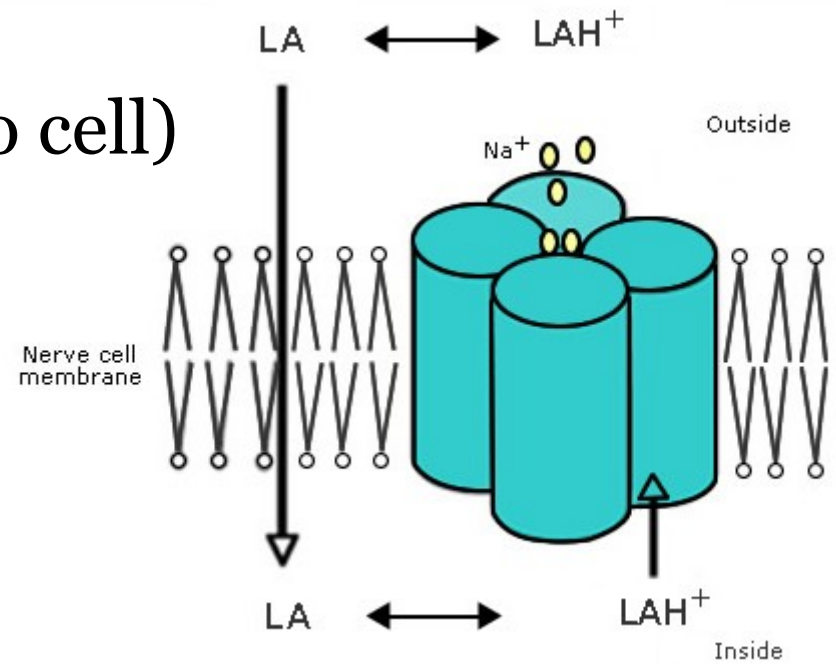
Brno October 2010

Anaesthesia = loss of sensation

- General (narcosis)
- Local / regional
- Combined

Local anaesthetic

- Reversible block
- Sodium ion canal (Na^+ to cell)



Nerve fibre

- A: myelinated
 - α (alfa): motor function, reflex activity a proprioception
 - β (beta): touch, pressure
 - γ (gama): muscular tonus
 - δ (delta): PAIN and sense of heat
- B: thin, myelinated preganglion-nerve fibre, autonomic function, smooth muscle of vessels
- C: non-myelinated, PAIN

Nerve block - signs

- (B fibre) block of sympathetic = heat
- (C + A δ fibre) block of pain and heat
- (A β) loss of touch sensation
- (A α) motor block

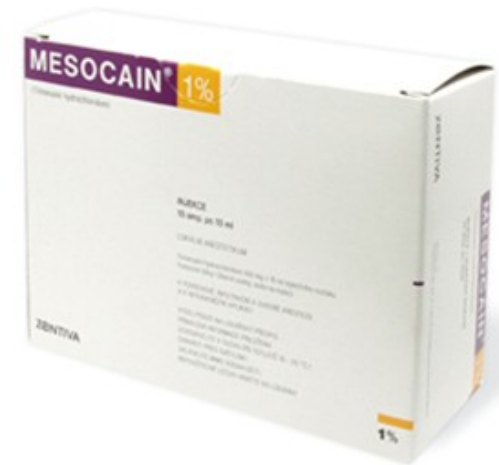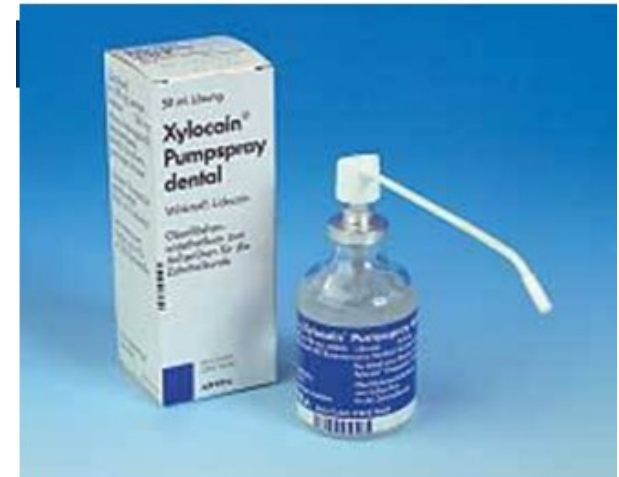Local anaesthetics

Potentially toxic!

- CNS
 - Convulsion, coma, depression of breath!
 - Perioral tingling, iron taste, somnolence, vertigo, tinnitus (ringing), nystagmus, visual disturbance
- Cardiovascular system
 - Hypotension, bradycardia, colaps of circulation, asystoly or ventricular fibrillation!

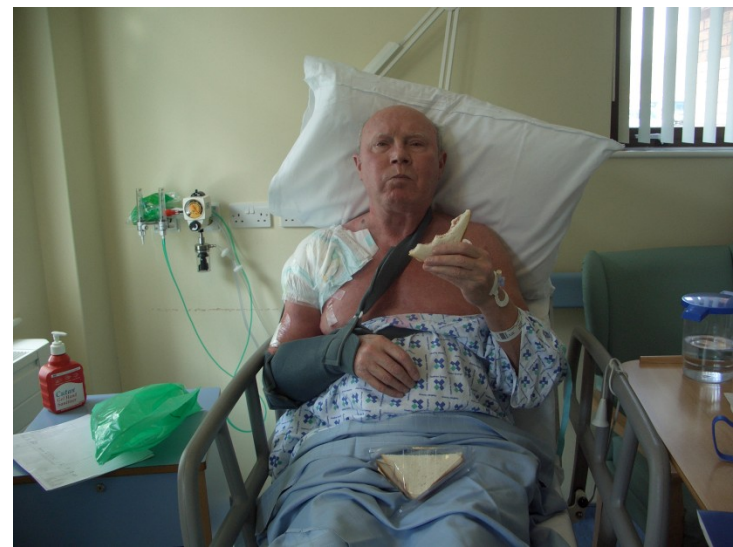Local anaesthetics

- Esters
- Amides
- **Examples:** lidokain, trimecain (Mesocain)
bupivakain (Marcaine), prokain,
artikain (Ultracain, Supracain),
ropivakain (Naropin)



When to use regional techniques

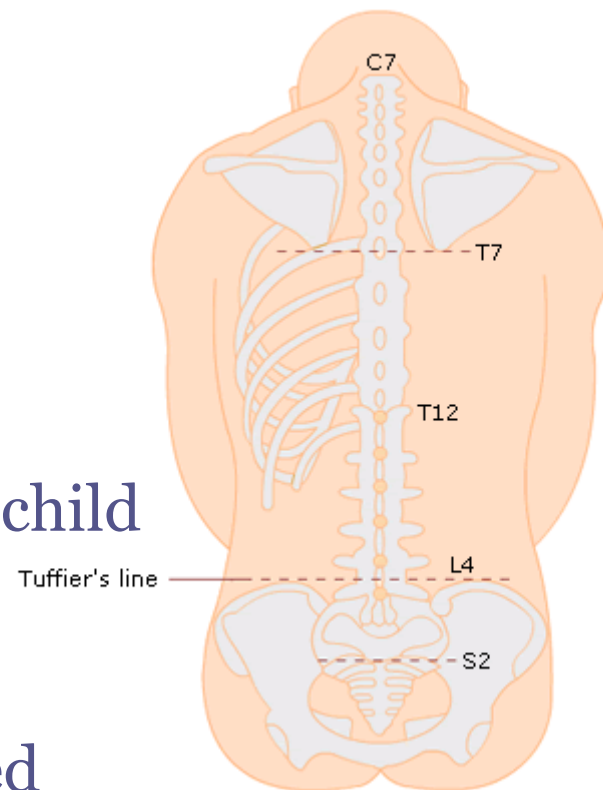
1. **Patient safety** – frail elderly, comorbidities
2. **Patient satisfaction** – ealy oral intake, no PONV, no sore throat
3. **Surgical outcome** - awake craniotomy

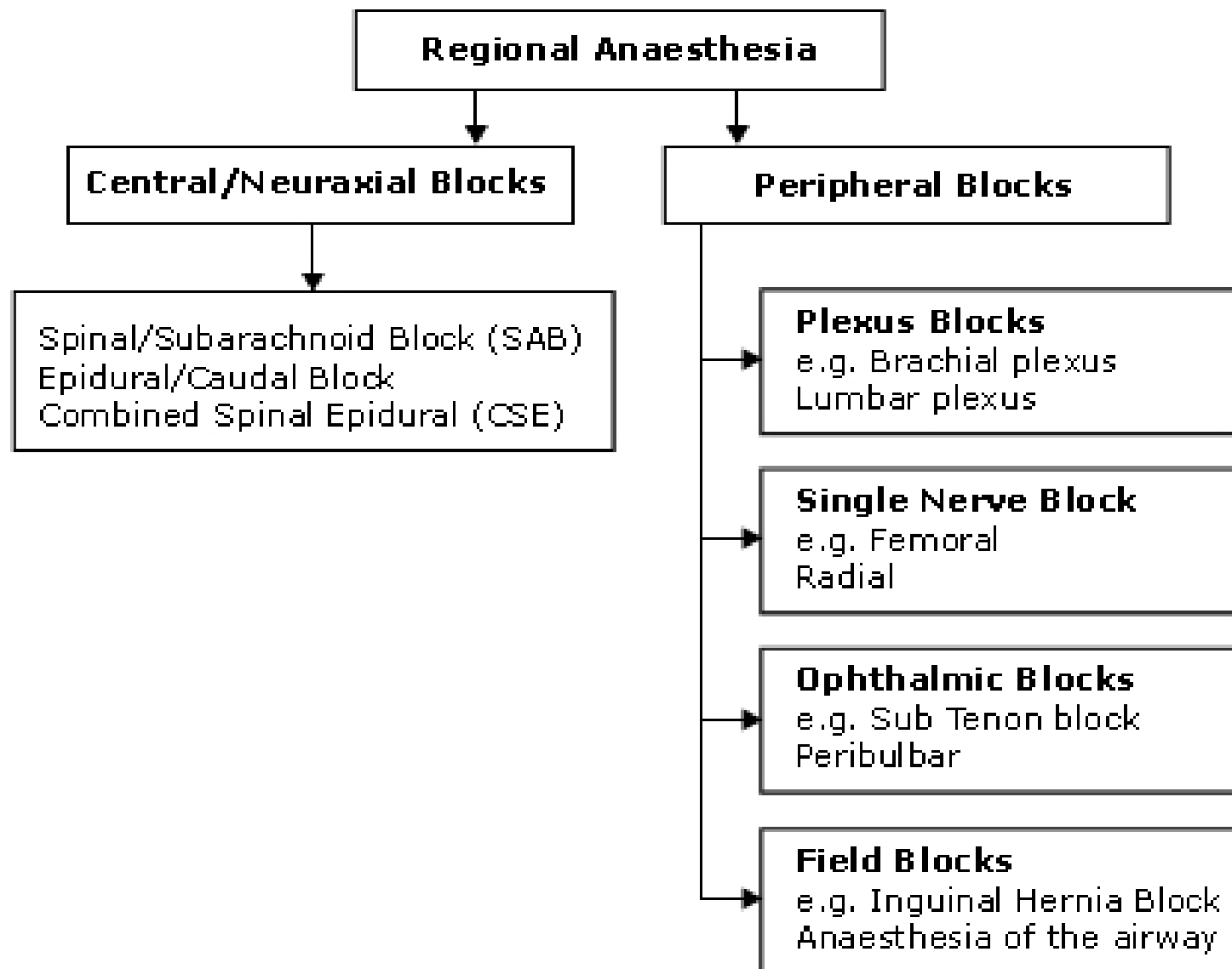


Most common regional anaesthesia

Caesarian section

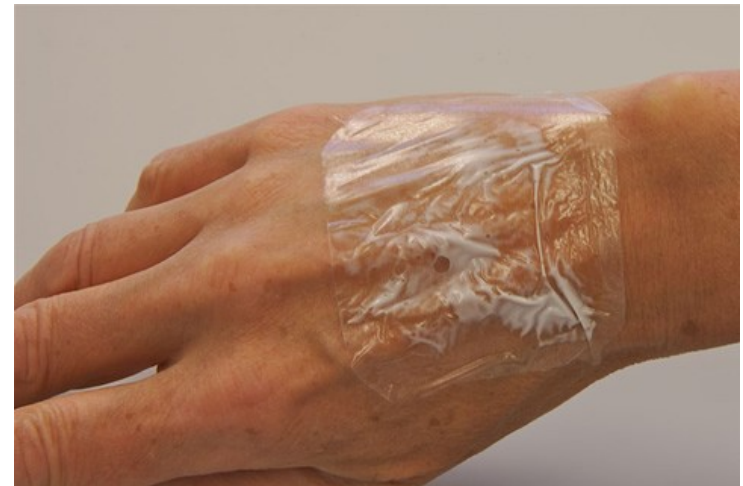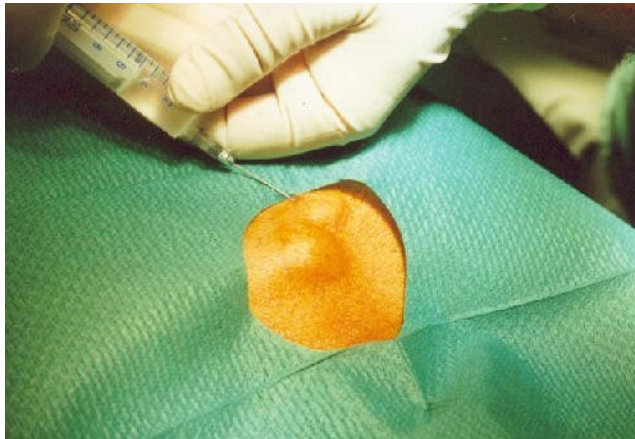
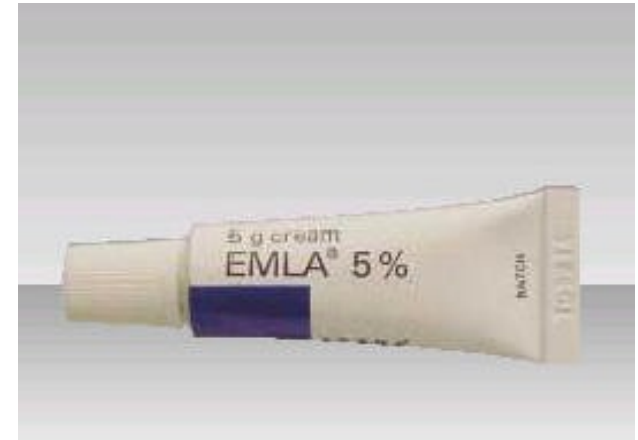
- Patient safety
 - Control of airway
- Patient satisfaction
 - Awake during the delivery of the child
 - Presence of partner
- Surgical outcome
 - Intraoperative bleeding is reduced
 - Reduced stress response





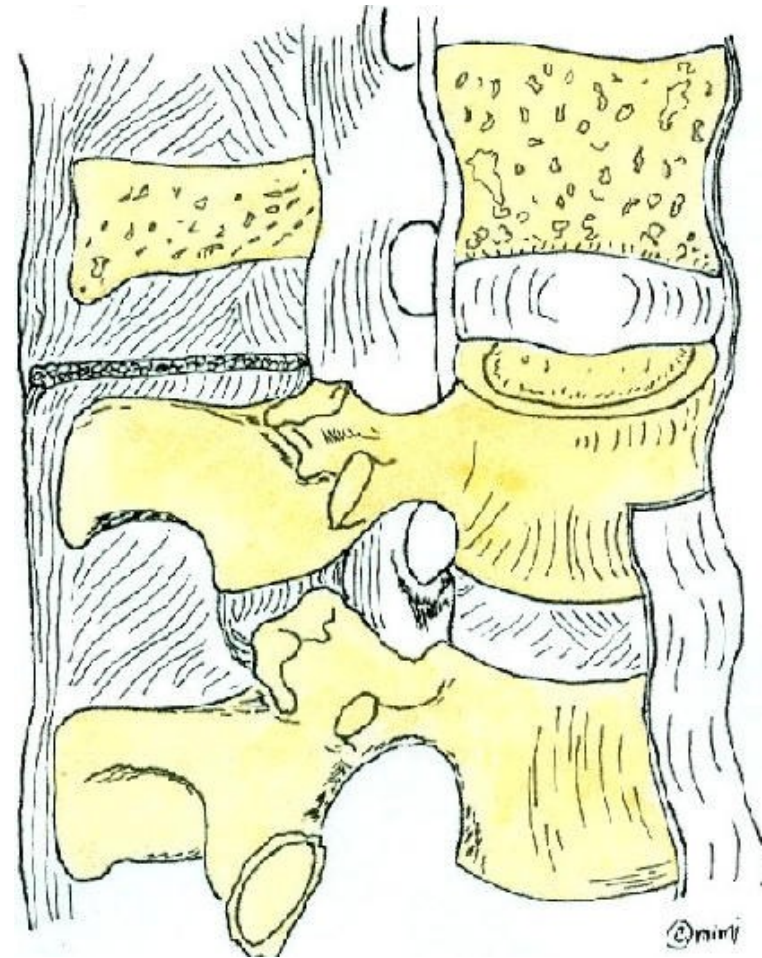
Local anaesthesia

- **Local anaesthesia**
 - Superficial (topic, mucosa)
 - Infiltration



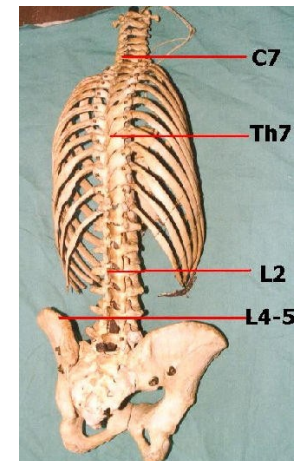
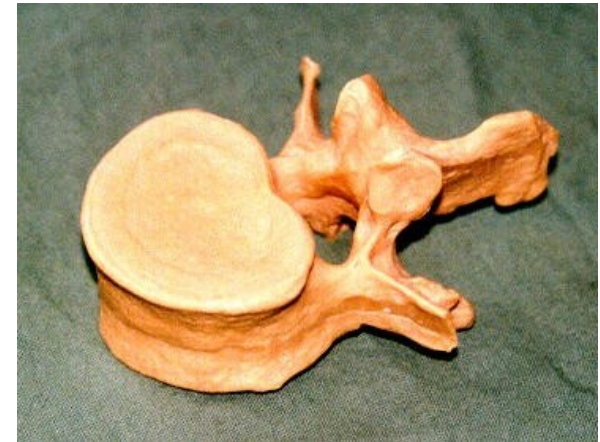Central neuroaxial block

- Epidural
- Subarachnoideal (spinal)

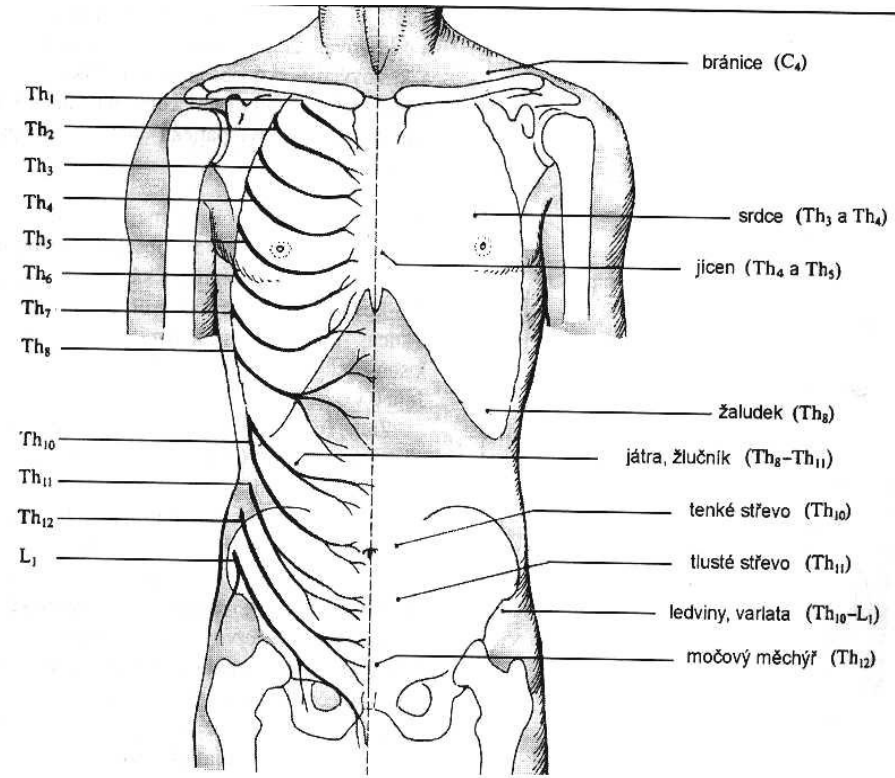
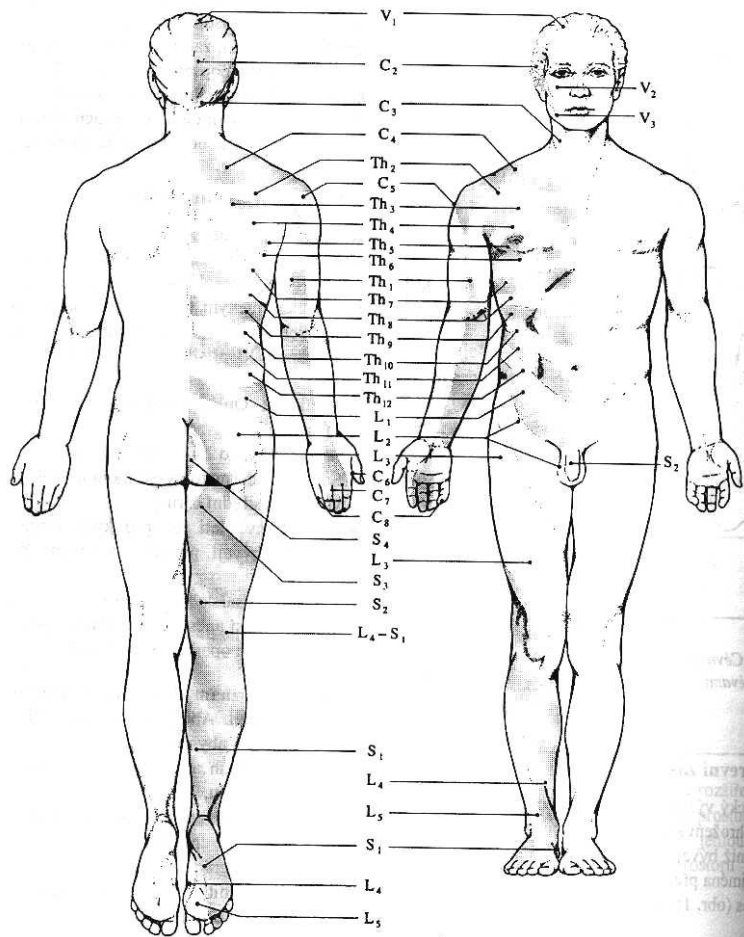


Anatomy of spinal cord

- 7 C, 12 Th, 5 L, 5 S a 4-5 Co
- spinal cord L1/2
- spinal cord cover
(pia mater, arachnoidea, dura mater)
- ligameta (ligg. supra- , interspinalia, lig. flavum)
- epidural a subarachnoid space



Skin dermatomas

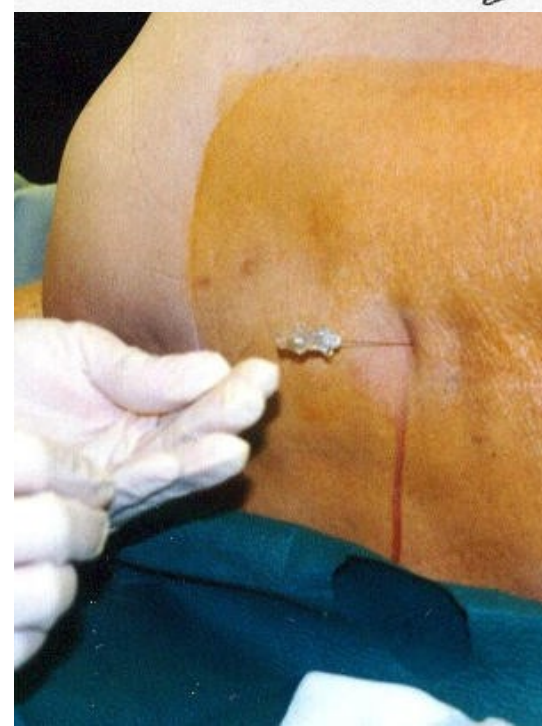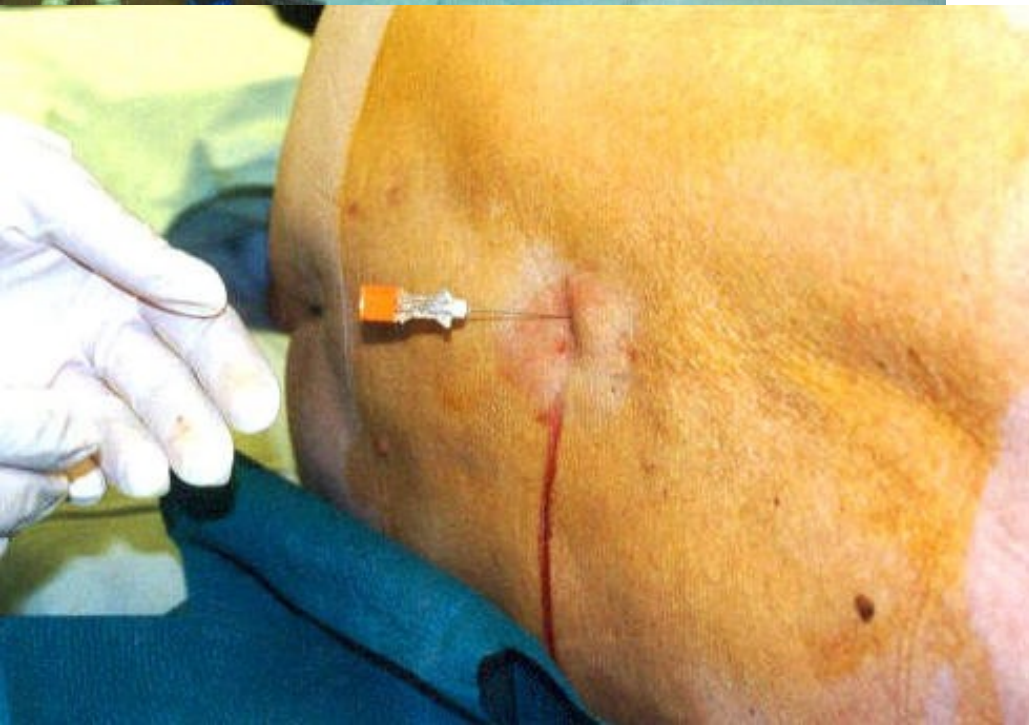
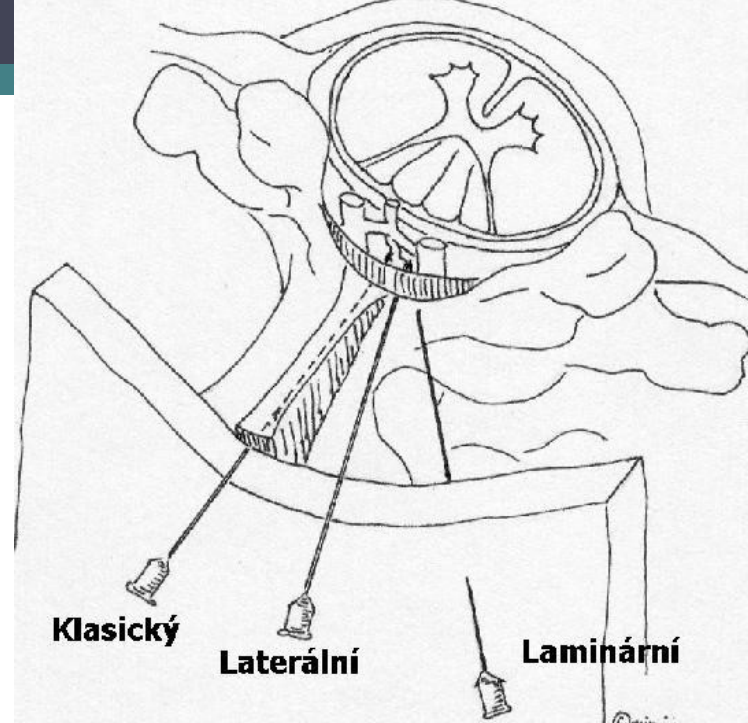

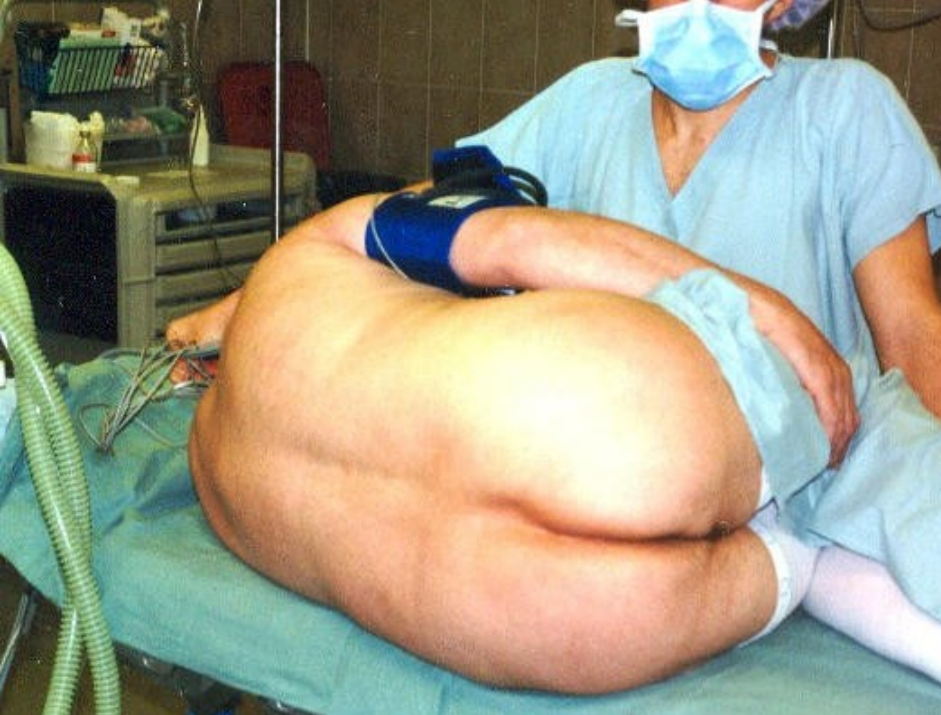
Central neuroaxial block

- Indication:
 - Surgery bellow umbilicus
 - Combined anaesthesia for abdom. surgery
 - Continual technic for postoperative pain relief
 - Labour analgesia and anaesthesia
- Contraindication
 - Patient's refusal
 - Local infection
 - Hypotension, hypovolemia, shock
 - Valve stenosis - fixed cardiac output
 - Coagulopathies (warfarin, heparin)

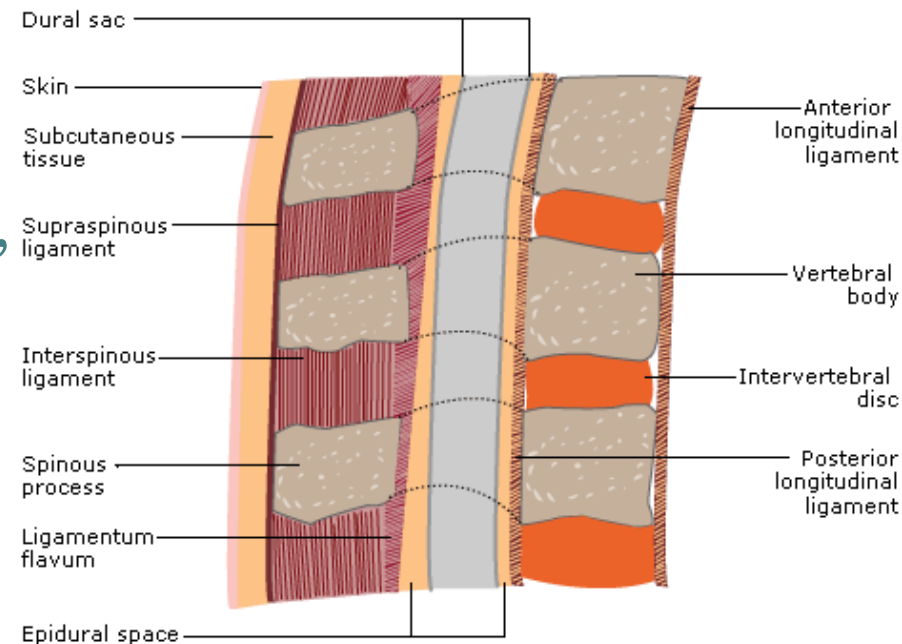
Systemic effect of central blockade

- Cardiovascular system
 - Sympathetic block
 - Hypotension
 - Reduced venous return
 - Relative hypovolemia
- Ventilation: small influence
- Urination: urinary retention



Epidural anaesthesia

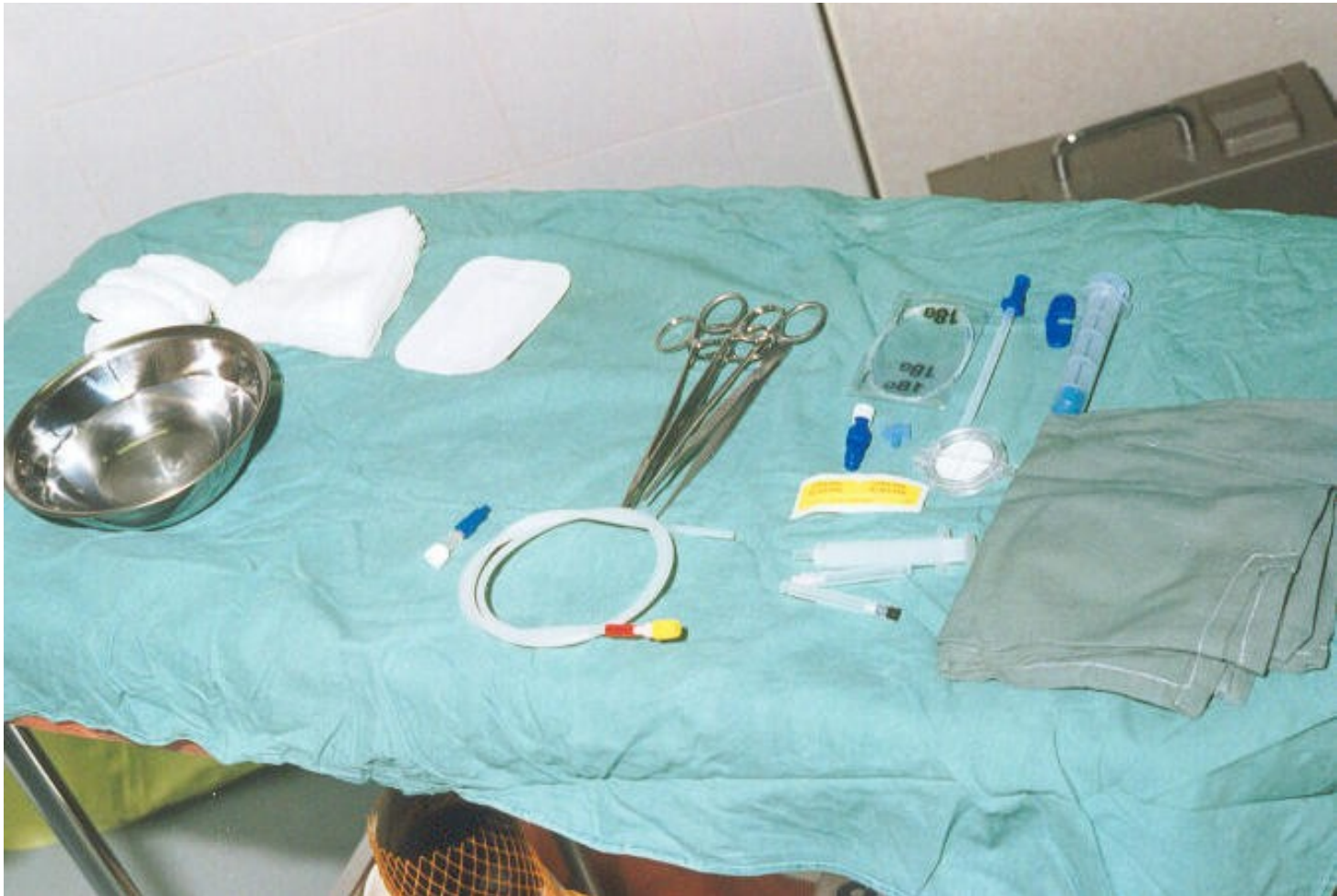- Epidural space
 - posterior border: lig. flavum vertebral arches
 - Content: fat connective tissue, lymphatic vessels, vessels for vertebra and spinal cord, **radices of spinal nerves, spinal cord, spinal covers**
 - thickness of epidural space >
 - lumbar: 5 - 6 mm
 - thoracic: 3 - 5 mm
 - cervical: about 3 mm



Epidural anaesthesia

- Spread of anaesthetics:
 - Both direction from the end of needle or catheter
- Dose: 2 ml per segment
- Density of block depends on the concentration of LA used

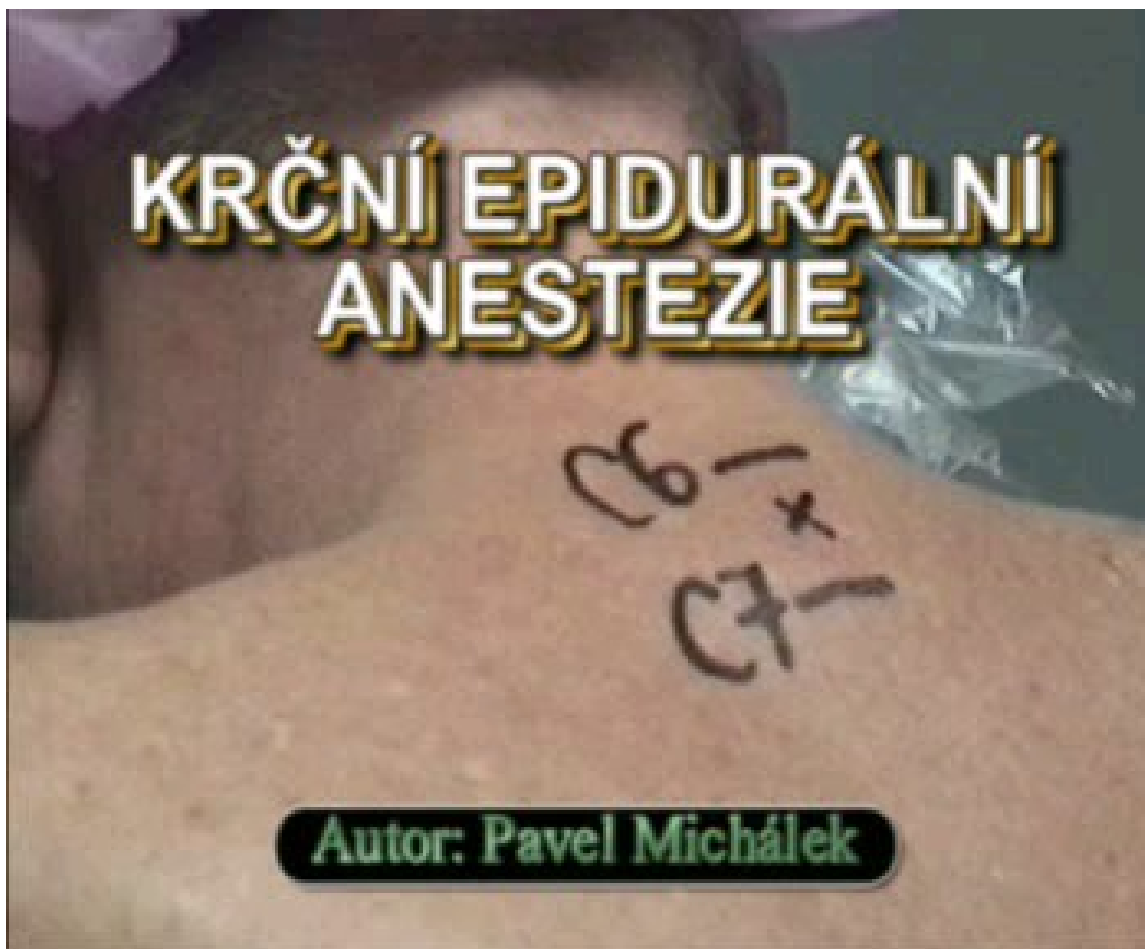Equipment



Lumbar epidural block



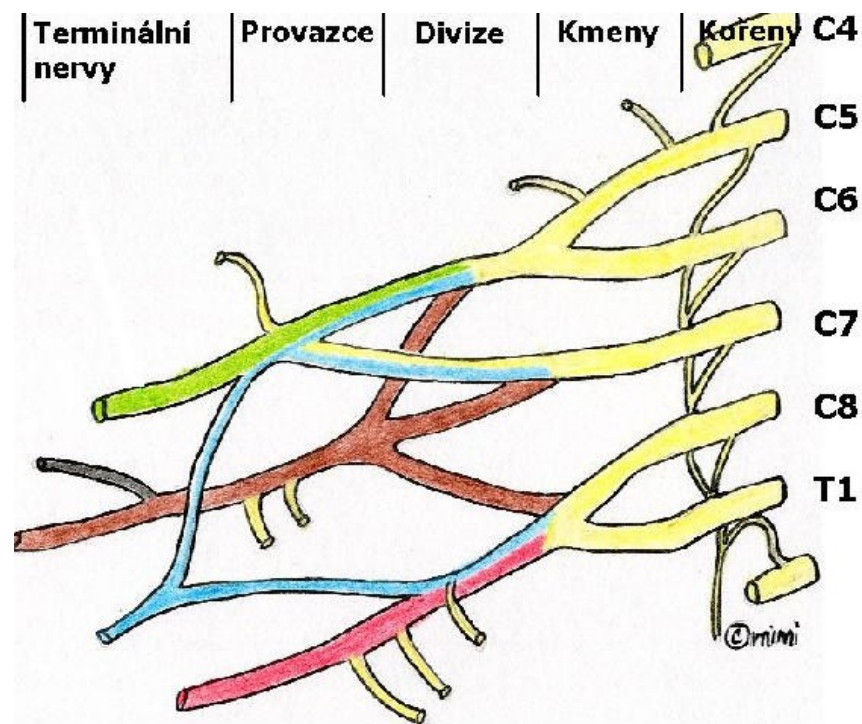
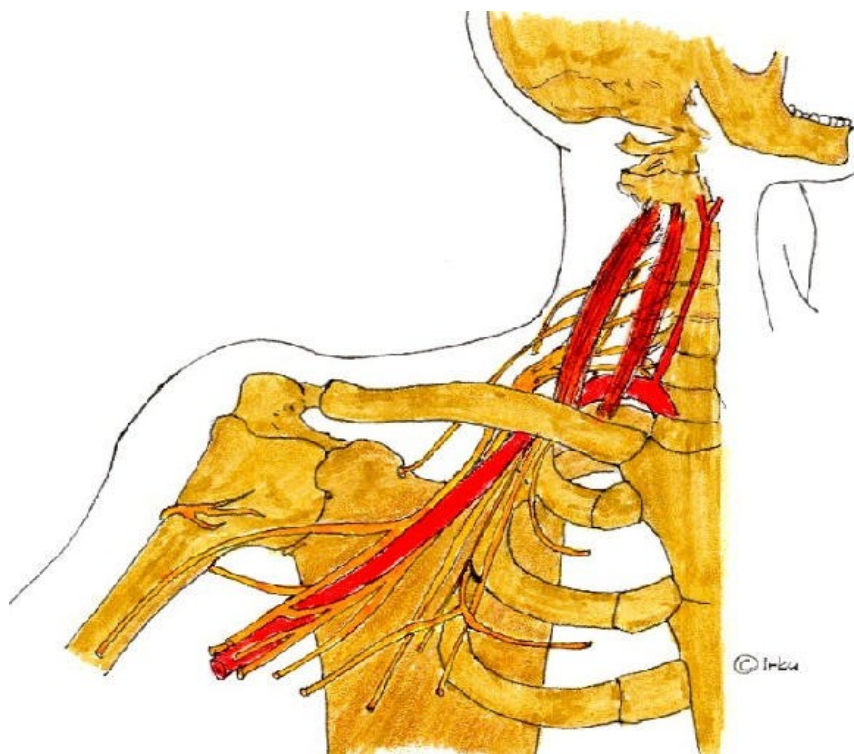
Cervical epidural



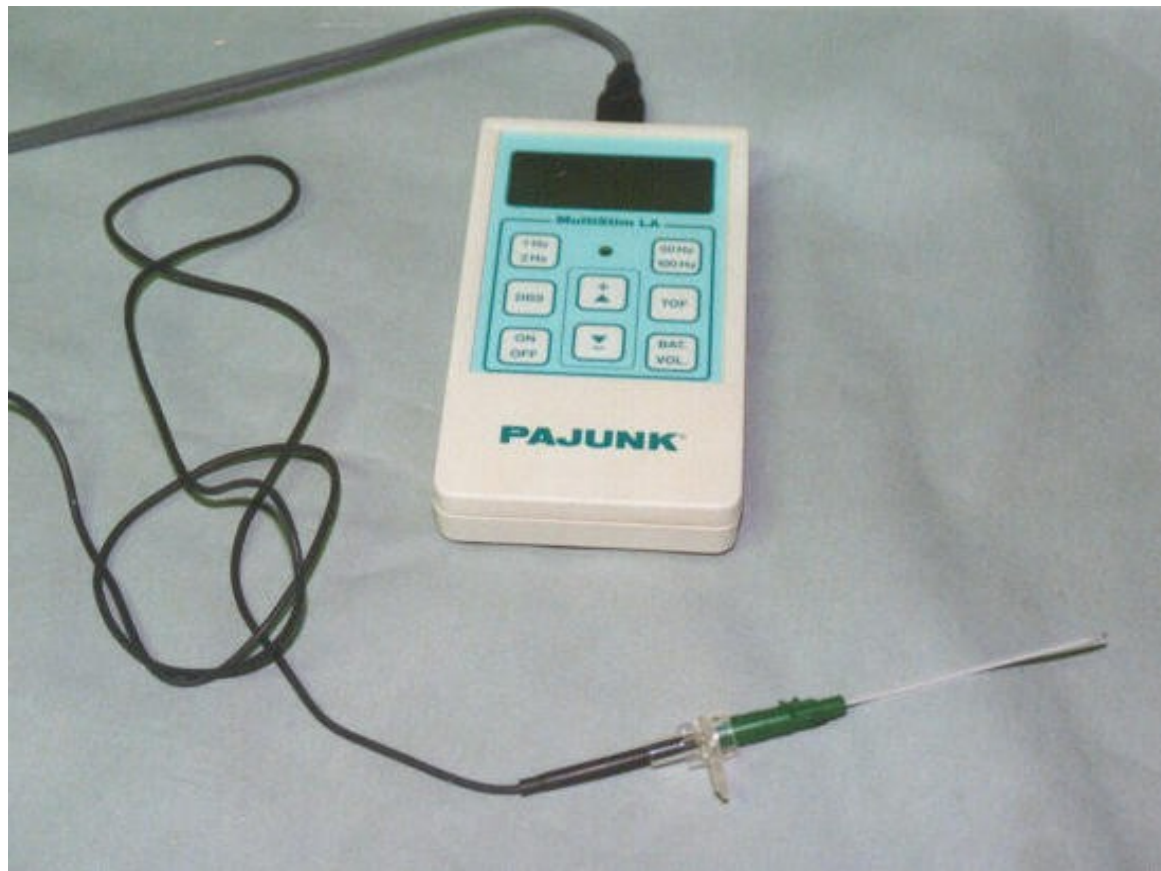
Peripheral blocks

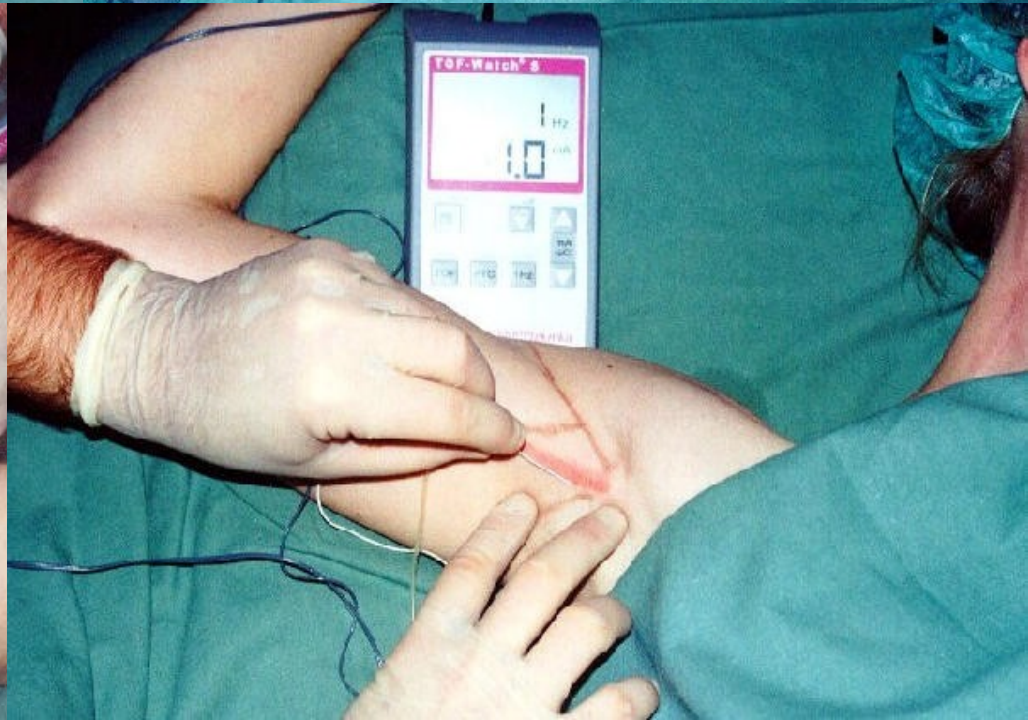
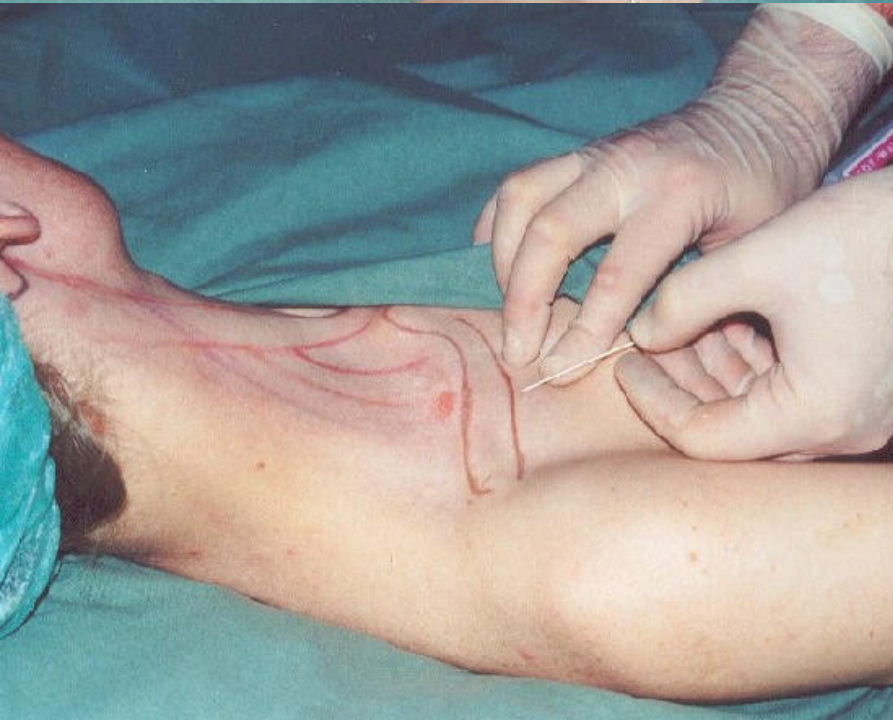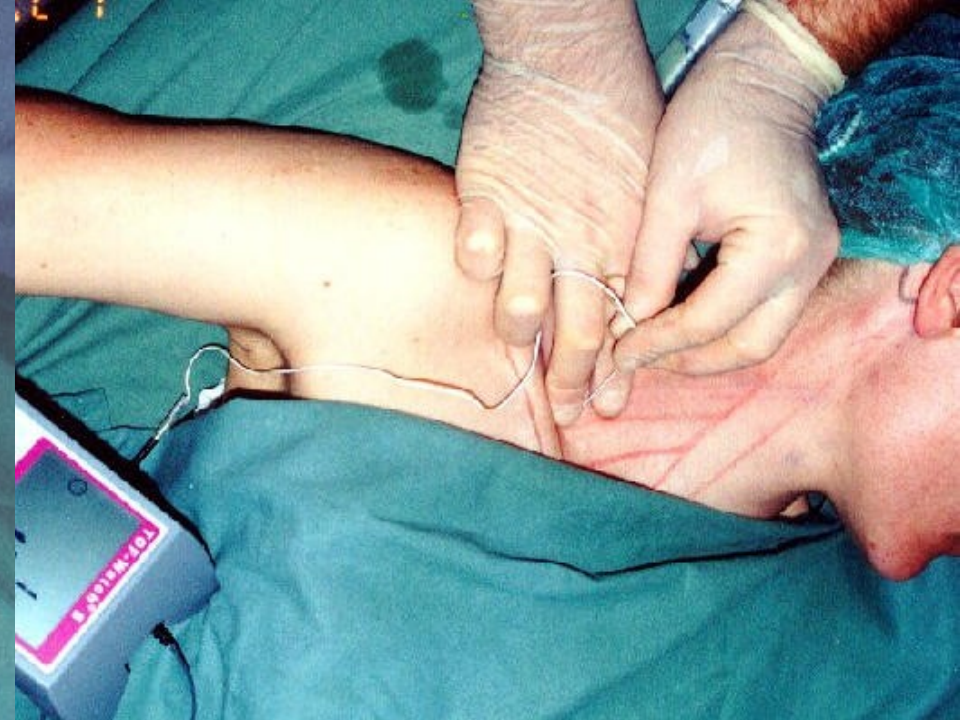
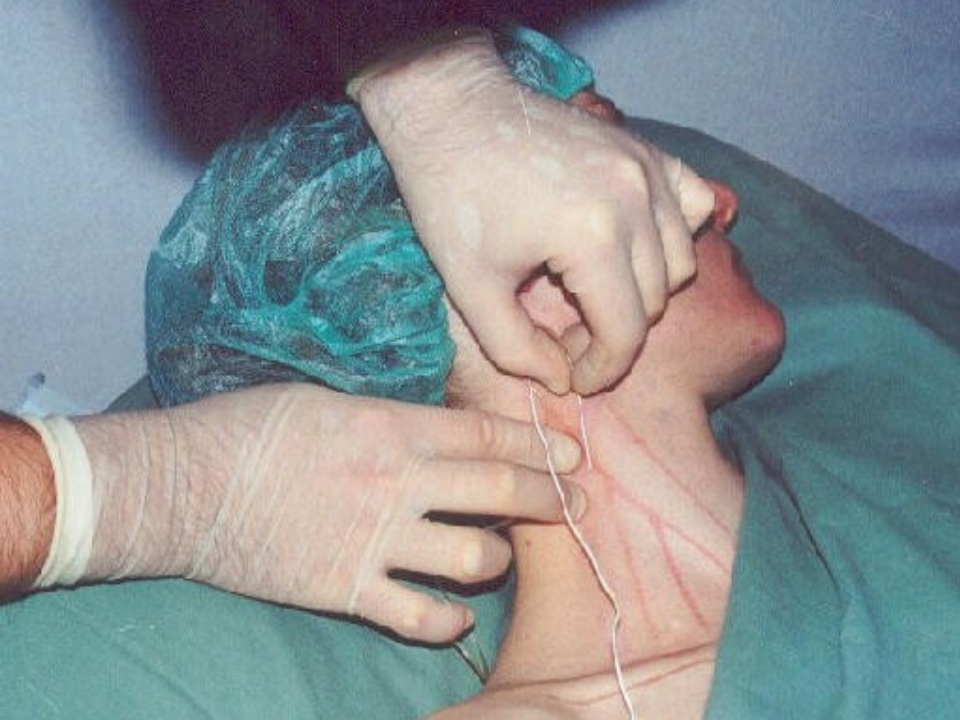- Single nerves
- Nerve plexuses

Plexus brachialis



Stimulator





Questions ?