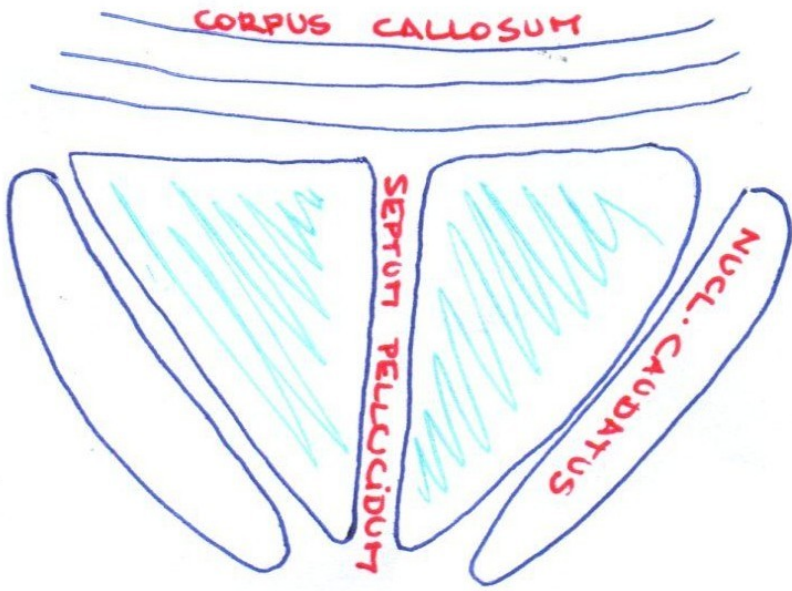
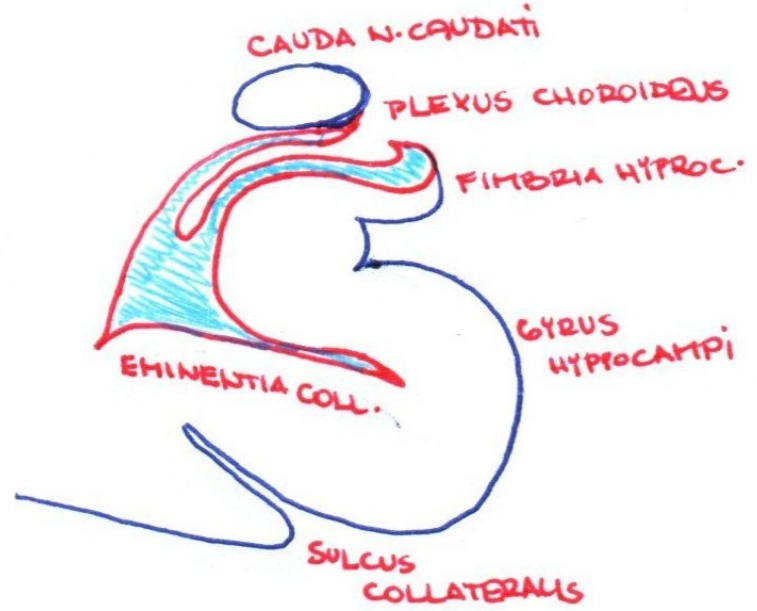


Schémata

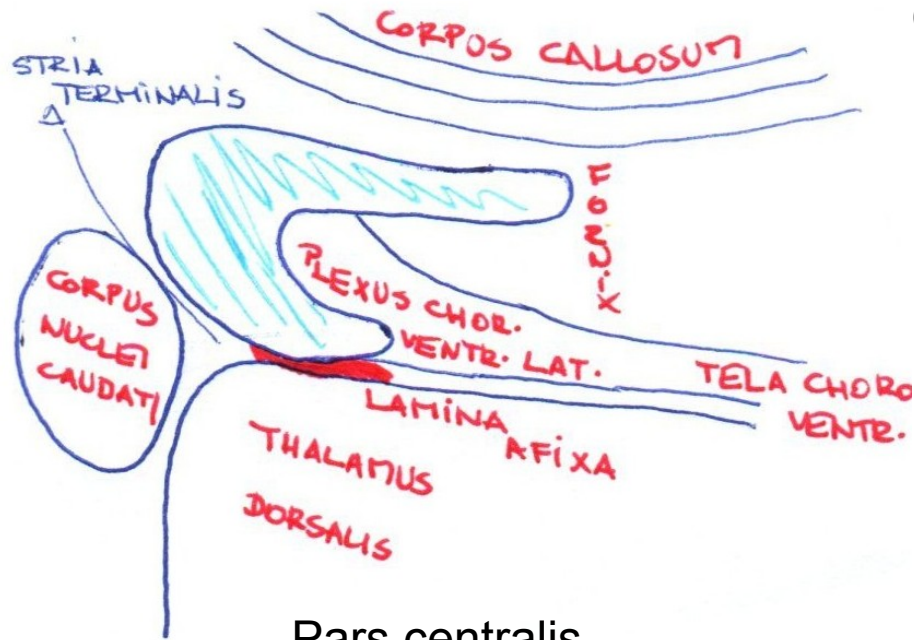
Ventriculus lateralis



Cornu frontale

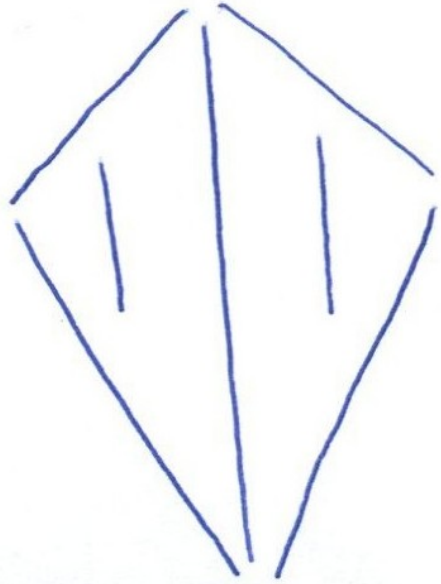


Cornu temporale

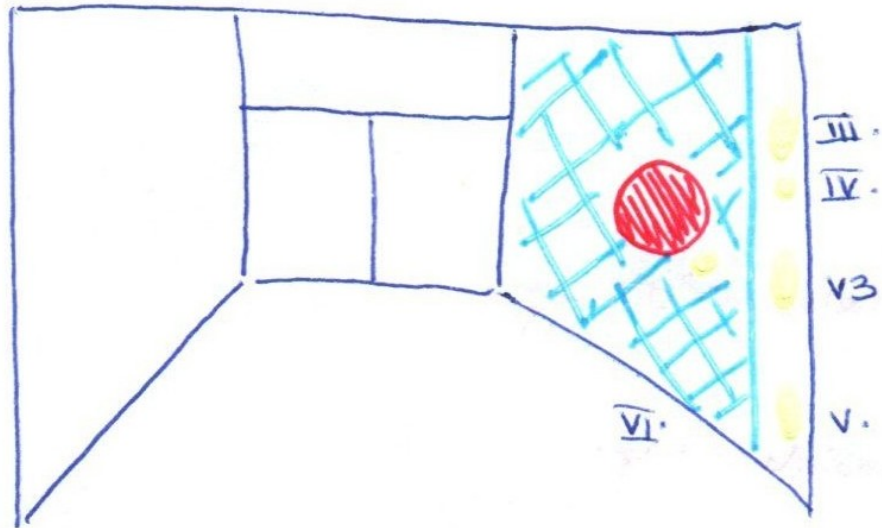
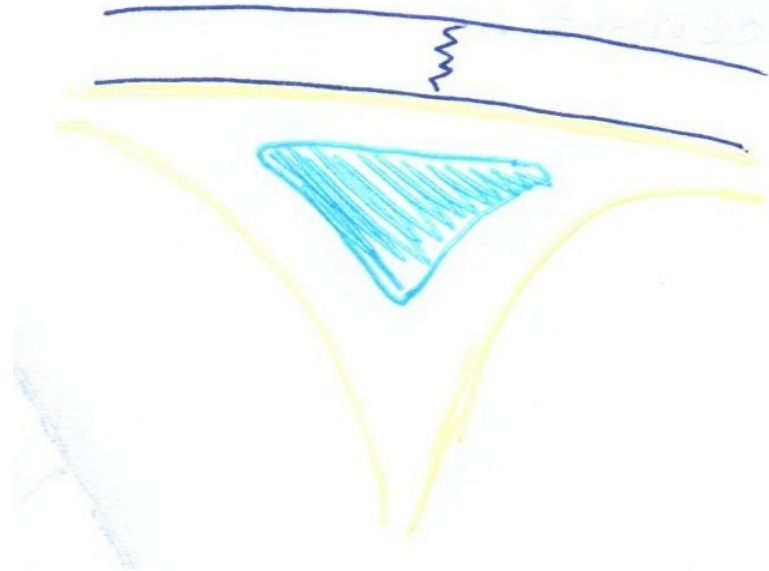

Pars centralis

Fossa rhomboidea

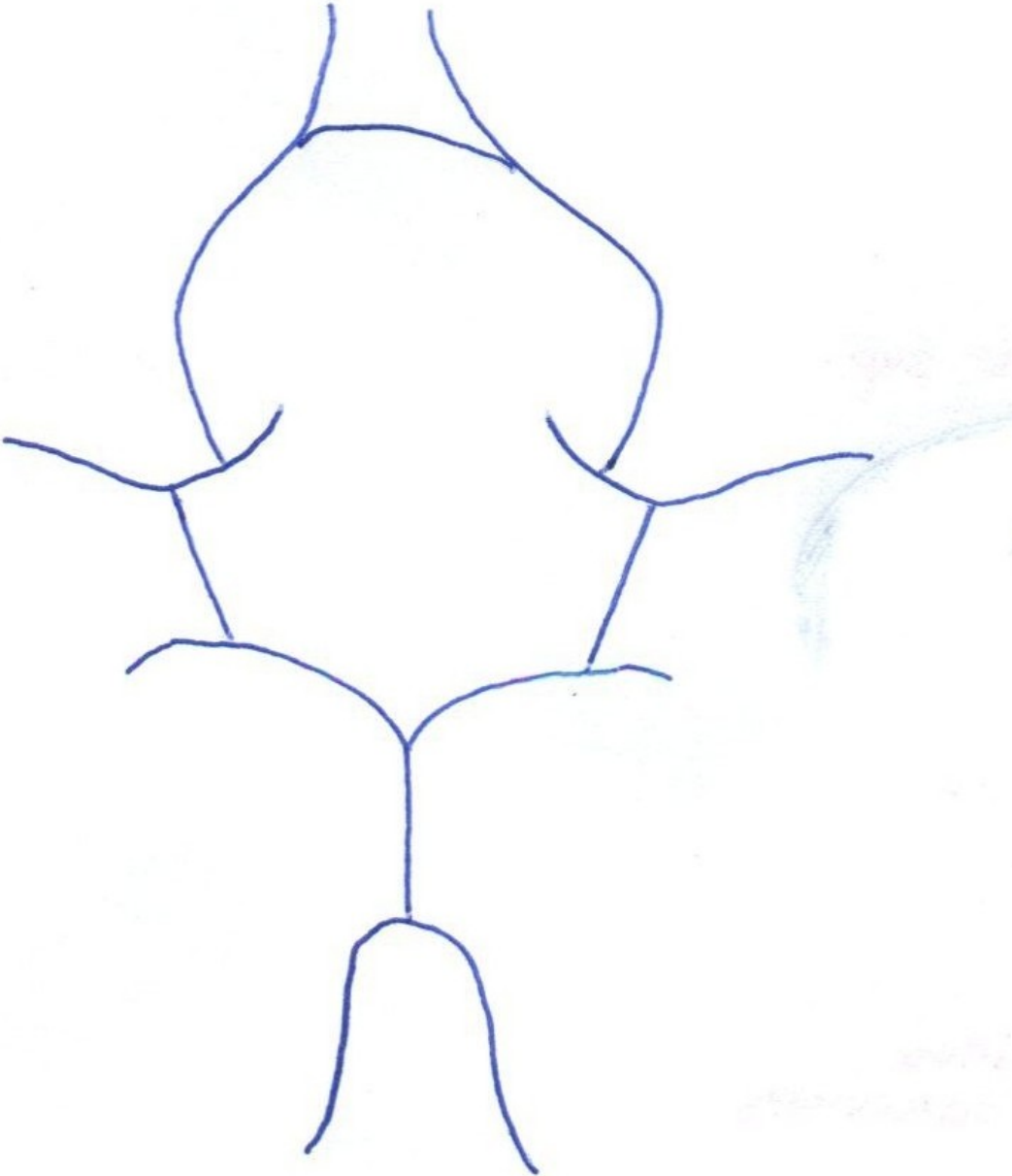


Sinus sagittalis superior

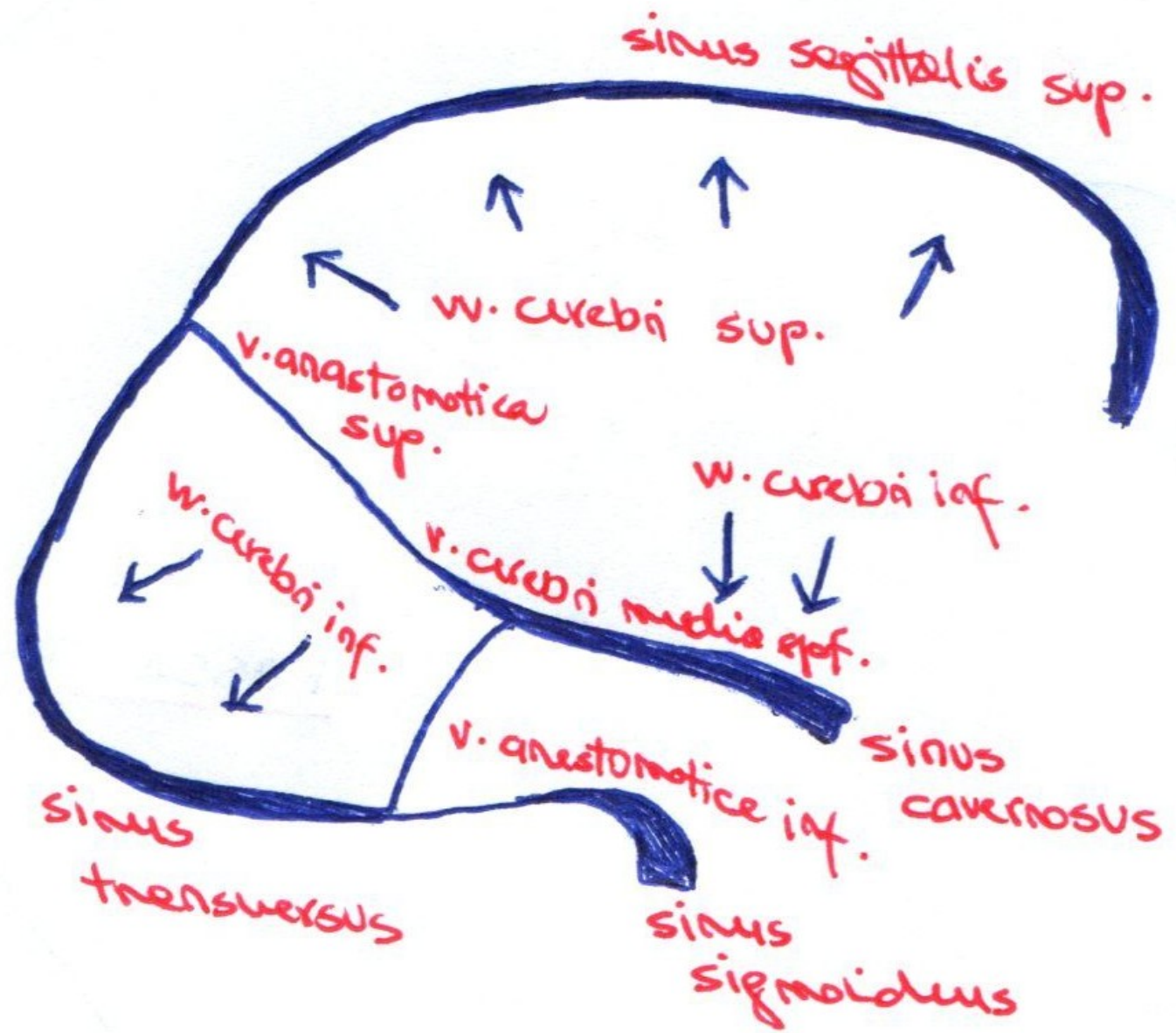


Sinus cavernosus

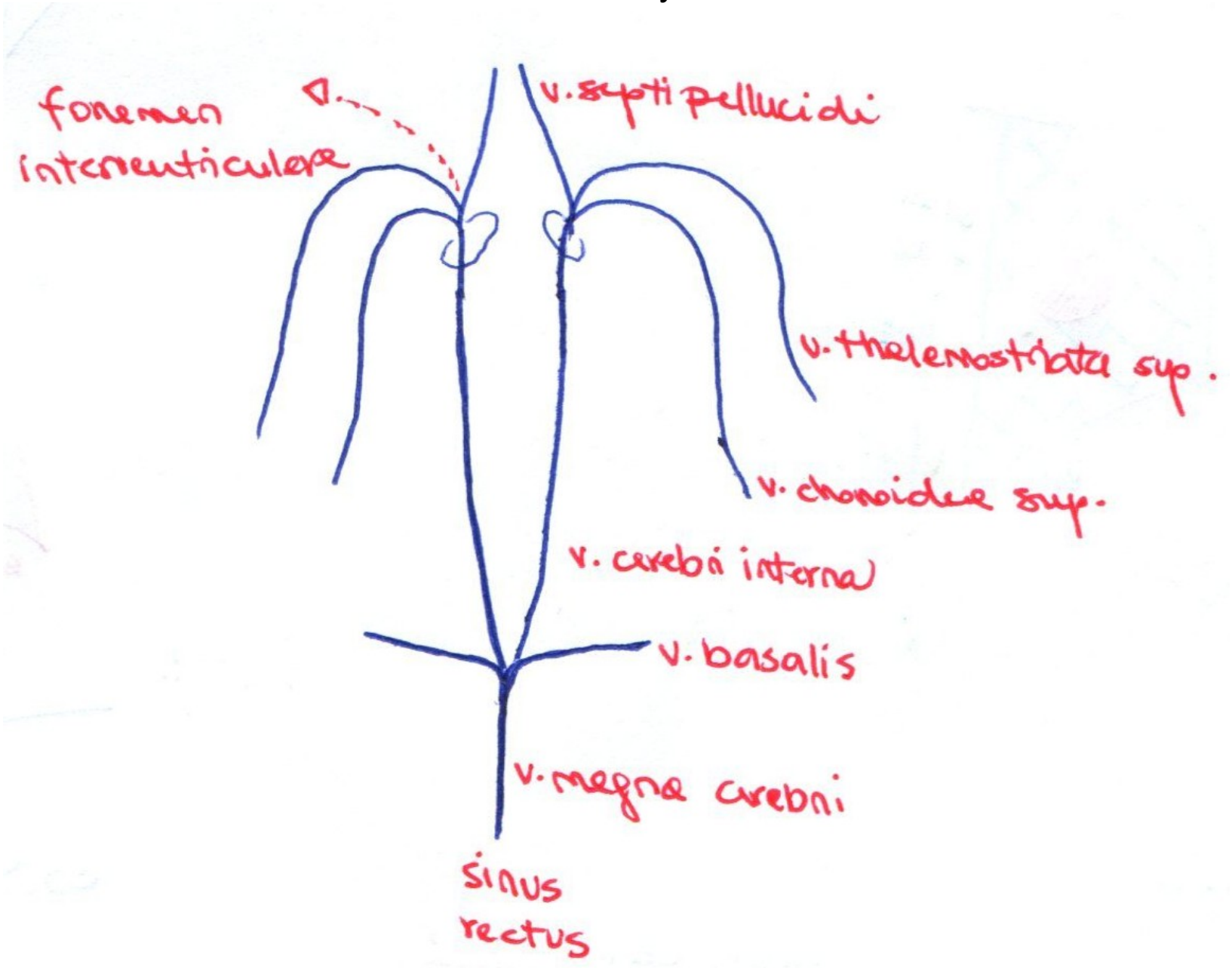
Circulus arteriosus Willisii



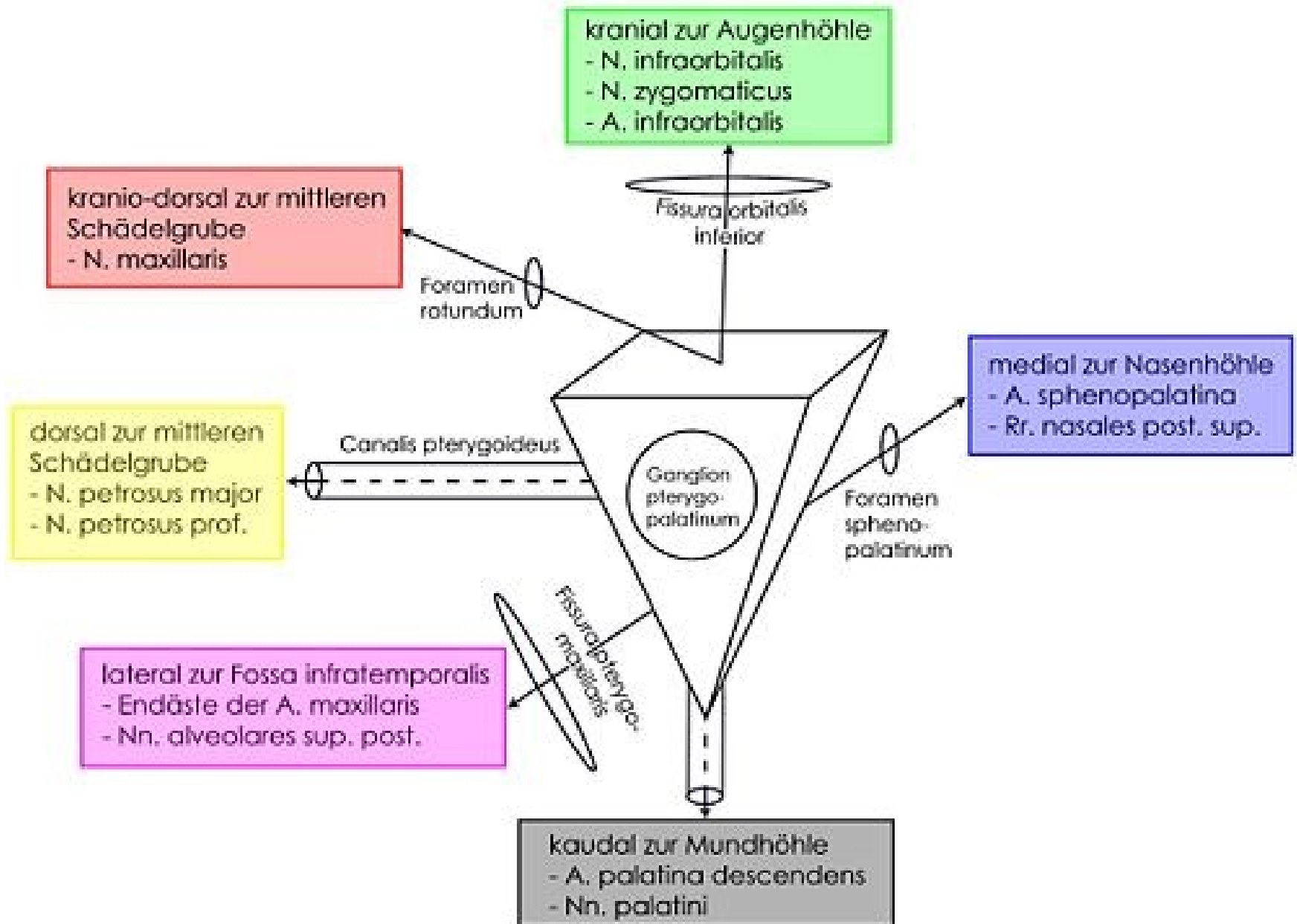
Povrchové žíly mozku



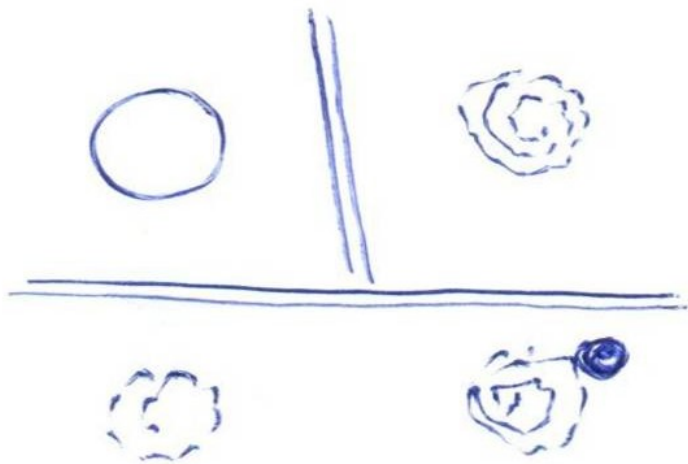
Hluboké žíly mozku



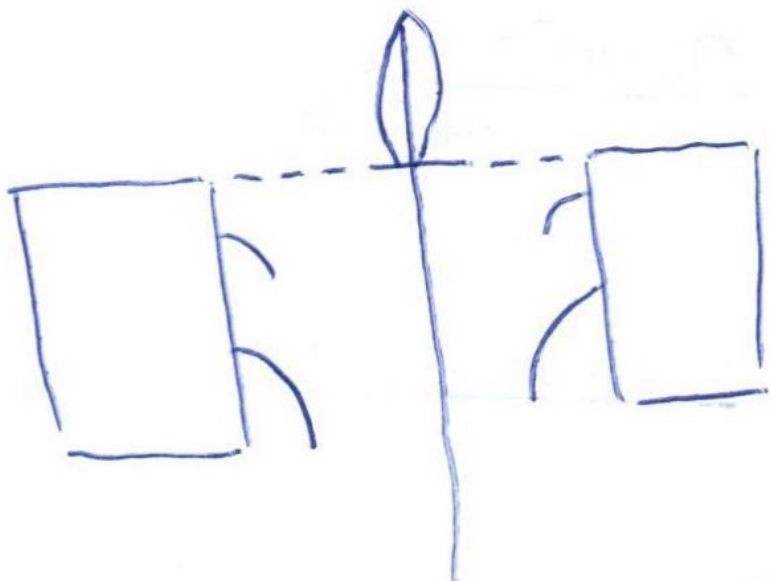
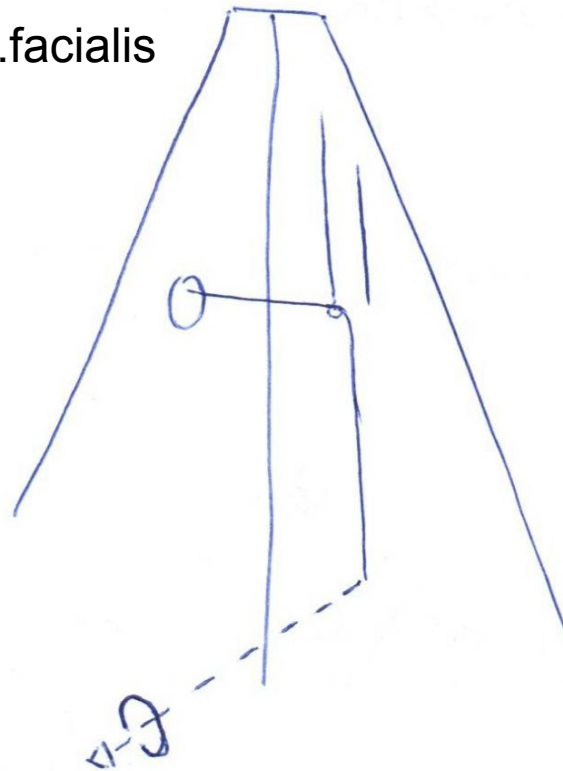
Fossa pterygopalatina



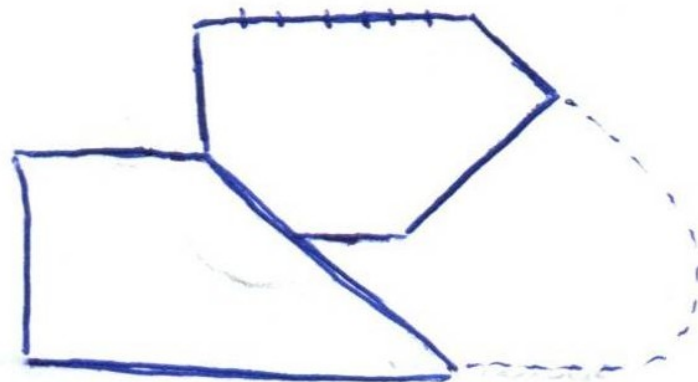
Fundus meatus acustici internus



Canalis n. facialis

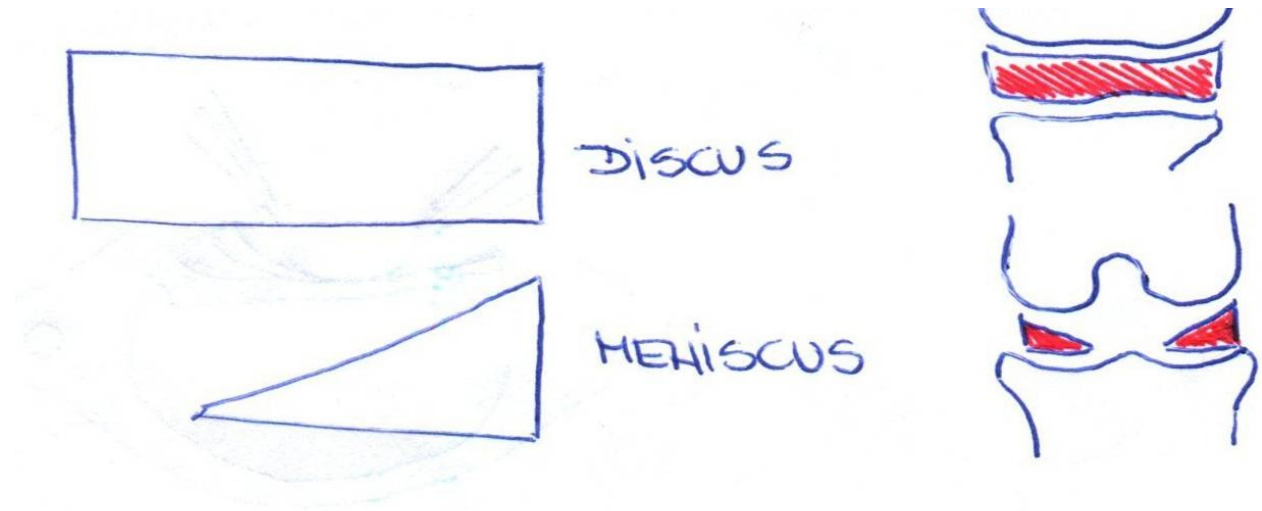


Os ethmoidale

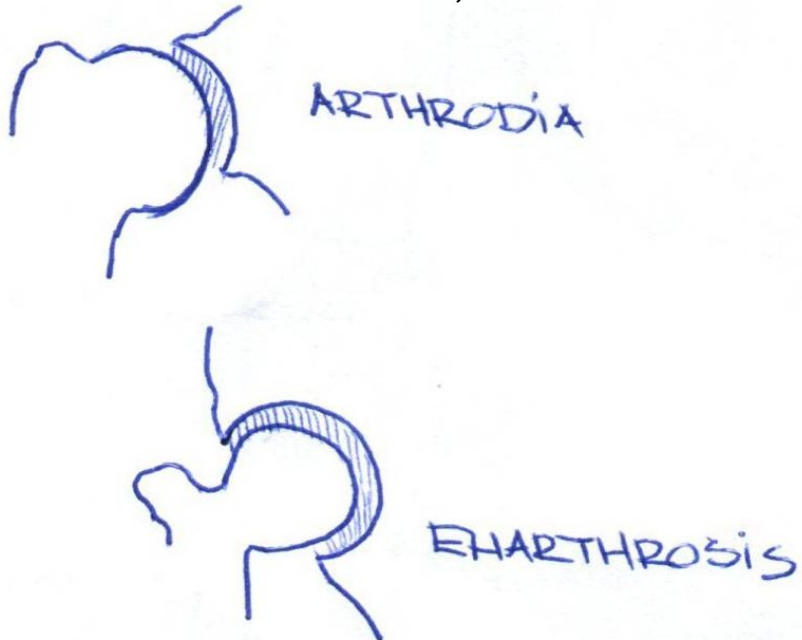


Septum nasi osseum

Rozdíl- discus, meniscus



Rozdíl- arthrodia, enarthrosis



Articulatio atlantoaxialis mediana