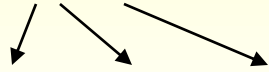


Spirochetes

Borrelia

Causative agents of Lyme borreliosis

B. burgdorferi sensu lato



B. burgdorferi sensu stricto, afzelii, garinii



Microscopy: eclipsed, soft spirales, el. microscopy

Cultivation: Barbour-Stoenner-Kelly medium

Antigens stimulating production of antibodies: **flagelin, Osp C** (stimulates early response)
p18, 39, 100 (stimulates later response), others (Osp A, B)

Pathogenicity: 3 stages:

I. early localised - 3-30 days after suckling of a tick occur erythema (5 cm high), erythema migrans – occurs other lesions on the body, headache, joints

II. early disseminate – borrelia lymphocytoma (skin lesion), neurological + cardiac expresses

III. later – acrodermatitis chronica atrophicans (skin lesion), arthritis, carditis, polyneuritis

Epidemiology: transport due to ticks (*Ixodes ricinus*)

Diagnostic: direct: cultivation, PCR, ELM, shadow microscopy

Indirect: ELISA screening, in case of positivity WB confirmation

3-4 weeks after beginning of disease occurs IgM (antibodies against **flagelin, Osp C**)

In 4-6 weeks occurs IgG (against antigens **p18, 39, 100**)

Therapy: PNC, doxycyclin, ceftriaxon

Drawback fevers

B. recurrentis

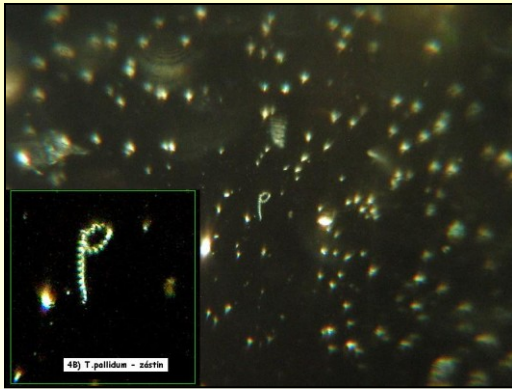

Pathogenicity: repeated fevers

Epidemiology: transfer – body louse

Diagnostic: direct: shadow microscopy, indirect: agglutination

Therapy: doxycyclin



Treponemas

T. pallidum (lues, syphilis)



Microscopy: eclipsed, spirales

Cultivation: not cultivable on medias, only on rabbit

Pathogenicity: stages - **early**

primary – ulcus durum, ulceration on genitals, heal itself, antibodies - 4 weeks later

secondary – fever, condylomata lata, heal itself, serology +


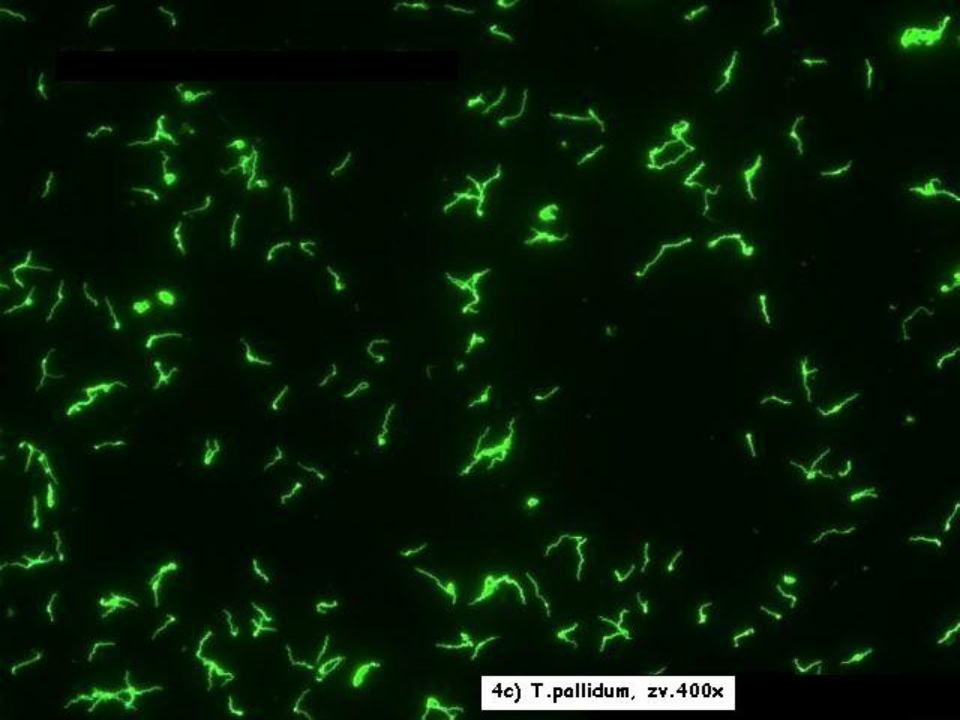
early latent – asymptomatic, about the year after secondary lues

later - later latent priod (various length)

tertiary – gummata (on skin, bones), neurosyphilis (progressive paralysis, brain atrophy), cardiovascular syphilis (aneurysma)

Congenital: early congenital lues - hepatosplenomegaly, periostitis

latence, later congenit. stage (after 2 years length) - malformation, deafness, saddle-back nose, barrel incisors, + often abortion



Diagnostic: direct: shadow microscopy, PCR, rabbit, immunofluorescence, silver staining

indirect: screening - 2 reactions: **RRR** and **TPHA**, in case of positivity confirmation via **FTA-ABS**, **ELISA** and **WB** (IgM + IgG), **TPIT** (Treponema Pallidum Immobilisation Test) - obsolent

RRR - antigen is a cardiolipin, not treponema, must be completed **TPHA**

Therapy and epidemiology: transport - sex. contact, prevention – screening in pregnancy, screening of blood-donors, safe sex, PNC, macrolides, doxycyclin

Leptospira

L. icterohaemorrhagiae, grippotyphosa, sejroe

Microscopy: spirales curved on both ends

Cultivation: long, special medias

Pathogenicity: 2 forms:

icteric – bleeding, icterus, renal insufficiency – **Weil's disease** (*L. icterohaemorrhagiae*)

anicteric – **field fever** (*L. grippotyphosa*)

Epidemiologie: contact with animals (pigs, horses, crowfoots, rodents
– rats, !on fields, channels)

Therapy: PNC, doxycyclin

Diagnostic: *direct:* microscopy, cultivation

indirect: MAT (microscopic agglutination test),
specialised laboratories

