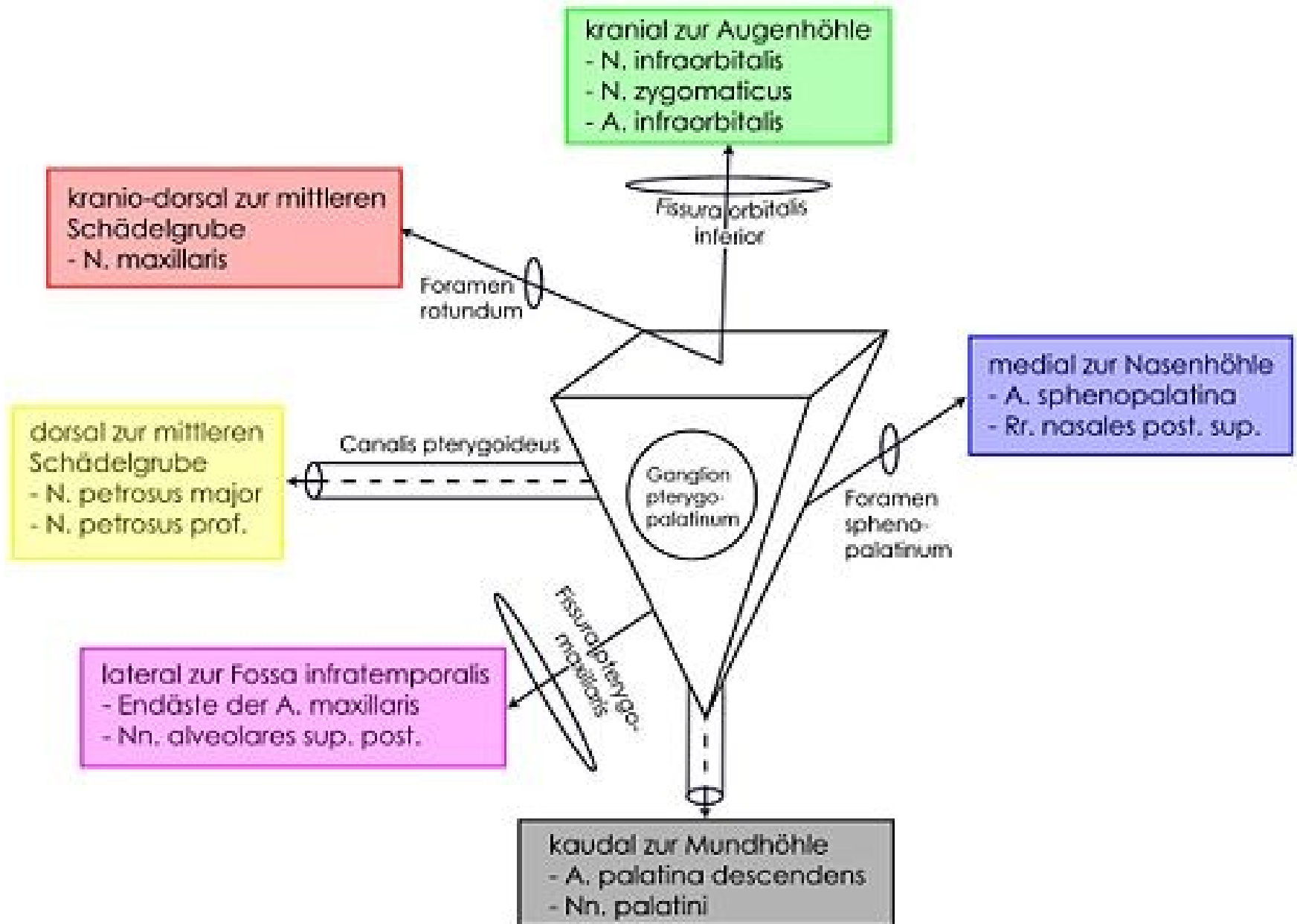


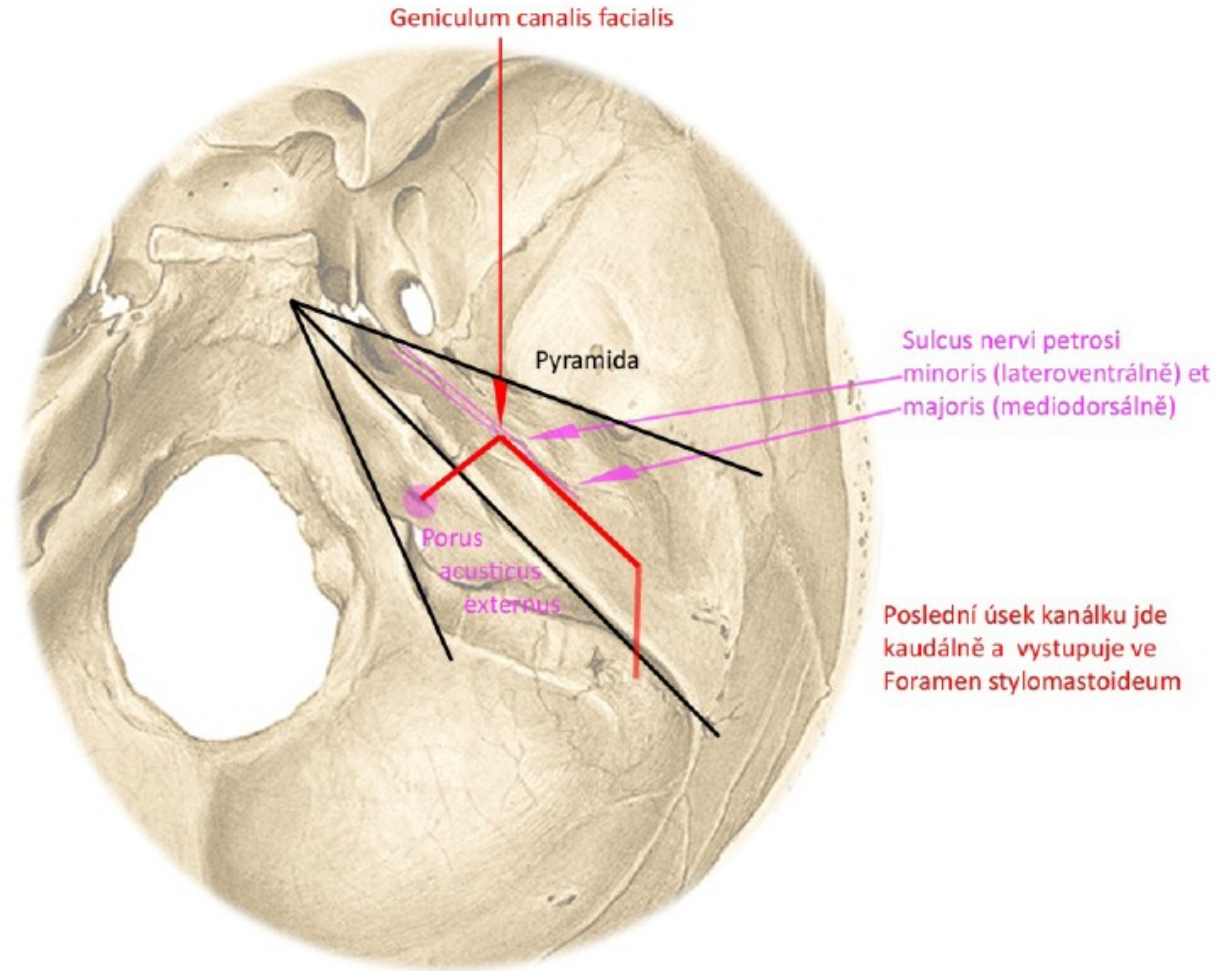
SCHÉMATA 1. SEMESTR

Fossa pterygopalatina

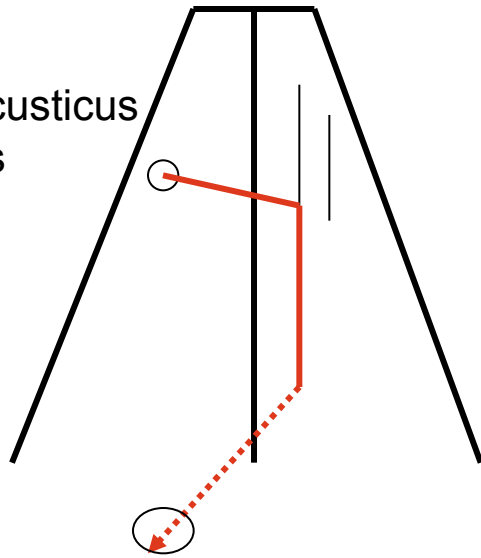


PRŮBĚH CANALIS NERVI FACIALIS V PYRAMIDĚ

Pohled shora

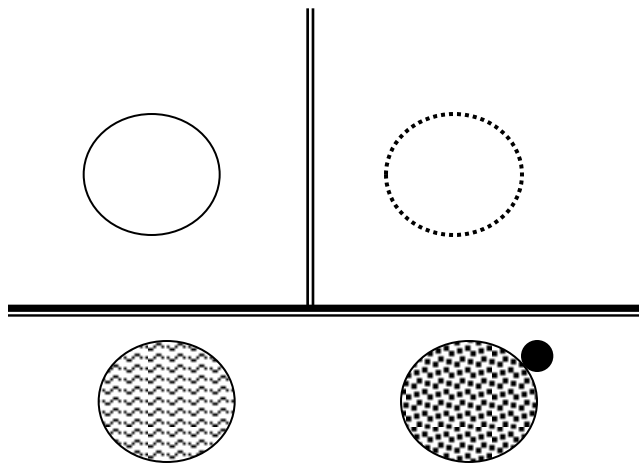
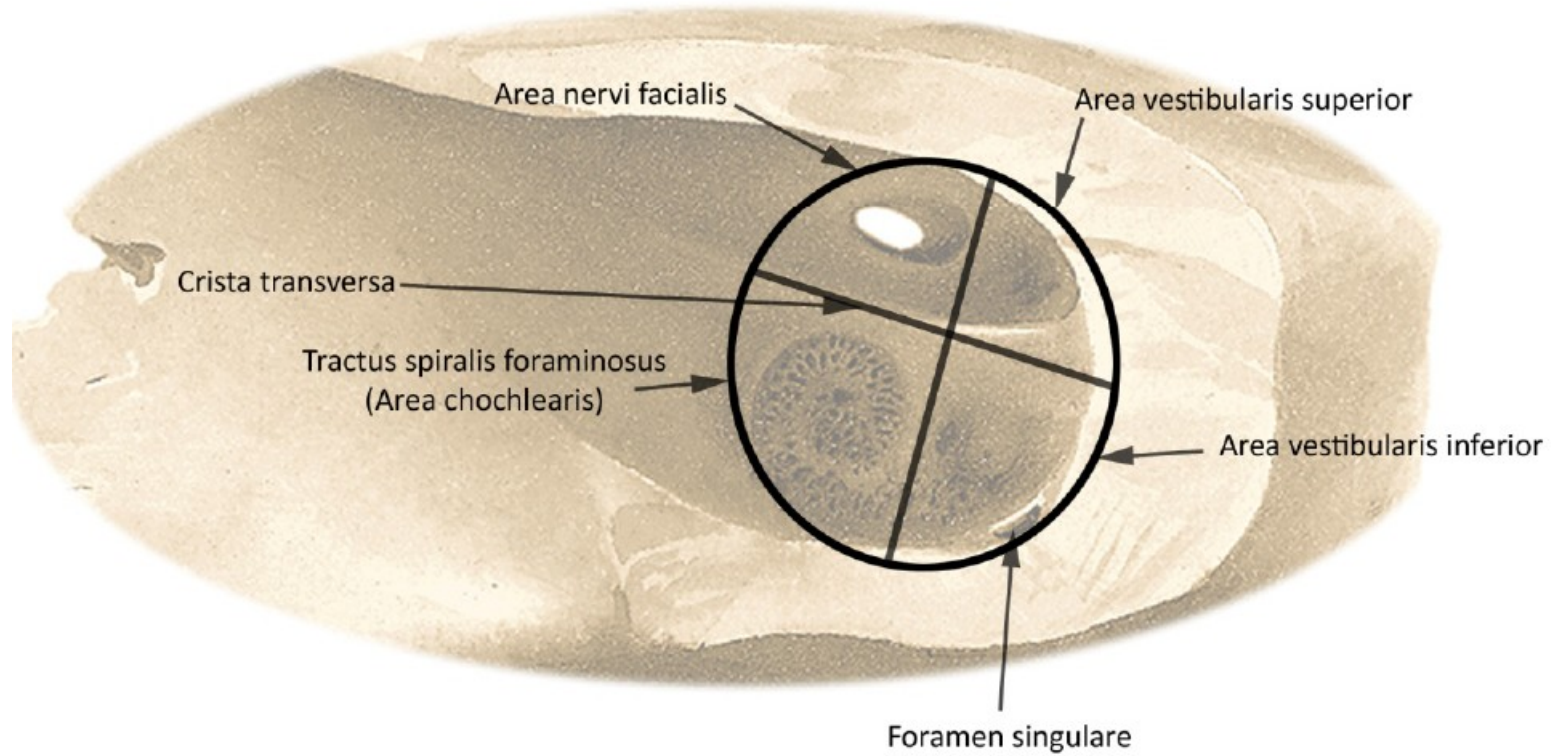


porus acusticus internus

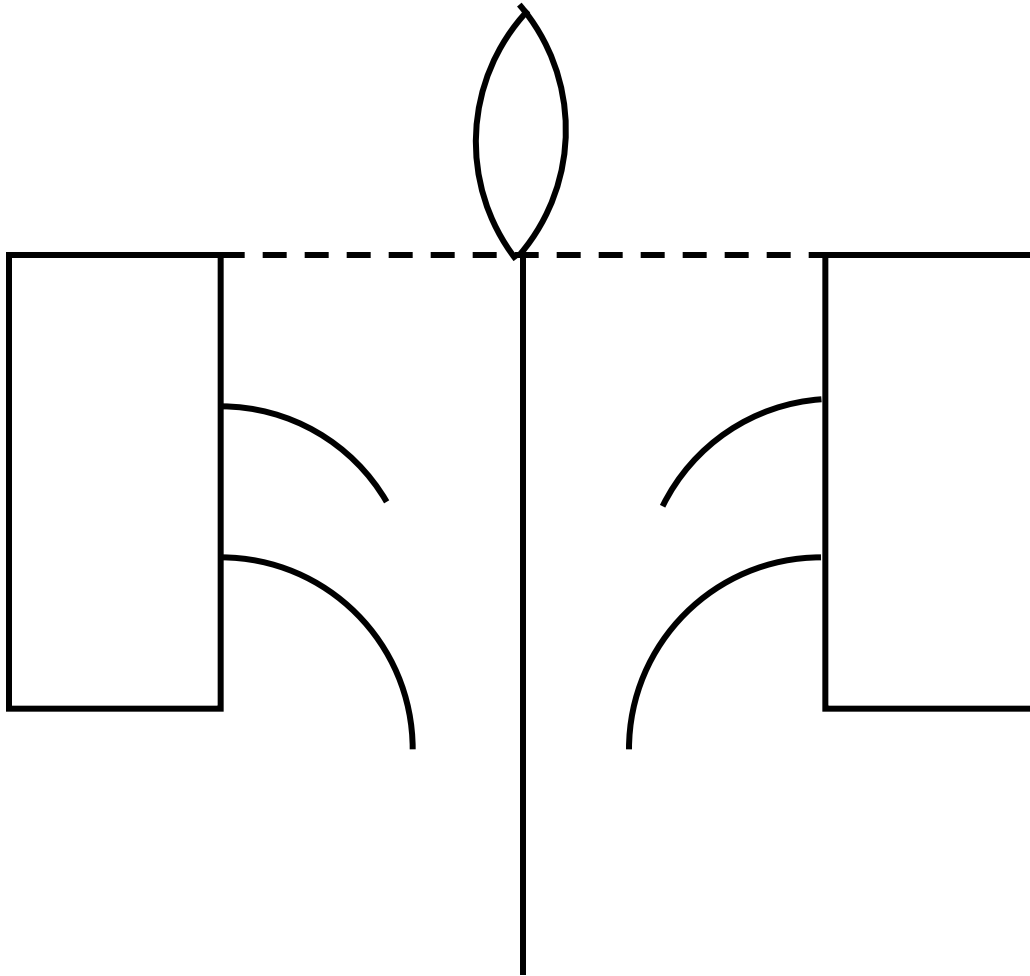


foramen stylomastoideum

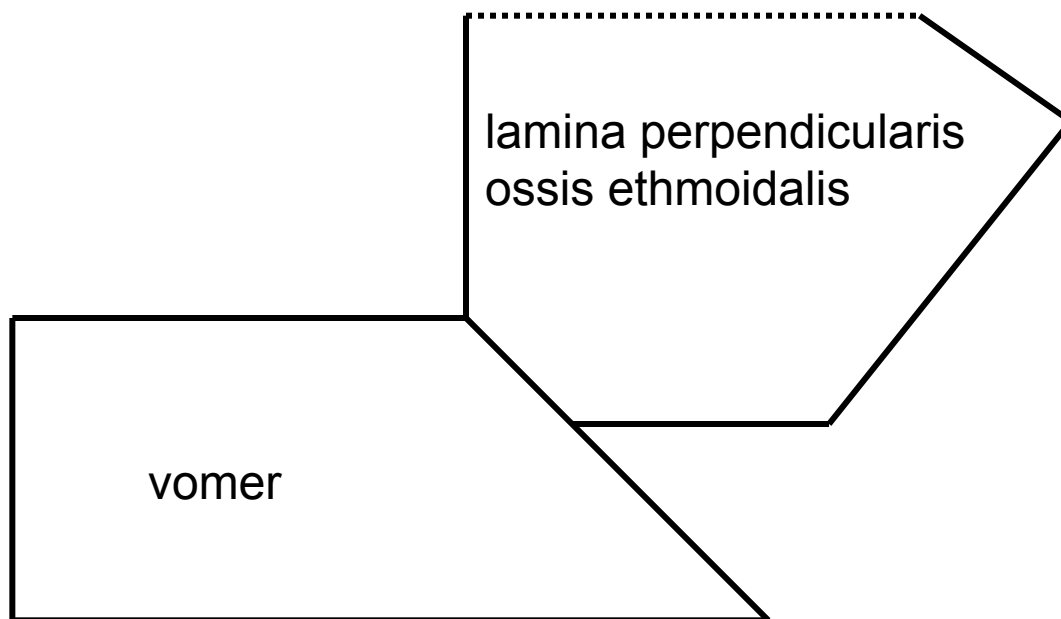
ROZDĚLENÍ FUNDUS MEATUS ACUSTICUS INTERNUS



Os ethmoidale



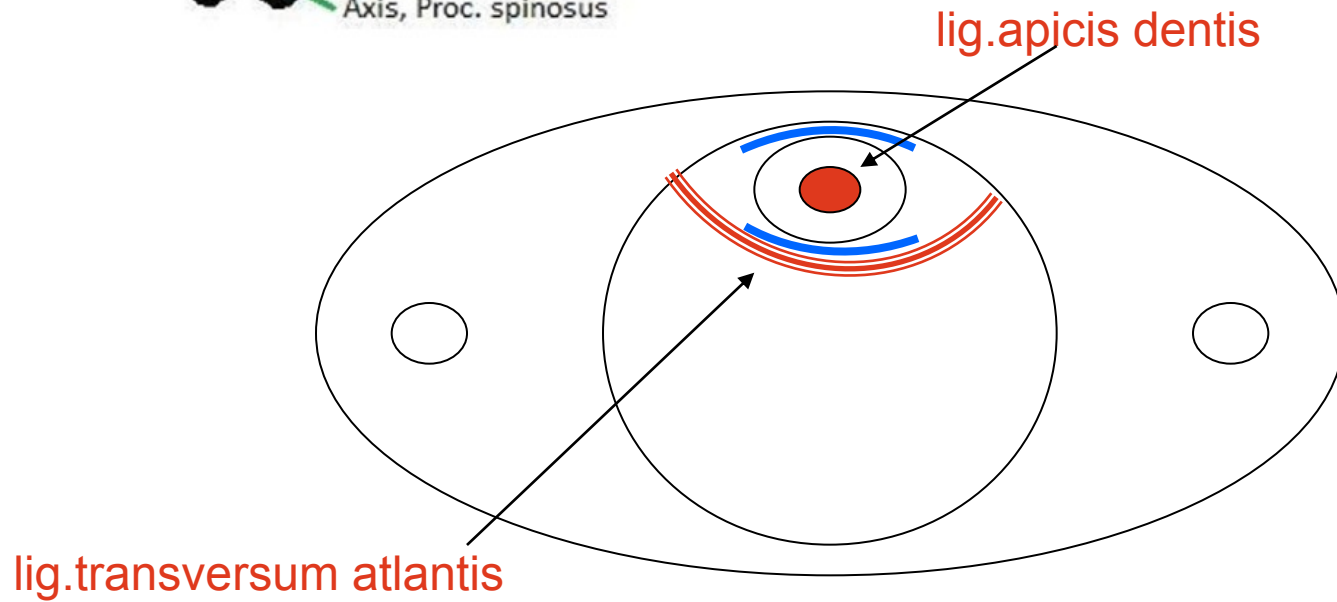
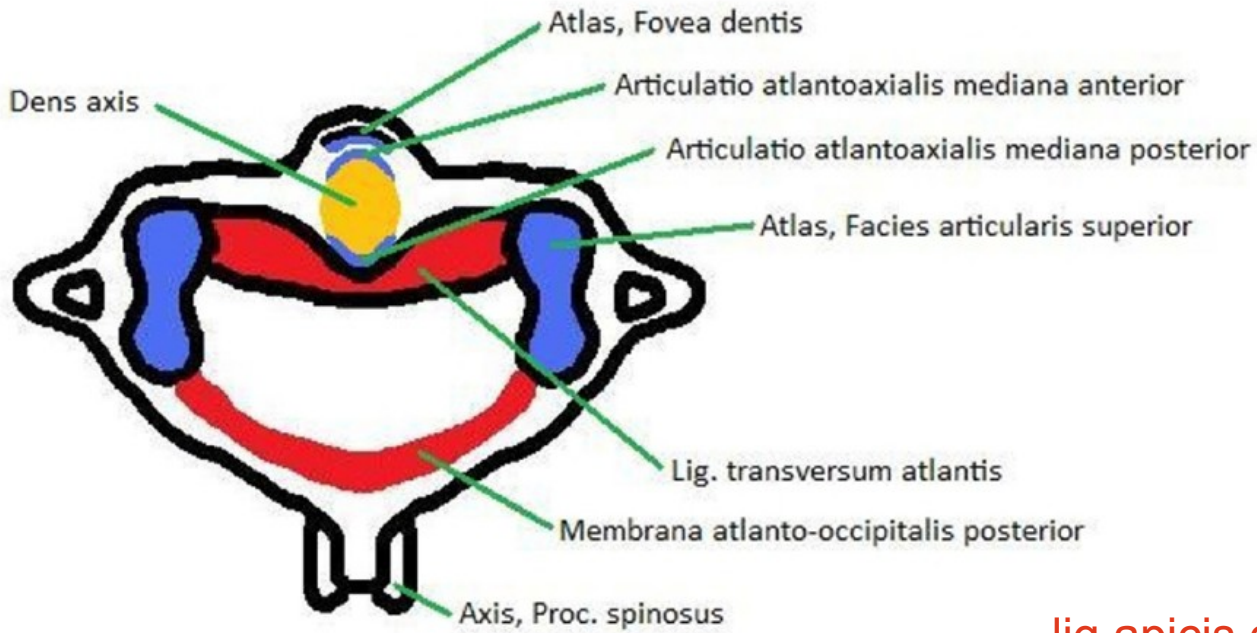
Kostěná nosní přepážka



Rozdíl mezi diskem a meniskem na příčném řezu

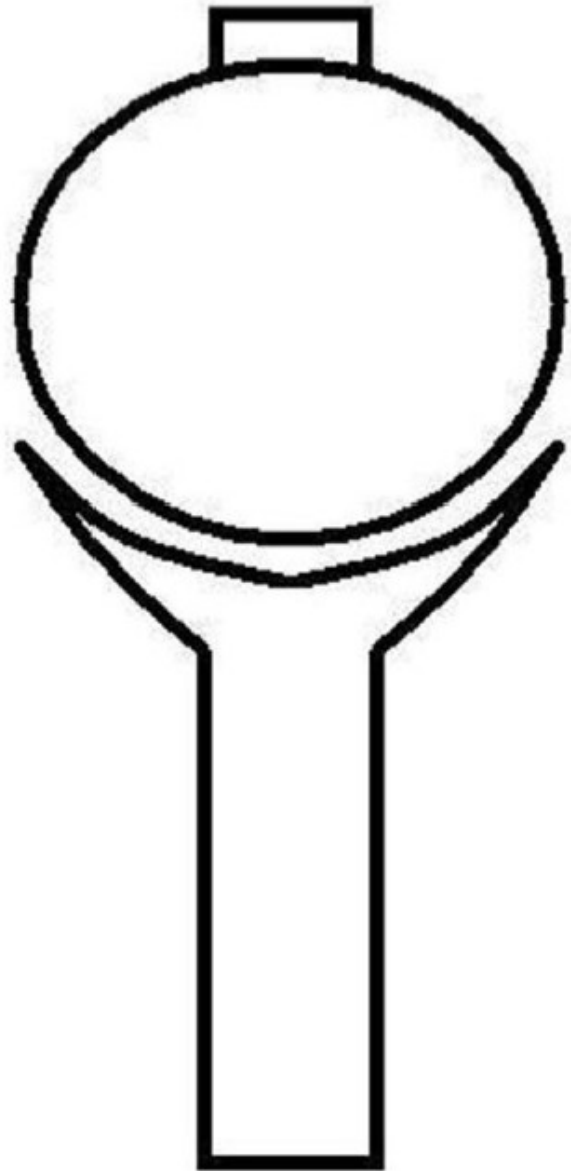


Vazy atlanto-axiálního spojení, pohled shora

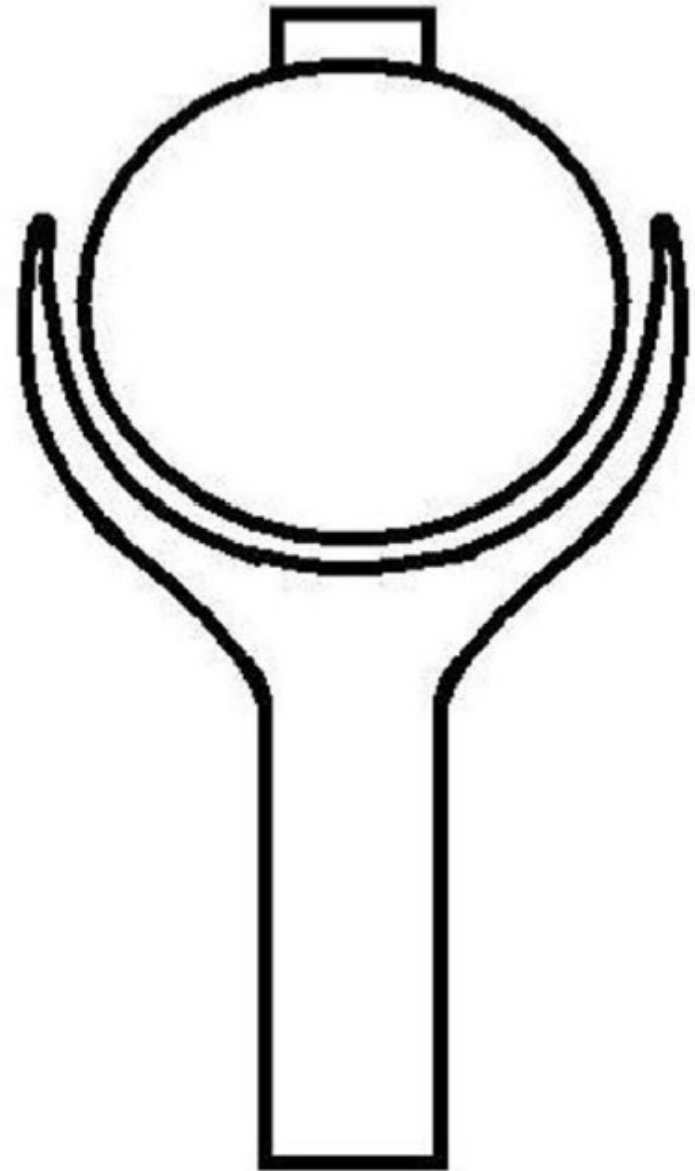


Rozdíl mezi arthrodiem et enarthrosis

Kloub kulový volný (arthrodia)

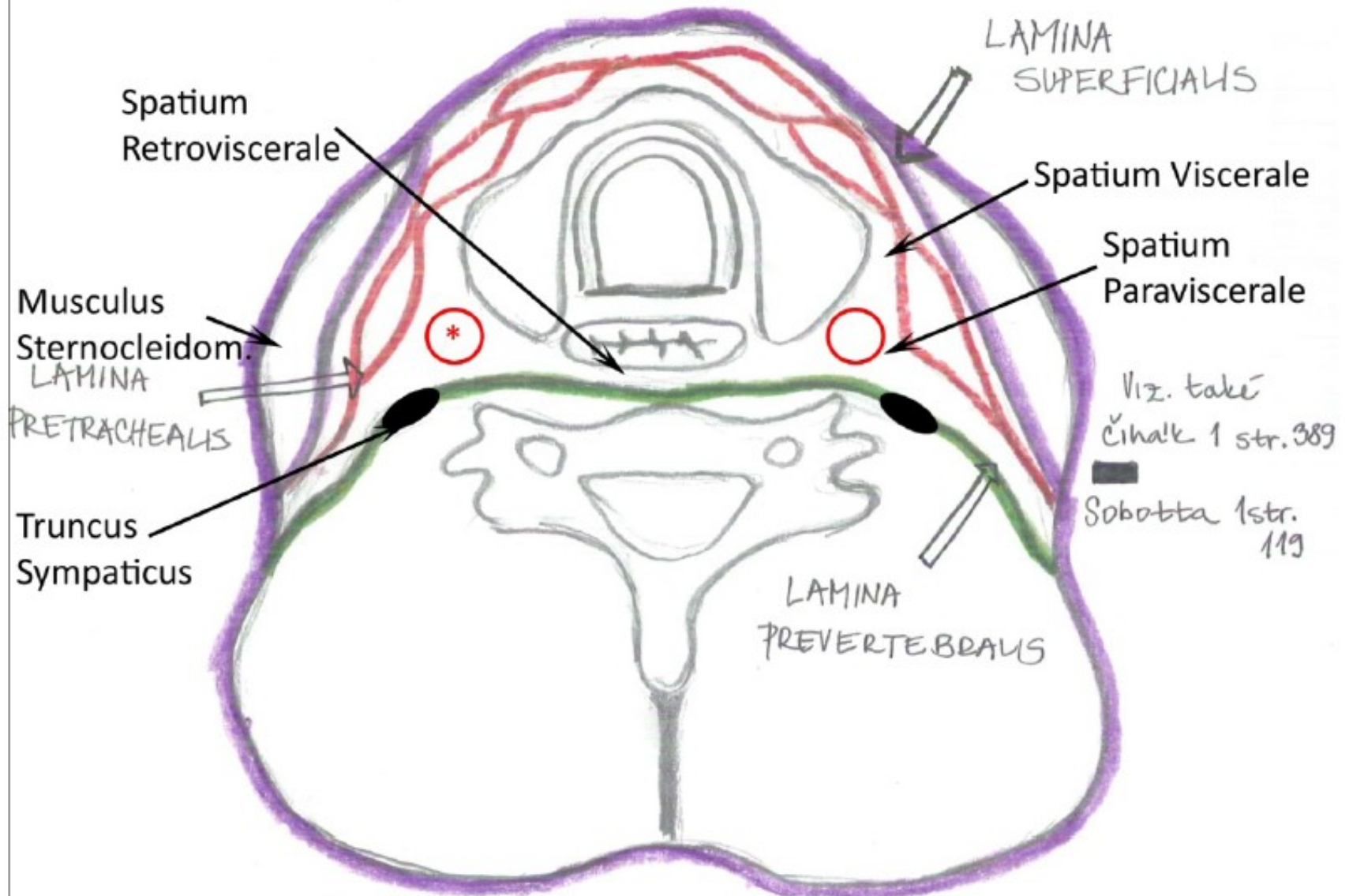


Kloub kulový omezený (enarthrosis)



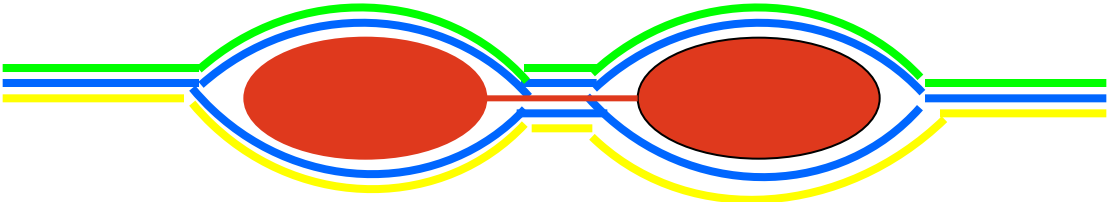
Fasciae colli (horizontální řez)

* A. carotis communis, v. jugularis interna, n. vagus



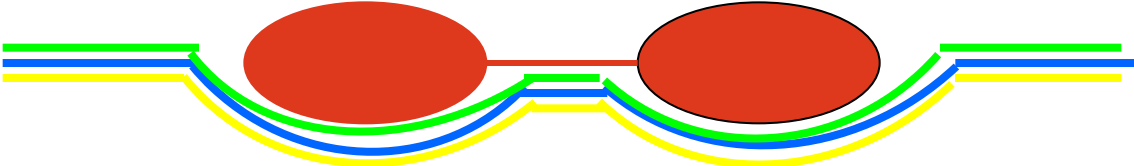
Vagina m.recti abd.

Aponeuroza m.transversus abdominis

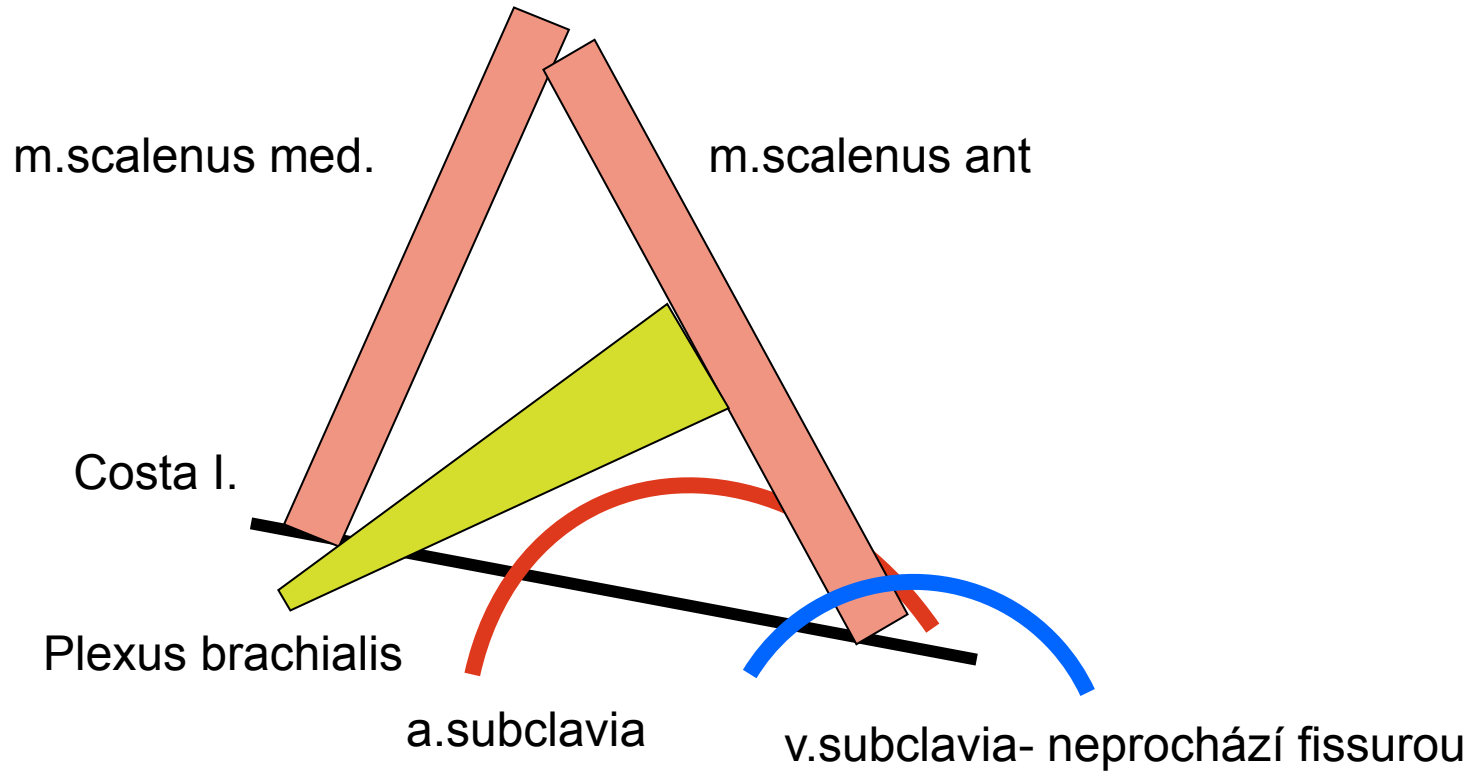


Aponeuroza
m.obliquus
internus

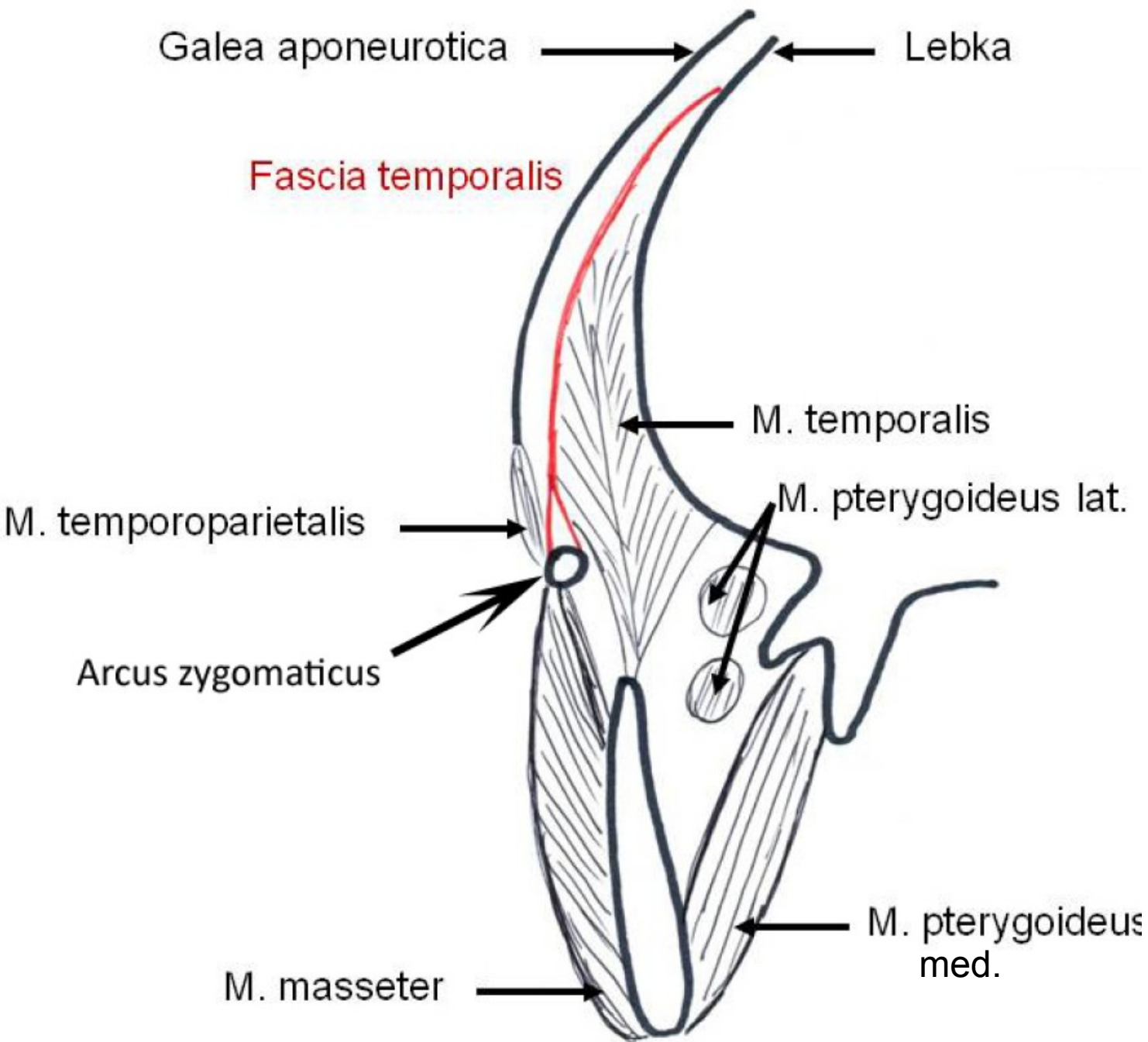
Aponeuroza m.obliquus externus

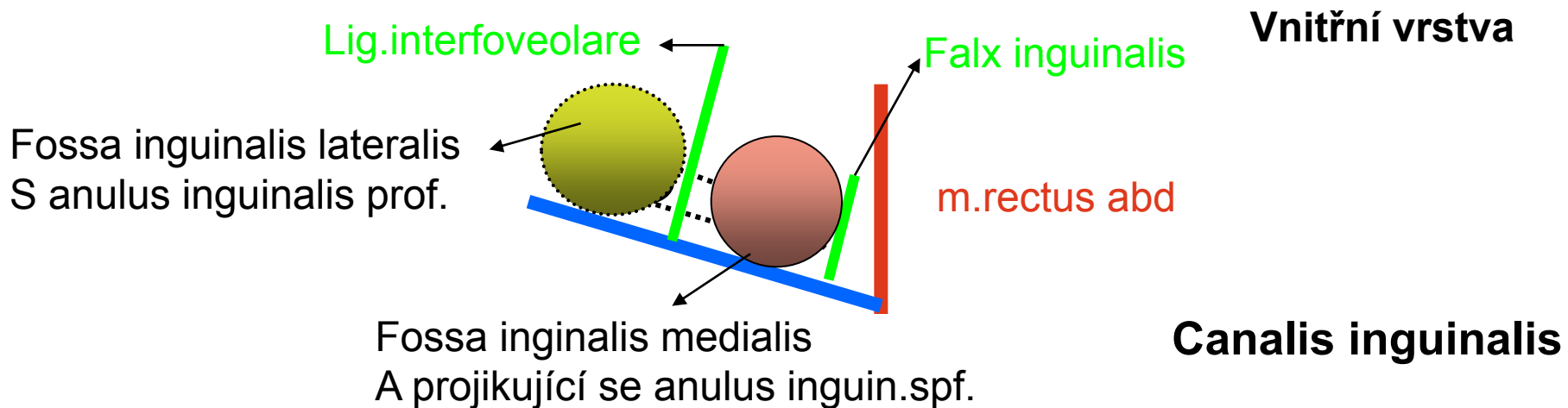
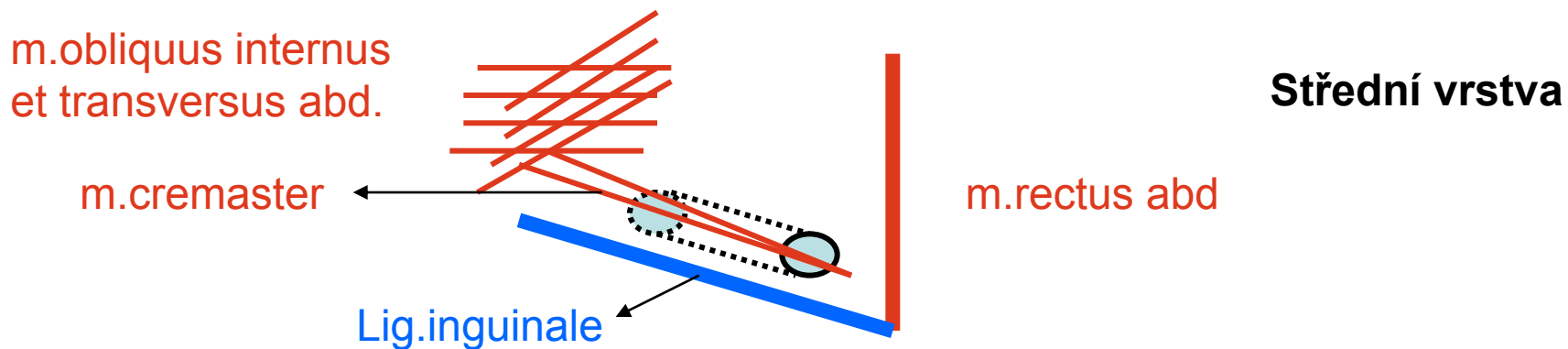
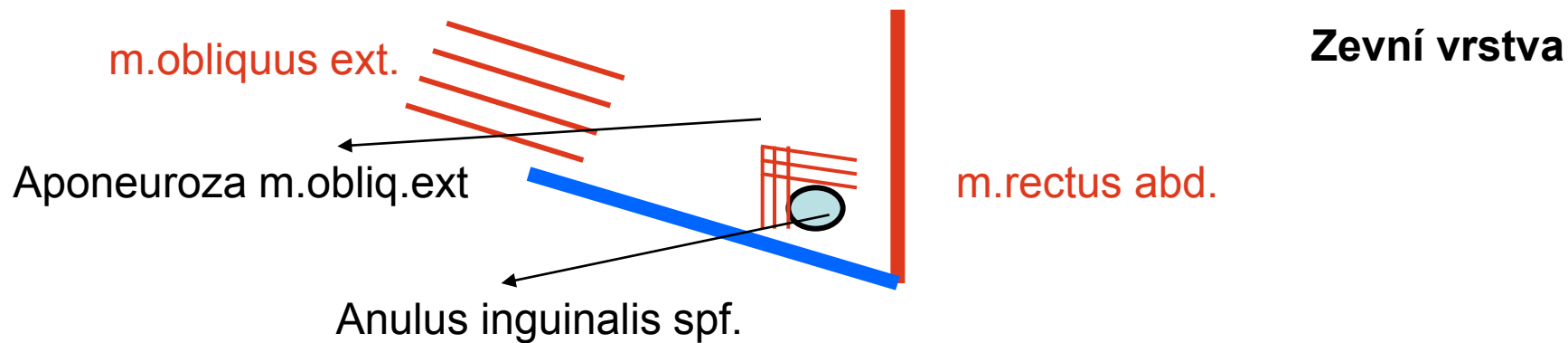


Fissura scalenorum

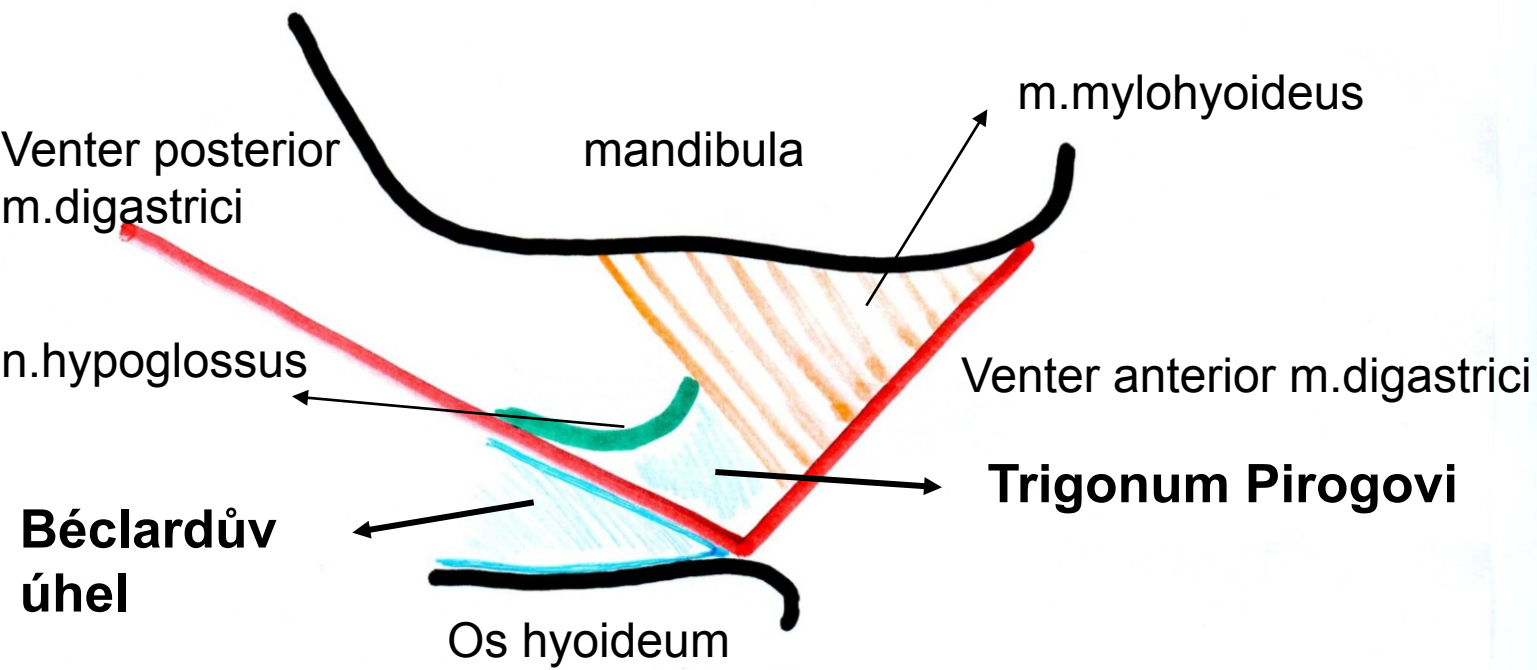
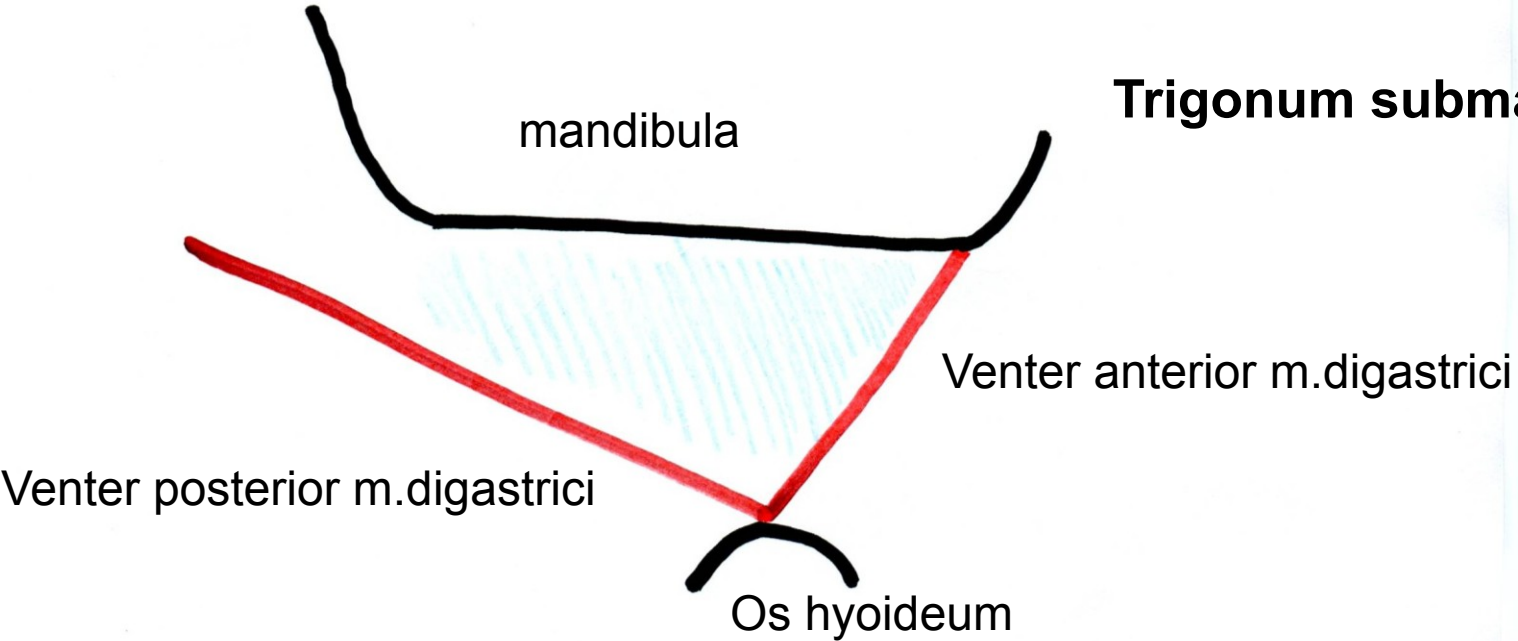


Fossa temporalis na frontálním řezu, úpon fascie





Trigonum submandibulare

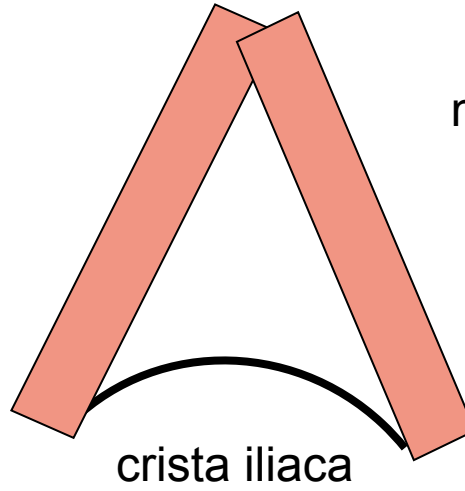


**Béclardův
úhel**

Trigonum lumbale- Petiti

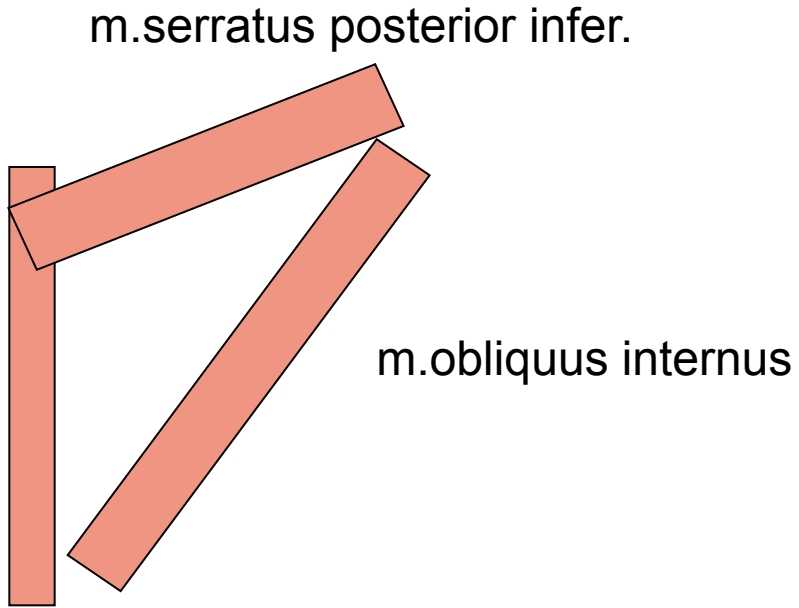
m.latissimus dorsi

m.obliquus externus



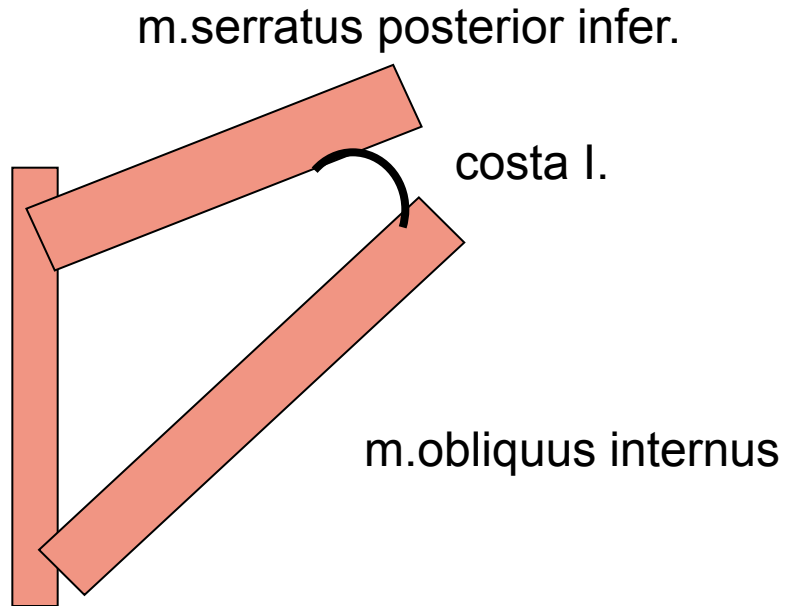
Trigonum Grynfelti

m.erector spinae



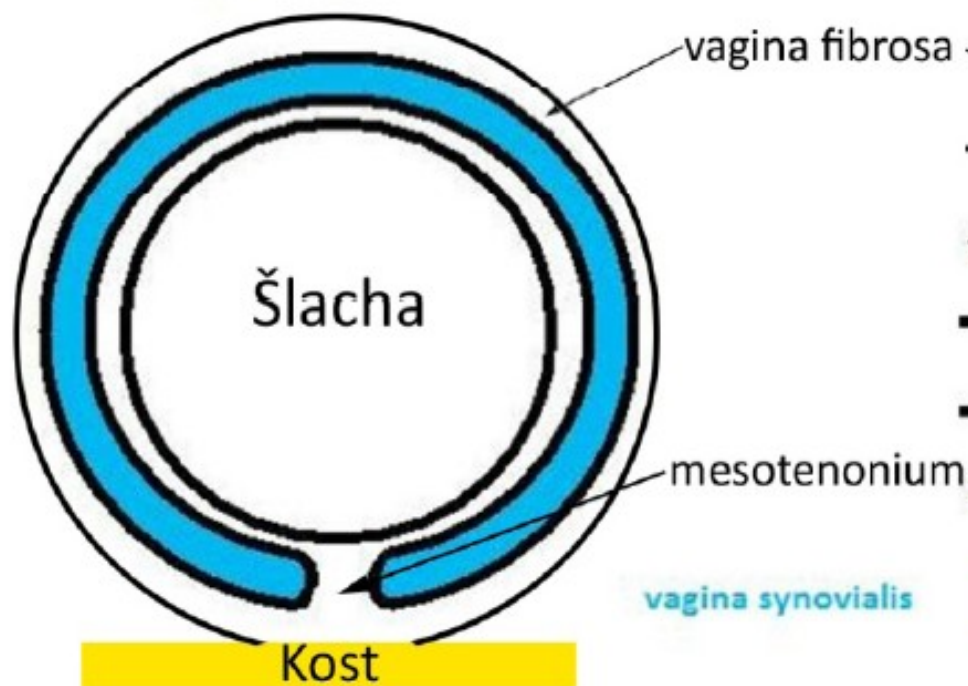
Tetragon Krausei

m.erector spinae

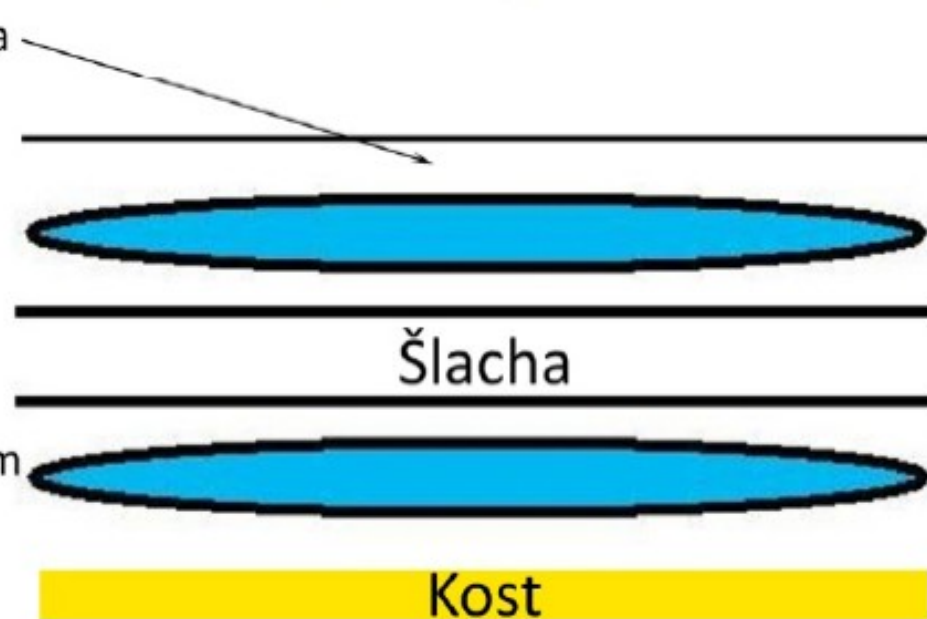


Vagina synovialis na podélném příčném řezu

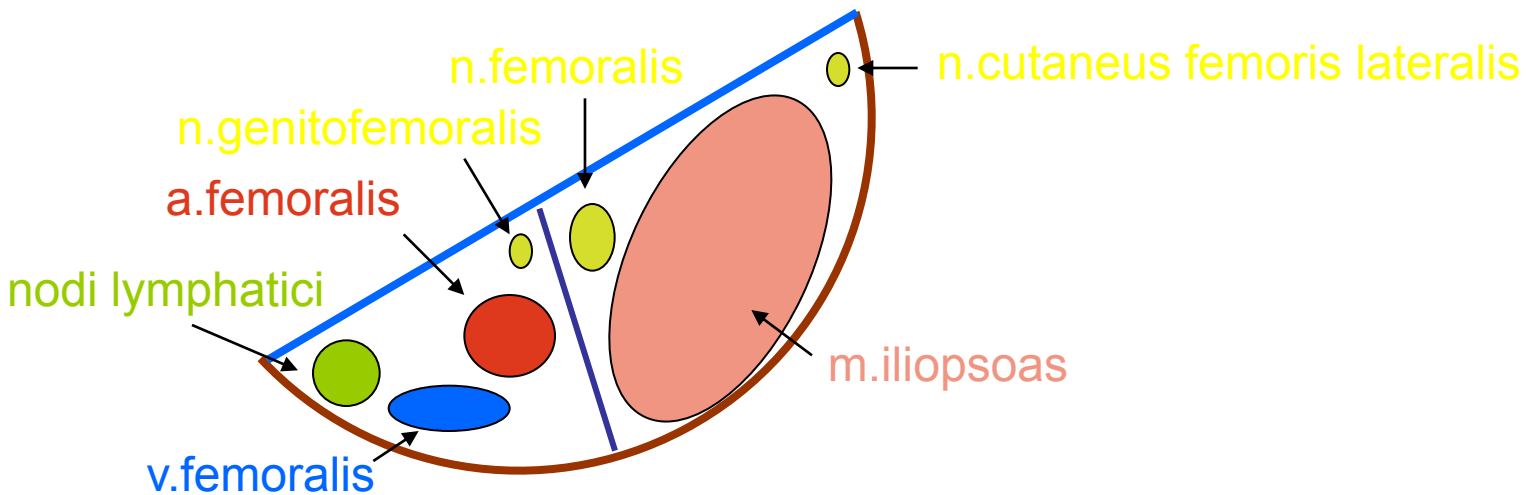
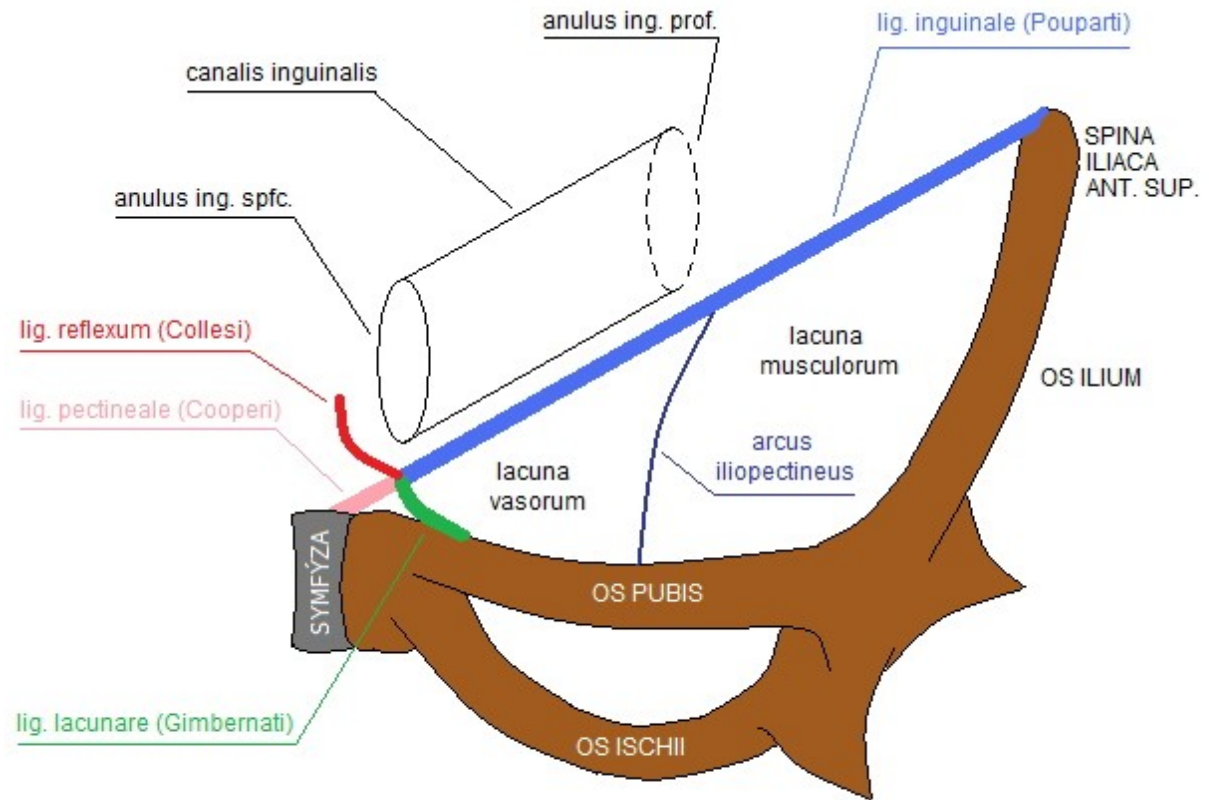
příčný řez



podélný řez



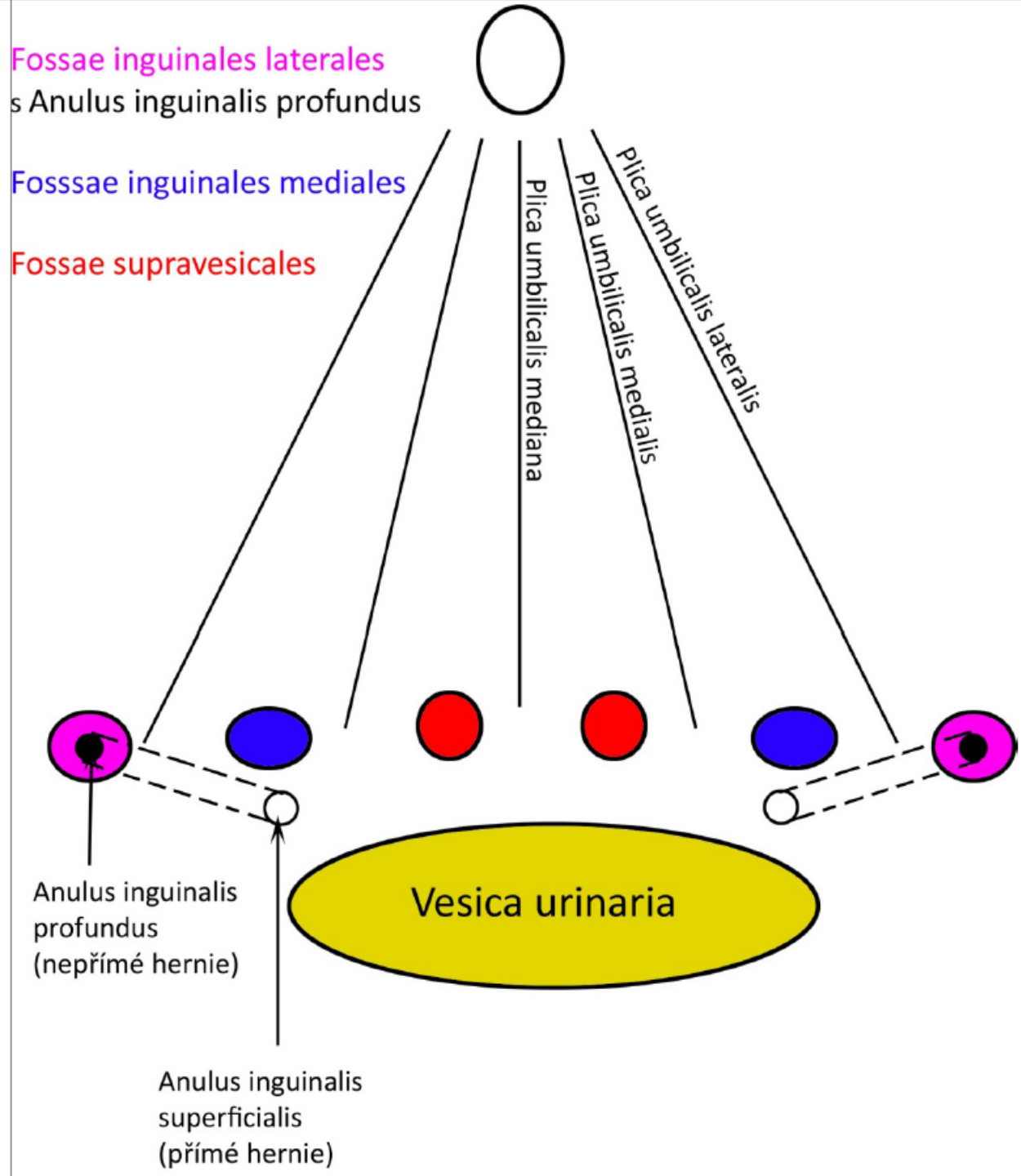
Lacuna musculorum et vasorum



Plica umb.**mediana**=
Lig.umb.**mediale**=
obliterovaný urachus

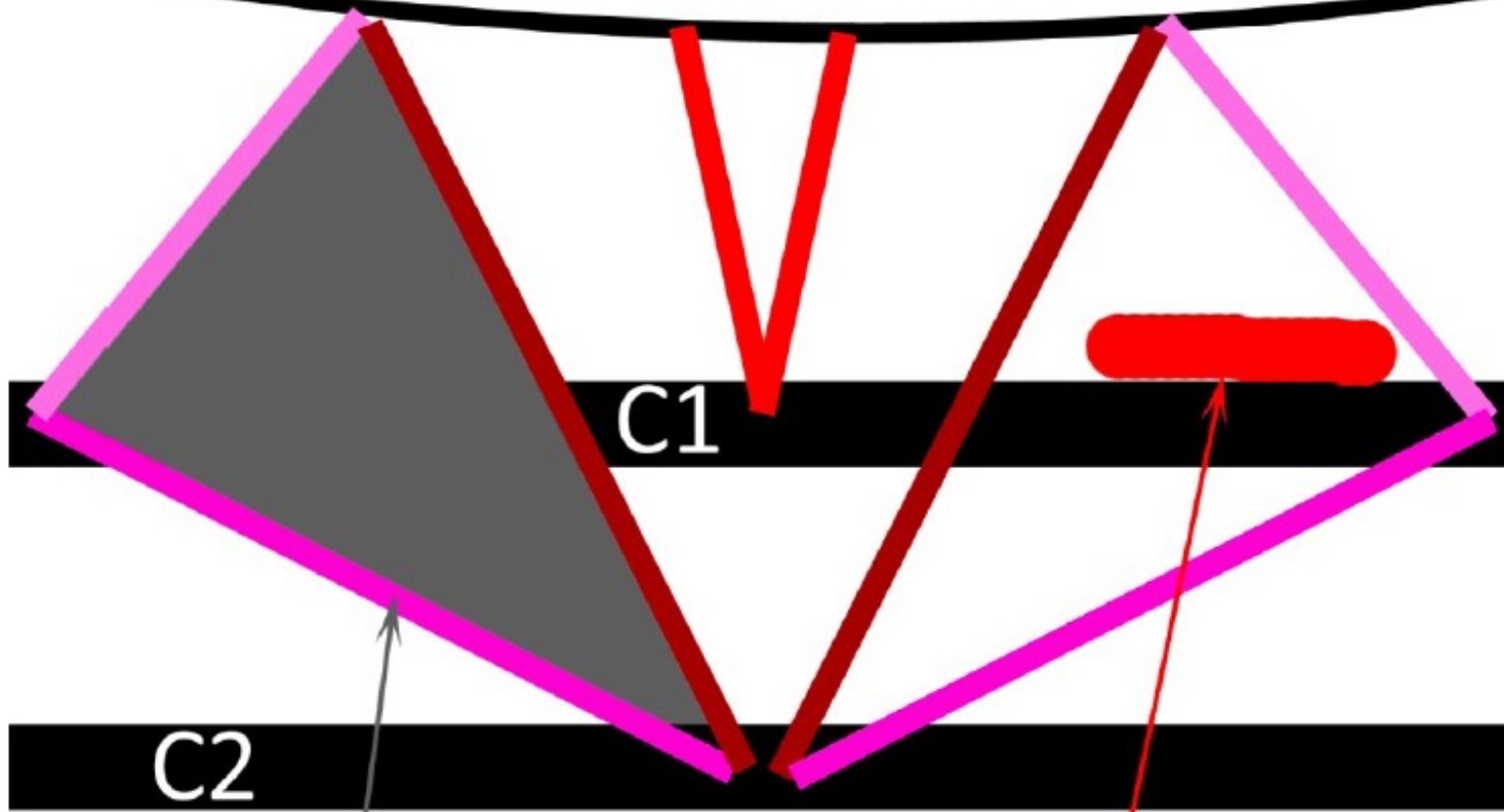
Plica umb.**medialis**=
Lig.umb.**laterale**=
obliterovaná a.umbilicalis

Plica umb.**lateralis**=
Lig.interfoveolare=
vasa epigastrica inferiora



Trigonum suboccipitale

Linea nuchae inferior



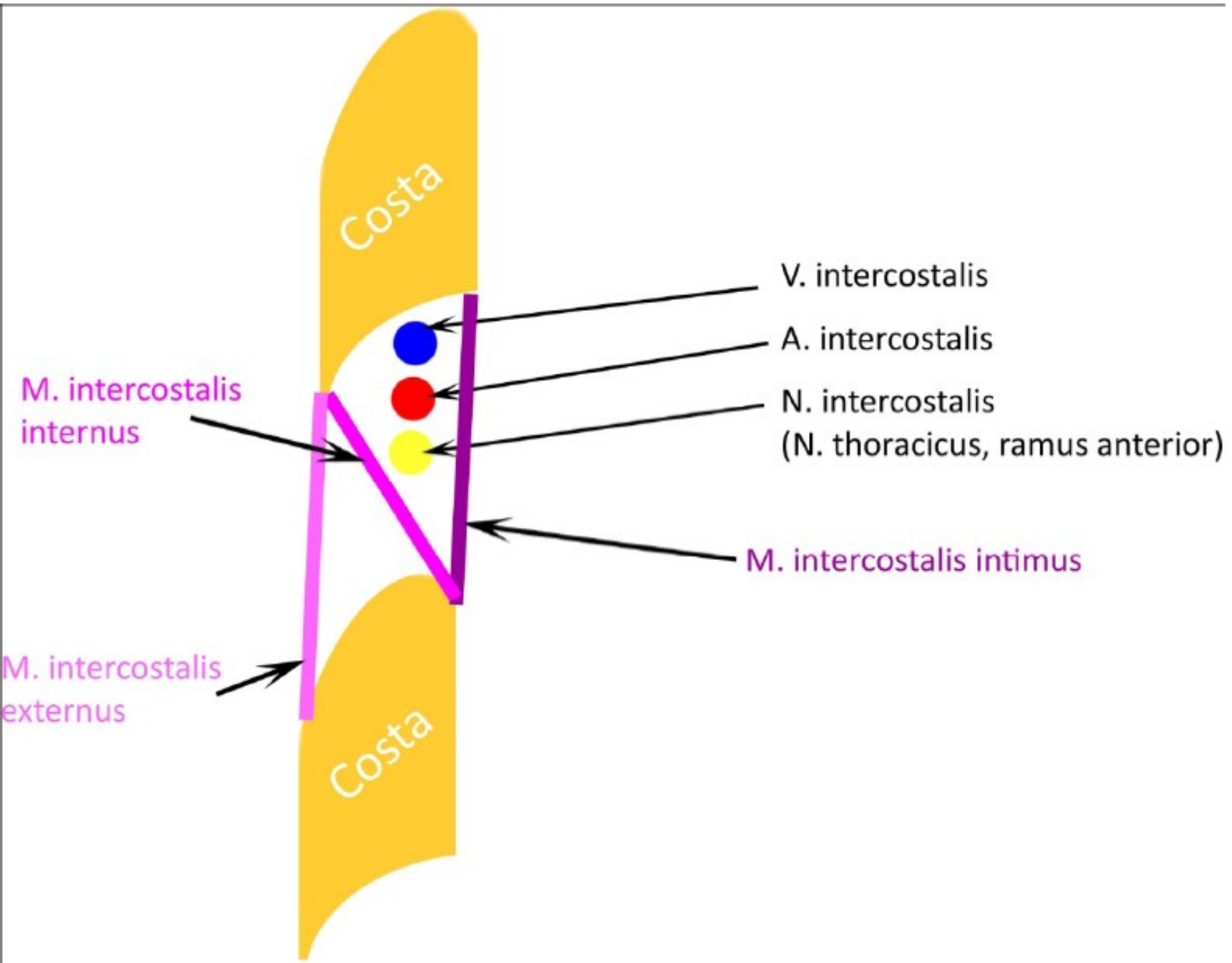
C1

C2

Trigonum suboccipitale

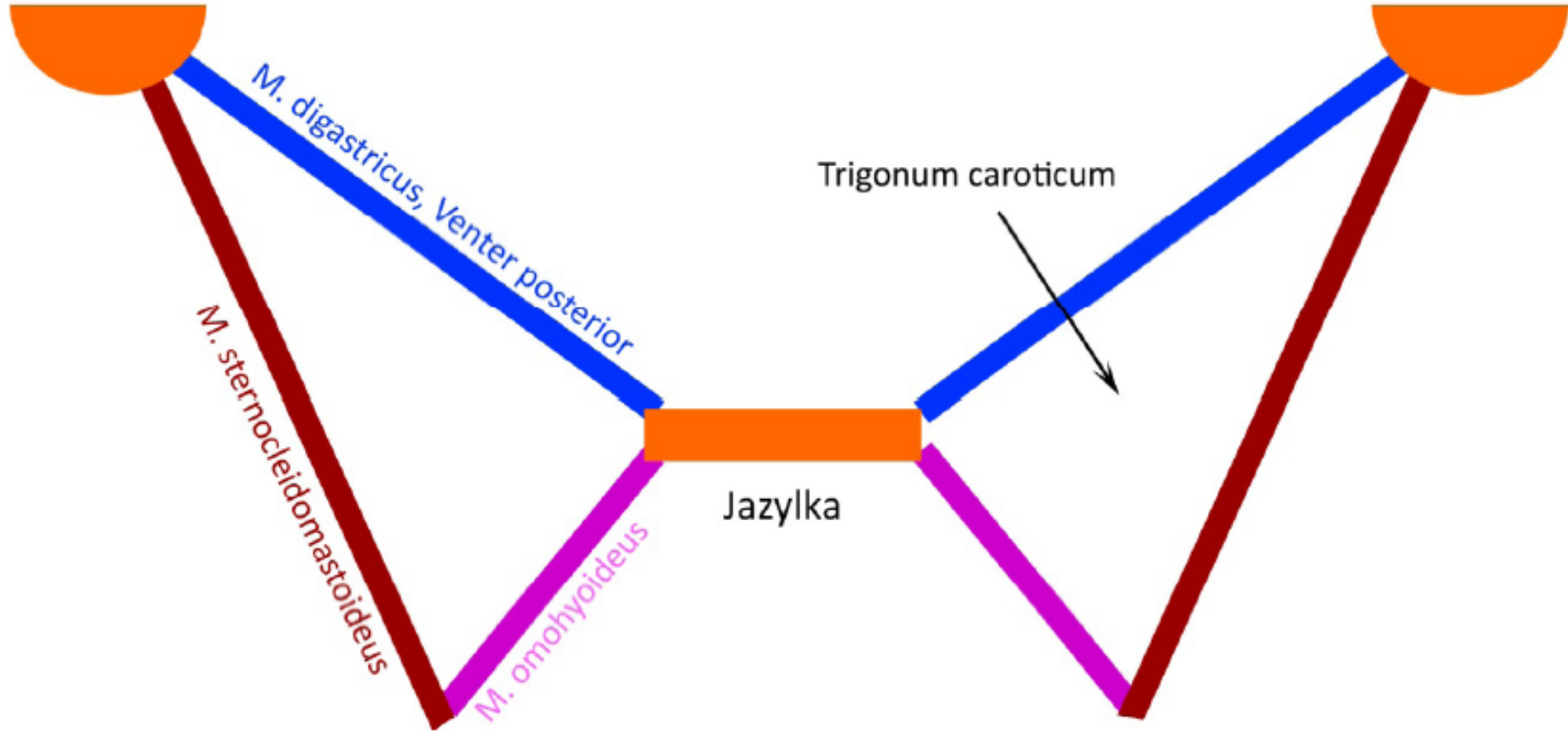
Arteria vertebralis

Průběh nervů a cév v mezižebří



Trigonum caroticum

processus mastoideus



Trojúhelníky na krku

