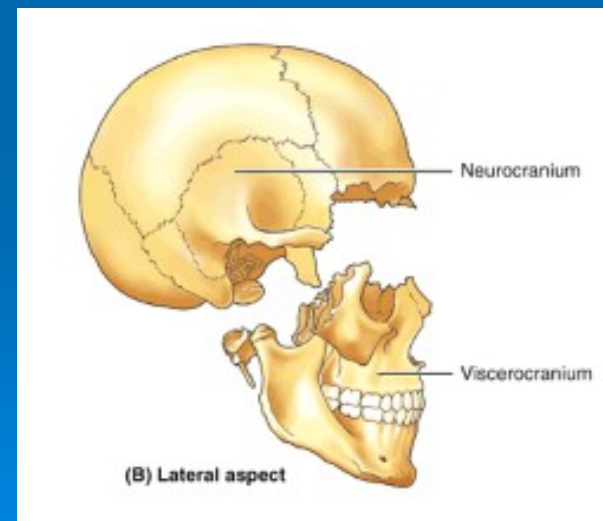


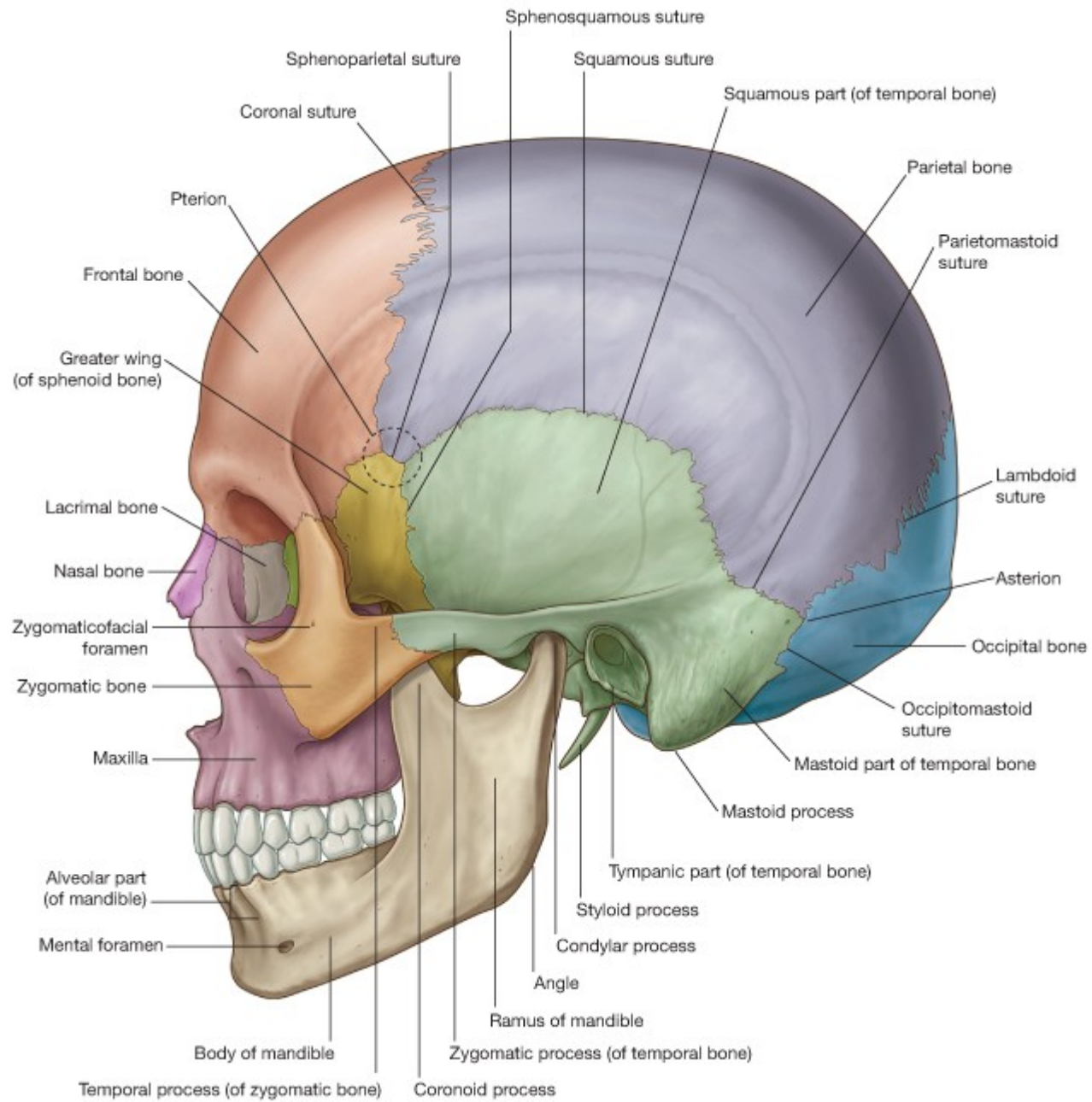
# NEUROCRANIUM

Pages 184 - 199



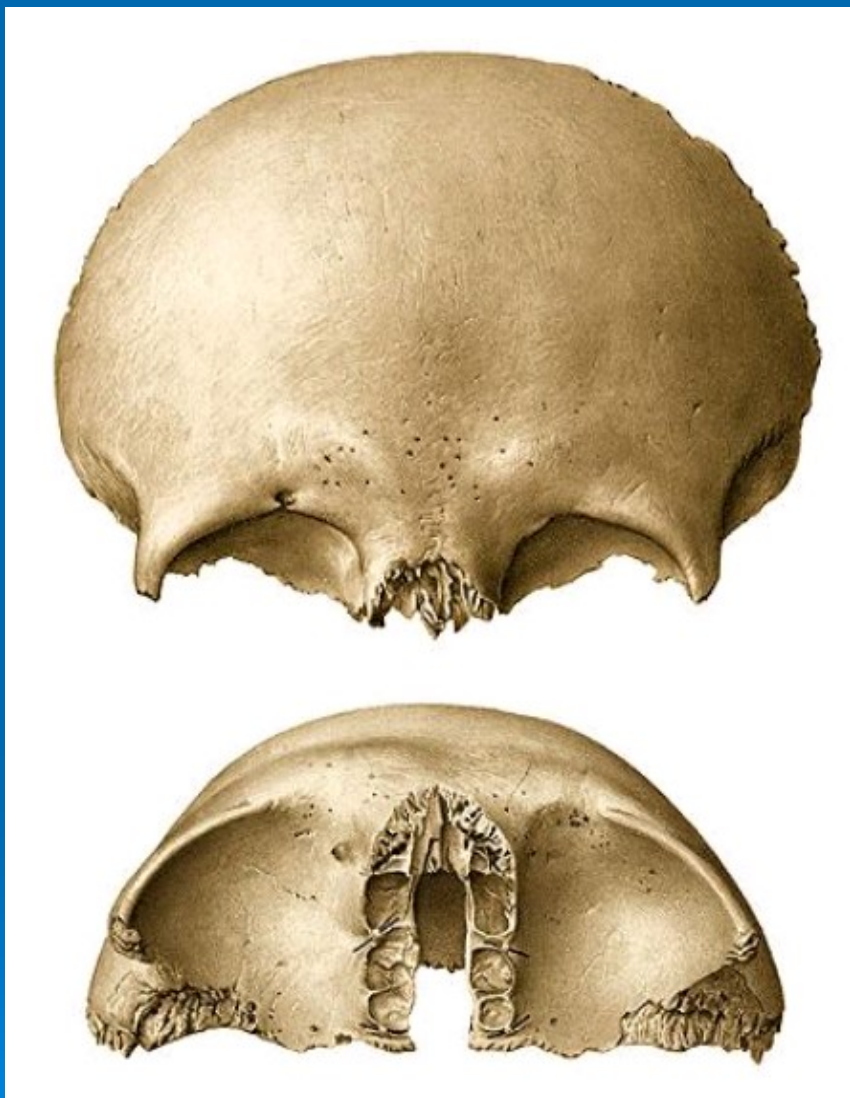
- formed by a series of eight bones, four singular bones centered on the midline - **frontal, ethmoidal, sphenoidal and occipital**
- two sets of bones occurring as bilateral pairs - **temporal and parietal**
- a dome-like roof - **calvaria**
- a floor - **cranial base**





# Frontal bone





- **Squama frontalis**

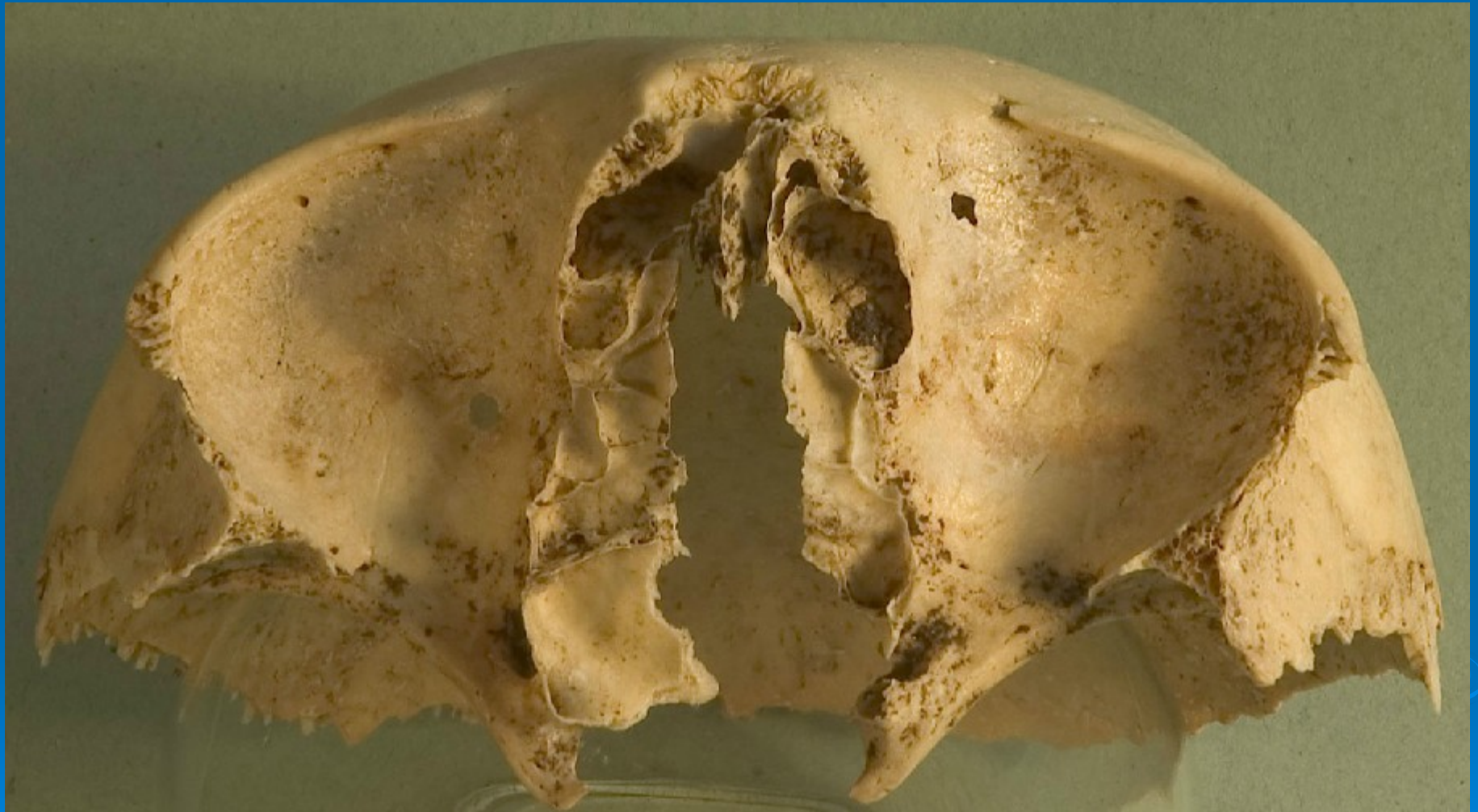- supraorbital margin
  - frontal tuber
  - nasal margin
  - zygomatic process
  - inferior temporal line

- **Orbital part**

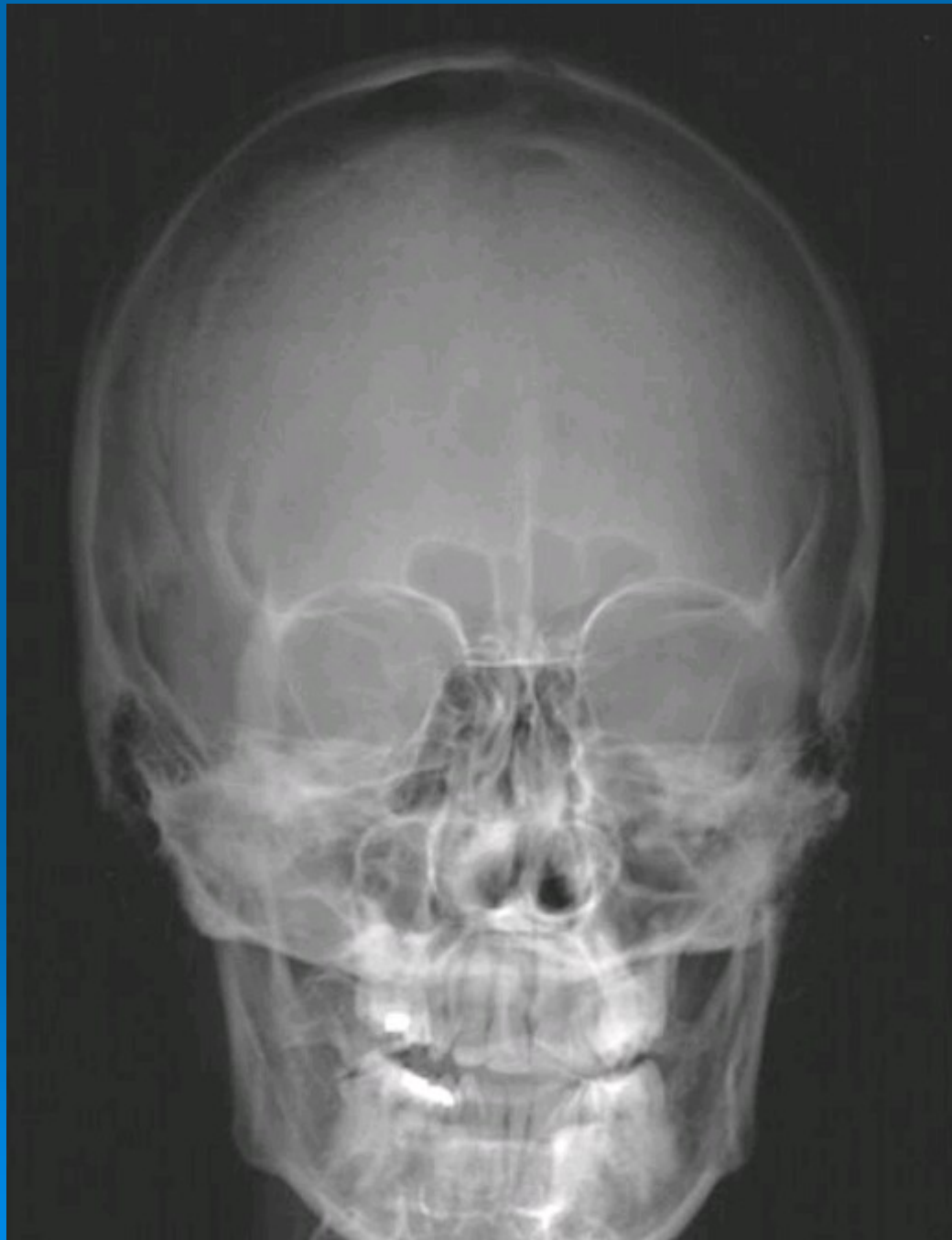- supraorbital foramen/notch
  - superciliary arch
  - glabella
  - lacrimal fossa
  - trochlear fovea
  - ant. et post. ethmoidal for.

- **Nasal part**

- frontal sinus



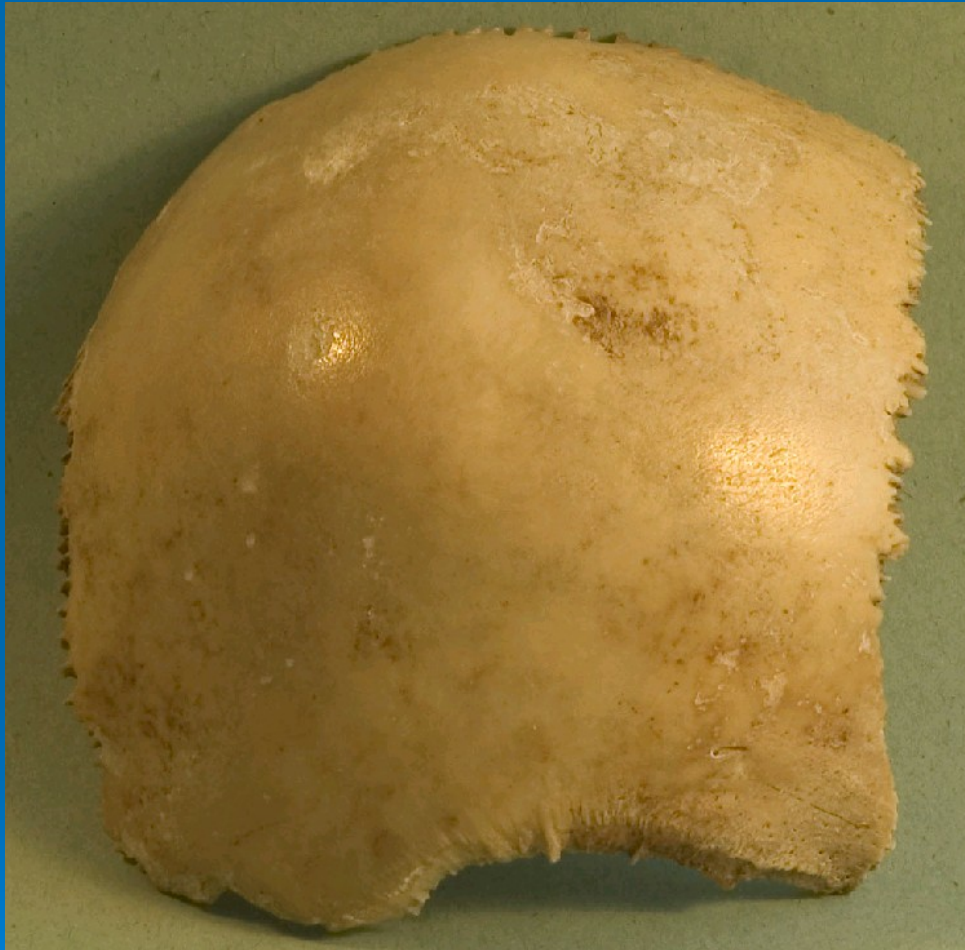





# Parietal bone





- **External surface**

- temporal lines superior

- temporal lines inferior

- parietal eminence

- parietal foramens

- **Internal surface**

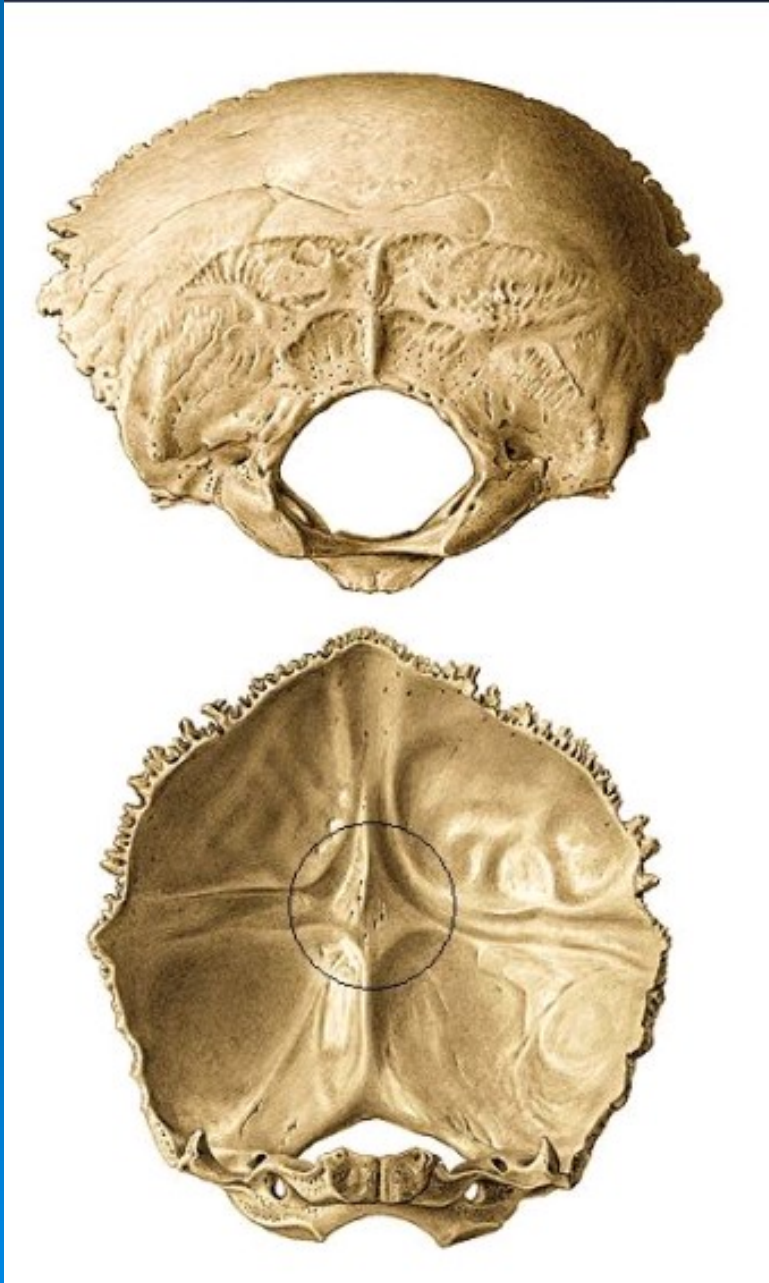- granular foveolae

- middle meningeal grooves

- superior sagittal sulcus

# Occipital bone





- **Squama - exter. surface**

- external occipital protuberance
- superior nuchal lines
- inferior nuchal lines
- highest nuchal lines
- external occipital crest

- **Squama - inter. surface**

- internal occipital protuberance
- superior sagittal sulcus
- transverse sulcus occipital
- internal occipital crest
- cruciform eminence
- cerebral and cerebella markings

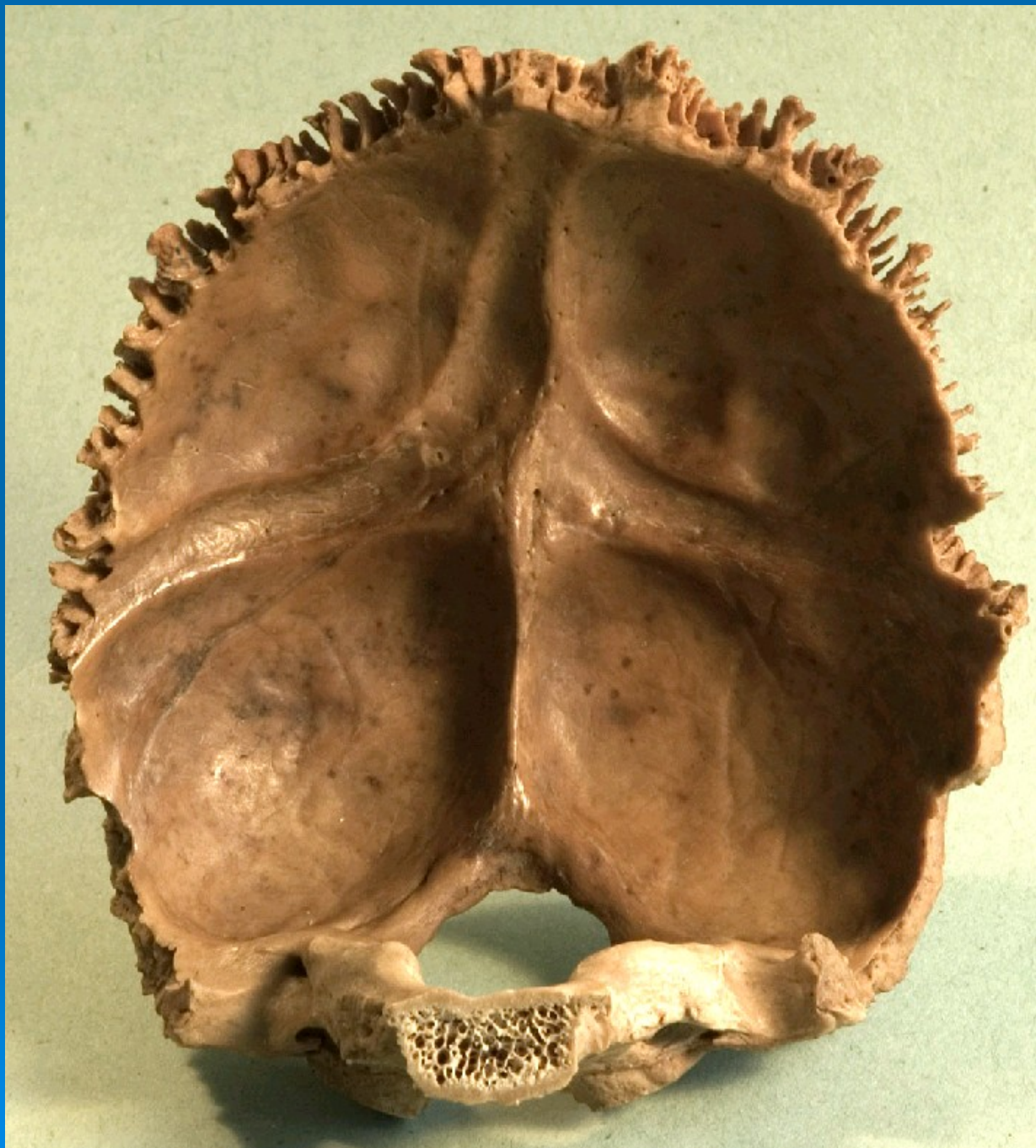

- **Condylar part**

- occipital condyle
- jugular notch
- hypoglossal canal
- condylar canal
- condylar fossa

- **Basilar part**

- clivus
- pharyngeal tubercle



# Temporal bone





- **Squama**

- zygomatic process
  - mandibular fossa
  - articular eminence
  - glenoid tubercle
  - postglenoid tubercle

- **Mastoid part**

- mastoid process
  - mastoid notch
  - styloid process
  - stylomastoid foramen
  - digastric notch
  - groove for occipital artery



- **Petrous part - bone**

- apex

- base

- ant., post. and inf. surface

- superior et inferior borders

- superior petrosal sulcus

- meningeal artery

- **Petrous part - inf. surf.**

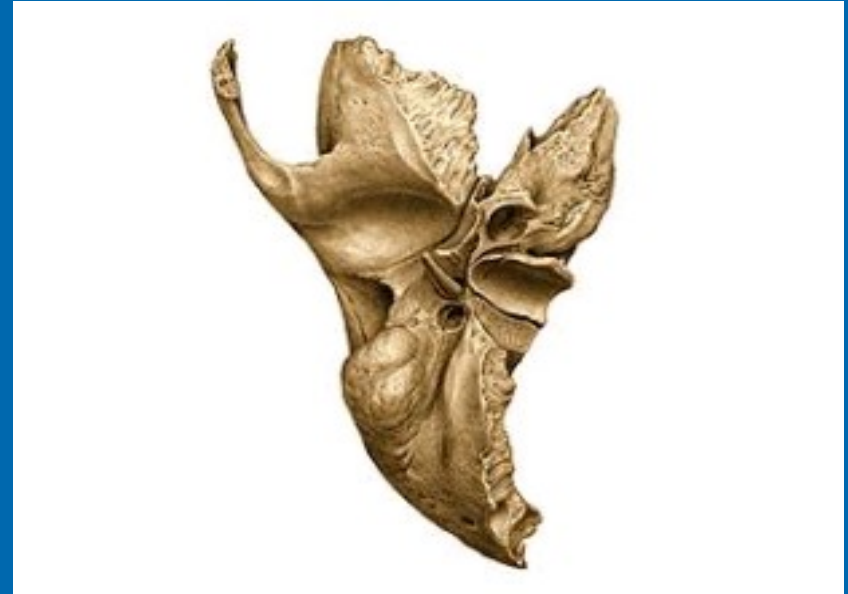
- carotid canal

- pharyngotympanic canal

- petrosal fossula with tympanic canaliculus

- jugular fossa with mastoid canaliculus

- external opening of cochlear canaliculi



- **Petrous part - ant. surf.**

- hiatus and groove for greater petrosal nerve

- hiatus and groove for lesser petrosal nerve

- trigeminal depression

- arcuate eminence

- tegmen tympani

- **Petrous part - post. surf.**

- internal acoustic meatus

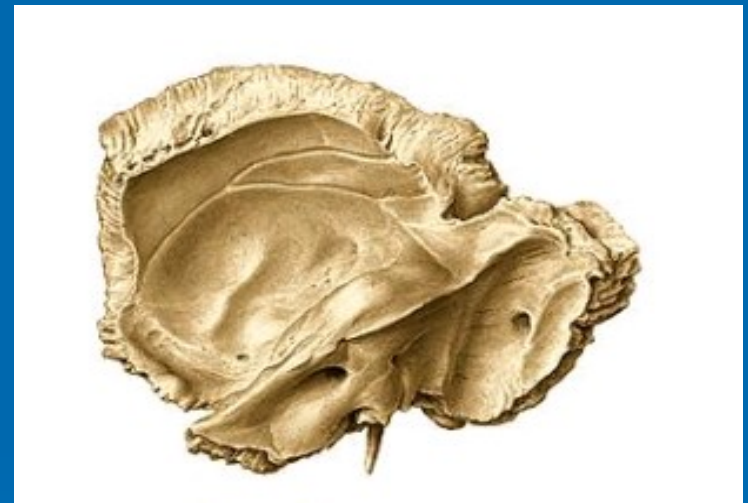- groove for superior petrosal sinus

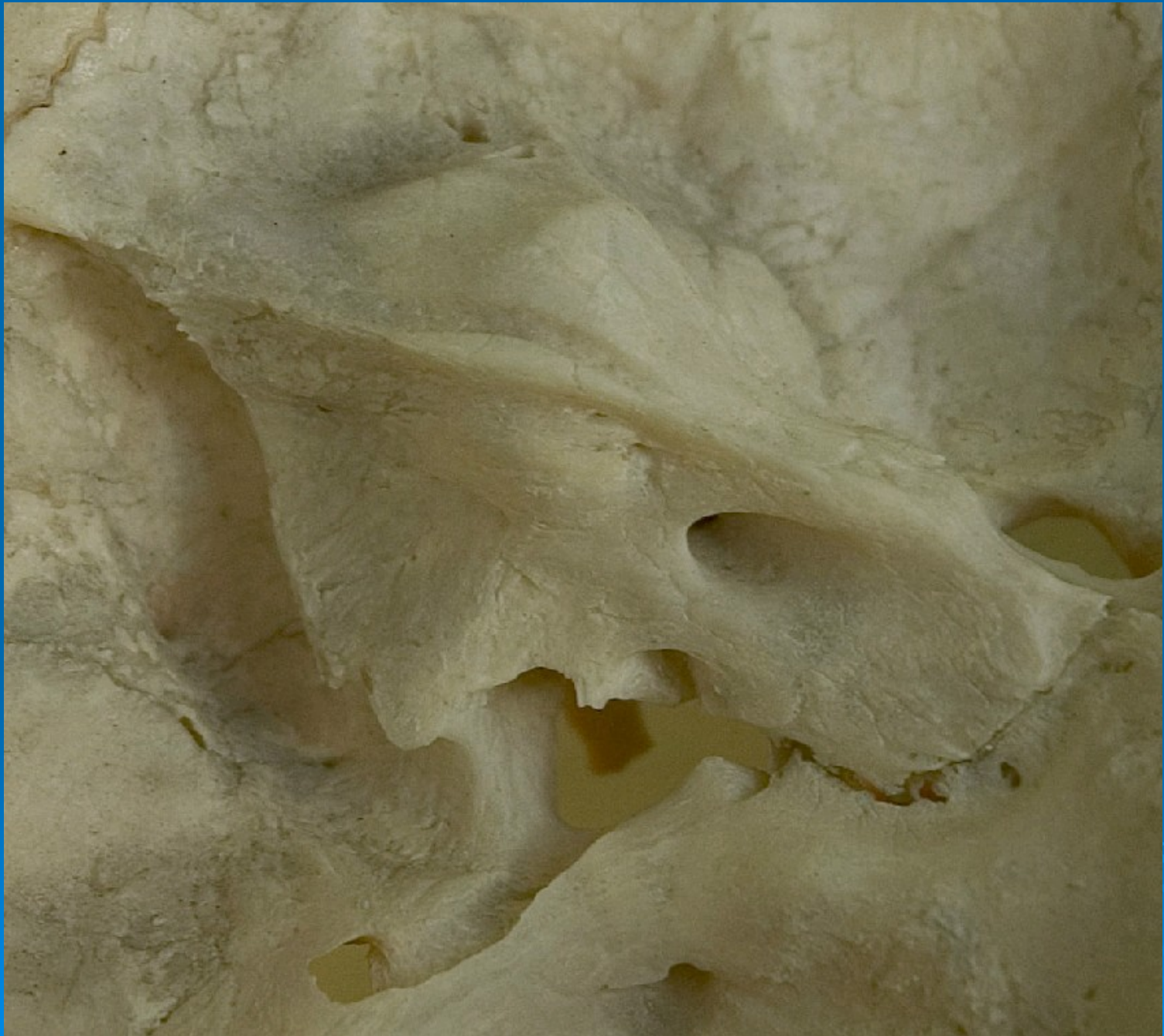
- groove for inferior petrosal sinus

- external opening of vestibular aqueduct

- sigmoid sulcus

- jugular notch

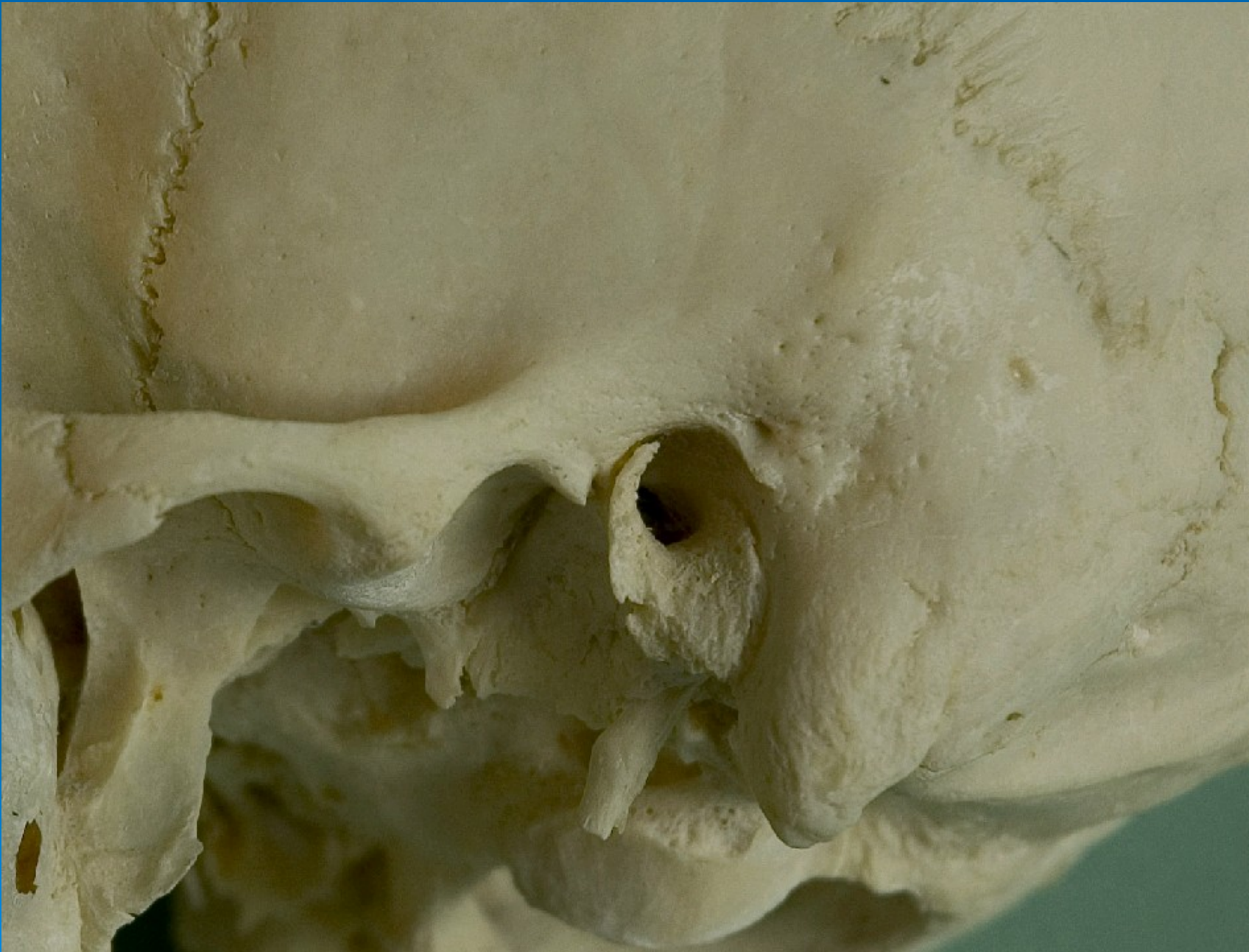






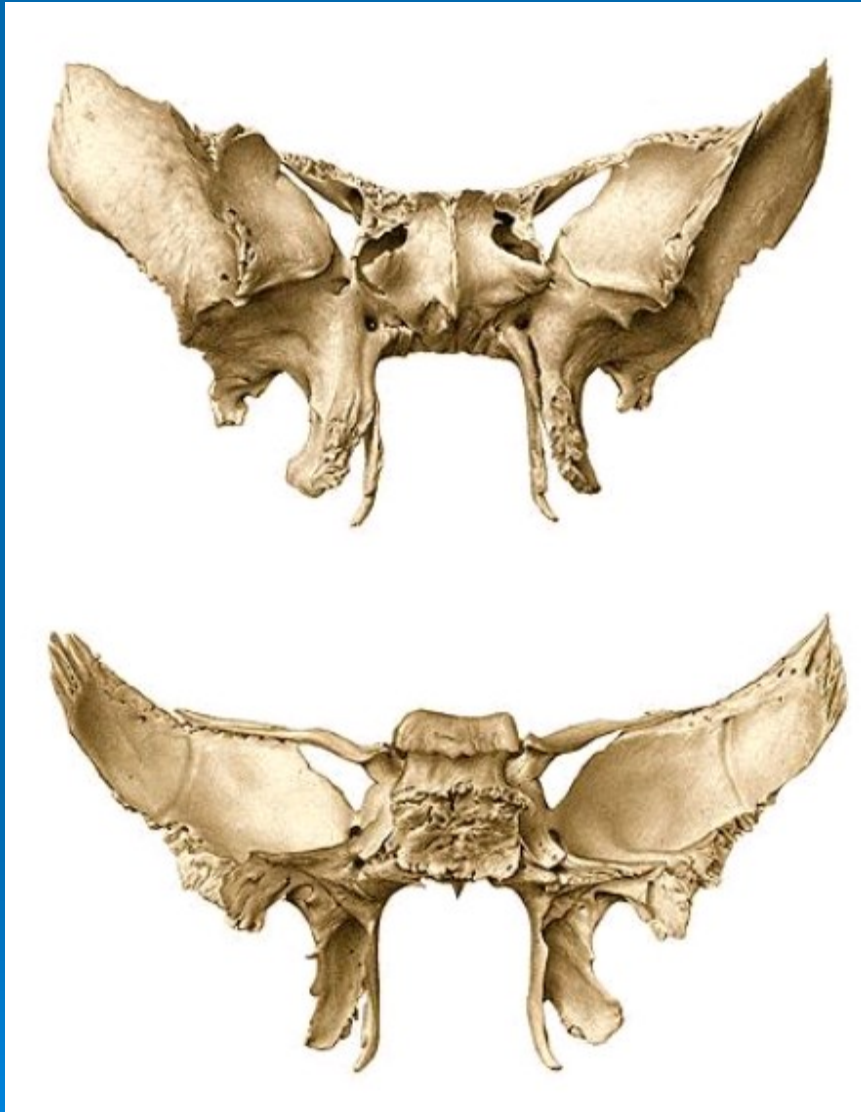
- **Tympanic portion**

- external acoustic meatus
- tympanic notch
- squamotympanic fissure
- petrotympanic fissure
- petrosquamous fissure
- tympanomastoid fissure



# Sphenoid bone





- **Corpus**

sphenoidal crest

rostrum

sphenoid sinus

opening of the sphenoid sinus

sella turcica

hypophyseal fossa

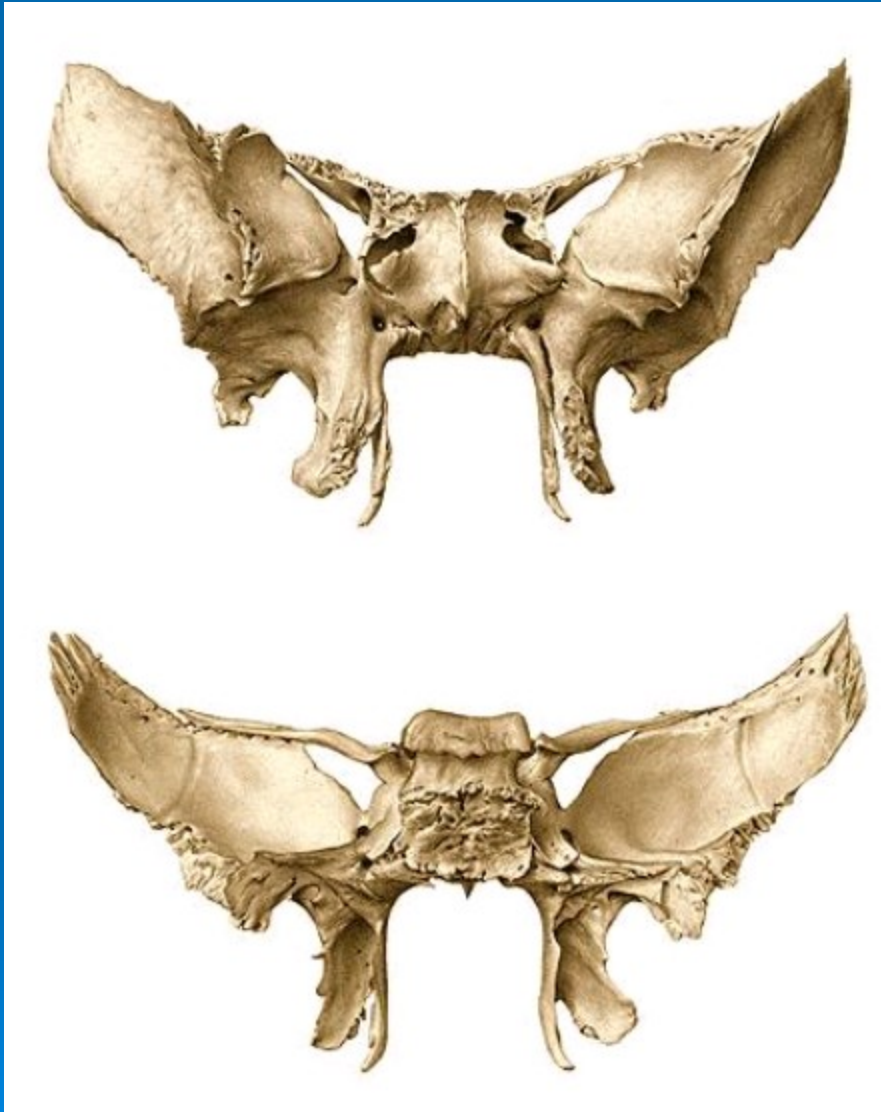
carotic groove

chiasmatic groove

dorsum sellae

posterior clinoid processes

lingula sphenoidalis



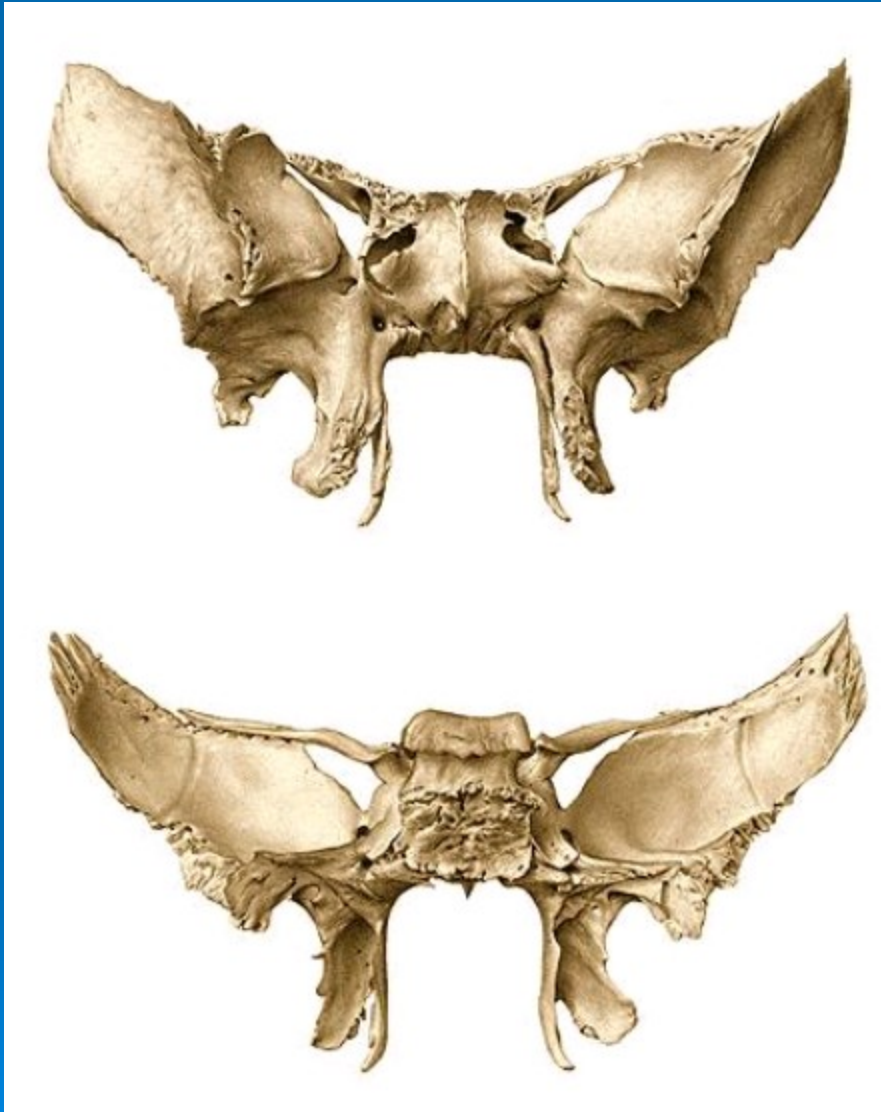
- **Lesser wings**

- anterior clinoid process
  - optic canal
  - superior orbital fissure

- **Greater wings**

- foramen rotundum
  - foramen ovale
  - foramen spinosum
  - spine of the sphenoid
  - cerebral, temporal, infratemporal, maxillary and orbital surfaces





- **Pterygoid process**

lateral pterygoid plate  
medial pterygoid plate

hamulus

pterygoid fossa

scaphoid fossa

pterygoid notch

pterygoid canal



