

UPPER EXTREMITY

Pages 388 - 393

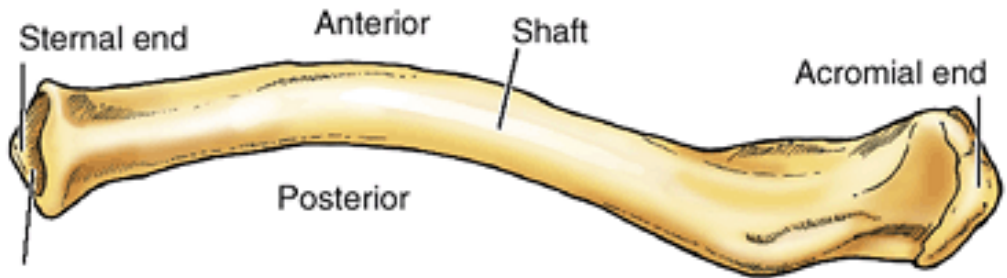


Clavicle - Collarbone



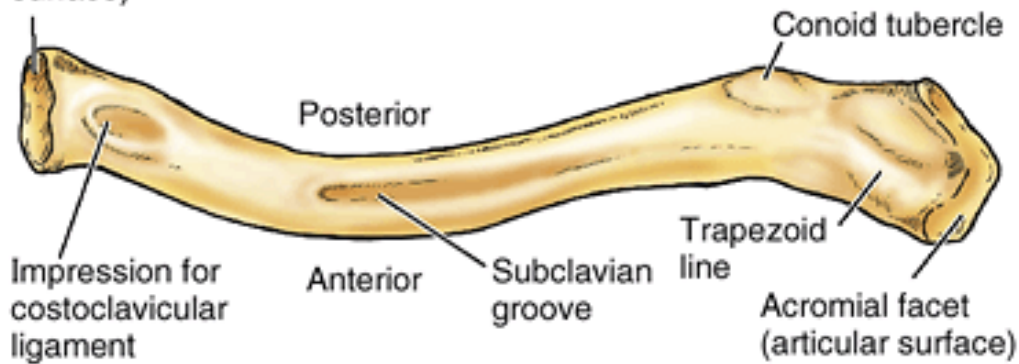
- **S- shaped double curvature long** bone
- form the anterior portion of the shoulder girdle
- allows the scapula to move on the thoracic wall → increase the range of motion of the limb and trasmits shocks from the upper limb to the axial skeleton
- articulates **medially** with manubrium sterni and **laterally** with acromion of the scapula
- **medial** half is convex **anteriorly** while **lateral** half **posteriorly**
- **sternal end** is enlarged, acromial end is flat
- superior surface is **smooth** × inferior is **rough**

Right clavicle



Sternal facet
(articular
surface)

Superior surface

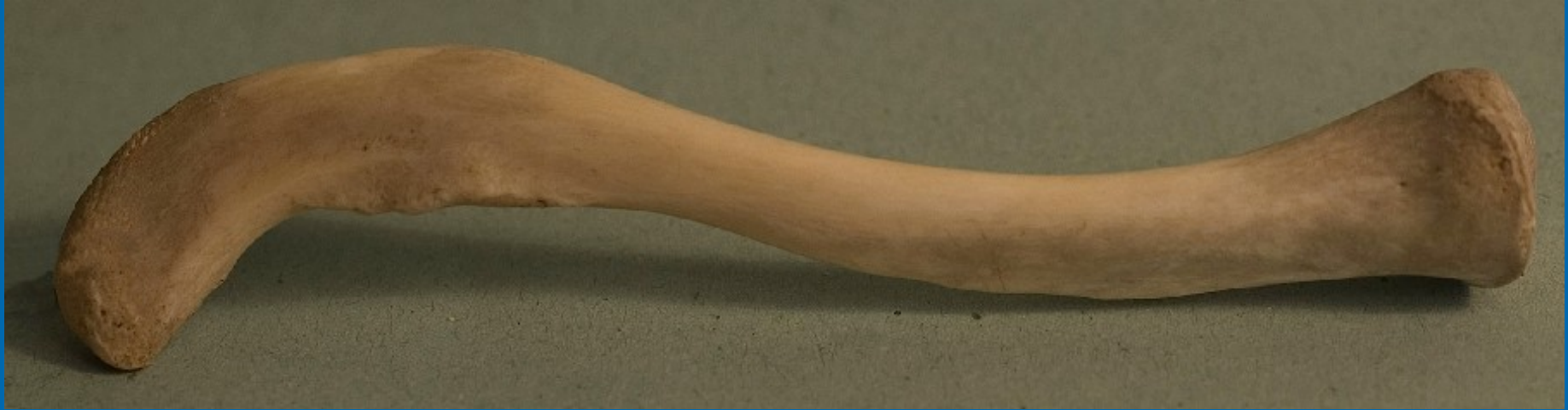

Inferior surface

- **Acromial extremity**
- **Body**

costal tubercle

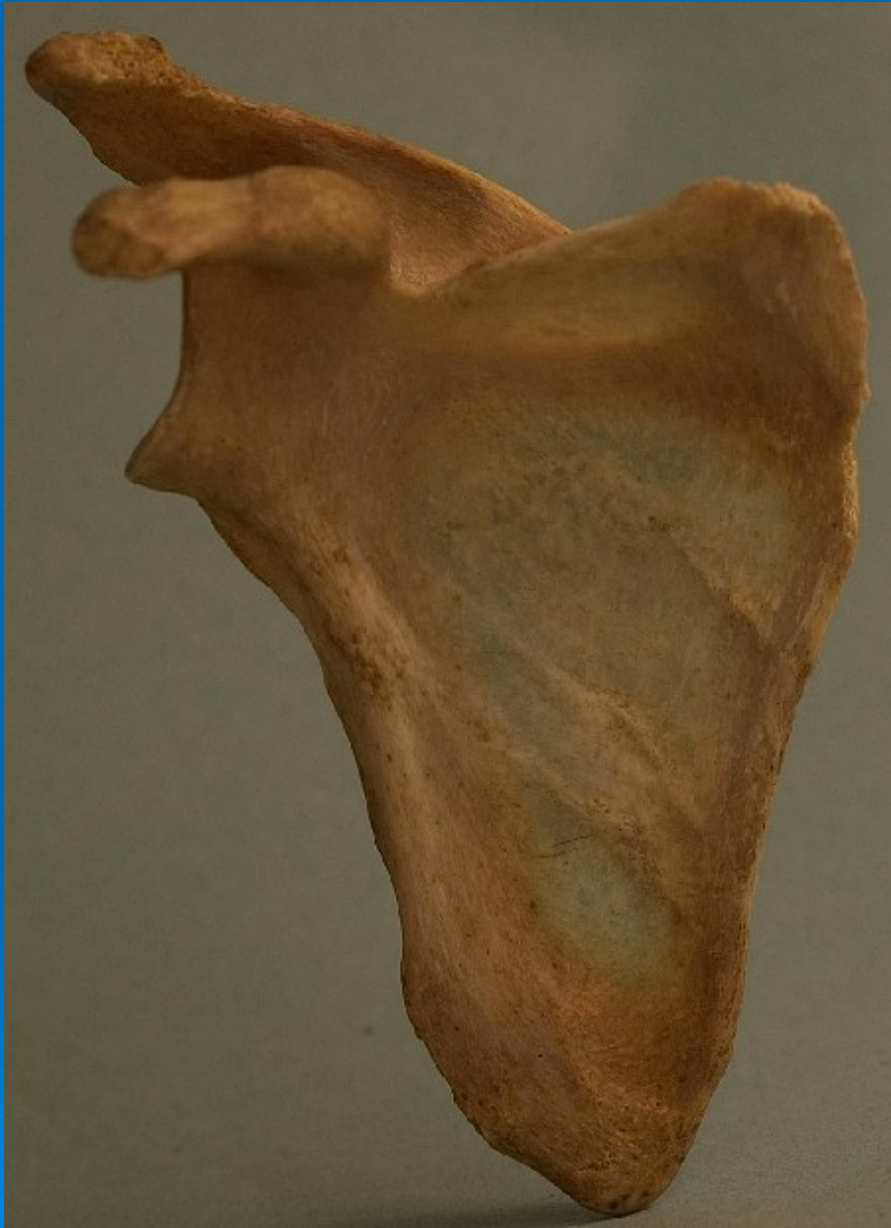- **Sternal extremity**



Scapula

A triangular bone, that lies on the posterolateral aspect of the thorax, overlying the 2nd – 7th ribs





- **borders**

- superior = suprascapular

- medial = vertebral

- lateral = axillary

- **sup. and inf. angle**

- **lateral angle**

- glenoid cavity

- supraglenoid tubercle

- infraglenoid tubercle

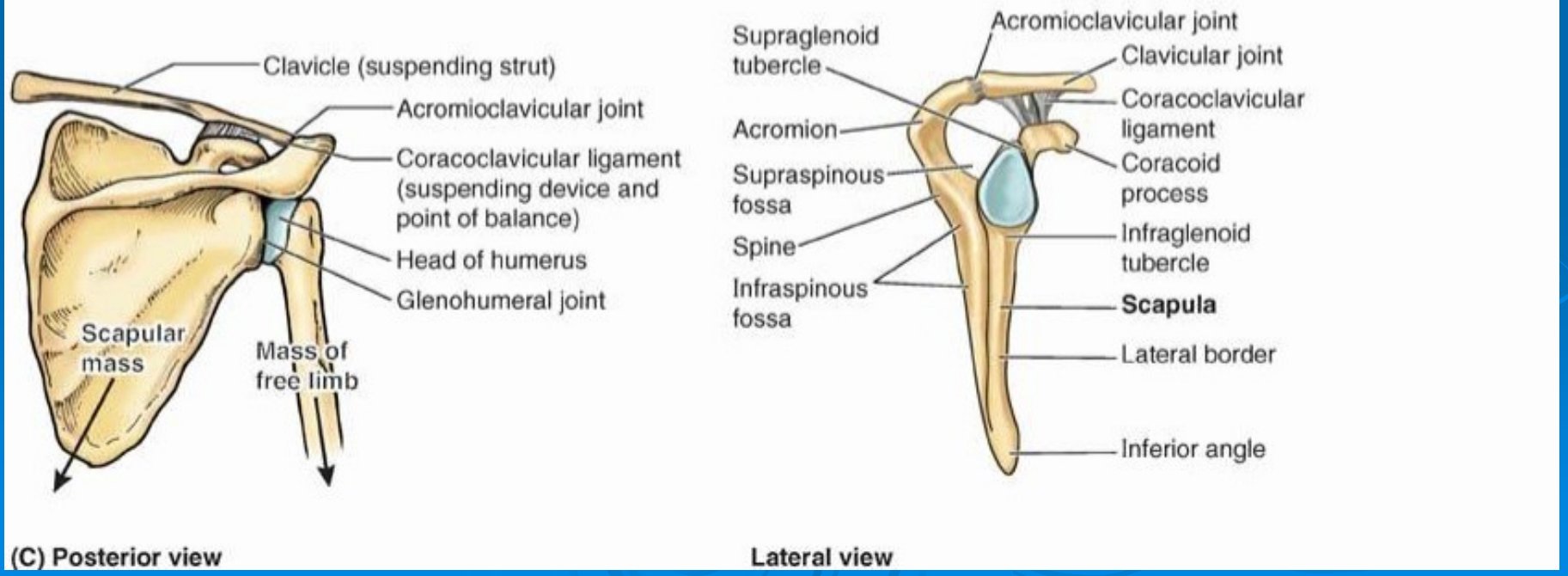
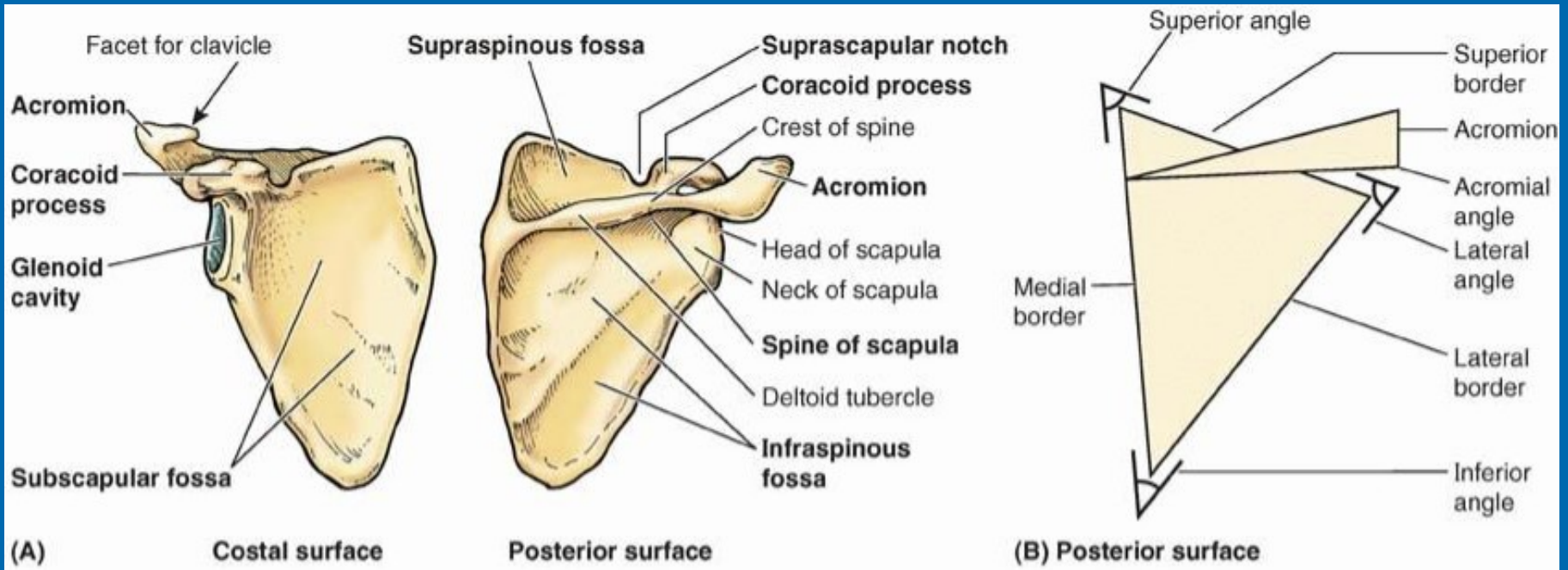
- neck of scapula

- coracoid process

- scapular notch



- **posterior surface**
 - spine of the scapula
 - supraspinous fossa
 - infraspinous fossa
- **anterior surface**
 - subscapular fossa
- **acromion**
 - acromial artic. facet



Humerus





- **Proximal epiphysis**

- head

- anatomical neck

- surgical neck

- greater tubercle

- lesser tubercle

- intertubercular groove

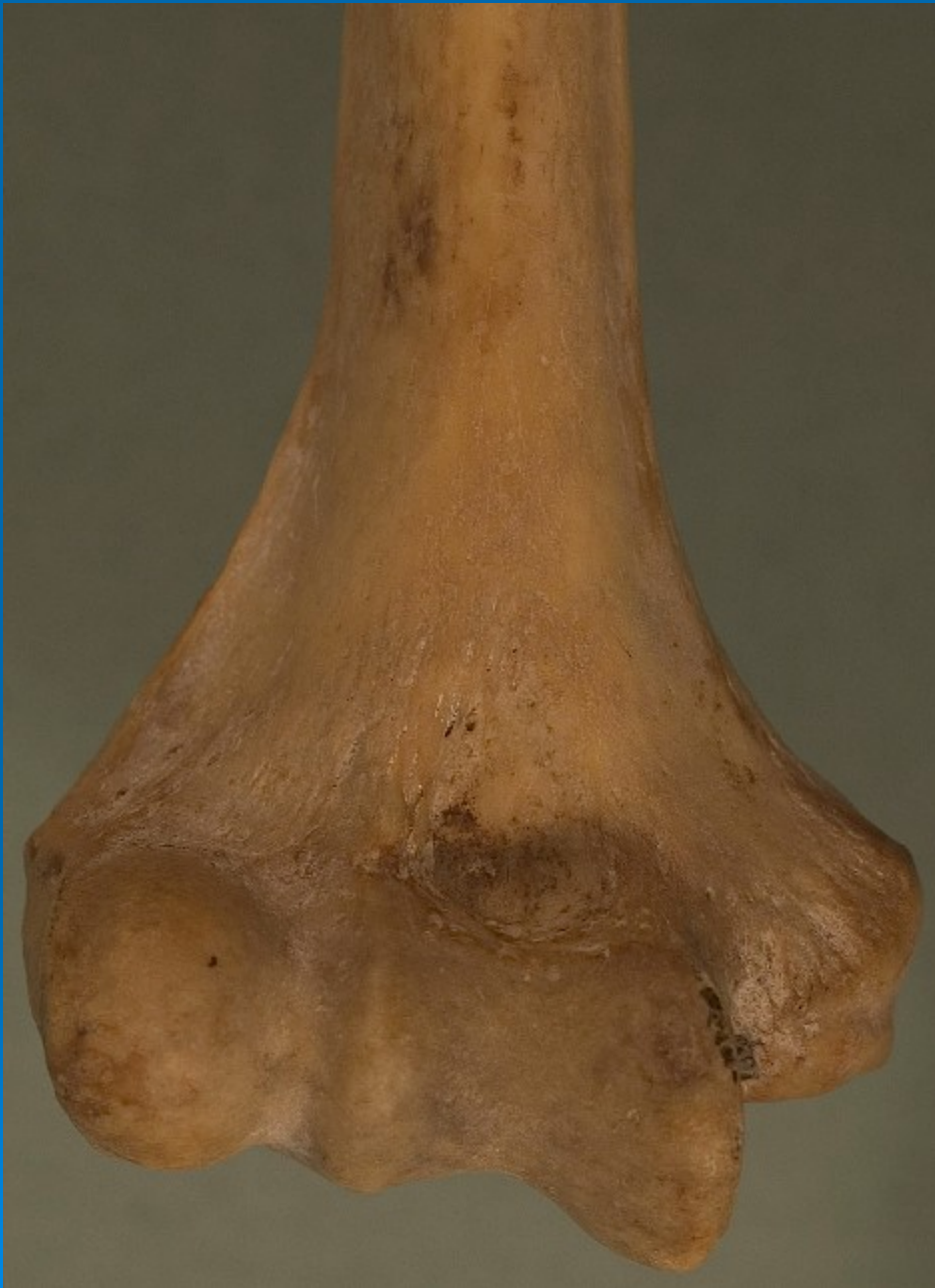- crest of lesser tubercle

- crest of greater tubercle

- **Diaphysis**

- deltoid tuberosity

- radial groove



- **Distal epiphysis**

- medial epicondyle

- trochlea

- coronoid fossa

- lateral epicondyle

- capitulum

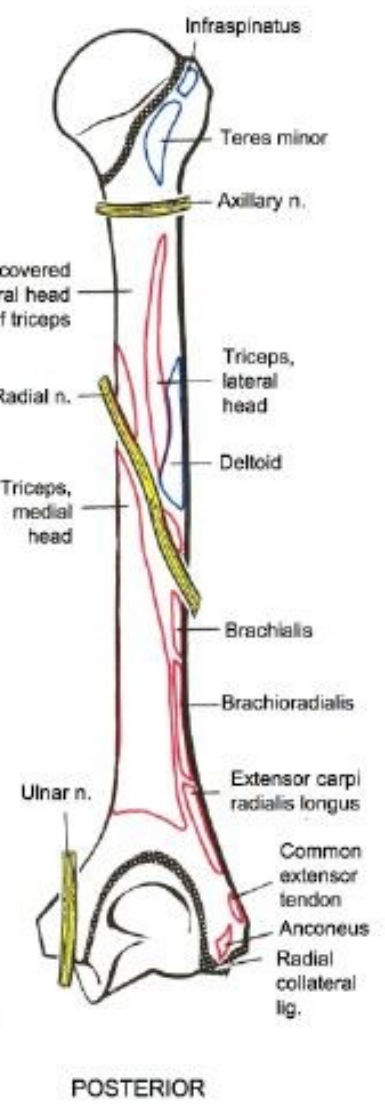
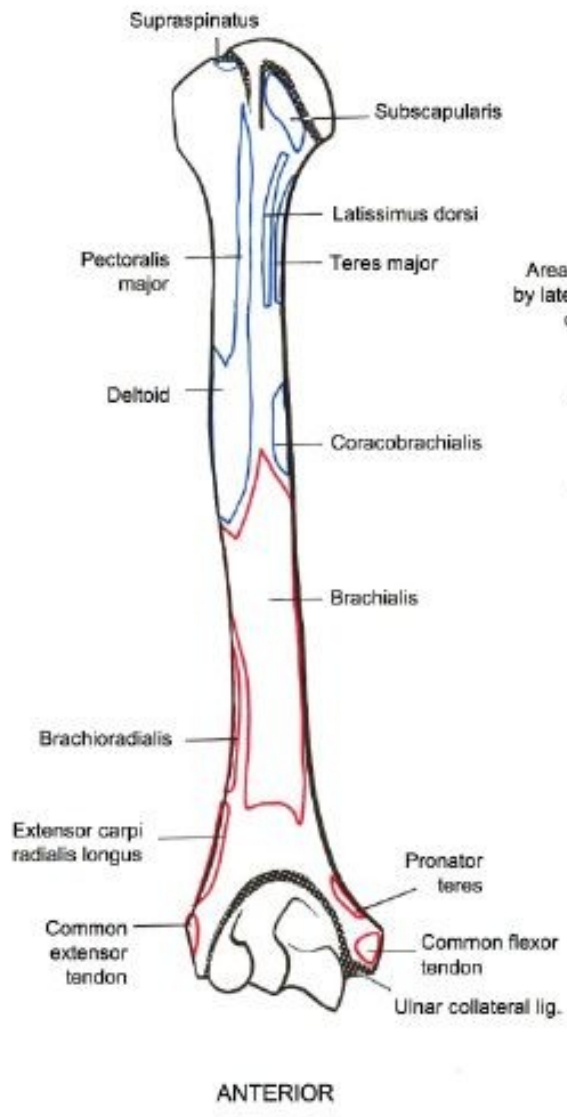
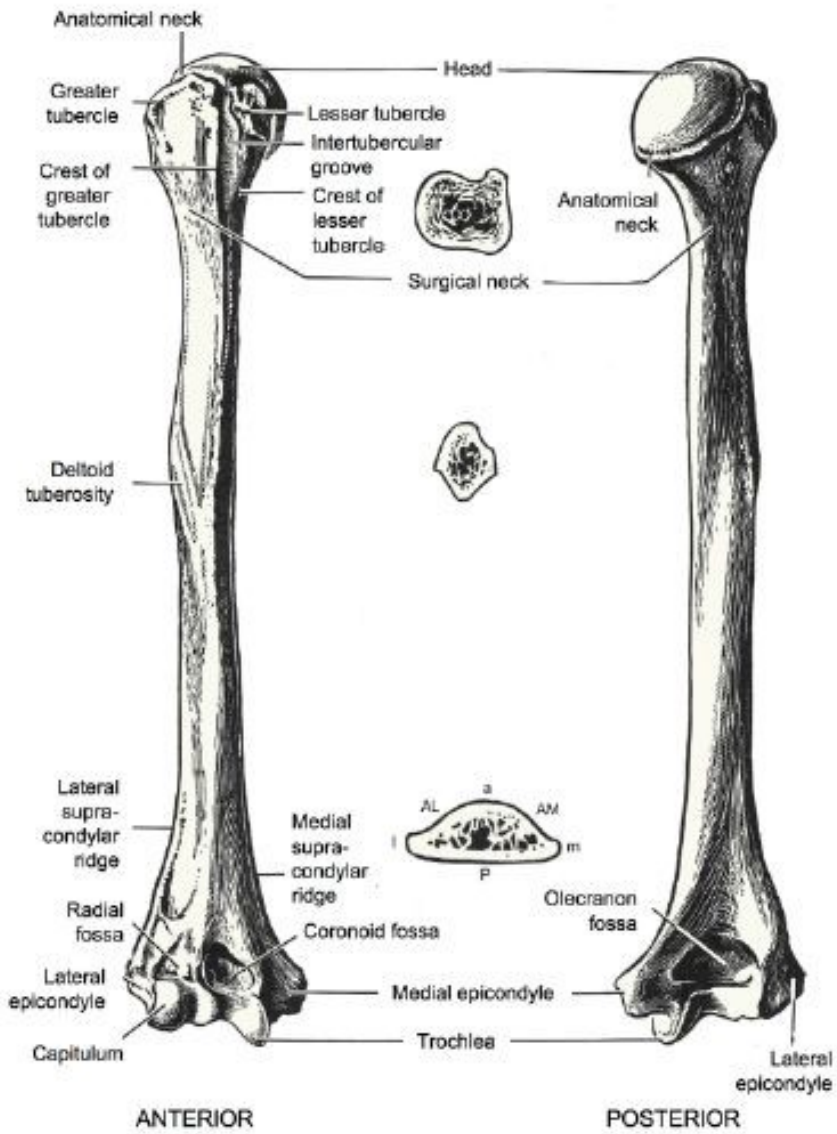
- radial fossa

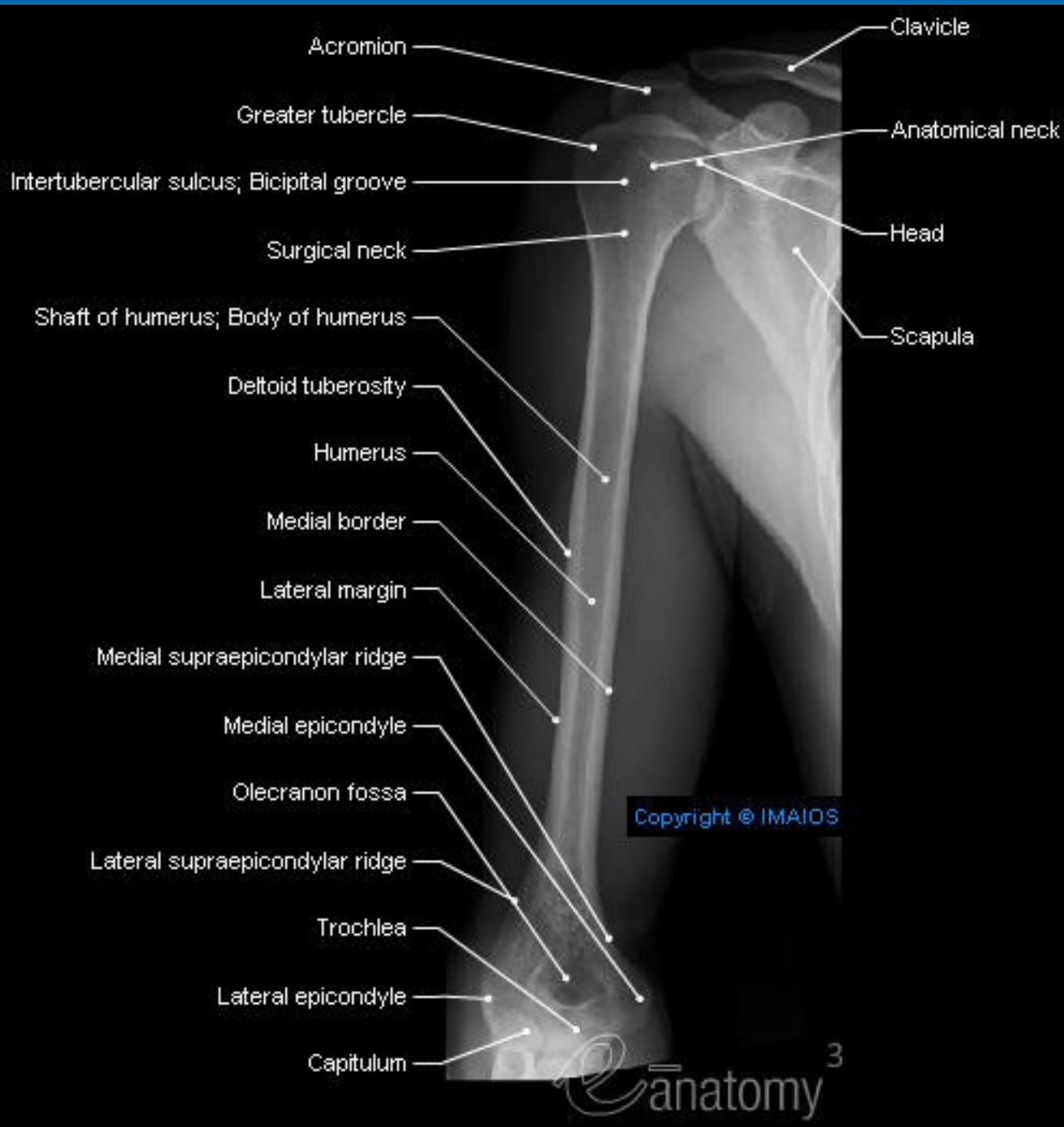
- olecranon fossa

- groove for ulnar nerve

- supracondylar ridge







Radius





- **Proximal epiphysis**

- head with articular fovea
 - neck of radius
 - radial tuberosity
 - articular circumference

- **Diaphysis**

- anterior border
 - posterior border
 - interosseous border
 - oblique line



- **Distal epiphysis**

- styloid process

- ulnar notch

- carpal articular surface

- dorsal tubercle

- 4 grooves for muscles

Ulna





- **Proximal epiphysis**

- olecranon

- coronoid process

- radial notch

- trochlear notch

- ulnar tuberosity

- **Diaphysis**

- anterior border

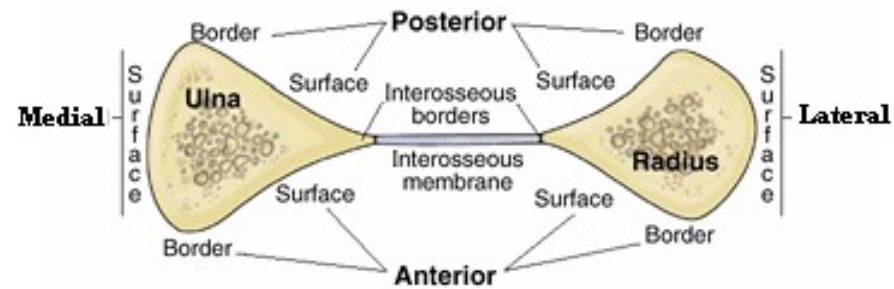
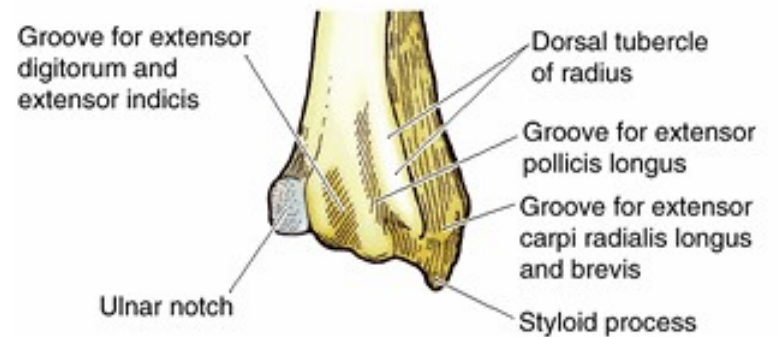
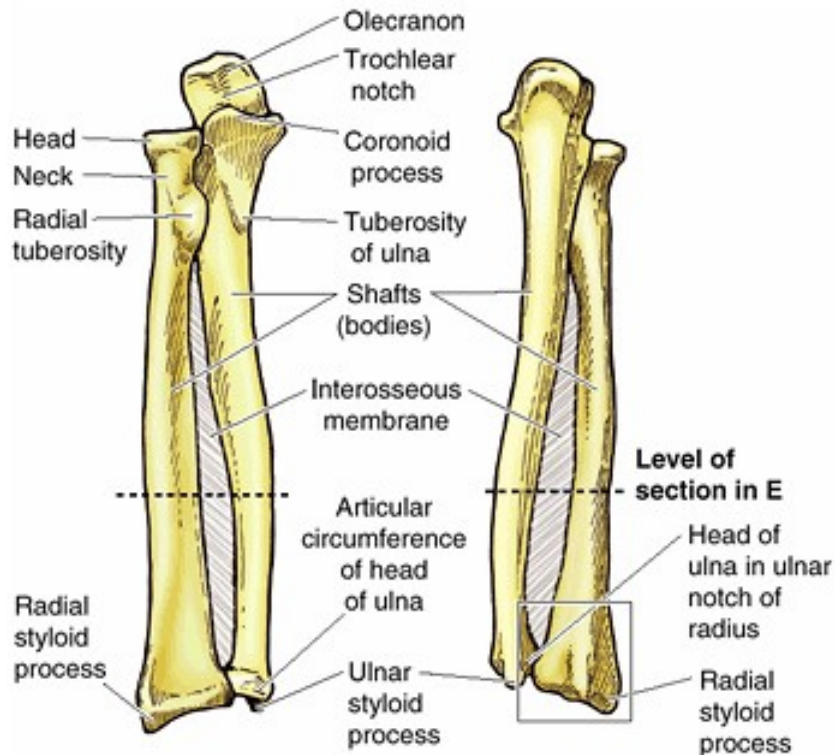
- posterior border

- interosseous border

- **Distal epiphysis**

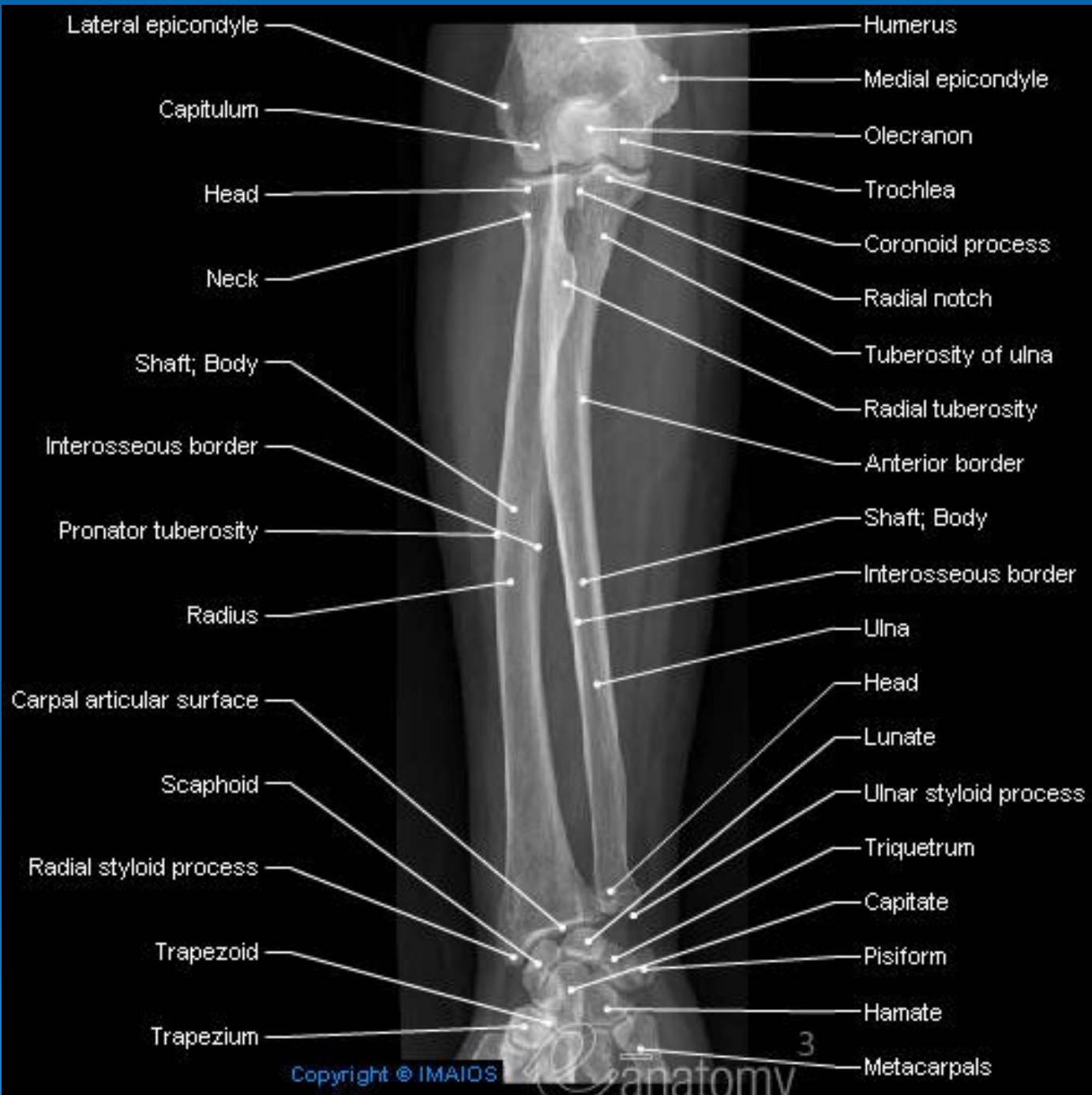
- articular circumference

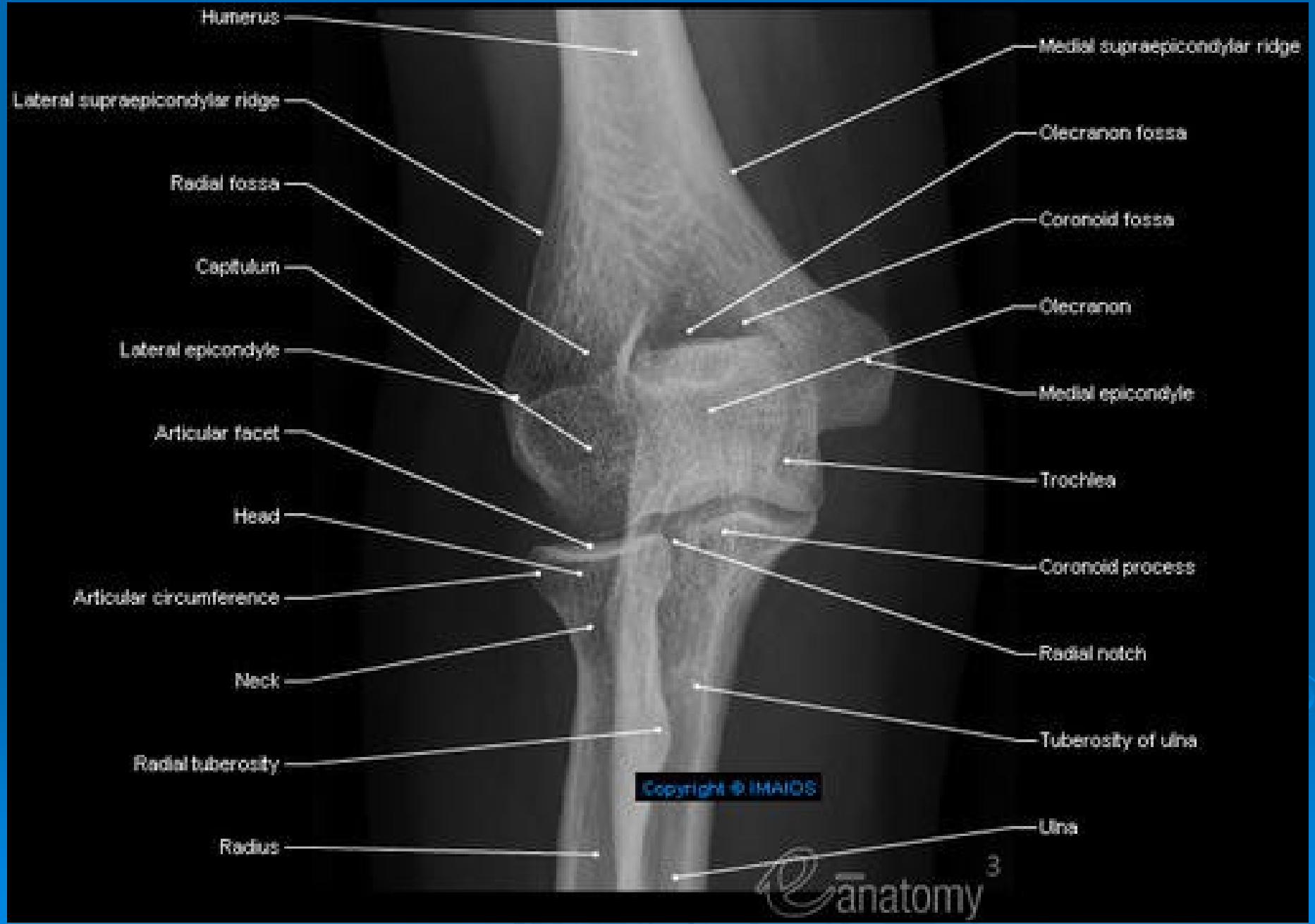- styloid process



(A) Anterior view

(B) Posterior view





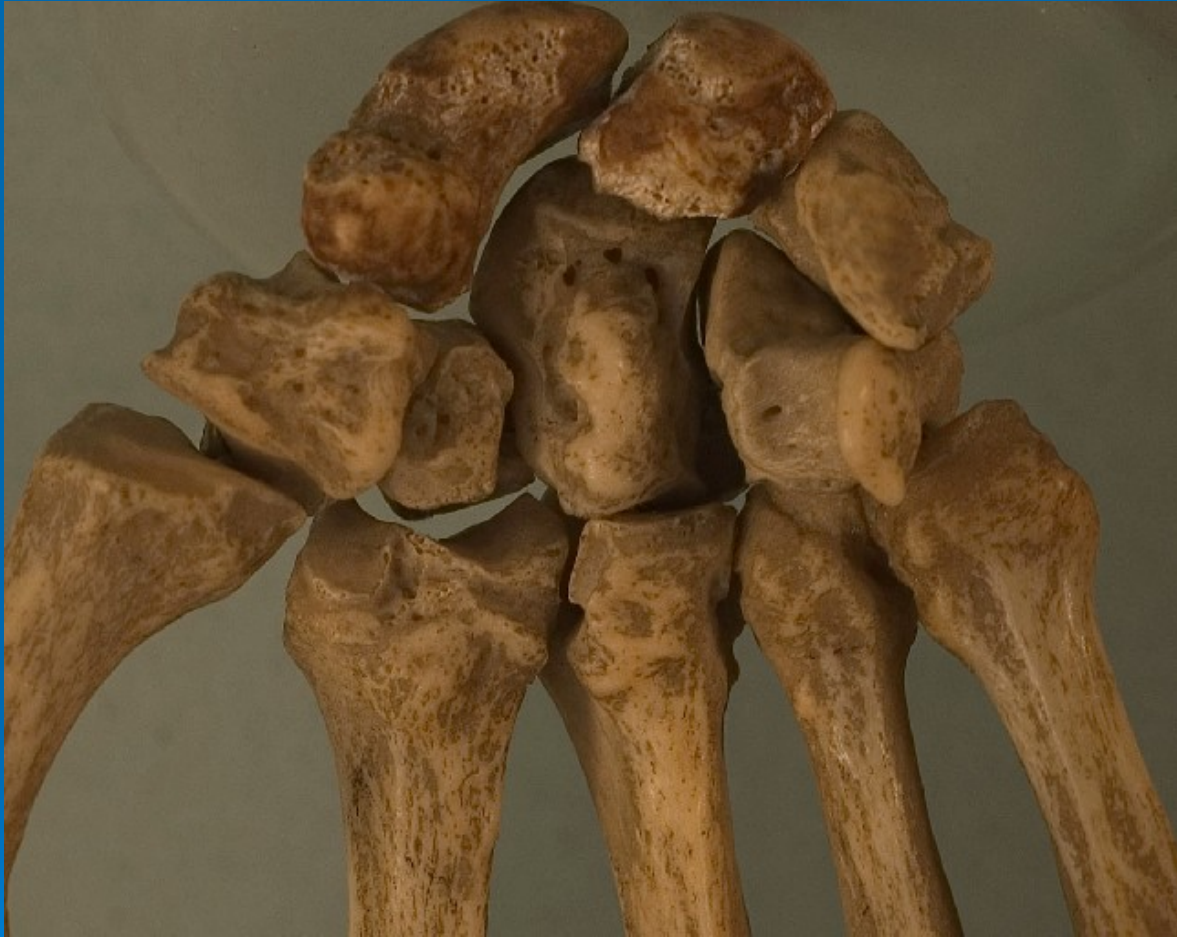Humerus
Lateral supraepicondylar ridge
Radial fossa
Capitulum
Lateral epicondyle
Articular facet
Head
Articular circumference
Neck
Radial tuberosity
Radius

Medial supraepicondylar ridge
Olecranon fossa
Coronoid fossa
Olecranon
Medial epicondyle
Trochlea
Coronoid process
Radial notch
Tuberosity of ulna
Ulna

Copyright © IMAIOS

Carpal bones, Metacarpals & Phalanges





- **Proximal row**

- scaphoid

- lunate

- triquetral

- pisiform

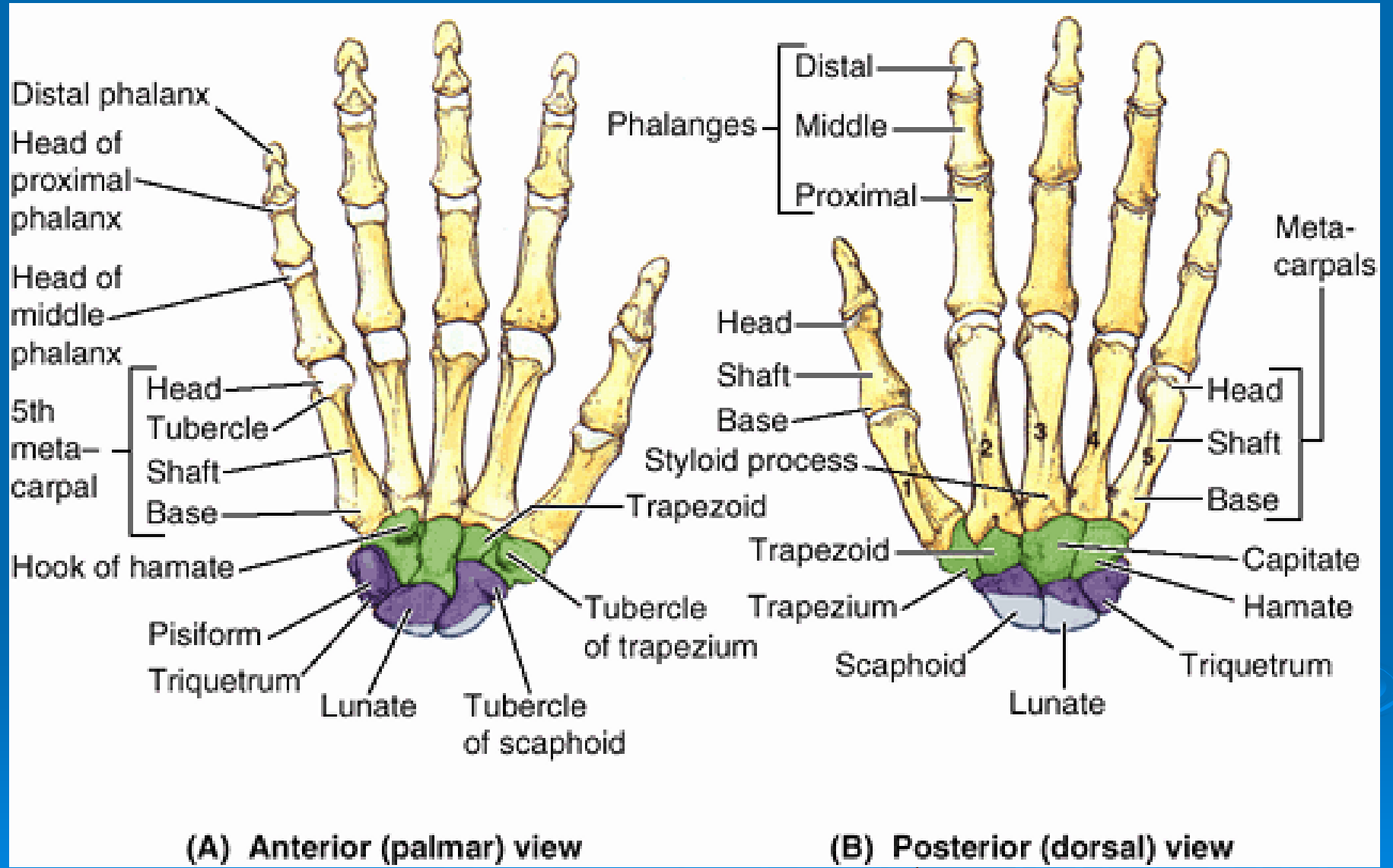
- **Diaphysis**

- trapezium

- trapezoid

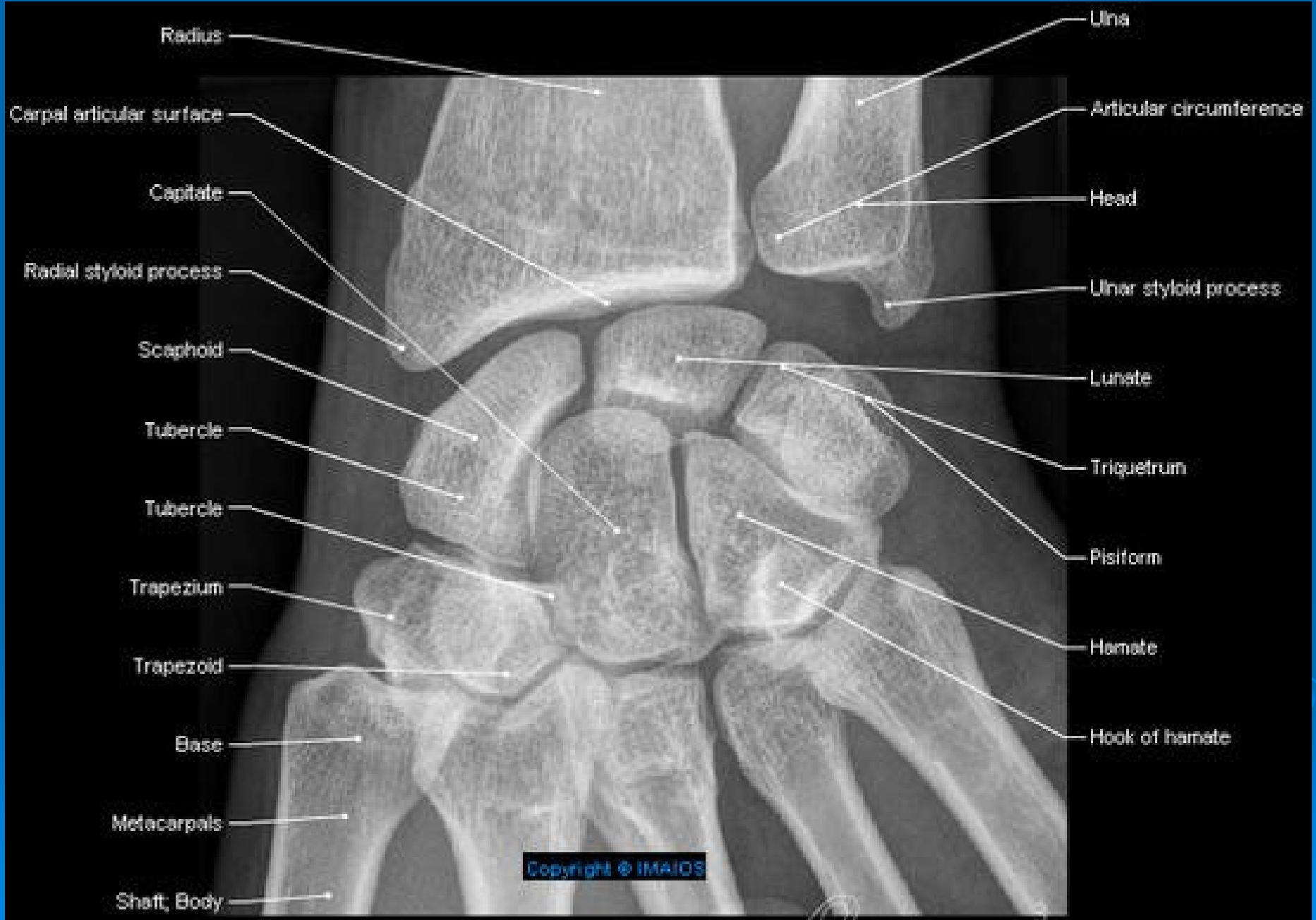
- capitate

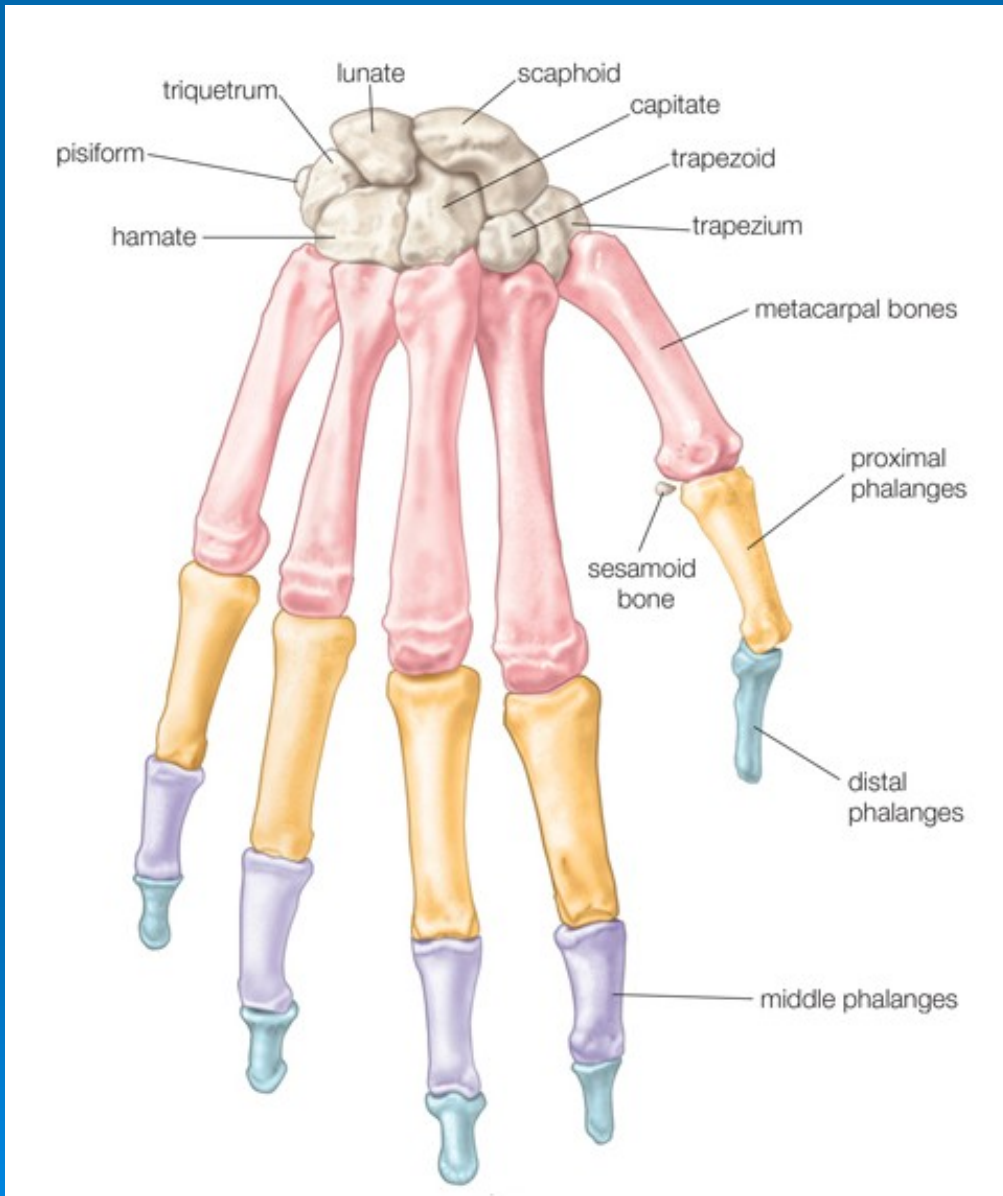
- hamate



(A) Anterior (palmar) view

(B) Posterior (dorsal) view





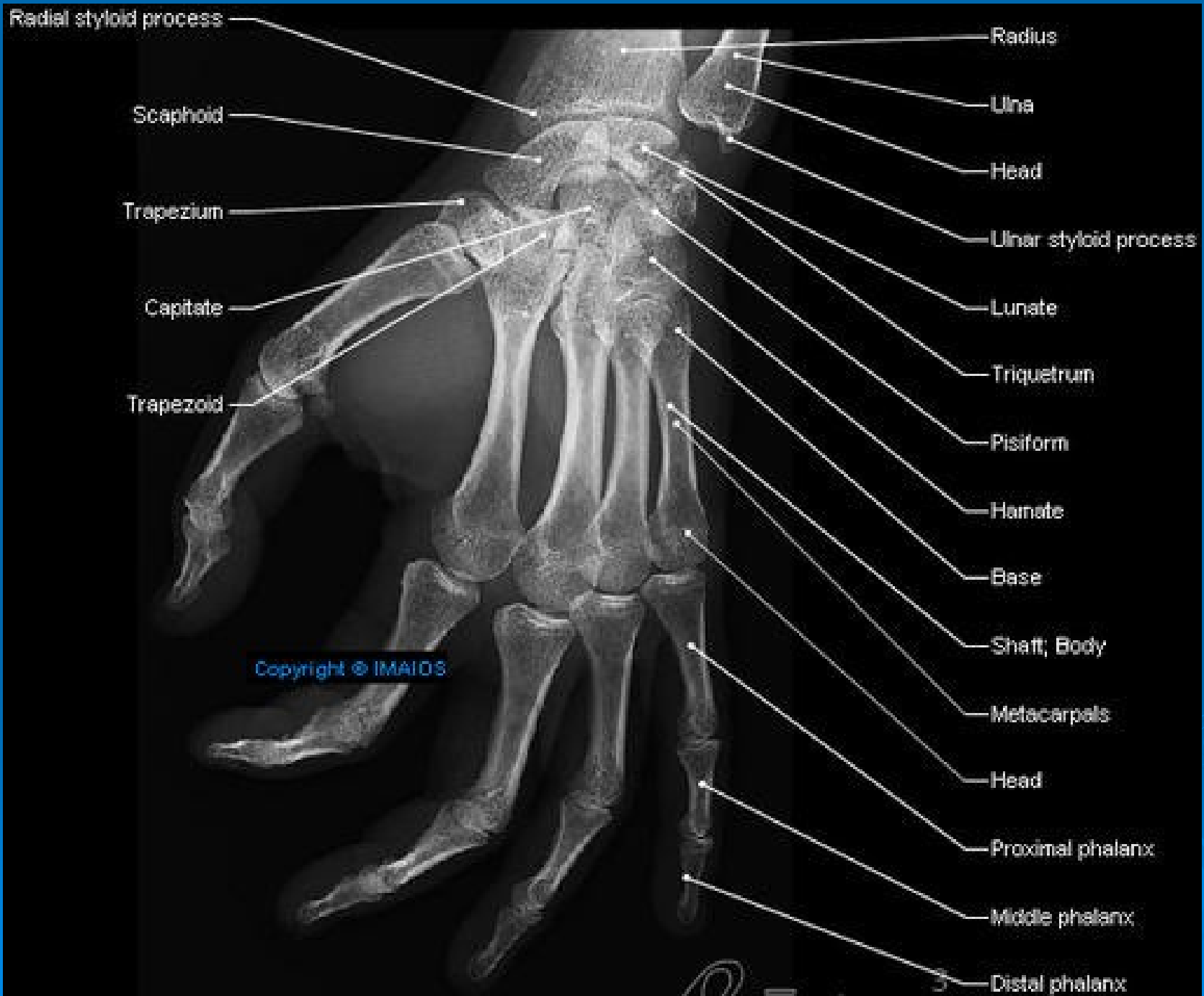
- **Metacarpals**

- **Phalanges**

proximal

middle (except thumb)

distal



Copyright © IMAIOS