

Joints and ligaments of the Thorax and the Back

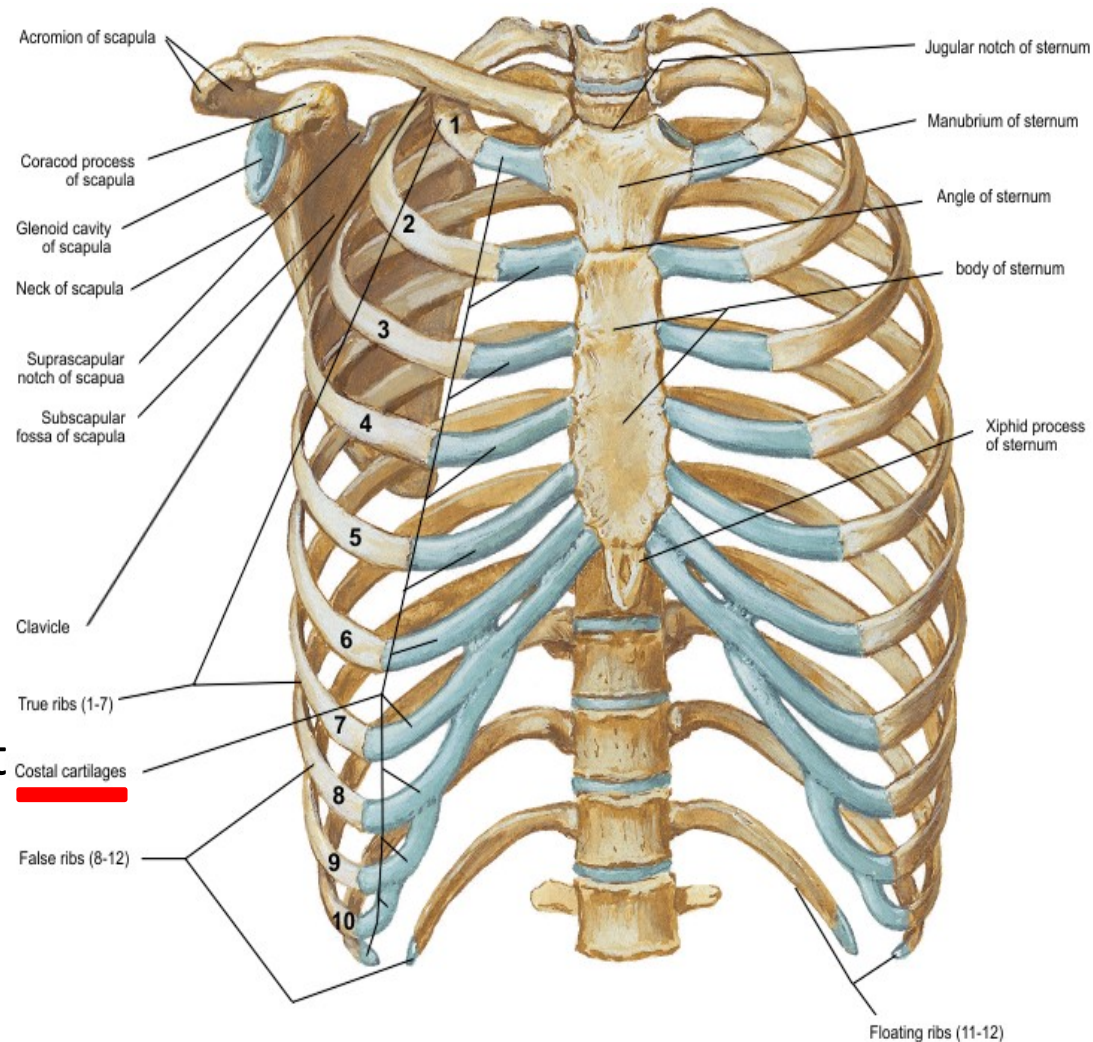
Stelios Valerkos

Joints and Ligaments of the Thorax

- Costal cartilage
- Radiate sternocostal ligaments
- Angle of sternum
- Sternocostal joint
- Xiphisternal joint

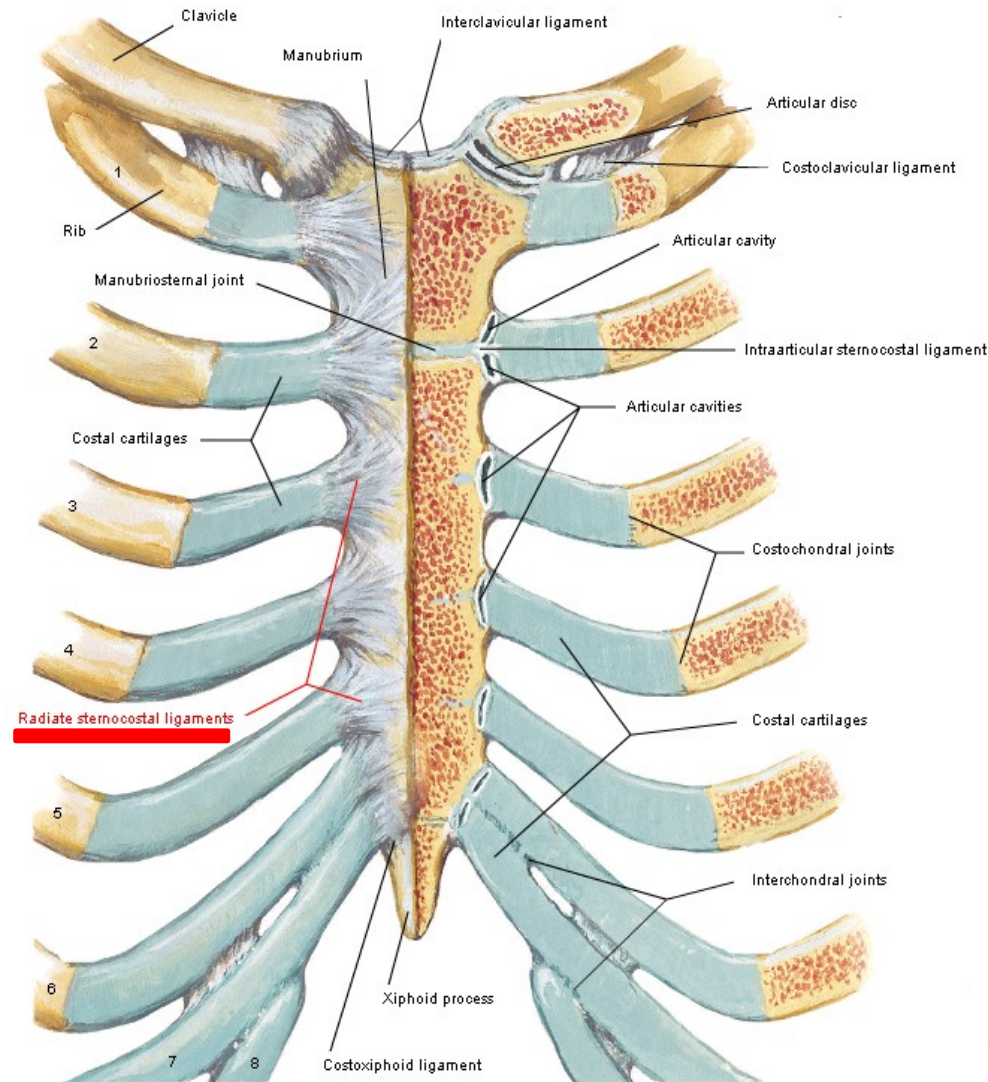
Costal cartilage

A bar of hyaline cartilage that attaches a rib to the sternum in the case of true ribs, or to the rib immediately above in the case of the upper false ribs. Costal cartilages of ribs 1-7 connect to the sternum; costal cartilages of ribs 8-10 connect to the costal cartilage of rib 7; costal cartilages of ribs 11 & 12 do not articulate anteriorly but end in the muscles of the abdominal wall



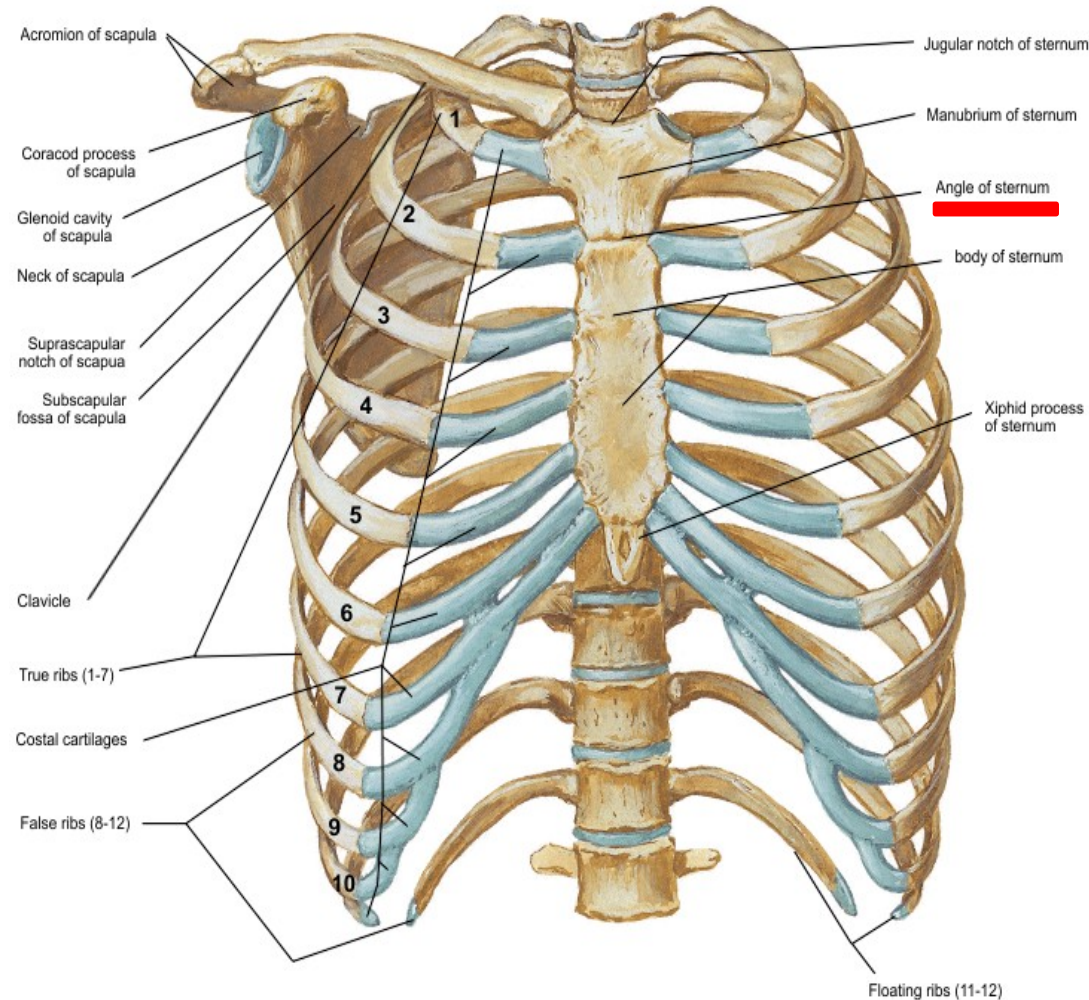
Radiate sternocostal ligaments

Fibrous bands that cross from the sternal end of the costal cartilage to the ventral part of the sternum. These ligaments connect the costal cartilages of ribs 1-7 with the sternum on both the anterior and posterior surfaces of the sternocostal articulation



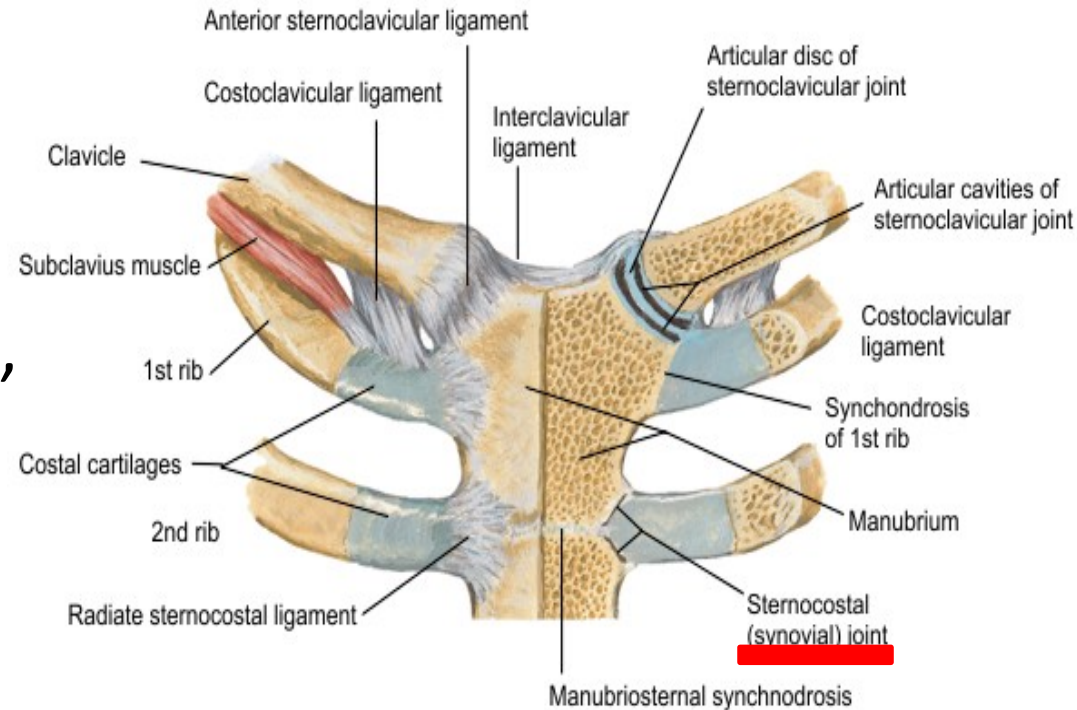
Angle of sternum

The angle formed by the articulation between the manubrium and the body of the sternum. The cartilage within this joint usually does not become ossified until old age; the angle formed by this articulation is also called the angle of Louis; the sternal angle marks the level of the second costal cartilage from which all other ribs are counted



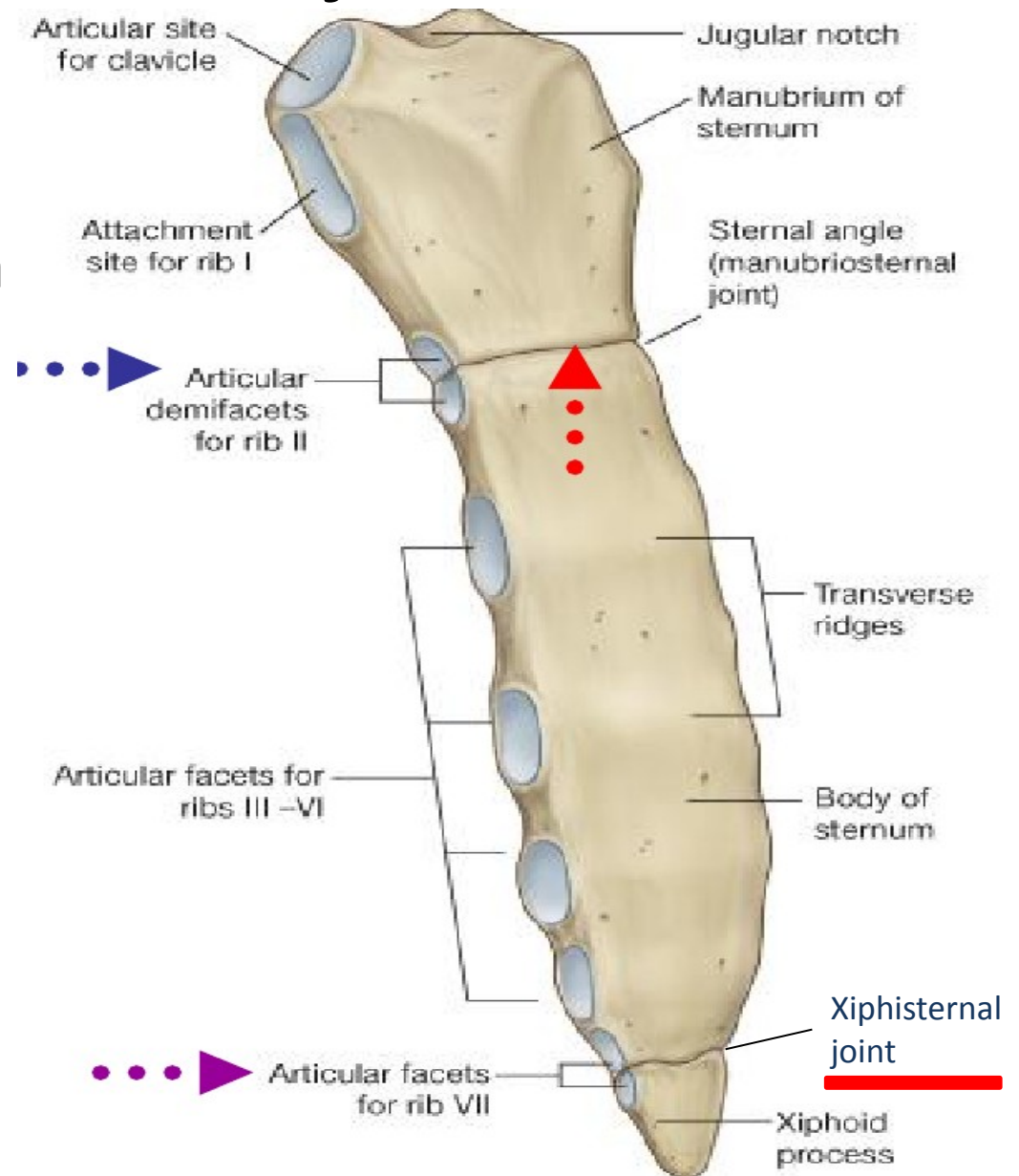
Sternocostal joint

The articulations that connect the costal Cartilages with the Sternum. The sternocotal joints are arthrodial joints, with the exception of the first, in which the cartilage is directly united with the sternum, and which is, therefore, a synarthrodial articulation.



Xiphisternal joint

located near the bottom of the sternum, this articulation connects the xiphoid process with the body of the sternum.



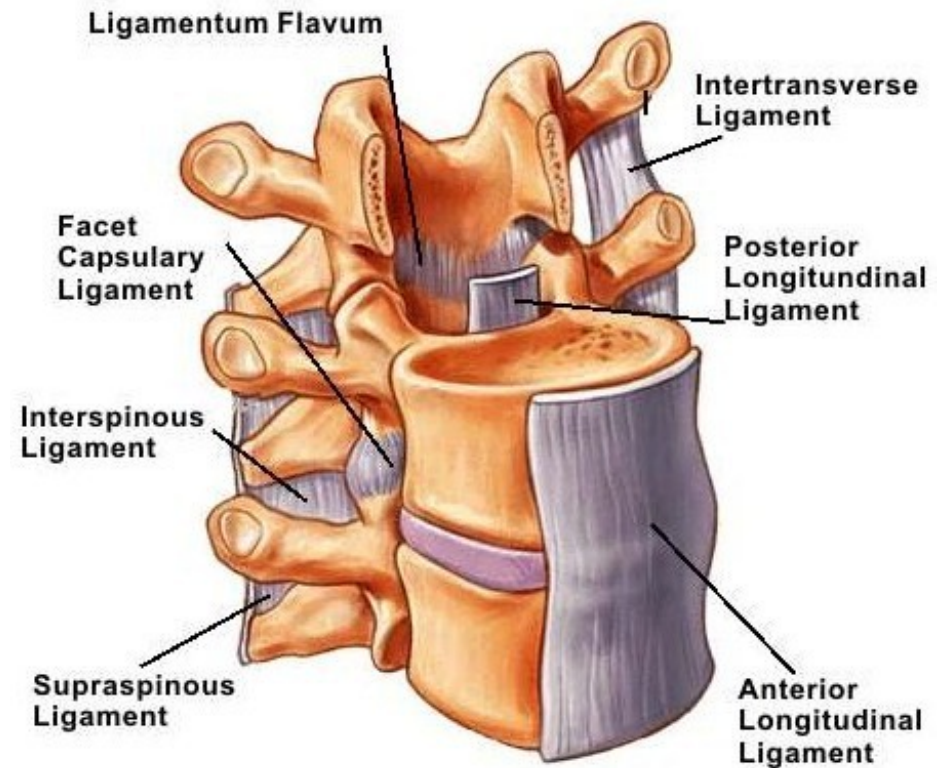
Joints and Ligaments of the Back

- Anterior longitudinal ligament
- Interspinous ligaments
- Intervertebral disks
- Ligamenta flava
- Nuchal ligament
- Posterior longitudinal ligament
- Supraspinous ligaments
- Zygapophyseal joint

Anterior longitudinal ligament

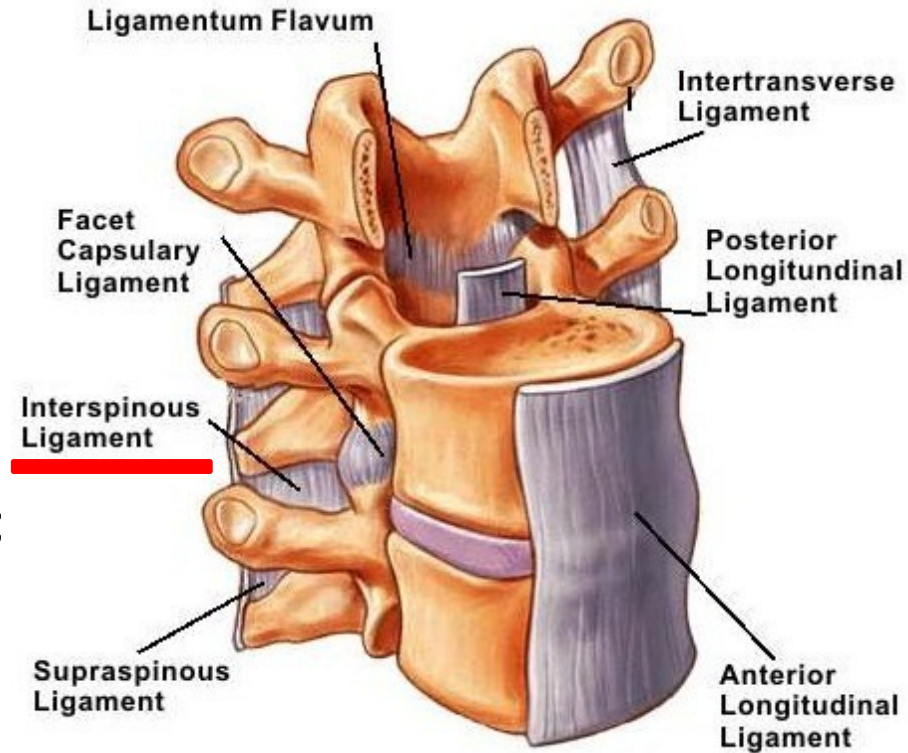
A ligament that runs down the anterior surface of the spine. It traverses all of the vertebral bodies and intervertebral discs.

It lies directly posterior to the thoracic and abdominal viscera. Detailed information about the spine can be found [here](#).



Interspinous ligaments

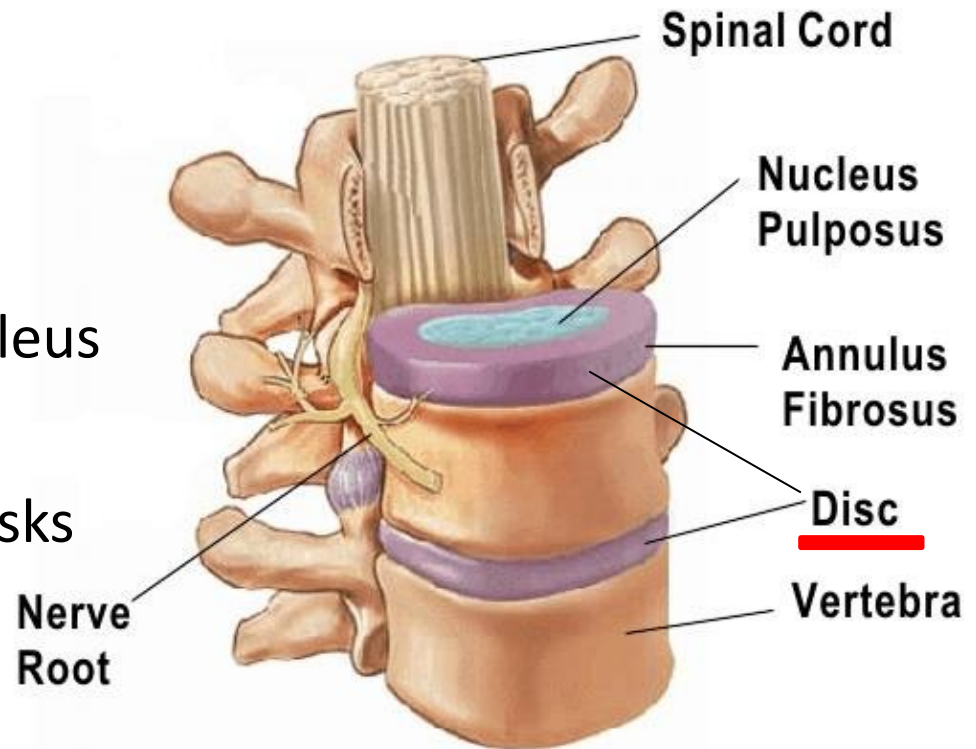
Also known as the interspinal ligaments, they connect the spinous processes of two adjacent vertebra; They meet the ligamenta flava in front and the supraspinal ligament behind. They are narrow and elongated in the thoracic region; broader, thicker, and quadrilateral in form in the lumbar region; and only slightly developed in the neck



Intervertebral disks

A fibrocartilaginous disk between adjacent vertebral bodies.

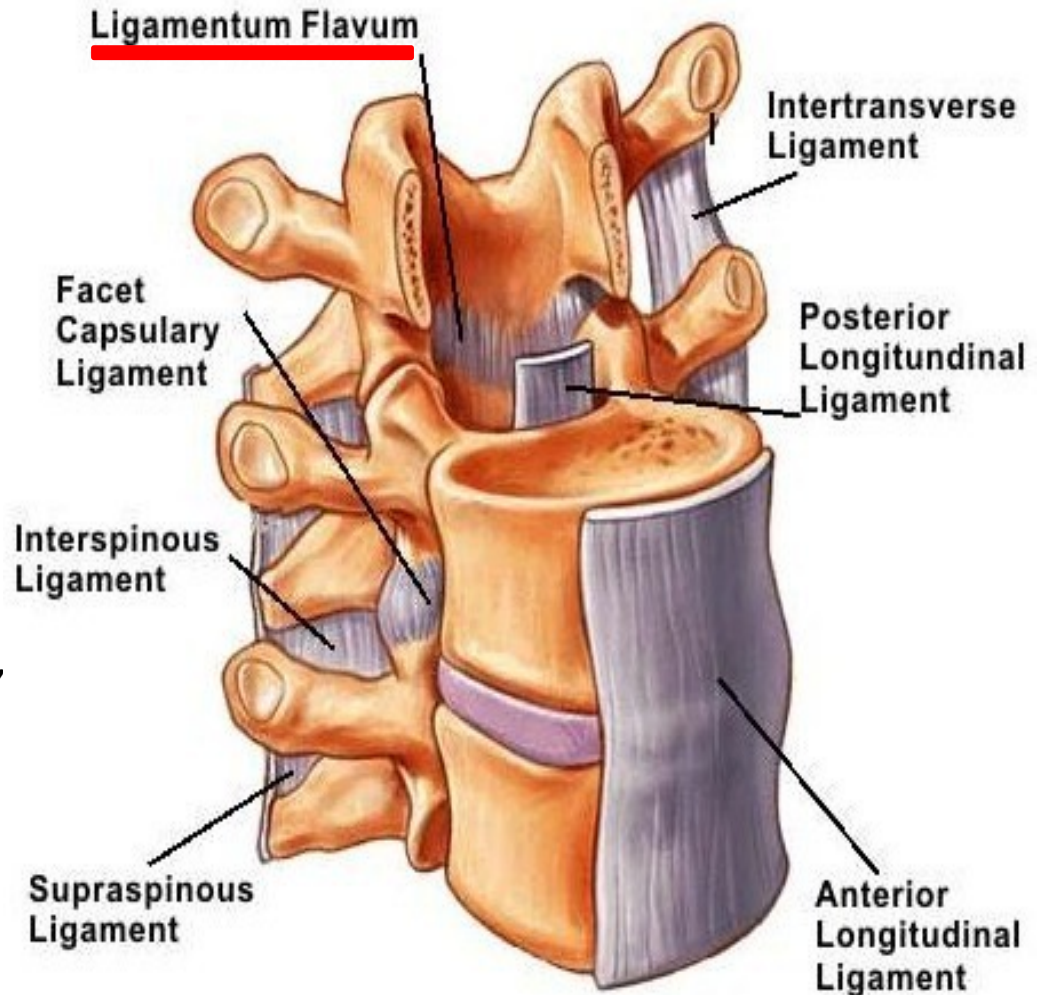
it is composed of two parts: an outer anulus fibrosus and an inner nucleus pulposus; the nucleus pulposus is the remnant of the notochord; the intervertebral disks are important shock absorbers between vertebrae. Detailed information about the intervertebral disc can be found [here](#).



Ligamenta flava

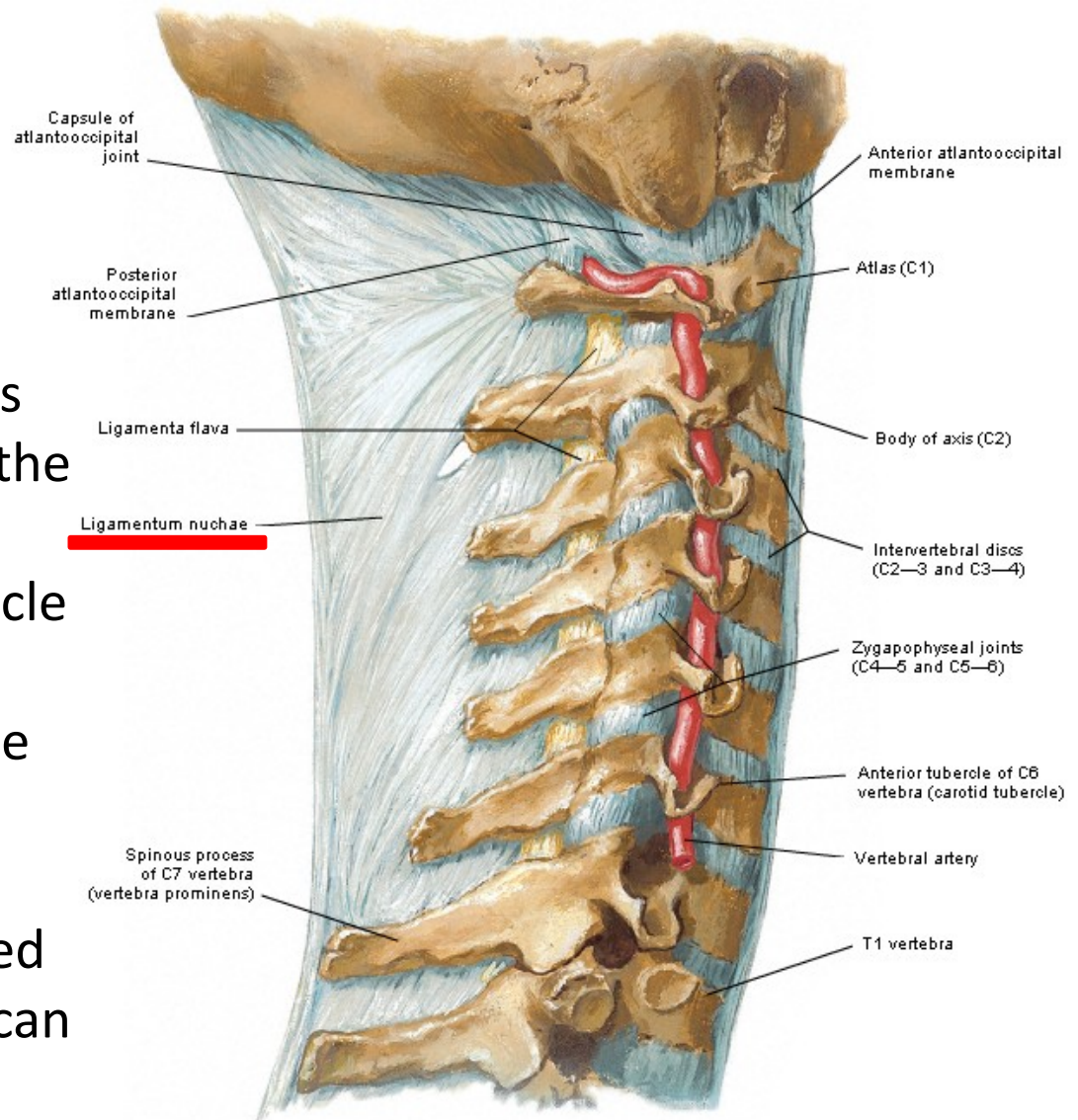
They connect the laminae of adjacent vertebrae, all the way from the axis to the first segment of the sacrum (C2 to S1). They are best seen from the interior of the vertebral canal; when looked at from the outer surface they appear short, being overlapped by the laminae.

The ligamentum flavum is penetrated by the needle during spinal tap; the word flavum is derived from the Latin word flavus, which means "yellow" a reference to the predominance of yellow elastic fibers which gives this ligament its grossly visible color.



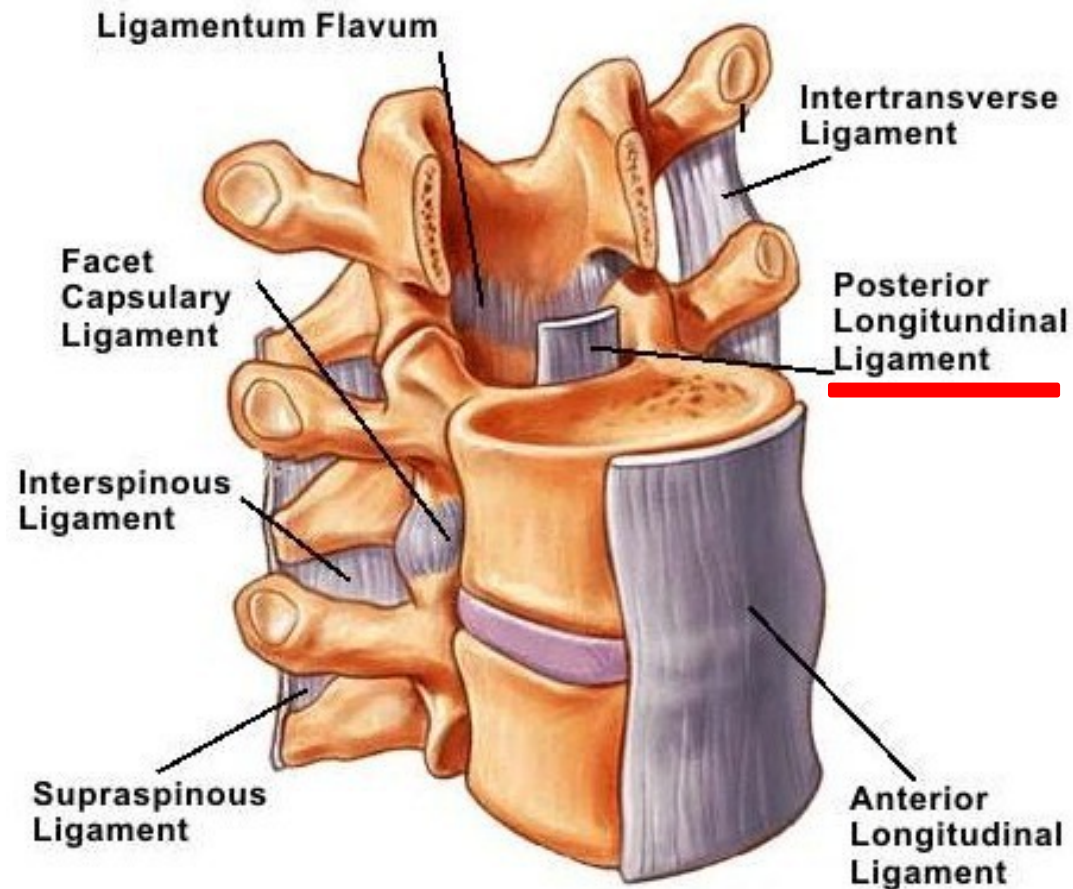
Nuchal ligament

Also known as the paxwax ligament, this is a midline ligament that extends posteriorly from the spinous processes of cervical vertebrae and extends from the base of the skull to the 7th cervical vertebra syndesmosis; it provides muscle attachments to the cervical spinous processes without the necessity of long spinous processes that would hinder extension of the neck. Detailed information about the spine can be found [here](#).



Posterior longitudinal ligament

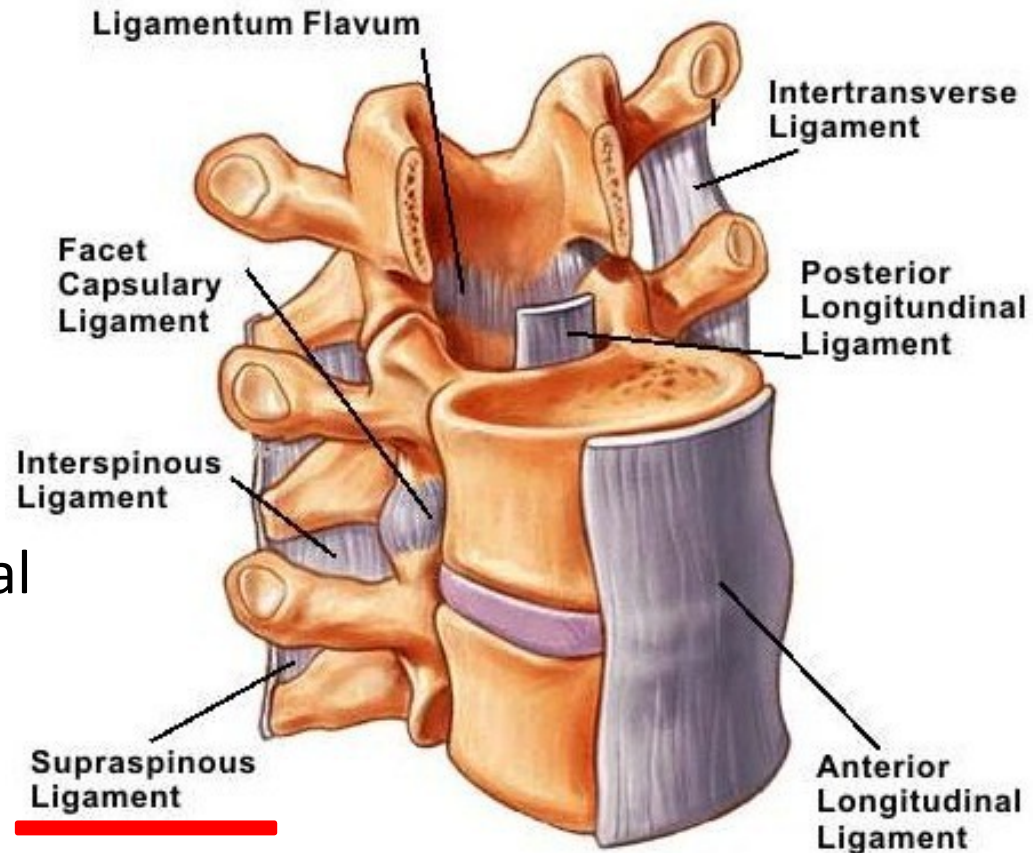
A ligament that is situated within the vertebral canal and courses from superior to inferior along the posterior surfaces of all vertebral bodies; it is broader above than below, and thicker than in the cervical and lumbar regions.



supraspinous ligaments

They are strong fibrous cords that connect the tips of the Spinous processes of thoracic and lumbar vertebrae

The supraspinous ligament begins at the C7 vertebra and ends at the mid-sacral segmental level; it serves as a muscle attachment site; between the spinous processes it is continuous with the interspinous ligaments.



Zygapophyseal joint

They are located between the superior articular process of one vertebra and the inferior articular process of the vertebra directly above it. There are two facet joints in each spinal motion segment.

